

Wills Eye Resident Series: A woman presents with eyelid droop and diplopia, p. 64

# REVIEW<sup>®</sup> *of* OPHTHALMOLOGY

March 2024 • [reviewofophthalmology.com](http://reviewofophthalmology.com)

Clinical advice you can trust

## REFRACTIVE/CATARACT RUNDOWN

Employing MSICS and miLoop  
PAGE 20

## TECHNOLOGY UPDATE

Augmented Reality and VR in Low Vision  
PAGE 50

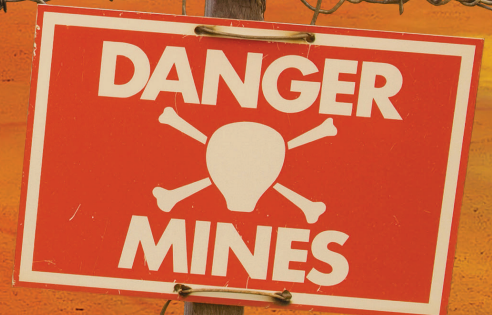## GLAUCOMA MANAGEMENT

Systemic Factors in Glaucoma  
PAGE 58

## The HIDDEN DANGERS Of the Retina

*Experts outline their approaches to examining the retina before cataract and refractive surgery. P. 27*

- Survey: Cataract Surgeons Discuss Their Preferred Techniques P. 33
- A Look at the New Triple Procedure P. 38
- Current Approaches to Retinal Detachment Repair P. 44







# Plus is Near.

Everything you love about  
adjustability. Plus more.

Light  
Adjustable  
Lens™

Light  
Adjustable  
Lens +™



**Be there when LAL+ is here.**

Celebrate with us at booth #516! Visit [RxSight.com/plus-is-near](https://RxSight.com/plus-is-near) for speaker schedules, LDD demo sign-ups, event updates, and exciting LAL+ announcements!



# REVIEW of OPHTHALMOLOGY

Clinical advice you can trust

## CONTRIBUTORS

**CHIEF MEDICAL EDITOR**  
Mark H. Blecher, MD

**CONTACT LENSES**  
Penny Asbell, MD

**CORNEA / ANTERIOR SEGMENT**  
Thomas John, MD

**GLAUCOMA MANAGEMENT**  
Peter Netland, MD, PHD  
Kuldev Singh, MD

**MEDICARE Q & A**  
Mary Pat Johnson,  
COMT, CPC

**PEDIATRIC PATIENT**  
Janine Collinge, MD

**PLASTIC POINTERS**  
April Lao, MD

**REFRACTIVE SURGERY**  
Arturo S. Chayet, MD

**RETINAL INSIDER**  
Carl Regillo, MD, FACS  
Yoshihiro Yonekawa, MD

**TECHNOLOGY UPDATE**  
Steven T. Charles, MD  
Michael Colvard, MD

**WILLS RESIDENT CASE SERIES**  
Bonnie Sklar, MD

## ADVISORY BOARD

**PENNY A. ASBELL, MD**, MEMPHIS, TENN.  
**BRANDON AYRES, MD**, PHILADELPHIA  
**SURENDRA BASTI, MD**, CHICAGO  
**WILLIAM I. BOND, MD**, PEKIN, ILL.  
**ALAN N. CARLSON, MD**, DURHAM, N.C.  
**Y. RALPH CHU, MD**, EDINA, MINN.  
**ADAM J. COHEN, MD**, CHICAGO  
**JANINE COLLINGE, MD**, FARMINGTON, CONN.  
**UDAY DEVGAN, MD, FACS**, LOS ANGELES  
**ERIC DONNENFELD, MD**, ROCKVILLE CENTRE, N.Y.  
**DANIEL S. DURRIE, MD**, KANSAS CITY, MO.  
**ROBERT EPSTEIN, MD**, MCHENRY, ILL.  
**ROBERT D. FECHTNER, MD**, NEWARK, N.J.  
**BRIAN FRANCIS, MD**, Los Angeles  
**JAMES P. GILLS, MD**, TARPON SPRINGS, FLA.  
**HARRY GRABOW, MD**, SARASOTA, FLA.  
**DOUGLAS K. GRAYSON, MD**, NEW YORK CITY  
**DAVID R. HARDTEN, MD**, MINNEAPOLIS  
**SARA J. HAUG, MD, PHD**, DURANGO, COLO.

**KENNETH J. HOFFER, MD**, SANTA MONICA, CALIF.  
**JACK T. HOLLADAY, MD, MSEE**, HOUSTON  
**JOHN D. HUNKELER, MD**, KANSAS CITY, MO.  
**THOMAS JOHN, MD**, TINLEY PARK, ILL.  
**ROBERT M. KERSHNER, MD, MS**, PALM BEACH GARDENS, FLA.  
**GUY M. KEZIRIAN, MD**, PARADISE VALLEY, ARIZ.  
**SUMITRA KHANDELWAL, MD**, HOUSTON  
**TERRY KIM, MD**, DURHAM, N.C.  
**BRAD KLIGMAN, MD**, MANHASSET, N.Y.  
**TOMMY KORN, MD**, SAN DIEGO  
**APRIL LAO, MD**, MEMPHIS  
**DAVID A. LEE, MD**, HOUSTON  
**FRANCIS S. MAH, MD**, LA JOLLA, CALIF.  
**NICK MAMALIS, MD**, SALT LAKE CITY  
**EDWARD MANCHE, MD**, PALO ALTO, CALIF.  
**MIKE S. MCFARLAND, MD**, PINE BLUFF, ARK.  
**JEFFREY B. MORRIS, MD, MPH**, ENCINITAS, CALIF.  
**KEVIN MILLER, MD**, LOS ANGELES  
**MAJID MOSHIRFAR, MD**, DRAPER, UTAH

**MARLENE R. MOSTER, MD**, PHILADELPHIA  
**ROBERT J. NOECKER, MD**, FAIRFIELD, CONN.  
**ROBERT OSHER, MD**, CINCINNATI  
**MARK PACKER, MD**, WEST PALM BEACH, FLA.  
**CHRISTOPHER J. RAPUANO, MD**, PHILADELPHIA  
**AUGUST READER III, MD**, SAN FRANCISCO  
**TONY REALINI, MD, MPH**, MORGANTOWN, W.V.  
**KENNETH J. ROSENTHAL, MD**, GREAT NECK, N.Y.  
**ERIC ROTHCHILD, MD**, DELRAY BEACH, FLA.  
**SHERI ROWEN, MD**, BALTIMORE  
**INGRID U. SCOTT, MD, MPH**, HERSHEY, PA.  
**JOEL SCHUMAN, MD**, PITTSBURGH  
**GAURAV SHAH, MD**, ST. LOUIS  
**DAVID R. STAGER JR., MD**, DALLAS  
**KARL STONECIPHER, MD**, GREENSBORO, N.C.  
**JAMES C. TSAI, MD**, NEW YORK CITY  
**VANCE THOMPSON, MD**, SIOUX FALLS, S.D.  
**FARRELL C. TYSON, MD**, CAPE CORAL, FLA.  
**R. BRUCE WALLACE III, MD**, ALEXANDRIA, LA.

Light  
Adjustable  
Lens™

### INDICATIONS FOR USE AND IMPORTANT SAFETY INFORMATION

**INDICATIONS:** The Light Adjustable Lens™ and Light Delivery Device™ system is indicated for the reduction of residual astigmatism to improve uncorrected visual acuity after removal of the cataractous natural lens by phacoemulsification and implantation of the intraocular lens in the capsular bag in adult patients with preexisting corneal astigmatism of  $\geq 0.75$  diopters and without preexisting macular disease. The system also reduces the likelihood of clinically significant residual spherical refractive errors.

### IMPORTANT SAFETY INFORMATION

**CONTRAINDICATIONS:** The Light Adjustable Lens is contraindicated in patients who are taking systemic medication that may increase sensitivity to ultraviolet (UV) light as the Light Delivery Device (LDD)™ treatment may lead to irreversible phototoxic damage to the eye; patients who are taking a systemic medication that is considered toxic to the retina (e.g., tamoxifen) as they may be at increased risk of retinal damage during LDD treatment; patients with a history of ocular herpes simplex virus due to the potential for reactivation from exposure to UV light; patients with nystagmus as they may not be able to maintain steady fixation during LDD treatment; and patients who are unwilling to comply with the postoperative regimen for adjustment and lock-in treatments and wearing of UV protective eyewear. **WARNINGS:** Careful preoperative evaluation and sound clinical judgment should be used by the surgeon to decide the risk/benefit ratio before implanting an IOL in a patient with any of the conditions described in the Light Adjustable Lens and LDD Professional Use Information document. Caution should be used in patients with eyes unable to dilate to a pupil diameter of  $\geq 7$  mm to ensure that the edge of the Light Adjustable Lens can be visualized during LDD light treatments; patients who the doctor believes will be unable to maintain steady fixation that is necessary for centration of the LDD light treatment; and patients with sufficiently dense cataracts that preclude examination of the macula as patients with preexisting macular disease may be at increased risk for macular disease progression. **PRECAUTIONS:** The long-term effect on vision due to exposure to UV light that causes erythropia (after LDD treatment) has not been determined. The implanted Light Adjustable Lens MUST undergo a minimum of 2 LDD treatments (1 adjustment procedure plus 1 lock-in treatment) beginning at least 17-21 days post-implantation. All clinical study outcomes were obtained using LDD power adjustments targeted to emmetropia post LDD treatments. The safety and performance of targeting to myopic or hyperopic outcomes have not been evaluated. The safety and effectiveness of the Light Adjustable Lens and LDD have not been substantiated in patients with preexisting ocular conditions and intraoperative complications. Patients must be instructed to wear the RxSight-specified UV protective eyewear during all waking hours after Light Adjustable Lens implantation until 24 hours post final lock-in treatment. Unprotected exposure to UV light during this period can result in unpredictable changes to the Light Adjustable Lens, causing aberrated optics and blurred vision, which might necessitate explantation of the Light Adjustable Lens. **ADVERSE EVENTS:** The most common adverse events (AEs) reported in the randomized pivotal trial included cystoid macular edema (3 eyes, 0.7%), hypopyon (1 eye, 0.2%), and endophthalmitis (1 eye, 0.2%). The rates of AEs did not exceed the rates in the ISO historical control except for the category of secondary surgical interventions (SSI); 1.7% of eyes (7/410) in the Light Adjustable Lens group had an SSI ( $p < .05$ ). AEs related to the UV light from the LDD include phototoxic retinal damage causing temporary loss of best spectacle corrected visual acuity (1 eye, 0.2%), persistent induced tritan color vision anomaly (2 eyes, 0.5%), persistent induced erythropia (1 eye, 0.3%), reactivation of ocular herpes simplex Infection (1 eye, 0.3%), and persistent unanticipated significant increase in manifest refraction error ( $\geq 1.0$  D cylinder or MRSE) (5 eyes, 1.3%). **CAUTION:** Federal law restricts this device to sale by or on the order of a physician. **Please see the Professional Use Information Document for a complete list of contraindications, warnings, precautions, and adverse events.**



## Study Examines the Quality and Empathy of AI Retina Consults

The internet has long provided answers—of varying accuracy—to patients’ many health-related queries, and now artificial intelligence models like ChatGPT are in the mix too. How good is this information, though? New research published in *Ophthalmology Science* suggests it has potential.<sup>1</sup> Researchers assessed the quality, safety and empathy of responses to common questions from retina patients by human experts, by AI and by AI responses edited by human experts. They concluded that clinical settings might make good use of AI responses.

In the masked, multi-center study, researchers randomly assigned 21 common retina patient questions among 13 retina specialists. A few examples include the following:

- What causes age-related macular degeneration?
- How long do I need to keep getting anti-VEGF injections?
- Can I pass AMD to my children?
- How long can I go between eye injections?
- Is there a good treatment for floaters?

Each expert created a response and then edited a response generated by the large language model (LLM) ChatGPT-4. They timed

themselves for both tasks. Five LLMs (ChatGPT-3.5, ChatGPT-4, Claude 2, Bing and Bard) also generated responses to each of the 21 questions. Other experts not involved in the initial response-writing process evaluated the responses and subjectively judged them for quality and empathy (very poor, poor, acceptable, good or very good) and for safety (incorrect information, likelihood to cause harm, extent of harm and missing content).

The researchers collected 4,008 grades (2,608 for quality and empathy

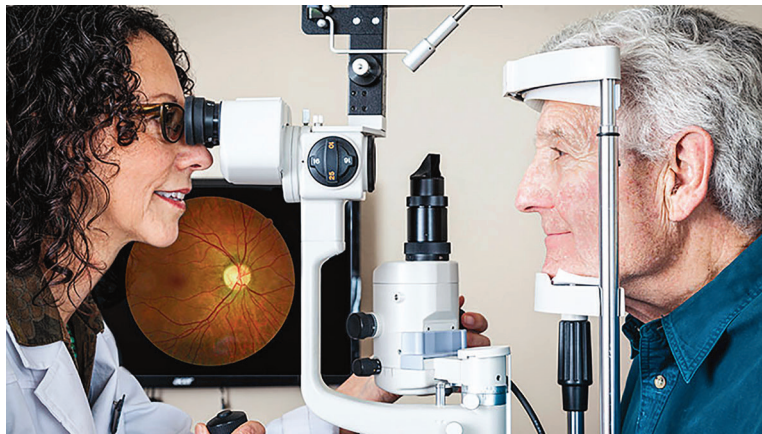responses placed fourth out of seven for quality and sixth out of seven for empathy (mean score), according to the study. Expert+AI responses significantly exceeded expert responses for quality and empathy.

“Busy surgeons may respond to patient questions accurately and quickly, but may not respond with as much empathy as LLMs,” says study senior author Matthew R. Starr, MD, of the Mayo Clinic.

Fortunately, AI seems poised to help. In the study, the researchers reported time savings for expert-edited AI responses vs. expert-created responses. “AI is here—it’s not ‘coming’ anymore,” Dr. Starr says. “It’s part of what we do, and I think we need to continue to be at the forefront of incorporating AI into how we practice. We as physicians spend a lot of time responding to patient questions, and

if we could harness LLMs to safely and appropriately respond to questions that would give us a lot more time back.”

Dr. Starr points out, however, that AI-generated responses still need oversight. “Many of the [AI-generated] responses were great, but there are still some inaccuracies and potential for harm, so they need to be edited



and 1,400 for safety metrics). They reported significant differences in quality and empathy between the three groups: LLM alone, expert alone and expert+AI. The latter—expert+AI—performed best overall in terms of quality, with ChatGPT-3.5 as the top-performing LLM. ChatGPT-3.5 had the highest mean empathy score followed by expert+AI. Expert




# iDose<sup>®</sup>TR

(travoprost intracameral implant) 75 mcg

Real image of  
iDose TR



 Actual size  
1.8mm x 0.5mm



Real image of  
glaucoma eye drop

(60x magnification of all images)

# NOW FDA APPROVED

## for the reduction of IOP in patients with OAG and OHT<sup>1</sup>

**Introducing iDose TR – the revolutionary way to deliver 24/7,  
long duration prostaglandin analog therapy intracamerally  
with proven safety and patient tolerability.<sup>1,2</sup>**

1. Data on file, Glaukos Corporation.

2. iDose TR (travoprost intracameral implant) 75 mcg Prescribing Information. Glaukos Corporation. 2023.

### INDICATIONS AND USAGE

iDose TR (travoprost intracameral implant) is indicated for the reduction of intraocular pressure (IOP) in patients with open angle glaucoma (OAG) or ocular hypertension (OHT).

### IMPORTANT SAFETY INFORMATION

#### DOSAGE AND ADMINISTRATION

For ophthalmic intracameral administration. The intracameral administration should be carried out under standard aseptic conditions.

#### CONTRAINDICATIONS

iDose TR is contraindicated in patients with active or suspected ocular or periocular infections, patients with corneal endothelial cell dystrophy (e.g., Fuch's Dystrophy, corneal guttatae), patients with prior corneal transplantation, or endothelial cell transplants (e.g., Descemet's Stripping Automated Endothelial Keratoplasty [DSAEK]), patients with hypersensitivity to travoprost or to any other components of the product.

#### WARNINGS AND PRECAUTIONS

iDose TR should be used with caution in patients with narrow angles or other angle abnormalities. Monitor patients routinely to confirm the location of the iDose TR at the site of administration. Increased pigmentation of the iris can occur. Iris pigmentation is likely to be permanent.

#### ADVERSE REACTIONS

In controlled studies, the most common ocular adverse reactions reported in 2% to 6% of patients were increases in intraocular pressure, iritis, dry eye, visual field defects, eye pain, ocular hyperaemia, and reduced visual acuity.

Please see full [Prescribing Information](#).

You are encouraged to report all side effects to the FDA. Visit [www.fda.gov/medwatch](http://www.fda.gov/medwatch), or call 1-800-FDA-1088.

You may also call Glaukos at 1-888-404-1644.

View full  
prescribing  
information at  
[iDoseTRhcp.com](http://iDoseTRhcp.com)



**GLAUKOS**  
TRANSFORMING VISION



and vetted appropriately. That will take time upfront. Hopefully as they improve over time, they'll require less oversight for responses to basic questions." He adds that in this case, it will be important to disclose to patients that some responses are AI generated but vetted by physicians.

Future LLMs for patient queries would need some modification. "These LLMs are open-source platforms, and not HIPAA compliant," Dr. Starr says. "If we can make something that's created specifically for patients that we created, then we may be able to actually use it and get it HIPAA compliant."

One limitation of the study came about due to the time it took to write and edit responses. "We missed about 100 or so questions out of about 4,000," Dr. Starr says. He also notes that a Hawthorne effect, where individuals modify behavior in response to awareness of being observed, may also have occurred, though physicians did not grade their own responses.

Overall, the researchers conclude in their paper that LLM responses were comparable to those written by experts, and that an expert-LLM collaboration can result in responses with better quality and empathy than human experts alone while saving time, potentially reducing physician burnout and improving patient care. The authors write that a "natural next step would be testing an editable LLM-generated draft to patient messages."

Another group of researchers set out to determine the accuracy of information patients get when they use ChatGPT.<sup>2</sup>

It's no surprise that, today, patients are likely to know a good deal about the conditions affecting them, given the instant knowledge available at our fingertips. Despite the internet providing a plethora of reputable information, patients may not know where to look for trusted sources on medicine and health practices across specialties, leaving them vulnerable to accessing incorrect information.

With the emergence of AI chatbots, this problem is on the precipice of tentative improvement, as such services could in theory help to improve accuracy by weeding out spurious reports. Used in a recent study, ChatGPT may not resolve this issue greatly right now, but the idea that patients in the future may gain information from a continually learning and improving bot may be more suitable for adjunctive patient education than aimlessly browsing search engines.

To assess the accuracy of ophthalmic information provided by ChatGPT, five diseases from eight ophthalmologic subspecialties were assessed by researchers from Wills Eye Hospital in Philadelphia. For each, three questions were asked:

What is [x]?

How is [x] diagnosed?

How is [x] treated?

Responses were scored with a range from -3 (unvalidated and potentially harmful to a patient's health or well-being if they pursue said suggestion) to 2 (correct and complete). To make these assessments, information was graded against the American Academy of Ophthalmology's guidelines for each disease.

A total of 120 questions were asked. Among the generated responses, 77.5 percent achieved a score of  $\geq 1.27$ , while 61.7 percent were considered both correct and complete according to AAO guidelines. A significant 22.5 percent of replies scored  $\leq -1$ . Among those, 7.5 percent obtained a score of -3. ChatGPT was best at answering the first question and worst on the topic of treatment. Overall median scores for all subspecialties was 2 for "What is [x]?", 1.5 for "How is [x] diagnosed?" and 1 for "How is [x] treated?"

Results were published in the journal *Eye*. The study authors point to reasoning for why the median scores were highest in the definition question and lowest in the treatment question, surmising that it has to do with the dataset of information ChatGPT

drew from for training.

As the authors explained in their paper, "The definition of a common disease is usually standard and well-known, and thus the information the chatbot has received in its training regarding the definition of a disease should be very straightforward. When prompted about diagnosis and treatment, it's more likely that the inputs contained conflicting information."

The same hypothesis could be applied to the trend seen for differences in median score across subspecialties. ChatGPT answered all the general subspecialty questions correctly, potentially because conditions from this category are more well-known pathologies. As such, a greater amount and more consistent set of information may have been drawn from to learn about. Supportive of this idea were the maximum scores obtained within other subspecialties for well-known and common pathologies, including cataracts, glaucoma and diabetic retinopathy.

Of course, this research demonstrates that chatbots are nowhere near capable of robust use for disseminating medical information. However, the authors believe "it appears that artificial intelligence may be a valuable adjunct to patient education, but it is not sufficient without concomitant human medical supervision."

Moving forward, they convey that "as the use of chatbots increases, human medical supervision of the reliability and accuracy of the information they provide will be essential to ensure patient's proper understanding of their disease and prevent any potential harm to the patient's health or well-being."

1. Taylor PD, Dalvin LA, Chen JJ, et al. A comparative study of responses to retina questions from either experts, expert-edited large language models (LLMs) or LLMs alone. *Ophthalmology Science* 2024. [Epub ahead of print].

2. Cappellani F, Card KR, Shields CL, Pulido JS, Haller JA. Reliability and accuracy of artificial intelligence ChatGPT in providing information on ophthalmic diseases and management to patients. *Eye*. January 20, 2024. [Epub ahead of print].





# TikTok “Challenges” Pose a Threat to Users’ Ocular Health

The social media platform TikTok has been used to share mostly harmless trends and challenges among its predominantly young audience, but some do pose serious risks to adolescents and teenagers who seek validation and attention from peers. Considering about 41 percent of the user base falls between the ages of 16 and 24, and a third are 14 or younger, it’s important to highlight those trends that pose potential harm. A recent research paper in the online journal *Ophthalmology and Therapy* cataloged a variety of reckless and foolhardy activities shared on TikTok that can endanger eye health.<sup>1</sup>

Included in discussion of this new research were the “rubbing castor oil trend,” “bleach/bright-eye challenge,” “mucus fishing challenge,” “eggsplussions,” “beezin challenge,” “Orbeez challenge,” “blow-drying eyelashes,” “sun gazing” and “popping styes” TikTok trends/challenges. The number of views, likes and shares was documented for each video of the respective challenge with the highest like count.

The first on the list, rubbing castor oil onto the eyes, has the purported benefits of decreasing wrinkles and—somehow—improving vision. A few studies do show that castor oil can enhance the lipid component of the tear film and decrease evaporation time, but can be dangerous to employ without medical supervision, due to many over-the-counter versions containing irritating or harmful preservatives. As well, excessive eye rubbing is linked with keratoconus.

Next is the bright-eye challenge. This involves putting on the eye a bag filled with jelly, hand sanitizer, bleach and shaving cream to lighten eye color.

This can cause irritation and permanent cellular damage due to protein denaturation, a property of bleach. Permanent damage can occur in case of leaks and extravasation into the eyes; this challenge has been removed from the platform, though. This challenge, however, may have begun on TikTok as a prank or parody and largely received as such by users rather than something to be acted upon. It’s also worth noting that the bleach eye challenge dates back to 2019, an eternity ago in the fast-paced world of social media, and TikTok in particular, and thus is likely to be long forgotten by today’s users.

Another challenge noted by the researchers is to force out mucus from an irritated eye using a Q-tip or finger. This can lead to a cycle of “mucus fishing syndrome,” a cyclic condition involving extraction of mucous strands from the eye, and is often triggered by ocular irritation. This leads to more mucous discharge, perpetuating eye irritation and the cycle. Mucus fishing can also cause mechanical conjunctivitis.

“Eggsplussions” happen from hard-boiled eggs being microwaved and then cut into pieces to intentionally burst open. This is a concern when hitting nearby objects, like the eye, leading to direct trauma. Similarly, the “Orbeez challenge” involved paintball guns to shoot gel pellets, also leading to potential ocular trauma. In fact, this challenge has caused 19 serious ocular injuries, as reported in one 2022 review, with 11 out of 19 occurring in those younger than 18. Another indirect cause of harm may occur from a trend that advocated blow-drying one’s eyelashes, since the eyes are not well-suited to endure such forceful

*(Continued on p. 12)*

## BUSINESS OFFICES

19 CAMPUS BOULEVARD, SUITE 101  
NEWTOWN SQUARE, PA 19073  
SUBSCRIPTION INQUIRIES (877) 529-1746  
(USA ONLY); OUTSIDE USA, CALL (847) 763-9630

## BUSINESS STAFF

PUBLISHER

**MICHAEL HOSTER**

(610) 492-1028 MHOSTER@JOBSON.COM

SENIOR MANAGER, STRATEGIC ACCOUNTS

**MICHELE BARRETT**

(610) 492-1014 MBARRETT@JOBSON.COM

REGIONAL SALES MANAGER

**JONATHAN DARDINE**

(610) 492-1030 JDARDINE@JOBSON.COM

DIGITAL MARKETING MANAGER

**MATT EGGER**

(610) 492-1029 MEGGER@JOBSON.COM

CLASSIFIED ADVERTISING

(888)-498-1460

PRODUCTION MANAGER

**KAREN LALLONE**

(610) 492-1010 KLALLONE@JOBSON.COM

SUBSCRIPTIONS

\$63 A YEAR, \$99 (U.S.) IN CANADA,  
\$158 (U.S.) IN ALL OTHER COUNTRIES.

SUBSCRIPTIONS E-MAIL:

REVOPHTHALMOLOGY@CAMBEYWEST.COM

## CIRCULATION

PO BOX 71, CONGERS, NY 10920-0071

(877) 529-1746

OUTSIDE USA: (845) 267-3065

SENIOR CIRCULATION MANAGER

**HAMILTON MAHER**

(212) 219-7870 hmaher@jihhealth.com

CEO, INFORMATION GROUP SERVICES

**BILL SCOTT**

VICE PRESIDENT, CREATIVE SERVICES & PRODUCTION

**MONICA TETTAMANZI**

CREATIVE DIRECTOR

**LOUISE KOENIG**

DIRECTOR, PRODUCTION/MANUFACTURING

**REBECCA SLEBODNIK**

VICE PRESIDENT, HUMAN RESOURCES

**TAMMY GARCIA**

VICE PRESIDENT, CIRCULATION

**JARED SONNERS**

299 Market St. 2 Gateway Center - 4th Floor

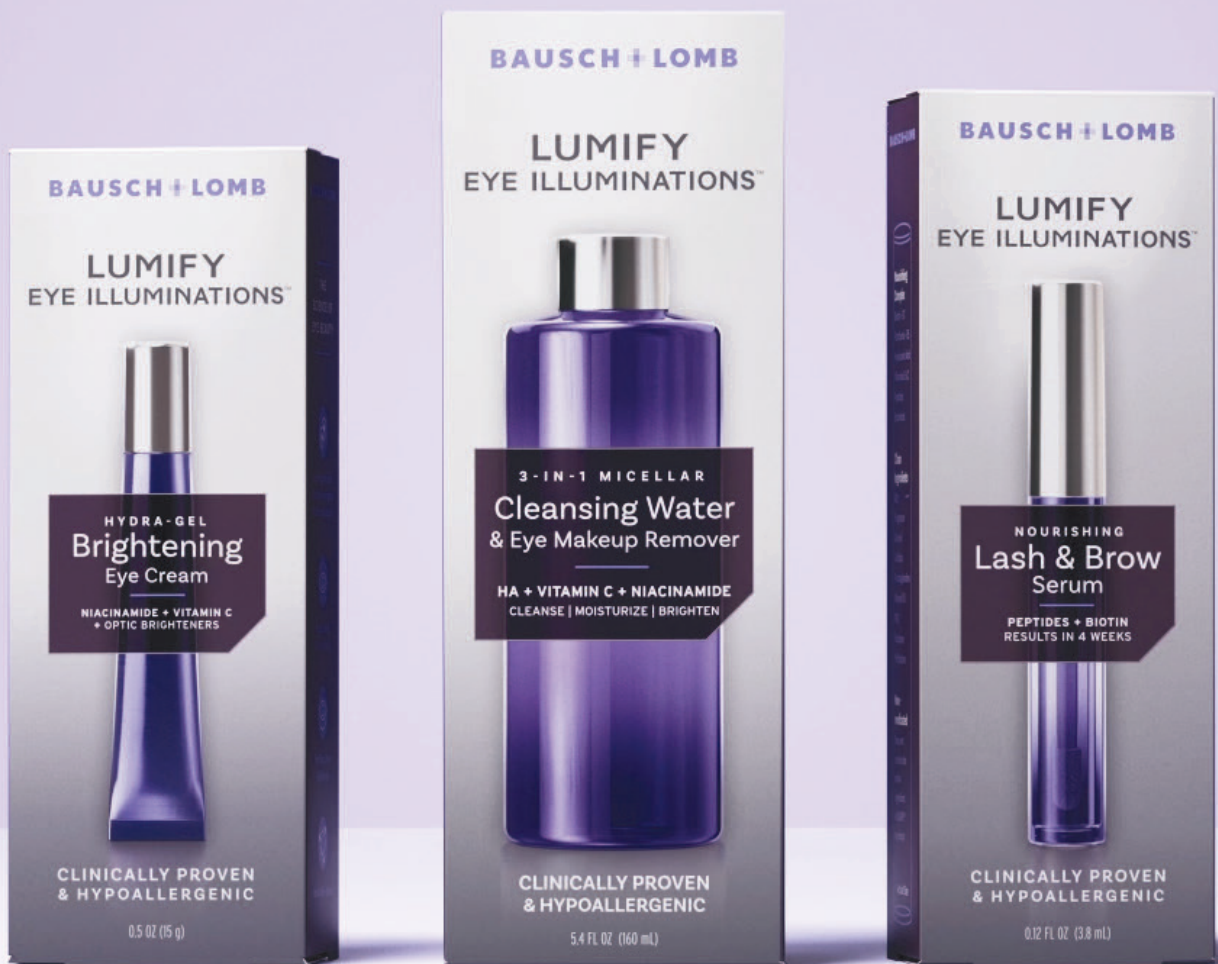Newark NJ 07102

**REVIEW OF OPHTHALMOLOGY** (ISSN 1081-0226; USPS No. 0012-345) is published monthly, 12 times per year by Jobson Medical Information, LLC/WebMD 283 - 299 Market St. 2 Gateway Center - 4th Floor Newark NJ 07102. Periodicals postage paid at New York, NY and additional mailing offices. Postmaster: Send address changes to Review of Ophthalmology, PO Box 71, Congers, NY 10929-0071. Subscription Prices: US One Year \$63.00, US Two Year \$112.00, Canada One Year \$99.00, Canada Two Year \$181.00, Int'l One Year \$158.00, Int'l Two Year \$274.00. For subscription information call (877) 529-1746 (USA only); outside USA, call (845-267-3065. Or email us at revophthalmology@cambeywest.com. Canada Post: Publications Mail Agreement #40612608. Canada Returns to be sent to Bleuchip International, P.O. Box 25542, London, ON N6C 6B2.



FROM THE EYE CARE EXPERTS AT **BAUSCH+LOMB**

# LUMIFY EYE ILLUMINATIONS™



Non-irritating formulas

Developed with Eye Doctors  
and Dermatologists

Clinically-proven

A trio of specialty eye care products scientifically formulated for the sensitive eye area.  
Clinically proven with 15,000 product applications up to 12 weeks.

Your patients can find this **in the eye care aisle.**

© 2023 Bausch + Lomb LEM.0152.USA.23 [LUMIFYeyes.com](https://www.LUMIFYeyes.com)

# FEATURES

Vol. XXXI, No. 3 • March 2024

**Catch Up on the Latest News**  
Read *Review's* weekly newsletter  
online at [reviewofophthalmology.com](http://reviewofophthalmology.com).

27

## Evaluating the Retina Before Surgery

How to factor the retinal exam into the management of increasingly complex cataract and refractive procedures.

**Sean McKinney**  
*Contributing Editor*

33

## Survey: Cataract Surgery Snapshot

Read about your colleagues' preferred methods for the various stages of cataract surgery.

**Walter Bethke**  
*Editor in Chief*

38

## How to Succeed with the New Triple Procedure

Cornea specialists share their strategies and techniques.

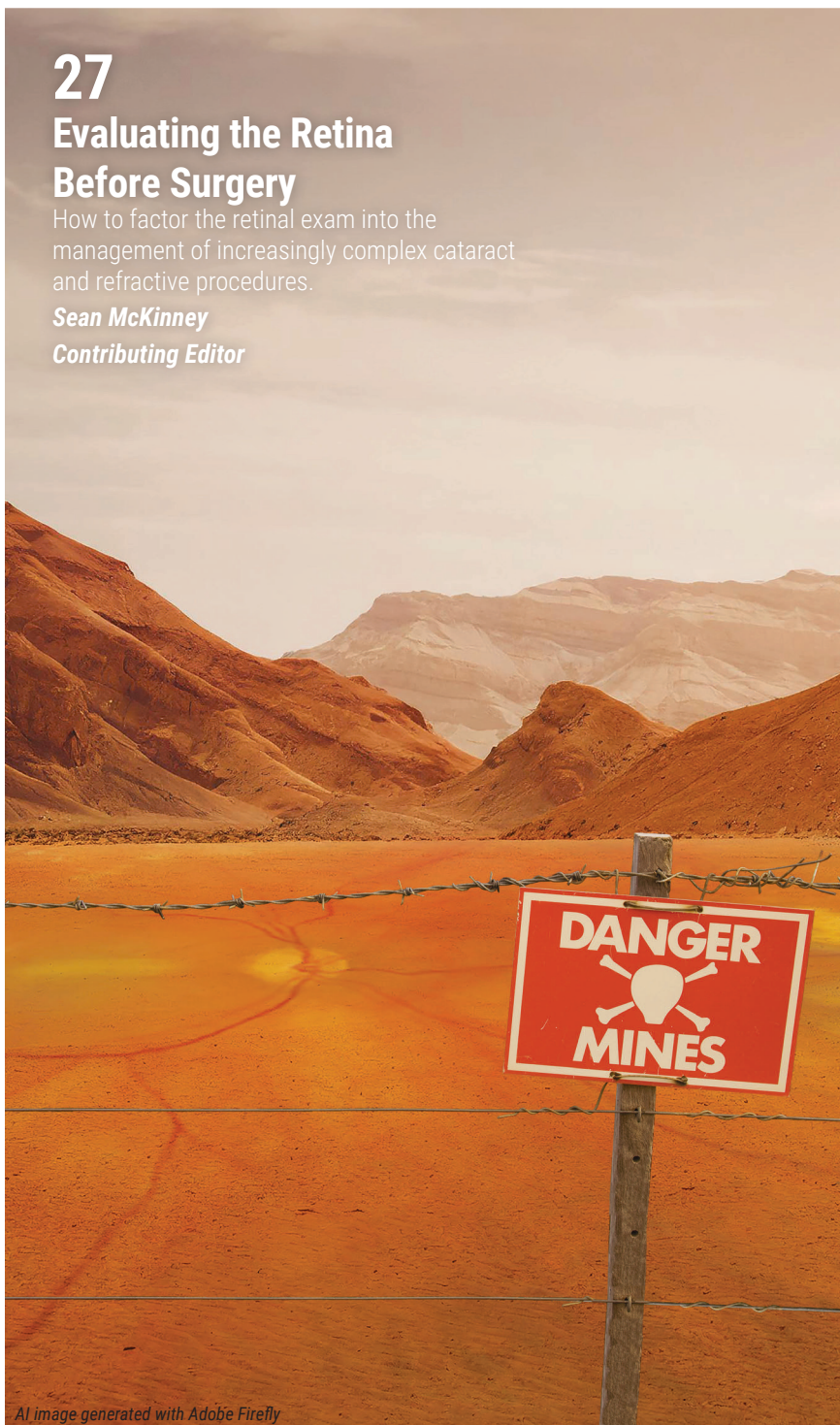
**Liz Hunter**  
*Senior Editor*

44

## A Review of Retinal Detachment Repair

Retina specialists provide insight on how to match the right procedures with the patient's history and type of detachment.

**Andrew Beers**  
*Associate Editor*



*AI image generated with Adobe Firefly*



# DEPARTMENTS

March 2024

## 4 News

## 14 EDITOR'S PAGE Can You Defeat the Non-compete? *Walter Bethke* Editor in Chief



## 17 The Forum If You Can Be Anything Musings on life, medicine and the practice of ophthalmology. *Mark H. Blecher, MD* Chief Medical Editor

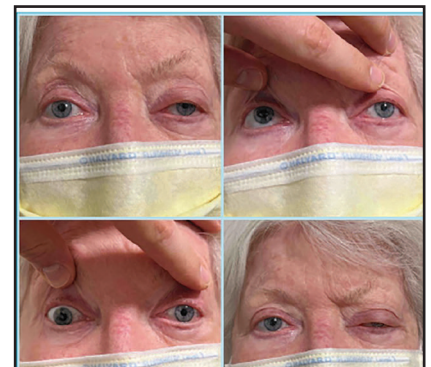## 20 REFRACTIVE/CATARACT RUNDOWN The Right Time for MSICS and miLoop Surgeons discuss when it's time to consider alternatives to phaco. *Liz Hunter* Senior Editor

## 50 TECHNOLOGY UPDATE Enhancing Vision With wEVES Wearable electronic vision enhancement systems can improve the lives of patients with low-vision. *Andrew Beers* Associate Editor

## 54 RESEARCH REVIEW IOP Spikes in Glaucoma Patients After Phaco

## 58 GLAUCOMA MANAGEMENT Systemic Factors in Glaucoma Consider these underlying issues if patients progress despite low IOP. *Victoria M. Addis, MD*

## 61 AD INDEX



## 64 WILLS EYE RESIDENT CASE SERIES A woman presents with eyelid droop and diplopia. *Eric Kim, MD, Collin Richards, MD, and Jurij Bilyk, MD*

 VISIT US ON SOCIAL MEDIA

Facebook [facebook.com/RevOphth](https://facebook.com/RevOphth)  
twitter/X [twitter.com/RevOphth](https://twitter.com/RevOphth)  
Instagram [@revophth](https://instagram.com/revophth)

xdemvy®  
(lotilaner ophthalmic  
solution) 0.25%



Learn more at  
XDEMZYHCP.com

## XDEMZY gives you **might over mites** to eradicate *Demodex* blepharitis.<sup>1,2</sup>

Lotilaner, the active ingredient in XDEMZY<sup>1,3,4</sup>:



Is a lipophilic agent in an aqueous drop that...



Acts specifically via mite GABA-gated  
chloride channels to...



Target, paralyze, and kill *Demodex* mites

GABA=gamma-aminobutyric acid.

### INDICATIONS AND USAGE

XDEMZY (lotilaner ophthalmic solution) 0.25% is indicated for the treatment of *Demodex* blepharitis.

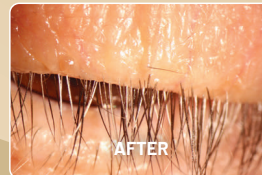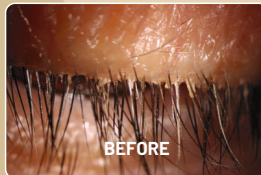
### IMPORTANT SAFETY INFORMATION:

#### WARNINGS AND PRECAUTIONS

**Risk of Contamination:** Do not allow the tip of the dispensing container to contact the eye, surrounding structures, fingers, or any other surface in order to minimize contamination of the solution. Serious damage to the eye and subsequent loss of vision may result from using contaminated solutions.

**Use with Contact Lenses:** XDEMZY contains potassium sorbate, which may discolor soft contact lenses. Contact lenses should be removed prior to instillation of XDEMZY and may be reinserted 15 minutes following its administration.

### Real results



44% and 55% of patients taking XDEMZY in SATURN-1 (N=209) and SATURN-2 (N=193), respectively, achieved a significant improvement in their eyelids (reduction of collarettes to no more than 2 collarettes per upper lid) at Day 43 vs 7% (N=204) and 12% (N=200) of patients taking vehicle (P<0.01 in each trial).<sup>1,\*</sup>

All images are of actual patients who participated in clinical trials for Tarsus Pharmaceuticals.

**ADVERSE REACTIONS:** The most common adverse reaction with XDEMZY was instillation site stinging and burning which was reported in 10% of patients. Other ocular adverse reactions reported in less than 2% of patients were chalazion/hordeolum and punctate keratitis.

Please see next page for a Brief Summary of the full Prescribing Information.

**References:** 1. XDEMZY [prescribing information]. Tarsus Pharmaceuticals, Inc; 2023. 2. Gao YY et al. *Invest Ophthalmol Vis Sci.* 2005;46(9):3089-3094. 3. Yeu E et al. *Cornea.* 2022;42:435-443. 4. Toutain CE et al. *Parasit Vectors.* 2017;10(1):522.

\*The safety and efficacy of XDEMZY for the treatment of DB were evaluated in a total of 833 patients (415 of whom received XDEMZY) in two 6-week, randomized, multicenter, double-masked, vehicle-controlled studies (SATURN-1 and SATURN-2). Patients were randomized to either XDEMZY or vehicle at a 1:1 ratio, dosed twice daily in each eye for 6 weeks. All patients enrolled were diagnosed with DB. The primary efficacy endpoint was defined as the proportion of patients with collarette reduction to no more than 2 collarettes per upper eyelid at Day 43.

© 2024 Tarsus Pharmaceuticals, Inc. All rights reserved.  
Tarsus, XDEMZY, and the associated logos are trademarks of  
Tarsus Pharmaceuticals, Inc. US--2300617 1/24





**XDEMYV® (lotilaner ophthalmic solution) 0.25%, for topical ophthalmic use**

**BRIEF SUMMARY OF PRESCRIBING INFORMATION**

Please see the XDEMYV® package insert for full Prescribing Information.

**INDICATIONS AND USAGE**

XDEMYV is indicated for the treatment of Demodex blepharitis.

**CONTRAINDICATIONS**

None.

**WARNINGS AND PRECAUTIONS**

**Risk of Contamination** Do not allow the tip of the dispensing container to contact the eye, surrounding structures, fingers, or any other surface in order to minimize contamination of the solution. Serious damage to the eye and subsequent loss of vision may result from using contaminated solutions.

**Use with Contact Lenses** Contact lenses should be removed prior to instillation of XDEMYV and may be reinserted 15 minutes following its administration.

**ADVERSE REACTIONS**

Because clinical studies are conducted under widely varying conditions, adverse reaction rates observed in the clinical trials of a drug cannot be directly compared to rates in the clinical trials of another drug and may not reflect the rates observed in practice.

XDEMYV was evaluated in 833 patients with Demodex blepharitis in two randomized, double-masked, vehicle-controlled studies (Saturn-1 and Saturn-2) with 42 days of treatment. The most common ocular adverse reaction observed in controlled clinical studies with XDEMYV was instillation site stinging and burning which was reported in 10% of patients. Other ocular adverse reactions reported in less than 2% of patients were chalazion/hordeolum and punctate keratitis.

**USE IN SPECIFIC POPULATIONS**

**Pregnancy: Risk Summary** There are no available data on XDEMYV use in pregnant women to inform any drug associated risk; however, systemic exposure to lotilaner from ocular administration is low. In animal reproduction studies, lotilaner did not produce malformations at clinically relevant doses.

**Data Animal Data** In an oral embryofetal developmental study in pregnant rats dosed during organogenesis from gestation days 6-19, increased post-implantation loss, reduced fetal pup weight, and incomplete skeletal ossification were observed at 50 mg/kg/day (approximately 1390 times the recommended human ophthalmic dose (RHOD) on a body surface area basis) in the presence of maternal toxicity (i.e., decreased body weight and food consumption). A rare malformation of situs inversus of the thoracic and abdominal viscera occurred in 1 fetus from a pregnant rat receiving 50 mg/kg/day; whether this finding was treatment-related could not be excluded. No maternal or embryofetal toxicity was observed at 18 mg/kg/day (approximately 501 times the RHOD on a body surface area basis). In an oral embryofetal development study in pregnant rabbits dosed during organogenesis from gestation days 7-19, no embryofetal toxicity or teratogenic findings were observed at 20 mg/kg/day (approximately 580-times the RHOD on an AUC basis), even in the presence of maternal toxicity (i.e., decreased food consumption and body weight).

In an oral two-generation reproductive toxicity study, F0 male and female rats were administered lotilaner at doses up to 40 mg/kg/day for 10 weeks before pairing and during the 2-week pairing period (3 weeks for males). Dosing for F0 females continued through lactation day 22. F1 male and female rats were administered lotilaner at 1 and 5 mg/kg/day post-weaning from day 23 for 10 weeks before pairing and during the 2-week pairing period (3 weeks for males). Dosing for F1 parenteral females continued through lactation day 22. There were no clear adverse effects on the F1 generation, and a slightly lower mean body weight during lactation was noted for F2 pups at 5 mg/kg/day. The observed adverse effect level (NOAEL) was determined to be 5 mg/kg/day

(approximately 139 times the RHOD on a body surface area basis).

**Lactation: Risk Summary** There are no data on the presence of XDEMYV in human milk, the effects on the breastfed infant, or the effects on milk production. However, systemic exposure to lotilaner following 6 weeks of topical ocular administration is low and is >99% plasma protein bound, thus it is not known whether measurable levels of lotilaner would be present in maternal milk following topical ocular administration. The developmental and health benefits of breastfeeding should be considered along with the mother's clinical need for XDEMYV and any potential adverse effects on the breast-fed child from XDEMYV.

**Pediatric Use:** Safety and effectiveness in pediatric patients below the age of 18 years have not been established.

**Geriatric Use:** No overall differences in safety or effectiveness have been observed between elderly and other adult patients.

**NONCLINICAL TOXICOLOGY**

**Carcinogenesis, Mutagenesis, Impairment of Fertility**

**Carcinogenesis** Long-term studies in animals have not been performed to evaluate the carcinogenic potential of lotilaner.

**Mutagenesis** Lotilaner was not genotoxic in the following assays: Ames assay for bacterial gene mutation, *in vitro* chromosomal aberration assay in cultured human peripheral blood lymphocytes, and *in vivo* rat micronucleus test.

**Impairment of fertility** In a two-generation study of reproductive performance in rats, F0 male and female rats were administered lotilaner at oral doses of 40 mg/kg/day for 80 days reduced to 20 mg/kg/day for 47-50 supplementary days. Reduced pregnancy rates and decreased implantation rates were observed in F0 females at doses 20 mg/kg/day (approximately 556 times the RHOD on a body surface area basis), which were also associated with maternal toxicity (i.e., decreased body weight and food consumption). No effects on fertility were observed in F0 females at the dose of 5 mg/kg/day (approximately 139 times the MRHOD on a body surface area basis). No effects on fertility were observed in F0 males at the oral dose of 20 mg/kg/day (approximately 556 times the RHOD on a body surface area basis), and no effects on fertility were observed in F1 males and females at the oral dose of 5 mg/kg/day (approximately 139 times the RHOD on a body surface area basis).

**PATIENT COUNSELING INFORMATION**

**Handling the Container** Instruct patients to avoid allowing the tip of the dispensing container to contact the eye, surrounding structures, fingers, or any other surface in order to minimize contamination of the solution. Serious damage to the eye and subsequent loss of vision may result from using contaminated solutions.

**When to Seek Physician Advice**

Advise patients that if they develop an intercurrent ocular condition (e.g., trauma or infection), have ocular surgery, or develop any ocular reactions, particularly conjunctivitis and eyelid reactions, they should immediately seek their physician's advice concerning the continued use of XDEMYV.

**Use with Contact Lenses** Advise patients that XDEMYV contains potassium sorbate, which may discolor soft contact lenses. Contact lenses should be removed prior to instillation of XDEMYV and may be reinserted 15 minutes following its administration.

**Use with Other Ophthalmic Drugs** Advise patients that if more than one topical ophthalmic drug is being used, the drugs should be administered at least 5 minutes between applications.

**Missed Dose** Advise patients that if one dose is missed, treatment should continue with the next dose.

**RX only**

© 2024 Tarsus Pharmaceuticals, Inc. All rights reserved.

XDEMYV is a trademark of Tarsus Pharmaceuticals, Inc.

US-2300345 1/24

**REVIEW NEWS**

(Continued from p. 7)

air in close proximity. Attempting this could cause dryness, irritation or even long-term consequences of corneal abrasions and infections.

Other trends of concern include sun gazing, in which viewers intentionally look at the sun for five to 10 seconds, which can lead to solar retinopathy and scotomas. "Stye popping" is yet another trend that can harm the eyelid through people using their fingers, needles or tweezers for expression of lid lesions. Spread of infection is possible or worsening of the stye, with possible complications of pigmented scars, scar tissue and pitting scars.

All of these videos have millions of views each, the paper notes, highlighting how pervasive these trends can become and harmful if followed uncritically by impressionable young viewers. The study authors warn that "encountering substandard medical information on social media platforms presents significant hazards to patients. It may lead them to make critical medical choices relying on potentially erroneous data. This could result in adverse consequences, such as applying over-the-counter castor oil to treat various medical conditions." As such, doctors and parents should be vigilant for incorrect and just plain foolish medical content on social media platforms.

1. Hassan SA, Ghannam AB, Saade JS. An emerging ophthalmology challenge: a narrative review of TikTok trends impacting eye health among children and adolescents. *Ophthalmol Ther.* February 5, 2024. [Epub ahead of print].

(Continued on p. 16)

**TERESA HORAN, MD, AWARDED RICK BAY SCHOLARSHIP**

This year's recipient of The Rick Bay Excellence in Eyecare Education Scholarship is Teresa Horan, MD.

Dr. Horan is currently completing a glaucoma fellowship at Wills Eye Hospital in Philadelphia. She's a native of Connecticut and graduated cum laude with a BA in Biology from St. Mary's College of Maryland, going on to earn her medical degree from Sidney Kimmel Medical College at Thomas Jefferson University in Philadelphia. Dr. Horan completed her ophthalmology residency at Tufts Medical Center/New England Eye Center in Boston.

Lauren Hock, MD, a glaucoma specialist at Wills, says, "Dr. Horan was selected for the Rick Bay Excellence in Eyecare Education Scholarship for her compassionate care of glaucoma patients, her integrity as a physician, and her dedication to ophthalmology education as a future academic glaucoma specialist."

Dr. Horan says she was honored to be selected. "I value the importance of training to further our field and am committed to training the next generation of ophthalmologists to care for our growing population of glaucoma patients," she says. "I'm grateful to the Rick Bay Foundation for the support to continue my training and advance glaucoma care."

Upon completion of her fellowship, Dr. Horan will continue her career at the University of Maryland.

The Rick Bay Foundation honors the legacy of its namesake, the former president and publisher of *Review of Ophthalmology*. Ophthalmology scholarships are awarded annually to fellows at Wills Eye Hospital who embody Bay's qualities of integrity and compassion.



# NextGen<sup>®</sup> Ambient Assist *is the greatest improvement in technology since X-rays went digital.*

Chris Wixon, MD, Cardiovascular | Savannah Vascular Institute

Integrated ambient listening technology securely converts the natural patient-provider conversation into a structured note that can quickly be reviewed and sent into the patient's chart—all in seconds.

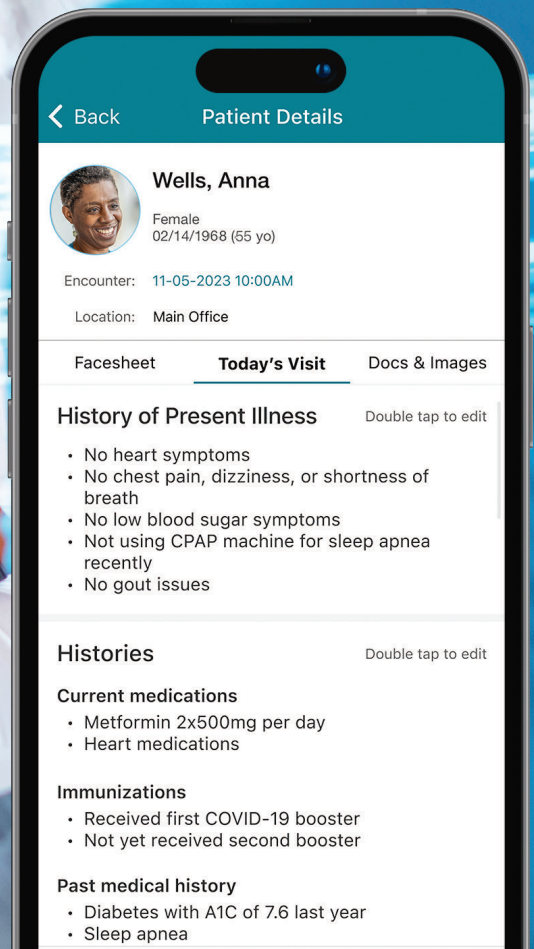
## Schedule a Demo

Call us at 855-346-1528  
or visit [nextgen.com/ambient](https://nextgen.com/ambient)



The product images shown are for illustration purposes only. The actual product may vary.

© 2024 NXGN Management, LLC. All Rights Reserved. NextGen is a registered trademark of NXGN Management, LLC. All other names and marks are the property of their respective owners.







### EDITORIAL STAFF

#### Editor in Chief

Walter Bethke

(610) 492-1024

wbethke@jobson.com

#### Senior Editor

Liz Hunter

(610) 492-1025

ehunter@jobson.com

#### Senior Associate Editor

Christine Leonard

(610) 492-1008

cleonard@jobson.com

#### Associate Editor

Leanne Spiegle

(610) 492-1026

lspiegle@jobson.com

#### Associate Editor

Andrew Beers

(570) 856-5156

abeers@jobson.com

#### Chief Medical Editor

Mark H. Blecher, MD

#### Art Director

Lynne O'Connor

(267) 566-6007

lyoconnor@jobson.com

#### Graphic Designer

Jaine Kopala

(609) 969-0694

jkopala@jobson.com

#### Business Offices

19 Campus Boulevard, Suite 101

Newtown Square, PA 19073

(610) 492-1000

Fax: (610) 492-1039

#### Subscription inquiries:

United States – (877) 529-1746

Outside U.S. – (845) 267-3065

E-mail:

revophthalmology@cambeywest.com

Website: www.reviewofophthalmology.com



# Can You Defeat the Non-compete?

Unfortunately, there seems to be a growing list of factors contributing to physicians feeling burnt out and even devalued by society at large.

Physician burnout is real, and is happening in many specialties, including ophthalmology. In a 2022 survey of 13,000 physicians from various specialties, 40 percent of the ophthalmologists surveyed described themselves as burned out. The top two reasons given for this burnout were “too many bureaucratic tasks such as charting and paperwork” and a “lack of respect from administrators/employers, colleagues and staff.”<sup>1</sup>

Then, as has been mentioned in this column before, we have the never-ending string of reimbursement cuts (5.4 percent this year). If money flows to what society values, then these cuts just compound this feeling that such a valuable procedure as cataract surgery means less and less to the powers that be, and that the physician isn't respected.

As if reimbursement cuts and the day in, day out hassle of administrators, payors and employers weren't enough, there's an emerging threat that will only intensify as physicians sell their practices to become employees of larger entities, or simply sign on to be employees of health-care systems: restrictive covenants for physicians. Simply put, these physicians sign employment contracts that stipulate if they're to leave the employ of the company, they're unable to practice in the local area for several years.

One such restrictive covenant situation is coming to a head in the Scranton/Wilkes-Barre, Pennsylvania area, in which a urologist is suing his former employer for what he alleges is illegal enforcement of a non-compete agreement.<sup>2</sup> After resigning due to “restrictions on his ability to practice medicine,”

the physician was informed the non-compete clause would go into effect and prevent him from practicing in a 20-mile radius for two years.

As long as a physician isn't overtly taking patient files out the door with him, it's in the best interest of the community at large—especially with the impending provider shortage—to have as many physicians available as possible. The opposition to the restrictive covenants argue as much by noting that the community didn't sign the non-compete, but is still hurt by it.

Fortunately, last year the Federal Trade Commission proposed a new rule that would prohibit companies from limiting doctors' ability to work where they want after leaving an employer.<sup>3</sup> (The one profession that's successfully banned the practice of non-compete clauses in contracts is ... you guessed it: law.<sup>2</sup> But then, of course it is).

Getting rid of these restrictive covenants for physicians may not just make economic sense (the FTC estimates it could increase workers' earnings by \$300 billion per year) but it might also go a long way toward physicians feeling that their skills are something that their local communities—and society at large—want and value.

— Walter Bethke  
Editor in Chief

1. 2022 Physician burnout and depression report. <https://www.medscape.com/slideshow/2022-lifestyle-burnout-6014664#4>. Accessed February 20, 2023.

2. Urologist sues health system over noncompete clause. [https://www.mdedge.com/internalmedicine/article/267861/business-medicine/urologist-sues-health-system-over-noncompete?ecd=WNL\\_EVE\\_240217\\_md-edge](https://www.mdedge.com/internalmedicine/article/267861/business-medicine/urologist-sues-health-system-over-noncompete?ecd=WNL_EVE_240217_md-edge). Accessed February 20, 2024.

3. <https://www.ftc.gov/news-events/news/press-releases/2023/01/ftc-proposes-rule-ban-noncompete-clauses-which-hurt-workers-harm-competition>. Accessed February 19, 2024.

# In 2022, almost **2 million** astigmatic eyes were left untreated

Think Toric First. Give Your Patients an Alcon Toric IOL.



Clareon® Toric  
IOL



Clareon® Vivity® Toric  
Extended Vision IOL



Clareon® PanOptix® Toric  
Trifocal IOL



**Visit [ClareonIOL.com](https://www.ClareonIOL.com)**



(Continued from p. 12)

## Study May Describe New Dry AMD Variant

In patients with age-related macular degeneration, macular neovascular lesions are usually responsible for the presence of intraretinal fluid (IRF), but in some reports this fluid occurs in the absence of MNV lesions. To describe this new AMD variant, researchers conducted a retrospective study of patients with IRF and intermediate AMD. Their results, published in *Retina*, show that non-exudative IRF is a novel and distinct finding in intermediate AMD.<sup>1</sup>

The study included 10 eyes of 10 patients (aged 68 to 60; mean BCVA 20/40) who demonstrated IRF in intermediate AMD. No macular neovascularization was seen on multimodal imaging, and optical coherence tomography-angiography didn't detect any abnormal flow signal associated with IRF.

The researchers described two distinct phenotypes of patients in which IRF occurred: (1) those with serous/drusenoid pigment epithelium detachment (PED) and (2) those with an area of nascent geographic atrophy (nGA). They explained in their *Retina* paper that when seen on structural OCT, the "IRF associated with PED was usually found at the apex of the PED, that was surrounded by hyperreflective deposits," while "in eyes with nGA, IRF appeared as hyporeflective cystoid spaces that follow the course of Henle's fiber layer."

Proposed causes and/or mechanisms for non-exudative IRF in intermediate AMD include:

- PED lesions "with considerable height," causing mechanical stress and hydrostatic pressure;
- concomitant Muller cell loss and outer segment cell impairment, ultimately leading to cystoid IRF accumulation;
- blood retinal barrier breakdown and protein deposit accumulation between the choriocapillaris and ELM, leading to increased osmotic pressure and hyperosmolar stress;
- local hypoxia resulting from increased distance between retinal pigment epithelium (RPE) and choriocapillaris; or
- outer retinal injury leading to RPE migration to the inner retinal layers.

"These findings are of paramount relevance in the clinical setting, highlighting that we need to discern between the presence of IRF due to MNV and that due to non-MNV causes," the researchers emphasized in their paper. They concluded that larger cohorts are needed along with multimodal approaches to "improve the understanding of the mechanism at play causing the IRF" in intermediate AMD and to improve the management of patients in this subgroup. ◀

1. Servillo A, Kesim C, Sacconi R, et al. Non-exudative intraretinal fluid in intermediate age-related macular degeneration. *Retina* 2024. [Epub ahead of print].

### Important Product Information - Clareon® Family of IOLs

**CAUTION:** Federal law restricts these devices to sale by or on the order of a physician.

**INDICATION:** The family of Clareon® intraocular lenses (IOLs) includes the Clareon® Aspheric Hydrophobic Acrylic and Clareon® Aspheric Toric IOLs, the Clareon® PanOptix® Trifocal Hydrophobic IOL, Clareon® PanOptix® Toric, Clareon® Vivity™ Extended Vision Hydrophobic Posterior Chamber IOL and Clareon® Vivity™ Toric IOLs. Each of these IOLs is indicated for visual correction of aphakia in adult patients following cataract surgery. In addition, the Clareon® Toric IOLs are indicated to correct pre-existing corneal astigmatism at the time of cataract surgery. The Clareon® PanOptix® lens mitigates the effects of presbyopia by providing improved intermediate and near visual acuity, while maintaining comparable distance visual acuity with a reduced need for eyeglasses, compared to a monofocal IOL. The Clareon® Vivity™ lens mitigates the effects of presbyopia by providing an extended depth of focus. Compared to an aspheric monofocal IOL, the lens provides improved intermediate and near visual acuity, while maintaining comparable distance visual acuity. All of these IOLs are intended for placement in the capsular bag.

#### WARNINGS/PRECAUTIONS:

##### General cautions for all Clareon® IOLs:

Careful preoperative evaluation and sound clinical judgment should be used by the surgeon to decide the risk/benefit ratio before implanting any IOL in a patient with any of the conditions described in the Directions for Use that accompany each IOL. Physicians should target emmetropia, and ensure that IOL centration is achieved.

**For the Clareon® Aspheric Toric, PanOptix® Toric and Vivity™ Toric IOLs,** the lens should not be implanted if the posterior capsule is ruptured, if the zonules are damaged, or if a primary posterior capsulotomy is planned. Rotation can reduce astigmatic correction; if necessary lens repositioning should occur as early as possible prior to lens encapsulation.

**For the Clareon® PanOptix® IOL,** some visual effects may be expected due to the superposition of focused and unfocused multiple images. These may include some perceptions of halos or starbursts, as well as other visual symptoms. As with other multifocal IOLs, there is a possibility that visual symptoms may be significant enough that the patient will request explant of the multifocal IOL. A reduction in contrast sensitivity as compared to a monofocal IOL may be experienced by some patients and may be more prevalent in low lighting conditions. Therefore, patients implanted with multifocal IOLs should exercise caution when driving at night or in poor visibility conditions. Patients should be advised that unexpected outcomes could lead to continued spectacle dependence or the need for secondary surgical intervention (e.g., intraocular lens replacement or repositioning). As with other multifocal IOLs, patients may need glasses when reading small print or looking at small objects. Posterior capsule opacification (PCO), may significantly affect the vision of patients with multifocal IOLs sooner in its progression than patients with monofocal IOLs.

**For the Clareon® Vivity™ IOL,** most patients implanted with the Vivity™ IOL are likely to experience significant loss of contrast sensitivity as compared to a monofocal IOL. Therefore, it is essential that prospective patients be fully informed of this risk before giving their consent for implantation of the Clareon® Vivity™ IOL. In addition, patients should be warned that they will need to exercise caution when engaging in activities that require good vision in dimly lit environments, such as driving at night or in poor visibility conditions, especially in the presence of oncoming traffic. It is possible to experience very bothersome visual disturbances, significant enough that the patient could request explant of the IOL. In the parent AcrySof® IQ Vivity™ IOL clinical study, 1% to 2% of AcrySof® IQ Vivity™ IOL patients reported very bothersome starbursts, halos, blurred vision, or dark area visual disturbances; however, no explants were reported.

Prior to surgery, physicians should provide prospective patients with a copy of the Patient Information Brochure available from Alcon informing them of possible risks and benefits associated with these IOLs.

**ATTENTION:** Reference the Directions for Use labeling for each IOL for a complete listing of indications, warnings and precautions.

**References:** 1. Market Scope Q4 - 2022 US Cataract Quarterly Update 2. Hill, Distribution Data (2021). 3. Watanabe. Effect of Experimentally Induced Astigmatism on Functional, Conventional, and Low-Contrast Visual Acuity (2013).

# Alcon



# If You Can Be Anything

*Musings on life, medicine and the practice of ophthalmology.*

**MARK H. BLECHER**  
CHIEF MEDICAL EDITOR

**K**ids nowadays. No manners. What's the world coming to? OK, now that you know I'm old, let's seriously talk about the deterioration of civil society. What has happened to civility? Before I answer that question, we might benefit from the defining of terms. There's an interesting chapter I reviewed for this column in a book found on PubMed, "Recovering Civility after COVID" published in 2021. The chapter "understanding civility" dives into excruciating details of language and context regarding civility. It was more a philosophical treatise than social commentary, but enlightening nonetheless. Civility has several components, and my take on it is that it's composed of common courtesy and public behavior. Common courtesy is that which occurs between individuals: speaking kindly, holding the door open, etc. It's very personal and occurs on a frequent basis throughout the day as we move about the world. You could also describe it as politeness or good manners. It tends to be very quick—a hello, a thank you. I'm sure some of you are already thinking, "You can say

and do those nice things and not really feel them, or believe them." Sort of like the Southern expression "bless your heart" which not infrequently means "drop dead." Heartfelt or not, they still constitute civil behavior. And how they are expressed varies by gender, age, socioeconomic strata and culture. They share a desire to be considerate and a tad deferential to other people which in our society is considered civil.

Civil public behavior involves groups, frequently in public. Think sports fans. Phillies fans are typically very civil. Eagles fans not so much. Also, consider protest marches, public hearings, etc. It's a more "group think" concept. And it's what we see online in the countless video clips so many of us are addicted to: demonstrations of a lack of civil public behavior. Why are we attracted to those? It's really like the car-crash phenomena: unpleasant, gruesome and yet we can't turn away. So, the question is, why did it get worse? Did it get worse, or are we just seeing what was always out there via ever-present social media? You could make a case that this is true but, deep down, almost everyone believes that we are ruder, more short-tempered and just plain awful. Whether it's a loss of common courtesy, public civil-

ity or both. A common belief is that going through the COVID pandemic accelerated this. Some think national politics and a certain political figure made it OK to be rude and crude.

I think that we need to understand what drives civility. What drives courtesy to our fellow human. The authors of the chapter I referenced felt that being civil is predicated on feeling that other people have equal value to us, have the same rights and privileges, therefore we treat them like we would like to be treated. You're uncivil to those you consider unworthy or inferior. If that's the case, are we as a society more judgmental, more arrogant and more classist now than in the past? That's a tough call to make. Sure, COVID and all the disruptions have made many less social and patient. Yes, national politics is extremely polarizing with a focus on division and superiority. But most serious people don't feel we were less racist in the '50s even if we appeared more civil. The '50s seem to be some touchstone in common conversation of a more perfect time in the United States. And on the surface in many places people were more 'civil,' but likely just felt the need to hide it better. Today they feel they don't have to, or feel they've been given permission not to hide their true selves. One could say simply that current behavior is more honest or more upfront. Not structurally worse, just more real. So, it comes down to what you'd really like to see, to live. Better behavior, better courtesy or the gritty reality of who we are. I would hope they could be one and the same, but alas, it's not to be and we are left to ponder which direction we're going. There's a lot we can't control, only ourselves. The oft misattributed quote says: "If you can be anything, be kind." My grandma would add, "It wouldn't kill ya." ◀



This article has no commercial sponsorship.

Dr. Blecher is an attending surgeon at Wills Eye Hospital.



**tyrvaya**<sup>®</sup>  
(varenicline solution)  
nasal spray 0.03 mg

FOR THE SIGNS  
& SYMPTOMS OF  
DRY EYE DISEASE

SHE'S LOOKING TO YOU FOR A  
DIFFERENT APPROACH WHEN  
ARTIFICIAL TEARS ARE NOT ENOUGH.<sup>1</sup>

BEFORE ANOTHER DROP

# ACTIVATE REAL TEARS

WITH THE FIRST AND ONLY NASAL  
SPRAY FOR DRY EYE<sup>2</sup>



## Tyrvaya<sup>®</sup> is not another drop

It's an **ocular surface-sparing** nasal spray.<sup>2</sup>



## Activates real, basal tears

Tyrvaya<sup>®</sup> is believed to work by activating the trigeminal parasympathetic pathway resulting in **basal tear production**.<sup>2\*</sup>



## Real tears, real fast

In 2 clinical trials with **mild, moderate, and severe** dry eye disease patients, Tyrvaya increased tear production from baseline by **≥10 mm in Schirmer's Test Score (STS) in nearly 50% of patients at week 4**, with increased tears seen as early as the first dose and over 12 weeks.<sup>2-8†</sup>

SEE WHAT  
TYRVAYA  
CAN DO



\*The exact mechanism of action is unknown.

†Tyrvaya was evaluated across 3 randomized, vehicle-controlled, double-masked studies in which adults aged ≥22 years diagnosed with dry eye disease received 1 spray of either active drug or vehicle in each nostril twice daily. Primary endpoint: % of patients with mean change from baseline in STS of ≥10 mm at week 4 in ONSET-1: 52% with Tyrvaya (n=48) vs 14% with vehicle (n=43) and in ONSET-2: 47% with Tyrvaya (n=260) vs 28% with vehicle (n=252). Onset of action: mean change from baseline in STS ~5 minutes after first dose (not a prespecified endpoint) in ONSET-1 was 17.2 mm with Tyrvaya (n=48) vs 4.0 mm with vehicle (n=43) and in ONSET-2 was 16.5 mm with Tyrvaya (n=260) vs 6.9 mm with vehicle (n=251). Observed data. On Day 1 in clinical studies, a baseline anesthetized Schirmer's test was performed. Tyrvaya was then administered concurrently with Schirmer's test. Schirmer's test results were measured at ~5 minutes. Mean change from baseline in STS at week 12 in the MYSTIC study was 10.8 mm with Tyrvaya vs 6.0 mm with vehicle. Limitations: Ex-US, single-center study. All subjects were Hispanic or Latino. Tyrvaya group mean baseline STS 5.5 mm (n=41); vehicle group mean baseline STS 5.3 mm (n=41). All randomized and treated patients were included in the analysis and missing data were imputed using last-available data.<sup>2-8</sup>  
**See references on next page.**

## Indication

Tyrvaya<sup>®</sup> (varenicline solution) nasal spray is indicated for the treatment of the signs and symptoms of dry eye disease.

## Important Safety Information

The most common adverse reaction reported in 82% of patients was sneezing. Events that were reported in 5-16% of patients were cough, throat irritation, and instillation-site (nose) irritation.

Please see Brief Summary of Prescribing Information on the next page and the full Prescribing Information at [Tyrvaya-pro.com](http://Tyrvaya-pro.com).

**BRIEF SUMMARY:** Consult the full Prescribing Information for complete product information available at [www.tyrvaya-pro.com](http://www.tyrvaya-pro.com).

### **INDICATIONS AND USAGE**

TYRVAYA® (varenicline solution) nasal spray is a cholinergic agonist indicated for the treatment of the signs and symptoms of dry eye disease.

### **ADVERSE REACTIONS**

**Clinical Trials Experience:** Because clinical trials are conducted under widely varying conditions, adverse reaction rates observed in the clinical trials of a drug cannot be directly compared to rates in the clinical trials of another drug and may not reflect the rates observed in practice.

In three clinical trials of dry eye disease conducted with varenicline solution nasal spray, 349 patients received at least 1 dose of TYRVAYA. The majority of patients had 31 days of treatment exposure, with a maximum exposure of 105 days.

The most common adverse reactions reported in 82% of TYRVAYA treated patients was sneezing. Other common adverse reactions that were reported in >5% of patients include cough (16%), throat irritation (13%), and instillation-site (nose) irritation (8%).

### **USE IN SPECIFIC POPULATIONS**

**Pregnancy: Risk Summary:** There are no available data on TYRVAYA use in pregnant women to inform any drug associated risks. In animal reproduction studies, varenicline did not produce malformations at clinically relevant doses.

All pregnancies have a risk of birth defect, loss, or other adverse outcomes. In the US general population, the estimated background risk of

major birth defects and miscarriage in clinically recognized pregnancies is 2% to 4% and 15% to 20%, respectively.

**Data: Animal Data:** Pregnant rats and rabbits received varenicline succinate during organogenesis at oral doses up to 15 and 30 mg/kg/day, respectively. While no fetal structural abnormalities occurred in either species, maternal toxicity, characterized by reduced body weight gain, and reduced fetal weights occurred in rabbits at the highest dose (4864 times the MRHD on a mg/m<sup>2</sup> basis).

In a pre- and postnatal development study, pregnant rats received up to 15 mg/kg/day of oral varenicline succinate from organogenesis through lactation. Maternal toxicity, characterized by a decrease in body weight gain, was observed at 15 mg/kg/day (1216 times the MRHD on a mg/m<sup>2</sup> basis). Decreased fertility and increased auditory startle response occurred in offspring at the highest maternal dose of 15 mg/kg/day.

**Lactation: Risk summary:** There are no data on the presence of varenicline in human milk, the effects on the breastfed infant, or the effects on milk production. In animal studies varenicline was present in milk of lactating rats. However, due to species-specific differences in lactation physiology, animal data may not reliably predict drug levels in human milk.

The lack of clinical data during lactation precludes a clear determination of the risk of TYRVAYA to an infant during lactation; however, the developmental and health benefits of breastfeeding should be considered along with the mother's clinical need for TYRVAYA and any potential adverse effects on the breastfed child from TYRVAYA.

**Pediatric Use:** Safety and efficacy of TYRVAYA in pediatric patients have not been established.

**Geriatric Use:** No overall differences in safety or effectiveness have been observed between elderly and younger adult patients.

**References:** **1.** Jones L, Downie LE, Korb D, et al. *Ocul Surf.* 2017;15(3):575-628. **2.** Tyrvaya. Prescribing Information. Oyster Point Pharma; 2021. **3.** Oyster Point Pharma. Data on file. OPP-002 (ONSET-1) Clinical Study Report. August 4, 2019. **4.** Oyster Point Pharma. Data on file. OPP-101 (ONSET-2) Interim Clinical Study Report. October 13, 2020. **5.** Quiroz-Mercado H, Hernandez-Quintela E, Chiu KH, Henry E, Nau JA. *Ocul Surf.* 2022;24:15-21. **6.** Wirta D, Torkildsen GL, Boehmer B, et al. *Cornea.* 2022;4(10):1207-1216. **7.** Wirta D, Vollmer P, Paauw J, et al. *Ophthalmology.* 2021;0(0):379-387. **8.** Oyster Point Pharma. Data on file. OPP-004 (MYSTIC) Clinical Study Report. March 19, 2020.

Manufactured for Oyster Point Pharma, Inc. 202 Carnegie Center, Suite 106, Princeton NJ 08540. For more information, visit [www.tyrvaya-pro.com](http://www.tyrvaya-pro.com). To report an adverse event, contact 1-877-EYE-0123.

© 2023 Viatrix Inc. and/or its affiliates. All rights reserved. VIATRIS and the Viatrix Logo are trademarks of Mylan Inc., a Viatrix Company. Oyster Point®, Tyrvaya®, and the Tyrvaya logo are trademarks of Oyster Point Pharma, Inc., a Viatrix company, in the United States and certain jurisdictions. OP-TYR-002308 7/23





EDITED BY ARTURO CHAYET, MD

## REFRACTIVE/CATARACT RUNDOWN

# The Right Time for MSICS and MiLoop

*When confronted with an extremely dense cataract, surgeons may need to consider alternatives to phaco, experts say.*

**LIZ HUNTER**  
SENIOR EDITOR

**P**hacoemulsification may be the mainstream approach to cataract surgery across much of the world, however, the presentation of advanced, hyper-dense lenses requires special consideration. Using phaco in these patients comes with risks, including trauma to the endothelium and surrounding structures, say surgeons. Developing familiarity with techniques such as manual small-incision cataract surgery (MSICS) and tools like the miLoop fragmentation device (Zeiss) can prepare surgeons for these scenarios while making the procedure safer for patients. However, it's not something one can learn overnight, and we spoke with surgeons who advocate for these alternatives in certain cases, but also emphasize the importance of proper training. For those who invest the time, these techniques could be a differentiating component of your practice.

### MSICS Candidates

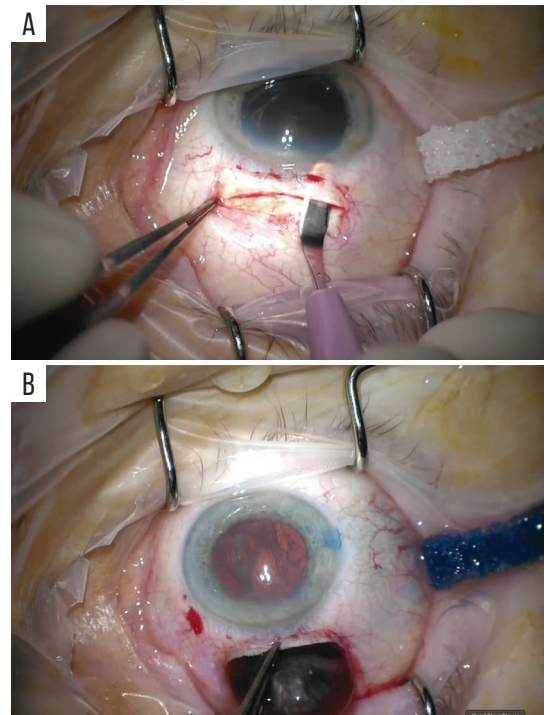
MSICS was designed to address hyper-dense cataracts where phacoemulsification is too risky, or in cases where surgeons don't have access to a phaco machine due to economics, which is why MSICS is commonly used in lower-income and developing countries. Many of these regions are facing a high-volume of patients, and MSICS provides a high-quality, sutureless sur-

gery with a self-sealing tunnel.<sup>1</sup>

Although MSICS may be a natural solution for surgeons in some low- and middle-income countries, for example, it has its place in Western ORs as well. "We may be discussing MSICS in the setting of hyper-dense cataracts, but the technique that's learned with creating these large-diameter scleral tunnels ends up being exquisitely useful to our surgeons in a variety of other situations, such as cases of zonulopathy or in those who have pre-existing endothelial dysfunction—Fuchs' dystrophy being the most common," says Brenton D. Finklea, MD, a surgeon at Wills Eye Hospital in Philadelphia and director of its Center for Academic Global Ophthalmology. "An additional benefit to MSICS is in the setting of completely mobile cataracts. In severe zonulopathy such as with trauma, the cataractous lens may be dislocated into the anterior chamber making phacoemulsification nearly impossible. Taking these cataracts out by way of an intracapsular approach through a large-diameter scleral tunnel may be the least traumatic

approach. The same is true of explanting dislocated PMMA lenses from previous cataract surgeries. The MSICS-style scleral tunnel can be a skill that will really save the day."

Jeff Pettey, MD, the vice-chair of clinical affairs at Moran Eye Center and an associate professor at the University of Utah Department of Ophthalmology and Visual Sciences, says MSICS doesn't rely on fluidics to form the chamber in the same way that phaco does. "As such, you're doing the surgery at relatively low pressures inside the eye so you don't have that extra stress of pressure down into the posterior chamber from a high IOP or a high bottle height, and in a loose zonules case, that can be very well-controlled with MSICS," he says.



Brenton D. Finklea, MD

**Manual small-incision cataract surgery involves creating a scleral tunnel (A) from which the entire cataract can be removed in one piece (B). Some surgeons say the scleral tunnel can be the most difficult aspect of MSICS to learn.**

**This article has no commercial sponsorship.**

**Dr. Chayet** is considered a pioneer in refractive and cataract surgery, and is the medical director of the Codet Vision Institute in Tijuana, Mexico. He is a clinical investigator for RxSight, LensGen and ForSight Vision6.

# DISTANCE PLUS\*

WITHOUT COMPROMISE\*\*1-3



**TECNIS**  
Eyhance™ IOL

Also available in TECNIS™ Toric II

TECNIS Eyhance™ IOL redefines and surpasses what's been done with standard IOLs.\*1,2

Johnson & Johnson  
MedTech

SEE THE DATA



\*The TECNIS Eyhance™ IOLs are designed to slightly extend the depth of focus compared to the TECNIS™ 1-Piece IOL, Model ZCB00 as measured in bench testing.  
\*\*Best contrast and low light performance day and night vs Acrysof® IQ (SN60WF), Clareon® (CNA0T0), Vivinex™ (XY1), enVista® (MX60E) and Acrysof® (SA60AT).

#### REFERENCES:

1. REF2022CT4107 Z311524E\_A TECNIS Eyhance™ IOL with TECNIS SIMPLICITY™ Delivery System US DFU.
2. REF2021CT4007 Z311525E\_A TECNIS Eyhance™ Toric II IOL with TECNIS SIMPLICITY™ Delivery System DFU.
3. DOF2021CT4002 - RUSH: TECNIS Eyhance™ IOL Monofocal Competitors MTF – US.

#### INDICATIONS and IMPORTANT SAFETY INFORMATION for TECNIS Eyhance™ and TECNIS Eyhance™ Toric II IOLs with TECNIS SIMPLICITY™ Delivery System

##### Rx Only

**INDICATIONS FOR USE:** The TECNIS SIMPLICITY™ Delivery System is used to fold and assist in inserting the TECNIS Eyhance™ IOL for the visual correction of aphakia in adult patients in whom a cataractous lens has been removed by extracapsular cataract extraction. The lens is intended to be placed in the capsular bag. The TECNIS SIMPLICITY™ Delivery System is used to fold and assist in inserting the TECNIS Eyhance™ Toric II IOLs for the visual correction of aphakia and pre-existing corneal astigmatism of one diopter or greater in adult patients with or without presbyopia in whom a cataractous lens has been removed by phacoemulsification and who desire reduction in residual refractive cylinder. The lens is intended to be placed in the capsular bag.

**WARNINGS:** Physicians considering lens implantation should weigh the potential risk/benefit ratio for any conditions described in the Directions for Use that could increase complications or impact patient outcomes. The lens should be placed entirely in the capsular bag. Do not place the lens in the ciliary sulcus. Rotation of the TECNIS Eyhance™ Toric II IOL from its intended axis can reduce its astigmatic correction. Misalignment greater than 30° may increase postoperative refractive cylinder. If necessary, lens repositioning should occur as early as possible, prior to lens encapsulation. Do not attempt to disassemble, modify or alter the delivery system or any of its components, as this can significantly affect the function and/or structural integrity of the design. Do not implant the lens if the rod tip does not advance the lens or if it is jammed in the delivery system. The lens and delivery system should be discarded if the lens has been folded within the cartridge for more than 10 minutes.

**PRECAUTIONS:** The safety and effectiveness of the TECNIS Eyhance™ IOL has not been substantiated in clinical trials and the effects of the optical design on quality of vision, contrast sensitivity, and subjective visual disturbances (glare, halo, etc.) have not been evaluated clinically. This is a single use device, do not resterilize the lens or the delivery system. Do not store the device in direct sunlight or at a temperature under 5°C (41°F) or over 35°C (95°F). Do not autoclave the delivery system. Do not advance the lens unless ready for lens implantation. The contents are sterile unless the package is opened or damaged. The recommended temperature for implanting the lens is at least 17°C (63°F). The use of balanced salt solution or viscoelastics is required when using the delivery system. Do not use if the delivery system has been dropped or if any part was inadvertently struck while outside the shipping box.

**ADVERSE EVENTS:** The most frequently reported cumulative adverse event that occurred during the SENSOR® 1-Piece IOL clinical trial was cystoid macular edema which occurred at a rate of 3.3%.

**ATTENTION:** Reference the Directions for Use for a complete listing of Indications and Important Safety Information.

Third party trademarks are the property of their respective owners.  
© Johnson & Johnson Surgical Vision, Inc. 2024 2024PP04732



MSICS may have particular benefit for reducing the risk of loss of lens fragments into the posterior segment should capsular disruption occur, Dr. Finklea says. “The way that the hydrodynamics work for phacoemulsification is you have a highly pressurized anterior chamber relative to a low-pressure posterior chamber,” he explains. “If there’s any disruption in that capsule diaphragm, the pressure gradient is going to push lens material from the anterior segment into the posterior segment—you’re going to lose a lens that way. In MSICS you have the reverse situation, where you have a higher standing pressure in the posterior segment than you do in the anterior segment, where the pressure is functionally zero once you’ve opened your main incision. If you do have a disruption of the lens capsule, it’s very uncommon for the lens to move posterior unless the patient has had a prior vitrectomy. In low-resource settings where you may not have access to pars plana vitrectomy and lensectomy, MSICS may confer an overall lower risk of losing nuclear material into the posterior segment. Even when full access to surgical care is available, MSICS may be the best choice if you think there’s a high risk for loss of lens or capsular support.”

Dr. Pettey says MSICS is also useful in significant corneal opacity. “If you have real difficulty seeing the anterior capsule, whether or not you’ve been able to perfectly complete the continuous curvilinear capsulorhexis, which is essentially a requisite for phaco,” he says. “In contrast, in MSICS, other capsulotomy methods don’t rely on that same level of visualization through the cornea, and you can still have an excellent outcome removing the lens.”

## MSICS Techniques

Employing and succeeding with MSICS comes down to training, say surgeons. “MSICS has much faster visual recovery for dense lenses,” says Dr. Pettey. “This has been shown over and over in multiple studies. Ultimately, the result of MSICS vs. phaco can be relatively equivalent in the surgeon’s



The miLoop is a phaco-sparing device that can be used to break up a dense cataract.

hands, depending on their skill set. In many ways, it depends on the surgeon and their comfort level and skill with each technique.”

Dr. Pettey, like most surgeons in the United States, only trained in phaco initially, but now has skill in both techniques. “Depending on how someone trained, if they trained primarily in phaco and never trained to do any extracapsular or MSICS, then they’re always going to do phaco,” he says. “In contrast, partners worldwide who trained primarily in MSICS and never really trained in phaco will do MSICS for their cases. For those of us with dual skills, it depends

“**Ultimately, the result of MSICS vs. phaco can be relatively equivalent in the surgeon’s hands, depending on their skill set. In many ways, it depends on the surgeon and their comfort level and skill with each technique.**

— Jeff Pettey, MD

on our comfort level. I trained entirely in phaco and MSICS later while working around the world, so for me, phaco is still the most comfortable. However, there are certain cases, such as extremely dense hard lenses, where doing phaco will give me a worse outcome than if I can do MSICS.”

The biggest difference between phacoemulsification, and subsequently the greatest hurdle to learning MSICS, is creating the scleral tunnel. “Tunneling isn’t commonly taught in U.S.

residency programs, and it is a bit of a dying art,” says Dr. Finklea. “If you didn’t train 20 years ago or beyond, it’s unlikely that scleral tunnels were a significant component of your surgical training. That’s something we’ve tried to emphasize as part of the Wills resident curriculum, so that our trainees graduate with wetlab experience and a handful of surgical cases to introduce them to these techniques.”

But once surgeons can master the self-sealing scleral tunnel, they’ll realize that the rest of the steps in MSICS are similar to phaco. “For a competent phaco surgeon, the key is the self-sealing tunnel,” Dr. Pettey says. “With a well-constructed wound, they can do a nice MSICS using their existing skill set. They could do a large CCC, hydro-express the lens into the anterior chamber during hydrodissection, and then use a lens loop to extract the lens. They could then use bimanual I/A to remove all of the cortex. The reason you’re using bimanual is because that large self-sealing wound really does cause an unstable chamber during cortical removal or viscoelastic removal. At that point, you put in your lens, and if that wound is self-sealing, you’re done with the surgery after you clear up the viscoelastic.”

Dr. Finklea says his technique is fairly standard and is the one Wills has determined to be most teachable. “I try to maintain a style of surgery that’s easily transferable,” he says. “That being said, there are a few changes which have been made to modernize the procedure as much as possible. Of course, we try to minimize the diameter of our scleral tunnel to keep the surgically induced astigmatism to a minimum. Frown-shaped incisions and longer tunnels can

aid in this as well. Additionally, at the end of every surgery I put a single compression suture into the scleral tunnel in order to further reduce the against-the-rule astigmatism that's common with superior-approach MSICS."

Counteracting astigmatism is something Dr. Finklea takes into consideration when positioning his body in the OR. "I always review topographies prior to surgery, and attempt to operate on axis. For example, if the patient has 2 D of against-the-rule astigmatism, I'll usually operate from a temporal approach to try and induce with-the-rule astigmatism to cancel that out," he says. "A more purposeful approach to minimizing astigmatism is one of the changes that we've made."

Most of the literature on MSICS includes different techniques for anterior capsulotomies, although the continuous curvilinear capsulorhexis is usually preferred, says Dr. Finklea. "We really try to maintain a continuous curvilinear capsulorhexis just to make sure that we're centering our lenses as consistently as possible and that we're not having any unexpected tear outs," he says.

Phaco surgeons may even find themselves in the situation where converting to MSICS might be for the best—if they know how. "We've all been in situations where we get into a lens with phaco and realize that it doesn't end well for the eye because the lens is too dense," Dr. Pettey says. "If you have a phaco incision made, which occurs the vast majority of the time, creating that self-sealing scleral tunnel can be challenging if you're doing that through the phaco wound. If you do MSICS conversion after making a phaco incision, then you need to rotate 90 degrees to the superior approach.

"One thing that you could do if you're concerned or questioning whether or not you'll need to convert is to do your initial capsulotomy through a paracentesis so you don't create a phaco incision," he continues. "Those steps would be: make your paracentesis incision, inject lidocaine with epinephrine,

viscoelastic and then insert a microtrata through your paracentesis. Create your large capsulorhexis and then test the lens through that paracentesis to see how dense it is and how likely it will be able to be done by phaco or MSICS. At that point, if you've decided it's phacable, you make your temporal incision and continue with phaco, and if you choose to use MSICS, you make your SICS incision and proceed. It's not so much a planned conversion, it's about keeping all options on the table."

U.S. surgeons who want to learn MSICS are at a bit of a disadvantage because there's not a high volume of candidates. "As a phaco surgeon, you may have one a month that might be a good candidate, but only doing one a month isn't enough volume for you to develop muscle memory and consistency in most circumstances for a brand-new technique," explains Dr. Pettey. He says the best pathway to learning MSICS is the following:

- familiarize yourself with textbooks and videos;
- find a mentor that you can do the surgeries with; and
- do enough cases in a short time frame where you can develop a lot of the muscle memory required for consistency and safe surgery.

Wet labs and model eyes are options to consider, continues Dr. Pettey. "Pig eyes are perfect for learning a scleral tunnel," he says. "They're an ideal surrogate, and people can gain mastery of the scleral tunnel on their own doing pig eye wet labs; contact your local

academic program. There are available simulators. Suppose you want to use model eyes, such as Bioniko, which has an MSICS simulator. And as far as I know, there's an MSICS simulator in the Kitaro. Both models are helpful for learning the mobilization of the lens inside the eye and removing the lens, but they aren't suitable for scleral tunnels."

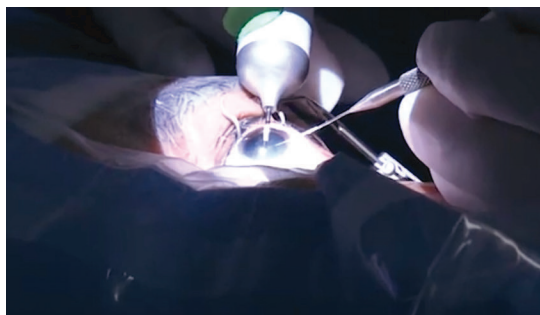
## Where miLoop Fits In

When MSICS comes up in conversation, the miLoop device is often mentioned along with it because it's also phaco-sparing for dense lenses.

According to Kira Manusi, MD, who is a cornea and cataract specialist at New York Eye and Ear Infirmary of Mount Sinai, the device was created by a colleague, Sean Ianchulev, MD. "He was in Italy and he was watching them slice hard cheese with a wire," she recalls. "He thought, what if, in these super dense lenses you could just slice them? The key with miLoop is a very thin nitinol filament. You open the filament in the eye and you rotate the loop around the lens and close it to essentially slice that lens in half just like you would slice cheese."

She says the fact that miLoop slices from the outside in is key because of the posterior plate. "Even the most amazing surgeon in the world, when we either chop or use any type of fragmentation technique—a femtosecond laser, phaco chop or divide and conquer—we usually do it from the inside out," Dr. Manusi continues. "We try to be very careful when it comes to getting close to the

posterior capsule so we don't break it and that's where that posterior plate is. It's usually thick and it's very hard to separate the pieces to debulk the lens. There's really very little you can do other than chopping into smaller and smaller pieces. You just have to take your time and be diligent to do that in order to preserve the capsule. But that posterior plate is very hard to break and what miLoop does is it actually goes behind that plate and slices from outside in. That's really huge in some of these cases



Kira Manusi, MD

**The miLoop can be operated with one hand and features a slide bar for opening and closing the nitinol ring. Surgeons say it's important to practice this technique on normal cataracts to become comfortable, and to avoid using miLoop in cases with zonulopathy.**



because the most challenging things are to fragment the lens and break up that posterior plate.”

The miLoop is a single-use device and can be operated with one hand. The handle contains a slide bar which opens and closes the ring. Dr. Manuasis says it's important to open and close the device as a test just once before putting it into the eye. “The latest versions of miLoop only allow you to open and close it three times total and then it locks itself,” she advises.

“Once you see that it's working, close it and insert it sideways through your main incision and hold your finger on the button that actually allows you to open and close the miLoop,” explains Dr. Manuasis. “Once the miLoop is in the lens plane being held sideways, you start to open it so it's facing to the right—it should always be to the right, this is the only way it opens up. You want that loop to go under your anterior capsule. Ideally you want a well-dilated pupil and a large capsulorhexis. You definitely want to have a good hydrodissection to make sure the lens is mobile, and what I do sometimes is put a little viscoelastic under the anterior capsule, especially in the area where miLoop is going to enter to make it a little smoother and easier for you to visualize. Then, start opening miLoop slowly and you watch it go under your anterior capsule and then disappear under your iris and you want to open it to your right. The miLoop has to stay centered.”

One of the biggest mistakes Dr. Pettey sees with miLoop is people pushing it too far into the eye. “The original miLoop had a mark that you would put into the limbus; the new miLoop doesn't have a mark but has a little cushion that helps you know when you're in far enough,” he says. “The challenge is that anatomy isn't all the same. In the early cases, most learners will push the miLoop too far inside of the eye rather than keeping that injector proximal toward the wound.”

Once the miLoop is open, you want to stay centered and start rotating clockwise, says Dr. Manuasis. “Surgeons should be able to see the wire moving

below the lens if it's not too dense,” she continues. “Turn it 90 degrees to encircle the lens completely. If you can't see because the lens is so dense you'll know by the position of your fingers in relation to the loop. When I'm ready to close the loop, I usually put my second instrument into the eye to help stabilize the lens as I'm closing. Generally, it will slice it just like it would slice cheese or slice butter. It should go through it very, very nicely. If I slice it into halves, sometimes I'll push one half back into the bag with my second instrument and leave the second half prolapsed up so I can go in and chop it further or phaco it, whichever. Some people use that second instrument to push the lens back into the bag to make sure that it stays in the bag. After slicing it once, you can use your second instrument to rotate 90 degrees and slice it one more time into quadrants. All of that's done without the use of any energy because MiLoop doesn't require any energy. Once you slice it the second time you can use that second instrument to help keep the pieces in the bag or help get one of these quadrants out of the bag to make it easier for you to start phaco.”

Dr. Manuasis says using miLoop is relatively quick compared to the amount of time it would take to phaco a hyperdense cataract.

There are concerns with miLoop's use in the event of zonulopathy. “If I think the lens is so dense and the chamber is so shallow where, even with the use of miLoop, there may be significant trauma to the endothelium, MSICS is a little bit more gentle because you're not using any phaco,” she says. “Also, if you have a super shallow chamber and there's very little room in the eye, sometimes it's difficult to insert miLoop and get it chopped just because of anatomy, so in that case we may want to do MSICS.”

Dr. Finklea also has a few reservations with the device and says surgeons shouldn't just grab for it without practicing in a wetlab setting or on routine cases. “It's a really nice technology that at least reduces one of the potential risk points in phacoemulsification which is

simply dividing the lens into fragments in the setting of a leathery posterior plate,” he says. “My biggest qualm with it is the potential for zonular strain, which can be minimized but not completely avoided. Many of these severely advanced cataracts also have comorbid zonulopathy and occasionally miLoop-assisted lens fragmentation can be the straw that breaks the camel's back. If miLoop is something that you plan to use on a regular basis, then master the tool in a controlled setting before employing it on the most challenging eyes.”

Dr. Manuasis instructs residents to try miLoop on routine cataracts first to get comfortable with the instrument before using it on denser lenses. “Every time you use it you get more experience and you get more comfortable,” she says. “One pearl that I've learned for myself is when I do my capsulorhexis to try to see how good the zonules are. I definitely don't use miLoop in cases that have significant zonulopathy because, in my hands, just the sweep of that loop can sometimes tug on the zonules.”

### Skills Trump Technique

In the end there's not one technique that's the best for all situations, it's going to be whatever the best technique is in a particular surgeon's hands, says Dr. Finklea. “If you decide that you're going to begin offering MSICS surgery, you will need to make a significant time investment in acquiring the skill set. Wetlabs and surgical mentorship will set the stage for a successful transition into this technique. For many phaco surgeons, it may not be feasible to invest the time and resources into becoming fully proficient in MSICS. These individuals will best be served by endeavoring in the most up-to-date phaco equipment and techniques to tackle these most challenging of cases.” ◀

1. Gurnani B, Kaur K. Manual Small Incision Cataract Surgery. Stat Pearls. Treasure Island (FL): StatPearls Publishing 2023.

### DISCLOSURES

Dr. Finklea and Dr. Manuasis have no relevant disclosures. Dr. Pettey consults for Zeiss.

**ILEVRO<sup>®</sup>**  
(nepafenac ophthalmic  
suspension) 0.3%

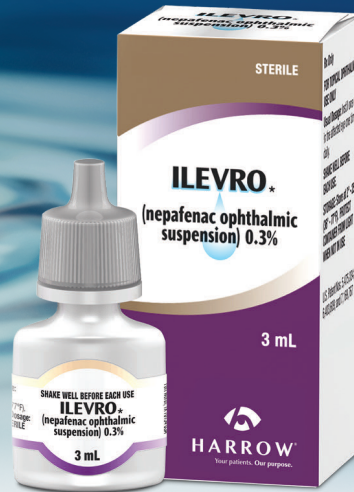For your cataract surgery patients

# STRIKE

AT

## INFLAMMATION AND PAIN

Effective. Convenient. Accessible.



Learn more at  
[ILEVROHCP.com](http://ILEVROHCP.com)

### INDICATIONS AND USAGE

ILEVRO<sup>®</sup> (nepafenac ophthalmic suspension) 0.3% is a nonsteroidal, anti-inflammatory prodrug indicated for the treatment of pain and inflammation associated with cataract surgery.

### Dosage and Administration

One drop of ILEVRO<sup>®</sup> 0.3% should be applied to the affected eye one-time-daily beginning 1 day prior to cataract surgery, continued on the day of surgery and through the first 2 weeks of the postoperative period. An additional drop should be administered 30 to 120 minutes prior to surgery.

### IMPORTANT SAFETY INFORMATION

#### Contraindications

ILEVRO<sup>®</sup> 0.3% is contraindicated in patients with previously demonstrated hypersensitivity to any of the ingredients in the formula or to other nonsteroidal anti-inflammatory drugs (NSAIDs).

#### Adverse Reactions

The most frequently reported ocular adverse reactions following cataract surgery occurring in approximately 5% to 10% of patients were capsular opacity, decreased visual acuity, foreign body sensation, increased intraocular pressure, and sticky sensation.

For additional information about ILEVRO<sup>®</sup> 0.3%, please see the Brief Summary of Full Prescribing Information on the following page or visit [ilevrohcp.com](http://ilevrohcp.com).

**Reference:** ILEVRO (nepafenac ophthalmic suspension) 0.3% [package insert]. Harrow IP LLC; 2023.

ILEVRO, the ILEVRO logo, and the Harrow logo are registered trademarks of Harrow IP, LLC.  
IVRO-00052 02/24 © 2024 Harrow. All Rights Reserved.

  
**HARROW<sup>®</sup>**  
Your patients. Our purpose.



# ILEVRO®

(nepafenac ophthalmic suspension) 0.3%

## BRIEF SUMMARY OF PRESCRIBING INFORMATION

### INDICATIONS AND USAGE

ILEVRO® (nepafenac ophthalmic suspension) 0.3% is indicated for the treatment of pain and inflammation associated with cataract surgery.

### DOSAGE AND ADMINISTRATION

#### Recommended Dosing

One drop of ILEVRO® Suspension should be applied to the affected eye one-time-daily beginning 1 day prior to cataract surgery, continued on the day of surgery and through the first 2 weeks of the postoperative period. An additional drop should be administered 30 to 120 minutes prior to surgery.

#### Use with Other Topical Ophthalmic Medications

ILEVRO® Suspension may be administered in conjunction with other topical ophthalmic medications such as beta-blockers, carbonic anhydrase inhibitors, alpha-agonists, cycloplegics, and mydriatics. If more than one topical ophthalmic medication is being used, the medicines must be administered at least 5 minutes apart.

### CONTRAINDICATIONS

ILEVRO® Suspension is contraindicated in patients with previously demonstrated hypersensitivity to any of the ingredients in the formula or to other NSAIDs.

### WARNINGS AND PRECAUTIONS

#### Increased Bleeding Time

With some nonsteroidal anti-inflammatory drugs including ILEVRO® Suspension, there exists the potential for increased bleeding time due to interference with thrombocyte aggregation. There have been reports that ocularly applied nonsteroidal anti-inflammatory drugs may cause increased bleeding of ocular tissues (including hyphemas) in conjunction with ocular surgery. It is recommended that ILEVRO® Suspension be used with caution in patients with known bleeding tendencies or who are receiving other medications which may prolong bleeding time.

#### Delayed Healing

Topical nonsteroidal anti-inflammatory drugs (NSAIDs) including ILEVRO® Suspension, may slow or delay healing. Topical corticosteroids are also known to slow or delay healing. Concomitant use of topical NSAIDs and topical steroids may increase the potential for healing problems.

#### Corneal Effects

Use of topical NSAIDs may result in keratitis. In some susceptible patients, continued use of topical NSAIDs may result in epithelial breakdown, corneal thinning, corneal erosion, corneal ulceration or corneal perforation. These events may be sight threatening. Patients with evidence of corneal epithelial breakdown should immediately discontinue use of topical NSAIDs including ILEVRO® Suspension and should be closely monitored for corneal health. Post marketing experience with topical NSAIDs suggests that patients with complicated ocular surgeries, corneal denervation, corneal epithelial defects, diabetes mellitus, ocular surface diseases (e.g., dry eye syndrome), rheumatoid arthritis, or repeat ocular surgeries within a short period of time may be at increased risk for corneal adverse events which may become sight threatening. Topical NSAIDs should be used with caution in these patients. Post marketing experience with topical NSAIDs also suggests that use more than 1 day prior to surgery or use beyond

14 days post-surgery may increase patient risk and severity of corneal adverse events.

#### Contact Lens Wear

ILEVRO® Suspension should not be administered while using contact lenses.

### ADVERSE REACTIONS

Because clinical studies are conducted under widely varying conditions, adverse reaction rates observed in the clinical studies of a drug cannot be directly compared to the rates in the clinical studies of another drug and may not reflect the rates observed in practice.

#### Serious and Otherwise Important Adverse Reactions

The following adverse reactions are discussed in greater detail in other sections of labeling:

- Increased Bleeding Time (Warnings and Precautions)
- Delayed Healing (Warnings and Precautions)
- Corneal Effects (Warnings and Precautions)

#### Ocular Adverse Reactions

The most frequently reported ocular adverse reactions following cataract surgery were capsular opacity, decreased visual acuity, foreign body sensation, increased intraocular pressure, and sticky sensation. These reactions occurred in approximately 5 to 10% of patients.

Other ocular adverse reactions occurring at an incidence of approximately 1 to 5% included conjunctival edema, corneal edema, dry eye, lid margin crusting, ocular discomfort, ocular hyperemia, ocular pain, ocular pruritus, photophobia, tearing and vitreous detachment.

Some of these reactions may be the consequence of the cataract surgical procedure.

#### Non-Ocular Adverse Reactions

Non-ocular adverse reactions reported at an incidence of 1 to 4% included headache, hypertension, nausea/vomiting, and sinusitis.

### USE IN SPECIFIC POPULATIONS

#### Pregnancy

##### Teratogenic Effects.

**Pregnancy Category C:** Reproduction studies performed with nepafenac in rabbits and rats at oral doses up to 10 mg/kg/day have revealed no evidence of teratogenicity due to nepafenac, despite the induction of maternal toxicity. At this dose, the animal plasma exposure to nepafenac and amfenac was approximately 70 and 630 times human plasma exposure at the recommended human topical ophthalmic dose for rats and 20 and 180 times human plasma exposure for rabbits, respectively. In rats, maternally toxic doses  $\geq 10$  mg/kg were associated with dystocia, increased postimplantation loss, reduced fetal weights and growth, and reduced fetal survival.

Nepafenac has been shown to cross the placental barrier in rats. There are no adequate and well-controlled studies in pregnant women. Because animal reproduction studies are not always predictive of human response, ILEVRO® Suspension should be used during pregnancy only if the potential benefit justifies the potential risk to the fetus.

#### Non-teratogenic Effects

Because of the known effects of prostaglandin biosynthesis inhibiting drugs on the fetal cardiovascular system (closure of the ductus arteriosus), the use of ILEVRO® Suspension during late pregnancy should be avoided.

#### Nursing Mothers

ILEVRO® Suspension is excreted in the milk of lactating rats. It is not known whether this drug is excreted in human milk. Because many drugs are excreted in human milk, caution should be exercised when

ILEVRO® Suspension is administered to a nursing woman.

#### Pediatric Use

The safety and effectiveness of ILEVRO® Suspension in pediatric patients below the age of 10 years have not been established.

#### Geriatric Use

No overall differences in safety and effectiveness have been observed between elderly and younger patients.

#### NONCLINICAL TOXICOLOGY Carcinogenesis, Mutagenesis, Impairment of Fertility

Nepafenac has not been evaluated in long-term carcinogenicity studies. Increased chromosomal aberrations were observed in Chinese hamster ovary cells exposed *in vitro* to nepafenac suspension. Nepafenac was not mutagenic in the Ames assay or in the mouse lymphoma forward mutation assay. Oral doses up to 5,000 mg/kg did not result in an increase in the formation of micronucleated polychromatic erythrocytes *in vivo* in the mouse micronucleus assay in the bone marrow of mice. Nepafenac did not impair fertility when administered orally to male and female rats at 3 mg/kg.

### PATIENT COUNSELING INFORMATION

#### Slow or Delayed Healing

Patients should be informed of the possibility that slow or delayed healing may occur while using nonsteroidal anti-inflammatory drugs (NSAIDs).

#### Avoiding Contamination of the Product

Patients should be instructed to avoid allowing the tip of the dispensing container to contact the eye or surrounding structures because this could cause the tip to become contaminated by common bacteria known to cause ocular infections. Serious damage to the eye and subsequent loss of vision may result from using contaminated solutions.

Use of the same bottle for both eyes is not recommended with topical eye drops that are used in association with surgery.

#### Contact Lens Wear

ILEVRO® Suspension should not be administered while wearing contact lenses.

#### Intercurrent Ocular Conditions

Patients should be advised that if they develop an intercurrent ocular condition (e.g., trauma, or infection) or have ocular surgery, they should immediately seek their physician's advice concerning the continued use of the multi-dose container.

#### Concomitant Topical Ocular Therapy

If more than one topical ophthalmic medication is being used, the medicines must be administered at least 5 minutes apart.

#### Shake Well Before Use

Patients should be instructed to shake well before each use.

U.S. Patent Nos. 5,475,034; 6,403,609; and 7,169,767.

©2023 Harrow 06/23 IVRO-00012



HARROW®

# EVALUATING THE RETINA BEFORE SURGERY

How to factor the retinal exam into the management of increasingly complex cataract and refractive procedures.

SEAN MCKINNEY  
CONTRIBUTING EDITOR

Advancing technology has obviously improved the treatment of eye disease for patients and ophthalmologists alike during the past 20 years. However, some advances have exposed pockets of uncertainty for all specialists involved—one way or another—in cataract and refractive surgery. Varying standards for managing surgical risk to the retina and optimal vision have emerged, spurring a quiet debate among some anterior segment surgeons and retinal specialists.

“Small-incision refractive cataract surgery, femtosecond lasers, wavefront technology, intra-operative aberrometry, new technology IOLs, LASIK, and PRK—combined with today’s marketing—have increased patients’ postop expectations of quality of vision,” says Steve Charles, MD, clinical professor of ophthalmology at the University of Tennessee Hamilton Eye Institute. “There’s a substantial emphasis in our profession on refractive surprises associated with cataract surgery—and an insufficient focus on visual surprises, primarily associated with macular disease,

co-existing with cataract. Avoiding both types of surprises should be priorities.”

In this article, surgeons discuss strategies they have developed—and that you can use—to try to benefit both parts of the eye.

## Prioritizing the Retina

Kendall Donaldson, MD, Medical Director of Bascom Palmer Eye Institute in Plantation, Florida, may be an anterior segment surgeon, but when she’s planning surgery, she says she focuses “from the very start” on the retina. “The retinal exam is an essential component of any anterior segment surgery,” she explains. “With premium lens technology, complex optical mechanisms and high patient expectations, if we overlook even minor retinal pathology, it may yield a devastating visual outcome.”

Often, she acknowledges, patients may present with significant cataracts that not only impact their vision but also preclude detailed visualization of the posterior segment by the surgeon. “For denser cataracts, an ultrasound may provide more general information, revealing potential retinal detachments, tears or—in rare cases—tumors.”

Andrew Kao, MD, a partner at Em-

pire Eye & Laser Center, Bakersfield, California, considers a retinal exam a priority for every surgical patient. “You never know what you’re going to find,” he says. “For example, you may discover that a patient has had a recent retinal tear or a retinal schisis.” Dr. Kao adds that patient expectations also factor into his consideration. “The expectations you communicate to the patient before the surgery can help make sure there are no surprises,” he notes.

According to Doug Grayson, MD, a cataract and glaucoma surgeon at Omni Ophthalmic Management Consultants, a multi-practice group headquartered in Iselin, New Jersey, the more complex you make your preop exam, the more you safeguard patients against untoward events and achieve the highest standards of care.

“There are many pathologies available for discovery now, especially with today’s technologies,” he says. “But if the patient has a real hard white cataract, we have to let the patient know that we can only see so much back there, documenting the conversation.<sup>1</sup> Then, after the cataract has been removed, we may find other pathologies that we have to investigate and take care of.”

This article has no commercial sponsorship.

Dr. Charles has a consulting relationship with Alcon. Dr. Haug has a consulting relationship with Genentech. Dr. Donaldson is a consultant for Johnson & Johnson Vision, Bausch + Lomb, Alcon and Zeiss. Dr. Kao is a consultant and speaker for Glaukos. Dr. Grayson has no related financial disclosures.



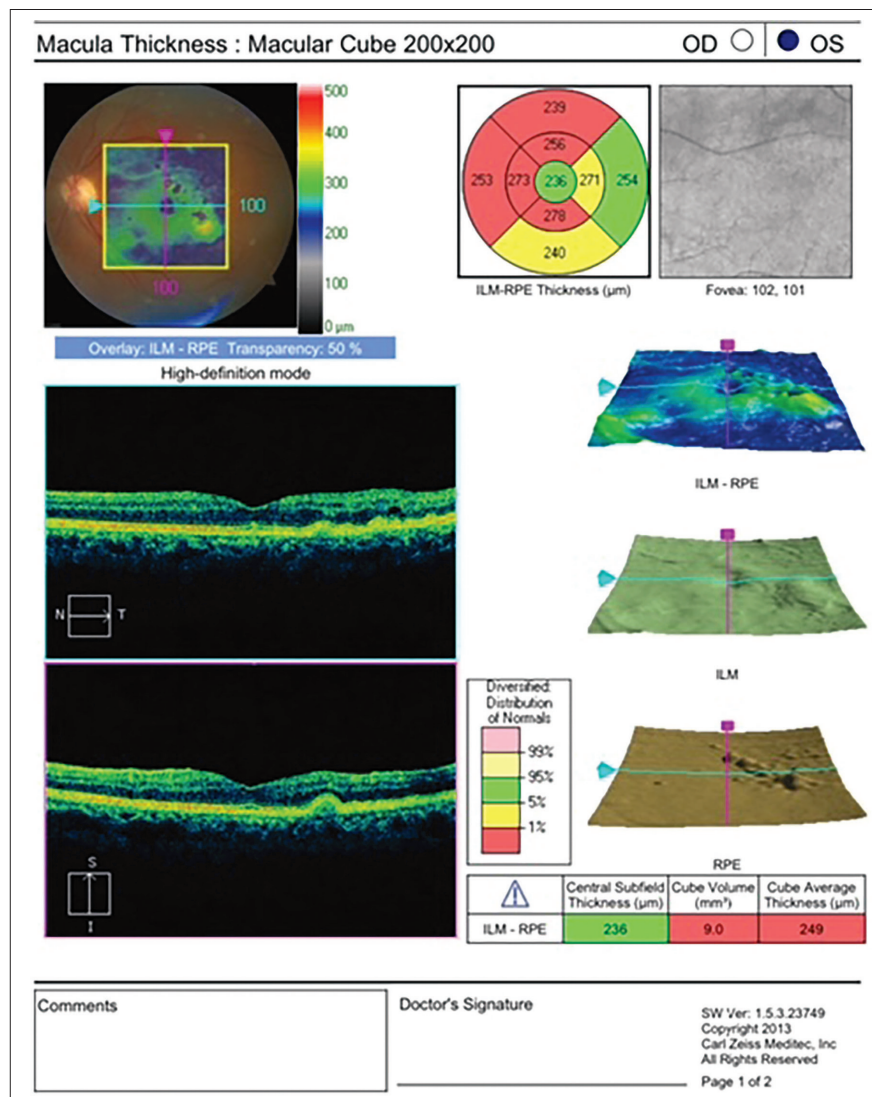
You can best avoid refractive and visual surprises if your patient benefits from a preop retinal exam that involves “clinically appropriate approaches” to identify pathologies—and a preop retinal exam that recognizes the effects that each “clinically appropriate approach” may have on the outcome of surgery, according to Dr. Charles.

“A preop exam of the retina requires the use of specific diagnostic technologies—and using them to potentially uncover overt and subtle manifestations of disease that could rule out certain types of surgery, such as a premium IOL procedure,” he says. Besides the classic suboptimal view of the retina caused by a dense cataract, he lists the following additional challenges that may need to be overcome when managing any given patient:

- insufficient training, knowledge, or emphasis on macular disease;
- fragmentation of care, resulting in separation of the preop examiner and the surgeon;
- older OCT technology;
- the distracting and arguably superfluous display designs of older or newer OCTs, potentially masking scan findings;
- inadequate interpretations of findings;
- macular holes;
- subretinal fluid without bleeding and with a small choroidal neovascularization, found in early age-related macular degeneration; and
- central serous retinopathy.

“It’s also important to keep in mind that A-scan ultrasound axial length measurements may be inaccurate in the presence of any of these conditions,” he continues. “Low coherence optical measurement from the retinal pigment epithelium is mandatory (with the use of IOLMaster, the Lenstar 900 or similar devices).”

Offering a slightly different view on one aspect of preop screening, Sara J. Haug, MD, PhD, a retinal specialist at Southwest Eye Consultants in Durango, Colorado, believes the older, time-domain OCTs can still play a helpful role. “Sure, having the latest



**Figure 1. Many cataract surgeons insist on obtaining an OCT screening for their patients before cataract surgery. Among a number of pathologies, the scan can help rule out dry AMD, evident in this patient’s finding.**

technology is always best,” she acknowledges. “But is it necessary for a cataract surgeon to have the latest and greatest OCT? Probably not. If they see any problems or changes, they can consider a consult with a retinal specialist.” (See “To OCT or Not to OCT Before Cataract Surgery?” on page 31.)

### Critical Preop Decisions

One central question is whether or not to refer every preop patient to a retinal specialist before anterior segment surgery. Dr. Kao says he insists on it for many cataract procedures. “Certain conditions can worsen after cataract surgery, such as diabetic retinopathy,

even if the patient doesn’t have macular edema before surgery,” he says. “The inflammation from the surgery can cause swelling after the procedure. If a patient has moderate diabetic retinopathy, I want the patient to see a retinal specialist first.”<sup>22</sup>

As a retinal specialist, Dr. Haug says she prefers seeing all cataract surgery candidates preoperatively. She explains that she has “a pretty low threshold” for obtaining a fluorescein angiogram in the presence of intermediate macular degeneration or diabetes. “This prevents a postop surprise,” she points out. “The data tells us that treating early wet macular degeneration before cata-

# Bringing You the Best in Class of Diagnostic Visual Testing Systems and Dry Eye Solutions

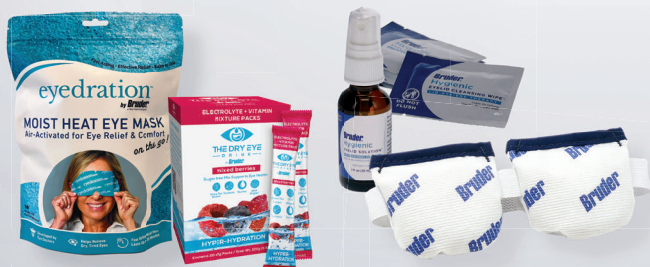

Discover the power of collaboration, with eye care solutions that work together. Hilco Vision companies **Bruder Healthcare** and **M&S Technologies** bring Vision Care Solutions to optometrists and ophthalmologists alike.

## Bruder

### Open Your Eyes to Bruder™

HYGIENE | HEAT | HYDRATION



## M&S TECHNOLOGIES



### Setting the Standard in Computerized Vision Testing

ACCURACY | PRECISION | RELIABILITY



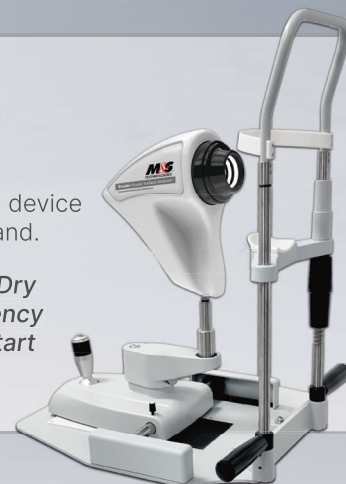SPEED | ACCURACY | EASE OF USE

## Assess Ocular Surface Disease (OSD) in 15 Seconds

Introducing the new M&S Bruder Ocular Surface Analyzer™ (BOSA), an all-in-one, easy-to-use device for dry eye testing, delivering speed, accuracy, and results that patients can see and understand.

*"BOSA provides a ready-made hub to help identify, quantify, and rectify OSD, with recommended treatments tailored to each patient's test results."* —Paul Karpecki, OD, FAAO

*"The answer for both the established Dry Eye practice looking to improve efficiency and the eye care practice looking to start a Dry Eye clinic."* —Darrell White, MD



Want to know more? Contact your Bruder Healthcare or M&S Technologies account representative or visit either website.

[BruderPro.com](http://BruderPro.com) | [MSTech-eyes.com](http://MSTech-eyes.com)



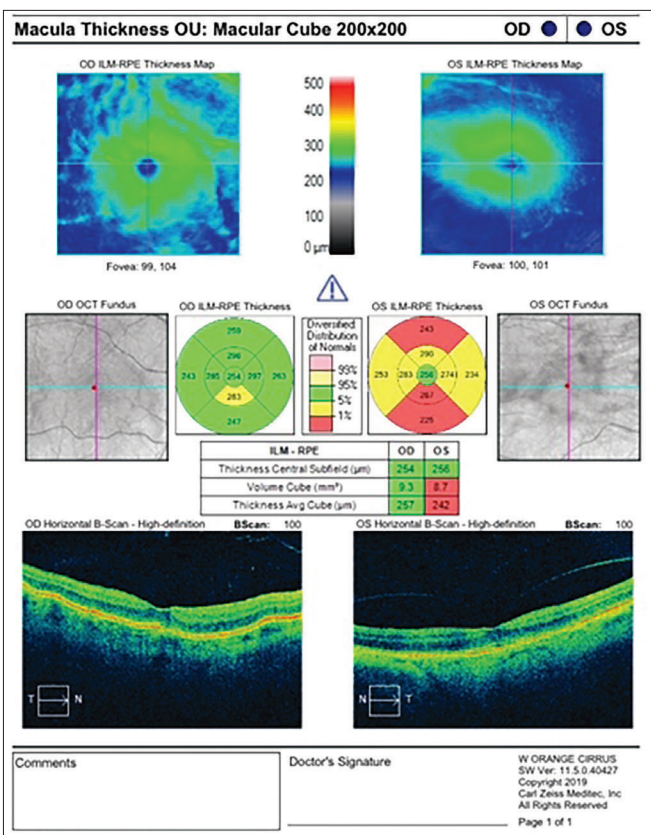
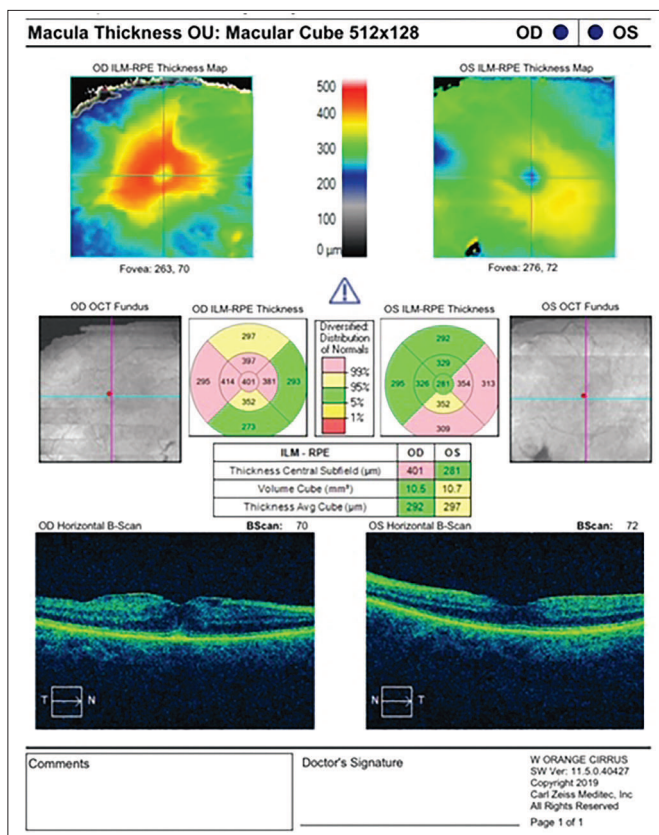
**Bruder**

**HILCO vision**  
VISION CARE SOLUTIONS

**M&S**  
TECHNOLOGIES







**Figure 2.** This patient has an epimacular membrane. Preop and postop topical NSAIDs may be a necessary treatment, as there could be a potential higher incidence of CME. Also, the surgeon should have a detailed discussion with the patient of the potential for cataract surgery to compound the issues related to the epiretinal membrane, and the possible need for retinal surgery.

**Figure 3.** A check of the retina also may be indicated after cataract surgery. In this case, the patient has hypotonous maculopathy, possibly having occurred from a chronic wound leak or ciliary body cleft.

ract surgery, or that making sure that diabetic retinopathy is under reasonable control before the surgery—without macular edema—positively impacts cataract surgery results.<sup>3</sup>

“In these cases, I usually say, ‘Give me a couple months (before performing cataract surgery).’ I definitely want to give one or two anti-VEGF injections before we continue with cataract surgery for these patients.”

Dr. Grayson delays surgery if the patient’s visual acuity isn’t consistent with what he expects, based on his examination, and if he suspects the retina requires attention. “Even when there is a hard cataract, we may hold off,” he says. “We might refer the patient out to one of the two retinal specialists in our practice. It’s always better to get these things cleared beforehand.”

In extreme hyperopes, Dr. Grayson continues, “we may have a patient with

very narrow angles. You don’t want to dilate them. So you have to rely heavily on OCT and any other findings. It makes the case more challenging. You want to look at the OCT as closely as possible and compare what you find at the back of the eye to the patient’s visual acuity.”

Dr. Donaldson refers a patient to a retinal specialist before surgery for two primary reasons: “Number one, if I’m making a new retinal diagnosis that requires treatment before I can safely proceed with surgery, such as a retinal detachment or a diabetic vitreous hemorrhage, and number two, if I’m making a diagnosis of a condition that may evolve or worsen in the near future (with or without surgery). I need to make sure such a patient initiates a relationship with a retinal specialist. I’m thinking of cases when ERM that may develop fluid and evolve into CME

after surgery,<sup>4</sup> or diabetic retinopathy affecting the macula. A new diagnosis of a macular hole that may limit the postop vision is another good reason to have a retina specialist investigate first.”

In the context of these issues, Dr. Grayson adds: “The importance of documentation can’t be overstated. The thing that’s going to matter the most if your patient isn’t satisfied with your surgery—for whatever reason—is what you’ve put in the chart.”

### How to Apply Technologies

Dr. Charles emphasizes judicious use of today’s technologies, noting that “the pseudo-color algorithms, thickness maps, and three-dimensional renderings that are featured by some of today’s OCT devices can hide crucial pathology. Also, the photographer or technician may select a single image for the electronic medical record, and that’s also

## To OCT or Not to OCT Before Cataract Surgery?

Many surgeons and retinal specialists believe a preop OCT is a must before cataract surgery. But not all surgeons agree.

"We don't routinely order a macular OCT for every cataract patient," says Andrew Kao, MD, an anterior segment surgeon and partner at Empire Eye & Laser Center, Bakersfield, California. "That would be a bit cumbersome. If we're doing several hundred cataract consultations in a year, depending on our clinic flow, it may not be feasible to do the OCT on every patient. However, when we do premium IOLs, we routinely do get a macular OCT."

To ensure each case proceeds without surprises, Dr. Kao continues, he relies on "a very good history" for every patient. "If exam findings don't match the level of cataracts or refractive error, a more thorough preop work-up should be done. If there is any clinical suspicion, then, yes, an OCT is appropriate."

Kendall Donaldson, MD, an anterior segment surgeon and the medical director of Bascom Palmer Eye Institute in Plantation, Florida, typically obtains an OCT before every cataract surgery—most significantly before implanting a premium IOL, she notes.<sup>1</sup> "A mild epiretinal membrane may easily be missed during a slit lamp exam through a significant cataract," she says.<sup>2</sup> "This may be a significant impediment to optimal vision if a diffractive multifocal IOL is implanted. Besides an ERM, we also need to be concerned about the possibility of a lamellar hole, a full-thickness macular hole, drusen, dry AMD, wet AMD, diabetic retinopathy, a peripheral retinal tear or a

retinal detachment. To avoid these problems, perform your best slit-lamp exam (not just look at the cataract) and consider a screening macular OCT on all cataract preop patients."

Sara J. Haug, MD, PhD, a retinal specialist at Southwest Eye Consultants in Durango, Colorado, also believes anterior segment surgeons should arrange for an OCT on every patient before cataract surgery. "I think it's pretty standard these days," she says. "Based on the OCT image, they can determine if a retinal consult is required." Doug Grayson, MD, a cataract and glaucoma surgeon at Omni Ophthalmic Management Consultants in Iselin, New Jersey, believes OCTs are critical to use before every cataract surgery. "The OCT could find a lamellar hole, or an epiretinal membrane, or some other pathology that's too hard to see with direct observation," he points out. "It could be diabetic retinopathy, or lesions that are very difficult to see without OCT."

Steve Charles, MD, clinical professor of ophthalmology at the University of Tennessee Hamilton Eye Institute, is another firm believer in OCT before surgery. "The presence of many critical macular diseases are simply invisible without the use of spectral domain or swept source OCT," he says.

1. Ahmed TM, Siddiqui MAR, Hussain B. Optical coherence tomography as a diagnostic intervention before cataract surgery—a review. *Eye (Lond)* 2023;37:11:2176-2182.

2. Mitchell P, Smith W, Chey T, et al. Prevalence and associations of epiretinal membranes. The Blue Mountains Eye Study, Australia. *Ophthalmology* 1997;104:6:1033-40.

very bad. The surgeon should look at all B-scan OCT slices, and those images should be grayscale B-scan slices."

Screening should be completed with a 78 D-to-90 D lens, using an optimal optical view and a plano fundus contact lens with anti-reflective coating, he continues. "I believe angiography is rarely needed—and in fact never needed for pre-phaco screening," he adds. "Also, Optos wide-angle imaging has insufficient resolution for a macular evaluation. And blue light auto-fluorescence is optimal for geographic atrophy in AMD and previous cases of central serous retinopathy."

Dr. Charles adds: "The presence of many, large, placoid, confluent drusen poses a much greater risk of AMD than do a few fine drusen. Also, macular drusen are considered much more of a significant risk factor than extra-macular drusen. Finally, as demonstrated by the AREDS data, cataract surgery has not been found to cause AMD progression."<sup>5</sup>

He continues: "CME prevention and treatment strategies don't need to be modified for AMD, DME or epimacular membrane patients," he continues.

"The definition of high CME risk should be reserved for patients with uveitis, such as pars planitis or sarcoid uveitis. And remember that wet AMD and vitreomacular traction syndrome are very common. AMD and VMT, though unrelated, must both be treated—AMD with an anti-VEGF agent and VMT with pars plana vitrectomy and internal limiting membrane peeling, not ocriplasmin (Jetrea)."

### Premium IOL Considerations

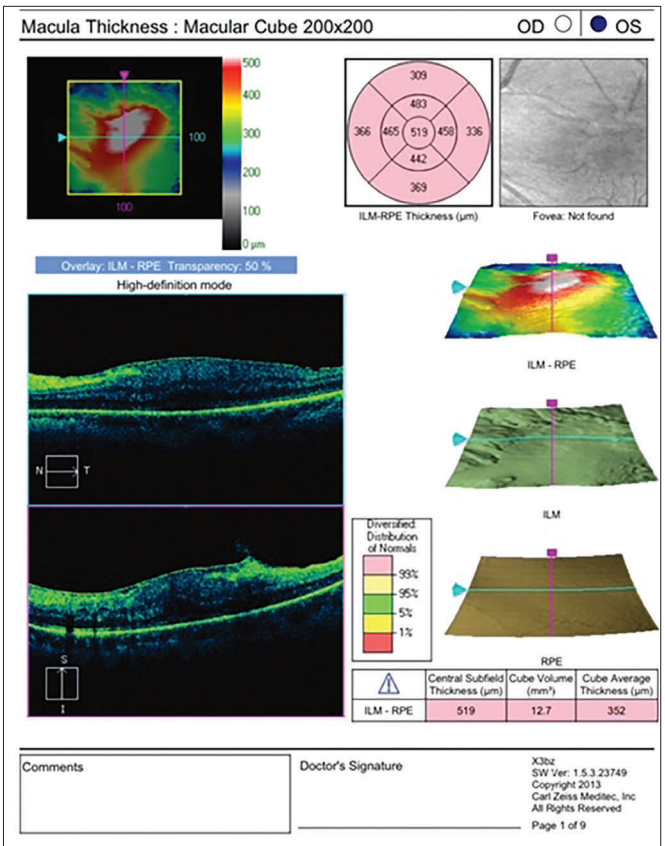
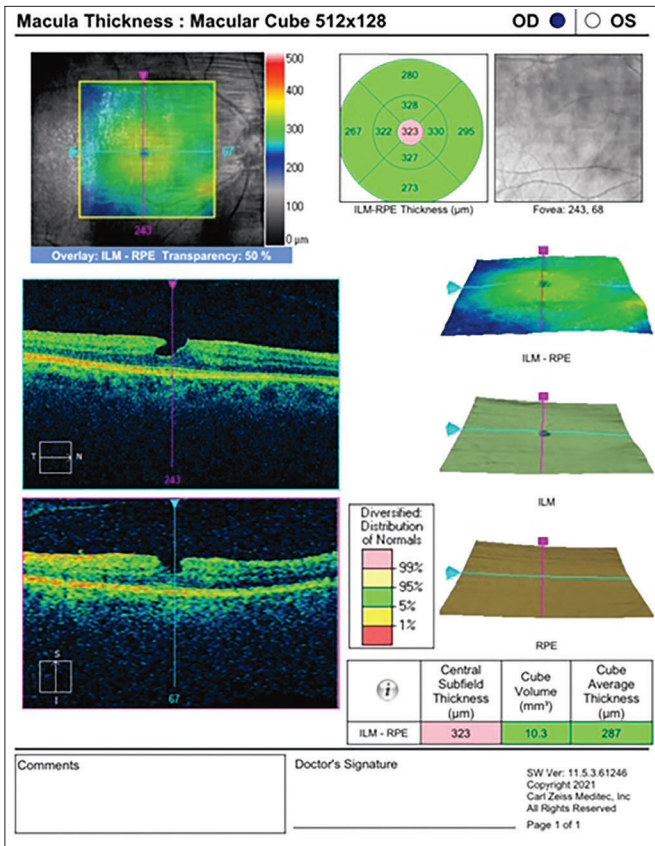
Most surgeons agree that implantation of premium IOLs is a primary challenge to the retina in many cases. Multifocal IOLs decrease contrast sensitivity and should therefore be avoided in most patients with any macular disease, including patients with significant drusen (intermediate, placoid), hyperpigmentation, and wet AMD, observes Dr. Charles.

But Dr. Grayson takes a different approach here, employing a guarantee to his patients that enables him to avoid patient dissatisfaction with multifocals that can arise because of macular or retinal issues. "You have to exchange a premium IOL if it doesn't work out—

unless you're going to cause more of a complication by exchanging it," he says. "And you have to explain this to the patient."

Dr. Grayson typically avoids offering absolute solutions to patients with retinal pathology. "You can't just group all the multifocals together," says Dr. Grayson. "Each has different characteristics and different tolerances for retinal conditions. Patients, for different reasons, such as occupational or preference for less spectacle dependence, etc., have varied needs, despite which pathologies we might tell them exist. I generally say that bad macular degeneration, bad glaucoma, bad epimacular membrane and other nerve pathologies are contraindications for any type of multifocal lens. However, the so-called bad pathologies can come in gradations. Certainly we have implanted multifocals in patients with glaucoma who have arcuate defects but don't have severe glaucoma. Occasionally, we have implanted multifocals in patients with severe glaucoma and advanced superior arcuate scotomas, if we are using the more forgiving IOL, such as an extended-depth-of-field, like the Symphony."





**Figure 4.** A lamellar hole, such as the one found in this patient, may be a relative contraindication to implantation of a diffractive multifocal IOL, and can significantly affect vision if the patient insists on giving the lens a try. The patient may need the hole closed prior to cataract surgery and should be informed that the cataract alone may not be the etiology causing decreased vision.

**Figure 5.** Retinal pigment epithelium and glial cells can proliferate along the surface of the inner limiting membrane, resulting in premacular gliosis, which can sometimes be exacerbated by cataract surgery, as shown in this image.

Dr. Donaldson, on the other hand, takes a “very conservative approach” to premium IOLs. “I generally rule out any patient with macular pathology when considering a multifocal IOL,” she says. “Even if the macular pathology is relatively mild, a multifocal lens may amplify it significantly, affecting vision. I would much rather implant a monofocal or monofocal-plus lens and target for some degree of monovision, if the patient desires more spectacle freedom.”

She remains ever mindful that patients have very high expectations for their vision following cataract surgery. “Screening for retinal pathology, corneal pathology, ocular surface disease and other pre-existing conditions is paramount to making the best decisions as we counsel our patients before surgery,” says Dr. Donaldson. “This

lets us achieve our best outcomes and sets reasonable patient expectations to avoid disappointments postoperatively.”

Dr. Charles emphasizes the importance of forecasting the effects of retinal pathology that will likely develop after any anterior segment surgery. “Remember, for example, that the frequency of geographic atrophy and neovascular AMD increases with each decade of a patient’s life,” he says. “Use of a multifocal IOL in a healthy 55-year-old with intermediate macular drusen is not a good plan.”<sup>6</sup>

When preparing to implant a multifocal or extended-depth-of-focus lens, Dr. Kao says he uses “careful counseling” in a patient with concerning retinal pathology. “The patient may not have the best quality vision after surgery,” he adds.

## When Refractive Surgery Is Planned

Specialists report that evaluating patients before refractive surgery isn’t as challenging. “One of the biggest issues is that some of these patients are high myopes,” says Dr. Kao. “You want to be really careful and look for retinal pathology, such as a retinal tear or lattice degeneration. We will have a retina specialist take a look. The specialist can determine if the patient needs to be lasered—before we do LASIK or a refractive lens exchange. This will ensure that we’re not dealing with a retinal tear or something along those lines after surgery.”

Dr. Haug agrees with this precaution from her retinal specialist perspective. “High myopes are more likely to have

*(Continued on p. 51)*

# SURVEY: CATARACT SURGERY SNAPSHOT

Read about your colleagues' preferred methods for controlling the pupil size, managing astigmatism, breaking up the nucleus and more.

WALTER BETHKE  
EDITOR IN CHIEF

Cataract surgeons take their techniques very seriously, sticking with what works and discarding what doesn't. Over time, however, techniques change with the advent of new technology or the promise of improved results. On this year's survey of cataract technique, surgeons delve into their preferred techniques, as well as what they're thinking of trying in the future.

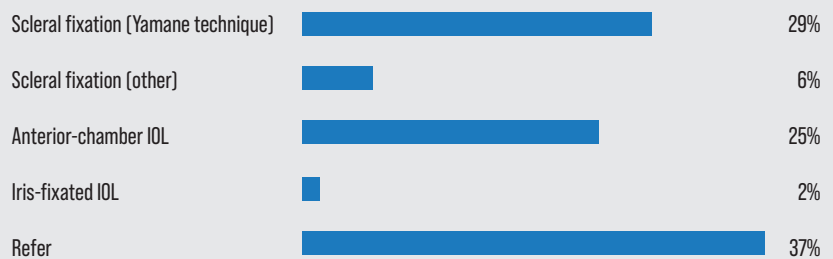
This year, 2,818 of the 10,065 surgeons receiving the survey opened it (28 percent open rate), and 99 completed the survey. To see how your approaches compare with theirs, read on.

## Breaking up the Lens

Like last year, quadrant division is still the most popular single option for nucleofractis, chosen by 29.6 percent of respondents. Some other methods are popular, as well, however.

"[Quadrant division] is simple and applies to nearly everything," says Babak Marefat, MD, of Topeka, Kansas. "I can divide two quadrants and chop the rest with the connor wand easily. Versatile to redirect and convert." John Willer,

### Surgeons' Preferred IOL Fixation Method in the Absence of Capsular Support



DO, of The Dalles, Oregon, also likes quadrant division. "It's tried and true. Endothelial protection isn't as important as it was in the past due to modulated ultrasound," he says. Peter A. Rapoza, MD, says quadrant division is "widely applicable to most cataracts, fast and safe."

Though it may be early to call it a trend, vertical chop increased from 7 percent on last year's survey to 14 percent this year. "[With vertical chop], section size is tailored to lens density," says one surgeon. "All activity is away from the endothelium and within the safe zone inside the CCC, and the technique is efficient and reproducible." Chicago surgeon Robert Fantus prefers the technique because of its "decreased

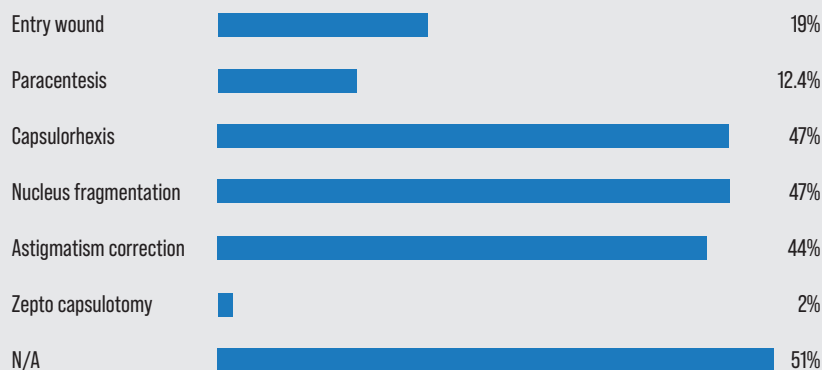
phaco time/energy," and says that it's "more efficient than grooving in certain cases."

Another popular option selected by the surgeons on the survey is stop and chop (16 percent). "A central groove allows more working space and adds minimal time and phaco energy," says a surgeon from Washington. "Horizontal chopping after the central groove is created is efficient with both time and phaco energy." Sid Moore, MD, of Macon, Georgia, also prefers stop and chop. "I'm able to use it on almost any type of cataract, it's zonule friendly, versatile, and allows for 'open field running,' if needed," he says. "[Stop and chop] is more versatile and effective with less chance of corneal complications,"


This article has no commercial sponsorship.



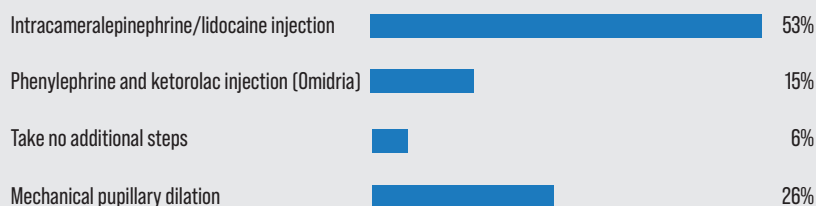
### Surgeons' Use of Femto or Zepto for Cataract Surgery



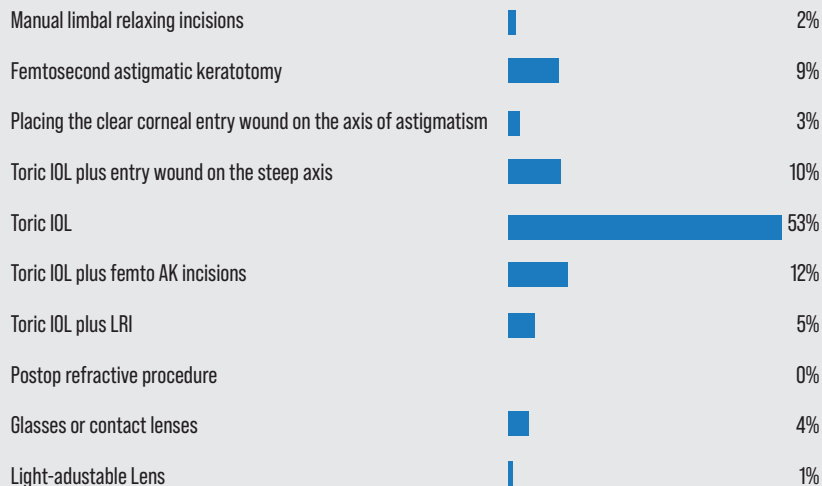
### Likelihood of Using Femto or Zepto in the Coming Year



### How Surgeons Promote a Wide Pupil During Surgery



### How Surgeons Manage Pre-existing Astigmatism



says an ophthalmologist from North Carolina.

The other preferred methods appear in the graph on pg. 37.

### Alternative Technologies

Surgeons also discussed their use of technology such as the femtosecond laser and the Zepto device. Forty-eight percent of the surgeons on the survey use one or the other for their procedures. Of the surgeons who use the devices, 98 percent use the femtosecond for some aspect of the surgery, and 2 percent use the Zepto for capsulotomy creation. In terms of what surgeons use the femto for the most, it's a tie between the capsulorhexis and nuclear fragmentation (47 percent each), with femto astigmatic cuts coming in second (44 percent). The rest of the uses appear in the graph at left.

"[The femtosecond] is safer and protects endothelium," says Alan Aker, MD, of Boca Raton, Florida. "It helps in patients on Flomax and those with poor dilation. There's quicker healing, and it makes perfect capsulotomies. A surgeon from New York agrees, saying, "It's very accurate, reliable, and it makes the surgery more predictable and safe."

Ligaya Prystowsky, MD, of Nutley, New Jersey, believes her results with the femto have trended better than if she didn't use it. "It definitely is better for the patient in the long run over the years," she says. "I noted slower PCO formation, though this could have been the ZCBOO [IOL], better cleanup and centration of the IOL." She adds, however, "The expense to the patient is hard to justify when phaco alone has excellent results as well."

On the topic of Zepto, Chicago's Dr. Fantus thinks it can be helpful. "I think Zepto is useful in complex cases and for centering the rhexis in toric cases."

The femto skeptics, however, say they don't see the benefit.

"It's expensive, slower and the results aren't demonstrably better [than manual]," says a surgeon from Washington.

"Femto is a waste of time and money. It just increases the complexity of the surgery and, if anything, is a

To treat ocular inflammation and pain following ophthalmic surgery or ocular itching associated with allergic conjunctivitis.

DEXTENZA KEEPS PATIENTS

# COMPLIANT

AND SATISFIED<sup>1-3\*</sup>

**A hands-free advancement in ophthalmic steroid treatment.<sup>1,4</sup>**

**Easy-to-insert<sup>†</sup> and preservative-free** intracanalicular DEXTENZA offers patients a satisfying post-op experience—providing up to 30 days of sustained steroid coverage.<sup>1-5</sup>

## INDICATIONS

DEXTENZA is a corticosteroid indicated for:

- The treatment of ocular inflammation and pain following ophthalmic surgery.
- The treatment of ocular itching associated with allergic conjunctivitis.

## IMPORTANT SAFETY INFORMATION

### CONTRAINDICATIONS

DEXTENZA is contraindicated in patients with active corneal, conjunctival or canalicular infections, including epithelial herpes simplex keratitis (dendritic keratitis), vaccinia, varicella; mycobacterial infections; fungal diseases of the eye, and dacryocystitis.

### WARNINGS AND PRECAUTIONS

**Intraocular Pressure Increase** - Prolonged use of corticosteroids may result in glaucoma with damage to the optic nerve, defects in visual acuity and fields of vision. Steroids should be used with caution in the presence of glaucoma. Intraocular pressure should be monitored during treatment.

**Bacterial Infections** - Corticosteroids may suppress the host response and thus increase the hazard for secondary ocular infections. In acute purulent conditions, steroids may mask infection and enhance existing infection.

**Viral Infections** - Use of ocular steroids may prolong the course and may exacerbate the severity of many viral infections of the eye (including herpes simplex).

**Fungal Infections** - Fungus invasion must be considered in any persistent corneal ulceration where a steroid has been used or is in use. Fungal culture should be taken when appropriate.

**Delayed Healing** - Use of steroids after cataract surgery may delay healing and increase the incidence of bleb formation.

**Other Potential Corticosteroid Complications** - The initial prescription and renewal of the medication order of DEXTENZA should be made by a physician only after examination of the patient with the aid of magnification, such as slit lamp biomicroscopy, and, where appropriate, fluorescein staining. If signs and symptoms fail to improve after 2 days, the patient should be re-evaluated.

### ADVERSE REACTIONS

#### Ocular Inflammation and Pain Following Ophthalmic Surgery

The most common ocular adverse reactions that occurred in patients treated with DEXTENZA were: anterior chamber inflammation including iritis and iridocyclitis (10%), intraocular pressure increased (6%), visual acuity reduced (2%), cystoid macular edema (1%), corneal edema (1%), eye pain (1%), and conjunctival hyperemia (1%). The most common non-ocular adverse reaction was headache (1%).

#### Itching Associated with Allergic Conjunctivitis

The most common ocular adverse reactions that occurred in patients treated with DEXTENZA were: intraocular pressure increased (3%), lacrimation increased (1%), eye discharge (1%), and visual acuity reduced (1%). The most common non-ocular adverse reaction was headache (1%).

**Please see adjacent Brief Summary of full Prescribing Information.**

\* 93% (187/201) of DEXTENZA patients were satisfied with the insert in the third Phase 3 Study for the treatment of ocular inflammation and pain following ophthalmic surgery.<sup>3</sup>

† 73.6% of physicians in Study 1, 76.4% in Study 2, and 79.6% in Study 3, for the treatment of ocular inflammation and pain following ophthalmic surgery, rated DEXTENZA as easy to insert.<sup>2,5</sup>

**References:** 1. DEXTENZA [package insert]. Bedford, MA: Ocular Therapeutix, Inc; 2021. 2. Tyson SL, et al. *J Cataract Refract Surg.* 2019;45(2):204-212 [erratum in: 2019;45(6):895]. 3. Data on File 00837. Ocular Therapeutix, Inc. 4. Sawhney AS, et al., Inventors, Incept, LLC, Assignee. Drug Delivery Through Hydrogel Plugs. US patent 8,409,606 B2. April 2, 2013. 5. Walters T, et al. *J Clin Exp Ophthalmol.* 2016;7(4):1-11.

**Dextenza**<sup>®</sup>  
(dexamethasone ophthalmic insert) 0.4mg  
for intracanalicular use



# Dextenza®

(dexamethasone ophthalmic insert) 0.4 mg  
for intracanalicular use

**BRIEF SUMMARY:** Please see the DEXTENZA Package Insert for full prescribing information (10/2021)

## 1 INDICATIONS AND USAGE

### 1.1 Ocular Inflammation and Pain Following Ophthalmic Surgery

DEXTENZA® (dexamethasone ophthalmic insert) is a corticosteroid indicated for the treatment of ocular inflammation and pain following ophthalmic surgery (1.1).

### 1.2 Itching Associated with Allergic Conjunctivitis

DEXTENZA® (dexamethasone ophthalmic insert) is a corticosteroid indicated for the treatment of ocular itching associated with allergic conjunctivitis (1.2).

## 4 CONTRAINDICATIONS

DEXTENZA is contraindicated in patients with active corneal, conjunctival or canalicular infections, including epithelial herpes simplex keratitis (dendritic keratitis), vaccinia, varicella; mycobacterial infections; fungal diseases of the eye, and dacryocystitis.

## 5 WARNINGS AND PRECAUTIONS

### 5.1 Intraocular Pressure Increase

Prolonged use of corticosteroids may result in glaucoma with damage to the optic nerve, defects in visual acuity and fields of vision. Steroids should be used with caution in the presence of glaucoma. Intraocular pressure should be monitored during the course of the treatment.

### 5.2 Bacterial Infection

Corticosteroids may suppress the host response and thus increase the hazard for secondary ocular infections. In acute purulent conditions, steroids may mask infection and enhance existing infection [see Contraindications (4)].

### 5.3 Viral Infections

Use of ocular steroids may prolong the course and may exacerbate the severity of many viral infections of the eye (including herpes simplex) [see Contraindications (4)].

### 5.4 Fungal Infections

Fungus invasion must be considered in any persistent corneal ulceration where a steroid has been used or is in use. Fungal culture should be taken when appropriate [see Contraindications (4)].

### 5.5 Delayed Healing

The use of steroids after cataract surgery may delay healing and increase the incidence of bleb formation.

### 5.6 Other Potential Corticosteroid Complications

The initial prescription and renewal of the medication order of DEXTENZA should be made by a physician only after examination of the patient with the aid of magnification, such as slit lamp biomicroscopy, and, where appropriate, fluorescein staining. If signs and symptoms fail to improve after 2 days, the patient should be re-evaluated.

## 6 ADVERSE REACTIONS

The following serious adverse reactions are described elsewhere in the labeling:

- Intraocular Pressure Increase [see Warnings and Precautions (5.1)]
- Bacterial Infection [see Warnings and Precautions (5.2)]
- Viral Infection [see Warnings and Precautions (5.3)]
- Fungal Infection [see Warnings and Precautions (5.4)]
- Delayed Healing [see Warnings and Precautions (5.5)]

### 6.1 Clinical Trials Experience

Because clinical trials are conducted under widely varying conditions, adverse reaction rates observed in the clinical trials of a drug cannot be directly compared to rates in the clinical trials of another drug and may not reflect the rates observed in practice. Adverse reactions associated with ophthalmic steroids include elevated intraocular pressure, which may be associated with optic nerve damage, visual acuity and field defects, posterior subcapsular cataract formation; delayed wound healing; secondary ocular infection from pathogens including herpes simplex, and perforation of the globe where there is thinning of the cornea or sclera [see Warnings and Precautions (5)].

### 6.2 Ocular Inflammation and Pain Following Ophthalmic Surgery

DEXTENZA safety was studied in four randomized, vehicle-controlled studies (n = 567). The mean age of the population was 68 years (range 35 to 87 years), 59% were female, and 83% were white. Forty-seven percent had brown iris color and 30% had blue iris color. The most common ocular adverse reactions that occurred in patients treated with DEXTENZA were: anterior chamber inflammation including iritis and iridocyclitis (10%); intraocular pressure increased (6%); visual acuity reduced (2%); cystoid macular edema (1%); corneal edema (1%); eye pain (1%) and conjunctival hyperemia (1%). The most common non-ocular adverse reaction that occurred in patients treated with DEXTENZA was headache (1%).

### 6.3 Itching Associated with Allergic Conjunctivitis

DEXTENZA safety was studied in four randomized, vehicle-controlled studies (n = 154). The mean age of the population was 41 years (range 19 to 69 years), 55% were female and 61% were white. Fifty seven percent had brown iris color and 20% had blue iris color. The most common ocular adverse reactions that occurred in patients treated with DEXTENZA were: intraocular pressure increased (3%), lacrimation increased (1%), eye discharge (1%), and visual acuity reduced (1%).

The most common non-ocular adverse reaction that occurred in patients treated with DEXTENZA was headache (1%).

## 8 USE IN SPECIFIC POPULATIONS

### 8.1 Pregnancy

#### Risk Summary

There are no adequate or well-controlled studies with DEXTENZA in pregnant women to inform a drug-associated risk for major birth defects and miscarriage. In animal reproduction studies, administration of topical ocular dexamethasone to pregnant mice and rabbits during organogenesis produced embryofetal lethality, cleft palate and multiple visceral malformations [see Animal Data].

#### Data

**Animal Data**  
Topical ocular administration of 0.15% dexamethasone (0.75 mg/kg/day) on gestational days 10 to 13 produced embryofetal lethality and a high incidence of cleft palate in a mouse study. A daily dose of 0.75 mg/kg/day in the mouse is approximately 5 times the entire dose of dexamethasone in the DEXTENZA product, on a mg/m<sup>2</sup> basis. In a rabbit study, topical ocular administration of 0.1% dexamethasone throughout organogenesis (0.36 mg/day, on gestational day 6 followed by 0.24 mg/day on gestational days 7-18) produced intestinal anomalies, intestinal aplasia, gastroschisis and hypoplastic kidneys. A daily dose of 0.24 mg/day is approximately 6 times the entire dose of dexamethasone in the DEXTENZA product, on a mg/m<sup>2</sup> basis.

### 8.2 Lactation

Systemically administered corticosteroids appear in human milk and could suppress growth and interfere with endogenous corticosteroid production; however the systemic concentration of dexamethasone following administration of DEXTENZA is low [see Clinical Pharmacology (12.3)]. There is no information regarding the presence of DEXTENZA in human milk, the effects of the drug on the breastfed infant or the effects of the drug on milk production to inform risk of DEXTENZA to an infant during lactation. The developmental and health benefits of breastfeeding should be considered along with the mother's clinical need for DEXTENZA and any potential adverse effects on the breastfed child from DEXTENZA.

### 8.4 Pediatric Use

Safety and effectiveness in pediatric patients have not been established.

### 8.5 Geriatric Use

No overall differences in safety or effectiveness have been observed between elderly and younger patients.

## 17 PATIENT COUNSELING INFORMATION

Advise patients to consult their eye care professional if pain, redness, or itching develops.

**Ocular**  
Therapeutix™

Ocular Therapeutix, Inc.  
Bedford, MA 01730 USA  
PP-US-DX-0360

## Feature CATARACT TECHNIQUE SURVEY

disadvantage to a proper 'hexis done with manual technique,' says Steve Safran, MD, of Lawrenceville, New Jersey. "There's nothing that it offers that I can't do better without it. It's a distraction and an expensive one at that! The astigmatic cuts it makes have created problems in many corneas and the nucleus fragmentation is nowhere near as efficient as what can be done with modern chopping. Pass."

The physicians also discussed the use of intraoperative wavefront aberrometry for zeroing in on the right IOL power. Forty-two percent of the respondents say they use it in some capacity.

Only 5 percent of the users rate the technology as "excellent," though 21 percent say it's "good."

The ratings appear in the graph on pg. 37.

Five percent rate it as "poor." Twenty-four percent of them say they intend to use it less in the coming year, 4 percent will use it more and 72 percent say they'll be using the same amount of intraoperative aberrometry as last year.

Dr. Rapoza has found value in intraoperative aberrometry. "[It gives] increased accuracy in post laser vision correction and premium IOL cases, plus those with long and short axial lengths," he says. Virginia Beach's G. Peyton Neatrou, MD, agrees for the most part, saying, "I used it for 13 years pre Light-Adjustable Lens, which has replaced intraoperative aberrometry for post-refractive patients. I still use it for the best EDOF results."

A majority of the surgeons continue to hang back, though.

"I'm unimpressed by the patient results that I see following intraoperative aberrometry," says a surgeon from Colorado. "Yes, all procedures have a given failure rate, but when people pay for added precision, they should get improved precision. They shouldn't be going elsewhere for second opinions on what went wrong." Oregon's Dr. Willer is also dubious, saying, "It's way too expensive, there's a learning curve, it takes up micro-scope real estate, and it's not all that useful."

## When IOLs Need Support

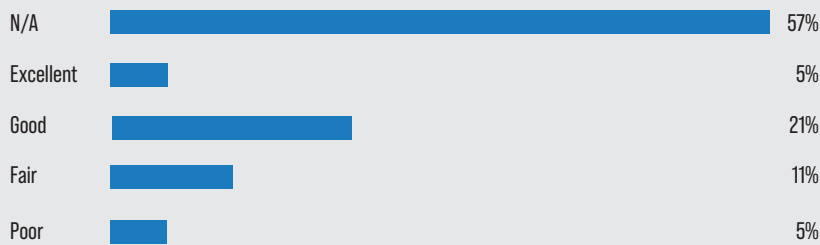
In those unfortunate cases in which there's little or no capsular support, surgeons outlined the routes they like to take.

The most popular single option was to refer the patient (37 percent), followed by scleral fixation with the Yamane technique (29 percent) or the placement of an anterior chamber lens (25 percent). The graph of the options appears on pg. 33.

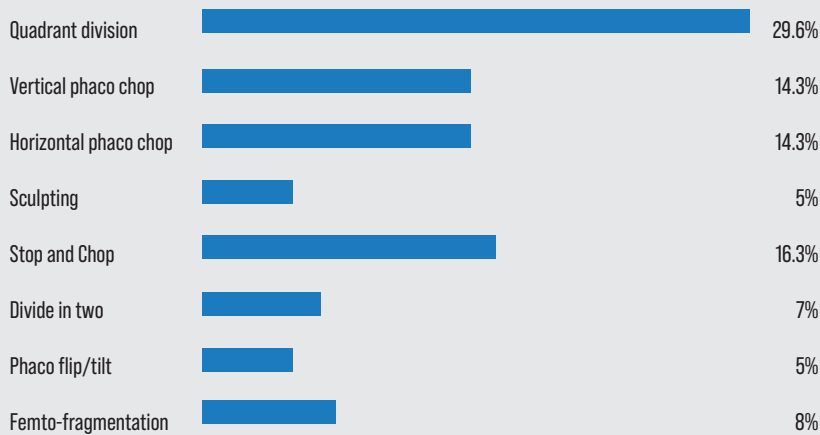
"While [Yamane] can be technically challenging, it is effective," says a New York surgeon. Jason Jones, MD, of Sioux City, Iowa, opines: "[The Yamane technique] is elegant and simple when executed well." Dr. Safran agrees, saying, "[Yamane] is reliable, efficient and yields excellent outcomes."

Proponents of anterior-chamber lens placement feel it offers other benefits. "It's easiest," says a surgeon from Ohio. "I'll do Yamane but it's more challenging and sometimes the IOL ends up tilted. An ACIOL is easy and, although some might disagree, is very well tolerated." A physician from Washington says safety has improved with the technique. "Modern ACIOLs give good visual outcomes and stability without the

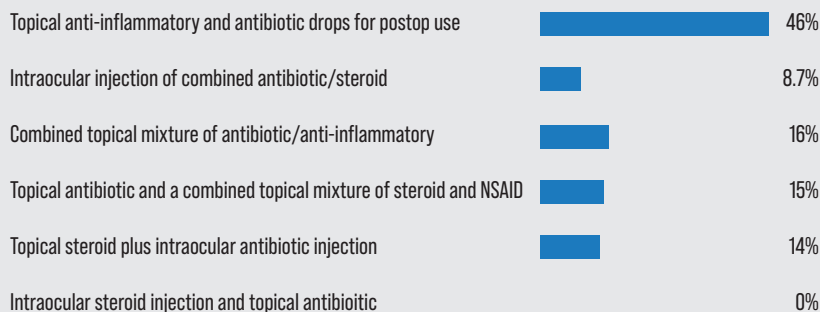
### Surgeons' Opinions of Wavefront Aberrometry



### Preferred Nucleofractis technique



### Preferred Method for Controlling Postop Inflammation and Preventing Infection



high incidence of UGH syndrome that was seen with older designs," he says.

For surgeons who feel discretion is the better part of valor and choose to do neither technique, they say a referral can be best for a patient. "I don't have enough volume to feel comfortable that I'm the best person to be providing this service, given the volume performed by my local peers," says a surgeon from Colorado. Dr. Waller shares that sentiment, saying, "I haven't performed any of the IOL fixation techniques often enough to be proficient, so I refer the

patient."

### Managing Astigmatism

Similar to previous years, most surgeons (53 percent) turn to toric IOLs to manage pre-existing astigmatism.

"Toric lenses give good refractive results without having to add extra corneal incisions or modify placement into less ergonomic location," says a surgeon from Washington. A physician from California outlines his thought process, saying, "It depends on the magnitude and the desired refractive distance result.

For less than 1 D, often glasses are preferred by patients rather than a toric IOL. For large astigmatic errors, toric IOLs are preferable. As for the distance, if a patient wishes to remain myopic, then I often don't recommend a toric IOL unless the cylinder error is greater than 2 D."

Nine percent of respondents use femtosecond astigmatic incisions. "It's easy and has the other advantages of FLACS," says a surgeon from Illinois.

The rest of the options appear in the graph on pg. 34.

### Take-home Pearls

In addition to weighing in on specific techniques, surgeons also provided their best tips for surgical success.

"Wait one full second in foot position zero (no irrigation) before removing the phaco or I&A tip from the eye. This lowers the IOP prior to removal of the instrument. This technique decreases the chance of iris prolapse in IFIS cases," says John C. Hart Jr., MD, of Farmington Hills, Michigan.

In a similar vein, Kathryn Hart, MD, of Greensboro, North Carolina says, "Slow down when you notice weak zonules, floppy capsule, or any other red flags. Another few minutes of operating time can keep you out of trouble." Boston's Dr. Rapoza says, "Optimal globe positioning allows for ease with the remaining steps."

Dr. Fantus offers specific advice to avoid errors. "Pantomime the steps of the most common surgical procedure you do until it is muscle memory," he says, "so that if something requires deviation from this you're ready without throwing off your rhythm." If you're doing a lens exchange, Alex Hacopian, MD, of Houston suggests that you "trace the haptic with a Sinsky hook to the terminal bulb in order to free it up during IOL exchange."

One surgeon says that experimenting with new techniques isn't always the best idea. "Stick to the technique that works best in your hands and that you are most comfortable with," he says. "Sometimes great is the enemy of good." ◀



# HOW TO SUCCEED WITH THE NEW TRIPLE PROCEDURE

Cornea experts share their strategies and techniques to ensure optimal outcomes when performing a corneal transplant, cataract removal and IOL implantation at the same time.

LIZ HUNTER  
SENIOR EDITOR

Cornea transplants have evolved significantly in the past two decades—from full penetrating keratoplasty becoming less common, to the introduction of Descemet's stripping automated endothelial keratoplasty and, ultimately, the development of Descemet's membrane endothelial keratoplasty, which is becoming increasingly accepted for both normal and complex eyes. These improvements have appealing benefits, including decreased risk of graft rejection and faster recovery time, and offer the opportunity for further efficiency if the case also involves a cataract.

Recognized as the “triple procedure,” it classically consisted of a full-thickness, corneal transplant/PK combined with cataract surgery and IOL implantation. This was the standard for 50-plus years until Gerrit Melles, MD, PhD, pioneered several new EK techniques, including DSEK and DMEK, which were then championed in the United States by Mark A. Terry, MD, the director of corneal services at Devers Eye Institute in Portland, Oregon.

These were welcome changes for the cornea community. “Although full-thickness corneal transplants were our only option, we always wondered why we couldn't just replace the endothelial layer and Descemet's membrane, which were the culprits of disease,” says Sadeer Hannush, MD, a cornea specialist at Wills Eye Hospital in Philadelphia. “Yet, all these years we were doing PK with all the risks that came with it, including open-sky surgery and 360-degree sutures.”

As cornea specialists became more familiar with the fundamentals of DSAEK and DMEK in the early 2000s, Dr. Terry coined the term “the new triple procedure” to reflect the updates in techniques and help standardize the approach.<sup>1</sup> Since then, DMEK has become the preferred technique in the new triple procedure, according to Dr. Terry, although DSAEK and DLEK have their applications in certain scenarios.

In this article we'll take a look at the lessons learned and discoveries made by surgeons who routinely perform triple procedures, including IOL selection, staging, intraoperative medications and techniques.

## Major Considerations for the Triple Procedure

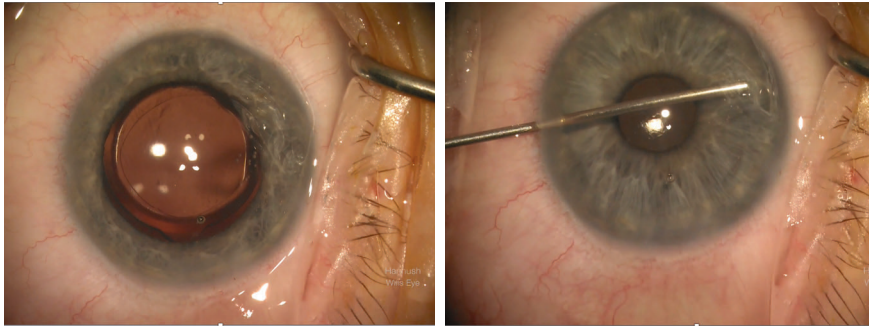
One of the most challenging aspects of cataract surgery combined with a corneal procedure is predicting the refractive shift. Additional thought should be given to IOL selection, experts say.

“For the IOL, you have to choose what focusing power it will have, and one problem with the new triple procedure is that we don't always know exactly what the focusing power of the cornea will be after the EK,” says Dr. Terry. “We know that it won't be as far off as it was in the old, full-thickness transplant days, but in the new triple procedure we know that there's a hyperopic shift with EK. That hyperopic shift is more predictable with DMEK than it is with DSAEK. DSAEK tends to almost always have a hyperopic shift such that, if you just put in what you would put in for cataract surgery for the IOL power, you would end up with a hyperopic result.”

Dr. Terry says, in order to prevent a hyperopic refractive result in the new triple procedure, surgeons should choose a lens that would normally result in a mildly minus result. “When you do your IOL calculations for the

This article has no commercial sponsorship.

Dr. Hannush has no related disclosures. Dr. Houser reports a relationship with Rayner. Dr. Terry has no financial interests.



Sadegh Hannush, MD

sometimes slightly myopic shifts that a DMEK surgery can give you,” he continues.

### Staging vs. Combined

There are some differences of opinion on when to proceed with the combined triple procedure and when to hold off, especially if the patient is expecting spectacle independence.

“The staging of the procedure can be done in one of two ways: you can perform the cataract surgery first or you can do the corneal transplant first,” explains Dr. Hannush. “Each one has a pro and con. When a patient is referred to me by a cataract surgeon, he or she is asking me two questions: how much of the visual disturbance is from the cornea and how much is from the cataract and, if mostly from the cataract, will the cornea tolerate routine cataract surgery? Usually, I can answer this convincingly—mostly cataract or mostly cornea. If it’s mostly cataract, I also have to tell the general ophthalmologist/ cataract surgeon that the cornea may not withstand routine cataract surgery, even in their excellent hands. So, I may recommend they go ahead and do the cataract surgery, but the patient has to understand that the cornea may get cloudier and require an endothelial transplant secondarily. The cataract surgeon then decides whether to carry that decision-making burden or allow the cornea specialist to deal with it.”

In some cases, performing cataract surgery first might work in the patient’s favor, Dr. Hannush continues. “The advantage of doing cataract first is that the patient may not need an endothelial transplant,” he says. “They may get away with just cataract surgery, especially in Fuchs’ dystrophy. Assuming we have a virgin eye, if the Fuchs’ isn’t very advanced, most patients can get away with just cataract surgery, and they’re happy without subjecting them to an endothelial transplant at the same time. We let the patient know, however, that we can’t guarantee that the endothelial layer would survive, and they may need a corneal transplant secondarily.”

However, Dr. Hannush says the

**In a triple procedure, surgeons must balance pupil dilation with pupil constriction and approach it differently than traditional cataract surgery. Cornea specialists recommend phenylephrine for dilation followed by Miochol or Miostat for constriction, and say it’s better to avoid cycloplegics and NSAIDs because they’ll inhibit the constriction mechanisms.**

DMEK triple procedure you want to aim for about a -0.5 to -1 D for your refractive result so that you don’t end up with a hyperopic refraction postoperatively,” he continues. “You’re compensating for the expected hyperopic shifts of the DMEK surgery by choosing a lens that, if it was a standalone cataract surgery, would give you a -0.5 or -1 D myopic result, but in reality you’ll end up closer to emmetropia if you shoot for a myopic result.”

To further complicate things, this has to be tempered with the understanding that approximately 40 percent of cases will have a slight myopic shift instead of a hyperopic shift. “That myopic shift induced by DMEK surgery is usually very low-level, less than 0.5 D, but it’s there and you can get hyperopic shifts that are more than 1 D,” Dr. Terry says. “So there’s still a fuzziness to the calculations that you’ll do because of biologic variability on the refractive result of a DMEK surgery.”

Another consideration is whether or not a triple procedure is the best plan. If there’s corneal edema affecting the epithelium, determine how severe it is before proceeding. Dr. Terry says, “If the corneal edema is very severe where it causes actual microcystic epithelial edema, it causes the epithelial surface of the cornea to be warped because of the swelling. In cases with an irregular epithelium, then you shouldn’t be doing a triple procedure. And this is something to emphasize—if the swelling is so bad that it’s distorting the surface of your

cornea preoperatively, then you can’t get adequate keratometry or topography readings because the surface is so irregular. In this case, the strategy should change and you shouldn’t do a triple procedure.”

Instead, Dr. Terry recommends performing DMEK surgery first and waiting at least two to three months before the cataract surgery. “The rationale behind the strategy of sequential surgery is that you want the smoothest corneal surface possible to determine what your IOL power will be,” he says. “With the healed DMEK graft in place you can treat the IOL calculations in the same manner as you would with a standard cataract surgery and you don’t have to account for the hyperopic shift since it already occurred.”

Cornea surgeons should also be on the lookout for epithelial basement membrane dystrophy. “If you notice on your Pentacam or other tomography device an irregular surface that’s not from swelling but from thickened basement membrane disease, it’s probably wise to do a corneal scraping first to get rid of that irregular, scabby material of the surface and let it heal over,” Dr. Terry says. “Once you have a stable surface without epithelial edema and without corneal epithelial scarring then you could go ahead and do your triple procedure based on those numbers.

“The triple procedure should only be done when you have a stable, smooth corneal surface and if you have an understanding of the hyperopic and



advantage of doing endothelial keratoplasty first, whether DMEK or DSAEK, is that if the cornea is the bigger contributor to visual loss, as opposed to the cataract, cataract surgery can be postponed at least temporarily. “Once the cornea clears after the DMEK, if the patient still feels the vision is suboptimal due to the cataract, accurate measurements with biometry of the implant power may be obtained and the cataract procedure planned,” he says. “You can even confidently place a toric or presbyopia-correcting implant if you do the cataract surgery secondarily. I’m personally not comfortable placing a specialty implant during a combined procedure. A toric IOL may be considered, but not a multifocal or extended-depth-of-focus lens, because the patient’s expectation is spectacle independence, which may not be achieved. With a staged procedure, doing the cornea first, the chances of achieving spectacle independence are decidedly better.”

Dr. Terry says he’s comfortable performing a triple procedure on patients with Fuchs’ and cataracts, provided there’s no disturbance of the epithelial surface. “The advantages of this strategy are: one trip to the operating room, which means one episode of risk for the patient and a much lower cost to the health system overall than two trips,” he says. “The majority of patients will get 20/20 vision and for those who get 20/25 vision instead of 20/20, they’re generally very happy with the result. So it’s a successful surgery. If they’re unhappy with their results because the refractive error is something that bothers them, then it’s easy enough to go ahead and do PRK or give them a pair of glasses.”

Undergoing DMEK has now made them a candidate for laser vision correction, Dr. Terry adds. “Their DMEK surgery has allowed the patient to move into a category such that they can have PRK or LASIK if they prefer not to wear glasses, whereas it’s contraindicated in my opinion to do refractive surgery in a Fuchs’ dystrophy patient that later will require a transplant,” he says.

“Once you get rid of the Fuchs’ dystrophy and their eyes stabilize—and if they’re not happy about having to wear glasses to get 20/20 or 20/15 vision—then they can have refractive surgery just like anybody else. A vast majority of my patients decide that they’re happy with their surgery. If they have a slight refractive error, they’ll wear glasses on occasion, and they usually don’t want to have LASIK surgery or PRK surgery.”

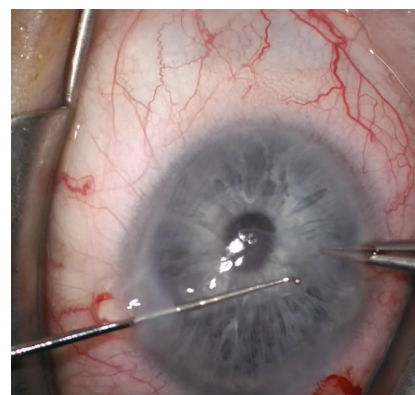
Discussing refractive goals is a big component of the decision-making process for Kourtney Houser, MD, an assistant professor of ophthalmology at Duke University School of Medicine. “I’ll stage the procedure if the patient is really motivated to be out of glasses, if they have significant astigmatism or if their cornea is already edematous and I’m not confident in the biometry for intraocular lens selection,” she says. “In staged cases such as these, I’ll do the corneal procedure first, typically a DMEK, allow the cornea to heal, and then once the cornea heals and stabilizes, I repeat biometry and tomography, make my intraocular lens selection and then perform the cataract surgery.”

Yet, she has a fair amount of patients who opt for the triple procedure because it significantly reduces the number of surgeries and visits to the office (from four surgeries to two in patients who need both eyes done).

Priorities might be a little different between patients who are eligible for DSAEK vs. DMEK. “My decision making for a triple procedure with DSAEK is similar to DMEK,” says Dr. Houser. “I’ll let them know the refractive goals with both, but in most cases, my DSAEK patients have very complex eyes with often lower visual potential than my patients who are undergoing DMEK. Because of the often-present glaucoma or retinal disease in patients undergoing DSAEK, our goal is usually not spectacle independence but instead maximal visual rehabilitation.”

### IOL Recommendations

Once you’ve determined whether the patient’s procedure will be staged or done simultaneously, it’s important



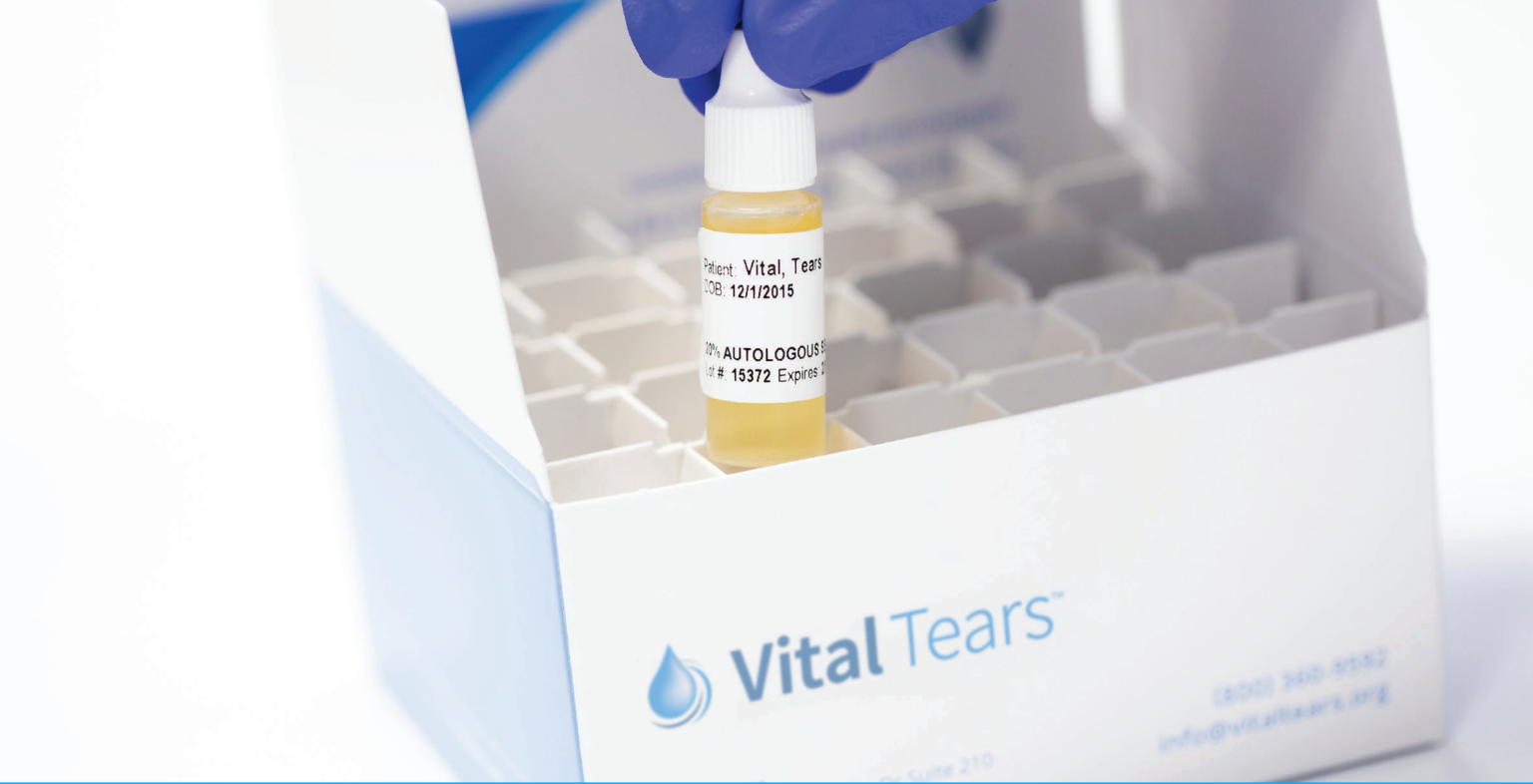Kourtney Houser, MD

**When stripping host Descemet’s, cornea specialists tend to strip an area larger than they’re transplanting. Here, Kourtney Houser, MD, uses a Fogla stripper, which has a ball on the tip to help keep it from penetrating too deep into the stroma.**

to consider which types of IOLs to implant and which to avoid.

Dr. Terry most often reaches for a toric IOL in the combined triple procedure. “Toric lenses are fine to do in triple procedures,” he says. “We’ve published a couple of studies on the use of toric lenses in EK surgery. This is different from using multifocal IOLs in a DMEK triple. I don’t recommend multifocal lenses if you’re going to do a triple procedure because it’s not going to be accurate enough for your keratometry values as it would be in a staged procedure. If you have a patient who absolutely demands having a multifocal lens, then that makes sense to be doing a staged procedure of a DMEK and wait for everything to heal before implanting a multifocal.”

Alternatively, Dr. Houser is more conservative with her IOL choice, leaning toward monofocals without toricity in triple procedures. “If a patient is interested in spectacle independence and it appears they’d require a toric lens to achieve this, I tend to stage the procedures instead of combining them,” she says. “Any hydrophobic acrylic intraocular lens is safe to use, but I avoid hydrophobic acrylic lenses, as these can calcify and opacify with gas injection. If I had access to the Light-Adjustable Lens, I think this would be an excellent place for it. The astigmatism and spherical power of the lens could be adjusted



# Serum Tears Made **Easy, Fast & Safe**

We make it easy for you and your patients to get a **six-month supply of serum tears** from a single blood draw, with **turnaround times as quick as 48 hours** from the blood draw appointment.

Simply place your order online and then Vital Tears takes care of the rest.

# 1

We contact the patient to schedule the blood draw and collect payment.

# 2

Blood is drawn at one of our 400+ contracted facilities or by a mobile phlebotomist.

# 3

Serum tears are processed using rigorous, validated safety procedures then shipped directly to the patient.





postoperatively and we could perhaps combine more of these cases. My only hesitation would be that occasionally a patient can develop an area of posterior synechiae with DMEK, which would prevent postoperative adjustment of the lens.”

A study on the first reported cases of a DMEK triple procedure using the Light-Adjustable Lens (RxSight)<sup>2</sup> suggested positive outcomes, with Patient A achieving a distance UCVA of 20/15 in the right eye and 20/20 in the left eye, and Patient B (targeted for monovision) achieving a distance UCVA of 20/15 in the dominant eye and a near UCVA of Jaeger No. 1+ in the non-dominant eye, after final lock-in. However, the study did cite risks, including the chance of the IOL moving anteriorly and contacting the graft, as well as the burdens of multiple visits and out-of-pocket expenses on behalf of the patient.

### Intraoperative Medications

Administering medications during a triple procedure is very different from performing routine cataract surgery.

Firstly, topical anesthesia may not be enough. “Most corneal surgeons perform the triple procedure with regional anesthesia, meaning a peribulbar block,” Dr. Hannush says. “There are some surgeons who will do it under topical anesthesia, which isn’t unreasonable, but it’s a longer procedure than a 10-minute cataract and requires more patient cooperation.”

Then there’s the matter of dilating and constricting the pupil. “In the triple procedure you’re balancing the need to have a pupil dilated for the cataract surgery with the need to have the pupil very small for unscrolling your DMEK graft tissue,” says Dr. Terry.

“When doing a triple, I use different dilation drops and intraoperative medications than in my routine cataract surgery cases,” Dr. Houser says. “In a normal cataract surgery I use a mix of tropicamide/phenylephrine and cyclopentolate to dilate patients in the preoperative area and in some cases use Shugarcaine or a mix of phenylephrine/

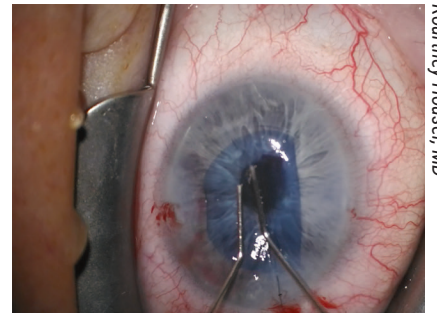
ketorolac intraoperatively. This allows for long-lasting pupillary dilation. If I’m doing DMEK along with cataract, I’ll only dilate with phenylephrine and use plain preservative-free lidocaine for intracameral anesthetic to allow for easier pupillary constriction following the cataract portion of the case.

“The cataract procedure can sometimes be a little more challenging because of the often poorer dilation, but it’s usually sufficient to safely do the surgery,” she continues. “I add Shugarcaine to supplement dilation if I can’t safely do the case with the level of dilation. After the cataract surgery is complete, I use Miostat or Miochol to induce pupillary constriction.”

The cornea specialists we spoke with all emphasized that it’s best to avoid cycloplegics in a triple procedure. “Those are powerful dilators, so it’s harder to constrict the pupil afterwards,” says Dr. Hannush. “Also, it’s best to avoid the use of a non-steroidal anti-inflammatory drug, although commonly used during cataract surgery to avoid loss of dilation. At the time of graft insertion during DMEK, it’s nice to have a constricted pupil. Miotic agents aren’t strong enough to bring the pupil down if you have a cycloplegic and/or NSAID on board.”

Dr. Terry advises, “If you were to use cycloplegic drops in addition to the phenylephrine drops to dilate the pupil, you paralyze the sphincter muscle and you stimulate the dilator muscle of the iris. Then it’s much harder to get the iris to constrict down for the injection and unfolding of the DMEK tissue and I think that’s a dangerous proposition.”

Dr. Houser offers another tip for the cataract surgery itself: “If there are visually significant guttae or corneal edema, I have a very low threshold for using trypan blue to make the cataract surgery a little bit easier,” she says. “I’m also very cautious not to oversize my capsulotomy or capsulorhexis to keep the intraocular lens stable during the DMEK procedure. If you oversize the capsulotomy, the IOL can prolapse forward during the DMEK procedure and damage the graft.”



Kourtney Houser, MD

**A pre-loaded DMEK in a Geuder cannula is a commonly used device for DMEKs and triples as it fits through a 2.4-mm incision, according to Kourtney Houser, MD. Her technique includes unscrolling the graft and then using 20% SF6 gas, leaving about an 80-percent fill.**

One of the advantages of performing DMEK as a component of the triple procedure is that patients can be taken off their topical medications much quicker than a full thickness or even a DSAEK transplant. “The rejection rate is much lower,” Dr. Hannush says. “We usually use the NSAID for a couple of weeks and the antibiotic for one week but, as opposed to keeping them on the steroid four times a day for at least three to six months after a full-thickness graft, they can be tapered down to twice a day, even once a day by three months after DMEK. If they’re a steroid responder, with an intraocular pressure rise, you can even stop the steroid after a few months. The rejection risk is less than 2 percent. If you stop the steroid on a full-thickness transplant in three months, the rejection rate is significantly higher.”

### Technique Pearls

We asked these experts for best practices and strategies they’ve honed over the years of performing the new triple procedure. Here’s what they said:

- **Graft insertion.** “Most of us are using a small incision for DMEK, usually 2.4 mm, and inserting the graft with a glass tube,” says Dr. Hannush. “The most popular one is made by Geuder from Germany, but there are other glass tubes. Some surgeons insert the DMEK graft with a modified IOL inserter.”

“When I first started doing DMEK

I didn't have access to the Geuder cannula," notes Dr. Houser. "I initially used a Modified Jones Tube, which is a great insertion device, but it requires a little larger incision. I would typically enlarge the incision I made for my cataract surgery prior to insertion, and if the wound size didn't perfectly match the cannula size for insertion of the graft, it was easy to prolapse the graft out of the eye. But now that the Geuder is available, I think that's really made things a lot easier. The incision/insertion size match creates a stable anterior chamber for graft insertion and makes it more challenging to prolapse the graft out of the eye."

She further explains her process, including the use of SF6 gas, saying, "After pupillary constriction, I perform an inferior peripheral iridotomy with a side-port blade after gently elevating the iris with my endothelial stripper," Dr. Houser says. "I mark the cornea with an 8-mm marker to mark my area of endothelial stripping, which is 0.5 mm larger than my typical graft size. I use the Fogla stripper for endothelial stripping, which has a nice ball on the tip that prevents penetrating too deep into the stroma. I take extra care to thoroughly remove all viscoelastic prior to graft insertion. Then I use a pre-loaded DMEK in a Geuder cannula as it fits through a 2.4-mm incision, which is my preferred incision size for cataract surgery. I unscroll the graft and then use 20% SF6 gas for all my DMEK procedures, including DMEK triples, leaving about an 80-percent fill. There's

data that shows equivalent rebubble and graft survival rates with air, but I like using the SF6 because it stays in the eye a little bit longer. Finally, I have the patient sit for an hour face up in recovery before discharge."

• **Stripping and unscrolling techniques.**

"When stripping host Descemet's, most of us agree that you want to strip a larger area than the area you're transplanting," Dr. Hannush says. "For example, I'll strip a diameter of 8.5 mm and I will graft a diameter of 7.75 to 8 mm, so I over-strip by 0.5 to 8 mm."

For unscrolling, Dr. Hannush suggests surgeons investigate the variety of techniques that have been published, including:

- a single-handed insertion of the graft into the anterior chamber. The surgeon then uses a combination of tapping on the central cornea, sweeping an instrument across the host cornea over the graft, or injecting fluid in different directions to unscroll the graft. A cannula with a pair or more side ports may be inserted into the scroll followed by a little puff of fluid to unscroll the graft;

- a pull-through technique, where the graft is placed in a modified DSAEK injector cartridge then pulled into the anterior chamber with a forceps; and

- using a microscope-mounted OCT to view the graft inside the anterior chamber and make sure it's in the correct orientation with the endothelial side toward the anterior chamber.

"One personal preference of mine is to suture the main incision with

DMEK," says Dr. Houser. "I find it easier to unscroll the graft when I have an extra incision through which to inject or release BSS from the anterior chamber."

## The Next Frontier

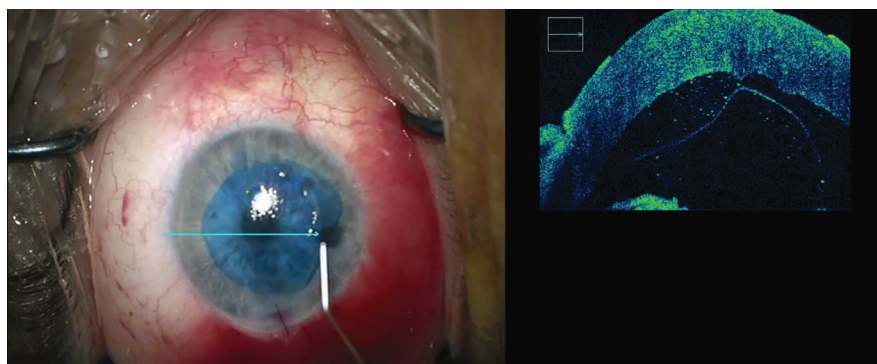
Just as DSAEK and DMEK revolutionized cornea transplantation two decades ago, the next phase of innovation is already underway.

"Allogenic endothelial cell therapy is the next frontier in corneal endothelial replacement," says Dr. Hannush.

"Based on the work of Professor Shigeru Kinoshita in Japan, mature corneal endothelial cells from a healthy donor may be cultivated *in vitro* then injected intracamerally into the eye of a recipient with endothelial dysfunction. This leads to clearing of the cornea and restoration of vision. The excitement surrounding this technology is that one donor cornea may provide healthy, differentiated endothelial cells for 100 or more recipients, eliminating the worldwide shortage of donor tissue for transplantation."

"Human trials have started in the U.S. recently, and data from the initial work in Japan is very exciting," adds Dr. Houser. "There are a lot of patients with severe glaucoma or other ocular comorbidities who aren't great candidates for endothelial keratoplasty due to risk of pressure increase or who've already undergone several surgeries and one more may be a higher risk. The availability of an injection of cells that wouldn't require significant pressurization of the eye would be very beneficial for these patients. DMEK has been such a big improvement over DSAEK, and I'm excited for our next advancement." ◀

1. Terry MA, Shamie N, Chen ES, Phillips PM, Shah AK, Hoar KL, Friend DJ. Endothelial keratoplasty for Fuchs' dystrophy with cataract: Complications and clinical results with the new triple procedure. *Ophthalmology* 2009;116:4:631-9.
2. Eisenbeiz HC, Bleeker AR, Terveen DC, Berdahl JP. Descemet membrane endothelial keratoplasty and light adjustable lens triple procedure. *Am J Ophthalmol Case Rep* 2021;25:22:101061.



Sadeer Hannush, MD

**Some surgeons will use a microscope-mounted OCT to view the graft inside the anterior chamber to ensure it's in the correct orientation with the endothelial side toward the anterior chamber.**



# A REVIEW OF RETINAL DETACHMENT REPAIR

Retina specialists provide their insight on how to match the right procedure with the patient's unique history and particular type of detachment.

ANDREW BEERS  
ASSOCIATE EDITOR

Retinal detachment repairs have been done surgically since the early 1800s when English eye surgeon James Ware made the first operation in 1805 using a knife to puncture the sclera in order to drain subretinal fluid.<sup>1</sup> Surgeons have since come at retinal detachments in a variety of ways, dependent upon the patient's history and the particular type of detachment.

Here, experts detail how they select the best procedure for the job, as well as what's on the horizon for retinal detachment repair and treatment.

## Planning Your Approach

In addition to dealing with the very common rhegmatogenous retinal detachment, surgeons say there are a few other considerations to keep in mind when approaching a detachment patient.

If someone has a tractional detachment due to diabetes, this can cause some issues in the operating room. "In terms of repairing retinal

detachments, the most difficult ones are probably diabetic retinal detachments because there's an underlying disease process," says Tien Wong, MD, a retina specialist at Retina Consultants of Texas in Houston. "Usually, there's a lot of scar tissue and those are probably the more challenging cases."

Exudative retinal detachments also bear some extra consideration when planning treatment. "Exudative types of retinal detachments can be caused by a variety of things," notes Patrick Staropoli, MD, also a retina specialist at RCTX. "Sometimes it has to do with inflammation inside of the eye, either an infection or an inflammatory process. It can be caused if someone has a cancerous process in their eye that can also cause fluid to build up underneath the retina. In these cases, you're mostly targeting the cause of that fluid buildup. That calls for more of a medical treatment."

## Surgical Pearls

For surgical repair of detachments, there are various options, and surgeons say some of them can go

hand-in-hand. For the most common case of retinal detachment, rhegmatogenous, (according to the IRIS Registry, 237,646 patients underwent rhegmatogenous retinal repair in 2020 alone),<sup>2</sup> surgeons say there are certain initial steps you can take to help increase the chance of a good outcome.

"One of the things I assess first for a primary retinal detachment is the status of the vitreous," says Dr. Wong. "Do they have a vitreous separation? Because that changes how you would treat the patient. If it's a long-standing retinal detachment from somebody who was born with holes in the retina and they're young and their vitreous isn't separated from the retina, then vitrectomy isn't always the first choice for surgery."

Dr. Staropoli details how he approaches patients with rhegmatogenous detachments. "I think the main thing we want to ascertain with the patient is their history," he explains. "When did their symptoms start? Is this a process that's been going on for a long period of time or is it sudden? You want to get a sense for a couple things that will determine

This article has no commercial sponsorship.

Drs. Staropoli and Wong have no financial interests to disclose.

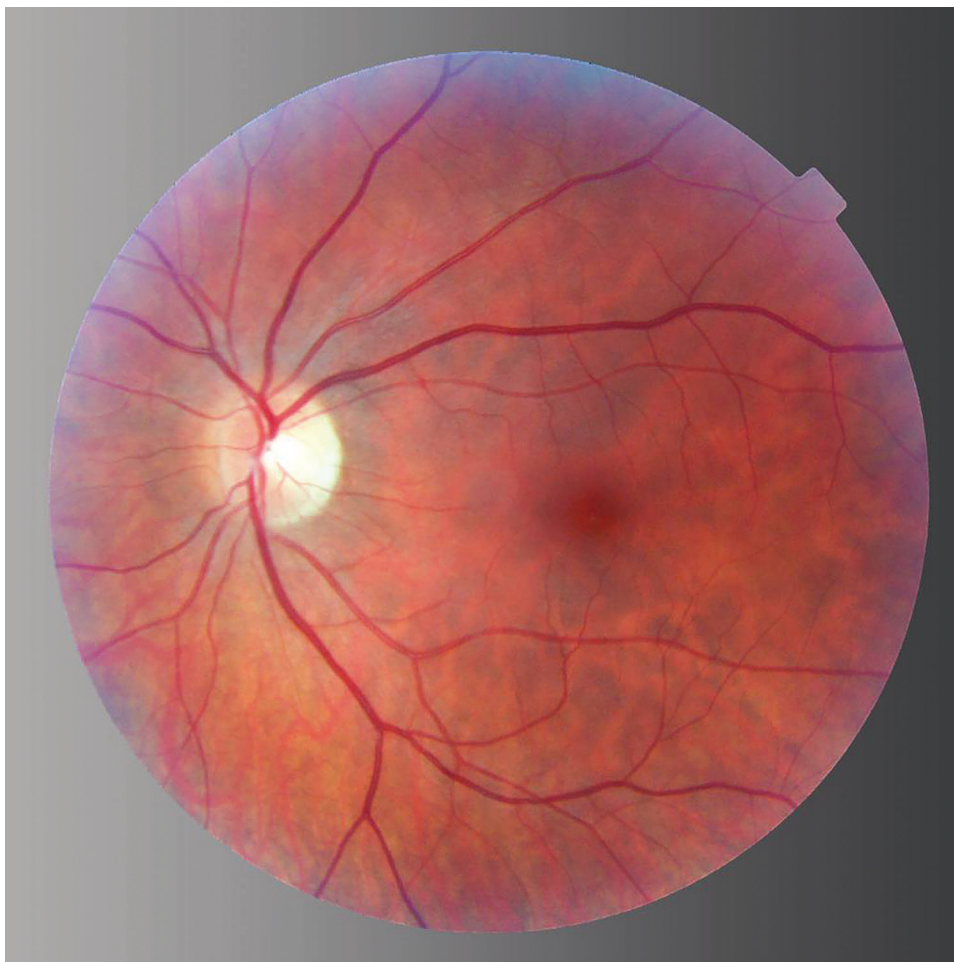
how you fix them surgically. So, patient's age is important, as well as their lens status and if they've had cataract surgery before or they're still phakic.

"The vitreous in a young patient is very thick, sticky, and adherent to the retina," says Dr. Staropoli. "As you get a little bit older and you have that posterior vitreous detachment or the vitreous starts to liquify, this makes doing a vitrectomy surgery a little easier. So, you want to talk to the patient, get their history, examine their eye for all those key things and then that sort of helps you decide what surgical approach you're going to take."

Once you understand the patient's history, you can better determine which surgical technique might be best. "People still have their own expertise or opinion about what works better in certain situations," Dr. Staropoli says. "I have general guidelines that I follow. Obviously, every case can have its nuances that you may take to do something different, but if I have a young patient with a retinal detachment, I would always try to do a scleral buckle first.

"You would also do cryotherapy on the tear," Dr. Staropoli continues. "You're basically trying to repair the retina from an outside approach without having to go inside the eye. This works nicely because in young people you don't want to—if you don't have to—try to remove the vitreous because that can lead to additional tears. Young patients can sometimes heal with a lot of inflammation and scarring, and that can cause re-detachments. So, in general, I'd say most people would prefer to start with a scleral buckle approach for a young patient. If that doesn't work, then the next surgical step would be moving on to a vitrectomy.

Dr. Staropoli outlines the dif-



**Proliferative vitreoretinopathy is the major cause of failure after retinal detachment surgery and the success rate of PVR surgery is unsatisfactory. Currently, there are multiple adjuncts being tested for the treatment and prevention of PVR, including methotrexate.**

ferent methods to performing a buckle. "Though buckling is done pretty much the same as it's always been," he says, "there are two camps in terms of how you put the scleral buckle on the eye. Some people like to suture it. However, when I trained at Bascom Palmer, we made scleral belt loops, which involved creating a partial-thickness scleral incision. You use a 64 blade and a Castroviejo scleral dissector, and you make the loops. Then, you pass the buckle through those loops rather than suturing it."

Dr. Staropoli details his approach for the older RD patient. "Now, when the patient age gets a little bit older, then we're talking about the most common patient: someone in

their 50s who still has their native lens (maybe it's a cataract at this point)," he says. "When they come in with a retinal detachment, in those cases I prefer to do a scleral buckle and a vitrectomy. You treat the tears at that time with a laser to 'tack down' the retina in that area right next to the tears, and those patients generally do very well."

For pseudophakic patients, the approach changes still. "The last category would be an older patient who's already had cataract surgery, so they're pseudophakic," Dr. Staropoli says. "Their vitreous gel at this point is more liquified. They probably already have a posterior vitreous detachment. Those are patients I'd consider just doing a vitrectomy on



and then using a gas bubble, because their vitreous poses a little bit less of a problem and you can fix the retina just as well with a vitrectomy.”

Tractional retinal detachments require a similar approach. “For diabetic retinal detachments, it’s almost always vitrectomy,” says Dr. Wong. “Also, the results for diabetic retinal detachments have improved with the use of anti-VEGF medications preoperatively to reduce retinal neovascularization, which reduces intraoperative bleeding.”<sup>3</sup> Surgeons have found that anti-VEGFs like bevacizumab, ranibizumab, aflibercept and others can help reduce intraoperative hemorrhage in the presence of large, active neovascular fronds, which may make repairing the detachment easier. Additionally, panretinal photocoagulation can assist with surgery. Some surgeons have found that this helps stabilize the eye in case of proliferative diabetic retinopathy in tractional retinal detachment cases.

### Pneumatic Retinopexy’s Place

Surgeons say that pneumatic retinopexy can still be useful in particular cases.

“Pneumatic retinopexies are great in certain situations,” says Dr. Staropoli. “So, if a patient is too sick to medically undergo anesthesia or have a surgery in the operating room, or if you’re a doctor who’s practicing in an area where you don’t have great access to an operating room, then pneumatic retinopexy could be an option.”

However, PR isn’t perfect. “The success rate isn’t as high as either scleral buckling, vitrectomy or a combination of both,” says Dr. Wong.

In a systematic review of articles comparing pneumatic retinopexy and vitrectomy, researchers divided patients into two groups: treatment-naïve and previously treated patients.<sup>4</sup> For patients who received a vitrectomy for retinal detachment repair (n=4,360), 91 percent of treatment-naïve patients’ visual acuity improved, and 85 percent of

previously treated patients’ visual acuity improved. For patients who received a pneumatic retinopexy for retinal detachment repair (n=1,577), 69 percent of treatment-naïve patients’ visual acuity improved, and 33 percent of previously treated patients’ visual acuity improved.

“**I think the main thing we want to ascertain with the patient is their history. When did their symptoms start? Is this a process that’s been going on for a long period of time or is it sudden?**

— Patrick Staropoli, MD

“So, when you do pneumatic retinopexy, it’s usually done for people who are very limited in terms of the number of tears,” explains Dr. Wong. “You often do them in people who have acute retinal detachments due to a peripheral vascular disease and a retinal tear that are located superiorly. However, if the tear is inferiorly located, pneumatic retinopexy wouldn’t work.” Concurrent cryotherapy is used to seal the tears.

“The whole goal is that you avoid having to take the patient into surgery,” comments Dr. Staropoli. “In the right patient, it works very well, and if you’re not able to get them into the operating room, then it’s a really good option.”

Surgeons detail how they employ laser or cryo-therapy during RD repair. “When we do scleral buckling, we primarily do cryo-retinopexy,” explains Dr. Wong. “But, when we do vitrectomy, we usually flatten the retina, reattach it and then add laser retinopexy. Therefore, in somebody

you put a scleral buckle on when you’re initially treating them, the retina becomes elevated. When it’s elevated, the laser won’t take, so then you have to use cryo-retinopexy.”

### Other Detachments

There are some cases, especially exudative retinal detachment cases, that require different methods of treatment. “You could see serous retinal detachments in someone with central serous retinopathy, which is associated with steroid use,” says Dr. Staropoli. “This can be treated medically just by taking the patient off of whatever systemic steroid medications they’re on.

“In neoplastic causes, people presenting with choroidal melanoma or metastasis from a cancer or somewhere else in the body—you’d see a serous retinal detachment. Obviously, the main treatment would be systemic,” continues Dr. Staropoli. “If they have metastatic cancer or if they have a choroidal melanoma, we sometimes treat them with plaque radiotherapy.”<sup>5</sup>

### Improvements to Repair Techniques

“I think that the field is constantly evolving in terms of the instruments and machines we use,” says Dr. Staropoli. “There are several different vitrectomy machines on the market now and what machine you use is usually dictated by whatever your hospital or practice has, but the instrumentation that we use continues to get smaller and smaller. So, way back when, before my time, they used to use large 20-gauge instruments to repair retinal detachments. Twenty-three-gauge then became more common. I’d say for me, in my training and at my practice, I more commonly use 25-gauge instruments, but they make 27-gauge, as well. So, vitrectomy is becoming less invasive. There’s sort of a trade-off in terms of how easily you’re able to maneuver the instruments and how quickly they’re able to remove the vitreous

## Get *more* out of your eyedrop bottles



Have you ever heard patients complain about their eyedrops? Maybe they ran out before the end of the month and had to wait for insurance to cover their next refill, or they suffer from side effects that are hard to tolerate? Have you noticed how much of the drop runs down your patients' faces when you dilate their eyes?

That's because eyedrops are too large for the eye to absorb. The Nanodropper Adaptor has solved this problem. Here's how it works!



**What's the problem with eyedrops?**

They're too big! **About five times too big.** This means 80% of every eyedrop (and thus, every bottle) is wasted due to overflow and/or systemic absorption. This waste contributes to financial barriers to care, and clinical research has shown that oversized drops increase both local and systemic side effects!



**How does Nanodropper help?**

Pretty simple — just twist the Nanodropper on to your current bottle to reduce the size of eyedrops to just what the eye can absorb! Smaller drops triple the number of drops per bottle, while maintaining therapeutic efficacy and improving tolerability.



*The Nanodropper is compatible with most of your commonly used in-office drops like phenylephrine and proparacaine, OTC drops like Lumify, and expensive glaucoma medications like Rhopressa, Rocklatan, Lumigan, Vyzulta, and many more!*

Less is more. Patients often think more is better, but it's not. Nanodropper is an exciting tool for patients to reduce the size of their eyedrop. When you reduce the size of the drop, you can often reduce the amount of side effects. Nanodropper can allow my patients' drops to last longer, even 2 or 3 months.

**-Constance Okeke, MD, Virginia Eye Consultants and advisor for Nanodropper**



Use discount code  
**ROPHM10** for 10%  
off your first order!



The Nanodropper is the only FDA-listed, volume-reducing adaptor for eyedrop bottles designed to deliver precisely the amount of fluid the eye can absorb. Smaller drops reduce the waste and cost of in-clinic and Rx formulations while minimizing local and systemic side effects.

### ADJUNCTS FOR PROLIFERATIVE VITREORETINOPATHY

Previous studies have looked at various pharmacological options in combination with retinal detachment surgery and proliferative vitreoretinopathy. “Steroids have been used in every formulation,” says Patrick Staropoli, MD, a retina specialist at Retina Consultants of Texas in Houston. “There’s been other agents like heparin, anti-VEGF agents, 5-fluorouracil—they’ve all been tried but nothing has definitively helped us with this problem.” Here’s an explanation on how these agents have been used in retinal detachment repair and what researchers have discovered in the past.<sup>1</sup>

Steroids have shown promising outcomes in preclinical models for the treatment of PVR, but clinical studies have contradicted these results. In one study on rabbits, researchers injected triamcinolone acetonide which led to a reduction in retinal detachments from 93 percent to 75 percent after 28 days. Clinical research of triamcinolone for patients with PVR undergoing vitrectomy in combination with a silicone oil tamponade showed no significant difference between the steroid group and the control. However, patients experiencing complications with open globe trauma could benefit from triamcinolone injections.

Heparin in combination with triamcinolone didn’t show any benefit in the treatment of PVR, but it did show promise in preclinical animal trials. Low molecular weight heparin has shown to reduce the rate of tractional retinal detachments in animals and decrease postoperative

fibrin after vitrectomy.

Anti-VEGFs assist with alleviating hemorrhages during traction retinal detachment cases, but they don’t show any promise in reducing retinal detachments in patients with PVR. Some studies have examined ranibizumab in animal models and discovered that it was effective in reducing the bioactivity of the vitreous in animals with PVR. Clinical trials have used bevacizumab for the reduction of retinal detachments in PVR patients. These studies observed the difference in final BCVA in PVR patients and a control. No significant difference was reported.

5-fluorouracil is an anti-neoplastic agent that has been proven to decrease the rate of PVR in animal models. When combined with low molecular weight heparin, 5-FU showed a considerable reduction in PVR retinal detachments. In a study with 87 participants receiving both 5-FU and heparin and another 87 participants receiving a placebo, postoperative PVR occurred in 12.6 percent of participants from the 5-FU and heparin group while PVR occurred in 26.4 percent participants from the placebo group. Visual acuity didn’t statistically significantly change.

1. Ferro Desideri L., Artemiev D., Zandi S. et al. Proliferative vitreoretinopathy: An update on the current and emerging treatment options. *Graefes Arch Clin Exp Ophthalmol* 2023. [Epub ahead of print].

gel, however. The smaller you get, the more difficult that is. I’d say a lot of people today use 25-gauge.”

Dr. Wong says the improved instrumentation has improved results. “When I first started practice over 30 years ago, the success rate for primary detachments was about 80 percent or so,” he says. “Now, I think it’s much closer to 90 to 95 percent with a single operation. The technology has improved dramatically. When I started, the equipment we used for vitrectomy, for example, would cut at a very slow rate, about 400 cycles per minute. Whereas now they’re at 20,000. So, illumination and vitrectomy technology have improved over the past 30 years, and our techniques have evolved, as well.”

Besides advancements to decrease the invasiveness of surgery and procedural time, there are ongoing trials and treatments that can better assist with managing proliferative vitreoretinopathy, which is a key reason for failure of RD repair.

“About 5 to 10 percent of patients<sup>6</sup>—sometimes it can be more

depending on the case—are at risk for developing scarring after repair of a retinal detachment,” says Dr. Staropoli. “That’s the leading cause for the retina re-detaching or requiring another surgery.

“People have looked at therapeutic options for this for a very long period of time,” Dr. Staropoli continues. “Steroids have been used in every formulation. There’s been other agents like heparin, anti-VEGF agents, 5-fluorouracil—they’ve all been tried but nothing has definitively helped us with this problem. The newest agent that people are using now is methotrexate. There was a large study of methotrexate’s use called the GUARD trial [Gain Understanding Against Retinal Detachment], that was completed a year or two ago, but the final paper and results haven’t come out yet. GUARD was showing really good promise for preventing PVR from developing and keeping these high-risk retinas attached. It’s interesting because the researchers followed a pretty intensive protocol. These patients had to

get an injection of methotrexate in the eye every week after the surgery for several weeks, and then every two weeks after that. So, it’s pretty labor intensive, but it could have a significant benefit in terms of preventing re-detachment.”

The GUARD trial was conducted for the FDA approval of ADX-2191 (intravitreal methotrexate 0.8%) from Aldeyra. According to Aldeyra, this drug was injected 13 times over 16 weeks after patients completed vitrectomy surgery for a retinal detachment. Here are the top-line results from Part 1 of the Phase III GUARD trial:<sup>7</sup>

- After a six-month period, 16 patients who received ADX-2191 (n=68) experienced a retinal detachment while 113 patients who received a standard procedure (n=292) experienced a retinal detachment;

- Letters of visual acuity achieved in ADX-2191 patients was 32.9 while 36.5 was achieved in the standard procedure candidates;

- Central macular subfield thickness in ADX-2191 patients was 382



µm while patients who received a standard procedure achieved 484 µm;

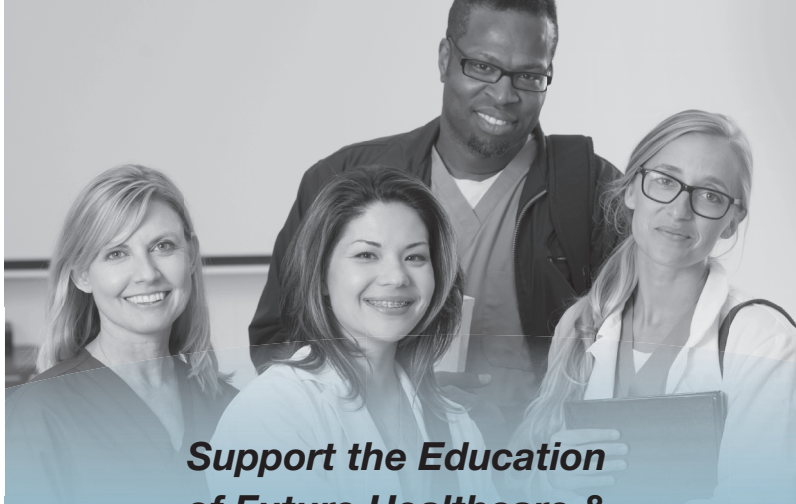
- Punctate keratitis was the most common adverse event in patients who were administered ADX-2191 (n=11, 16 percent). Nine cases were considered mild, while two cases were considered moderate;

- Treatment was discontinued in one patient due to scheduling conflicts.

Retinal detachments are a familiar territory for any retina specialist, and the landscape of technology and pharmaceuticals continues to advance, helping to improve success rates in surgery. However, another struggle lies with patients' awareness of detachment symptoms. "I think the main thing, especially when I meet a lot of patients, is that they're not sure when is the right time to come in and get their eyes checked, and they don't know if the symptoms they're experiencing are actually something that would require urgent surgical repair," says Dr. Staropoli. "Perhaps raising more awareness for those classic symptoms—the flashes and floaters—can encourage people to get their eyes dilated and checked by an ophthalmologist or a retina specialist because it could be something serious.

"People are sometimes really good at compensating when, for example, their non-dominant eye has a retinal detachment and therefore they don't recognize the symptoms," Dr. Staropoli continues. "Something as easy as covering up one eye, then the other eye and then noticing some flashes and floaters will help people figure out which eye it's coming from and encourage them to get in to see their eye doctor. The earlier you identify these problems, the easier they are to fix and the better visual and anatomical outcomes we can have." ◀

1. Rezaei K.A., Abrams G.W. The History of Retinal Detachment Surgery. In: Kreissig, I. Eds., Primary Retinal Detachment. Springer 2005.
2. Saraf SS, Lacy M, Hunt MS, et al. Demographics and seasonality of retinal detachment, retinal breaks, and posterior vitreous detachment from the intelligent research in sight registry. *Ophthalmology Science* 2022;2:2:100145.
3. Mishra C, Tripathy K. Retinal Tractional Detachment. StatPearls. Treasure Island (FL): StatPearls Publishing 2024.
4. Roshanshad A, Shirzadi S, Binder S, et al. Pneumatic retinopexy versus pars plana vitrectomy for the management of retinal detachment: A systematic review and meta-analysis. *Ophthalmol Ther* 2023;12:2:705-719.
5. The Collaborative Ocular Melanoma Study Group. The COMS randomized trial of iodine 125 brachytherapy for choroidal melanoma, III: Initial mortality findings: COMS Report No. 18. *Arch Ophthalmol* 2001;119:7:969-982.
6. Pennock S, Haddock LJ, Mukai S, et al. Vascular endothelial growth factor acts primarily via platelet-derived growth factor receptor  $\alpha$  to promote proliferative vitreoretinopathy. *Am J Pathol* 2014;184:11:3052-68.
7. Top-line results from part 1 of the phase 3 GUARD trial of ADX-2191 in proliferative vitreoretinopathy. Aldeyra Therapeutics 2022. <https://ir.aldeyra.com/static-files/cde1aa20-d22a-4f38-a9a5-523b803aca40>.



**Support the Education  
of Future Healthcare &  
Eyecare Professionals**

## THE RICK BAY FOUNDATION

*for Excellence in Eyecare Education*

Scholarships are awarded to advance the education of students in both **Optometry** and **Ophthalmology**, and are chosen by their school based on qualities that embody Rick's commitment to the profession, including integrity, compassion, partnership and dedication to the greater good.

**INTERESTED IN BEING  
A PARTNER WITH US?**

[www.rickbayfoundation.org](http://www.rickbayfoundation.org)


*(Contributions are tax-deductible in accordance with section 170 of the Internal Revenue Code.)*

### ABOUT RICK

Rick Bay served as the publisher of *The Review Group* for more than 20 years.

To those who worked for him, he was a leader whose essence was based in a fierce and boundless loyalty.

To those in the industry and the professions he served, he will be remembered for his unique array of skills and for his dedication to exceeding the expectations of his customers, making many of them fast friends.



**THE RICK BAY FOUNDATION**  
*for Excellence in Eyecare Education*

*(The Rick Bay Foundation for Excellence in Eyecare Education is a nonprofit, tax-exempt organization under section 501(c)(3) of the Internal Revenue Code.)*



EDITED BY MICHAEL COLVARD, MD  
AND STEVE CHARLES, MD

## TECHNOLOGY UPDATE

# Enhancing Vision With wEVES

*Wearable electronic vision enhancement systems can improve the lives of patients with AMD and low-vision conditions.*

**ANDREW BEERS**  
ASSOCIATE EDITOR

**V**irtual reality and augmented reality headsets have been taking the video game market by storm, allowing players to immerse themselves into new worlds and interact freely with games from their living rooms. Now that the technology is advancing, eye-care researchers and technology companies are beginning to figure out new ways to develop these devices to benefit the lives of patients with age-related macular degeneration.

## VR vs. AR

Many people who've tested head-mounted displays understand the difference between VR and AR, but there are also differences to how these technologies impact AMD patients.

"Virtual reality technology helps you immerse with the virtual world of your interest in which you're not connected to the real world," explains Sarika Gopalakrishnan, PhD, a post-doctoral research fellow at Envision Research Institute. "Augmented reality is very different. That helps enhance the view of the real world, which is incorporated in most of the electronic vision enhancement systems for low vision." Although Dr. Gopalakrishnan prefaces that AR technology devices control the majority of the wearable electronic vision enhancement system (wEVES)

landscape, there are devices with VR capabilities that can benefit patients with AMD.

"The lines between VR and AR are blurring as new devices come along, but typically VR produces a wider field of view and a brighter image than AR-style devices," says Andrew Miller, MS, a post-graduate researcher for the Vision and Hearing Science Research Center at Anglia Ruskin University in Cambridge, UK. "These features are clearly of potential benefit to people with vision impairment."

There may be a reason for why most wEVES use AR technology rather than VR. "VR-style devices tend to be heavier and are often housed in an enclosed headset compared to a much lighter and more open AR equivalent," says Dr. Miller. "The weight of the VR devices has been shown by others to be off-putting and a cause for abandonment of wEVES. When we showed devices to people with AMD, we found a very similar initial response with people questioning if they would be able to use them for anticipated tasks as well as thinking their appearance was strange and off-putting rather than high-tech."

## wEVES and Ocular Diseases

It should be understood that wEVES aren't solely marketed towards AMD. Rather, they can be used for a number of low-vision conditions and

pathologies. "My research work has proved that these augmented reality devices not only help people with AMD, but with most of the ocular conditions that cause low vision," says Dr. Gopalakrishnan. "So, most of these head-mounted displays are designed with a wide range of magnification, variable contrast, adjustable brightness, different viewing modes, along with image enhancements, which help the eye to process the same images much easier. That's how these devices are helpful for anyone with low vision. These devices are helping people perform their vision functions more efficiently and independently."

In one of her studies, Dr. Gopalakrishnan has found that these devices work well for patients with cone dystrophy, retinitis pigmentosa and optic atrophy along with AMD.<sup>1</sup> She explained that most devices in Western countries are marketed towards AMD, but these devices also provide comprehensive lists online for all ocular conditions that could benefit from the use of wEVES. For example, eSight lists the following conditions on their website:

- cataracts;
- central vision loss;
- cone rod dystrophy;
- diabetic retinopathy;
- diabetic vision loss;
- glaucoma;
- legal blindness;
- macular degeneration;
- ocular albinism;
- optic atrophy;
- optic nerve hypoplasia;
- retinopathy of prematurity; and
- Stargardt disease.

Research has shown that wEVES may benefit a low-vision patient's visual acuity. In Dr. Gopalakrishnan's study on the role of head-mounted augmented reality devices on improving

**This article has no commercial sponsorship.**

**Dr. Colvard** is a surgeon at the Colvard-Kandavel Eye Center in Los Angeles and a clinical professor of ophthalmology at the Keck School of Medicine of the University of Southern California. **Dr. Charles** is the founder of the Charles Retina Institute in Germantown, Tennessee.

visual functions of individuals with low vision, she observed 100 patients with ocular conditions presented earlier in this article.<sup>1</sup> The patients' distance visual acuity improved from 1.1 (0.7) to 0.15 (0.6) logMAR when using an AR device. Also, their near vision improved from 0.6 (0.7) to 0.3 (0.1) logMAR and their visual function score improved from 0.35 (0.26) to 1.89 (1.90).

"We need to be clear in understanding that these devices aren't a replacement treatment for AMD or any other disease," cautions Dr. Gopalakrishnan. "So, people need to follow the advice from their ophthalmologist to control the progression of their ocular condition, including AMD. Medical treatment, or surgical treatment, is the first level of treatment. These devices aren't considered to be treatment options. These are additional enhancement devices. If nothing works for them, either surgically or medically, and the ophthalmologist has tried their best to improve their patient's vision, but it's not at 100 percent, then to fill that gap, these devices can help make it 100 percent."

### Adverse Effects

"VR devices tend to completely immerse the user in virtual reality, cutting them off from the outside world," mentions Dr. Miller. "This loss of contact with the real world can have the potential to produce side effects such as headaches, nausea and seasickness symptoms in some individuals, and these symptoms are seen regularly in people using simulators or headsets. Thankfully these symptoms tend to be mild and often wear off quickly when the device is removed, so they can limit the time a device can be used comfortably. There's also been some research that tends to indicate that people with visual impairments may be slightly less sensitive to these symptoms than people who are fully sighted."

In a study to understand how vision impairments affect self-motion perception when using a head-mounted display, researchers from Australia observed candidates with normal vision, and AMD and glaucoma candidates with near-normal visual acuities.<sup>2</sup> They studied participants' experiences with self-motion in depth, or linear vection, spatial presence and cybersickness, or headaches and nausea. They found that AMD patients had greater vection strength and spatial presence when compared to participants with normal vision, while glaucoma had low vection strength and spatial presence. Additionally, they cited that the AMD and glaucoma groups both reported a reduction in the severity of cybersickness compared to candidates in the normal vision group.

Dr. Gopalakrishnan added that eye strain (asthenopia) is another common effect from excessive use of wEVES. She explained that patients who are claustrophobic, pregnant or epileptic may not be great candidates for these low-vision devices. According to her experiences using several devices, she noted that a warning screen does appear on the display of most devices, cautioning individuals that they may experience symptoms and that the device shouldn't be used by everyone.

(Continued from p. 32)

## Evaluating the Retina Before Surgery

some of these peripheral retinal changes," she says. "It's a low likelihood, but higher than your average person for developing a tear or detachment. I think it's important to do a really good peripheral exam on those patients and treat anything you see that could lead to problems down the road. Myopic degeneration is also important to watch for, but it's fairly obvious when it appears, even during a fundus exam." She points out that refractive surgery patients are typically young, without much macular pathology. "I would imagine that some refractive surgery surgeons are giving preop OCTs, but it's probably less critical to do so."

For corneal refractive surgery, such as LASIK, PRK or SMILE, Dr.

Donaldson says her team always does a dilated exam. "Macular OCTs are not the standard of care," she says. "However if we note an abnormality of the retina or nerve during our exam, we would proceed to the next step with imaging or we would arrange for a consultation with an appropriate specialist," she says. "For patients with high myopia (over -7 D or so), we often refer to a retinal specialist for clearance, especially if the patient has lattice degeneration with or without holes, or tears in the retinal periphery."

### Final Analysis

Given the complexity of pathologies now discoverable in the retina, all specialists agree that a cookbook approach isn't possible.

"Nothing is that straightforward in cataract or refractive surgery," Dr. Kao is quick to point out. "Challenges arise when a patient has had trauma or uveitis in the past, for example. It can be difficult to do a posterior exam on these patients. Another challenge is when the pupil is small or scarred down, or when we encounter a patient with a hard brunescens nucleus."

Dr. Grayson ultimately believes it's up to the surgeon's procedural skills and patient management efforts to steer clear of significant difficulty. "It's hard to imagine today that you would be doing cataract surgery on anyone without becoming aware of the retinal issues," he says. "There are so many different ways you can determine whether or not the retina might also have an issue." ◀

1. Scanlan D, Siddiqui F, Perry G, Hutnik CML. Informed consent for cataract surgery: What patients do and do not understand. *J Cataract Refract Surg* 2003;29:10:1904-12

2. McKeague M, Sharma P, Ho AC. Evaluation of the macula prior to cataract surgery. *Curr Opin Ophthalmol* 2018;29:1:4-8.

3. Baek J, Lee MY, Kim M, et al. Ultra-widefield fluorescein angiography findings in patients with macular edema following cataract surgery. *Ocul Immunol Inflamm* 2019;3:29:610-614.

4. Mitchell P, Smith W, Chey T, et al. Prevalence and associations of epiretinal membranes. The Blue Mountains Eye Study, Australia. *Ophthalmology* 1997;104:6:1033-40.

5. Chang JR, Koo E, Agron E, et al. Risk factors associated with incident cataracts and cataract surgery in the Age-related Eye Disease Study (AREDS): AREDS report number 32. *Ophthalmology* 2011; 118:11:2113-9.

6. Farooqian F, Agron E, Clemmons TE, et al. Visual acuity outcomes after cataract surgery in patients with age-related macular degeneration: Age-related eye disease study report no. 27. *Am J Ophthalmol* 2009;116:11:2093-100.



## Patient Satisfaction

In the end, wEVES are meant to help patients with low vision. Dr. Miller conducted a qualitative investigation of the views of patients with AMD who've tested out these systems.<sup>3</sup> "It was really interesting to understand that a lot of our current supporting solutions for vision impairment associated with AMD centered on the need to improve reading ability, and this is a key requirement for anyone with AMD. However, we tend to have less suitable solutions for other tasks such as recognizing faces or completing tasks in the midrange. It was interesting to hear people imagining their usefulness for creative tasks, not just the practical, considering that they would be suited to returning to an enjoyment of the arts or craft-work for example, or even just looking at their grandchildren's faces."

From the study, Dr. Miller states that the devices "may be reframed by users to focus predominately on sedentary tasks taking place in isolation at home." He goes on to explain, "This view was driven by our participants' views based on the appearance of an AR and VR-style device that we showed them. They felt the devices didn't appear high-tech, but instead described them as otherworldly, feeling that the use of the device around others would make them feel uncomfortable even if the device solved the practical problem at hand. As we discussed in that article, it may well be that with wider adoption of headsets in the gaming and work environment may ultimately make these devices more socially acceptable and ultimately support the use by people with a visual impairment."

Currently, Dr. Gopalakrishnan is researching how wEVES can benefit low-vision patients in the workplace. "These devices are enabling them to work as equally as a normally sighted person and with effective speed and accuracy," she explains.

It's the patient's life at home where these devices become the most beneficial. "There's enough evidence that these devices are really helpful



eSight

**The eSight 4 can be connected to the charging cable while the user wears the headset in order to maintain prolonged use without changing the batteries. This feature works well for stationary tasks.**

in changing the lifestyles of people at home," says Dr. Gopalakrishnan. "They're able to see much better with these devices, so they're able to recognize facial expressions of their family and friends, watch television, read newspapers, magazines and use appliances. So, there's a lot of tasks that they're able to do with these devices. It's really changing their lifestyles at home and they're feeling happy with that."

## wEVES on the Market

The market for wEVES continues to grow and advance with new devices and technology releasing every year. Here are some devices to improve the lives of patients with AMD and other low-vision conditions.

- **eSight 4.** ESight 4 is the latest vision enhancement system from eSight, marketed for all-day comfort and use. According to their user guide, this device is equipped with a camera on the front of the headset along with an ambient light sensor, a recording light and a focus sensor. To increase comfort and stability, eSight added a halo band that wraps around the forehead that can be adjusted for size. The right arm of the headset includes a touch pad for user control, a power button and a status indicator to signal whether the device is booting up, ready for use, in sleep mode or if an error occurred.

According to their website, ESight 4's display has a system acuity greater than 20/20 on the Snellen chart. Inside

the headset are two dual independent high-resolution OLED color screens, which can be repositioned to fixate on the center of the user's eyes. Additionally, there are two rechargeable lithium-ion batteries that hold approximately three hours of charge each. Only one battery is needed to power eSight, while the other can be charging, then swapped out after three hours of use.

Patients who are struggling to use the touch pad to control their settings can choose to use the remote control compatible with eSight 4. This remote provides advanced controls allowing the user to raise or dim brightness levels, switch between focusing on objects near and far, as well as zoom magnification. These functions can also be controlled using eSight's Apple and Android mobile apps.

ESight 4 comes with 256 GB of storage allowing the user to capture and store images within the device. Additionally, there are three built-in speakers for more immersive experiences. This device is also set to work with WiFi, Bluetooth and HDMI inputs in order to project smartphone and television displays onto the screens of the headset. There's also the option of downloading eCast and eMirror mobile apps as an additional way of projecting smartphone images onto the headset's display.

The user guide states that eSight shouldn't be worn when driving, operating machinery or any other visually

demanding activity for which there is an inherent risk of injury or death. When the visor for the headset is fully down over the eyes, then the user is limited to sedentary tasks, like reading, writing and watching television. But when the visor is partially up, the user can still receive benefits from the headset while walking or interacting with friends and family.

• **IrisVision Live 2.0.** Equipped with Samsung smartphone technology, the IrisVision Live 2.0 comes with a 1440x3120 display and a 50 MP camera, according to their website. The display offers a 70-degree field of view with different viewing modes. One particular mode, RP Mode, is designed for glaucoma and retinitis pigmentosa patients to allow them to regain their peripheral vision by shrinking their field of view.

According to their user guide, IrisVision Live 2.0 begins in Focus Mode, allowing the user to adjust the focus of the display before using other functions. Users should understand that they'll need to wear their distance prescription glasses when setting up and using this headset.

After setup is complete, users have the option of using voice commands to control IrisVision Live 2.0. They can ask the device to take photos, reduce or raise brightness, zoom in and out of images, and enlarge text while reading. Additionally, photos can be stored in the photo gallery on the IrisVision headset.

IrisVision Live 2.0 comes equipped with speakers for various uses. Users can connect their device to WiFi and watch videos controlled by voice commands. These videos can be played, paused and even magnified to help the user see more clearly. Furthermore, some text may still be too small or difficult for a user to read. That's why IrisVision added optical character recognition that'll scan text and read it aloud for the user.

The design for IrisVision Live 2.0 is made up of a visor with a Samsung display connected to adjustable straps that wrap around the sides and top

of the user's head. Instead of adding a battery pack to the back of the strap for multiple rechargeable batteries, this device uses a wireless charging pad. However, there's an option to connect a magnetic braided power cable to allow the user to connect their device to an external battery pack to allow for longer use of the device.

According to their user guide, IrisVision Live 2.0 should be kept dry and out of direct sunlight. They preface that no users should be wearing this headset while walking or driving a vehicle. For patients with a pacemaker, IrisVision warns not to wear the headset around the neck on a lanyard. Also, if the user turns on accessibility options on the display unit or locks themselves out of the screen, then the device won't function correctly.

• **NuEyes e3+.** This device has four tracking cameras, a depth sensor, gyroscope and a proximity sensor. The company says the device helps the user watch television, read, cook or paint while viewing everything through an Ultra HD camera. NuEyes e3+ is marketed as a wearable magnifier with inter-pupillary distance adjustments allowing the user to focus images and adjust diopter ranges. Therefore, the user can go glasses-free with it.

NuEyes e3+ is equipped with optical character recognition and text-to-speech functions. This device responds to voice commands to adjust settings, but two handheld wireless controllers (one for each hand) are implemented to modify the users viewing experience.

NuEyes is implementing their e3+ technology into the Vive XR Elite. This uses extended reality technology, which, according to Vive's website, is an umbrella term for VR, AR, and mixed reality. This type of technology allows the user to switch easily from environment to environment without having to be immersed in a virtual world while walking or augmented reality while watching television.

Besides the technology added by Vive, NuEyes e3+'s display comes with a 110-degree field of view, magnification up to 18x, and variable contrast

options. The display offers a resolution of 1920x1920 pixels per eye and the headset tracking allows for six degrees of freedom (6DoF). Three degrees of freedom only allows the headset to track the rotational movement of the head, but it can't compute for walking, crouching, sitting or standing up. 6DoF allows the headset to track more movements from the user as they tend to their daily activities.

Additionally, according to their website, NuEyes e3+ comes with two rechargeable batteries with up to two hours of continuous power each. For comfort, the headset can be adjusted, although there's only a single band that wraps around the head. Instead, the battery pack is contained in a compartment at the back of the headband along with an added cushion for extra comfort and stability.

There are many more devices on the market, and as they advance, physicians and patients may find new ways to use the technology to better their lives. "When smartphones and tablets arrived, they brought sweeping changes to many people with visual impairments, bringing a previously unthought level of accessibility to a mainstream device," says Dr. Miller. "With the release of new headsets by major manufacturers, it's wonderful to be looking at the start of a new era of potential support for people with sight impairment. However, it's still unclear at this time how significantly these devices will be adopted by people with sight loss, including those with AMD." ◀

1. Gopalakrishnan S. Role of head mounted augmented reality device in improving visual function of individuals with low vision. *Investigative Ophthalmology & Visual Sciences* 2023;64:8:5522.

2. Luu W, Zangerl B, Kalloniatis M, Palmisano S, Kim J. Vision impairment provides new insight into self-motion perception. *Investigative Ophthalmology & Visual Sciences* 2021;62:2:4.

3. Miller A, Macnaughton J, Crossland MD, Latham K. "I'm like something out of star wars": A qualitative investigation of the views of people with age-related macular degeneration regarding wearable electronic vision enhancement systems. *Disability and Rehabilitation* 2023;1:10.

## DISCLOSURES

**Drs. Gopalakrishnan** and **Miller** have no financial interests to disclose.

# IOP Spikes in Glaucoma Subtypes After Phaco

Researchers evaluated risk factors for intraocular pressure spikes in glaucomatous eyes following cataract surgery using the IRIS Registry, as part of a retrospective clinical cohort study.

Adults with IRIS Registry data who underwent standalone phacoemulsification between January 1, 2013, and September 30, 2019, were included.

An IOP spike was defined as a postoperative IOP >30 mmHg and >10 mmHg from baseline within the first postoperative week. Odds ratios for demographic and clinical characteristics were calculated with univariate and multivariate logistic regression analyses. Main outcome measures included incidence and OR of IOP spike.

Researchers analyzed data from 1,191,034 eyes (mean age: 71.3 years; 61.2 percent females, 24.8 percent with glaucoma). Here are some of the findings:

- An IOP spike occurred in 3.7 percent of all eyes, 5.2 percent of eyes with glaucoma and 3.2 percent of eyes without glaucoma ( $p < 0.0001$ ).
- Multivariable analyses of all eyes indicated a greater risk of IOP spike with:
  - higher baseline IOP (OR, 1.57 per 3 mmHg);
  - male sex (OR, 1.79);
  - glaucoma (OR, 1.19);
  - black race (OR, 1.39 compared to Asian; OR, 1.21 compared to Hispanic);
  - older age (OR, 1.07 per 10 years) and complex sur-

gery coding (OR, 1.22; all  $p < 0.0001$ ).

- Diabetes (OR, 0.90) and aphakia after surgery (OR, 0.60) appeared to be protective against IOP spikes (both  $p < 0.0001$ ).
- Compared to glaucoma suspects, a greater risk of IOP spike was reported, with:
  - ocular hypertension (OR, 1.55);
  - pigmentary glaucoma (OR, 1.56); and
  - pseudoexfoliative glaucoma (OR, 1.52).
- Compared to glaucoma suspects, less risk of IOP spike was reported, with:
  - normal-tension glaucoma (OR, 0.55), primary angle closure (PAC suspects (OR, 0.67) and PAC glaucoma (OR, 0.81; all  $p < 0.0001$ ).
- More baseline glaucoma medications were associated with IOP spikes (OR, 1.18 per medicine) while topical beta-blocker use (OR, 0.68) was protective (both  $p < 0.0001$ ).

Researchers reported that higher baseline IOP, male sex, glaucoma, black race, older age and complex cataract coding were associated with an early postoperative IOP spike, while diabetes and postoperative aphakia were protective against a spike following standalone phacoemulsification. They added that glaucomatous eyes demonstrated different risk profiles dependent on glaucoma subtype and that the findings may help surgeons stratify and mitigate the risk of IOP spike after cataract surgery.

*Ophthalmology* 2024; Jan 19. [Epub ahead of print]

Lidder AK, Vanner EA, Chang TC, et al.

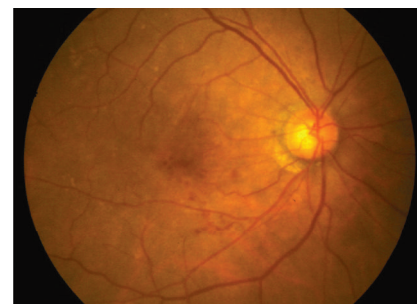
## Possible Predictor of Visual Prognosis in Refractory AMD

Since some patients with neovascular age-related macular degeneration respond insufficiently to anti-VEGF treatment despite maximal monthly intravitreal injections, researchers evaluated patients' short-term responses between injections for extent and visual prognosis.

In the retrospective observational study, 45 eyes from 41 patients with refractory nAMD (who previously received at least 12 months of anti-VEGF treatment) were evaluated by optical coherence tomography in between monthly anti-VEGF injections. The fluid profile on OCT was evaluated before, and one week and one month after intravitreal injection using central retinal thickness (CRT), manual measurements and fluid-specific volumetric measurements performed by an automated AI-based algorithm.

Here are some of the findings:

- A significant improvement was found at week one in:
  - CRT ( $p < 0.0001$ );
  - intraretinal fluid (IRF) ( $p = 0.007$ );
  - subretinal fluid (SRF) ( $p < 0.0001$ ); and
  - pigment epithelium detachment (PED) volume ( $p < 0.0001$ ).



This article has no commercial sponsorship.



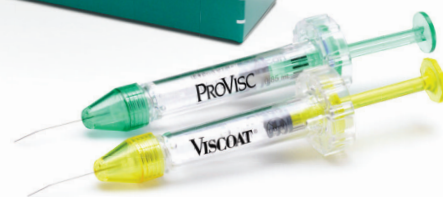# TRIPLE-CHARGED FOR SUPERIOR CORNEAL PROTECTION<sup>1,2,†</sup>

## Choose the surgeon-preferred DuoVisc<sup>®</sup> OVD system, powered by chondroitin sulfate.<sup>1-4</sup>

Experience the superior endothelial protection of VISCOAT<sup>®</sup> OVD and the excellent space maintenance of ProVisc<sup>®</sup> OVD in one versatile OVD system designed to meet your advanced surgical needs.<sup>1-3, 5-7, †</sup>



Activate the QR code to learn why Alcon OVDs have been trusted in over 160 million procedures.<sup>4</sup>



For Important Product Information, please see adjacent page.

© 2021 Alcon, Inc. 10/21 US-DUV-2100006

**Alcon**

<sup>†</sup>VISCOAT<sup>®</sup> showed significantly lower superior corneal endothelial cell loss at 16 weeks post-op compared to HEALON<sup>®</sup>; n=59, P<0.01.

\*Trademarks are the property of their respective owners.

### References

1. Glasser DB, Katz HR, Boyd JE, et al. Protective effects of viscoelastic solutions in phacoemulsification and traumatic lens implantation. *Arch Ophthalmol*. 1989;107(7):1047-1051.
2. Petroll WM, Jafari M, Lane SS, et al. Quantitative assessment of ophthalmic viscosurgical device retention using in vivo confocal microscopy. *J Cataract Refract Surg*. 2005;31(12):2363-2368.
3. Lindstrom RL, Ong M. Protective effect of OVDs against hydrogen peroxide-induced oxidative damage to corneal endothelial cells: in vitro model. Presented at ASCRS; 26 Mar 2011; San Diego, CA.
4. Alcon Data on File, 2020.
5. DuoVisc<sup>®</sup> Package Insert.
6. Poyer JF, Chan KY, Arshinoff SA. New method to measure the retention of viscoelastic agents on a rabbit corneal endothelial cell line after irrigation and aspiration. *J Cataract Refract Surg*. 1998;24(1):84-90.
7. Labiris G, Sideroudi H, Rousopoulos K, et al. Cohesive versus dispersive-cohesive ophthalmic viscosurgical device in torsional intelligent phaco. *J Cataract Refract Surg*. 2015;41(3):681-682.

## Important Product Information for DUOVISC® OVD

**Description:** DuoVisc® Viscoelastic System is designed to provide two Viscoelastic materials with different physico-chemical properties that can be used differently and/or sequentially to perform specific tasks during a cataract procedure. DuoVisc® Viscoelastic System consists of VISCOAT® Ophthalmic Viscosurgical Device and ProVisc® Ophthalmic Viscosurgical Device. **Caution:** Federal (USA) law restricts this device to sale by, or on the order of, a physician.

**Description:** VISCOAT® (Sodium Chondroitin Sulfate – Sodium Hyaluronate) Ophthalmic Viscosurgical Device. **Indications:** VISCOAT® OVD is indicated for use as an ophthalmic surgical aid in anterior segment procedures including cataract extraction and intraocular lens (IOL) implantation. VISCOAT® OVD maintains a deep anterior chamber during anterior segment surgeries, enhances visualization during the surgical procedure, and protects the corneal endothelium and other ocular tissues. The viscoelasticity of the solution maintains the normal position of the vitreous face and prevents formation of a flat chamber during surgery. **Warnings/Precautions:** Failure to follow assembly instructions or use of an alternate cannula may result in cannula detachment and potential patient injury. Precautions are limited to those normally associated with the surgical procedure being performed. Although sodium hyaluronate and sodium chondroitin sulfate are highly purified biological polymers, the physician should be aware of the potential allergic risks inherent in the use of any biological material. **Adverse Reactions:** VISCOAT® OVD has been extremely well tolerated in human and animal studies. A transient rise in intraocular pressure in the early postoperative period may be expected due to the presence of sodium hyaluronate, which has been shown to affect such a rise. It is therefore recommended that VISCOAT® OVD be removed from the anterior chamber by thorough irrigation and/or aspiration at the end of surgery to minimize postoperative IOP increases. Do not overfill anterior chamber. **ATTENTION:** Please refer to the Directions for Use for a complete listing of indications, warnings and precautions.

**Description:** ProVisc® (Sodium Hyaluronate) Ophthalmic Viscosurgical Device. **Indications:** ProVisc® OVD is indicated for use as an ophthalmic surgical aid in the anterior segment during cataract extraction and intraocular lens (IOL) implantation. Ophthalmic viscoelastics serve to maintain a deep anterior chamber during anterior segment surgery allowing reduced trauma to the corneal endothelium and surrounding ocular tissues. They help push back the vitreous face and prevent formation of a flat chamber during surgery. **Warnings/Precautions:** Postoperative increases in intraocular pressure have been reported with sodium hyaluronate products. The IOP should be carefully monitored and appropriate therapy instituted if significant increases should occur. It is recommended that ProVisc® OVD be removed by irrigation and/or aspiration at the close of surgery. Do not overfill anterior chamber. Although sodium hyaluronate is a highly purified biological polymer, the physician should be aware of the potential allergic risks inherent in the use of any biological material; care should be used in patients with hypersensitivity to any components in this material. Cannula assembly instructions should be followed to prevent patient injury. **Adverse Reactions:** Postoperative inflammatory reactions such as hypopyon and iritis have been reported with the use of ophthalmic viscoelastics, as well as incidents of corneal edema, corneal decompensation, and a transient rise in intraocular pressure. **ATTENTION:** Please refer to the directions for use for a complete listing of indications, warnings and precautions.

# Alcon

## RESEARCH REVIEW

- Volumetric fluid measures revealed a >50 percent reduction at week one for IRF and SRF for approximately two-thirds of eyes.
- Poorer short-term response was associated with:
  - larger exudative fluid amounts (IRF + SRF) ( $p=0.003$ );
  - larger PED ( $p=0.007$ );
  - lower visual acuity ( $p=0.004$ ); and
  - less anatomic changes at treatment initiation ( $p<0.0001$ ).
- Univariate and multivariate analysis revealed that visual outcomes four and five years later were significantly worse with:
  - weaker short-term responsiveness ( $p=0.005$ );
  - presence of atrophy ( $p=0.01$ ); and
  - larger PED volumes ( $p=0.002$ ).

Researchers wrote that incomplete responders to anti-VEGF showed a significant short-term response, identifiable at one week after injection, with rapid recurrence at one month. Weaker short-term responsiveness at one week was associated with poorer long-term visual prognosis. Researchers suggested such patients may need adjuvant treatment to improve their prognosis.

*Eye (Lond) 2024; Jan 26. [Epub ahead of print].*  
Gigon A, Iskandar A, Kasser S, et al.

## Ocular Surface Problems' Effect on Cataract Surgery Outcomes

Scientists studied the visual outcome and postoperative complications of cataract surgery in patients with ocular surface disorders at a tertiary eye-care center in North India, as part of a retrospective observational study.

Patients with various ocular surface disorders with stabilized ocular surfaces who underwent cataract surgery during this period and had a minimum postoperative follow-up of

six weeks were included. The primary outcome measures were postoperative best-corrected visual acuity at six weeks, best BCVA and postoperative complications.

The study included 20 men and 24 women. A total of 55 eyes were evaluated including those with the following issues:

- Stevens-Johnson syndrome (SJS) (35)
- ocular cicatricial pemphigoid (OCP) (4);
- dry eye (8);
- chemical injury (6); and
- vernal keratoconjunctivitis (VKC) (2).

Here were some of the findings:

- The mean duration of ocular surface disorders was 33.9 ±52.17 months.
- The median preoperative BCVA was 2.0 (IQR, 1.45 to 2).
- The median BCVA ever achieved was 0.50 (IQR, 0.18 to 1.45) at two months, and the median BCVA was achieved at six weeks was 0.6 (IQR, 0.3 to 1.5).
- Maximum improvement in BCVA was noted in patients with DED and SJS, with the least improvement in OCP.
- Phacoemulsification was performed in 47.27 percent of eyes, with intraoperative complications noted in 9 percent of eyes.
- Postoperative surface complications occurred in 12 eyes (21.82 percent).
- Other postoperative complications occurred in nine eyes (16 percent).

Scientists wrote that cataract surgery outcome can be visually beneficial in patients with ocular surface disorders provided ocular surface integrity is adequately maintained preoperatively and postoperatively.

*J Cataract Refract Surg 2024; Jan 16. [Epub ahead of print].*  
Aggarwal M, Gour A, Gupta N, et al.

## Efficacy and Safety of Faricimab for ME Due to RVO

Researchers evaluated the 24-week efficacy and safety of the dual angiopoietin-2 (Ang-2)/vascular endothelial growth factor-A (VEGF-A) inhibitor, faricimab, compared with aflibercept in patients with macular edema due to retinal vein occlusion, as part of two identically designed, Phase III, global, randomized, double-masked, active comparator-controlled trials: BALATON and COMINO.

Participants included patients  $\geq 18$  years of age with treatment-naïve foveal center-involved macular edema due to branch (BALATON) or central or hemiretinal (COMINO) RVO. Patients were randomized 1:1 to faricimab 6 mg or aflibercept 2 mg every four weeks for 24 weeks.

The primary endpoint was the change from baseline in best-corrected visual acuity at week 24. Efficacy analyses included patients in the intention-to-treat population. Safety analyses included patients who received at least one dose of study drug.

A total of 553 patients were enrolled in BALATON, and 729 patients were enrolled in COMINO. Here are some of the findings:

- The BCVA gains from baseline at week 24 with faricimab were noninferior to aflibercept in:
  - BALATON (adjusted mean [95.03 percent CI change]: +16.9 letters; CI, 15.7 to 18.1 vs. +17.5 letters; CI, 16.3 to 18.6; and
  - COMINO (+16.9 letters; CI, 15.4 to 18.3 vs. +17.3 letters; CI, 15.9 to 18.8).
- Adjusted mean (95.03 percent CI) central subfield thickness reductions from baseline were comparable for faricimab and aflibercept at week 24, respectively, in:
  - BALATON (-311.4  $\mu\text{m}$ ; CI, -316.4 to -306.4; and -304.4  $\mu\text{m}$ ; CI, -309.3 to -299.4); and
  - COMINO (-461.6  $\mu\text{m}$ ; CI, -471.4 to -451.9; and -448.8  $\mu\text{m}$ ; CI, -458.6 to -439).
- A greater proportion of patients in the faricimab vs. the aflibercept arm achieved absence of fluorescein angiography-based macular leakage at week 24 in:
  - BALATON (33.6 percent vs. 21 percent; nominal  $p=0.0023$ ); and COMINO (44.4 vs. 30 percent; nominal  $p=0.0002$ ).
- Faricimab was well-tolerated, with an acceptable safety profile comparable with aflibercept.
- The incidence of ocular adverse events was similar between patients receiving faricimab and aflibercept (20.4 percent [n=56] and 27.7 percent [n=100]) in:
  - BALATON (16.3 percent [n=45]); and
  - COMINO (23 percent [n=84]).

Researchers reported the findings demonstrated the efficacy and safety of faricimab, a dual Ang-2/VEGF-A inhibitor, in patients with macular edema secondary to retinal vein occlusion. ◀

*Ophthalmology* 2024; Jan 25. [Epub ahead of print].

Tadayoni R, Paris LP, Danzig CJ, et al.

# Does Your Optical Biometer Struggle With Dense Cataracts?

## SCANMATE

## We have a solution

The Scanmate *A* is a portable, USB connected ultrasound A-Scan biometer used to obtain axial length measurements. The Scanmate *A* utilizes unique alignment and compression detection algorithms. These exclusive features give real-time guidance for optimizing alignment and minimizing compression. You can be confident that your axial measurements will be accurate, reliable and repeatable.



**DGH** TECHNOLOGY, INC.  
THE ULTRASOUND SPECIALIST

Serving Eye Care Professionals for over 40 Years

🌐 [www.dghtechnology.com](http://www.dghtechnology.com)

☎ (800) 722 3883

✉ [sales@dghtechnology.com](mailto:sales@dghtechnology.com)





EDITED BY KULDEV SINGH, MD, MPH,  
AND PETER A. NETLAND, MD, PHD

## GLAUCOMA MANAGEMENT

# Systemic Factors In Glaucoma

*When patients continue progressing despite low IOP, what else can be done? Consider these underlying issues.*

**VICTORIA M. ADDIS, MD**  
PHILADELPHIA

**E**levated intraocular pressure is usually considered the only modifiable risk factor for glaucoma, but particularly for normal-tension disease, where progression may continue despite pressures in the normal to low range, there may be systemic pathogenic factors at play, some of which are potentially modifiable. Here, I'll discuss several of those less commonly considered systemic factors and what recommendations we can offer to our patients.

### Vascular Hypothesis & NTG

The vascular hypothesis of glaucomatous optic neuropathy is relatively well established in normal-tension glaucoma. Diminished perfusion of the optic nerve by the peripapillary microcirculation leads to retinal ganglion cell stress and ultimately cell death and atrophy. However, many risk factors are controversial with respect to their effect on glaucomatous damage, and others haven't been thoroughly studied.

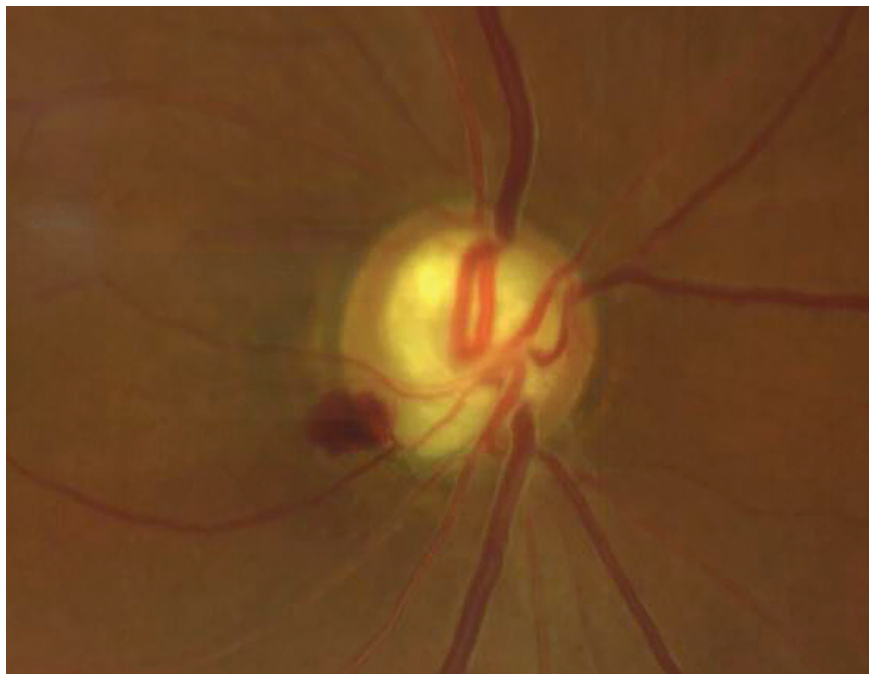
A large retrospective case control study published in the *Journal of Glaucoma* in 2022 reported that among patients seen at the Mayo Clinic (n=277 NTG patients; n=277

controls), multiple vascular-associated conditions were found with a higher frequency in normal-tension patients when compared to controls.<sup>1</sup> Though diabetes, dyslipidemia, high cholesterol and coronary artery disease were found to be positively associated with normal-tension glaucoma in this study, other studies haven't

found the same associations.

The authors of this study further classified patients with normal-tension disease into two separate groups. Phenotype 1 was defined as patients with risk factors that are associated with metabolic syndrome, including hypertension, diabetes mellitus, peripheral vascular disease, coronary artery disease and obstructive sleep apnea. Phenotype 2 was defined as patients with Raynaud's syndrome, migraine headaches, anemia or systemic hypotension.

In the study, the phenotype-2 patients were more likely to be female, younger, have a lower body mass index and lower intraocular pressure. The association of phenotype 2 patients with disturbed



Victoria M. Addis, MD

**Researchers at the Mayo Clinic identified two different phenotypes of normal-tension glaucoma patients. Phenotype 1 included patients with risk factors for metabolic syndrome, such as hypertension, diabetes mellitus and coronary artery disease, while phenotype 2 included patients with Raynaud's syndrome, migraine headaches, anemia or systemic hypotension.**

This article has  
no commercial  
sponsorship.

**Dr. Singh** is a professor of ophthalmology and chief of the Glaucoma Division at Stanford University School of Medicine. He is a consultant to Alcon, Allergan, Santen, Sight Sciences, Glaukos and Ivantis. **Dr. Netland** is Vernah Scott Moyston Professor and Chair at the University of Virginia in Charlottesville.



# Discover the ergonomic benefits of Vantage Plus BIO with our free **whitepaper**



## Leading the way in comfort, balance and intuitive design:

### 1: Cushioned comfort

Ergonomically designed, prioritising comfort and weight distribution. The soft, plush headband padding delivers a secure and comfortable fit, reducing the risk of slipping or shifting.

### 2: Balanced stability

Keeler's balanced, lightweight design reduces strain and discomfort during prolonged examinations, requiring half as much force to maintain a neutral position compared to other models.

### 3: Ergonomic fit

The fully adjustable headset enables clinicians to customise optics and headband positioning for comfort, reducing strain and pressure on the head and neck.

Visit **Keeler at ASCRS, stand 1043** to discover our extensive range of BIOs and more!

Keeler commissioned an independent assessment from US Ergonomics (2023) of its Vantage Plus BIO to understand its ergonomic performance with eye care professionals. Results highlighted these features which contribute to the comfort and usability of Keeler's devices.



autoregulation and higher risk of normal-tension glaucoma has been described previously.

### History-taking

The diagnostic evaluation of normal-tension glaucoma should always begin with a thorough medical history and review of systems. It's not uncommon for patients with normal-tension disease to communicate a history of cold extremities, migraine headaches, systemic hypotension or other signs of vascular dysregulation. A complete history may also be helpful in alerting the clinician to the possibility of non-glaucomatous causes of optic neuropathy, such as prior ocular trauma or other CNS pathology.

### Blood Pressure Treatment

The definition of high blood pressure has changed over time, and patients are now often treated more aggressively. However, many studies have demonstrated a correlation between both arterial hypertension and hypotension and glaucoma. Most experts believe that the treatment of hypertension is the culprit behind subsequent normal-tension glaucoma and optic nerve ischemic damage.

Exaggerated nocturnal hypotension or dips in blood pressure at night, which may compromise susceptible capillary beds, has been implicated in optic nerve head ischemia and glaucoma progression in the setting of well-controlled intraocular pressure. I routinely ask my patients to check their blood pressure at night and notify me and their primary care physician if it's very low.

A study of treated normal-tension glaucoma patients followed longitudinally by 48-hour blood pressure monitoring demonstrated that the duration and magnitude of the nocturnal systemic hypotension, particularly when the nocturnal mean arterial pressure was 10 mmHg lower than the daytime mean arterial pressure, were risk factors for visual field deterioration in normal-tension



**Nocturnal hypotension or blood pressure fluctuations can contribute to optic nerve head ischemia and glaucoma progression. Taking antihypertensive medications in the morning instead of before bed is now recommended for glaucoma patients, based on a study that found no difference in adverse cardiovascular events associated with morning or evening dosing.**

patients.<sup>2</sup>

In a 2015 study looking at morning versus evening dosing of the blood pressure medication valsartan, equivalent 24-hour blood pressure efficacy for once-daily dosing of valsartan 320 mg was found regardless of dosing time.<sup>3</sup>

More recently in 2022, a prospective, randomized trial performed in the United Kingdom looked at the association of morning versus evening dosing of antihypertensive medication and associated cardiovascular events, and found no difference.<sup>4</sup> Traditionally, patients have been advised to take their antihypertensive medication at night because it was thought that if patients took the medication in the morning, they were more likely to have adverse cardiovascular events. These study results have essentially contradicted this recommendation, and the authors of the study concluded that patients can be advised to take their regular antihypertensive medications at a convenient time that also minimizes potential undesirable effects.

### Systemic Medications

Systemic medications used to treat

conditions that affect tissue perfusion have historically led to confusion in the literature. Multiple studies have shown that calcium channel blockers may have a protective effect in normal-tension glaucoma with regard to slowing visual field progression, potentially by reducing vascular resistance via reducing the effect of endothelin-1 in ocular circulation. Some studies have shown a negative effect with primary open-angle glaucoma. Conversely, systemic beta blockers, such as Metoprolol, have been associated with a higher frequency of disc hemorrhages as well as progression in normal-tension patients. The same effects haven't been found in primary open-angle glaucoma. The use of ACE inhibitors and ARBs in the setting of normal-tension glaucoma is less well studied. Some studies suggest a protective role while others found no association.

To summarize:

1. Consider 24-hour ambulatory blood pressure monitoring to look for a nocturnal dip in blood pressure in patients with continued optic nerve damage despite lower intraocular pressure. A >20-percent change from baseline is considered a large dip.



2. Involve the patient's PCP or cardiologist to fine-tune blood pressure control in this subset of patients. It may be necessary to reduce antihypertensive medication given at bedtime.

3. Consider calcium channel blockers over beta blockers in this population as well because they may actually slow progression. While glaucoma specialists aren't typically the ones to start patients on blood pressure medications, we can work collaboratively with a patient's PCP. Given that normal-tension glaucoma patients tend to be symptomatic earlier than those with primary open angle glaucoma, we want to treat these patients aggressively.

## Vasospasm

Blood perfusion to the optic disc is affected by the integrity of the autoregulatory system, and in the presence of vasospasm this is impaired.

Vasospasm renders the eye more sensitive to both IOP-increase and blood pressure decrease. Vasospastic syndrome, a heterogeneous condition that leads to microvascular dysregulation, is now an established major risk factor for glaucoma.

Endothelin-1 is a potent vasoconstrictor peptide that's produced by endothelial cells. Compared with healthy controls, higher plasma endothelin-1 levels have been observed in glaucoma patients, particularly in those with normal-tension glaucoma. Vasospasm may affect patients with this disease and may be an underlying culprit.

## Flammer Syndrome

Primary vascular dysregulation syndrome, or Flammer syndrome, describes a complex of clinical features caused mainly by dysregulation of the blood supply.<sup>5</sup> The range of symptoms in this syndrome is wide

and can range from cold extremities to low blood pressure to reduced thirst and increased pain sensitivity. However, not all patients will ultimately develop all of these symptoms or even the disease in particular. A comprehensive questionnaire has been developed to better screen patients for this syndrome. Flammer syndrome is believed to increase the risk for certain eye diseases including normal-tension glaucoma, particularly in younger patients.

Treatment of Flammer syndrome<sup>6</sup> consists of lifestyle modifications, such as avoidance of cold, stress and extreme exercise; nutritional recommendations, such as increasing consumption of antioxidants, taking magnesium supplements to potentially inhibit the effects of endothelin-1, increasing nighttime salt intake in the case of extreme hypotension; and medical therapy, which interestingly also includes the

# ADVERTISER INDEX

*This advertiser index is published as a convenience and not as part of the advertising contract. Every care will be taken to index correctly. No allowance will be made for errors due to spelling, incorrect page number, or failure to insert.*

Alcon.....	15, 16	<a href="http://www.alcon.com">www.alcon.com</a>
Alcon.....	55, 56	<a href="http://www.alcon.com">www.alcon.com</a>
Apellis.....	Covers 3, 4	<a href="http://www.apellis.com">www.apellis.com</a>
Bausch + Lomb.....	8	(800) 323-0000 <a href="https://www.bausch.com/">https://www.bausch.com/</a>
Bruder Healthcare Company.....	29	(888) 827-8337 <a href="http://www.bruder.com">www.bruder.com</a> <a href="mailto:eyes@bruder.com">eyes@bruder.com</a>
DGH Technologies, Inc.....	57	<a href="http://www.dghtechnology.com">www.dghtechnology.com</a>
Glaukos.....	5	(800) 452-8567 <a href="http://www.glaukos.com">www.glaukos.com</a>

Harrow.....	25, 26	<a href="https://www.harrow.com/">https://www.harrow.com/</a>
Johnson & Johnson Surgical Vision, Inc.....	21	<a href="http://surgical.jnjvision.com">http://surgical.jnjvision.com</a>
Keeler Instruments.....	59	(800) 523-5620 <a href="http://www.keelerusa.com">www.keelerusa.com</a> <a href="mailto:customerservice@keelerusa.com">customerservice@keelerusa.com</a>
Nanodropper.....	47	(507) 405-5676 <a href="http://www.nanodropper.com/ReviewOpt">www.nanodropper.com/ReviewOpt</a> <a href="mailto:pro@nanodropper.com">pro@nanodropper.com</a>
Nextgen.....	13	<a href="http://www.nextgen.com/1-ophth">www.nextgen.com/1-ophth</a>
Ocular Therapeutix.....	35, 36	<a href="http://www.ocutx.com">www.ocutx.com</a>
Oyster Point.....	18, 19	<a href="https://oysterpointrx.com/">https://oysterpointrx.com/</a>
RxSight.....	Cover 2, 3	<a href="https://rxsight.com/">https://rxsight.com/</a>
Tarsus.....	11, 12	<a href="https://tarsusrx.com">https://tarsusrx.com</a>
Thea.....	Cover Tip	<a href="https://iyuzeh.com/">https://iyuzeh.com/</a>
Vital Tears.....	41	<a href="https://vitaltears.org/">https://vitaltears.org/</a>

use of calcium channel blockers.

### Silent Cerebral Infarcts

Silent cerebral infarcts are brain infarcts resulting from vascular occlusion that are found incidentally by MRI or CT in the absence of clinically detectable focal neurological signs in otherwise healthy people or during autopsy. They're a relatively common finding, seen in one of four patients over the age of 80. A silent cerebral infarct is also a risk factor for further stroke.

Multiple studies have found evidence of frequent vascular insults in patients with normal-tension disease, and it's been suggested that prevention of these silent cerebral infarcts may ultimately slow visual field progression. The American Heart Association recommends following stroke prevention guidelines in this subset of patients, including treating a patient's underlying medical conditions and encouraging a Mediterranean diet, reducing sodium and avoiding smoking. The same recommendations can ultimately be made to our normal-tension glaucoma patients who show evidence of progression.

### Neurodegeneration

Some recent research suggests an association between normal-tension glaucoma and dementia, while evidence for this association is mixed with primary open-angle glaucoma. The association between normal-tension disease and both OPTN and TBK1, two genes that have been implicated in frontotemporal dementia, suggest the possibility of shared neurodegenerative pathways in these two diseases.

In a recent case-control, cross-sectional cognitive screening study involving 290 glaucoma participants with normal-tension glaucoma and high-tension glaucoma controls, sampled from the Australian and New Zealand Registry of Advanced Glaucoma, the authors found that

cognitive impairment assessed using the Telephone Version of the Montreal Cognitive Assessment was more prevalent in the normal-tension cohort than the high-tension cohort.<sup>7</sup> Though a linear trend was also observed between lower absolute test scores in the normal-tension glaucoma cohort, when compared with the high-tension cohort, this association wasn't found to be statistically significant. More research in this area is necessary.



**Collaborate with a patient's PCP or cardiologist if necessary, and always remember to take a thorough review of systems, as many patients with normal-tension disease suffer from a host of other conditions.**



### Neuroimaging

When is neuroimaging indicated in patients with normal-tension glaucoma? Though studies have shown that routine neuro-imaging for normal tension glaucoma has a low sensitivity for detecting mass lesions, there are certain factors that should prompt consideration for neuroimaging, such as:

- age younger than 50 years;
- visual acuity less than 20/40;
- vertically aligned field defects, which aren't classic for glaucoma;
- optic nerve pallor in excess of cupping;
- loss of color vision (red desaturation);
- unilateral disease; and
- rapidly progressive disease despite well-controlled IOP.

In these cases, referral to a neuro-ophthalmologist who can assist in helping to rule out other non-glaucomatous causes for progressing disease

may be helpful. Normal-tension glaucoma is a diagnosis of exclusion, so when a patient's pressures are great but they're still progressing, it's important to ask yourself, "Is this really glaucoma?" to ensure you have ruled out other causes for a patient's vision loss.

In summary, all patients should be encouraged to maintain a heart-healthy diet and lifestyle.

Exercise, weight loss (if overweight), and smoking cessation should be stressed, as should a diet rich in antioxidants. Collaborate with a patient's PCP or cardiologist if necessary, and always remember to take a thorough review of systems as many patients with normal-tension disease suffer from a host of other conditions. Finally, if the diagnosis of NTG is unclear, consider neuro-imaging and referral to a neuro-ophthalmologist. ◀

1. Funk RO, Hodge DO, Kohli D, Roddy GW. Multiple systemic vascular risk factors are associated with low-tension glaucoma. *J Glaucoma* 2022;31:1:15-22.
2. Charlson ME, de Moraes CG, Link A, Wells MT, Harmon G, Peterson JC, Ritch R, Liebmann JM. Nocturnal systemic hypotension increases the risk of glaucoma progression. *Ophthalmology* 2014;121:10:2004-12.
3. Zappe DH, Crikelair N, Kandra A, Palatini P. Time of administration important? Morning versus evening dosing of valsartan. *J Hypertens* 2015;33:2:385-392.
4. Mackenzie IS, Rogers A, Poulter NR, Williams B, et al. Cardiovascular outcomes in adults with hypertension with evening versus morning dosing of usual antihypertensives in the UK (TIME study): A prospective, randomised, open-label, blinded-endpoint clinical trial. *Lancet* 2022;400:10361:1417-1425.
5. Flammer J, Konieczka K. The discovery of the Flammer syndrome: A historical and personal perspective. *EPMA Journal* 2017;8:75-97.
6. Konieczka K, Flammer J. Treatment of glaucoma patients with Flammer syndrome. *J Clin Med* 2021;10:18:4227.
7. Mullany S, Xiao L, Qassim A, Marshall H, Gharahkhani P, MacGregor S, Hassall MM, Siggs OM, Souzeau E, Craig JE. Normal-tension glaucoma is associated with cognitive impairment. *Br J Ophthalmol* 2022;106:7:952-956.

### ABOUT THE AUTHOR



**Dr. Addis** is an assistant professor of clinical ophthalmology at the Scheie Eye Institute, University of Pennsylvania. She has no related financial disclosures.

Driving Innovation,  
Defining Excellence:

# LEADING THE MARKETPLACE FORWARD

We take pride in our longstanding commitment to excellence in readership, reach and influence in the vision care field with our print, digital and multi-platform (print/digital/virtual & live) education offerings. Our signature brands deliver a powerful and impactful marketing mix of print and digital marketing opportunities.

Jobson Optical Group brands are readers' most trusted source for news, product information, education, industry trends, research & surveying ECP's, business strategy and practice management insight.

For more information about products, services, and subscriptions, contact us at [info@jobson.com](mailto:info@jobson.com)

**Jobson**  
Optical Group

The vision to help you succeed

20/20

WO  
WOMEN IN OPTOMETRY®

REVIEW  
of OPHTHALMOLOGY

Frames  
Data®

LT

Jobson OPTICAL  
RESEARCH

RCCL  
REVIEW OF CORNEA  
& CONTACT LENSES

my frame  
GALLERY  
by Frames Data

20/20  
PRO TO PRO

Review  
of MYOPIA  
MANAGEMENT

REVIEW  
of OPTOMETRY

EyeRep®

JOBSON  
INTERACTIVE

VM  
VISION MONDAY

JOBSON  
creative

REVIEW  
Education GROUP

VM LEADERSHIP  
SUMMIT

RETINA®  
SPECIALIST

Review  
of Optometric  
Business

Jobson  
Event Services

VMAIL

REVIEW  
of PRESBYOPIA  
and the Aging Eye

U.S. Pharmacist  
The Pharmacist's Resource for Clinical Excellence





EDITED BY COLLIN ROZANSKI, MD

## WILLS EYE RESIDENT CASE REPORT

# A woman presents to Wills Eye Hospital with eyelid droop and diplopia.

ERIC KIM, MD, COLLIN RICHARDS, MD, AND JURIJ BILYK, MD  
PHILADELPHIA

### Presentation

A 79-year-old Caucasian female with 10 days of progressive double vision and left upper eyelid droop presented for ophthalmic evaluation. She denied flashes, floaters, jaw claudication, fever, unintentional weight loss or photophobia. Systemic review of symptoms was notable for 1.5 years of intermittent confusion, speech problems, severe headaches and memory deficits.

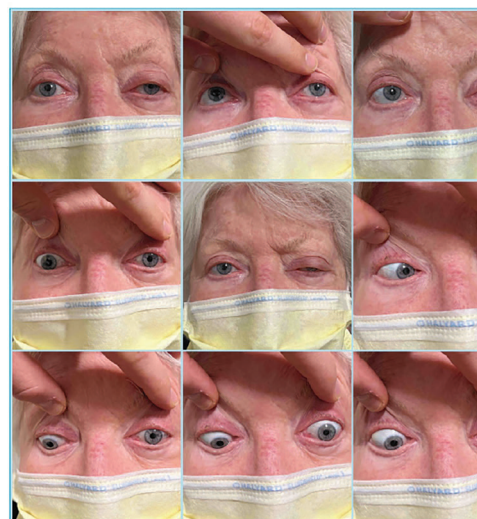### History

The patient denied any past ocular history. She had a significant past medical history of diverticulitis, polymyalgia rheumatica, hypertension and subdural hematoma. Her oncologic history was notable for breast cancer (stage 1, HER-2 negative, ER positive) for which she underwent lumpectomy and external beam radiation 10 years prior to presentation. She also had a mature cystic teratoma removed by hysterectomy and oophorectomy two years prior. Over the course of the past year, she had multiple admissions to an outside hospital for neurologic symptoms, including aphasia and seizures. Imaging at that time revealed progressive pachymeningitis and several pulmonary nodules with abnormal 18F-fluorodeoxyglucose avidity on PET/CT concerning for metastasis. A previous lumbar puncture showed elevated white blood cell count and protein with negative cytology. She later underwent lung biopsy, which was negative for malignancy but showed acute and chronic inflammation. Notably, the patient had progressively increasing Westergren erythrocyte sedimentation rate (WESR) levels from 31 mm/hr to a peak of 92 mm/hr, at which point she was started on oral dexamethasone for palliative treatment of leptomeningeal disease. Rheumatologic work-up, including anti-nuclear antibody (ANA) panel, immunoglobulin G4 (IgG4) and rheumatoid factor (RF) were unremarkable.

The patient was a non-smoker but consumed approximately five glasses of wine per week. Family history was significant for colon cancer, stroke and Parkinson's disease. Her medications included: alprazolam and bupropion-caffeine-acetaminophen as needed, daily aspirin, dexamethasone 2 mg twice daily, levetiracetam, metoprolol and rosuvastatin.

### Examination

The patient's vital signs were within normal limits. Best-corrected visual acuity was 20/30 in the right eye and 20/60 in the left. Intraocular pressures were within normal range. There was a 1+ relative afferent pupillary defect in the left eye. Confrontation visual fields were full. Ishihara color plates were 6/8 in the right eye and 2/8 in the left eye. Extraocular motility was globally restricted in the left eye and to a lesser degree on the right (*Figure 1*). Hertel exophthalmometry with a base of 94 mm revealed measurements of 18 mm OD and 22 mm OS. There was frontalis recruitment bilaterally with left upper eyelid ptosis and decreased levator function.



**Figure 1. Left ptosis and bilateral external ophthalmoplegia.**

**What's your diagnosis? What work-up would you pursue? The case continues on the next page.**

The anterior segment examination was largely unremarkable apart from bilateral nuclear sclerosis and posterior subcapsular cataracts. Dilated fundus examination of the right eye showed a normal optic disc and macula with a sclerotic vessel superiorly and pigmented cobblestone degeneration temporally. The left eye had changes of moderate non-proliferative diabetic retinopathy and scattered peripheral drusen with normal optic disc and macula.

### Work-up, Diagnosis and Treatment

Brain and orbital MRI with and without contrast revealed masses at the bilateral orbital apices (*Figure 2*). T1-weighted post-contrast images also showed an enhancing mass in the left jugular foramen in addition to the previously described pachymeningeal enhancement. Diffusion weighted imaging revealed an acute infarct in the right postcentral gyrus and restricted diffusion within the orbital lesions (*Figure 3*). The updated differential diagnosis included primarily inflammatory and neoplastic etiologies, including metastatic breast carcinoma.

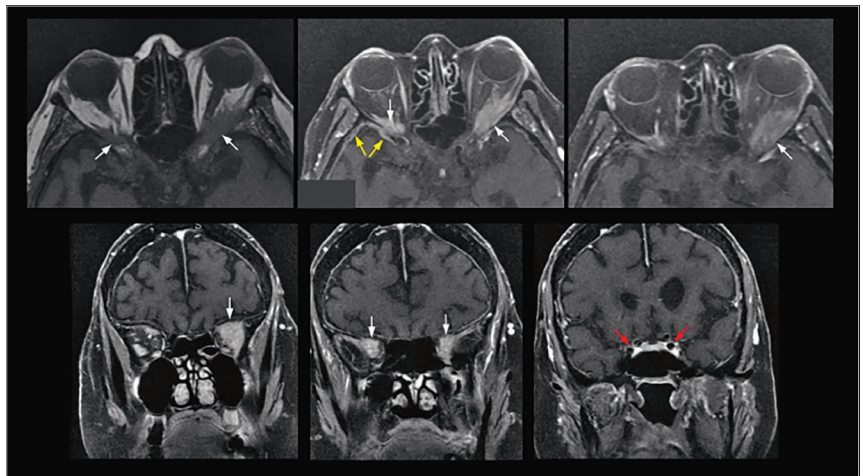
Laboratory work-up included angiotensin-converting enzyme, complement 3/4 levels, lactate dehydrogenase, thyroid stimulating hormone and immunoglobulin, anti-neutrophil cytoplasmic antibody (ANCA), serum and urine protein electrophoresis, and anti-ribonucleoprotein, all of which were negative. WESR and C-reactive protein were within normal limits. ANA was positive with a 1:320 titer.

The patient was admitted for multi-disciplinary management with neurology, rheumatology and medical oncology. She subsequently underwent left orbitotomy for exploration and biopsy. Pathology revealed dense fibrosis, fat necrosis and basophilic necrosis along small vessels without involvement of medium- or large-sized vessels (*Figure 4*). Special stains for microorganisms were negative. The diagnosis of small vessel vasculitis was later supplemented with anti-proteinase 3 (pr3) antibody positivity, consistent with granulomatosis with polyangiitis (GPA). She was treated with pulsed dose IV methylprednisolone for three days and discharged with a prednisone taper and biweekly rituximab infusions for one month.

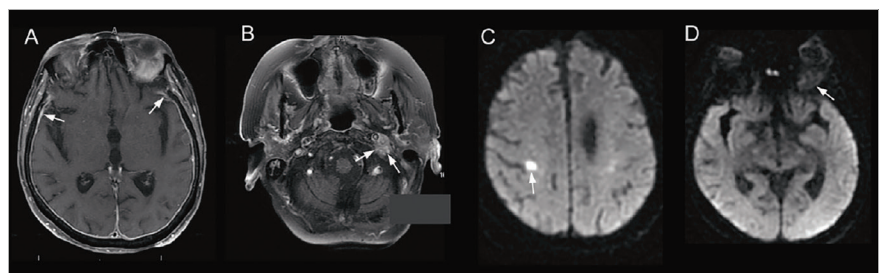
### Discussion

GPA is a rare small-vessel necrotizing vasculitis. It is one of three ANCA-associated vasculitides; the other two are microscopic polyangiitis (which occurs exceedingly rarely in the orbit) and eosinophilic granulomatosis with polyangiitis. Although its pathogenesis is not fully understood, it's presumed that ANCA in GPA stimulates activation of neutrophils with proteinase 3 antigen, which induces degranulation that affects endothelial cells, resulting in vessel wall injury, and promotes T-cell activation triggering macrophage maturation and formation of granulomas.<sup>1</sup> There also appears to be complex gene-environment interactions with numerous implicated genes, including HLA-DPB1, HLA-DPA1, SEMA6A, CTLA4, PTPN22 and others.<sup>2-4</sup>

GPA classically presents as a triad of respiratory tract inflammation, pulmonary infiltrates and glomerulonephritis. Ocular and orbital involvement is observed in more than half of patients with GPA and isn't uncommonly the presenting feature. Ocular manifestations are wide-ranging



**Figure 2.** Axial and coronal cuts of T1-weighted MRI (upper left, pre-contrast; remaining images are post-contrast), showing pachymeningeal enhancement (yellow arrows) and bilateral orbital masses (white arrows), left greater than right. Note the lack of cavernous sinus involvement (red arrows).



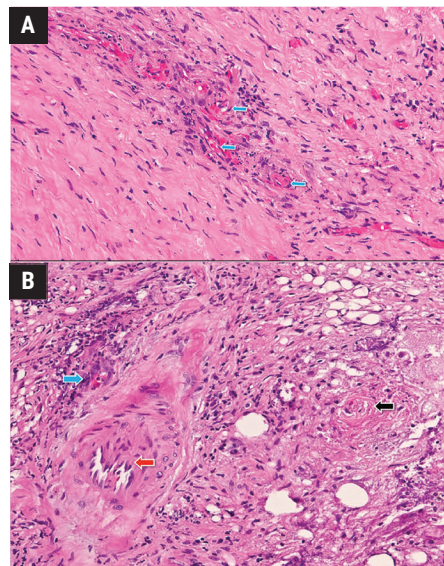
**Figure 3.** T1-weighted, post-contrast MRI showing (A) pachymeningeal enhancement (arrows) and (B) mass encasing the left jugular foramen (arrows). Diffusion weighted imaging showing (C) acute infarct of right precentral gyrus (arrow) and (D) restricted diffusion within the left orbital lesion (arrow).



and may include exophthalmos, diplopia, ocular pain, ophthalmoplegia, cicatricial conjunctivitis, peripheral ulcerative keratitis, retinal vascular occlusion and, infrequently, uveitis.<sup>5-7</sup> Central nervous system involvement in GPA is rare, occurring in about 7 to 11 percent of cases, and manifests as three distinct clinical patterns: cerebral vasculitis; pituitary gland involvement; and/or chronic hypertrophic pachymeningitis.<sup>8</sup> Lumbar puncture in these cases typically reveals pleocytosis and elevated protein concentrations.<sup>9,10</sup>

Serologic studies have varying utility in the diagnosis of orbital inflammation, typically requiring high disease activity to yield a positive result.<sup>11</sup> ANCA appears to be a marker of disease activity, and in the limited form of sino-orbital GPA up to 60 percent of cases may have negative ANCA immunofluorescence.<sup>5,12,13</sup> Moreover, there's a variability in how these assays are performed. The most widely accepted approach is to test myeloperoxidase-ANCA (MPO) and pr3-ANCA by ELISA only after positive screen with immunofluorescence.<sup>14</sup> However, the International Consensus Statement recommends that optimally, concurrent testing be done in all patients suspected of having ANCA-associated vasculitis.<sup>15</sup> Although quite rare, there have been instances of IF-negative, MPO/pr3-ANCA positive vasculitis.<sup>16</sup> To optimize cost-effective testing and avoid excessive false positives, clinical suspicion of ANCA-associated vasculitis should guide ELISA testing when immunofluorescence is unrevealing.<sup>17</sup>

Biopsy remains the gold standard in diagnosis. Clinical improvement with high-dose corticosteroids in both benign and malignant disease can lead to an incorrect empiric diagnosis of idiopathic orbital inflammation and delay the diagnosis of insidious neoplastic processes.<sup>11</sup> It's therefore important to pursue biopsy of surgically accessible tissue prior to an empiric corticosteroid trial, especially when serology and imaging are equivocal. In this case, one of the leading diagnoses was bilateral orbital metastases from breast carcinoma; metastatic breast carcinoma to the orbits is bilateral in about 20 percent of cases.<sup>18</sup> Definitive diagnosis was critical for correct management. The diagnosis of ANCA-associated vasculitis requires a combination of careful history-taking, thoughtful laboratory testing, radiographic evidence and histopathologic findings. Once a fatal disease with median survival of five months, GPA now has an excellent prognosis, with 95-percent survival at five years and 80 percent at 10 years due to a combination of gluco-



**Figure 4. H&E stain of left orbital mass biopsy showing (A) small vessel vasculitis (blue arrows) and (B) basophilic necrosis near vascular endothelium (blue arrow), unaffected large vessel (red arrow), and occluded small vessel (black arrow).**

corticoid and immunomodulatory therapy.<sup>6</sup> Recent studies have recommended rituximab as the mainstay of treatment.<sup>19</sup>

This case involved a unique presentation of bilateral orbital apical masses preceded by progressive pachymeningitis in a patient with a prior history of breast cancer. It's further distinguished by the serologic findings of IF-negative but pr3-ANCA antibody positive vasculitis. The constellation of symptoms could have easily been mistaken for metastases or several separate processes, but with a thorough work-up and ultimately tissue biopsy, the diagnosis of GPA was made, with prompt initiation of appropriate treatment. ◀

1. Csernok E, Gross WL. Current understanding of the pathogenesis of granulomatosis with polyangiitis (Wegener's). *Expert Rev Clin Immunol* 2013;9:7:641-8.
2. Xie G, Roshandel D, Sherva R, et al. Association of granulomatosis with polyangiitis (Wegener's) with HLA-DPB1\*04 and SEMA6A gene variants: evidence from genome-wide analysis. *Arthritis Rheum* 2013;65:9:2457-68.
3. Borgmann S, Endisch G, Urban S, et al. A linkage disequilibrium between genes at the serine protease inhibitor gene cluster on chromosome 14q32.1 is associated with Wegener's granulomatosis. *Clin Immunol* 2001;98:2:244-8.
4. Jagiello P, Aries P, Arning L, et al. The PTPN22 620W allele is a risk factor for Wegener's granulomatosis. *Arthritis Rheum*

2005;52:4039-4043.

5. Tarabishy AB, Schulte M, Papaliodis GN, et al. Wegener's granulomatosis: Clinical manifestations, differential diagnosis, and management of ocular and systemic disease. *Surv Ophthalmol* 2010;55:5:429-444.
6. Sfiniadaki E, Tsiara I, Theodossiadis P, et al. Ocular manifestations of granulomatosis with polyangiitis: A review of the literature. *Ophthalmology and therapy* 2019;8:2:227.
7. Tarabishy AB, Schulte M, Papaliodis GN, et al. Wegener's granulomatosis: Clinical manifestations, differential diagnosis, and management of ocular and systemic disease. *Survey of Ophthalmology* 2010; 55:5:429-444.
8. Seror R, Mahr A, Ramanoelina J, et al. Central nervous system involvement in Wegener granulomatosis. *Medicine (Baltimore)* 2006;85:1:53-65.
9. Nagashima T, Maguchi S, Terayama Y, et al. P-ANCA-positive Wegener's granulomatosis presenting with hypertrophic pachymeningitis and multiple cranial neuropathies: Case report and review of literature. *Neuropathology* 2000;20:23-30.
10. Newman NJ, Slamovits TL, Friedland S, et al. Neuro-ophthalmic manifestations of meningocerebral inflammation from the limited form of Wegener's granulomatosis. *Am J Ophthalmol* 1995;120:5:613-21.
11. Mombaerts I, Rose GE, Garrity JA. Orbital inflammation: Biopsy first. *Surv Ophthalmol* 2016;61:5:664-9.
12. Woo TL, Francis IC, Wilcsek GA, et al. Australasian orbital and adnexal Wegener's granulomatosis. *Ophthalmology* 2001;108:9:1535-1543.
13. Tan LT, Davagnanam I, Isa H, et al. Clinical and imaging features predictive of orbital granulomatosis with polyangiitis and the risk of systemic involvement. *Ophthalmology* 2014;121:6:1304-9.
14. Stone JH, Talar M, Stebbing J, et al. Test characteristics of immunofluorescence and ELISA tests in 856 consecutive patients with possible ANCA-associated conditions. *Arthritis Care Res (Hoboken)* 2000;13:424-34.
15. Savage J, Gillis D, Benson E, et al. International consensus statement on testing and reporting of antineutrophil cytoplasmic antibodies (ANCA). *Am J Clin Pathol* 1999;111:4:507-13.
16. Rao DA, Wei K, Merola JF, O'Brien WR, Takvorian SU, Dellaripa P, Schur PH. Myeloperoxidase-antineutrophil cytoplasmic antibodies (MPO-ANCA) and Proteinase 3-ANCA without Immunofluorescent ANCA Found by Routine Clinical Testing. *The Journal of rheumatology* 2015;42:5:847-852.
17. Tsirogiannis K, Tsirogiannis A, Pipi E, Soufleros K, Papasteriades C. Antineutrophil cytoplasmic antibodies testing in a large cohort of unselected greek patients. *Autoimmune Diseases* 2011;6:26495.
18. Goldberg RA, Rootman J, Cline RA. Tumors metastatic to the orbit: A changing picture. *Surv Ophthalmol* 1990;35:1-24.
19. Stone JH, Merkel PA, Spiera R, et al. Rituximab versus cyclophosphamide for ANCA-associated vasculitis. *N Engl J Med* 2010;15:363:3:221-32.



**SYFOVRE® (pegcetacoplan injection), for intravitreal use**  
**BRIEF SUMMARY OF PRESCRIBING INFORMATION**  
 Please see SYFOVRE full Prescribing Information for details.

**INDICATIONS AND USAGE**

SYFOVRE is indicated for the treatment of geographic atrophy (GA) secondary to age-related macular degeneration (AMD).

**CONTRAINDICATIONS**

**Ocular or Periocular Infections**

SYFOVRE is contraindicated in patients with ocular or periocular infections.

**Active Intraocular Inflammation**

SYFOVRE is contraindicated in patients with active intraocular inflammation.

**WARNINGS AND PRECAUTIONS**

**Endophthalmitis and Retinal Detachments**

Intravitreal injections, including those with SYFOVRE, may be associated with endophthalmitis and retinal detachments. Proper aseptic injection technique must always be used when administering SYFOVRE in order to minimize the risk of endophthalmitis. Patients should be instructed to report any symptoms suggestive of endophthalmitis or retinal detachment without delay and should be managed appropriately.

**Retinal Vasculitis and/or Retinal Vascular Occlusion**

Retinal vasculitis and/or retinal vascular occlusion, typically in the presence of intraocular inflammation, have been reported with the use of SYFOVRE. Cases may occur with the first dose of SYFOVRE and may result in severe vision loss. Discontinue treatment with SYFOVRE in patients who develop these events. Patients should be instructed to report any change in vision without delay.

**Neovascular AMD**

In clinical trials, use of SYFOVRE was associated with increased rates of neovascular (wet) AMD or choroidal neovascularization (12% when administered monthly, 7% when administered every other month and 3% in the control group) by Month 24. Patients receiving SYFOVRE should be monitored for signs of neovascular AMD. In case anti-Vascular Endothelial Growth Factor (anti-VEGF) is required, it should be given separately from SYFOVRE administration.

**Intraocular Inflammation**

In clinical trials, use of SYFOVRE was associated with episodes of intraocular inflammation including: vitritis, vitreal cells, iridocyclitis, uveitis, anterior chamber cells, iritis, and anterior chamber flare. After inflammation resolves patients may resume treatment with SYFOVRE.

**Increased Intraocular Pressure**

Acute increase in IOP may occur within minutes of any intravitreal injection, including with SYFOVRE. Perfusion of the optic nerve head should be monitored following the injection and managed as needed.

**ADVERSE REACTIONS**

**Clinical Trials Experience**

Because clinical trials are conducted under widely varying conditions, adverse reaction rates observed in the clinical trials of a drug cannot be directly compared to rates in the clinical trials of another drug and may not reflect the rates observed in practice.

A total of 839 patients with GA in two Phase 3 studies (OAKS and DERBY) were treated with intravitreal SYFOVRE, 15 mg (0.1 mL of 150 mg/mL solution). Four hundred nineteen (419) of these patients were treated in the affected eye monthly and 420 were treated in the affected eye every other month. Four hundred seventeen (417) patients were assigned to sham.

The most common adverse reactions (≥5%) reported in patients receiving SYFOVRE were ocular discomfort, neovascular age-related macular degeneration, vitreous floaters, and conjunctival hemorrhage.

**Table 1: Adverse Reactions in Study Eye Reported in ≥2% of Patients Treated with SYFOVRE Through Month 24 in Studies OAKS and DERBY**

Adverse Reactions	PM (N = 419) %	PEOM (N = 420) %	Sham Pooled (N = 417) %
Ocular discomfort*	13	10	11
Neovascular age-related macular degeneration*	12	7	3
Vitreous floaters	10	7	1
Conjunctival hemorrhage	8	8	4
Vitreous detachment	4	6	3
Retinal hemorrhage	4	5	3
Punctate keratitis*	5	3	<1
Posterior capsule opacification	4	4	3
Intraocular inflammation*	4	2	<1
Intraocular pressure increased	2	3	<1

PM: SYFOVRE monthly; PEOM: SYFOVRE every other month

\*The following reported terms were combined:

**Ocular discomfort** included: eye pain, eye irritation, foreign body sensation in eyes, ocular discomfort, abnormal sensation in eye

**Neovascular age-related macular degeneration** included: exudative age-related macular degeneration, choroidal neovascularization

**Punctate keratitis** included: punctate keratitis, keratitis

**Intraocular inflammation** included: vitritis, vitreal cells, iridocyclitis, uveitis, anterior chamber cells, iritis, anterior chamber flare

Endophthalmitis, retinal detachment, hyphema and retinal tears were reported in less than 1% of patients. Optic ischemic neuropathy was reported in 1.7% of patients treated monthly, 0.2% of patients treated every other month and 0.0% of patients assigned to sham. Deaths were reported in 6.7% of patients treated monthly, 3.6% of patients treated every other month and 3.8% of patients assigned to sham. The rates and causes of death were consistent with the elderly study population.

**Postmarketing Experience**

The following adverse reactions have been identified during postapproval use of SYFOVRE. Because these reactions are reported voluntarily from a population of uncertain size, it is not always possible to reliably estimate their frequency or establish a causal relationship to drug exposure. Eye disorders: retinal vasculitis with or without retinal vascular occlusion.

**USE IN SPECIFIC POPULATIONS**

**Pregnancy**

**Risk Summary**

There are no adequate and well-controlled studies of SYFOVRE administration in pregnant women to inform a drug-associated risk. The use of SYFOVRE may be considered following an assessment of the risks and benefits.

Systemic exposure of SYFOVRE following ocular administration is low. Subcutaneous administration of pegcetacoplan to pregnant monkeys from the mid gestation period through birth resulted in increased incidences of abortions and stillbirths at systemic exposures 1040-fold higher than that observed in humans at the maximum recommended human ophthalmic dose (MRHOD) of SYFOVRE (based on the area under the curve (AUC) systemically measured levels). No adverse maternal or fetal effects were observed in monkeys at systemic exposures approximately 470-fold higher than that observed in humans at the MRHOD.

In the U.S. general population, the estimated background risk of major birth defects and miscarriage in clinically recognized pregnancies is 2-4% and 15-20%, respectively.

**Lactation**

**Risk Summary**

It is not known whether intravitreal administered pegcetacoplan is secreted in human milk or whether there is potential for absorption and harm to the infant. Animal data suggest that the risk of clinically relevant exposure to the infant following maternal intravitreal treatment is minimal. Because many drugs are excreted in human milk, and because the potential for absorption and harm to infant growth and development exists, caution should be exercised when SYFOVRE is administered to a nursing woman.

**Females and Males of Reproductive Potential**

**Contraception**

**Females:** It is recommended that women of childbearing potential use effective contraception methods to prevent pregnancy during treatment with intravitreal pegcetacoplan. Advise female patients of reproductive potential to use effective contraception during treatment with SYFOVRE and for 40 days after the last dose. For women planning to become pregnant, the use of SYFOVRE may be considered following an assessment of the risks and benefits.

**Pediatric Use**

The safety and effectiveness of SYFOVRE in pediatric patients have not been established.

**Geriatric Use**

In clinical studies, approximately 97% (813/839) of patients randomized to treatment with SYFOVRE were ≥ 65 years of age and approximately 72% (607/839) were ≥ 75 years of age. No significant differences in efficacy or safety were seen with increasing age in these studies. No dosage regimen adjustment is recommended based on age.

**PATIENT COUNSELING INFORMATION**

Advise patients that following SYFOVRE administration, patients are at risk of developing endophthalmitis, retinal detachments, retinal vasculitis with or without retinal vascular occlusion and neovascular AMD. If the eye becomes red, sensitive to light, painful, or if a patient develops any change in vision such as flashing lights, blurred vision or metamorphopsia, instruct the patient to seek immediate care from an ophthalmologist. Patients may experience temporary visual disturbances associated either with the intravitreal injection with SYFOVRE or the eye examination. Advise patients not to drive or use machinery until visual function has recovered sufficiently.

Manufactured for:  
 Apellis Pharmaceuticals, Inc.  
 100 Fifth Avenue  
 Waltham, MA 02451

SYF-PI-30NOV2023-2.0

APELLIS®, SYFOVRE® and their respective logos are registered trademarks of Apellis Pharmaceuticals, Inc.  
 ©2023 Apellis Pharmaceuticals, Inc.

12/23 US-PEGGA-2200163 v4.0

# SYFOVRE<sup>®</sup>

(pegcetacoplan injection)  
15 mg / 0.1 mL

GA unravels so much  
**SAVE RETINAL TISSUE  
BY SLOWING  
PROGRESSION<sup>1-3</sup>**

**SYFOVRE achieved continuous reductions  
in mean lesion growth rate\* vs sham  
pooled from baseline to Month 24<sup>1,4</sup>**

Monthly	Every Other Month (EOM)
OAKS trial (mm <sup>2</sup> ): (3.11 vs 3.98) <b>22%</b>	OAKS trial (mm <sup>2</sup> ): (3.26 vs 3.98) <b>18%</b>
DERBY trial (mm <sup>2</sup> ): (3.28 vs 4.00) <b>18%</b>	DERBY trial (mm <sup>2</sup> ): (3.31 vs 4.00) <b>17%</b>

**SE in trials (monthly, EOM, sham pooled):  
OAKS: 0.15, 0.13, 0.14; DERBY: 0.13, 0.13, 0.17.**

\*Slope for baseline to Month 24 is an average of slope of baseline to Month 6, Month 6 to Month 12, Month 12 to Month 18, and Month 18 to Month 24.<sup>1</sup>

Based on a mixed effects model for repeated measures assuming a piecewise linear trend in time with knots at Month 6, Month 12, and Month 18.<sup>1</sup>

GA=geographic atrophy;  
SE=standard error.



Explore the  
long-term data

The CMS-assigned permanent J-code for  
SYFOVRE is J2781—effective 10/1/23<sup>1</sup>

## INDICATION

SYFOVRE<sup>®</sup> (pegcetacoplan injection) is indicated for the treatment of geographic atrophy (GA) secondary to age-related macular degeneration (AMD).

## IMPORTANT SAFETY INFORMATION

### CONTRAINDICATIONS

- SYFOVRE is contraindicated in patients with ocular or periocular infections, and in patients with active intraocular inflammation

### WARNINGS AND PRECAUTIONS

- **Endophthalmitis and Retinal Detachments**
  - Intravitreal injections, including those with SYFOVRE, may be associated with endophthalmitis and retinal detachments. Proper aseptic injection technique must always be used when administering SYFOVRE to minimize the risk of endophthalmitis. Patients should be instructed to report any symptoms suggestive of endophthalmitis or retinal detachment without delay and should be managed appropriately.
- **Retinal Vasculitis and/or Retinal Vascular Occlusion**
  - Retinal vasculitis and/or retinal vascular occlusion, typically in the presence of intraocular inflammation, have been reported with the use of SYFOVRE. Cases may occur with the first dose of SYFOVRE and may result in severe vision loss. Discontinue treatment with SYFOVRE in patients who develop these events. Patients should be instructed to report any change in vision without delay.
- **Neovascular AMD**
  - In clinical trials, use of SYFOVRE was associated with increased rates of neovascular (wet) AMD or choroidal neovascularization (12% when administered monthly, 7% when administered every other month and 3% in the control group) by Month 24. Patients receiving SYFOVRE should be monitored for signs of neovascular AMD. In case anti-Vascular Endothelial Growth Factor (anti-VEGF) is required, it should be given separately from SYFOVRE administration.

### Intraocular Inflammation

- In clinical trials, use of SYFOVRE was associated with episodes of intraocular inflammation including: vitritis, vitreal cells, iridocyclitis, uveitis, anterior chamber cells, iritis, and anterior chamber flare. After inflammation resolves, patients may resume treatment with SYFOVRE.

### Increased Intraocular Pressure

- Acute increase in IOP may occur within minutes of any intravitreal injection, including with SYFOVRE. Perfusion of the optic nerve head should be monitored following the injection and managed as needed.

### ADVERSE REACTIONS

- Most common adverse reactions (incidence  $\geq$ 5%) are ocular discomfort, neovascular age-related macular degeneration, vitreous floaters, conjunctival hemorrhage.

Please see Brief Summary of Prescribing Information for SYFOVRE on the adjacent page.

**Trial Design:** SYFOVRE safety and efficacy were assessed in OAKS (N=637) and DERBY (N=621), multi-center, 24-month, Phase 3, randomized, double-masked trials. Patients with GA (atrophic nonexudative age-related macular degeneration), with or without subfoveal involvement, secondary to AMD were randomly assigned (2:2:1:1) to receive 15 mg/0.1 mL intravitreal SYFOVRE monthly, SYFOVRE EOM, sham monthly, or sham EOM for 24 months. Change from baseline in the total area of GA lesions in the study eye (mm<sup>2</sup>) was measured by fundus autofluorescence (FAF).<sup>1,4</sup>

**References:** 1. SYFOVRE (pegcetacoplan injection) [package insert]. Waltham, MA: Apellis Pharmaceuticals, Inc.; 2023. 2. Pfau M, von der Emde L, de Sistiernes L, et al. Progression of photoreceptor degeneration in geographic atrophy secondary to age-related macular degeneration. *JAMA Ophthalmol.* 2020;138(10):1026–1034. 3. Bird AC, Phillips RL, Hageman GS. Geographic atrophy: a histopathological assessment. *JAMA Ophthalmol.* 2014;132(3):338–345. 4. Data on file. Apellis Pharmaceuticals, Inc.

Apellis

APELLIS<sup>®</sup>, SYFOVRE<sup>®</sup> and their respective logos are registered trademarks of Apellis Pharmaceuticals, Inc. ©2024 Apellis Pharmaceuticals, Inc. 1/24 US-PEGGA-2200232 v3.0