

INTERSECTION OF OCULAR SURFACE DISEASE & GLAUCOMA

Protecting Ocular Surface
Health in a Glaucoma
Population

A Supplement to

REVIEW
of Ophthalmology

Sponsored by

 **AKORN**

Intersection of Ocular Surface Disease & Glaucoma

Protecting Ocular Surface Health in a Glaucoma Population

The intersection of glaucoma and ocular surface disease (OSD) is increasingly becoming clear as research into these chronic and progressive diseases grows. Not only are we learning that these conditions often present and progress concomitantly, but a growing body of research is revealing the negative effects of eye drop pre-

servatives on the ocular surface.

This is of utmost concern, as a damaged ocular surface and an unstable tear film can degrade the glaucoma patient's vision-related quality of life, as well as compromise the individual's compliance with glaucoma therapies and jeopardize the opportunity for positive

surgery results. Amplifying patient discomfort or treatment dissatisfaction in a population potentially burdened by two ocular diseases could lead to, in a worst-case scenario, patient dropout.

Investigators are increasingly turning up associations between the presence of preservatives such as benzalkonium chloride (BAK)—included in many topical glaucoma treatments—and altered tear film break-up time (TFBUT) along with increased tear film osmolarity.^{1,2} These findings reinforce our long-held suspicions that certain glaucoma therapies may be damaging the ocular surface and further stressing a tear film that could already be compromised.

These results carry even greater significance when considering that last year's seminal International Dry Eye Workshop II (DEWS II) report highlighted the pivotal roles that tear film hyperosmolarity and ocular surface inflammation play in dry eye and ocular surface diseases.³

These new insights leave us with two key takeaways about best practices for

FACULTY:



Robert D. Fechtner, MD
Upstate Medical University in Syracuse, NY



I. Ben Gaddie, OD, FAAO
Gaddie Eye Centers, Louisville, KY



Marguerite McDonald, MD, FACS
Ophthalmic Consultants of Long Island,
a Dry Eye Center of Excellence, Lynbrook, NY



Paul Karpecki, OD, FAAO Dipl. ABO
Kentucky Eye Institute, Lexington, KY

care of the glaucoma patient. The first is that any eye care professional who is managing patients with glaucoma consequently has an OSD practice. We cannot afford to address eye pressures and ignore the impact on the tear

film. The second is that maintaining ocular surface health in glaucoma patients doesn't have to mean sacrificing intraocular pressure (IOP) control. The right strategy and therapeutic decisions can ensure adequate control of

patient pressures while at the same time safeguarding the individual's ocular surface from unnecessary irritation, aggravation and damage. Our patients' eye health and vision quality of life deserve nothing less.

– Robert D. Fechtner, MD

Glaucoma Medication and OSD

Dr. Fechtner: *Studies show that nearly 60% of patients with glaucoma or ocular hypertension treated with IOP-lowering medications have symptoms consistent with OSD.⁴⁻⁹ Have you noticed an OSD association in glaucoma patients who are already on glaucoma treatments when they present at your practice?*

Dr. Gaddie: Without a doubt, we see this association in practice for two primary reasons: One, the demographics of glaucoma and dry eye, especially as they pertain to age, are very similar and overlapping; and two, the preservatives in many glaucoma agents exacerbate dry eye symptoms and signs.

Dr. McDonald: Unquestionably. I have seen even one preserved glaucoma drop negatively impact the ocular surface of some patients.

Dr. Karpecki: Yes, it's very common to see glaucoma patients with OSD—especially those on prostaglandin analogs (PGAs). Since this is the primary treatment for most patients, OSD is extremely prevalent. I would estimate, and studies support this, that more than 90% of my patients on PGAs have OSD issues such as blepharitis, meibomian gland dysfunction (MGD) and dry eye disease (DED).¹⁰

Dr. Fechtner: When my practice began questioning

glaucoma patients who were using eye drops, about 50% of them had symptoms of OSD. Though most of us in eye care have known for some time that glaucoma patients commonly have uncomfortable eyes, I'm not sure we appreciated the magnitude of the problem. Once I started looking more closely at the issue, I realized that I could identify early tear breakup and MGD in many of my treated patients. Perhaps the tipoff that we ignored in the past was the frequency with which glaucoma patients were using supplemental ocular lubricants.

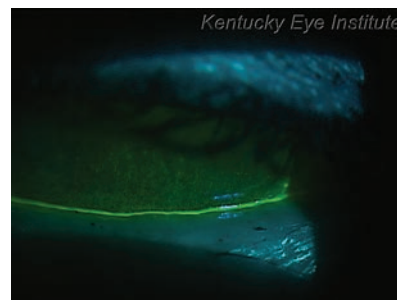Cataract & Refractive Surgery: Start With a Healthy Surface

Dr. Fechtner: *Research indicates that BAK negatively impacts conjunctival and Tenon's capsule tissue, and penetrates corneal skeletal limbal tissue, affecting trabecular endothelial and non-pigmented ciliary epithelial lines.¹¹⁻¹³ As well, research has revealed that existing ocular surface damage during cataract surgery is a pathogenic factor for ocular discomfort and DED after surgery.¹⁴ In your experience, how does the preoperative health of the ocular surface affect cataract and refractive surgery?*

Dr. McDonald: Preoperative biometry is adversely affected, and preexisting MGD has been identified as a causative factor in endophthalmitis. In addition, I have found that the postop-

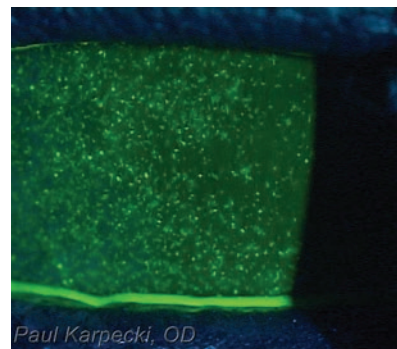
erative 'wow' factor is greatly diminished without stabilizing the ocular surface prior to surgery; the recovery of BCVA is considerably slower and often doesn't reach the level it does in patients without OSD. I won't operate on someone with significant preoperative OSD until it's successfully treated.

Dr. Karpecki: The preoperative ocular surface health affects biometry calculations

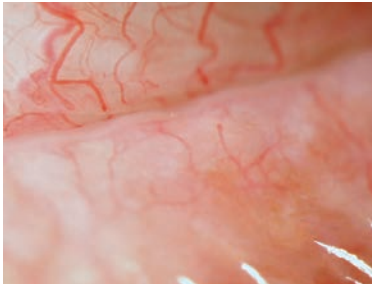


A patient on a PGA and beta-blocker, both containing BAK, exhibits advanced OSD (SPK and extremely thin tear meniscus) likely due to chronic BAK toxicity and subsequent impact on the meibomian glands.

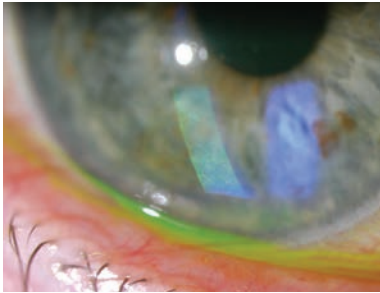
Photos: Paul Karpecki, OD, FAAO



A case of medicamentosa or toxicity secondary to drops or preservatives in drops.



Magnified view of MGD in PGA patient.
Photos: I. Ben Gaddie, OD, FFAO



SPK in PGA patient.

and accuracy of the IOL power, healing and recovery. In addition, blurred VA secondary to OSD can be misconstrued as poor vision after cataract surgery by many patients. Surgery, even with today's impressive minimally invasive techniques, is still trauma to the eye. Nerves can be affected, and patients with preoperative dry eye risk can tip over into chronic dry eye post-surgery.

Dr. Fechtner: The best visual outcomes start with a healthy ocular surface. A patient who requires chronic glaucoma medications must be evaluated carefully, with special attention to the ocular surface prior to cataract and refractive surgery. The meticulous surgeon will address OSD and tear deficiency before proceeding with surgery.

Dr. Fechtner: How do you prepare glaucoma patients for cataract and refractive surgeries to

ensure optimal outcomes?

Dr. McDonald: I use a complex treatment scheme based on tear osmolarity and MGD scores.

Dr. Karpecki: From the start, I try to set proper expectations for the patient. And I consider non-BAK containing glaucoma drops while treating OSD in preparation for surgery; otherwise, it will take far too long to get the ocular surface to an optimal state to proceed with surgery.

Dr. Fechtner: If the patient is on a single, once-daily medication containing BAK, I rarely change the preoperative medical regimen unless significant underlying OSD is evident. For patients on multiple medications, I reduce the medications if possible and may treat for a few weeks with topical steroids prior to surgery. I may also switch to preservative-free medications before and after the procedure.

Dr. Fechtner: If a pre-cat-

aract/refractive surgical patient presents with OSD, would you delay surgery until the OSD is improved?

Dr. McDonald: I do delay surgery, and have never—to my knowledge—lost a patient by being careful. This is why I don't allow out-of-town patients to book preoperative exams and cataract/refractive surgery during the same visit; I often find preoperative OSD that needs treatment for at least one month.

Dr. Karpecki: Yes. You have to treat the ocular surface first or the patient will believe the cataract or refractive surgery caused the preexisting dry eye/OSD.

Dr. Fechtner: Patient expectations are very high with cataract and refractive surgery. I would much rather take the time before procedures to improve patients' ocular surface health than have to explain and deal with disappointing surgical results due to avoidable ocular surface problems.

Considering the Glaucoma Patient's Quality of Life

In addition to the physical burdens OSD and DED present to patients, studies have determined negative effects of the diseases on daily-living tasks such as reading, carrying out professional tasks and driving.¹⁵ Considering patients' potentially diminished quality of life from introducing new, or aggravating existing, OSD and DED, along with IOP control when prescribing glaucoma drops is essential to a comprehensive approach to eye care.

- 'This is the paradigm shift that has to take place. Because I have a referral-based practice for advanced OSD, I see many glaucoma patients with significant DED/OSD. We need to proactively start asking these patients questions about symptoms and signs when they present to us, throughout treatment and during ongoing management. If we do this, I think we will find that patients' life enjoyment is greatly impacted and, thus, adherence to medication is reduced. We need a new way of thinking about these patients that may make us change our approach, even if it's just small steps.' — **Dr. Karpecki**
- 'Early glaucoma has no symptoms. Most patient complaints stem from adverse effects of therapies. With each additional topical glaucoma medication, we must assess efficacy and tolerability. Unsatisfactory performance in either of those areas is a good reason to select another therapy. A rapid TBUT is an easy entry point to a conversation about the impact of therapy and related symptoms that may affect quality of life. Addressing underlying factors that aggravate existing OSD (including glaucoma medications and preservatives within them) is an essential part of tailoring care to the individual.' — **Dr. Fechtner**

Long-Term Impacts for Tear Film & Glaucoma Surgery

Dr. Fechtner: Research shows that BAK induces toxicity, alters TFBUT and increases tear film osmolarity.^{1,2} Have you found that BAK contributes to the destabilization of the tear film?

Dr. McDonald: Absolutely. I often see rapid TBUT and superficial punctate keratitis (SPK), especially central SPK, resulting from BAK's contribution to such symptoms.

Dr. Karpecki: Without question. In one study, 96% of glaucoma patients on PGA therapy had OSD/MGD, and 58% on non-PGA medications had OSD.¹⁰ I believe the former finding is due to BAK. It's clear from the latter finding that this population is already prone to OSD/DED, and then we pile on chronic administration of BAK. Almost all of my glaucoma patients have a rapid TFBUT and SPK. A newer sensitive test for DED—osmolarity—also enables us to see that these medications rapidly foster a hyperosmolar environment.

Dr. Fechtner: I wholeheartedly agree. BAK creates a harsh environment in the bottle that is unfriendly to microbes, so it's not surprising that it is also unfriendly to the ocular surface. Some medications actually employ BAK concentrations as a strategy for greater ocular penetration; i.e., rough up the cornea so more drug can pass through. The DEWS II report identified BAK as an important factor in destabilizing the tear film, so clinicians should be aware of the BAK content of prescribed glaucoma medications.³

Dr. Gaddie: I'm not sure that I associate BAK with tear film destabilization as much as with

Glaucoma & OSD Implications

- 50% to 60% of glaucoma patients present with concomitant OSD and DED.¹⁻⁴
- Glaucoma patients with concomitant OSD experience 4x to 12x higher rates of therapy side effects than those with only glaucoma.⁵
- Patients experiencing side effects from glaucoma treatment have greater losses in their fields of vision and damage to optic nerves than those who don't.^{6,7}

1. Fechtner RD, Godfrey DG, Budenz D, Stewart JA, Stewart WC, Jasek MC. Prevalence of ocular surface complaints in patients with glaucoma using topical intraocular pressure-lowering medications. *Cornea*. 2010;29(6):618-21.
2. Baudouin C, Renard JP, Nordmann JP, et al. Prevalence and risk factors for ocular surface disease among patients treated over the long term for glaucoma or ocular hypertension. *Eur J Ophthalmol*. 2013;23(1):47-54.
3. Leung EW, Medeiros FA, Weinreb RN. Prevalence of ocular surface disease in glaucoma patients. *J Glaucoma*. 2008;17(5):350-5.
4. Garcia-Feijoo J, Sampaolles JR. A multicenter evaluation of ocular surface disease prevalence in patients with glaucoma. *Clin Ophthalmol*. 2012;6:441-6.
5. Erb C, Gast U, Schremmer D. German register for glaucoma patients with dry eye: I. basic outcome with respect to dry eye. *Graefes Arch Clin Exp Ophthalmol*. 2008;246(11):1593-1601.
6. Denis P. Adverse effects, adherence and cost-benefits in glaucoma treatment. *Eur Ophthalmic Rev*. 2011;5(2):116-122.
7. Denis P, Lafuma A, Berdeaux G. Medical outcomes of glaucoma therapy from a nationwide representative survey. *Clin Drug Invest*. 2004; 24(6):343-52.

ocular surface destabilization in general.

Dr. Fechtner: Studies also have shown that long-term antiglaucomatous drug administration may cause dry eye, irritation, allergy, subconjunctival fibrosis and increased risk of glaucoma surgery failure, potentially due to BAK, whose toxic, proinflammatory and detergent effects have been reported in the literature.^{16,17} Do you have concerns regarding BAK's cumulative effect on OSD specifically?

Dr. Gaddie: Yes. In particular, I find that IOP-reducing drugs requiring greater than once-

these side effects seriously. BAK is cytotoxic—plain and simple—even in low doses. Because these eye drops are chronically administered, the patient gets a cumulative effect. At my OSD center, I also see diminished VA and increased osmolarity, along with increased rates of blepharitis and MGD. I'm aware of 13 studies off the top of my head supporting these findings.¹⁸⁻³¹

Dr. Fechtner: I have concerns as well. Moreover, damage to the ocular surface posed by BAK doesn't immediately resolve when the BAK-containing drop is discontinued.

'I have seen even one preserved glaucoma drop negatively impact the ocular surface of some patients.' – Marguerite McDonald, MD, FACS

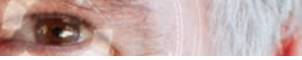per-day administration cause exponential cumulative damage to the ocular surface.

Dr. McDonald: Definitely. I have seen all of these issues along with, on occasion, the eventual failure of the BAK-containing drop to control the glaucoma.

Dr. Karpecki: Undoubtedly. And many clinicians don't take

Dr. Fechtner: How does patients' preoperative ocular surface health affect glaucoma surgery outcomes?

Dr. McDonald: Subconjunctival fibrosis is well-documented as a possible side effect of BAK-containing drops; this can decrease the chance of success with glaucoma surgery.



Dr. Karpecki: The chronic use of BAK has been shown to affect surgical outcomes because of cytotoxicity. This can lead to scarring of tissue in filtering procedures and

ing, often prolonged, upon instillation and blurring are the main problems I hear about.

Dr. Karpecki: The combination of BAK and a PGA alone

and more difficult to treat and reverse.

Dr. Gaddie: I find these effects usually yield complaints of fluctuating vision.

‘The combination of BAK and a PGA alone is significant over time and, in my opinion, greatly affects the ocular surface. Two or more drops that contain BAK are even more detrimental to the patient, especially if one of them is a PGA.’ – Paul Karpecki, OD, FAAO

possibly even minimally invasive glaucoma surgeries (MIGS). One patient I sent for a MIGS procedure was on three topical medications a day (all had BAK) prior to seeing me, and did not get the positive surgical outcome many MIGS patients do. The PESO study affirmed that increased preoperative exposure to ophthalmic solutions preserved with BAK was a risk factor for earlier surgical failure, independent of the number of medications used.³¹

Dr. Fechtner: An inflamed eye is a poor candidate for surgery. I have switched patients in the short-term to oral medications to reduce the ocular surface burden in anticipation of glaucoma surgery. Similar considerations should apply to refractive cataract surgery.

Dr. Fechtner: *Patients experiencing side effects from glaucoma treatment have been shown to experience greater visual field loss and optic nerve damage than those that don't.*^{32,33} *Can you discuss negative vision-related effects reported by patients with glaucoma or concomitant glaucoma and OSD who are undergoing glaucoma treatment?*

Dr. McDonald: Sting-

is significant over time and, in my opinion, greatly affects the ocular surface. Two or more drops that contain BAK are even more detrimental to the patient, especially if one of them is a PGA.

However, most glaucoma patients don't complain about DED/OSD as I would expect. I have seen glaucoma patients with grade 3 central staining who only came in because vision had dropped two lines. When asked about irritation, dryness, burning, etc., they have stated that the symptoms started with the first prescribed drops (PGAs). It's only when vision was affected that many sought help. By then, the OSD was usually very advanced,

Dr. Fechtner: Glaucoma results in many subtle and not-so-subtle defects to vision. Complicating matters, both glaucoma and OSD can result in decreased contrast sensitivity, difficulty with night vision and poor resolution of fine detail.

A Different Approach to Glaucoma Therapy

Dr. Fechtner: *What overarching strategy do you use to preserve ocular surface health in patients with glaucoma, while managing IOP?*

Dr. McDonald: I change therapy to preservative-free drops if I see evidence of ocular surface disturbance on the exam or if the patient complains.

Dr. Gaddie: Not all patients will develop glaucoma medication-related dry eye, so I prefer to proactively treat individuals exhibiting baseline symptoms or signs with a non-preserved PGA or laser. However, my goal is to reduce IOP, despite what may

Case Study: Restoring a Former Physician's Vision Quality of Life

By Dr. Fechtner

Switching a patient from preservative-containing to preservative-free glaucoma therapy can improve the patient's vision-related and all-around quality of life. One retired ophthalmologist, who presented to me with glaucoma as a result of complications he experienced from a vascular occlusive event, saw improvements from making such a change.

When the man first came to see me, he complained that when he took all of his glaucoma medications, his pressure was controlled but his vision was poor. If he stopped taking his medications, he could see well enough to read but his pressures went back up. Evaluations revealed he had significant visual field loss in one eye.

I streamlined the patient's treatment by using a preservative-free prostaglandin; preservative-free, fixed-combination therapy as well as topical anti-inflammatory drug. And I addressed underlying MGD with local measures and a short course of oral antibiotics.

The patient's vision improved to the point where he could return to his normal visual activities. When the patient's IOP rose again several years later, we performed successful glaucoma surgery on him, which resulted in acceptable visual quality of life.

come of the ocular surface. It's not ideal, but rather, a reality in glaucoma care today.

Dr. Karpecki: My strategy can be something as simple as turning to drops without BAK if patients describe symptoms of dry eye or I see findings of OSD. I think a significant issue facing glaucoma care today is that most doctors who treat glaucoma are not looking for signs of OSD, so they only respond to patient complaints.

Dr. Fechtner: One of the best ways to preserve ocular surface health in glaucoma patients is to minimize the burden of topical therapy and preservatives. For almost every class of drugs, there is either a BAK-free or preservative-free drug available. Laser trabeculoplasty is also a useful adjunct procedure to reduce the need for topical medication. The physician should strive to address underlying conditions (e.g., MGD, systemic medications, environmental factors, etc.). Even though the patient may not be complaining, my experience has found that there is a 50% to 60% likelihood that the individual is symptomatic. I believe we must ask about, and address, these symptoms to achieve the best outcomes. Preservative-free medications are less likely to aggravate OSD, although it's difficult to measure in clinical trials. I also believe most thoughtful clinicians would agree that BAK is not good for the eye. It's not always apparently harmful and has long been a part of multidose formulations. However, just because some eyes can tolerate BAK and it's a component in the most commonly used generic medications does not make it good for ocular health.

1. Walimbe T, Chelerkar V, Purvi Bhagat P, et al. Effect of benzalkonium chloride-free latanoprost ophthalmic solution on ocular surface in patients with glaucoma. *Clin Ophthalmol*. 2016; 10: 821-7.

2. Labbé A, Terry D, Brasnu E, Van Went C, Baudouin C. Tear film osmolality in patients treated for glaucoma or ocular hypertension. *Cornea*. 2012;31(9):994-999.
3. Nelson JD, Craig JP, Esen A, et al. TFOS DEWS II Report. *Ocul Surf* 2017; 2017 July;15(3):269-650.
4. Fechtner RD, Godfrey DG, Budenz D, Stewart JA, Stewart WC, Jasek MC. Prevalence of ocular surface complaints in patients with glaucoma using topical intraocular pressure-lowering medications. *Cornea*. 2010;29(6):618-621.
5. Baudouin C, Renard JP, Nordmann JP, et al. Prevalence and risk factors for ocular surface disease among patients treated over the long term for glaucoma or ocular hypertension. *Eur J Ophthalmol*. 2013;23(1):47-54.
6. Leung EW, Medeiros FA, Weinreb RN. Prevalence of ocular surface disease in glaucoma patients. *J Glaucoma*. 2008;17(5):350-5.
7. Garcia-Feijoo J, Sampaols JR. A multicenter evaluation of ocular surface disease prevalence in patients with glaucoma. *Clin Ophthalmol*. 2012;6:441-446.
8. Erb C, Gast U, Schremmer D. German register for glaucoma patients with dry eye: I. basic outcome with respect to dry eye. *Graefes Arch Clin Exp Ophthalmol*. 2008;246(11):1593-1601.
9. Jaenen N, Baudouin C, Pouliquen P, Manni G, Figueiredo A, Zeyen T. Ocular symptoms and signs with preserved and preservative-free glaucoma medications. *Eur J Ophthalmol*. 2007;17(3):341-349.
10. Mocan MC, Uzunosmanoglu E, Kocabeyoglu S, et al. The association of chronic topical prostaglandin analog use with meibomian gland dysfunction. *J Glaucoma*. 2016; Sep;25(9):770-4.
11. Sherwood MB, Grierson I, Millar L, Hitchings RA. Long-term morphologic effects of antiglaucoma drugs on the conjunctiva and Tenon's capsule in glaucomatous patients. *Ophthalmology*. 1989;96:327-35.
12. McCarey B, Edelhauser H. In vivo corneal epithelial permeability following treatment with prostaglandin analogs [correction of analogues] with or without benzalkonium chloride. *J Ocul Pharmacol Ther*. 2007 Oct;23(5):445-51.
13. Collin HB, Grabsch BE. The effect of ophthalmic preservatives on the healing rate of the rabbit corneal epithelium after keratectomy. *Am J Optom Physiol Opt*. 1982;59:215-22.
14. Oh T, Jung Y, Chang D, et al. Changes in the tear film and ocular surface after cataract surgery. *Jpn J Ophthalmol*. 2012 Mar;56(2):113-8.
15. Miljanovi B, Dana R, Sullivan DA, et al. Impact of dry eye syndrome on vision-related quality of life. *Am J Ophthalmol*. 2007 Mar;143(3):409-15.
16. Baudouin C, Denoyer A, Desbenoit N, et al. In vitro and in vivo experimental studies on trabecular meshwork degeneration induced by benzalkonium chloride (an American Ophthalmological Society thesis). *Trans Am Ophthalmol Soc*. 2012 Dec;110:40-63.
17. Broadway DC, Grierson I, O'Brien C, et al. Adverse effects of topical antiglaucoma medication. II. The outcome of filtration surgery. *Arch Ophthalmol*. 1994 Nov;112(11):1446-54.
18. Brasnu E, Brignole-Baudouin F, Riancho L, et al. In vitro effects of preservative-free tafluprost and preserved latanoprost, travoprost, and bimatoprost in a conjunctival epithelial cell line. *Curr Eye Res*. 2008;33(4):303-12.
19. Jaenen N, Baudouin C, Pouliquen P, et al. Ocular symptoms and signs with preserved and preservative-free glaucoma medications. *European Journal of Ophthalmology*. 2007;17(3):341-9.
20. Nakagawa S, Usui T, Yokoo S, et al. Toxicity evaluation of antiglaucoma drugs using stratified human cultivated corneal epithelial sheets. *Invest Ophthalmol Vis Sci*. 2012;53(9):5154-60.
21. Ammar DA, Noecker RJ, Kahook MY. Effects of benzalkonium chloride-preserved, polyquad-preserved, and sofZia-preserved topical glaucoma medications on human ocular epithelial cells. *Adv Ther*. 2010;27(11):837-45.
22. Liang H, Pauly A, Riancho L, et al. Toxicological evaluation of preservative-containing and preservative-free topical prostaglandin analogues on a three-dimensional-reconstituted corneal epithelium system. *Br J Ophthalmol*. 2011;95(6):869-75.
23. Pellinen P, Huhtala A, Tolonen A, et al. The cytotoxic effects of preserved and preservative-free prostaglandin analogs on human corneal and conjunctival epithelium in vitro and the distribution of benzalkonium chloride homologs in ocular surface tissues in vivo. *Curr Eye Res*. 2012;37(2):145-54.
24. Ayaki M, Iwasawa A, Niwano Y. In vitro assessment of the cytotoxicity of six topical antibiotics to four cultured ocular surface cell lines. *Biocontrol Sci*. 2012;17(2):93-9.
25. Ayaki M, Iwasawa A, Niwano Y. Comparative study of in vitro ocular surface cytotoxicity of a fixed combination of 0.5% timolol/1% dorzolamide eyedrop and its components with 0.005% benzalkonium chloride. *Biocontrol Sci*. 2012;17(3):115-20.
26. Ayaki M, Iwasawa A, Niwano Y. Cell viability score as an integrated indicator for cytotoxicity of benzalkonium chloride-containing antiglaucoma eyedrops. *Biocontrol Sci*. 2012;17(3):121-8.
27. Ayaki M, Iwasawa A, Niwano Y. Comparative assessment of the cytotoxicity of six anti-inflammatory eyedrops in four cultured ocular surface cell lines, as determined by cell viability scores. *Clin Ophthalmol*. 2012;6:1879-84.
28. Guenoun JM, Baudouin C, Rat P, et al. In vitro comparison of cytoprotective and antioxidative effects of latanoprost, travoprost, and bimatoprost on conjunctiva-derived epithelial cells. *Invest Ophthalmol Vis Sci*. 2005;46(12):4594-9.
29. Kahook MY, Ammar DA. In vitro toxicity of topical ocular prostaglandin analogs and preservatives on corneal epithelial cells. *J Ocul Pharmacol Ther*. 2010;26(3):259-63.
30. Whitson JT, Petroll WM. Corneal epithelial cell viability following exposure to ophthalmic solutions containing preservatives and/or antihypertensive agents. *Adv Ther*. 2012;29(10):874-88.
31. Boimer C, Birt C. M. Preservative exposure and surgical outcomes in glaucoma patients: the PESO study. *Journal of Glaucoma*. 2013;22(9):730-5.
32. Denis P, Lafuma A, Berdeaux G. Medical outcomes of glaucoma therapy from a nationwide representative survey. *Clin Drug Invest*. 2004; 24(6):343-52.
33. Denis P. Adverse effects, adherence and cost-benefits in glaucoma treatment. *Eur Ophthalmic Rev*. 2011;5(2):116-22.

In my eyes

The GLAUCOMA & OSD CONNECTION



A powerful story that delves into the fears and anxieties patients experience when they suffer from both glaucoma and ocular surface disease.

www.ReviewOfOphthalmology.com/ms/ocularsurface



Asim Farooq, MD



Mildred Olivier, MD



Brian Jacobs, MD



Diane



Luvenia



Venola