

Wills Eye Resident Series: A man presents with plaque-like swelling of his eyelid, p. 64

# REVIEW<sup>®</sup> of OPHTHALMOLOGY

February 2024 • [reviewofophthalmology.com](http://reviewofophthalmology.com)

Clinical advice you can trust

## REFRACTIVE/CATARACT RUNDOWN

Nucleo-fractis Techniques

PAGE 18

## PEDIATRIC PATIENT

New Amblyopia Therapies

PAGE 57

## GLAUCOMA MANAGEMENT

Cutting Edge Glaucoma Research

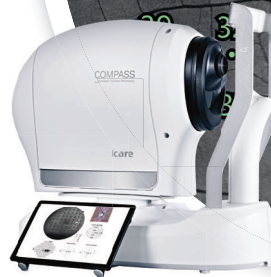PAGE 61

## AI Visual Field Testing

NEW FEATURES!

iCare COMPASS

## The next level of automated tracked perimetry



ZEST Fast strategy  
decreases  
exam time



Smart Progression  
Analysis (SPA)  
report shows  
change over time



SmartMosaic  
function offering  
wider TrueColor  
retinal images



Active Retinal Tracking  
reduces artifacts  
improving reliability  
and accuracy



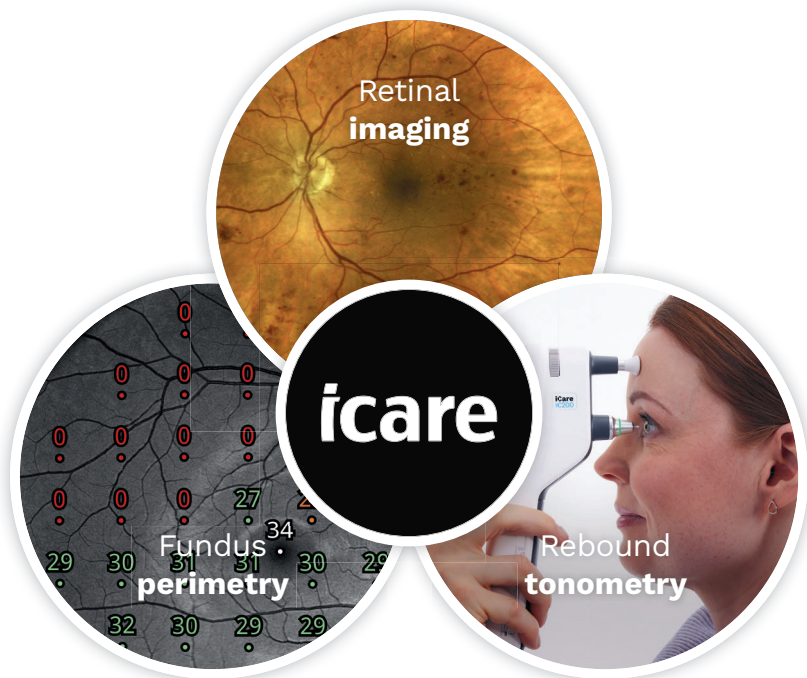
Follow us or visit [www.icare-world.com/USA](http://www.icare-world.com/USA)

icare

20 YEARS OF  
INNOVATION

**You know us  
for tonometry.**

**Get to know  
iCare for  
imaging and  
perimetry.**



Discover the next level of eye care with  
our full line of devices.

Scan or visit [www.icare-world.com/USA](http://www.icare-world.com/USA)



iCare is a trademark of iCare Finland Oy. iCare Finland Oy, iCare USA, Inc., iCare World Australia Pty Ltd and Centervue S.p.A., are parts of Revenio Group and represent the brand iCare. iCare COMPASS, iCare DRSplus, iCare EIDON, iCare EIDON AF, iCare EIDON FA, iCare IC100, iCare IC200 and iCare ILLUME are trademarks or registered trademarks of iCare Finland Oy in the EU and the USA and/or other countries. Centervue S.p.A. is the legal manufacturer of DRSplus, COMPASS, EIDON, EIDON AF, EIDON FA, EIDON UWF Module, DRS, MAIA and S-MAIA. Not all products, accessories, services or offers are approved in every market. Approved labelling and instructions may vary from one country to another. ©2023 iCare Finland Oy. All rights reserved. ICARE-TRADE-ADS-378-EN-1.0-US



Wills Eye Resident Series: A man presents with plaque-like swelling of his eyelid, p. 64

# REVIEW<sup>®</sup> *of* OPHTHALMOLOGY

February 2024 • reviewofophthalmology.com

Clinical advice you can trust

## REFRACTIVE/CATARACT RUNDOWN

Nucleo-fractis Techniques

PAGE 18

## PEDIATRIC PATIENT

New Amblyopia Therapies

PAGE 57

## GLAUCOMA MANAGEMENT

Cutting Edge Glaucoma Research

PAGE 61

## VR Visual Field Testing



*Experts break down the pros, cons and where perimetry is headed. P. 25*

### Also Inside:

- Back to Basics: Visual Field Interpretation P. 37
- Solving Dry-eye Conundrums P. 42
- Managing Refractive Surgery Complications P. 50

For the treatment of all stages  
of neurotrophic keratitis (NK)



## NOT JUST ANY SOLUTION A RESOLUTION

### Complete and long-lasting resolution of NK for most patients\*<sup>1-4</sup>

- **Up to 72% of patients** achieved complete corneal healing in clinical trials\*\*<sup>1-3</sup>
- **80% of these patients** remained healed at 1 year (REPARO trial)\*<sup>4</sup>

\* Resolution was evaluated in clinical trials as complete corneal healing, defined as the absence of staining in the lesion area and no persistent staining in the rest of the cornea after 8 weeks of treatment and as <0.5-mm lesion staining at 48-week follow-up.<sup>1,3</sup>

† Key study findings were after 8 weeks of treatment, 6 times daily. REPARO (Study NGF0212): 52 European patients with neurotrophic keratitis (NK) in 1 eye per group; 72% of patients completely healed; vehicle response rate 33.3%. Study NGF0214: 24 US patients with NK in 1 or both eyes per group; 65.2% completely healed; vehicle response rate 16.7%.<sup>2,3</sup>

### Important Safety Information WARNINGS AND PRECAUTIONS

#### Use with Contact Lens

Contact lenses should be removed before applying OXERVATE because the presence of a contact lens (either therapeutic or corrective) could theoretically limit the distribution of cenegermin-bkbj onto the area of the corneal lesion. Lenses may be reinserted 15 minutes after administration.

#### Eye Discomfort

OXERVATE may cause mild to moderate eye discomfort such as eye pain during treatment. The patient should be advised to contact their doctor if a more serious eye reaction occurs.

#### ADVERSE REACTIONS

In clinical trials, the most common adverse reaction was eye pain following instillation which was reported in approximately 16% of patients. Other adverse reactions occurring in 1% to 10% of OXERVATE patients and more frequently than in the vehicle-treated patients included corneal deposits, foreign body sensation, ocular hyperemia, ocular inflammation and tearing.

#### USE IN SPECIFIC POPULATIONS

##### Pregnancy

There are no data from the use of OXERVATE in pregnant women to inform any drug associated risks.

##### Lactation

The developmental and health benefits of breastfeeding should be considered, along with the mother's clinical need for OXERVATE, and any potential adverse effects on the breastfed infant from OXERVATE.

##### Pediatric Use

The safety and effectiveness of OXERVATE have been established in the pediatric population. Use of OXERVATE in pediatric patients 2 years of age and older is supported by evidence from adequate and well-controlled trials of OXERVATE in adults with additional safety data in children.

##### INDICATION

OXERVATE® (cenegermin-bkbj) ophthalmic solution 0.002% (20 mcg/mL) is indicated for the treatment of neurotrophic keratitis.

##### DOSAGE AND ADMINISTRATION

Instill one drop of OXERVATE in the affected eye(s), 6 times a day at 2-hour intervals for eight weeks.

**To report ADVERSE REACTIONS, contact Dompé U.S. Inc. at 1-833-366-7387 or FDA at 1-800-FDA-1088 or [www.fda.gov/medwatch](http://www.fda.gov/medwatch).**

**Please see the Brief Summary of full Prescribing Information for OXERVATE on the following page.**

**References:** 1. OXERVATE® (cenegermin-bkbj) ophthalmic solution 0.002% (20 mcg/mL) [US package insert], Boston, MA; Dompé U.S. Inc.; 2019. 2. Bonini S, et al. *Ophthalmology*. 2018;125:1332-1343. 3. Pflugfelder SC, et al. *Ophthalmology*. 2020;127:14-26. 4. Data on File. Clinical Study Report (NGF0212). Dompé U.S. Inc., 2016.

**oxervate**®   
(cenegermin-bkbj ophthalmic  
solution) 0.002% (20 mcg/mL)





## Brief Summary of full Prescribing Information

Consult the full Prescribing Information for complete product information, available at [www.oxervate.com/prescribing-information](http://www.oxervate.com/prescribing-information).

### INDICATIONS AND USAGE

OXERVATE® (cenegermin-bkbj) ophthalmic solution 0.002% is indicated for the treatment of neurotrophic keratitis.

### DOSAGE AND ADMINISTRATION

#### General Dosing Information

Contact lenses should be removed before applying OXERVATE and may be reinserted 15 minutes after administration.

If a dose is missed, treatment should be continued as normal, at the next scheduled administration.

If more than one topical ophthalmic product is being used, administer the eye drops at least 15 minutes apart to avoid diluting products. Administer OXERVATE 15 minutes prior to using any eye ointment, gel or other viscous eye drops.

#### Recommended Dosage and Dose Administration

Instill one drop of OXERVATE in the affected eye(s), 6 times a day at 2-hour intervals for eight weeks.

### WARNINGS AND PRECAUTIONS

#### Use with Contact Lens

Contact lenses should be removed before applying OXERVATE because the presence of a contact lens (either therapeutic or corrective) could theoretically limit the distribution of cenegermin-bkbj onto the area of the corneal lesion. Lenses may be reinserted 15 minutes after administration.

#### Eye Discomfort

OXERVATE may cause mild to moderate eye discomfort such as eye pain during treatment. The patient should be advised to contact their doctor if a more serious eye reaction occurs.

### ADVERSE REACTIONS

#### Clinical Studies Experience

Because clinical studies are conducted under widely varying conditions, adverse reaction rates observed in the clinical studies of a drug cannot be directly compared to rates in the clinical studies of another drug and may not reflect the rates observed in practice.

In two clinical trials of patients with neurotrophic keratitis, a total of 101 patients received cenegermin-bkbj eye drops at 20 mcg/mL at a frequency of 6 times daily in the affected eye(s) for a duration of 8 weeks. The mean age of the population was 61 to 65 years of age (18 to 95). The majority of the treated patients were female (61%). The most common adverse reaction was eye pain following instillation which was reported in approximately 16% of patients. Other adverse reactions occurring in 1-10% of OXERVATE patients and more frequently than in the vehicle-treated patients included corneal deposits, foreign body sensation, ocular hyperemia, ocular inflammation and tearing.

### USE IN SPECIFIC POPULATIONS

#### Pregnancy

##### Risk Summary

There are no data from the use of OXERVATE in pregnant women to inform any drug associated risks.

Administration of cenegermin-bkbj to pregnant rats or rabbits during the period of organogenesis did not produce adverse fetal effects at clinically relevant doses. In a pre- and postnatal development study, administration of cenegermin-bkbj to pregnant rats throughout gestation and lactation did not produce adverse effects in offspring at clinically relevant doses.

#### Lactation

##### Risk Summary

There are no data on the presence of OXERVATE in human milk, the effects on breastfed infant, or the effects on milk production. The developmental and health benefits of breastfeeding should be considered, along with the mother's clinical need for OXERVATE, and any potential adverse effects on the breastfed infant from OXERVATE.

#### Pediatric Use

The safety and effectiveness of OXERVATE have been established in the pediatric population. Use of OXERVATE in this population is supported by evidence from adequate and well-controlled trials of OXERVATE in adults with additional safety data in pediatric patients from 2 years of age and older.

#### Geriatric Use

Of the total number of subjects in clinical studies of OXERVATE, 43.5 % were 65 years old and over. No overall differences in safety or effectiveness were observed between elderly and younger adult patients.

### NONCLINICAL TOXICOLOGY

#### Carcinogenesis, Mutagenesis, Impairment of Fertility

##### Carcinogenesis and Mutagenesis

Animal studies have not been conducted to determine the carcinogenic and mutagenic potential of cenegermin-bkbj.

##### Impairment of fertility

Daily subcutaneous administration of cenegermin-bkbj to male and female rats for at least 14 days prior to mating, and at least 18 days post-coitum had no effect on fertility parameters in male or female rats at doses up to 267 mcg/kg/day (1709 times the MRHOD).

In general toxicology studies, subcutaneous and ocular administration of cenegermin-bkbj in females was associated with ovarian findings including persistent estrus, ovarian follicular cysts, atrophy/reduction of corpora lutea, and changes in ovarian weight at doses greater than or equal to 19 mcg/kg/day (119 times the MRHOD).





## Study Looks at the Potential of Handheld AI Screening for DR

An exponential increase in diabetes has taken place globally in recent decades, with 2021 projections from the International Diabetes Federation estimating that 537 million, or one in 10 adults, aged 20 to 79 live with diabetes. This translates into roughly a billion eyes needing screening for diabetic retinopathy at least once annually, or around three million eyes daily. The amount of images that must be graded in a timely manner has placed an overwhelming burden on human graders, thus leading to more research coming forth about potential aid from artificial intelligence tools.

One new study, published in *Ophthalmology Science*, prospectively evaluated mydriatic handheld retinal imaging performance assessed by point-of-care AI as compared to retinal imaging graders at a centralized reading center to identify DR and diabetic macular edema.<sup>1</sup> A total of 5,585 eyes were observed from 2,793 patients with diabetes.

By reading center evaluation, DR severity in the sample was broken down as:

- no DR—67.3 percent;
  - mild nonproliferative DR—9.7 percent;
  - moderate nonproliferative DR—8.6 percent;
  - severe nonproliferative DR—4.8 percent;
  - proliferative DR—3.8 percent; and ungradable images—5.8 percent.
- DME by reading center evaluation

was as follows:

- no DME, 80.4 percent;
- non-center-involving DME, 7.7 percent;
- center-involving DME, 4.4 percent; and
- ungradable images—7.5 percent.

Referable DR was present in 25.3 percent of eyes and vision-threatening DR in 17.5 percent. Ungradable images were twice as likely with AI at 15.4 percent; however, there was substantial agreement between AI and the reading center for referable DR and moderate agreement for vision-threatening DR.

Sensitivity/specificity of AI evaluation was 0.86/0.86 for referable DR and 0.92/0.80 for vision-threatening DR. Based on these rates, the AI demonstrated it meets the current sensitivity and specificity for referable DR as set by FDA thresholds of 85 percent and 82.5 percent, but it doesn't meet the threshold for vision-threatening DR.

Co-author Paolo S. Silva, MD, of the Joslin Diabetes Center's Beetham Eye Institute in Boston, says one of the motivations behind the study was to make diabetic retinopathy screening more useful for all types of people, rather than just those that were used to make the initial datasets.

"The camera in our study was employed in population that isn't usually represented in large diabetic retinopathy fundus photo databases," Dr. Silva says. "The databases generally consist of white, East Asian or South Asian individuals. That doesn't represent

everyone in the world. There's a vast population that's underrepresented in these datasets. The end goal for everyone who does diabetic retinopathy screening is to develop a system that will be able to assess everyone, provide care for the remotest populations and in areas that are disadvantaged or have lower resources."

To this point, the study authors speculate that one potential reason for the high ungradable image rate of the AI is because the algorithm was trained using a different camera type than the one used in the study. A tabletop retinal camera was the source of images used to train the AI, whereas a handheld device was used in the study. While the authors are hopeful this AI technology can be used in the future, they do caution that the high failure rate will need to be addressed in future versions of the software, since this would affect the efficiency and acceptability of AI. To do so, it may need to undergo optimization using a training set of images comparable to the intended population.

"What the study shows is that handheld imaging coupled with AI is a viable option for screening diabetic retinopathy, particularly in remote settings," says Dr. Silva. "One thing that stood out was the high ungradable rate in this particular study based on the AI we used. But most AI algorithms aren't trained on handheld retinal images. Handheld retinal images compared to tabletop retinal cameras are very different from each other. Handheld

DEFINING THE  
FUTURE OF  
MONOFOCALS

## TECNIS Eyhance™ IOL



**Continuous increase in power from edge to center** designed to slightly extend depth of focus at plano\*<sup>1,2</sup>



**Provides sharp quality of vision** by maintaining correction of spherical aberration<sup>3</sup>



**Best-in-Category\*\* Contrast and Low Light Performance** – day and night<sup>4</sup>

TECNIS  
Eyhance™ IOL

with TECNIS SIMPLICITY® Delivery System



Also available in TECNIS® Toric II.

Learn more at [TECNISEyhanceIOL.com](https://TECNISEyhanceIOL.com)

Made Possible.

Johnson & Johnson VISION

\*The TECNIS Eyhance™ IOLs are designed to slightly extend the depth of focus compared to the TECNIS® 1-Piece IOL, Model ZCB00 as measured in bench testing. \*\*vs Acrysof® IQ (SN60WF), Clareon® (CNA0T0), Vivinex™ (XY1), enVista® (MX60E), and Acrysof® (SA60AT).

#### REFERENCES:

1. REF2022CT4107 Z311524E\_A TECNIS Eyhance™ IOL with TECNIS Simplicity® Delivery System US DFU.
2. REF2021CT4007 Z311525E\_A TECNIS Eyhance™ Toric II IOL with TECNIS Simplicity® Delivery System DFU.
3. Piers P, Manzanera S, Prieto P, Gorceix N, Artal P. Use of adaptive optics to determine the optimal ocular spherical aberration. *J Cataract Refract Surg.* 2007;33(10):1721-1726.
4. DOF2021CT4002 - RUSH: TECNIS Eyhance™ IOL Monofocal Competitors MTF - US.

**INDICATIONS and IMPORTANT SAFETY INFORMATION for TECNIS Eyhance™ and TECNIS Eyhance™ Toric II IOLs with TECNIS Simplicity® Delivery System Rx Only**

**INDICATIONS FOR USE:** The TECNIS Simplicity® Delivery System is used to fold and assist in inserting the TECNIS Eyhance™ IOL for the visual correction of aphakia in adult patients in whom a cataractous lens has been removed by extracapsular cataract extraction. The lens is intended to be placed in the capsular bag. The TECNIS Simplicity® Delivery System is used to fold and assist in inserting the TECNIS Eyhance™ Toric II IOLs for the visual correction of aphakia and pre-existing corneal astigmatism of one diopter or greater in adult patients with or without presbyopia in whom a cataractous lens has been removed by phacoemulsification and who desire reduction in residual refractive cylinder. The lens is intended to be placed in the capsular bag.

**WARNINGS:** Physicians considering lens implantation should weigh the potential risk/benefit ratio for any conditions described in the Directions for Use that could increase complications or impact patient outcomes. The lens should be placed entirely in the capsular bag. Do not place the lens in the ciliary sulcus. Rotation of the TECNIS Eyhance™ Toric II IOL from its intended axis can reduce its astigmatic correction. Misalignment greater than 30° may increase postoperative refractive cylinder. If necessary, lens repositioning should occur as early as possible, prior to lens encapsulation. Do not attempt to disassemble, modify or alter the delivery system or any of its components, as this can significantly affect the function and/or structural integrity of the design. Do not implant the lens if the rod tip does not advance the lens or if it is jammed in the delivery system. The lens and delivery system should be discarded if the lens has been folded within the cartridge for more than 10 minutes.

**PRECAUTIONS:** The safety and effectiveness of the TECNIS Eyhance™ IOL has not been substantiated in clinical trials and the effects of the optical design on quality of vision, contrast sensitivity, and subjective visual disturbances (glare, halo, etc.) have not been evaluated clinically. This is a single use device, do not resterilize the lens or the delivery system. Do not store the device in direct sunlight or at a temperature under 5°C (41°F) or over 35°C (95°F). Do not autoclave the delivery system. Do not advance the lens unless ready for lens implantation. The contents are sterile unless the package is opened or damaged. The recommended temperature for implanting the lens is at least 17°C (63°F). The use of balanced salt solution or viscoelastics is required when using the delivery system. Do not use if the delivery system has been dropped or if any part was inadvertently struck while outside the shipping box.

**ADVERSE EVENTS:** The most frequently reported cumulative adverse event that occurred during the SENSAR® 1-Piece IOL clinical trial was cystoid macular edema which occurred at a rate of 3.3%.

**ATTENTION:** Reference the Directions for Use for a complete listing of Indications and Important Safety Information.

Third party trademarks are the property of their respective owners.  
© Johnson & Johnson Surgical Vision, Inc. 2023 PP2023CT4336

retinal cameras have somewhat low image quality and more imaging artifacts, vs. an office setting, where lighting is optimized and patients may be dark-adapted, and a tabletop camera's overall image quality is generally better than a handheld retinal camera's. What you see here—especially if a transition toward community-based screening is going to be done more in the future—is that handheld cameras may be the way to go, and AI algorithms need to be able to adapt to that, by training their algorithms in the future based on datasets

from handheld retinal cameras.”

Despite this limitation, the AI has proved efficacy for one of the two main categories, which the authors see as a future solution to the ever-increasing burden of human graders and clinicians, who may struggle to grade all images captured within the day and deal with backlogs as a result. The AI only refers patients at risk of losing their sight for an in-person consult, thus relieving a part of the issue.

As the authors explained in their paper, the use of point-of-care AI and

handheld imaging as a DR screening tool “has the potential to decrease the burden on reading centers especially in low-income settings or geographically isolated communities. Reliable AI assessment of DR at point of care with real-time output can guide clinical decision-making and referral recommendations.”

1. Salongcay RP, Aquino LAC, Alog GP, et al. Accuracy of integrated artificial intelligence grading using handheld retinal imaging in a community diabetic eye screening program. *Ophthalmol Sci.* December 14, 2023. [Epub ahead of print].

## Take a Deep Breath ... And Help Prevent Glaucoma?

Spending five minutes taking slow, deep breaths three times per day—a technique called “365 breathing”—is recommended by therapists to help deal with stress, as controlled slow breathing techniques have been shown to shift towards parasympathetic dominance, increase respiratory sinus arrhythmia and augment heart rate variability. As previous studies showing that mindfulness-based stress reduction helps reduce intraocular pressure, researchers recently evaluated the effect of the 365 breathing technique on IOP autonomic functions and stress biomarkers in patients with primary open angle glaucoma and found that it caused a significant reduction in IOP (2 mm Hg) in the intervention group after six weeks of practice.<sup>1</sup>

A total of 40 subjects in intervention group followed 365 breathing for three times a day at a breathing rate of six cycles per minute for five minutes, in addition to their pharmacological glaucoma treatment. It was explained to subjects that breathing should be smooth, slow, deep and via nasal route, with five seconds devoted to each inhalation and exhalation. “Each day patients were asked to practice first session as soon as they wake up; second session four hours after the first session or just before lunch and the third session at the end of their work-

day or before starting their evening,” the researchers wrote in their paper.

Another 40 subjects in the control group continued only with their pharmacological glaucoma treatment. IOP, serum cortisol, heart rate variability and heart rate response to a deep breathing test were recorded at pre-intervention and six weeks post-intervention.

The 365 breathing technique caused a significant reduction in IOP (2 mm Hg) and significantly increased the parasympathetic activity in intervention group after six weeks of practice. Previous studies reported a 1.5 mm Hg to 6.1 mm Hg of IOP reduction after a short course (three to six weeks duration) of meditation/mindfulness-based stress reduction in patients with glaucoma/ocular hypertension.

The 365 breathing technique also reduced serum cortisol (stress biomarker) and improved autonomic dysfunction in glaucoma patients.

“Stress is not only a result but also a possible risk factor/cause of glaucoma,” the authors explained. “Acute and chronic stress have been shown to increase IOP. Studies have demonstrated that stress can cause a decline in parasympathetic activity, NO-cGMP dysfunction, endothelial and vascular dysfunction, glial cell activation and downregulation of neurotrophins, all of which have been speculated to play

a role in complex pathophysiology of glaucoma,” the authors explained.

Cortisol is known to increase in response to stress and alter trabecular meshwork morphology resulting in reduced aqueous humor outflow, thereby elevating IOP, the authors noted.

It's proposed that the increase in melatonin and nitric oxide could have led to decrease in IOP. An additional decrease in cortisol, as noted in this study, also contributes to decrease in IOP. The decreased sympathetic activity and increased parasympathetic activity can decrease aqueous production and increase aqueous outflow leading to decreased IOP, the authors explained.

“In our study, the IOP reduction after six weeks of practicing 365 breathing was 11 percent and though this is a small reduction, it can help in preventing long-term glaucoma progression. So, the 365 breathing technique cannot be used as a stand-alone modality to reduce IOP, but can be used as an adjuvant therapy along with glaucoma medications,” the authors explained.

1. Dada T, Gwal RS, Mahalingam K, et al. Effect of ‘365 breathing technique’ on intraocular pressure and autonomic functions in glaucoma patients: a randomised controlled trial. *J Glaucoma.* Jan 9, 2024 [Epub ahead of print].

(Continued on p. 12)



# iyuzeh™

(latanoprost ophthalmic solution) 0.005%

## HIGHLIGHTS OF PRESCRIBING INFORMATION

This brief summary does not include all the information needed to use IYUZEH safely and effectively. See full prescribing information for IYUZEH.

Initial U.S. Approval: 2022

### INDICATIONS AND USAGE

IYUZEH is a prostaglandin F2α analogue indicated for the reduction of elevated intraocular pressure in patients with open-angle glaucoma or ocular hypertension.

### CONTRAINDICATIONS

Known hypersensitivity to latanoprost or any other ingredients in this product.

### WARNINGS AND PRECAUTIONS

**Pigmentation:** Topical latanoprost ophthalmic products, including IYUZEH have been reported to cause changes to pigmented tissues. The most frequently reported changes have been increased pigmentation of the iris, periorbital tissue (eyelid), and eyelashes. Pigmentation is expected to increase as long as latanoprost is administered.

The pigmentation change is due to increased melanin content in the melanocytes rather than to an increase in the number of melanocytes. After discontinuation of latanoprost, pigmentation of the iris is likely to be permanent, while pigmentation of the periorbital tissue and eyelash changes have been reported to be reversible in some patients. Patients who receive treatment should be informed of the possibility of increased pigmentation. The long-term effects of increased pigmentation are not known.

Iris color change may not be noticeable for several months to years. Typically, the brown pigmentation around the pupil spreads concentrically towards the periphery of the iris and the entire iris or parts of the iris become more brownish. Neither nevi nor freckles of the iris appear to be affected by treatment. While treatment with IYUZEH can be continued in patients who develop noticeably increased iris pigmentation, these patients should be examined regularly.

**Eyelash Changes:** Latanoprost ophthalmic products, including IYUZEH may gradually change eyelashes and vellus hair in the treated eye; these changes include increased length, thickness, pigmentation, the number of lashes or hairs, and misdirected growth of eyelashes. Eyelash changes are usually reversible upon discontinuation of treatment.

**Intraocular Inflammation:** IYUZEH should be used with caution in patients with a history of intraocular inflammation (iritis/uveitis) and should generally not be used in patients with active intraocular inflammation because inflammation may be exacerbated.

**Macular Edema:** Macular edema, including cystoid macular edema, has been reported during treatment with latanoprost ophthalmic products, including IYUZEH. IYUZEH should be used with caution in aphakic patients, pseudophakic patients with a torn posterior lens capsule, or in patients with known risk factors for macular edema.

**Herpetic Keratitis:** Reactivation of herpes simplex keratitis has been reported during treatment with latanoprost. IYUZEH should be used with caution in patients with a history of herpetic keratitis and should be avoided in cases of active herpes simplex keratitis because inflammation may be exacerbated.

**Contact Lens Use:** Contact lenses should be removed prior to the administration of IYUZEH and may be reinserted 15 minutes after administration.

### ADVERSE REACTIONS

The following adverse reactions have been reported with the use of topical latanoprost products and are discussed in greater detail in the prescribing information:

- Iris pigmentation changes
- Eyelid skin darkening
- Eyelash changes (increased length, thickness, pigmentation, and number of lashes)
- Intraocular inflammation (iritis/uveitis)
- Macular edema, including cystoid macular edema

Because clinical trials are conducted under widely varying conditions, adverse reaction rates observed in the clinical trials of a drug cannot be directly compared to rates in the clinical trials of another drug and may not reflect the rates observed in practice.

In the two clinical trials conducted with IYUZEH (latanoprost ophthalmic solution) 0.005% comparing it to XALATAN the preserved 0.005% latanoprost reference product, the most frequently reported ocular adverse reactions were conjunctival hyperemia and eye irritation (Table 1).

Table 1. Adverse Reactions

Symptom/Finding	Adverse Reactions [n (%)]	
	IYUZEH (n=378)	XALATAN (n=358)
Conjunctival hyperemia	129 (34)	133 (37)
Eye irritation	72 (19)	112 (31)
Eye pruritus	57 (15)	58 (16)
Abnormal sensation in eyes	51 (14)	52 (15)
Foreign body sensation in eyes	44 (12)	36 (10)
Vision blurred	28 (7)	30 (8)
Lacrimation increased	19 (5)	14 (4)
Photophobia	13 (3)	17 (5)

### POSTMARKETING EXPERIENCE

The following adverse reactions have been identified during post-approval use of topical latanoprost products. Because these reactions are reported voluntarily from a population of uncertain size, it is not always possible to reliably estimate their frequency or establish a causal relationship to drug exposure. The reactions, which have been chosen for inclusion due to either their seriousness, frequency of reporting, possible causal connection to ophthalmic latanoprost products, or a combination of these factors, include:

- Nervous System Disorders: Dizziness; headache; toxic epidermal necrolysis
- Eye Disorders: Eyelash and vellus hair changes of the eyelid (increased length, thickness, pigmentation, and number of eyelashes); keratitis; corneal edema and erosions; intraocular inflammation (iritis/uveitis); macular edema, including cystoid macular edema; trichiasis; periorbital and lid changes resulting in deepening of the eyelid sulcus; iris cyst; eyelid skin darkening; localized skin reaction on the eyelids; conjunctivitis; pseudomphigoid of the ocular conjunctiva.
- Respiratory, Thoracic and Mediastinal Disorders: Asthma and exacerbation of asthma; dyspnea
- Skin and Subcutaneous Tissue Disorders: Pruritus
- Infections and Infestations: Herpes keratitis
- Cardiac Disorders: Angina; palpitations; angina unstable
- General Disorders and Administration Site Conditions: Chest pain

### DRUG INTERACTIONS

The combined use of two or more prostaglandins, or prostaglandin analogs including IYUZEH is not recommended, and administration of these prostaglandin drug products more than once daily may decrease the IOP lowering effect or cause paradoxical IOP elevations.

### USE IN SPECIFIC POPULATIONS

**Pregnancy:** There are no adequate and well-controlled studies of IYUZEH administration in pregnant women to inform drug-associated risks.

**Lactation:** It is not known whether this drug or its metabolites are excreted in human milk. Because many drugs are excreted in human milk, caution should be exercised when IYUZEH is administered to a nursing woman. The developmental and health benefits of breastfeeding should be considered along with the mother's clinical need for IYUZEH and any potential adverse effects on the breastfed child from IYUZEH.

**Pediatric Use:** The safety and effectiveness of IYUZEH have not been established in pediatric patients.

**Geriatric Use:** No overall differences in the safety or effectiveness of IYUZEH have been observed between elderly and younger adult patients.

### OVERDOSAGE

Intravenous infusion of up to 3 mcg/kg of latanoprost in healthy volunteers produced mean plasma concentrations 200 times higher than during clinical treatment with latanoprost ophthalmic solution and no adverse reactions were observed. IV dosages of 5.5 to 10 mcg/kg caused abdominal pain, dizziness, fatigue, hot flushes, nausea, and sweating.

### HANDLING THE CONTAINER

IYUZEH is a sterile solution that does not contain a preservative supplied in a single-dose container. The solution from one individual container is to be used immediately after opening for administration to one or both eyes. Since sterility cannot be maintained after the individual container is opened, the remaining contents should be discarded immediately after administration. Open a new single-dose container every time you use IYUZEH.

Manufactured for: Thea Pharma Inc. Waltham, MA.

All rights reserved.

U.S. Patent N°. 8,637,054.

Revised: 04/2023

©2021 Laboratoires Théa. All Rights Reserved. IYUZEH™ is a trademark of Laboratoires Théa.

IYUZEH™ (latanoprost ophthalmic solution) 0.005% is the first and only preservative-free latanoprost for patients with primary open-angle glaucoma (POAG) and ocular hypertension (OHT).

**iyuzeh**™  
(latanoprost ophthalmic solution) 0.005%



Transform how you lower IOP.

**POWER  
WITHOUT  
PRESERVATIVES.**



*We owe it to our patients with elevated intraocular pressure, with open-angle glaucoma or ocular hypertension to provide a new evidence-based approach. It is an extremely exciting time to prescribe IYUZEH™ for my patients.*

**Monique M. Barbour, MD, MHA, FFAO**

Dr. Barbour is a paid consultant of Thea Pharma Inc.



## INDICATIONS AND USAGE

IYUZEH™ is a prostaglandin analogue indicated for the reduction of elevated intraocular pressure in patients with open-angle glaucoma or ocular hypertension.

## IMPORTANT SAFETY INFORMATION

### CONTRAINDICATIONS

Known hypersensitivity to latanoprost or any other ingredients in this product.

### WARNINGS AND PRECAUTIONS

**Pigmentation:** Topical latanoprost ophthalmic products, including IYUZEH™ have been reported to cause changes to pigmented tissues. The most frequently reported changes have been increased pigmentation of the iris, periorbital tissue (eyelid), and eyelashes. Pigmentation is expected to increase as long as latanoprost is administered.

The pigmentation change is due to increased melanin content in the melanocytes rather than to an increase in the number of melanocytes. After discontinuation of latanoprost, pigmentation of the iris is likely to be permanent, while pigmentation of the periorbital tissue and eyelash changes have been reported to be reversible in some patients. Patients who receive treatment should be informed of the possibility of increased pigmentation. The long-term effects of increased pigmentation are not known.

Iris color change may not be noticeable for several months to years. Typically, the brown pigmentation around the pupil spreads concentrically towards the periphery of the iris and the entire iris or parts of the iris become more brownish. Neither nevi nor freckles of the iris appear to be affected by treatment. While treatment with IYUZEH™ can be continued in patients who develop noticeably increased iris pigmentation, these patients should be examined regularly.

**Eyelash Changes:** Latanoprost ophthalmic products, including IYUZEH™ may gradually change eyelashes and vellus hair in the treated eye; these changes include increased length, thickness, pigmentation, the number of lashes or hairs, and misdirected growth of eyelashes. Eyelash changes are usually reversible upon discontinuation of treatment.

**Intraocular Inflammation:** IYUZEH™ should be used with caution in patients with a history of intraocular inflammation (iritis/uveitis) and should generally not be used in patients with active intraocular inflammation because inflammation may be exacerbated.

**Macular Edema:** Macular edema, including cystoid macular edema, has been reported during treatment with latanoprost ophthalmic products, including IYUZEH™. IYUZEH™ should be used with caution in aphakic patients, in pseudophakic patients with a torn posterior lens capsule, or in patients with known risk factors for macular edema.

**Herpetic Keratitis:** Reactivation of herpes simplex keratitis has been reported during treatment with latanoprost. IYUZEH™ should be used with caution in patients with a history of herpetic keratitis. IYUZEH™ should be avoided in cases of active herpes simplex keratitis because inflammation may be exacerbated.

**Contact Lens Use:** Contact lenses should be removed prior to the administration of IYUZEH™ and may be reinserted 15 minutes after administration.

### ADVERSE REACTIONS

The following adverse reactions have been reported with the use of topical latanoprost products: iris pigmentation changes, eyelid skin darkening, eyelash changes (increased length, thickness, pigmentation, and number of lashes), intraocular inflammation (iritis/uveitis), and macular edema, including cystoid macular edema.


### DRUG INTERACTIONS

The combined use of two or more prostaglandins, or prostaglandin analogs including IYUZEH™ is not recommended. It has been shown that administration of these prostaglandin drug products more than once daily may decrease the IOP lowering effect or cause paradoxical elevations in IOP.

**Please see full Prescribing Information at [www.iyuzeh.com](http://www.iyuzeh.com) and Brief Summary on the next page.**

Explore the power of preservative-free latanoprost at [iyuzeh.com](http://iyuzeh.com)

**Théa**  
let's open our eyes





# FEATURES

Vol. XXXI, No. 2 • February 2024

**Catch Up on the Latest News**

Read *Review's* weekly newsletter

online at [reviewofophthalmology.com](http://reviewofophthalmology.com).

25

## A Virtual Reality Check: Where VR Perimetry Fits

Experts discuss the potential of VR visual fields and cut through the hype.

**Christine Yue Leonard**

*Senior Associate Editor*

37

## Back to Basics: Visual Field Interpretation

Findings need to be considered in correlation with the patient exam.

**Michelle Stephenson**

*Contributing Editor*

42

## Solving Dry-Eye Conundrums

Cornea specialists highlight the rare and unique diseases that can affect the ocular surface and how they often mystify even the most experienced clinician.

**Liz Hunter**

*Senior Editor*

50

## Managing Refractive Surgery Complications

Though refractive surgery has advanced a great deal over the decades, complications can still occur. Here's what to expect from the major procedures.

**Michelle Stephenson**

*Contributing Editor*





# DEPARTMENTS

February 2024

## 4 News

## 14 EDITOR'S PAGE The Darker Side of Animal Gambling

Walter Bethke  
Editor in Chief



## 17 THE FORUM New Years Yet To Come

Musings on life, medicine and the practice of ophthalmology.  
Mark H. Blecher, MD  
Chief Medical Editor

## 18 REFRACTIVE/CATARACT RUNDOWN More Than One Way to Crack a Nucleus

Cataract surgeons discuss their preferred techniques and when to modify for certain scenarios.  
Liz Hunter  
Senior Editor



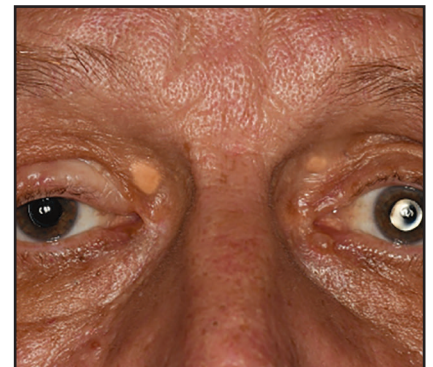## 57 PEDIATRIC PATIENT New Ways to Address Amblyopia

Digital therapeutics present promising ways to boost compliance and treat patients.  
Edward Kuwera, MD, and  
Courtney L. Kraus, MD

## 61 GLAUCOMA MANAGEMENT Cutting Edge Glaucoma Research

A round-up of standout ARVO papers advancing glaucomatology.  
Ahmara G. Ross, MD, PhD

## 62 AD INDEX



## 64 WILLS EYE RESIDENT CASE SERIES A man presents with plaque-like swelling of his eyelid.

Brian T. Cheng, MD, Sara E. Lally, MD,  
Carol L. Shields, MD, and Tatyana  
Milman, MD

### VISIT US ON SOCIAL MEDIA

Facebook [facebook.com/RevOphth](https://facebook.com/RevOphth)  
twitter/X [twitter.com/RevOphth](https://twitter.com/RevOphth)  
Instagram [@revophth](https://instagram.com/revophth)

xdemvy®  
(lotilaner ophthalmic  
solution) 0.25%



Learn more at  
XDEMZYHCP.com

## XDEMZY gives you **might over mites** to eradicate *Demodex* blepharitis.<sup>1,2</sup>

Lotilaner, the active ingredient in XDEMZY<sup>1,3,4</sup>:



Is a lipophilic agent in an aqueous drop that...



Acts specifically via mite GABA-gated  
chloride channels to...



Target, paralyze, and kill *Demodex* mites

GABA=gamma-aminobutyric acid.

### INDICATIONS AND USAGE

XDEMZY (lotilaner ophthalmic solution) 0.25% is indicated for the treatment of *Demodex* blepharitis.

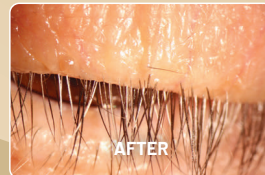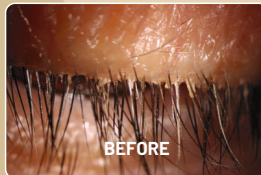
### IMPORTANT SAFETY INFORMATION:

#### WARNINGS AND PRECAUTIONS

**Risk of Contamination:** Do not allow the tip of the dispensing container to contact the eye, surrounding structures, fingers, or any other surface in order to minimize contamination of the solution. Serious damage to the eye and subsequent loss of vision may result from using contaminated solutions.

**Use with Contact Lenses:** XDEMZY contains potassium sorbate, which may discolor soft contact lenses. Contact lenses should be removed prior to instillation of XDEMZY and may be reinserted 15 minutes following its administration.

### Real results



44% and 55% of patients taking XDEMZY in SATURN-1 (N=209) and SATURN-2 (N=193), respectively, achieved a significant improvement in their eyelids (reduction of collarettes to no more than 2 collarettes per upper lid) at Day 43 vs 7% (N=204) and 12% (N=200) of patients taking vehicle (P<0.01 in each trial).<sup>1,\*</sup>

All images are of actual patients who participated in clinical trials for Tarsus Pharmaceuticals.

**ADVERSE REACTIONS:** The most common adverse reaction with XDEMZY was instillation site stinging and burning which was reported in 10% of patients. Other ocular adverse reactions reported in less than 2% of patients were chalazion/hordeolum and punctate keratitis.

Please see next page for a Brief Summary of the full Prescribing Information.

**References:** 1. XDEMZY [prescribing information]. Tarsus Pharmaceuticals, Inc; 2023. 2. Gao YY et al. *Invest Ophthalmol Vis Sci.* 2005;46(9):3089-3094. 3. Yeu E et al. *Cornea.* 2022;42:435-443. 4. Toutain CE et al. *Parasit Vectors.* 2017;10(1):522.

\*The safety and efficacy of XDEMZY for the treatment of DB were evaluated in a total of 833 patients (415 of whom received XDEMZY) in two 6-week, randomized, multicenter, double-masked, vehicle-controlled studies (SATURN-1 and SATURN-2). Patients were randomized to either XDEMZY or vehicle at a 1:1 ratio, dosed twice daily in each eye for 6 weeks. All patients enrolled were diagnosed with DB. The primary efficacy endpoint was defined as the proportion of patients with collarette reduction to no more than 2 collarettes per upper eyelid at Day 43.

© 2024 Tarsus Pharmaceuticals, Inc. All rights reserved.  
Tarsus, XDEMZY, and the associated logos are trademarks of  
Tarsus Pharmaceuticals, Inc. US--2300617 1/24





(Continued from p. 6)

## Lung Cancer Increases Keratitis Risk by 50 Percent

Epidermal growth factor receptor inhibitors are now some of the most prescribed drugs to treat lung cancer. Ocular side effects have been documented for numerous cancer medications, and EGFRis are no exception; ocular toxicity can manifest as trichomegaly, dry eye or defects of the tear film or epithelium. Adding to this list, a recent study found that EGFRi therapy—especially second-generation afatinib—also increases the risk of new-onset keratitis.

The study involved all patients treated for lung cancer over the last 20 years. Of 1,388,108 total cases identified, 22,225 received EGFRi therapy. The researchers discovered that these patients were 50 percent more likely to develop keratitis than those who didn't take the drug. Subtypes of EGFRi-associated keratitis included keratoconjunctivitis (hazard ratio, HR: 1.37), superficial keratitis (HR: 1.64) and corneal ulcer (HR: 2.13).

“Notably, keratoconjunctivitis, a common presentation in dry-eye disease, was a frequent subtype observed in this study, suggesting that EGFRi-treated patients may have a higher risk of dry eye,” the researchers wrote in their paper, published in *JAMA Ophthalmology*.<sup>1</sup>

Three generations of commonly prescribed EGFRis exist: first-generation gefitinib and erlotinib, second-generation afatinib and third-generation osimertinib. In this study, patients taking afatinib displayed the highest risk of keratitis (HR: 2.23). The authors pointed out that this finding is consistent with past studies that have reported greater adverse effects with afatinib than erlotinib.

There are several mechanisms that could contribute to the elevated risk of keratitis with EGFRi treatment. For one, EGFRi therapy has previously been linked to trichomegaly, “a recognized ocular adverse effect that elevates the risk of corneal cell damage due to abnormal overgrowth and misaligned eyelashes,” the researchers explained. “Additionally,” they continued, “EGFRis inhibit the proliferation, stratification, and migration of limbal and corneal stem cells, impeding the proper repair of damaged corneal epithelial cells.”

When seeing patients undergoing treatment for lung cancer, it's important to clarify which medication (or medications) they're taking to assess the potential risk for keratitis. EGFRi-associated ocular effects require prompt diagnosis and management to prevent serious complications or treatment disruptions, the authors urge. ◀

1. Huang P, Lin C, Dana R, Ma KS. Epidermal growth factor receptor inhibitors for lung cancer and the risk of keratitis. *JAMA Ophthalmol*. January 11, 2024. [Epub ahead of print].

**XDEMYV® (lotilaner ophthalmic solution) 0.25%, for topical ophthalmic use**

### BRIEF SUMMARY OF PRESCRIBING INFORMATION

Please see the XDEMYV® package insert for full Prescribing Information.

### INDICATIONS AND USAGE

XDEMYV is indicated for the treatment of *Demodex* blepharitis.

### CONTRAINDICATIONS

None.

### WARNINGS AND PRECAUTIONS

**Risk of Contamination** Do not allow the tip of the dispensing container to contact the eye, surrounding structures, fingers, or any other surface in order to minimize contamination of the solution. Serious damage to the eye and subsequent loss of vision may result from using contaminated solutions.

**Use with Contact Lenses** Contact lenses should be removed prior to instillation of XDEMYV and may be reinserted 15 minutes following its administration.

### ADVERSE REACTIONS

Because clinical studies are conducted under widely varying conditions, adverse reaction rates observed in the clinical trials of a drug cannot be directly compared to rates in the clinical trials of another drug and may not reflect the rates observed in practice.

XDEMYV was evaluated in 833 patients with *Demodex* blepharitis in two randomized, double-masked, vehicle-controlled studies (Saturn-1 and Saturn-2) with 42 days of treatment. The most common ocular adverse reaction observed in controlled clinical studies with XDEMYV was instillation site stinging and burning which was reported in 10% of patients. Other ocular adverse reactions reported in less than 2% of patients were chalazion/hordeolum and punctate keratitis.

### USE IN SPECIFIC POPULATIONS

**Pregnancy: Risk Summary** There are no available data on XDEMYV use in pregnant women to inform any drug associated risk; however, systemic exposure to lotilaner from ocular administration is low. In animal reproduction studies, lotilaner did not produce malformations at clinically relevant doses.

**Data Animal Data** In an oral embryofetal developmental study in pregnant rats dosed during organogenesis from gestation days 6–19, increased post-implantation loss, reduced fetal pup weight, and incomplete skeletal ossification were observed at 50 mg/kg/day (approximately 1390 times the recommended human ophthalmic dose (RHOD) on a body surface area basis) in the presence of maternal toxicity (i.e., decreased body weight and food consumption). A rare malformation of situs inversus of the thoracic and abdominal viscera occurred in 1 fetus from a pregnant rat receiving 50 mg/kg/day; whether this finding was treatment-related could not be excluded. No maternal or embryofetal toxicity was observed at 18 mg/kg/day (approximately 501 times the RHOD on a body surface area basis). In an oral embryofetal development study in pregnant rabbits dosed during organogenesis from gestation days 7–19, no embryofetal toxicity or teratogenic findings were observed at 20 mg/kg/day (approximately 580-times the RHOD on an AUC basis), even in the presence of maternal toxicity (i.e., decreased food consumption and body weight).

In an oral two-generation reproductive toxicity study, F0 male and female rats were administered lotilaner at doses up to 40 mg/kg/day for 10 weeks before pairing and during the 2-week pairing period (3 weeks for males). Dosing for F0 females continued through lactation day 22. F1 male and female rats were administered lotilaner at 1 and 5 mg/kg/day post-weaning from day 23 for 10 weeks before pairing and during the 2-week pairing period (3 weeks for males). Dosing for F1 parenteral females continued through lactation day 22. There were no clear adverse effects on the F1 generation, and a slightly lower mean body weight during lactation was noted for F2 pups at 5 mg/kg/day. The no observed adverse effect level (NOAEL) was determined to be 5 mg/kg/day

(approximately 139 times the RHOD on a body surface area basis).

**Lactation: Risk Summary** There are no data on the presence of XDEMYV in human milk, the effects on the breastfed infant, or the effects on milk production. However, systemic exposure to lotilaner following 6 weeks of topical ocular administration is low and is >99% plasma protein bound, thus it is not known whether measurable levels of lotilaner would be present in maternal milk following topical ocular administration. The developmental and health benefits of breastfeeding should be considered along with the mother's clinical need for XDEMYV and any potential adverse effects on the breast-fed child from XDEMYV.

**Pediatric Use:** Safety and effectiveness in pediatric patients below the age of 18 years have not been established.

**Geriatric Use:** No overall differences in safety or effectiveness have been observed between elderly and other adult patients.

### NONCLINICAL TOXICOLOGY

#### Carcinogenesis, Mutagenesis, Impairment of Fertility

**Carcinogenesis** Long-term studies in animals have not been performed to evaluate the carcinogenic potential of lotilaner.

**Mutagenesis** Lotilaner was not genotoxic in the following assays: Ames assay for bacterial gene mutation, *in vitro* chromosomal aberration assay in cultured human peripheral blood lymphocytes, and *in vivo* rat micronucleus test.

**Impairment of fertility** In a two-generation study of reproductive performance in rats, F0 male and female rats were administered lotilaner at oral doses of 40 mg/kg/day for 80 days reduced to 20 mg/kg/day for 47–50 supplementary days. Reduced pregnancy rates and decreased implantation rates were observed in F0 females at doses 20 mg/kg/day (approximately 556 times the RHOD on a body surface area basis), which were also associated with maternal toxicity (i.e., decreased body weight and food consumption). No effects on fertility were observed in F0 females at the dose of 5 mg/kg/day (approximately 139 times the RHOD on a body surface area basis). No effects on fertility were observed in F0 males at the oral dose of 20 mg/kg/day (approximately 556 times the RHOD on a body surface area basis), and no effects on fertility were observed in F1 males and females at the oral dose of 5 mg/kg/day (approximately 139 times the RHOD on a body surface area basis).

#### PATIENT COUNSELING INFORMATION

**Handling the Container** Instruct patients to avoid allowing the tip of the dispensing container to contact the eye, surrounding structures, fingers, or any other surface in order to minimize contamination of the solution. Serious damage to the eye and subsequent loss of vision may result from using contaminated solutions.

#### When to Seek Physician Advice

Advise patients that if they develop an intercurrent ocular condition (e.g., trauma or infection), have ocular surgery, or develop any ocular reactions, particularly conjunctivitis and eyelid reactions, they should immediately seek their physician's advice concerning the continued use of XDEMYV.

**Use with Contact Lenses** Advise patients that XDEMYV contains potassium sorbate, which may discolor soft contact lenses. Contact lenses should be removed prior to instillation of XDEMYV and may be reinserted 15 minutes following its administration.

**Use with Other Ophthalmic Drugs** Advise patients that if more than one topical ophthalmic drug is being used, the drugs should be administered at least 5 minutes between applications.

**Missed Dose** Advise patients that if one dose is missed, treatment should continue with the next dose.

RX only

© 2024 Tarsus Pharmaceuticals, Inc. All rights reserved.

XDEMYV is a trademark of Tarsus Pharmaceuticals, Inc.

US—2300345 1/24



## CONTRIBUTORS

### CHIEF MEDICAL EDITOR

Mark H. Blecher, MD

### CONTACT LENSES

Penny Asbell, MD

### CORNEA / ANTERIOR SEGMENT

Thomas John, MD

### GLAUCOMA MANAGEMENT

Peter Netland, MD, PHD  
Kuldev Singh, MD

### MEDICARE Q & A

Mary Pat Johnson,  
COMT, CPC

### PEDIATRIC PATIENT

Janine Collinge, MD

### PLASTIC POINTERS

April Lao, MD

### REFRACTIVE SURGERY

Arturo S. Chayet, MD

### RETINAL INSIDER

Carl Regillo, MD, FACS  
Yoshihiro Yonekawa, MD

### TECHNOLOGY UPDATE

Steven T. Charles, MD  
Michael Colvard, MD

### WILLS RESIDENT CASE SERIES

Collin Rozanski, MD

## ADVISORY BOARD

**PENNY A. ASBELL, MD**, MEMPHIS, TENN.

**BRANDON AYRES, MD**, PHILADELPHIA

**SURENDRA BASTI, MD**, CHICAGO

**WILLIAM I. BOND, MD**, PEKIN, ILL.

**ALAN N. CARLSON, MD**, DURHAM, N.C.

**Y. RALPH CHU, MD**, EDINA, MINN.

**ADAM J. COHEN, MD**, CHICAGO

**JANINE COLLINGE, MD**, FARMINGTON, CONN.

**UDAY DEVGAN, MD, FACS**, LOS ANGELES

**ERIC DONNENFELD, MD**, ROCKVILLE CENTRE, N.Y.

**DANIEL S. DURRIE, MD**, KANSAS CITY, MO.

**ROBERT EPSTEIN, MD**, MCHENRY, ILL.

**ROBERT D. FECHTNER, MD**, NEWARK, N.J.

**BRIAN FRANCIS, MD**, Los Angeles

**JAMES P. GILLS, MD**, TARPON SPRINGS, FLA.

**HARRY GRABOW, MD**, SARASOTA, FLA.

**DOUGLAS K. GRAYSON, MD**, NEW YORK CITY

**DAVID R. HARDTEN, MD**, MINNEAPOLIS

**SARA J. HAUG, MD, PHD**, DURANGO, COLO.

**KENNETH J. HOFFER, MD**, SANTA MONICA, CALIF.

**JACK T. HOLLADAY, MD, MSEE**, HOUSTON

**JOHN D. HUNKELER, MD**, KANSAS CITY, MO.

**THOMAS JOHN, MD**, TINLEY PARK, ILL.

**ROBERT M. KERSHNER, MD, MS**, PALM BEACH GARDENS, FLA.

**GUY M. KEZIRIAN, MD**, PARADISE VALLEY, ARIZ.

**SUMITRA KHADELWAL, MD**, HOUSTON

**TERRY KIM, MD**, DURHAM, N.C.

**BRAD KLIGMAN, MD**, MANHASSET, N.Y.

**TOMMY KORN, MD**, SAN DIEGO

**APRIL LAO, MD**, MEMPHIS

**DAVID A. LEE, MD**, HOUSTON

**FRANCIS S. MAH, MD**, LA JOLLA, CALIF.

**NICK MAMALIS, MD**, SALT LAKE CITY

**EDWARD MANCHE, MD**, PALO ALTO, CALIF.

**MIKE S. MCFARLAND, MD**, PINE BLUFF, ARK.

**JEFFREY B. MORRIS, MD, MPH**, ENCINITAS, CALIF.

**KEVIN MILLER, MD**, LOS ANGELES

**MAJID MOSHIRFAR, MD**, DRAPER, UTAH

**MARLENE R. MOSTER, MD**, PHILADELPHIA

**ROBERT J. NOECKER, MD**, FAIRFIELD, CONN.

**ROBERT OSHER, MD**, CINCINNATI

**MARK PACKER, MD**, WEST PALM BEACH, FLA.

**CHRISTOPHER J. RAPUANO, MD**, PHILADELPHIA

**AUGUST READER III, MD**, SAN FRANCISCO

**TONY REALINI, MD, MPH**, MORGANTOWN, W.V.

**KENNETH J. ROSENTHAL, MD**, GREAT NECK, N.Y.

**ERIC ROTHCHILD, MD**, DELRAY BEACH, FLA.

**SHERI ROWEN, MD**, BALTIMORE

**INGRID U. SCOTT, MD, MPH**, HERSHEY, PA.

**JOEL SCHUMAN, MD**, PITTSBURGH

**GAURAV SHAH, MD**, ST. LOUIS

**DAVID R. STAGER JR., MD**, DALLAS

**KARL STONECIPHER, MD**, GREENSBORO, N.C.

**JAMES C. TSAI, MD**, NEW YORK CITY

**VANCE THOMPSON, MD**, SIOUX FALLS, S.D.

**FARRELL C. TYSON, MD**, CAPE CORAL, FLA.

**R. BRUCE WALLACE III, MD**, ALEXANDRIA, LA.



### BUSINESS OFFICES

19 CAMPUS BOULEVARD, SUITE 101  
NEWTOWN SQUARE, PA 19073  
SUBSCRIPTION INQUIRIES (877) 529-1746  
(USA ONLY); OUTSIDE USA, CALL (847) 763-9630

### BUSINESS STAFF

PUBLISHER

**MICHAEL HOSTER**

(610) 492-1028 MHOSTER@JOBSON.COM

SENIOR MANAGER, STRATEGIC ACCOUNTS

**MICHELE BARRETT**

(610) 492-1014 MBARRETT@JOBSON.COM

REGIONAL SALES MANAGER

**JONATHAN DARDINE**

(610) 492-1030 JDARDINE@JOBSON.COM

DIGITAL MARKETING MANAGER

**MATT EGGER**

(610) 492-1029 MEGGER@JOBSON.COM

CLASSIFIED ADVERTISING

(888)-498-1460

PRODUCTION MANAGER

**KAREN LALLONE**

(610) 492-1010 KLALLONE@JOBSON.COM

SUBSCRIPTIONS

\$63 A YEAR, \$99 (U.S.) IN CANADA,  
\$158 (U.S.) IN ALL OTHER COUNTRIES.

SUBSCRIPTIONS E-MAIL:

REVOPHTHALMOLOGY@CAMBEYWEST.COM

CIRCULATION

PO BOX 71, CONGERS, NY 10920-0071

(877) 529-1746

OUTSIDE USA: (845) 267-3065

SENIOR CIRCULATION MANAGER

**HAMILTON MAHER**

(212) 219-7870 hmaher@jhihealth.com

CEO, INFORMATION GROUP SERVICES

**BILL SCOTT**

VICE PRESIDENT, CREATIVE SERVICES & PRODUCTION

**MONICA TETTAMANZI**

DIRECTOR, PRODUCTION/MANUFACTURING

**REBECCA SLEBODNIK**

VICE PRESIDENT, HUMAN RESOURCES

**TAMMY GARCIA**

VICE PRESIDENT, CIRCULATION

**JARED SONNERS**

299 Market St. 2 Gateway Center - 4th Floor

Newark NJ 07102



## EDITORIAL STAFF

**Editor in Chief**  
**Walter Bethke**

(610) 492-1024  
wbethke@jobson.com

**Senior Editor**  
**Liz Hunter**

(610) 492-1025  
ehunter@jobson.com

**Senior Associate Editor**  
**Christine Leonard**

(610) 492-1008  
cleonard@jobson.com

**Associate Editor**  
**Leanne Spiegle**

(610) 492-1026  
lspiegle@jobson.com

**Associate Editor**  
**Andrew Beers**

(570) 856-5156  
abeers@jobson.com

**Chief Medical Editor**  
**Mark H. Blecher, MD**

**Art Director**

**Lynne O'Connor**

(267) 566-6007  
lyoconnor@jobson.com

**Graphic Designer**  
**Jaine Kopala**

(609) 969-0694  
jkopala@jobson.com

**Business Offices**

19 Campus Boulevard, Suite 101  
Newtown Square, PA 19073  
(610) 492-1000  
Fax: (610) 492-1039

**Subscription inquiries:**

United States – (877) 529-1746  
Outside U.S. – (845) 267-3065  
E-mail:  
revophthalmology@cambeywest.com  
Website: www.reviewofophthalmology.com



# The Darker Side of Animal Gambling

**W**hen word came down that Medicare would be cutting reimbursement by 5.4 percent in 2024, some physicians no doubt felt an understandable wave of anxiety. “How will we manage with the new payment cut?” they’d wonder. And then, on another level, they’d probably also wonder, “Are these endless cuts necessary? Aren’t there other, less vital programs that could be cut first, rather than sight-saving surgery?” It turns out, these surgeons are probably right.

At the end of 2023, Kentucky Senator Rand Paul assembled his annual list of wasteful government spending and, as usual, you have to laugh to keep from crying. Here’s a look at some of the highlights which show that if wasteful spending were curtailed just a little bit, it might give physicians a little more reimbursement breathing room.

In one example of waste, the government lost around \$180 million worth of equipment because they couldn’t store it properly. One instance involved 80 military turbine engines (\$1.1 million each) that were left to fall apart outside, rather than being housed in a building. The second saw 135 hydraulic transmissions (\$12.6 million total) in leaky containers outside, sitting in pools of standing water and oil.<sup>1</sup> In the third instance, \$68.2 million worth of tank treads went to seed by being allowed to sit out in the elements rather than a shed.

The government also seems to love giving drugs to animals to come to conclusions that we pretty much knew already. In one such insightful study, researchers gave monkeys meth in the morning and then tracked their sleep habits. It wouldn’t be that bad if it didn’t cost the National Institutes of Health \$12 million dollars in grant money.<sup>1</sup>

Spoiler alert: Substituting meth for an Egg McMuffin every day affects your sleep.

In other news, do you think the Medicare system could use \$400.6 million? It could? OK, because that’s how much has been sitting in the Presidential Election Campaign Fund account (funded by that little checkbox on your tax return where you can donate \$3). Since 2008, no major party’s candidate has accepted any funds from it. So it’s just sitting there.<sup>1</sup> Though these funds obviously couldn’t be accessed to help Medicare’s budget, they are an example of how adept the government is at wasting hundreds of millions of dollars.

Before you think we got away from 2023 without funding any animal gambling research—think again. Researchers can’t seem to get enough of gambling animals. It’s their monkey meth. A couple of years ago, it was slot-machine-loving pigeons, this year, it’s high-rolling monkeys. As described in the report, two rhesus macaques had part of their skull removed to allow researchers to inject a tracer into their brain that allowed the study doctors to monitor neural activity. The monkeys then gambled between options they saw on screens with different risk/reward values. It turns out, monkeys choose the high-risk/high-reward option more than 70 percent of the time, and it only cost us \$3.7 million to learn.<sup>1</sup>

Let’s hope that, in 2024, the government takes some of its gambling animal money and puts it toward physician reimbursement instead. The payouts are much better for everyone.

— *Walter Bethke*  
*Editor in Chief*

1. The Festivus Report: 2023. <https://www.hsgac.senate.gov/wp-content/uploads/Festivus-2023.pdf>. Accessed January 21, 2024.



# SYFOVRE<sup>®</sup>

(pegcetacoplan injection)  
15 mg / 0.1 mL

GA unravels so much  
**SAVE RETINAL TISSUE  
BY SLOWING  
PROGRESSION**<sup>1-3</sup>

SYFOVRE achieved continuous reductions in mean lesion growth rate\* vs sham pooled from baseline to Month 24<sup>1,4</sup>

Monthly	Every Other Month (EOM)
OAKS trial (mm <sup>2</sup> ): (3.11 vs 3.98) <b>22%</b>	OAKS trial (mm <sup>2</sup> ): (3.26 vs 3.98) <b>18%</b>
DERBY trial (mm <sup>2</sup> ): (3.28 vs 4.00) <b>18%</b>	DERBY trial (mm <sup>2</sup> ): (3.31 vs 4.00) <b>17%</b>

SE in trials (monthly, EOM, sham pooled):  
OAKS: 0.15, 0.13, 0.14; DERBY: 0.13, 0.13, 0.17.

\*Slope for baseline to Month 24 is an average of slope of baseline to Month 6, Month 6 to Month 12, Month 12 to Month 18, and Month 18 to Month 24.<sup>1</sup>

Based on a mixed effects model for repeated measures assuming a piecewise linear trend in time with knots at Month 6, Month 12, and Month 18.<sup>1</sup>

GA=geographic atrophy;  
SE=standard error.



Explore the  
long-term data

The CMS-assigned permanent J-code for  
SYFOVRE is J2781—effective 10/1/23<sup>1</sup>

## INDICATION

SYFOVRE<sup>®</sup> (pegcetacoplan injection) is indicated for the treatment of geographic atrophy (GA) secondary to age-related macular degeneration (AMD).

## IMPORTANT SAFETY INFORMATION

### CONTRAINDICATIONS

- SYFOVRE is contraindicated in patients with ocular or periocular infections, and in patients with active intraocular inflammation

### WARNINGS AND PRECAUTIONS

#### • Endophthalmitis and Retinal Detachments

- Intravitreal injections, including those with SYFOVRE, may be associated with endophthalmitis and retinal detachments. Proper aseptic injection technique must always be used when administering SYFOVRE to minimize the risk of endophthalmitis. Patients should be instructed to report any symptoms suggestive of endophthalmitis or retinal detachment without delay and should be managed appropriately.

#### • Neovascular AMD

- In clinical trials, use of SYFOVRE was associated with increased rates of neovascular (wet) AMD or choroidal neovascularization (12% when administered monthly, 7% when administered every other month and 3% in the control group) by Month 24. Patients receiving SYFOVRE should be monitored for signs of neovascular AMD. In case anti-Vascular Endothelial Growth Factor (anti-VEGF) is required, it should be given separately from SYFOVRE administration.

#### • Intraocular Inflammation

- In clinical trials, use of SYFOVRE was associated with episodes of intraocular inflammation including: vitritis, vitreal cells, iridocyclitis, uveitis, anterior chamber cells, iritis, and anterior chamber flare. After inflammation resolves, patients may resume treatment with SYFOVRE.

#### • Increased Intraocular Pressure

- Acute increase in IOP may occur within minutes of any intravitreal injection, including with SYFOVRE. Perfusion of the optic nerve head should be monitored following the injection and managed as needed.

## ADVERSE REACTIONS

- Most common adverse reactions (incidence  $\geq 5\%$ ) are ocular discomfort, neovascular age-related macular degeneration, vitreous floaters, conjunctival hemorrhage.

Please see Brief Summary of Prescribing Information for SYFOVRE on the adjacent page.

**Trial Design:** SYFOVRE safety and efficacy were assessed in OAKS (N=637) and DERBY (N=621), multi-center, 24-month, Phase 3, randomized, double-masked trials. Patients with GA (atrophic nonexudative age-related macular degeneration), with or without subfoveal involvement, secondary to AMD were randomly assigned (2:2:1:1) to receive 15 mg/0.1 mL intravitreal SYFOVRE monthly, SYFOVRE EOM, sham monthly, or sham EOM for 24 months. Change from baseline in the total area of GA lesions in the study eye (mm<sup>2</sup>) was measured by fundus autofluorescence (FAF).<sup>1,4</sup>

**References:** 1. SYFOVRE (pegcetacoplan injection) [package insert]. Waltham, MA: Apellis Pharmaceuticals, Inc.; 2023. 2. Pfau M, von der Emde L, de Sistiemes L, et al. Progression of photoreceptor degeneration in geographic atrophy secondary to age-related macular degeneration. *JAMA Ophthalmol.* 2020;138(10):1026-1034. 3. Bird AC, Phillips RL, Hageman GS. Geographic atrophy: a histopathological assessment. *JAMA Ophthalmol.* 2014;132(3):338-345. 4. Data on file. Apellis Pharmaceuticals, Inc.

Apellis

APPELLIS<sup>®</sup>, SYFOVRE<sup>®</sup> and their respective logos are registered trademarks of Apellis Pharmaceuticals, Inc.  
©2023 Apellis Pharmaceuticals, Inc. 7/23 US-PEGGA-2200232 v2.0



## **SYFOVRE® (pegcetacoplan injection), for intravitreal use**

### **BRIEF SUMMARY OF PRESCRIBING INFORMATION**

Please see SYFOVRE full Prescribing Information for details.

#### **INDICATIONS AND USAGE**

SYFOVRE is indicated for the treatment of geographic atrophy (GA) secondary to age-related macular degeneration (AMD).

#### **CONTRAINDICATIONS**

##### **Ocular or Periocular Infections**

SYFOVRE is contraindicated in patients with ocular or periocular infections.

##### **Active Intraocular Inflammation**

SYFOVRE is contraindicated in patients with active intraocular inflammation.

#### **WARNINGS AND PRECAUTIONS**

##### **Endophthalmitis and Retinal Detachments**

Intravitreal injections, including those with SYFOVRE, may be associated with endophthalmitis and retinal detachments. Proper aseptic injection technique must always be used when administering SYFOVRE in order to minimize the risk of endophthalmitis. Patients should be instructed to report any symptoms suggestive of endophthalmitis or retinal detachment without delay and should be managed appropriately.

##### **Neovascular AMD**

In clinical trials, use of SYFOVRE was associated with increased rates of neovascular (wet) AMD or choroidal neovascularization (12% when administered monthly, 7% when administered every other month and 3% in the control group) by Month 24. Patients receiving SYFOVRE should be monitored for signs of neovascular AMD. In case anti-Vascular Endothelial Growth Factor (anti-VEGF) is required, it should be given separately from SYFOVRE administration.

##### **Intraocular Inflammation**

In clinical trials, use of SYFOVRE was associated with episodes of intraocular inflammation including: vitritis, vitreal cells, iridocyclitis, uveitis, anterior chamber cells, iritis, and anterior chamber flare. After inflammation resolves patients may resume treatment with SYFOVRE.

##### **Increased Intraocular Pressure**

Acute increase in IOP may occur within minutes of any intravitreal injection, including with SYFOVRE. Perfusion of the optic nerve head should be monitored following the injection and managed as needed.

#### **ADVERSE REACTIONS**

##### **Clinical Trials Experience**

Because clinical trials are conducted under widely varying conditions, adverse reaction rates observed in the clinical trials of a drug cannot be directly compared to rates in the clinical trials of another drug and may not reflect the rates observed in practice.

A total of 839 patients with GA in two Phase 3 studies (OAKS and DERBY) were treated with intravitreal SYFOVRE, 15 mg (0.1 mL of 150 mg/mL solution). Four hundred nineteen (419) of these patients were treated in the affected eye monthly and 420 were treated in the affected eye every other month. Four hundred seventeen (417) patients were assigned to sham.

The most common adverse reactions ( $\geq 5\%$ ) reported in patients receiving SYFOVRE were ocular discomfort, neovascular age-related macular degeneration, vitreous floaters, and conjunctival hemorrhage.

**Table 1: Adverse Reactions in Study Eye Reported in  $\geq 2\%$  of Patients Treated with SYFOVRE Through Month 24 in Studies OAKS and DERBY**

<b>Adverse Reactions</b>	<b>PM (N = 419) %</b>	<b>PEOM (N = 420) %</b>	<b>Sham Pooled (N = 417) %</b>
Ocular discomfort*	13	10	11
Neovascular age-related macular degeneration*	12	7	3
Vitreous floaters	10	7	1
Conjunctival hemorrhage	8	8	4
Vitreous detachment	4	6	3
Retinal hemorrhage	4	5	3
Punctate keratitis*	5	3	<1
Posterior capsule opacification	4	4	3
Intraocular inflammation*	4	2	<1
Intraocular pressure increased	2	3	<1

PM: SYFOVRE monthly; PEOM: SYFOVRE every other month

\*The following reported terms were combined:

**Ocular discomfort** included: eye pain, eye irritation, foreign body sensation in eyes, ocular discomfort, abnormal sensation in eye

**Neovascular age-related macular degeneration** included: exudative age-related macular degeneration, choroidal neovascularization

**Punctate keratitis** included: punctate keratitis, keratitis

**Intraocular inflammation** included: vitritis, vitreal cells, iridocyclitis, uveitis, anterior chamber cells, iritis, anterior chamber flare

Endophthalmitis, retinal detachment, hyphema and retinal tears were reported in less than 1% of patients. Optic ischemic neuropathy was reported in 1.7% of patients treated monthly, 0.2% of patients treated every other month and 0.0% of patients assigned to sham. Deaths were reported in 6.7% of patients treated monthly, 3.6% of patients treated every other month and 3.8% of patients assigned to sham. The rates and causes of death were consistent with the elderly study population.

#### **USE IN SPECIFIC POPULATIONS**

##### **Pregnancy**

###### **Risk Summary**

There are no adequate and well-controlled studies of SYFOVRE administration in pregnant women to inform a drug-associated risk. The use of SYFOVRE may be considered following an assessment of the risks and benefits.

Systemic exposure of SYFOVRE following ocular administration is low. Subcutaneous administration of pegcetacoplan to pregnant monkeys from the mid gestation period through birth resulted in increased incidences of abortions and stillbirths at systemic exposures 1040-fold higher than that observed in humans at the maximum recommended human ophthalmic dose (MRHOD) of SYFOVRE (based on the area under the curve (AUC) systemically measured levels). No adverse maternal or fetal effects were observed in monkeys at systemic exposures approximately 470-fold higher than that observed in humans at the MRHOD.

In the U.S. general population, the estimated background risk of major birth defects and miscarriage in clinically recognized pregnancies is 2-4% and 15-20%, respectively.

##### **Lactation**

###### **Risk Summary**

It is not known whether intravitreal administered pegcetacoplan is secreted in human milk or whether there is potential for absorption and harm to the infant. Animal data suggest that the risk of clinically relevant exposure to the infant following maternal intravitreal treatment is minimal. Because many drugs are excreted in human milk, and because the potential for absorption and harm to infant growth and development exists, caution should be exercised when SYFOVRE is administered to a nursing woman.

##### **Females and Males of Reproductive Potential**

###### **Contraception**

**Females:** It is recommended that women of childbearing potential use effective contraception methods to prevent pregnancy during treatment with intravitreal pegcetacoplan. Advise female patients of reproductive potential to use effective contraception during treatment with SYFOVRE and for 40 days after the last dose. For women planning to become pregnant, the use of SYFOVRE may be considered following an assessment of the risks and benefits.

###### **Pediatric Use**

The safety and effectiveness of SYFOVRE in pediatric patients have not been established.

###### **Geriatric Use**

In clinical studies, approximately 97% (813/839) of patients randomized to treatment with SYFOVRE were  $\geq 65$  years of age and approximately 72% (607/839) were  $\geq 75$  years of age. No significant differences in efficacy or safety were seen with increasing age in these studies. No dosage regimen adjustment is recommended based on age.

#### **PATIENT COUNSELING INFORMATION**

Advise patients that following SYFOVRE administration, patients are at risk of developing neovascular AMD, endophthalmitis, and retinal detachments. If the eye becomes red, sensitive to light, painful, or if a patient develops any change in vision such as flashing lights, blurred vision or metamorphopsia, instruct the patient to seek immediate care from an ophthalmologist.

Patients may experience temporary visual disturbances associated either with the intravitreal injection with SYFOVRE or the eye examination. Advise patients not to drive or use machinery until visual function has recovered sufficiently.

Manufactured for:  
Apellis Pharmaceuticals, Inc.  
100 Fifth Avenue  
Waltham, MA 02451

SYF-PI-17Feb2023-1.0

APELLIS®, SYFOVRE® and their respective logos are registered trademarks of Apellis Pharmaceuticals, Inc.  
©2023 Apellis Pharmaceuticals, Inc.

7/23 US-PEGGA-2200163 v3.0



# New Years Yet To Come

*Musings on life, medicine and the practice of ophthalmology.*

**MARK H. BLECHER**  
CHIEF MEDICAL EDITOR

**T**he new year is well underway, and as always I can't remember which one it is. I barely got used to it being 2023, and now it's 2024.

And while this is something I and probably many of you have dealt with all our lives, it seems now to me that the numbers are just impossible. Seriously, who thought we would ever make it to 2024? With the insane fixation of pop culture on 'apocalypse' movies, you can't blame us. I remember thinking at one point that 2000 was both far off and scary. Until it wasn't. And our worst fears never materialized. "2001: A Space Odyssey" was crazy sci-fi of the distant future. For better or worse, we didn't really get anywhere close to the reality portrayed in the movie. I'm not so much disappointed that we don't have manned travel to Jupiter even a quarter century beyond that infamous year, but that, when it was released in 1968, 2001 seemed so distant. The future is just that: the future—with impossibly large numbers so far away. But in reality they're not. I saw a meme this week that said that we are as close to 2034 as to 2014. But in our heads, my head anyway, 2014 was just yesterday and 2034 is way out there. In thinking back over my many years, the future

has always been subjectively further away than the past even if it isn't. The past seems so touchable, so real and in some cases so painful. The future is simply scary. It's unknown, unknowable and, on the whole, uncontrollable. "Man plans, and God laughs," as they say. The future has too many variables, the past has none. So perhaps that's why we put it off in our heads. It is a time yet to be dealt with.



After googling for this column, it turns out there's literature and a study that seems to support just the opposite: That events in the future actually seem closer than those equidistant in the past. However, as with all comparisons, the metrics need to be the same. In the journal *Psychological Science*, researchers found that the students that were the subjects of the study felt that

events a week and a year in the future were closer than those a week and year in the past. This seeming contradiction to my obviously more correct premise above might be resolved by noting two things: In this case, the time involved in the study is relatively close: a week and a year, not years, or decades. And in that study they postulated the reason the future felt closer than the past was that time is linked to space. More specifically movement through space. And since the future is something we're moving toward, it seems shorter than the past which, in our minds, is static; it's already happened and not going anywhere. And the closer the future, the more apparent the movement seemed, which is again logical. Driving toward the distant mountain, the sense of movement is unimpressive, but

watching the road signs zip by is something quite different. It isn't often that popular perception can be found to be in concordance with Einstein's theory of relativity. That's kind of profound and a little scary. And in some ways, it's neat that we can experience it for ourselves.

Of course as regular readers of my column know, I'm a big believer in living in the present, that it's neither useful nor healthy to be dwelling on either the past or the future, no matter how close or far they may seem. But, we live in a world that reminds us of both, a world in constant motion, filled with currents of time that make it both exciting and scary. If you focus on the moment to moment of your life, everything flows in small increments so the future doesn't seem so momentous when it gets here. As a result, new years to come will be both unsurprising and expected. ◀





EDITED BY ARTURO CHAYET, MD

## REFRACTIVE/CATARACT RUNDOWN

# More Than One Way to Crack a Nucleus

*Cataract surgeons discuss their preferred techniques and when to modify for certain scenarios.*

**LIZ HUNTER**  
SENIOR EDITOR

There are as many types of nuclei a cataract surgeon may encounter as there are techniques to break them. Although some of these techniques are used more often than others, situations do occur when a less-employed technique comes in handy. We asked cataract surgeons about their personal preferences, honed over years of experience, and what makes them favorable compared to others.

### Divide and Conquer

This continues to be the most widely used technique despite the arguments against its efficiency.

Introduced in 1991 by Howard V. Gimbel, MD, this technique involves creating a deep central groove in the nucleus, which is then manually cracked and then fragmented into sections before it's emulsified.<sup>1</sup> According to Dr. Gimbel, this technique makes it possible to use phacoemulsification on patients with small pupils or hypermature and brunescant cataracts who would otherwise not be candidates.

In a 2022 survey conducted by *Review of Ophthalmology*, 46 percent of respondents named divide and conquer as their preferred technique, with many citing its safety and application for multiple types of cataracts.

Another factor that plays into its popularity is that it's usually the first

technique taught to residents.

"I'm at a university and when we're teaching residents how to perform phaco, we'll initially do a four quadrant divide-and-conquer technique," says Nick Mamalis, MD, a professor of ophthalmology at the John Moran Eye Center, University of Utah. "What this allows us to do is make two grooves 90 degrees apart, essentially dividing the nucleus into quadrants, manually separate the pieces, then phaco them. It's a tried-and-true method of doing the nucleus disassembly and it's a safe way of doing it. We start our residents doing this prior to going to the chop techniques."

Cristos Ifantides, MD, MBA, who's in private practice in Cape

Coral, Florida, and an adjunct assistant professor of ophthalmology at the University of Colorado, says he was only taught divide and conquer during his residency. "I was never taught how to chop in residency," he says. "I only learned chop in my fellowship at Wills, but every residency program is different."

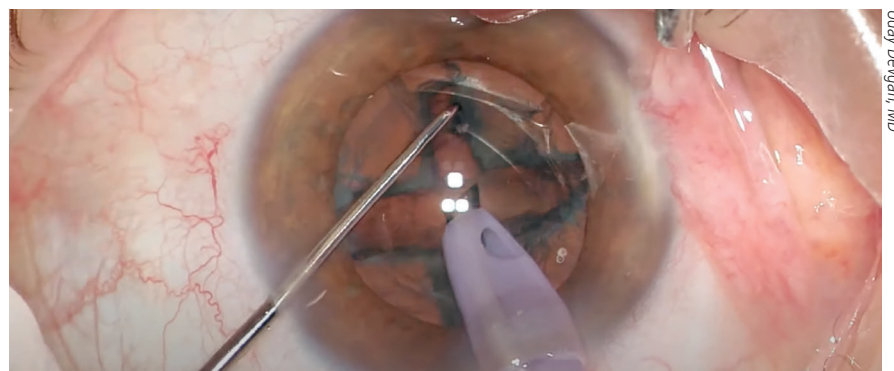Surgeons speculate that their colleagues may continue to employ divide and conquer years after residency purely because of the comfort level, but most advance on to chop techniques.

"Divide and conquer puts a lot of energy into the eye, and it's a slower, inefficient procedure," says Uday Devgan, MD, FACS, who practices in Los Angeles and previously taught at UCLA. "It's also riskier than chop because, when you make the phaco grooves, the tip is 1 mm or less from the posterior capsule. When performing a chop technique, you're never near it."

### Phaco Chop

There are a few variations to the phaco chop, from the "stop-and-chop" to vertical and horizontal chop, and these have a bit more of a learning curve.

"Once a person has more experi-



Uday Devgan, MD

**Divide and conquer is the first technique residents are taught. The nucleus is divided into four quadrants before phacoemulsification. Some surgeons prefer this technique for its safety and usefulness on multiple types of nuclei, while others argue it's too time consuming.**

**This article has no commercial sponsorship.**

**Dr. Chayet** is considered a pioneer in refractive and cataract surgery, and is the medical director of the Codet Vision Institute in Tijuana, Mexico. He is a clinical investigator for RxSight, LensGen and ForSight Vision6.

# vevye™

(cyclosporine ophthalmic solution) 0.1%

# NOW AVAILABLE!

## A Different Cyclosporine

VEVYE® (cyclosporine ophthalmic solution) 0.1% is the first and only water-free cyclosporine dissolved in a semifluorinated alkane (perfluorobutylpentane) approved to treat both the signs and symptoms of dry eye disease.<sup>1-3</sup>

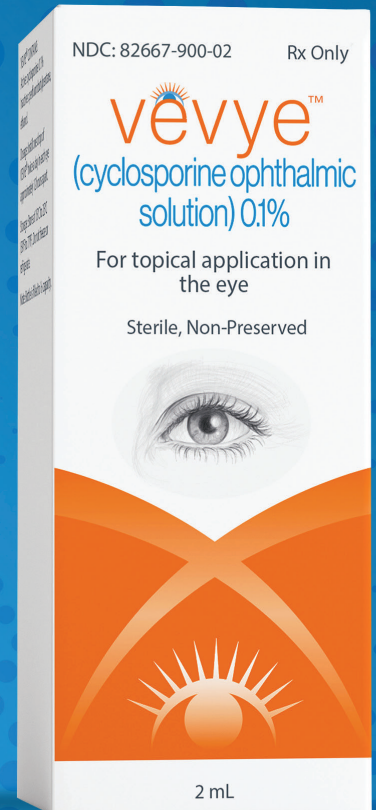
In clinical studies,

- Over 50% of patients had 3 grades of total corneal fluorescein staining improvement at Day 15\*<sup>4</sup>
- 72% of patients showed at least 3 grades of improvement in corneal staining at day 29\*<sup>4</sup>
- 99.8% of patients experienced no or mild instillation site irritation\*<sup>4</sup>
- VEVYE provided sustained improvement over 12 months\*\*<sup>4</sup>

\* A Phase 3, multi-center, randomized, double-masked, vehicle-controlled clinical trial

\*\* An open-label, single-arm, extension study

Scan or visit [vevye.com](http://vevye.com) to learn more or request FREE samples



**INDICATION AND USAGE:** VEVYE (cyclosporine ophthalmic solution) 0.1% is indicated for the treatment of the signs and symptoms of dry eye disease.

### IMPORTANT SAFETY INFORMATION

#### Warnings and Precautions

- **Potential for Eye Injury and Contamination** – To avoid the potential for eye injury and/or contamination, patients should not touch the bottle tip to the eye or other surfaces.
- **Use with Contact Lenses** – VEVYE should not be administered while wearing contact lenses. If contact lenses are worn, they should be removed prior to administration of the solution. Lenses may be reinserted 15 minutes following the administration of VEVYE.

#### Adverse Reactions

In clinical trials with 738 subjects receiving at least 1 dose of VEVYE, the most common adverse reactions were instillation site reactions (8%) and temporary decreases in visual acuity (3%).

You are encouraged to report negative side effects of prescription drugs to the FDA. Visit [www.fda.gov/medwatch](http://www.fda.gov/medwatch), or call 1-800-FDA-1088.

**For additional information about VEVYE, please see Brief Summary on adjacent page and Full Prescribing Information at [vevye.com](http://vevye.com).**

References: 1. Vevye (cyclosporine ophthalmic solution) 0.1% [package insert]. Harrow IP, LLC; 2023. 2. Cequa (cyclosporine ophthalmic solution) .09% [package insert]. Sun Ophthalmics, LLC; 2023. 3. Restasis (cyclosporine ophthalmic emulsion) 0.05% [package insert]. Allergan, LLC; 2023. 4. Data on file.

Vevye and the Vevye logo are trademarks of Novaliq GmbH.

Harrow and the Harrow logo are registered trademarks of Harrow IP, LLC. ©2023 Harrow. All Rights Reserved. VYE-00051 01/24



**HARROW**



# vevye™

(cyclosporine ophthalmic solution) 0.1%

## BRIEF SUMMARY – PLEASE SEE THE VEVYE® PACKAGE INSERT FOR FULL PRESCRIBING INFORMATION

### INDICATIONS AND USAGE:

VEVYE® (cyclosporine ophthalmic solution) 0.1% is indicated for the treatment of the signs and symptoms of dry eye disease.

### DOSAGE AND ADMINISTRATION:

Instill one drop of VEVYE® twice a day in each eye approximately 12 hours apart.

### WARNINGS AND PRECAUTIONS

- **Potential for Eye Injury and Contamination** – To avoid the potential for eye injury and/or contamination, patients should not touch the bottle tip to the eye or other surfaces.
- **Use with Contact Lenses** – VEVYE® should not be administered while wearing contact lenses. If contact lenses are worn, they should be removed prior to administration of the solution. Lenses may be reinserted 15 minutes following the administration of VEVYE®.

### ADVERSE REACTIONS

**Clinical Trial Experience** - Because clinical trials are conducted under widely varying conditions, adverse reaction rates observed in the clinical trials of a drug cannot be directly compared to rates in the clinical trials of another drug and may not reflect the rates observed in practice.

In clinical trials with 738 subjects receiving at least 1 dose of VEVYE®, the most common adverse reactions were instillation site reactions (8%) and temporary decreases in visual acuity (3%).

### USE IN SPECIFIC POPULATIONS

#### PREGNANCY

##### Risk Summary

There are no adequate and well-controlled studies of VEVYE® administration in pregnant women to inform a drug-associated risk. Oral administration of cyclosporine to pregnant rats or rabbits did not produce teratogenicity at clinically relevant doses. VEVYE® doses are approximately 4,700 times lower than recommended oral doses, with blood concentrations being undetectable after topical administration.

##### Data

*Animal Data:* Oral administration of cyclosporine oral solution to pregnant rats or rabbits was teratogenic at maternally toxic doses of 30 mg/kg/day in rats and 100 mg/kg/day in rabbits, as indicated by increased pre- and postnatal mortality, reduced fetal weight and skeletal retardations. These doses (normalized to body weight) were approximately 7,250 and 48,000 times higher than the daily maximum recommended human ophthalmic dose (MRHOD) of 0.67 mcg/kg/day, respectively.

No adverse embryofetal effects were observed in rats or rabbits receiving cyclosporine during organogenesis at oral doses up to 17 mg/kg/day or 30 mg/kg/day, respectively (approximately 4,100 and 14,500 times higher than the MRHOD, respectively).

An oral dose of 45 mg/kg/day cyclosporine (approximately 10,900 times higher than MRHOD) administered to rats from Day 15 of pregnancy until Day 21 postpartum produced maternal toxicity and an increase in postnatal mortality in offspring. No adverse effects in mothers or offspring were observed at oral doses of up to 15 mg/kg/day (3600 times greater than MRHOD).

### LACTATION

#### Risk Summary

Cyclosporine is known to be excreted in human milk following systemic administration but excretion in human milk after topical treatment has not been investigated. VEVYE® doses are approximately 4,700 times lower than recommended oral doses of cyclosporine, with blood concentrations being undetectable after topical administration. However, caution should be exercised when VEVYE® is administered to a nursing woman.

### PEDIATRIC USE

Safety and effectiveness in pediatric patients below the age of 18 years have not been established.

### GERIATRIC USE

No overall difference in safety or effectiveness has been observed between elderly and younger patients.

### NONCLINICAL TOXICOLOGY

#### Carcinogenesis, Mutagenesis, Impairment of Fertility

##### Carcinogenesis

Evaluation of the potential carcinogenicity of cyclosporine was conducted in male and female mice and rats. In a 78-week oral (diet) mouse study, at doses of 1, 4, and 16 mg/kg/day, evidence of a statistically significant trend was found for lymphocytic lymphomas in females, and the incidence of hepatocellular carcinomas in mid-dose males significantly exceeded the control value.

In a 24-month oral (diet) rat study, conducted at 0.5, 2, and 8 mg/kg/day, pancreatic islet cell adenomas significantly exceeded the control rate in the low dose level. The hepatocellular carcinomas and pancreatic islet cell adenomas were not dose related. The low doses in mice and rats were approximately 120 times higher than the maximum recommended human ophthalmic dose (0.67 mcg/kg/day), normalized to body surface area.

##### Mutagenesis

In genetic toxicity tests, cyclosporine has not been found to be mutagenic/genotoxic in the Ames Test, the V79-HGPRT Test, the micronucleus test in mice and Chinese hamsters, the chromosome-aberration tests in Chinese hamster bone-marrow, the mouse dominant lethal assay, and the DNA-repair test in sperm from treated mice. Cyclosporine was positive in an in vitro sister chromatid exchange (SCE) assay using human lymphocytes.

##### Impairment of Fertility

Oral administration of cyclosporine to rats for 12 weeks (male) and 2 weeks (female) prior to mating produced no adverse effects on fertility at doses up to 15 mg/kg/day (approximately 3,600 times higher than the maximum recommended human ophthalmic dose).

### PATIENT COUNSELING INFORMATION

#### Risk of Contamination

Advise patients to wash their hands well before each use. Advise patients not to allow the dropper tip to touch the eye or any other surface, as this may contaminate the solution.

#### Contact Lens Wear

Advise patients not to touch the dropper tip to any surface to avoid contaminating the contents.



**HARROW®**

Distributed by  
Harrow Eye, LLC  
102 Woodmont Blvd. Suite 610  
Nashville, TN 37205  
USA  
©2023

ence and is more comfortable doing phacoemulsification, more comfortable using two hands rather than one hand, then they can go to a chop technique,” says Dr. Mamalis.

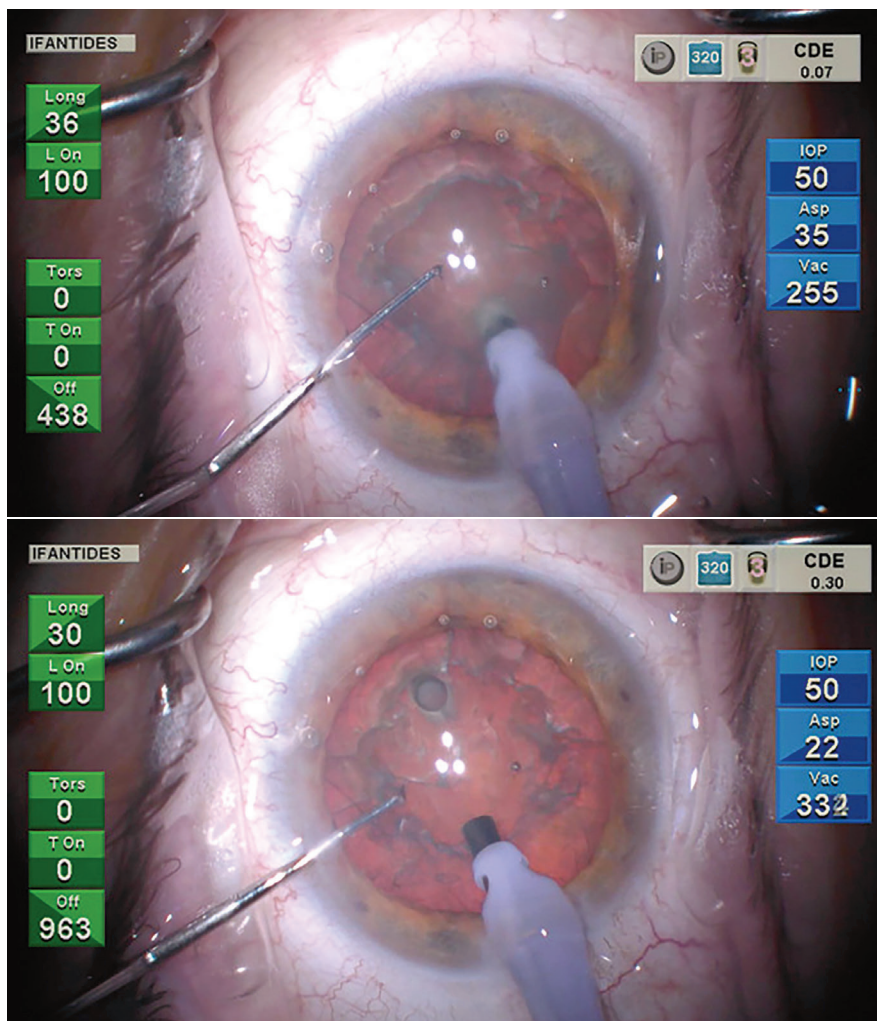
“I’ve taught surgeons in other parts of the world and chopping is a difficult skill to teach and it can be very difficult to learn, even with a good teacher and talented learner,” says Dr. Ifantides. “You need multiple cases to learn it and dozens of cases to get good at it. It’s more technical and can be frustrating.”

Stop and chop is a good bridge between divide and conquer and phaco chop, says Dr. Devgan. Described in 1994 by Paul Koch, MD,<sup>2</sup> this requires creating a trench in the nucleus to create two halves, similar to the beginning of divide and conquer, but then you switch to a phaco chop to crack the nucleus. “Instead of breaking it into four quadrants, we’ll break it down the middle and make two halves and then each half can be brought up to chop and it’s easier to do,” Dr. Devgan continues.

For those who are looking to advance their skills and increase their volume of cataract surgeries, the horizontal (or Nagahara) and vertical phaco chops are arguably the most efficient techniques. Kunihiro Nagahara, MD, presented the horizontal chop technique in 1995, which brings together the tips of the chopper and the phaco handpiece within the horizontal plane. The phaco tip holds the nucleus in place with the vacuum level building up to keep it secure, explains Dr. Devgan. “You then have a small window of about one to two seconds to perform the chop, otherwise the vacuum slowly breaks down the nucleus and you lose the grip,” he says.

Vertical chop is another option, this time performed in the vertical plane. Both Dr. Mamalis and Dr. Ifantides say vertical chop is their most common technique used.

“I do like the stop-and-chop technique, using a vertical chop,” says Dr. Mamalis. “I make a groove that’s no more than 1.5 phaco tips in diameter



**For very dense cataracts, Cristos Ifantides, MD, describes this “Rotary Chop” technique in which pilot holes are created by the phaco tip around the periphery of the nucleus, which helps penetrate deeper into the posterior plate to propagate a crack.**

and about 80-percent depth of the nucleus. That gives me enough room that I can go in and do the vertical chop. Once I’ve made the groove, I crack the nucleus in half using the chopper through a sideport incision and then the phacoemulsification handpiece through the main incision. Once it’s cracked, I rotate the nucleus 90 degrees.

“Depending on the hardness of the nucleus, I’ll either do one or two chops to break up the nucleus either into quarters or into thirds just depending on how firm the nucleus is,” he continues. “If the nucleus is very firm, we want to really try to chop it into smaller pieces, so we use less phacoemulsification energy. When the nucleus is just

moderately firm, we could even just chop it in half with a single chop on each hemi-section and then go ahead and use phaco to emulsify the piece of nucleus and take it out.”

Dr. Ifantides says he opts for this technique because it uses the least amount of phaco energy and can be employed in most cases. “It ends up being quite fast,” he says. “Chopping really depends on the chopper—the second instrument. For vertical chopping you want to be able to use a sharper second instrument that can impale the nucleus. With the phaco you burrow in and impale the nucleus, hold it in place with high vacuum and then the chopper gets buried into the nucleus as well and then you pull the

two together. The vertical component is really the puncturing into the lens with the chopper and then bringing the two instruments together, propagating a crack.”

Dr. Mamalis says he likes the control of a vertical chop. “You can do it on most densities of nuclei, unless they’re severely dense, which is—at least nowadays in the United States—not that common,” he says. “But for most levels of nuclei density, I find that I get good control with a vertical chop. I like to use the stop and chop because I like to make a thin groove in the middle of the nucleus and then crack it in half, and then do the vertical chop. Many surgeons don’t do the groove—they just go right in and chop, but I like the little bit of room that it gives me when I make a small groove and crack the nucleus. Then it allows me to chop the hemi-sections more easily.”

For those who are in the process of learning the vertical chop, Dr. Mamalis says there are some pearls to keep in mind. “You want to make sure that your phacoemulsification tip has a

good purchase on the piece of nucleus that’s being chopped, meaning that you have a high enough vacuum that the piece is fixated to the phaco tip to go ahead and to make the chop,” he says. “What we find when we’re teaching residents early is they’re just a little bit shy about keeping that vacuum power up high to keep that piece of nucleus held tightly so that you can make a chop. So, oftentimes, they’ll begin to chop and then the piece of nucleus falls off the phaco tip and they can’t complete the chop. Whenever you’re doing any kind of a vertical chop technique, it’s very important that you have the phaco tip adequately buried into that piece of nucleus and enough vacuum that it doesn’t let go of the nucleus as you’re doing the chop. Often, there’ll be a setting that you can set, depending on your phaco machine, either a quadrant setting or chop setting, and that has a much higher vacuum than does the setting that you use when you’re grooving the nucleus initially.”

One of the most important pearls of phacoemulsification is being aware not

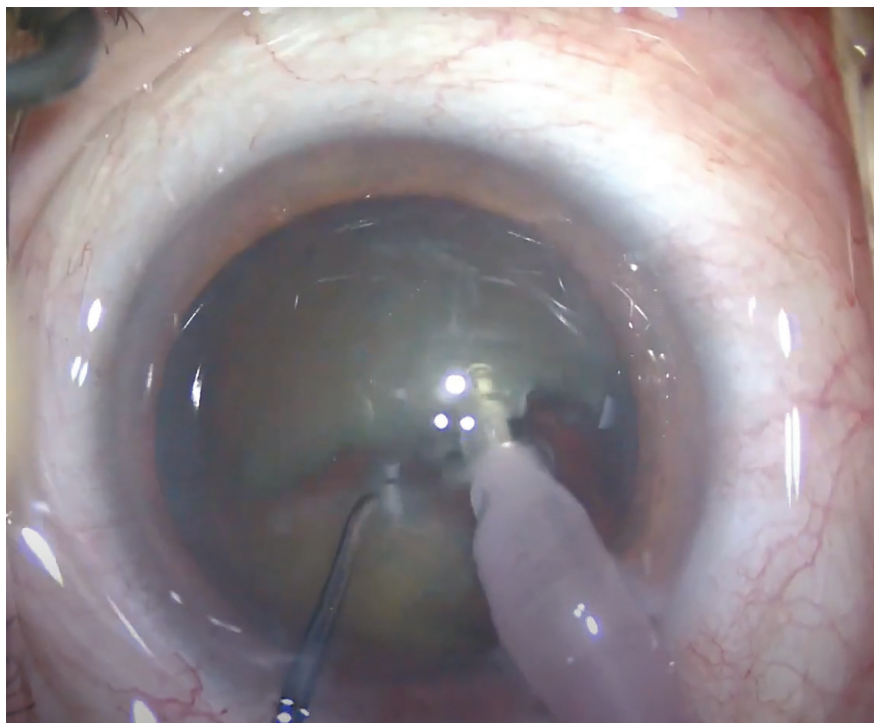
to disturb either the anterior capsule or going so deep that you risk rupturing the posterior capsule. “You always want to be aware in three dimensions of how deep you’re going with the phaco, where your chopper is, and sometimes in a darker nucleus or denser nucleus—again looking at residents when we’re training them—make sure to put that chopper in so it doesn’t disturb the anterior capsule,” Dr. Mamalis advises. “You don’t want to accidentally cause a tear to form in the anterior capsule with your chopper.”

### When to Consider Other Techniques

One technique doesn’t necessarily fit all, so it’s important to stay up to date on other methods for breaking the nucleus.

- **Soft nucleus.** Dr. Ifantides says vertical chop isn’t ideal if the cataract is soft and young. “In this case I’ll either prolapse the lens into the anterior chamber, or I’ll do a partial divide and conquer where I’ll make a three-quarters length groove rather than a full groove and crack the distal portion of the cataract in half, leaving it attached sub-incisionally, and then switch to quadrant removal and aspirate the left distal side,” he says. “Because it’s still connected, as you vacuum it and eat up that hemi-nucleus the other hemi-nucleus rotates around and comes with it. It’s a pretty quick way to do that. I personally don’t vertical chop soft cataracts with high aspiration/vacuum.”

In soft cataracts, Dr. Mamalis says he uses a pre-chopping instrument. “In a softer nucleus you go in with the pre-chopper and you bury it into the nucleus and then spread the blades of the pre-chopper and that will actually divide the nucleus in half and then you can rotate it 90 degrees and again, bury the pre-chopper into the nucleus and then spread it apart and do the cracks with the pre-chopper,” he says. “So in a softer nucleus where it’s very difficult to do a chopping technique itself, I use the pre-chopper to divide it into four quadrants and then just do a four-quadrant technique.”



Uday Deygan, MD

**Chop techniques weren’t always included in residency programs and there’s a learning curve to the variations, say surgeons. Some favor the vertical chop (shown here) for its speed and reduced use of phaco energy.**



An efficiency tool that propels your practice into the future.



## The Olleyes VisuALL

We bring you unparalleled office efficiency, cutting edge testing technology, and the new era of patient comfort, in just one device.

### 3 essential elements that place you at the cutting edge.

#### Dynamic Matrix



Our proprietary eye tracking algorithm can reduce fixation losses to zero, automatically.

#### Scientific Validation



Reliable, accurate results validated by esteemed scientific institutions.

#### AI Virtual Assistant



Annie can increase office efficiency, monitor patients, speak over 35+ languages and so much more.

### One product. One complete diagnostic universe.



Visual Acuity



Visual Field



Extraocular Motility



Color Vision



Pupillometry



Contrast Sensitivity



Equip your practice with a game-changing technology today.

Scan code to know more or visit [www.olleyes.com](http://www.olleyes.com)

• **Hard/dense cataracts.** For very hard nuclei, that's a different matter, says Dr. Mamalis. "If you have an extremely hard nucleus, it's sometimes very difficult to break that into smaller pieces that you can then emulsify and so those are the patients where we can sometimes use the miLoop, which can actually help to break a very hard nucleus in either semi-halves or quadrants," he says.

Another technique is the small-incision extracapsular extraction, which is commonly used in the developing world or in places without access to phaco. "The advantage of this technique is you do a scleral corneal tunnel with a frown shape to it—think of it as an upside down U—then you use a blade to go half thickness through the sclera until you enter the cornea and then enter the anterior chamber. You then can make a wider internal opening than there is an external opening and that allows you to remove the very hard nucleus whole without having to disassemble it," continues Dr. Mamalis.

Dr. Ifantides described a technique called the rotary chop for dense cataracts.<sup>3</sup> In this technique, the surgeon makes a hole in the cataract, spins it around and puts the chopper in that hole, then makes a second hole with their phaco needle again, like in a regular vertical chop. "That helps get deep into the posterior plate and propagate a crack," he says. "We published that a couple of years ago. After publishing it, I found another surgeon who has also been doing that technique, James Katz, MD. He presented that about 10 years ago at a meeting I didn't happen to attend, so I always want to give credit where credit's due. That's another way for dense cataracts to be segmented."

He will also occasionally do a horizontal chop. "I'm actually part of a clinical trial where I have a chopper with a light at the end of it and you can use that for horizontal chopping," Dr. Ifantides says. "It's called the iChopper (Oculight). It's helpful for horizontal chop and all types of nucleo-fractis if the visibility isn't that

great."

• **Loose zonules.** Dr. Mamalis says vertical chop is applicable in patients with pseudoexfoliation. "In cases where there might be some issues with the capsular fragility or with zonule adherence, for example, patients with exfoliation syndrome, I do find that stop and chop with a vertical chopper is actually a very zonular-friendly technique," he says. "We'll often use that even in patients with exfoliation syndrome or with some questions about the integrity of the zonules all the way around."

• **Phaco flip/tilt.** This technique has fallen out of favor somewhat, but comes down to personal preference. "It could be useful for a brunescient cataract," says Dr. Devgan.

There are a few too many risks with this technique, says Dr. Ifantides. "Some people still use it for soft cataracts and for loose zonules, but others will do it every single time where they'll prolapse the lens on purpose, at least partially out of the bag, trying to keep it away from the posterior capsule," he says. "I don't love this technique because you end up putting strain on the anterior capsule, and in refractive-cataract surgery, we prefer to have an anterior capsule that overlaps the optic of the premium IOL. In order to do that you need a 5.5-mm or less capsulotomy. It's hard to prolapse a more mature cataract from that and to be working with the lens partially prolapsed can put a lot of strain on the anterior capsule and cause an anterior capsular rent. I think people who make bigger capsulotomies like this technique a bit more unless they prolapse it all the way out, basically putting the cataract in the anterior chamber and eating it there. The con being you're closer to their cornea and the lens can hit the cornea."

## Continuing Education

Dr. Devgan says it's important for all surgeons, even those in mid-career, to keep learning and that includes phaco chop if they haven't mastered

it already. "It's not that difficult and it will be far more effective," he says.

Dr. Ifantides says not to get discouraged when attempting new techniques. "Surgeons will give up on something before they may have adequate performance on it," he says. "We fail to compare certain techniques. To graduate residency you need 80-plus cataract surgeries that are pretty much all done with phaco. If you gave somebody a phaco machine and asked them to try it for the first time and give you feedback, I think most people would say it's not an ideal device. It takes training and persistence to master. We should have the same mentality of saying, 'If it takes 80-plus times to get safe with phaco, and way more to get really good with phaco, maybe we should be giving other devices and techniques a chance beyond just one or five or 10 tries.'"

It's important not to become complacent, either, Dr. Ifantides continues. "If you're doing the same style, type, steps of surgery as you were five years ago, you're not reading enough or trying things out enough because things continue to improve," he says. "Being plastic, I think, is really important, and having that desire to see how other people operate is important. Any chance that people get to spend time in other surgeons' ORs is very valuable. No matter how good you think you are, there's always something to learn from another surgeon and it's really eye opening when you do that. You'll always pick up skills if you're paying attention." ◀

1. Gimbel HV. Divide and conquer nucleofractis phacoemulsification: Development and variations. *J Cataract Refract Surg* 1991;17:3:281-91.

2. Koch PS, Katzen LE. Stop and chop phacoemulsification. *J Cataract Refract Surg* 1994;20:5:566-70.

3. Ifantides C, Sieck EG, Christopher KL. Rotary chop: A new technique for teaching chop and tackling mature cataracts. *Ophthalmol Ther* 2020;9:2:321-327.

## DISCLOSURES

**Dr. Devgan** is the owner of CataractCoach.com. **Dr. Ifantides** discloses relationships with Alcon, Bausch + Lomb, Johnson & Johnson Vision and Centricity. **Dr. Mamalis** has no related disclosures.

# A VIRTUAL REALITY CHECK: WHERE VR PERIMETRY FITS

Experts discuss the potential of VR visual fields and cut through the hype.

**CHRISTINE YUE LEONARD**  
SENIOR ASSOCIATE EDITOR

**W**hat was once science fiction is now literal virtual reality. Head-mounted VR perimeters are capable of conducting visual field tests and many other vision tests with minimal oversight from humans while producing promising results. Experts say VR visual fields have a bright future in screening, as an adjunctive instrument in the clinic and in the fast-approaching world of remote care. However, the technology still has a long way to go before it's ready to substitute for standard automated perimetry.

We spoke with glaucoma specialists about the VR features they're

excited about, and what's needed for this technology to take off in the clinic.

## Virtual Reality Highlights

There's a lot to look forward to in this new realm of computer-generated care, from faster thresholding to increased portability and ease of use. Here's what glaucoma specialists have to say about it:

- **Eye-tracking technology.** One of the key features of many VR visual field devices is a type of technology that tracks the eyes' movements with high precision (e.g., by one degree) and alters the test accordingly. "When you ask the patient to look at a central target, a machine [with eye-tracking technology]

moves the whole visual field to expose the specific part of the retina that's supposed to receive the light," explains Reza M. Razeghinejad, MD, a glaucoma specialist at Wills Eye Hospital in Philadelphia. "If the eye movement is more than, say, 15 degrees off-center, the machine can send an alert to the patient, letting them know they need to refocus at the central target. We don't have the ability to do that with the standard machine. Instead, the standard perimeter requires that a technician be in the room during the test to watch for fixation losses and notify the patient. How accurate is your technician, and for how long?"

- **Foveal reflex-friendly.** On a similar note, some VR perimeters

## Virtual Reality Through Time<sup>1</sup>

- **1929:** The Link Trainer commercial flight simulator by Edward Link, an electromechanical device mimicking movement during flight (e.g., turbulence), used later to train U.S. pilots in World War II.
- **1935:** *Pygmalion's Spectacles* by Stanley G. Weinbaum, an early fictional account of virtual reality goggles.
- **1939:** View-Master stereoscope for virtual tourism.

- **1950s:** The arcade-style theater cabinet Sensorama by cinematographer Morton Heilig.
- **1960:** The Telesphere Mask by Morton Heilig, the first head-mounted VR display.
- **1961:** Headsight, the first head-mounted VR display with motion tracking and an early version of our modern head-mounted VR displays.

This article has no commercial sponsorship.

**Dr. Razeghinejad** has conducted research for Olleyes. **Dr. Tsai** is a consultant for AI Nexus Healthcare, EYENOVIA, ReNet X Bio and Smartlens. **Dr. Grajewski** is the medical director of Virtual Vision Health and has a financial interest in the company. **Dr. Ou** has no related financial interests.



MANY  
MANIFESTATIONS  
OF THYROID EYE  
DISEASE (TED)

# ONE ROOT CAUSE<sup>1-3</sup>







## TEPEZZA is indicated for the treatment of Thyroid Eye Disease (TED) *regardless of disease activity or duration*<sup>4</sup>

Designed to **target and block IGF-1R**, a key driver of TED pathophysiology

### TEPEZZA has shown to:



Decrease proptosis<sup>4,5,7</sup>



Improve diplopia<sup>4-7</sup>



Reduce orbital pain, redness, and swelling<sup>5,7</sup>



Improve functional vision and patient appearance<sup>5,7\*</sup>

\*Patient reported based on GO-QOL scale

...in two 24-week, randomized, double-masked, placebo controlled clinical studies of 171 patients with TED.<sup>4</sup>



See how TEPEZZA can help reduce the burden of TED

Teprotumumab-trbw's mechanism of action in patients with TED has not been fully characterized. Teprotumumab-trbw binds to IGF-1R and blocks its activation and signaling.

IGF-1R, insulin-like growth factor-1 receptor.

**References:** 1. Patel A, Yang H, Douglas RS. A new era in the treatment of thyroid eye disease. *Am J Ophthalmol*. 2019;208:281-288. 2. Chen H, Mester T, Raychaudhuri N, et al. Teprotumumab, an IGF-1R blocking monoclonal antibody inhibits TSH and IGF-1 action in fibrocytes. *J Clin Endocrinol Metab*. 2014;99(9):E1635-E1640. 3. Tsui S, Naik V, Hoa N, et al. Evidence for an association between thyroid-stimulating hormone and insulin-like growth factor 1 receptors: a tale of two antigens implicated in Graves' disease. *J Immunol*. 2008;181(6):4397-4405. 4. TEPEZZA (teprotumumab-trbw) [prescribing information] Horizon. 5. Douglas RS, Kahaly GJ, Patel A, et al. Teprotumumab for the treatment of active thyroid eye disease. *N Engl J Med*. 2020;382(4):341-352. 6. Douglas RS. Teprotumumab, an insulin-like growth factor-1 receptor antagonist antibody, in the treatment of active thyroid eye disease: a focus on proptosis. *Eye (Lond)*. 2019;33(2):183-190. 7. Smith TJ, Kahaly GJ, Ezra DG, et al. Teprotumumab for thyroid-associated ophthalmopathy. *N Engl J Med*. 2017;376(18):1748-1761.



TEPEZZA and the HORIZON logo are trademarks owned by or licensed to Horizon. © 2023 Horizon Therapeutics plc P-TEP-US-00538-3-A\_09/23

### INDICATION

TEPEZZA is indicated for the treatment of Thyroid Eye Disease regardless of Thyroid Eye Disease activity or duration.

### IMPORTANT SAFETY INFORMATION

#### WARNINGS AND PRECAUTIONS

**Infusion Reactions:** TEPEZZA may cause infusion reactions. Infusion reactions have been reported in approximately 4% of patients treated with TEPEZZA. Reported infusion reactions have usually been mild or moderate in severity. Signs and symptoms may include transient increases in blood pressure, feeling hot, tachycardia, dyspnea, headache, and muscular pain. Infusion reactions may occur during an infusion or within 1.5 hours after an infusion. In patients who experience an infusion reaction, consideration should be given to premedicating with an antihistamine, antipyretic, or corticosteroid and/or administering all subsequent infusions at a slower infusion rate.

**Preexisting Inflammatory Bowel Disease:** TEPEZZA may cause an exacerbation of preexisting inflammatory bowel disease (IBD). Monitor patients with IBD for flare of disease. If IBD exacerbation is suspected, consider discontinuation of TEPEZZA.

**Hyperglycemia:** Increased blood glucose or hyperglycemia may occur in patients treated with TEPEZZA. In clinical trials, 10% of patients (two-thirds of whom had preexisting diabetes or impaired glucose tolerance) experienced hyperglycemia. Hyperglycemic events should be controlled with medications for glycemic control, if necessary. Assess patients for elevated blood glucose and symptoms of hyperglycemia prior to infusion and continue to monitor while on treatment with TEPEZZA. Ensure patients with hyperglycemia or preexisting diabetes are under appropriate glycemic control before and while receiving TEPEZZA.

**Hearing Impairment Including Hearing Loss:** TEPEZZA may cause severe hearing impairment including hearing loss, which in some cases may be permanent. Assess patients' hearing before, during, and after treatment with TEPEZZA and consider the benefit-risk of treatment with patients.

#### ADVERSE REACTIONS

The most common adverse reactions (incidence  $\geq 5\%$  and greater than placebo) are muscle spasm, nausea, alopecia, diarrhea, fatigue, hyperglycemia, hearing impairment, dysgeusia, headache, dry skin, weight decreased, nail disorders, and menstrual disorders.

Please see Full Prescribing Information or visit [TEPEZZAhcp.com](https://www.tepezza.com) for more information.



For injection, for intravenous use

**Brief Summary - Please see the TEPEZZA package insert for full prescribing information.**

**INDICATIONS AND USAGE**

TEPEZZA is indicated for the treatment of Thyroid Eye Disease regardless of Thyroid Eye Disease activity or duration.

**WARNINGS AND PRECAUTIONS**

**Infusion Reactions**

TEPEZZA may cause infusion reactions. Infusion reactions have been reported in approximately 4% of patients treated with TEPEZZA. Signs and symptoms of infusion-related reactions include transient increases in blood pressure, feeling hot, tachycardia, dyspnea, headache and muscular pain. Infusion reactions may occur during any of the infusions or within 1.5 hours after an infusion. Reported infusion reactions are usually mild or moderate in severity and can usually be successfully managed with corticosteroids and antihistamines. In patients who experience an infusion reaction, consideration should be given to pre-medicating with an antihistamine, antipyretic, corticosteroid and/or administering all subsequent infusions at a slower infusion rate.

**Exacerbation of Preexisting Inflammatory Bowel Disease:**

TEPEZZA may cause an exacerbation of preexisting inflammatory bowel disease (IBD). Monitor patients with IBD for flare of disease. If IBD exacerbation is suspected, consider discontinuation of TEPEZZA.

**Hyperglycemia:**

Hyperglycemia or increased blood glucose may occur in patients treated with TEPEZZA. In clinical trials, 10% of patients (two-thirds of whom had preexisting diabetes or impaired glucose tolerance) experienced hyperglycemia. Hyperglycemic events should be controlled with medications for glycemic control, if necessary.

Assess patients for elevated blood glucose and symptoms of hyperglycemia prior to infusion and continue to monitor while on treatment with TEPEZZA. Ensure patients with hyperglycemia or preexisting diabetes are under appropriate glycemic control before and while receiving TEPEZZA.

**Hearing Impairment Including Hearing Loss:**

TEPEZZA may cause severe hearing impairment including hearing loss, which in some cases may be permanent. Assess patients' hearing before, during, and after treatment with TEPEZZA and consider the benefit-risk of treatment with patients.

**ADVERSE REACTIONS**

The following clinically significant adverse reactions are described elsewhere in the labeling:

- Infusion Reactions [see *Warnings and Precautions*]
- Exacerbation of Preexisting Inflammatory Bowel Disease [see *Warnings and Precautions*]
- Hyperglycemia [see *Warnings and Precautions*]
- Hearing Impairment Including Hearing Loss [see *Warnings and Precautions*]

**Clinical Trials Experience**

Because clinical trials are conducted under widely varying conditions, adverse reaction rates observed in the clinical trials of a drug cannot be directly compared to rates in the clinical trials of another drug and may not reflect the rates observed in practice.

The safety of TEPEZZA was evaluated in two randomized, double-masked, placebo-controlled clinical studies (Study 1 [NCT:01868997] and Study 2 [NCT:03298867]) consisting of 170 patients with Thyroid Eye Disease (84 received TEPEZZA and 86 received placebo). Patients were treated with TEPEZZA (10 mg/kg for first infusion and 20 mg/kg for the remaining 7 infusions) or placebo given as an intravenous infusion every 3 weeks for a total of 8 infusions. The majority of patients completed 8 infusions (89% of TEPEZZA patients and 93% of placebo patients).

The most common adverse reactions (≥5%) that occurred at greater incidence in the TEPEZZA group than in the control group during the treatment period of Studies 1 and 2 are summarized in Table 1. In addition, menstrual disorders (amenorrhea, metrorrhagia, dysmenorrhea) were reported in approximately 23% (5 of 22 patients) of menstruating women treated with TEPEZZA compared to 4% (1 of 25 patients) treated with placebo in the clinical trials.

**Table 1. Adverse Reactions Occurring in 5% or More of Patients Treated with TEPEZZA and Greater Incidence than Placebo**

Adverse Reactions	TEPEZZA N=84, N (%)	Placebo N=84, N (%)
Muscle spasms	21 (25%)	6 (7%)
Nausea	14 (17%)	8 (9%)
Alopecia	11 (13%)	7 (8%)
Diarrhea	10 (12%)	7 (8%)
Fatigue*	10 (12%)	6 (7%)
Hyperglycemia*	8 (10%)	1 (1%)
Hearing impairment†	8 (10%)	0
Dysgeusia	7 (8%)	0
Headache	7 (8%)	6 (7%)
Dry skin	7 (8%)	0
Weight decreased	5 (6%)	0
Nail disorder‡	4 (5%)	0

a - Fatigue includes asthenia

b - Hyperglycemia includes blood glucose increase

c - Hearing impairment including hearing loss (deafness, including sensorineural deafness, eustachian tube dysfunction, hyperacusis, hypoacusis, autophony and tinnitus)

d - Nail disorder (includes nail discoloration, nail disorder and onychoclasia)

**Immunogenicity**

As with all therapeutic proteins, there is potential for immunogenicity. The detection of antibody formation is highly dependent on the sensitivity and specificity of the assay.

In a placebo-controlled study with TEPEZZA, 1 of 42 patients treated with placebo had detectable levels of antidrug antibodies in serum. In the same study, none of the 41 patients treated with TEPEZZA had detectable levels of antidrug antibodies in serum.

**Postmarketing Experience**

The following adverse reactions have been identified during postapproval use of TEPEZZA. Because these reactions are reported voluntarily from a population of uncertain size, it is not always possible to reliably estimate their frequency or establish a causal relationship to drug exposure.

*Metabolism and Nutrition Disorders:* diabetic ketoacidosis, hyperosmolar hyperglycemic state (HHS).

*Otologic:* severe hearing impairment including hearing loss, which in some cases may be permanent.

**USE IN SPECIFIC POPULATIONS**

**Pregnancy**

Risk Summary

Based on findings in animals and its mechanism of action inhibiting insulin-like growth factor 1 receptor (IGF-1R), TEPEZZA may cause fetal harm when administered to a pregnant woman. Adequate and well-controlled studies with TEPEZZA have not been conducted in pregnant women. There are insufficient data with TEPEZZA use in pregnant women to inform any drug associated risks for adverse developmental outcomes. In utero teprotumumab exposure in cynomolgus monkeys dosed once weekly with teprotumumab throughout pregnancy resulted in external and skeletal abnormalities. Teprotumumab exposure may lead to an increase in fetal loss [see *Data*]. Therefore, TEPEZZA should not be used in pregnancy, and appropriate forms of contraception should be implemented prior to initiation, during treatment and for 6 months following the last dose of TEPEZZA. If the patient becomes pregnant during treatment, TEPEZZA should be discontinued and the patient advised of the potential risk to the fetus.

The background rate of major birth defects and miscarriage is unknown for the indicated population. In the U.S. general population, the estimated background risks of major birth defects and miscarriage in clinically recognized pregnancies are 2-4% and 15-20%, respectively.

Data

*Animal Data*

In an abridged pilot embryofetal development study, seven pregnant cynomolgus monkeys were dosed intravenously at one dose level of teprotumumab, 75 mg/kg (2.8-fold the maximum recommended human dose [MRHD] based on AUC) once weekly from gestation day 20 through the end of gestation. The incidence of abortion was higher for the teprotumumab treated group compared to the control group. Teprotumumab caused decreased fetal growth during pregnancy, decreased fetal size and weight at caesarean section, decreased placental weight and size, and decreased amniotic fluid volume. Multiple external and skeletal abnormalities were observed in each exposed fetus, including: misshapen cranium, closely set

eyes, micrognathia, pointing and narrowing of the nose, and ossification abnormalities of skull bones, sternbrae, carpals, tarsals and teeth. The test dose, 75 mg/kg of teprotumumab, was the maternal no observed adverse effect level (NOAEL).

Based on mechanism of action inhibiting IGF-1R, postnatal exposure to teprotumumab may cause harm.

**Lactation**

Risk Summary

There is no information regarding the presence of TEPEZZA in human milk, the effects on the breast-fed infant or the effects on milk production.

**Females and Males of Reproductive Potential**

Contraception

*Females*

Based on its mechanism of action inhibiting IGF-1R, TEPEZZA may cause fetal harm when administered to a pregnant woman [see *Use in Specific Populations*]. Advise females of reproductive potential to use effective contraception prior to initiation, during treatment with TEPEZZA and for 6 months after the last dose of TEPEZZA.

**Pediatric Use**

Safety and effectiveness have not been established in pediatric patients.

**Geriatric Use**

Of the 171 patients in the two randomized trials, 15% were 65 years of age or older; the number of patients 65 years or older was similar between treatment groups. No overall differences in efficacy or safety were observed between patients 65 years or older and younger patients (less than 65 years of age).

**OVERDOSAGE**

No information is available for patients who have received an overdose.

**PATIENT COUNSELING INFORMATION**

Embryo-Fetal Toxicity

- Advise females of reproductive potential that TEPEZZA can cause harm to a fetus and to inform their healthcare provider of a known or suspected pregnancy.
- Educate and counsel females of reproductive potential about the need to use effective contraception prior to initiation, during treatment with TEPEZZA and for 6 months after the last dose of TEPEZZA.

Infusion-related reactions

- Advise patients that TEPEZZA may cause infusion reactions that can occur at any time. Instruct patients to recognize the signs and symptoms of infusion reaction and to contact their healthcare provider immediately for signs or symptoms of potential infusion-related reactions.

Exacerbation of Preexisting Inflammatory Bowel Disease

- Advise patients on the risk of inflammatory bowel disease (IBD) and to seek medical advice immediately if they experience diarrhea, with or without blood or rectal bleeding, associated with abdominal pain or cramping/colic, urgency, tenesmus or incontinence.

Hyperglycemia

- Advise patients on the risk of hyperglycemia and, if diabetic, discuss with the healthcare provider to adjust glycemic control medications as appropriate. Encourage compliance with glycemic control.

Hearing Impairment Including Hearing Loss

- Advise patients that TEPEZZA may cause severe hearing impairment including hearing loss, which in some cases may be permanent. Instruct patients to contact their healthcare provider if they experience any signs or symptoms of hearing impairment or any changes in hearing.

Manufactured by:

Horizon Therapeutics Ireland DAC  
Dublin, Ireland  
U.S. License No. 2022

Distributed by:

Horizon Therapeutics USA, Inc.  
Deerfield, IL 60015  
TEPEZZA and the HORIZON logo are trademarks owned by or licensed to Horizon.

© 2023 Horizon Therapeutics plc L-TEP-US-00036 07/23



don't require fixation on a central target at all. Yvonne Ou, MD, an associate professor of ophthalmology who's used the Vivid Vision Perimeter (Vivid Vision) in NIH-funded research at the University of California, San Francisco, says this device employs a testing strategy in which patients are asked to move their head or pointer, depending on what they're using, toward the fixation, stimulus or fixation task, and then perform the stimulus task. "Basically, every time the stimulus is presented," she says, "the patient is looking at the stimulus [as opposed to only fixating on a central target], which I think makes the test easier to understand and perform for patients because they don't need to suppress their desire to look at the stimulus."

• **Patient comfort.** Those familiar with VR perimeters seem to agree that patients find this approach more comfortable than sitting at the traditional standard automated perimeter. Dr. Razeghinejad, who's

used the VisuALL (Olleyes) in company-funded studies at Wills, says that with these headsets patients can sit in any position or take the test in an exam chair, waiting room chair or wheelchair.

“Many of our glaucoma patients have comorbidities. They may have back pain or neck pain or other issues that make it difficult to sit at the [standard] machine... Virtual perimetry helps a lot with these patients.”

— Reza Razeghinejad, MD

“Many of our glaucoma patients have other comorbidities,” he says. “They may have back pain or neck pain or other issues that make it difficult to sit at the [standard] ma-

chine. Positioning can be a problem, because the patient's forehead must go exactly against the bar and the chin in the chin cup. If the head is tilted, the results could differ from that of normal positioning.

“Virtual perimetry helps a lot with these patients,” he continues. “I've tried these devices for those who aren't able to produce a reliable result with the standard machine. Some of my patients did better with these devices, which is a huge help for managing them.”

Alana L. Grajewski, MD, a glaucoma specialist in Miami and the medical director of Virtual Vision Health, maker of the Virtual Vision perimeter, points out that these devices are particularly good for testing young children. “It's very difficult to patch children, but these devices don't require patching. Patients can't tell which eye they're looking out of. So, it's quite easy in that regard.”

• **Testing those with advanced glaucoma.** “Another group that

### Virtual Reality Visual Field Devices

Here are some of the currently available VR perimeters on the market:

• **VisuALL (Olleyes).** Olleyes says its VisuALL perimeters provide comfortable, comprehensive testing while the multilingual AI assistant monitors patients to promote clinician multitasking. According to the company, the devices are disinfectable, suitable for multiple age groups and positioning needs, feature a 4K display and are compact and portable. The perimeters are part of a three-pronged virtual reality platform (VRP) suite which also consists of a web-based application and a HIPAA-compliant cloud for provider-patient interaction. VisuALL ETS and S Models are available. The new VisuALL VRP Choice package includes a headset and a suite of the company's customizable testing options such as AVA-fast 24-2 and 30-2, pediatric protocols, supra threshold testing and more. To learn more, visit [olleyes.com](http://olleyes.com).

• **Vivid Vision Perimeter (Vivid Vision).** Vivid Vision Perimetry or VVP head-mounted device includes a variety of testing protocols such as 24-2, 10-2 and 30-2-M, along with the Ladybug protocols. Clinicians can also create custom visual field tests using their own csv. The company says that the VVP prompts natural fixation and also allows patients to guess as often they'd like without biasing their results thanks to the device's advanced psychological approach. The device is suitable for office and home-based use for more frequent monitoring. To learn more, visit [perimetry.seevidly.com](http://perimetry.seevidly.com).

• **Virtual Vision (Virtual Vision Health).** Virtual Vision Health's Virtual Eye device features 256-bit encryption, printable and EHR-compatible examination records and cloud-based software for reviewing or conducting tests remotely. It comes with audio instruction to replace technician monitoring and is easily sanitized, according to the company. The company also says the Virtual Eye device's testing modalities, accuracy and repeatability are comparable to standard automated perimetry. Test patterns include 5-2, 10-2, 24-2, 24-2C and 30-2; full field 120; superior 64 and 36 (ptosis); Esterman; and color sensitivity; along with thresholding strategies and stimulus sizes III, V (I-VI). The Virtual Eye's visual field reports include progression analysis, raw threshold values, glaucoma hemifield test, mean deviation, pattern standard deviation, visual field index and reliability indices. To learn more, visit [virtualvision.health](http://virtualvision.health).

• **Easyfield VR (Oculus).** Easyfield VR is a mobile visual field analyzer and vision tester headset. Oculus says that in addition to improving practice flow and reducing technician time, this device doesn't rely on an internet connection, uses continuous eye tracking, includes English and Spanish audio support, integrates with all Oculus diagnostic devices and allows patients to test quickly and comfortably. Tests include 45-second visual field screening; under three-minute thresholds 10-2, 24-2, 30-2; progression analysis with a familiar printout; ptosis and Esterman visual fields; as well as testing for color vision, stereoacuity and contrast sensitivity. To learn more, visit [oculus.de/us/products/easyfield-vr](http://oculus.de/us/products/easyfield-vr).

### Virtual Reality Visual Field Devices (Continued)

• **Smart System VR Headset (M&S Technologies).** M&S Technologies' Smart System VR headset with SMARTracker2 eye tracking software has quick screening protocols (a 45-second QuickScreen test) and full threshold testing in under three minutes per eye. The company says the device gives audio and visual cues to both technician and patient, works without an internet connection and provides immediately exportable results to the practice's EMR. The lightweight headset is easily portable and compact, M&S says. A host of tests are built in, including 10-2, 24-2 and 30-2 thresholding; supra threshold, ptosis and Esterman; color vision, stereo testing and contrast sensitivity. M&S says they offer live, immediate technical support. To learn more, visit [mstech-eyes.com/vr-headset](http://mstech-eyes.com/vr-headset).

• **VF3 (Virtual Field).** Virtual Field says its head-mounted perimeters are user-friendly and allow for patients to sit where they're most comfortable, whether at a table or in the exam chair. The perimeter uses CPT codes 92081, 92082, 92083 and 95919. Built-in progression analysis software enables clinicians to track visual field loss over time. The VF3 includes visual field testing and color vision screening. The VF3 Pro includes visual fields, color vision, pupillometry, active eye tracking and kinetic visual fields (Goldmann perimetry). To learn more, visit [virtualfield.io](http://virtualfield.io).

• **VF2000 (MicroMedical Devices).** The VR2000 VR headsets provide full and fast threshold testing as well as a number of other vision screenings, a 4K display and the company's Active Eye Tracking technology in the VF2000 NEO model. The devices can be used without a Wi-Fi connection, are ADA compliant and also include multi-language instruction in the self-guided patient testing interface. The company says the available tests and screenings satisfy CPT codes 92081, 92082, 92083 and 92283. Other available models include the VF2000 G2. To learn more, go to [micromedinc.com](http://micromedinc.com).

• **Advanced Vision Analyzer (Elisar Vision Technology).** Elisar says its AVA Advanced Vision Analyzer is simple to use and includes advanced infrared tracking technology that automatically corrects for fixation loss. It includes test patterns 24-2, 30-2 and 10-2 and screening strategies, full threshold, Elisar Standard and Elisar Fast. The AVA enables multiple patient testing positions, including reclined positioning. The company also notes that the AVA generates a patient-friendly version of the visual field report to help the clinician better explain the diagnosis. Additionally, the cloud-based software updates automatically. To learn more, visit [elisar.com](http://elisar.com).

• **VirtualEye Perimeter (BioFormatix).** This head-mounted perimeter performs 24-2 visual field testing using a manual (subjective) mode, where patient response is recorded via mouse click and a visual grasp (objective) mode, where an eye tracker registers evidence of target acquisition by sensing changes in gaze. The company says this gaze-tracking feature increases test reliability and accuracy while enabling hands-free operation. Additionally, BioFormatix says its technology can be reconfigured to accommodate emerging and future testing scenarios. The headset includes a display and eye-tracking camera as well as space for a trial lens and an infrared illuminator. It's compatible with Windows computers. To learn more, visit [bioformatix.com/perimetry.html](http://bioformatix.com/perimetry.html).

• **nGoggle (nGoggle).** The nGoggle is a portable, brain-based, head-mounted device for detection of glaucomatous field loss with electrophysiological sensors, mA current stimulators and cloud-based software. Wireless electroencephalography measures brain activity and eye-brain-visual field communication. To learn more, visit [ngoggle.com](http://ngoggle.com).

benefits from VR testing are those who have really advanced glaucoma with tiny central islands of vision," Dr. Razeghinejad says. "It's sometimes challenging to find the eyeline and positioning at the standard machine, but it seems easier to find the central fixation with these devices since it's so much closer to the eye, and position isn't critical."

• **User-friendly for patients.** In addition to providing a comfortable testing environment, many VR perimeters also have built-in audio/visual features that instruct patients on how to take the test and how they're performing. Based on her patients' experiences and survey responses, Dr. Ou says the instructions are easy to understand

and the test is easy to perform. "They prefer it over the Humphrey visual field, both in terms of comfort and decreased fatigue," she says.

It helps if patients have some degree of familiarity with technology, but it's not a requirement, Dr. Ou adds. "We did a study this past summer with participants whose primary language wasn't English, to see if the test is translatable across different populations. With some additional training, these patients were also able to perform the test successfully. I think it's definitely a test that's broadly applicable to a lot of different situations and different patients."

• **A potential time saver.** "When

you're checking perimetry virtually, you don't need to move the patient around the clinic, so it saves a lot of time for the physician," says Dr. Razeghinejad.

Additionally, the in-headset training minimizes the need for a technician to administer the test, freeing up that time.

• **Affordability.** VR perimeters vary in price but are relatively inexpensive. "Eventually, for patients to have these in their home, [the VR perimeters] are going to be what I call device agnostic, meaning there's going to be software and not really the device itself, in order for it to be affordable. It'll likely be off-the-shelf devices."

• **Home testing.** In the same vein, experts say that one future use of



Unique J-Code J-2403 Helps Facilitate Reimbursement

**IHEEZO**<sup>™</sup>  
(chloroprocaine HCl ophthalmic gel) 3%

# IHEEZO Gives You Nothing



Visit [IHEEZO.com](https://www.iheezo.com)  
to learn more.



IHEEZO<sup>™</sup> is the topical ocular anesthetic that compromises on nothing. Rapid onset and an established safety profile for your patients. No uncertainty with a sterile, single-use unit.

In a Phase III clinical trial of IHEEZO,

**NO** supplemental treatment needed to maintain anesthesia\*<sup>1</sup>

**NO** serious adverse events with an established safety profile<sup>2</sup>

**NO** patients reported experiencing pain<sup>2</sup>

\*In the clinical trial, no patient undergoing routine cataract surgery receiving IHEEZO required supplemental treatment to maintain anesthesia; this was not the case for patients receiving tetracaine. Supplemental treatment was defined as general anesthesia, intraoperative systemic analgesia, or local anesthesia. Though supplemental administration was not required by any patient in the clinical trial, IHEEZO may be reapplied as needed to maintain anesthesia.<sup>1,2</sup>

<sup>1</sup>Sufficient anesthesia with IHEEZO lasted an average of 21.5 minutes in the clinical trial, while mean total surgical time was 13.9 minutes.<sup>2</sup>

## APPROVED USE

IHEEZO is indicated for ocular surface anesthesia.

## IMPORTANT SAFETY INFORMATION

IHEEZO is contraindicated in patients with a history of hypersensitivity to any component of this preparation.

IHEEZO should not be injected or intraocularly administered.

Patients should not touch the eye for at least 10 to 20 minutes after using anesthetic as accidental injuries can occur due to insensitivity of the eye.

Prolonged use of a topical ocular anesthetic may produce permanent corneal opacification and ulceration with accompanying visual loss.

Do not touch the dropper tip to any surface as this may contaminate the gel.

IHEEZO is indicated for administration under the direct supervision of a healthcare provider. IHEEZO is not intended for patient self-administration.

The most common adverse reactions in studies following IHEEZO administration (incidence greater than or equal to 5%) were mydriasis, conjunctival hyperemia, and eye irritation.

You are encouraged to report suspected adverse reactions to the FDA. Visit [www.fda.gov/medwatch](https://www.fda.gov/medwatch), or call 1-800-FDA-1088.

Please see Brief Summary of Full Prescribing Information for IHEEZO on adjacent page.



**HARROW**<sup>®</sup>  
Your patients. Our purpose.

# IHEEZO™

(chloroprocaine HCl ophthalmic gel) 3%

## BRIEF SUMMARY OF PRESCRIBING INFORMATION

### 1 INDICATIONS AND USAGE

IHEEZO™ (chloroprocaine hydrochloride ophthalmic gel) 3% is a preservative-free ester anesthetic indicated for ocular surface anesthesia.

### 4 CONTRAINDICATIONS

IHEEZO is contraindicated in patients with a history of hypersensitivity to any component of this preparation.

### 5 WARNINGS AND PRECAUTIONS

#### 5.1 Not for Injection or Intraocular Administration

IHEEZO should not be injected or intraocularly administered.

#### 5.2 Corneal Injury Due to Insensitivity

Patients should not touch the eye for at least 10 to 20 minutes after using anesthetic as accidental injuries can occur due to insensitivity of the eye.

#### 5.3 Corneal Opacification

Prolonged use of a topical ocular anesthetic may produce permanent corneal opacification and ulceration with accompanying visual loss.

#### 5.4 Risk of Contamination

Do not touch the dropper tip to any surface as this may contaminate the gel.

#### 5.5 For Administration by Healthcare Provider

IHEEZO is indicated for administration under the direct supervision of a healthcare provider. IHEEZO is not intended for patient self-administration.

### 6 ADVERSE REACTIONS

#### 6.1 Clinical Trials Experience

Because clinical trials are conducted under widely varying conditions, adverse reaction rates observed in the clinical trials of a drug cannot be directly compared to rates in the clinical trials of another drug and may not reflect the rates observed in practice.

The data described below reflect 201 patients undergoing various surgical ocular procedures in two placebo-controlled trials (Study 1 and Study 2). Patients in Study 1 were randomized to receive a single instillation of 3 drops of IHEEZO or placebo. Patients in Study 2 were randomized to receive a single or multiple instillations of 1, 3, or 3+3 drops of IHEEZO or placebo.

The most common adverse reactions in these studies (incidence greater than or equal to 5%) following IHEEZO administration were mydriasis, conjunctival hyperemia, and eye irritation.

### 8 USE IN SPECIFIC POPULATIONS

#### 8.1 Pregnancy

##### Risk Summary

There are no adequate and well-controlled studies of IHEEZO use in pregnant women to inform a drug-associated risk. There are no animal reproduction studies for chloroprocaine.

#### 8.2 Lactation

##### Risk Summary

There are no data on the presence of chloroprocaine in human milk, the effects on the breastfed infant, or the effects on milk production. The developmental and health benefits of breastfeeding should be considered along with the mother's clinical need for IHEEZO and any potential adverse effects on the breastfed infant from IHEEZO.

#### 8.4 Pediatric Use

The safety and effectiveness of IHEEZO have not been established in pediatric patients.

#### 8.5 Geriatric Use

No overall differences in safety or effectiveness of IHEEZO have been observed between elderly and younger patients.

### 12 CLINICAL PHARMACOLOGY

#### 12.1 Mechanism of Action

Chloroprocaine, like other local anesthetics, blocks the generation and the conduction of nerve impulses, presumably by increasing the threshold for electrical excitation in the nerve, slowing the propagation of the nerve impulse, and reducing the rate of rise of the action potential. In general, the progression of anesthesia is related to the diameter, myelination, and conduction velocity of affected nerve fibers. Clinically, the order of loss of nerve function is as follows: (1) pain, (2) temperature, (3) touch, (4) proprioception, and (5) skeletal muscle tone.

#### 12.3 Pharmacokinetics

The systemic exposure to chloroprocaine following topical ocular administration of IHEEZO has not been studied.

##### Elimination

##### Metabolism

Chloroprocaine is metabolized by plasma pseudocholinesterases and nonspecific esterases in ocular tissues. Chloroprocaine is rapidly metabolized in plasma by hydrolysis of the ester

linkage by pseudocholinesterase. The hydrolysis of chloroprocaine results in the production of 8-diethylaminoethanol and 2-chloro-4-aminobenzoic acid, which inhibits the action of the sulfonamides.

##### Excretion

Chloroprocaine plasma half-life in vitro is approximately 25 seconds in adults and approximately 43 seconds in neonates. The kidney is the main excretory organ for most local anesthetics and their metabolites. Urinary excretion is affected by urinary perfusion and factors affecting urinary pH.

### 13 NONCLINICAL TOXICOLOGY

#### 13.1 Carcinogenesis, Mutagenesis, Impairment of Fertility

##### Carcinogenesis

Long-term studies in animals to evaluate carcinogenic potential of chloroprocaine have not been conducted.

##### Mutagenesis

2-chloroprocaine and the main metabolite, ACBA, were negative in the in vitro bacterial reverse mutation test (Ames assay) and the in vitro chromosome aberrations assay.

##### Impairment of Fertility

Studies in animals to evaluate the impairment of fertility have not been conducted with chloroprocaine.

### 14 CLINICAL STUDIES

#### 14.1 Study 1 and Study 2

Study 1 (NCT04779606) and Study 2 (NCT04753710) were randomized, double-blinded, placebo-controlled studies conducted to evaluate the efficacy, safety, and local tolerability of IHEEZO in 145 healthy volunteers.

In Study 1, 85 healthy males and females were randomized in a 4:1 ratio to receive a single ocular instillation of IHEEZO (n=68) or placebo (n=17). The double-blinded treatment included an IHEEZO or a placebo dose of 3 drops instilled at 1-minute ( $\pm 15$  seconds) intervals in the right eye of each volunteer. The median age was 39 years (range 19 to 55 years); 59% female and 41% male.

In Study 2, 60 healthy males and females were randomized (40:20) to receive single or multiple ocular instillations of an IHEEZO dose of 3 drops in the right eye. The median age was 25 years (range 18 to 59 years); 54% female and 46% male.

The efficacy in Study 1 and Study 2 was determined by proportion of patients achieving full conjunctival anesthesia evaluated by conjunctival pinching 5 minutes after administration.

##### Efficacy results of Study 1

The proportion of subjects with successful anesthesia was 90% in the IHEEZO group and 12% in the placebo group ( $P < 0.01$ ). The median time for the IHEEZO group achieving anesthesia was 0.67 minutes. The median duration of anesthesia was 14.3 minutes.

##### Efficacy results of Study 2

The proportion of subjects with successful anesthesia was 95% in the IHEEZO group and 20% in the placebo group ( $P < 0.01$ ). The median time for the IHEEZO group achieving anesthesia was 0.67 minutes. The median duration of anesthesia was 19.3 minutes.

#### 14.2 Study 3

Study 3 (NCT04685538) was a randomized, prospective, multicenter, active-controlled, observer-masked study conducted to evaluate the efficacy and safety of IHEEZO (n=166) versus tetracaine ophthalmic solution 0.5% (n=172) in patients undergoing cataract surgery.

The primary endpoint was defined as the proportion of patients in each treatment group gaining successful anesthesia without any supplementation. On average, patients needed 1 to 1.5 minutes to obtain sufficient anesthesia to successfully perform the surgical procedure, which lasted on average 22 minutes.

No patient treated with IHEEZO required supplemental treatment to complete the intended surgical procedure.

### 17 PATIENT COUNSELING INFORMATION

#### Eye Care Precaution

Do not touch the dropper tip to any surface as this may contaminate the gel. Advise patients that their eyes will be insensitive for up to 20 minutes due to the effect of the anesthetic, and that care should be taken to avoid accidental injuries.

For Full Prescribing Information, please visit [www.iheezo.com/prescribinginformation](http://www.iheezo.com/prescribinginformation).

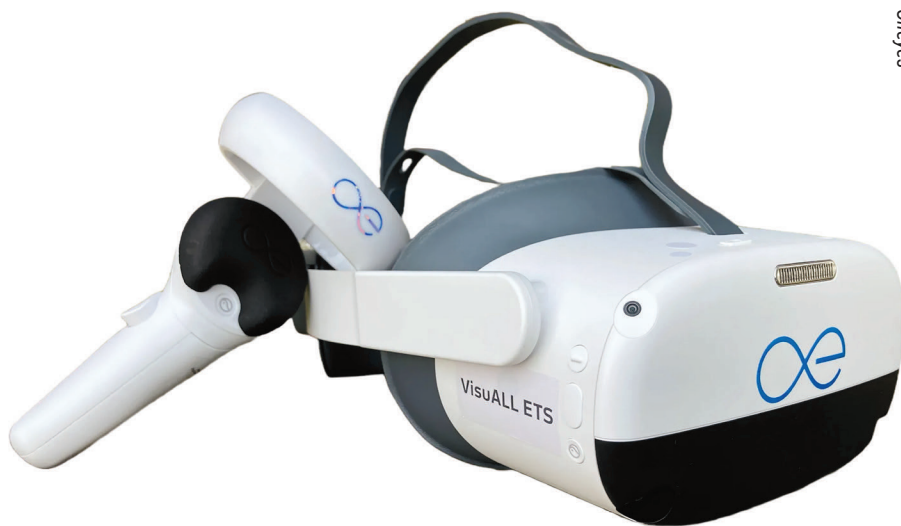

**HARROW®**

Distributed by

Harrow Eye, LLC  
102 Woodmont Blvd., Suite 610  
Nashville, TN 37205  
USA





Olleyes

“We know that these devices are comparable in many ways, but we don’t have as much data as the gold standard,” Dr. Grajewski says. She says the outlook is hopeful for overcoming this challenge. “Over time, because these devices are gaining in popularity, we’ll have that data. In fact, we have more data now than three months ago.”

### Practical Considerations for VR Integration

Rapid innovation is both a blessing and curse. Since glaucoma diagnosis relies on longitudinal data, the stability of the visual field testing platform is key. “The standard automated Humphrey and Octopus visual fields are pretty stable platforms,” says Dr. Tsai. “There may be some slight changes in, let’s say, software or algorithms, but they’re steady.

“It’d be a lot easier to use VR visual fields if someone were to develop a program that either takes the data we’ve garnered over the years [on SAP] and translates it into what we’d see in the VR visual field data, or vice versa. If you were starting all your patients on VR visual fields, then it’d be very simple. You’d follow them with the same platform longitudinally.”

Dr. Razeghinejad points out that most of the VR perimeters have their own thresholding algorithms. “The instruments aren’t talking to each other,” he says. “You may get the same pattern of visual field loss, but the numbers and depths may not be exactly the same.”

Though VR visual field data and SAP data aren’t interchangeable, Dr. Grajewski says VR perimeters could increase the frequency of monitoring if used alongside SAP. “Right now, patients come in every four months or every six months for a visual field, but wouldn’t it be nice if we were monitoring every month? If you saw something grossly different [on VR perimetry] you might repeat it with that device, and

Many virtual reality head-mounted perimeters, such as the VisuALL ETS (Olleyes), include common testing protocols such as 24-2, 10-2, 30-2, 24-2C, and other tests such as color vision, visual acuity, contrast sensitivity, pupillometry and more.

VR perimetry lies in home testing. “It’ll be exciting for patients to be able to test themselves, and the doctor will be able to see [the results] from wherever they are,” Dr. Grajewski says.

• **Screening in remote areas.** The portability of these VR headsets makes them ideal for use in remote areas and regions without access to standard visual field testing. Dr. Razeghinejad says future additions to the headsets will boost their screening utility even more. “I think these devices are going to change a lot in the coming years. They track not only the visual field, but many can also check visual acuity, color vision and pupil reaction. Some are working on checking eye motility. That’s going to be really helpful. In the future, adding fundus imaging will be fantastic.”

### What’s Missing?

Though head-mounted VR perimetry presents many new and exciting opportunities, there’s still a considerable amount of groundwork that needs to be done and questions that need answers before they’re ready for more widespread adoption. Chiefly

among the obstacles is a lack of a normative database since this perimetry technology in its current form is so new.

“

“We know that these devices are comparable in many ways, but we don’t have as much data as the gold standard. Over time, because these devices are gaining in popularity, we’ll have that data. In fact, we have more data now than three months ago.

— Alana L. Grajewski, MD

”

Glaucoma specialist James C. Tsai, MD, MBA, of New York Eye and Ear Infirmary of Mount Sinai in New York, says that more research is needed. “We need new publications that work out the correlation between the results on the VR visual field and traditional automated perimetry,” he says.

if it was still grossly different, you'd bring the patient in to get their baseline [on SAP] and compare that to their previous SAP results. There's good data that indicates that following patients more frequently leads to better care.

"At the moment, VR visual fields aren't near the sophistication of Humphrey or Octopus, which have years and years of investigation and standardization with respect to the algorithms," Dr. Grajewski acknowledges. "Clinicians are always going to make major decisions based on progression analysis and SAP. There will be times when VR is preferable and there will be times when you'll use SAP. Will the technology of these VR devices eventually catch up? Possibly. A lot of work is going into them, but we need more time and we need more data."

She adds that some patients may get better test reliability outside of the office. "Sometimes what you lose in sensitivity you'll pick up in the ability of a patient to take the test better," she says. "That's one of the things I think all of us have seen with the head-mounted devices. But when you really want to see an area, you'll use the instrument with years and years of robust data. With VR visual fields, you could decide if somebody was worse or needs to come in, but I'd say most glaucoma specialists are still waiting for more information on monitoring with VR devices. From a screening point of view, they're fabulous."

### Screening and Monitoring

The glaucoma monitoring capabilities of VR perimeters are still developing. Dr. Ou says that one of the barriers to incorporation right now is that clinicians want a test that can monitor glaucoma progression. "There's still quite a bit of work to be done on the clinical research side to definitively demonstrate that [VR devices'] test-retest reliability is sufficient



Virtual Vision Health

**With virtual reality testing, patients can test in a comfortable position in various locations such as a waiting room or exam chair. Eye-tracking software and audio instructions minimize the need for a technician to administer and monitor the test. Additionally, several companies offer test instructions in multiple languages.**

and that they're sensitive enough to detect glaucoma progression. To my knowledge, the field hasn't demonstrated that these tests can be used for monitoring. I do think that screening would be a great situation for portable visual fields or VR visual fields. We'll need to establish outcome measures for screening: What is a failed screening test? What is a successful screening test? How do we determine the cutoff for a pass/fail?"

Dr. Tsai states that VR visual field headsets would work very well in a population-health model. "In a population-health model, you're not paid per test, but instead you're aiming for tests that are cost-effective and easily done at home, at community centers, outside of doctors' offices, and tests that don't require skilled personnel. If we move forward to that type of health-care environment—less fee-for-service—then I see these VR tests really taking off."

He says a primary care office could be a good setting for such a test. "Patients with a family history

of glaucoma or those who've been told they have elevated eye pressure could come in and be readily tested in primary care offices, rather than sending the patient for a much more costly comprehensive eye exam," he says. "If we paired VR visual field headsets with some AI-guided analysis of the optic nerve and a portable way to measure eye pressure, we'd have three very important test points. That would really help define which patients should be seen by an ophthalmologist/glaucoma specialist and which patients might be able to be followed in their primary care office for yearly exams because they're at very low risk for developing glaucoma."

Dr. Tsai is the director of the newly formed Center for Ophthalmic Artificial Intelligence and Human Health at Mount Sinai. "As we embrace either AI-guided technology and/or technologies such as VR visual field headsets that rely on AI-based software, we'll be able to validate these technologies and demonstrate their clinical usefulness in many different models



MICRO MEDICAL DEVICES

# How to Choose The Right VR VISUAL FIELD HEADSET

If you are looking to free up space, increase the number of patients you can test, and test patients you couldn't test on stationary machines of the past; all while getting fast and reliable reports, a VR Visual Field may be right for you. Our competitors may all claim to be **EASY TO USE, FAST, AND RELIABLE** – we invite you to see for yourself. Set up a free demo and 30-day trial by scanning the code at the bottom of this page and see if we can help you increase

"When you compare apples to apples, the VF2000 has the best reliability and the best people standing behind it – that's the reason why I purchased it." - Mark Perry, OD

## VF2000 Technology



- Use With Or Without Wi-Fi
- Available With Or Without Eye Tracking
- Over 20 VF Test Patterns Included
- Additional Testing Module Bundles (FDT, 5 Color Tests, Stereopsis, Eye Motility, Pupil Reaction)

## What to Look for

### Is it versatile?



"Having a virtual reality visual field allows us to bring that difficult test that's in only one room to utilize it in multiple rooms. So, from an efficiency and flow perspective, it helps a great deal."

- Paul Singh, MD

### Is it easy to use?



"With techs there's always turnover, but within a week our newest tech mastered the device. Traditionally technology takes a couple of months to master, but with this device, it is so much more automated and helpful – they can learn it so fast."

- Rajesh Khanna, MD

### Is it efficient?



"Older patients have trouble doing that cumbersome test [on the HFA and similar devices] and it can take forever. That 10 minutes feels like 10 years. With this, it's not 10 minutes, it's just a few minutes. In fact, I [don't] even leave the room."

- Seema Nanda, OD

### Is it helpful?




"It's extremely versatile. The purchase of this device can also allow for practice growth that's part of the goals of that practice."

- Deepan Selvadurai, MD

## VF2000 Reports

- Easy to read reports
- Results in line with HFA
- Reports include at-a-glance MD progression chart



Schedule

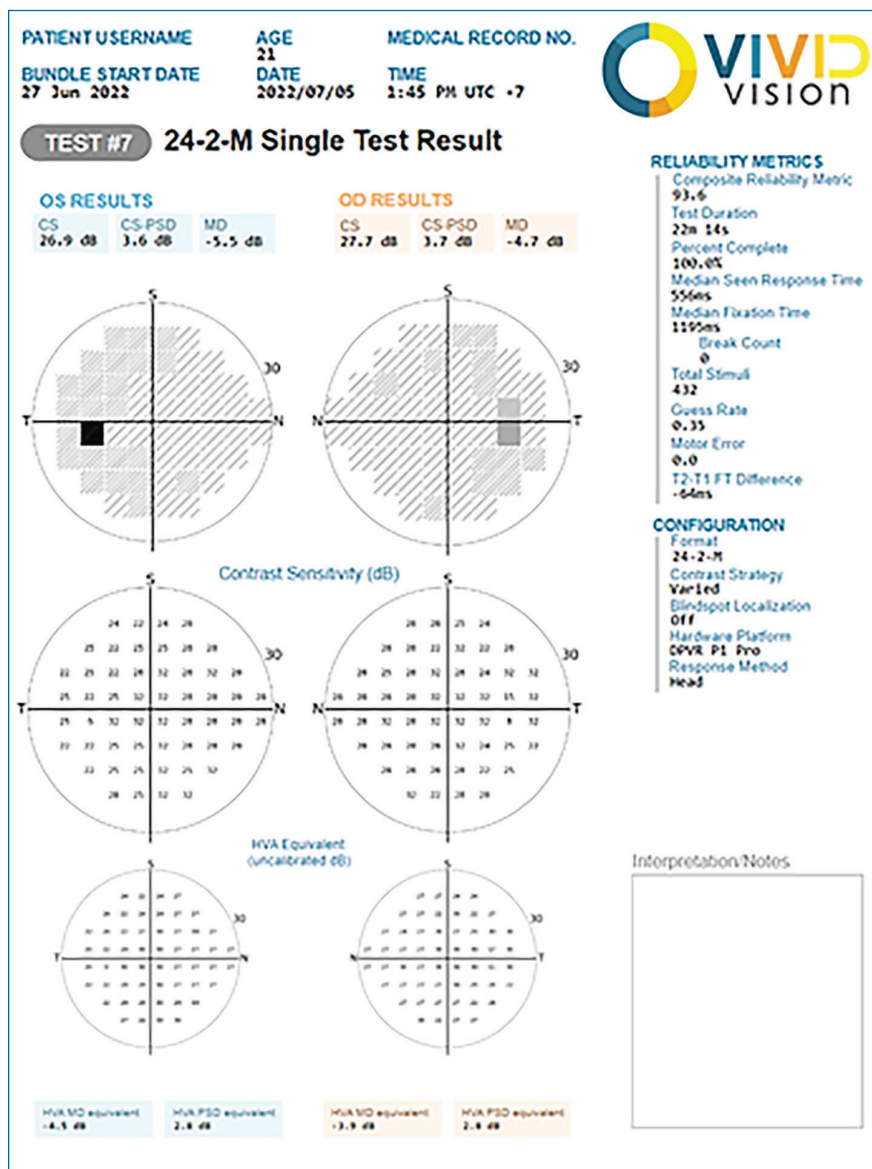
a demo and set-up  
a free 30-day trial



Or call us at  
**818-222-3310**



Vivid Vision



Most virtual reality perimeters include readouts that closely resemble the ones physicians are already familiar with from standard automated perimetry.

of care, not just population health, even though that’s what we’re leaning towards because we see there could be a real benefit,” he says.

### Reimbursement

“In glaucoma practice, we believe that if we can get reliable visual fields on a consistent basis over time, we have a better chance of determining whether a patient is truly progressing or remaining stable,” says Dr. Tsai. “Currently, the payment system model

doesn’t readily reimburse for very frequently performed visual fields.

“One of the challenges of glaucoma care is that there’s got to be a way to get compensated for the care of patients,” he continues. “One of those ways is the traditional visual field, with a CPT code that’s been proven. With these new technologies, there are questions about what the reimbursement will be, how it compares to what we get compensated for traditional visual fields, and the fact that we may still

need to perform traditional visual field testing to ensure we’re not missing anything.

“Computer-based visual field testing has been around for decades,” he adds, “but there was very low adoption of that, primarily because it’s difficult to figure out how to monetize or make it attractive for practices to rely upon.”

### Held to the Standard of Care

Widespread adoption of VR visual fields by the majority of practitioners is slow going. “The challenge with medicine is that we can embrace innovation, but we’re always held to a traditional standard of care,” Dr. Tsai explains. “Standard of care tends to be less innovative because it’s had to be tested and validated over many years. That’s what we rely upon. Even doctors who want to move forward with these innovative technologies are still held back by concerns such as, ‘What if I rely on this VR visual field to tell me that this patient is stable, when in fact they’re not stable? What if I miss something?’ or ‘What if this VR visual field tells me the patient’s progressed when they haven’t?’ Those are all questions I believe clinicians have that we’re very interested in exploring.

“Novel technology is great,” he continues. “Anything that makes it easier for patients to receive top-notch care is fantastic. But we need to know that the companies marketing these devices have done enough background research that we’re convinced the technology is reliable and has been validated and that we aren’t doing patients any harm by relying on these technologies. That said, I hope we’ll be able to figure out in the near future how to incorporate VR visual fields into our normal workflow of glaucoma patients.” ◀

1. History of Virtual Reality. Virtual Reality Society. [vrs.org.uk](https://vrs.org.uk). Accessed January 11, 2024.

# BACK TO BASICS: VISUAL FIELD INTERPRETATION

Findings need to be considered in correlation with the patient exam.

**MICHELLE STEPHENSON**  
CONTRIBUTING EDITOR

**T**abeltop visual field analysis is the gold standard for assessing the functional component of glaucoma and following patients over time to look for progression of disease, but the test results are difficult to interpret. The test is operator- and patient-dependent, and the results shouldn't be considered in isolation, physicians say. Here, glaucoma experts review the strengths and weaknesses of visual field testing, as well as provide their tips on interpreting patients' fields.

## Visual Fields: An Overview

"When patients are diagnosed with glaucoma, they either have no functional deficits and a normal visual field, or they have some deficits. Once we establish a baseline with the visual field and initiate treatment, then we monitor that over time and look for any changes that might indicate progression of their glaucoma," explains Leonard Seibold, MD, who is in practice in Aurora, Colorado.

According to Jonathan Eisengart, MD, who is in practice at the Cleveland Clinic in Ohio, the visual field test can

face challenges from the test-takers themselves. "To take this test, patients need to be able to cooperate, so they need to be able to pay attention and not fall asleep, which is hard for many people. Additionally, they need to have reflexes that are fast enough to push the button when the light flashes. Cataract, corneal disease, or retinal disease certainly can affect the outcome of the visual field," he says.

In addition to being difficult for some patients to take, the test results can be difficult to interpret. "If a patient has an obvious, dark, classic visual field defect that easily matches the appearance of the optic nerve in the OCT—so there's a structure-function correlation—then it's not that hard to interpret. The problem is that there are just so many nonspecific results. Many times, we get results that are kind of wishy-washy. There are the classically defined visual field defects that are typically glaucoma. But, many times, we just get scatterings and groupings of defects that don't coalesce into a classic pattern, and then you're left trying to decide if that's a meaningful result or not. A lot of what we do is trying to filter out what's real and what's just random variation that

you get from test to test. We must try to determine if it's real change from glaucoma getting worse, or if it is sort of the intrinsic inaccuracy and variability built into the test itself. This is where it can be very tough to interpret a visual field in isolation. You really need the rest of the exam and all of the other data that you collect when you see the patient," Dr. Eisengart explains.

## Understanding the Visual Field

In addition to following progression, visual field tests can be used to stage the severity of glaucoma. "The ICD-10 coding classification has a well-described way to stage glaucoma based on the visual field. It defines mild disease as having no visual field deficits on a 24-2 Humphrey visual field, whereas any scotoma that's not within 10 degrees of the central fixation and is only on one hemifield is moderate glaucoma, and any scotomas that are either in both superior and inferior hemifields or within 10 degrees of fixation are considered severe," Dr. Seibold explains.

Unfortunately, visual fields are highly nonspecific. According to Dr. Eisengart, there are many false-positive results, and any visual field can be inaccurate.

*This article has no commercial sponsorship.*

**Drs. Eisengart, Miller, Murphy and Seibold** have no financial interest in any of the products or companies mentioned in this article.

“If I see something on a visual field that looks worse, I need to either have that test repeated, or I need to have something corroborating it. So, for instance, let’s say I have a visual field that looks like the patient is developing a glaucomatous defect. If I’m going to believe that one test, I must have something to corroborate it, such as high pressure or the optic nerve changing. Or, I need to have the OCT changing in a way that’s consistent with the visual field change. If I don’t have another piece of evidence that points to the same thing, I will need to repeat the visual field later because I know that there’s a really high false-positive rate with these tests,” he says.

He adds that the visual field results need to be placed in the complete clinical context. “This includes the patient’s intraocular pressure, their adherence to medications, their optic nerve imaging like OCT, and the optic nerve exam,” Dr. Eisengart says. “Also, when I’m looking at visual fields and I’m trying to decide what to do, a small change might be significant in someone who’s 50 or 60 years old, but a small change with a mild visual field defect in someone who’s 85 might be something that can be safely monitored. So, we must look at the overall patient and his or her health to decide what to do. However, it’s an extremely important test because, besides visual acuity, it’s the only test that shows us what the patient sees. It’s extremely important for determining the function of the optic nerve, but we also must be careful when we interpret it because of its intrinsic unreliability.”

Kevin M. Miller, MD, who is in practice in Los Angeles, adds that visual fields are best at identifying progression in moderate to severe glaucoma. “Visual

fields are terrible indicators of early disease,” he says. “You literally must lose half of your optic nerve to pressure damage before you start seeing the first defects, and the first defects in glaucoma are usually nasal step defects. If you look at the nasal side of the macula, you’ll see a blind spot that respects the horizontal midline. It can be above or below the horizontal midline, but that’s where you’ll find it. As it progresses, you’ll see the defect extends from that nasal step area either under or over the macula in an arcuate pattern. Then, the arcuate defect tends to just expand, while still respecting the midline. Then, when you have really advanced glaucoma, you see arcuate defects on both sides. The nasal portion of the disc is very resilient to pressure damage, and the macula fibers are also resilient to pressure damage. Those are the last two things to go.”

**Limitations**

According to James T. Murphy, MD, who is in practice in New Haven, Connecticut, the popular Humphrey


All images: Kevin M. Miller, MD

Visual Field Analyzer has several limitations. First, the results are operator- and patient-dependent. “Technicians administer the visual fields, so it starts with planning and communicating what field you want to have done and how to do it. Additionally, fields are only as good as patients’ reliability, attention and endurance,” Dr. Murphy explains. His practice uses the Humphrey Visual Field Analyzer as well as Virtual Field and Olleyes, which are wearable virtual reality devices. (For an in-depth look at VR perimetry, see this issue’s cover story on pg. 25.)

Dr. Miller agrees. “If a patient is daydreaming and clicking the button randomly or looking all around, then you’re going to get meaningless results,”

he says. “I consider three things to determine whether the results are usable or reliable: One is fixation loss. You must have the fixation monitor turned on. But, if it’s turned on, then what happens is, every so often, the instrument will throw a light onto the perimeter where the blind spot is supposed to be. And if the patient is looking straight ahead, the patient should not see that light, no matter how bright it is. In a typical exam, the instrument will throw the light into the blind spot maybe 17 to 20 times, and then you can count how many times the patient saw the light. So, if they say they saw the light four out of 19 times, that means the patient wasn’t looking straight ahead more than 20 percent of the time. The other two things I look at when judging reliability are false-positives and false-negatives.”

According to Dr. Seibold, there are several parameters that can provide a sense of the reliability of the test. “In addition to looking at fixation losses, false-positives and false-negatives, we make sure that the prescription the



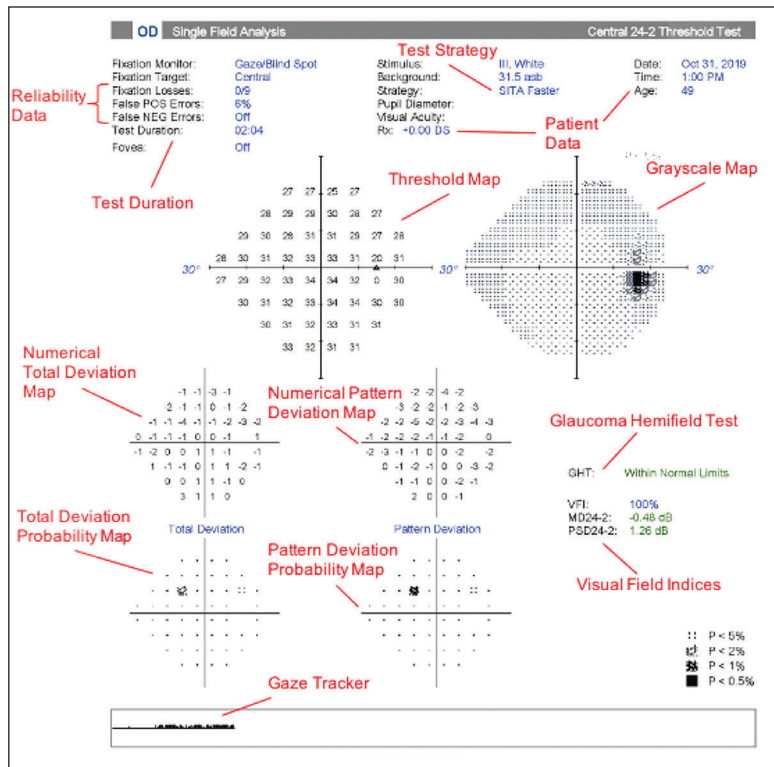
**Figure 1. Humphrey visual field 30-2 test of the left eye of a patient with a nasal step and incomplete arcuate scotoma. The patient recently underwent a trabeculectomy for visual field loss progression.**



technician puts into the machine is accurate for that patient. We also look at the pattern of any visual field deficits to make sure that it's in a pattern that makes sense with the patient's disease and that it correlates to where the patient has optic nerve damage. Looking at all of those things can help you gauge test reliability. However, even if all of those check out, and there's no obvious parameter that looks off, we still repeat it," he says.

According to Dr. Seibold, with glaucoma, changes are often observed on OCT first. "Most commonly in moderate glaucoma, you will see changes on OCT and visual field in concert with each other, so you'll see an optic nerve change along with a visual field deficit that correlates," he says. "That gives you a lot more confidence deciding if a change that you're seeing is real. If only one of them is changing, I'm more suspicious that it could just be the natural variation or variability of that particular test, whether it's an OCT change or a visual field change."

Dr. Murphy notes that the clinician needs to be aware of sources for confounding field defects that are non-glaucomatous in nature. For example, dense nuclear sclerotic cataract, macular holes, and macular degeneration, and even a dense vitreous opacity can cause a central scotoma. Glaucomatous defect progression can be concealed by other defects from retinal disease, prior cerebrovascular accidents or defects caused by non-arteritic anterior ischemic optic neuropathy. "One must be able to use prior fields, structure-function correlation, and deduction to determine what is glaucomatous and what isn't, as well as what is true progression and what is



**Figure 2. Understanding the Humphrey Visual Field.**

performance and reliability variability. During the pandemic, glaucoma specialists noticed that bulkier N95 masks were causing an inferior nasal step-like artifact. Unusual nasal or edge defects could represent a mask, or even the patient's facial, eyelid or orbital anatomy or their positioning (or lack thereof) during the field testing. Patients with low test endurance can sometimes slouch away from the lens attached to the HFA. If his or her eye moves far enough away from that lens, and your office staff isn't watching closely enough, then the lens rim becomes a source of artifact. Positioning is very important for Zeiss' HFA product," he says.

### Tips for Success

Though commonly used perimeters have limitations, there are ways to improve the reliability of the results. For example, Dr. Murphy always reviews previous fields and decides what protocol to run. "I decide whether it's going to be a 24-2, a 10-2 or a 24-2C with added central points near fixation," he says. "I always have the foveal sensitivity turned on because during any field

protocol it aids with maintaining fixation and can provide valuable information about the patient's central field sensitivity. In contrast, some of the wearable devices test both eyes simultaneously in alternating fashion, which is especially helpful for patients who have one eye with poor vision or poor fixation. In these cases, the good eye helps keep the poorer eye fixated throughout the duration of testing."

His practice sees patients who speak languages other than English, and he's excited about the virtual test options that offer an extensive list of languages.

"Both Olleyes and Virtual Field have an audio component that includes an earpiece that provides real-time audio feedback to help the patient test more reliably and accurately," he says. "I serve a patient base that speaks a wide array of languages, and we simply could never have testing staff on hand to serve all these patients properly. I believe all patients deserve to have access to native language coaching for their diagnostics. Olleyes and Virtual Field can both provide needed translation and standardized, reliable coaching, and that can dramatically increase the diagnostic value of these tests."

It can also be helpful to have multiple devices in your office. "We used to offer only Zeiss HFA," says Dr. Murphy. "Some patients who are wheelchair-bound or who have limited neck, back, or spine mobility can have physical limitations that prevent them from being able to position properly for traditional tabletop perimetry. So, having an option that will allow you to serve all your patients regardless of their physical limitations has really added to our practice and those patients' management." ◀

**tyrvaya**<sup>®</sup>  
(varenicline solution)  
nasal spray 0.03 mg

FOR THE SIGNS  
& SYMPTOMS OF  
DRY EYE DISEASE

SHE'S LOOKING TO YOU FOR A  
DIFFERENT APPROACH WHEN  
ARTIFICIAL TEARS ARE NOT ENOUGH.<sup>1</sup>

BEFORE ANOTHER DROP

# ACTIVATE REAL TEARS

WITH THE FIRST AND ONLY NASAL  
SPRAY FOR DRY EYE<sup>2</sup>



## Tyrvaya<sup>®</sup> is not another drop

It's an **ocular surface-sparing** nasal spray.<sup>2</sup>



## Activates real, basal tears

Tyrvaya<sup>®</sup> is believed to work by activating the trigeminal parasympathetic pathway resulting in **basal tear production**.<sup>2\*</sup>



## Real tears, real fast

In 2 clinical trials with **mild, moderate, and severe** dry eye disease patients, Tyrvaya increased tear production from baseline by **≥10 mm in Schirmer's Test Score (STS) in nearly 50% of patients at week 4**, with increased tears seen as early as the first dose and over 12 weeks.<sup>2-8†</sup>

SEE WHAT  
TYRVAYA  
CAN DO



\*The exact mechanism of action is unknown.

†Tyrvaya was evaluated across 3 randomized, vehicle-controlled, double-masked studies in which adults aged ≥22 years diagnosed with dry eye disease received 1 spray of either active drug or vehicle in each nostril twice daily. Primary endpoint: % of patients with mean change from baseline in STS of ≥10 mm at week 4 in ONSET-1: 52% with Tyrvaya (n=48) vs 14% with vehicle (n=43) and in ONSET-2: 47% with Tyrvaya (n=260) vs 28% with vehicle (n=252). Onset of action: mean change from baseline in STS ~5 minutes after first dose (not a prespecified endpoint) in ONSET-1 was 17.2 mm with Tyrvaya (n=48) vs 4.0 mm with vehicle (n=43) and in ONSET-2 was 16.5 mm with Tyrvaya (n=260) vs 6.9 mm with vehicle (n=251). Observed data. On Day 1 in clinical studies, a baseline anesthetized Schirmer's test was performed. Tyrvaya was then administered concurrently with Schirmer's test. Schirmer's test results were measured at ~5 minutes. Mean change from baseline in STS at week 12 in the MYSTIC study was 10.8 mm with Tyrvaya vs 6.0 mm with vehicle. Limitations: Ex-US, single-center study. All subjects were Hispanic or Latino. Tyrvaya group mean baseline STS 5.5 mm (n=41); vehicle group mean baseline STS 5.3 mm (n=41). All randomized and treated patients were included in the analysis and missing data were imputed using last-available data.<sup>2-8</sup>  
**See references on next page.**

## Indication

Tyrvaya<sup>®</sup> (varenicline solution) nasal spray is indicated for the treatment of the signs and symptoms of dry eye disease.

## Important Safety Information

The most common adverse reaction reported in 82% of patients was sneezing. Events that were reported in 5-16% of patients were cough, throat irritation, and instillation-site (nose) irritation.

Please see Brief Summary of Prescribing Information on the next page and the full Prescribing Information at [Tyrvaya-pro.com](http://Tyrvaya-pro.com).



**BRIEF SUMMARY:** Consult the full Prescribing Information for complete product information available at [www.tyrvaya-pro.com](http://www.tyrvaya-pro.com).

### **INDICATIONS AND USAGE**

TYRVAYA® (varenicline solution) nasal spray is a cholinergic agonist indicated for the treatment of the signs and symptoms of dry eye disease.

### **ADVERSE REACTIONS**

**Clinical Trials Experience:** Because clinical trials are conducted under widely varying conditions, adverse reaction rates observed in the clinical trials of a drug cannot be directly compared to rates in the clinical trials of another drug and may not reflect the rates observed in practice.

In three clinical trials of dry eye disease conducted with varenicline solution nasal spray, 349 patients received at least 1 dose of TYRVAYA. The majority of patients had 31 days of treatment exposure, with a maximum exposure of 105 days.

The most common adverse reactions reported in 82% of TYRVAYA treated patients was sneezing. Other common adverse reactions that were reported in >5% of patients include cough (16%), throat irritation (13%), and instillation-site (nose) irritation (8%).

### **USE IN SPECIFIC POPULATIONS**

**Pregnancy: Risk Summary:** There are no available data on TYRVAYA use in pregnant women to inform any drug associated risks. In animal reproduction studies, varenicline did not produce malformations at clinically relevant doses.

All pregnancies have a risk of birth defect, loss, or other adverse outcomes. In the US general population, the estimated background risk of

major birth defects and miscarriage in clinically recognized pregnancies is 2% to 4% and 15% to 20%, respectively.

**Data: Animal Data:** Pregnant rats and rabbits received varenicline succinate during organogenesis at oral doses up to 15 and 30 mg/kg/day, respectively. While no fetal structural abnormalities occurred in either species, maternal toxicity, characterized by reduced body weight gain, and reduced fetal weights occurred in rabbits at the highest dose (4864 times the MRHD on a mg/m<sup>2</sup> basis).

In a pre- and postnatal development study, pregnant rats received up to 15 mg/kg/day of oral varenicline succinate from organogenesis through lactation. Maternal toxicity, characterized by a decrease in body weight gain, was observed at 15 mg/kg/day (1216 times the MRHD on a mg/m<sup>2</sup> basis). Decreased fertility and increased auditory startle response occurred in offspring at the highest maternal dose of 15 mg/kg/day.

**Lactation: Risk summary:** There are no data on the presence of varenicline in human milk, the effects on the breastfed infant, or the effects on milk production. In animal studies varenicline was present in milk of lactating rats. However, due to species-specific differences in lactation physiology, animal data may not reliably predict drug levels in human milk.

The lack of clinical data during lactation precludes a clear determination of the risk of TYRVAYA to an infant during lactation; however, the developmental and health benefits of breastfeeding should be considered along with the mother's clinical need for TYRVAYA and any potential adverse effects on the breastfed child from TYRVAYA.

**Pediatric Use:** Safety and efficacy of TYRVAYA in pediatric patients have not been established.

**Geriatric Use:** No overall differences in safety or effectiveness have been observed between elderly and younger adult patients.

**References:** 1. Jones L, Downie LE, Korb D, et al. *Ocul Surf.* 2017;15(3):575-628. 2. Tyrvaya. Prescribing Information. Oyster Point Pharma; 2021. 3. Oyster Point Pharma. Data on file. OPP-002 (ONSET-1) Clinical Study Report. August 4, 2019. 4. Oyster Point Pharma. Data on file. OPP-101 (ONSET-2) Interim Clinical Study Report. October 13, 2020. 5. Quiroz-Mercado H, Hernandez-Quintela E, Chiu KH, Henry E, Nau JA. *Ocul Surf.* 2022;24:15-21. 6. Wirta D, Torkildsen GL, Boehmer B, et al. *Cornea.* 2022;4(10):1207-1216. 7. Wirta D, Vollmer P, Paauw J, et al. *Ophthalmology.* 2021;0(0):379-387. 8. Oyster Point Pharma. Data on file. OPP-004 (MYSTIC) Clinical Study Report. March 19, 2020.

Manufactured for Oyster Point Pharma, Inc. 202 Carnegie Center, Suite 106, Princeton NJ 08540. For more information, visit [www.tyrvaya-pro.com](http://www.tyrvaya-pro.com). To report an adverse event, contact 1-877-EYE-0123.

© 2023 Viatris Inc. and/or its affiliates. All rights reserved. VIATRIS and the Viatris Logo are trademarks of Mylan Inc., a Viatris Company. Oyster Point®, Tyrvaya®, and the Tyrvaya logo are trademarks of Oyster Point Pharma, Inc., a Viatris company, in the United States and certain jurisdictions. OP-TYR-002308 7/23

# SOLVING DRY-EYE CONUNDRUMS

Cornea specialists highlight the rare and unique diseases that can affect the ocular surface and how they often mystify even the most experienced clinician.

LIZ HUNTER  
SENIOR EDITOR

One of the most common diseases seen by cornea specialists is dry eye. The telltale signs of redness, irritation, foreign body sensation and tearing are recognizable to these trained professionals, and there's no shortage of patients seeking treatment. However, there are instances when a patient doesn't respond to traditional dry-eye therapy or develops severe symptoms practically overnight, suggesting there's something else going on. Cornea specialists are challenged by rare conditions, including autoimmune and infectious diseases, that can manifest as ocular surface problems, and must play detective to determine the root cause and best path forward to bring relief to these patients—many of whom were unaware of their actual disease. Here, they tell us about some of the conditions and how to recognize them.

## Autoimmune Diseases

Dry eye itself hasn't been classified as an autoimmune disease, although some have tried to make the connection, hypothesizing that it's a localized autoim-

mune disease caused by an imbalance of the protective immunoregulatory and proinflammatory pathways of the ocular surface.<sup>1</sup> It is, however, associated with Sjögren's syndrome, rheumatoid arthritis and lupus. Then there are the ones cornea specialists don't come across as often.

• **Stevens-Johnson syndrome/toxic epidermal necrolysis.** These are immune-mediated, mucocutaneous diseases that can be severe and potentially lethal. Ocular involvement occurs in a vast majority of cases, and if not caught and treated in the acute phase, can result in corneal blindness.<sup>2</sup>

SJS/TEN can be triggered by medications within the first few weeks of administration. "In severe cases, acute SJS is a severe allergic reaction to drugs such as antiepileptics, ibuprofen, acetaminophen, antibiotics, or unknown etiology," says Clara C. Chan, MD, FRCSC, FACS, an associate professor at the University of Toronto Department of Ophthalmology and Vision Sciences. "The patient experiences sloughing of their skin throughout the body like a third-degree burn and mucosal membranes can be affected to a severe extent that their airways can be impacted and

patients need to be intubated. Very sick patients may be admitted to the ICU or a burn unit for systemic care. Ocular involvement can occur in acute SJS and presents as conjunctival inflammation, lid margin desquamation and severe dry eye. Severity can range from mild to severe and it's impossible to predict the degree with which patients are impacted."

The acute phase can vary, but it's anywhere from a week up to about a month or so. "That's when there's active sloughing of the skin," says Darren Gregory, MD, a professor of ophthalmology at the University of Colorado Anschutz Medical Campus, who has extensive experience treating patients with acute SJS. "In the first week or so, at least as far as the eyes are concerned, that's been shown to be the best opportunity to make a difference. To make a difference you have to cover the edges of the eyelids, the backs of the eyelids and much of the ocular surface or surface the eyeball with amniotic membrane. It's the most proven treatment to be effective in limiting the damage."

The fact that patients are routinely admitted to burn units for acute SJS complicates treatment. One survey

This article has no commercial sponsorship.

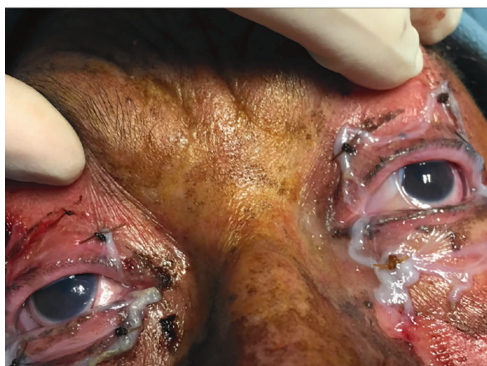Dr. Chan, Dr. Chang, Dr. Gregory and Dr. Rapuano have no disclosures on this topic.



found that only 66 percent of burn ICUs in the United States consult ophthalmology for SJS/TEN patients.<sup>3</sup> “One of the challenges with the amniotic membrane is that it needs to be done relatively urgently,” Dr. Gregory says. Ophthalmology needs to be consulted during the admission process, he adds.

“When I first get called about a patient I want to know how long ago the symptoms started, particularly in the eyes,” he continues. “This allows me to determine for myself if I need to start talking to the operating room to arrange for urgent surgical time. I also want to know the age of the patient. It tends to behave a little less predictably in patients over age 50. I think it tends to follow a fairly fulminant sort of explosive course in young patients, whereas in older patients, they may have other debilitating illnesses so it can sometimes be a little more of a smoldering disease rather than explosive. I also want to know what the skin tone or the race of the patient is, because patients with darker skin pigmentation tend to have more significant disease in the acute phase. So knowing their age, the onset of symptoms and their race helps determine my initial level of concern. I also want to know if they’ve identified a triggering medicine, particularly one called Lamictal (Lamotrigine) that’s frequently used to treat bipolar disorder. There have been published reports that it tends to lead to more severe cases. Allopurinol and sulfa antibiotics are also notorious triggers. I ask all those questions to kind of get a sense of the level of urgency and assess how likely it is that we’ll be surgically treating the patient.”

Awareness is still needed about the viability of amniotic membrane for these patients, he says. “Even after almost 20 years of experience and multiple publications on amniotic membrane, doctors may not be aware of its effectiveness. They may only inspect the eyes every few days and look for scar tissue formation or adhesions between the lids and the surface of the eye and feel like they’ve done what’s needed,”



Hall  
Chew MD

**A patient with Stevens-Johnson syndrome with amniotic membrane covering the complete ocular surface and lid margins after trimming of all lashes and symblepharon ring in situ.**

Dr. Gregory says.

Instead, ophthalmologists may initially instill artificial tears, to the patient’s detriment. “They may inspect the patient every few days to look for the formation of symblepharon, and they’ll often start a patient on some form of antibiotic and corticosteroid drops,” says Dr. Gregory. “There’s some evidence that topical corticosteroids help, but they’re not sufficient by themselves if you’re trying to minimize long-term scarring sequelae.”

Dr. Gregory has published criteria for grading the severity of SJS.<sup>4</sup> “In our published case series, we described varying disease severities: mild; moderate; severe; and extremely severe categories of involvement based on these factors:

- How extensive is the sloughing on the epithelium along the edge of the eyelids;
- How extensive is the sloughing on the conjunctiva lining the backs of the eyelids and the surface of the eye; and
- Is there any sloughing of the corneal epithelium?

“If more than one-third of the lid margin is sloughed that’s considered severe,” continues Dr. Gregory. “Other criteria for being severe are if there’s more than 1 cm of diameter area of conjunctival sloughing; if there’s any sloughing of the cornea, other than punctate staining; if there’s an actual discreet epithelial defect on the cornea—all of those we found to be concerning features that should certainly increase the level of intensity of care, meaning that urgent

amniotic membrane and not just the Prokera AM should be arranged.”

Dr. Gregory says Prokera is like an amniotic membrane contact lens. “It’s useful for treating a number of ocular surface problems, and it can be part of the treatment process in Stevens-Johnson syndrome if the sloughing of the bulbar conjunctiva isn’t extensive,” he explains. “It can be used on the cornea and adjacent conjunctiva, but you also have to treat the back surface of the lids with amniotic membrane or else these patients can still end up with severe scarring problems that lead to the cascade of longer-term visual consequences.”

After the first month, patients enter the sub-acute phase where they’re back home and recovering and no longer critically ill. However, the eyes continue to deteriorate and the effects of all the sloughing and inflammation and early scar tissue formation tend to continue if nothing has been done about them early on.

Dr. Gregory says antibiotics aren’t generally continued in this phase if there weren’t any corneal epithelial defects, but a topical steroid, such as fluorometholone, for longer term treatment may be used due to its lower risk of affecting eye pressure. “If the dry-eye symptoms are improving, we will taper off of steroid drops over the course of a couple of months,” he says. “And we usually have them on cyclosporine drops of some form as well, although the data on whether or not that has an additive benefit in Stevens-Johnson syndrome is probably lacking, but certainly there’s a long history of it being used as a treatment for dry eyes in general. We’ll continue the cyclosporine drops indefinitely if they continue to have dry-eye symptoms.”

Dr. Chan says long-term management of these patients requires chronic control of ocular surface inflammation, aggressive multimodal treatment of dry eye and lid margin disease, and scleral contact lenses to protect the corneal surface from mechanical trauma caused by lid margin keratinization. “Patients with limbal stem cell deficiency and/

**Reichert**  
AMETEK

Left

IO Pcc 14.9

CH 12.3

IO Pg 16.7

WS 8.4

Ocular Response Analyzer® G3 with  
Corneal Hysteresis + IO Pcc





# SHOULD I TREAT THEM?

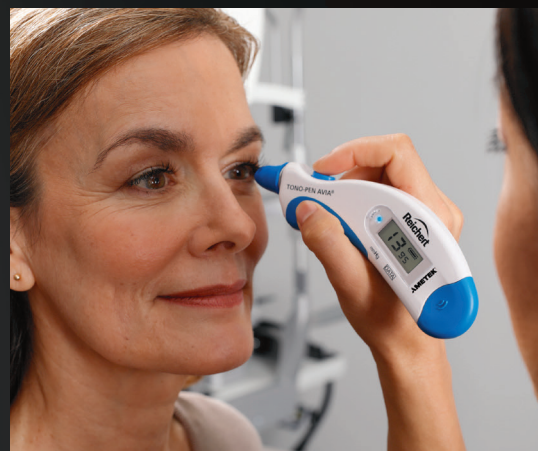Personalize and improve **glaucoma risk assessment**. From Corneal Hysteresis and IOPcc to trusted and innovative new handheld tonometers.

Better data means more informed decisions.

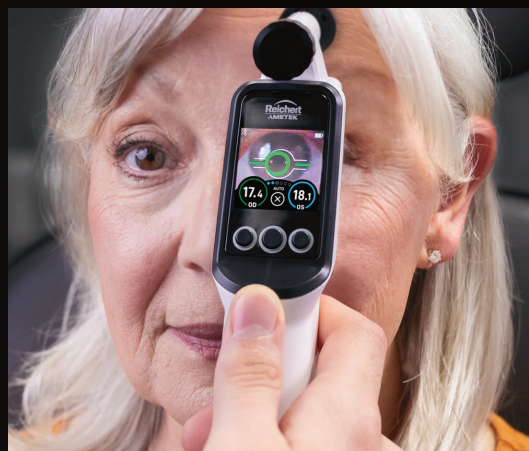WATCH NOW



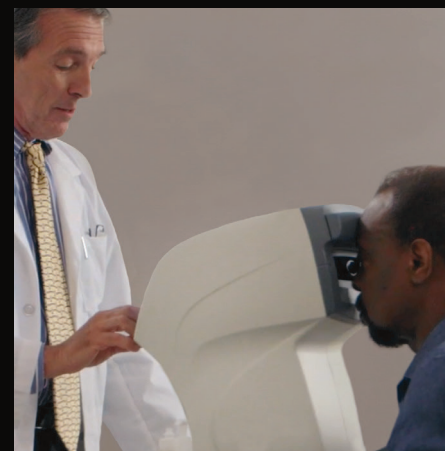WATCH MORE AT [REICHERT.COM/GLAUCOMA](https://reichert.com/glaucoma)



Tono-Pen AVIA® Tonometer



Tono-Vera® Tonometer - *Coming Soon*



Reichert® 7CR Auto Tonometer + IOPcc

**Reichert**  
AMETEK

*passionate about eye care*

or severe conjunctival scarring/symblepharon formation and conjunctival deficiency, may be candidates for limbal stem cell transplantation surgery and/or mucosal membrane grafting onto the lid margins with systemic immunosuppression," she says.

• **Ocular cicatricial pemphigoid.** If SJS can be likened to a hurricane blowing through quickly, leaving a trail of damage, then ocular cicatricial pemphigoid is a slow, urban decay, explains Dr. Gregory. "In ocular cicatricial pemphigoid (also referred to as mucous membrane pemphigoid), there's a slow, smoldering burn of inflammation in the deeper layers of the mucosal epithelium. But the end result after years of untreated OCP can be almost identical to someone who had a severe case of Stevens-Johnson syndrome years before."

Peter Y. Chang, MD, FACS, who is the co-president and partner of the Massachusetts Eye Research and Surgery Institution, says his is one of the highest referral centers in the country for OCP.

"OCP is an autoimmune disease that's commonly thought to affect an older population—usually people in their 60s and above," says Dr. Chang. "In our experience, it's often discovered by an astute oculoplastic surgeon who received a referral for entropion, only to discover that the entropion isn't from involutional changes but conjunctival scarring. The scarring (symblepharon) can take months to years to form, although a severe bout of inflammation can lead to its sudden formation. Many times, these patients have low-grade, chronic conjunctivitis that never goes away. Unlike viral pink eye, which comes on suddenly with the eye changing to a pink or reddish hue with a mucous discharge, in OCP patients the inflammation could be really low-grade to the point that they don't generate a lot of discharge. That's probably the most common presentation for these patients to complain of typical dry-eye symptoms, irritation and light sensitivity. They get treated with all of the various dry-eye modalities but they don't respond well and they sometimes get

written off as having severe dry eye and are expected to live with it."

Ophthalmologists must be on high alert if patients with refractory dry eye syndrome have failed most known therapies, Dr. Chang advises. "An ongoing, underlying systemic inflammation must be considered."

If not treated properly, OCP patients end up having extensive scarring on their conjunctiva turning their eye inward, causing their eyelashes to start scratching the cornea. "They can get a corneal abrasion that doesn't heal very well, and this often can rapidly progress to a corneal ulcer," Dr. Chang says. "Corneal blindness is ultimately how OCP patients lose their sight, unless a corneal transplant is performed. However, human corneal transplant often doesn't fare well in OCP patients, and an artificial corneal transplant (keratoprosthesis) may be needed."

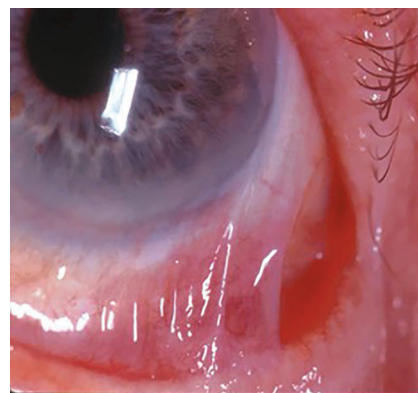
Once a symblepharon is noted, patients should be sent for biopsy. "We'll try to ensure that the piece of tissue removed contains at least 50 percent normal conjunctiva as well so that the pathologist can identify the transition zones," says Dr. Chan. "The tissue is sent in Mitchell's media so that immunofluorescence staining can be done to identify antibody deposition in a linear fashion on the basement membrane zone. A biopsy of any oral mucosal lesions can also be helpful since the sensitivity of immunofluorescence can be very low."

Dr. Chang concurs that a biopsy is necessary to confirm the diagnosis. "Once we find [the particular antibody deposition] we'll recommend systemic therapy," he says. "This isn't something you treat with topical drops only because there's not a whole lot that you can do other than chronic topical steroid drops and we all know it's not good to use those on a long-term basis. It can also put these types of patients at higher risk of infection especially with trichiatric lashes constantly threatening the integrity of the epithelium. We put these patients on systemic immunosuppressive therapy, ranging from oral anti-metabolites to biological infusion

therapy. You want to suppress a systemic hyperactive immune response."

A biopsy can also rule out or identify patients with severe atopic disease. "Atopic diseases can look just like OCP, and sometimes we find they have both the pemphigoid antibody on their conjunctiva and atopic features as well," says Dr. Chang. "For OCP, taking a good medical history is also important because sometimes these patients also have skin manifestations or other mucous membrane involvement, not just in the eye. You should ask them about voice hoarseness because sometimes they have blisters in their vocal cords. I'll ask about dysphasia (difficulty swallowing) because of blisters in the esophagus. I'll ask about blisters in their mouth and tongue. I ask them if there are any blisters or skin sloughing because all of these could be a manifestation of pemphigoid. We have patients who have blisters in their nasal pharyngeal cavity, causing chronic nosebleeds. Many of them are seeing an ENT for these issues. Dentists are often among the first to notice these symptoms."

Ocular rosacea could also lead to cicatricial changes and is among the many differential diagnoses of OCP, which also includes Stevens-Johnson, sarcoidosis, gonococcal and trachoma conjunctivitis, and even a severe bout of viral conjunctivitis. "Taking a good look at medication history is also really important because there's a so-called pseudo-



Peter Y. Chang, MD

**In this stage of ocular cicatricial pemphigoid, symblepharon is evident and cornea specialists say a biopsy is necessary to confirm the diagnosis and rule out any differential diagnoses.**



pemphigoid,” Dr. Chang says. “You can get cicatricial conjunctivitis just from a toxic reaction to prostaglandin drops, for example. You have to play detective and if you don’t ask, the patients aren’t going to tell you.”

OCP is a chronic disease that needs immunosuppressant therapy, which can take six to eight weeks to work. “We’ll give them topical steroids in the bridging period to systemic therapy,” notes Dr. Chang. “Once the systemic therapy is on board for several weeks to a month or two, we start weaning the patients off the topical steroids. We generally recommend getting the patient on immunosuppressive therapy so that their eyes are completely quiet—no mucous discharge, irritation or redness. Now it gets tricky because sometimes these patients have eyelashes turning inward, so even after you get the inflammation under control, it’s not like the eyelash is going to unturn itself, because the scar is already there. What happens is these lashes can still cause problems, so there’s a lot of upkeep for some of these patients, especially if we diagnosed it later in the game.”

Lubricating the eye is part of this upkeep, he continues. “Start patients on artificial tears and dry-eye medication such as Restasis or Xiidra. You also have to see patients pretty frequently to pull their eyelashes. These patients are slightly older so it’s taxing to have family members taking them to these appointments. It’s important to have family/support,” says Dr. Chang.

Dr. Gregory says closely inspecting the eye in both SJS and OCP is an important step. “Pull the lower eyelid down and take a look at the backs of the eyelids and into the fornix because there can be a lot of hidden inflammation or sloughing there,” he says. “In SJS, if you don’t look there, you may not recognize that the case is actually more severe than you thought. In pemphigoid, early subepithelial fibrosis in the inferior fornix with whitening of the pink mucosal skin that lines the backs of the eyelids can occur and can be an early tip off that this isn’t just dry eye. It only takes a few seconds just to pull the lid down and

have a look. You may see changes that suggest pemphigoid. The importance is that, for pemphigoid in particular, there are very effective systemic treatments, the most effective of which is rituximab, that can halt a lot of the immune activity that’s leading to the scarring.”

• **Sarcoidosis.** This is an autoimmune, multi-organ disease, and Dr. Chang says the eye is affected 20 percent of the time. “That 20 percent doesn’t mean it’s necessarily vision-threatening,” he says. “Some patients just have dry eye because the lacrimal gland is involved, but there’s a pretty decent subset who may require systemic therapy.”

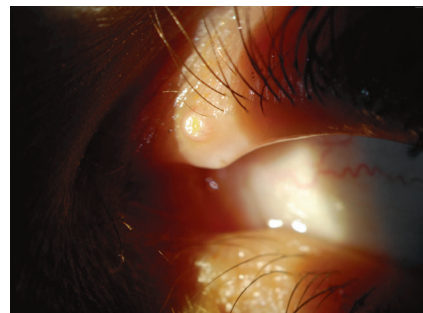
Sarcoidosis can cause chronic conjunctivitis, and it doesn’t always cause cicatrization, but it could, if left untreated,” he continues. “Sarcoidosis infrequently causes conjunctivitis, but can cause inflammation in any part of the eye. It can cause problems in the lacrimal gland. It can cause problems in the optic nerve, it can cause neurosarcoidosis. Sarcoidosis can affect practically any tissue in the body. As far as the ocular surface is concerned for sarcoidosis, it tends to be a little easier to treat and more responsive to traditional dry-eye treatment.”

## Infectious Diseases

Just as autoimmune diseases can be tricky to identify and diagnose, there are a number of unique infections and syndromes that could be misdiagnosed or puzzling.

• **Gonococcal conjunctivitis.** Christopher J. Rapuano, MD, chief of the cornea service at Wills Eye Hospital, says this is rarely seen at Wills, despite it being a tertiary care ER and infectious disease center.

“It’s classically a hyper-acute type of conjunctivitis, so patients get mucopurulent discharge,” says Dr. Rapuano. “You see pus coming out of their eye, you wipe it away, you look at their cornea, you go to type in your notes, and five minutes later the pus is back again. If you get that you have to suspect gonococcal conjunctivitis. You have to look at the entire cornea because sometimes the lids are so swollen and there’s



**In molluscum contagiosum, a viral wart is usually found on the eyelids and can cause severe follicular conjunctivitis. Patients often go misdiagnosed and receive ineffective treatment.**

so much mucous that you can’t get a good view. You may think it looks OK, even though you didn’t see the whole cornea. But if there’s a scratch on the cornea, that can ulcerate very quickly and perforate within 24 hours. Often it’s at the top of the cornea, so if the lid is swollen and the patient won’t look down because the eye hurts, this will prevent you from seeing the superior cornea.” Dr. Rapuano says you may have to consider examining the patient under general anesthesia.

Relief from these symptoms could be fairly quick with appropriate treatment, within a couple of days. “GC requires systemic antibiotics,” according to Dr. Rapuano. “If the cornea isn’t involved, they get a single dose of intramuscular antibiotics, usually 1 g of ceftriaxone. If it does involve the cornea then they get intravenous ceftriaxone for three days. During the acute phase, they’re put on topical antibiotics and that usually helps a lot. The prognosis is very good if you treat them before they have a corneal ulcer. Once a corneal ulcer occurs, then the prognosis is guarded. Corneas can end up perforating, sometimes quickly. They can go from no scratch to an ulcer in 24 hours. For most bacterial infections, it takes days for things to go bad. In this case, if you miss the diagnosis, the patient could be in big trouble.”

• **Molluscum contagiosum.** This is a viral wart, usually found on the eyelids, that can cause severe follicular conjunctivitis. “The eye could just be red and inflamed, and it can be one eye or both eyes,” says Dr. Rapuano. “Patients typi-

cally are treated for blepharitis or allergy with steroids and not getting better. You have to look for these viral warts which can be really small on the eyelid or the lid margin, and they can be hidden within the eyelashes. It's not an active conjunctivitis, but an allergic reaction to the viral particles that fall into the tear film from the wart. Once you get rid of the wart, the eye gets better.

"You can treat the molluscum lesions a bunch of different ways," he continues. "You can scrape it until it causes bleeding, cauterize it, do a shave biopsy, do cryotherapy. Many treatments work, but it takes probably about four to six weeks for the redness to go away completely."

• **Superior limbic keratoconjunctivitis.** The symptoms of SLK are often typical ocular surface dryness, irritation, redness, foreign body sensation, pretty non-specific symptoms, says Dr. Rapuano. "When you encounter patients with these chronic ocular surface complaining symptoms, it's important to consider SLK. The way to diagnose it is to have the patient look down and examine their superior bulbar conjunctiva and in SLK there's this leash of red, inflamed tissue. Put some fluorescein on the eye or lissamine green or rose bengal, and it'll light up. If you don't have the patient look down and pull the eyelid up to see the white part of the upper lid, you'll miss the diagnosis every time," he says. "It's typically treated with a

stepwise approach with lubrication and anti-inflammatories, and you could do cautery to that area to tighten up the tissue or surgery to remove some of that loose tissue."

• **Toxic soup conjunctivitis.** This may not be a common term, but it's a nickname coined by Dr. Chan and colleagues to describe a disease process whereby patients can complain of tearing and present with often unilateral (but can be bilateral) conjunctivitis and papillary reaction on the inferior palpebral conjunctiva along with punctal stenosis or punctal obliteration.

"The poor tear outflow mechanism leads to pooling of inflammatory mediators (from topical medication toxicity, untreated blepharitis, rosacea-related advanced meibomian gland dysfunction, etc.) and nasolacrimal obstruction is ruled out by irrigation," she says. "The conjunctivitis can come on quite suddenly if the punctal occlusion or downstream canalicular narrowing developed in an acute fashion, for example, after a bout of severe epidemic keratoconjunctivitis or due to sudden migration of a punctal plug downstream."

To diagnose this condition, examination of the puncta is crucial, as is looking for the papillary changes in the inferior palpebral conjunctiva. "In advanced untreated cases, patients have even developed limbal stem cell deficiency due to the chronic inflammation leading to destruction of the limbal stem cell niche," says Dr. Chan. "The punctal opening could be covered by a membrane, narrowed to less than 0.3 mm or completely scarred over. Dilation and irrigation through the puncta can be diagnostic (to rule out nasal lacrimal duct obstruction) and therapeutic."

Identification of the etiology for the pooled inflammatory or toxic mediators is important so that the ocular surface environment can be optimized and the toxic agent discontinued (example, topical glaucoma drops with preservatives), she continues. "Topical steroids and steroid-sparing agents (cyclosporine, lifitegrast, tacrolimus) are crucial and some patients may need long-term maintenance with dilute compounded

preservative-free topical dexamethasone 0.01% once to twice daily," says Dr. Chan. "Lid margin optimization (hot compresses, thermal pulsation, intense pulsed light therapy, lid hygiene, *Demodex* eradication, antibiotic steroid pulse therapy to the lid margin, etc); oral tetracyclines to treat rosacea; and treatment of lid eczema and atopic keratoconjunctivitis are all crucial.

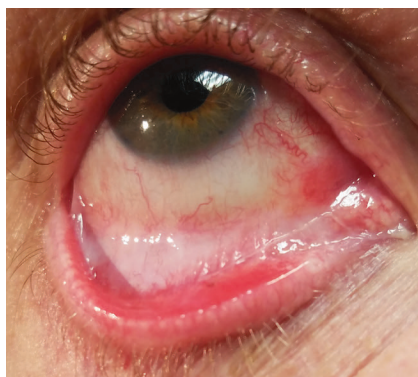"However, the underlying problem must be addressed," she continues. "If a membrane is noted to have grown over the punctal opening it should be peeled away or punctured with dilation and irrigation of the puncta with a 27- to 30-ga. cannula. Referral to oculoplastics may be needed if the puncta scars closed again and a punctoplasty (3-snip) procedure can be done to maintain patency more permanently. More aggressive dilation and irrigation can also help if there's downstream canalicular blockage."

• **Mucous fishing syndrome.** "Patients with this problem will have symptoms of red eye, irritation, itching, tearing and mucous discharge. They develop a habit of picking out the mucous multiple times a day, traumatizing the inferior bulbar and palpebral conjunctival," says Dr. Chan.

"In this scenario, a patient may get something in their eye and they feel it causes a scratch on the cornea so they keep poking at it to make it feel better, and they realize the poking helps it feel better," Dr. Rapuano explains. "When the initial problem has healed, the poking is now the problem. The poking is causing scratchiness and it's a vicious cycle because it feels worse, they poke more, it feels good, it feels even worse and they poke even more. So it's hard to diagnose because people don't tell you that they're doing it."

To diagnose these patients, doctors will often observe their picking actions firsthand. "Sometimes they just do it right in the office while you're writing your note," says Dr. Rapuano. "You look at them and they've got a Q-tip, their finger or a tissue in their eyes poking at it. If you ask what they're doing, they say

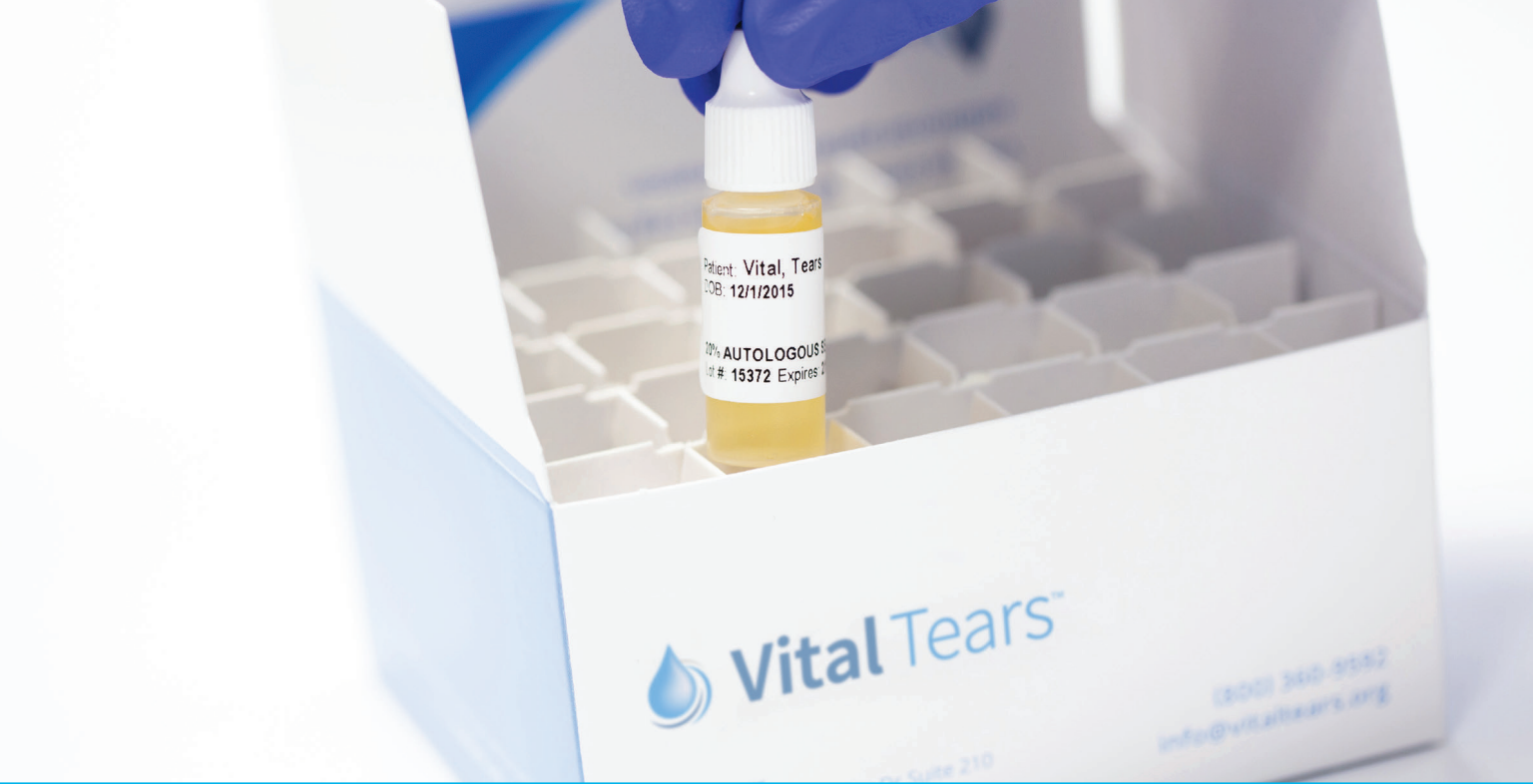(Continued on page 56)



Darren Gregory, MD

**This image shows whitening of the forniceal conjunctiva due to subepithelial fibrosis from ocular cicatricial pemphigoid and demonstrates the importance of pulling down the lower lid to inspect the palpebral conjunctiva and fornix for signs of disease activity.**





# Serum Tears Made **Easy, Fast & Safe**

We make it easy for you and your patients to get a **six-month supply of serum tears** from a single blood draw, with **turnaround times as quick as 48 hours** from the blood draw appointment.

Simply place your order online and then Vital Tears takes care of the rest.

## 1

We contact the patient to schedule the blood draw and collect payment.

## 2

Blood is drawn at one of our 400+ contracted facilities or by a mobile phlebotomist.

## 3

Serum tears are processed using rigorous, validated safety procedures then shipped directly to the patient.



# MANAGING REFRACTIVE SURGERY COMPLICATIONS

Though refractive surgery has advanced a great deal over the decades, complications can still occur. Here's what to expect from the major procedures.

MICHELLE STEPHENSON  
CONTRIBUTING EDITOR

No matter the surgery, there's always the potential for complications, and keratorefractive procedures—such as PRK, LASIK, and SMILE—are no exception. Ongoing advances in technology have improved the safety of these surgical approaches and lessened the risk of complications; however, surgeons must still be prepared to manage any issues that arise.

Below, we'll delve into various complications associated with these procedures and discuss how to manage patients who undergo keratorefractive surgery while optimizing visual outcomes.

## Intraoperative Complications

There are a number of complications—both intraoperative and postoperative—associated with LASIK and PRK. Most of the possible intraoperative complications of keratorefractive surgeries, according to Rockville, Maryland, cornea/refractive surgeon Okezie Igboeli, MD, occur during flap creation.

• **Flap complications.** While the development of new technologies and techniques have made flap-related issues less common, these complications can still occur. Possible intraoperative complications include irregular, incomplete, decentered or buttonhole flaps.

Incomplete flaps can happen for a variety of reasons, such as a malfunctioning flap-making device or suction loss. “With some laser platforms, the surgeon may be able to re-dock and restart/continue the flap creation,” says Dr. Igboeli. “Otherwise, the cornea is allowed to heal, and LASIK or surface ablation may be attempted at a later date. If suction is lost during the side cut, the surgeon may be able to re-do the side cut only, or manually complete the side cut if suction loss occurred during the last seconds of the side cut.”

In the case of a decentered flap, which can be caused by a misaligned suction ring, surgeons should turn off suction and the ring should be repositioned. If there are repeated attempts without success, waiting five to 10 minutes can allow the “decentered gutter-like impression to disappear.”<sup>1</sup>

When there's an interruption of the passage of the microkeratome across

the cornea, buttonhole flaps can occur. “This can result from poor suction, problems with the blade, [and] steep corneal curvatures,” says Dr. Igboeli. “If a buttonhole is noted in the flap, the flap shouldn't be lifted. However, if the flap is lifted prior to noticing the defect, the flap should be replaced, and bandage contact lens should be applied to the eye.”

Although rare, flap tears are another potential complication that can happen during the flap lift. This is more commonly observed in femtosecond LASIK procedures. Risk factors include a large diameter flap with corneal pannus, re-treatment procedures, the presence of a corneal scar and faulty instruments.<sup>1</sup>

Surgeons note that flap tears at the hinge can result in a free cap. In case of a small peripheral tear, the flap should be dissected away from the tear, recommends one study of complications. However, the authors go on to add, if it involves the visual axis, the procedure should be aborted and followed by re-treatment with surface ablation.<sup>1</sup>

• **Free cap.** In rare instances, a free cap can be created during LASIK. This can occur, according to Dr. Igboeli,

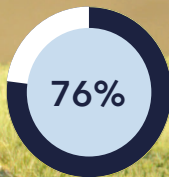This article has no commercial sponsorship.

Drs. Igboeli and Moshirfar report no relevant disclosures.



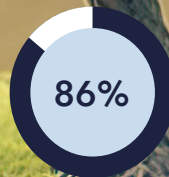
# Help your patients see the world again.

## DRY EYE



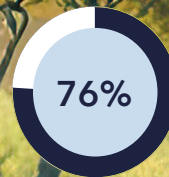
of patients with dry eye reported significant success with PROSE

## KERATOCONUS AND ECTASIA



of patients with keratoconus or ectasia reported significant success with PROSE

## OCULAR GVHD



of patients with ocular GVHD reported significant success with PROSE

PROSE® (prosthetic replacement of the ocular surface ecosystem) is a treatment pioneered by BostonSight. For thousands of patients suffering from the most complex ocular surface diseases, PROSE is often the ideal, and sometimes only, treatment capable of restoring visual function and reducing eye pain and light sensitivity, and all without surgery.



[www.bostonsight.org/practitioners](http://www.bostonsight.org/practitioners)

PROSE is a registered trademark of BostonSight. Patients referred for PROSE treatment must have tried and been unsuccessful with RGP and scleral lenses before consideration for PROSE treatment. Patient statistics are based on a survey of 1,000 PROSE patients. Copyright 2023 BostonSight.





when a microkeratome doesn't stop at the predetermined point. Risk factors include flat corneas (less than 40 D) or improperly assembled microkeratomes.

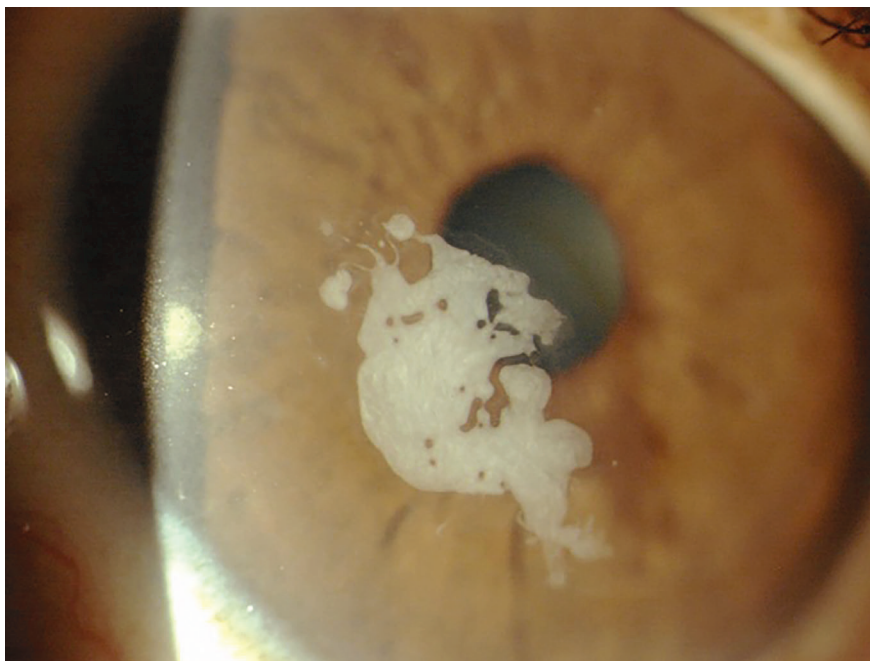
"In such instances, if the stromal bed is regular and large enough for the laser treatment, the treatment can be completed," notes Dr. Igboeli. "The free cap should be kept in a moist chamber while the treatment is taking place. The flap is then replaced ensuring that the epithelial side is up, and a bandage contact lens should be placed over the flap.

"If, however, the free cap is a smaller size without a large enough stromal bed, the free cap is replaced and a BCL placed," he explains. "Surface ablation can be attempted at a later date (usually at least three months) after the cornea has healed."

• **Vertical gas breakthrough.** In some cases, the gas released during flap creation with the femtosecond laser essentially creates a buttonhole, explains Dr. Igboeli. "Ideally, when this happens, the flap shouldn't be lifted," he says. "Just as with buttonholes, if the flap is lifted before the defect is noticed, the flap should be replaced and a BCL placed over the cornea. After the defect has healed, surface ablation may be attempted."

There are rare instances when the gas released during flap creation can travel into the anterior chamber. If large enough, the bubbles can interfere with the tracking system of the laser, Dr. Igboeli notes. As a result, surgeons may have to wait a few hours for the bubbles to decrease in size before continuing the procedure. Placing ice packs over the affected eye can help speed up this process.

• **Corneal perforation.** This rare yet devastating LASIK complication can occur during flap creation. This can be the result of a microkeratome that's not properly assembled, which was a requirement in older models. In older microkeratomes, improper placement of the depth plate could lead to perforations. "If using a microkeratome, it's extremely important to ensure that it is properly assembled prior to



Epithelial ingrowth in the visual axis needs an escalated response, say surgeons.

use," emphasizes Dr. Igboeli. "Newer microkeratomes come with fixed depth plates to avoid this complication."

When corneal perforation occurs, surgeons say that suction should be immediately stopped.<sup>1</sup> Conservative management by repositioning the flap and placing a BCL is done for small perforation; however, a large perforation requires surgical repair under sterile conditions.<sup>1</sup>

### Postoperative Complications

Following PRK and LASIK, careful management and postoperative care is critical to address potential complications.

#### • *Over- and undercorrections.*

Whenever the refractive target isn't hit, it's important to review all the preoperative data to ensure that the intended treatment was performed and that it was the correct treatment for the patient, notes Dr. Igboeli, who encourages surgeons to resist the urge to rush to an enhancement. "Wait at least three to six months before moving forward with enhancements, and always rule out ectasia prior to performing enhancement procedures," he recommends. "In older patients, consider the possibility that the change in refrac-

tive error may be from progression of cataracts."

• **Corneal haze.** While the risk of this PRK complication has lessened, corneal haze is still an issue that can present in clinical practice. Therefore, comprehensive management is critical and that begins with a work-up with imaging, including anterior OCT with two views of the corneal cross section, 9-mm epithelial map and corneal densitometry using Scheimpflug technology, according to Majid Moshirfar, MD, a professor of ophthalmology at the John A. Moran Eye Center, University of Utah School of Medicine, and research medical director at Hoopes Vision Research Center.<sup>2</sup>

Determining the best treatment approach will depend on several factors, including whether or not a patient presents with early- or late-onset haze. "Early-onset haze—within the first six months—may respond better to intensive steroid therapy, while late-onset haze may require a shorter steroid regimen or surgical intervention," says Dr. Moshirfar, who is also the medical co-director of the Utah Lions Eye Bank. "Surgical options include mechanical debridement or superficial phototherapeutic keratectomy for superficial haze,



and deep PTK or therapeutic myopic PRK ablation for deeper haze.”

Ophthalmologists should also consider preventive measures, such as intraoperative mitomycin C applied immediately after the PRK ablation. In 2021, researchers conducted a meta-analysis to analyze surgical outcomes in cases in which MMC was used intraoperatively after PRK for myopia and myopic astigmatism.<sup>3</sup> They looked at 2,232 eyes that were prophylactically treated with MMC and 1,304 control eyes. The investigators found that MMC decreased the rate of both early and late onset corneal haze, with less loss of VA postoperatively in the treated group.

The duration of MMC application may vary based on ablation depth, according to Dr. Moshirfar, who is currently studying MMC’s effect on post-PRK haze.<sup>2</sup>

• **Dry eyes.** A common adverse event of laser refractive surgery, most patients will return to their baseline level of dryness by three to six months after the procedure, according to Dr.

Igboeli. Screening for dry eyes or signs of ocular surface disease is important prior to surgery, however, note surgeons. Additionally, patient education and optimization of the ocular surface pre- and post-procedure is a priority. This includes maximizing tear film stability prior to the procedure. Effective management involves assessment of the eyelid, tear-film breakup time, rose bengal staining, corneal esthesiometry and Schirmer test. There are a number of treatment options, which have been covered extensively in various publications.<sup>4</sup>

• **Decentered ablations.** Optimal visual outcomes following LASIK and PRK depend on a number of factors, including good centration during excimer treatment, notes Dr. Igboeli.

“A decentered ablation can occur with improper positioning of the patient’s head, or with drifting of the patient’s eye during treatment,” he says. “Modern tracking systems have reduced the risk and incidents of decentration; however, it’s important to take note of conditions that can lead

to decentration such as high refractive correction because of the longer time that it takes for treatment, and hyperopic ablations.”

When decentered ablations occur, topography-guided technology can help correct the potential irregular astigmatism, suggests Dr. Igboeli.<sup>5</sup> RGP contact lenses and miotics for the reduction of optical aberrations from a decentration are management options surgeons can consider when addressing this complication.<sup>1</sup>

• **Diffuse lamellar keratitis.** An acute sterile inflammatory response following LASIK, DLK generally responds to topical corticosteroid treatment; however, when left unchecked, or in severe cases, there can be flap melting or severe scarring, explains Dr. Igboeli.

DLK is classified into four stages based on disease progression, this condition requires early recognition and prompt treatment. The stages, as defined by the American Academy of Ophthalmology:

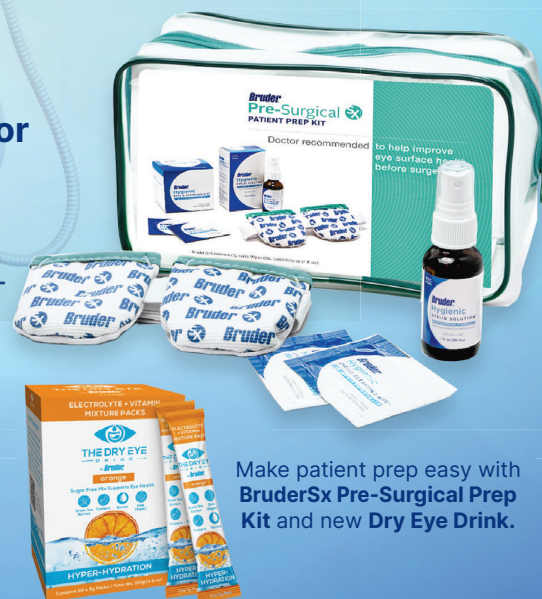— Stage 1 typically arises one to two days after refractive surgery. It’s

## Empower your patients to take part in their surgical success

The benefits of having a healthy ocular surface prior to cataract surgery are well established.

Bruder products can help.

Recommending three easy steps - **hygiene, heat and hydration** - empowers patients to participate in better pre- and post-operative results. By cleaning the lids and lashes and reducing bacteria with Bruder lid hygiene products; unclogging meibomian glands with a Bruder Mask; and hydrating with Dry Eye Drink, patients can help stabilize the tear film. The result: more accurate pre-surgical measurements, while improving post-op recovery and ultimately, vision.



Make patient prep easy with BruderSx Pre-Surgical Prep Kit and new Dry Eye Drink.



Scan to download the Bruder Patient Empowerment Guide and see what doctors are saying about patient prep.

888-827-8337 | [eyes@bruder.com](mailto:eyes@bruder.com) | [bruder.com/pro](http://bruder.com/pro)

**OPEN YOUR EYES**  
**to Bruder**  
a Hilco Vision Company

characterized by peripheral inflammatory infiltrates without central corneal involvement.

— Stage 2 typically arises on postoperative days three or four, when inflammatory cells begin migrating from the periphery into the central cornea often compromising visual acuity.

— Stage 3 is characterized by further centripetal migration of inflammatory cells and the development of permanent corneal scarring. Stage 3 is often referred to as the “threshold” DLK subtype because of the likelihood that eyes in this stage will develop permanent scarring and a resultant loss of visual acuity.

— Stage 4 describes the phase in which stromal melting and further corneal scarring occur. The significant epithelial destruction that ensues during this phase often results in a hyperopic shift.<sup>6</sup>

“The earlier the condition is diagnosed, and treatment started, the more likely it is to resolve without progression to the more worrisome stages (3 and 4),” says Dr. Igboeli. “If there’s concern of progression to stage 3, there should be a low threshold to lift the flap and irrigate the interface. There should be close follow up until resolution of the condition.

Checking for signs of this condition is a crucial aspect of postop day one following LASIK. If there’s a concern about possible flap-edge inflammation, Dr. Igboeli notes that it’s reasonable to increase topical steroid use and follow up sooner than initially planned.

• **Infectious keratitis.** This sight-threatening complication can occur after both PRK and LASIK. This condition typically develops two to three days following surgery, according to Dr. Igboeli, who notes that management should be initiated as soon as the infection is identified.

The initial work up involves lifting of the flap, culturing the source or the interface, and irrigating the stromal bed with antibiotics. If there’s concern about infection, the flap should be lifted and the interface should be cultured and irrigated with antibiotics,



**A corneal abnormality can cause vertical gas breakthrough with the femtosecond.**

recommends Dr. Igboeli. “Infections can lead to flap melts and scarring so close follow-up is warranted.”

• **Flap striae.** This complication, which is classified into micro-striae and macro-striae, typically presents within the first few days of LASIK. Depending on the nature of the striae, the patient may remain asymptomatic with good vision (in which case observation is appropriate), or the striae may be visually significant, according to Dr. Igboeli.

Cases of visually significant striae should be treated as early as possible to prevent the striae from becoming fixed into the flap through epithelial changes, which can occur in as little as 24 hours, Dr. Igboeli explains. Management techniques will vary depending on the individual, and can include gentle stroking of the flap with a wet sponge at the slit-lamp perpendicular to striae (flap-sliding technique), to flap lift and hydration followed by repositioning.<sup>1</sup>

In cases that present late, fixed folds can occur, and treatment includes debridement of corneal epithelium from the flap and exposed stromal bed along with a flap lift, flap hydration, and then repositioning it by stretching it into position.<sup>7</sup> If the fold persists, suturing of the flap may be necessary.

• **Traumatic flap dislocation.** This rare LASIK complication can occur within the first 24 hours, or years after the procedure. Cases within the first 24 hours postop are typically related to excessive eye squeezing, eye rubbing or

dryness, according to Dr. Igboeli, who also notes that traumatic flap dislocation from blunt trauma or blast injuries, has been reported years after the initial surgery.

“In all instances, the goal of repair is to place the flap back in position ensuring that the epithelial side is up, and the strong side is down,” he says. “They should be done as soon as possible to reduce the chance of epithelial ingrowth. The underside of the flap should also be irrigated and scraped if necessary.”

• **Epithelial ingrowth.** While most patients who experience this complication will present with it within four weeks of the refractive procedure, delayed presentations are possible.<sup>1</sup>

“If the patient is asymptomatic and only has nests of cells in the peripheral flap edge, they can usually be monitored without the need for further intervention so long as there’s no progression of the cells,” recommends Dr. Igboeli.

However, if the cells are progressing toward the visual axis or the patient is symptomatic with visual changes, foreign body sensation or pain, a flap lift is indicated, he notes. “After lifting the flap, the epithelial cells are scraped off the underside of the flap as well as off the stromal bed. The flap is then replaced, and a BCL is placed over the flap,” Dr. Igboeli says.

In some cases of recurrent ingrowth, surgeons will lift, scrape and then place sutures to secure the edge of the flap. In one retrospective study comparing lift/scrape vs. lift/scrape/suture, the authors note that, in the literature, the recurrence rate for lift/scrape is between 23.3 to 44 percent, whereas it was 19.6 percent in their study over two-and-a-half years.<sup>8</sup> They go on to say that, in terms of lift/scrape/suture, one report found that of 20 patients undergoing this approach, only one patient had recurrence of ingrowth, and no patients required any further flap lifts.<sup>9</sup> In their study, there was no recurrence with lift/scrape/suture, though the sutures did induce a short-term increase in astigmatism which affected visual



acuity. Both groups had similar visual outcomes at a year, however.<sup>8</sup>

• **Ectasia.** Patients who undergo LASIK, and in some instances, PRK, can experience this biomechanical weakening, thinning and steepening of the cornea after refractive surgery, which occurs in a pattern very similar to keratoconus. Risk factors include young age, thin corneas, high myopia and abnormal topography. Patient screening can help reduce the incidence of postoperative ectasia.

Spectacles, RGP contact lenses or intracorneal ring segments are all visual rehabilitation tools that can help.<sup>1</sup> In cases of progressive ectasia, corneal collagen cross-linking is considered a first-line treatment to prevent further progression. The currently approved protocol in use in the United States consists of epithelial debridement, instillation of riboflavin and then irradiation (UV-A, 3 mW/cm for 30 minutes).

Determining the best management approach, including surgical interventions, depends on the ectasia's severity.<sup>10</sup>

• **Sterile infiltrates.** A potential complication of PRK, sterile infiltrates are associated with bandage contact lens use, explains Dr. Igboeli, while emphasizing the importance of distinguishing these infiltrates from infectious infiltrates.

These infiltrates typically don't disrupt the epithelium, he notes, and treatment usually consists of topical corticosteroids, discontinuation of topical NSAIDs if in use, and discontinuation of the BCL if the epithelium has fully healed. Otherwise changing the BCL may be in order.

### Optimizing SMILE

While this relatively new procedure has proven to be safe and effective, small-incision lenticule extraction also comes with potential complications; however, with the right approach they can be

managed effectively. As with other keratorefractive surgeries, potential postoperative complications include dry eye, epithelial ingrowth, microstriae and ectasia. (*Several of SMILE's potential problem areas were covered in last month's Refractive/Cataract Run-down.*)

In the case of SMILE, surgeons must be prepared to manage issues associated with lenticule creation, such as suction loss, the formation of an opaque bubble layer, subconjunctival hemorrhage, incisional bleeding and black spots, explains Dr. Moshirfar.

If suction loss occurs when less than 10 percent of the lenticule has been cut, the surgeon can re-dock and re-center the laser, he advises. However, if greater than 10 percent of it's been cut, they'll have to convert to either PRK or LASIK.

Addressing the formation of an opaque bubble layer can be done intraoperatively and involves massag-



# THE RICK BAY FOUNDATION

*for Excellence in Eyecare Education*

## Support the Education of Future Healthcare & Eyecare Professionals

Scholarships are awarded to advance the education of students in both **Optometry** and **Ophthalmology**, and are chosen by their school based on qualities that embody Rick's commitment to the profession, including integrity, compassion, partnership and dedication to the greater good.

INTERESTED IN BEING A PARTNER WITH US?

[www.rickbayfoundation.org](http://www.rickbayfoundation.org)

*(Contributions are tax-deductible in accordance with section 170 of the Internal Revenue Code.)*

#### ABOUT RICK

Rick Bay served as the publisher of *The Review Group* for more than 20 years. To those who worked for him, he was a leader whose essence was based in a fierce and boundless loyalty.

To those in the industry and the professions he served, he will be remembered for his unique array of skills and for his dedication to exceeding the expectations of his customers, making many of them fast friends.



THE RICK BAY FOUNDATION  
*for Excellence in Eyecare Education*

ing it out of the interface, according to Dr. Moshirfar, who recommends using the SMILE dissector or a spatula for this maneuver. To eliminate black spots, which occur due to the entrapment of debris or air bubbles between the laser's curved contact glass and the corneal surface, Dr. Moshirfar recommends that surgeons clean the glass and the ocular surface, as needed.

## Best Practices

Ongoing advancements in keratorefractive technologies as well as improvements in the patient selection process for these procedures has significantly lessened the risk for complications. However, when these issues occur, surgeons must have the necessary tools and knowledge to effectively care for their patients.

Dr. Igboeli urges his colleagues to take the time to position the patient correctly prior to treating. "It also helps to speak to the patient and keep them engaged and fixating during the procedure to ensure good centration, and to minimize drifting of the eyes during treatments," he recommends.

It's also important for surgeons to have a thorough understanding of the flapmaking platform that's in use at their facility. "If using an older microkeratome, ensure that it's properly assembled prior to each use," he says. "Femtosecond lasers should be serviced as directed by the manufacturers. The surgeon should be very familiar with the proper laser functions and know when they're not functioning properly."

No matter the procedure, confidence comes with experience. Dr. Moshirfar emphasizes the importance of using the resources at your disposal. "Take the time to learn from your more seasoned colleagues," he advises. "Hands-on learning and experience will help you optimize your skills and ensure you're equipped to manage any possible complications." ◀

1. Sahay P, Bafna RK, Reddy JC, et al. Complications of laser-assisted in situ keratomileusis. *Indian J Ophthalmol* 2021;69:7:1658-69.
2. Moshirfar M, Wang Q, Theis J, et al. Management of corneal haze after photorefractive keratectomy. *Ophthalmol Ther* 2023;12:6:2841-62.
3. Chang YM, Chang ML, Tzu-Heng W, et al. Mitomycin C for the prevention of corneal haze in photorefractive keratectomy: A meta-analysis and trial sequential analysis. *Acta Ophthalmol* 2021;99:652-662.
4. Spadea L, Giovannetti F. Main complications of photorefractive keratectomy and their management. *Clin Ophthalmol* 2019;13:2305-2315.
5. Kanellopoulos AJ, Asimellis G. LASIK ablation centration: An objective digitized assessment and comparison between two generations of an excimer laser. *J Refract Surg* 2015;31:3:164-9.
6. EyeWiki. [https://eyewiki.aao.org/Diffuse\\_Lamellar\\_Keratitis](https://eyewiki.aao.org/Diffuse_Lamellar_Keratitis).
7. [https://eyewiki.aao.org/Flap\\_Striae\\_After\\_LASIK#Early\\_Management](https://eyewiki.aao.org/Flap_Striae_After_LASIK#Early_Management).
8. Yesilirmak N, Chhadva P, Cabot F. Post-LASIK Epithelial Ingrowth: Treatment, recurrence and long-term results. *Cornea* 2018;37:12:1517-1521.
9. Rojas MC, Lumba JD, Manche EE. Treatment of epithelial ingrowth after Laser In Situ Keratomileusis with mechanical debridement and flap suturing. *Arch Ophthalmol* 2004;122:997-1001.
10. Bohac M, Biscevic A, Ahmedbegovic-Pjano M, et al. Management of post-LASIK ectasia. *Mater Sociomed* 2023;35:1:73-8.

(Continued from page 48)

"I've been doing this for weeks and it's not helping."

Dr. Chan says you can also confirm the diagnosis with fluorescein staining to reveal erosions on the inferior bulbar and palpebral conjunctival surfaces.

"To treat these patients, they need to be educated about the importance of discontinuing the fishing action," she says. "A course of topical antibiotics and steroids also is needed. Lubrication or rinsing out the accumulated mucous may also provide some relief."

• **Medicamentosa and anesthetic abuse.** Medicamentosa is caused by patients who have been on an abundance of medications, says Dr. Rapuano. "They started off with a problem, pink eye for example, and they were prescribed medications but it wasn't getting better, so they got other medications, then others," he says. "Eventually, the pink eye has come and gone, but now the patient has so much toxicity from the medications that you can't tell what's going on. You need to ask what medications they've been on and how long they've been taking them. Sometimes I say stop everything except for preservative-free tears and come back and see me in a few weeks."

Anesthetic abuse is an offshoot of medicamentosa, he continues. "For instance, if a patient has a scratched cornea, they go to the ER because it hurts, and they get a drop of anesthetic and it takes the pain away instantly," says Dr. Rapuano. "But then the pain comes back after half an hour. So sometimes people will steal the eyedrops from the ER or the doctor's office and dose themselves every half hour, but then the effect is reduced to 20 minutes, then 10 minutes, and before they know it, patients are using drops every five minutes and it's causing significant problems. So if you see ocular surface issues that aren't resolving, you might want to think about this."

## Final Pearls

"Millions and millions of people have dry eye, but not all dry eyes are equal," concludes Dr. Chang. "When you encounter a more refractory case, you want to consider a potential underlying ocular surface inflammation or conjunctivitis as a cause because there's a reason why their tear film is unstable. If you don't feel comfortable treating this, then refer to rheumatology for a head-to-toe examination and a cornea or uveitis specialist. And always take a thorough medical history."

And to ensure no diagnosis is missed, Dr. Rapuano emphasizes to "always lift the lids." ◀

1. Stern ME, Schaumburg CS, Pflugfelder SC. Dry eye as a mucosal autoimmune disease. *Int Rev Immunol* 2013;32:1:19-41.
2. Metcalfe D, Iqbal Q, Chodosh J, Bouchard CS, Saeed HN. Acute and chronic management of ocular disease in Stevens Johnson Syndrome/Toxic Epidermal Necrolysis in the USA. *Front Med (Lausanne)* 2021;12:8:662897.
3. Le HG, Saeed H, Mantagos IS, Mitchell CM, Goverman J, Chodosh J. Burn unit care of Stevens Johnson syndrome/toxic epidermal necrolysis: A survey. *Burns* 2016;42:4:830-5.
4. Gregory DG. New grading system and treatment guidelines for the acute ocular manifestations of Stevens-Johnson Syndrome. *Ophthalmology* 2016;123:8:1653-1658.





EDITED BY JANINE COLLINGE, MD

## PEDIATRIC PATIENT

# New Ways to Address Amblyopia

*Digital therapeutics present promising ways to boost compliance and treat patients.*

EDWARD KUWERA, MD, AND COURTNEY L. KRAUS, MD  
BALTIMORE

**A**mblyopia is a disorder of visual development, and early diagnosis of visual dysfunction associated with amblyopia is crucial. Treatment needs to begin at a stage where the neurological pathways are still amenable to stimulation, recovery and reversal of cortical damage. All children should have routine visual screenings, as the potential for successful treatment of amblyopia is best in young children. If not promptly recognized or treated, functional deficits from amblyopia may result and persist into adulthood, with impact on productivity and quality of life.

Here, we'll discuss how new

digital therapeutics for amblyopia are shaping up, as well as our experiences with one of them.

### Amblyopia's Effects

The resulting morbidities from amblyopia include:

- **Ocular comorbidities (most often strabismus).** Strabismus can be more obvious to peers and associated with negative peer interactions. Children begin to develop a negative attitude toward classmates with strabismus as early as age 6. This attitude adversely affects interpersonal relationships, self-image, schoolwork, participation in sports, and only intensifies in the teen and adult years.<sup>1</sup>

- **Increased risk of impairment of the good eye.** The lifetime risk of impairment to the sound eye is

estimated to be 1:100 to 1:1,000 from accidental trauma, or other etiologies such as macular degeneration and retinal vein occlusion.<sup>2,3</sup>

- **Impaired binocular function.**

Amblyopia doesn't just affect the vision, it's a binocular disorder with accompanying dysfunction of accommodation, fixation, vergence, reading speed and fluency and contrast sensitivity. There can be reduced, or absent, stereopsis which can affect visual-motor skills and even restrict certain careers such as aviation.

### Standards of Care

Current standards of care in the treatment of amblyopia are based on the work of two study groups that conducted randomized clinical trials to define optimal treatment protocols: The UK-based Monitored Occlusion Treatment of Amblyopia Study (MOTAS) and the U.S.-based Pediatric Eye Disease Investigator Group (PEDIG). The strengths of these studies include a large cohort, broad age groups, different types of amblyopia in a wide range of acuities, certified examiners and standardized acuity testing protocols.

Mainstays in the treatment of amblyopia include refractive correction (glasses), occlusion therapy (or patching of the non-amblyopic eye) and pharmacological penalization (use of atropine dilating drops in the non-amblyopic eye). Although glasses and patching are the gold standard of amblyopia treatment, there are drawbacks. Many parents complain about skin irritation from adhesive patches, some of which are severe enough to require intensive skin emollients or alternative therapy. As a result of discomfort, there may be poor adherence to



**Figure 1.** The head-mounted Luminopia system treats amblyopia by reducing contrast in the sound eye to 15 percent and by using complementary masking so that binocularity is necessary to view the full video.

This article has no commercial sponsorship.

Dr. Collinge is an assistant professor in the Department of Pediatrics of the University of Connecticut School of Medicine. She has no financial interest in any of the products discussed in the article.

treatment.

Children also can be resistant to patching, for many reasons—one of which is that it occludes their better-seeing eye. Atropine offers the ability to bypass patient compliance, with a single nighttime drop effecting 24 hours of better-seeing-eye blur. However, it's less effective if this eye is myopic. The long-lasting dilating effects are particularly difficult for blue irides and can compromise outdoor comfort.

As a clinician, it's perhaps most upsetting to see children with excellent patching compliance fail to improve in their vision. This has been supported by the literature. When occlusion dose monitors are used, it's been shown that even children with excellent patch compliance sometimes fail to improve. For this reason, alternative treatments, e.g., dichoptic therapy, are particularly interesting to physicians and to parents.

### What is Dichoptic Therapy?

This method of treatment involves presenting a different visual stimulus to each eye independently and altering it in a way to encourage use of an amblyopic eye with simultaneous binocular function. This is often done by reducing contrast of the sound eye to a point that overcomes suppression of the amblyopic eye.

Eileen Birch, PhD, and her colleagues in Texas studied the effects of binocular versus sham games in children ages 3 to less than 7 years and found improvement in the binocular treatment group's vision, but with no significant effect on stereoacuity. Some members of each study group also patched, but in the patients who were compliant (i.e., completed at least half of the intended binocular treatment time), a similar improvement was demonstrated regardless of whether or not the patient patched or not.<sup>4,5</sup>

Due to these impressive preliminary results, the PEDIG network



**Figure 2. A boy with myelinated nerve fibers and anisometropic amblyopia. He experienced one line of improvement after failing patching and atropine 1%.**

studied binocular iPad-based dichoptic treatment. Courtney L. Kraus, MD, one of the authors of this article, participated in both PEDIG subsequent studies and “was not surprised by the study results.” Namely, when comparing a “falling blocks” game to patching and glasses, both the younger (ages 5 to 12) and older (ages 13 to 16) cohorts of children had greater improvement with part-time patching than with iPad therapy.<sup>6,7</sup> The game itself was what prevented many children from seeing the benefit of dichoptic treatment. Children didn't find the falling blocks game (similar to Tetris) engaging, and compliance with iPad therapy was a major issue. Less than 20 percent of kids finished the prescribed treatment.<sup>8</sup>

### Dig Rush

Dr. Kraus remembers how discouraging the initial results were, and how the investigators tried to address the issue of compliance with a more engaging game, Dig Rush. They also changed the study question to whether dichoptic iPad play could be better than glasses treatment alone. While the younger cohort of kids showed an initial four-week outpacing of the glasses alone

group, everything evened out by eight weeks, and it was concluded that there was no difference between study groups in VA or stereoacuity.<sup>8,9</sup> Compliance was better here than in the falling blocks studies, but still barely half of children completed 75 percent of the prescribed time.<sup>8</sup> Therefore, for our practices, we feel that the dichoptic stimulus games in their current iterations lack strong support for effectiveness or patient engagement.

In recent years, two digital therapeutics presenting streaming content in a dichoptic fashion have received FDA approval for their use in

the treatment of amblyopia. Of the two, both authors have experience prescribing Luminopia.

### Luminopia

This device is a virtual reality headset used to present dichoptic images projected at optical infinity. The device is paired with a smartphone to stream content licensed from shows on PBS, Nickelodeon, Sesame Street and DreamWorks, among others. The system treats amblyopia in a twofold fashion by 1) reducing contrast in the better eye to 15 percent, and 2) complementary masking in each eye such that binocularity is necessary to see the full video. Specifically, the center of the amblyopic eye is kept clear. David Hunter, MD, PhD, and his team at Boston Children's Hospital studied the device.<sup>10,11</sup> Children aged 4 to 7 had a 1.5-line VA improvement with Luminopia after 12 weeks versus 1.2 lines after patching in an age-matched cohort, with significant gains in stereopsis in the VR treatment group. Even older children (8 to 12) and kids with one year of prior treatment had improvement with Luminopia. It must be noted that there was significantly better compliance with Luminopia compared



to patching and similar dichoptic treatments. The contrast in Luminopia was also kept at 15 percent while other dichoptic studies gradually increased contrast over time.<sup>12,13</sup>

### Authors' Experiences

The “prescription” for Luminopia should be sent to PhilRx, upon which patients will receive a text message with further instructions. This can be done through the electronic medical record. Edward Kuwera, MD, an author of the current article, typically prescribes six refills for six months of treatment before re-evaluating the need to continue. Luminopia is calibrated to optical infinity, meant to be worn over glasses, and isn't suitable for children with a pupillary distance less than 52 mm. Dr. Kraus has encountered at least one child who met age, as well as amblyopia, criteria for Luminopia, but unfortunately had too small a face to try the treatment. She is currently pushing patching for three more months for that little girl, but if she fails to improve, Dr. Kraus may still try Luminopia despite falling short of pupillary distance requirements.

With standard use of the device in children with anisometropic amblyopia, Dr. Kuwera has had success with a 6-year-old and an 8-year-old male. Both had been patching for almost one year prior to dichoptic treatment. Both children used Luminopia for at least six months prior to follow up. The 6-year-old improved by three lines, and the 8-year-old by one line. Despite great evidence for its use, even in children who've had prior treatment, he still advises parents that patching is the gold standard of amblyopia therapy and that these devices are a backup.

Dr. Kuwera reports two “off-label” usages of the device. He's tried them in a 60-year-old patient with patching-naïve mild amblyopia (acuity 20/40), and an aphakic 5-year-old with 20 PD of esotropia and 20/150

acuity despite years of patching, spectacle-wear and strabismus surgery. The device was successful in improving acuity by one line after six months in the adult patient, but not in the child. Dr. Kraus hypothesizes this child may have too large a strabismus to allow binocular play and is possibly just using the reduced contrast, non-amblyopic eye during viewing.

Dr. Kraus reports that she's almost exclusively used Luminopia “off-label” for children with challenging-to-treat amblyopia. Dr. Kraus has a clinical practice that skews heavily towards anterior segment pathology—these patients often have strabismic, anisometropic and deprivational components to their amblyopia. She's seen modest gains in children with extensive patching history, due to childhood cataracts. Personally, she's found the high hyperopic aphakic prescriptions aren't well suited to the VR headset, and mostly used the VR technology after implanting secondary intraocular lenses. She's most excited by a child who had unilateral congenital glaucoma and subsequent high myopia. Her parents were never able to successfully patch. The child is 4 years old and refused to allow her sound eye to be patched for acuity testing. They just started Luminopia, and for the first time, the child allowed VA testing in the office. She was 20/400—but maybe that was some improvement!

### CureSight

NovaSight received FDA approval for their device, CureSight, about one year after Luminopia. The authors have yet to prescribe this to patients, but there are perhaps some advantages over other digital therapeutics. CureSight is novel in its incorporation of an eye-tracking software that allows the device to selectively blur and reduce contrast to only the fovea of the sound eye. This means that as the child glances around the digital device, the eye-tracking changes the area of blur. The magnitude and diameter of the blurred area are fit according to the VA of both the amblyopic and the dominant eye. The lower the VA and larger the VA difference between the eyes, the greater the blur amplitude and diameter. The sharpness of the peripheral area isn't affected by blur to encourage binocularity. Like the iPad-based dichoptic play, CureSight makes use of red-blue glasses to create the dichoptic environment.

The strongest evidence supporting the use of CureSight comes from a randomized, noninferiority trial of 103 children between 4 and 9 years of age done in Israel. In the 16-week study, children were randomized in a 1:1 fashion to 90 mins/day CureSight six days a week versus two hours/day patching seven days a week. Dr. Kraus' impression of CureSight is that it offers more appeal to older children. The digital platform allows for streaming of any site the child



**Figure 3.** An 8-year-old boy who gained one line of vision at six months, after previously failing more than a year of patching.

may wish to access, with parental controls able to be placed. Netflix, Prime Video, Disney Plus, YouTube, Hulu—these are all accessible on CureSight. For the older children who have reported growing tired of the digital media library of Luminopia, or feeling the content skews towards a younger audience, this solves that issue. Compliance in the study demonstrated the popularity, with 91 percent of children completing their prescribed treatment.<sup>14</sup>

### Final Thoughts

We're at an exciting crossroads in the treatment of amblyopia. Digital therapeutics offer the potential to attract children to amblyopia therapy without some of the stigma and discomfort that comes with patching or atropine penalization. However, the American Academy of Pediatrics continues to recommend that children ages 2 to 5 watch no more than N hour of digital media per day. Balancing therapeutics with digital media, especially for those children who may require more hours of treatment, is an important consideration.

### Key Takeaways

Here are several points to keep in mind:

- Correcting refractive error remains the first line in improving visual acuity and amblyopia.
- Patching is usually the next step in treating amblyopia. We prefer this treatment, though studies have shown equivalent efficacy with atropine.
- Because of the prolonged dilation, and lessened effect with myopic eyes, atropine is a treatment to use when parents are unable to complete patching. It can be used either in isolation, or in combination with whatever amount of patching is able to be completed.



**Figure 4. A 6-year-old girl with bilateral pseudophakia after IOL implants one year ago due to congenital cataracts.**

• Dichoptic treatments have only been available with FDA approval for the last two years. Therefore, we're only just beginning to use them in practice. Enthusiasm has been high from patients, and we expect compliance rates to be similar. This mirrors study findings.

• Luminopia received FDA approval first, therefore there's more experience with its use. It's best for the recommended ages 4 to 9, with older children finding the content less appealing.

• CureSight studies show significant promise, even improving visual acuity over patching. The authors will likely begin using this more in the year to come. ◀

1. Carlton J, Kaltenthaler E. Amblyopia and quality of life: A systematic review. *Eye (Lond)* 2011;25:4:403-13.
2. Rahi J, Logan S, Timms C, Russell-Eggitt I, Taylor D. Risk, causes, and outcomes of visual impairment after loss of vision in the non-amblyopic eye: A population-based study. *Lancet* 2002;360:9333:597-602.
3. Tommila V, Tarkkanen A. Incidence of loss of vision in the healthy eye in amblyopia. *Br J Ophthalmol* 1981;65:8:575-7.
4. Birch EE, Li SL, Jost RM, et al. Binocular iPad treatment for amblyopia in preschool children. *JAAPOS* 2015;19:1:6-11.
5. Kelly KR, Jost RM, Dao L, Beauchamp CL, Leffler JN,

- Birch EE. Binocular iPad game vs patching for treatment of amblyopia in children: A randomized clinical trial. *JAMA Ophthalmol* 2016;134:12:1402-1408.
6. Holmes JM, Manh VM, Lazar EL, et al. Effect of a binocular iPad game vs part-time patching in children aged 5 to 12 years with amblyopia: A randomized clinical trial. *JAMA Ophthalmol* 2016;134:1391-400.
7. Manh VM, Holmes JM, Lazar EL, et al. A randomized trial of a binocular iPad game versus part-time patching in children aged 13 to 16 years with amblyopia. *Am J Ophthalmol* 2018;186:104-115.
8. Pediatric Eye Disease Investigator Group; Holmes JM, Manny RE, Lazar EL, Birch EE, Kelly KR, Summers AI, Martinson SR, Raghuram A, Colburn JD, Law C, Marsh JD, Bitner DP, Kraker RT, Wallace DK. A randomized trial of binocular Dig Rush game treatment for amblyopia in children aged 7 to 12 years. *Ophthalmology* 2019;126:3:456-466.
9. Manny RE, Holmes JM, Kraker RT, Li Z, Waters AL, Kelly KR, Kong L, Crouch ER, Lorenzana IJ, Alkharashi MS, Galvin JA, Rice ML, Melia BM, Cotter SA; Pediatric Eye Disease Investigator Group. A randomized trial of binocular Dig Rush game treatment for amblyopia in children aged 4 to 6 years. *Optom Vis Sci* 2022;99:3:213-227.

10. Xiao S, Angjeli E, Wu HC, Gaier ED, Gomez S, Travers DA, Binenbaum G, Langer R, Hunter DG, Repka MX; Luminopia Pivotal Trial Group. Randomized controlled trial of a dichoptic digital therapeutic for amblyopia. *Ophthalmology* 2022 Jan;129:1:77-85. Erratum in: *Ophthalmology* 2022;129:5:593.
11. Xiao S, Gaier ED, Wu HC, Angjeli E, Nuth PL, Bohra LI, Miller AM, Mazow ML, Stout AU, Morse CL, Blumenfeld LC, Glaser SR, Crouch E, Ekdawi NS, Lyon DW, Silbert DI, Hunter DG. Digital therapeutic improves visual acuity and encourages high adherence in amblyopic children in open-label pilot study. *J AAPOS* 2021 Apr;25:2:87. e1-87.e6.
12. Li SL, Reynaud A, Hess RF, et al. Dichoptic movie viewing treats childhood amblyopia. *J AAPOS* 2015;19:401-5.
13. Birch EE, Jost RM, De La Cruz A, et al. Binocular amblyopia treatment with contrast-rebalanced movies. *J AAPOS* 2019;23:160.e1-5.
14. Wagnanski-Jaffe T, Kushner BJ, Moshkovitz A, Belkin M, Yehezkel O; CureSight Pivotal Trial Group. An eye-tracking-based dichoptic home treatment for amblyopia: A multicenter randomized clinical trial. *Ophthalmology* 2023;130:3:274-285.

### ABOUT THE AUTHORS



**Dr. Kuwera** is an assistant professor of ophthalmology and **Dr. Kraus** is an associate professor of ophthalmology at The Zanvyl Krieger Children's Eye Center, The Wilmer Eye Institute, The Johns Hopkins University School of Medicine in Baltimore. They have no related financial disclosures.







EDITED BY KULDEV SINGH, MD, MPH,  
AND PETER A. NETLAND, MD, PHD

## GLAUCOMA MANAGEMENT

# Cutting Edge Glaucoma Research

A round-up of standout ARVO papers advancing glaucomatology.

AHMARA G. ROSS, MD, PHD  
PHILADELPHIA

As glaucoma specialists, we're all humbled by treating glaucoma and watching patients progress despite maintaining target pressure with drops, lasers, medications or regular monitoring with OCT and visual fields. When I see these patients, some of the questions that come to mind are: How can we find you sooner? Is there a technology we can use to identify fast progressors or those at the end of their disease? Is there anything we can offer these patients to enhance their lives despite vision loss from glaucoma?

As a clinician scientist, I'm constantly thinking about how the findings presented at our meetings might be implemented in the clinic. Here, I'll review some exciting advances in our field from ARVO 2023: Emerging technologies for studying architecture, dynamics and function; improving deep learning and AI to diagnose glaucoma; and developing therapies to improve care after diagnosis and disease progression.

### Emerging Technology

One of the technologies we've watched evolve in subsequent

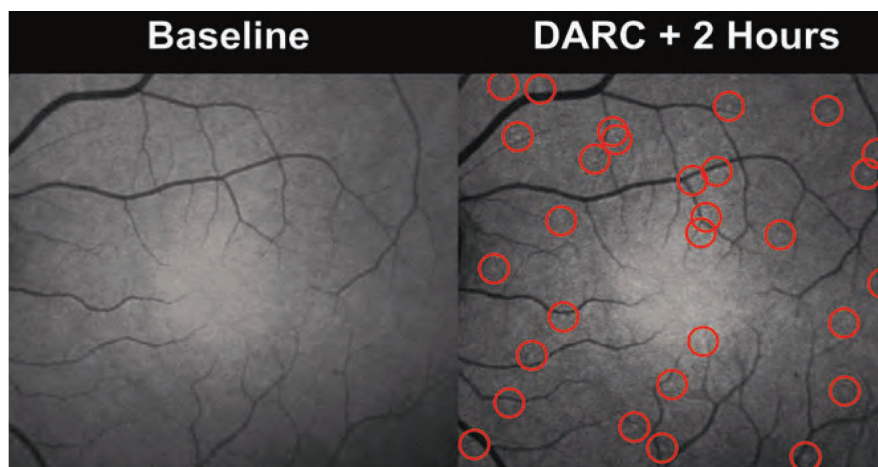
ARVO meetings is Detection of Apoptosing Retinal Cells (DARC), a method of visualizing apoptosis in real time. With this technology, we can detect glaucomatous cell damage at earlier stages in the disease and may one day be able to employ it as evidence of treatment efficacy.

DARC relies on the protein Annexin V as a sensitive probe to identify dying retinal ganglion cells with the assistance of a fluorescent dye. During apoptosis, which begins early in the disease process, the cell surface undergoes multiple changes. One of those changes is

the transport of phosphatidylserine from the inside of the cell to the cell surface. When these receptors move from the inside to the outside of the cell, Annexin V is able to bind to the cell surface.

DARC is now able to be used in human diseases. Recently, Professor M. Francesca Cordeiro of Imperial College London and University College London in the United Kingdom, and colleagues demonstrated that distinct types of DARC spots could be observed *in vivo* and that an increased proportion of irregularly shaped DARC spots was associated with diseases that kill retinal ganglion cells, such as glaucoma, multiple sclerosis and demyelinating optic neuritis.

James Owler, of Novai, the company developing DARC, presented the team's findings at ARVO. The study<sup>1</sup> included 36 healthy adults (mean age: 45.97) and patients with glaucoma (n=20,



Professor M. Francesca Cordeiro

Once apoptosing cells are made visible by DARC technology, they can be imaged and measured using confocal scanning laser ophthalmoscopy. Above, bright spots corresponding to cells externalizing phosphatidylserine are detectable in a patient's retina two hours after administration of the fluorescent Annexin V. The spots are identified with a convolutional neural network algorithm.

This article has no commercial sponsorship.

Dr. Singh is a professor of ophthalmology and chief of the Glaucoma Division at Stanford University School of Medicine. He is a consultant to Alcon, Allergan, Santen, Sight Sciences, Glaukos and Ivantis. Dr. Netland is Vernah Scott Moyston Professor and Chair at the University of Virginia in Charlottesville.

mean age: 61.74) and multiple sclerosis optic neuritis (n=12, mean age: 44.47). The researchers applied hysteresis thresholding for each DARC spot to identify perimeters and extract a set of morphometrics: spot area; eccentricity; etc. Hierarchical clustering of these morphometrics showed distinct populations of DARC spots—C0: small regular; C1: irregular; C2: large regular. The most common type of DARC spot type in each eye differed significantly among the groups.

This study has massive implications. We now have the ability to use live imaging to study cellular architecture. By identifying which cells are dying and their dynamics, we could potentially demonstrate loss of function and use this technology to develop neuroprotective therapies in the future.



**Visual function improvement was observed in patients after using an augmented reality device consisting of AR software and a smartphone paired with a Samsung Gear headset<sup>®</sup> like the one above.**

### Deep Learning

This type of artificial intelligence uses representation-learning methods to extract patterns from raw data. In ophthalmology, deep learning algorithms are primarily used in diabetic retinopathy and retinopathy of prematurity, but the technology is also being investigated in glaucoma and age-related macular degenera-

tion, in particular with the prediction of progression based on fundus images and OCT volume and thickness maps.

One of the challenges deep learning models in glaucoma face is imbalanced datasets used to train the programs, as many are skewed toward “glaucoma cases.” There haven’t been many large population datasets of patients who are glaucoma suspects, and many studies throw out glaucoma

suspect samples. However, such imbalanced training models can lead to inaccurate estimation and generalization failure.

New research presented at ARVO by Ashkan Abbasi, PhD, of the Casey Eye Institute, found that studying glaucoma suspect eyes using a semi-supervised, resampling approach can lead to improvements

## ADVERTISER INDEX

*This advertiser index is published as a convenience and not as part of the advertising contract. Every care will be taken to index correctly. No allowance will be made for errors due to spelling, incorrect page number, or failure to insert.*

Apellis .....	15, 16
<a href="http://www.apellis.com">www.apellis.com</a>	
Boston Sight .....	51
<a href="https://www.bostonsight.org/">https://www.bostonsight.org/</a>	
Bruder Healthcare Company .....	53
(888) 827-8337	
<a href="http://www.bruder.com">www.bruder.com</a>	
Dompe .....	Cover 2, 3
<a href="http://www.oxervate.com/HCP">www.oxervate.com/HCP</a>	
Glaukos .....	Cover 4
(800) 452-8567	
<a href="http://www.glaukos.com">www.glaukos.com</a>	
Horizon Therapeutics .....	26 -28
(866) 479-6742	
<a href="http://www.horizontherapeutics.com">www.horizontherapeutics.com</a>	
Icare USA .....	Cover Tip
(888) 389-4022	
<a href="http://www.icare-usa.com">www.icare-usa.com</a>	

Johnson & Johnson Surgical Vision, Inc. ....	5
<a href="http://surgical.jnjvision.com">http://surgical.jnjvision.com</a>	
Micro Medical Devices .....	35
<a href="https://micromedinc.com/vf2000-visual-field-analyzer/">https://micromedinc.com/vf2000-visual-field-analyzer/</a>	
Olleyes .....	23
<a href="http://www.olleyes.com">www.olleyes.com</a>	
Oyster Point .....	40, 41
<a href="https://oysterpointrx.com/">https://oysterpointrx.com/</a>	
Reichert Technologies .....	44, 45
(888) 849-8955	
<a href="http://www.reichert.com">www.reichert.com</a>	
Tarsus .....	11, 12
<a href="https://tarsusrx.com">https://tarsusrx.com</a>	
Thea .....	7, 8
<a href="http://www.ivizia.com/ecp">www.ivizia.com/ecp</a>	
Topcon .....	Cover 3
<a href="http://www.topconhealthcare.com">www.topconhealthcare.com</a>	
Vital Tears .....	49
<a href="https://vitaltears.org/">https://vitaltears.org/</a>	



in AI diagnostic performance that ameliorate imbalanced learning.<sup>2</sup> He and his colleagues developed a baseline 3D convolutional neural network and trained it on a real-world glaucoma dataset, which is naturally skewed toward glaucoma cases. They applied three methods (reweighting samples, data resampling to form balanced batches and semi-supervised learning) to glaucoma suspect data and found statistically significant improvements in all metrics compared with traditional supervised training using weighted cross-entropy loss (95.24-percent mean accuracy, 97.42-percent F1 score and 95.64 percent AUCROC vs. 92.88 percent, 96.12 percent and 92.72 percent, respectively). The authors emphasized that making use of data with uncertain diagnosis can alleviate some imbalance in datasets, so long as combined semi-supervised and class-imbalanced learning strategies are used.

With this approach, the algorithm was also able to determine not only whether a patient had glaucoma or not, but who was a glaucoma suspect, who skewed more toward having pre-perimetric disease and who was a healthy control. This type of tool could potentially determine which glaucoma suspects might convert.

## Improving Care

At the end-stages of glaucoma, there's still hope for patients' residual vision. Technologies such as augmented reality and virtual reality may help. AR overlays digital information onto a real-world environment while VR is a completely immersive, computer-generated environment. A prospective study presented at ARVO by Sarika Gopalakrishnan, PhD, FAAO, of the Envision Research Institute in Wichita, Kansas, found that visual function improvement was seen in patients with low vision (n=100) after using an AR device.<sup>3</sup> At baseline, 21 percent of patients had

central field loss, 35 percent had peripheral field loss and 44 percent had overall blurred vision. Common causes for moderate and severe visual impairment included myopic macular degeneration, cone dystrophy, retinitis pigmentosa and optic atrophy. After using the AR device, patients demonstrated significant improvements in distance vision (1.1 to 0.15 logMAR), near vision (0.6 to 0.3 logMAR) and two-week visual function score (VA LV VFQ-48; 0.35 to 1.90).

Retinal engineering and retinal



**When I see these patients, some of the questions that come to mind are:**

**How can we find you sooner? Is there a technology we can use to identify fast progressors or those at the end of their disease? Is there anything we can offer these patients to enhance their lives despite vision loss from glaucoma?**



ganglion cell replacement are two other promising avenues for glaucoma care. Retinal ganglion cell death is irreversible, but repopulation approaches have the potential to reverse optic neuropathy-associated vision loss, provided that the transplanted cells establish themselves.

Currently, the RReSTORE (Retinal ganglion cell Repopulation, Stem cell Transplantation, and Optic nerve Regeneration) Consortium, is attempting to overcome barriers to vision replacement in patients with optic neuropathies.<sup>4</sup> The Consortium's goals include defining and prioritizing the most critical challenges and questions related to retinal ganglion cell regeneration; brainstorming innovative tools and experimental approaches to meet

these challenges; and fostering collaborative scientific research among diverse investigators.

RReSTORE Consortium program leader, Thomas V. Johnson, MD, PhD, of the Wilmer Eye Institute, Johns Hopkins School of Medicine, explained in his ARVO presentation<sup>5</sup> that the group is currently developing techniques to differentiate retinal ganglion cells from human stem cells and how to enhance the transplantation of retinal ganglion cells into live retina. His group found that the internal limiting membrane was a barrier to retinal cell engrafting and is working to evaluate other cell integration approaches. The Consortium will hold a mini-symposium on the topic at this year's ARVO 2024 in Seattle.

In summary, there are several exciting developments in glaucomatology that have the potential to alter the course of clinical treatment. Many of these discoveries in imaging, artificial intelligence, augmented reality and stem cell science have clear translational potential. ◀

1. Owlser J, Daws RE, Lotery P, et al. Abnormal retinal apoptosis morphometry in glaucoma and optic neuritis. *Invest Ophthalmol Vis Sci* 2023;64:8:4676.
2. Abbasi A, Antony BJ, Gowrisankaran S, et al. Can glaucoma suspect data help to improve the performance of glaucoma diagnosis? *Transl Vis Sci Technol* 2023;12:6.
3. Gopalakrishnan S. Role of head mounted augmented reality device in improving visual function of individuals with low vision. *Invest Ophthalmol Vis Sci* 2023;64:5522.
4. Johnson TV, Baranov P, Di Polo A, Ross AG, et al. The Retinal ganglion cell Repopulation, Stem cell Transplantation, and Optic nerve Regeneration Consortium. *Ophthalmology Science* 2023. [Epub August 24, 2023].
5. Johnson T. Retinal engineering and RGC replacement: Enhancing integration of transplanted RGCs. *Invest Ophthalmol Vis Sci* 2023;64:929.

## ABOUT THE AUTHOR



**Dr. Ross** is an assistant professor of ophthalmology and neuro-ophthalmology at the University of Pennsylvania, Scheie Eye Institute. In addition to clinical responsibilities, she leads a basic science laboratory with the goal of understanding combined molecular mechanisms of glaucoma. She also acts as a scientific consultant with Gyroscopic Therapeutics and Noveome Therapeutics. She holds a patent for gene therapy for ocular disorders.



EDITED BY COLLIN ROZANSKI, MD

## WILLS EYE RESIDENT CASE REPORT

# A 72-year-old man presents for evaluation of plaque-like swelling on the right upper eyelid.

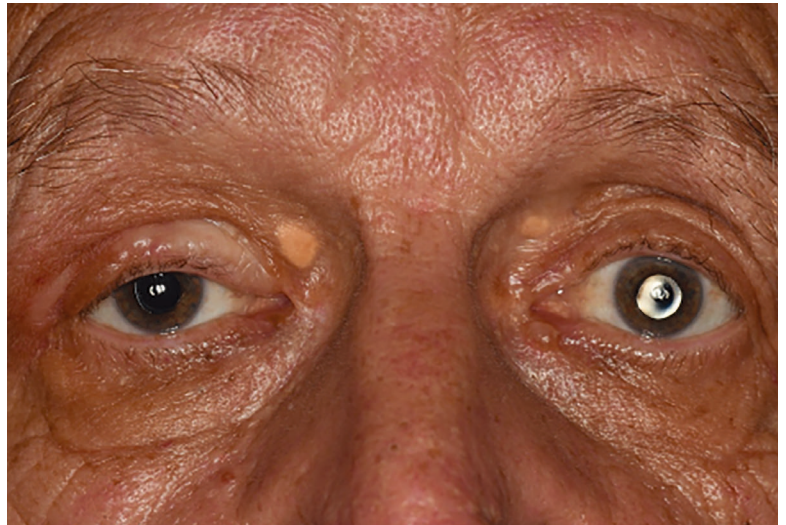BRIAN T. CHENG, MD, SARA E. LALLY, MD, CAROL L. SHIELDS, MD, AND TATYANA MILMAN, MD  
PHILADELPHIA

### Presentation

A 72-year-old Caucasian male was referred to the Ocular Oncology Service at Wills Eye Hospital for a plaque-like lesion on the right upper eyelid. He had noticed thickening of the right upper eyelid and development of a hard nodule one year prior. An incisional biopsy by the referring oculoplastic surgeon revealed an atypical vascular neoplasm. The patient had no cervical lymphadenopathy and was otherwise asymptomatic.

### History

Past ocular history was unremarkable aside from previous cataract surgery in both eyes. Past medical history was notable for chronic obstructive pulmonary disease and benign prostatic hyperplasia. He had previous surgical replacement of both hip joints and lumbar spinal fusion. The patient had no history of cancer, including skin cancer. Family history included liver cancer in his father, macular degeneration in his mother and systemic lupus erythematosus in his sister. Social history was significant for previous tobacco use, though he quit smoking more than 50 years ago. There was no social or occupational history of extensive ultraviolet light or radiation exposure. Current medications included fluticasone-salmeterol for chronic obstructive pulmonary disease and finasteride for benign prostatic hyperplasia; he had no known drug allergies.



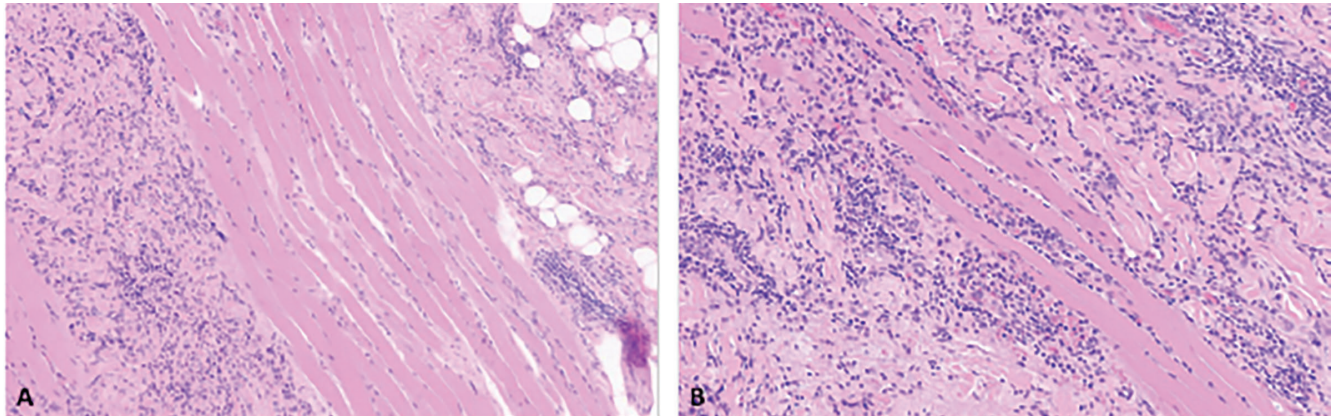
**Figure 1.** External photograph demonstrates subtle right upper eyelid mass with edema, a healed scar of prior biopsy and blepharoptosis. Bilateral xanthelasmata are also present superonasally.

### Examination

Visual acuity was 20/20 in the right eye and 20/40 in the left eye with pinhole improvement to 20/30. Pupils were round and reactive to light with no relative afferent pupillary defect. Intraocular pressure was 14 mmHg in the right and 11 mmHg in the left eye. Examination of the eyelids and adnexa demonstrated a 40 x 30 mm, diffuse, subtly violaceous thickening of the right upper eyelid with a well-healed overlying incision (*Figure 1*). Lashes were intact. There was a 10 x 10 mm palpable nodule superior to the right lateral canthus and bilateral medial eyelid xanthelasma. Anterior segment examination was notable only for bilateral posterior capsule intraocular lenses in good position, and dilated ophthalmoscopic examination was unremarkable.

***What's your diagnosis? What management would you pursue? The case continues on the next page.***





**Figure 2. Primary eyelid angiosarcoma, initial resection, histologic findings. Infiltrative neoplasm involving adipose tissue (A) and skeletal muscle (B) composed of vascular channels lined by mildly pleomorphic spindle and ovoid cells (hematoxylin-eosin stain; 100x (A), 150x (B)).**

### Work-up, Diagnosis and Treatment

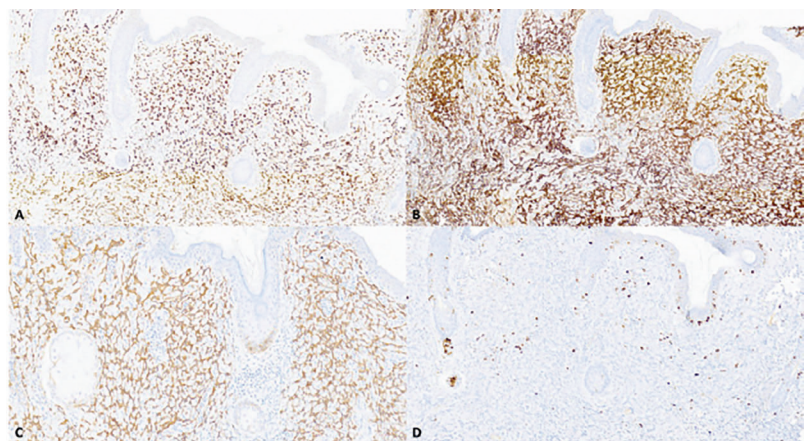
Pathology review of prior biopsy and discussion at the multidisciplinary tumor board led to a working differential of low-grade angiosarcoma vs. possible benign and borderline vascular neoplasms, such as hemangioma and hemangioendothelioma. Magnetic resonance imaging of the orbits showed a thickened enhanced right upper eyelid, without a discrete mass or lymphadenopathy. Six weeks after initial referral to ocular oncology, the patient was taken to the operating room for incisional biopsy. Histopathologic examination showed an infiltrating neoplasm composed of vascular channels lined by mildly pleomorphic spindle and ovoid cells. Mitotic figures were not conspicuous. There was no evidence of necrosis (*Figure 2*). Neoplastic cells co-expressed vascular and lymphatic endothelial markers erythroblast transformation-specific [ETS]-related gene (ERG) and CD31, and lymphatic endothelial marker D2-40 (*Figure 3A-C*). Neoplastic cells were negative for human herpes virus-8 (HHV8), excluding the diagnosis of Kaposi sarcoma. The Ki-67 proliferative index was low (*Figure 3D*). Although there were no high-grade morphologic features typical of angiosarcoma, the infiltrative pattern of this vascular proliferation was concerning for well-differentiated angiosarcoma.

After discussion at the orbital tumor board, the decision was made to observe the patient closely given the low-grade morphology and low risk for metastatic disease.

Six months later, repeat MRI demonstrated interval increased enhancement of the right upper eyelid and no orbital or lacrimal mass. The patient underwent repeat biopsy 11 months after initial presentation to ocular oncology, which showed a neoplasm morphologically and immunohistochemically similar to the initial biopsies. Because of the locally aggressive behavior of the tumor, the patient underwent systemic neoadjuvant chemotherapy with taxol prior to a definitive tumor resection. Histopathologic evaluation of the resected tumor showed an infiltrative vascular neoplasm with a more complex architecture when compared to the initial biopsies, supporting the diagnosis of well-differentiated angiosarcoma (*Figure 4*).

### Discussion

Primary angiosarcoma of the eyelid is a rare and aggressive sarcoma that shows vascular and lymphatic endothelial cell differentiation. Ultraviolet light exposure and radiation exposure are well-recognized risk factors for angiosarcoma of the head and neck skin, including the eyelid.<sup>1</sup> Diagnosis of eyelid angiosarcoma can be difficult because the presenting clinical features are diverse and may be subtle. In a systematic review of 42 eyelid angiosarcoma cases, this neoplasm was most commonly

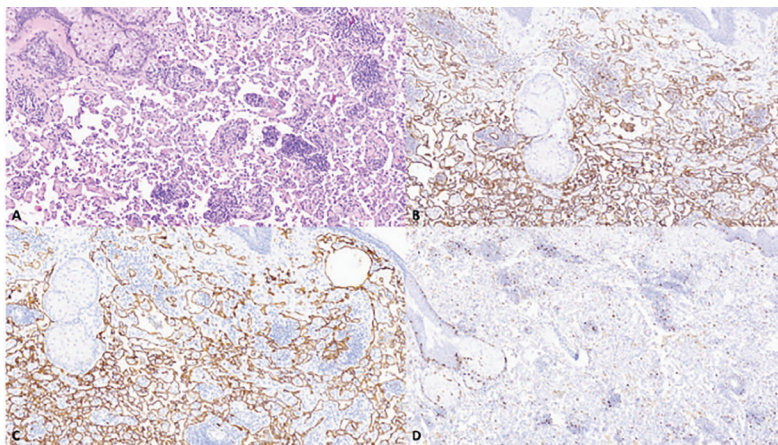


**Figure 3. Primary eyelid angiosarcoma, initial resection, immunohistochemical findings. The neoplastic cells express erythroblast transformation-specific [ETS]-related gene [ERG] (A), CD31 (B) and D2-40 (C). The Ki-67 proliferative index is low (<1%) (D). All images are 100x magnification.**

described as having reddish, erythematous color and less frequently has been reported to appear violaceous, yellow, brown or without any change in color.<sup>2</sup> The lesion shape was frequently described as a papular or plaque-like mass or edema of the eyelid. However, there were also cases of color change without any apparent induration or tumefaction.<sup>3</sup> As such, eyelid angiosarcoma may be a difficult diagnosis to make clinically and is frequently misdiagnosed prior to biopsy.<sup>4,5</sup> The most frequent preoperative diagnoses for primary eyelid angiosarcoma are cellulitis (19 percent), angioedema (12 percent) and hematoma (5 percent).<sup>2</sup> Therefore, for erythematous eyelid swelling or mass-like lesions that don't appear to resolve with initial anti-inflammatory therapy, clinicians may consider biopsy to exclude this malignancy.

Histopathologic diagnosis of eyelid angiosarcoma can be particularly challenging. Angiosarcomas are usually high-grade neoplasms. However, eyelid angiosarcoma shows a spectrum of histopathologic findings, ranging from well-differentiated to poorly-differentiated tumors.<sup>4,5</sup> Well-differentiated angiosarcomas are characterized by endothelial cells with mild nuclear atypia and few mitotic figures, similar to benign vascular lesions such as hemangioma and pyogenic granuloma. In these cases, an infiltrative growth pattern should raise your suspicion of malignancy, but the diagnosis is challenging in a small biopsy as exemplified by our patient's tumor. Poorly differentiated angiosarcomas are typically composed of markedly atypical cells, frequently with epithelioid morphology and markedly pleomorphic nuclei in complex arrangements or in sheets, raising consideration of poorly differentiated carcinoma and other sarcomas. Immunohistochemical staining can help in these challenging cases. Angiosarcoma frequently co-expresses vascular and lymphatic endothelial markers (ERG, CD31, and D2-40) and is negative for HHV8, which excludes Kaposi sarcoma.

The four-year overall survival of patients with eyelid angiosarcoma was 49 percent in a review of previously published cases.<sup>2</sup> Patients with angiosarcoma isolated to the eyelid had 100-percent survival, and those with diffuse disease involving adjacent facial structures had 57-percent survival at three years.<sup>3</sup> The data on the prognostic value of tumor differentiation in periocular angiosarcoma are mixed and limited.<sup>6</sup> Some studies suggest that poorly differentiated tumors with epithelioid morphology and necrosis are associated with increased mortality.<sup>3,7,8</sup> Treatment varies by location and characteristics of the angiosarcoma, but typically involves a combination of surgical resection, chemotherapy and radiotherapy. The rarity of periocular angiosarcoma means there is little data to guide formal recommendations for treatment. Surgical resection of eyelid angiosarcoma is associated with significantly decreased mortality and recurrence, compared to patients who receive chemotherapy,



**Figure 4. Primary eyelid angiosarcoma, recurrent lesion. Recurrent lesion has a more complex architecture when compared to the initial resection (A). The complex vascular network is highlighted with CD31 (B) and D2-40 (C). Low Ki-67 proliferative index (<1%) (D). All images are 100x magnification.**

radiotherapy, or combined chemotherapy and radiotherapy.<sup>2</sup> However, complete resection is often challenging because of the tendency to widely infiltrate along the skin and other periocular tissues. Another analysis of cutaneous angiosarcoma involving the periorbital area reported a 60-percent recurrence among patients who underwent neoadjuvant chemotherapy alone and a 40-percent recurrence in patients who underwent surgical resection with adjuvant chemotherapy or radiotherapy.<sup>9</sup> As such, patients with lid angiosarcoma require close follow-up to monitor for recurrence, regardless of treatment.

This case of primary eyelid angiosarcoma is unusual because angiosarcoma typically involves the scalp, forehead, and face and may secondarily extend into the eyelid. However, primary eyelid angiosarcoma is very rare, with fewer than 50 patients reported in the literature. The diagnosis is challenging because eyelid angiosarcoma can mimic the features of many other benign and malignant eyelid lesions. ◀

1. Painter CA, Jain E, Tomson BN, et al. The Angiosarcoma Project: Enabling genomic and clinical discoveries in a rare cancer through patient-partnered research. *Nature Medicine* 2020;26:2:181-187.

2. Hwang G, Shin J, Lee JY, et al. The eyelid angiosarcoma: A systematic review of characteristics and clinical course. *J Clin Med* 2022;11:14.

3. Papalas JA, Manavi CK, Woodward JA, Sanguenza OP, Cummings TJ. Angiosarcoma of the eyelid: A clinicopathologic comparison between isolated unilateral tumors and tumors demonstrating extrapalpebral involvement. *Am J Dermatopathol* 2010;32:7:694-699.

4. Ferguson DC, Mawn LA, Al-Rohil RN. Cutaneous angiosarcoma of the eyelid mimicking morbihan disease. *Am J Dermatopathol* 2018;40:8:617-620.

5. Milman T, Shields CL, Brooks JSJ, et al. Primary cutaneous angiosarcoma of the eyelid: A diagnostic and therapeutic challenge. *Ocul Oncol Pathol* 2018;4:4:230-235.


6. Shustef E, Kazlouskaya V, Prieto VG, Ivan D, Aung PP. Cutaneous angiosarcoma: A current update. *J Clin Pathol* 2017;70:11:917-925.

7. Dettenborn T, Wermker K, Schulze HJ, Klein M, Schwipper V, Hallermann C. Prognostic features in angiosarcoma of the head and neck: A retrospective monocenter study. *J Craniomaxillofac Surg* 2014;42:8:1623-1628.

8. Deyrup AT, McKenney JK, Tighiouart M, Folpe AL, Weiss SW. Sporadic cutaneous angiosarcomas: A proposal for risk stratification based on 69 cases. *Am J Surg Pathol* 2008;32:1:72-77.

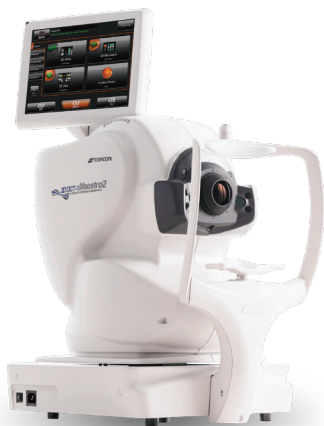9. DeMartelere SL, Roberts D, Burgess MA, et al. Neoadjuvant chemotherapy-specific and overall treatment outcomes in patients with cutaneous angiosarcoma of the face with periorbital involvement. *Head & Neck* 2008;30:5:639-646.



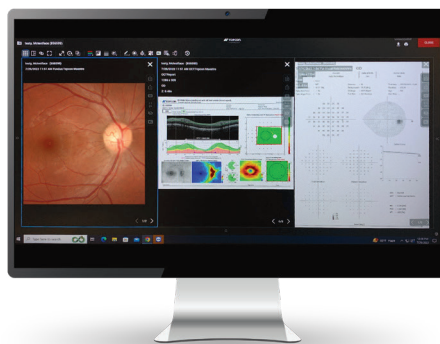


# NEW! Glaucoma Management Suite

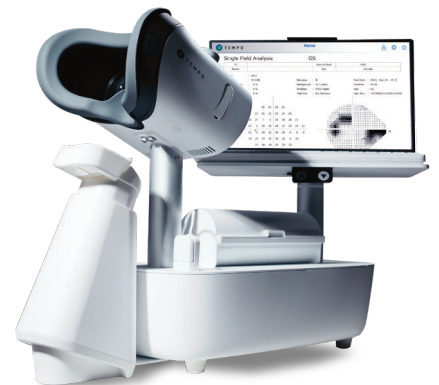Combine the power of Maestro2 structural imaging with TEMPO™ visual field function through Topcon Harmony® clinical data management.



**MAESTRO2**  
OCT & Color  
Fundus Camera



**HARMONY®**  
Clinical Data  
Management



**TEMPO™**  
Visual Field  
Analyzer

Visit [topconhealthcare.com/glaucomasuite](https://topconhealthcare.com/glaucomasuite) to learn more.




MCA #5328

©2024 Topcon Healthcare | [topconhealthcare.com](https://topconhealthcare.com)

 **TOPCON Healthcare**

iStent  
infinite® ...

THE POWER OF 3



## The Beginning of the Interventional Glaucoma Revolution

# infinite possibilities

Brought to you by the founder of MIGS, iStent infinite® is the first-ever micro-invasive, standalone implantable alternative. Built on the #1 MIGS platform worldwide, it is designed to provide powerful technology that delivers foundational, 24/7, long-term IOP control in glaucoma patients who have failed prior medical and surgical intervention.<sup>1</sup>

#### REFERENCE

1. Glaukos Data on File.

#### iStent infinite® IMPORTANT SAFETY INFORMATION

**INDICATION FOR USE.** The iStent infinite® Trabecular Micro-Bypass System Model iS3 is an implantable device intended to reduce the intraocular pressure (IOP) of the eye. It is indicated for use in adult patients with primary open-angle glaucoma in whom previous medical and surgical treatment has failed. **CONTRAINDICATIONS.** The iStent infinite is contraindicated in eyes with angle-closure glaucoma where the angle has not been surgically opened, acute traumatic, malignant, active uveitic, or active neovascular glaucoma, discernible congenital anomalies of the anterior chamber (AC) angle, retrobulbar tumor, thyroid eye disease, or Sturge-Weber Syndrome or any other type of condition that may cause elevated episcleral venous pressure. **WARNINGS.** Gonioscopy should be performed prior to surgery to exclude congenital anomalies of the angle, PAS, rubeosis, or conditions that would prohibit adequate visualization that could lead to improper placement of the stent and pose a hazard. **MRI INFORMATION.** The iStent infinite is MR-Conditional, i.e., the device is safe for use in a specified MR environment under specified conditions; please see Directions for Use (DFU) label for details. **PRECAUTIONS.** The surgeon should monitor the patient postoperatively for proper maintenance of IOP. Three out of 61 participants (4.9%) in the pivotal clinical trial were phakic. Therefore, there is insufficient evidence to determine whether the clinical performance of the device may be different in those who are phakic versus in those who are pseudophakic. **ADVERSE EVENTS.** The most common postoperative adverse events reported in the iStent infinite pivotal trial included IOP increase  $\geq 10$  mmHg vs. baseline IOP (8.2%), loss of BSCVA  $\geq 2$  lines (11.5%), ocular surface disease (11.5%), perioperative inflammation (6.6%) and visual field loss  $\geq 2.5$  dB (6.6%). **CAUTION:** Federal law restricts this device to sale by, or on the order of, a physician. Please see DFU for a complete list of contraindications, warnings, precautions, and adverse events.

Glaukos® and iStent infinite® are registered trademarks of Glaukos Corporation. All rights reserved. ©2022

PM-US-0909

GLAUKOS®