

Wills Eye Resident Series: Blurred vision and metamorphopsia in a young woman, p. 72

# REVIEW<sup>®</sup> of OPTHALMOLOGY

September 2023 • [reviewofophthalmology.com](http://reviewofophthalmology.com)

Clinical advice you can trust

## REFRACTIVE/CATARACT RUNDOWN

Tips for LASIK Enhancements  
PAGE 16

## GLAUCOMA MANAGEMENT

Steroid-induced Glaucoma  
PAGE 57

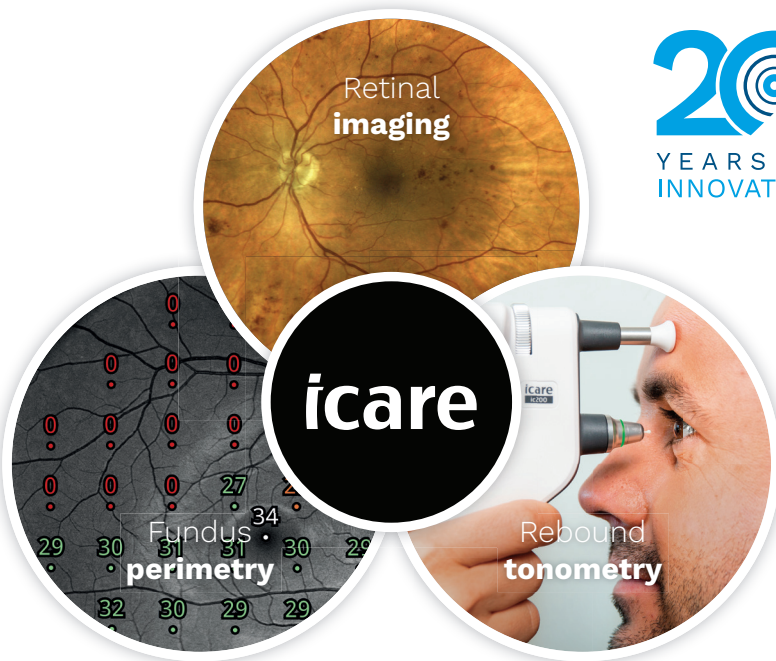
## RETINAL INSIDER

Illuminating Fundus Autofluorescence  
PAGE 61

## How to Diagnose The Red Eye

You know us  
for tonometry.

Get to know  
iCare for  
imaging and  
perimetry.



Discover the next level of eye care  
with our full line of devices.

Scan or visit [www.icare-world.com/USA](http://www.icare-world.com/USA)



iCare COMPASS

# More than a standard perimeter



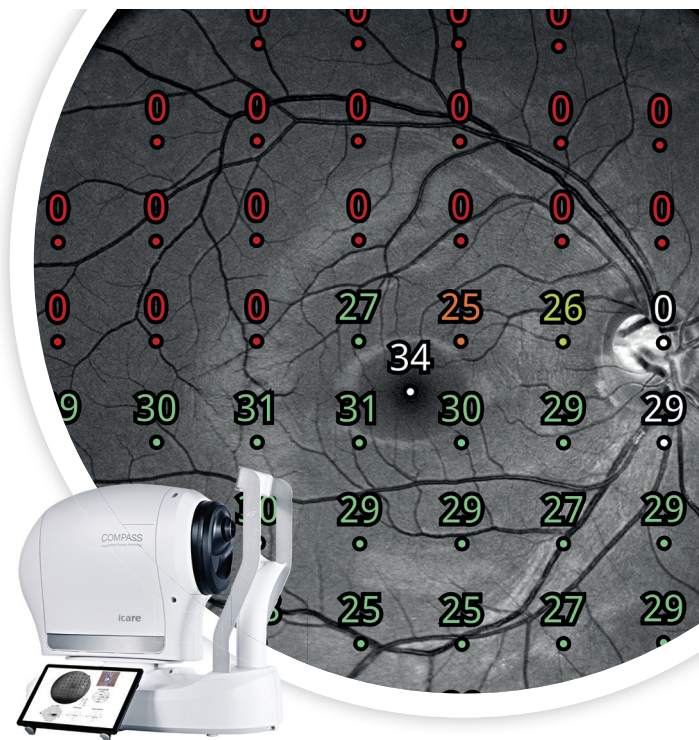
Unique technology combining a visual field test with fundus imaging



Active retinal tracking compensates for eye movements creating reliable, repeatable results



Auto-focus capability omits the need for trial lenses eliminating ring artifacts



Discover the next level of eye care with our full line of devices.

Scan or visit [www.icare-world.com/USA](http://www.icare-world.com/USA)

**icare**  
For better perception



Wills Eye Resident Series: Blurred vision and metamorphopsia in a young woman, p. 72

# REVIEW<sup>®</sup> *of* OPHTHALMOLOGY

September 2023 • [reviewofophthalmology.com](http://reviewofophthalmology.com)

Clinical advice you can trust

## How to Diagnose The Red Eye

*With careful examination and history-taking, most unusual causes of red eye can be uncovered. P. 40*

### Also inside

- Dry-eye Treatment Continues to Evolve P. 24
- How Experts Evaluate the Dry-eye Patient P. 34
- IOL Fixation: Tried-and-True Techniques P. 48

### REFRACTIVE/CATARACT RUNDOWN

Tips for LASIK Enhancements

PAGE 16

### GLAUCOMA MANAGEMENT

Steroid-induced Glaucoma

PAGE 57

### RETINAL INSIDER

Illuminating Fundus Autofluorescence

PAGE 61



## TREAT DRY EYE FLARES FIRST & FAST<sup>1\*</sup>

EYSUVIS<sup>®</sup> IS DESIGNED TO GO  
DEEP TO DELIVER LOTEPREDNOL NANOPARTICLES  
TO THE SITE OF INFLAMMATION<sup>2,3</sup>

Start with EYSUVIS<sup>®</sup> – the  
first and only FDA-approved  
corticosteroid for the  
short-term treatment of  
dry eye (up to 2 weeks).<sup>4,5</sup>

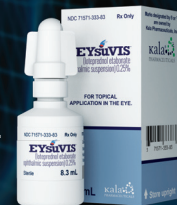EYSUVIS<sup>®</sup>, with proprietary AMPPLIFY Drug Delivery Technology, is designed to deliver loteprednol nanoparticles to the sites of ocular surface inflammation, where dry eye flares start.<sup>2,3</sup>

EYSUVIS<sup>®</sup> goes to work fast and provides rapid improvement of ocular discomfort, with results as early as Day 4 after starting treatment.<sup>1\*</sup>

Go deep to treat dry eye with EYSUVIS<sup>®</sup>.<sup>2,3</sup>

ACCESS  
GRANTED

**EYSUVIS<sup>®</sup>**  
(loteprednol etabonate  
ophthalmic suspension) 0.25%



\*The safety and efficacy of EYSUVIS<sup>®</sup> was assessed in 4 multicentered, randomized, double masked, placebo-controlled trials in 2,871 patients with documented Dry Eye Disease. Patients received either EYSUVIS<sup>®</sup> or vehicle 4 times a day for at least 2 weeks. In one Phase 3 study, patients using EYSUVIS<sup>®</sup> showed significant reduction in the symptoms of dry eye (ocular discomfort) as early as Day 4 after starting treatment (vs. vehicle). Symptom improvement continued up to the end of the treatment period (Day 15, primary endpoint). Patients using EYSUVIS<sup>®</sup> also showed significant reduction in signs of dry eye (conjunctival hyperemia) at Day 15 vs. vehicle.

### INDICATION

EYSUVIS is a corticosteroid indicated for the short-term (up to two weeks) treatment of the signs and symptoms of dry eye disease.

### IMPORTANT SAFETY INFORMATION

#### Contraindication:

EYSUVIS, as with other ophthalmic corticosteroids, is contraindicated in most viral diseases of the cornea and conjunctiva including epithelial herpes simplex keratitis (dendritic keratitis), vaccinia, and varicella, and also in mycobacterial infection of the eye and fungal diseases of ocular structures.

#### Warnings and Precautions:

**Delayed Healing and Corneal Perforation:** Topical corticosteroids have been known to delay healing and cause corneal and scleral thinning. Use of topical corticosteroids in the presence of thin corneal or scleral tissue may lead to perforation. The initial prescription and each renewal of the medication order should be made by a physician only after examination of the patient with the aid of magnification, such as slit lamp biomicroscopy, and, where appropriate, fluorescein staining.

**Intraocular Pressure (IOP) Increase:** Prolonged use of corticosteroids may result in glaucoma with damage to the optic nerve, as well as defects in visual acuity and fields of vision. Corticosteroids should be used with caution in the presence of glaucoma. Renewal of the medication order should be made by a physician only after examination of the patient and evaluation of the IOP.

**Cataracts:** Use of corticosteroids may result in posterior subcapsular cataract formation.

**Bacterial Infections:** Use of corticosteroids may suppress the host response and thus increase the hazard of secondary ocular infections. In acute purulent conditions, corticosteroids may mask infection or enhance existing infection.

**Viral Infections:** Use of a corticosteroid medication in the treatment of patients with a history of herpes simplex requires great caution. Use of ocular corticosteroids may prolong the course and may exacerbate the severity of many viral infections of the eye (including herpes simplex).

**Fungal Infections:** Fungal infections of the cornea are particularly prone to develop coincidentally with long-term local corticosteroid application. Fungus invasion must be considered in any persistent corneal ulceration where a corticosteroid has been used or is in use.

#### Adverse Reactions:

The most common adverse drug reaction following the use of EYSUVIS for two weeks was instillation site pain, which was reported in 5% of patients.

Please see Brief Summary of Full Prescribing Information on the following page.

**REFERENCES:** **1.** Holland E, Nichols K, Foulks G, et al. Safety and efficacy of KPI-121 ophthalmic suspension 0.25% for dry eye disease in four randomized controlled trials. Presented at: AAO 2020; November 13-15, 2020; virtual meeting. **2.** Schopf L, Enlow E, Popov A, et al. Ocular pharmacokinetics of a novel loteprednol etabonate 0.4% ophthalmic formulation. *Ophthalmol Ther.* 2014;3(1-2):63-72. **3.** Popov A. Mucus-penetrating particles and the role of ocular mucus as a barrier to micro- and nanosuspensions. *J Ocul Pharmacol Ther.* 2020;36(6): 366-375. **4.** Alcon Data on File, 2022. **5.** Alcon Data on File, 2022.



## BRIEF SUMMARY OF FULL PRESCRIBING INFORMATION

### INDICATIONS AND USAGE

EYSUVIS is a corticosteroid indicated for the short-term (up to two weeks) treatment of the signs and symptoms of dry eye disease.

### CONTRAINDICATIONS

EYSUVIS, as with other ophthalmic corticosteroids, is contraindicated in most viral diseases of the cornea and conjunctiva including epithelial herpes simplex keratitis (dendritic keratitis), vaccinia, and varicella, and also in mycobacterial infection of the eye and fungal diseases of ocular structures.

### WARNINGS AND PRECAUTIONS

**Delayed Healing and Corneal Perforation**—Topical corticosteroids have been known to delay healing and cause corneal and scleral thinning. Use of topical corticosteroids in the presence of thin corneal or scleral tissue may lead to perforation. The initial prescription and each renewal of the medication order should be made by a physician only after examination of the patient with the aid of magnification, such as slit lamp biomicroscopy, and, where appropriate, fluorescein staining. **Intraocular Pressure (IOP) Increase**—Prolonged use of corticosteroids may result in glaucoma with damage to the optic nerve, as well as defects in visual acuity and fields of vision. Corticosteroids should be used with caution in the presence of glaucoma. Renewal of the medication order should be made by a physician only after examination of the patient and evaluation of the IOP. **Cataracts**—Use of corticosteroids may result in posterior subcapsular cataract formation. **Bacterial Infections**—Use of corticosteroids may suppress the host response and thus increase the hazard of secondary ocular infections. In acute purulent conditions of the eye, corticosteroids may mask infection or enhance existing infection. **Viral Infections**—Use of corticosteroid medication in the treatment of patients with a history of herpes simplex requires great caution. Use of ocular corticosteroids may prolong the course and may exacerbate the severity of many viral infections of the eye (including herpes simplex). **Fungal Infections**—Fungal infections of the cornea are particularly prone to develop coincidentally with long-term local corticosteroid application. Fungus invasion must be considered in any persistent corneal ulceration where a corticosteroid has been used or is in use. Fungal cultures should be taken when appropriate. **Risk of Contamination**—Do not to allow the dropper tip to touch any surface, as this may contaminate the suspension. **Contact Lens Wear**—The preservative in EYSUVIS may be absorbed by soft contact lenses. Contact lenses should be removed prior to instillation of EYSUVIS and may be reinserted 15 minutes following administration.

### ADVERSE REACTIONS

Adverse reactions associated with ophthalmic corticosteroids include elevated intraocular pressure, which may be associated with infrequent optic nerve damage, visual acuity and field defects, posterior subcapsular cataract formation, delayed wound healing and secondary ocular infection from pathogens including herpes simplex, and perforation of the globe where there is thinning of the cornea or sclera. **Clinical Trials Experience**—Because clinical trials are conducted under widely varying conditions, adverse reaction rates observed in the clinical trials of a drug cannot be directly compared to rates in the clinical trials of another drug and may not reflect the rates observed in practice. The most common adverse reaction observed in clinical trials with EYSUVIS was instillation site pain, which was reported in 5% of patients.

### USE IN SPECIFIC POPULATIONS

**Pregnancy**—Risk Summary: There are no adequate and well controlled studies with loteprednol etabonate in pregnant women. Loteprednol etabonate produced teratogenicity at clinically relevant doses in the rabbit and rat when administered orally during pregnancy. Loteprednol etabonate produced malformations when administered orally to pregnant rabbits at doses 1.4 times the recommended human ophthalmic dose (RHOD) and to pregnant rats at doses 34 times the RHOD. In pregnant rats receiving oral doses of loteprednol etabonate during the period equivalent to the last trimester of pregnancy through lactation in humans, survival of offspring was reduced at doses 3.4 times the RHOD. Maternal toxicity was observed in rats at doses 347 times the RHOD, and a maternal no observed adverse effect level (NOAEL) was established at 34 times the RHOD. The background risk in the U.S. general population of major birth defects is 2 to 4%, and of miscarriage is 15 to 20%, of clinically recognized pregnancies. Data: Animal Data. Embryofetal studies were conducted in pregnant rabbits administered loteprednol etabonate by oral gavage on gestation days 6 to 18, to target the period of organogenesis.

Loteprednol etabonate produced fetal malformations at 0.1 mg/kg (1.4 times the recommended human ophthalmic dose (RHOD) based on body surface area, assuming 100% absorption). Spina bifida (including meningocele) was observed at 0.1 mg/kg, and exencephaly and craniofacial malformations were observed at 0.4 mg/kg (5.6 times the RHOD). At 3 mg/kg (41 times the RHOD), loteprednol etabonate was associated with increased incidences of abnormal left common carotid artery, limb flexures, umbilical hernia, scoliosis, and delayed ossification. Abortion and embryofetal lethality (resorption) occurred at 6 mg/kg (83 times the RHOD). A NOAEL for developmental toxicity was not established in this study. The NOAEL for maternal toxicity in rabbits was 3 mg/kg/day. Embryofetal studies were conducted in pregnant rats administered loteprednol etabonate by oral gavage on gestation days 6 to 15, to target the period of organogenesis. Loteprednol etabonate produced fetal malformations, including absent innominate artery at 5 mg/kg (34 times the RHOD); and cleft palate, agnathia, cardiovascular defects, umbilical hernia, decreased fetal body weight and decreased skeletal ossification at 50 mg/kg (347 times the RHOD). Embryofetal lethality (resorption) was observed at 100 mg/kg (695 times the RHOD). The NOAEL for developmental toxicity in rats was 0.5 mg/kg (3.4 times the RHOD). Loteprednol etabonate was maternally toxic (reduced body weight gain) at 50 mg/kg/day. The NOAEL for maternal toxicity was 5 mg/kg. A peri-/postnatal study was conducted in rats administered loteprednol etabonate by oral gavage from gestation day 15 (start of fetal period) to postnatal day 21 (the end of lactation period). At 0.5 mg/kg (3.4 times the clinical dose), reduced survival was observed in live-born offspring. Doses  $\geq$  5 mg/kg (34 times the RHOD) caused umbilical hernia/incomplete gastrointestinal tract. Doses  $\geq$  50 mg/kg (347 times the RHOD) produced maternal toxicity (reduced body weight gain, death), decreased number of live-born offspring, decreased birth weight, and delays in postnatal development. A developmental NOAEL was not established in this study. The NOAEL for maternal toxicity was 5 mg/kg. **Lactation**—There are no data on the presence of loteprednol etabonate in human milk, the effects on the breastfed infant, or the effects on milk production. The developmental and health benefits of breastfeeding should be considered, along with the mother's clinical need for EYSUVIS and any potential adverse effects on the breastfed infant from EYSUVIS. **Pediatric Use**—Safety and effectiveness in pediatric patients have not been established. **Geriatric Use**—No overall differences in safety and effectiveness have been observed between elderly and younger adult patients.

### NONCLINICAL TOXICOLOGY

**Carcinogenesis, Mutagenesis, Impairment of Fertility**—Long-term animal studies have not been conducted to evaluate the carcinogenic potential of loteprednol etabonate. Loteprednol etabonate was not genotoxic in vitro in the Ames test, the mouse lymphoma thymidine kinase (tk) assay, in a chromosome aberration test in human lymphocytes, or in vivo in the single dose mouse micronucleus assay. Treatment of male and female rats with 25 mg/kg/day of loteprednol etabonate (174 times the RHOD based on body surface area, assuming 100% absorption) prior to and during mating caused pre-implantation loss and decreased the number of live fetuses/live births. The NOAEL for fertility in rats was 5 mg/kg/day (34 times the RHOD).

**For a copy of the Full Prescribing Information, please visit [www.eysuvis-ecp.com/](http://www.eysuvis-ecp.com/)**

Manufactured for:  
Kala Pharmaceuticals, Inc.  
Watertown, MA 02472

Marks designated by <sup>™</sup> or <sup>®</sup> are owned by Kala Pharmaceuticals, Inc.  
Patented. [WWW.KALARX.COM/PATENTS](http://WWW.KALARX.COM/PATENTS)

© 2020 Kala Pharmaceuticals, Inc. All rights reserved. US-EYS-2300027

PI Version Date: 10/2020

  
**EYSUVIS**<sup>®</sup>  
(loteprednol etabonate  
ophthalmic suspension) 0.25%

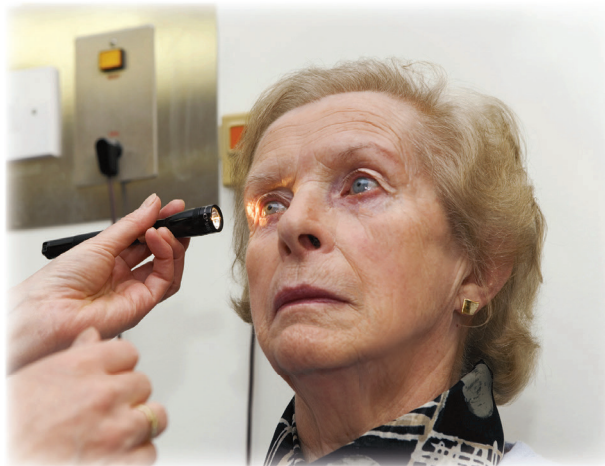## Hospital EDs Strained by Neuro-ophthalmology Consults

The suggested workforce-to-population ratio required for adequate delivery of neuro-ophthalmology services has been estimated to be one specialist per 1.2 million people. However, in 2022 only eight U.S. states met this threshold; in the worst-served areas, six had no neuro-ophthalmologists in the entire state. With increasing outpatient demand, and the subspecialty's scarcity, one new study wanted to determine what the typical presentations to the emergency department for related issues look like.

The prospective study published in *Ophthalmology* included one academic care institution's ED and inpatient neuro-ophthalmology consultation patterns and patient outcomes over one year.<sup>1</sup> Of the 494 consecutive adult consultations, 49 percent took place at night or on weekends. Of the emergency consults (65 percent), 39 percent of these occurred during weekdays, 39 percent on weekends and 22 percent on weekends/holidays. Of 322 ED consultations, 70 percent presented with a chief neuro-ophthalmic complaint.

Referrals to the ED by health-care professionals were primarily made by eye-care specialists (76 percent, 196 patients). Most commonly encountered questions for emergency referral were due to papilledema at 23 percent and vision loss at 22 percent. A sizable

68 percent had a final active neuro-ophthalmic diagnosis, 69 percent had high or very high complexity and 44 percent needed admission.



Science Source

Of the remaining 172 inpatient consultations, most were requested by hospitalists, including neurologists (41 percent) and oncologists (12 percent) for vision loss (25 percent) and eye movement disorders (20 percent), as well as neurosurgery (33 percent) to examine for mass or preoperative evaluation (11 percent). Active neuro-ophthalmic diagnosis was confirmed in 67 percent of patients, and a striking 90 percent of cases found neuro-ophthalmic assessment appropriate to make a diagnosis or evaluate for ophthalmic manifestations of disease. Follow-up with outpatient neuro-ophthalmology was required in 59 percent of patients.

The study authors note that overall,

61 percent of patients were diagnosed with a life- or vision-threatening pathology. Of the 49 percent of consultations occurring during off-hours, only 25 percent of these were urgent—highlighting “the paradoxical relationship between the additional burden generated by these unscheduled urgent neuro-ophthalmology consultations and the genuine need for these patients to be examined by a neuro-ophthalmologist, to whom limited access generates more such consultations.”


Driving the spikes in neuro-ophthalmology referrals or consultations are factors of delayed consultations resulting in diagnostic errors, increased cost and worse outcomes, made worse by associated risk for litigation for the provider if not done promptly. Further motivation for patient referral to hospitals than outpatient clinics is that ED or hospital evaluation is time efficient, which allows for immediate multidisciplinary care and testing which may be delayed otherwise with outpatient settings.

To deal with the rising rates, the authors propose that increasing the number of available outpatient neuro-ophthalmologists may be one solution. They also propose that “there is a need for expanded development and utilization of technological and diagnostic aids such as nonmydriatic fundus cameras in EDs as well as telehealth



# Your Complete Resource.

MERCHANDISING • SPACE PLANNING • DESIGN • SEATING • LIGHTING • OPTICAL ART



ARCHITECTURE • SPACE PLANNING • FRAME DISPLAYS • DISPENSING FURNITURE

EXAM LANES • DRY EYE • LIGHTING • SEATING • OPTICAL ART



START TODAY!

**EYEDESIGNS**  
 CUSTOM INTERIORS + FURNITURE *group*  
 800-346-8890 • www.eyedesigns.com

**VOM**  
 venture optical management™

A New **VISION** in  
**Optical Management.**

OUR FOCUS IS ON THE BUSINESS OF OPTICAL

609-472-6848 // www.VentureOpticalManagement.com

delivery processes for integration into health-care settings. Finally, creating and implementing standardized neuro-ophthalmology ED and hospital protocols for commonly encountered

presentations and diseases should facilitate rapid diagnosis and treatment of common neuro-ophthalmologic disorders.”

1. Smolar ALQ, Ray HJ, Dattilo M, et al. Neuro-ophthalmology emergency department and inpatient consultations at a large academic referral center. *Ophthalmology*. August 4, 2023. [Epub ahead of print].

---

## Apellis Gives Update on Syfovre Safety Issues

On the heels of several class action lawsuits filed against it as a result of reported safety events involving Syfovre (pegcetacoplan injection), Apellis Pharmaceuticals provided an update on company-supplied injection kits and an update on events of retinal vasculitis reported in real-world treatment with Syfovre for geographic atrophy secondary to age-related macular degeneration.

According to Apellis, eight events of retinal vasculitis (five occlusive, three non-occlusive) have been confirmed. The last confirmed event of retinal vasculitis occurred on June 20. There are also two other cases of unconfirmed retinal vasculitis from May and August.

Here is an update on the injection kits from the company:

As part of the company’s investigation into real-world safety events, internal structural variations were identified

in the specific 19-ga x 1.5-inch filter needle included in certain injection kits. Filter needles are used to withdraw treatment from the vial when preparing for an injection procedure. A causal relationship has not been established between the structural variations in this 19-ga filter needle and the rare events of retinal vasculitis in the real world. The company recommends that practitioners immediately discontinue use of any injection kits that contain the 19-ga filter needle and use injection kits with the 18-ga filter needle, which are already in distribution. While injection kits previously contained one of two types of filter needles (either 18- or 19-ga), Apellis is now exclusively distributing injection kits with the 18-ga filter needle.”

Durango, Colorado, retina specialist Sara Haug says she’s following the

company’s guidance, but that others might seek other options. “I can’t imagine the filter needles were the culprit but I have switched to using the 18-ga filter needle they suggest,” she opines. “I have also not stopped using Syfovre due to the cases of vasculitis, since the number of patients having this complication has been so low. Compared to brolicizumab which had a 1 to 2 percent complication rate, the complication rate so far with Syfovre is around 0.01 percent, I believe. I have colleagues who have stopped using Syfovre, however, due to the complications, and haven’t restarted even with the information about the filter needle. Honestly, it’s a bit hard to know what to make of it all, and I’m guessing a lot of us will switch to Izervay, as that is now approved.”

---

## Weak Relationship Between Dry Eye Signs and Symptoms

The list of potential ocular manifestations associated with dry eye disease (DED) are non-specific, comprising redness, burning, stinging, foreign body sensation, photophobia and pruritis. While DED diagnosis is dependent upon reports of ocular symptoms and measurements of signs, literature has not clearly demonstrated a link between signs and symptoms. One new study assessed this need by determining correlations among symptoms and signs of dry eye in the Dry Eye Assessment and Management (DREAM) study.<sup>1</sup>

Moderate to severe dry eye was

assessed in a total of 535 patients, using the Ocular Surface Disease Index (OSDI) for symptoms. Four DED signs were tested in both eyes, including conjunctival lissamine green staining, corneal fluorescein staining, Schirmer’s testing and tear breakup time following standard protocol at baseline and follow-up visits at three, six and 12 months.

The researchers found OSDI scores at baseline didn’t correlate with signs, but OSDI subscale score of ocular symptoms was weakly associated with corneal staining score and Schirmer test

score. There were correlations among the four signs. Correlations among changes in signs and symptoms were weaker, with the highest correlation being between change in conjunctival staining and corneal staining. Overall, the results yielded low correlation of DED symptoms with signs, even weaker correlation among changes in symptoms and signs, but low to moderate correlation among the four signs.

The study researchers, as part of their discussion, relay that the weak associations observed may be due to comorbidities that could increase the percep-



tion of ocular symptoms in dry-eye patients, such as with neuropathic pain or other chronic pain conditions. They also mention that although the OSDI subscale and ocular symptoms displayed weak association with corneal staining and Schirmer's test scores, these correlations didn't differ with sex or depression status, although were stronger in patients with Sjögren's syndrome.

Similarly, despite low correlations among the four signs of dry eye, the highest correlation was seen with corneal and conjunctival staining and was higher in the population of patients with Sjögren's.

The authors discuss how mental health disorders can also contribute to the symptom level experienced with DED, which aren't consistent with the severity of DED signs. One previous study outlined that DREAM participants with depression experienced more severe dry-eye symptoms than those without. Another observed depression to be more prevalent in DED patients and was associated with symptoms of dry eye but not signs. The current study found that the correlation was weaker between dry-eye signs and symptoms for those with depression than those without. As such, this may play a part in

some of the discordance seen between signs and symptoms, but offers no complete explanation, and is likely not the majority of causation of these findings.

These observations prompt the authors to convey that "better objective minimally invasive metrics that capture biologic changes in the eye might lead to a better assessment of the severity of ocular surface changes in DED and perhaps a better correlation with symptoms."

1. Tawfik A, Pistilli M, Maguire MG, et al. Association of dry eye symptoms and signs in patients with dry eye disease. *Ophthalmic Epidemiol.* August 17, 2023. [Epub ahead of print].

## Cataract Surgery a Boon in Acute Angle Closure Glaucoma

Sudden pressure increases that accompany acute angle closure can have devastating visual consequences. Prompt treatment is required to re-open the angle, often consisting of laser peripheral iridotomy to improve pupillary block. This approach doesn't always open up narrow angles, however. Removing the lens via phacoemulsification is an alternative approach for deepening the anterior chamber, and in fact, a recent article published in the *Journal of Cataract and Refractive Surgery* reported that phaco was both safe and effective for this purpose.<sup>1</sup>

The study included 50 eyes of

patients who underwent phaco within a week of presenting with acute angle-closure glaucoma and receiving IOP lowering treatment. All eyes were imaged and measured using anterior segment OCT and Pentacam.

The mean preoperative IOP was 40.3 mm Hg, which decreased to 14.9 mm Hg within one week of operation. Further pressure lowering was observed at postop weeks four and 12, to 12.4 and 11.44 mmHg, respectively.

The mean preoperative temporal angle width was 18.13°, which widened respectively to 32.6°, 34.6° and 36.2° at one, four and 12 weeks

postop. The mean preoperative nasal angle width also increased from 17.8° to 32.7°, 34.5° and 36.2° at postop weeks one, four and 12, respectively.

The researchers conclude in their paper that "early phacoemulsification is very effective in treating acute angle-closure glaucoma cases immediately after medical control of high intraocular pressure and resolution of corneal edema." ◀

1. Anbar MA, Mahmoud HA, Abdellah MM. Angle, anterior chamber parameters and intraocular pressure changes after early phacoemulsification in acute angle-closure glaucoma. *J Cataract Refract Surg* 2023. [Epub ahead of print].

### INDUSTRY NEWS

#### FDA Approves Eylea HD Injection 8 Mg for Treatment of Wet AMD, DME & DR

Regeneron Pharmaceuticals announced the FDA approved Eylea HD (afibercept) Injection 8 mg for the treatment of patients with wet age-related macular degeneration, diabetic macular edema and diabetic retinopathy. The recommended dose for Eylea HD is 8 mg (0.07 mL of 114.3 mg/mL solution) every four weeks (monthly) for the first three months across all indications, followed by 8 mg every eight to 16 weeks in wAMD and DME, and every eight to 12 weeks for DR.

#### Iveric Bio/Astellas Receives FDA Nod for Izervay Treatment for GA

Last month, Astellas Pharma announced that the FDA approved Izervay (avacincaptad pegol) for the treatment of geographic atrophy secondary to AMD. The company says Izervay, a new complement C5 inhibitor, is the only approved GA treatment with a statistically significant reduction ( $p < 0.01$ ) in the rate of geographic atrophy progression at the 12-month primary endpoint across two Phase III trials.

#### Oculis Announces Findings for OCS-01 in Phase III OPTIMIZE

Oculis announced topline results from its Phase

III OPTIMIZE clinical trial with OCS-01 eye drops, which the company describes as a novel, once-daily, high-concentration, preservative-free, topical Optireach formulation of dexamethasone for the treatment of inflammation and pain following ocular surgery.

#### Harrow To Sell Vigamox in the United States

Harrow received the rights to the New Drug Application for the antibiotic Vigamox (first approved in 2003). Harrow purchased the U.S. commercial rights to Vigamox in January 2023.

The Keeler logo, featuring a stylized 'K' icon followed by the word 'Keeler' in a sans-serif font.

# Take a second look at Keeler

In collaboration with clinicians, and using our expertise, Keeler are delivering new enhancements to improve yours and your patient's experience.



## The next evolution in slit lamps

- Keeler Konnect digital imaging software now comes with DICOM capabilities, so you can integrate your slit lamp into your patient management system.
- 14mm slit aperture allows you to see a larger area of the retina.
- Finer slit width diaphragm scale enabling you to precisely measure pathologies, within even smaller increments.

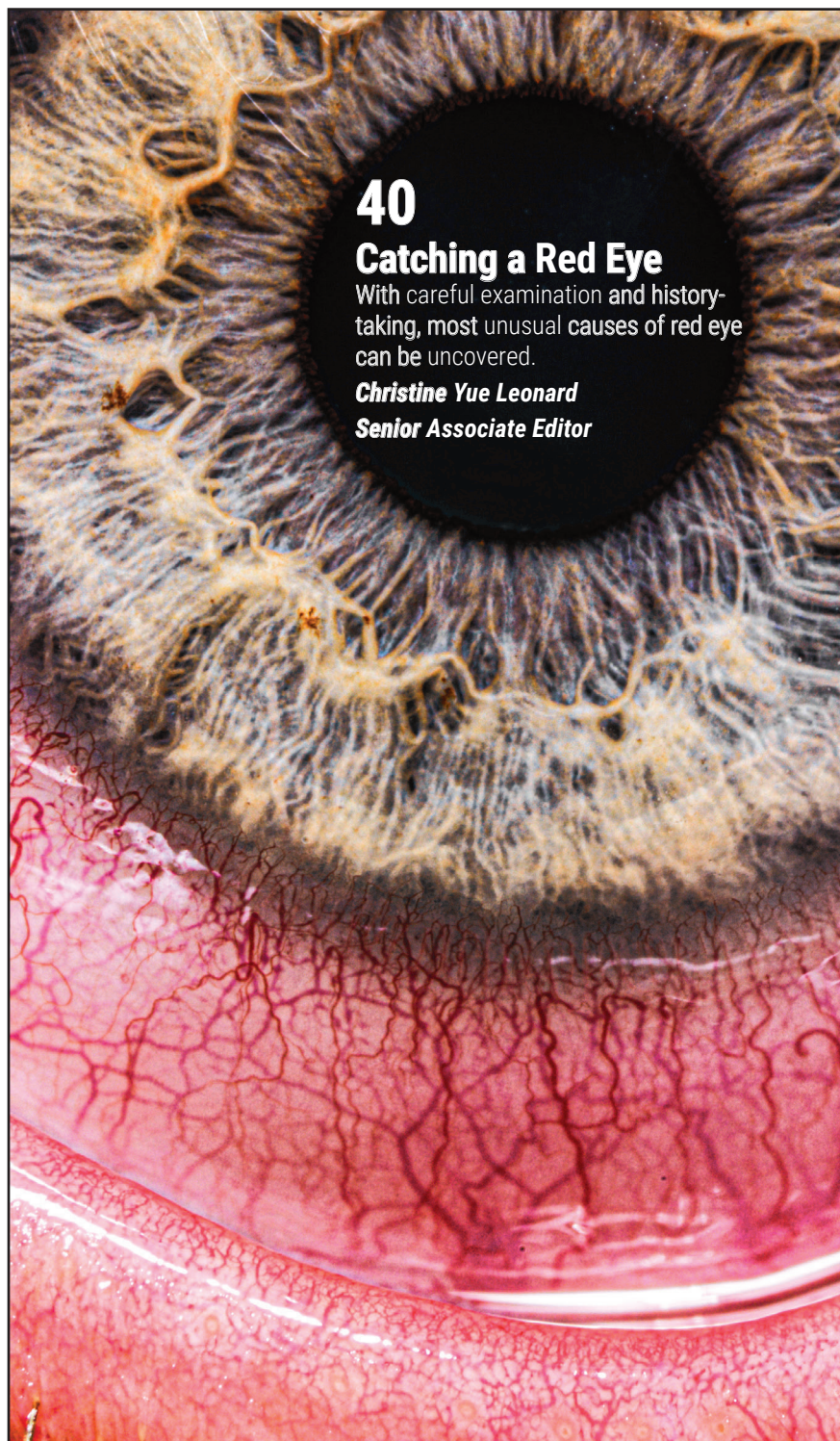



# FEATURES

Vol. XXX, No. 9 • September 2023

**Catch Up on the Latest News**  
Read *Review's* weekly newsletter  
online at [reviewofophthalmology.com](http://reviewofophthalmology.com).



**40**

## **Catching a Red Eye**

With careful examination and history-taking, most unusual causes of red eye can be uncovered.

**Christine Yue Leonard**  
*Senior Associate Editor*

**24**

## **Dry-eye Treatments Continue to Evolve**

Every year, clinicians' understanding of dry-eye disease changes as more findings and treatments surface in eye care.

**Andrew Beers**  
*Associate Editor*

**34**

## **How the Experts Diagnose Dry Eye**

Grading the severity of dry eye by assessing signs and symptoms helps ophthalmologists treat and follow dry-eye patients.

**Michelle Stephenson**  
*Contributing Editor*

**48**

## **IOL Fixation: Tried-and-true Techniques**

When faced with lack of capsular support, cataract surgeons have a variety of options to secure an IOL, each with its own strengths and flaws, say experts.

**Liz Hunter**  
*Senior Editor*

# DEPARTMENTS

September 2023

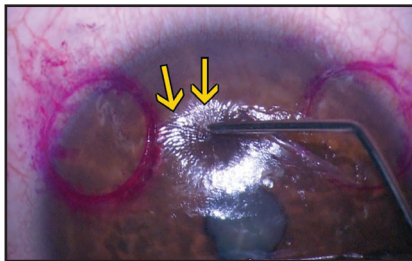
## 4 News

## 12

EDITOR'S PAGE

### Summer Blockbusters

Walter Bethke  
Editor in Chief



## 16

REFRACTIVE/CATARACT RUNDOWN

### LASIK Enhancements: Handle with Care

Refractive surgeons say the keys to managing these cases are patience and precision.

Liz Hunter, Senior Editor

## 23

THE FORUM

### The March of Time

Mark H. Blecher, MD  
Chief Medical Editor

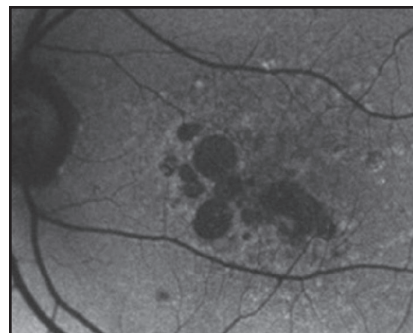
## 57

GLAUCOMA MANAGEMENT

### Managing Steroid- Induced Glaucoma

This secondary glaucoma has a unique pathophysiology that may inform treatment approaches.

Douglas J. Rhee, MD



## 61

RETINAL INSIDER

### An Update on Fundus Autofluorescence

This imaging method can help elucidate retinal disease, monitor progression and help advance therapy.

Yse Borella, MD, Harshit Vaidya, MD and  
Jay Chhablani, MD

## 69

TECHNOLOGY UPDATE

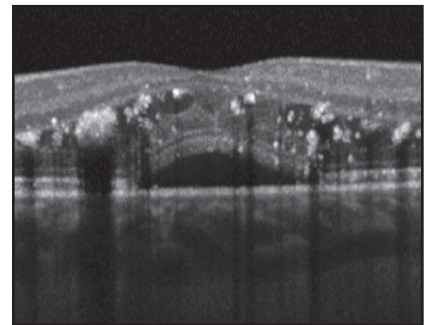
### Help for Intravitreal Injections

Traditional intravitreal injection techniques are tried-and-true, but there are devices that can help guide the procedure.

Andrew Beers  
Associate Editor

## 71

AD INDEX



## 72

WILLS EYE RESIDENT CASE SERIES


### A young woman presents with sudden- onset blurred vision and metamorphopsia in one eye.

Mara E. Penne, MD, and  
Carol L. Shields, MD

 VISIT US ON SOCIAL MEDIA

Facebook [www.facebook.com/RevOphth](https://www.facebook.com/RevOphth)  
Twitter/X [twitter.com/RevOphth](https://twitter.com/RevOphth)  
Instagram [@revophth](https://www.instagram.com/revophth)





**xdemyvy™**  
(lotilaner ophthalmic  
solution) 0.25%

**NOW AVAILABLE TO PRESCRIBE**



Learn more at [XDEMZYHCP.com](https://www.XDEMZYHCP.com)



Tarsus, XDEMYVY, and the associated logos are trademarks of Tarsus Pharmaceuticals, Inc.

© 2023 Tarsus Pharmaceuticals, Inc. US--2300350 9/23

## EDITORIAL STAFF

### Editor in Chief

Walter Bethke

(610) 492-1024

wbethke@jobson.com

### Senior Editor

Liz Hunter

(610) 492-1025

ehunter@jobson.com

### Senior Associate Editor

Christine Leonard

(610) 492-1008

cleonard@jobson.com

### Associate Editor

Leanne Spiegle

(610) 492-1026

lspiegle@jobson.com

### Associate Editor

Andrew Beers

(570) 856-5156

abeers@jobson.com

### Chief Medical Editor

Mark H. Blecher, MD

### Senior Art Director

Jared Araujo

(610) 492-1032

jaraujo@jobson.com

### Graphic Designer

Lynne O'Connor

(267) 566-6007

lyoconnor@jobson.com

### Business Offices

19 Campus Boulevard, Suite 101

Newtown Square, PA 19073

(610) 492-1000

Fax: (610) 492-1039

### Subscription inquiries:

United States – (877) 529-1746

Outside U.S. – (845) 267-3065

E-mail:

revophthalmology@cambeywest.com

Website: www.reviewofophthalmology.com



WALTER C. BETHKE, EDITOR IN CHIEF

## EDITOR'S PAGE

# Summer Blockbusters

When you hear the term “summer blockbuster,” you think of a movie like the box-office juggernaut “Barbie.” However, there are other kinds of blockbusters, too—the kind that, in addition to raking in \$16 billion in one year, can transform our behavior and our waistlines. I’m talking about the weight-loss drugs Ozempic and Wegovy (both semaglutide) from Novo Nordisk. The buzz around these two meds really kicked into overdrive this summer with the revelation of positive study findings such as semaglutide’s ability to cut cardiovascular events by 20 percent<sup>1</sup> and give renewed vigor to heart-failure patients.<sup>2</sup>

The drugs’ success is affecting the business world, too, sending companies associated with diabetes therapy and obesity scrambling. For instance, the value of Medifast, a company that provides weight-loss programs, dropped 26 percent. Insulin-pump makers are also hurting, and the maker of the DaVinci robotic surgery system, which is used in bariatric procedures, says the drugs are cutting into patient demand—some patients just don’t need the surgery now.<sup>3</sup>

However, there are potential negatives with these wonder drugs. First, as pointed out in a recent *JAMA* commentary, the drugs’ success is hamstringing our desire to study the actual roots of obesity. Why do the hard work on the topic when patients can just get an injection? “Big pharma can come up with a billion dollars to take a promising drug through Phase III clinical trials without difficulty because the profits can be enormous,” wrote David S. Ludwig, MD, PhD, an endocrinologist and researcher at Boston Children’s Hospital, “whereas researchers trying to understand the environmental and dietary drivers of obesity must man-

age with a shoestring budget.”<sup>4</sup>

In ophthalmology, paradoxically, the increased use of semaglutide may result in increased complications related to diabetic retinopathy, according to the results of the SUSTAIN 6 trial, though increases in DR appear to be transient.

Probably the most pressing issue—is it almost always—is cost. These drugs cost \$10,000 to \$15,000 per year, which has the potential to increase U.S. health-care spending by 50 percent.<sup>4</sup> However, now there are rumblings that Medicare may start paying for the drugs for some patients—but analysts say that could be disastrous; at the drugs’ current cost, paying for 100 million obese patients could potentially bankrupt Medicare.<sup>3</sup> Where will the money come from? Hopefully, if Medicare gets involved, CMS won’t start eyeing cataract surgery or other ophthalmic procedures, because everything in those arenas has been cut to the bone. The situation probably calls for proactive interactions with lawmakers to reinforce the idea that cataract surgery is a service that’s of tremendous value to patients. Maybe an ophthalmology blockbuster is in order?

I can see it now: “Cataract Surgery 2: This Time, It’s Personal.”

—Walter Bethke  
Editor in Chief

1. Company communication, the SELECT Trial. <https://tinyurl.com/ywejd92b>.

2. Kosiborod MN, Abildstrom SZ, Borlaug BA, et al. Semaglutide in patients with heart failure with preserved ejection fraction and obesity. *NEJM* 2023; Aug 25. [Epub ahead of print]. doi: 10.1056/NEJMoa2306963.

3. Wainer D. The Ozempic craze could put these companies on a crash diet. *WSJ*. August 18, 2023.

4. Powell A. Are new weight-loss drugs the answer to America’s obesity problem? *The Harvard Gazette*. July 10, 2023. <https://news.harvard.edu/gazette/story/2023/07/are-new-weight-loss-drugs-the-answer-to-americas-obesity-problem/>.



For the treatment of all stages  
of neurotrophic keratitis (NK)



## NOT JUST ANY SOLUTION A RESOLUTION

### Complete and long-lasting resolution of NK for most patients\*<sup>1-4</sup>

- Up to 72% of patients achieved complete corneal healing in clinical trials\*<sup>†1-3</sup>
- 80% of these patients remained healed at 1 year (REPARO trial)\*<sup>4</sup>

\* Resolution was evaluated in clinical trials as complete corneal healing, defined as the absence of staining in the lesion area and no persistent staining in the rest of the cornea after 8 weeks of treatment and as <0.5-mm lesion staining at 48-week follow-up.<sup>1,3</sup>

† Key study findings were after 8 weeks of treatment, 6 times daily, REPARO (Study NGF0212): 52 European patients with neurotrophic keratitis (NK) in 1 eye per group; 72% of patients completely healed; vehicle response rate 33.3%. Study NGF0214: 24 US patients with NK in 1 or both eyes per group; 65.2% completely healed; vehicle response rate 16.7%.<sup>2,3</sup>

### Important Safety Information WARNINGS AND PRECAUTIONS

#### Use with Contact Lens

Contact lenses should be removed before applying OXERVATE because the presence of a contact lens (either therapeutic or corrective) could theoretically limit the distribution of cenergermin-bkbj onto the area of the corneal lesion. Lenses may be reinserted 15 minutes after administration.

#### Eye Discomfort

OXERVATE may cause mild to moderate eye discomfort such as eye pain during treatment. The patient should be advised to contact their doctor if a more serious eye reaction occurs.

#### ADVERSE REACTIONS

In clinical trials, the most common adverse reaction was eye pain following instillation which was reported in approximately 16% of patients. Other adverse reactions occurring in 1% to 10% of OXERVATE patients and more frequently than in the vehicle-treated patients included corneal deposits, foreign body sensation, ocular hyperemia, ocular inflammation and tearing.

#### USE IN SPECIFIC POPULATIONS

##### Pregnancy

There are no data from the use of OXERVATE in pregnant women to inform any drug associated risks.

#### Lactation

The developmental and health benefits of breastfeeding should be considered, along with the mother's clinical need for OXERVATE, and any potential adverse effects on the breastfed infant from OXERVATE.

#### Pediatric Use

The safety and effectiveness of OXERVATE have been established in the pediatric population. Use of OXERVATE in pediatric patients 2 years of age and older is supported by evidence from adequate and well-controlled trials of OXERVATE in adults with additional safety data in children.

#### INDICATION

OXERVATE<sup>®</sup> (cenergermin-bkbj) ophthalmic solution 0.002% (20 mcg/mL) is indicated for the treatment of neurotrophic keratitis.

#### DOSAGE AND ADMINISTRATION

Instill one drop of OXERVATE in the affected eye(s), 6 times a day at 2-hour intervals for eight weeks.

**To report ADVERSE REACTIONS, contact Dompé U.S. Inc. at 1-833-366-7387 or FDA at 1-800-FDA-1088 or [www.fda.gov/medwatch](http://www.fda.gov/medwatch).**

**Please see the Brief Summary of full Prescribing Information for OXERVATE on the following page.**

**References:** 1. OXERVATE<sup>®</sup> (cenergermin-bkbj) ophthalmic solution 0.002% (20 mcg/mL) [US package insert], Boston, MA; Dompé U.S. Inc.; 2019. 2. Bonini S, et al. *Ophthalmology*. 2018;125:1332-1343. 3. Pflugfelder SC, et al. *Ophthalmology*. 2020;127:14-26. 4. Data on File. Clinical Study Report (NGF0212). Dompé U.S. Inc., 2016.

oxervate<sup>®</sup>   
(cenergermin-bkbj ophthalmic  
solution) 0.002% (20 mcg/mL)



## Brief Summary of full Prescribing Information

Consult the full Prescribing Information for complete product information, available at [www.oxervate.com/prescribing-information](http://www.oxervate.com/prescribing-information).

### INDICATIONS AND USAGE

OXERVATE® (cenegermin-bkbj) ophthalmic solution 0.002% is indicated for the treatment of neurotrophic keratitis.

### DOSAGE AND ADMINISTRATION

#### General Dosing Information

Contact lenses should be removed before applying OXERVATE and may be reinserted 15 minutes after administration.

If a dose is missed, treatment should be continued as normal, at the next scheduled administration.

If more than one topical ophthalmic product is being used, administer the eye drops at least 15 minutes apart to avoid diluting products. Administer OXERVATE 15 minutes prior to using any eye ointment, gel or other viscous eye drops.

#### Recommended Dosage and Dose Administration

Instill one drop of OXERVATE in the affected eye(s), 6 times a day at 2-hour intervals for eight weeks.

### WARNINGS AND PRECAUTIONS

#### Use with Contact Lens

Contact lenses should be removed before applying OXERVATE because the presence of a contact lens (either therapeutic or corrective) could theoretically limit the distribution of cenegermin-bkbj onto the area of the corneal lesion. Lenses may be reinserted 15 minutes after administration.

#### Eye Discomfort

OXERVATE may cause mild to moderate eye discomfort such as eye pain during treatment. The patient should be advised to contact their doctor if a more serious eye reaction occurs.

### ADVERSE REACTIONS

#### Clinical Studies Experience

Because clinical studies are conducted under widely varying conditions, adverse reaction rates observed in the clinical studies of a drug cannot be directly compared to rates in the clinical studies of another drug and may not reflect the rates observed in practice.

In two clinical trials of patients with neurotrophic keratitis, a total of 101 patients received cenegermin-bkbj eye drops at 20 mcg/mL at a frequency of 6 times daily in the affected eye(s) for a duration of 8 weeks. The mean age of the population was 61 to 65 years of age (18 to 95). The majority of the treated patients were female (61%). The most common adverse reaction was eye pain following instillation which was reported in approximately 16% of patients. Other adverse reactions occurring in 1-10% of OXERVATE patients and more frequently than in the vehicle-treated patients included corneal deposits, foreign body sensation, ocular hyperemia, ocular inflammation and tearing.

### USE IN SPECIFIC POPULATIONS

#### Pregnancy

##### Risk Summary

There are no data from the use of OXERVATE in pregnant women to inform any drug associated risks.

Administration of cenegermin-bkbj to pregnant rats or rabbits during the period of organogenesis did not produce adverse fetal effects at clinically relevant doses. In a pre- and postnatal development study, administration of cenegermin-bkbj to pregnant rats throughout gestation and lactation did not produce adverse effects in offspring at clinically relevant doses.

#### Lactation

##### Risk Summary

There are no data on the presence of OXERVATE in human milk, the effects on breastfed infant, or the effects on milk production. The developmental and health benefits of breastfeeding should be considered, along with the mother's clinical need for OXERVATE, and any potential adverse effects on the breastfed infant from OXERVATE.

#### Pediatric Use

The safety and effectiveness of OXERVATE have been established in the pediatric population. Use of OXERVATE in this population is supported by evidence from adequate and well-controlled trials of OXERVATE in adults with additional safety data in pediatric patients from 2 years of age and older.

#### Geriatric Use

Of the total number of subjects in clinical studies of OXERVATE, 43.5 % were 65 years old and over. No overall differences in safety or effectiveness were observed between elderly and younger adult patients.

### NONCLINICAL TOXICOLOGY

#### Carcinogenesis, Mutagenesis, Impairment of Fertility

##### Carcinogenesis and Mutagenesis

Animal studies have not been conducted to determine the carcinogenic and mutagenic potential of cenegermin-bkbj.

##### Impairment of fertility

Daily subcutaneous administration of cenegermin-bkbj to male and female rats for at least 14 days prior to mating, and at least 18 days post-coitum had no effect on fertility parameters in male or female rats at doses up to 267 mcg/kg/day (1709 times the MRHOD).

In general toxicology studies, subcutaneous and ocular administration of cenegermin-bkbj in females was associated with ovarian findings including persistent estrus, ovarian follicular cysts, atrophy/reduction of corpora lutea, and changes in ovarian weight at doses greater than or equal to 19 mcg/kg/day (119 times the MRHOD).



## CONTRIBUTORS

### CHIEF MEDICAL EDITOR

Mark H. Blecher, MD

### CONTACT LENSES

Penny Asbell, MD

### CORNEA / ANTERIOR SEGMENT

Thomas John, MD

### GLAUCOMA MANAGEMENT

Peter Netland, MD, PHD  
Kuldev Singh, MD

### MEDICARE Q & A

Mary Pat Johnson,  
COMT, CPC

### PEDIATRIC PATIENT

Janine Collinge, MD

### PLASTIC POINTERS

April Lao, MD

### REFRACTIVE SURGERY

Arturo S. Chayet, MD

### RETINAL INSIDER

Carl Regillo, MD, FACS  
Yoshihiro Yonekawa, MD

### TECHNOLOGY UPDATE

Steven T. Charles, MD  
Michael Colvard, MD

### WILLS RESIDENT CASE SERIES

Collin Rozanski, MD

## ADVISORY BOARD

**PENNY A. ASBELL, MD**, MEMPHIS, TENN.

**BRANDON AYRES, MD**, PHILADELPHIA

**SURENDRA BASTI, MD**, CHICAGO

**WILLIAM I. BOND, MD**, PEKIN, ILL.

**ALAN N. CARLSON, MD**, DURHAM, N.C.

**Y. RALPH CHU, MD**, EDINA, MINN.

**ADAM J. COHEN, MD**, CHICAGO

**JANINE COLLINGE, MD**, FARMINGTON, CONN.

**UDAY DEVGAN, MD, FACS**, LOS ANGELES

**ERIC DONNENFELD, MD**, ROCKVILLE CENTRE, N.Y.

**DANIEL S. DURRIE, MD**, KANSAS CITY, MO.

**ROBERT EPSTEIN, MD**, MCHENRY, ILL.

**ROBERT D. FECHTNER, MD**, NEWARK, N.J.

**BRIAN FRANCIS, MD**, Los Angeles

**JAMES P. GILLS, MD**, TARPON SPRINGS, FLA.

**HARRY GRABOW, MD**, SARASOTA, FLA.

**DOUGLAS K. GRAYSON, MD**, NEW YORK CITY

**DAVID R. HARDTEN, MD**, MINNEAPOLIS

**SARA J. HAUG, MD, PHD**, DURANGO, COLO.

**KENNETH J. HOFFER, MD**, SANTA MONICA, CALIF.

**JACK T. HOLLADAY, MD, MSEE**, HOUSTON

**JOHN D. HUNKELER, MD**, KANSAS CITY, MO.

**THOMAS JOHN, MD**, TINLEY PARK, ILL.

**ROBERT M. KERSHNER, MD, MS**, PALM BEACH GARDENS, FLA.

**GUY M. KEZIRIAN, MD**, PARADISE VALLEY, ARIZ.

**SUMITRA KHADELWAL, MD**, HOUSTON

**TERRY KIM, MD**, DURHAM, N.C.

**BRAD KLIGMAN, MD**, MANHASSET, N.Y.

**TOMMY KORN, MD**, SAN DIEGO

**APRIL LAO, MD**, MEMPHIS

**DAVID A. LEE, MD**, HOUSTON

**FRANCIS S. MAH, MD**, LA JOLLA, CALIF.

**NICK MAMALIS, MD**, SALT LAKE CITY

**EDWARD MANCHE, MD**, PALO ALTO, CALIF.

**MIKE S. MCFARLAND, MD**, PINE BLUFF, ARK.

**JEFFREY B. MORRIS, MD, MPH**, ENCINITAS, CALIF.

**KEVIN MILLER, MD**, LOS ANGELES

**MAJID MOSHIRFAR, MD**, DRAPER, UTAH

**MARLENE R. MOSTER, MD**, PHILADELPHIA

**ROBERT J. NOECKER, MD**, FAIRFIELD, CONN.

**ROBERT OSHER, MD**, CINCINNATI

**MARK PACKER, MD**, WEST PALM BEACH, FLA.

**CHRISTOPHER J. RAPUANO, MD**, PHILADELPHIA

**AUGUST READER III, MD**, SAN FRANCISCO

**TONY REALINI, MD, MPH**, MORGANTOWN, W.V.

**KENNETH J. ROSENTHAL, MD**, GREAT NECK, N.Y.

**ERIC ROTHCHILD, MD**, DELRAY BEACH, FLA.

**SHERI ROWEN, MD**, BALTIMORE

**JAMES J. SALZ, MD**, LOS ANGELES

**INGRID U. SCOTT, MD, MPH**, HERSHEY, PA.

**JOEL SCHUMAN, MD**, PITTSBURGH

**GAURAV SHAH, MD**, ST. LOUIS

**DAVID R. STAGER JR., MD**, DALLAS

**KARL STONECIPHER, MD**, GREENSBORO, N.C.

**JAMES C. TSAI, MD**, NEW YORK CITY

**VANCE THOMPSON, MD**, SIOUX FALLS, S.D.

**FARRELL C. TYSON, MD**, CAPE CORAL, FLA.

**R. BRUCE WALLACE III, MD**, ALEXANDRIA, LA.



### BUSINESS OFFICES

19 CAMPUS BOULEVARD, SUITE 101  
NEWTOWN SQUARE, PA 19073  
SUBSCRIPTION INQUIRIES (877) 529-1746  
(USA ONLY); OUTSIDE USA, CALL (847) 763-9630

### BUSINESS STAFF

PUBLISHER

**MICHAEL HOSTER**

(610) 492-1028 MHOSTER@JOBSON.COM

SENIOR MANAGER, STRATEGIC ACCOUNTS

**MICHELE BARRETT**

(610) 492-1014 MBARRETT@JOBSON.COM

REGIONAL SALES MANAGER

**JONATHAN DARDINE**

(610) 492-1030 JDARDINE@JOBSON.COM

DIGITAL MARKETING MANAGER

**MATT EGGER**

(610) 492-1029 MEGGER@JOBSON.COM

CLASSIFIED ADVERTISING

(888)-498-1460

PRODUCTION MANAGER

**KAREN LALLONE**

(610) 492-1010 KLALLONE@JOBSON.COM

SUBSCRIPTIONS

\$63 A YEAR, \$99 (U.S.) IN CANADA,  
\$158 (U.S.) IN ALL OTHER COUNTRIES.

SUBSCRIPTIONS E-MAIL:

REVOPHTHALMOLOGY@CAMBEYWEST.COM

### CIRCULATION

PO BOX 71, CONGERS, NY 10920-0071

(877) 529-1746

OUTSIDE USA: (845) 267-3065

SENIOR CIRCULATION MANAGER

**HAMILTON MAHER**

(212) 219-7870 hmaher@jhihealth.com

CEO, INFORMATION GROUP SERVICES

**BILL SCOTT**

SENIOR VICE PRESIDENT, OPERATIONS

**JEFF LEVITZ**

VICE PRESIDENT, HUMAN RESOURCES

**TAMMY GARCIA**

VICE PRESIDENT, CREATIVE SERVICES & PRODUCTION

**MONICA TETTAMANZI**

CORPORATE PRODUCTION DIRECTOR

**JOHN ANTHONY CAGGIANO**

VICE PRESIDENT, CIRCULATION

**JARED SONNERS**

299 Market St. 2 Gateway Center - 4th Floor  
Newark NJ 07102

REVIEW OF OPHTHALMOLOGY (ISSN 1081-0226; USPS No. 0012-345) is published monthly, 12 times per year by Jobson Medical Information, LLC/WebMD 283 - 299 Market St. 2 Gateway Center - 4th Floor Newark NJ 07102. Periodicals postage paid at New York, NY and additional mailing offices. Postmaster: Send address changes to Review of Ophthalmology, PO Box 71, Congers, NY 10929-0071. Subscription Prices: US One Year \$63.00, US Two Year \$112.00, Canada One Year \$99.00, Canada Two Year \$181.00, Int'l One Year \$158.00, Int'l Two Year \$274.00. For subscription information call (877) 529-1746 (USA only); outside USA, call (845-267-3065. Or email us at revophthalmology@cambeywest.com. Canada Post: Publications Mail Agreement #40612608. Canada Returns to be sent to Bleuchip International, P.O. Box 25542, London, ON N6C 6B2.





EDITED BY ARTURO CHAYET, MD

## REFRACTIVE/CATARACT RUNDOWN

# LASIK Enhancements: Handle with Care

*Refractive surgeons say the keys to managing these cases are patience and precision.*

**LIZ HUNTER**  
SENIOR EDITOR

Despite LASIK's accuracy, enhancements simply come with the territory. Every once in a while a target is missed or a patient from years ago will show up with visual complaints and refractive surgeons must consider time, technique and potential risks of retreatment. We asked some veteran refractive surgeons for their insight and pearls for these rare but unavoidable situations.

### Reasons for Enhancements

Enhancements typically fall into two categories: early and late. Early enhancements take place within the first few months of the initial LASIK procedure, usually due to a refractive miss that was noticed quickly following surgery. Late enhancements happen years down the line as a result of changes in the patient's natural lens.

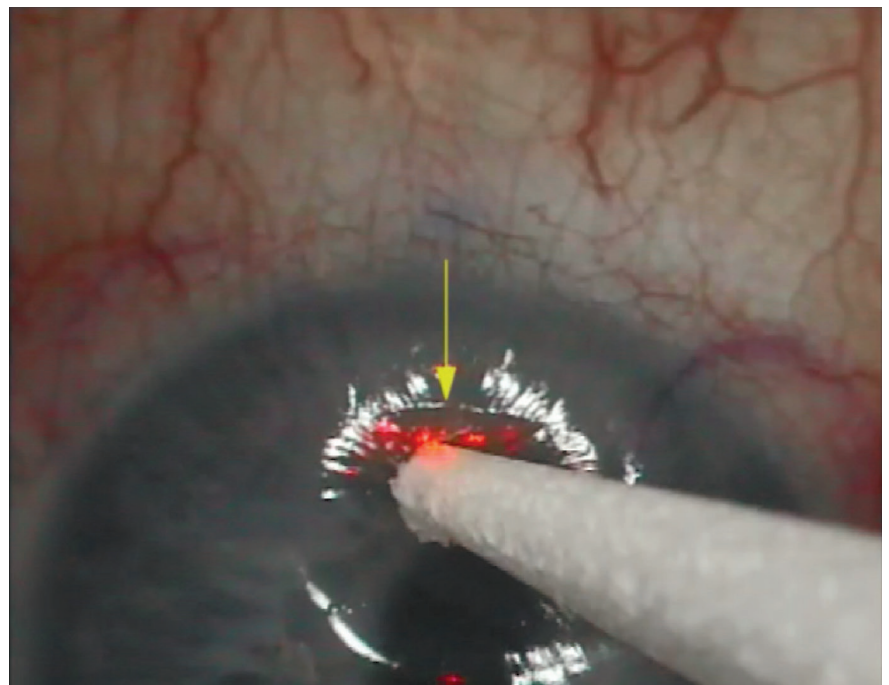
Regarding early enhancements, "If the patient's unhappy with their vision in the early postop period, and you missed the target by 0.75 to 1 D, our objective at that point is to get them through that period," says Scott MacRae, MD, the director of refractive services in the department of ophthalmology at the University of Rochester. "Many times we'll fit them with a soft contact lens so they can see better, particularly for patients who are overcor-

rected and hyperopic in the presbyopic age group. Those patients can really struggle, but fitting them with a hyperopic soft contact lens in that early postop period can help them get back to a much more functional state for going back to the office/daily activities. We try to nurse them through that two to three month period."

Reliable measurements are critical in this early enhancement phase, continues Dr. MacRae. "If somebody's really having a hard time, you could

consider retreating at two months postop but you probably want two or three measurements before you actually go ahead and do your retreatment, particularly in patients who don't have a real clear endpoint. Sometimes they're still changing. That's more true for dry eyes and hyperopic correction than with myopic correction. Usually myopic correction is relatively stable after the first week or two after the dryness issues clear up," he says. "If the patients are still dry at two or three months postop and you're not getting reliable refractions, make sure that you aggressively treat the dryness before you get your final numbers and proceed with retreatment."

Sometimes, the neuroadaptation of the patient needs to be considered and explained. "My tendency is that if the patient is 20/happy and I'm really close to the target, then I don't encourage the patient to have retreatment



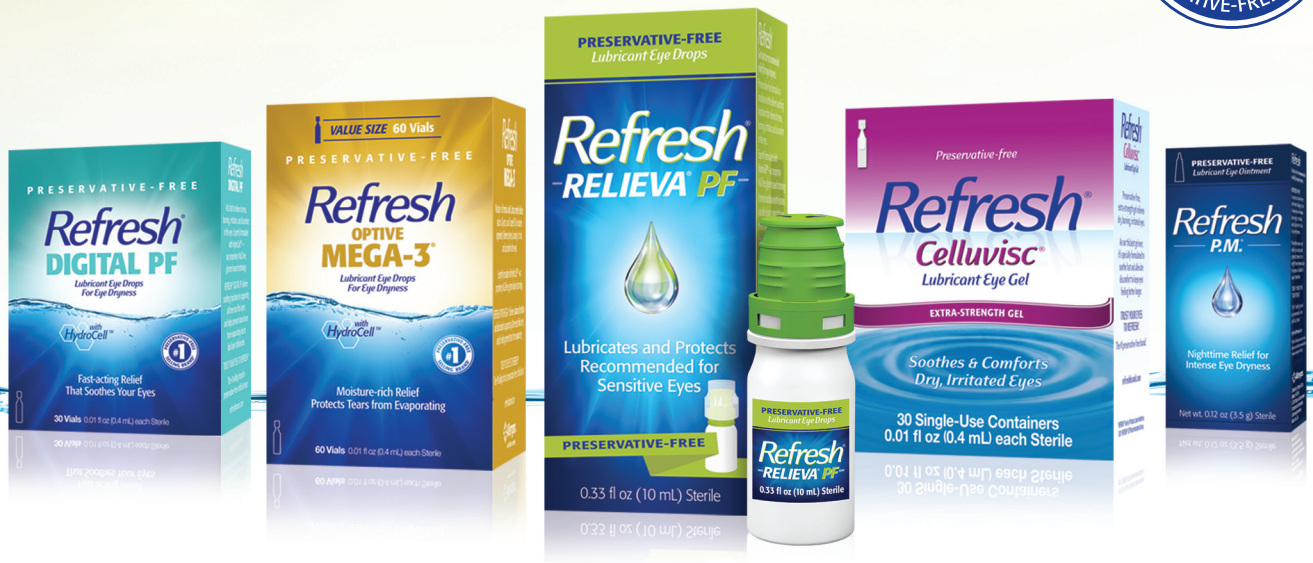**Figure 1.** In his "Dry and Depress" technique for lifting a LASIK flap, Richard Mackool, MD, uses a dry sponge and gently presses on the central cornea until he spots the flap.

**This article has no commercial sponsorship.**

**Dr. Chayet** is considered a pioneer in refractive and cataract surgery, and is the medical director of the Codet Vision Institute in Tijuana, Mexico. He is a clinical investigator for RxSight, LensGen and ForSight Vision6.

# PRESERVATIVE-FREE POWERHOUSE

— SYMPTOM RELIEF FOR DRY EYES —



No two patients' eyes are the same. That's why REFRESH® provides a portfolio of products expertly formulated around your patients' specific needs.

RECOMMEND THE LEADER IN PRESERVATIVE-FREE\*

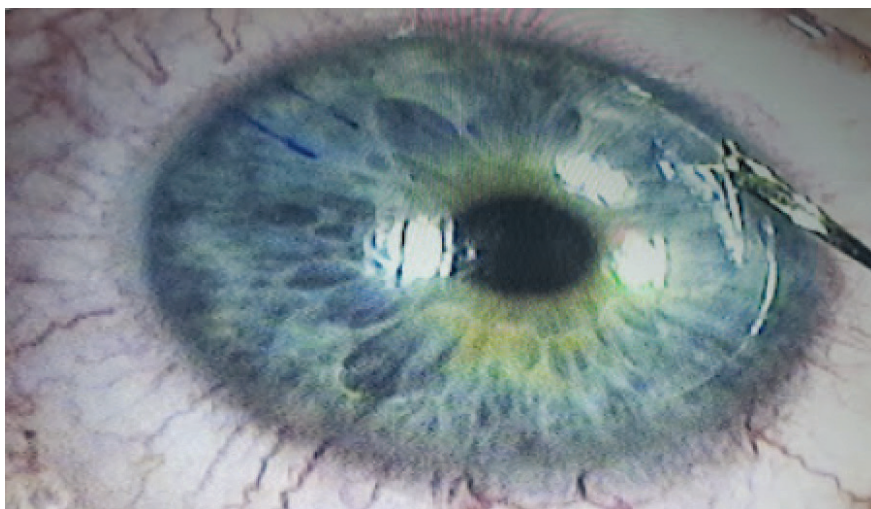
**Refresh**<sup>®</sup>  
Lubricant Eye Drops

[refreshbrand.com/doc](http://refreshbrand.com/doc)

\*REFRESH® Family of Products, Ipsos Healthcare, 2021 REFRESH® ECP Recommendation Survey  
© 2023 AbbVie. All rights reserved. All trademarks are the property of their respective owners.

 **Allergan**<sup>®</sup>  
an AbbVie company

US-RFS-230038 03/23



**Figure 2.** Scott MacRae, MD, developed an instrument called the MacRae Flap Flipper that allows him to gently lift and separate the LASIK flap, which he says has made epithelial ingrowth a rare occurrence.

unless they're really insistent," says Dr. MacRae. "If they're insistent, then there are some tricks to that. Typically I'll go ahead and refract them myself, or have my trusted staff refract the patient. Then we put that prescription into a spectacle trial frame and actually have the patient look at the difference compared to their uncorrected vision in each eye. If they notice a pretty significant visual improvement subjectively then I'll go ahead and retreat, even if it's relatively minor.

"The optics are more complicated than just simple numbers—there's image quality, which can be affected by higher order aberrations or other subtleties that the patient is perceiving," he continues. "Certain patients are much more neuroadaptive to their vision than others, so some patients can tolerate a small amount of refractive error, while other patients are really insistent that their image quality isn't good enough and they want an improvement."

Setting them up in a spectacle trial can be helpful in comparing each uncorrected eye to the best corrected vision with the trial lens. "If they don't notice a difference, then I say, 'If we try to go back and retreat, I don't think it's going to make any improvement,'" says Dr. MacRae. "Sometimes that's enough for the patient to say, 'My vision is pretty good. I'm happy. The doctor

tried to do everything they can to get me the best vision I can get and I can settle for this.' Doing the trial lens is actually really helpful because it avoids that situation where you go ahead and retreat, but then the patient doesn't notice any difference and you've gone through this whole process. It really saves everybody time."

In cases of late enhancements, Louisville, Kentucky's Asim Piracha, MD, says, "You have to consider why they need an enhancement two, three or five years later. It's not that the LASIK 'wore off' or that the initial treatment didn't work—it's that something has changed to make them either myopic or hyperopic. For myopes, it's even still more uncommon because their vision is pretty stable long term, and for hyperopes, they tend to get a bit more hyperopic over time. So, if you have a hyperope, usually they have a lot of accommodation and, as they get older, they lose accommodation which makes them more hyperopic. This may be the reason for the enhancement."

Topography will reveal a wealth of information. "If they're beyond a couple years out and they have a myopic astigmatic change, my first thought is to see if there is any ectasia," Dr. Piracha says. "Before any enhancement you must be really careful to make sure their topography is normal and there's

no sign of even subtle ectasia. We like to look at the preop topography and postop topography to see what's changed. If there's any progressive myopia, astigmatism or steepening of the inferior cornea, bullous keratopathy on the surface or posterior surface, then we're concerned about ectasia.

"For those patients you have to be cautious and have them come back in six months and make sure there are no progressive changes," he continues. "If it's completely stable and there's any concern at all about ectasia, then I would only enhance with surface ablation, I wouldn't lift the flap. If there are signs of ectasia progression I wouldn't enhance them at all and I would do a cross-linking treatment to stabilize the cornea and then consider going back and doing a surface treatment to enhance them (ASA or PRK) once they're stable, which I'm pretty cautious in waiting at least a year but ideally 18 months after cross-linking before doing any enhancement."

Dr. Piracha takes a different approach if the patient is hyperopic. "Usually it's not a sign of ectasia," he says. "Typically it's a loss of accommodation as they get older or their near vision is an issue. If they're over 40 and hyperopic I'd possibly offer an enhancement, monovision or even a refractive lens exchange to enhance them vs. laser vision correction. In all patients after 40 and definitely after 45, I do wavefront measurements on the iTrace of their eyes and look for any dysfunctional lens syndrome—aberrations in the cornea vs. aberrations from their natural lens. That influences whether we pursue a lens exchange or not."

Cataract development could also be contributing to their vision changes, notes Dr. MacRae. "If it's an early cataract and we think that it's progressing, we'll recommend waiting for six to 12 months and seeing whether their refraction changes," he says. "If the refraction is changing then it's not a good time to go ahead and treat—you want to make sure that the refraction is stabilized. If they continue to prog-



ress and their refraction continues to change then we recommend cataract surgery or refractive lens exchange.”

## Treatments and Techniques

Surgeons traditionally treat LASIK enhancements with PRK or by re-lifting the flap and ablating the bed. Whether the patient falls under the early or late enhancement category plays a major role in the decision.

“If they’re less than two years out, I typically lift the flap and enhance them,” says Dr. Piracha. “If the patient’s beyond two years there are definitely several studies and reports to show a higher rate for epithelial ingrowth.”

Dr. MacRae concurs. “I’ll go back and retreat with a flap lift up to about two years postop but avoid it after that since epithelial ingrowth is more common with flap lifting after the first few years postop,” he says. “After two years post LASIK, typically I’ll go and do PRK on a retreat. Sometimes, we’ll see patients that are 10 or 15 years postop and they still have a little residual refractive error and they come back for just a small tune up, in which case I’ll do PRK on those eyes as well.”

## PRK

For his PRK retreats, Dr. MacRae has a process, beginning with an 8.5-mm corneal trephine to demarcate the epithelium he wants to remove centrally vs. what he wants to preserve peripherally. “It very accurately demarcates the edge of the epithelium that you’re taking off so you don’t have scrolls and other irregularities,” he says. He uses an 8.5-mm well filled with 20% alcohol over the area and lets it sit on the cornea for 40 seconds. “Before removing the well, I use a Weck-Cel and allow it to swell. Then I gently twirl the Weck-Cel,” he continues. “The twirling motion causes those lateral adhesions of the epithelium to continue to adhere but the vertical epithelium anchor actually breaks or dehisces, in which case you’ll have a swirl of epithelium that comes off very easily. Then, I just take a Maloney spatula and gently remove

the epithelium until I get to the edge of the area.”

One of the problems with treating or retreating with PRK is that patients can get recurrent erosions from loose epithelium, says Dr. MacRae. “PRK (or LASIK) can create mild erosion symptoms from the epithelium not vertically anchoring well. On all PRK and PTK retreats that I do, I use mitomycin-C prior to inserting the TSCL. Even if there’s a 1 percent haze rate we’d rather not have to have to deal with that at all.”

If you do notice scrolling of the epithelium, or it’s breaking down and not doing well, Dr. MacRae uses a Johnston applanator to smooth and stretch the flap. “If you notice the epithelium starting to loosen, use the Johnston applanator to applanate and stretch the flap, rather than trying to stretch the flap with Weck-Cels,” he says. “This instrument is a great option with friable epithelium and eyes with unrecognized anterior basement membrane disease to avoid damaging the epithelium further.

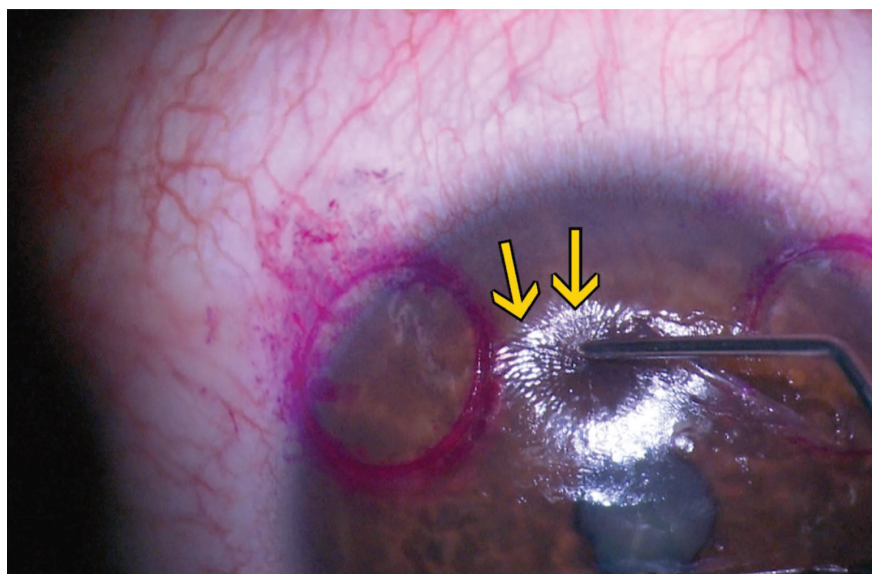
“Following treatment or retreatment with the excimer laser, I insert a bandage soft contact lens for seven to 10 days—sometimes, we might even leave it on longer,” he continues. “We

used to worry about infection with a therapeutic soft contact lens but that’s an extremely rare event, as long as the patients are treated with antibiotics and they’re well instructed in terms of good hand-washing, rinsing the eye out in the morning with artificial tears and avoiding dust and dirt for that first week. After the bandage lens is removed, we put them on Muro 128 or a generic equivalent hypertonic ointment at bedtime for two months. This prevents recurrent erosion.”

## Re-lifting the Flap

However, PRK doesn’t always make sense, even for late enhancements, notes Richard J. Mackool, MD, the founder and director of The Mackool Eye Institute and Laser Center in Queens, New York, as well as a professor at the New York Eye and Ear Infirmary and NYU Medical Center. “There are reasons the patient didn’t opt for PRK in the first place, including slow recovery, risk of haze and often discomfort,” he says. “The patient probably doesn’t want to go that route for retreatment.”

Dr. Mackool developed his own flap elevation technique that has since proven successful even for a LASIK flap created 29 years earlier. Dubbed



**Another example of Richard Mackool, MD, finding the LASIK flap with the “Dry and Depress” technique. Dr. Mackool reports success using this technique on flaps created as far back as 29 years prior.**

the “Dry and Depress” technique, it requires nothing more than the standard tools a refractive surgeon would already have on hand, and consists of the following steps:

- With the surgeon seated superiorly at the excimer laser microscope, the patient looks upward, bringing the inferior cornea into view. At the 8 to 10 mm optical zone, the inferior cornea is gently dried with a sponge to improve the surgeon’s ability to detect areas of epithelial irregularity, depression or elevation.

- With a dry sponge, gently depress the adjacent central region of the cornea to flatten the mid-peripheral cornea and cause the corneal light reflex to shift peripherally. Dr. Mackool says this is the ‘a-ha’ moment when you then see the junction of the LASIK flap (*Figure 1*).

- A blunt spatula is run back and forth along the groove, penetrating the epithelium and Bowman’s membrane, and passed beneath the flap to continue the standard flap elevation. (*A video of the procedure is available at [reviewofophthalmology.com](http://reviewofophthalmology.com).*)

“We’ve used this technique in 50 of 51 eyes (all had their original LASIK flap created by a microkeratome) that were between six months and 29 years post-LASIK. In one eye we could not penetrate the incision, so we performed PRK,” Dr. Mackool says. “Most notably, none of these patients developed epithelial ingrowth. We believe it’s because of the minimal disruption of the epithelium, similar to primary LASIK.”

Dr. Mackool advises surgeons to take their time looking for the flap. “If you don’t immediately find it down at 6 o’clock, look a little toward 7 or 8 o’clock, or 4 or 5 o’clock,” he says. “Just do a careful examination. We find it 100 percent of the time.”

Dr. Piracha’s technique for finding the flap varies. “You can mark the edge of the flap at the slit lamp—not the laser—with a 25- or 27-gauge needle,” he says. “That way, when you lift the flap, you’re not creating a corneal abrasion. Another way is with the current

lasers with a slit lamp attached, and the third way is to actually press on the cornea with a Merocel sponge and the margin of the flap shows up. At that point, I take a very fine Sinsky hook and cleanly dissect it and initiate the flap. Then I’ll take a cannula or LASIK spatula and go underneath that space and open the flap. I’m very particular about initiating that because if you’re rough identifying the margin and entering the central space from the flap, you can get epithelial ingrowth and the ingrowth can be recurrent and persistent. If it keeps returning you may have to suture the flap, which I’ve done on patients with recurrent epithelial ingrowth.”

“**Epithelium tends to adhere more laterally than it does vertically where it’s anchored, so the real challenge is to get those side adhesions separated.**  
— Scott MacRae, MD

Dr. MacRae’s flap-lifting technique was adapted from Steve Wilson, MD, of the Cleveland Clinic. “He described this technique at one of the meetings, and showed a video where he took a platypus type forceps, made a small notch at the flap edge, and then just lifted the entire flap open,” he says. “I was somewhat shocked at how quickly he lifted it. It created a really clean separation of the epithelium at the edge of the flap with very little epithelial scrolls or epithelial defects around the edge of the flap. Prior to this, I used to just push the instrument horizontally to separate the flap edge, which caused more epithelial scrolls.”

It inspired Dr. MacRae to develop an instrument called the MacRae Flap Flipper (Storz). “I score the flap edge at the slit lamp with a Sinsky hook or the Flap Flipper,” says Dr. MacRae. “The leading edge of the Flap Flipper looks like a dandelion digger that allows me to gently lift and separate the

flap while moving forward and lifting around the flap edge. Dr. Wilson was absolutely correct that lifting actually separates those horizontal or lateral adhesions of the epithelium, clearly avoiding epithelial tears.”

As all of these surgeons attest, nurturing the epithelium is critical. “Epithelium tends to adhere more laterally than it does vertically where it’s anchored, so the real challenge is to get those side adhesions separated,” says Dr. MacRae. “Dr. Wilson’s technique confirms that concept that the edges are cleaner if you tug vertically as you’re lifting rather than driving horizontally. That’s actually a key to performing retreats without having epithelial ingrowth. Sparing the epithelium and epithelial defects will dramatically reduce the rates of epithelial ingrowth in my experience. Using that technique, it’s extremely rare for me to have an epithelial ingrowth. If you do see a little tag of epithelium slip into the interface after you’ve lifted, then just gently tease it back away from the interface or from the edge of the flap and tease it peripherally away from the flap margin.”

Finally, Dr. Piracha advises the close consideration for lens exchange as an alternative to PRK and lifting the flap. “You have to look at the epithelial thickness and take an OCT and explain to the patient that if we do a surface treatment, it’s going to take a long time for vision to come back, and it might be worse for the first six months,” he says. “Then you have the argument to consider a lens replacement as opposed to surface treatment. That’s an option, especially with post-LASIK IOL calculations (Barrett True-K formula) and OCT imaging, and they have several options—monofocal lenses, multifocal lenses, EDOF lenses, the IC-8. It’s appealing because you don’t have the risk of an epithelial defect and it doesn’t take long to heal.” ◀

#### DISCLOSURES

Dr. Mackool has no relevant disclosures. Dr. MacRae is the creator of the MacRae Flap Flipper. Dr. Piracha is a consultant to Johnson & Johnson Vision and Zeiss.

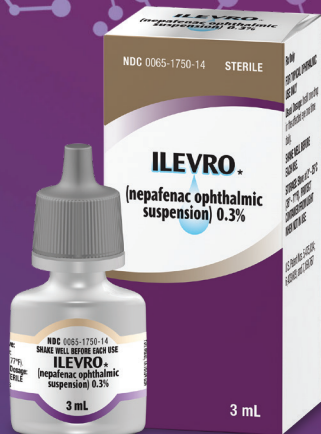

Not an actual patient.

# ILEVRO<sup>®</sup>

(nepafenac ophthalmic suspension) 0.3%

Potency Precisely  
Where It's Needed



## ILEVRO<sup>®</sup> HELPS MANAGE PAIN AND INFLAMMATION FOR YOUR CATARACT SURGERY PATIENTS.

**Proven efficacy for post-cataract-surgery pain and inflammation.<sup>1</sup>**

- Ocular pain completely resolved in 84% to 86% of patients at day 14<sup>1,2,\*†</sup>
- Inflammation completely cleared in 61% to 65% of patients at day 14<sup>1,2,\*†</sup>

**ILEVRO<sup>®</sup> Suspension is the only prodrug NSAID formulated for once-daily post-op use.<sup>1,4-6</sup>**

DISCOVER MORE AT [ILEVROHCP.COM](http://ILEVROHCP.COM)

### INDICATIONS AND USAGE

ILEVRO<sup>®</sup> (nepafenac ophthalmic suspension) 0.3% is a nonsteroidal, anti-inflammatory prodrug indicated for the treatment of pain and inflammation associated with cataract surgery.

### Dosage and Administration

One drop of ILEVRO<sup>®</sup> 0.3% should be applied to the affected eye one-time-daily beginning 1 day prior to cataract surgery, continued on the day of surgery and through the first 2 weeks of the postoperative period. An additional drop should be administered 30 to 120 minutes prior to surgery.

### IMPORTANT SAFETY INFORMATION

#### Contraindications

ILEVRO<sup>®</sup> 0.3% is contraindicated in patients with previously demonstrated hypersensitivity to any of the ingredients in the formula or to other nonsteroidal anti-inflammatory drugs (NSAIDs).

#### Warnings and Precautions

- **Increased Bleeding Time** – With some NSAIDs, including ILEVRO<sup>®</sup> 0.3%, there exists the potential for increased bleeding time. Ocularly applied NSAIDs may cause increased bleeding of ocular tissues (including hyphema) in conjunction with ocular surgery.
- **Delayed Healing** – Topical NSAIDs, including ILEVRO<sup>®</sup> 0.3%, may slow or delay healing. Concomitant use of topical NSAIDs and topical steroids may increase the potential for healing problems.

• **Corneal Effects** – Use of topical NSAIDs may result in keratitis. In some patients, continued use of topical NSAIDs may result in epithelial breakdown, corneal thinning, corneal erosion, corneal ulceration, or corneal perforation. These events may be sight threatening. Patients with evidence of corneal epithelial breakdown should immediately discontinue use of topical NSAIDs, including ILEVRO<sup>®</sup> 0.3%, and should be closely monitored for corneal health.

Patients with complicated ocular surgeries, corneal denervation, corneal epithelial defects, diabetes mellitus, ocular surface diseases (e.g., dry eye syndrome), rheumatoid arthritis, or repeat ocular surgeries within a short period of time may be at increased risk for corneal adverse events, which may become sight threatening. Topical NSAIDs should be used with caution in these patients.

Use more than 1 day prior to surgery or use beyond 14 days post surgery may increase patient risk and severity of corneal adverse events.

• **Contact Lens Wear** – ILEVRO<sup>®</sup> 0.3% should not be administered while using contact lenses.

#### Adverse Reactions

The most frequently reported ocular adverse reactions following cataract surgery occurring in approximately 5% to 10% of patients were capsular opacity, decreased visual acuity, foreign body sensation, increased intraocular pressure, and sticky sensation.

**For additional information about ILEVRO<sup>®</sup>, please refer to the Brief Summary of Prescribing Information on the adjacent page.**

**Study Design:** Results from 2 randomized, multicenter, controlled, double-masked trials of adult patients undergoing cataract extraction. In Study 1, patients were randomized to receive either ILEVRO<sup>®</sup> Suspension (n=851), NEVANAC<sup>®</sup> Suspension (n=845), ILEVRO<sup>®</sup> Suspension vehicle (n=211), or NEVANAC<sup>®</sup> Suspension vehicle (n=213). In Study 2, patients were randomized to receive either ILEVRO<sup>®</sup> Suspension (n=540) or ILEVRO<sup>®</sup> Suspension vehicle (n=268).<sup>2,3</sup>

<sup>†</sup>61% to 65% with ILEVRO<sup>®</sup> Suspension versus 24% to 32% with vehicle;  $P < 0.05$ .

<sup>\*</sup>84% to 86% with ILEVRO<sup>®</sup> Suspension versus 38% to 46% with vehicle;  $P < 0.05$ .

**References:** **1.** ILEVRO (nepafenac ophthalmic suspension) 0.3% [package insert]. Harrow IP, LLC; 2022. **2.** Data on file. **3.** Nevenac (nepafenac ophthalmic suspension) 0.1% [package insert]. Harrow IP, LLC; 2022. **4.** Prolensa [package insert]. Tampa, FL: Bausch & Lomb Inc; 2016. **5.** Bromsite [package insert]. Cranbury, NJ: Sun Pharmaceutical Industries, Inc; 2016. **6.** Ketorolac [package insert]. Lake Forest, IL: Akorn, Inc; 2012.



**HARROW<sup>®</sup>**  
Your patients. Our purpose.

Harrow  
102 Woodmont Blvd. Suite 610, Nashville, TN 37205

ILEVRO, the ILEVRO logo, and the Harrow logo are trademarks of Harrow IP, LLC.  
© 2023 Harrow. All Rights Reserved. IVRO-00019 07/23

# ILEVRO®

(nepafenac ophthalmic suspension) 0.3%

## BRIEF SUMMARY OF PRESCRIBING INFORMATION

### INDICATIONS AND USAGE

ILEVRO® (nepafenac ophthalmic suspension) 0.3% is indicated for the treatment of pain and inflammation associated with cataract surgery.

### DOSAGE AND ADMINISTRATION

#### Recommended Dosing

One drop of ILEVRO® Suspension should be applied to the affected eye one-time-daily beginning 1 day prior to cataract surgery, continued on the day of surgery and through the first 2 weeks of the postoperative period. An additional drop should be administered 30 to 120 minutes prior to surgery.

#### Use with Other Topical Ophthalmic Medications

ILEVRO® Suspension may be administered in conjunction with other topical ophthalmic medications such as beta-blockers, carbonic anhydrase inhibitors, alpha-agonists, cycloplegics, and mydriatics. If more than one topical ophthalmic medication is being used, the medicines must be administered at least 5 minutes apart.

### CONTRAINDICATIONS

ILEVRO® Suspension is contraindicated in patients with previously demonstrated hypersensitivity to any of the ingredients in the formula or to other NSAIDs.

### WARNINGS AND PRECAUTIONS

#### Increased Bleeding Time

With some nonsteroidal anti-inflammatory drugs including ILEVRO® Suspension, there exists the potential for increased bleeding time due to interference with thrombocyte aggregation. There have been reports that ocularly applied nonsteroidal anti-inflammatory drugs may cause increased bleeding of ocular tissues (including hyphemas) in conjunction with ocular surgery. It is recommended that ILEVRO® Suspension be used with caution in patients with known bleeding tendencies or who are receiving other medications which may prolong bleeding time.

#### Delayed Healing

Topical nonsteroidal anti-inflammatory drugs (NSAIDs) including ILEVRO® Suspension, may slow or delay healing. Topical corticosteroids are also known to slow or delay healing. Concomitant use of topical NSAIDs and topical steroids may increase the potential for healing problems.

#### Corneal Effects

Use of topical NSAIDs may result in keratitis. In some susceptible patients, continued use of topical NSAIDs may result in epithelial breakdown, corneal thinning, corneal erosion, corneal ulceration or corneal perforation. These events may be sight threatening. Patients with evidence of corneal epithelial breakdown should immediately discontinue use of topical NSAIDs including ILEVRO® Suspension and should be closely monitored for corneal health. Post marketing experience with topical NSAIDs suggests that patients with complicated ocular surgeries, corneal denervation, corneal epithelial defects, diabetes mellitus, ocular surface diseases (e.g., dry eye syndrome), rheumatoid arthritis, or repeat ocular surgeries within a short period

of time may be at increased risk for corneal adverse events which may become sight threatening. Topical NSAIDs should be used with caution in these patients. Post marketing experience with topical NSAIDs also suggests that use more than 1 day prior to surgery or use beyond 14 days post-surgery may increase patient risk and severity of corneal adverse events.

#### Contact Lens Wear

ILEVRO® Suspension should not be administered while using contact lenses.

### ADVERSE REACTIONS

Because clinical studies are conducted under widely varying conditions, adverse reaction rates observed in the clinical studies of a drug cannot be directly compared to the rates in the clinical studies of another drug and may not reflect the rates observed in practice.

#### Serious and Otherwise Important Adverse Reactions

The following adverse reactions are discussed in greater detail in other sections of labeling:

- Increased Bleeding Time (Warnings and Precautions)
- Delayed Healing (Warnings and Precautions)
- Corneal Effects (Warnings and Precautions)

#### Ocular Adverse Reactions

The most frequently reported ocular adverse reactions following cataract surgery were capsular opacity, decreased visual acuity, foreign body sensation, increased intraocular pressure, and sticky sensation. These reactions occurred in approximately 5 to 10% of patients.

Other ocular adverse reactions occurring at an incidence of approximately 1 to 5% included conjunctival edema, corneal edema, dry eye, lid margin crusting, ocular discomfort, ocular hyperemia, ocular pain, ocular pruritus, photophobia, tearing and vitreous detachment.

Some of these reactions may be the consequence of the cataract surgical procedure.

#### Non-Ocular Adverse Reactions

Non-ocular adverse reactions reported at an incidence of 1 to 4% included headache, hypertension, nausea/vomiting, and sinusitis.

### USE IN SPECIFIC POPULATIONS

#### Pregnancy

##### Teratogenic Effects.

**Pregnancy Category C:** Reproduction studies performed with nepafenac in rabbits and rats at oral doses up to 10 mg/kg/day have revealed no evidence of teratogenicity due to nepafenac, despite the induction of maternal toxicity. At this dose, the animal plasma exposure to nepafenac and amfenac was approximately 70 and 630 times human plasma exposure at the recommended human topical ophthalmic dose for rats and 20 and 180 times human plasma exposure for rabbits, respectively. In rats, maternally toxic doses  $\geq 10$  mg/kg were associated with dystocia, increased postimplantation loss, reduced fetal weights and growth, and reduced fetal survival.

Nepafenac has been shown to cross the placental barrier in rats. There are no adequate and well-controlled studies in pregnant women. Because animal reproduction studies are not always predictive of human response, ILEVRO® Suspension should be used during pregnancy only if the potential benefit justifies the potential risk to the fetus.

#### Non-teratogenic Effects

Because of the known effects of prostaglandin biosynthesis inhibiting drugs on the fetal cardiovascular system (closure of the ductus arteriosus), the use of ILEVRO® Suspension during late pregnancy should be avoided.

### Nursing Mothers

ILEVRO® Suspension is excreted in the milk of lactating rats. It is not known whether this drug is excreted in human milk. Because many drugs are excreted in human milk, caution should be exercised when ILEVRO® Suspension is administered to a nursing woman.

### Pediatric Use

The safety and effectiveness of ILEVRO® Suspension in pediatric patients below the age of 10 years have not been established.

### Geriatric Use

No overall differences in safety and effectiveness have been observed between elderly and younger patients.

### NONCLINICAL TOXICOLOGY

#### Carcinogenesis, Mutagenesis, Impairment of Fertility

Nepafenac has not been evaluated in long-term carcinogenicity studies. Increased chromosomal aberrations were observed in Chinese hamster ovary cells exposed *in vitro* to nepafenac suspension. Nepafenac was not mutagenic in the Ames assay or in the mouse lymphoma forward mutation assay. Oral doses up to 5,000 mg/kg did not result in an increase in the formation of micronucleated polychromatic erythrocytes *in vivo* in the mouse micronucleus assay in the bone marrow of mice. Nepafenac did not impair fertility when administered orally to male and female rats at 3 mg/kg.

### PATIENT COUNSELING INFORMATION

#### Slow or Delayed Healing

Patients should be informed of the possibility that slow or delayed healing may occur while using nonsteroidal anti-inflammatory drugs (NSAIDs).

#### Avoiding Contamination of the Product

Patients should be instructed to avoid allowing the tip of the dispensing container to contact the eye or surrounding structures because this could cause the tip to become contaminated by common bacteria known to cause ocular infections. Serious damage to the eye and subsequent loss of vision may result from using contaminated solutions.

Use of the same bottle for both eyes is not recommended with topical eye drops that are used in association with surgery.

#### Contact Lens Wear

ILEVRO® Suspension should not be administered while wearing contact lens.

#### Intercurrent Ocular Conditions

Patients should be advised that if they develop an intercurrent ocular condition (e.g., trauma, or infection) or have ocular surgery, they should immediately seek their physician's advice concerning the continued use of the multi-dose container.

#### Concomitant Topical Ocular Therapy

If more than one topical ophthalmic medication is being used, the medicines must be administered at least 5 minutes apart.

#### Shake Well Before Use

Patients should be instructed to shake well before each use.

U.S. Patent Nos. 5,475,034; 6,403,609; and 7,169,767.

©2023 Harrow 06/23 IVRO-00012



**HARROW®**  
Your patients. Our purpose.





# The March Of Time

*Musings on life, medicine and the practice of ophthalmology.*

**MARK H. BLECHER**  
CHIEF MEDICAL EDITOR

I was fortunate enough to have a wonderful vacation this summer—one of my ‘bucket list’ trips: an in-depth visit to Norway. It’s a magnificent country, with majestic mountains, waterfalls, glacier lakes, and interesting cities and towns—the whole thing. And, as one does, we took a lot of pictures of said mountains and beautiful vistas. Of course, to prove we were there, we took pictures of us standing in front of all those magnificent places, too. The whole nine yards. Very cliché, but somewhat expected.

I had the opportunity on the long flight back home to review them in order to see what I wanted to keep, delete, print and share. And in so many of them there was this gray-haired, wrinkled, squinty-eyed old man photobombing my pictures! I had

hoped I would see that dapper, handsome, bon vivant I was used to seeing but somehow that was not to be. Someone must have stolen that portrait I had hidden in the attic, as I now hardly recognized myself. It’s curious that looking at myself in the bathroom mirror every morning wasn’t warning enough: There was something about the static image of the photo that was particularly surprising and jarring at the same time—and a bit depressing.

It’s not that I’m afraid of growing older, or of my mortality. Nor do I feel that much older. OK, I guess I do feel somewhat more sedentary, but I’ve been blaming that on the pandemic and the interruption of my previous routines. And yes, I make noises when I get up from sitting down, but I didn’t have the self-awareness of how both my physical appearance or my engagement with life have changed. At one point in this somewhat energetic trip, I must have

demurred to going on another hike or something and got told to “Stop acting like an 85-year-old.” That was a shock. My response of course was that I was “just practicing.” However, as I thought about it, it’s not as far away as it should have sounded. And acting it is definitely worse than actually being it, at any age.

I do like to think that I’ve dealt with my ongoing ‘maturation’ pretty well, but really, who thinks of themselves as getting old? I imagine that most people have an awareness in their head of a version of themselves many decades younger. We don’t really see what we see; that person in the mirror is just poor lighting. I mean who really embraces feeling old? And if you don’t feel old, why should you look old? I know that’s very vain and superficial, but hey there’s a lot of money to be made addressing this insecurity. It’s very unlikely that I’ll do much about it, but maybe I should start using sunscreen. I’m way too much of a baby to get filler and Botox that I’d have to repeat every few months. So, I’m left to internalizing that slightly unsettling vision of myself as the current me. It’s inevitable.

It could be worse: I still do really think though that feeling and acting older is the sin, not the wrapper it comes in. ◀



This article has no commercial sponsorship.

Dr. Blecher is an attending surgeon at Wills Eye Hospital.

# DRY-EYE TREATMENTS CONTINUE TO EVOLVE

Every year, clinicians' understanding of dry-eye disease changes as more findings and treatments surface in eye care.

ANDREW BEERS  
ASSOCIATE EDITOR

**D**ry eye affects millions of patients, and clinicians need to understand the signs and symptoms of the disease in order to help mitigate dry eye's effects. Dry eye is difficult to define, which leads clinicians to categorize the disease as mild, moderate and severe for most cases. But there's always underlying factors that go unrecognized which lead to ineffective treatment options for dry eye. "The key to dry-eye treatment is early identification, early intervention and prevention as much as possible," says Christopher Starr, MD, an ophthalmologist at Weill Cornell Medicine in New York and a global ambassador for the Tear Film and Ocular Surface Society.

This article will examine various treatment options to help clinicians manage DED after identifying all signs and symptoms.

## The Roots of Dry Eye

"Dry eye is an umbrella term. It

includes different symptoms and signs all of which can be driven by various contributors," says Anat Galor, MD, MSPH, an ophthalmologist at the University of Miami Health System in Florida.

The eye is affected everyday by many factors contributing to dry eye, which make it more difficult to define DED.

Initially, dry eye was defined as a disorder, instead of a disease, that lead to tear deficiency and tear evaporation, but this definition failed to describe any specific pathophysiologic basis.<sup>1</sup> In the TFOS DEWS report, society members defined dry eye as a disease for the first time, but many clinicians interpreted this definition as primarily diagnostic criteria.<sup>1</sup> The current TFOS definition for DED was described in the DEWS II report. It states that "Dry eye is a multifactorial disease of the ocular surface characterized by a loss of homeostasis of the tear film, and accompanied by ocular symptoms, in which tear film instability and hyperosmolarity, ocular surface inflammation and damage, and neurosensory abnormalities play etiological roles."<sup>1</sup>

"There has to be a balance of all the key components of the ocular surface, the tear film and various mechanisms, from sensation and corneal nerves to the brain with the trigeminal and the lacrimal functional unit of all the lacrimal glands and the accessory lacrimal glands, to the meibomian glands and the goblet cells," says Dr. Starr. "All of these things need to be in tight homeostasis regulation."

## At-Home Treatments

"No matter what's causing symptoms, there are a few things individuals can do on their own before they seek care," continues Dr. Galor. "These include buying tear supplements, marketed under the term artificial tears, that have various viscosities and different compounds."

Over recent years, many preservative-free eye drops began making their way on the market. Each eye drop is a unique solution with different properties to help treat various symptoms of DED. "I don't think there's a right artificial tear supplement; it's more what works

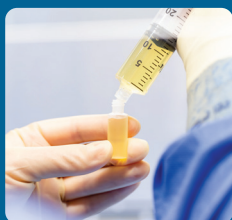This article has no commercial sponsorship.

Dr. Starr is a consultant for Allergan, Bausch + Lomb, Kala Pharmaceuticals, Novartis Pharmaceuticals and Oyster Point Pharma and has been affiliated with the Bausch + Lomb medical education program. Dr. Galor is a consultant for Novaliq, Novartis Pharmaceuticals, AstraZeneca, Dompé, Tarsus, Bausch + Lomb, and Allergan. Dr. Akpek is a consultant for Dompé, HanAll, Iolyx, Kyria, Novaliq, Sinqi and Xequel and has received research support from Novartis Pharmaceuticals and Ocular Therapeutics.



# Serum Tears Made Simple.

Think serum tears are hard to get?  
Learn how **Vital Tears** has simplified the process.



At Vital Tears, our mission is to make serum tears easily available and affordable for your patients. We've done that for patients across the country through our:

- **Rapid serum drop delivery**
- **Convenient blood draw options**
- **Affordable payment options**
- **Superior customer service**

SCAN THIS CODE TO DOWNLOAD OUR  
PHYSICIAN INFORMATION PACKET



OR CALL TOLL-FREE (800) 360-9592

 **Vital Tears™**  
THE LEADER IN SERUM TEARS

for an individual person, finding the right composition and viscosity that improves symptoms and doesn't blur vision," says Dr. Galor. "The more viscous the artificial tear, the more likely it is to blur vision temporarily. We try to steer people away from preservatives like BAK that can have adverse effects on nerves and epithelial cells, but there are lots of great products out there for people to try."

While artificial tears are useful, they aren't always the best solution for all cases. "If a patient is having to use these eye drops eight times a day or more, they'd better switch to a gel form or ointment," says Esen Akpek, MD, an ophthalmologist at Johns Hopkins Sjögren's Center in Maryland. "We have the impression that instilling too many eye drops could be harmful to the ocular surface by washing the mucin and oil components of the tear film."

Other ways to treat mild dry-eye cases include home remedies that are simple for patients to include in their daily regimen. "Warming up the eyelids is a tried-and-true over-

the-counter maintenance therapy, and there are many ways of doing that from run-of-the-mill washcloths under warm water to microwaving potatoes and putting them in socks to tea bags," says Dr. Starr. "There are more sophisticated methods. For instance, the Bruder company has something call the Bruder Moist Heat Eye Compress, which is a reusable, microwavable mask."

"Another thing people can do on their own is recognize that symptoms and signs of dry eye can be driven by environmental contributors, so it's important to consider the environment around you," says Dr. Galor. "Optimizing temperature and humidity, maintaining a clean environment as much as you can by changing your air filter, addressing sources of mold and installing an air purifier are all ways to improve your indoor environment."

One environment that many patients neglect to recognize as a contributing factor is the office space. Strenuous activity in front of a screen for a long period of time eventually leads to DED complications. "Be-

ing on the computer for 12 hours a day affects your blink rate, which can affect your tear metrics," says Dr. Galor. "People talk about the 20/20/20 rule: Set a timer, stand up, and blink a few times. Take breaks and consider the work environment. For example, installing a humidifier if your work area is arid may help your eyes feel better." The 20/20/20 rule suggests that patients suffering from DED should set a timer for 20 minutes during computer use. Then, after the timer goes off, they should stand for 20 seconds staring and blinking at an object 20 feet away. This helps reduce screen time and encourages an increase in blink rate.

### Antibiotics and Anti-Inflammatories

"If a patient has physician-measured clinical signs consistent with dry eye, such as decreased tear production as measured with Schirmer's, ocular surface damage, evidenced by lissamine green or fluorescein staining, or increased osmolarity, then I definitely go on to the next step, which is

**TABLE 1. SOME TEAR REPLACEMENT THERAPIES**

Product	Company	Notes
iVizia	Similasan	A preservative-free artificial tear with sodium hyaluronate, polymers and trehalose. Available in multidose bottles. Lubricant eye gel available in single-dose vials.
Clear Eyes Pure Relief	Prestige Consumer Healthcare	A preservative-free artificial tear formulated with glycerin and sodium hyaluronate. Available in multidose bottles.
Optase Dry Eye Intense	Scope	A preservative-free artificial tear with hyaluronic acid. The MGD Advanced lipid-based drop is also preservative-free. Both are available in multidose bottles.
Biotrue	Bausch + Lomb	A preservative-free artificial tear with hyaluronic acid. Available in single-dose vials and multidose bottles. Safe to use with contact lenses.
Blink Triple Care	J&J Vision	A hypo-osmolar viscoelastic formula that mimics human tears to restore the tear film and provide relief from dry-eye symptoms by regulating osmolarity levels.
Retain HPMC	Ocusoft	A hypromellose ophthalmic solution 0.3% that relieves dry-eye symptoms by resembling natural tears.
Freshkote	Eyevance	Supports the eye's tear film with antimicrobials and a blend of polyvinyl alcohol 2.7% and povidone 2%, which results in high oncotic pressure on the ocular surface to draw excess water from epithelial cells. Preservative-free.
Systane Hydration	Alcon	A preservative-free artificial tear formulated for sensitive eyes with HydroBoost. Available in multidose bottles.
Soothe XP Emollient	Bausch + Lomb	Restores the lipid layers with mineral oils to seal in moisture and protect against irritation.
Refresh Optive Mega-3	Allergan	Restores the lipid layer with a natural oil blend and relieves MGD symptoms. Includes carboxymethylcellulose sodium 0.5%, glycerin 1% and polysorbate 80 0.5%. Preservative-free.
Refresh Celluvisc	Allergan	A preservative-free artificial tear gel that contains carboxymethylcellulose sodium 1%.
TheraTears	TheraTears	A hypotonic, electrolyte-balanced formula that replicates healthy tears.



prescription eye drops,” says Dr. Akpek. “It’s important to choose the eye drop according to the clinical finding. We need to differentiate aqueous-deficient from evaporative dry eye.”

In the past, corticosteroids have been used off-label to treat inflammation in dry-eye patients. “I have a very low threshold for steroid use for inflamed eyes,” says Dr. Starr. “There’s now an FDA approved steroid for dry-eye disease flares, Eysuvis.”

Eysuvis (loteprednol etabonate 0.25%, Kala Pharmaceuticals), Lotemax (loteprednol etabonate 0.5%, Bausch + Lomb) and Flarex FML (fluorometholone acetate 0.1%, Eyevance) in rapidly relieving the symptoms and signs of moderate or severe dry eye.<sup>2</sup>

“Anti-inflammatories, like cyclosporine products and lifitegrast, are generally used as a first-line therapy in people who have an immune component to their dry eye, such as Sjögren’s, graft-versus-host disease and other autoimmune diseases,” adds Dr. Galor. “But, of course, there are no absolutes and there are a lot of crossovers, so people

with autoimmune dry eye also get MGD, and they often get prescribed antibiotics. People who have ocular surface inflammation, without a known autoimmune disease, often get a trial of an anti-inflammatory medication.”

Other ways to reduce inflammation in dry-eye patients is by treating with antibiotics. “A lot of the antibiotics that we use in the realm of ocular surface disease actually have some anti-inflammatory properties, and that’s where doxycycline, minocycline and azithromycin—both topical and oral—have antibiotic properties which can certainly help when there’s bacteria that are sensitive to those antibiotics,” says Dr. Starr. “They can help debulk the bacterial load, the lid margin and the ocular surface, and can play a role in everything from bacterial conjunctivitis to things like MGD and anterior blepharitis. Their anti-inflammatory properties are beneficial in the ocular surface diseases where inflammation is the core mechanism and pathophysiology.”

A novel approach to reducing inflammation and increasing tear

production is Oyster Point’s Tyrvaya (varenicline). “It’s a secretagogue that is applied to the nasal mucosa,” says Dr. Akpek. “Tyrvaya could be a good replacement for over-the-counter drops because it stimulates the natural tears and doesn’t upset tear-film homeostasis through drop instillation.”

Dr. Starr adds that “this neuro-stimulation nasal spray for dry eye very likely reduces inflammation with long-term treatment.”

### Treating MGD and Blepharitis

“MGD can present itself in several ways,” says Dr. Galor. “Some patients present with plugging and/or keratinization of the gland openings, others with thick, toothpaste-like meibum or gland dropout. Over-the-counter approaches to MGD including heating masks along with eyelid hygiene. There are several products available over the counter for this purpose.

“There are also a lot of office-based procedures that target different aspects of MGD,” Dr. Galor continues. “When people have intact glands but poor meibum quality, a procedure

**TABLE 2. SOME OPTIONS FOR TREATING INFLAMMATION, PROMOTING TEAR PRODUCTION AND/OR RESTORING THE OCULAR SURFACE**

Product	Company	Notes
Tyrvaya	Oyster Point	A prescription varenicline solution nasal spray that stimulates the trigeminal nerve to naturally increase tear production.
Restasis	Allergan	A prescription ophthalmic emulsion (cyclosporine 0.05%) that increases the eye's natural ability to produce tears and reduces inflammation.
Generic cyclosporine ophthalmic emulsion 0.05%	Mylan Pharmaceuticals	A Restasis generic (cyclosporine ophthalmic emulsion 0.05%), available in single-use vials.
Cequa	Sun Ophthalmics	A cyclosporine ophthalmic solution 0.09%; this prescription drop increases tear production using nanomicellar technology.
Xiidra	Novartis	A prescription drop (lifitegrast ophthalmic solution 5%) that targets the source of dry-eye inflammation.
Lotemax	Bausch + Lomb	A loteprednol etabonate ophthalmic suspension 0.5% often used off-label for treating dry eye.
Inveltys	Kala Pharmaceuticals	A loteprednol etabonate ophthalmic suspension 1% with mucus-barrier penetration technology, often used off-label for treating dry eye.
Eysuvis	Kala Pharmaceuticals	A loteprednol etabonate ophthalmic suspension 0.25% with mucus-barrier penetration technology for dry eye.
Klarity-L Drops	ImprimisRx	A preservative-free loteprednol-chondroitin 0.5% ophthalmic suspension for controlling acute inflammation.
Klarity-C Drops	ImprimisRx	A preservative-free cyclosporine ophthalmic emulsion 0.1%.
Oxervate	Dompé	A cenergermin-bkbj ophthalmic solution 0.02% (recombinant human nerve growth factor) for treating neurotrophic keratitis.
iTear100	Olympic Ophthalmics	A handheld, noninvasive neurostimulator that stimulates the trigeminal nerve to increase tear production.
Veveye	Novaliq	A cyclosporine ophthalmic solution 0.1% indicated for the treatment of inflammation and other symptoms of dry-eye disease.

When Selecting a Prescription  
Dry Eye Treatment

**DON'T**

**MAKE  
HER  
WAIT.**



Not an actual patient.

### **Indication**

Xiidra® (lifitegrast ophthalmic solution) 5% is indicated for the treatment of signs and symptoms of dry eye disease (DED).

### **Important Safety Information**

- Xiidra is contraindicated in patients with known hypersensitivity to lifitegrast or to any of the other ingredients.
- In clinical trials, the most common adverse reactions reported in 5-25% of patients were instillation site irritation, dysgeusia and reduced visual acuity. Other adverse reactions reported in 1% to 5% of the patients were blurred vision, conjunctival hyperemia, eye irritation, headache, increased lacrimation, eye discharge, eye discomfort, eye pruritus and sinusitis.
- To avoid the potential for eye injury or contamination of the solution, patients should not touch the tip of the single-use container to their eye or to any surface.



**Novartis Pharmaceuticals Corporation**  
East Hanover, New Jersey 07936-1080





**CHOOSE XIIDRA**  
Because lasting symptom  
relief can start as early as  
**2 WEEKS<sup>1\*</sup>**



Access to Xiidra is  
better than ever<sup>2</sup>

\*Xiidra reduced symptoms of eye dryness at 2 weeks (based on Eye Dryness Score compared to vehicle) in 2 out of 4 studies, with improvements observed at 6 and 12 weeks in all 4 studies.<sup>1†</sup>

### Important Safety Information (cont)

- Contact lenses should be removed prior to the administration of Xiidra and may be reinserted 15 minutes following administration.
- Safety and efficacy in pediatric patients below the age of 17 years have not been established.

**Please see Brief Summary of Important Product Information on adjacent page.**

#### <sup>†</sup>Pivotal trial data

The safety and efficacy of Xiidra were assessed in four 12-week, randomized, multicenter, double-masked, vehicle-controlled studies (N=2133). Patients were dosed twice daily. **Use of artificial tears was not allowed during the studies.** The study end points included assessment of signs (based on Inferior fluorescein Corneal Staining Score [ICSS] on a scale of 0-4) and symptoms (based on patient-reported Eye Dryness Score [EDS] on a visual analogue scale of 0-100).<sup>1</sup>

Effects on symptoms of dry eye disease: A larger reduction in EDS favoring Xiidra was observed in all studies at day 42 and day 84. Xiidra reduced symptoms of eye dryness at 2 weeks (based on EDS) compared to vehicle in 2 out of 4 clinical trials.<sup>1</sup>

Effects on signs of dry eye disease: At day 84, a larger reduction in ICSS favoring Xiidra was observed in 3 of the 4 studies.<sup>1</sup>

**References:** 1. Xiidra [package insert]. East Hanover, NJ: Novartis Pharmaceuticals Corp. 2. Data on file. DRF Fingertip Formulary<sup>®</sup> Novartis Pharmaceuticals Corp; July 2022.

**XIIDRA, the XIIDRA logo and ii are registered trademarks of Novartis AG.**

**XIIDRA® (lifitegrast ophthalmic solution), for topical ophthalmic use**

**Initial U.S. Approval: 2016**

**BRIEF SUMMARY: Please see package insert for full prescribing information.**

**1 INDICATIONS AND USAGE**

Xiidra® (lifitegrast ophthalmic solution) 5% is indicated for the treatment of the signs and symptoms of dry eye disease (DED).

**4 CONTRAINDICATIONS**

Xiidra is contraindicated in patients with known hypersensitivity to lifitegrast or to any of the other ingredients in the formulation [see *Adverse Reactions (6.2)*].

**6 ADVERSE REACTIONS**

The following serious adverse reactions are described elsewhere in the labeling:

- Hypersensitivity [see *Contraindications (4)*]

**6.1 Clinical Trials Experience**

Because clinical trials are conducted under widely varying conditions, adverse reaction rates observed in clinical trials of a drug cannot be directly compared to rates in the clinical trials of another drug and may not reflect the rates observed in practice.

In five clinical trials of DED conducted with lifitegrast ophthalmic solution, 1401 patients received at least one dose of lifitegrast (1287 of which received lifitegrast 5%). The majority of patients (84%) had less than or equal to 3 months of treatment exposure. One hundred-seventy patients were exposed to lifitegrast for approximately 12 months. The majority of the treated patients were female (77%). The most common adverse reactions reported in 5%-25% of patients were instillation-site irritation, dysgeusia, and reduced visual acuity.

Other adverse reactions reported in 1%-5% of the patients were blurred vision, conjunctival hyperemia, eye irritation, headache, increased lacrimation, eye discharge, eye discomfort, eye pruritus, and sinusitis.

**6.2 Postmarketing Experience**

The following adverse reactions have been identified during post-approval use of Xiidra. Because these reactions are reported voluntarily from a population of uncertain size, it is not always possible to reliably estimate their frequency or establish a causal relationship to drug exposure.

Rare serious cases of hypersensitivity, including anaphylactic reaction, bronchospasm, respiratory distress, pharyngeal edema, swollen tongue, urticaria, allergic conjunctivitis, dyspnea, angioedema, and allergic dermatitis have been reported. Eye swelling and rash have also been reported [see *Contraindications (4)*].

**8 USE IN SPECIFIC POPULATIONS**

**8.1 Pregnancy**

Risk Summary

There are no available data on Xiidra use in pregnant women to inform any drug-associated risks. Intravenous (IV) administration of lifitegrast to pregnant rats, from pre-mating through gestation day 17, did not produce

teratogenicity at clinically relevant systemic exposures. Intravenous administration of lifitegrast to pregnant rabbits during organogenesis produced an increased incidence of omphalocele at the lowest dose tested, 3 mg/kg/day (400-fold the human plasma exposure at the recommended human ophthalmic dose [RHOD], based on the area under the curve [AUC] level). Since human systemic exposure to lifitegrast following ocular administration of Xiidra at the RHOD is low, the applicability of animal findings to the risk of Xiidra use in humans during pregnancy is unclear [see *Clinical Pharmacology (12.3) in the full prescribing information*].

Data

Animal Data

Lifitegrast administered daily by IV injection to rats, from pre-mating through gestation day 17, caused an increase in mean pre-implantation loss and an increased incidence of several minor skeletal anomalies at 30 mg/kg/day, representing 5,400-fold the human plasma exposure at the RHOD of Xiidra, based on AUC. No teratogenicity was observed in the rat at 10 mg/kg/day (460-fold the human plasma exposure at the RHOD, based on AUC). In the rabbit, an increased incidence of omphalocele was observed at the lowest dose tested, 3 mg/kg/day (400-fold the human plasma exposure at the RHOD, based on AUC), when administered by IV injection daily from gestation days 7 through 19. A fetal no observed adverse effect level (NOAEL) was not identified in the rabbit.

**8.2 Lactation**

Risk Summary

There are no data on the presence of lifitegrast in human milk, the effects on the breastfed infant, or the effects on milk production. However, systemic exposure to lifitegrast from ocular administration is low [see *Clinical Pharmacology (12.3) in the full prescribing information*]. The developmental and health benefits of breastfeeding should be considered, along with the mother's clinical need for Xiidra and any potential adverse effects on the breastfed child from Xiidra.

**8.4 Pediatric Use**

Safety and efficacy in pediatric patients below the age of 17 years have not been established.

**8.5 Geriatric Use**

No overall differences in safety or effectiveness have been observed between elderly and younger adult patients.

Distributed by:  
Novartis Pharmaceuticals Corporation  
One Health Plaza  
East Hanover, NJ 07936  
T2020-87



that heats and/or massages the lids can be used. Some of the clinically available devices include LipiFlow [J&J Vision], Systane iLux2 [Alcon] and TearCare [SightSciences], to name a few.”

“Some people have keratinization and/or obstruction of their meibomian glands, and in this, situation eyelid probing can be considered,” says Dr. Galor. “For this procedure, a small probe is introduced

into the meibomian gland opening to try to relieve the obstruction.” For example, Maskin MGI probes (Katena) along with a jojoba anesthetic ointment containing 8% lidocaine releases periductal fibroses from meibomian glands, freeing glands from strictures that block the flow of indispensable meibum.<sup>3</sup>

“IPL, or intense pulse light, is gaining traction, and there’s growing evidence that it can help treat some

forms of blepharitis and MGD with intense pulses of light, often in patients with rosacea and ocular lid margin disease,” says Dr. Starr. Products such as OptiLight (Lumenis) and LacryStim IPL (Quantel Medical) use wavelengths of light to stimulate the meibomian glands to facilitate the secretion of meibum, along with other beneficial mechanisms.

“Blepharitis is tied to dry-eye disease because it has an impact on

**TABLE 3. A SAMPLE OF TREATMENTS FOR BLEPHARITIS & MEIBOMIAN GLAND DYSFUNCTION**

Product	Company	Notes
<b>For Blepharitis &amp; Lid Hygiene</b>		
BlephEx	BlephEx	A painless, in-office device that helps maintain and clean the eyelid margins. Removes bacteria, biofilm and bacterial toxins. Replacement tips available.
NuLids	NuSight Medical	An at-home treatment for dry eye and lid hygiene. An oscillating tip stimulates the meibomian glands and cleans away debris.
Ocusoft Lid Scrub	Ocusoft	Contains a non-irritating formula that removes dirt, oil, debris and pollen from the eyelids.
Sterilid	TheraTears	An eyelid cleanser for removing external irritants from lids and lashes.
Avenova	NovaBay Pharmaceuticals	A hypochlorous acid wash 0.01% for long-term hygiene management of blepharitis. Kills a broad spectrum of bacteria.
Cliradex	BioTissue	A tea-tree-oil-based cleanser that relieves symptoms associated with <i>Demodex</i> , blepharitis, MGD, rosacea, dry eye, chalazion and other lid margin diseases. Comes in towelettes and light foam. Preservative-free.
I-Lid ‘N Lash Pro	I-MED Pharma	A professional-use hydrating cleansing gel with 20% tea tree oil for removing ocular debris and intensive cleaning of the lids and lashes. Available in a 50-mL metered dose pump.
Xdemvy	Tarsus	A lotilaner ophthalmic solution 0.25% indicated for the treatment of <i>Demodex</i> blepharitis.
TheraPearl Eye Mask	Bausch + Lomb	A hot-and-cold therapy that helps to alleviate dry eye.
<b>For Meibomian Gland Dysfunction</b>		
LipiFlow	J&J Vision	A vector thermal pulsation system for treating MGD in the office. Delivers therapeutic pulsation energies to meibomian glands to liquefy and evacuate meibum.
Systane iLux2	Alcon	A handheld, portable device that targets the meibomian glands with light-based heat and compression under direct visualization in less than 12 minutes.
TearCare	SightSciences	An open-eye, blink-associated device suite that delivers consistent thermal energy to the lid structure.
MiBo Thermoflo	MiBo Medical Group	Treats dry eye by delivering consistent, emissive heat and ocular massage to the meibomian glands.
eyeXpress	Holbar Medical Products	An eye hydration system for in-office therapy. A goggle system delivers uniform, regulated heat to the lid structure.
OptiLight	Lumenis	An intense pulsed light system for MGD indicated for professional use in patients 22 or older with moderate to severe DED and with Fitzpatrick skin types I-IV.
LacryStim IPL	Quantel Medical	Intense pulsed light system that uses a unique wavelength spectrum and train of pulses to stimulate the lacrimal and meibomian glands, reduce inflammation and improve tear film quality.
Epi-C PLUS	Espansione Group	A no-gel IPL with low-level laser therapy approved for dermatological use in the U.S. For ophthalmic use, white and yellow masks stimulate lymphatics and increase drainage. Wavelength: 633 ±10 nm; emission power: 100 mW per cm <sup>2</sup> .
Thermal 1-Touch	Ocusoft	A localized heat therapy that applies heat and gentle pressure to the lids to release meibum.
Miebo	Bausch + Lomb; Novaliq	A perfluorohexyloctane ophthalmic solution indicated for the treatment of signs and symptoms associated with meibomian gland dysfunction.

the meibomian glands,” says Dr. Starr. “If there’s blepharitis, I want to know if it’s anterior, posterior or both; if it’s due to bacteria, to *Demodex*, to medications, to hormones, or to a whole host of things, because that helps me to guide my treatment.”

Depending on whether the blepharitis is anterior, posterior or mixed, the treatment options may differ. “When people have anterior blepharitis, removing the debris on the eyelashes with BlephEx is an option,” says Dr. Galor. BlephEx is a microblepharoexfoliation device that removes bacteria and toxins from the eyelids. For posterior treatments, Cliradex (BioTissue), containing 4-terpineol, a compound found in tea tree oil, cleanses the eyelid, ridding the surface of *Demodex*. Additionally, practitioners now have access to Xdemvy (lotilaner ophthalmic solution 0.25%), the first FDA-approved treatment for *Demodex* blepharitis.

“When you start talking about parasitic mites that live in your eyelids and crawl out onto your eyelid margin and deposit eggs and waste products on your eyelashes, that’s really an uncomfortable conversation to have with a patient,” says Dr. Starr. “If you see the collarettes, it’s pathognomonic and you want to decrease the mite

burden and population.”

### Contact Lenses

There’s also an interplay between contact lens use and dry-eye signs and symptoms.

“Contact lens wear can affect the eye in two ways: First, we think it affects the health of the meibomian glands,” says Dr. Galor. “Patients who are long-time contact lens wearers often have meibomian gland dropout on exam. We believe that contact lens wear at least partially contributes to this finding. Second, contact lens wear can also impact corneal nerves. People who wear contact lenses for a long time sometimes lose nerve sensitivity, so they don’t respond to the environment as robustly as they should.”

Proposing daily disposable contact lenses can help reduce the risk of DED. “We find that the daily disposable contact lenses with the more modern materials tend to be the safest of all and provide the least induction of major ocular surface issues in dry eye,” says Dr. Starr. “These tend to be very well tolerated, leading to lower risks of infections and hypoxia.”

For more severe dry-eye cases, clinicians can offer more durable and advanced contact lens options. “Scleral lenses are a good option for individu-

als with very low tear production and corneal and conjunctival epithelial disruption,” says Dr. Galor. “Scleral lenses produce an artificial tear layer underneath the lens that protects the surface during the day. You can also put autologous serum tears in the scleral lens to give the surface extra growth factors.”

Patients should be well educated about other treatment options and the long-term effects of scleral lenses before moving forward. “They are permanent in that the patient will have to wear them for prolonged periods of time,” says Dr. Akpek. “It’s not an interim treatment. It’s sort of like a last-resort treatment, and that’s usually done after attempting to improve the tear secretion or production and then lessening the tear loss by basically blocking the tear ducts and putting the patient on the autologous tears to renew and regenerate the epithelium.”

### Autologous Serum Eye Drops

As pointed out in the previous section, autologous serum tears can go hand-in-hand with scleral lenses, as well as other lens options. Formulating autologous serum eye drops is a process in which the cellular and liquid components of a patient’s blood are separated in a diluted saline solution,

**TABLE 4. SOME PUNCTAL PLUGS & SCLERAL LENS OPTIONS**

Product	Company	Notes
<b>Punctal Plugs for Aqueous Deficiency</b>		
Vera180	Lacrivera	Synthetic, absorbable lacrimal plugs (poly-p-dioxanone) designed to provide temporary occlusion for approximately 180 days. Available in sizes of 0.2 to 0.5 mm.
Soft Plug Extended Duration	Oasis Medical	A short-term plug (less than three months). Available in sizes of 0.2 to 0.5 mm. Also available: absorbable collagen and permanent intracanalicular plugs.
<b>Scleral Lenses for Severe Dry Eye</b>		
PROSE	BostonSight	A gas-permeable prosthetic device that reduces dry-eye symptoms of pain and light sensitivity and supports ocular surface healing.
DigiForm	TruForm Optics & Contamac	A scleral lens made of material with a low wetting angle to alleviate dry-eye symptoms, corneal distortion and surface irregularities. Also available in Optimum Extra and Optimum Extreme.
Onefit	Blanchard Contact Lenses	A scleral lens to help alleviate end-of-day dryness symptoms and intolerance of environmental effects with soft lenses. Provides a thin fluid cushion over the eye.
Boston IV	Bausch + Lomb	A rigid, gas-permeable contact lens with a non-stick surface that resists dirt and debris. B+L says it’s an economical choice for vision correction and dry eye. Other options such as the Boston XQ2, XO, EO and ES have B+L’s Tangible Hydra-PEG coating technology, which B+L says increases surface water retention and lubricity and minimizes deposits on the lens.



which contains biological nutrients that are similarly present in tears.<sup>4</sup>

“For me, the autologous serum drops are generally reserved for the more advanced, higher-severity-level ocular surface and dry-eye disease patients,” says Dr. Starr. “Because one will try traditional treatments first from over-the-counter products to FDA-approved prescription medications, punctal plugs, procedural treatments, and so on. It’s in patients with more severe disease—these are generally cases with autoimmune disease, chemical burns and chronic cicatrizing issues—that’s not necessarily amenable to multiple traditional treatments.”

Dr. Akpek elaborates further on how to use these eye drops. “In those patients who don’t respond to, for example, bandage contact lenses, punctal plugs or trying to improve the corneal epithelium, autologous serum tears with a concentration from 20 to 100 percent, four-to-six

times a day, could be used,” says Dr. Akpek. “In order to enhance corneal epithelium regeneration, I do frequently employ autologous serum eye drops, whether the dry eye is aqueous deficient or evaporative.”

“**The key to dry-eye treatment is early identification, early intervention and prevention as much as possible.**

— Christopher Starr, MD

### Recent FDA Approvals

There have been recent FDA approvals as well. Miebo (Bausch + Lomb; Novaliq) Vevye (Novaliq) and Xdemvy (Tarsus) are the latest treatments to receive approval in 2023.

Miebo (perfluorohexyloctane ophthalmic solution, Bausch + Lomb), originally NOV03, is a prescription

eye drop for DED that directly targets tear evaporation, especially in cases with MGD. Miebo underwent two Phase III studies, GOBI and MOJAVE. According to the clinical studies, Miebo met both its primary sign and symptom efficacy endpoints. The two primary endpoints studied were the change from baseline at week eight in total corneal fluorescein staining (tCFS) and eye dryness Visual Analog Scale (VAS) score. Researchers reported that Miebo patients experienced relief from their symptoms as early as day 15 with statistically significant reductions in VAS eye dryness scores. There was also a significant reduction in tCFS at day 15 as observed in both studies. The most common adverse reactions patients experienced were blurred vision (1.3 percent, GOBI; 3 percent, MOJAVE) and eye redness (1 percent, GOBI; 3 percent, MOJAVE).

Vevye (cyclosporine 0.1%, Novaliq),

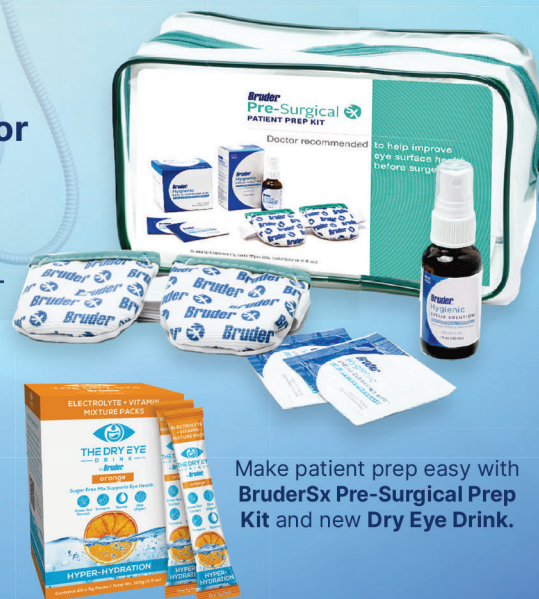*(Continued on p. 56)*

# Empower your patients to take part in their surgical success

The benefits of having a healthy ocular surface prior to cataract surgery are well established.

Bruder products can help.

Recommending three easy steps - **hygiene, heat and hydration** - empowers patients to participate in better pre- and post-operative results. By cleaning the lids and lashes and reducing bacteria with Bruder lid hygiene products; unclogging meibomian glands with a Bruder Mask; and hydrating with Dry Eye Drink, patients can help stabilize the tear film. The result: more accurate pre-surgical measurements, while improving post-op recovery and ultimately, vision.



Make patient prep easy with BruderSx Pre-Surgical Prep Kit and new Dry Eye Drink.



Scan to download the Bruder Patient Empowerment Guide and see what doctors are saying about patient prep.

888-827-8337 | eyes@bruder.com | bruder.com/pro

**OPEN YOUR EYES**  
**to Bruder**  
a Hilco Vision Company

# HOW THE EXPERTS DIAGNOSE DRY EYE

Grading the severity of dry eye by assessing signs and symptoms helps ophthalmologists treat and follow dry-eye patients.

**MICHELLE STEPHENSON**  
CONTRIBUTING EDITOR

**T**he evaluation and diagnosis of dry eye is challenging. It's a multifactorial condition, and reported symptoms aren't always consistent with ocular surface changes. Generally, diagnosis of dry-eye disease entails patient history and slit-lamp examination, with additional testing performed as needed.

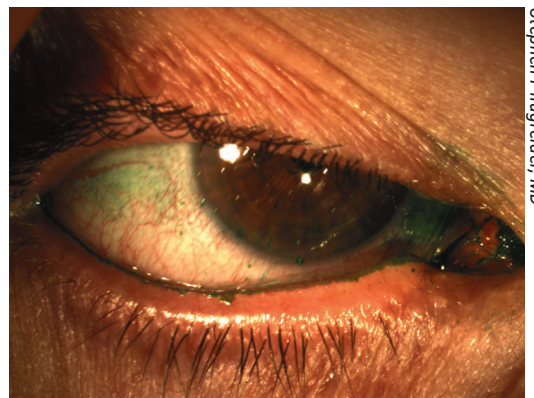
According to Stephen Pflugfelder, MD, who's in practice at Baylor College of Medicine in Houston, it's important to evaluate both signs and symptoms. "A patient could be a grade 4 from symptoms alone but not really have any signs, or he or she could be a grade 4 with signs but have no symptoms. In either case, treatment should be tailored to the severity, and it will determine how aggressive you want to be and what your options for therapy will be," he says.

## Patient Symptoms

Christopher J. Rapuano, MD, who's in practice at Wills Eye Hospital in Philadelphia, recommends starting with a history and asking about patient

symptoms. "Certain symptoms go more along with dry eye than with other conditions," he says. "The first is the time of day when the patient is experiencing symptoms. Dry-eye symptoms tend to be worse toward the end of the day or during or after concentrated visual tasks, such as reading, computer work, watching screens and driving. Environment is also important. Do patients work in an air-conditioned office or where a fan is blowing on them? Is it a cold, dry day? Those things clue me in to the diagnosis of dry eye. The severity of the symptoms typically goes along with the severity of the dry eye."

He adds that the importance of the patient's history can't be overemphasized. "I think that we miss a lot if we're not listening to the patient's symptoms," Dr. Rapuano says. "Some of those will really help us determine whether it's more dry eye, whether it's more blepharitis, and whether it has a neurotrophic component to it. We also need to find out whether the patient has a history of herpes or diabetes.



Stephen Pflugfelder, MD

**Figure 1. Conjunctival lissamine green staining with corneal filaments.**

Many diabetic patients have ocular surface issues, and it may be related to some of the neurotrophic aspects of their long-term diabetes."

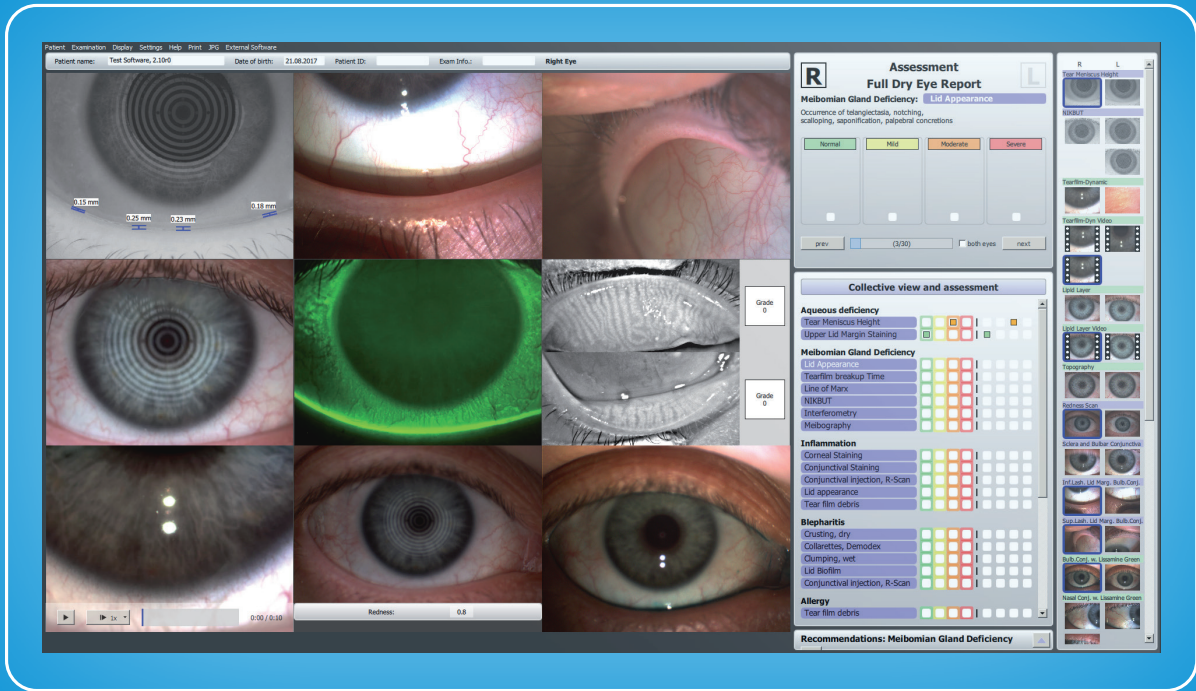
When assessing symptoms, Dr. Pflugfelder explains that there's no universal questionnaire, but that many ophthalmologists have their own questionnaires. "The ones that seem to be used the most are the Allergan OSDI and visual analog scales, like the Symptom Assessment in Dry Eye (SANDE)," he says. "DEWS grades symptoms on a scale from 1 to 4. Symptoms include discomfort, severity

This article has no commercial sponsorship.

Drs. Pflugfelder and Rapuano have no financial interests to disclose.



# Make Dry Eye Diagnosis Crystal Clear!



-  Delegable measurements
-  All results at a glance
-  Comprehensive screening



## OCULUS Keratograph® 5M with Crystal TEAR Report: All relevant information at a glance!

Dry eye management has never been this easy. The Crystal TEAR Report helps you perform comprehensive screenings, using the measuring results as a basis for diagnosing dry eye syndrome. The workflow is optimized for time saving and patient friendliness. All results are documented and summarized for you and your patient in a neat and easily understandable printout.

and frequency, and these are two questions on the SANDE questionnaire. The first one is to grade the severity of dry eye, basically from 0 to 100, and then the frequency is the second question. In grade 1, it would be mild or episodic, occurring under environmental stress, and that would range all the way to grade 4 with severe and disabling and constant symptoms, so that would probably be 100 on the questionnaire.”

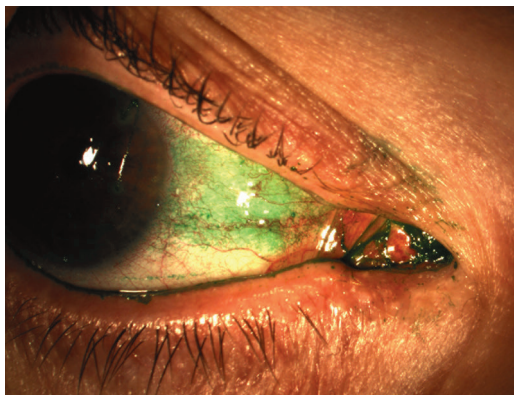Studies have shown the OSDI and the SANDE questionnaires are equally effective. In one study, data collected from the SANDE questionnaire showed a significant correlation and negligible score differences with those from the OSDI, suggesting that the SANDE visual analog scale-based questionnaire has the potential to provide clinicians with a short, quick and reliable measure for dry-eye symptoms.<sup>1</sup>

The study included 114 patients with dry-eye disease. All patients were administered the OSDI and SANDE questionnaires at baseline and follow-up visits. The correlations between both questionnaires' scores were evaluated using the Spearman coefficient, and their clinical differences were assessed using Bland-Altman analysis.

At the baseline visit, the OSDI and SANDE questionnaire scores significantly correlated. Additionally, a significant correlation was found between changes in the OSDI and SANDE scores from baseline to follow-up visits.

## Signs

Dr. Rapuano notes that slit-lamp findings are crucial for grading dry eye. “Fluorescein stain is important. The more fluorescein staining there is, the less healthy the ocular surface and the worse the dry eye,” he says. “And, I’ll often do lissamine green staining of the cornea, but especially of the conjunctiva. That’s important to me because some patients who have a lot of symptoms have a great-looking



**Figure 2. Conjunctival lissamine green staining can catch patients with symptoms but no corneal stain.**

cornea with no fluorescein staining, but they have tons of lissamine green staining of the conjunctiva, and that goes along with dry eye. Before we were performing consistent lissamine green staining, we were missing a lot of these patients.”

He often performs a Schirmer’s test on patients he is seeing for the first time. “I often don’t repeat it unless I need to, but it can be very helpful when evaluating first-time dry-eye patients,” Dr. Rapuano adds. “It’s helpful if it’s above 15 or below 5. In the 5 to 15 range, it’s often not super helpful, but the highs and the lows give me some idea of tear production. If it’s high, I’m thinking maybe it’s really not dry eye. If it’s really low, I’m thinking there’s definitely some aqueous deficiency going on here.”

According to Dr. Pflugfelder, another criterion is visual changes, which can range from nothing to constant and possibly disabling. “There could also be a decrease in the patient’s actual visual acuity. The next item is conjunctival injection, ranging from none or mild to 2+,” Dr. Pflugfelder says. “Again, there are schemes to grade injection, like the Waterloo scale. Conjunctival staining can range from none to marked, and corneal staining can range from none to severe punctate and confluent staining. DEWS criteria grade corneal signs from none to grade 4, which would be filamentary keratitis, mucus clumping, adherent debris or corneal ulceration. Then, we evaluate lids and meibomian glands.

Grade 1 would mean meibomian gland disease is variably present, and grade 3 would be that it’s definitely present and moderate to severe. The next item is fluorescein tear breakup time. Grade 1 would be variable, and grade 4 would be immediate breakup. The last criterion is the Schirmer test score, which would range from normal tear production to the most severe aqueous deficiency, which is less than 2 mm. Again, the problem is that the DEWS scale doesn’t weight any of these. There is no composite score, so it’s really a gestalt. I use the scale to grade clinical severity, and if the patient has any of the criteria for grade 3 or 4, that’s how I would grade it. It doesn’t have to be all of them, but they do usually go together.”

He adds that he doesn’t like the grading systems, but his preference is for the one from the first DEWS study. “It combines signs and symptoms. However, it could be flawed because we don’t know how to weight the signs and symptoms,” Dr. Pflugfelder explains. “Some of the dry-eye patients we see objectively don’t look like they have severe dry eye. Rapid tear breakup time may be the only sign, but their symptoms could be off the charts. Other patients who have severe autoimmune dry eye, like Sjögren’s syndrome, may have very minimal symptoms, but their corneas look horrible and they can’t see well. Right now, I’m just not aware of anything that would distinguish between those groups, but the DEWS at least includes both. I’ve been using a stepwise grading scheme from 1 to 4 if either the symptoms or the signs are bad.”

Dr. Rapuano adds that classifying dry eye is important both for determining treatment and for following patients after they’ve begun treatment. “I’ll usually call it mild, moderate, severe, or very severe,” he says. “As it gets more severe, I’m much more aggressive with my treatment. The more severe the dry eye is, the more frequently I’m following them, and I’ll increase the regimen more quickly.”

Stephen Pflugfelder, MD

# OASIS®

The ingredients of Oasis TEARS VISION® were carefully chosen to develop this patent pending formulation and support optimal visual health.

## Oasis TEARS VISION®

- Addresses age-related vision changes associated with oxidative stress and inflammation<sup>1</sup>
- Supports dietary supplementation for general eye health through antioxidant and anti-inflammatory compounds<sup>1</sup>



## Learn more with our NEW White Papers



1. Bungau S, Abdel-Daim MM, Tit DM, et al. Health Benefits of Polyphenols and Carotenoids in Age-Related Eye Diseases. Oxidative medicine and cellular longevity. 2019;2019:9783429.

Nourishing and sustaining the eye-care community—for the long term.



**View and Download  
the White Papers**

Learn More

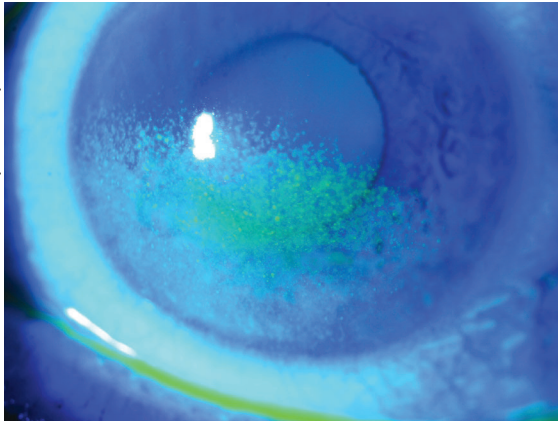
Call (844) 820-8940

Email [customerservice@oasismedical.com](mailto:customerservice@oasismedical.com)

Visit [www.oasismedical.com](http://www.oasismedical.com)



Christopher J. Rapuano, MD



**Figure 3. Severe fluorescein staining over the inferior half of the cornea in a patient with moderate to severe dry eye.**

He explains that mild dry-eye patients may be seen every three to six months, while severe patients may be seen every few weeks to a month. “If it’s mild, we start a regimen with the plan to see the patient in six months. We tell him or her to come in sooner if it’s getting worse,” Dr. Rapuano says. “Whereas, if it’s a pretty severe patient, I might see him or her in a month, or if it’s a super severe patient, I might see him or her in a week or two just to make sure there’s not any corneal erosion. For the vast majority of patients, it’s one to three months, and the three-month time period is because some of our treatments, such as Restasis or Xiidra, are getting reasonably good results by the three-month time period, so if I’m starting a patient on one of those, I often want to give the full three-month course to see whether that treatment is working or not.”

Dr. Pflugfelder says you don’t need to be overwhelmed with tests to be effective. “Ophthalmologists would be doing a great job to have a symptom questionnaire and then just follow a standardized protocol for staining the cornea and the conjunctiva, looking at the meibomian glands, and assessing tear production or volume,” Dr. Pflugfelder says. “If they’re doing that, they’re doing a great job, and with those components, they can definitely grade the severity and classify it as meibomian gland disease or aqueous deficiency. If a physician is going to

make dry eye a large part of his or her practice, he or she should probably develop a standardized protocol for diagnosis and grading.”

## DEWS II Recommendations

The Tear Film and Ocular Surface Society (TFOS) Dry Eye Workshop (DEWS) II Diagnostic Methodology Subcommittee has recommended the following order and clinical practice procedural

guidelines:<sup>2</sup>

Regarding symptoms, a positive result is a DEQ-5 score of 6 or above or an OSDI score of 13 or higher.

Regarding signs, the first step is to assess tear breakup time. According to DEWS II, three measurements should be taken, with the median value recorded. For diagnostic purposes, choose the lower median breakup value of the two eyes. The cut-off for a positive finding can be as low as 2.7 seconds for automated algorithms and up to 10 seconds for subjective observation techniques.

When non-invasive techniques cannot be used, fluorescein tear breakup time can be considered. However, because it’s more invasive, osmolarity measurement should be performed first. For fluorescein tear breakup time, fluorescein should be instilled at the outer canthus to avoid ocular surface damage. For optimal results, view the eye one to three minutes after instillation. A positive finding is a breakup time less than 10 seconds. The following tips can be helpful:

- Osmolarity should be assessed with a temperature-stabilized, calibration-checked device. A positive result is 308 mOsm/L or more in either eye or an interocular difference of more than 8 mOsm/L.

- Lissamine green staining is performed to assess conjunctival and lid margin damage. Observation should occur between one and four minutes

after instillation. Observation through a red filter potentially aids visualization. A positive score is more than nine conjunctival spots.

- Fluorescein staining is performed to assess corneal damage. Optimal viewing time is between one and three minutes after instillation, and a positive result is more than five corneal spots.

- Lid wiper epitheliopathy can be observed stained with fluorescein, rose bengal or lissamine green dyes, although there seems to be a preference for just lissamine green in recent research, with viewing recommended three to six minutes after repeat instillation using two separate strips wet with two saline drops. A positive result indicates lid wiper epitheliopathy of 2 mm or more in length and/or 25 percent or more sagittal width (excluding Marx’s line).

- Dry eye severity can vary according to the time of day, so this should be considered when interpreting results and for monitoring dry-eye disease over time.

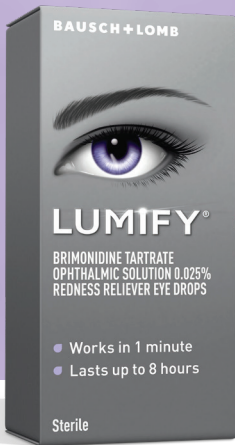
## The Future of Dry Eye

Dr. Pflugfelder says that the incidence of dry eye is on the rise. “I could see dry-eye patients 10 hours every day,” he says. “Part of it is our lifestyle and climate change. Many people work on a computer at least eight hours a day in an air-conditioned environment. There are occupational, environmental, and probably nutritional factors that are contributing to its increased prevalence. We also have an aging population.”

Dr. Rapuano agrees. “With the warming of the world, global climate change may be part of that,” he says. “Masking for the past three years was also a part of that. The air would just kind of blow up in people’s faces from the mask.” ◀

1. Amparo F, Schaumberg DA, Dana R. Comparison of two questionnaires for dry eye symptom assessment: The Ocular Surface Disease Index and the Symptom Assessment in dry eye. *Ophthalmology* 2015;122:7:1498-1503.

2. Wolffsohn JS, Arita R, Chalmers R, et al. TFOS DEWS II diagnostic methodology report. *The Ocular Surface* 2017;15:3:539-574.



# BRIGHTER LOOKING EYES WITH ONE DROP

## The Conversation Eye Care Providers Should Be Having with Patients



### Melissa Toyos, MD

Practices at Toyos Clinic located in Tennessee, Mississippi, and New York

Aesthetics are an important patient concern that can affect how they feel about themselves and around other people. Patients commonly use products and services that promise aesthetic enhancement, including lash extensions, eyelash growth treatments, colored contact lenses, eye makeup, eye creams, and serums. Increasingly, patients also seek out redness-relieving eye drops to improve the appearance of their eyes.

### Ocular Redness: A Key Patient Concern

Demand is substantial: 4 in 10 sales in the over-the-counter (OTC) eye drop category are for redness relievers.<sup>1</sup> Because ocular redness is often caused by "minor" eye irritations, patients may not recognize it as a valid concern that they can discuss with their eye care provider (ECP) and are, therefore, not always professionally counseled on which redness reliever is best for them. Without their ECP's input, patients can sometimes lean on potentially unreliable sources, such as the store shelf, their peers, commercials, or the internet. Herein lies an opportunity to educate patients and guide them through the enormous ocular redness market while also addressing the root cause of their symptoms.

### LUMIFY®: A Clinically Proven Approach to Treating Ocular Redness

LUMIFY® (brimonidine tartrate ophthalmic solution) 0.025% drops are indicated for relieving redness of the eye due to minor eye irritations.<sup>2</sup> Most redness relievers are  $\alpha$ 1- or  $\alpha$ 1/ $\alpha$ 2-adrenergic receptor agonists;  $\alpha$ 1-adrenergic receptor agonism constricts corneal arterioles, hindering oxygen delivery to the cornea, which causes rebound redness. Brimonidine tartrate, by contrast, is selective for the  $\alpha$ 2-adrenergic receptor, primarily constricting ocular surface venules, which

do not affect ocular surface oxygen delivery and therefore is not associated with high levels of rebound redness.<sup>3</sup>

In 6 clinical studies with over 600 patients, low-dose brimonidine tartrate demonstrated a 1 minute onset of action, which persisted for up to 8 hours.<sup>4</sup> It had a favorable safety profile and, consistent with its mechanism of action, a low incidence of rebound redness (1.2%).<sup>4,5,6</sup> Adverse event rates did not significantly differ from control, and the most common adverse events in brimonidine-treated eyes were reduced visual acuity (4.0%) and conjunctival redness (2.6%).<sup>5</sup>

### Opportunity for ECPs to Step In

Market research indicates that patients report using of redness relievers an average of 3 days per week.<sup>7</sup> Ocular redness is a key concern for many patients, but the OTC eye care market contains an often overwhelming array of products. Understanding and communicating the benefits and challenges of available products is key to helping patients narrow down which products—out of everything on the shelf—might work best for them.


**LUMIFY® provides safe and effective redness relief for my patients dealing with minor eye irritations**

LUMIFY® is a redness reliever drop differentiated in its mechanism of action, rapid effects, and minimal rebound redness. LUMIFY® provides patients with excellent redness relief. In recommending a product as efficacious and reliable as LUMIFY®, ECPs can establish themselves as trusted professionals who can



### Incorporating ocular aesthetics into the patient conversation

- ✓ Ask patients if they are happy with how their eyes look and feel
- ✓ Ask patients if they use OTC eye care products and if they are satisfied with them
- ✓ Consider that the aesthetic aspect of eye care may be just as important to a patient as the clinical aspect
- ✓ Be ready and willing to provide OTC recommendations



address patients' needs—both clinical and aesthetic. This can lead not only to improved patient outcomes and satisfaction but could also enhance trust in their relationship with their ECP.

1. IQVIA Sales Data, Latest 52 weeks ending 6/18/2023
2. LUMIFY® [Drug facts]. Bausch & Lomb Incorporated, Bridgewater, NJ.
3. Corboz MR, Rivelli MA, Varty L, et al. Pharmacological characterization of postjunctional  $\alpha$ -adrenoceptors in human nasal mucosa. *Am J Rhinol.* 2005;19(5):495-502.
4. McLaurin E, Cavet ME, Gomes PJ, Ciolino JB. Brimonidine ophthalmic solution 0.025% for reduction of ocular redness: a randomized clinical trial. *Optom Vis Sci.* 2018;95(3):264-271.
5. Ackerman SL, Torkildsen GL, McLaurin E, Vittitow JL. Low-dose brimonidine for relief of ocular redness: integrated analysis of four clinical trials. *Clin Exp Optom.* 2019;102(2):131-139.
6. Torkildsen GL, Sanfilippo CM, DeCory HH, Gomes PJ. Evaluation of efficacy and safety of brimonidine tartrate ophthalmic solution, 0.025% for treatment of ocular redness. *Curr Eye Res.* 2018;43(1):43-51.
7. Data on file. Bausch & Lomb. Rochester, NY

# CATCHING A RED EYE

With careful examination and history-taking, most unusual causes of red eye can be uncovered.

**CHRISTINE YUE LEONARD**  
SENIOR ASSOCIATE EDITOR

Ophthalmologists are no strangers to the classic red eye presentation, which tends to rear its head in the clinic on a daily or weekly basis. Typical causes include conjunctivitis, subconjunctival hemorrhage, dry eye, blepharitis, topical glaucoma medications and contact lens overwear. The full list of red-eye differentials is vast, however.

Here, experts share some tips for narrowing down the cause, as well as some of the more unusual culprits behind red eye.

## Patient Symptoms

Asking patients about any associated symptoms is a key step toward determining the underlying cause of red eye. “I usually ask patients if they’re having any irritation, pain, discharge, light sensitivity or foreign body sensation,” says Masako Chen, MD, an assistant professor of ophthalmology and director of Comprehensive Eye Services at New York Eye and Ear Infirmary of Mount Sinai. “If I’m suspicious for some of the more

unusual causes of red eye, I might also ask certain patients about recent sun exposure or contact with sick people, topical and systemic medication use, history of past eye or other infections, and history of skin lesions or skin cancer removal.”

“If patients report symptoms such as redness, some irritation, dryness and foreign body sensation that have been occurring on and off for a long time, that makes me think of a dry-eye situation,” says Sezen Karakus, MD, an assistant professor of ophthalmology at the Wilmer Eye Institute, Johns Hopkins University School of Medicine. “But, if they mention pain, light sensitivity, difficulty opening the eyes or decreasing vision, those are red flags that something more serious may be going on.”

## A Thorough Examination

Simple symptoms can sometimes mean serious disease. Dr. Karakus says it’s very important to carry out a thorough comprehensive exam for red-eye patients. “Some of the issues causing surface diseases may affect the corneal nerves as well,” she says, “and in those cases, patients may not have significant

pain or discomfort, but their vision may change.”

Here are some points to keep in mind during the exam:

- **Observe the patient.** “The exam begins the second you walk into the room and see the patient,” says Bennie H. Jeng, MD, chair of the ophthalmology department and director of the Scheie Eye Institute at Penn Medicine in Philadelphia. “In addition to the eyes themselves, look at the eyelids and the face. See what the patient’s reaction is when the lights are on. If they have photophobia, that may point you to something else. When looking at the eyelids, note their position. Is there any malposition that might be causing exposure that then causes red eye?”

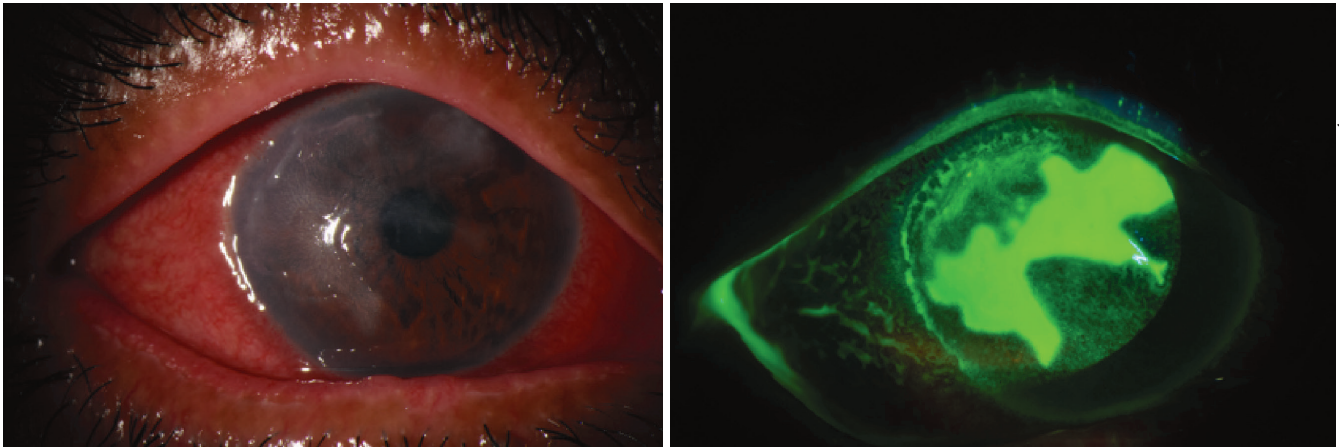
When examining the eyelids and face, Dr. Karakus says she checks for any signs of active skin disease such as rosacea, eczema or other inflammatory skin diseases that could contribute to red eye.

- **Look with the lights on.** “Looking with the lights on is important because sometimes red eyes will appear differently under different lighting,” says Dr. Jeng. “With scleritis, for example,

This article has no commercial sponsorship.

Drs. Jeng, Chen, Karakus and Bunya have no related financial disclosures.





A patient with herpes simplex keratitis presented with a geographic ulcer, patchy corneal opacities and diffuse conjunctival injection. In the second photograph, ulcer area is visualized using fluorescein dye under cobalt blue light.

the quality of the redness and inflammation is different when you look at it without the slit lamp under room lighting.”

• **Be methodical and consistent.**

“During the exam, go carefully from front to back,” says Dr. Chen. “Make sure there’s no scarring, blepharitis or meibomian gland disease. Look at the palpebral conjunctiva to ensure there aren’t any tumors, foreign bodies, follicles, papillae, symblepharon or other abnormalities. Examine the cornea to ensure there are no infiltrates or ulcers, and check for anterior chamber cells to rule out anterior uveitis. Depending how the exam goes, you may choose to dilate the patient for a fundus exam. I tend not to dilate patients with viral conjunctivitis to make sure I don’t infect my equipment.”

• **Always flip the lids.** When checking the conjunctiva, it’s important to pull the lower lid out and flip the upper eyelid to check for abnormalities such as foreign body, follicles, papillae or symblepharon. “Follicles or papillae are signs of a certain type of inflammation with allergic or infectious causes,” Dr. Karakus says. “Also check for scarring, because that could indicate more serious problems.”

“A foreign body in the eye is an unusual cause of chronic conjunctivitis,” says Dr. Jeng. “A contact lens may be stuck in the upper fornix, or sutures may have eroded from underneath the conjunctiva.”

• **Stain the eye for additional clues.** “When checking for corneal and conjunctival abnormalities, we use vital dyes to identify areas with more dryness or inflammation or anything abnormal,” Dr. Karakus says. “With those vital dyes, we can see which parts of the eye are particularly affected by the disease. This could give us a clue as to whether the red eye results from underlying autoimmune disease or is a nerve-related issue, for example. It may also be toxicity from certain eyedrops or environmental exposure. If the lower part of the cornea is dry, then that might indicate a lid margin-related disease such as blepharitis or meibomian gland dysfunction.”

• **Check for abnormal color.** “If the eye isn’t a normal color or the cornea has a gray or white spot, this may indicate a more serious inflammatory cause or infection,” Dr. Karakus continues. “There may be other findings within the cornea such as edema or irregularities. From there, you’d go through the differentials.”

• **Check for abnormal vasculature.** More serious causes of red eye, including keratitis, iritis or scleritis, often present with abnormal vasculature. “Ocular surface squamous neoplasia often presents with abnormal corkscrew vessels,” adds Dr. Chen. “Dilated and large vessels may mean you need to do gonioscopy to look for tumors, masses or iris lesions.”

• **Ask about “redness relief” drops.**

“Patients don’t like the appearance of red eye,” says Vatinee Y. Bunya, MD, MSCE, co-director of the Penn Dry Eye and Ocular Surface Center of Scheie Eye Institute in Philadelphia. “I always tell patients that there’s a danger of rebound redness if vasoconstrictors (e.g., naphazoline) are used chronically and then stopped. The eyes may appear redder than before. For special occasions, such as a wedding or a big meeting, using an anti-redness drop such as Lumify (brimonidine tartrate) is okay, but like vasoconstrictors, it shouldn’t be used long-term. It’s best to treat the root cause of the red eye, rather than mask it.”

Dr. Bunya says that it’s possible these drops could make it more difficult to tell what’s going on since the patient may feel okay and their eyes don’t look visibly red. However, “more serious causes will have signs other than a red eye,” she says. “Lumify won’t help with light sensitivity or a bad infection.”

• **Bring the patient back sooner.**

If the patient history doesn’t fit the exam, don’t be afraid to rethink the diagnosis, especially if the patient isn’t getting better. “Chlamydia, for example, can cause a chronic conjunctivitis that doesn’t respond to treatment and can last several weeks,” Dr. Bunya says. “If I’m not 100-percent sure about the diagnosis, I’ll bring the patient back a bit sooner. Most times, if you see the



MANY  
MANIFESTATIONS  
OF THYROID EYE  
DISEASE (TED)

# ONE ROOT CAUSE<sup>1-3</sup>







## Treat TED at the source<sup>1,4-6</sup>

TEPEZZA is the **first and only FDA-approved** treatment specifically for TED<sup>1,4</sup>

TEPEZZA has been shown to be effective in patients with a **wide range of clinical manifestations**<sup>5-7</sup>

TEPEZZA **alleviates many of the symptoms of TED** by producing anatomic changes to the tissues behind the eye<sup>1,4,7-10</sup>

**TEPEZZA treats the root cause of TED and has been proven to:**



Decrease proptosis<sup>4</sup>



Improve diplopia<sup>4</sup>



Reduce orbital pain, redness, and swelling<sup>7,11</sup>



Improve functional vision and patient appearance<sup>7,11</sup>

... in patients with TED, without concomitant steroids (vs placebo at Week 24) in 2 clinical studies.<sup>7,11,12</sup>



See how TEPEZZA can transform your patients' eyes

IGF-1R, insulin-like growth factor-1 receptor.

**References:** 1. Patel A, Yang H, Douglas RS. A new era in the treatment of thyroid eye disease. *Am J Ophthalmol.* 2019;208:281-288. 2. Chen H, Mester T, Raychaudhuri N, et al. Teprotumumab, an IGF-1R blocking monoclonal antibody inhibits TSH and IGF-1 action in fibrocytes. *J Clin Endocrinol Metab.* 2014;99(9):E1635-E1640. 3. Tsui S, Naik V, Hoa N, et al. Evidence for an association between thyroid-stimulating hormone and insulin-like growth factor 1 receptors: a tale of two antigens implicated in Graves' disease. *J Immunol.* 2008;181(6):4397-4405. 4. TEPEZZA (teprotumumab-trbw) [prescribing information] Horizon. 5. Dimiz SB, Cohen LM, Roelofs KA, Rootman DB. Early experience with the clinical use of teprotumumab in a heterogeneous thyroid eye disease population. *Ophthalm Plast Reconstr Surg.* 2021;37(6):583-591. 6. Ugardar S, Kang J, Kossler AL, et al. Teprotumumab for the treatment of chronic thyroid eye disease. *Eye (Lond).* 2021. Published online ahead of print July 9, 2021. 7. Douglas RS, Kahaly GJ, Patel A, et al. Teprotumumab for the treatment of active thyroid eye disease. *N Engl J Med.* 2020;382(4):341-352. 8. Douglas RS. Teprotumumab, an insulin-like growth factor-1 receptor antagonist antibody, in the treatment of active thyroid eye disease: a focus on proptosis. *Eye (Lond).* 2019;33(2):183-190. 9. Pritchard J, Han R, Horst N, Cruikshank WW, Smith TJ. Immunoglobulin activation of T cell chemoattractant expression in fibroblasts from patients with Graves' disease is mediated through the insulin-like growth factor 1 receptor pathway. *J Immunol.* 2003;170(12):6348-6354. 10. Huang Y, Fang S, Li D, Zhou H, Li B, Fan X. The involvement of T cell pathogenesis in thyroid-associated ophthalmopathy. *Eye (Lond).* 2019;33(2):176-182. 11. Smith TJ, Kahaly GJ, Ezra DG, et al. Teprotumumab for thyroid-associated ophthalmopathy. *N Engl J Med.* 2017;376(18):1748-1761. 12. Smith TJ, Kahaly GJ, Ezra DG, et al. Teprotumumab for thyroid-associated ophthalmopathy. *N Engl J Med.* 2017;376(18)(suppl):1748-1761. [https://www.nejm.org/doi/suppl/10.1056/NEJMoal614949/suppl\\_file/nejmoal614949\\_appendix.pdf](https://www.nejm.org/doi/suppl/10.1056/NEJMoal614949/suppl_file/nejmoal614949_appendix.pdf).



TEPEZZA and the HORIZON logo are trademarks owned by or licensed to Horizon. © 2023 Horizon Therapeutics plc P-TEP-US-00538-2 01/23

## INDICATION

TEPEZZA is indicated for the treatment of Thyroid Eye Disease.

## IMPORTANT SAFETY INFORMATION

### WARNINGS AND PRECAUTIONS

**Infusion Reactions:** TEPEZZA may cause infusion reactions. Infusion reactions have been reported in approximately 4% of patients treated with TEPEZZA. Reported infusion reactions have usually been mild or moderate in severity. Signs and symptoms may include transient increases in blood pressure, feeling hot, tachycardia, dyspnea, headache, and muscular pain. Infusion reactions may occur during an infusion or within 1.5 hours after an infusion. In patients who experience an infusion reaction, consideration should be given to premedicating with an antihistamine, antipyretic, or corticosteroid and/or administering all subsequent infusions at a slower infusion rate.

### Preexisting Inflammatory Bowel Disease:

TEPEZZA may cause an exacerbation of preexisting inflammatory bowel disease (IBD). Monitor patients with IBD for flare of disease. If IBD exacerbation is suspected, consider discontinuation of TEPEZZA.

**Hyperglycemia:** Increased blood glucose or hyperglycemia may occur in patients treated with TEPEZZA. In clinical trials, 10% of patients (two-thirds of whom had preexisting diabetes or impaired glucose tolerance) experienced hyperglycemia. Hyperglycemic events should be controlled with medications for glycemic control, if necessary. Assess patients for elevated blood glucose and symptoms of hyperglycemia prior to infusion and continue to monitor while on treatment with TEPEZZA. Ensure patients with hyperglycemia or preexisting diabetes are under appropriate glycemic control before and while receiving TEPEZZA.

## ADVERSE REACTIONS

The most common adverse reactions (incidence  $\geq 5\%$  and greater than placebo) are muscle spasm, nausea, alopecia, diarrhea, fatigue, hyperglycemia, hearing impairment, dysgeusia, headache, dry skin, weight decreased, nail disorders, and menstrual disorders.

Information or visit [TEPEZZAhcp.com](https://www.tepezza.com) for more information.



For injection, for intravenous use

**Brief Summary - Please see the TEPEZZA package insert for full prescribing information.**

### INDICATIONS AND USAGE

TEPEZZA is indicated for the treatment of Thyroid Eye Disease regardless of Thyroid Eye Disease activity or duration.

### WARNINGS AND PRECAUTIONS

#### Infusion Reactions

TEPEZZA may cause infusion reactions. Infusion reactions have been reported in approximately 4% of patients treated with TEPEZZA. Signs and symptoms of infusion-related reactions include transient increases in blood pressure, feeling hot, tachycardia, dyspnea, headache and muscular pain. Infusion reactions may occur during any of the infusions or within 1.5 hours after an infusion. Reported infusion reactions are usually mild or moderate in severity and can usually be successfully managed with corticosteroids and antihistamines. In patients who experience an infusion reaction, consideration should be given to pre-medicating with an antihistamine, antipyretic, corticosteroid and/or administering all subsequent infusions at a lower infusion rate.

#### Exacerbation of Preexisting Inflammatory Bowel Disease:

TEPEZZA may cause an exacerbation of preexisting inflammatory bowel disease (IBD). Monitor patients with IBD for flare of disease. If IBD exacerbation is suspected, consider discontinuation of TEPEZZA.

#### Hyperglycemia:

Hyperglycemia or increased blood glucose may occur in patients treated with TEPEZZA. In clinical trials, 10% of patients (two-thirds of whom had preexisting diabetes or impaired glucose tolerance) experienced hyperglycemia. Hyperglycemic events should be controlled with medications for glycemic control, if necessary.

Assess patients for elevated blood glucose and symptoms of hyperglycemia prior to infusion and continue to monitor while on treatment with TEPEZZA. Ensure patients with hyperglycemia or preexisting diabetes are under appropriate glycemic control before and while receiving TEPEZZA.

#### Hearing Impairment Including Hearing Loss:

TEPEZZA may cause severe hearing impairment including hearing loss, which in some cases may be permanent. Assess patients' hearing before, during, and after treatment with TEPEZZA and consider the benefit-risk of treatment with patients.

### ADVERSE REACTIONS

The following clinically significant adverse reactions are described elsewhere in the labeling:

- Infusion Reactions [see *Warnings and Precautions*]
- Exacerbation of Preexisting Inflammatory Bowel Disease [see *Warnings and Precautions*]
- Hyperglycemia [see *Warnings and Precautions*]
- Hearing Impairment Including Hearing Loss [see *Warnings and Precautions*]

#### Clinical Trials Experience

Because clinical trials are conducted under widely varying conditions, adverse reaction rates observed in the clinical trials of a drug cannot be directly compared to rates in the clinical trials of another drug and may not reflect the rates observed in practice.

The safety of TEPEZZA was evaluated in two randomized, double-masked, placebo-controlled clinical studies (Study 1 [NCT:01868997] and Study 2 [NCT:03298867]) consisting of 170 patients with Thyroid Eye Disease (84 received TEPEZZA and 86 received placebo). Patients were treated with TEPEZZA (10 mg/kg for first infusion and 20 mg/kg for the remaining 7 infusions) or placebo given as an intravenous infusion every 3 weeks for a total of 8 infusions. The majority of patients completed 8 infusions (89% of TEPEZZA patients and 93% of placebo patients).

The most common adverse reactions (≥5%) that occurred at greater incidence in the TEPEZZA group than in the control group during the treatment period of Studies 1 and 2 are summarized in Table 1. In addition, menstrual disorders (amenorrhea, metrorrhagia, dysmenorrhea) were reported in approximately 23% (5 of 22 patients) of menstruating women treated with TEPEZZA compared to 4% (1 of 25 patients) treated with placebo in the clinical trials.

**Table 1. Adverse Reactions Occurring in 5% or More of Patients Treated with TEPEZZA and Greater Incidence than Placebo**

Adverse Reactions	TEPEZZA N=84, N (%)	Placebo N=84, N (%)
Muscle spasms	21 (25%)	6 (7%)
Nausea	14 (17%)	8 (9%)
Alopecia	11 (13%)	7 (8%)
Diarrhea	10 (12%)	7 (8%)
Fatigue <sup>a</sup>	10 (12%)	6 (7%)
Hyperglycemia <sup>b</sup>	8 (10%)	1 (1%)
Hearing impairment <sup>c</sup>	8 (10%)	0
Dysgeusia	7 (8%)	0
Headache	7 (8%)	6 (7%)
Dry skin	7 (8%)	0
Weight decreased	5 (6%)	0
Nail disorder <sup>d</sup>	4 (5%)	0

a - Fatigue includes asthenia

b - Hyperglycemia includes blood glucose increase

c - Hearing impairment including hearing loss (deafness, including sensorineural deafness, eustachian tube dysfunction, hyperacusis, hypoacusis, autophony and tinnitus)

d - Nail disorder (includes nail discoloration, nail disorder and onychoclasia)

#### Immunogenicity

As with all therapeutic proteins, there is potential for immunogenicity. The detection of antibody formation is highly dependent on the sensitivity and specificity of the assay.

In a placebo-controlled study with TEPEZZA, 1 of 42 patients treated with placebo had detectable levels of antidrug antibodies in serum. In the same study, none of the 41 patients treated with TEPEZZA had detectable levels of antidrug antibodies in serum.

#### Postmarketing Experience

The following adverse reactions have been identified during postapproval use of TEPEZZA. Because these reactions are reported voluntarily from a population of uncertain size, it is not always possible to reliably estimate their frequency or establish a causal relationship to drug exposure.

*Metabolism and Nutrition Disorders:* diabetic ketoacidosis, hyperosmolar hyperglycemic state (HHS).

*Otologic:* severe hearing impairment including hearing loss, which in some cases may be permanent.

### USE IN SPECIFIC POPULATIONS

#### Pregnancy

##### Risk Summary

Based on findings in animals and its mechanism of action inhibiting insulin-like growth factor 1 receptor (IGF-1R), TEPEZZA may cause fetal harm when administered to a pregnant woman. Adequate and well-controlled studies with TEPEZZA have not been conducted in pregnant women. There are insufficient data with TEPEZZA use in pregnant women to inform any drug associated risks for adverse developmental outcomes. In utero teprotumumab exposure in cynomolgus monkeys dosed once weekly with teprotumumab throughout pregnancy resulted in external and skeletal abnormalities. Teprotumumab exposure may lead to an increase in fetal loss [see *Data*]. Therefore, TEPEZZA should not be used in pregnancy, and appropriate forms of contraception should be implemented prior to initiation, during treatment and for 6 months following the last dose of TEPEZZA. If the patient becomes pregnant during treatment, TEPEZZA should be discontinued and the patient advised of the potential risk to the fetus.

The background rate of major birth defects and miscarriage is unknown for the indicated population. In the U.S. general population, the estimated background risks of major birth defects and miscarriage in clinically recognized pregnancies are 2-4% and 15-20%, respectively.

#### Data

##### Animal Data

In an abridged pilot embryofetal development study, seven pregnant cynomolgus monkeys were dosed intravenously at one dose level of teprotumumab, 75 mg/kg (2.8-fold the maximum recommended human dose [MRHD] based on AUC) once weekly from gestation day 20 through the end of gestation. The incidence of abortion was higher for the teprotumumab treated group compared to the control group. Teprotumumab caused decreased fetal growth during pregnancy, decreased fetal size and weight at caesarean section, decreased placental weight and size, and decreased amniotic fluid volume. Multiple external and skeletal abnormalities were observed in each exposed fetus, including: misshapen cranium, closely set

eyes, micrognathia, pointing and narrowing of the nose, and ossification abnormalities of skull bones, sternbrae, carpals, tarsals and teeth. The test dose, 75 mg/kg of teprotumumab, was the maternal no observed adverse effect level (NOAEL).

Based on mechanism of action inhibiting IGF-1R, postnatal exposure to teprotumumab may cause harm.

#### Lactation

##### Risk Summary

There is no information regarding the presence of TEPEZZA in human milk, the effects on the breast-fed infant or the effects on milk production.

### Females and Males of Reproductive Potential

#### Contraception

##### Females

Based on its mechanism of action inhibiting IGF-1R, TEPEZZA may cause fetal harm when administered to a pregnant woman [see *Use in Specific Populations*]. Advise females of reproductive potential to use effective contraception prior to initiation, during treatment with TEPEZZA and for 6 months after the last dose of TEPEZZA.

#### Pediatric Use

Safety and effectiveness have not been established in pediatric patients.

#### Geriatric Use

Of the 171 patients in the two randomized trials, 15% were 65 years of age or older; the number of patients 65 years or older was similar between treatment groups. No overall differences in efficacy or safety were observed between patients 65 years or older and younger patients (less than 65 years of age).

### OVERDOSAGE

No information is available for patients who have received an overdose.

### PATIENT COUNSELING INFORMATION

#### Embryo-Fetal Toxicity

- Advise females of reproductive potential that TEPEZZA can cause harm to a fetus and to inform their healthcare provider of a known or suspected pregnancy.
- Educate and counsel females of reproductive potential about the need to use effective contraception prior to initiation, during treatment with TEPEZZA and for 6 months after the last dose of TEPEZZA.

#### Infusion-related reactions

- Advise patients that TEPEZZA may cause infusion reactions that can occur at any time. Instruct patients to recognize the signs and symptoms of infusion reaction and to contact their healthcare provider immediately for signs or symptoms of potential infusion-related reactions.

#### Exacerbation of Preexisting Inflammatory Bowel Disease

- Advise patients on the risk of inflammatory bowel disease (IBD) and to seek medical advice immediately if they experience diarrhea, with or without blood or rectal bleeding, associated with abdominal pain or cramping/colic, urgency, tenesmus or incontinence.

#### Hyperglycemia

- Advise patients on the risk of hyperglycemia and, if diabetic, discuss with the healthcare provider to adjust glycemic control medications as appropriate. Encourage compliance with glycemic control.

#### Hearing Impairment Including Hearing Loss

- Advise patients that TEPEZZA may cause severe hearing impairment including hearing loss, which in some cases may be permanent. Instruct patients to contact their healthcare provider if they experience any signs or symptoms of hearing impairment or any changes in hearing.

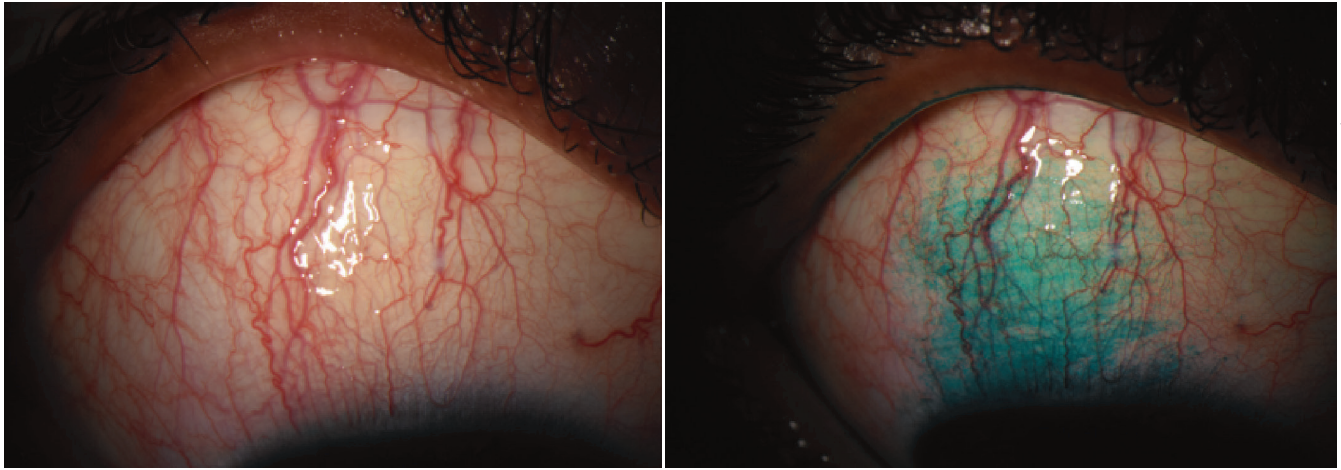
#### Manufactured by:

Horizon Therapeutics Ireland DAC  
Dublin, Ireland  
U.S. License No. 2022

#### Distributed by:

Horizon Therapeutics USA, Inc.  
Deerfield, IL 60015  
TEPEZZA and the HORIZON logo are trademarks owned by or licensed to Horizon.

© 2023 Horizon Therapeutics plc L-TEP-US-00036 07/23



Sezen Karakus, MD

**A patient with superior limbic keratoconjunctivitis, showing injection of the superior bulbar conjunctiva with engorgement of vertically-oriented blood vessels. In the second photograph, the affected area is visualized with lissamine green staining. SLK is an inflammation of the superior bulbar conjunctiva along with the adjacent limbus and corneal epithelium.**

patient back again, the diagnosis will become obvious. I always tell patients to call immediately if they experience any warning signs such as decreased vision or worsening pain—basically if they aren't responding to the treatment plan."

### Chemical Burn

Among the less run-of-the-mill reasons behind red eye are chemical burns. Chemical burns often result from household cleaning agents and medications. Fortunately, Dr. Karakus says, "It's often obvious when a chemical was involved because the patient is usually able to tell you about an incident, the type of chemical and which areas were exposed."

"Sometimes only part of the eye is affected, and other times the whole conjunctiva appears severely inflamed," she continues. "Abrasions or ulcers of the cornea or conjunctiva may also be present. Chemical burns often cause inflammation in the limbus."

Mild burns are usually treated with topical steroids and lubricants. If epithelial defects are present, prophylactic antibiotics may be used.

### Photokeratitis

"When you see diffuse corneal staining, that's usually an indication of some form of toxicity from something in the air, preservatives in eyedrops or

even ultraviolet light," says Dr. Karakus. "Many patients aren't aware of the damage from UV-light exposure until they start having symptoms."

Careful questioning about activities or recent trips can help pinpoint the cause. Dr. Karakus says UV-sterilization devices that aren't properly covered while in use are often the culprits behind this form of keratitis, but highly reflective surfaces can also cause UV-induced keratitis. "I once had a patient who went skiing without goggles on, and the sunlight reflecting off the snow caused a diffuse keratitis," she says.

A case of nightclub photokeratitis was described in which a 30-year-old nightclub technician reported working with intense ultraviolet lights for six hours before experiencing symptoms.<sup>1</sup> He had severe conjunctival injection and corneal punctate epithelial erosions, and was treated with oral analgesics, timolol, lubricant eyedrops and antibiotic prophylaxis. At one week his corneas were clear, BCVA was 20/20 (from 20/30 OD and 20/40 OS) and IOP was 12 mmHg OU.

### Anterior Uveitis

"Anterior uveitis is differentiated from more common causes of red eye such as conjunctivitis by the presence of inflammation and accumulated white blood cells in the anterior chamber,"

Dr. Karakus says. "Patients often have pronounced limbal flush."

Other signs may include keratic precipitates, hypopyon and iris nodules. Patients usually report symptoms of rapid-onset pain, redness and photophobia. A thorough medical history can provide further clues, as anterior uveitis often arises from illness, a virus or an associated underlying disease. Ankylosing spondylitis and psoriatic arthritis are risk factors. Acute anterior uveitis resolves with anti-inflammatory therapy.

Dr. Chen notes that "there was a case that was initially diagnosed as bilateral conjunctivitis, but on the anterior segment examination, there were a lot of cells, and no follicles or papillae on the eyelids. The patient was diagnosed with bilateral anterior uveitis and further bloodwork confirmed tubulointerstitial nephritis and uveitis (TINU)."

### Acute Angle Closure

One of the more unusual and serious causes of a red eye is acute angle closure glaucoma, where outflow pathways are obstructed, often by ocular trauma. "Patients have acute onset of redness and sometimes light sensitivity," says Dr. Bunya. "They may have blurred vision because the cornea is edematous from the acute rise in pressure. At the slit lamp, the anterior

chamber will appear narrower. Pressures will be high.

“Any time a patient has any sort of acute vision loss or severe pain, that puts them in a different category of urgency than someone who comes in with no changes in vision and little pain,” she explains.

Intraocular pressure-lowering treatment should be initiated as a first-line treatment for acute angle closure.

## Episcleritis & Scleritis

Episcleritis and scleritis may be idiopathic or arise from associated systemic conditions, but scleritis is more frequently associated with underlying systemic disease, particularly rheumatologic conditions.

“Scleritis affects the deeper vessels and has more of a radial pattern than the articulated network that you’d normally see with either episcleritis or conjunctivitis,” says Dr. Jeng. “Both episcleritis and scleritis can be localized, in contrast with conjunctivitis which generally affects the entire conjunctiva.”

Patients with episcleritis are usually asymptomatic. “Episcleritis isn’t as disruptive a disease, so supportive therapy such as lubrication is often all that’s needed,” Dr. Jeng says. “If the patient is bothered by it, a low-dose mild steroid can sometimes work.

“Scleritis, on the other hand, requires treatment,” he continues. “I don’t generally find that topical drops are all that effective. Scleritis patients usually need to be treated systemically. First, identify and treat the underlying disease. That will usually treat the scleritis. If the patient doesn’t have an underlying disease associated with the scleritis, I’ll usually go with a nonsteroidal anti-inflammatory to treat the inflammation.”

## Herpes Simplex

Primary herpes simplex virus ocular disease is often mistaken for conjunctivitis. It may manifest with unilateral follicular conjunctivitis. Common symptoms include eye redness, pain, light sensitivity, watery eyes and eyelid

inflammation. Reactivation of the disease may be triggered by stress, sun exposure, fever or certain medications. It’s important to identify and treat herpes infections promptly with antivirals.

“Be careful about prescribing steroids to patients without seeing them,” Dr. Bunya points out. “I recently had a patient whom I followed for years for dry eye and other chronic eye problems. She called, asking if I could call in some steroid drops for what she thought was a typical flare-up, but I said, ‘It’s better if you come in so I can take a quick look.’ It turned out that she had a herpes simplex infection of the cornea. If I had prescribed steroids without seeing her, her herpes infection would have worsened.”

## OSSN

Experts say that though it’s rare, ocular surface squamous neoplasia should remain on clinicians’ radar when evaluating red-eye patients, as OSSN may masquerade as chronic conjunctivitis.

“Ocular cancers should always be in our differential, especially if the patient isn’t responding to treatment,” Dr. Karakus says. “If there’s a lesion, you’ll usually see it either within the conjunctiva or growing over the cornea. It’s very important to check the undersides of the eyelids—flip the upper lid and look inside the lower lid. You’ll see signs such as a lesion or bumps and lumps. Sometimes there may be follicular conjunctivitis, which would make you think of a second infectious cause or some other chronic inflammation. But if the patient isn’t improving with standard treatment, always consider OSSN.”

Treatment depends on the size of the lesion and what you’re suspicious for. “For an ocular surface tumor such as a small squamous cell, we generally do an excisional biopsy with cryotherapy and take the whole thing, and then check for margins on pathology,” says Dr. Jeng. “If it’s large, an incisional biopsy can be done for diagnosis, and then it may be treated using

topical chemotherapy drops. Optical coherence tomography is sometimes used to diagnose the type of tumor and treat it without getting a biopsy.”

## Conjunctivochalasis

With decreases in collagen, older patients may experience a red-orange eye from conjunctivochalasis. “Conjunctivochalasis isn’t usually recognized early on, and patients are often given only artificial tears,” Dr. Karakus says. “The condition may also result from chronic inflammation of the eyes due to conditions such as prior thyroid eye disease, ocular rosacea, dry eye or chronic eye allergies.”

It’s important to differentiate this condition from conjunctivitis and lid malposition disorders such as floppy eyelid syndrome. “Every time the patient blinks, the loose conjunctival folds that develop cause irritation, redness and more inflammation,” she says. “Patients experience irritation, pain, discomfort and fluctuating vision problems.”

Lubricants can relieve mild symptoms, but topical corticosteroids are sometimes needed to help reduce inflammation. In some cases, approaches to tighten redundant conjunctiva are employed, such as cauterization, conjunctival excision or scleral fixation.

“It’s worthwhile to mention that superior limbic keratoconjunctivitis will present with more pronounced redness under the upper lid in the bulbar conjunctiva,” Dr. Karakus adds. “Sometimes the conjunctiva will bunch in that area, creating friction. SLK is also associated with thyroid diseases.”

“As long as you have the differentials in your head and do a thorough anterior segment exam, you’ll get to the right diagnosis,” says Dr. Chen. “Take a really thorough history. If the history doesn’t fit with the exam, investigate further. Be methodical about the exam and go from the front to back in a consistent manner, and don’t skip any steps. Always flip the lid.” ◀

1. Singh RB, Thakur S. Nightclub photokeratitis. *Ophthalmology* 2020;127:2:239.



NEW!

Indicated for the treatment of the signs and symptoms of DED

Miebo™  
(perfluorohexyloctane  
ophthalmic solution)

MIEBO is the first and only Rx eye drop for DED that directly targets evaporation<sup>1</sup>



### Inhibits tear evaporation<sup>1-3\*</sup>

- Forms a monolayer at the air-liquid interface of the tear film which can be expected to reduce evaporation



### Rapid and sustained relief<sup>†</sup>

- Improvement in tCFS and eye dryness as early as Day 15 continued through Day 57 in 2 pivotal studies



### Excellent tolerability<sup>1,4-6‡</sup>

- Low rate of burning or stinging on instillation
- Blurred vision and conjunctival redness were reported in 1%-3% of individuals

\*The exact mechanism of action for MIEBO in DED is not known.<sup>1</sup>

<sup>1</sup>**Study design:** Two 57-day, multicenter, double-masked, saline-controlled studies (GOBI and MOJAVE) were conducted in adults ≥18 years old with a self-reported history of DED in both eyes. Across GOBI and MOJAVE, 614 patients received MIEBO and 603 patients received control with 591 and 575, respectively, assessed on Day 57. **Primary endpoints were change from baseline in tCFS and change from baseline in eye dryness score at Day 57.** Day 15 was the earliest time point at which signs and symptoms were evaluated in the trials. Day 57 was the last.<sup>1,5,6</sup>

<sup>†</sup>In 2 pivotal studies of >1200 patients (614 patients received MIEBO), there were no incidences of serious ocular AEs with MIEBO. Most AEs were considered mild. The discontinuation rate for MIEBO was comparable to control (pooled: 0.2% vs 0.5%; GOBI: 0.3% vs 1.0%; MOJAVE: 0% vs 0%). 0.5% (pooled) of patients experienced instillation site pain AEs, such as burning or stinging (GOBI: 1.0%; MOJAVE: 0%). Blurred vision (pooled: 2.1%; GOBI: 3.0%; MOJAVE: 1.3%) and conjunctival redness (pooled: 0.8%; GOBI: 0%; MOJAVE: 1.3%) were reported in 1%-3% of individuals.<sup>1,4-6</sup>

AE, adverse event; DED, dry eye disease; tCFS, total corneal fluorescein staining.

#### INDICATION

MIEBO™ (perfluorohexyloctane ophthalmic solution) is a semifluorinated alkane indicated for the treatment of the signs and symptoms of dry eye disease.

#### IMPORTANT SAFETY INFORMATION

- MIEBO should not be administered while wearing contact lenses. Contact lenses should be removed before use and for at least 30 minutes after administration of MIEBO
- Instruct patients to instill one drop of MIEBO into each eye four times daily
- The safety and efficacy in pediatric patients below the age of 18 have not been established
- The most common ocular adverse reaction was blurred vision (1% to 3% of patients reported blurred vision and conjunctival redness)

You are encouraged to report negative side effects of prescription drugs to the FDA. Visit [www.fda.gov/medwatch](http://www.fda.gov/medwatch) or call 1-800-FDA-1088.

Please see accompanying Brief Summary of full Prescribing Information for MIEBO.

**References:** **1.** MIEBO. Prescribing Information. Bausch & Lomb, Inc; 2023. **2.** Sheppard JD, Nichols KK. Dry eye disease associated with meibomian gland dysfunction: focus on tear film characteristics and the therapeutic landscape. *Ophthalmol Ther.* 2023;12(3):1397-1418. doi:10.1007/s40123-023-00669-1 **3.** Vittitow J, Kissling R, DeCory H, Borchman D. In vitro inhibition of evaporation with perfluorohexyloctane, an eye drop for dry eye disease. *Curr Ther Res Clin Exp.* 2023;98:100704. doi:10.1016/j.curtheres.2023.100704 **4.** Data on file. Bausch & Lomb, Inc; 2023. **5.** Tauber J, Berdy GJ, Wirta DL, Krösser S, Vittitow JL; GOBI Study Group. NOV03 for dry eye disease associated with meibomian gland dysfunction: results of the randomized phase 3 GOBI study. *Ophthalmology.* 2023;130(5):516-524. doi:10.1016/j.ophtha.2022.12.021 **6.** Sheppard JD, Kurata F, Epitropoulos AT, Krösser S, Vittitow JL; MOJAVE Study Group. NOV03 for signs and symptoms of dry eye disease associated with meibomian gland dysfunction: the randomized phase 3 MOJAVE study. *Am J Ophthalmol.* 2023;252:265-274. doi:10.1016/j.ajo.2023.03.008

BAUSCH+LOMB

©2023 Bausch + Lomb  
MBO.0098.USA.23



Learn more at  
[MIEBO-ECP.COM](http://MIEBO-ECP.COM)

# IOL FIXATION: TRIED-AND-TRUE TECHNIQUES

When faced with lack of capsular support, cataract surgeons have a variety of options to secure an IOL, each with its own strengths and flaws, say experts.

LIZ HUNTER  
SENIOR EDITOR

**A**lthough cataract surgery is the most common surgery being performed currently, the occasional hiccup does occur. For example, a lack of capsular support presents a challenge requiring the surgeon to determine how to fixate an intraocular lens. Common reasons for loss of support include trauma, endophthalmitis or uveitis, Marfan's syndrome and pseudoexfoliation, to name a few.<sup>1</sup>

For decades, surgeons didn't have many options for situations where capsular support was lacking. Today, new techniques have come to the forefront and gained widespread popularity. We asked experts to discuss their preferred methods and they shared tips and pitfalls every surgeon should consider.

## Capsular Tension Rings and Scleral-Sutured IOLs

Anterior chamber IOLs, which date back to the 1950s, aren't favored by many in modern ophthalmology due to their long-term risks of bullous

keratopathy and glaucoma.<sup>2,3</sup> Historically, one of the other popular techniques was to suture a lens to the iris with a Prolene suture. "The problem with suturing the lens to the iris is that it rubs right on the back of the iris and that chafing can also cause iritis, macular edema and pigment dispersion, and therefore it can cause clogging of the trabecular meshwork and glaucoma," says Naveen Rao, MD, who is a cornea, cataract and anterior segment surgeon practicing in Boston. "Iris suturing may initially work for many patients, but there can be some late complications of that as well, which is why many surgeons currently opt for scleral fixation instead of iris fixation."

Scleral-sutured IOLs have long been the chosen technique of Gregory S. H. Ogawa, MD, who practices in New Mexico. Proponents of scleral-sutured lenses note that studies have shown scleral-sutured IOLs to have a better safety profile than anterior chamber IOLs or iris-fixed IOLs.<sup>3</sup> Scleral-sutured IOLs can reduce the risks of complications because the lens is positioned farther away from anterior segment structures.

One prevailing concern with scleral-sutured IOLs has been the risk of suture breakage. A retrospective case study reported 30 of 61 eyes needed two or more procedures due to a complication during or after the surgery, 17 of which were due to breakage of polypropylene sutures.<sup>4</sup> Some of this concern has been mitigated with the introduction and use of Gore-Tex.

For his part, Dr. Ogawa partially attributes his preference of scleral-sutured IOLs to geography. "In New Mexico, some patients drive up to five hours from remote locations for surgery," he says. "I take a one-and-done philosophy. If I try new techniques and they don't work as well, my patients can't easily come back to my office to remedy the issue. For me, scleral suturing is a bulletproof approach."

Dr. Ogawa always uses a one-piece PMMA CZ70BD IOL (Alcon). Once he notices bad zonules, Dr. Ogawa uses capsule support hooks before carefully removing the cataract. He then makes a pair of scleral incisions behind the iris 2 mm apart and a 7-mm wide scleral groove. "I use a

This article has no commercial sponsorship.

Drs. Agarwal, Masket, Ogawa and Rao have no relevant disclosures.



2L Cionni ring, which has two suturing eyelets, and put a 1.5-cm piece of Gore-Tex through the suturing eyelet that I want to use. I usually put a 5-cm piece of 10-0 nylon through the lead eyelet—not the suturing eyelet because I want to help minimize stress on the capsular bag,” says Dr. Ogawa. “I then reach through the scleral incisions with 25-ga. curved forceps to externalize those pieces of Gore-Tex CV-8 (which is the smallest currently made) and then put a two-wrap throw.”

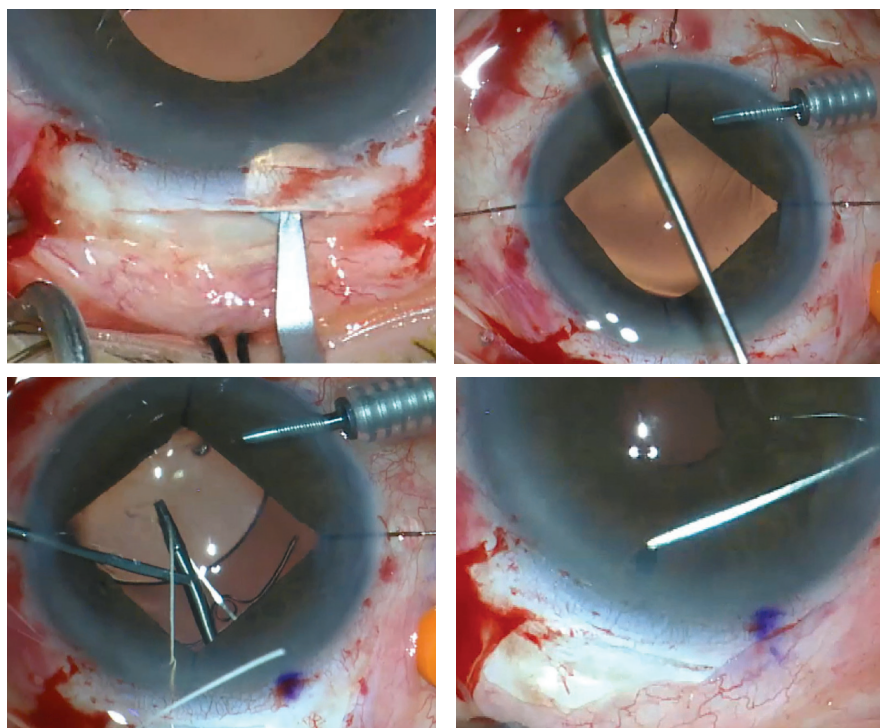
If the zonules are bad due to pseudoexfoliation, Dr. Ogawa will suture both eyelets.

“Essentially, even if the zonules are absolutely terrible, this will support the bag,” he continues. “I place the lens implant in the bag before I remove the OVD and use a self-retaining infusion cannula at the limbus to keep things formed if need be. Then I’ll adjust the tension on the two sutures to make sure I can center things well, and then I put four single-wrap throws on both of those Gore-Tex sections. I cut the tails off the Gore-Tex and use straight tying forceps to bury the knot inside the eye. It needs to be totally inside the eye, otherwise it can erode through the conjunctiva. For this I’ll take down conjunctiva in those places and then use 10-0 vicryl to close the conjunctiva.” (Figure 1)

If a situation is particularly extreme and proves too difficult to insert a 2L ring, Dr. Ogawa will remove the capsular bag and perform an anterior vitrectomy and implant a Gore-Tex sutured IOL.

For nearly 30 years Dr. Ogawa has used this technique and the reliable, long-term results have given him no reason to adopt one of the more recently developed techniques. He estimates that he’s scleral-fixated over 2,000 IOLs, about half with Gore-Tex and the other half with polypropylene.

Although most surgeons would currently opt for smaller incisions and perhaps suture Ahmed segments with a regular CTR, Dr. Ogawa sees an advantage of a scleral tunnel with



Gregory Ogawa, MD

**Figure 1. Scleral-suture Fixation Steps: (Top left) A scleral groove is created with a tunneling blade. (Top right) One suture arm comes over through the lead haptic's eyelet, the other between the eyelet and optic. (Bottom left) IOL placement occurs simultaneously while the straight tying forceps hold the externalized sutures. Before closing the case, intraoperative Purkinje images confirm lens centration (bottom right).**

a self-sealing incision when using a 7-mm optic. “Creating that tunnel incision is something that came from the fact that I started doing eye surgery when incisions were bigger, and that might be a challenge for someone who just finished residency within the last five years and never performed a single scleral tunnel incision,” he says. “When I’m hands-on teaching this technique, we use cadaver eyes and make 15 scleral tunnels in the eye all over just to practice.”

He adds, “If speed is the most important thing, then this isn’t the technique for you. For me, the most important thing is having a good result that stands the test of time.”

Dr. Ogawa evaluated the results of 202 scleral-sutured 9-0 polypropylene posterior-chamber IOL surgeries several years ago (before the use of Gore-Tex) and the data revealed no cases of IOL tilt, suture erosion or unusual IOP elevation. Patients showed overall improvement in visual acuity,

sustained IOL fixation and refractive stability and minor complications.

There are some potential risks to be cognizant of if choosing to scleral fixate, notes Dr. Rao. “The reason that a lot of surgeons don’t favor scleral-suturing is, historically, those scleral-sutured lenses were made of non-foldable PMMA plastic, which requires a big 7-mm incision. That large incision can be more of a risk, especially in older patients, including the risk of suprachoroidal hemorrhage and the requirement to use many sutures to close the incision,” he says. “There are also a variety of other strategies that can be adopted but, generally speaking, most of us don’t want to use a large incision. There are some smaller foldable lenses that can be used for scleral fixation. One of them that’s been popular with our retina colleagues is the Akreos lens, which is a foldable hydrophilic acrylic. However, hydrophilic material tends to opacify over time, especially if there





**izervay**<sup>TM</sup>  
(avacincaptad pegol  
intravitreal solution) 2 mg

#### **INDICATION**

IZERVAY<sup>TM</sup> (avacincaptad pegol intravitreal solution) is indicated for the treatment of geographic atrophy (GA) secondary to age-related macular degeneration (AMD)

#### **IMPORTANT SAFETY INFORMATION**

##### **CONTRAINDICATIONS**

- IZERVAY is contraindicated in patients with ocular or periocular infections and in patients with active intraocular inflammation.

##### **WARNINGS AND PRECAUTIONS**

- Endophthalmitis and Retinal Detachments
  - Intravitreal injections, including those with IZERVAY, may be associated with endophthalmitis and retinal detachments. Proper aseptic injection technique must always be used when administering IZERVAY in order to minimize the risk of endophthalmitis. Patients should be instructed to report any symptoms suggestive of endophthalmitis or retinal detachment without delay and should be managed appropriately.

# NOW APPROVED

for the treatment of geographic atrophy (GA) secondary to age-related macular degeneration (AMD).



To learn more and stay up to date,  
visit [IZERVAYecp.com](https://www.IZERVAYecp.com)

- Neovascular AMD
  - In clinical trials, use of IZERVAY was associated with increased rates of neovascular (wet) AMD or choroidal neovascularization (7% when administered monthly and 4% in the sham group) by Month 12. Patients receiving IZERVAY should be monitored for signs of neovascular AMD.
- Increase in Intraocular Pressure
  - Transient increases in intraocular pressure (IOP) may occur after any intravitreal injection, including with IZERVAY. Perfusion of the optic nerve head should be monitored following the injection and managed appropriately.

## ADVERSE REACTIONS

- Most common adverse reactions (incidence  $\geq 5\%$ ) reported in patients receiving IZERVAY were conjunctival hemorrhage, increased IOP, blurred vision, and neovascular age-related macular degeneration.

**Please see Brief Summary of Prescribing Information for IZERVAY on the following page.**



## IZERVAY™ (avacincaptad pegol intravitreal solution)

Rx only

**Brief Summary:** This information is not comprehensive. Visit IZERVAYecp.com to obtain the FDA-approved product labeling or call 609-474-6755.

### 1 INDICATIONS AND USAGE

IZERVAY is indicated for the treatment of geographic atrophy (GA) secondary to age-related macular degeneration (AMD).

### 2 DOSAGE AND ADMINISTRATION

#### 2.1 General Dosing Information

IZERVAY must be administered by a qualified physician.

#### 2.2 Recommended Dosage

The recommended dose for IZERVAY is 2 mg (0.1 mL of 20 mg/mL solution) administered by intravitreal injection to each affected eye once monthly (approximately every 28 ± 7 days) for up to 12 months.

#### 2.4 Injection Procedure

Only 0.1 mL (2 mg) should be administered to deliver a single dose. Any excess volume should be disposed.

Prior to the intravitreal injection, patients should be monitored for elevated intraocular pressure (IOP) using tonometry. If necessary, ocular hypotensive medication can be given to lower the IOP.

The intravitreal injection procedure must be carried out under controlled aseptic conditions, which includes the use of surgical hand disinfection, sterile gloves, a sterile drape, and a sterile eyelid speculum (or equivalent). Adequate anesthesia and a broad-spectrum topical microbicide should be given prior to the injection.

Inject slowly until the rubber stopper reaches the end of the syringe to deliver the volume of 0.1 mL. Confirm delivery of the full dose by checking that the rubber stopper has reached the end of the syringe barrel.

Immediately following the intravitreal injection, patients should be monitored for elevation in intraocular pressure (IOP). Appropriate monitoring may consist of a check for perfusion of the optic nerve head or tonometry.

Following intravitreal injection, patients should be instructed to report any symptoms suggestive of endophthalmitis (e.g., eye pain, redness of the eye, photophobia, blurring of vision) without delay.

Each vial and syringe should only be used for the treatment of a single eye. If the contralateral eye requires treatment, a new vial and syringe should be used and the sterile field, syringe, gloves, drapes, eyelid speculum, filter needle, and injection needle should be changed before IZERVAY is administered to the other eye. Repeat the same procedure steps as above.

Any unused medicinal product or waste material should be disposed of in accordance with local regulations.

### 3 DOSAGE FORMS AND STRENGTHS

Intravitreal solution: 20 mg/mL clear to slightly opalescent, colorless to slightly yellow solution in a single-dose vial.

### 4 CONTRAINDICATIONS

#### 4.1 Ocular or Periocular Infections

IZERVAY is contraindicated in patients with ocular or periocular infections.

#### 4.2 Active Intraocular Inflammation

IZERVAY is contraindicated in patients with active intraocular inflammation.

### 5 WARNINGS AND PRECAUTIONS

#### 5.1 Endophthalmitis and Retinal Detachments

Intravitreal injections may be associated with endophthalmitis and retinal detachments. Proper aseptic injection techniques must always be used when administering IZERVAY in order to minimize the risk of endophthalmitis. Patients should be instructed to report any symptoms suggestive of endophthalmitis or retinal detachment without delay, to permit prompt and appropriate management.

#### 5.2 Neovascular AMD

In clinical trials, use of IZERVAY was associated with increased rates of neovascular (wet) AMD or choroidal neovascularization (7% when administered monthly and 4% in the sham group) by Month 12. Patients receiving IZERVAY should be monitored for signs of neovascular AMD.

#### 5.3 Increase in Intraocular Pressure

Transient increases in intraocular pressure (IOP) have been observed after an intravitreal injection, including with IZERVAY. Perfusion of the optic nerve head should be monitored following the injection and managed as needed.

### 6 ADVERSE REACTIONS

The following potentially serious adverse reactions are described elsewhere in the labeling:

- Ocular and periocular infections
- Active intraocular inflammation
- Endophthalmitis and retinal detachments
- Neovascular AMD
- Increase in intraocular pressure

#### 6.1 Clinical Trials Experience

Because clinical trials are conducted under widely varying conditions, adverse reaction rates observed in the clinical trials of a drug cannot be directly compared to rates in the clinical trials of another drug and may not reflect the rates observed in practice.

The safety of avacincaptad pegol was evaluated in 733 patients with AMD in two sham-controlled studies (GATHER1 and GATHER2). Of these patients,

292 were treated with intravitreal IZERVAY 2 mg (0.1 mL of 20 mg/mL solution). Three hundred thirty-two (332) patients were assigned to sham.

Adverse reactions reported in ≥2% of patients who received treatment with IZERVAY pooled across GATHER1 and GATHER2, are listed below in Table 1.

**Table 1: Common Ocular Adverse Reactions (≥2%) and greater than Sham in Study Eye**

Adverse Drug Reactions	IZERVAY N=292	Sham N=332
Conjunctival hemorrhage	13%	9%
Increased IOP	9%	1%
Choroidal neovascularization	7%	4%
Blurred Vision*	8%	5%
Eye pain	4%	3%
Vitreous floaters	2%	<1%
Blepharitis	2%	<1%

\* Blurred vision includes visual impairment, vision blurred, visual acuity reduced, visual acuity reduced transiently.

### 8 USE IN SPECIFIC POPULATIONS

#### 8.1 Pregnancy

##### Risk Summary

There are no adequate and well-controlled studies of IZERVAY administration in pregnant women. The use of IZERVAY may be considered following an assessment of the risks and benefits.

Administration of avacincaptad pegol to pregnant rats and rabbits throughout the period of organogenesis resulted in no evidence of adverse effects to the fetus or pregnant female at intravenous (IV) doses 5.1 times and 3.2 times the human exposure (based on AUC) at the maximum recommended human dose (MRHD) of 2 mg once monthly, respectively.

In the U.S. general population, the estimated background risks of major birth defects and miscarriage in clinically recognized pregnancies is 2-4% and 15%-20%, respectively.

#### Animal Data

An embryo fetal developmental toxicity study was conducted with pregnant rats. Pregnant rats received daily intravenous (IV) injections of avacincaptad pegol from day 6 to day 17 of gestation at 0.1, 0.4, 1.2 mg/kg/day. No maternal or embryofetal adverse effects were observed at any dose evaluated. An increase in the incidence of a non-adverse skeletal variation, described as short thoracolumbar (ossification site without distal cartilage) supernumerary ribs, was observed at all doses evaluated. The clinical relevance of this finding is unknown. Plasma exposures at the high dose were 5.1 times the MRHD, based on Area Under the Curve (AUC).

An embryo fetal developmental toxicity study was conducted with pregnant rabbits. Pregnant rabbits received daily IV injections of avacincaptad pegol from day 7 to day 19 of gestation at 0.12, 0.4, 1.2 mg/kg/day. No maternal or embryofetal adverse effects were observed at any dose evaluated. Plasma exposure in pregnant rabbits at the highest dose of 1.2 mg/kg/day was 3.2 times the human exposure at the MRHD, based on AUC.

#### 8.2 Lactation

There is no information regarding the presence of avacincaptad pegol in human milk, the effects of the drug on the breastfed infant or on milk production.

The developmental and health benefits of breastfeeding should be considered along with the mother's clinical need for IZERVAY and any potential adverse effects on the breastfed infant from IZERVAY.

#### 8.4 Pediatric Use

Safety and effectiveness of IZERVAY in pediatric patients have not been established.

#### 8.5 Geriatric Use

Of the total number of patients who received IZERVAY in the two clinical trials, 90% (263/292) were ≥65 years and 61% (178/292) were ≥75 years of age. No significant differences in efficacy or safety of avacincaptad pegol were seen with increasing age in these studies. No dose adjustment is required in patients 65 years and above.

### 17 PATIENT COUNSELING INFORMATION

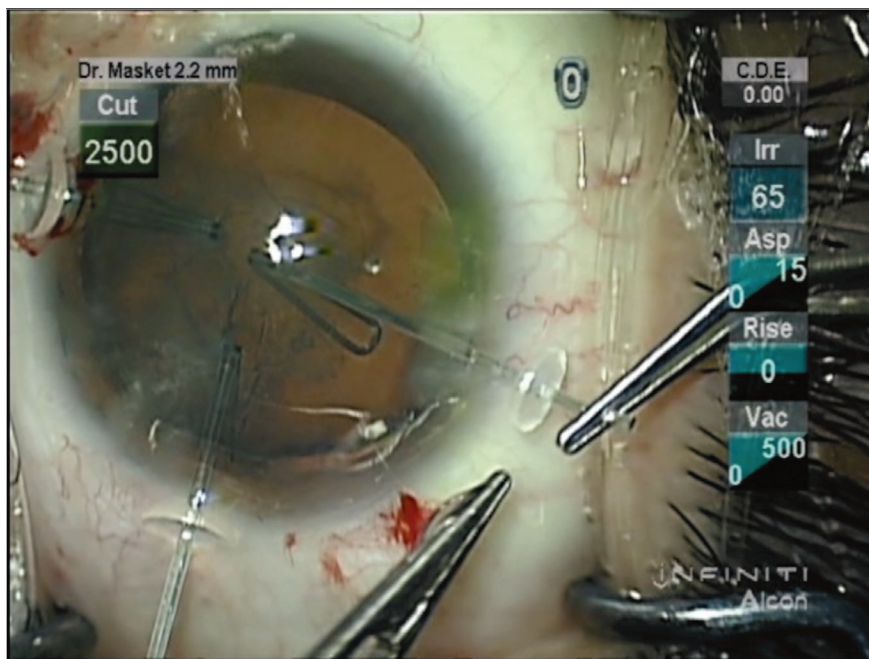
Advise patients that following IZERVAY administration, patients are at risk of developing neovascular AMD, endophthalmitis, elevated intraocular pressure and retinal detachments. If the eye becomes red, sensitive to light, painful, or if a patient develops a change in vision, instruct the patient to seek immediate care from an ophthalmologist.

Patients may experience temporary visual disturbances and blurring after an intravitreal injection with IZERVAY and the associated eye examinations. Advise patients not to drive or use machinery until visual function has recovered sufficiently.

Manufactured by:

IVERIC bio, Inc., An Astellas Company. Parsippany, NJ 07054

©2023 IVERIC bio, Inc., An Astellas Company. IZERVAY is a trademark of IVERIC bio, Inc., An Astellas Company.



Samuel Masket, MD

**Figure 2. Samuel Masket, MD, demonstrates the use of MST capsule support hooks to aid in the removal of a cataract before placing a capsular tension ring.**

are subsequent procedures that involve the use of gas or air inside the eye—and several retinal surgeries require gas and air, and several corneal procedures, such as endothelial keratoplasty, require gas and air, and that can cause opacification of this lens that’s now been sutured.”

Samuel Masket, MD, who is a founding partner of Advanced Vision Care, and clinical professor at the Stein Eye Institute, UCLA, advocates use of the femtosecond laser, capsule support hooks and in-the-bag devices such as a capsular tension ring, Ahmed segments (CTS) and/or modified capsular tension rings (Cionni, Malyugin). “Once the capsular bag is emptied the degree of zonulopathy is assessed and appropriate capsule support devices implanted,” he says. “I also advocate careful cleaning of the anterior subcapsular lens epithelial cells in all cases at surgery to prevent fibrosis and phimosis of the anterior capsulotomy. Depending on the degree of zonulopathy, it might be necessary to perform a pars plana anterior vitrectomy.”

Dr. Masket was presented with a 54-year-old female patient who had sustained a bungee cord injury to the

left eye that resulted in a cataract with significant zonulopathy and anterior vitreous prolapse. “At surgery a triamcinolone-assisted bimanual anterior vitrectomy was performed followed by cataract removal aided by capsule support hooks (MST),” he says (*Figure 2*). “Subsequently, a CTR was placed in the capsule bag and an Ahmed segment sutured to the sclera inferotemporally. During OVD removal vitreous was noted to prolapse through the main incision, necessitating pars plana vitrectomy. Five years later, the IOL capsule bag complex was noted to be stable and centered and there’s no evidence of anterior capsule phimosis.” (*A video of this procedure is available at [reviewofophthalmology.com](http://reviewofophthalmology.com).*)

For patients with pseudoexfoliation with or without zonulysis needing cataract surgery it may be advisable to place a CTR at the initial surgery if a premium IOL is implanted, advises Dr. Masket. “While the CTR won’t prevent capsular contraction and late zonulysis, later on should that IOL-capsular-bag become subluxated, the CTR itself can be suture fixated to the eyewall,” he says. “This allows the bag/IOL/CTR complex to be reattached

with more than two-point fixation. This maneuver can result in ‘perfect’ centration, which is necessary for a premium IOL.”

In an occasional case there will be a sufficient and stable capsule remnant that can allow the IOL optic to be captured by the capsulotomy, leaving the IOL loops anterior to the capsule while the optic is prolapsed behind a central opening in the posterior capsule, says Dr. Masket. “This creates a firm anchoring of the IOL in a simple and fast surgical approach. In some cases, a posterior capsulotomy can be sculpted with a vitrector in order to provide the scaffolding for optic capture. In those cases where optic capture of a three-piece IOL isn’t possible, iris suture fixation of the loops offers a viable alternative.”

### Intrascleral Haptic Fixation

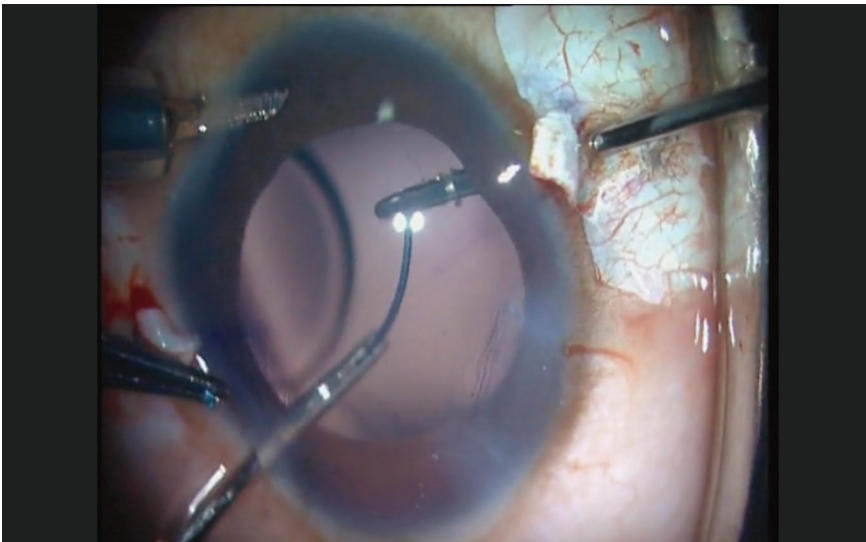
“There’s no doubt that intrascleral haptic fixation is the current method of choice for most surgeons,” says Dr. Masket. “These procedures generally take less time and require smaller incision sizes than scleral suturing methods with large PMMA IOLs.”

Intrascleral haptic fixation builds on the sutureless technique developed by Gabor Scharioth, MD, in 2006. The Scharioth technique fixates a three-piece IOL in the ciliary sulcus and the haptics in a limbus-parallel scleral tunnel or pocket. Burying the haptics reduces risks of conjunctival erosion, chronic inflammation and recurrent bleeding.<sup>5</sup>

About one year later, the first glued PC IOL implantation was done by Amar Agarwal, MD, of Chennai, India. In a “glued” IOL technique, a scleral flap covers the part of the externalized haptic and seals it with fibrin glue.<sup>6</sup>

The technique begins with corneal marking 180-degrees opposite each other for the creation of two 2.5-mm scleral flaps, followed by conjunctival peritomy and wet cautery of the sclera at the corneal marks. Two straight sclerotomies are made 1 mm from the limbus under the existing scleral





Amar Agarwal MD

**Figure 3. The glued IOL technique externalizes the IOL haptics through two sclerotomies and requires a “handshake” technique to transfer the tip of the trailing haptic from one set of forceps to another.**

flaps with a 22-ga. needle. After the vitreous is removed from the anterior chamber, a 2.8-mm corneal incision is made for inserting a three-piece foldable IOL. While being inserted, forceps pass through the left sclerotomy site and grasp the leading haptic to pull it through after the IOL has unfolded. Dr. Agarwal recommends an assistant hold this haptic tip to prevent slippage into the anterior chamber. The trailing haptic is flexed inside and its tip externalized through the other sclerotomy. Haptic tips are tucked inside a scleral tunnel, followed by a vitrectomy at the sclerotomy site, then suturing of the corneal incision with 10-0 vicryl sutures or fibrin glue. The scleral flaps and conjunctiva are then sealed with the fibrin glue.<sup>6</sup>

Dr. Agarwal points out that the “handshake” technique—when the second haptic flexes into the anterior chamber and is grabbed by the other set of glued forceps—is an essential component of its success (*Figure 3*). “You’re transferring the haptic from one hand to the other until you catch it on the tip,” Dr. Agarwal explains. “Imagine if you grabbed it in the middle, the haptic has a risk of breaking. Catching it on the tip allows it to come out easily and clearly.” (*A video of this procedure is available at*

[reviewofophthalmology.com](http://reviewofophthalmology.com).)

Since developing this technique, this is the only one he uses for IOL fixation. In 2020, he published a retrospective case series to assess the results and complications of “glued” IOLs >5-12 years postop. Clinically, no tilt was seen in 87 of 91 eyes and no sub-scleral haptic was visible in 50 percent of them. The highest complication was glaucoma (7.6 percent), IOL luxation (4.4 percent) and macular edema (4.3 percent).<sup>7</sup> In another separate study of 50 patients (25 with sutured IOLs and 25 with glued), more complications were encountered in the suture-fixation group (56 percent) vs. glued (28 percent) ( $p=0.045$ ).<sup>8</sup>

Dr. Agarwal offers a few examples of candidates for the glued IOL technique. “Take a patient with a micro cornea, about 8 mm. If I put a normal 12.5-mm IOL in the bag of an 8-mm eye, the lens will never have space to open,” he says. “In this case we would use the glued IOL technique with an 8 mm IOL, but the haptics are outside, meaning the optic is 6 mm.

“If a patient has a large eye, we perform a small iridotomy in the area where the sclerotomy will bring me, coming out 1 to 2 mm from the limbus,” he continues. “I bring it out 0.5 mm from the limbus so I’m more

anterior, and the more haptic I’m externalizing, the more haptic I’m tucking into the Scharioth pocket. And that is why those patients do very well.”

Dr. Agarwal says patients are very happy with this technique and notes he even performed it on his own 85-year-old mother-in-law.

The technique has become popular in the field, and Dr. Rao says it’s successful. “However, it does require a conjunctival peritomy,” he says. “Taking down the conjunctiva is a little bit time consuming and requires some scleral and conjunctival dissection. So, that has its downsides as well. There’s a little more time required because you have to then close the conjunctiva and close the scleral flaps that are made. That would be the only downside of that, although it’s a great technique.”

Dr. Masket has had complications related to the glued technique referred to him, including an extruding haptic three years postop. “With the glued IOL technique, the haptic scleral tunnel must be well constructed and of appropriate and uniform depth,” he notes.

Approximately 10 years after the glued IOL technique was introduced, Shin Yamane, MD, introduced the “flange” technique, in which the IOL haptics are cauterized at a low temperature, creating a flange that is buried in the sclera, obviating the need for sutures or tunnels. “The ‘flange’ method has also been adapted to malpositioned IOLs, employing large-bore Prolene suture material,” says Dr. Masket.

Recognized and referred to as the “Yamane” technique, it involves two bent needles. A three-piece IOL is inserted into the anterior chamber with the trailing haptic externalized. Using a thin-walled 30-ga. needle, an angled sclerotomy is made through the conjunctiva 90 degrees from the lens incision, 2 mm posterior to the limbus. As it enters the sulcus, the needle goes toward the leading haptic, which is threaded through it with intraocular forceps. Another sclerotomy is made

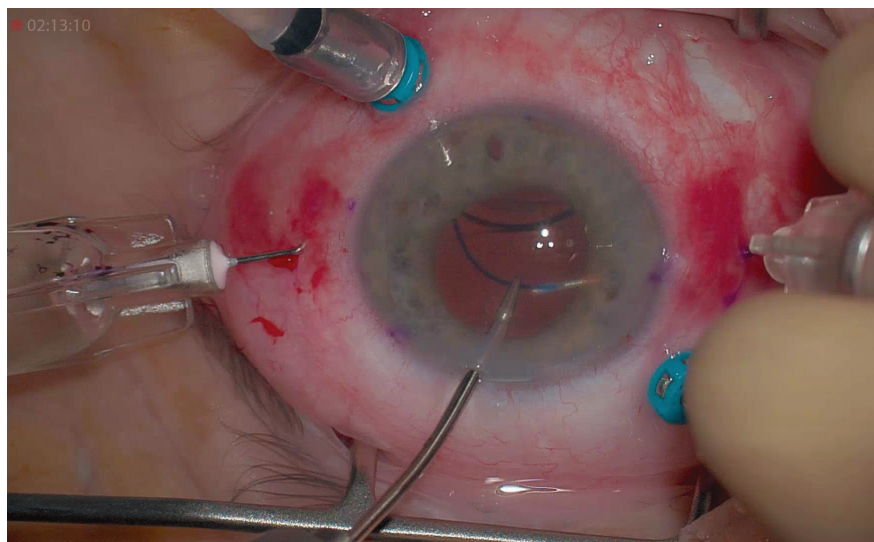
180 degrees from the first, again with a 30-ga. thin-walled needle, through which the trailing haptic is threaded (Figure 4). After confirming centration of the lens, both haptics are externalized into the conjunctiva and then heated with low-temperature cautery to create a 0.3-mm flange. The flanges are tucked through the conjunctiva and into the scleral tunnels.<sup>9</sup>

“The reason the Yamane technique is so popular is because it’s very elegant,” says Dr. Rao. “It doesn’t require any conjunctival or scleral dissection. All that’s needed is the little tracks that get created in the sclera with two 30-ga. thin-walled needles. And the nice thing about it is it’s quick, it’s much less invasive and it’s compatible with a very stable lens position. Many of us have switched over to that as our primary mode of fixation when there’s no capsular support.”

Dr. Rao says the most common complication would be a decentered or tilted lens. “Once the lens has been placed in the eye and surgery is over, it’s hard to go back in there and resurround that lens—usually that means we have to take out that lens and put in another one,” he says. “There are other risks, such as the potential to inadvertently pass the needle through the ciliary body, or if you’re not careful you could inadvertently pass the needle into the retina. I haven’t seen that complication, but that would be one concern that some surgeons have with needles that are passing in and out of the eye. Normally, we prefer to use blunt tip cannulas in the eye rather than needles. This is a unique surgery where we’re actually passing a needle inside the eye.”

“I’ve seen complications with the Yamane technique,” says Dr. Masket. “Among the concerns is that the intrascleral needle passages are ‘blind’ but need to be symmetrical and exactly 180 degrees apart in order to prevent decentration, tilt and optic capture. Perhaps using ‘on-board’ OCT can help guide the needle passes for more accurate placement.”

Dr. Rao agrees and admits the



**Figure 4.** During the Yamane technique, lens haptics are threaded or docked through two 30-ga. thin-walled needles.

Yamane technique comes with a significant learning curve. “It’s not totally straightforward, especially for people who are doing their first few cases,” he says. “It can be quite tricky to know how to pass the needle through the sclera in such a way that the lens sits totally symmetrically and it has to be centered and it shouldn’t have any tilt to it. So there’s some difficulty there in judging the angle that the needles are tunneled through the sclera. It has to be very symmetrical. There are some tricks to do it but certainly, for the first five to 10 cases there’s a significant learning curve. Some surgeons have attempted it and then felt like it didn’t work, and it’s usually because of an asymmetry of the angle of the needle trajectories through the sclera.”

He recommends practicing at labs and on model eyes. “At most meetings, there are labs to learn this,” Dr. Rao notes. “There’s a wonderful eye model for the Yamane technique made by Simuleye, called Iris Suturing and IOL Fixation. We use this model in the AAO intrascleral haptic fixation lab, for which I’m course director. It’s a much better model honestly than pig eyes because the size and the dimensions of the eye match the size that you would need for the Yamane technique. When you use a pig eye, the problem is the lens implant that

we practice with is not anywhere near the size that you need for pig eye, so the dimensions just don’t work.”

If a surgeon feels the Yamane technique isn’t working during surgery, the glued IOL is a great backup plan, says Dr. Rao. “However, fewer and fewer surgeons, at least in the United States, are learning the glued IOL technique. Most people are learning the Yamane technique, so unless someone has glued IOL training or has seen enough videos to know what to do if this happens, they may have some difficulty there. In the AAO lab for glued IOL and Yamane techniques, I like to stress to learn both, not just Yamane. I think it’s really important.”

As an instructor and surgeon adept in the Yamane technique, Dr. Rao offers some important pearls for success.

- **Always use a thin-walled, 30-ga. needle** and it has to be from the manufacturer TSK, which is in Japan,” he says. “No other 30-ga. needles will work; no other thin-walled needles will work. There are other manufacturers that say they have thin-walled 30-ga. needles and I would just urge any surgeons learning this technique not to trust it—it must be the one made by TSK.”

- **The preferred lens for Yamane is the Zeiss CT Lucia 602 lens.** “There are some surgeons who have tried



the Yamane technique with other lenses such as the Johnson & Johnson Vision AR40 or ZA9003, but I really would encourage anyone starting with this technique to start with the Zeiss CT Lucia 602 lens, which has much more resilient haptics that are made of PVDF,” Dr. Rao says. “I have no financial interest in that or at any of these products. It’s just much more versatile for this technique. The haptics of that lens can be manipulated much more than any other three-piece lens with less risk of damage to the lens.”

• **Consider involving retina colleagues.** “It’s really important when there’s a dislocated IOL to do pars plana vitrectomy or when there’s any complex cataract surgery and the surgeon thinks there may be any lenticular fragments that fall into the vitreous,” he says. “Those really should be cleaned out with a pars plana vitrectomy in combination with a retinal

surgeon in many cases, because otherwise those lens particles can cause chronic cystoid macular edema.

“If you’re going to be going in there for the Yamane technique, try to do this in conjunction with a retinal surgeon so that a full pars plana vitrectomy can be done,” continues Dr. Rao. “I also encourage most surgeons to create a peripheral iridotomy, because sometimes with the Yamane technique, the iris can backbow postoperatively, and plaster itself against the IOL and it can cause chafing. To relieve this reverse pupillary block it’s good if surgeons create a peripheral iridotomy in any clock hour of the iris.” ◀

1. Holt DG, Young J, Stagg B, Ambati BK. Anterior chamber intraocular lens, sutured posterior chamber intraocular lens, or glued intraocular lens: Where do we stand? *Curr Opin Ophthalmol* 2012;23:1:62-7.
2. Droutsas K, Lazaridis A, Kymionis G, Chatzistefanou K, Papaconstantinou D, Sekundo W, Koutsandrea C. Endothelial keratoplasty in eyes with a retained angle-support-

- ed intraocular lens. *Int Ophthalmol* 2019;39:5:1027-1035.
3. Öltulu R, Erşan İ, Şatırtav G, Donbaloglu M, Kerimoğlu H, Özkağınçı A. Intraocular lens explantation or exchange: Indications, postoperative interventions, and outcomes. *Arq Bras Oftalmol* 2015;78:3:154-7.
4. Vote BJ, Tranos P, Bunce C, Charteris DG, Da Cruz L. Long-term outcome of combined pars plana vitrectomy and scleral fixated sutured posterior chamber intraocular lens implantation. *Am J Ophthalmol* 2006;141:2:308-12.
5. Gabor SG, Pavlidis MM. Sutureless intrascleral posterior chamber intraocular lens fixation. *J Cataract Refract Surg* 2007;33:11:1851-4.
6. Narang P, Agarwal A. Glued intrascleral haptic fixation of an intraocular lens. *Indian J Ophthalmol* 2017;65:12:1370-1380.
7. Kumar DA, Agarwal A, Dhawan A, Thambusamy VA, Sivangnanam S, Venkatesh T, Chandrasekar R. Glued intraocular lens in eyes with deficient capsules: Retrospective analysis of long-term effects. *J Cataract Refract Surg* 2021;1:47:4:496-503.
8. S. Ganekal, S. Venkataratnam, S. Dorairaj, V. Jhanji. Comparative evaluation of suture-assisted and fibrin glue-assisted scleral fixated intraocular lens implantation. *J Refract Surg* 2012;28:249-252.
9. Gelman RA, Garg S. Novel Yamane technique modification for haptic exposure after glued intrascleral haptic fixation. *Am J Ophthalmol Case Rep* 2019;4:14:101-104.

(Continued from p. 33)

## DED Treatments

originally CyclASol, is a prescription eye drop for the treatment of signs and symptoms of DED. According to clinical trials, Vevey’s safety and efficacy was assessed in a total of 1,369 patients with dry-eye disease, of which 738 received Vevey. The primary endpoint was the percentage of patients achieving  $\geq 10$ -mm improvement from baseline in Schirmer’s Tear Test score. In the CYS-002 study, 8 percent of 51 Vevey patients achieved this endpoint at 29 days as opposed to 0 percent in the placebo group (n=51). In the CYS-004 study, 11 percent of 409 Vevey patients achieved this endpoint at 29 days as opposed to 7 percent of the 395-patient placebo group. The most common adverse effects Vevey patients experienced were instillation-site reactions (8 percent) and temporary decrease in visual acuity (3 percent).

Xdemvy (lotilaner 0.25%, Tarsus), originally TP-03, is a prescription eye

drop for the treatment of *Demodex* blepharitis. According to clinical trials, efficacy was demonstrated by a significant improvement in the reduction of collarettes by day 43, with some patients seeing improvement as early as two weeks. The endpoints in two Phase III studies, SATURN-1 and SATURN-2 (n=833), observed mite eradication and erythema cure. Out of 833 patients, 415 received Xdemvy for treatment and 418 received a placebo.

In the SATURN-1 trial, 81 percent of Xdemvy patients had a collarette grade of 0 or 1 (range 0 to 4, where Grade 0 indicates  $\leq 2$  collarettes on the eyelid and Grade 4 indicates  $\geq$  two-thirds of the eyelid has collarettes) on day 43 as opposed to 23 percent in the placebo group. In the SATURN-2, 89 percent of Xdemvy patients had similar results to those in the treatment arm of SATURN-1 as opposed to 33 percent in the placebo group.

By day 15, the SATURN-1 trial reported 68 percent of Xdemvy patients achieved complete mite eradication.

The most common adverse reactions patients experienced were instillation site stinging and burning (10 percent), and more severe reactions experienced were chalazion and punctate keratitis (2 percent).

“When looking under a slit lamp you’ll see the collarettes, especially in somebody who has symptoms of dry eye or recurrent itchy, scaly lid margins,” says Dr. Starr. “This can be treated with the approved drop. I’m sure there’s going to be a lot of after-market studies looking at things like adjuncts that might make Xdemvy more effective and work faster.” ◀

1. Craig JP, Nichols KK, Akpek EK, et al. TFOS DEWS II Definition and Classification Report. *Ocul Surf* 2017;15:3:276-283.
2. Yang CQ, Sun W, Gu YS. A clinical study of the efficacy of topical corticosteroids on dry eye. *J Zhejiang Univ Sci B* 2006;7:8:675-8.
3. Detailed review of the maskin protocol for meibomian gland probing. MGD Innovations. <https://mgdi.com/detailed-mg-probing-protocol>. August 11, 2023.
4. Valencia Castillo SL, Martín ES, García Frade LJ, et al. Autologous serum eye drops improve tear production, both lachrymal flow and stability tests and conjunctival impression cytology with transfer in dry eye disease. *Blood Transfus* 2021;19:1:45-53.



EDITED BY KULDEV SINGH, MD, MPH,  
AND PETER A. NETLAND, MD, PHD

## GLAUCOMA MANAGEMENT

# Managing Steroid-Induced Glaucoma

*This secondary glaucoma has a unique pathophysiology that may inform treatment approaches.*

DOUGLAS J. RHEE, MD  
CLEVELAND

Nearly 30 to 40 percent of all normal adults, and almost all primary open-angle glaucoma patients are steroid responders,<sup>1</sup> demonstrating clinically significant elevated intraocular pressures following corticosteroid use. It's important to intervene early in the course of steroid-induced glaucoma to prevent irreversible optic neuropathy and vision loss. This condition can be tricky to treat in patients who require continued steroid therapy for underlying conditions.

Though it's considered a form of open-angle glaucoma, steroid-induced glaucoma has a different pathophysiology from primary open-angle glaucoma.

Here, I'll discuss why these two diseases may require different management approaches.

## Risk Factors for a Steroid Response

Key risk factors for a steroid response include high myopia, type 1 diabetes mellitus, connective tissue disorders (e.g., rheumatoid arthritis), pigment dispersion, traumatic angle recession,<sup>2</sup> primary open-angle glaucoma, prior penetrating keratoplasty, the duration of steroid therapy and the steroid's anti-inflammatory

potency.

Age is also a risk factor. Children have a strong intraocular pressure response to topical steroids,<sup>3</sup> and younger patients (under 10 years old) are at the greatest risk for steroid-induced glaucoma. This glaucoma subtype accounts for about a quarter of all acquired glaucoma in children.<sup>4</sup>

## Route of Administration

As a general rule of thumb, the closer to the center of the eye the steroid is administered, the greater the risk. So, for example, steroid response risk is very low with intra-articular joint and intranasal administration and increases with inhaled, oral, intravenous, topical, periocular and intraocular administration.

- A meta-analysis on intranasal corticosteroids (484 studies with 10 RCT) reported a relative risk of 2.24 (95% CI, 0.68 to 7.34 percent) compared with placebo.<sup>5</sup> The absolute increase in incidence of elevated intraocular pressure was 0.8 percent (95% CI, 0 to 1.6 percent) compared with placebo in non-glaucomatous individuals—a risk of less than 1 percent.

- A single case report described elevated intraocular pressure with inhaled steroids in a young child.<sup>6</sup>

- The risk with systemic administration of steroids varies, but it's

been reported to be low, ranging from less than 1 percent to 10 percent.<sup>7</sup>

- About 3 to 4 percent of patients treated with topical difluprednate experience a significant IOP increase >10 mmHg above baseline to 21 mmHg or more.<sup>8-9</sup> Steroid-induced IOP responses after corneal transplantation are also well documented.<sup>10-11</sup> Steroids are readily absorbed by the thin skin of the eyelids and around the eyes—anecdotally, many ophthalmologists have heard of a physician self-treating with a steroid face cream who comes in with pressures of 40 mmHg and massive vision loss.

- Periocular administration carries a significantly greater risk of steroid response compared with topical steroids.<sup>12</sup> The sub-Tenon's route has a significantly high risk, likely due to its proximity to the anterior chamber angle.<sup>13</sup> A multicenter study of individuals treated with cortisone for uveitis demonstrated a 35-percent incidence of IOP elevation >24 mmHg.<sup>14</sup>

- For intravitreal administration, there's a reported 12- to 15-percent risk of a >10-mmHg IOP rise after Ozurdex (dexamethasone), and an up to 50-percent risk with intravitreal triamcinolone acetonide.<sup>15</sup>

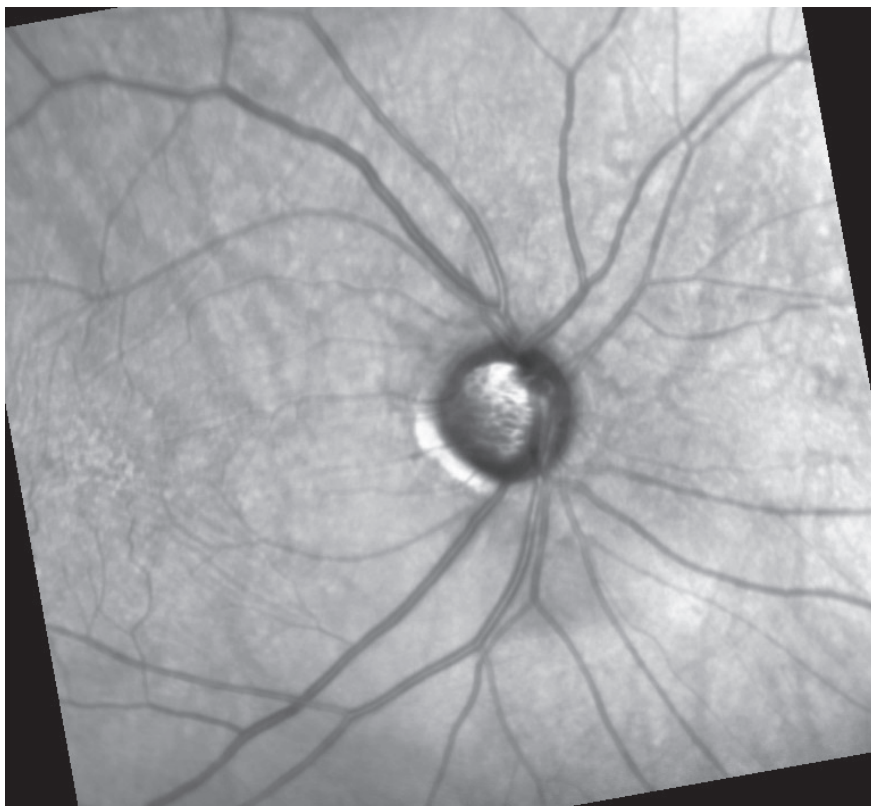
## Two Unique Pathophysiologies

Though they share a mechanism of increased aqueous outflow resistance, steroid-induced glaucoma and primary open-angle glaucoma aren't the same disease. Unlike primary open-angle glaucoma, steroid-induced glaucoma typically resolves spontaneously once steroids are discontinued. Based on their respective pathophysiologies, different approaches to treatment may be

This article has no commercial sponsorship.

Dr. Singh is a professor of ophthalmology and chief of the Glaucoma Division at Stanford University School of Medicine. He is a consultant to Alcon, Allergan, Santen, Sight Sciences, Glaukos and Ivantis. Dr. Netland is Vernah Scott Moyston Professor and Chair at the University of Virginia in Charlottesville.





The risk for steroid-induced glaucoma is partially influenced by the site of administration. In general, the closer to the center of the eye, the greater the risk. The steroid's anti-inflammatory potency and the duration of steroid therapy also play a role.

warranted.

- **Primary open-angle glaucoma.**

The mechanism of primary open-angle glaucoma involves an increase of transforming growth factor beta-2 (TGFB2), which causes dysregulation of the extracellular matrix within the juxtacanalicular trabecular meshwork.

Another probable mechanism of this glaucoma subtype may be decreased trabecular meshwork cellularity.<sup>16</sup> However, this mechanism has been observed only in cadaver eyes that were medically treated and/or had previously undergone surgery, not in untreated trabecular meshwork tissue. So, it's unclear whether decreased cellularity was the result of the disease itself or its treatment. Another challenge with this theory is that the rate of cellularity decline is the same for non-glaucomatous eyes. If decreased cellularity were disease pathophysiology, one would expect the rate of cell

loss to be greater in glaucomatous eyes.

- **Steroid-induced glaucoma.** One way steroids increase resistance to outflow by inducing dysregulation of the actin cytoskeleton (cross-linked actin networks [CLANs]). CLANs cause endothelial cellular stiffness and subsequently trigger an IOP increase.<sup>17</sup> This has been observed within trabecular meshwork cells in cell cultures, cadaveric organ perfusion and in live mice. Very limited evidence suggests CLAN formation may also play a role in primary open-angle glaucoma pathophysiology, but the mechanism hasn't been observed in untreated trabecular meshwork tissue.

In addition to CLAN formation, steroid-induced glaucoma involves dysregulation of the extracellular matrix, but this dysregulation is markedly different from that of primary open-angle glaucoma when seen on electron microscopy. Steroid-induced

glaucoma exhibits more extracellular matrix accumulation in the juxtacanalicular region, as well as increases in curly collagen 6 and inhibition of matrix metalloproteinase enzymes from increasing levels of TIMPs. Additionally, a buildup of fine fibrillar material resembling fingerprints occurs, along with collagen IV, heparin sulfate, fibronectin, and an increase in other matrix proteins such as decorin, myocilin, fibrillin and secreted frizzled-related protein.

## Medical Management

Discontinue steroids first, if possible. If the patient has been on steroid therapy for more than 18 months, IOP elevation may last for several weeks.<sup>18</sup> Topical steroids can be switched to a lower potency. Then, start a prostaglandin analog—either topical or sustained release bimatoprost.

I recommend trying a rho kinase inhibitor sooner, rather than following the usual stepping pattern after a prostaglandin analog to the medications that decrease aqueous, because the rho kinase inhibitor mechanism of action potentially targets the pathophysiology of steroid-induced glaucoma.

Rho kinase inhibitors affect the actin cytoskeleton by disrupting the actin stress fibers and focal adhesions in trabecular meshwork cells.<sup>19-20</sup> In a steroid-induced OHT mouse model study published earlier this year (n=56), morphological changes (extracellular matrix accumulation) and reduced trabecular meshwork effective filtration area induced by dexamethasone were partially reversed after one week of treatment with a rho kinase inhibitor ( $p < 0.05$ ) or five-week discontinuation of dexamethasone ( $p < 0.01$ ).<sup>21</sup> This correlated with reduced IOP. IOP reductions were greater in rho kinase inhibitor-treated eyes than eyes that discontinued dexamethasone treatment.

Prostaglandin analogs should remain the first-line treatment,

however, because they impact MMPs and TIMPs, targeting another part of steroid-induced glaucoma's pathophysiology. These drugs shift the MMP/TIMP balance in the ciliary body and the trabecular meshwork toward greater turnover of extracellular matrix.<sup>22-29</sup>

## Selective Laser Trabeculoplasty

It's unclear whether there are any meaningful differences between primary open-angle glaucoma and steroid-induced glaucoma with regard to SLT success. A retrospective study reported a 72-percent SLT success rate ( $\geq 20$  percent reduction from baseline IOP) in 25 eyes with steroid-induced glaucoma.<sup>30</sup>

Another retrospective study (n=608 eyes) reported that steroid-induced glaucoma patients did better with SLT than primary open-angle ( $p=0.005$ ) or pseudoexfoliation ( $p=0.01$ ) glaucoma patients, but a significantly higher baseline IOP for steroid-induced glaucoma eyes may have been a confounder.<sup>31</sup>

In the same study, the two-year failure rate for steroid-induced glaucoma patients was 54-percent failure, compared with 84 percent ( $p=0.01$ ) for pseudoexfoliation glaucoma and 84 percent for primary open-angle glaucoma ( $p=0.005$ ).

## Surgical Management

There's a paucity of literature specifically comparing the efficacy of our incisional surgical procedures in POAG versus steroid-induced glaucoma.

• **Goniotomy.** A retrospective study of steroid-induced glaucoma versus primary open-angle glaucoma using Trabectome found no difference in the survival curve.<sup>32</sup> A greater IOP response was seen in the steroid-induced eyes, but they also had a much higher baseline IOP—a problem with retrospective cohort comparisons.

The incidence of steroid response after either Trabectome or iStent

goniotomy is about 12 percent.<sup>33</sup> Greater axial length, low-tension glaucoma and traumatic glaucoma were risk factors for steroid response after goniotomy. In eyes with axial length  $>25$  mm, the incidence was 40 percent.

• **GATT.** A retrospective chart review of 13 patients demonstrated that GATT was effective for steroid-induced glaucoma,<sup>34</sup> which isn't surprising. GATT resulted in a significant IOP reduction at all postop visits, with all patients experiencing IOP reduction  $>20$  percent at two years. The number of glaucoma medications also decreased significantly from an average of 3.1 medications preoperatively to 0.8 medications at the last follow-up.



The rho kinase inhibitor mechanism of action potentially targets the pathophysiology of steroid-induced glaucoma.



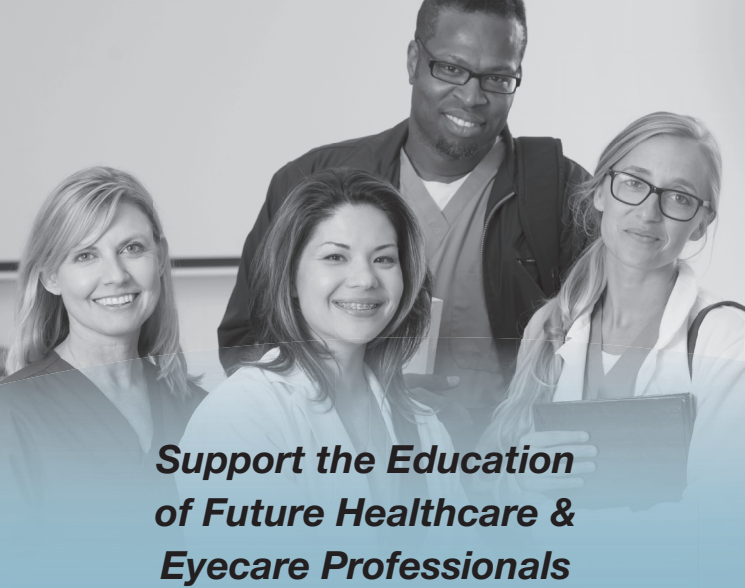Another retrospective chart review of 46 eyes reported that GATT was effective for short-duration steroid-induced glaucoma.<sup>35</sup> IOP decreased from mean  $30.8 \pm 8.3$  mmHg at baseline to  $11.2 \pm 2.6$  mmHg after one to two years (n=28). At the final follow-up, 45 eyes had IOP  $<21$  mmHg and 39 eyes had IOP  $<18$  mmHg with or without medication. Steroid response wasn't seen in any eyes after surgery. A few other case reports have reported GATT efficacy.<sup>36-37</sup>

In conclusion, SLT and incisional procedures have comparable efficacies in steroid-induced glaucoma and primary open-angle glaucoma. Anecdotally, I've observed that trabeculectomies do better if the depot steroid remains in the eye. For medical management, I recommend

using a prostaglandin analog as a first-line agent because these drugs alter the MMP/TIMP balance and can reduce the buildup of extracellular matrix. Consider using a rho kinase inhibitor as a second-line agent after the prostaglandin analog because this drug class directly affects CLANs. ◀

1. Dibas A Yorio T. Glucocorticoid therapy and ocular hypertension. *Eur J Pharmacol* 2016;787:57-71.
2. Jones III R, Rhee DJ. Corticosteroid-induced ocular hypertension and glaucoma: A brief review and update of the literature. *Curr Opin Ophthalmol* 2006;17:163.
3. Ohji M, Kinoshita S, Ohmi E, et al. Marked intraocular pressure to instillation of corticosteroids in children. *Am J Ophthalmol* 1991;112:450-454.
4. Kaur S, Dhiman I, Kaushik S, Raj S, Pandav SS. Outcome of ocular steroid hypertensive response in children. *J Glaucoma* 2016;25:4:343-347.
5. Valenzuela CV, et al. Intranasal corticosteroids do not lead to ocular changes: A systematic review and meta-analysis. *Laryngoscope* 2019;129:6-12.
6. Desnoeck M, Casteels I, Casteels K. Intraocular pressure elevation in a child due to the use of inhalation steroids—A case report. *Bull Soc Belge Ophtalmol* 2001;280:97-100.
7. Ritch R, Shields MB, Krupin T. *The Glaucomas*: Basic Sciences, 2nd ed. Mosby-Year. 1996.
8. Korenfeld MS, Silverstein SM, Cooke DL, Vogel R, Crockett RS; Difluprednate ophthalmic emulsion 0.05% (Durezol) Study Group. Difluprednate ophthalmic emulsion 0.05% for postoperative inflammation and pain. *J Cataract Refract Surg*. 2009;35:1:26-34.
9. Smith S, Lorenz D, Peace J, McLeod K, Crockett RS, Vogel R. Difluprednate ophthalmic emulsion 0.05% (Durezol) administered two times daily for managing ocular inflammation and pain following cataract surgery. *Clin Ophthalmol* 2010;4:983-991.
10. Kornmann HL, Gedde SJ. Glaucoma management after corneal transplantation surgeries. *Curr Opin Ophthalmol* 2016;27:2:132-139.
11. Price MO, Price DA, Price FW Jr. Long-term risk of steroid-induced ocular hypertension/glaucoma with topical prednisolone acetate 1% after Descemet stripping endothelial keratoplasty. *Cornea* 2023. Published ahead of print, June 7.
12. Chew EY, Glassman AR, Beck RW, et al. Ocular side effects associated with peribulbar injections of triamcinolone acetonide for diabetic macular edema. *Retina* 2011;31:2:284-289.
13. McGhee CN, Dean S, Danesh-Meyer H. Locally administered ocular corticosteroids: benefits and risks. *Drug Saf* 2002;25:1:33-55.
14. Sen HN, Vitale S, Gangaputra SS, Nussenblatt RB, Liesegang TL, Levy-Clarke GA, Rosenbaum JT, Suhler EB, Thorne JE, Foster CS, Jabs DA, Kempner JH. Periocular corticosteroid injections in uveitis: Effects and complications. *Ophthalmology* 2014;121:11:2275-86.
15. Rhee DJ, Peck RE, Belmont J, et al. Intraocular pressure alterations following intravitreal triamcinolone acetonide. *Br J Ophthalmol* 2006;90:999-1003.
16. Alvarado J, Murphy C, Juster R. Trabecular meshwork cellularity in primary open-angle glaucoma and nonglaucomatous normal. *Ophthalmology* 1984;91:564.
17. Rohen JW. Why is intraocular pressure elevated in chronic simple glaucoma? *Ophthalmology* 1983;90:7:758-765.





**Support the Education  
of Future Healthcare &  
Eyecare Professionals**

# THE RICK BAY FOUNDATION

*for Excellence in Eyecare Education*

Scholarships are awarded to advance the education of students in both **Optometry** and **Ophthalmology**, and are chosen by their school based on qualities that embody Rick's commitment to the profession, including integrity, compassion, partnership and dedication to the greater good.

**INTERESTED IN BEING  
A PARTNER WITH US?**

[www.rickbayfoundation.org](http://www.rickbayfoundation.org)

*(Contributions are tax-deductible in accordance with section 170 of the Internal Revenue Code.)*

## ABOUT RICK

Rick Bay served as the publisher of *The Review Group* for more than 20 years.

To those who worked for him, he was a leader whose essence was based in a fierce and boundless loyalty.

To those in the industry and the professions he served, he will be remembered for his unique array of skills and for his dedication to exceeding the expectations of his customers, making many of them fast friends.



**THE RICK BAY FOUNDATION**  
*for Excellence in Eyecare Education*

*(The Rick Bay Foundation for Excellence in Eyecare Education is a nonprofit, tax-exempt organization under section 501(c)(3) of the Internal Revenue Code.)*

## GLAUCOMA MANAGEMENT | Steroid-induced Glaucoma

18. Sihota R, Konkal VL, Dada T, Agarwal HC, and Singh R. Prospective, long-term evaluation of steroid-induced glaucoma. *Eye* 2008;22:1:26-30.
19. Lin CW, Sherman B, Moore LA, et al. Discovery and preclinical development of netarsudil, a novel ocular hypotensive agent for the treatment of glaucoma. *J Ocul Pharmacol Ther* 2018;34;1-2:40-51.
20. Keller KE, Kopczynski C. Effects of netarsudil on actin-driven cellular functions in normal and glaucomatous trabecular meshwork cells: A live imaging study. *J Clin Med* 2020 Oct 31;9:3524.
21. Ruiji R, Humphrey AA, Kopczynski C, Gong H. Rho kinase inhibitor AR-12286 reverses steroid-induced changes in intraocular pressure, effective filtration areas and morphology in mouse eyes. *Invest Ophthalmol Vis Sci* 2023;64:7.
22. Weinreb RN, Kashiwagi K, Kashiwagi F, Tsukahara S, Lindsey JD. Prostaglandins increase matrix metalloproteinase release from human ciliary smooth muscle cells. *Invest Ophthalmol Vis Sci* 1997;38:2778-2780.
23. Anthony TL, Lindsey JD, Weinreb RN. Latanoprost's effects on TIMP-1 and TIMP-2 expression in human ciliary muscle cells. *Invest Ophthalmol Vis Sci* 2002;43:3705-3711.
24. Weinreb RN, Lindsey JD. Metalloproteinase gene transcription in human ciliary muscle cells with latanoprost. *Invest Ophthalmol Vis Sci* 2002;43:716-722.
25. Oh DJ, Martin JL, Williams AJ, Peck RE, Pokorny C, Russell P, Birk DE, Rhee DJ. Analysis of expression of matrix metalloproteinases and tissue inhibitors of metalloproteinases in human ciliary body after latanoprost. *Invest Ophthalmol Vis Sci* 2006;47:953-963.
26. Oh DJ, Martin JL, Williams AJ, Russell P, Birk DE, Rhee DJ. Effect of latanoprost on the expression of matrix metalloproteinases and their tissue inhibitors in human trabecular meshwork cells. *Invest Ophthalmol Vis Sci* 2006;47:3887-3895.
27. Ooi YH, Oh DJ, Rhee DJ. Effect of bimatoprost, latanoprost, and unoprostone on matrix metalloproteinases and their inhibitors in human ciliary body smooth muscle cells. *Invest Ophthalmol Vis Sci* 2009;50:5259-5265.
28. Heo JY, Ooi YH, Rhee DJ. Effect of prostaglandin analogs: Latanoprost, bimatoprost, and unoprostone on matrix metalloproteinases and their inhibitors in human trabecular meshwork endothelial cells. *Exp Eye Res* 2020;194:108019.
29. Stamer WD, Perkumas KM, Kang MH, Dibas M, Robinson MR, Rhee DJ. Proposed mechanism of long-term intraocular pressure lowering with the bimatoprost implant. *Invest Ophthalmol Vis Sci* 2023;64:15.
30. Al Obaida I, Al Owaifeer AM, Aljasim L, et al. Outcomes of selective laser trabeculoplasty in corticosteroid-induced ocular hypertension and glaucoma. *Euro J Ophthalmol* 2022;32:3:1525-1529.
31. Zhou Y, Pruet CM, Fang C, Khanna CL. Selective laser trabeculoplasty in steroid-induced and uveitis glaucoma. *Can J Ophthalmol* 2022;57:4:277-283.
32. Dang Y, Kaplowitz K, Parikh HA, et al. Steroid-induced glaucoma treated with trabecular ablation in a matched comparison with primary open-angle glaucoma. *Clin Exp Ophthalmol* 2016;44:783-788.
33. Abtahi M, Rudnisky CJ, Nazarali S and Damji KF. Incidence of steroid response in microinvasive glaucoma surgery with trabecular microbypass stent and ab interno trabeculectomy. *Can J Ophthalmol* 2022;57:3:167-174.
34. Boese EA, Shah M. Gonioscopy-assisted transluminal trabeculectomy (GATT) is an effective procedure for steroid-induced glaucoma. *J Glaucoma* 2019;28:9:803-807.
35. van Rijn LJR, Eggink CA, Janssen SF. Circumferential (360°) trabeculectomy for steroid-induced glaucoma in adults. *Graefes Arch Clin Exp Ophthalmol* 2023;261:7:1987-1994.
36. Nazarali S, Cote SL, Gooi P. Gonioscopy-assisted transluminal trabeculectomy (GATT) in postpenetrating keratoplasty steroid-induced glaucoma: A case report. *J Glaucoma* 2018;27:10:e162-e164.
37. Hopen ML, Gallardo MJ, Grover DS. Gonioscopy-assisted transluminal trabeculectomy in a pediatric patient with steroid-induced glaucoma. *J Glaucoma* 2019;28:10:e156-e158.

## ABOUT THE AUTHOR

**Dr. Rhee** is a professor and chair of the Department of Ophthalmology and Visual Sciences at Case Western Reserve University School of Medicine.

He is also the director of the Eye Institute, University Hospitals of Cleveland.

He receives researching funding from Allergan/Abbvie, Glaukos, Ivantis/Alcon, Cleveland Eye Bank Foundation and Ocular

Therapeutix. He is also an ad hoc consultant for Alcon, Allergan, Avellino and Iantrek.





EDITED BY CARL REGILLO, MD,  
AND YOSHIHIRO YONEKAWA, MD

## RETINAL INSIDER

# An Update on Fundus Autofluorescence

*This imaging method can help elucidate retinal disease, monitor progression and possibly advance therapy.*

**YSE BORELLA, MD** PITTSBURGH  
**HARSHIT VAIDYA, MD** MUMBAI, INDIA  
**JAY CHHABLANI, MD** PITTSBURGH

**A**utofluorescence is a natural phenomenon by which a fluorophore is excited by a certain wavelength of light, causing it to re-emit this light at a longer wavelength. It's also a powerful tool for monitoring endogenous fluorophores and biological conditions.<sup>1</sup> Fundus autofluorescence is an *in vivo* imaging tool that enables non-invasive metabolic mapping of natural and pathological fluorophores in the posterior pole, mainly the retina and retinal pigment epithelium.

In this review, we highlight some recent developments in FAF imaging

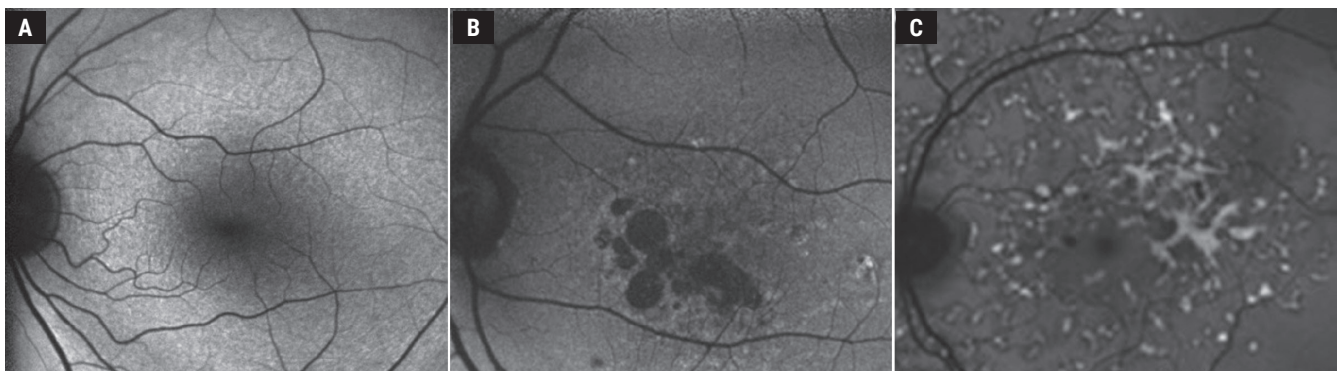
that have enhanced our understanding of retinal diseases and have promising prospects for monitoring disease progression, following patients in clinical trials and potentially influencing treatment outcomes.

### Autofluorescence Explained

There's a relationship between the morphofunctional properties of the fluorophores and their emission feature.<sup>1</sup> Each fluorophore has a particular AF signature. There's probably a continuum of the spectral fundus autofluorescence from blue to near-infrared (NIR) because of the combination of the different fluorophores (for example melanolipofuscin granules of different orders). FAF must be interpreted depending on the wave-

length used, as different wavelengths will excite different fluorophores.<sup>2</sup> The fluorescent spectrum can therefore allow for topographical mapping of the endogenous fluorophores like lipofuscin, melanin or melanolipofuscin at the level of (post mitotic) retinal pigment epithelium/photoreceptor (outer segment) complex.<sup>3,4</sup>

Schepens Eye Research Institute's Francis Charles Delori, PhD, and his colleagues<sup>5</sup> first noticed *in vivo* FAF during vitreous fluorophotometry. Several types of light sources can be used to stimulate the fundus to exhibit autofluorescence. Flood illumination projects a single flashlight to the entire retina, but pre-retinal structures can impede the AF signals. A study by New York retinal specialist Richard Spaide suggested shifting the emission and excitation wavelengths to the red end of the spectrum to resolve the impeding signals from pre-retinal structures.<sup>6</sup> Other teams proposed the use of filters of longer wavelengths (excitation filter: 535 to 580 nm; barrier filter: 615 to 715 nm). These operate with excitation in the green spectrum and emission in the yellow-orange spectrum and are also

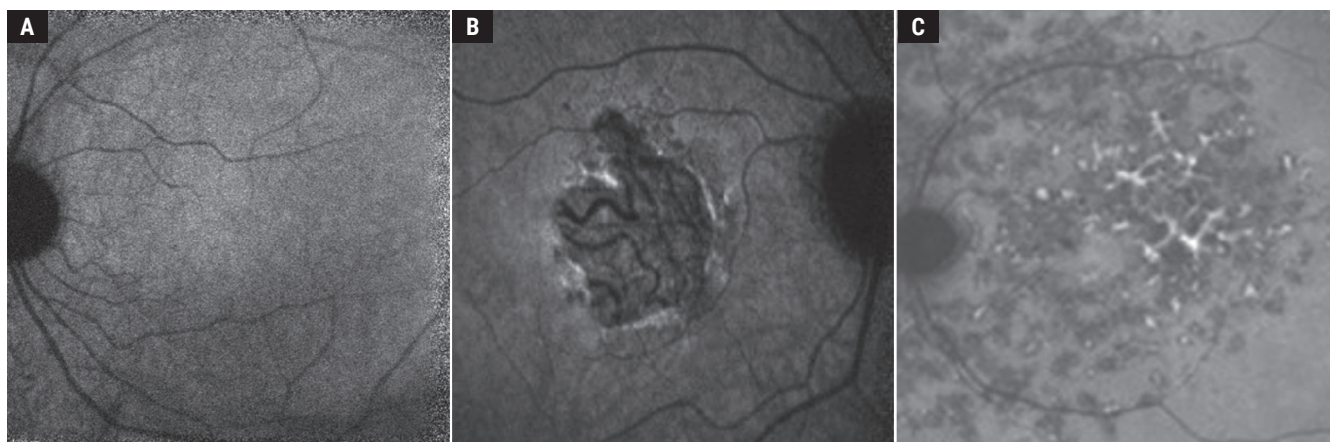


**Figure 1. Blue Autofluorescence. Normal autofluorescence (A), dry AMD (B) (adapted from Ly et al<sup>13</sup>) and Stargardt's disease (C) (adapted from Jeffery et al<sup>14</sup>).** Copyright license for Fig. 1, B and C: <http://creativecommons.org/licenses/by-nc/4.0/>. Images have not been modified from original publication.

**This article has no commercial sponsorship.**

**Dr. Regillo** is the director of the Retina Service of Wills Eye Hospital, a professor of ophthalmology at Thomas Jefferson University School of Medicine and the principle investigator for numerous major international clinical trials.

**Dr. Yonekawa** is an assistant professor of ophthalmology at Sidney Kimmel Medical College at Thomas Jefferson University. He serves on the Education Committee of the American Society of Retina Specialists and on the Executive Committee for the Vit Buckle Society, where he is also the vice president for academic programming.



**Figure 2. Near-infrared autofluorescence. Normal fundus (A), dry AMD (B) and Stargardt's disease (C), the same patient as in Fig. 1C; adapted from Jeffery et al.<sup>14</sup> Copyright license for Fig. 2B: <http://creativecommons.org/licenses/by-nc/4.0/>. Images have not been modified from original publication.**

called green-AF.<sup>4</sup> The most used and most efficient type of light source is therefore a laser (with a fixed unique wavelength) through the use of confocal scanning laser ophthalmoscopy, which helps overcome AF signals from preretinal structures like the lens, and has the best signal-to-noise ratio and retinal safety.<sup>7</sup> To date, the commercially available cSLOs allow for exploration of FAF at 488 nm (blue) and 787 nm (NIR). The RPE/retina complex is known to be autofluorescent both with blue excitation and at near-infrared autofluorescence, and have a different pattern, due to the selective excitation of different fluorophores by each wavelength.

### Blue Autofluorescence

Low-powered laser beams are used in cSLO, with excitation filters (488 nm) and emission filters (500 to 580 nm) which are used to detect AF signals and are also called short wavelength (SW) AF or blue AF. Blue AF was the first clinically used AF as a diagnosis tool, after the use of the blue excitation light for fluorescein angiography.<sup>7</sup>

The blue AF comes from the outer segment of the photoreceptors and the RPE due to the formation and accumulation of lipofuscin.<sup>8</sup> An irreversible non-enzymatic reaction of retinaldehyde with lipid (phosphatidylethanolamine) in photoreceptor

outer segments, results in formation of lipofuscin/bisretinoid fluorophores, which can be excited by blue light, emitting a green light.<sup>5,9,10</sup> The bisretinoids of lipofuscin are a family of 20 compounds, of which A2E is the best-known fluorophore. These accumulate in the lysosomal storage bodies from photo-oxidative alterations, and its conjugate double bonds promote light absorption and fluorescence emission.<sup>11</sup> The emission spectra of the fundus shift slightly to shorter wavelengths in healthy subjects and even more in patients with age-related macular degeneration,<sup>12</sup> likely reflecting the accumulation of lipofuscin in the RPE/retina with aging and in AMD.

High concentration of xanthophylls (lutein and zeaxanthin) and melanin result in hypoAF of the foveal region because of a masking effect. Lack of RPE in the optic disc and blocking of AF by the blood contents in the retinal vessels result in the dark appearance of both optic disc and vessels on AF (*Fig. 1A*). Less evident blockage by macular pigments and less signal reduction over the optic disc and retinal vessels are noted on green-AF (fundus camera).<sup>4</sup> HypoAF signal is noted in conditions with reduced RPE cell number, masking or lower concentration of lipofuscin. RPE atrophy (such as in atrophic AMD, *Figure 1B*), fibrosis, presence of

intraretinal fluid, pigment or blood accumulation are all causes for hypoAF. HyperAF signals are often noted in conditions with increased lipofuscin (such as Stargardt's disease [*see Figure 1C*], Best's and other types of dystrophies).<sup>1,2</sup>

### Near-Infrared (NIR) Autofluorescence

This is an *in-vivo* imaging technique that uses excitation at 787 nm and emission (>830 nm) beyond the red end of the visible spectrum. The fluorophores examined by NIR-AF are melanin and melanolipofuscin,<sup>15,16</sup> with a major contribution from RPE and a smaller contribution from the choroid. The antioxidant properties of melanin are believed to have a protective effect on the eye with AMD. Melanin helps delay the accumulation of lipofuscin in the retina and choroid. In healthy eyes and contrary to blue AF, the NIR-AF signal is maximal in the foveal area, which has a horizontal width of 8.8 degrees.<sup>11</sup> This is due to a larger concentration of RPE cells in the foveal area, and no absorption of emitted NIR-AF signal by macular pigments (*See Figure 2A*).<sup>7</sup> Some studies suggest that melanin becomes AF in NIR following oxidization,<sup>15</sup> with an increase of NIR-AF signal in aging patients<sup>17,18</sup> and at the border of atrophic lesions in AMD patients (*Figure 2B*).<sup>19,20</sup>



# Find qualified ophthalmic technicians fast

Finding a qualified ophthalmic technician for your practice can be difficult. That's why private practices and large employers alike trust Eyes On Eyecare® for specialized job posting and recruiting services.

## SOURCE TALENT MORE EFFICIENTLY WITH OUR:



Large talent pool of active and passive job seekers



Syndication to major job platforms and cross-promotion to our affiliate network



Dedicated recruiting team with years of eyecare experience sourcing talent for specialized positions



*"I had such a wonderful experience using Eyes On Eyecare. It was so easy to post a job and they walk you through the entire process. I recommend them to everyone I know."*

*- Ashley Wojcik*

PROUD PARTNER OF JOBSON OPTICAL GROUP

Learn more at [eyesoneyecare.com/hire-now](https://eyesoneyecare.com/hire-now)

While blue AF requires a strong blue illumination, NIR-AF uses a laser source above 750 nm, which is a faint red light, well-tolerated by patients. This allows the potential of longer imaging times (~30 seconds) with adapted set-ups, mainly adaptive optics SLO (AOSLO), to characterize RPE at a cellular scale using their NIR-AF potential.<sup>21-23</sup>

Short wavelength (SW)-AF and NIR-AF have complementary roles in evaluation of lipofuscin and melanin, and their role in AMD pathogenesis. SW-AF failed to detect geographic atrophy in 24 percent of the eyes with GA. With the introduction of Syfovre (pegcetacoplan, Apellis) and Izervay (avacincaptad pegol), c5 complement inhibitors for arresting GA progression, NIR-AF seems to have more

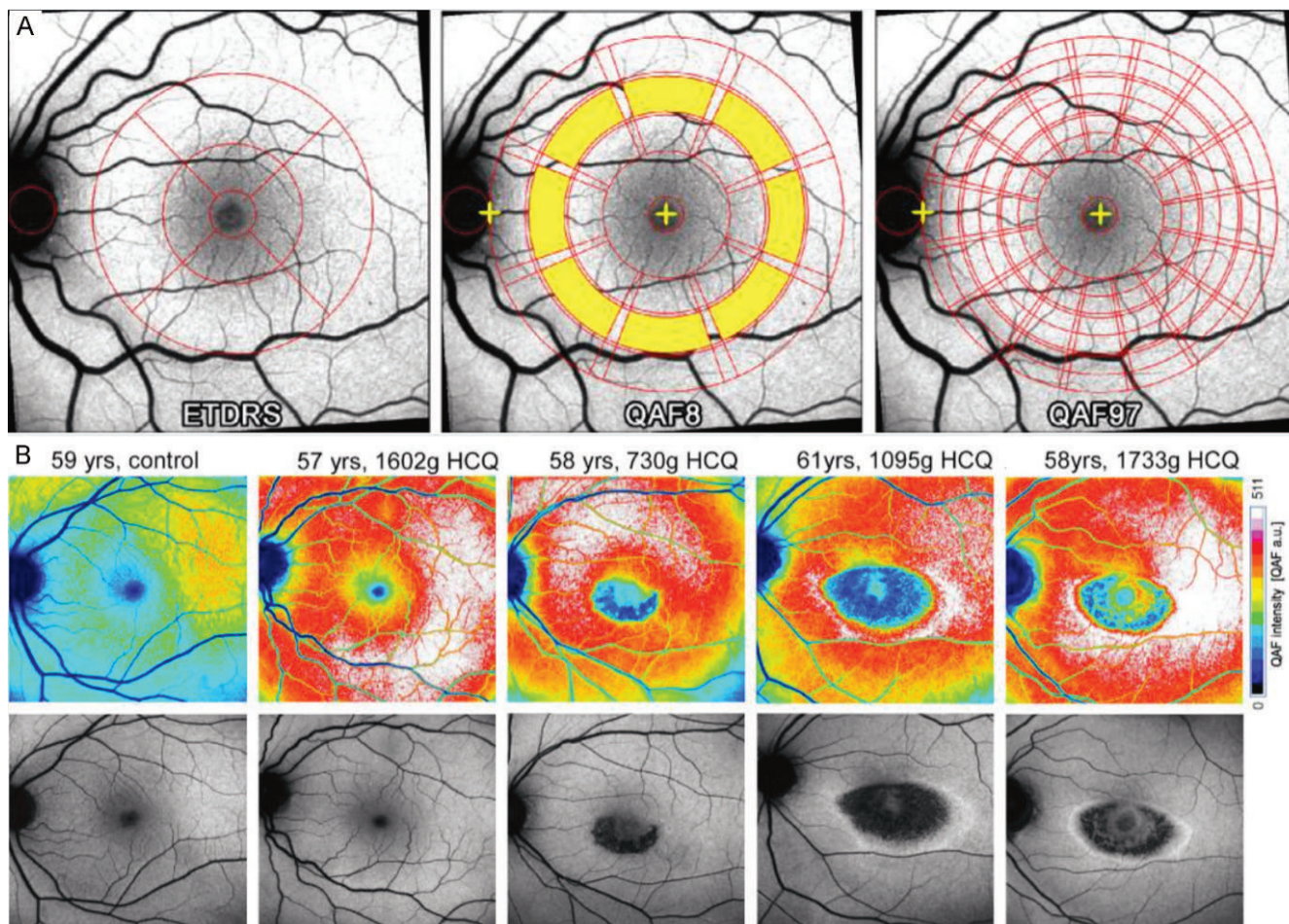
promise. The use of AF in these clinical trials plays an important role, and thus missing 24 percent of GA would have a significant impact on these trials and outcomes.<sup>24,25</sup> NIR-AF helps detect changes earlier than SW-AF in patients with GA. The fovea appears hypoAF in blue AF due to macular xanthophyll pigments absorbing the blue light, whereas on NIR-AF, the fovea is brighter than the parafoveal region due to increased melanin content and a lack of NIR filtering by macular xanthophylls. Hence, SW-AF may overestimate GA in the foveal area and underestimate it in the extrafoveal area. Therefore, some suggest to use NIR-AF in conjunction with SW-AF for monitoring patients with GA.<sup>24,26</sup>

Interestingly, in ABCA4 diseases

(with elevated lipofuscin levels), lipofuscin fluorophores are noted to contribute to NIR-AF signals and are thought to be melanolipofuscin-associated fluorophores (See Figure 2C).<sup>10,11,14</sup>

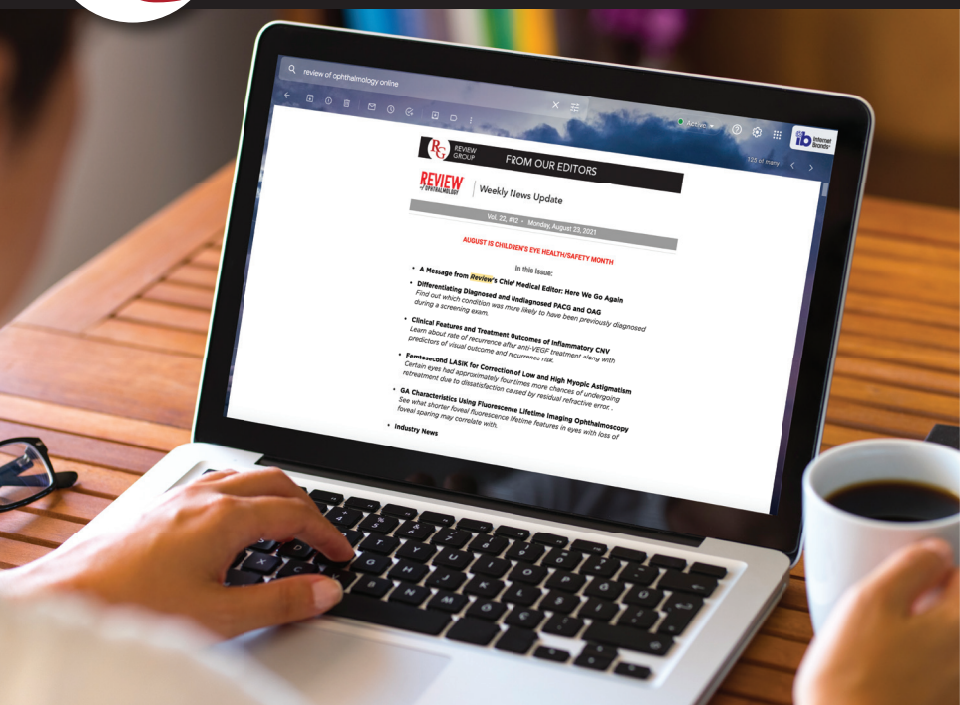### Fluorescence Lifetime Imaging Ophthalmoscopy (FLIO)

FLIO is a relatively novel imaging tool that's gained interest in the ophthalmic community and has shown promise in diagnosis and monitoring of various retinal disorders. Fluorescence lifetime imaging has been used *in vivo* for cancer diagnosis and skin evaluation. It's used by the Heidelberg Spectralis system and has been shown to provide additional information when compared to traditional imaging techniques. Essentially, it measures the

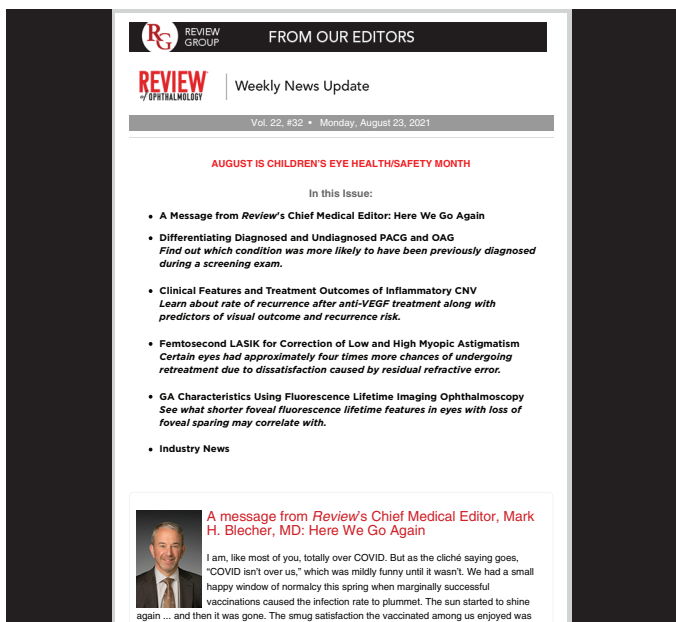


**Figure 3. Quantitative autofluorescence. A:** Different patterns used to measure qAF to different precision degree (adapted from Kleefeld et al.)<sup>31</sup> **B:** Example from different patients treated with hydroxychloroquine (HCQ) at different doses (adapted from Reichel et al.)<sup>32</sup> Copyright license for Figs. 3A and B: <http://creativecommons.org/licenses/by-nc/4.0/>. Images have not been modified from original publication.





# Read the Latest from our Editors



If you aren't already a subscriber, please be sure to sign up for our recurring e-journal, *Review of Ophthalmology Weekly News Update*.

Join the thousands of MDs and ophthalmic industry readers who turn to us each week to see a curated digest of the latest, most relevant clinical studies and industry news. You'll also receive monthly hot-takes from *Review's* Chief Medical Editor, Mark Blecher, MD.

Visit: **JMI | Newsletter Signup**  
[www.jhihealth.com/globalemail/](http://www.jhihealth.com/globalemail/)

to sign up for *Review of Ophthalmology Weekly News Update*, and other e-newsletters distributed by Jobson Medical Information.

**FOR ADVERTISING OPPORTUNITIES, PLEASE CONTACT**

- Michael Hoster:** Mhoster@jobson.com  
610-492-1028
- Michele Barrett:** Mbarrett@jobson.com  
215-519-1414
- Jon Dardine:** Jdardine@jobson.com  
610-492-1030

## REVIEW OF OPHTHALMOLOGY WEEKLY NEWS UPDATE:

**Reaches 9,000 MDs weekly**

**Content:** Clinical information & Industry news

**Metrics:** 21.5% average opens

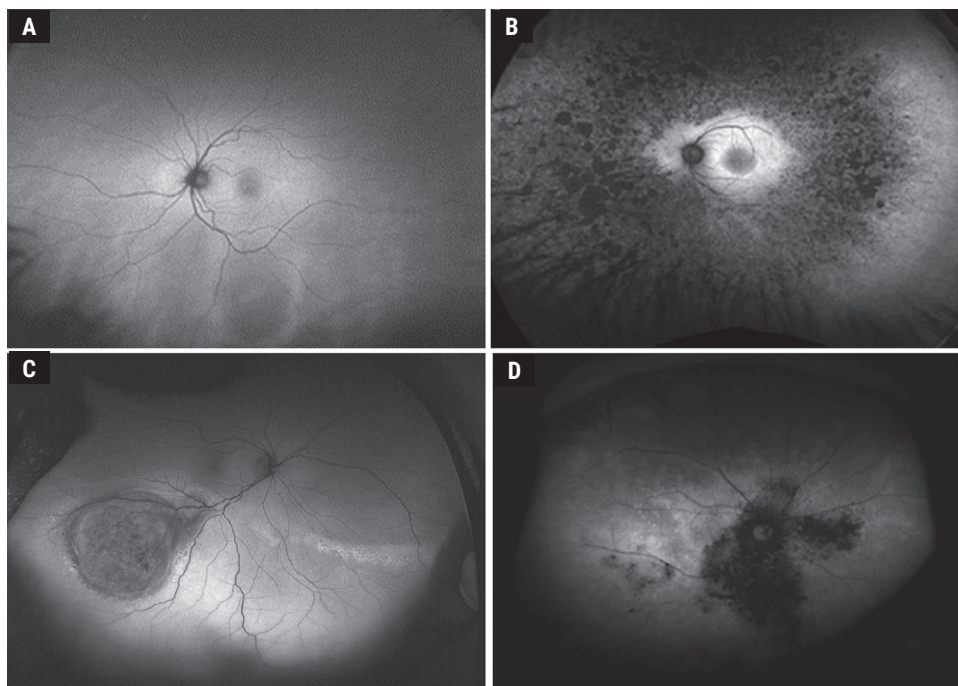


lifetime of fluorescence emitted by certain fluorophores within the eye, allowing for detection of subtle changes in metabolic as well as cellular activity.<sup>27</sup>

In FLIO, a short burst of light is used to excite certain molecules in the eye and then the system measures the time taken for the decay of the fluorescence from those molecules. AF lifetimes are excited at 473 nm and the device detects fluorescence decay in two separate wavelength channels. The long spectral channel (LSC), or red emission fluorescence (560 to 790 nm), records information from lipofuscin, while the short spectral channel (SSC)/green emission fluorescence (498 to 560 nm) records information from other fluorophores, including nicotinamide adenine dinucleotide (NAD), flavin adenine dinucleotide (FAD) and retinal carotenoids.<sup>27,28</sup> Lens fluorescence impedes SSC, while LSC

is relatively unaffected. It typically images an area of 30 degrees (256 x 256 pixels or 9 x 9 mm). A signal threshold of ~1,000 photons per pixel is essential for a good quality FLIO imaging, and it takes a total of two minutes per eye. FLIO lifetimes (FLT) are intensity independent, and FLT can be both prolonged or shortened in areas of low or high FAF intensity. An extensive literature review found that FLIO was particularly useful for four retinal conditions so far: AMD; Stargardt's disease; hydroxychloroquine toxicity; and macular telangiectasia type 2.<sup>27</sup>

A ring-shaped pattern (1.5 to 3 mm from the fovea) of prolonged FLT can be observed consistent with changes of AMD, even before the hallmark signs of drusen appear, helping to distinguish between ambiguous cases of AMD and other retinal diseases. Stargardt's disease typically lacks prolonged FLT and absence of ring shaped pattern of FLT differentiates it from AMD.<sup>29</sup> The flecks in Stargardt's disease can be detected a year prior



**Figure 4. Widefield autofluorescence with Optos system. Normal fundus (A) (adapted from Ly et al<sup>13</sup>). Retinitis pigmentosa (B) (adapted from Cicinelli et al<sup>51</sup>). Choroidal melanoma (C) (adapted from Callaway et al<sup>41</sup>). Birdshot chorioretinopathy (D) (adapted from Le Piffer et al<sup>40</sup>). Copyright license for Fig. 4, A, B and C: <http://creativecommons.org/licenses/by-nc/4.0/>. Images have not been modified from original publication.**

to being noticed on other imaging modalities. This early detection can not only help in prognosis but also aid in clinical trials.

In cases of MacTel2, a temporal crescent or ring-shaped pattern of prolonged FLT is typically noted in an area called the MacTel2 zone (oval area 9 degrees vertical and 5 degrees horizontal, centered on the fovea).<sup>30</sup>

FLIO has shown to detect hydroxychloroquine toxicity at an early stage, prior to structural changes. A typical pattern of prolonged FLT, more pronounced on the SSC channel, can aid in early and easier detection of toxicity than multifocal ERGs. However, a complex fitting process and image analysis are a challenge at this stage for its use in clinical settings. This modality holds much promise in its application in a variety of retinal conditions in the future.

### Quantitative Autofluorescence (qAF)

Conventional AF images record

spatial distribution of the AF signal with designated pixel grayscale values between 0 and 255. A qualitative description of signal modulation has helped in the diagnosis and monitoring in various retinal disorders. However, with advances in technology, additional information could be acquired through a quantitative approach. The qAF approach measures the intensity of SW-AF along with spatial information, which allows for the distinction between disease-related changes from the normal age-related increase in retinal/RPE lipofuscin.<sup>12</sup> By enabling comparison of AF intensities between individuals, and by using internal reference for long term follow-up, qAF helps address the shortcomings of conventional AF.<sup>31</sup>

Confocal SLO with a 30 x 30-degree field, 488 nm excitation and an emission range of 500 to 680 nm are used in a standardized approach for measuring qAF. A formula published by Dr. Delori's group<sup>12</sup> is used to cal-

culate qAF values. Selected images are aligned, averaged and saved in a non-normalized format. Different patterns can be used for the comparison of different retinal zones with different degrees of precision (*Figure 3A*). Trained and skilled operators as well as good quality images are essential for obtaining reliable qAF. Quantitative AF increases with increasing eccentricity 10 to 15 degrees from the fovea, with maximal values noted supero-temporally. qAF also differs among healthy individuals and is difficult to compare from one patient to another.<sup>12,31,33</sup> It's higher in females and whites; and lower in blacks and Asians likely due to increased melanin pigmentation in the RPE and the choroid. A non-linear rise in AF is observed between the ages 20 and 70. Repeatability in healthy eyes between two sessions was observed to differ by more than 6 to 11 percent on 5 percent of the occasions. Similar repeatability was observed in recessive Stargardt's (10 percent) and Best vitelliform macular dystrophy (7 percent).<sup>34</sup> Early and intermediate AMD patients had lower qAF values compared to healthy individuals.<sup>35</sup> These qAF values in AMD patients were reliable and repeatable not just on the same day, but on follow-up visits at three and six months as well.

The widespread use of qAF is currently hindered because it requires a trained operator, installation of an internal fluorescent reference as well as appropriate software. Despite these limitations, qAF has enhanced the understanding of lipofuscin-related retinal disorders. A group led by Columbia University researcher Janet Sparrow, PhD,<sup>11</sup> highlighted qAF's utility in genotype-phenotype correlations as well as in guiding clinical diagnosis and genetic testing. It has the potential to serve as a biomarker for disease risk and progression (such as during chloroquine maculopathy,<sup>32</sup> [*Figure 3B*]). They also believe that qAF can reflect visual cycle activity in various retinal diseases. If researchers and manufacturers can make this

a technically less challenging process that's easier to integrate into routine clinical practice, it may be able to enhance patient care to a great degree.

### Widefield Autofluorescence

Widefield imaging is defined by a field of view greater than 50 degrees, and "ultra-widefield" is greater than 100 degrees.<sup>36</sup> A field of view up to 267 degrees can be obtained thanks to montaging of different photographs. Clarus 500 (Zeiss) allows a field of view of 200 degrees by combining two 133-degree images, with blue and NIR-AF. Mirante (Nidek) has a field of view of 163 degrees and can perform multimodal imaging. Contact lenses can allow larger fields of view on a single image, but require the patient's cooperation. The Heidelberg Spectralis imaging system uses the confocal scanning laser ophthalmoscope to obtain a 150-degree field of view with a contact lens attachment, allowing blue and NIR-AF. The Optomap ultra-widefield system (blue and NIR-AF) can obtain non-contact images of 82 percent of the retinal surface or up to a 200-degree field of view, but with spatial distortion. This system uses green AF (532 nm laser for excitation and 570 to 780 nm for the emission filter<sup>37</sup> [*Figures 3 and 4*]), making it difficult to compare with other devices, and unable to distinguish between lipofuscin-like fluorophores (blue AF) or melanin-like fluorophores (NIR-AF). It combines cSLO with an ellipsoid mirror to allow ultra-widefield imaging. The latter has two focal points, one close to the mirror and the second near the pupillary plane. Imaging through undilated pupils, short acquisition time (250 ms), and relatively better penetration through media opacity are additional advantages of the imaging system.<sup>38,39</sup>

With better imaging modalities, we're now able to unearth many peripheral retinal manifestations of predominantly posterior pole diseases. For instance, peripheral AF abnormalities were noted in 63 to 69 percent of AMD cases. Central serous

chorioretinopathy and Vogt Koyanagi Harada syndrome also had peripheral AF changes in 57 percent and 70 percent, respectively.<sup>38</sup> Other uveitides<sup>40</sup> (*Figure 4B*), choroidal tumors<sup>41</sup> (*Figure 4C*), retinal detachment and retinoschisis<sup>42</sup> have shown peripheral AF changes also. There are limitations to evaluating widefield AF, since AF peripheral abnormalities aren't always disease-specific. For example, both healthy and AMD patients had peripheral AF abnormalities,<sup>43</sup> and AF often can't distinguish between peripheral RD or retinoschisis.<sup>44</sup> However, widefield systems are beneficial for specific peripheral diseases such as inherited retinal diseases (*Figure 4D*). Standardized grading systems and genotype-phenotype correlations in different RP genotypes were formulated using ultra-widefield FAF systems.<sup>45-47</sup> Similarly, atrophy expansion rates and age-dependent changes in the total lesion size were demonstrated using UWF-AF in patients with ABCA4 mutations.<sup>48-50</sup> Future studies with this tool can highlight the clinical relevance of these peripheral changes and may thereby alter management guidelines.

In conclusion, fundus autofluorescence imaging has come a long way in recent years and continues to prove its worth as an invaluable tool for clinicians. Its expanding role in various retinal diseases, along with the emergence of newer imaging modalities such as FLIO and qAF, only serve to further highlight its potential. With continued advancements in technology and efforts to make these techniques more user-friendly, these modalities can have a wider use in clinical practice. Widefield AF has provided insights into the peripheral changes of diseases which were previously considered to have macular manifestations only. We believe that this imaging modality will continue to provide critical insights into the pathogenesis, diagnosis and management of retinal diseases, and should remain an essential adjunct tool in the armamentarium of clinicians. ◀



1. Croce AC, Bottiroli G. Autofluorescence spectroscopy and imaging: A tool for biomedical research and diagnosis. *Eur J Histochem* 2014;58:4:2461.
2. Kellner U, Kellner S, Weintz S. Fundus autofluorescence (488 nm) and near-infrared autofluorescence (787 NM) visualize different retinal pigment epithelium alterations in patients with age-related macular degeneration. *Retina* 2010;30:1:6–15.
3. Schmitz-Valckenberg S, Pfau M, Fleckenstein M, Staurenghi G, Sparrow JR, Bindewald-Wittich A, Spaide RF, Wolf S, Sadda SR, Holz FG. Fundus autofluorescence imaging. *Prog Retin Eye Res* 2021;81:100893.
4. Gabai A, Veritti D, Lanzetta P. Fundus autofluorescence applications in retinal imaging. *Indian J Ophthalmol* 2015;63:5:406–415.
5. Delori FC, Dorey CK, Staurenghi G, Arend O, Goger DG, Weiter JJ. In vivo fluorescence of the ocular fundus exhibits its retinal pigment epithelium lipofuscin characteristics. *Invest Ophthalmol Vis Sci* 1995;36:3:718–729.
6. Spaide R. Autofluorescence from the outer retina and subretinal space: Hypothesis and review. *Retina* 2008;28:1:5–35.
7. Fischer J, Otto T, Delori F, Pace L, Staurenghi G. Scanning laser ophthalmoscopy (SLO). In: Bille JF, ed. *High Resolution Imaging in Microscopy and Ophthalmology: New Frontiers in Biomedical Optics*. Chicago: Springer Cham, 2019.
8. Meleppat RK, Ronning KE, Karlen SJ, Kothandath KK, Burns ME, Pugh EN Jr, Zawadzki RJ. In situ morphologic and spectral characterization of retinal pigment epithelium organelles in mice using multicolor confocal fluorescence imaging. *Investigative Ophthalmology & Visual Science* 2020;61:1:13.
9. Tsang SH, Sharma T. Fundus autofluorescence. *Adv Exp Med Biol* 2018 1085;15–16.
10. Sparrow JR, Gregory-Roberts E, Yamamoto K, Blonska A, Ghosh SK, Ueda K, Zhou J. The bisretinoids of retinal pigment epithelium. *Prog Retin Eye Res* 2012;31:2:121–135.
11. Sparrow JR, Duncker T, Schuerch K, Paavo M, de Carvalho JRL. Lessons learned from quantitative fundus autofluorescence. *Prog Retin Eye Res* 2020;74:100774.
12. Delori F, Greenberg JP, Woods RL, Fischer J, Duncker T, Sparrow J, Smith RT. Quantitative measurements of autofluorescence with the scanning laser ophthalmoscope. *Invest Ophthalmol Vis Sci* 2011;52:13:9379–9390.
13. Ly A, Nivison-Smith L, Assaad N, Kalloniatis M. Fundus autofluorescence in age-related macular degeneration. *Optom Vis Sci* 2017;94:2:246–259.
14. Jeffrey R, Chen F. Stargardt Disease: Multimodal imaging: A review. *Clinical & experimental ophthalmology* 2021;49:5.
15. Sarna T, Burke JM, Korytowski W, Rózanowska M, Skumatz CMB, Zareba A, Zareba M. Loss of melanin from human RPE with aging: Possible role of melanin photooxidation. *Exp Eye Res* 2003;76:1:89–98.
16. Lapierre-Landry M, Carroll J, Skala MC. Imaging retinal melanin: A review of current technologies. *J Biol Eng* 2018;12:29.
17. Boulton M, Docchio F, Dayhaw-Barker P, Ramponi R, Cubeddu R. Age-related changes in the morphology, absorption and fluorescence of melanosomes and lipofuscin granules of the retinal pigment epithelium. *Vision Res* 1990;30:9:1291–1303.
18. Taubitz T, Fang Y, Biesemeier A, Julien-Schraermeyer S, Schraermeyer U. Age, lipofuscin and melanin oxidation affect fundus near-infrared autofluorescence. *EBioMedicine* 2019;48:592–604.
19. Bonilha VL, Bell BA, Hu J, Milliner C, Pauer GJ, Hagstrom SA, Radu RA, Hollyfield JG. Geographic atrophy: Confocal scanning laser ophthalmoscopy, histology, and inflammation in the region of expanding lesions. *Invest Ophthalmol Vis Sci* 2020;61:8:15.
20. Paques M, Norberg N, Chaumette C, Sennlaub F, Rossi E, Borella Y, Grieve K. Long term time-lapse imaging of geographic atrophy: A pilot study. *Frontiers in Medicine* 2022;9.
21. Grieve K, Gofas-Salas E, Ferguson RD, Sahel JA, Paques M, Rossi EA. In vivo near-infrared autofluorescence imaging of retinal pigment epithelial cells with 757 nm excitation. *Biomed Opt Express* 2018;9:12:5946–5961.
22. Vienola KV, Zhang M, Snyder VC, Sahel JA, Dansingani KK, Rossi EA. Microstructure of the retinal pigment epithelium near-infrared autofluorescence in healthy young eyes and in patients with AMD. *Sci Rep* 2020;10:1:9561.
23. Rossi EA, Rangel-Fonseca P, Parkins K, Fischer W, Latchney LR, Folwell MA, Williams DR, Dubra A, Chung M M. In vivo imaging of retinal pigment epithelium cells in age related macular degeneration. *Biomed Opt Express* 2013;4:11:2527–2539.
24. Pilotto E, Vujosevic S, Melis R, Convento E, Sportiello P, Alemany-Rubio E, Segalina S, Midea E. Short wavelength fundus autofluorescence versus near-infrared fundus autofluorescence, with microperimetric correspondence, in patients with geographic atrophy due to age-related macular degeneration. *Br J Ophthalmol* 2011;95:8:1140–1144.
25. Heiferman MJ, Fawzi AA. Discordance between blue-light autofluorescence and near-infrared autofluorescence in age-related macular degeneration. *Retina* 2016;36 (Suppl 1):S137–S146.
26. Forte R, Querques G, Querques L, Massamba N, Le Tien V, Souied EH. Multimodal imaging of dry age-related macular degeneration. *Acta Ophthalmol* 2012;90:4:e281–287.
27. Sauer L, Vitale AS, Modersitzki NK, Bernstein PS. Fluorescence lifetime imaging ophthalmoscopy: Autofluorescence imaging and beyond. *Eye (Lond)* 2021;35:1:93–109.
28. Dysli C, Wolf S, Berezin MY, Sauer L, Hammer M, Zinkernagel MS. Fluorescence lifetime imaging ophthalmoscopy. *Prog Retin Eye Res* 2017;60:120–143.
29. Sauer L, Gensure RH, Andersen KM, Kreilkamp L, Hageman GS, Hammer M, Bernstein PS. Patterns of fundus autofluorescence lifetimes in eyes of individuals with nonexudative age-related macular degeneration. *Invest Ophthalmol Vis Sci* 2018;59:4:AMD65–AMD77.
30. Sauer L, Gensure RH, Hammer M, Bernstein PS. Fluorescence lifetime imaging ophthalmoscopy: A novel way to assess macular telangiectasia type 2. *Ophthalmol Retina* 2018;2:6:587–598.
31. Kleefeldt N, Bermond K, Tarau IS, Hillenkamp J, Berlin A, Sloan KR, Ach T. Quantitative fundus autofluorescence: Advanced analysis tools. *Translational Vision Science & Technology* 2020;9:8:2.
32. Reichel C, Berlin A, Radun V, Tarau IS, Hillenkamp J, Kleefeldt N, Sloan KR, Ach T. Quantitative fundus autofluorescence in systemic chloroquine/hydroxychloroquine therapy. *Transl Vis Sci Technol* 2020;9:9:42.
33. Greenberg JP, Duncker T, Woods RL, Smith RT, Sparrow JR, Delori FC. Quantitative fundus autofluorescence in healthy eyes. *Investigative Ophthalmology & Visual Science* 2013;54:8:5684–5693.
34. Reiter GS, Told R, Baratsits M, Hecht A, Schlanitz FG, Sacu S, Schmidt-Erfurth U. Repeatability and reliability of quantitative fundus autofluorescence imaging in patients with early and intermediate age-related macular degeneration. *Acta Ophthalmol* 2019;97:4:e526–e532.
35. Gliem M, Müller PL, Finger RP, McGuinness MB, Holz FG, Charbel-Issa P. Quantitative fundus autofluorescence in early and intermediate age-related macular degeneration. *JAMA Ophthalmol* 2016;134:7:817–824.
36. Kumar V, Surve A, Kumawat D, Takkar B, Azad S, Chawla R, Shroff D, Arora A, Singh R, Venkatesh P. Ultra-wide field retinal imaging: A wider clinical perspective. *Indian J Ophthalmol* 2021;69:4:824–835.
37. Oishi A, Oishi M, Ogino K, Morooka S, Yoshimura N. Wide-field fundus autofluorescence for retinitis pigmentosa and cone/cone-rod dystrophy. *Adv Exp Med Biol* 2016;854:307–313.
38. Xu A, Chen C. Clinical application of ultra-widefield fundus autofluorescence. *Int Ophthalmol* 2021;41:2:727–741.
39. Bhambra N, Francisconi CLM, Marafon SB, Figueiredo NA, Juncal VR, Brosh K, Hillier RJ, Muni RH. A novel method of quantifying retinal displacement using ultra-widefield fundus autofluorescence imaging. *Am J Ophthalmol* 2022;244:1–10.
40. Piffer ALL, Boissonnot M, Gobert F, Zenger A, Wolf S, Wolf U, Korobelnik JF, Rougier MB. Relevance of wide-field autofluorescence imaging in birdshot retinochoroidopathy: Descriptive analysis of 76 eyes. *Acta Ophthalmologica* 2014;92:6:e463–e469.
41. Callaway NF, Mruthyunjaya P. Widefield imaging of retinal and choroidal tumors. *Int J Retina Vitreous* 2019;5 (Suppl 1):49.
42. Navaratnam J, Salvanos P, Vavvas DG, Bragadóttir R. Ultra-widefield autofluorescence imaging findings in retinoschisis, rhegmatogenous retinal detachment and combined retinoschisis retinal detachment. *Acta Ophthalmol* 2021;99:2:195–200.
43. Guduru A, Fleischman D, Shin S, Zeng D, Baldwin JB, Houghton OM, Say EA. Ultra-widefield fundus autofluorescence in age-related macular degeneration. *PLoS One* 2017;12:6:e0177207.
44. Cao JL, Conti TF, Hom GL, Babiuch AS, Greenlee T, Ehlers JP, Rachitskaya A, Sharma S, Yuan A, Kaiser PK, Singh RP. Comparative assessment of widefield fundus autofluorescence patterns in retinoschisis and retinal detachment. *J Vitreoretin Dis* 2020;4:4:286–292.
45. Patal R, Banin E, Batash T, Sharon D, Levy J. Ultra-widefield fundus autofluorescence imaging in patients with autosomal recessive retinitis pigmentosa reveals a genotype-phenotype correlation. *Graefes Arch Clin Exp Ophthalmol* 2022;60:11:3471–3478.
46. Hariri AH, Gui W, Datto O'Keefe GA, Ip MS, Sadda SR, Gorin MB. Ultra-widefield fundus autofluorescence imaging of patients with retinitis pigmentosa: A standardized grading system in different genotypes. *Ophthalmol Retina* 2018;2:7:735–745.
47. Trichonas G, Traboulsi EI, Ehlers JP. Ultra-widefield fundus autofluorescence patterns in retinitis pigmentosa and other retinal dystrophies. *Ophthalmic Genet* 2017;38:1:98–100.
48. Heath Jeffery RC, Thompson JA, Lamey TM, McLaren TL, McAllister IL, Constable IJ, Mackey DA, De Roach JN, Chen FK. Classifying ABCA4 mutation severity using age-dependent ultra-widefield fundus autofluorescence-derived total lesion size. *Retina* 2021;41:12:2578–2588.
49. Heath Jeffery RC, Thompson JA, Lo J, Lamey TM, McLaren TL, McAllister IL, Mackey DA, Constable IJ, De Roach JN, Chen FK. Atrophy expansion rates in Stargardt disease using ultra-widefield fundus autofluorescence. *Ophthalmol Sci* 2021;1:1:100005.
50. Klufas MA, Tsui I, Sadda SR, Hosseini H, Schwartz SD. Ultra-widefield autofluorescence in ABCA4 STARGARDT disease. *Retina* 2018;38:2:403–415.
51. Cicinelli MV, Marchese A, Bordato A, Manitto MP, Bandello F, Battaglia Parodi M. Reviewing the role of ultra-widefield imaging in inherited retinal dystrophies. *Ophthalmol Ther* 2020;9:2:249–263.

ABOUT THE AUTHORS



**Dr. Borella** is an ophthalmology resident and PhD candidate at the Department of Ophthalmology, University of Pittsburgh School of Medicine, and the Vision Institute, 15-20 National Ophthalmology Hospital and Sorbonne University in Paris, France.

**Dr. Vaidya** practices at Dr. Vaidya Eye Hospital in Mumbai, India. Drs. Borella and Vaidya are co-first authors.

**Dr. Chhablani** is a Professor of Ophthalmology at the University of Pittsburgh School of Medicine.



EDITED BY MICHAEL COLVARD, MD  
AND STEVE CHARLES, MD

## TECHNOLOGY UPDATE

# Help for Intravitreal Injections

*Traditional intravitreal injection techniques are tried-and-true, but there are devices that can help guide the procedure.*

**ANDREW BEERS**  
ASSOCIATE EDITOR

Since the development of anti-vascular endothelial growth factor injections, they've become the standard treatment for age-related macular degeneration, macular edema, diabetic retinopathy and retinal vein occlusion. Though physicians are adept at performing the injections, there's always the risk for a possible complication. The use of intravitreal injection guides can potentially reduce subconjunctival hemorrhage while ensuring patient comfort.

"There are basically three functions that the guide should fulfill: First, to expose the injection site," says, Harvey Uy, MD, medical director of Peregrine Eye and Laser Institute at the University of Philippines. "The second function is to identify the site of the injection, which is typically around 3.5 mm from the limbus. Thirdly is to allow you to inject at a set depth so that it limits the depth of the needle incursion."

Here, we'll take a look at some of the available injection guides.

### Precivia (FCI Ophthalmics)

Precivia, originally called InVitria, is a single-use intravitreal injection guide from FCI Ophthalmics. This is a clear-plastic device placed on the patient's eye without the need for a

speculum, caliper or pressure plate. A guide tube with a fixed angle of 28 degrees and a fixed distance of 3.5 mm from the limbus allows ophthalmologists to safely inject without losing the position of the injection site. The cylindrical design has a rigid handgrip at the top for easier placement and stabilization, and the rounded base ensures that both eyelids are positioned properly for injection, the company says.

According to FCI, by gently pushing down and rotating the Precivia device, the eye becomes stabilized, which will create an anesthetic effect for the patient due to the pressure. Also, after the device has been positioned, the patient won't be able to see when the needle is coming. After the needle is removed, by rotating the device again post-injection, the conjunctiva is replaced, and the injection hole is sealed.

In a prospective review of 200 intravitreal injections, 100 using Precivia and the other 100 using traditional methods, surgeons' perceptions and patients' intraoperative visual analogue scale (VAS) pain scores were recorded. The average VAS pain score in the Precivia group was 1.38 compared to 2.58 in the traditional group, which was statistically significant. Additionally, surgeons reported that insertion using Precivia was easy in

89 cases, moderate in 10 cases, and difficult in one case. The surgeons added that the device offered excellent globe stability and a safe, reproducible entry site and angle needle insertion.<sup>1</sup>

### Rapid Access Vitreal Injection (RAVI) Guide (Katalyst Surgical)

The Rapid Access Vitreal Injection Guide is a reusable, metal intravitreal injection guide. A baseplate at the end of the handle measures 7 mm by 7 mm. Two flanges on opposite sides of the baseplate hold the ocular structure, creating an injection site with a distance of approximately 3 to 4 mm from the limbus. After setting the device onto the ocular surface, the physician can safely make an injection through the 1.5-mm diameter aperture in the center of the baseplate.

The inventors of the RAVI Guide noted that the device can replace the function of both a lid speculum and caliper. In a prospective study to evaluate their device, the inventors along with a team of physicians performed 54 intravitreal injections using either the RAVI Guide or a lid speculum.

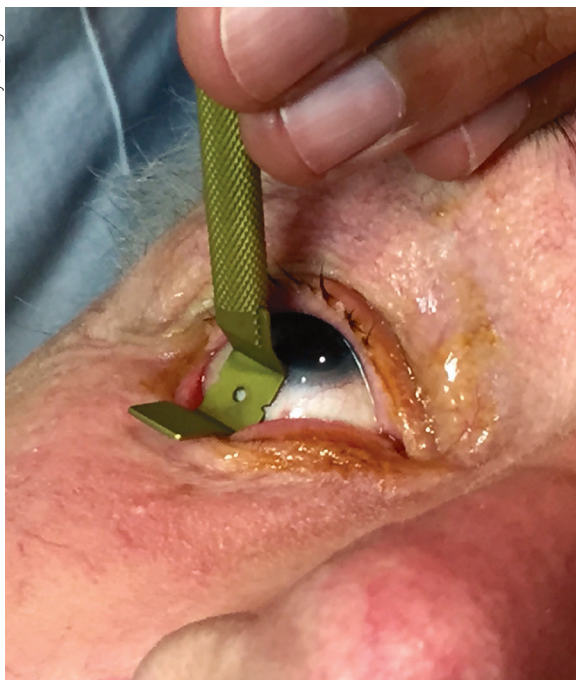FCI Ophthalmics



**A faint line down the side of the Precivia device to the base of the guide tube can help physicians better position the device properly on the limbus.**

This article has no commercial sponsorship.

**Dr. Colvard** is a surgeon at the Colvard-Kandavel Eye Center in Los Angeles and a clinical professor of ophthalmology at the Keck School of Medicine of the University of Southern California. **Dr. Charles** is the founder of the Charles Retina Institute in Germantown, Tennessee.



Developers of the RAVI Guide noted that as the needle is withdrawn, the base plate may be slid over the conjunctiva to close the injection site if needed.

They wanted to study patient acceptance of the device, complication rates and operative goals.

During the study, researchers had patients use the Wong-Baker FACES pain scale to rate their intraoperative treatments. The scale allows patients to choose from zero (no pain or discomfort) to 10 (severe levels of pain and discomfort), along with illustrated faces depicting emotions ranging from happy to sad. This simple rating scale helped researchers understand patient acceptance of the RAVI Guide compared to the speculum. In the RAVI Guide group, 72 percent (n=32) of patients had a pain-free experience compared to 64 percent (n=22) of patients in the speculum group. A pain score of two or higher was reported in 16 percent of RAVI Guide patients and 32 percent of speculum patients.<sup>2</sup>

Researchers reported that operative goals to safely inject anti-VEGFs were achieved in all patients, and there weren't any significant operative complications observed for either device.<sup>2</sup>

### Doi-Uematsu Intravitreal Injection Guide (Duckworth & Kent)

The Doi-Uematsu Intravitreal Injection Guide is a reusable guide suitable for right-handed surgeons, as the guide's handle was designed to be held in the left hand leaving the right hand free for needle insertion. At the base of the handle is a 12-mm diameter ring with a "snow-tire" pattern for a firmer grip on the ocular surface and increased stabilization. According to D&K, there's a 5.5-mm break in the ring that enables an anterior chamber tap, if required, in order to avoid intraocular pressure spikes. The

guide hole is 0.5 mm in diameter, which is suitable for 27-gauge or smaller needles. This device is autoclavable.

Researchers who designed the device conducted a retrospective review to compare the safety and efficacy of the guide. The study included 256 patients who underwent 992 intravitreal anti-VEGF injections over a two-year period. Of the total injections, 907 were done using the intravitreal guide, while 60 were done without it. A remaining 25 injections weren't determined ahead of the study. Overall, local complications in the guide group consisted of one case of uveitis, one case of retinal tear and one case of amaurosis fugax. There were no local complications in the non-guide group. Researchers reported no major complications during the study. The researchers say that though all complications occurred in the Doi-Uematsu Guide group,

the difference between groups wasn't statistically significant.<sup>3</sup>

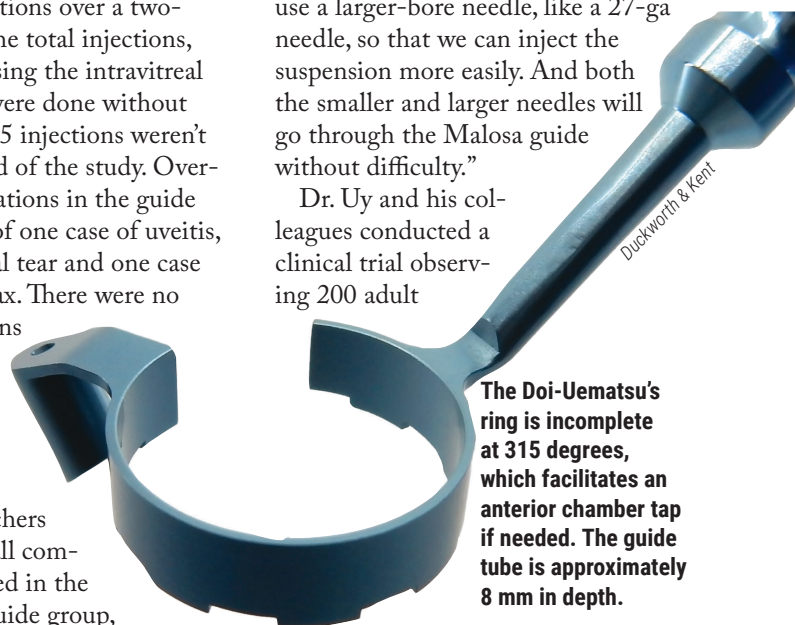
### Malosa Intravitreal Injection Guide (Beaver-Visitec International)

The Malosa Intravitreal Injection Guide, designed by UAE surgeon Salman Waqar, is a single-use injection guide. According to Beaver-Visitec International, the guide is designed with a polycarbonate lash guard and a stainless-steel guide tube. The handle is shaped like a wishbone and positioned at a 45-degree angle to increase stabilization and ensure that it doesn't become a disturbance during treatment.

"Aside from helping you inject anti-VEGF drugs, you can use it to guide you for injecting other medications such as antibiotics, for example, and it can also be used to help someone extract vitreous material from the posterior segment," says Dr. Uy.


"Sometimes in an effort to further decrease patient discomfort, we might use a smaller needle," continues Dr. Uy. "Typically, we use a 30-ga needle, but sometimes we can transfer the drug through a 31-ga needle. That's smaller so it's more comfortable, and sometimes before injecting triamcinolone—which is not a liquid but more of a suspension—we will use a larger-bore needle, like a 27-ga needle, so that we can inject the suspension more easily. And both the smaller and larger needles will go through the Malosa guide without difficulty."

Dr. Uy and his colleagues conducted a clinical trial observing 200 adult



The Doi-Uematsu's ring is incomplete at 315 degrees, which facilitates an anterior chamber tap if needed. The guide tube is approximately 8 mm in depth.





Beaver-Visites International

**Dr. Salman Waqar, is the inventor of the Malosa Intravitreal Injection Guide. He sought to design a device for rapid, safe and precise delivery of injections without using a technique needing drapes, calipers and speculums.**

eyes undergoing intravitreal injection treatment. “We found two additional benefits when using the Malosa: One is that the patients report less pain compared to using the standard dual-blade eyelid retraction device,” says Dr. Uy. “Secondly, we saw less subconjunctival hemorrhage.”

During the study, 100 eyes were assigned injections using the Malosa Guide, and the other 100 eyes received treatment with a conventional dual-blade speculum and a surgical caliper. The study sought to com-

pare the mean procedural time and complications when using either the guide or a speculum and caliper. The mean procedural time was shorter in the guide group (9.94 ±2.87 seconds) versus the speculum group (21.85 ±7.25 seconds). Dr. Uy reported that the rate of post-injection subconjunctival hemorrhage was higher in the speculum group, for which he had no explanation. No other injection-related adverse reactions were observed in either of the patient groups.<sup>4</sup>

“Physicians’ workloads are very

heavy, especially with regard to the need to inject a lot of patients,” says Dr. Uy. “However, injections shouldn’t hinder physicians’ work of seeing patients and doing other procedures in the clinic. So, if we can find a way to minimize the time to do the injections, that’ll make our workflow more efficient.” ◀

1. Ratnarajan G, Nath R, Appaswamy S, Watson S. Intravitreal injections using a novel conjunctival mould: A comparison with a conventional technique. *British Journal of Ophthalmology* 2013;97:395-397.
2. Han DP, McKenney KC, Kim JE, Weinberg DV, Singh RSJ. Clinical evaluation of the Rapid Access Vitreal Injection (RAVI) Guide: A hand-held instrument for assisting intravitreal injections. *Invest. Ophthalmol Vis Sci* 2016;57:12:2673.
3. Watanabe K, Masafumi U, Mohamed YH, Watanabe T, Doi Y, Azusa F, Kitaoka T. Safety of intravitreal injection guide. *Journal of VitreoRetinal Diseases* 2018;2:1:26-31.
4. Uy HS, Artiaga JCM. Comparison of two different intravitreal injection techniques. *Clin Ophthalmol* 2021;15:2383-2389.

#### DISCLOSURES

Dr. Uy has no financial interests to disclose.

## ADVERTISER INDEX

*This advertiser index is published as a convenience and not as part of the advertising contract. Every care will be taken to index correctly. No allowance will be made for errors due to spelling, incorrect page number, or failure to insert.*

Alcon .....	Cover 2, 3
.....	.....(800) 451-3937
.....	..... <a href="http://www.alcon.com">www.alcon.com</a>
Allergan, Inc. ....	17
.....	..... <a href="http://www.allerganeye.com/product-information">www.allerganeye.com/product-information</a>
Bausch + Lomb .....	39
.....	.....(800) 323-0000
.....	..... <a href="http://www.lumifydrops.com">www.lumifydrops.com</a>
Bausch + Lomb .....	47
.....	.....(800) 323-0000
.....	..... <a href="http://www.bausch.com">www.bausch.com</a>
Bruder Healthcare Company .....	33
.....	.....(888) 827-8337
.....	..... <a href="mailto:eyes@bruder.com">eyes@bruder.com</a>
.....	..... <a href="http://www.bruder.com">www.bruder.com</a>
Dompe .....	13, 14
.....	..... <a href="http://www.oxervate.com/HCP">www.oxervate.com/HCP</a>
Eye Designs .....	5
.....	.....(800) 346-8890
.....	..... <a href="http://www.evedesigns.com">www.evedesigns.com</a>
Harrow .....	21, 22
.....	..... <a href="http://www.harrow.com">www.harrow.com</a>
Horizon .....	42-44
.....	..... <a href="http://www.TEDImpact.com">www.TEDImpact.com</a>

Icare USA .....	Cover Tip
.....	.....(888) 422-7313
.....	..... <a href="mailto:infoUSA@icare-world.com">infoUSA@icare-world.com</a>
.....	..... <a href="http://www.icare-world.com/USA">www.icare-world.com/USA</a>
Iveric Bio .....	50-52
.....	..... <a href="http://www.IvericBio.com">www.IvericBio.com</a>
Keeler Instruments .....	8
.....	.....(800) 523-5620
.....	..... <a href="mailto:customerservice@keelerusa.com">customerservice@keelerusa.com</a>
.....	..... <a href="http://www.keelerusa.com">www.keelerusa.com</a>
Novartis Pharmaceuticals .....	28-30
.....	..... <a href="http://www.novartis.com">www.novartis.com</a>
Oasis .....	37
.....	.....(844) 820-8940
.....	..... <a href="mailto:customerservice@oasismedical.com">customerservice@oasismedical.com</a>
.....	..... <a href="http://www.oasismedical.com">www.oasismedical.com</a>
Oculus, Inc. ....	35
.....	.....(888) 519-5375
.....	..... <a href="mailto:ads@oculususa.com">ads@oculususa.com</a>
.....	..... <a href="http://www.pentacam.com">www.pentacam.com</a>
Regeneron Pharmaceuticals, Inc. ....	Insert
.....	..... <a href="http://www.regeneron.com">www.regeneron.com</a>
Regeneron Pharmaceuticals, Inc. ....	Polybag Insert
.....	..... <a href="http://www.regeneron.com">www.regeneron.com</a>
Tarsus .....	11
.....	..... <a href="http://www.tarsusrx.com">www.tarsusrx.com</a>
Thea Pharma .....	Cover 3
.....	..... <a href="http://theapharmainc.com/preservative-free">theapharmainc.com/preservative-free</a>
Thea Pharma .....	Cover 4
.....	..... <a href="http://www.iyuzeh.com">www.iyuzeh.com</a>
Vital Tears .....	25
.....	..... <a href="http://www.vitaltears.org">www.vitaltears.org</a>



EDITED BY COLLIN ROZANSKI, MD

## WILLS EYE RESIDENT CASE REPORT

# A young woman presents with sudden-onset blurred vision and metamorphopsia in one eye.

MARA E. PENNE, MD, AND CAROL L. SHIELDS, MD  
PHILADELPHIA

### Presentation

A 29-year-old Caucasian female with sudden onset of blurred vision and metamorphopsia in her left eye presented for ophthalmic evaluation. She was 20 weeks pregnant at presentation. She denied any history of trauma. She denied any concurrent pain, headache, diplopia, flashes, floaters or photophobia. She denied any symptoms in the right eye. Systemic review of symptoms was negative. Of note, her pregnancy had been uncomplicated up to this point.

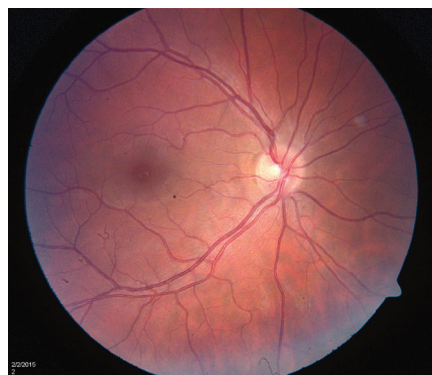### History

Past ocular history included myopia in both eyes. Past medical history disclosed celiac disease. Family history included a mother with melanoma of the skin, maternal grandmother with colon cancer, and maternal grandfather with bladder cancer. Social history was significant for rare alcohol consumption, but was otherwise unremarkable. She did not have any known drug allergies. Current medications included pre-natal vitamins.

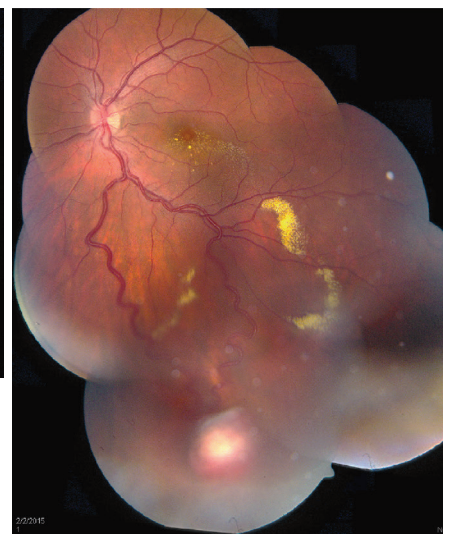### Examination

The patient's vital signs were within normal limits. Ocular examination demonstrated best-corrected visual acuity of 20/20 in the right eye and 20/25 in the left eye. Pupils were equally round and reactive in both eyes without afferent pupillary defect in either eye. Intraocular pressures were 10 mmHg in both eyes. Confrontation visual fields were full in both eyes. Extraocular motility was full bilaterally. The anterior segment examination was largely unremarkable and didn't reveal any abnormalities.

Dilated fundus examination of the right eye demonstrated a normal optic disc, macula, vessels and peripheral retina (Figure 1). The left eye demonstrated a normal optic disc, macular edema with hard exudation, as well as venous dilation and tortuosity inferiorly. Peripheral examination in the left eye revealed a 4x4 mm retinal vascular mass at 5:00 with dilated feeding and draining vessels, as well as additional exudation extending into the periphery (Figure 1).

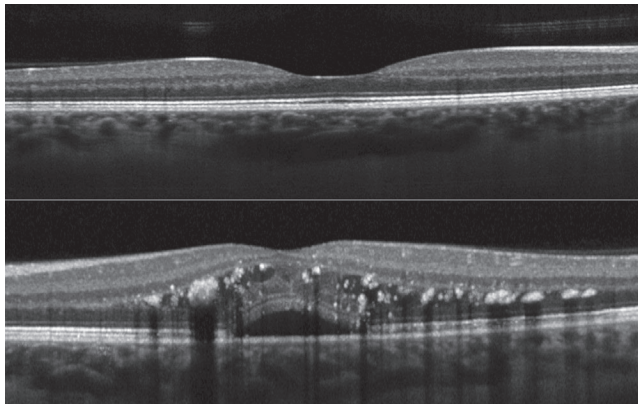


**Figure 1. The right eye's fundus (above) is normal. The left eye (right) demonstrates an inferior retinal vascular mass with large dilated feeding/draining vessels, as well as macular edema and hard exudates.**

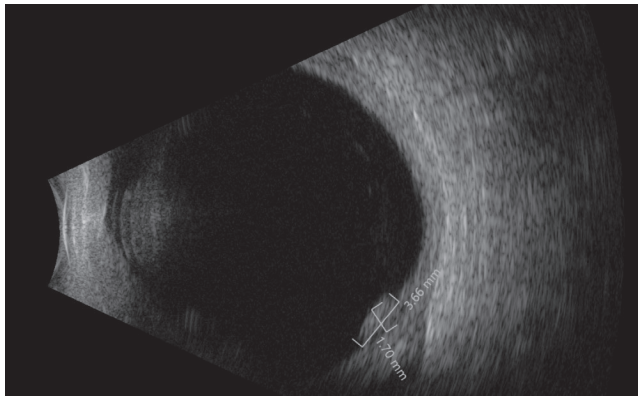


**What's your diagnosis? What work-up would you pursue? The diagnosis appears on the opposite page.**

## Work-up, Diagnosis and Treatment



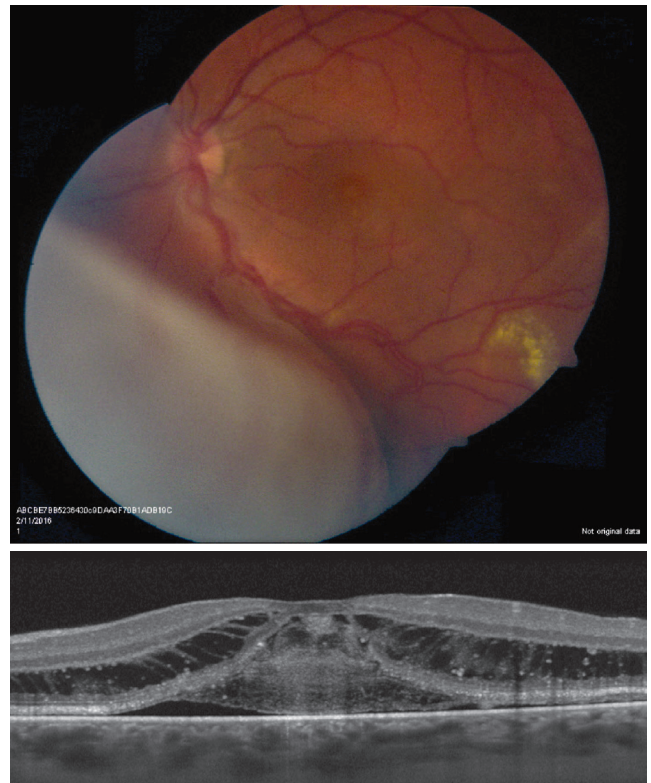
**Figure 2.** OCT through the macula and optic nerve of the right eye demonstrating normal retinal layers and contour. The left eye demonstrates macular edema in the outer nuclear layer with hard exudates in the outer plexiform layer, and subretinal fluid.



**Figure 3.** Ultrasonography of the left eye demonstrating an acoustically solid retinal mass measuring 3.7 mm in basal length with 1.7 mm thickness. The retina appears attached.

Ancillary imaging was obtained including optical coherence tomography (Figure 2) and ophthalmic ultrasonography of the left eye (Figure 3). OCT of the left eye demonstrated macular edema in the outer nuclear layer with associated hard exudation in the outer plexiform layer and shallow subretinal fluid involving the fovea. Ultrasonography revealed an echodense retinal mass with 3.7 mm basal diameter and 1.7 mm retinal thickness.

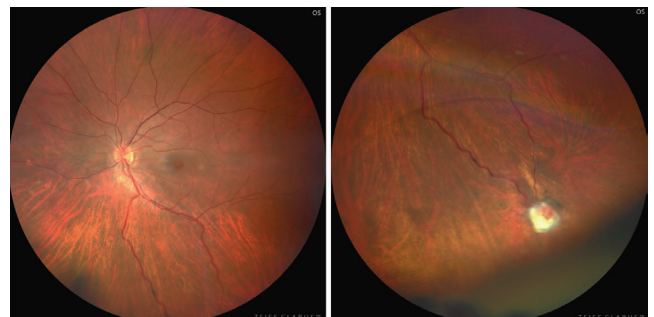
The differential diagnosis in this patient with unilateral vision loss, found to have a retinal vascular lesion associated with macular edema and hard exudation, includes retinal hemangioblastoma (RH), cavernous hemangioma, acquired vasoproliferative tumor, choroidal hemangioma and retinal racemose hemangiomas. Given the dilated and tortuous feeder vessels of the lesion, the presence of associated exudation, and the lack of other ocular conditions, a diagnosis of retinal hemangioblastoma was made. Treatment options, including verteporfin-enhanced photodynamic therapy, fluorescein-enhanced argon laser photocoagulation, transpupillary thermotherapy,



**Figure 4.** Widefield fundus photo of the left eye demonstrating an exudative retinal detachment in the inferonasal region, as well as dilated vessels and peripheral hard exudation inferiorly. OCT through the macula of the left eye demonstrates cystoid macular edema with subretinal fluid and scattered hard exudation.

cryotherapy and radiotherapy were discussed. The patient chose to defer treatment until the post-partum period. Genetic testing for von Hippel-Lindau (VHL) syndrome was performed and was negative.

At the seven-month follow-up visit, now three months post-partum without any intervention, the patient reported a subjective improvement in her vision. Visual acuity OS improved to 20/20 from 20/25 on initial presentation. Dilated



**Figure 5.** Fundus photographs of the left eye demonstrate normal macula (left) and treated, fibrotic retinal hemangioblastoma in the inferior periphery (right). The feeder vessels demonstrate reduced dilation.



fundus examination revealed a vascular lesion, stable in size, with persistently dilated vessels. OCT demonstrated spontaneous resolution of the macular edema and exudation. The patient continued to defer treatment until cessation of breastfeeding one year from presentation (seven months post-partum). At this time, visual acuity was 20/20 and OCT showed a flat macula without exudation. The RH tumor was unchanged in size. Transpupillary PDT was performed. On postoperative day #1 the patient presented with a visual acuity of 20/400 OS and was

found to have severe cystoid macular edema with an exudative retinal detachment (*Figure 4*). She was treated twice with intravitreal ranibizumab with resulting resolution of the macular edema and retinal detachment. At the most recent follow-up visit, seven years from initial presentation, visual acuity in the left eye was 20/30. Examination and imaging demonstrated a regressed fibrotic retinal lesion measuring 3 mm x 3 mm with nondilated feeder vessels and without the presence of macular edema or exudation (*Figure 5*).

## Discussion

Retinal hemangioblastoma is a benign, slow-growing retinal vascular tumor that appears clinically as a red-orange mass.<sup>1</sup> This tumor classically presents with prominent feeder vessels extending from the optic disc and can be located in the peripapillary or peripheral retina.<sup>1</sup> This tumor can be associated with accumulation of subretinal fluid, sub- and intraretinal exudation, and vitreoretinal fibrosis, which can result in profound visual loss.<sup>1</sup> The exudation often accumulates in the macula and presents as a macular star.<sup>2</sup> Diagnosis can typically be made on dilated fundoscopic examination, though additional imaging is helpful, particularly in the cases of small tumors. In some cases, this tumor can be detected on fluorescein angiography as hyperfluorescent, before it becomes symptomatic.<sup>2</sup> Biopsy isn't required for diagnosis.

Clinical onset occurs most commonly in the first three decades of life.<sup>1,2</sup> Importantly, retinal hemangioblastoma can be associated with VHL syndrome, and a thorough workup is required for any case of suspected hemangioblastoma. VHL syndrome is an autosomal dominant disorder caused by a mutation in the VHL tumor suppressor gene, located on chromosome 3.<sup>3,4</sup> This mutation has a prevalence of 1 in 40,000 to 50,000.<sup>4</sup> Detection of these tumors by an ophthalmologist is critical, as 70 percent of individuals with VHL syndrome are diagnosed by detection of RH tumors.<sup>5</sup> This prompts a full systemic workup for other tumors, including renal cell carcinoma, which constitutes the greatest cause of mortality in these patients.<sup>2</sup>

Treatment for RH is varied and depends on the size and location of the tumor, as well as the VHL association. Some believe that this tumor can be safely observed in select cases when asymptomatic without subretinal fluid.<sup>2,3,6</sup> However, most are treated and those with VHL association tend to be more aggressive.<sup>2,6</sup> Those near the macula can lead to profound vision loss, and thus also require prompt treatment. Treatment methods vary based on tumor size. Small lesions (<3 mm) can be treated with laser photocoagulation or PDT; medium lesions (3 to 6 mm) can be treated with PDT or cryotherapy; and large (>6 mm) lesions can be treated with PDT, plaque radiotherapy or internal resection by pars plana vitrectomy.<sup>6</sup> Therapy with PDT can be associated with a transient exudative response, as was noted in 24 percent of patients in a recent case series of 17 patients.<sup>7,8</sup> Anti-vascular endothelial growth factor (VEGF)

therapy is useful in reducing macular edema and subretinal fluid, but has no demonstrated effect in reducing tumor size.<sup>3,8</sup>

This case was unique in that our patient initially presented with an RH tumor during pregnancy; similar cases aren't well-documented in the literature. She demonstrated a spontaneous resolution of secondary macular edema post-partum, as has been seen in cases of macular edema associated with other underlying conditions such as diabetic retinopathy and circumscribed choroidal hemangioma.<sup>9</sup> The tumor remained stable in size; however, treatment was deemed necessary due to the threat of recurrence of subretinal fluid.

In conclusion, retinal hemangioblastoma can present with decreased visual acuity, commonly secondary to macular edema with exudation, as was the case with our patient. For those tumors diagnosed in pregnancy, spontaneous resolution of subretinal fluid may occur in the postpartum period. Treatment modalities vary based on size, location and association with VHL syndrome. Management with PDT, which is used to treat tumors of all sizes, can cause a transient exudative response. Anti-VEGF therapy can be useful in treating associated macular edema and subretinal fluid. ◀


- Singh A, Turell M. Vascular tumors of the retina and choroid: Diagnosis and treatment. *Middle East African Journal of Ophthalmology* 2010;17:3:191. doi:<https://doi.org/10.4103/0974-9233.65486>.
- Singh AD, Shields CL, Shields JA. von Hippel-Lindau disease. *Surv Ophthalmol* 2001;46:117-42.
- Wiley HE, Krivosic V, Gaudric A, et al. Management of retinal hemangioblastoma in von Hippel-Lindau disease. *Retina* 2019;39;12:2254-2263. doi:<https://doi.org/10.1097/iae.0000000000002572>.
- Maher ER, Neumann HP, Richard S. von Hippel-Lindau disease: A clinical and scientific review. *European Journal of Human Genetics* 2011;19:6:617-623. doi:<https://doi.org/10.1038/ejhg.2010.175>.
- Şahin Atik S, Solmaz AE, Öztaş Z, et al. Von Hippel-Lindau Disease: The importance of retinal hemangioblastomas in diagnosis. *Türk Oftalmoloji Dergisi* 2017;47:3:180-183. doi:<https://doi.org/10.4274/tjo.90912>.
- Singh AD, Nouri M, Shields CL, Shields JA, Perez N. Treatment of retinal capillary hemangioma. *Ophthalmology* 2002;109:10:1799-1806. doi:[https://doi.org/10.1016/s0161-6420\(02\)01177-6](https://doi.org/10.1016/s0161-6420(02)01177-6).
- Di Nicola M, Williams BK, Hua J, et al. Photodynamic therapy for retinal hemangioblastoma: Treatment outcomes of 17 consecutive patients. *Ophthalmology Retina* 2022;6:1:80-88. doi:<https://doi.org/10.1016/j.oret.2021.04.007>.
- Borgia F, Giuffrida R, Caradonna E, Vaccaro M, Guarneri F, Cannavò SP. Early and late onset side effects of photodynamic therapy. *Biomedicines* 2018;6:1. doi:<https://doi.org/10.3390/biomedicines6010012>.
- Muslubas IS, Arf S, Hocaoglu M, Ozdemir H, Karacoru M. Spontaneous regression of serous retinal detachment associated with circumscribed choroidal hemangioma after childbirth. Published online January 1, 2017. doi:<https://doi.org/10.1097/icb.0000000000000274>.

# ALL THOSE IN FAVOR OF PRESERVATIVE FREEDOM, **SAY EYE**

As eye care professionals, eye drops play a central role in the care we provide for our patients. Many prescription and OTC eye drops continue to include preservatives—compounds that are proven deleterious to the ocular surface.

Preservative Freedom is a commitment to preserve patient eye health.

**We're pledging to break through our indifference and old habits,  
and to do so while keeping our patients' eye care as the highest priority.**



**PRESERVATIVE  
FREEDOM**

Learn more, and join the movement at  
[PreservativeFreedom.com](https://www.PreservativeFreedom.com)

 **Théa**  
let's open our eyes

**THE FUTURE IS  
CLOSING IN**

**iyuzeh<sup>TM</sup>**

(latanoprost ophthalmic solution) 0.005%

Prepare now at [iyuzeh.com](https://iyuzeh.com)

