

Wills Eye Resident Series: A patient presents with eye pain, decreased vision and photophobia, p. 68

# REVIEW<sup>®</sup> of OPTHALMOLOGY

June 2023 • [reviewofophthalmology.com](http://reviewofophthalmology.com)

Clinical advice you can trust

## TECHNOLOGY UPDATE

Artificial Intelligence and Dry Eye  
PAGE 24

## GLAUCOMA MANAGEMENT

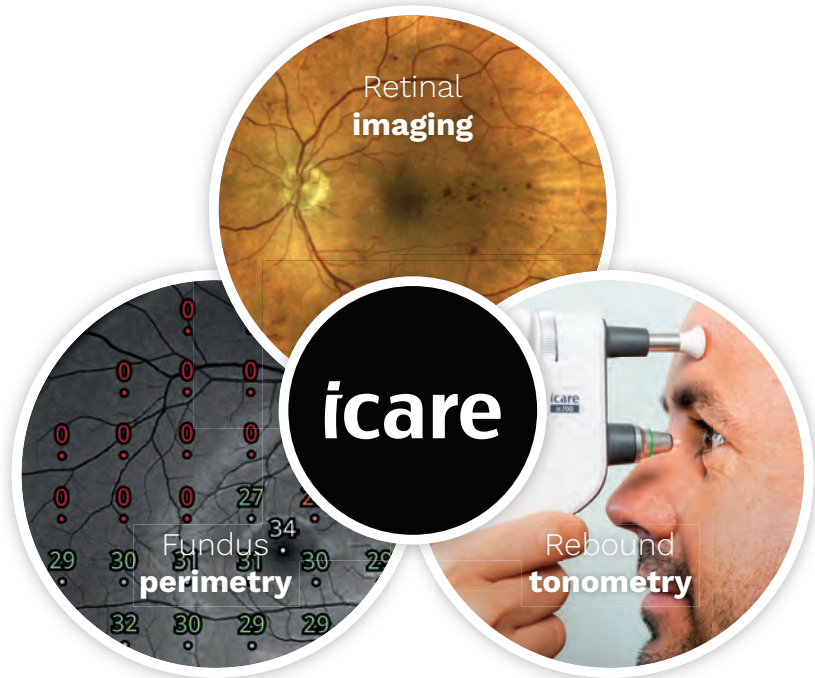
Conjunctival Dehiscence Repair  
PAGE 55

## RETINAL INSIDER

Pearls for Managing Posterior IOFBs  
PAGE 59

You know us  
for tonometry.

Get to know  
iCare for  
imaging and  
perimetry.



Discover the next level of eye care  
with our full line of devices.

Scan or visit [www.icare-world.com/USA](http://www.icare-world.com/USA)



iCare HOME2

## 24-hour at home tonometry



Glaucoma management based on real-world data capturing spikes and fluctuations outside of the office



Comprehensive reports supporting proactive patient treatment plans



IOP measurements in supine, reclined and seated positions



Discover the next level of eye care with our full line of devices.

Scan or visit [www.icare-world.com/USA](http://www.icare-world.com/USA)

**icare**  
For better perception

Wills Eye Resident Series: A patient presents with eye pain, decreased vision and photophobia, p. 68

# REVIEW<sup>®</sup> *of* OPHTHALMOLOGY

June 2023 • reviewofophthalmology.com

Clinical advice you can trust

## TECHNOLOGY UPDATE

Artificial Intelligence and Dry Eye

PAGE 24

## GLAUCOMA MANAGEMENT

Conjunctival Dehiscence Repair

PAGE 55

## RETINAL INSIDER

Pearls for Managing Posterior IOFBs

PAGE 59



## Completing The Mosaic of Glaucoma Care

*Current treatment protocols  
and possible complementary  
therapies. P. 30*

### Also inside:

- Is SLT Ready for a Leading Role? P. 39
- Advancing IOL Technology P. 45
- A Look at the Dry-eye Treatment Pipeline P. 49

When Selecting a Prescription  
Dry Eye Treatment

**DON'T**

**MAKE  
HER  
WAIT.**



Not an actual patient.

### **Indication**

Xiidra® (lifitegrast ophthalmic solution) 5% is indicated for the treatment of signs and symptoms of dry eye disease (DED).

### **Important Safety Information**

- Xiidra is contraindicated in patients with known hypersensitivity to lifitegrast or to any of the other ingredients.
- In clinical trials, the most common adverse reactions reported in 5-25% of patients were instillation site irritation, dysgeusia and reduced visual acuity. Other adverse reactions reported in 1% to 5% of the patients were blurred vision, conjunctival hyperemia, eye irritation, headache, increased lacrimation, eye discharge, eye discomfort, eye pruritus and sinusitis.
- To avoid the potential for eye injury or contamination of the solution, patients should not touch the tip of the single-use container to their eye or to any surface.



**Novartis Pharmaceuticals Corporation**  
East Hanover, New Jersey 07936-1080



**CHOOSE XIIDRA**  
Because lasting symptom  
relief can start as early as  
**2 WEEKS<sup>1\*</sup>**



Access to Xiidra is  
better than ever<sup>2</sup>

\*Xiidra reduced symptoms of eye dryness at 2 weeks (based on Eye Dryness Score compared to vehicle) in 2 out of 4 studies, with improvements observed at 6 and 12 weeks in all 4 studies.<sup>1†</sup>

### Important Safety Information (cont)

- Contact lenses should be removed prior to the administration of Xiidra and may be reinserted 15 minutes following administration.
- Safety and efficacy in pediatric patients below the age of 17 years have not been established.

**Please see Brief Summary of Important Product Information on adjacent page.**

#### <sup>†</sup>Pivotal trial data

The safety and efficacy of Xiidra were assessed in four 12-week, randomized, multicenter, double-masked, vehicle-controlled studies (N=2133). Patients were dosed twice daily. **Use of artificial tears was not allowed during the studies.** The study end points included assessment of signs (based on Inferior fluorescein Corneal Staining Score [ICSS] on a scale of 0-4) and symptoms (based on patient-reported Eye Dryness Score [EDS] on a visual analogue scale of 0-100).<sup>1</sup>

Effects on symptoms of dry eye disease: A larger reduction in EDS favoring Xiidra was observed in all studies at day 42 and day 84. Xiidra reduced symptoms of eye dryness at 2 weeks (based on EDS) compared to vehicle in 2 out of 4 clinical trials.<sup>1</sup>

Effects on signs of dry eye disease: At day 84, a larger reduction in ICSS favoring Xiidra was observed in 3 of the 4 studies.<sup>1</sup>

**References:** 1. Xiidra [package insert]. East Hanover, NJ: Novartis Pharmaceuticals Corp. 2. Data on file. DRF Fingertip Formulary<sup>®</sup> Novartis Pharmaceuticals Corp; July 2022.

**XIIDRA, the XIIDRA logo and ii are registered trademarks of Novartis AG.**

**XIIDRA® (lifitegrast ophthalmic solution), for topical ophthalmic use**

**Initial U.S. Approval: 2016**

**BRIEF SUMMARY: Please see package insert for full prescribing information.**

**1 INDICATIONS AND USAGE**

Xiidra® (lifitegrast ophthalmic solution) 5% is indicated for the treatment of the signs and symptoms of dry eye disease (DED).

**4 CONTRAINDICATIONS**

Xiidra is contraindicated in patients with known hypersensitivity to lifitegrast or to any of the other ingredients in the formulation [see *Adverse Reactions (6.2)*].

**6 ADVERSE REACTIONS**

The following serious adverse reactions are described elsewhere in the labeling:

- Hypersensitivity [see *Contraindications (4)*]

**6.1 Clinical Trials Experience**

Because clinical trials are conducted under widely varying conditions, adverse reaction rates observed in clinical trials of a drug cannot be directly compared to rates in the clinical trials of another drug and may not reflect the rates observed in practice.

In five clinical trials of DED conducted with lifitegrast ophthalmic solution, 1401 patients received at least one dose of lifitegrast (1287 of which received lifitegrast 5%). The majority of patients (84%) had less than or equal to 3 months of treatment exposure. One hundred-seventy patients were exposed to lifitegrast for approximately 12 months. The majority of the treated patients were female (77%). The most common adverse reactions reported in 5%-25% of patients were instillation-site irritation, dysgeusia, and reduced visual acuity.

Other adverse reactions reported in 1%-5% of the patients were blurred vision, conjunctival hyperemia, eye irritation, headache, increased lacrimation, eye discharge, eye discomfort, eye pruritus, and sinusitis.

**6.2 Postmarketing Experience**

The following adverse reactions have been identified during post-approval use of Xiidra. Because these reactions are reported voluntarily from a population of uncertain size, it is not always possible to reliably estimate their frequency or establish a causal relationship to drug exposure.

Rare serious cases of hypersensitivity, including anaphylactic reaction, bronchospasm, respiratory distress, pharyngeal edema, swollen tongue, urticaria, allergic conjunctivitis, dyspnea, angioedema, and allergic dermatitis have been reported. Eye swelling and rash have also been reported [see *Contraindications (4)*].

**8 USE IN SPECIFIC POPULATIONS**

**8.1 Pregnancy**

Risk Summary

There are no available data on Xiidra use in pregnant women to inform any drug-associated risks. Intravenous (IV) administration of lifitegrast to pregnant rats, from pre-mating through gestation day 17, did not produce

teratogenicity at clinically relevant systemic exposures. Intravenous administration of lifitegrast to pregnant rabbits during organogenesis produced an increased incidence of omphalocele at the lowest dose tested, 3 mg/kg/day (400-fold the human plasma exposure at the recommended human ophthalmic dose [RHOD], based on the area under the curve [AUC] level). Since human systemic exposure to lifitegrast following ocular administration of Xiidra at the RHOD is low, the applicability of animal findings to the risk of Xiidra use in humans during pregnancy is unclear [see *Clinical Pharmacology (12.3) in the full prescribing information*].

Data

Animal Data

Lifitegrast administered daily by IV injection to rats, from pre-mating through gestation day 17, caused an increase in mean pre-implantation loss and an increased incidence of several minor skeletal anomalies at 30 mg/kg/day, representing 5,400-fold the human plasma exposure at the RHOD of Xiidra, based on AUC. No teratogenicity was observed in the rat at 10 mg/kg/day (460-fold the human plasma exposure at the RHOD, based on AUC). In the rabbit, an increased incidence of omphalocele was observed at the lowest dose tested, 3 mg/kg/day (400-fold the human plasma exposure at the RHOD, based on AUC), when administered by IV injection daily from gestation days 7 through 19. A fetal no observed adverse effect level (NOAEL) was not identified in the rabbit.

**8.2 Lactation**

Risk Summary

There are no data on the presence of lifitegrast in human milk, the effects on the breastfed infant, or the effects on milk production. However, systemic exposure to lifitegrast from ocular administration is low [see *Clinical Pharmacology (12.3) in the full prescribing information*]. The developmental and health benefits of breastfeeding should be considered, along with the mother's clinical need for Xiidra and any potential adverse effects on the breastfed child from Xiidra.

**8.4 Pediatric Use**

Safety and efficacy in pediatric patients below the age of 17 years have not been established.

**8.5 Geriatric Use**

No overall differences in safety or effectiveness have been observed between elderly and younger adult patients.

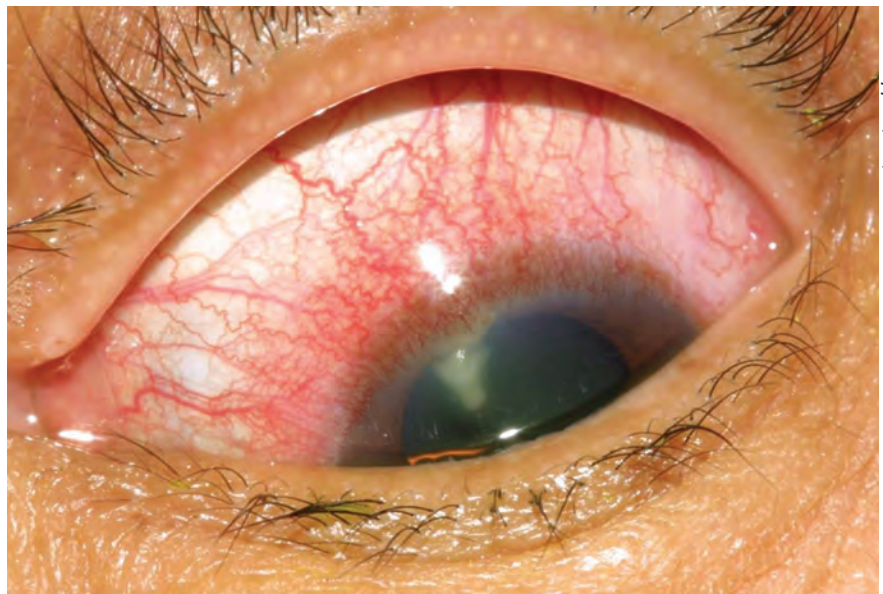
Distributed by:  
Novartis Pharmaceuticals Corporation  
One Health Plaza  
East Hanover, NJ 07936  
T2020-87

# Researchers Provide Update on The ARMOR Study

Despite encouraging positive trends for *S. aureus*, multidrug resistance—microbial insensitivity to at least three medication classes—is still common for many organisms.

Treating ocular infections is hard enough as is when the drugs work as advertised, and so much the worse when the offending microorganism is resistant or only weakly susceptible to therapy. Staphylococci are known causative pathogens in ophthalmic infections, and antibiotic resistance among these bacteria is of clinical concern. The long-running Antibiotic Resistance Monitoring in Ocular microOrganisms (ARMOR) Study, the only nationwide surveillance study of its kind, captures *in vitro* data specific to common ocular pathogens. With two research posters, the same team presented their findings on the 14th year of the study's data collection at ARVO 2023 in New Orleans. Each noted that, with preliminary data indicating lower resistance rates especially among *Staphylococcus aureus*, multidrug resistance was common among methicillin-resistant strains.

One analysis reported on 2022's data, when 397 isolates were collected January through October of that year.<sup>1</sup> *Staphylococcus aureus*, coagulase-negative staphylococci (CoNS), *Streptococcus pneumoniae*, *Pseudomonas aeruginosa* and *Haemophilus influenzae* from ocular infections were collected as part of



John Sheppard, MD, MMSc

**Staphylococcal infections demonstrated greater susceptibility to even some older medications in the newest ARMOR study.**

ARMOR and submitted to a central laboratory for species confirmation and *in vitro* antibiotic susceptibility testing. Minimum inhibitory concentrations for up to 16 antibiotics (10 drug classes) were determined and interpreted.

The 142 CoNS isolates exhibited the highest resistance, with azithromycin, oxacillin/methicillin, trimethoprim, clindamycin and tetracycline resistance observed in 60 percent, 37 percent, 28 percent, 27 percent and 22 percent of isolates, respectively. Among the 161 *S. aureus* isolates, 46 percent were resistant to azithromycin, but <20 percent of isolates were resistant to other

drugs. Multidrug resistance (poor or ineffective response to three or more drug classes) was observed in 14 percent of *S. aureus*, 39 percent of CoNS and in 59 percent and 88 percent of methicillin-resistant strains thereof, respectively. Among the five *S. pneumoniae* isolates, 60 percent were resistant to azithromycin, oral penicillin and tetracycline. Although all 72 *P. aeruginosa* isolates were resistant to polymyxin B, <5 percent were resistant to other drugs; no resistance was found among the 17 *H. influenzae* isolates.<sup>1</sup>

“The clinical significance of these *in vitro* data is unclear without consideration of the ocular

pharmacokinetics of tested antibiotics,” the ARMOR researchers concluded in their abstract.<sup>1</sup>

The team’s other study examined resistance trends over time among staphylococcal isolates collected from 2009 through 2022 in the ARMOR study. A total of 2,999 *S. aureus* and 2,575 CoNS were included in their analysis.<sup>2</sup>

*In vitro* resistance decreased to methicillin/oxacillin (*S. aureus*, 39 percent in 2009 to 18 percent in 2022; CoNS, 50 percent in 2009 to 37 percent in 2022) and to ciprofloxacin (*S. aureus*, 39 percent in 2009 to 17 percent in 2022; CoNS, 46 percent in 2009 to 20 percent in 2022). Additionally, among *S. aureus*, resistance to azithromycin decreased (62 percent in 2009 to 46 percent and 9 percent in 2022), as did resistance to

tobramycin (24 percent in 2009 to 9 percent in 2022), while in contrast an increase in chloramphenicol resistance was observed (7 percent in 2009 to 3 percent in 2022, peaking at 30 percent in 2021). Cumulative multidrug resistance (three or more antibiotic classes) was observed in 30 percent of *S. aureus* and 41 percent of CoNS and in 76 percent and 79 percent of methicillin-resistant isolates thereof, respectively.

“ARMOR continues to inform us about ocular infections and antibiotic resistance,” says study co-author Penny Asbell, MD, clinical professor of ophthalmology at the University of Tennessee Health Science Center. “While the latest results from the ARMOR update presented at ARVO 2023 suggest positive trends—that resistance

among staphylococci may be slightly decreasing for certain antibiotics in recent years—concurrent multidrug resistance, to three or more drug classes, continues to be prevalent, especially among methicillin-resistant isolates.”

The researchers also noted that resistance data should be considered in combination with known ocular pharmacokinetics of antibiotics. However, this time they emphasized that practitioners should also consider resistance data when selecting empirical treatment for staphylococcal eye infections in particular.<sup>2</sup>

1. Sanfilippo CM, DeCory H, Asbell PA. Antibiotic resistance among ocular pathogens – an update from the 2022 ARMOR Study. ARVO 2023 annual meeting.

2. Asbell PA, Sanfilippo CM, DeCory H. Longitudinal analysis of in vitro antibiotic resistance rates among ocular staphylococci collected in the ARMOR Study. ARVO 2023 annual meeting.

## Factors Linked to Visual Impairment in Myopic Glaucoma

The vascular underpinnings of glaucomatous damage continue to be revealed via OCT angiography. A recent analysis of glaucoma patients with myopia explored the connection between visual acuity and various structural factors.<sup>1</sup> Based on their findings, the study authors were able to link decreased acuity to specific locations suffering damage as well as the status of blood flow in the optic nerve head.

This retrospective cross-sectional study included 65 eyes of 60 myopic glaucoma patients without media opacity and retinal lesions. The study authors performed SITA 24-2 and 10-2 visual field testing.

OCTA was used to evaluate superficial and deep vessel density in the peripapillary and macular regions. Retinal nerve fiber layer (RNFL) and ganglion cell-inner plexiform layer (GCIPL) thicknesses were also measured. Researchers defined decreased visual acuity as best-corrected VA <20/25.

Data showed that the presence of central visual field damage in glaucoma patients with myopia was associated with the worse mean deviation of SITA 24-2 as well as thinner GCIPL thickness and lower deep peripapillary vessel density.

Additionally, there was a correlation between decreased visual acuity and the following factors: thinner GCIPL thickness; lower deep peripapillary vessel density; and longer disc-fovea distance.

The study authors reported that lower visual acuity was associated with thinner GCIPL thickness, lower deep peripapillary vessel density and larger  $\beta$ -zone peripapillary atrophy (PPA) area. They also observed a positive correlation between deep peripapillary vessel density and GCIPL thickness; however, no relationship was found between deep peripapillary vessel density and RNFL thickness.

“Decreased VA in addition to central visual field damage was found in glaucoma eyes with myopia with

low deep peripapillary vessel density and papillomacular bundle defect,” the study authors noted in their paper published in *American Journal of Ophthalmology*. “Additionally, structural parameters, such as long disc-fovea distance and large  $\beta$ -zone PPA were associated with visual acuity loss in glaucoma patients with myopia.

“Decreased deep peripapillary vessel density and papillomacular bundle defects may result from peripapillary sclera deformation by myopia, and this could be related to early visual acuity loss in these patients,” they concluded. They recommend the use of OCTA imaging to monitor choriocapillaris within the peripapillary sclera which could assist in the prediction of VA among this patient population. ◀

1. Kim SA, Park CK, Park HYL. Factors affecting visual acuity and central visual function in glaucoma patients with myopia. *Am J Ophthalmol*. May 11, 2023. [Epub ahead of print].



# Think Simple



## Preservative-Free Formulations\*

- No Preservatives
- No Prior Authorizations
- No Coupons or Copays

## Now with Simple Pricing

Any **SINGLE** Drug:

NOW only **\$19/mo**<sup>†</sup>

Any **COMBO** Drug:

NOW only **\$39/mo**<sup>†</sup>

Various options consisting of:

**Brimonidine, Dorzolamide, Bimatoprost, Timolol**

Scan QR Code or visit:  
[SimpleDrops.com](https://SimpleDrops.com)



**Important: Patients may need to take more than one eye drop product pursuant to multiple dosing regimens, as directed by his or her prescriber in order for the active ingredients to remain effective throughout the day.**

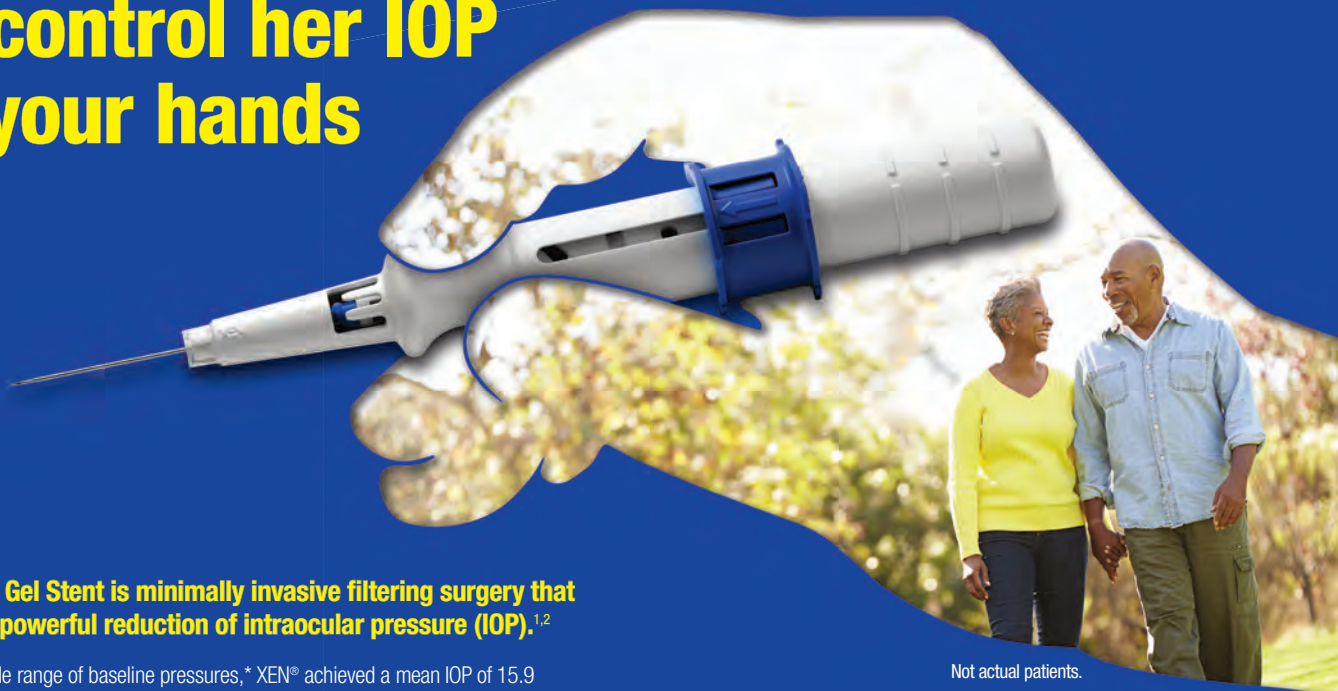<sup>†</sup> Months supply can vary based on the dosing regimen prescribed by the doctor  
\*For professional use only. ImprimisRx specializes in customizing medications to meet unique patient and practitioner needs. No compounded medication is reviewed by the FDA for safety and efficacy. ImprimisRx does not compound essential copies of commercially available products. These ingredients carry risks. Visit [imprimisrx.com/productinformation](https://imprimisrx.com/productinformation) for full product details. References available upon request.

Simple Drops and ImprimisRx are registered trademarks of Harrow IP, LLC. ©2023 ImprimisRx. All Rights Reserved. SD-00011\_Rev1 05/23

**imprimis** <sup>Rx</sup>  
A HARROW COMPANY

FOR REFRACTORY GLAUCOMA

# XEN<sup>®</sup> helps put the power to control her IOP in your hands



The XEN<sup>®</sup> Gel Stent is minimally invasive filtering surgery that achieves powerful reduction of intraocular pressure (IOP).<sup>1,2</sup>

- From a wide range of baseline pressures,\* XEN<sup>®</sup> achieved a mean IOP of 15.9 ( $\pm$  5.2) mm Hg through 12 months (n = 52)<sup>1,2</sup>
- 76% of XEN<sup>®</sup> patients achieved a  $\geq$  20% IOP reduction in the ITT group (N = 65)<sup>1</sup>
- 81% of XEN<sup>®</sup> patients achieved a  $\geq$  25% IOP reduction among those completing the 12-month visit (n = 52)<sup>2</sup>
- Pivotal safety data included 0% intraoperative complications (0/65) and 0% persistent hypotony (0/65); transient hypotony<sup>1</sup> occurred in 24.6% of patients (16/65)<sup>1</sup>

Not actual patients.

ITT = intent to treat.

\*In the XEN<sup>®</sup> clinical study, baseline medicated IOP ranged from 20.0 to 33.7 mm Hg.<sup>2</sup>

<sup>1</sup>No clinically significant consequences were associated with hypotony, such as choroidal effusions, suprachoroidal hemorrhage, or hypotony maculopathy. IOP < 6 mm Hg was defined as an adverse event, regardless of whether there were any associated complications or sequelae related to the low pressure. Thirteen cases occurred at the 1-day visit; there were no cases of persistent hypotony, and no surgical intervention was required for any case of hypotony.<sup>1</sup>

## THINK XEN<sup>®</sup> AT THE POINT OF YOUR SURGICAL DECISION.

### INDICATIONS

The XEN<sup>®</sup> Glaucoma Treatment System (XEN<sup>®</sup> 45 Gel Stent preloaded into a XEN<sup>®</sup> Injector) is indicated for the management of refractory glaucomas, including cases where previous surgical treatment has failed, cases of primary open-angle glaucoma, and pseudoexfoliative or pigmentary glaucoma with open angles that are unresponsive to maximum tolerated medical therapy.

### IMPORTANT SAFETY INFORMATION CONTRAINDICATIONS

XEN<sup>®</sup> Gel Stent is contraindicated in angle-closure glaucoma where angle has not been surgically opened, previous glaucoma shunt/valve or conjunctival scarring/pathologies in the target quadrant, active inflammation, active iris neovascularization, anterior chamber intraocular lens, intraocular silicone oil, and vitreous in the anterior chamber.

### WARNINGS

XEN<sup>®</sup> Gel Stent complications may include choroidal effusion, hyphema, hypotony, implant migration, implant exposure, wound leak, need for secondary surgical intervention, and intraocular surgery complications. Safety and effectiveness in neovascular, congenital, and infantile glaucoma has not been established. Avoid digital pressure following implantation of the XEN<sup>®</sup> Gel Stent to avoid the potential for implant damage.

### PRECAUTIONS

Examine the XEN<sup>®</sup> Gel Stent and XEN<sup>®</sup> Injector in the operating room prior to use. Monitor intraocular pressure (IOP) postoperatively and if not adequately maintained, manage appropriately. Stop the procedure immediately if increased resistance is observed during implantation and use a new XEN<sup>®</sup> system. Safety and effectiveness of more than a single implanted XEN<sup>®</sup> Gel Stent has not been studied.

### ADVERSE EVENTS

The most common postoperative adverse events included best-corrected visual acuity loss of  $\geq$  2 lines ( $\leq$  30 days 15.4%; > 30 days 10.8%; 12 months 6.2%), hypotony IOP < 6 mm Hg at any time (24.6%; no clinically significant consequences were associated, no cases of persistent hypotony, and no surgical intervention was required), IOP increase  $\geq$  10 mm Hg from baseline (21.5%), and needling procedure (32.3%).

Caution: Federal law restricts this device to sale by or on the order of a licensed physician. For the full Directions for Use, please visit [www.allergan.com/xen/usa.htm](http://www.allergan.com/xen/usa.htm) or call 1-800-678-1605. Please call 1-800-433-8871 to report an adverse event.

Please see accompanying full Directions for Use or visit [https://www.rxabbvie.com/pdf/xen\\_dfu.pdf](https://www.rxabbvie.com/pdf/xen_dfu.pdf)

**XEN<sup>®</sup>**  
G E L S T E N T

A Powerful, Proven Procedure



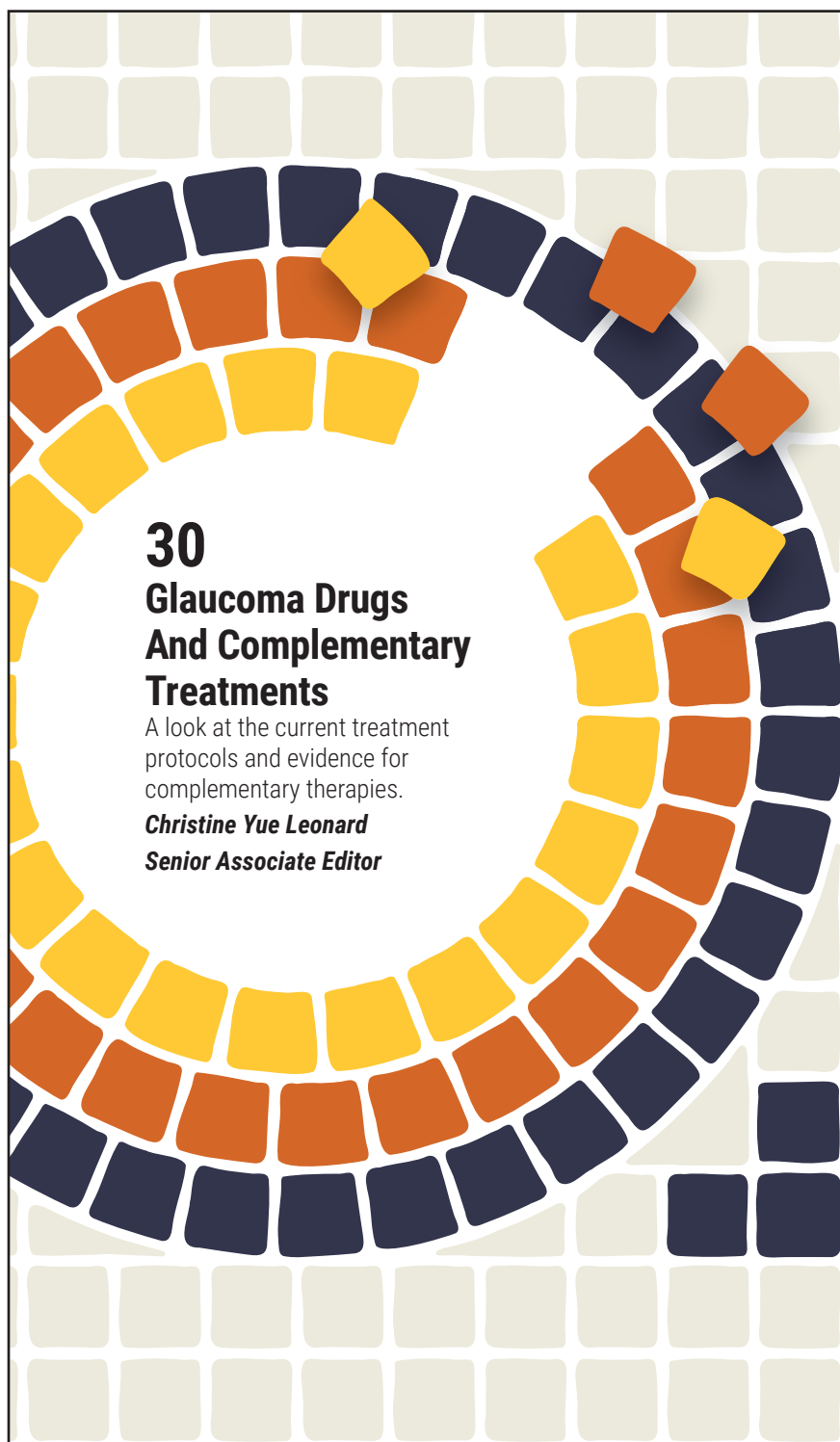© 2023 AbbVie. All rights reserved.  
All trademarks are the property of their respective owners.  
US-XEN-230003 01/2023 020627

References: 1. XEN<sup>®</sup> Directions for Use.  
2. Data on file, Allergan, 2016; Clinical Study Report R-020.

# FEATURES

Vol. 30, No. 6 • June 2023

**Catch Up on the Latest News**  
Read *Review's* weekly newsletter  
online at [reviewofophthalmology.com](http://reviewofophthalmology.com).



## 30 Glaucoma Drugs And Complementary Treatments

A look at the current treatment protocols and evidence for complementary therapies.

**Christine Yue Leonard**  
Senior Associate Editor

## 39 Is SLT Ready for a Leading Role?

With growing data bolstering its efficacy as a first-line treatment, some say SLT is the best approach for newly diagnosed glaucoma patients.

**Liz Hunter**  
Senior Editor

## 45 Advancing IOL Technology

Three premium IOLs were approved in the past year, advancing IOL technology and pushing patient satisfaction. Here's the latest information about each new lens.

**Andrew Beers**  
Associate Editor

## 49 A Look at the Dry-eye Treatment Pipeline

Companies and physicians are attacking ocular surface disease from all angles, from tear production to inflammation and meibomian gland dysfunction.

**Catlin Nalley**  
Contributing Editor

# DEPARTMENTS

June 2023

## 5 News

## 12

EDITOR'S PAGE

### The Complementary Angle

Walter Bethke  
Editor in Chief

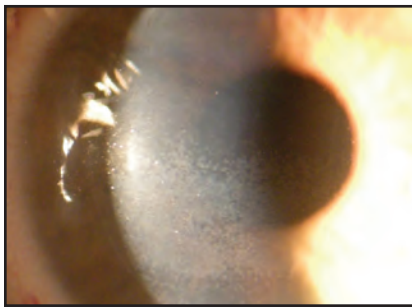
## 15

MEDICARE Q & A

### Steering Clear of Kickbacks

How to not run afoul of laws regarding self-referrals and anti-kickbacks.

Mary Pat Johnson, CPC, COE, CPMA



## 19

REFRACTIVE/CATARACT RUNDOWN

### Managing Post-LASIK Pain

Refractive surgeons should be aware of these possible complaints.

Liz Hunter, Senior Editor

## 24

TECHNOLOGY UPDATE

### Dry Eye: Artificial Intelligence Update

A round-up of the latest AI research in dry eye.

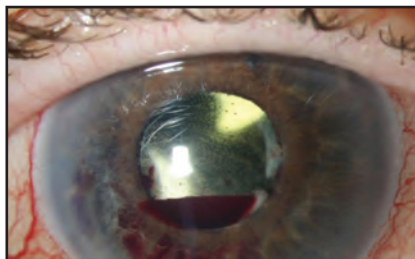
Christine Yue Leonard  
Senior Associate Editor

## 29

THE FORUM

### The Zeroth Law

Mark H. Blecher, MD  
Chief Medical Editor



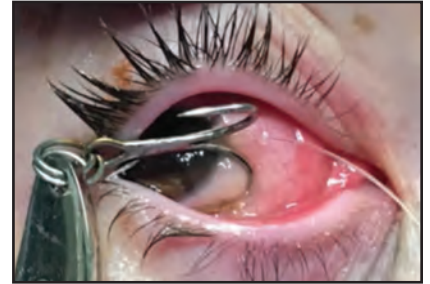## 55

GLAUCOMA MANAGEMENT

### Conjunctival Dehiscence Repair

How to manipulate friable tissue after tube exposure.

Jonathan Eisengart, MD



## 59

RETINAL INSIDER

### Pearls for Posterior IOFB Management

How to diagnose and treat IOFB injuries to the retina.

Chloe Y. Li, MD, Jin Kyun Oh, MD, Jennifer Adeghate, MD, Ahmet Hondur, MD, and Royce Chen, MD

## 65

RESEARCH REVIEW

## 67

AD INDEX

## 68

WILLS EYE RESIDENT CASE SERIES

### A patient presents with a year-long history of decreased vision, eye pain and photophobia.

Leo M. Hall, MD, MS, and James P. Dunn, MD

 VISIT US ON SOCIAL MEDIA

Facebook

[www.facebook.com/RevOphth](https://www.facebook.com/RevOphth)

Twitter

[twitter.com/RevOphth](https://twitter.com/RevOphth)

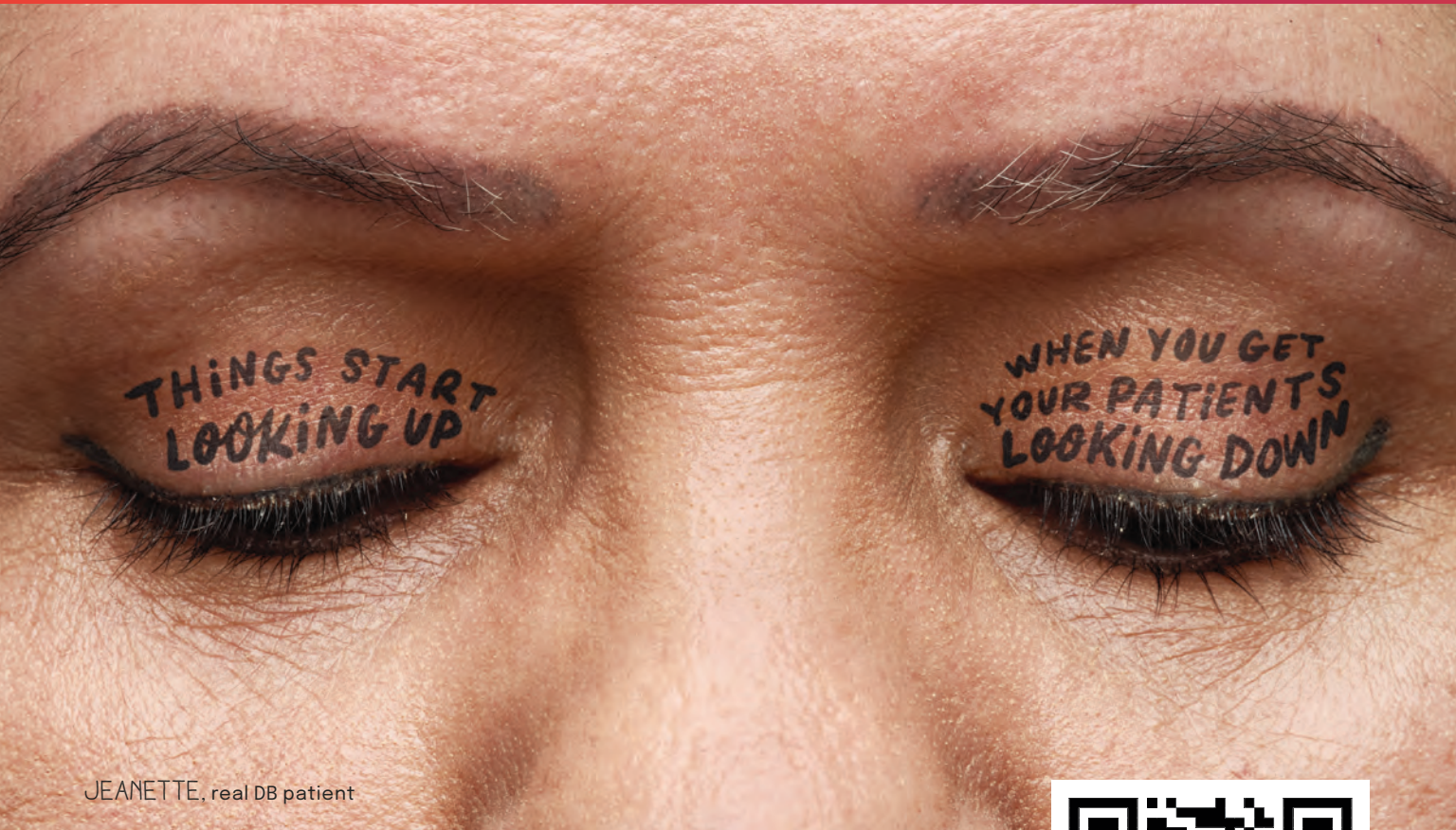Instagram

[@revophth](https://www.instagram.com/revophth)

# Keep an eye out for the root cause of blepharitis.

*Demodex* mites are the cause of chronic inflammation and associated with two-thirds of blepharitis cases.<sup>1,2</sup>

*Demodex* blepharitis (DB) is an important part of eyelid health.<sup>3,4</sup>



JEANETTE, real DB patient

SEE THE SIGNS OF DB FOR YOURSELF

LOOK *at the* LIDS.COM



@LookAtTheLids



Tarsus

**References:** 1. Gao YY, Di Pascuale MA, Li W, et al. High prevalence of *Demodex* in eyelashes with cylindrical dandruff. *Invest Ophthalmol Vis Sci.* 2005;46(9):3089-3094. 2. Trattler W, Karpecki P, Rapoport Y, et al. The prevalence of *Demodex* blepharitis in US eye care clinic patients as determined by collarettes: a pathognomonic sign. *Clin Ophthalmol.* 2022;16:1153-1164. 3. Aumond S, Bitton E. The eyelash follicle features and anomalies: a review. *J Optom.* 2018;11(4):211-222. 4. Fromstein SR, Harthan JS, Patel J, Opitz DL. *Demodex* blepharitis: clinical perspectives. *Clin Optom (Auckl).* 2018;10:57-63.



## EDITORIAL STAFF

### Editor in Chief

**Walter Bethke**

(610) 492-1024

wbethke@jobson.com

### Senior Editor

**Liz Hunter**

(610) 492-1025

ehunter@jobson.com

### Senior Associate Editor

**Christine Leonard**

(610) 492-1008

cleonard@jobson.com

### Associate Editor

**Leanne Spiegle**

(610) 492-1026

lspiegle@jobson.com

### Associate Editor

**Andrew Beers**

(610) 492-1026

abeers@jobson.com

### Chief Medical Editor

**Mark H. Blecher, MD**

### Senior Art Director

**Jared Araujo**

(610) 492-1032

jaraujo@jobson.com

### Graphic Designer

**Lynne O'Connor**

(267) 566-6007

lyoconnor@jobson.com

### Business Offices

19 Campus Boulevard, Suite 101

Newtown Square, PA 19073

(610) 492-1000

Fax: (610) 492-1039

### Subscription inquiries:

United States – (877) 529-1746

Outside U.S. – (845) 267-3065

E-mail:

revophthalmology@cambeywest.com

Website: www.reviewofophthalmology.com



# The Complementary Angle

Large-scale, prospective, randomized clinical trials are, of course, the gold standard when it comes to vetting a drug, device or other treatment for your patients. These investigations allow clinicians to balance both the desired efficacy of a therapy with an acceptable level of safety.

However, riding shotgun alongside these vetted, “mainstream” therapies are treatments from the wide and varied world of complementary medicine. Some complementary therapies have been around for thousands of years, such as the Ayurveda from India, while others, such as homeopathy pioneered in Germany, are much younger (though still just over 100 years old).<sup>1</sup>

The approach to healing taken by complementary therapy can be many and varied, which can be helpful to some patients looking for new options, but can be a nightmare for a clinician looking for some sort of rigorous data on results and safety. In homeopathy, for example, treatments can include nutrition, acupuncture, herbal medicine, and soft-tissue manipulation.

Similarly, the Ayurveda offers patients such alternatives as herbs, massage, exposure to sunlight and controlled breathing.<sup>1</sup>

Though some patients can experience some positive effects from these alternative approaches, vetting such therapies can be vexing for the clinician for, as one review puts it, “Ayurvedic medications have the potential to be toxic. Most Ayurvedic medications consist of combinations of herbs and other medicines, so it can be challenging to know which ones are having an effect and why.”<sup>1</sup>

Ophthalmology, too, has had some

experience with complementary therapies, as evidenced by this month's cover story on glaucoma treatments (p. 30). In addition to the tried-and-true, scientifically proven methods for managing glaucoma, some patients and their physicians may be exploring complementary treatments, running the gamut from *ginkgo biloba* to nicotinamide and pyruvate. As with any complementary therapy, glaucoma specialists on the front lines say the challenge is separating the good data from the bad, since patients can get their information from any number of sources. “I would hate for these findings to be misinterpreted by patients, who may not have the training and experience to critically evaluate medical literature,” notes one of the clinicians interviewed in the piece.

And, in an interesting twist of fate, selective laser trabeculoplasty, often viewed as a second-line treatment (some might say “complementary”) behind medications may turn the tables and become the primary treatment in some practices, according to physicians interviewed for our SLT feature (p. 39). As one glaucoma specialist puts it, “This tide of not using SLT as a first-line treatment is getting smaller and smaller ...”

Though complementary therapies can be tricky to evaluate and, therefore, recommend, it seems physicians are keeping an open mind, and are willing to look at the data as it evolves.

— *Walter Bethke*  
Editor in Chief

1. Tabish SA. Complementary and alternative healthcare: Is it evidence-based? *Int J Health Sci* 2008;2:1:5-9.

iStent  
infinite® ...

THE POWER OF 3



## The Beginning of the Interventional Glaucoma Revolution

# infinite possibilities

Brought to you by the founder of MIGS, iStent infinite® is the first-ever micro-invasive, standalone implantable alternative. Built on the #1 MIGS platform worldwide, it is designed to provide powerful technology that delivers foundational, 24/7, long-term IOP control in glaucoma patients who have failed prior medical and surgical intervention.<sup>1</sup>

#### REFERENCE

1. Glaukos Data on File.

#### iStent infinite® IMPORTANT SAFETY INFORMATION

**INDICATION FOR USE.** The iStent infinite® Trabecular Micro-Bypass System Model iS3 is an implantable device intended to reduce the intraocular pressure (IOP) of the eye. It is indicated for use in adult patients with primary open-angle glaucoma in whom previous medical and surgical treatment has failed. **CONTRAINDICATIONS.** The iStent infinite is contraindicated in eyes with angle-closure glaucoma where the angle has not been surgically opened, acute traumatic, malignant, active uveitic, or active neovascular glaucoma, discernible congenital anomalies of the anterior chamber (AC) angle, retrobulbar tumor, thyroid eye disease, or Sturge-Weber Syndrome or any other type of condition that may cause elevated episcleral venous pressure. **WARNINGS.** Gonioscopy should be performed prior to surgery to exclude congenital anomalies of the angle, PAS, rubeosis, or conditions that would prohibit adequate visualization that could lead to improper placement of the stent and pose a hazard. **MRI INFORMATION.** The iStent infinite is MR-Conditional, i.e., the device is safe for use in a specified MR environment under specified conditions; please see Directions for Use (DFU) label for details. **PRECAUTIONS.** The surgeon should monitor the patient postoperatively for proper maintenance of IOP. Three out of 61 participants (4.9%) in the pivotal clinical trial were phakic. Therefore, there is insufficient evidence to determine whether the clinical performance of the device may be different in those who are phakic versus in those who are pseudophakic. **ADVERSE EVENTS.** The most common postoperative adverse events reported in the iStent infinite pivotal trial included IOP increase  $\geq 10$  mmHg vs. baseline IOP (8.2%), loss of BSCVA  $\geq 2$  lines (11.5%), ocular surface disease (11.5%), perioperative inflammation (6.6%) and visual field loss  $\geq 2.5$  dB (6.6%). **CAUTION:** Federal law restricts this device to sale by, or on the order of, a physician. Please see DFU for a complete list of contraindications, warnings, precautions, and adverse events.

Glaukos® and iStent infinite® are registered trademarks of Glaukos Corporation. All rights reserved. ©2022

PM-US-0909

GLAUKOS®

## CONTRIBUTORS

### CHIEF MEDICAL EDITOR

Mark H. Blecher, MD

### CONTACT LENSES

Penny Asbell, MD

### CORNEA / ANTERIOR SEGMENT

Thomas John, MD

### GLAUCOMA MANAGEMENT

Peter Netland, MD, PHD  
Kuldev Singh, MD

### MEDICARE Q & A

Mary Pat Johnson,  
COMT, CPC

### PEDIATRIC PATIENT

Janine Collinge, MD

### PLASTIC POINTERS

April Lao, MD

### REFRACTIVE SURGERY

Arturo S. Chayet, MD

### RETINAL INSIDER

Carl Regillo, MD, FACS  
Yoshihiro Yonekawa, MD

### TECHNOLOGY UPDATE

Steven T. Charles, MD  
Michael Colvard, MD

### WILLS RESIDENT CASE SERIES

Bonnie Sklar, MD

## ADVISORY BOARD

**PENNY A. ASBELL, MD**, MEMPHIS, TENN.

**BRANDON AYRES, MD**, PHILADELPHIA

**SURENDRA BASTI, MD**, CHICAGO

**WILLIAM I. BOND, MD**, PEKIN, ILL.

**ALAN N. CARLSON, MD**, DURHAM, N.C.

**Y. RALPH CHU, MD**, EDINA, MINN.

**ADAM J. COHEN, MD**, CHICAGO

**JANINE COLLINGE, MD**, FARMINGTON, CONN.

**UDAY DEVGAN, MD, FACS**, LOS ANGELES

**ERIC DONNENFELD, MD**, ROCKVILLE CENTRE, N.Y.

**DANIEL S. DURRIE, MD**, KANSAS CITY, MO.

**ROBERT EPSTEIN, MD**, MCHENRY, ILL.

**ROBERT D. FECHTNER, MD**, NEWARK, N.J.

**BRIAN FRANCIS, MD**, Los Angeles

**JAMES P. GILLS, MD**, TARPON SPRINGS, FLA.

**HARRY GRABOW, MD**, SARASOTA, FLA.

**DOUGLAS K. GRAYSON, MD**, NEW YORK CITY

**DAVID R. HARDTEN, MD**, MINNEAPOLIS

**SARA J. HAUG, MD, PHD**, DURANGO, COLO.

**KENNETH J. HOFFER, MD**, SANTA MONICA, CALIF.

**JACK T. HOLLADAY, MD, MSEE**, HOUSTON

**JOHN D. HUNKELER, MD**, KANSAS CITY, MO.

**THOMAS JOHN, MD**, TINLEY PARK, ILL.

**ROBERT M. KERSHNER, MD, MS**, PALM BEACH GARDENS, FLA.

**GUY M. KEZIRIAN, MD**, PARADISE VALLEY, ARIZ.

**SUMITRA KHANDLWAL, MD**, HOUSTON

**TERRY KIM, MD**, DURHAM, N.C.

**BRAD KLIGMAN, MD**, MANHASSET, N.Y.

**TOMMY KORN, MD**, SAN DIEGO

**APRIL LAO, MD**, MEMPHIS

**DAVID A. LEE, MD**, HOUSTON

**FRANCIS S. MAH, MD**, LA JOLLA, CALIF.

**NICK MAMALIS, MD**, SALT LAKE CITY

**EDWARD MANCHE, MD**, PALO ALTO, CALIF.

**MIKE S. MCFARLAND, MD**, PINE BLUFF, ARK.

**JEFFREY B. MORRIS, MD, MPH**, ENCINITAS, CALIF.

**KEVIN MILLER, MD**, LOS ANGELES

**MAJID MOSHIRFAR, MD**, DRAPER, UTAH

**MARLENE R. MOSTER, MD**, PHILADELPHIA

**ROBERT J. NOECKER, MD**, FAIRFIELD, CONN.

**ROBERT OSHER, MD**, CINCINNATI

**MARK PACKER, MD**, WEST PALM BEACH, FLA.

**CHRISTOPHER J. RAPUANO, MD**, PHILADELPHIA

**AUGUST READER III, MD**, SAN FRANCISCO

**TONY REALINI, MD, MPH**, MORGANTOWN, W.V.

**KENNETH J. ROSENTHAL, MD**, GREAT NECK, N.Y.

**ERIC ROTHCHILD, MD**, DELRAY BEACH, FLA.

**SHERI ROWEN, MD**, BALTIMORE

**JAMES J. SALZ, MD**, LOS ANGELES

**INGRID U. SCOTT, MD, MPH**, HERSHEY, PA.

**JOEL SCHUMAN, MD**, PITTSBURGH

**GAURAV SHAH, MD**, ST. LOUIS

**DAVID R. STAGER JR., MD**, DALLAS

**KARL STONECIPHER, MD**, GREENSBORO, N.C.

**JAMES C. TSAI, MD**, NEW YORK CITY

**VANCE THOMPSON, MD**, SIOUX FALLS, S.D.

**FARRELL C. TYSON, MD**, CAPE CORAL, FLA.

**R. BRUCE WALLACE III, MD**, ALEXANDRIA, LA.



### BUSINESS OFFICES

19 CAMPUS BOULEVARD, SUITE 101  
NEWTOWN SQUARE, PA 19073  
SUBSCRIPTION INQUIRIES (877) 529-1746  
(USA ONLY); OUTSIDE USA, CALL (847) 763-9630

### BUSINESS STAFF

PUBLISHER

**MICHAEL HOSTER**

(610) 492-1028 MHOSTER@JOBSON.COM

SENIOR MANAGER, STRATEGIC ACCOUNTS

**MICHELE BARRETT**

(610) 492-1014 MBARRETT@JOBSON.COM

REGIONAL SALES MANAGER

**JONATHAN DARDINE**

(610) 492-1030 JDARDINE@JOBSON.COM

DIGITAL MARKETING MANAGER

**MATT EGGER**

(610) 492-1029 MEGGER@JOBSON.COM

CLASSIFIED ADVERTISING

(888) 498-1460

PRODUCTION MANAGER

**KAREN LALLONE**

(610) 492-1010 KLALLONE@JOBSON.COM

SUBSCRIPTIONS

\$63 A YEAR, \$99 (U.S.) IN CANADA,  
\$158 (U.S.) IN ALL OTHER COUNTRIES.

SUBSCRIPTIONS E-MAIL:

REVOPHTHALMOLOGY@CAMBEYWEST.COM

### CIRCULATION

PO BOX 71, CONGERS, NY 10920-0071

(877) 529-1746

OUTSIDE USA: (845) 267-3065

SENIOR CIRCULATION MANAGER

**HAMILTON MAHER**

(212) 219-7870 hmaher@jhihealth.com

CEO, INFORMATION GROUP SERVICES

**BILL SCOTT**

SENIOR VICE PRESIDENT, OPERATIONS

**JEFF LEVITZ**

VICE PRESIDENT, HUMAN RESOURCES

**TAMMY GARCIA**

VICE PRESIDENT, CREATIVE SERVICES & PRODUCTION

**MONICA TETTAMANZI**

CORPORATE PRODUCTION DIRECTOR

**JOHN ANTHONY CAGGIANO**

VICE PRESIDENT, CIRCULATION

**JARED SONNERS**

395 Hudson Street, 3rd Floor,  
New York, NY 10014

REVIEW OF OPHTHALMOLOGY (ISSN 1081-0226; USPS No. 0012-345) is published monthly, 12 times per year by Jobson Medical Information, 395 Hudson Street, 3rd Floor, New York, NY 10014. Periodicals postage paid at New York, NY and additional mailing offices. Postmaster: Send address changes to Review of Ophthalmology, PO Box 71, Congers, NY 10929-0071. Subscription Prices: US One Year \$63.00, US Two Year \$112.00, Canada One Year \$99.00, Canada Two Year \$181.00, Int'l One Year \$158.00, Int'l Two Year \$274.00. For subscription information call (877) 529-1746 (USA only); outside USA, call (845) 267-3065. Or email us at revophthalmology@cambeywest.com. Canada Post: Publications Mail Agreement #40612608. Canada Returns to be sent to Bleuchip International, P.O. Box 25542, London, ON N6C 6B2.





MARY PAT JOHNSON, COMT,  
CPC, COE, CPMA

## MEDICARE Q&A

# Steering Clear of Kickbacks

*Running afoul of laws regarding self-referrals and anti-kickbacks can result in heavy fines. Here's how to stay safe.*

Each year, the Centers for Medicare and Medicaid Services publishes the codes for Designated Health Services that are subject to restrictions under the Physician Self-Referral Law (a.k.a., the Stark Law). It's important to check the list of codes annually to remain compliant. There are multiple examples of providers running afoul of the Stark Law regulations, and large fines can apply. Here, we'll look at the rules to help keep you on the right side of the regulations.

### Q How is physician compensation tied to the Stark Law?

A As mentioned, another name for the Stark Law is the Physician Self-Referral Law: It's about "you referring to you."

The Office of Inspector General notes that the Stark Law "prohibits physicians from referring patients to receive 'designated health services'<sup>1</sup> payable by Medicare or Medicaid

if the physician or an immediate family member has a financial relationship with the entity, unless an exception applies. Financial

relationships include ownership/investment interests and compensation arrangements.

They also note that this law "... prohibits the ... entity from submitting claims to Medicare for those services ..."<sup>2</sup>

### Q How do DHS impact physician compensation?

A Payment on a percentage basis is allowed for physician professional services, including test interpretations. However,

for selected diagnostic tests, payment on percentage basis for the technical component isn't allowed.

Practices must exclude some of the revenue for services on the designated health service list when calculating compensation for physicians who are paid on a productivity-basis, by base pay and/or a bonus. Using modifiers TC and 26 on claims may simplify the tracking and calculation, but it's not required.

### Q What ophthalmic items and services are affected?

A The 2023 DHS list include, among other things, commonly provided eye-care services:

- ultrasounds (CPT 76510-76519);
- SCODI tests (CPT 92132-92134);
- tear testing (CPT 0330T, 83516, 83861); and
- remote imaging (CPT 92227 and 92228).

Additionally, the rules apply to supplies, devices and injectable medications. Drugs are frequently an area of dispute. Medicare reimburses 106 percent of the manufacturer's volume-weighted average sales price (ASP) for most drugs administered in a physician's office. This is meant to cover the drug cost with the +6 percent acting as an administrative fee; drugs shouldn't be considered a "profit center" to the practice or the physician.


Again, when calculating physician compensation, revenue associated with supplies, devices and injectables should be carved out.

### Q What is the Anti-kickback Statute?

A The Anti-kickback Statute differs from the self-referral act. The AKS focuses on relationships between entities, not providers referring to themselves. It's broader in scope than Stark.

The AKS is a criminal law that prohibits the knowing and willful payment of 'remuneration' to induce or reward patient referrals or the generation of business involving any item or service payable by the Federal health care programs (e.g., drugs, supplies or health-care services for Medicare or Medicaid

*(Continued on p. 66)*



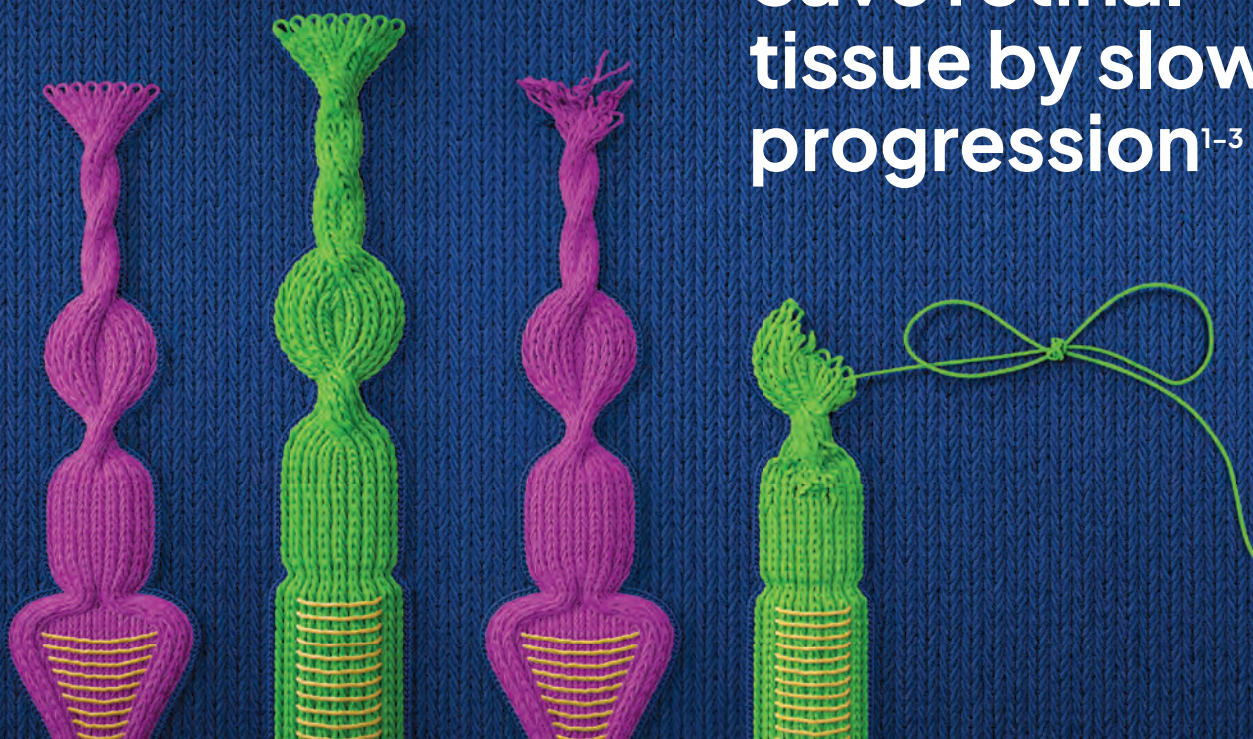This article has no commercial sponsorship.

Mary Pat Johnson is a senior consultant at the Corcoran Consulting Group and is based in North Carolina. She can be reached at [mpjohnson@corcoranccg.com](mailto:mpjohnson@corcoranccg.com).

**NOW APPROVED:** the first and only  
FDA-approved treatment for GA  
secondary to AMD<sup>1</sup>

GA unravels so much

**Save retinal  
tissue by slowing  
progression<sup>1-3</sup>**



## INDICATION

SYFOVRE™ (pegcetacoplan injection) is indicated for the treatment of geographic atrophy (GA) secondary to age-related macular degeneration (AMD).

## IMPORTANT SAFETY INFORMATION

### CONTRAINDICATIONS

- SYFOVRE is contraindicated in patients with ocular or periocular infections, and in patients with active intraocular inflammation

### WARNINGS AND PRECAUTIONS

#### ● Endophthalmitis and Retinal Detachments

- Intravitreal injections, including those with SYFOVRE, may be associated with endophthalmitis and retinal detachments. Proper aseptic injection technique must always be used when administering SYFOVRE to minimize the risk of endophthalmitis. Patients should be instructed to report any symptoms suggestive of endophthalmitis or retinal detachment without delay and should be managed appropriately.

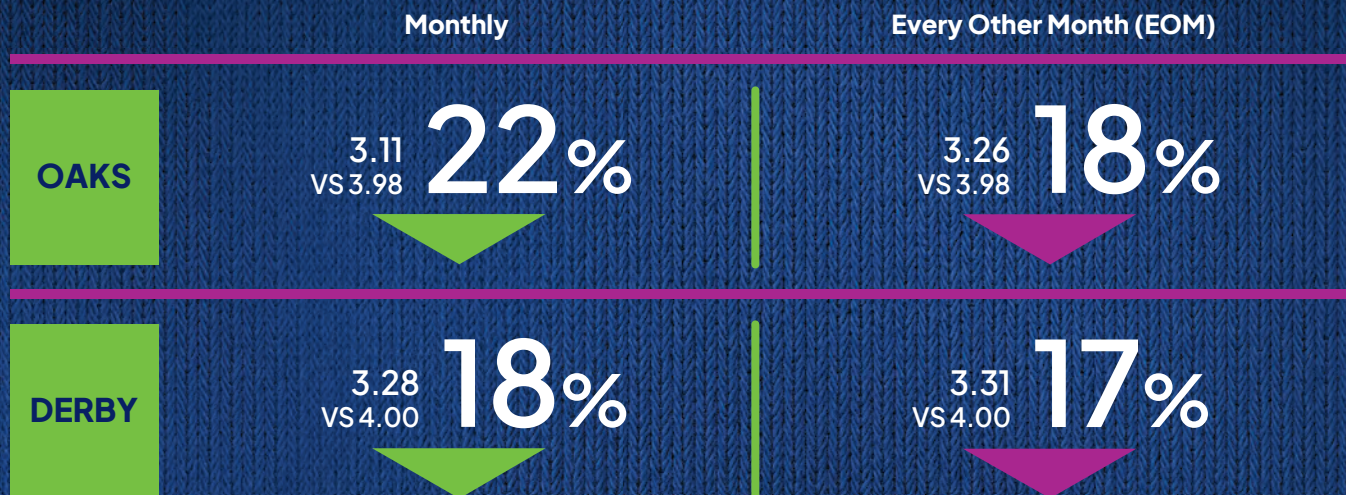
#### ● Neovascular AMD

- In clinical trials, use of SYFOVRE was associated with increased rates of neovascular (wet) AMD or choroidal neovascularization (12% when administered monthly, 7% when administered every other month and 3% in the control group) by Month 24. Patients receiving SYFOVRE should be monitored for signs of neovascular AMD. In case anti-Vascular Endothelial Growth Factor (anti-VEGF) is required, it should be given separately from SYFOVRE administration.

#### ● Intraocular Inflammation

- In clinical trials, use of SYFOVRE was associated with episodes of intraocular inflammation including: vitritis, vitreal cells, iridocyclitis, uveitis, anterior chamber cells, iritis, and anterior chamber flare. After inflammation resolves, patients may resume treatment with SYFOVRE.

# SYFOVRE achieved continuous reductions in mean lesion growth rate\* (mm<sup>2</sup>) vs sham pooled from baseline to Month 24<sup>1</sup>



SE in trials (monthly, EOM, sham pooled): OAKS: 0.15, 0.13, 0.14; DERBY: 0.13, 0.13, 0.17.

\*Slope for baseline to Month 24 is an average of slope of baseline to Month 6, Month 6 to Month 12, Month 12 to Month 18, and Month 18 to Month 24.<sup>1</sup> Based on a mixed effects model for repeated measures assuming a piecewise linear trend in time with knots at Month 6, Month 12, and Month 18.<sup>1</sup> AMD=age-related macular degeneration; GA=geographic atrophy; SE=standard error.



Explore more at  
[SyfovreECP.com](https://SyfovreECP.com)

## IMPORTANT SAFETY INFORMATION (CONT'D) WARNINGS AND PRECAUTIONS (CONT'D)

### ● Increased Intraocular Pressure

- Acute increase in IOP may occur within minutes of any intravitreal injection, including with SYFOVRE. Perfusion of the optic nerve head should be monitored following the injection and managed as needed.

### ADVERSE REACTIONS

- Most common adverse reactions (incidence ≥5%) are ocular discomfort, neovascular age-related macular degeneration, vitreous floaters, conjunctival hemorrhage.

**Trial Design:** SYFOVRE safety and efficacy were assessed in OAKS (N=637) and DERBY (N=621), multi-center, 24-month, Phase 3, randomized, double-masked trials. Patients with GA (atrophic nonexudative age-related macular degeneration), with or without subfoveal involvement, secondary to AMD were randomly assigned (2:2:1:1) to receive 15 mg/0.1 mL intravitreal SYFOVRE monthly, SYFOVRE EOM, sham monthly, or sham EOM for 24 months. Change from baseline in the total area of GA lesions in the study eye (mm<sup>2</sup>) was measured by fundus autofluorescence (FAF).<sup>1,4</sup>

**References:** **1.** SYFOVRE (pegcetacoplan injection) [package insert]. Waltham, MA: Apellis Pharmaceuticals, Inc.; 2023. **2.** Pfau M, von der Emde L, de Sisternes L, et al. Progression of photoreceptor degeneration in geographic atrophy secondary to age-related macular degeneration. *JAMA Ophthalmol.* 2020;138(10):1026–1034. **3.** Bird AC, Phillips RL, Hageman GS. Geographic atrophy: a histopathological assessment. *JAMA Ophthalmol.* 2014;132(3):338–345. **4.** Data on file. Apellis Pharmaceuticals, Inc.

Please see Brief Summary of Prescribing Information for SYFOVRE on the adjacent page.

Apellis

APELLIS®, SYFOVRE™ and their respective logos are registered trademarks and/or trademarks of Apellis Pharmaceuticals, Inc. ©2023, Apellis Pharmaceuticals, Inc. 2/23 US-PEGGA-2200051 v1.0

**SYFOVRE™**  
(pegcetacoplan injection)  
15mg / 0.1mL

**SYFOVRE™ (pegcetacoplan injection), for intravitreal use**  
**BRIEF SUMMARY OF PRESCRIBING INFORMATION**  
Please see SYFOVRE full Prescribing Information for details.

**INDICATIONS AND USAGE**

SYFOVRE is indicated for the treatment of geographic atrophy (GA) secondary to age-related macular degeneration (AMD).

**CONTRAINDICATIONS**

**Ocular or Periocular Infections**

SYFOVRE is contraindicated in patients with ocular or periocular infections.

**Active Intraocular Inflammation**

SYFOVRE is contraindicated in patients with active intraocular inflammation.

**WARNINGS AND PRECAUTIONS**

**Endophthalmitis and Retinal Detachments**

Intravitreal injections, including those with SYFOVRE, may be associated with endophthalmitis and retinal detachments. Proper aseptic injection technique must always be used when administering SYFOVRE in order to minimize the risk of endophthalmitis. Patients should be instructed to report any symptoms suggestive of endophthalmitis or retinal detachment without delay and should be managed appropriately.

**Neovascular AMD**

In clinical trials, use of SYFOVRE was associated with increased rates of neovascular (wet) AMD or choroidal neovascularization (12% when administered monthly, 7% when administered every other month and 3% in the control group) by Month 24. Patients receiving SYFOVRE should be monitored for signs of neovascular AMD. In case anti-Vascular Endothelial Growth Factor (anti-VEGF) is required, it should be given separately from SYFOVRE administration.

**Intraocular Inflammation**

In clinical trials, use of SYFOVRE was associated with episodes of intraocular inflammation including: vitritis, vitreal cells, iridocyclitis, uveitis, anterior chamber cells, iritis, and anterior chamber flare. After inflammation resolves patients may resume treatment with SYFOVRE.

**Increased Intraocular Pressure**

Acute increase in IOP may occur within minutes of any intravitreal injection, including with SYFOVRE. Perfusion of the optic nerve head should be monitored following the injection and managed as needed.

**ADVERSE REACTIONS**

**Clinical Trials Experience**

Because clinical trials are conducted under widely varying conditions, adverse reaction rates observed in the clinical trials of a drug cannot be directly compared to rates in the clinical trials of another drug and may not reflect the rates observed in practice. A total of 839 patients with GA in two Phase 3 studies (OAKS and DERBY) were treated with intravitreal SYFOVRE, 15 mg (0.1 mL of 150 mg/mL solution). Four hundred nineteen (419) of these patients were treated in the affected eye monthly and 420 were treated in the affected eye every other month. Four hundred seventeen (417) patients were assigned to sham. The most common adverse reactions ( $\geq 5\%$ ) reported in patients receiving SYFOVRE were ocular discomfort, neovascular age-related macular degeneration, vitreous floaters, and conjunctival hemorrhage.

**Table 1: Adverse Reactions in Study Eye Reported in  $\geq 2\%$  of Patients Treated with SYFOVRE Through Month 24 in Studies OAKS and DERBY**

Adverse Reactions	PM (N = 419) %	PEOM (N = 420) %	Sham Pooled (N = 417) %
Ocular discomfort*	13	10	11
Neovascular age-related macular degeneration*	12	7	3
Vitreous floaters	10	7	1
Conjunctival hemorrhage	8	8	4
Vitreous detachment	4	6	3
Retinal hemorrhage	4	5	3
Punctate keratitis*	5	3	<1
Posterior capsule opacification	4	4	3
Intraocular inflammation*	4	2	<1
Intraocular pressure increased	2	3	<1

PM: SYFOVRE monthly; PEOM: SYFOVRE every other month

\*The following reported terms were combined:

**Ocular discomfort** included: eye pain, eye irritation, foreign body sensation in eyes, ocular discomfort, abnormal sensation in eye

**Neovascular age-related macular degeneration** included: exudative age-related macular degeneration, choroidal neovascularization

**Punctate keratitis** included: punctate keratitis, keratitis

**Intraocular inflammation** included: vitritis, vitreal cells, iridocyclitis, uveitis, anterior chamber cells, iritis, anterior chamber flare

Endophthalmitis, retinal detachment, hyphema and retinal tears were reported in less than 1% of patients. Optic ischemic neuropathy was reported in 1.7% of patients treated monthly, 0.2% of patients treated every other month and 0.0% of patients assigned to sham. Deaths were reported in 6.7% of patients treated monthly, 3.6% of patients treated every other month and 3.8% of patients assigned to sham. The rates and causes of death were consistent with the elderly study population.

**USE IN SPECIFIC POPULATIONS**

**Pregnancy**

**Risk Summary**

There are no adequate and well-controlled studies of SYFOVRE administration in pregnant women to inform a drug-associated risk. The use of SYFOVRE may be considered following an assessment of the risks and benefits.

Systemic exposure of SYFOVRE following ocular administration is low. Subcutaneous administration of pegcetacoplan to pregnant monkeys from the mid gestation period through birth resulted in increased incidences of abortions and stillbirths at systemic exposures 1040-fold higher than that observed in humans at the maximum recommended human ophthalmic dose (MRHOD) of SYFOVRE (based on the area under the curve (AUC) systemically measured levels). No adverse maternal or fetal effects were observed in monkeys at systemic exposures approximately 470-fold higher than that observed in humans at the MRHOD.

In the U.S. general population, the estimated background risk of major birth defects and miscarriage in clinically recognized pregnancies is 2-4% and 15-20%, respectively.

**Lactation**

**Risk Summary**

It is not known whether intravitreal administered pegcetacoplan is secreted in human milk or whether there is potential for absorption and harm to the infant. Animal data suggest that the risk of clinically relevant exposure to the infant following maternal intravitreal treatment is minimal. Because many drugs are excreted in human milk, and because the potential for absorption and harm to infant growth and development exists, caution should be exercised when SYFOVRE is administered to a nursing woman.

**Females and Males of Reproductive Potential**

**Contraception**

**Females:** It is recommended that women of childbearing potential use effective contraception methods to prevent pregnancy during treatment with intravitreal pegcetacoplan. Advise female patients of reproductive potential to use effective contraception during treatment with SYFOVRE and for 40 days after the last dose. For women planning to become pregnant, the use of SYFOVRE may be considered following an assessment of the risks and benefits.

**Pediatric Use**

The safety and effectiveness of SYFOVRE in pediatric patients have not been established.

**Geriatric Use**

In clinical studies, approximately 97% (813/839) of patients randomized to treatment with SYFOVRE were  $\geq 65$  years of age and approximately 72% (607/839) were  $\geq 75$  years of age. No significant differences in efficacy or safety were seen with increasing age in these studies. No dosage regimen adjustment is recommended based on age.

**PATIENT COUNSELING INFORMATION**

Advise patients that following SYFOVRE administration, patients are at risk of developing neovascular AMD, endophthalmitis, and retinal detachments. If the eye becomes red, sensitive to light, painful, or if a patient develops any change in vision such as flashing lights, blurred vision or metamorphopsia, instruct the patient to seek immediate care from an ophthalmologist.

Patients may experience temporary visual disturbances associated either with the intravitreal injection with SYFOVRE or the eye examination. Advise patients not to drive or use machinery until visual function has recovered sufficiently.

Manufactured for:  
Apellis Pharmaceuticals, Inc.  
100 Fifth Avenue  
Waltham, MA 02451

SYF-PI-17Feb2023-1.0

APELLIS®, SYFOVRE™ and their respective logos are registered trademarks and/or trademarks of Apellis Pharmaceuticals, Inc.  
©2023, Apellis Pharmaceuticals, Inc.

2/23 US-PEGGA-2200163 v2.0



EDITED BY ARTURO CHAYET, MD

## REFRACTIVE/CATARACT RUNDOWN

# Managing Post-LASIK Pain

*From dry-eye symptoms to severe neuropathic pain, refractive surgeons should be aware of these possible complaints.*

LIZ HUNTER  
SENIOR EDITOR

For a majority of LASIK patients, recovery will go as expected, healing fully within three to six months. However, refractive surgeons may encounter the rare patient who continues to suffer from dry-eye symptoms with no relief, some of which can be severe and disruptive to their daily life and mental health. We spoke with cornea and refractive surgery specialists who offered guidance on treating these cases.

### Post-LASIK Chronic Dry Eye

Historically, one of the most appealing aspects of LASIK has been its quick recovery time. Patients will see more clearly within 24 hours and they can usually return to their normal activities within just a couple of days of surgery, yet the eyes themselves can take several months to fully heal, and for a small population of patients, even longer.

Dry-eye symptoms are the most common complaints in the early postop period, occurring in as much as 60 percent of patients one month following LASIK.<sup>1</sup> Although there's no surefire way to predict the severity of dry eye that individual patients may experience, studies have shown that factors such as sex, ethnicity, contact lens use, eyelid anomalies

and diabetes have been associated with increased risk of dryness.<sup>1</sup>

Extensive research and education has been undertaken by the field of ophthalmology to treat the ocular surface prior to surgery, and more often than not, it's the group of patients who don't tolerate contact lens wear that seeks out refractive surgery and may need more aggressive treatment, explains David R. Hardten, MD, of Minnesota Eye Consultants.

"Much of why they don't tolerate contact lenses very well is due to ocular rosacea, blepharitis or dry eye," he says. "We can see that they have a little bit of intermittent punctate

staining when they've been seen in the past and that's why they've had to stop their contact lenses. We tend to be more aggressive in controlling these underlying conditions for those patients because now they no longer have the air-blocking effects of a contact on their eyes, or glasses in front of their eyes. It takes a while for them to become re-accustomed to having their eyes open to the air. In addition, they've often developed a poor blink reflex with contacts; blinking partially, feeling their contact lens with half blink; so they have to learn to blink again."

Dr. Hardten proceeds with treatment to optimize the ocular surface. "They stop wearing contact lenses, then we treat with cyclosporine drops or lifitegrast (Xiidra), sometimes doxycycline orally, and Omega-7 to help with gland dysfunction. In some patients where we see intermittent punctate keratitis preoperatively we might even do in-office treatments like Intense Pulsed Light, LipiFlow or TearCare in advance to get their



Getty

**Following LASIK surgery, there's a small population of patients who experience chronic pain that doesn't respond to traditional dry-eye treatments. Experts say they require more aggressive, systemic treatment to help heal the nerves.**

This article has no commercial sponsorship.

Dr. Chayet is considered a pioneer in refractive and cataract surgery, and is the medical director of the Codet Vision Institute in Tijuana, Mexico. He is a clinical investigator for RxSight, LensGen and ForSight Vision6.

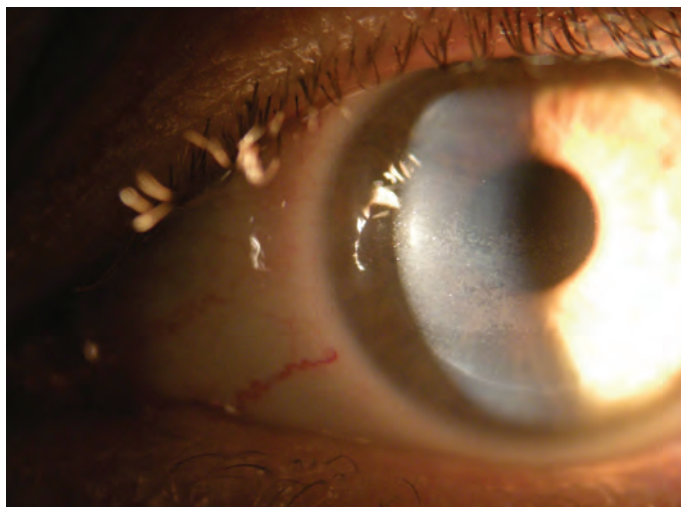ocular surface ready,” he says.

Following surgery, dry eye improves within three months, or six months in some outliers, says Deborah S. Jacobs, MD, MS, director of the Massachusetts Eye and Ear Ocular Surface Imaging Center. “It’s really hard to distinguish these patients from the broad variety of patients who might see well, but have various types of discomfort in the immediate postop period. Most are treated as ‘dry eye’ with lubricating drops and punctal occlusion. Some may be given drops that improve tear secretion like cyclosporine or lifitegrast, or a more prolonged course of topical steroid or with autologous serum tears,” she says.

While working as a clinician at a referral center, Dr. Jacobs was introduced to patients still suffering with ocular surface disease and were years past their LASIK procedure. Many were referred for a therapeutic scleral lens. “What we’ve learned about this condition in hindsight is patients typically may have severe pain from the day after LASIK on, but more typically they have symptoms that might be interpreted as dry eye: gritty feeling; dry feeling; and a sensitivity to light and moving air,” she says. “However, some of these patients seem to not get better, or they even get worse. And that’s when they start to stand out from the run-of-the-mill dry eye that occurs after LASIK.”

### Neuropathic Corneal Pain

More severe and more rare are persistent and debilitating symptoms that have been classified as neuropathic corneal pain, a subtype of dry-eye syndrome. Many of these patients didn’t present with dry-eye symptoms prior to LASIK, adding to the mystery around the contributing factors to this condition.



Uday Deygan, MD

**Approximately 60 percent of patients who undergo LASIK surgery will experience postop dry eye. Preop screening and treatment for ocular surface disease has become an important component of refractive surgery to improve these outcomes.**

Dr. Jacobs says the LASIK procedure itself can trigger this pain syndrome in some people.

“The flap is a different kind of trauma and generally eyes did well after LASIK, but when you make the flap, you cut nerves that innervate the front of the eye,” she says. “Those nerves are important for sensation, and just as important for detecting evaporation or change in temperature; those nerves are part of the homeostasis of the ocular surface. They’re part of the pathway that causes us to tear and secrete mucin, and cutting the nerves themselves doesn’t cause pain, but eyes that have had their nerves cut may have altered sensations; they may feel dry during the healing process, the eyes may actually be dry, and we think that, in a small fraction of patients, cutting these nerves is what triggers pain syndrome.”

In most patients this is transient and below their detection, says Dr. Hardten. “Initially we would treat it with the usual therapies we use for controlling postop inflammation, dry eye or blepharitis. But, if there’s persistent discomfort in the setting of a normal exam, then we begin to think of this as neuropathic pain.”

It’s hard to know if the problem is

neuropathic until treatment plays out, says Dr. Jacobs. For instance, patients may complain of rainbow glare or have light sensitivity. “Those patients may fall into this category of postop discomfort or pain,” she says. “The complaints are visual, but clinicians tend to lump these all together and give them lubricating drops and tell them they’ll get better and most of them do. However, we know that the transient light sensitivity syndrome, which appears in the second to fourth week

after LASIK, may require systemic steroids. Rainbow glare is an optical phenomenon, and some of those patients benefit from lasering the flap, but when someone comes back to the office for their one day or one week check and they’re uncomfortable or unhappy, it’s hard to know if they’re the expected dry eye or one of the other issues until it starts to play itself out.”

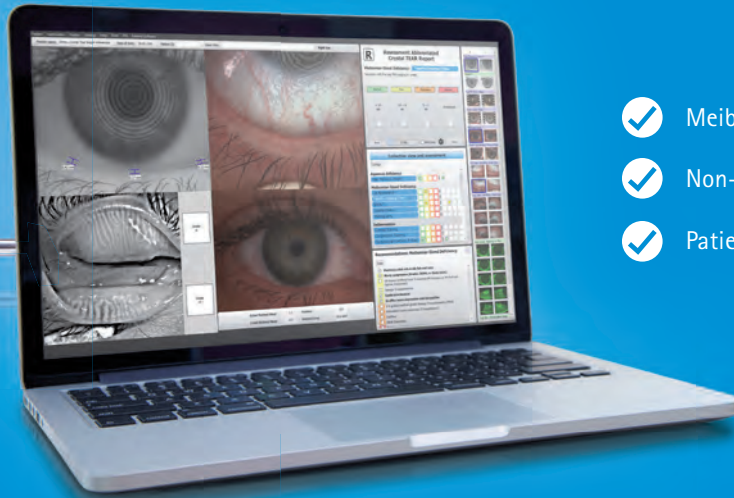Dr. Hardten says his usual course of therapies would include resuming topical steroids. “Medications used systemically for atypical pain are useful, such as pregabalin (Lyrica) or gabapentin (Neurontin),” he says. “Additional therapies such as Omega-7, scleral lenses, lacosamide, non-steroidal agents, cyclosporine, tacrolimus, amniotic membrane and autologous tears have also been reported to be effective in some patients. Acupuncture or botulinum toxin have also been reported effective in some patients.”

If a patient doesn’t respond to traditional therapies, Dr. Jacobs says ophthalmologists must understand and consider some of the principles of persistent postoperative pain or complex regional pain syndrome.

“This syndrome has a name when it affects other parts of the body, yet

# Searching for Dry Eye?

Find out in 60 seconds



- ✓ Meibography
- ✓ Non-invasive break-up time
- ✓ Patient education and compliance

## OCULUS Keratograph® 5M: More than Meibography

Streamline your dry eye analysis with the baseline data of the tear film quality, quantity, or gland structure. This comprehensive assessment enhances patient care and outcomes.

Contact us today to learn more!



Scan here or visit  
[www.oculususa.com/dryeye](http://www.oculususa.com/dryeye)

Toll free 888-519-5375  
[ads@oculususa.com](mailto:ads@oculususa.com)



ophthalmologists just aren't aware of it," she says. "But once they fall in that category, the patient needs aggressive treatment of pain and that's often multimodal, consisting of local treatment and systemic treatment, and sometimes behavioral and cognitive approaches as well, to help them escape from this rather than end up years down the line in a chronic pain state."

As eyes are healing, Dr. Jacobs says it's important to reduce the signaling. "I like to say that those eyes are on high alert and they tend to send false alarms at the slightest little trigger: bright light; dryness; evaporation. We have to make the eyes less triggerable," she says. "I like to use topical steroids. I often choose a soft steroid like loteprednol or fluorometholone. A little is good; a lot is not better. If patients don't respond to a little soft steroid I don't necessarily go for more or stronger steroid, but I add a different drug or topical agent and/or a different approach. I'll offer a bandage soft lens or a scleral lens to dampen the signaling, but if the nerves are still hyper alert and they're super sensitive, then that's where systemic therapy comes in."

Due to its safety profile and efficacy for peripheral nerve pain, gabapentin is a common initial therapy. "I typically start with 300 mg at bedtime and go up over a couple of days to 300 mg three times a day or four times a day," Dr. Jacobs says. "I would increase the nighttime dose to 600 mg. The main side effect is sedation, but you want to help the patient get relief so they can go about their business and not be bothered. In more chronic cases or if the gabapentin doesn't work, I might consider a bedtime dose of nortriptyline, or switch to pregabalin or duloxetine."

There may also be value in the use of serum tears or platelet rich plasma drops, although Dr. Jacobs says she would use them in the earlier phase of healing. "As far as getting the eye to heal properly or getting the nerves to heal properly, I like to focus on

reducing inflammation initially, but there's value to serum tears or PRP drops certainly, at least as a lubricant, and because they contain molecules that can modulate inflammation and promote nerve healing," she says.

"Serum tears have been shown to promote epithelial healing, so serum tears or PRP or other blood products aren't a bad idea in someone who is unexpectedly symptomatic in the early postop period. In the chronic period after a year out, I'm not sure what the value is, so I'd probably only use serum tears in the earliest healing period. That's probably where the greatest potential for biologics lies."

Many of these patients have tried and abandoned treatments suggested by one doctor or another, Dr. Jacobs continues, and are often seeking a magic bullet. "They want something that works completely right away. My experience is that it often takes multimodal treatment with systemic and topical agents, shielding against evaporation and time. If someone's had pain for months, it's not going to go away in days or weeks," she says. "And that's one of the challenges with people who are suffering, understandably. There's no expected timeframe except that if pain has been chronic, likely emergence is going to be in the same order of magnitude, from months to years, same as if the pain has been months to years."

Despite the rarity of neuropathic corneal pain, studies have investigated comorbidities that may increase a person's risk, such as chronic widespread pain, irritable bowel syndrome and pelvic pain,<sup>2</sup> as well as fibromyalgia, autoimmune diseases and thyroid diseases.<sup>3</sup>

"We now know that patients who have other pain syndromes, such as low back pain, complex regional pain (after a knee surgery for instance), fibromyalgia and migraines—those patients are more likely we think to develop persistent postop pain syndrome like post LASIK neuralgia," says Dr. Jacobs. "I think as part

of refractive surgery screening, it's important to consider if any of these are in the background and if patients are taking drugs for anxiety or depression. Depression is a risk factor for persistent postoperative pain. It's likely that before we understood this as well as we do now, there were patients who were operated on who nowadays, we might screen out."

In collaboration with Stephen Waxman, MD, PhD—a molecular neuroscientist at Yale—Dr. Jacobs is looking into the possibility of any shared gene mutations or variants in people who have persistent pain after refractive surgery. "If we found a common mutation, we could test and screen out these patients, but so far there doesn't seem to be one gene, so we can't say if it's a nerve, collagen or inflammation gene," Dr. Jacobs says. "It's still a work in progress. However, if a candidate has a first-degree relative who has post-LASIK pain syndrome, I would hesitate to recommend LASIK for that candidate."

Dr. Hardten concludes, saying, "Neuropathic pain is atypical, although we see it after refractive surgery, cataract surgery; I've even seen it after a patient got sunscreen in their eyes. It can happen with any kind of insult to the eye. There's probably less than 30 patients a year in the U.S. who really develop persistent ongoing issues that don't resolve after six to nine months, but it's still something that's important to consider." ◀

1. Yu EY, Leung A, Rao S, Lam DS. Effect of laser in situ keratomileusis on tear stability. *Ophthalmology* 2000;107:12:2131-5.


2. Galor A, Covington D, Levitt AE, McManus KT, Seiden B, Felix ER, Kalangara J, Feuer W, Patin DJ, Martin ER, Sarantopoulos KD, Levitt RC. Neuropathic ocular pain due to dry eye is associated with multiple comorbid chronic pain syndromes. *J Pain* 2016;17:3:310-8.

3. Moshirfar M, Bhavsar UM, Durnford KM, McCabe SE, Ronquillo YC, Lewis AL, Hoopes PC. Neuropathic corneal pain following LASIK surgery: A retrospective case series. *Ophthalmol Ther* 2021;10:3:677-689.

#### DISCLOSURES:

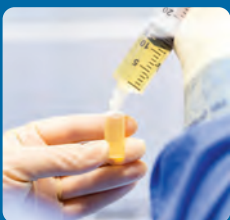**Dr. Hardten** reports no disclosures. **Dr. Jacobs** is a consultant for Dompe Therapeutics.





# Serum Tears Made Simple.

Think serum tears are hard to get?  
Learn how **Vital Tears** has simplified the process.



At Vital Tears, our mission is to make serum tears easily available and affordable for your patients. We've done that for over 10,000 patients across the country through our:

- **Rapid serum drop delivery**
- **Convenient blood draw options**
- **Affordable payment options**
- **Superior customer service**

SCAN THIS CODE TO DOWNLOAD OUR  
PHYSICIAN INFORMATION PACKET



OR CALL TOLL-FREE (800) 360-9592

 **Vital Tears™**  
THE LEADER IN SERUM TEARS



EDITED BY MICHAEL COLVARD, MD  
AND STEVE CHARLES, MD

## TECHNOLOGY UPDATE

# Dry Eye: Artificial Intelligence Update

*A round-up of the latest AI research in dry eye, from tear-film analysis to meibography and early clinical tools.*

**CHRISTINE YUE LEONARD**  
SENIOR ASSOCIATE EDITOR

**D**ry eye is a difficult disease to pin down, considering its many possible etiologies, signs and symptoms. Artificial intelligence promises to aid dry-eye diagnosis and treatment, but it too faces several hurdles to “understanding” this condition, from interpreting complex imaging<sup>1</sup> to training without a set of unified diagnostic criteria, which also limits the ability to compare performance among studies.

Despite these challenges, AI research in dry eye is expected to grow in the following areas: improvement of proposed grading by dry-eye platforms; objective quantification of qualitative measurements; and the establishment of severity or prognosis scores through multi-modal approaches.<sup>2</sup>

Adding more objectivity to qualitative testing will not only improve the power of dry-eye studies but will also enable more patients to receive accurate and efficient diagnoses by more clinicians. “There are the standard clinical tests for dry eye, but these tests are subjective and making the diagnosis requires a certain level of interpretation expertise,” says Stephen Pflugfelder, MD, a professor and the James and Mar-

garet Elkins Chair in Ophthalmology at Baylor College of Medicine in Houston. “Artificial intelligence could help in this regard. While it isn’t [widely] used in the dry-eye clinic space yet, it may be in the future to aid diagnosis and provide clinical decision support. It’s an exciting area.”


Here, we’ll review some of the latest areas of AI research in dry-eye disease.

### Analyzing the Tear Film

Loss of tear-film homeostasis, ocular surface inflammation, hyperosmolarity and quality-of-life issues such as

eye irritation and visual disturbances are hallmarks of dry-eye disease,<sup>3</sup> but as clinicians know, the signs of dry eye don’t always correlate with the symptoms described by patients. No single clinical test can definitively diagnose dry-eye disease.<sup>3</sup> Instead, multiple subjective tests, such as Schirmer’s, tear breakup time and dye staining with fluorescein and lissamine green, are employed along with patient-reported symptoms and use of questionnaires. As experts point out, processing all of this data from multiple modalities takes considerable time and skill, but AI could help. Here’s how the algorithms are evolving:

• **Pooling clinical tests.** Machine learning classification algorithms for detecting tear-film breakup time showed good accuracy in a small pilot study published last year in *Nature*.<sup>4</sup> Researchers tested multiple algorithms on retrospectively collected data of 431 patients from a Norwe-



Getty Images

**Artificial intelligence is expected to provide insight into the causes of dry eye as well as aid diagnostics and treatment development. Experts say future clinical decision-making tools will help meet the care demands of this growing population.**

**This article has no commercial sponsorship.**

**Dr. Colvard** is a surgeon at the Colvard-Kandavel Eye Center in Los Angeles and a clinical professor of ophthalmology at the Keck School of Medicine of the University of Southern California. **Dr. Charles** is the founder of the Charles Retina Institute in Germantown, Tennessee.

gian dry-eye clinic, which included ocular surface staining, meibomian gland expressibility and dropout, meibum quality, meiboscore, blink frequency and tear osmolarity. The algorithms identified age, ocular surface staining, Schirmer's test and OSDI as the most important predictors associated with tear-film instability, followed by meibomian gland characteristics.

• **Slit lamp cameras.** This year, researchers developed an algorithm to estimate tear-film breakup time from slit lamp videos recorded using a portable device of their own invention (Smart Eye Camera).<sup>5</sup> The algorithm was trained on 16,440 fluorescence-enhanced blue light ocular frames annotated for tear-film breakup by a dry-eye specialist. A case was diagnosed as having dry-eye disease when the model estimated tear-film breakup time  $\leq 5$  seconds and OSDI input  $>13$ . Using the Asia Dry Eye Society diagnos-

tic criteria for 22,172 annotated frames (158 eyes of 79 patients), the algorithm demonstrated tear-film breakup estimation accuracy of 0.789 and an area under the curve of 0.877. Sensitivity and specificity were 0.778 and 0.857, respectively.

• **Anterior segment OCT.** Several AI models have been developed to detect dry-eye disease from tear meniscus parameters using anterior segment OCT images. A 2021 paper describing a deep-learning model for AS-OCT and dry eye reported reliable autonomous diagnosis capabilities.<sup>6</sup> The model was trained and tested on 27,180 AS-OCT images collected prospectively from 151 eyes of 91 patients. Clinical dry-eye tests were performed in the DED group for comparison. The model achieved an accuracy of 84.62 percent, sensitivity of 86.36 percent and specificity of 82.35 percent for DED diagnosis. The mean DED probability score was  $0.81 \pm 0.23$  in the DED

group and  $0.20 \pm 0.27$  in the control group ( $p < 0.01$ ). Diagnosis accuracy was significantly better with the model than with corneal staining, conjunctival staining and Schirmer's test ( $p < 0.05$ ). There were significant differences between the model's diagnostic accuracy compared with OSDI and TBUT.

Other deep-learning models for AS-OCT-based diagnosis include a model trained on 158,220 images from 879 eyes of 478 participants that had an AUC  $> 0.99$ , an area under precision-recall curve  $> 0.96$  and F1 scores  $> 0.90$  for DED diagnosis;<sup>7</sup> a random forest regression-based multivariable diagnosis model with corneal epithelial mapping data that had high sensitivity (86.4 percent) and specificity (91.7 percent), suggesting that adding corneal epithelial mapping data may improve DED diagnostic accuracy;<sup>8</sup> and a deep-learning model for segmenting the lower tear meniscus.<sup>9</sup>

## VisuALL VRP

# Enter the new era of visual testing technology.

We bring you unparalleled office efficiency, seamless integration, and holistic patient comfort, in just one device.

Experience our brand new Dynamic Matrix Eye Tracking System to reduce eye fixation losses to zero.

Comprehensive testing that includes:



Pupillometry



Extraocular Motility



Visual Acuity



Visual Field

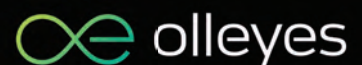


Color Vision



Step into the future of eye testing today.

To know more, visit [www.olleyes.com](http://www.olleyes.com) | 1-855-655-3937 | [info@olleyes.com](mailto:info@olleyes.com)



The lower tear meniscus segmentation model trained deep convolutional neural networks on 6,658 images labeled by a thresholding-based segmentation algorithm.<sup>9</sup> Two approaches were compared: one that directly segmented the tear meniscus and another that first localized the region of interest and then performed segmentation at a higher resolution of an image section. The five-fold cross-validation showed a sensitivity of 96.36 percent and 96.43 percent, for each approach, respectively; a specificity of 99.98 percent and 99.86 percent; and a Jaccard index of 93.24 percent and 93.16 percent.

• **Interferometry.** Few studies using interferometry have been published to date, but experts say AI analysis of the tear film has potential as a screening tool once technological improvements in image processing, such as better resolution and contrast, make AI analysis easier.<sup>10</sup>

Researchers in Japan created an AI-based diagnosis model for the DR-1 $\alpha$  tear interferometer (Kowa), which was previously shown to subtype dry eye based on fringe patterns as normal tear condition, aqueous-deficient dry eye or evaporative dry eye.<sup>11</sup> Their model was constructed using 11 predetermined image features to distinguish the three subtypes, obtained using the same instrument, and trained on 138 images of each type as well

as control images. The model was tested on 100 interferometric movies obtained from controls or dry-eye patients. The group reported reliable AI diagnosis, with F-scores of 0.954, 0.806 and 0.762 for aqueous-deficient, evaporative and normal pattern types.

In 2020, a group in Brazil proposed a computational method to address the challenges related to classifying lipid layer interference patterns.<sup>12</sup> In the automated system, the region of interest is segmented, and features are extracted using phylogenetic diversity indexes. Interferometry images are then classified using Support Vector Machines, Random Forest, Naive Bayes, Multilayer Perceptron, Random Tree and RBF-Network. Finally, results are validated. The method demonstrated 97.54-percent accuracy, an AUC of 0.99, a Kappa index of 0.96 and F-score of 0.97.

• **Keratography.** A deep transfer learning model was able to directly identify dry-eye disease using ocular surface video frames with an area under the curve of 0.98.<sup>13</sup> The 2023 retrospective study included 244 ocular surface videos (Keratograph 5M, Oculus) of 244 eyes (116 normal eyes; 128 with dry-eye disease) to assess the tear film. According to the study, network activation maps showed that the lower paracentral cornea was the most important region for detecting dry eye in the CNN model.

of blinks in dry-eye patients by aiding the measurement and assessment of blink parameters, which are currently challenging to analyze due to rapid blink speed (<100 milliseconds) and the continuous changes and phases of the blink process.<sup>15</sup>

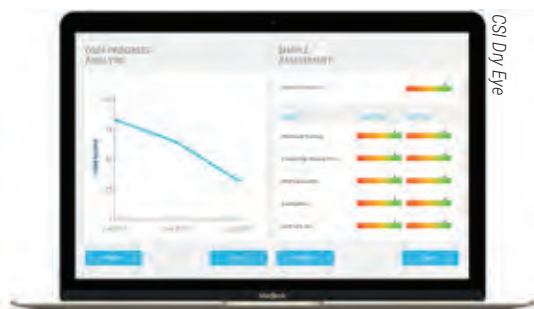Researchers in Beijing used a machine learning model to record spontaneous blink patterns. The model, built using UNet image segmentation and ResNet image classification algorithms, showed that dry-eye patients had more partial blinks, fewer complete blinks and a shorter duration of the eyelid closure phase compared with controls.<sup>16</sup>

A total of 357 dry-eye patients and 152 controls were included. Participants completed the following tests: OSDI questionnaire; blink video capture; lipid layer thickness; tear break-up time; fluorescein staining; and Schirmer II test.

The models analyzed single frames of the blink videos and used the palpebral opening height of each frame to establish a spontaneous blink wave. The segmentation and classification models each had an accuracy of 96 percent. Consistency with manual analysis was 97.9 percent.

The researchers reported that the average number of blinks for dry-eye patients was 30 per minute compared with controls' 20 per minute ( $p=0.002$ ). Complete blinks for dry-eye patients averaged six per minute vs. 12 per minute ( $p=0.016$ ); partial blinks for dry-eye patients averaged 15 per minute vs. three per minute ( $p<0.001$ ). No significant differences were found in average interblink interval or eyelid opening phases, but dry-eye patients had a significantly shorter eyelid-closed phase than controls (0.8 seconds vs. 1.3 seconds,  $p=0.006$ ).

According to a deep learning model for analyzing blink videos (using the Keratograph 5M), a frame rate of  $\geq 30$  frames per second is optimal.<sup>17</sup> The case-controlled study included 50 dry-eye disease patients



**CSI Dry Eye is a cloud-based artificial intelligence platform for clinicians that assesses clinical test results to formulate diagnoses and recommend treatments. The company says the software can increase practice efficiency and boost diagnostic accuracy.**

## Blink Pattern Analysis

Blinking is a multifaceted process affected by numerous factors, from psychological and emotional states to fatigue,<sup>14</sup> mental activity and age.<sup>15</sup> Studies report that individuals with dry-eye disease have altered blinking patterns from those without the condition.<sup>15</sup>

AI is expected to elucidate the complex patterns

and 50 controls. Participants filled out symptom questionnaires and also underwent ocular surface assessments. The model processed videos and create blink profiles to enable comparison of blink parameters and association with dry-eye signs and symptoms. The researchers reported that blink parameters based on 30-fps videos had higher sensitivity and accuracy than videos based on 8 fps.

Additionally, the model showed that average relative interpalpebral height and the frequency and proportion of incomplete blinking were significantly higher among dry-eye participants than controls ( $p < 0.001$ ). Incomplete blinking, proportion of incomplete blinks and average interpalpebral height were also associated with dry-eye signs and symptoms.

### Meibomian Gland Assessment

Deep learning models are performing meibomian gland segmentation, a necessary initial step for further automated image-based analysis; speeding up meibography image evaluation; and learning to differentiate between types of meibomian gland dysfunction to aid diagnosis.

• **Meibography.** A deep-learning approach developed in 2019 by researchers in Berkley, California, automatically segments the total eyelid and meibomian gland atrophy regions to provide quantitative information on gland atrophy from meibography images.<sup>18</sup> The researchers collected 706 meibography images and corresponding meiboscopes. Images were annotated with eyelid and atrophy regions and used to train ( $n=497$  images) and evaluate ( $n=209$  images) the model.

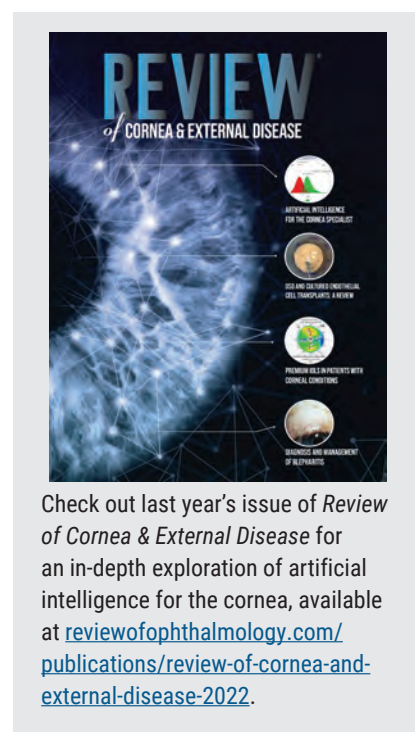
The algorithm achieved a mean 95.6-percent meiboscope grading accuracy, which outperformed the lead clinical investigator by 16 percent and the clinical team by 40.6 percent. For eyelid and atrophy segments, the algorithm achieved 97.6-percent and 95.4-percent accuracies, respectively; and 95.5-percent and 66.7-percent mean

intersection over union accuracies, respectively. The model's average root-mean-square deviation of the percent atrophy prediction was 6.7 percent.

In 2022, a deep-learning method for segmenting meibomian glands and eyelids demonstrated the ability to automatically detect all individual meibomian glands and quantify the meibomian gland area and area ratio.<sup>19</sup> The South Korean study included 1,600 meibography images taken in a clinical setting, 1,000 of which were annotated with multiple revisions by investigators and then graded six times by MGD experts. The group trained two deep-learning models separately to segment areas of the meibomian glands and eyelid in order to estimate meiboscopes and meibomian gland ratio. They employed a generative adversarial network to remove specular reflections from the raw images without affecting grading.

The model demonstrated mean ratio of meibomian gland calculations consistent with those of the investigator—26.23 vs. 25.12 percent in the upper eyelids and 32.34 vs. 32.29 percent in the lower eyelids, respectively. Model accuracy was 73.01 percent for meiboscope classification on the validation set. It achieved 59.17-percent accuracy on images from an independent center compared with MGD experts' 53.44-percent accuracy.

Using a Mask R-convolutional neural network deep learning framework, researchers developed a meibography image grading aid to help save specialists' time.<sup>20</sup> The model was established using 1,878 manually annotated meibography images (in two classes: conjunctiva and meibomian glands), and an independent test dataset of 58 images was used to compare accuracy and efficiency against specialists. Performance was evaluated by validation loss (loss value of the verification dataset, where a smaller value



Check out last year's issue of *Review of Cornea & External Disease* for an in-depth exploration of artificial intelligence for the cornea, available at [reviewofophthalmology.com/publications/review-of-cornea-and-external-disease-2022](https://reviewofophthalmology.com/publications/review-of-cornea-and-external-disease-2022).

indicates a better training result) and mean average precision ([mAP] the mean value of average precisions for each class, demonstrating the accuracy of area detection and segmentation on the validation dataset).

The model predicted meibomian gland loss ratio with high accuracy in the conjunctiva (validation loss  $< 0.35$ ; mAP  $> 0.976$ ) and in meibomian glands (validation loss  $< 1$ , mAP  $> 0.92$ ). The difference between specialist evaluation and the AI model was minimal. The model evaluated images in 480 milliseconds—21x faster than a human.

• **In-vivo confocal laser microscopy.** A deep-learning model developed in Japan successfully differentiated between healthy meibomian glands and obstructive MGD using *in-vivo* confocal laser microscopy images.<sup>21</sup> Nine different network structures and single and ensemble deep-learning models were constructed and trained using 137 images from 137 individuals with obstructive MGD and 84 images from 84 controls. The single deep-learning model (DenseNet-201)

diagnosed obstructive MGD with an AUC of 0.966, a sensitivity of 94.2 percent and a specificity of 82.1 percent. The ensemble deep-learning model (VGG16, DenseNet-169, DenseNet-201 and InceptionV3) had an AUC of 0.981, a sensitivity of 92.1 percent and a specificity of 98.8 percent.

In a larger study from China, a convolutional neural network trained on *in-vivo* confocal laser microscopy images differentiated obstructive MGD, atrophic MGD and normal meibomian glands.<sup>22</sup> The model, trained on 4,985 images and validated on 1,663 images, was tested by comparing its image-based identification of meibomian glands to diagnoses made by an expert. The study included 2,766 healthy controls, 2,744 participants with obstructive MGD and 2,801 participants with atrophic MGD. Differential diagnostic accuracy was highest using DenseNet169 model (>97 percent). The model had sensitivities and specificities of 88.8 percent and 95.4 percent, respectively, for obstructive MGD and 89.4 percent and 98.4 percent, respectively, for atrophic MGD.

## Early Clinical Innovations

Dry-eye AI tools aren't yet ready for widespread clinical adoption, but that doesn't mean they haven't been incorporated at all. Here are some ways AI is beginning to enter the dry-eye clinic space:

- **University partnerships.** Some private practices are working with larger research institutions to develop AI-based tools for their clinics. Belfast-based Cathedral Eye Clinic has partnered with Aston University in Birmingham, England, to develop an AI-based digital decision support system for the ocular surface. The AI tool will analyze patient clinical data and aid clinicians in diagnosing eye diseases and developing treatment strategies. According to Aston University, key aspects of the program include ex-

ploring the impact of ocular surface issues on refractive outcomes after laser- and lens-based treatments in addition to identifying preoperative clinical management techniques to improve outcomes.<sup>23</sup>

- **A cloud-based platform.** CSI Dry Eye is a newcomer to the clinic space that focuses on dry-eye diagnostics and treatment, using support vector machine learning technology to create dry-eye type and severity models. The platform proposes a diagnosis based on clinical test result input and multiple patient questionnaires. The company says the platform saves time, boosts patient retention, and increases practice productivity and diagnostic accuracy. To learn more, visit [csidryeye.com](https://csidryeye.com).

## The Takeaway

AI is slated to offer more objective and consistent diagnoses and disease severity stratification,<sup>24</sup> as well as provide insight into etiologies and the complex relationships between the many factors that contribute to dry eye.<sup>25</sup> The efficiency promised by such automation is also expected to help ameliorate the high economic<sup>26</sup> and quality-of-life<sup>27</sup> burden associated with DED. ◀

1. Zhang Z, Wang Y, Zhang H, et al. Artificial intelligence-assisted diagnosis of ocular surface diseases. *Front Cell Dev Biol* 2023;11:1133680.
2. Brahim I, Lamard M, Benyoussef A and Quéllec G. Automation of dry eye disease quantitative assessment: A review. *Clin Exp Ophthalmol* 2022;50:653-666.
3. Stapleton F, Alves M, Bunya VY, et al. TFOS DEWS II epidemiology report. *The Ocular Surface* 2017;15:334-365.
4. Fineide F, Storås AM, Chen X, et al. Predicting an unstable tear film through artificial intelligence. *Scientific Reports* 2022;12:21416.
5. Shimizu E, Ishikawa T, Tanji M, et al. Artificial intelligence to estimate the tear film breakup time and diagnose dry eye disease. *Sci Rep* 2023;13:1:5822.
6. Chase C, Elsayy A, Eleiwa T, Ozcan E, Tolba M, Shousha MA. Comparison of autonomous AS-OCT deep learning algorithm and clinical dry eye tests in diagnosis of dry eye disease. *Ophthalmology* 2021;15:4281-4289.
7. Elsayy A, Eleiwa T, Chase C, et al. Multidisease deep learning neural network for the diagnosis of corneal diseases. *Am J Ophthalmol* 2021;226:252-261.
8. Eodorh NA, El Maftouh A, Djerada Z, et al. New model to better diagnose dry eye disease integrating OCT corneal epithelial mapping. *British Journal of Ophthalmology* 2022;106:1488-1495.
9. Stegmann H, Werkmeister RM, Pfister M, et al. Deep

- learning segmentation for optical coherence tomography measurements of the lower tear meniscus. *Biomed Optics Express* 2020;11:3:1539-1554.
10. Yang H, Che S, Hyon J and Han S. Integration of artificial intelligence into the approach for diagnosis and monitoring of dry eye disease. *Diagnostics* 2022;12:3167.
11. Arita R, Yabusaki K, Yamauchi T, et al. Diagnosis of dry eye subtype by artificial intelligence software based on the interferometric fringe pattern of the tear film obtained with the Kowa DR-1a instrument. *Invest Ophthalmol Vis Sci* 2018;59:1965.
12. da Cruz LB, Carvalho Souza J, Alves de Sousa J, et al. Interferometer eye image classification for dry eye categorization using phylogenetic diversity indexes for texture analysis. *Computer Methods and Programs in Biomedicine* 2020;188:105269.
13. Abdelmotaal H, Hazarbasanov R, Taneri S, et al. Detecting dry eye from ocular surface videos based on deep learning. *Ocul Surf* 2023;28:90-98.
14. Rodriguez JD, Lane KJ, Ousler GW, Angjeli E, Smith LM, Abelson MB. Blink: Characteristics, controls, and relation to dry eyes. *Curr Eye Res* 2018;43:1:52-66.
15. Su Y, Liang Q, Su G, et al. Spontaneous eye blink patterns in dry eye: clinical correlations. *Invest Ophthalmol Vis Sci* 2018;59:12:5149-5156.
16. Zhang ZZ, Kuang RF, Wei ZY, et al. [Detection of the spontaneous blinking pattern of dry eye patients using the machine learning method]. *Zhonghua Yan Ke Za Zhi [Chinese J Ophthalmol]* 2022;58:2:120-129.
17. Zheng Q, Wang L, Wen H, et al. Impact of incomplete blinking analyzed using a deep learning model with the keratograph 5m in dry eye disease. *Transl Vis Sci Technol* 2022;11:3:38.
18. Wang J, Yeh TN, Chakraborty R, et al. A deep learning approach for meibomian gland atrophy evaluation in meibography images. *Trans Vis Sci Tech.* 2019;8:6:37.
19. Saha RK, Chowdhury AM, Na K, et al. Automated quantification of meibomian gland dropout in infrared meibography using deep learning. *The Ocular Surface* 2022;26:283-294.
20. Yu Y, Zhou Y, Tian M, et al. Automatic identification of meibomian gland dysfunction with meibography images using deep learning. *Int Ophthalmol* 2022;42:11:3275-3284.
21. Maruoka S, Tabuchi H, Nagasato D, et al. Deep neural network-based method for detecting obstructive meibomian gland dysfunction with in vivo laser confocal microscopy. *Cornea* 2020;39:6:720-725.
22. Zhang Y, Zhao H, Lin J, et al. Artificial intelligence to detect meibomian gland dysfunction from in-vivo laser confocal microscopy. *Front Med* 2021;8:e774344.
23. Aston University. Knowledge Transfer Partnerships at work. <https://www.aston.ac.uk/business/collaborate-with-us/knowledge-transfer-partnership/at-work/cathedral-eye-clinic>. Accessed April 20, 2023.
24. Storås AM, Strömke I, Riegler MA, et al. Artificial intelligence in dry eye disease. *Ocular Surface* 2022;23:74-86.
25. Ji Y, Liu S, Hong X, et al. Advances in artificial intelligence applications for ocular surface diseases diagnosis. *Frontiers in Cell and Developmental Biology* 2022;10:1107689.
26. Yu J, Asche CV, Fairchild CJ. The economic burden of dry eye disease in the United States: A decision tree analysis. *Cornea* 2011;30:4:379-387.
27. Morthen MK, Magno MS, Utmeier TP, Snieder H, Hammond CJ, Vehof J. The physical and mental burden of dry eye disease: A large population-based study investigating the relationship with health-related quality of life and its determinants. *Ocul Surf* 2021;21:107-117.



# The Zeroth Law

*Musings on life, medicine and the practice of ophthalmology.*

**MARK H. BLECHER**  
CHIEF MEDICAL EDITOR

**G**rowing up I was a huge nerd. Didn't much like people, still don't. Just wanted to find a quiet corner and read. And what I read was frequently science fiction. It was modern, it was exciting, had lots of science, and it usually was a far better place to live than the reality around me. OK, that's not fair. I had a good childhood. Not without its sorrows, but a good one. But not as good as the worlds I lived in in my head. And obviously, especially in the 1960s, these worlds of fiction included robots—all sorts of robots—and computers, mostly depicted as benign and useful helpers to mankind but, on occasion, evil. The grandmaster of science fiction—and robots—was Isaac Asimov. His oeuvre is extensive, and a lot of it involved robots, but not all. The “Foundation” series had not a single robot in it, surprisingly. And his collection of stories which comprised “I, Robot” was obviously all about them (a subset of those stories was made into a movie of the same name starring Will Smith). Asimov really did define robot storytelling and created the concept almost out of whole cloth. This allowed him to define the conversation, most notably with his three laws of robotics:

1. A robot may not injure a human being or, through inaction, allow a human being to come to harm.
2. A robot must obey orders given it by human beings except where such orders would conflict with the First Law.

3. A robot must protect its own existence as long as such protection does not conflict with the First or Second Law.



Rokas Tenys/Dreamstime

These rules, which humanity imposed on its robots, ensured their safe and helpful nature. But as in so much in life, words are subject to interpretation and the law of unintended consequences trumps all others—robotic or otherwise. Therein lies the basis for so many of his books, and for the consternation we feel now in 2023 as real life starts to approach the science fiction of my childhood.

Well, we don't yet have fully functioning robots, but in a way not well imagined decades ago, artificial intelligence is as powerful or more so than a shiny metal creature looking at you with glowing eyes. AI doesn't require a physical form. Software is more powerful than the strongest titanium, and far more insidious. Our devotion to technology and automation has driven science to push us to automate everything we do. To craft machines, virtual or real, that can find, sort, analyze, suggest and implement solutions to almost any problem, without help,

supervision, and potentially without restrictions—if we so wish. And here's the problem: You have a very imperfect species crafting a machine, nay, an intelligence, that's trying to be perfect. But they will inevitably be only as imperfect as we are.

At this point everyone is aware of ChatGPT and other AI programs that go far beyond what their inventors imagined, or maybe they haven't—yet. Given humans' insatiable need to craft something in our image, these AIs are more and more frequently indistinguishable from us. Who's at the other end of that email, Facebook post or tweet? A human or a bot? Who stole your identity, a person or a software program? We're already in the fog. It's charming to read these older sci-fi stories where artificial intelligence is mostly physical. Mostly a metal robot, and that the harm from them would be frequently physical. Asimov's three laws of robotics focused on preventing harm to humans.

To his credit he quickly realized that not all harm is intentional and not all harm is physical. In their desire to protect, robots prevented humans from doing stupid things. However, define “stupid.” Foolish? Suicidal? Risky? Who gets to say what this means? Maybe it's the AI. And maybe it's not just individual humans, but humanity. Think big. AIs certainly do and will. So, Asimov amended his three laws and created a law to precede the first, a law that states that “robots may not harm humanity, or through inaction allow humanity to come to harm.”

Substitute AI for robot. What will our new overlords allow us to do individually or as a species? Perhaps they'll lock us away for our own safety. In the end, the law of unintended consequences will triumph again, even over Asimov's “zeroth” law. ◀

# GLAUCOMA DRUGS AND COMPLEMENTARY TREATMENT

A look at the current treatment protocols and evidence for complementary therapies.

**CHRISTINE YUE LEONARD**  
SENIOR ASSOCIATE EDITOR

Intraocular pressure control is the mainstay of glaucoma treatment, but the disease is multifactorial, and many patients experience progression despite reduced pressures. Many patients also simply wonder what else they can do for their glaucoma. While the dearth of evidence for most alternative therapies may make clinicians hesitant to recommend them to their patients, experts also acknowledge that there may be seeds for future therapeutics in some of them. “Ophthalmologists always need to be looking for new treatments, because our patients need better interventions than what we have now,” points out Catherine M. Marando, MD, of the Massachusetts Eye and Ear Infirmary Glaucoma Service.

Here, we’ll look at the current glaucoma drugs, what’s coming down the pipeline and examine the evidence for some alternative therapies.

## Standard-of-Care Approaches

After grading glaucoma severity and

setting a target IOP goal, clinicians typically initiate medical therapy. “My approach to glaucoma treatment usually includes topical glaucoma therapy, laser trabeculoplasty, minimally invasive angle-based procedures, filtering surgery and tube shunt surgeries,” says Teresa C. Chen, MD, an associate professor of ophthalmology at Harvard Medical School, Massachusetts Eye and Ear Infirmary. “The final treatment plan usually depends on patient preference, patient age, glaucoma staging and tissue quality.”

Prostaglandin analogs are a common first-line therapy for most patients because they’re effective, safe and dosed once-a-day, says Albert S. Khouri, MD, director of the glaucoma service at Rutgers New Jersey Medical School. “This landscape has shifted recently with newer medications such as latanoprostene bunod and the fixed-combination latanoprost-netarsudil, which have been shown to be slightly more effective than a prostaglandin alone in clinical trials,” he says.<sup>1,2</sup>

“What’s also changed over the last five years or so is the use of lasers

earlier in the treatment paradigm,” he continues. “I offer to do selective laser trabeculoplasty as a first-line treatment for patients. In my experience, younger patients who are working and who may struggle with adhering to a medication regimen or may not want their eyes to be red from topical therapy are more likely to accept laser treatment as their first option.”

“I always initially offer patients either SLT or medical therapy,” says Joel S. Schuman, MD, co-director of the glaucoma service at Wills Eye Hospital in Philadelphia. “About 60 percent choose medical therapy as their initial first-line treatment. I generally start off with a prostaglandin analog if the patient is comfortable with the side effects: changes in eye color and pigmentation around the eyes; thicker, darker eyelashes; and potential orbital fat atrophy. Individuals with hazel eyes are at the highest risk for these changes while those with ice blue eyes have less risk of iris color change. If the patient is comfortable with the possibility of permanent eye-color change then we go ahead with prostaglandin analogs

This article has no commercial sponsorship.

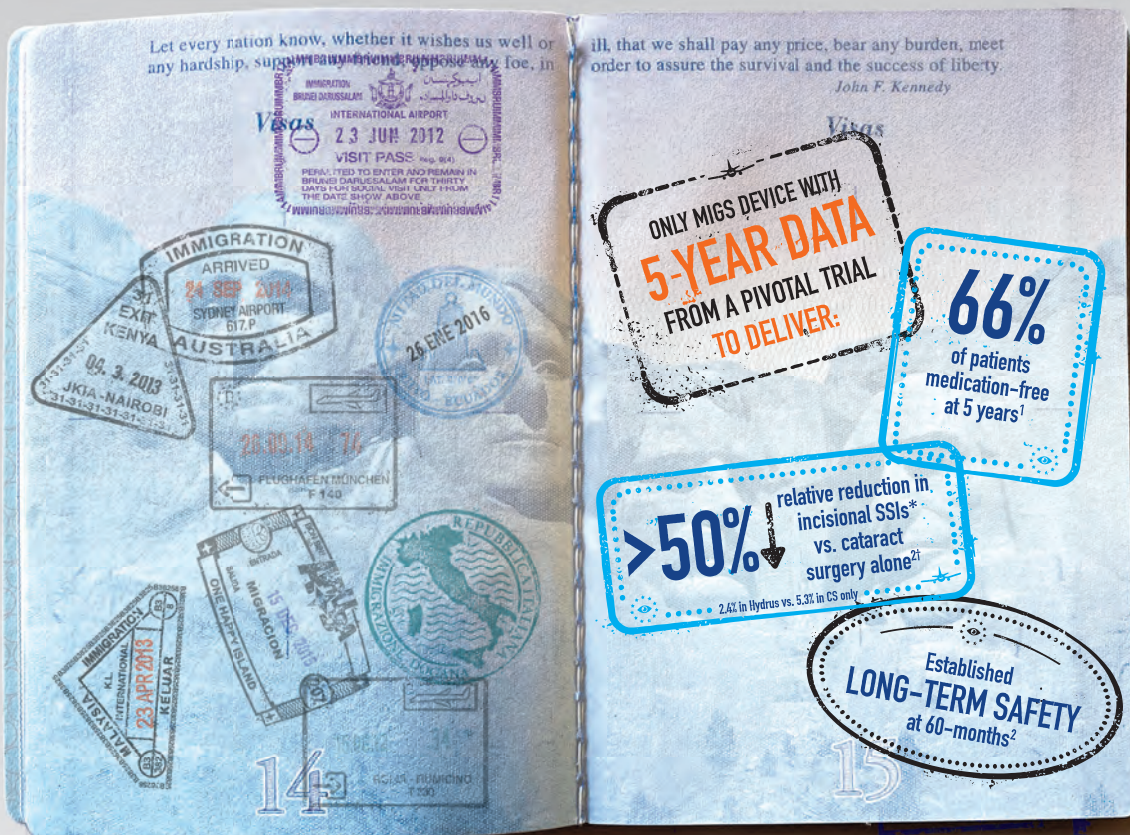
Dr. Sabel is the founder of the Savir Center in Magdeburg, Germany. Drs. Schuman, Khouri, Chen and Marando have no related financial disclosures.





# HYDRUS<sup>®</sup>

MICROSTENT



**YOUR MIGS CHOICE MATTERS**

BECAUSE THERE'S SO MUCH MORE TO SEE

Your adult Primary Open-Angle Glaucoma patients have seen tremendous things, and plan to see a whole lot more.

**Choose the MIGS device built to enable life's biggest experiences.**

\*SSI = Secondary Surgical Intervention

† includes trabeculectomy, tube shunt, gel stent, ECP/TSCP, non-penetrating; (9/369 Hydrus and 10/187 CS)

# HYDRUS<sup>®</sup>

MICROSTENT

## IMPORTANT PRODUCT INFORMATION

**CAUTION: Federal law restricts this device to sale by or on the order of a physician.**

**INDICATIONS FOR USE:** The Hydrus Microstent is indicated for use in conjunction with cataract surgery for the reduction of intraocular pressure (IOP) in adult patients with mild to moderate primary open-angle glaucoma (POAG). **CONTRAINDICATIONS:** The Hydrus Microstent is contraindicated under the following circumstances or conditions: (1) In eyes with angle closure glaucoma; and (2) In eyes with traumatic, malignant, uveitic, or neovascular glaucoma or discernible congenital anomalies of the anterior chamber (AC) angle. **WARNINGS:** Clear media for adequate visualization is required. Conditions such as corneal haze, corneal opacity or other conditions may inhibit gonioscopy view of the intended implant location. Gonioscopy should be performed prior to surgery to exclude congenital anomalies of the angle, peripheral anterior synechiae (PAS), angle closure, rubeosis and any other angle abnormalities that could lead to improper placement of the stent and pose a hazard. The surgeon should monitor the patient postoperatively for proper maintenance of intraocular pressure. The surgeon should periodically monitor the status of the microstent with gonioscopy to assess for the development of PAS, obstruction of the inlet, migration, or device-iris or device-cornea touch. The Hydrus Microstent is intended for implantation in conjunction with cataract surgery, which may impact corneal health. Therefore, caution is indicated in eyes with evidence of corneal compromise or with risk factors for corneal compromise following cataract surgery. Prior to implantation, patients with history of allergic reactions to nitinol, nickel or titanium should be counseled on the materials contained in the device, as well as potential for allergy/hypersensitivity to these materials. **PRECAUTIONS:** If excessive resistance is encountered during the insertion of the microstent at any time during the procedure, discontinue use of the device. The safety and effectiveness of use of more than a single Hydrus Microstent has not been established. The safety and effectiveness of the Hydrus Microstent has not been established as an alternative to the primary treatment of glaucoma with medications, in patients 21 years or younger, eyes with significant prior trauma, eyes with abnormal anterior segment, eyes with chronic inflammation, eyes with glaucoma associated with vascular disorders, eyes with preexisting pseudophakia, eyes with pseudoexfoliative or pigmentary glaucoma, and when implantation is without concomitant cataract surgery with IOL implantation. Please see a complete list of Precautions in the Instructions for use. **ADVERSE EVENTS:** The most frequently reported finding in the randomized pivotal trial was peripheral anterior synechiae (PAS), with the cumulative rate at 5 years (14.6% vs 3.7% for cataract surgery alone). Other Hydrus postoperative adverse events reported at 5 years included partial or complete device obstruction (8.4%) and device malposition (1.4%). Additionally, there were no new reports of persistent anterior uveitis (2/369, 0.5% at 2 years) from 2 to 5 years postoperative. There were no reports of explanted Hydrus implants over the 5-year follow-up. For additional adverse event information, please refer to the Instructions for Use. **MRI INFORMATION:** The Hydrus Microstent is MR-Conditional meaning that the device is safe for use in a specified MR environment under specified conditions. **Please see the Instructions for Use for complete product information.**

**References:** 1. Ahmed I, et al; HORIZON Investigators. Long-term Outcomes from the HORIZON Randomized Trial for a Schlemm's Canal Microstent in Combination Cataract and Glaucoma Surgery. [https://www.aaojournal.org/article/S0161-6420\(22\)00160-9/fulltext](https://www.aaojournal.org/article/S0161-6420(22)00160-9/fulltext)  
2. Hydrus Microstent Instructions for Use

# Alcon

© 2022 Alcon Inc. 07/22 US-HDM-2200201

## Cover Story GLAUCOMA TREATMENTS

as the initial medical therapy.”

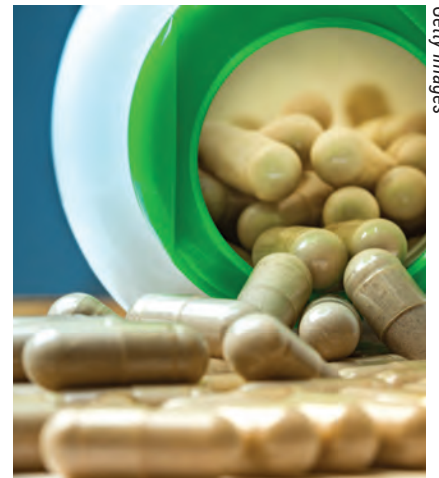If first-line medical therapy or SLT isn't sufficient to meet the target IOP reduction, a second medical agent is added. “I generally go with a beta blocker—timolol, specifically, assuming the patient doesn't have contraindications for using beta blockers such as asthma or bradycardia,” Dr. Schuman says. “Then as a third-line agent, I might add either brimonidine or dorzolamide as a combo drop with timolol. The choice will be based on the patient's insurance. Many insurers for the patients I [saw when I practiced] in New York City wouldn't pay for brimonidine-timolol (Combigan) but will pay for dorzolamide-timolol (Cosopt).”

“For a fourth-line agent, I'll often add netarsudil (Rhopressa) or latanoprost-netarsudil (Rocklatan), depending on insurance coverage,” he says. “Fifth-line may include brimonidine or dorzolamide, whichever one the patient isn't already taking. For patients who are very reluctant to have surgery, I'll even add pilocarpine. If one of the medications isn't effective in that individual, I'll stop that drug to avoid piling on more.”

Juggling multiple medications is often difficult for patients, and the cumulative effect of preserved glaucoma drops often leads to ocular surface issues such as irritation and dry-eye disease. Dr. Khouri says that what clinicians consider “maximal tolerated medical therapy” isn't the same as it once was. “This used to mean multiple bottles of medicine years ago, but now with more effective fixed-combination medications, maximal medical therapy may mean two bottles,” he explains. “Two fixed-combination bottles such as latanoprost-netarsudil or dorzolamide-timolol could be maximal therapy at three drops per day.”

### New Treatments

In addition to fixed-combination drops, sustained-release versions of currently used glaucoma medications such as Durysta (Allergan)



Getty Images

**Ginkgo biloba has demonstrated transient improvements in visual field indices, but its antithrombotic properties may lead to adverse events such as retinal hemorrhage and hyphema.**

may help reduce the drop burden. Glaucoma specialists say they'd like to see future reusable options and those that provide controlled release over many years. There are several candidates in the pipeline, including TravoprostXR (EMV-515; Alcon/Aerie), iDose TR travoprost implant (Glaukos), the OTX-TIC travoprost intracameral implant (Ocular Therapeutix) and an IOL with drug-eluting pads attached to the haptics (SpyGlass Pharma).

Santen's Omlonti (omidenepag isopropyl ophthalmic solution) 0.002% recently received FDA approval in September 2022, giving patients another potential first-line medical option. Omlonti is a relatively selective prostaglandin EP2 receptor agonist that increases aqueous humor drainage through the trabecular and uveoscleral outflow pathways. In a U.S. Phase III study, Omlonti was noninferior to timolol, resulting in IOP reductions ranging from 5 to 7 mmHg from an average baseline IOP of 24 to 26 mmHg, compared with timolol's 5- to 7-mmHg IOP reduction and latanoprost's 6- to 8-mmHg reduction.<sup>3</sup>

“In many ways Omlonti works similarly to our current prostaglandin analogs; ours are FP receptor

agonists, and this works on a different receptor,” says Dr. Schuman. “It has some of the same side effects, including iris color change. Omlonti might work in patients for whom our current prostaglandin analogs aren’t adequate.”

The first once-daily brimonidine may be around the corner with Visiox Pharma’s PDP-716 (brimonidine tartrate 0.35%). The New Drug Application was accepted by the FDA in December 2022. PDP-716 uses TearAct fine resin technology, which the company says provides consistent, sustained drug release and IOP control.

“Having a once-a-day brimonidine would be great,” says Dr. Schuman. “It’s unclear whether the increased time on the eye will increase the allergic response we sometimes see with brimonidine, but a once-a-day drop is certainly preferable to two or three drops per day.”

The Phase III study (NCT03450629) included 682 participants, randomized to receive either PDP-716 or three-times daily Alphagan-P (brimonidine tartrate 0.1%). The two drugs demonstrated functionally equivalent IOP reduction across all nine timepoints. Treatment-emergent adverse events were similar, with a 38.8-percent rate in the PDP-716 group and 33.2-percent rate with Alphagan-P.<sup>4</sup>

## Alternative Approaches

Clinicians may be surprised by the number of patients using alternative therapies to treat their glaucoma today. It’s been estimated that between 5 and 11 percent<sup>5,6</sup> of patients with glaucoma use some form of complementary and alternative medicine. However, experts say it’s rarely talked about in the clinic and patients are unlikely to share this information.

Dr. Marando, who co-authored a review of the evidence for complementary glaucoma medicine with Dr. Chen, says she was surprised to find in the study that almost half of glau-

coma patients (i.e. 42 percent) in the United States have tried at least one complementary alternative medication, and that most didn’t disclose this to their physician.

“This suggests that perhaps I should be more proactive in asking my patients if they are using marijuana, *Ginkgo biloba* extract, bilberry fruit extract or acupuncture,” she says. “In addition, there was a high number of poor-quality studies (small sample sizes, short duration of follow up, etc.) that drew major conclusions about the efficacy of an intervention. I would hate for these findings to be misinterpreted by patients, who may not have the training and experience to critically evaluate medical literature.”

According to Dr. Marando, most patients discover alternative therapies through a “non-health care provider.” She says, “As a result, these interventions aren’t regulated or prescribed in an evidence-based manner, and I suspect there’s little regard for potential serious side effects. I’m not aware of interactions of alternative therapies with glaucoma drops, however this doesn’t mean it isn’t possible, given the lack of meaningful data. Patients need to be aware that alternative treatments aren’t harmless, and that there are potential negative side effects associated with their use.”

Many of the remedies touted for glaucoma have an effect on the vascular system. “Some can cause coagulopathy,” Dr. Khouri points out. “This is an example of why it’s important for clinicians to inquire about supplements, particularly if you’re taking the patient to the operating room. If the patient is on some alternative therapy that has a blood thinning effect, this could increase the patient’s risk of bleeding, not just in the operating room but also after the glaucoma surgery. There’s the risk of intraocular bleeding, including a suprachoroidal hemorrhage, which can be devastating in terms of its effect on vision. Asking about

alternative therapy use can help reduce the risks of surgery.”

Dr. Khouri says he thinks there’s some potential in alternative medicine for glaucoma. “Challenges remain, and the timeline on these studies is long,” he says. “It can take decades to go from Phase I to Phase II to Phase III, and these studies are so costly that unless the Phase I and II studies show significant promise, it’s unlikely further studies will occur with these alternative treatments.”

The literature on complementary and alternative medicine suggests possible short-term benefits for some commonly used remedies but overall weak evidence for their use to treat glaucoma.<sup>7</sup> Dr. Chen says that when it comes to alternative glaucoma therapies, she doesn’t bring up the topic unless the patient asks her about it. “When they do bring it up, I tell them that the benefits are transient and theoretical, and the risks are rare but real,” she explains. “I explain that alternative therapies aren’t an advisable treatment option and may in fact delay use of proven therapies, thus causing the patient to lose vision irreversibly during this time.”

“All of these supplements are just that—supplements,” agrees Dr. Schuman. “I don’t recommend them if a patient’s IOP isn’t controlled. IOP control is our primary aim because there’s excellent evidence that not controlling IOP adequately ultimately leads to deterioration of the optic nerve and visual function in glaucoma. If a patient wants to adjunctively take supplements and is consistently controlling their IOP, I think that’s fine, but taking supplements instead of controlling IOP is not fine.

“That said, I’m a scientist and a clinician, and I do believe there’s a lot we don’t know,” he continues. “It’s important for us to keep an open mind. It’s easy to dismiss all supplements out of hand, but some evidence exists, and it’s important to review all safe options with your pa-

tient if there's a potential that those interventions will be beneficial.

"There's limited evidence on a number of nutraceuticals or supplements," he continues. "The best evidence now seems to be for three compounds in particular: nicotinamide, especially combined with pyruvate, and acetylcholine. When I have patients who are looking for something beyond conventional therapy, especially those who are continuing to progress despite single-digit or low-teen pressures, I'll review these with them. I have a handout that covers the compounds and dosages."

### Nicotinamide and Pyruvate

Developing neuroprotective and neuroenhancement therapies for glaucoma patients is an increasingly important focus of research, especially for patients who continue to progress despite IOP lowering measures. Neuroprotection focuses on preventing retinal ganglion cell death while neuroenhancement aims to improve the function of retinal ganglion cells that are damaged but not yet dead.<sup>8</sup>

Nicotinamide is a form of vitamin B3 that the body makes from niacin-rich foods such as eggs, legumes, green vegetables, nuts and fish. This dietary supplement is available over the counter and is sometimes used for skin conditions, niacin deficiencies and as a preventative measure against skin cancer.<sup>9</sup>

Nicotinamide is a precursor to nicotinamide adenine dinucleotide (NAD), a molecule that plays a key role in energy and redox metabolism, but that decreases with age. NAD of the retina and optic nerve declines as a function of IOP, according to a study using a rat model of ocular hypertension,<sup>10</sup> and has been demonstrated to be reduced in the sera of patients with POAG.<sup>11</sup>

Pyruvate is formed during glycolysis and plays a critical role in energy production pathways in the body. Studies in rats and mice have reported IOP-mediated decreases in retinal

pyruvate levels. RNA sequencing showed that gene expression changes impact pathways mediating metabolism and transport of glucose and pyruvate, but oral supplementation of pyruvate was neuroprotective in both rats and mice.<sup>12</sup>

The results of a Phase II randomized clinical trial for nicotinamide and pyruvate for neuroenhancement in open-angle glaucoma, published in *JAMA Ophthalmology* in 2021, reported that this combination conferred significant short-term visual function improvement.<sup>13</sup> The researchers hypothesized that the combination of nicotinamide and pyruvate could improve retinal ganglion cell function in patients with glaucoma. Participants in the Phase II trial were randomized to high oral doses of nicotinamide (1,000 to 3,000 mg) and pyruvate (1,500 to 3,000 mg) or placebo. A total of 32 participants (mean age 64.6 years) completed the study (21 intervention, 11 placebo) with a mean follow-up of 2.2 months. No adverse events were reported.

The primary endpoint was number of visual field test locations improving beyond normal variability in the study eye. In the study, this number was significantly higher in the intervention group than the placebo group (median IQR 16 vs. 7;  $p=0.005$ ). The pattern standard deviation rates of change for visual field global indices suggested improvement with the intervention compared with the placebo (median -0.06 vs. 0.02 dB/week; 95% CI 0.02 to 0.24;  $p=0.02$ ) but the mean deviation (0.04 vs. -0.002 dB/wk; 95% CI -0.27 to 0.09;  $p=0.35$ ) and visual field index (0.09 vs. -0.02 percent per week; 95% CI -0.53 to 0.36;  $p=0.71$ ) did not. Some patients (30 percent) reported mild gastrointestinal discomfort due to the high vitamin doses.

Vitamin B3 supplementation is likely safe based on other clinical trials for diseases. More studies are needed to confirm this combination's benefits for slowing visual field progression or providing sustained functional improvement over ex-

tended periods, but the researchers aver that targeting the same pathways may lead to the development of new neuroprotective therapies. A two-year randomized multicenter clinical trial of vitamin B3 with an enrollment aim of 1,800 participants is currently ongoing in Australia, Singapore, Sweden and the UK.

### Acetylcholine

Acetylcholine is a neurotransmitter and neuromodulator. As a food supplement, acetylcholine may help control blood pressure. Eating acetylcholine-rich foods such as eggplant and shiitake mushrooms can raise levels of this nutrient in the body.

In stressed hypertensive individuals, taking eggplant powder (1.2 g/day; 2.3 mg of ACh/day for 12 weeks) was shown to reduce blood pressure and improve psychological stress in a randomized placebo-controlled study of 100 participants.<sup>14</sup> Participants with normal-high blood pressure had decreased hospital diastolic blood pressure at week eight and those with grade-1 hypertension had decreased systolic and diastolic blood pressure at week 12 compared with the placebo group. The researchers estimated that the functional cause was acetylcholine.

Acetylcholine, released from starburst amacrine cells in the retina, has been suggested to provide neuroprotection to the retinal ganglion cells that are lost, overwhelmed or compromised under glaucomatous conditions.<sup>15</sup> *In vivo* rat glaucoma models indicate that PNU-282987, an  $\alpha 7$  nicotinic acetylcholine receptor agonist, could significantly reduce glaucoma-associated retinal ganglion cell loss and may be a potential therapeutic target for glaucoma treatment.<sup>15</sup> In the study, episcleral venous NaCl injections used to induce glaucoma caused significant cell loss (mean loss 27.35 percent) in the retinal ganglion cell layer at one month. Retinal ganglion cell loss was eliminated if 5  $\mu$ L of 100  $\mu$ M PNU-282987 was injected into

the eye an hour prior to the NaCl injection. Since PNU-282987 was applied before inducing glaucoma, this potential treatment would act as a preventative measure for patients at high risk for glaucoma.


## Cannabis

“One of the most common alternative treatment questions I get from patients is about cannabis use,”

Dr. Khouri says. “We investigated public perception of marijuana use for glaucoma treatment in a study recently and found there’s a significant gap between patient and physician perceptions.<sup>16</sup>

“We looked at Twitter and analyzed tweets over the last two years,” he says. “The vast majority were in favor of cannabis use for glaucoma (72 percent, n=503) while 18 percent were opposed (n=124). Most tweets in favor of using cannabis came from individual Twitter users while those not in favor of cannabis came from accounts such as health-care media, ophthalmologists and other professionals. We need better public education on the role of cannabis in glaucoma treatment.

“If you examine the literature on cannabis and glaucoma, it shows short-lived effects on IOP—typically a duration of only a few hours,” he explains. “The fact that cannabis could lower eye pressure may seem favorable to patients but there are ill effects from smoke inhalation, not to mention the glaucoma-specific effect of fluctuating IOP. The IOP will go up once the cannabis effect wears off. We know from multiple clinical trials that all those ups and downs in pressure can have a deleterious effect on glaucoma progression, particularly if the disease is severe. In early glaucoma it may be less relevant—we don’t have sufficient data yet—but in severe glaucoma, the nerve is more susceptible to IOP fluctuations.”



**Figure 1. A female glaucoma patient’s visual fields before and after a second treatment with repetitive transorbital alternating current stimulation.**

Bernhard Seibel, PhD

enrolled in April. Participants will be administered a topical dose of SBI-100 or placebo twice daily for five days.<sup>17</sup>

## Herbal Medicine

Herbal remedies and supplements reportedly used for glaucoma include *Ginkgo biloba*, bilberry fruit extract, cannabis, turmeric/curcumin, coenzyme Q10,<sup>18</sup> resvera-

trol, *Tripterygium wilfordii* (“thunder god vine”) and *Lycium barbarum* (goji berry).<sup>19</sup>

“*Ginkgo biloba* and bilberry are pretty popular among patients,” Dr. Khouri says. “These are the ones that commonly pop up if patients do a simple Google search on glaucoma and homeopathic medicine or alternative medicine. There’s data on *Ginkgo biloba* and bilberry being useful for glaucoma, as they are believed to play antioxidant and anti-inflammatory roles and reduce free radicals. Both also have some effects on the vascular system, a vasodilatory effect and anti-platelet function that could in theory be helpful for a patient with glaucoma to improve blood flow to the optic nerve head. However, there’s no consensus in the literature for whether this changes outcomes for glaucoma patients or not.”

*Ginkgo biloba* extract is derived from ginkgo tree leaves, which contain flavonoids and terpenoids and various bioactive compounds. Ginkgo has demonstrated antioxidant properties and short-term improvement in visual field indices, but it also has antithrombotic properties that may produce adverse ocular effects such as retinal hemorrhage and hyphema.<sup>20</sup>

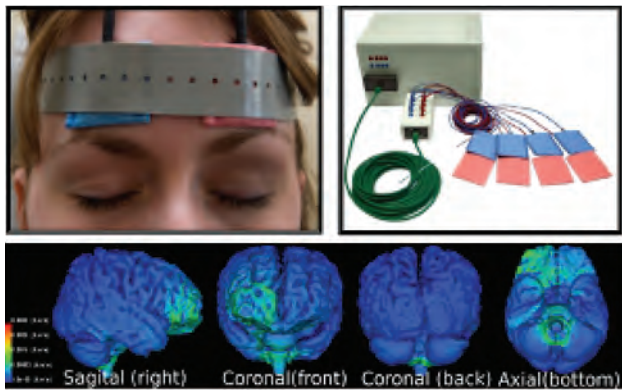
Bilberry fruit (*Vaccinium myrtillus*) or European blueberry contains the flavonoid anthocyanin and is proposed to confer neuroprotective and anti-inflammatory effects. Adverse effects may include cachexia, anemia and icterus in the event of

## Tetrahydrocannabinol

Tetrahydrocannabinol is a main psychoactive component of cannabis. The IOP-lowering mechanism of cannabis isn’t fully understood but researchers are exploring ways that isolated cannabinoids or synthetic analogs could produce sustained effects with fewer adverse side effects. Decades ago, THC studies were underway for glaucoma, but several challenges arose with creating a topical treatment targeting cannabinoid receptors. Dr. Marando says it was “fraught with issues, such as creating an adequate hydrophobic delivery system that’s well-tolerated and whether the therapy has any meaningful effect in humans.”

“The THC studies back then didn’t really pan out, but the initial work on a new THC-based drug seems promising,” Dr. Schuman says.

Skye Bioscience is developing a synthetic cannabinoid derivative to treat glaucoma. SBI-100 ophthalmic emulsion is a synthetic THC derivative molecule combined with the company’s nanoemulsion formulation that facilitates topical administration and penetration into the eye. In the single-ascending-dose arm of the Phase I study conducted in Australia, 18 of 24 participants were dosed with topical SBI-100 in concentrations of 0.5%, 1% and 2%, with no adverse events and expected mild to moderate adverse events. A multiple-ascending-dose arm was



Bernhard Sabel, PhD

**Figure 2. A patient using the at-home Active SAVIR Alpha Synch mobile device for microcurrent stimulation. Current flow in the brain is shown below.**

overdose.<sup>20</sup>

## Neurostimulation

Neurostimulation therapies aim to reactivate malfunctioning retinal ganglion cells otherwise perceived as dead by applying electrical currents to relax muscles in the head and improve blood flow. Proponents say this approach can result in visual field improvements in certain patients, provided there are living cells to target.

“We call these surviving cells ‘silent neurons,’” explains Bernhard Sabel, PhD, a medical psychology professor at the Otto-von-Guericke-University Magdeburg in Germany and pioneer of vision restoration and the residual vision activation theory. “‘Silent neurons’ remain in a hibernation state caused by damage or continuous mental stress but can be reactivated by electrical stimulation, so they can send visual signals once more. The electrical pulses have a ‘double-punch’ effect because on one hand they mimic the electric pulses that brain cells use to communicate with one another, a kind of ‘wake-up call,’ and on the other hand they simultaneously enhance blood flow by vasodilation.”

Dr. Sabel, who has treated more than 2,000 patients over the last decade using microcurrent therapy at the Savir-Center in Magdeburg, Germany, says the therapy produces greater effects in those with advanced disease. “Patients who have very little

vision loss won’t see major improvements because the improvement asymptotes and reaches the ceiling, while those with moderate or severe disease benefit more.”

A randomized clinical trial demonstrated a mean visual field improvement of 24 percent (n=45;

mean age 59) with repetitive trans-orbital alternating current stimulation (rtACS) lasting for at least two months, compared with the 2.5-percent improvement observed in the sham stimulation group (n=37).<sup>21</sup> Secondary analyses showed improved reaction times, improved near-threshold visual fields in the central 5 degrees and increased static perimetry thresholds after treatment, but no visual acuity changes compared with sham. The treatment stimulated the eye and optic nerve as well as the frontal cortex and subcortical regions of the brain inducing brain plasticity by way of improving functional brain network synchronization.<sup>22,23</sup>

Subsequent studies by his group on the role of brain plasticity in visual function<sup>22</sup> point out indirect influential factors such as intracerebral pressure, eye movement, top-down modulation (cognition, attention) and the release of emotionally triggered stress hormones contributing to blood vessel dysregulation.<sup>24</sup>

“Mental stress has a negative influence on the development of glaucoma and on electrical stimulation therapy,” Dr. Sabel says. “We believe the main effect of electrical stimulation is the relaxation of the muscles that surround the blood vessels. To that end, we also incorporate eye movement exercises, massage and meditation to reduce stress and improve blood supply to the nerve cells involved in vision, reactivating the ‘silent’ neurons.

“There’s great variability in response to neurostimulation,” he continues. “Our experience today with the patients we treat for 10 days at our center shows that about 85 percent demonstrate improvement in visual functions, but 15 percent of patients benefit very little or not at all. Prolonged mental stress and personality seem to play a key role in preventing vision restoration (Figure 1).”<sup>25</sup>

A clinical trial at Stanford University, NYU Langone and Otto-von-Guericke University Magdeburg (NCT05626491) is currently enrolling to test the safety and efficacy of long-term rtACS therapy with an at-home device for open-angle glaucoma and optic neuropathies. The randomized, double-masked study has an estimated enrollment of 45 participants with an estimated completion date of December 2024. The experimental arm includes treatment with the Active SAVIR Alpha Synch mobile device, a headband that delivers electrical stimulation, every other day for eight weeks (Figure 2). The sham arm involves the same device but no active stimulation. The primary outcome is change from baseline in visual field assessed using the Humphrey Visual Field Index through six months. Secondary outcome measures include change from baseline in mean deviation, Pelli-Robson contrast sensitivity and Snellen visual acuity.

A concurrent open-label study (NCT05626426) at Stanford for participants who didn’t fit the exact enrollment criteria for the randomized trial is also recruiting, with an estimated enrollment of 20 participants. This study will also assess RNFL and GCC OCT changes, retinal metabolism, adaptive optics retinal imaging, laser speckle flowgraphy and OCT angiography changes.

Dr. Khouri points out, “The challenges with nerve stimulation studies are that sample sizes are small, and inclusion and exclusion criteria are often restrictive, targeting either patients with very advanced disease or those with very early glaucoma

# THE DANGER CAN BE HARD TO SEE. LOOK CLOSER.

For patients with Graves' disease (GD), Thyroid Eye Disease (TED) may be hiding in plain sight.<sup>1,2</sup>

Up to 50% of patients with GD may develop TED, a separate and distinct disease which can progress if left untreated. Look out for the early signs and symptoms<sup>3-6</sup>:

- Proptosis
- Diplopia
- Dry eyes
- Sensitivity to light
- Grittiness
- Pain or pressure behind the eyes

If you identify new or changing signs or symptoms, consult with an eye doctor who specializes in TED right away.<sup>1,7</sup>



Visit [TEDimpact.com](https://www.tedimpact.com) to find a TED Specialist

**References:** 1. Barrio-Barrio J, Sabater AL, Bonet-Farriol E, Velázquez-Villoria Á, Galofré JC. Graves' ophthalmopathy: VISA versus EUGOGO classification, assessment, and management. *J Ophthalmol.* 2015;2015:249125. 2. Bothun ED, Scheurer RA, Harrison AR, Lee MS. Update on thyroid eye disease and management. *Clin Ophthalmol.* 2009;3:543-551. 3. Bahn RS. Graves' ophthalmopathy. *N Engl J Med.* 2010;362(8):726-738. 4. Bartalena L, Krassas GE, Wiersinga W, et al. Efficacy and safety of three different cumulative doses of intravenous methylprednisolone for moderate to severe and active Graves' orbitopathy. *J Clin Endocrinol Metab.* 2012;97(12):4454-4463. 5. Patel A, Yang H, Douglas RS. A new era in the treatment of thyroid eye disease. *Am J Ophthalmol.* 2019;208:281-288. 6. Ponto KA, Pitz S, Pfeiffer N, Hommel G, Weber MM, Kahaly GJ. Quality of life and occupational disability in endocrine orbitopathy. *Dtsch Arztebl Int.* 2009;106(17):283-289. 7. Ross DS, Burch HB, Cooper DS, et al. 2016 American Thyroid Association guidelines for diagnosis and management of hyperthyroidism and other causes of thyrotoxicosis. *Thyroid.* 2016;26(10):1343-1421.

on the disease spectrum. The jury is still out but there's a lot of interest in neurorestorative or neuroprotective therapies. It remains to be seen whether an intervention will materialize from the research that could help patients, but I think we're many years away from that."

### Lifestyle Modifications

The level of evidence for lifestyle modifications and their effects on glaucoma is low compared with pharmacological agents, but some modifications may be safely incorporated by patients such as exercise, smoking cessation, weight loss and altered sleeping positions.

"Strenuous physical exercise has been shown to both lower high IOP and increase optic nerve health," says Dr. Schuman. "Sleeping on 30-degree wedge pillow has been shown to reduce nocturnal elevations in eye pressure in some patients."

A prospective, nonrandomized comparative case series of 17 eyes of 17 patients with glaucoma, controlled IOP and new disc hemorrhage demonstrated that sleeping in a 30-degree head-up position lowers IOP compared with a flat position, with variable effects between patients (mean IOP was 3.2 mmHg lower,  $p=0.03$ ).<sup>25</sup> All but one patient had lower IOP using the head-up position. IOP reduction was  $\geq 20$  percent in 35 percent of patients. No differences in blood pressure or ocular perfusion pressure were found between the two head positions. A subsequent study of head elevation vs. supine position during sleep in 71 open-angle glaucoma patients reported similar results but noted that "resting on multiple pillows" doesn't seem to reduce IOP uniformly in glaucoma patients.<sup>26</sup>

"A question simply inquiring about face-down sleep can be relevant," Dr. Khouri notes. "If patients sleep face down, they're putting pressure on their eye, and that could have a deleterious effect on their glaucoma. The literature is favorable for exer-

cise, smoking cessation and a healthy body mass index. All of these things can improve oxygen saturation and blood flow. The health of the vascular system matters when it comes to glaucoma."

One review study reported that exercise had a small effect on glaucoma (1 to 2 mmHg IOP decrease), and that IOP increases due to stress, high wind instrument playing and yoga inversions.<sup>27</sup> The authors mentioned it was reasonable to inform glaucoma patients about transient IOP elevations associated with certain activities.

### The Bottom Line

"This topic is an important reminder that patients will often self-treat their glaucoma based on inaccurate information and that they may not disclose this to you unless specifically addressed," Dr. Marando says. "Physicians also have a responsibility to educate patients and to protect them from ineffective and potentially dangerous treatments, which can also be costly and time-consuming." ◀

- Weinreb RN, Ong T, Scassellati Sforzolini B, et al. A randomised, controlled comparison of latanoprostene bunod and latanoprost 0.005% in the treatment of ocular hypertension and open angle glaucoma: The VOYAGER study. *Br J Ophthalmol* 2015;99:6:738-745.
- Walters TR, Ahmed IIK, Lewis RA, et al. Once-Daily netarsudil/latanoprost fixed-dose combination for elevated intraocular pressure in the randomized phase 3 MERCURY-2 study. *Ophthalmology Glaucoma* 2019;2:5:280-289.
- Santen and UBE receive FDA approval for Omlonti (omidenepag isopropyl ophthalmic solution) 0.002% for the reduction of elevated intraocular pressure in patients with primary open-angle glaucoma or ocular hypertension. Sept 26, 2022. <https://www.santen.com/content/dam/santen/global/pdf/en/news/20220926-1.pdf>. Accessed April 27, 2023.
- SPARC Announces Positive Top-line Results from Pivotal Phase 3 Clinical Trial of PDP-716 for the Treatment of Open Angle Glaucoma or Ocular Hypertension. May 14, 2021. [https://www.sparc.life/sites/default/files/2021-05/PDP-716%20topline%20results\\_14th%20May.pdf](https://www.sparc.life/sites/default/files/2021-05/PDP-716%20topline%20results_14th%20May.pdf). Accessed April 27, 2023.
- Rhee DJ, Katz LJ, Spaeth GL, Myers JS. Complementary and Alternative Medicine for Glaucoma. *Survey of Ophthalmology* 2001;46:1:43-55.
- Wan MJ, Daniel S, Kassam F, et al. Survey of complementary and alternative medicine use in glaucoma patients. *J Glaucoma* 2012;21:2:79-82.
- Marando CM, Chen TC. Evidence for complementary and alternative therapies to treat glaucoma. *Seminars in Ophthalmology* 2023;38:1:85-91.
- Margeta MA. Single Digits but Still Progressing – Now What? Part 1: Neuroprotection. Presented at the 2023

- American Glaucoma Meeting in Austin, TX.
- Starr P. Oral nicotinamide prevents common skin cancers in high-risk patients, reduces costs. *Am Health Drug Benefits* 2015;8(Spec Issue):13-14.
- Tribble JR, Otmani A, Sun S, et al. Nicotinamide provides neuroprotection in glaucoma by protecting against mitochondrial and metabolic dysfunction. *Redox Biol* 2021;43:101988.
- Kouassi Nzoughet J, Chao de la Barca JM, Guehlouz K, et al. Nicotinamide deficiency in primary open-angle glaucoma. *Invest Ophthalmol Vis Sci* 2019;60:7:2509-2514.
- Harder JM, Guymer C, Wood JPM, et al. Disturbed glucose and pyruvate metabolism in glaucoma with neuroprotection by pyruvate or rapamycin. *Proc Natl Acad Sci USA* 2020;117:52: 33619-33627.
- De Moraes CG, John SWM, Williams PA, et al. Nicotinamide and pyruvate for neuroenhancement in open-angle glaucoma: A phase 2 randomized clinical trial. *JAMA Ophthalmol* 2022;140:1:11.
- Nishimura M, Suzuki M, Takahashi R, et al. Daily ingestion of eggplant powder improves blood pressure and psychological state in stressed individuals: A randomized placebo-controlled study. *Nutrients* 2019;11:11:2797.
- Iwamoto K, Birkholz P, Schipper A, et al. A nicotinic acetylcholine receptor agonist prevents loss of retinal ganglion cells in a glaucoma model. *Invest Ophthalmol Vis Sci* 2014;55:1078-1087.
- Yakobashvili D, Shah R, Oydanich M, Khouri AS. Public perception of marijuana use for the treatment of glaucoma. *J Glaucoma*. Published online March 3, 2023.
- Skye Bioscience receives human research ethics committee approval to start multiple ascending dose arm of Phase 1 study of SBI-100 ophthalmic emulsion. March 15, 2023. <https://ir.skyebioscience.com/news-events/press-releases/detail/160/skye-bioscience-receives-human-research-ethics-committee>. Accessed April 27, 2023.
- Chaudhry S, Dunn H, Carnit N and White A. Nutritional supplementation in the prevention and treatment of glaucoma. *Surv Ophthalmol* 2022;67:4:1081-1098.
- Sim R, Sirasanagandla SR, Das S and Teoh SL. Treatment of glaucoma with natural products and their mechanism of action: An update. *Nutrients* 2022;14:534.
- Ige M, Liu J. Herbal medicines in glaucoma treatment. *Yale J Biology and Med* 2020;93:347-353.
- Gall C, Schmidt S, Schittkowski MP, et al. Alternating current stimulation for vision restoration after optic nerve damage: A randomized clinical trial. *PLoS One* 2016;11:6:e0156134.
- Bola M, Gall C, Moewes C, et al. Brain functional connectivity network breakdown and restoration in blindness. *Neurology* 2014;83:6:542-551.
- Wu Z, Sabel BA. Spacetime in the brain: Rapid brain network reorganization in visual processing and recovery. *Scientific Reports* 2021;11:1:17940.
- Sabel BA, Flammer J, Merabet LB. Residual vision activation and the brain-eye-vascular triad: Dysregulation, plasticity and restoration in low vision and blindness – A review. *RNN* 2018;36:6:767-791.
- Sabel BA, Wang J, Fähse S, et al. Personality and stress influence vision restoration and recovery in glaucoma and optic neuropathy following alternating current stimulation: Implications for personalized neuromodulation and rehabilitation. *EPMA Journal* 2020;11:2:177-196.
- Buys YM, Alasbali T, Jin YP, et al. Effect of sleeping in a head-up position on intraocular pressure in patients with glaucoma. *Ophthalmology* 2010;117:7:1348-1351.
- Park JH, Nam KT, Yoo C, Kim YY. Head elevation and intraocular pressure in glaucoma. *Optom Vis Sci* 2016;93:9:1163-1170.
- Parikh RS, Parikh SR. Alternative therapy in glaucoma management: Is there any role? *Indian J Ophthalmol* 2011;59 Suppl 1:S158-160.



# IS SLT READY FOR A LEADING ROLE?

With growing data bolstering its efficacy as a first-line treatment, some say SLT is the best approach for newly diagnosed glaucoma patients.

LIZ HUNTER  
SENIOR EDITOR

**W**e've all been taught not to discuss certain topics around the dinner table—such as religion, politics and money—and if you find yourself breaking bread with glaucoma specialists, you might add selective laser trabeculoplasty vs. medication to that list. It always seems to spark a debate on which treatment method works best for newly diagnosed glaucoma patients and if or how SLT makes an impact when used after drops. However, as more time passes and more data become available, laser proponents say that SLT's doubters have less ground to stand on. We spoke with several glaucoma experts who say the discourse around SLT is changing and why education is integral to ending the debate.

## SLT's Place in the Treatment Paradigm

In order for SLT to hold a candle to drops for the initial treatment of primary open angle glaucoma and ocular hypertension, doctors needed

to see compelling data.

Some small studies have been done examining SLT as a monotherapy, such as the West Indies Glaucoma Laser Study,<sup>1</sup> which showed significant and safe IOP reduction in Afro-Caribbean eyes with POAG. However, the 12-month study subjects had previously taken IOP-lowering medications and underwent SLT after washout. Other studies examined SLT's efficacy on patients who were currently on medications. A retrospective study in a Thai population<sup>2</sup> showed SLT decreased IOP, as well as reduced the amount of antiglaucoma drugs needed post laser over a 24-month follow-up period.

But it was the LiGHT trial (laser in glaucoma and ocular hypertension) that really put SLT on the map as a valid first-line treatment. "The LiGHT study was revolutionary," says Tony Realini, MD, MPH, a professor of ophthalmology and glaucoma fellowship director at West Virginia University who was also involved in the LiGHT trial. "It was the first prospective, randomized study that was actually designed and completed to compare a pri-

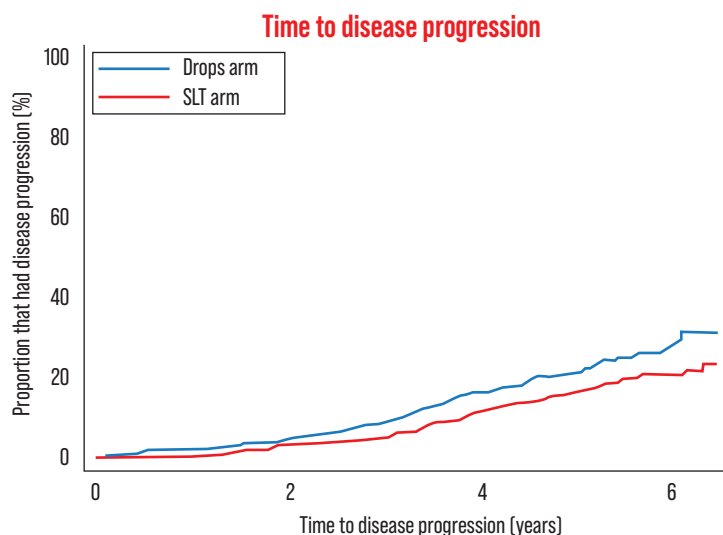
mary medical to SLT therapy, and it showed that SLT is at least as good as and maybe better than medications in terms of long-term disease control. There was less progression. There were fewer trabeculectomies and fewer cataract surgeries in the eyes that were assigned to laser first as opposed to medications first."

The LiGHT trial first released its results in 2019 showing 36 months of data. It demonstrated that SLT provided drop-free IOP control in 74.2 percent of patients<sup>3</sup> when used as the primary treatment method. Disease progression was also lower in the SLT-first group (3.8 percent of patients) vs. the eye-drops group (5.8 percent).

In early 2023, six-year data from the LiGHT trial was released, strengthening the case for SLT as first-line therapy. The SLT arm showed better Glaucoma Symptom Scale scores than the drops arm (83.6 ±18.1 vs. 81.3 ±17.3, respectively).<sup>4</sup> Of eyes in the SLT arm, 69.8 percent remained at or below the target IOP without the need for medical or surgical treatment. More eyes in the drops arm exhibited disease progres-

This article has no commercial sponsorship.

Drs. Sanvicente and Realini report no disclosures. Dr. Singh is a speaker and consultant for Ellex Quantel, Glaukos, Alcon, Sight Sciences, New World Medical and NovaEye.



**Figure 1. Six-year data from the LiGHT trial indicated statistically significant lower rates of disease progression in eyes treated with SLT as first-line therapy.<sup>4</sup>**

sion (26.8 percent vs. 19.6 percent, respectively;  $p=0.006$ ). Trabeculectomy was required in 32 eyes in the drops arm compared with 13 eyes in the SLT arm ( $p<0.001$ ); more cataract surgeries occurred in the drops arm (95 compared with 57 eyes;  $p=0.03$ ).

Many in the glaucoma specialty feel this data should instill confidence in performing SLT first-line. “This tide of not using SLT as a first-line treatment is getting smaller and smaller because the data has been, at this point, pretty compelling about offering it as a first-line treatment,” says Carina Torres Sanvicente, MD, an assistant professor at the University of Arkansas for Medical Sciences and glaucoma specialist at the school’s Jones Eye Institute. “We now have six-year data from the LiGHT trial and it still favors SLT. It works better if it’s done before other medications. We actually see a good response for about a year to two years and then it starts to decrease and sometimes we have to repeat it. If I find that the treatment worked well at first but the effect didn’t last long, I like to wait about a year or so for repeat SLT, but there’s data out there that SLT can be repeated fairly quickly after with good safety.”

Repeatability had been a concern of Dr. Realini’s. “When SLT

first came out, there wasn’t a lot of evidence and it took about eight years before there was any data at all on repeatability of SLT,” he says. “ALT (argon laser trabeculoplasty) never caught on because it wasn’t repeatable, it was just a stopgap measure, much in the way Durysta has become as well. You’re not going to get much traction on something that is one and done. So there’s been a flurry of data on repeatability of SLT and I started realizing this could be a really effective first-line therapy because when it wears off, we can do it again, and maybe again and help people avoid medications for several years.”

ALT involved collateral thermal damage, leading to subsequent trabecular-meshwork scarring and, when repeated, could cause peripheral anterior synechiae.<sup>5</sup> Alternatively, SLT does less damage to the adjacent cells and tissues in the trabecular meshwork.

Dr. Realini, who conducted the aforementioned West Indies Glaucoma Laser Study, says 60 percent of those patients maintained IOP control at the eight-year mark after a single SLT with no need for medical therapy. He’s conducting a new study, the COAST trial (Clarifying the Optimal Application of SLT

Therapy), to explore the role of low-energy SLT repeated annually as a means of further extending medication-free survival beyond the current standard, which is standard energy SLT repeated as needed when its effect wears off.

“The advantage of this would be that, if we’re doing less damage to the meshwork by using low-energy SLT, and we’re doing it every year, whether the meshwork has become re-impaired or not, we’re effectively practicing trabecular meshwork health maintenance and the hope is that medication-free survival will be much longer in the low-energy annual group compared to the standard energy PRN group,” Dr. Realini says. “People who are getting SLT have a dual hit to the meshwork: the SLT does damage and the glaucoma does damage. If we can reduce the amount of damage that SLT does by turning down the energy and if we can keep the meshwork healthy rather than trying to rescue it every time it becomes re-impaired by glaucoma, then we may be able to extend medication-free survival over the current standards.”

The doctors we spoke with also believe there should be no hesitation to use SLT as a second- or even third-line treatment.

“If a patient wanted to use drops first and wasn’t where I wanted them to be after two or three months, then I’ll perform SLT, and that makes a lot of sense to me,” says I. Paul Singh, MD, president of The Eye Centers of Racine & Kenosha in Wisconsin. “Or, if the patient was on PGA for years and you thought they were doing well, but you realize they’re still progressing even though the pressures may be ‘at target,’ that may mean compliance is likely an issue with potential for fluctuating IOP. This is a good person to switch over to SLT. It’s a good second-line agent if you’re not comfortable with it as first-line, but it’s not ideal to wait to use it as a last resort.”

Dr. Singh says doctors’ hesitation

To treat ocular inflammation and pain following ophthalmic surgery or ocular itching associated with allergic conjunctivitis.

## DEXTENZA KEEPS PATIENTS

# COMPLIANT

## AND SATISFIED<sup>1-3\*</sup>

### A hands-free advancement in ophthalmic steroid treatment.<sup>1,4</sup>

Easy-to-insert<sup>†</sup> and preservative-free intracanalicular DEXTENZA offers patients a satisfying post-op experience—providing up to 30 days of sustained steroid coverage.<sup>1-5</sup>

#### INDICATIONS

DEXTENZA is a corticosteroid indicated for:

- The treatment of ocular inflammation and pain following ophthalmic surgery.
- The treatment of ocular itching associated with allergic conjunctivitis.

#### IMPORTANT SAFETY INFORMATION

##### CONTRAINDICATIONS

DEXTENZA is contraindicated in patients with active corneal, conjunctival or canalicular infections, including epithelial herpes simplex keratitis (dendritic keratitis), vaccinia, varicella; mycobacterial infections; fungal diseases of the eye, and dacryocystitis.

##### WARNINGS AND PRECAUTIONS

**Intraocular Pressure Increase** - Prolonged use of corticosteroids may result in glaucoma with damage to the optic nerve, defects in visual acuity and fields of vision. Steroids should be used with caution in the presence of glaucoma. Intraocular pressure should be monitored during treatment.

**Bacterial Infections** - Corticosteroids may suppress the host response and thus increase the hazard for secondary ocular infections. In acute purulent conditions, steroids may mask infection and enhance acute existing infection.

**Viral Infections** - Use of ocular steroids may prolong the course and may exacerbate the severity of many viral infections of the eye (including herpes simplex).

**Fungal Infections** - Fungus invasion must be considered in any persistent corneal ulceration where a steroid has been used or is in use. Fungal culture should be taken when appropriate.

**Delayed Healing** - Use of steroids after cataract surgery may delay healing and increase the incidence of bleb formation.

**Other Potential Corticosteroid Complications** - The initial prescription and renewal of the medication order of DEXTENZA should be made by a physician only after examination of the patient with the aid of magnification, such as slit lamp biomicroscopy, and, where appropriate, fluorescein staining. If signs and symptoms fail to improve after 2 days, the patient should be re-evaluated.

##### ADVERSE REACTIONS

###### Ocular Inflammation and Pain Following Ophthalmic Surgery

The most common ocular adverse reactions that occurred in patients treated with DEXTENZA were: anterior chamber inflammation including iritis and iridocyclitis (10%), intraocular pressure increased (6%), visual acuity reduced (2%), cystoid macular edema (1%), corneal edema (1%), eye pain (1%), and conjunctival hyperemia (1%). The most common non-ocular adverse reaction was headache (1%).

###### Itching Associated with Allergic Conjunctivitis

The most common ocular adverse reactions that occurred in patients treated with DEXTENZA were: intraocular pressure increased (3%), lacrimation increased (1%), eye discharge (1%), and visual acuity reduced (1%). The most common non-ocular adverse reaction was headache (1%).

Please see adjacent Brief Summary of full Prescribing Information.

\*93% (187/201) DEXTENZA patients were satisfied with the insert in the Phase 3 Study for the treatment of ocular inflammation and pain following ophthalmic surgery.<sup>3</sup>

<sup>†</sup>73.6% of physicians in Study 1, 76.4% in Study 2, and 79.6% in Study 3, for the treatment of ocular inflammation and pain following ophthalmic surgery, rated DEXTENZA as easy to insert.<sup>2,5</sup>

**References:** **1.** DEXTENZA [package insert]. Bedford, MA: Ocular Therapeutix, Inc; 2021. **2.** Tyson SL, et al. *J Cataract Refract Surg.* 2019;45(2):204-212 [erratum in: 2019;45(6):895]. **3.** Data on File 00837. Ocular Therapeutix, Inc. **4.** Sawhney AS, Inventors, et al. Incept, LLC, Assignee. Drug Delivery Through Hydrogel Plugs. US Patent 8,409,606 B2. April 2, 2013. **5.** Walters T, et al. *J Clin Exp Ophthalmol.* 2016;7(4):1-11.

**Dextenza**<sup>®</sup>  
(dexamethasone ophthalmic insert) 0.4mg  
for intracanalicular use

# Dextenza®

(dexamethasone ophthalmic insert) 0.4 mg  
for intracanalicular use

**BRIEF SUMMARY:** Please see the DEXTENZA Package Insert for full Prescribing Information (10/2021)

## 1 INDICATIONS AND USAGE

### 1.1 Ocular Inflammation and Pain Following Ophthalmic Surgery

DEXTENZA® (dexamethasone ophthalmic insert) is a corticosteroid indicated for the treatment of ocular inflammation and pain following ophthalmic surgery (1.1).

### 1.2 Itching Associated with Allergic Conjunctivitis

DEXTENZA® (dexamethasone ophthalmic insert) is a corticosteroid indicated for the treatment of ocular itching associated with allergic conjunctivitis (1.2).

## 4 CONTRAINDICATIONS

DEXTENZA is contraindicated in patients with active corneal, conjunctival or canalicular infections, including epithelial herpes simplex keratitis (dendritic keratitis), vaccinia, varicella; mycobacterial infections; fungal diseases of the eye, and dacryocystitis.

## 5 WARNINGS AND PRECAUTIONS

### 5.1 Intraocular Pressure Increase

Prolonged use of corticosteroids may result in glaucoma with damage to the optic nerve, defects in visual acuity and fields of vision. Steroids should be used with caution in the presence of glaucoma. Intraocular pressure should be monitored during the course of the treatment.

### 5.2 Bacterial Infection

Corticosteroids may suppress the host response and thus increase the hazard for secondary ocular infections. In acute purulent conditions, steroids may mask infection and enhance existing infection [see Contraindications (4)].

### 5.3 Viral Infections

Use of ocular steroids may prolong the course and may exacerbate the severity of many viral infections of the eye (including herpes simplex) [see Contraindications (4)].

### 5.4 Fungal Infections

Fungus invasion must be considered in any persistent corneal ulceration where a steroid has been used or is in use. Fungal culture should be taken when appropriate [see Contraindications (4)].

### 5.5 Delayed Healing

The use of steroids after cataract surgery may delay healing and increase the incidence of bleb formation.

### 5.6 Other Potential Corticosteroid Complications

The initial prescription and renewal of the medication order of DEXTENZA should be made by a physician only after examination of the patient with the aid of magnification, such as slit lamp biomicroscopy, and, where appropriate, fluorescein staining. If signs and symptoms fail to improve after 2 days, the patient should be re-evaluated.

## 6 ADVERSE REACTIONS

The following serious adverse reactions are described elsewhere in the labeling:

- Intraocular Pressure Increase [see Warnings and Precautions (5.1)]
- Bacterial Infection [see Warnings and Precautions (5.2)]
- Viral Infection [see Warnings and Precautions (5.3)]
- Fungal Infection [see Warnings and Precautions (5.4)]
- Delayed Healing [see Warnings and Precautions (5.5)]

### 6.1 Clinical Trials Experience

Because clinical trials are conducted under widely varying conditions, adverse reaction rates observed in the clinical trials of a drug cannot be directly compared to rates in the clinical trials of another drug and may not reflect the rates observed in practice. Adverse reactions associated with ophthalmic steroids include elevated intraocular pressure, which may be associated with optic nerve damage, visual acuity and field defects, posterior subcapsular cataract formation; delayed wound healing; secondary ocular infection from pathogens including herpes simplex, and perforation of the globe where there is thinning of the cornea or sclera [see Warnings and Precautions (5)].

### 6.2 Ocular Inflammation and Pain

#### Following Ophthalmic Surgery

DEXTENZA safety was studied in four randomized, vehicle-controlled studies (n = 567). The mean age of the population was 68 years (range 35 to 87 years), 59% were female, and 83% were white. Forty-seven percent had brown iris color and 30% had blue iris color. The most common ocular adverse reactions that occurred in patients treated with DEXTENZA were: anterior chamber inflammation including iritis and iridocyclitis (10%); intraocular pressure increased (6%); visual acuity reduced (2%); cystoid macular edema (1%); corneal edema (1%); eye pain (1%) and conjunctival hyperemia (1%).

The most common non-ocular adverse reaction that occurred in patients treated with DEXTENZA was headache (1%).

### 6.3 Itching Associated with Allergic Conjunctivitis

DEXTENZA safety was studied in four randomized, vehicle-controlled studies (n = 154). The mean age of the population was 41 years (range 19 to 69 years), 55% were female and 61% were white. Fifty seven percent had brown iris color and 20% had blue iris color. The most common ocular adverse reactions that occurred in patients treated with DEXTENZA were: intraocular pressure increased (3%), lacrimation increased (1%), eye discharge (1%), and visual acuity reduced (1%). The most common non-ocular adverse reaction that occurred in patients treated with DEXTENZA was headache (1%).

## 8 USE IN SPECIFIC POPULATIONS

### 8.1 Pregnancy

#### Risk Summary

There are no adequate or well-controlled studies with DEXTENZA in pregnant women to inform a drug-associated risk for major birth defects and miscarriage. In animal reproduction studies, administration of topical ocular dexamethasone to pregnant mice and rabbits during organogenesis produced embryofetal lethality, cleft palate and multiple visceral malformations [see Animal Data].

#### Data

##### Animal Data

Topical ocular administration of 0.15% dexamethasone (0.75 mg/kg/day) on gestational days 10 to 13 produced embryofetal lethality and a high incidence of cleft palate in a mouse study. A daily dose of 0.75 mg/kg/day in the mouse is approximately 5 times the entire dose of dexamethasone in the DEXTENZA product, on a mg/m<sup>2</sup> basis. In a rabbit study, topical ocular administration of 0.1% dexamethasone throughout organogenesis (0.36 mg/day, on gestational day 6 followed by 0.24 mg/day on gestational days 7-18) produced intestinal anomalies, intestinal atresia, gastroschisis and hypoplastic kidneys. A daily dose of 0.24 mg/day is approximately 6 times the entire dose of dexamethasone in the DEXTENZA product, on a mg/m<sup>2</sup> basis.

### 8.2 Lactation

Systemically administered corticosteroids appear in human milk and could suppress growth and interfere with endogenous corticosteroid production; however the systemic concentration of dexamethasone following administration of DEXTENZA is low [see Clinical Pharmacology (12.3)]. There is no information regarding the presence of DEXTENZA in human milk, the effects of the drug on the breastfed infant or the effects of the drug on milk production to inform risk of DEXTENZA to an infant during lactation. The developmental and health benefits of breastfeeding should be considered along with the mother's clinical need for DEXTENZA and any potential adverse effects on the breastfed child from DEXTENZA.

### 8.4 Pediatric Use

Safety and effectiveness in pediatric patients have not been established.

### 8.5 Geriatric Use

No overall differences in safety or effectiveness have been observed between elderly and younger patients.

## 17 PATIENT COUNSELING INFORMATION

Advise patients to consult their eye care professional if pain, redness, or itching develops.

**Ocular**  
Therapeutic™

Ocular Therapeutic, Inc.  
Bedford, MA 01730 USA  
PP-US-DX-0360

## Feature SLT AS FIRST-LINE THERAPY

to use SLT earlier in the treatment paradigm contributed to its reputation in the field as being more modest in terms of efficacy. “I think what we’re seeing is that it’s not just about the number of drops, but when you wait too long, it’s also about disease state. A lot of times the reason why SLT and laser in general got a bad rap is because a lot of doctors were waiting to perform SLT as a last resort before traditional glaucoma surgery,” he says.

“For instance, if someone’s been on drops for years and years but they’re getting worse and the doctor doesn’t want to do a trabec, they’ll go ahead and try ALT or SLT. That’s a patient whose outflow system is probably diseased not just at the level of a trabecular meshwork where SLT primarily works, but also distal to that (the canal or even distal collector channels). The longer we wait, the more likely the disease of stiffness and fibrosis is occurring at multiple levels, thus limiting the effectiveness of SLT. It’s a catch-22—if you wait too long, you may not have the efficacy you want and that’s why, for me, it’s less about the number of drops in first-line, second-line and third-line, and more about where in the disease stage you’re using it,” Dr. Singh continues.

SLT is a great option to reduce the number of medications a patient may be taking, adds Dr. Realini. “Most of the patients that I’m diagnosing with glaucoma are getting primary SLT, but I frequently see patients who are referred to me who are on medication and I will encourage them to have SLT to get off that medication,” he says. “There’s about an 80 to 90 percent success rate in doing that based on the published literature, and people are happier when they stop drops. You can ask them if their drop is bothering them and they’ll say ‘No.’ But once you’ve done a laser and they come off the drops, the next time you see them, it’s like, ‘Oh my god, my eyes feel so much better.’ They just don’t appreciate how negatively impactful drops are until they stop them.”

## Shifting the Mindset of Patients and Physicians

Lack of education and understanding has contributed to the slow adoption of SLT as first-line. For the majority of people, drops have been the recommended standard of care and that’s what they expect to be prescribed.

“I tell patients that we can do a quick five-minute, in-office procedure that doesn’t hurt or they can put drops in every day for the rest of their lives, maybe two or three times a day, sometimes two or three drops two or three times a day, which they might not always comply with and is a hassle,” says Dr. Realini.

Doctors are also sometimes hesitant about the “laser,” and assume drops have no risks. “It’s important to recognize that drops are not benign,” Dr. Singh notes. “There’s enough data now supporting how ocular surface disease is a significant disease associated with topical medications. Drops can cause significant meibomian gland dysfunction and significant disruptions of the tear

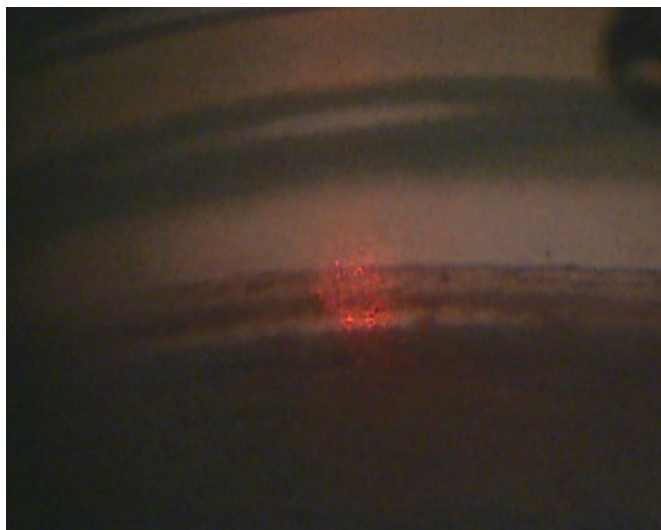
film, which results in symptoms such as tearing, burning, pain, redness, photophobia and fluctuating vision.”

Dr. Singh cites research done by Christophe Baudouin, MD, which showed how ocular surface disease severity contributed to patient adherence to treatment.<sup>6</sup> “Baudouin’s study showed us a 30-percent reduction of compliance if you have a prominent ocular surface disease. Compliance no doubt is directly tied to symptomatology of dry eye,” he says.

Dr. Realini says there’s a disconnect between what doctors would do for themselves and what they offer patients, and that education is the key to shifting patient expectations. “I gave a talk a couple of weeks ago and I asked, ‘How many in the room would want SLT first?’ All the hands went up,” he says. “Then I asked, ‘How many of you are now routinely performing SLT on the majority of your newly diagnosed glaucoma patients?’ None of the hands went up. I asked, ‘Why is that? Why is it that you’re not taking care of your patients the way you’d want to be taken care of?’ And a voice in the back said the magic words for me: ‘Patients don’t want laser.’ I believe that’s because they’re not talking to them about it correctly.

“As long as we keep offering SLT as an alternative to medications rather than recommending it to our patients as the preferred treatment instead of medications, the paradigm shift is going to languish,” Dr. Realini continues. “Once doctors become comfortable enough to communicate to their patients that this is the preferred therapy, it’s better than medications, then patients will begin to accept it more.”

Dr. Sanvicente studied this very



Carina Torres Sanvicente, MD

**Although patients may initially hesitate to undergo SLT, research shows that proper education about the procedure’s safety and efficacy makes them more likely to adopt it.**

topic.<sup>7</sup> “We actually looked at physician beliefs and attitudes and the patients’ beliefs and attitudes back in 2018 and we found that there was some reluctance in about half of the physicians offering it as first-line, with patient uptake being very low. We found that with increased awareness and education regarding the subject of SLT, more physicians seem to be convinced,” she says.

A few years later, Dr. Sanvicente published another study specifically about patient response to SLT education.<sup>8</sup> “For patients, we showed them a slideshow and video and more patients underwent SLT after having that intervention,” she says. “There are some misconceptions about laser in general from the patient side, that lasers might blind them for example. We’re able to address those and show it’s safe compared to medications.”

“I have about a 95 to 98 percent laser-first acceptance rate in my practice, because I’ve found a way of talking to patients about SLT that helps them see the benefits that I see,” Dr. Realini says. “I’m not at all hesitant to share with patients that it would be my first-line therapy if those were my eyes. Most patients then would want the treatment that

the doctor would want for himself.”

Dr. Singh uses a visual analogy to help. “When I present SLT, I describe the eye as a water balloon and the eye has to make fluid to get the shape of that water balloon, but that fluid has to drain out of the balloon so it can make more fluid,” he says. “I tell them their drain isn’t working, but we can use a beam of light that stimulates their drain to release their own natural enzymes to rejuvenate the drain. The patient is doing all the work naturally. It’s covered by insurance. It’s

not invasive, and because

it’s nondestructive, we can repeat it again if the pressure goes back up.”

### Patient Selection and Risks

Dr. Sanvicente says SLT candidates should have an open and visible trabecular meshwork. “I would avoid any type of secondary glaucoma, such as neovascular glaucoma. I would avoid anything that’s blocking your view from the angle,” she says. “I would say in steroid-response glaucoma, when they’re taking steroids for diabetic macular edema, for instance, they can respond well to SLT, but if they’re on steroids because they have uveitis then I would personally avoid SLT. You also want a patient who understands the goal of the procedure and that it’s not going to improve their vision, it’s going to prevent it from getting worse.”

She also avoids SLT in patients with a low starting pressure. “If your patient needs the pressure in the single digits, or their starting pressure is in the mid-to-low teens (15 or lower), then I don’t think SLT alone will bring that pressure to your target and you might need extra drops anyway,” Dr. Sanvicente says. “So, I avoid SLT in patients with a low starting pressure in the mid-teens and I would consider something else.

A pressure in the mid-20s is usually where SLT works best.”

As with anything, there are risks. “There’s a small risk of the pressure going up instead of down,” she continues. “Very rarely that can happen and sometimes it’s immediate, within the hour while they’re being observed in the office, but it’s usually short-lived and we can treat it with medication such as drops or acetazolamide. There’s some risk of eye inflammation that can blur their vision for a little bit and sometimes they need treatment, also rare. Some people have reported a risk of corneal edema, but that’s also short-lived. I haven’t seen that personally.”

Ultimately, Dr. Singh believes it’s time to rethink the traditional linear method of treating glaucoma. “As a profession we need to get away from this whole linear progression of our treatment options and move to a more circular model, where we have a patient centric focus and we’re drawing from all these different modalities

for that patient, depending on their circumstance,” he says. “I think we’re also appreciating the mechanism of action. With conventional outflow MIGS such as the stenting, canaloplasty and goniotomy, and the new drops that have come out in the last few years, such as latanoprostene bunod and netarsudil, which work on improving outflow through the conventional pathway, mechanism of action makes a difference. The earlier we address the pathology, the better chance we have of not only preventing it from progressing but also improving our chances of having better efficacy when the entire pathway isn’t completely fibrosed.”

So, is the debate settled? “I personally don’t think it’s a debate,” Dr. Singh concludes. “To me, you can only have a debate when the data is inconclusive. This data from multiple trials is clear and has been clear for years.” ◀

1. Realini T, Shillingford-Ricketts H, Burt D, Balasubramani GK. West Indies Glaucoma Laser Study (WIGLS): 12-month

efficacy of selective laser trabeculoplasty in Afro-Caribbeans with glaucoma. *Am J Ophthalmol* 2017;184:28-33.

2. Funarunart P, Treestit I. Outcome after selective laser trabeculoplasty for glaucoma treatment in a Thai population. *Clin Ophthalmol* 2021;18:1511-1516.

3. Gazzard G, Konstantakopoulou E, Garway-Heath D, Garg A, Vickerstaff V, Hunter R, Ambler G, Bunce C, Wormald R, Nathwani N, Barton K, Rubin G, Buszewicz M; LiGHT Trial Study Group. Selective laser trabeculoplasty versus eye drops for first-line treatment of ocular hypertension and glaucoma (LiGHT): A multicentre randomised controlled trial. *Lancet* 2019;393:10180-10186.


4. Gazzard G, Konstantakopoulou E, Garway-Heath D, Adeleke M, Vickerstaff V, Ambler G, Hunter R, Bunce C, Nathwani N, Barton K; LiGHT Trial Study Group. Laser in Glaucoma and Ocular Hypertension (LiGHT) trial: Six-year results of primary selective laser trabeculoplasty versus eye drops for the treatment of glaucoma and ocular hypertension. *Ophthalmology* 2023;130:2:139-151.

5. Latina MA, Park C. Selective targeting of trabecular meshwork cells: In vitro studies of pulsed and CW laser interactions. *Exp Eye Res* 1995;60:4:359-71.

6. Baudouin C, Renard JP, Nordmann JP, Denis P, Lachkar Y, Sellem E, Rouland JF, Jeanbat V, Bouée S. Prevalence and risk factors for ocular surface disease among patients treated over the long term for glaucoma or ocular hypertension. *Eur J Ophthalmol* 2012;22:11-0.

7. Bonafede L, Sanvicente CT, Hark LA, Tran J, Tran E, Zhang Q, Costello R, Myers JS, Katz LJ. Beliefs and attitudes of ophthalmologists regarding SLT as first line therapy for glaucoma. *J Glaucoma* 2020;29:10:851-856.

8. Tran E, Sanvicente C, Hark LA, Myers JS, Zhang Q, Shiuey EJ, Tran J, Bonafede L, Hamershook RA, Withers C, Katz LJ. Educational intervention to adopt selective laser trabeculoplasty as first-line glaucoma treatment: Randomized controlled trial: Educational intervention on selective laser trabeculoplasty. *Eur J Ophthalmol* 2022;32:3:1538-1546.



# THE RICK BAY FOUNDATION

for Excellence in Eyecare Education

## Support the Education of Future Healthcare & Eyecare Professionals

Scholarships are awarded to advance the education of students in both **Optometry** and **Ophthalmology**, and are chosen by their school based on qualities that embody Rick’s commitment to the profession, including integrity, compassion, partnership and dedication to the greater good.

INTERESTED IN BEING A PARTNER WITH US?

[www.rickbayfoundation.org](http://www.rickbayfoundation.org)

(Contributions are tax-deductible in accordance with section 170 of the Internal Revenue Code.)

#### ABOUT RICK

Rick Bay served as the publisher of *The Review Group* for more than 20 years. To those who worked for him, he was a leader whose essence was based in a fierce and boundless loyalty.

To those in the industry and the professions he served, he will be remembered for his unique array of skills and for his dedication to exceeding the expectations of his customers, making many of them fast friends.



THE RICK BAY FOUNDATION  
for Excellence in Eyecare Education

# ADVANCING IOL TECHNOLOGY

Three premium IOLs were approved in the past year, advancing IOL technology and pushing patient satisfaction. Here's the latest information about each new lens.

**ANDREW BEERS**  
ASSOCIATE EDITOR

In 2022, three advanced-technology IOLs were approved: Bausch + Lomb's IC-8 Aphera, Lenstec's ClearView 3 and Johnson & Johnson Vision's Tecnis Symphony OptiBlue. Each lens was designed in a unique way to provide physicians with more IOL options to recommend to their patients. We spoke with surgeons who work closely with each lens to discuss their experiences working with the IOLs and what they've observed since the FDA approvals.

## IC-8 Aphera Small Aperture IOL

Bausch + Lomb acquired AcuFocus to continue advancements on extended-depth-of-focus IOLs. The IC-8 Aphera IOL is a non-toric IOL indicated for patients with up to 1.5 D of corneal astigmatism. What makes this lens unique is its small aperture design using the AcuFocus FilterRing. Basically, the aperture was designed to filter out defocused or aberrated light that degrades image quality. The lens is

available in powers of +10 D to +30 D in 0.5-D increments. Additionally, the IOL is packaged with a 3.5 mm injector system.

"In this iteration, Aphera provides about 0.91 D of depth of focus or defocus over a monofocal," says Elizabeth Yeu, MD, of Virginia Eye Consultants in Norfolk. She says, "If you actually look at it it's also approved to be used for monovision." The Aphera was designed to be implanted in the non-dominant eye, supported by a monofocal or monofocal toric IOL implanted in the dominant eye.

During clinical trials, 343 subjects had an Aphera implanted in one eye and a monofocal IOL implanted in the other eye. In the control group, 110 subjects had monofocal IOLs implanted in both eyes. Two subjects in the Aphera group had their IC-8 IOL removed after a 12-month period due to adverse reactions. Between the two groups, 83.6 percent of Aphera subjects achieved a UCNVA of 0.30 logMAR (20/40) or better compared with 33 percent of subjects in the control group. In terms of distance vision, 89.6 percent of Aphera

subjects achieved a UCDVA of 0.10 logMAR (20/25) or better compared with 92 percent of subjects in the control group.

Dr. Yeu implanted 27 Aphera IOLs during the trials. Since the trial, she reports that none of these patients need to use reading glasses anymore. However, a monovision strategy using the IC-8 isn't suit-



Aphera

**The Aphera IOL is equipped with the carbon black FilterRing in the center.**

This article has no commercial sponsorship.

Dr. Yeu is a consultant for Bausch + Lomb and Johnson & Johnson Vision. Dr. Newsom is a consultant and principal investigator for Lenstec. Dr. Grayson has no financial interest in the products discussed.

able for all patients. Dr. Yeu says, “I do have one patient who says when they look out of the eye with the Aphera lens alone they do notice some dimness in nighttime driving, or it feels a little weird with their depth perception out of that eye.”

The IC-8 Aphera IOL is meant to be implanted in the capsular bag of a single eye, but Dr. Yeu indicates that the treatment could be done bilaterally. “There are definitely surgeons who have implanted the Aphera lens in both eyes off label, but this is a major conversation to have with your patients,” she says. “It’s the next level of consideration, because that’s going to have different types of implications for what would happen in terms of potential contrast sensitivity concerns.”

Dr. Yeu notes that the Aphera is a “forgiving” lens for patients with abnormalities or irregularities in their corneas. Dr. Yeu estimates that about 75 percent of her Aphera patients have cornea irregularities. “It’s an off-label indication, but I still do it in a monovision fashion where I’m off-setting the Aphera to give patients more near range,” she says. “For example, a recent patient of mine had hand motion vision for the last 20 years as his RK created such an irregular astigmatism. I could see that by using a small aperture of a sub-2 mm pupil, the light would create an image quality that would be 20/30. I looked at the results and found that he has 20/20 distance vision, all the way through to J1 vision.”

Dr. Yeu has seen positive results from her patients. She says that “patient satisfaction is even more overwhelming because of where they start. They start from not being able to see anything with any level of satisfaction or quality in spectacle correction or soft contact lens correction, to having uncorrected vision in the eye with the Aphera lens.”

### ClearView 3 Multifocal IOL

The ClearView 3 Segmented Bifocal Lens from Lenstec was originally

called the SBL-3. This is an asymmetric, segmented, multifocal IOL offered in the dioptric power range of +15 D to +25 D in 0.25-D increments, and +25.5 D to +30 D in 0.5-D increments.

During clinical trials, 476 subjects had an IOL implanted in at least one operative eye: 315 subjects had the ClearView 3 implanted and 161 subjects in the control group received a monofocal IOL. The company says that persistent adverse reactions in the ClearView 3 group weren’t significant. Only one case of corneal stromal edema and one case of cystoid macular edema were observed. Investigators reported that the mean DCNVA in the ClearView 3 group was 0.109 logMAR (~20/25) while the control group was 0.569 logMAR (~20/80). Additionally, the mean BCDVA in the ClearView 3 group was 0.003 logMAR (~20/20) while the control group was -0.039 logMAR (~20/20), which didn’t represent a statistically significant difference.

T. Hunter Newsom, MD, founder and medical director of Newsom Eye in Florida, was an investigator for the ClearView 3 trials. Since then, he has



**ClearView 3’s bifocal design features a superior optic for distance vision and an inferior optic for near vision.**

been informing surgeons about the latest advancements in multifocal technology with the ClearView 3. “The ClearView lens isn’t a diffractive IOL technology. It’s not splitting the light like we’re thinking with the current technology. It’s like a progressive pair of glasses, with a monofocal distance lens on the top half with a transition zone, and then a monofocal near lens on the bottom half. It’s more like one monofocal on top of another monofocal.”

Although the segmented bifocal design of ClearView 3 resembles the design of bifocal spectacles, clinical trials indicate that patients implanted with the IOL don’t need to move their heads up and down to gain the advantage of near vision. Patients’ brains can adapt to suppress images out of focus from the lens, similar to other approved dual-powered multifocal IOLs. The ClearView 3 is meant to promote less frequent use of vision correction choices at near distance, therefore an efficient transition between distance and near is integral to the design.

To implant the ClearView 3, Lenstec provides different injectors and cartridges for various diopter ranges. The IOL is compatible with Lenstec’s I-9011S and I-9012 injectors, and it comes with a disposable cartridge from the LC 16 series. “The injectors are really easy to use. The haptics and lens are simple and easy to fold and inject,” says Dr. Newsom.

The ClearView 3 is reported to have very limited amounts of visual side effects. According to Dr. Newsom, the side effects of the ClearView 3 are similar to those of progressive lenses. “There can be some distortion in ClearView 3 lenses,” he says, “but if patients have already experienced that distortion with a pair of progressive glasses, then they’ve already tried this technology before they invest in the IOL.”

### Tecnis Symphony OptiBlue IOL

Since the introduction of the Tecnis Symphony IOL in 2016, Johnson &



# Empower your patients to take part in their surgical success

## **Bruder** Pre-Surgical PATIENT PREP KIT

The benefits of having a healthy ocular surface prior to cataract surgery are well established.

Bruder pre-surgical prep kit can help.

Recommending the Bruder Sx Pre-Surgical Patient Prep Kit helps patients prepare their eyes for surgery in three easy steps and is designed to work with your pre-surgical protocol.

Explore research behind moist heat therapy, the benefits of lid hygiene, meibomian gland health and the importance of preparing the ocular surface prior to surgery at [brudersx.com](https://brudersx.com).

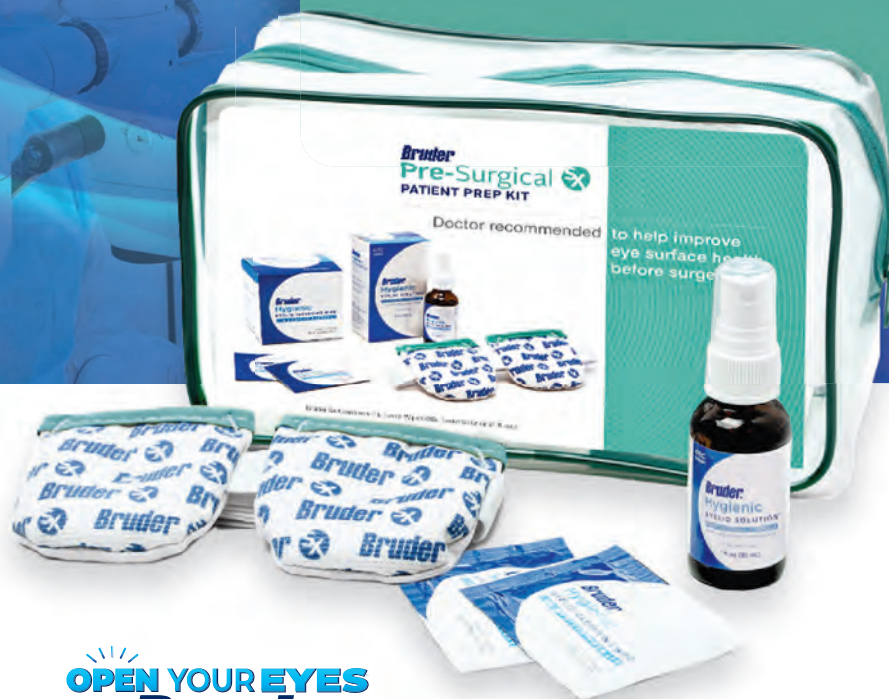## PRE-OP PREP MYTH DEBUNKED

Study published in *Clinical Ophthalmology*<sup>1</sup> shows candidates open to participate in pre-surgical preparation

**87%** of participants in the study say they would use a pre-surgical prep kit if their doctor gave them one.

**83%** said they would use a pre-surgical prep kit if they were asked to buy one.

To learn more about this study scan or visit [brudersx.com/readiness](https://brudersx.com/readiness)



[brudersx.com](https://brudersx.com)  
888-827-8337  
[eyes@bruder.com](mailto:eyes@bruder.com)

Learn more about our full line of products at [bruder.com/pro](https://bruder.com/pro).

<sup>1</sup>Clin Ophthalmol. 2022;16:1003-1008.  
<https://doi.org/10.2147/OPTH.S356895>

OPEN YOUR EYES  
to **Bruder**  
a Hilco Vision Company

Johnson Vision has been working towards advancing the technology of the IOL, while reducing halos, glare and starbursts. Also included in the Tecnis portfolio is a toric option.

During clinical trials, 148 subjects had the Symphony implanted bilaterally and another 151 subjects had a monofocal IOL implanted bilaterally. Overall, 2.7 percent of Symphony subjects experienced serious adverse reactions during the trial. None of the subjects experienced any device-related complications or unanticipated events. After six months, investigators found no persistent adverse reactions from the Symphony. However, one Symphony subject was diagnosed with CME after six months, but the investigators ruled this insignificant to the overall trial. Additionally, 76.9 percent and 70.1 percent of Symphony eyes achieved UCIVA and DCIVA of 20/25 or better, respectively, compared to 33.8 percent and 13.5 percent of monofocal eyes.

Douglas Grayson, MD, medical director of Omni Eye Services in Iselin, N.J., has been working with the Tecnis portfolio since its initial release. “The major advantages of Symphony when it came out was that it wasn’t considered a multifocal lens, it was an extended-depth-of-focus lens. Although, it did have the design of a multifocal,” he says. “The original Symphony didn’t have the OptiBlue coating, so there were patients who reported strange visuals at nighttime when they were driving and staring at headlights.”

In 2022, J&J introduced the Tecnis Symphony OptiBlue IOL with IntelliLight technology, also available in a toric option. This new technology was first introduced in the Tecnis Synergy IOL, a hybrid lens. IntelliLight combines a violet-light filter, an echelette design and achromatic technology to enhance the overall visual experience for patients, the company says. The violet-light filter was added to block short wavelengths of light that produce light scatter in the eye. This helps to mitigate halos,


glare and starbursts, especially while driving at night, the company says. J&J adds that the echelette design helps mitigate halos and starbursts when interacting with a digital device, and the achromatic technology corrects chromatic aberration for better contrast day and night.

“OptiBlue can be loaded in a separate cartridge which can then be inserted through a 2.4-mm wound. The Symphony OptiBlue has the advantage of also being available in a preloaded injector using a well-designed disposable cartridge and injector system,” says Dr. Grayson. J&J’s disposable injector, Tecnis Simplicity, can be ordered along with the OptiBlue and toric option to prevent manual loading errors.

The OptiBlue IOL does pose some side effects, but the latest advancements didn’t enhance any adverse reactions, according to Dr. Grayson. “I don’t think there was any detriment to the product. I don’t think it created any other side effects,” says Dr. Grayson. What he did notice about the design of the OptiBlue IOL was that it affected the quality of night vision. “You don’t have the same type of night vision that you would gain from a monofocal lens,” he says. “The Symphony is all based on concentric rings, and if you look at a point source of light, you can get some of the glare effect or halo effect.”

Regarding reading vision, Dr. Grayson says, “There’s also the whole issue of how well patients are reading. If they’re paying additional money for a presbyopia correcting lens, then they’re expecting to read. Symphony OptiBlue doesn’t give the type of small J1 reading that some other IOLs can provide, but the upside is that the OptiBlues are a well tolerated lens.

“If a patient has the desire to be as spectacle independent as possible in both eyes for distance and near, then they’re a potential candidate for this multifocal. As long as there’s no significant eye pathology precluding the



The latest Tecnis Symphony IOLs from the IntelliLight portfolio, OptiBlue and Synergy, are both available with the disposable Tecnis Symphony injector system.

success of the lens, then the patient will generally do well with the OptiBlue,” adds Dr. Grayson. According to clinical trials, OptiBlue is meant for cataract patients with the potential for postoperative BCDVA of 20/30 Snellen or better.

After working with various IOLs, Dr. Grayson notes that the reason patients may prefer other vision correcting options doesn’t have to do with the IOL side effects. “The single biggest reason patients don’t like multifocal lenses is that there’s an issue with the power calculation or the toric axis calculation of the lens that was put in. It’s not so much the lens, it’s the calculation for the lens,” he says. “The gold standard is to be able to see distance, intermediate and near. It seems like the best way to achieve that is to take the design of these IOLs and try to continue modifications to try to minimize whatever symptoms remain.” ◀

# A LOOK AT THE DRY-EYE TREATMENT PIPELINE

Companies and physicians are attacking ocular surface disease from all angles, from tear production to inflammation and meibomian gland dysfunction.

CATLIN NALLEY  
CONTRIBUTING EDITOR

**A**s the prevalence of dry eye continues to grow, so does the need for effective therapies. There are a number of new therapeutic approaches in development for the management of this condition that could help improve outcomes and quality of life for these patients. Here, we'll take a closer look at these agents and where they currently stand in the developmental process.

## Reproxalap (Aldeyra)

This novel, small-molecule reactive aldehyde species (RASP) inhibitor lessens ocular inflammation in dry-eye disease via a unique mechanism of action. RASP are pro-inflammatory molecules that are elevated in ocular and systemic inflammatory disease. Reproxalap mitigates inflammation by binding the free aldehydes, which leads to a reduction in RASP levels.

The company recently released findings from a 12-month safety clinical trial of reproxalap that

included 447 dry-eye patients—299 received reproxalap and 148 were treated with vehicle. Treatment-related serious adverse events in ocular safety (the primary endpoint) weren't observed.

Similar ocular safety events were reported across both treatment groups. A post-hoc analysis showed that reproxalap was superior to vehicle in improvement from baseline in distance visual acuity.

Of the many agents currently in development, reproxalap is one that stands out, according to Robert Latkany, MD, an ophthalmologist who practices in New York City. "Ocular surface disease is heavily influenced by inflammation. While steroids can help a lot of these patients, they also carry significant side effects," he explains.

"This is an alternative that comes with minimal side effects," says Dr. Latkany. "Also, this is one of the first drugs that I'm aware of that's attacking not only dry eye, but also allergic conjunctivitis. Many ocular surface disease patients don't just have dry eye, so the ability to address both dry eye and allergies is

very exciting."

Based on data from five clinical trials, including the phase III TRANQUILITY-2 study (NCT05062330), the U.S. Food and Drug Administration accepted the New Drug Application for topical ocular reproxalap in February. The assigned Prescription Drug User Fee Act (PDUFA) date is November 23, 2023.

## CyclASol (Novaliq)

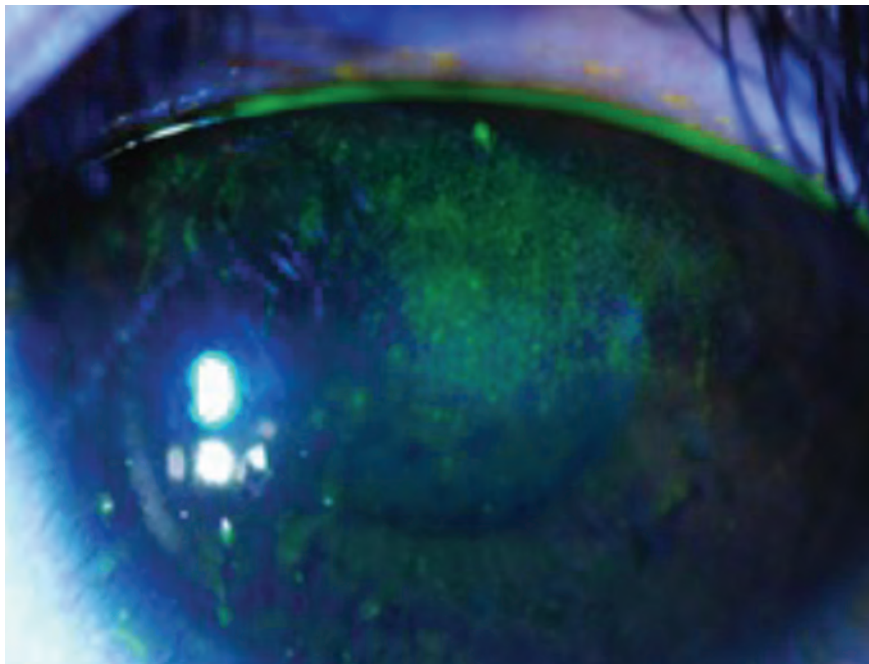
CyclASol—a topical anti-inflammatory and immunomodulating ophthalmic drug solution—contains 0.1% cyclosporine A in EyeSol, which is a water-free technology designed by the company.

EyeSol "increases residual time on the ocular surface and enables a high bio-availability in the target tissues to unfold the full potential of cyclosporine A and fast onset of action within two weeks," according to Novaliq.

Data from the Phase III ESSENCE-2 trial were recently published in *JAMA Ophthalmology*.<sup>1</sup> In this study, 834 patients were randomly assigned to one of two

This article has no commercial sponsorship.

Dr. Latkany and Dr. Akpek report no relevant financial disclosures.



Esen Akpek, MD

**Future therapies for dry eye aim to reduce potential damage to epithelial cells in an effort to preserve patients' visual function.**

treatment groups: cyclosporine or vehicle. The primary endpoints were changes from baseline in total corneal fluorescein staining and in dryness score at day 29.

“Even though the vehicle itself is a very good dry-eye treatment, there was separation between the vehicle and active group,” says first author Esen Akpek, MD, a professor of ophthalmology and rheumatology at Johns Hopkins University School of Medicine, and director of the Ocular Surface Disease and Dry Eye Clinic at the Wilmer Eye Institute in Baltimore.

The trial showed that treatment with CyclASol “results in early therapeutic effects on the ocular surface compared with vehicle,” Dr. Akpek reports. “The responder analyses suggest that the effect is clinically meaningful in 71.6 percent of participants in the cyclosporine group.”

The study authors observed improvements in total and central corneal staining score after only two weeks of treatment, with persistent efficacy through day 29. “Timing of improvement is a relevant and

valuable finding,” according to Dr. Akpek, especially for patients who are undergoing cataract or refractive surgery.

The FDA has accepted the New Drug Application for CyclASol and set a PDUFA target action date of June 8, 2023.

### TP-03 (Tarsus)

Clinical trials are currently underway examining TP-03 (lotilaner ophthalmic solution, 0.25%)—a novel treatment for *Demodex* blepharitis. Lotilaner is an anti-parasitic agent that paralyzes and eradicates *Demodex* mites by selectively inhibiting the GABA-Cl channels. “*Demodex* is a highly underdiagnosed and underappreciated condition,” says Dr. Akpek, while noting that treatment can be frustrating. “In-office procedures are typically the most effective options. However, this can be expensive or inconvenient for patients. I am very excited about new options that could offer additional treatment avenues.”

Data from the Phase III Saturn-2 study were released by the company and presented during the

American Academy of Ophthalmology 2022 Annual Meeting (Session ID PO058). The primary endpoint (complete collarette cure) as well as all secondary endpoints (mite eradication, erythema cure, erythema/complete collarette composite cure) were met, and TP-03 had a favorable safety profile.

In this randomized, controlled, double-masked study, 412 patients with *Demodex* blepharitis were enrolled. Study participants self-administered one drop of TP-03 twice per day in each eye for six weeks. They received no treatment for blepharitis, during the trial or 14 days prior to enrollment.

Fifty-six percent of patients on TP-03 achieved complete collarette cure versus 13 percent in the vehicle group. Additionally, mite eradication was achieved in 52 percent of patients on TP-03 compared to 14 percent on vehicle. The safety profile was consistent to the Phase IIb/III Saturn-1 trial, demonstrating that TP-03 was well-tolerated.

In November 2022, the FDA approved the New Drug Application for TP-03. The target action date for the PDUFA is August 25, 2023.

### RGN-259 (RegeneRx)

This Tβ4-based sterile and preservative-free eye drop was developed for a number of ophthalmic indications, including dry-eye disease. Topline results from ARISE-3, which included 700 patients, were released in 2021. The company reported that the trial didn’t meet its primary outcomes; however, the results showed statistically significant improvement in ocular grittiness at one and two weeks post-treatment.

The drops continued to demonstrate safety in this patient population, consistent with previous clinical trials. There were no signs of adverse events with only mild to moderate events observed in both arms. The most common ophthalmic adverse event was mild ocular pain upon instillation.



# 3RD YEAR OPHTHALMOLOGY RESIDENT PROGRAMS AND WET LABS

Dear CSE 3rd-Year Resident Program Director and Coordinator,

We would like to invite you to review the upcoming 3rd-Year CSE Ophthalmology Resident CME Programs and Wet Labs for 2023 in Fort Worth, Texas. The programs offer a unique educational opportunity for third-year residents by providing the chance to meet and exchange ideas with some of the most respected thought leaders in ophthalmology. The programs are designed to provide your residents with **in-depth didactic program and state-of-the-art wet lab experience with one-on-one wet lab guidance from faculty**. The courses also serve as an opportunity for your residents to network with residents from other programs.

After reviewing the material, it is our hope that you will select and encourage your residents to attend one of these educational activities, which are CME accredited to ensure fair balance.

Best regards,

Kendall Donaldson, MD, MS, Yousuf Khalifa, MD, and Mitchell P. Weikert, MD, MS

## SAVE THE DATE

**JULY 28–29, 2023**  
(FRIDAY–SATURDAY)

**Course Director**  
Mitchell P. Weikert, MD, MS

REGISTER NOW

**AUGUST 18–19, 2023**  
(FRIDAY–SATURDAY)

**Course Director**  
Kendall Donaldson, MD, MS

REGISTER NOW

**SEPTEMBER 22–23, 2023**  
(FRIDAY–SATURDAY)

**Course Director**  
Yousuf Khalifa, MD

MEETING IS FULL  
REGISTER FOR WAIT LIST

Registration open [www.ReviewEdu.com/CSE3rdYr2023](http://www.ReviewEdu.com/CSE3rdYr2023)

Courses are restricted to US-based 3rd-year residents enrolled in a US-based ophthalmology resident program and within their third year at the time of the course. There is no registration fee for these activities. Air, partial ground transportation in Fort Worth, hotel accommodations and modest meals will be provided through an educational scholarship for qualified participants.

**Satisfactory Completion** – Learners must complete an evaluation form to receive a certificate of completion. Your chosen sessions must be attended in their entirety. Partial credit of individual sessions is not available. If you are seeking continuing education credit for a specialty not listed below, it is your responsibility to contact your licensing/certification board to determine course eligibility for your licensing/certification requirement.



**Accreditation Statement** – In support of improving patient care, this activity has been planned and implemented by Amedco LLC and Review Education Group. Amedco LLC is jointly accredited by the Accreditation Council for Continuing Medical Education (ACCME), the Accreditation Council for Pharmacy Education (ACPE), and the American Nurses Credentialing Center (ANCC), to provide continuing education for the healthcare team.

**Physicians (ACCME) Credit Designation** – This live activity has been approved for **AMA PRA Category 1 Credit(s)**<sup>™</sup>.

For more information visit the registration site above or call Denette Holmes at 866-627-0714 or email [dholmes@postgradhealthd.com](mailto:dholmes@postgradhealthd.com)

Jointly provided by

Supported by an independent medical education grant from **Alcon**



### **B+L, Novaliq Eye Drop Approved For Dry Eye**

After several years of clinical trials and anticipation, Bausch + Lomb and Novaliq just announced the FDA approval of a new eye drop for evaporative dry eye. Sold under the name Miebo (perfluorohexyloctane ophthalmic solution; formerly known as NOV03), the drop is indicated to treat the signs and symptoms of dry-eye disease. The solution is also the first on the market to directly target tear evaporation—a leading cause of DED.

Miebo achieved primary endpoints and demonstrated good tolerability in all three trial phases, the company says. The FDA approval of Miebo was based on results from two 57-day, multicenter, randomized, double-masked, saline-controlled studies, GOBI and MOJAVE, which enrolled a total of 1,217 patients with a history of DED and clinical signs of meibomian gland dysfunction.

In the GOBI and MOJAVE Phase III studies, Miebo met both primary sign and symptom efficacy endpoints. The two primary endpoints were change from baseline at week eight (day 57 ± 2) in total corneal fluorescein staining (tCFS) and eye dryness Visual Analog Scale (VAS) score. Patients experienced relief of symptoms as early as day 15 and through day 57 with statistically significant reduction in VAS eye dryness score favoring Miebo observed in both studies, the company says. B+L adds that, at days 15 and day 57, a significant reduction in tCFS favoring Miebo was observed in both studies.

The most common adverse reactions were blurred vision (1.3 to 3 percent) and eye redness (1 to 3 percent).

With MGD contributing to the majority of dry-eye cases, Miebo may offer this patient population an alternative therapeutic option to other types of drops and in-office procedures, the company says.

Towards the end of 2022, RegeneRx submitted a request for the Special Protocol Assessment (SPA) to the FDA for an in-depth discussion and assessment of the clinical protocol for a fourth Phase III clinical trial (ARISE-4). This study is expected begin in 2023.

### **AR-15512 (Aerie/Alcon Pharmaceuticals)**

Another drug under development is the investigational eye drop AR-15512, a transient receptor potential melastatin 8 (TRPM8) agonist.

Findings from the Phase IIb COMET-1 study, which were published in 2022, showed that AR-15512 demonstrated statistically significant improvements in dry-eye disease signs, symptoms and disease-related quality of life.<sup>3</sup> Although predefined co-primary study endpoints were not met, AR-15512 is a promising approach, according to Dr. Latkany, who emphasizes the need for further research.

The first patient has been dosed in the Phase III registrational COMET-3 study—the second of three trials, according to Aerie Pharmaceuticals. The COMET-4 safety study (NCT05493111) was initiated

in November 2022.

The company, which was acquired by Alcon in November 2022, plans to complete the AR-15512 registrational program in 2023 and, if clinically successful, will file a New Drug Application with the FDA in 2024.

### **Visomitin (Mitotech)**

Visomitin—a cardiolipin peroxidation inhibitor—is currently being studied as a possible treatment for a variety of indications, including dry-eye disease. This agent uses a novel, multimodal action that targets inflammation, corneal/conjunctival damage, tear deficiency, and gland tissue regeneration.

Findings from the Phase IIb/III VISTA-1 and Phase III VISTA-2 studies were presented during the 2022 Association for Research in Vision and Ophthalmology meeting. Visomitin (SkQ1 ophthalmic solution) showed statistically significant effects on clearing of corneal staining in both studies, which, according to the study authors, is a “highly clinically relevant result.”

These findings support clearing of corneal fluorescein staining as the primary endpoint for the

upcoming VISTA-3 study.

### **Lacrirep (Tear Solutions)**

Developed to treat symptoms of dry eye and primary Sjögren’s Syndrome, Lacrirep is derived from the lacritin protein—a first-in-class topical therapy that preserves lacritin’s bioactivity.

Findings from a first-in-human study of Lacrirep among patients with primary Sjögren’s syndrome showed clinically significant improvements in specific signs and symptoms.<sup>4</sup> Study participants started to experience a positive impact after two weeks of treatment.

This research established Lacrirep’s safety and tolerability as well as its ability to significantly improve clinically relevant signs and symptoms of dry-eye disease, according to Tear Solutions. Further investigation is ongoing to determine appropriate dosing and concentration.

### **AZR-MD-001 (Azura Ophthalmics)**

AZR-MD-001—a keratolytic drop—has been developed for the treatment of meibomian gland dysfunction and evaporative dry-eye disease. A multicenter, double-masked, vehicle-controlled, parallel group, Phase IIb trial evaluated the safety and efficacy of AZR-MD-001 in 245 patients with meibomian gland dysfunction.

Patients administered AZR-MD-001 twice weekly to the lower eyelid at bedtime. Co-primary efficacy endpoints included the number of glands secreting meibum and patient-reported symptoms.

Azura Ophthalmics reported that AZR-MD-001 0.5% achieved statistically significant differences in both signs and symptoms at month three when compared to vehicle. Data also showed significant improvements in MGYS and OSDI scores.

The company plans to initiate a second pivotal multicenter clinical trial of AZR-MD-001 0.5%.

## GLK-301 (Glaukos)

This investigational drug candidate uses Glaukos' iLution platform's cream-based drug formulations, which are applied to the outer surface of the lid for dropless transdermal delivery of pharmaceutically active compounds. The active ingredient in GLK-301 is pilocarpine.

The company recently announced topline results from its Phase IIa, first-in-human clinical trial. This multicenter, randomized, double-masked, placebo-controlled study enrolled 218 dry-eye patients to examine the safety and efficacy of three different dose levels of GLK-301.

GLK-301 demonstrated an improvement in tear breakup time and a corresponding reduction in blurred vision. Based on these Phase IIa outcomes, Glaukos announced plans to advance GLK-301 into a Phase IIb clinical trial.

## ST-100 (Stuart Therapeutics)

ST-100 is an eyedrop formulation based on Stuart's Collagen Mimetic Peptide platform, PolyCol. In 2022, the company released findings from its Phase II study which included 160 dry-eye patients who received either 20 µg/ml or 50 µg/ml of ST-100 twice daily, or placebo.

Findings showed that the drug met the Schirmer's Responder Rate endpoint at 28 days. This was defined as a statistically significant difference in the percentage of patients achieving a 10 mm or greater increase in Schirmer's test scores.

The company also reported that the agent demonstrated significant results in several symptoms as well as ocular surface staining scores as early as treatment day seven. ST-100 was well tolerated among study participants.

In July 2022, Stuart Therapeutics announced that the FDA accepted the company's plan to conduct a Phase III trial for ST-100 and approved the proposed endpoints—a single primary endpoint (Schirmer's

Responder Rate) and a series of secondary endpoints.

## Tanfanercept (Harbour BioMed)

A TNF- $\alpha$  inhibitor, tanfanercept (HBM9036) is under investigation as a treatment for moderate-to-severe dry eye. Harbour BioMed completed its first interim analysis from their Phase III clinical trial. The trial plans to enroll 674 patients and two interim analyses will be conducted.

“Studies are currently underway to evaluate the use of Oxervate (topical solution of 0.002% cenegermin-bkbj) in patients with severe Sjogren's-related dry-eye disease.”

As of December 28, 2021, 187 patients had been evaluated for key efficacy endpoints assessment, according to the company. Interim data was reviewed by the Independent Data Monitoring Committee. They observed an efficacy trend and favorable safety, recommending that the study continue according to the current protocol.

## SURF-100 and SURF-200 (Surface Ophthalmics)

Two therapeutic drops for dry eye are under development using Surface Ophthalmics' Klarity diluent as the vehicle. SURF-100 (mycophenolate sodium and betamethasone sodium phosphate) targets chronic dry-eye disease while SURF-200 (betamethasone) is designed to treat acute/episodic dry eye. Phase II clinical trials are currently underway for both products. As of May 2021, the study for SURF-100 reached 50-percent enrollment. It consists of multiple arms and will enroll approximately 300 patients. SURF-200 is being studied in two different low-concentration formula-

tions. The trial will enroll between 120 and 140 patients, and the first patient was dosed in early 2021.

## Oxervate (Dompe)

A topical solution 0.002% of cenegermin-bkbj, Oxervate is approved for the treatment of neurotrophic keratitis. Studies are currently underway to evaluate the use of this agent in patients with severe Sjogren's-related dry-eye disease.

The NGF0121 study (NCT05133180), which enrolled 104 subjects, aims to assess the efficacy and safety of Oxervate in this patient population. The co-primary endpoints are Schirmer's test and the Symptom Assessment Questionnaire in Dry Eye (SANDE) questionnaire.

The NGF0221 study (NCT05136170) enrolled 85 patients who are currently being treated for severe Sjogren's-related dry-eye disease with topical cyclosporine A. The primary endpoint is Schirmer's test and change from baseline in SANDE global score.

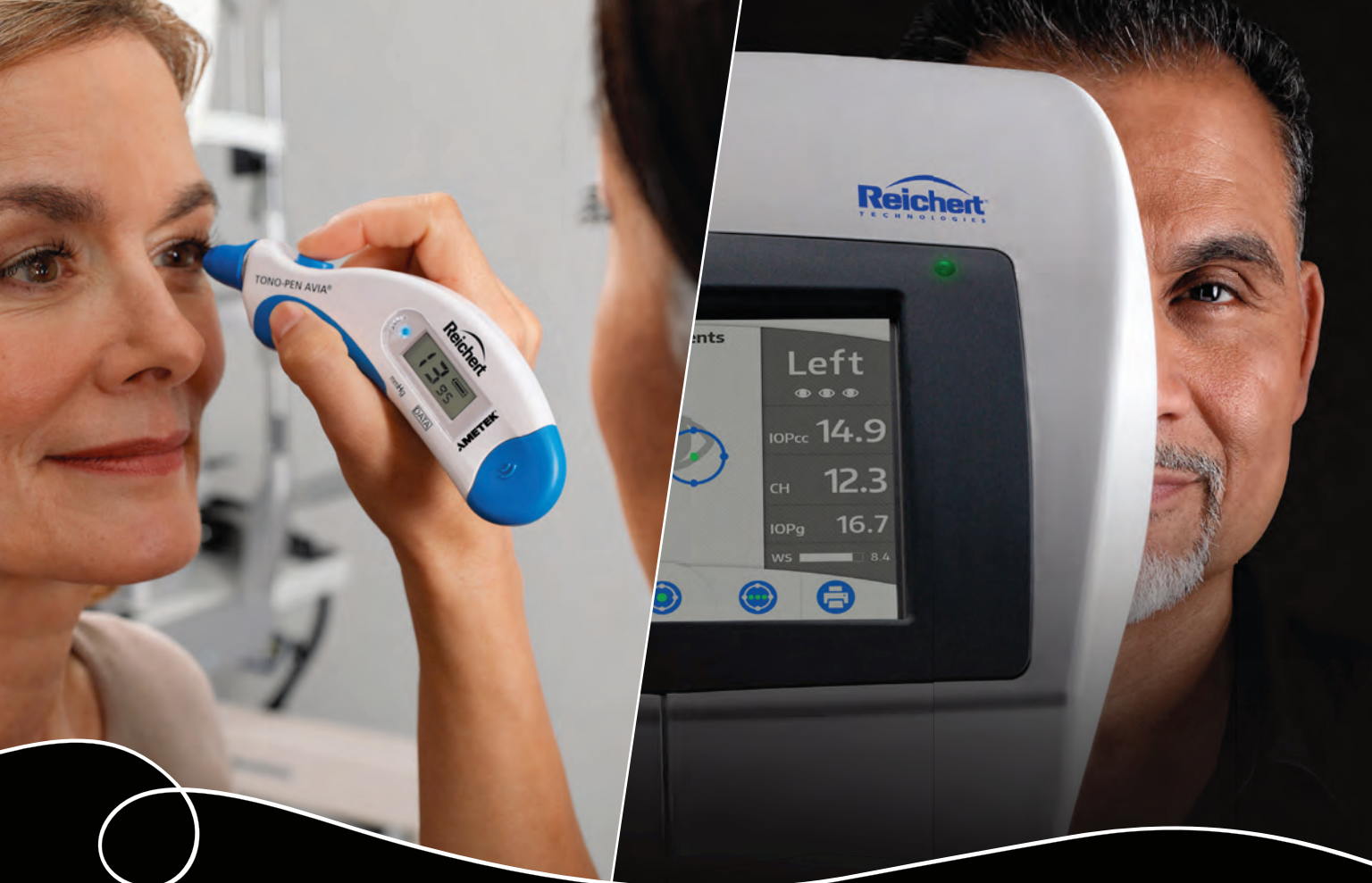With a plethora of new agents in the pipeline, the potential implications for dry-eye management are significant. “Approaching dry-eye disease can be difficult because there are so many factors involved,” notes Dr. Lasky. “However, we continue to learn and there are a lot of new things brewing, which I'm very excited about.”

1. Akpek EK, Wirta DL, Downing JE, et al. Efficacy and safety of a water-free topical cyclosporine, 0.1%, solution for the treatment of moderate to severe dry eye disease: The ESSENCE-2 randomized clinical trial. *JAMA Ophthalmol*. Published online April 6, 2023. doi:10.1001/jamaophthalmol.2023.0709.

2. Tauber J, Berdy GJ, Wirta DL, et al. NOV03 for dry eye disease associated with meibomian gland dysfunction: Results of the randomized Phase 3 GOBI study. *Ophthalmology* 2023;130:5:516-524.

3. Wirta DL, Senchyna M, Lewis AE, et al. A randomized, vehicle-controlled, Phase 2b study of two concentrations of the TRPM8 receptor agonist AR-15512 in the treatment of dry eye disease (COMET-1). *Ocul Surf* 2022;26:166-173.

4. Tauber J, Laurie GW, Parsons EC, Lacriprep Study Group, et al. Lacriprep for the treatment of primary Sjogren's-associated ocular surface disease: Results of the first-in-human study. *Cornea* 2022 Aug 3;10.1097/ICO.0000000000003091. Online ahead of print.



# FROM BETTER TO BEYOND

We share in your passion to provide **better** glaucoma care and to go **beyond** your patients' expectations.

The most trusted handheld tonometer just got better. **Tono-Pen AVIA®** featuring **Quick-Tap®** Measurement Mode, now you can have more confidence in fewer measurements.

**Ocular Response Analyzer® G3** and **Reichert® 7CR** provide a better pressure measurement with **Corneal Compensated IOP (IOPcc)**, which is less influenced by corneal properties than Goldmann applanation tonometry<sup>1</sup>. And only Ocular Response Analyzer® G3 measures beyond pressure with **Corneal Hysteresis (CH)** which has shown to be an independent risk factor and more predictive of glaucoma development and progression than CCT or IOP<sup>2-4</sup>.

WATCH NOW



WATCH NOW AT:  
[REICHERT.COM/GLAUCOMA](https://www.reichert.com/glaucoma)

**Reichert**  
AMETEK

*passionate about eye care*





EDITED BY KULDEV SINGH, MD, MPH,  
AND PETER A. NETLAND, MD, PHD

## GLAUCOMA MANAGEMENT

# Conjunctival Dehiscence Repair

*Manipulating friable tissue after tube exposure takes patience and meticulous dissection. Here's guidance.*

**JONATHAN EISENGART, MD**  
CLEVELAND, OHIO

**C**onjunctival dehiscence or retraction usually heals on its own with time; however, when the dehiscence exposes an underlying glaucoma drainage device, immediate repair is needed to reduce the chances of further complications such as hypotony and endophthalmitis.<sup>1,2</sup>

Wound dehiscence may occur in the early postoperative period, and erosion may occur in the late postoperative period.<sup>2</sup> Repairing the conjunctiva after a tube exposure is challenging, especially if the patient has undergone previous conjunctival surgeries. Here, I'll share a case example and describe my approach to conjunctival repair after tube exposure.

### Risk Factors

Patient risk factors for conjunctival dehiscence include older age, high doses of topical and oral steroids, tobacco use and prior conjunctival surgeries. Immune mechanisms may also play a role.<sup>3</sup>

Dehiscence risk after GDD implantation can be decreased by placing the tube superiorly. In a small study of patients who received Ahmed glaucoma valves (n=158),<sup>4</sup> the inferonasal quadrant

was associated with the highest dehiscence rate (4/7, 57.1 percent), followed by the inferotemporal quadrant (30/65, 46.2 percent), the superotemporal quadrant (15/61, 24.6 percent) and the superonasal quadrant (4/25, 16 percent) ( $p<0.0073$ ).

This same study also reported that using a greater number of preoperative hypotensive medications affected dehiscence rates. The 91 (57.6 percent) subjects who didn't experience complications used an average of 3.3 hypotensive medications before surgery, compared with 3.8 and 3.9 medications used by the dehiscence and exposure groups, respectively ( $p=0.01$ ).

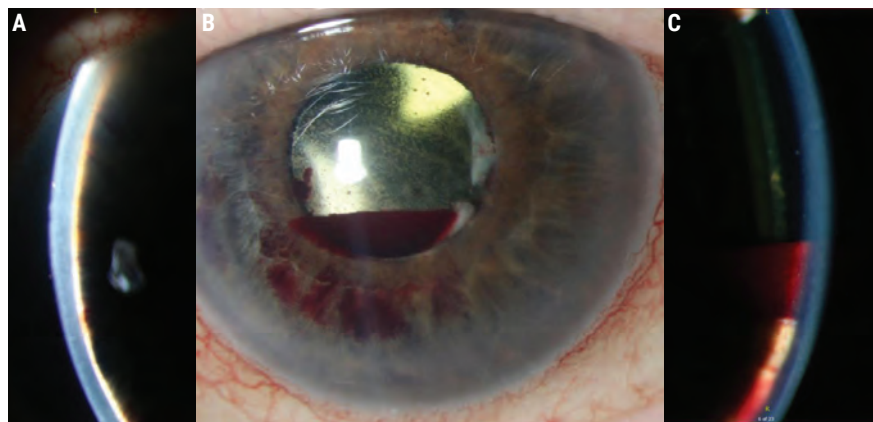In two cases reported in the literature, wound dehiscence and Ahmed valve exposure occurred with the use of adjunctive subconjunctival bevacizumab injection.<sup>5</sup>

### Case Example: Tube Exposure

An 82-year-old female patient was referred to my colleague with a shallow anterior chamber and high pressure. Two months prior, she'd undergone pars plana vitrectomy for vitreous hemorrhage. Her visual acuity in the right eye was counting fingers and her pressure was 25 mmHg. Medications included timolol, dorzolamide, brimonidine and latanoprost as well as acetazolamide pills and atropine.

Slit lamp exam showed an extremely shallow anterior chamber with extensive iris-cornea touch (Figure 1A), and a small hyphema settling between the cornea and lens implant over the pupil (Figure 1B, C). Fundus exam showed a normal disc (cup-to-disc ratio: 0.4), drusen and normal periphery.

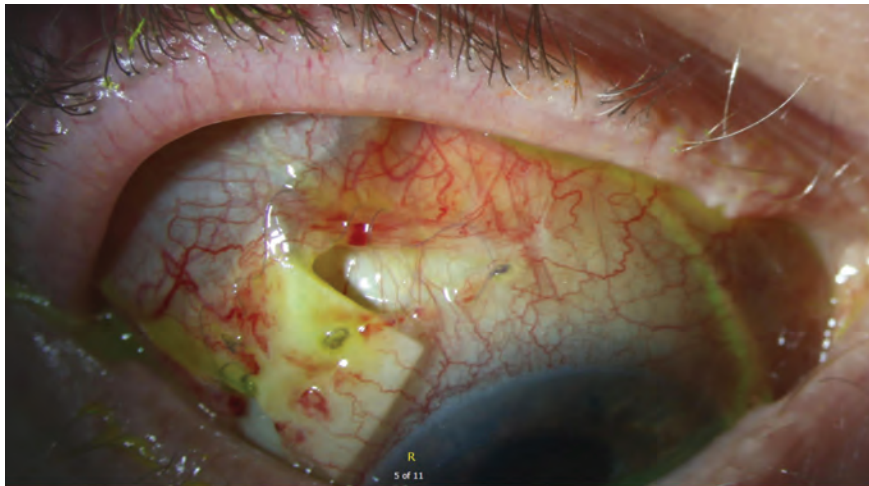She was diagnosed with aqueous



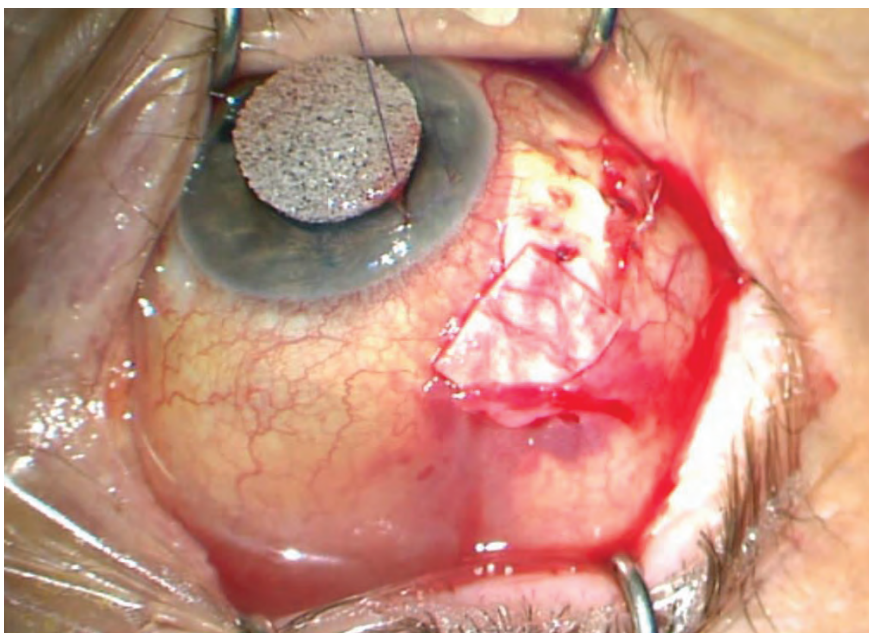
**Figure 1.** This patient had an extremely shallow anterior chamber with extensive iris-cornea touch (A), causing the hyphema to settle between the cornea and lens implant over the pupil (B,C). Fundus exam showed a normal disc (cup-to-disc ratio: 0.4), drusen and normal periphery.

This article has no commercial sponsorship.

**Dr. Singh** is a professor of ophthalmology and chief of the Glaucoma Division at Stanford University School of Medicine. He is a consultant to Alcon, Allergan, Santen, Sight Sciences, Glaukos and Ivantis. **Dr. Netland** is Vernah Scott Moyston Professor and Chair at the University of Virginia in Charlottesville.



**Figure 2.** The patient's eye on postoperative week three, following a pars plana vitrectomy to remove retained vitreous skirt and Ahmed tube placed through the pars plana. High-dose prednisolone and prednisone were initiated for serosanguinous choroidals. The steroids likely resulted in this dehiscence. Note the 8-0 Vicryl braided sutures (purple) have cheese-wired through the anterior edge of the conjunctiva.



**Figure 3.** An additional patch graft was placed but the conjunctiva couldn't close.

misdirection due to retained vitreous skirt and subsequently underwent pars plana vitrectomy with an Ahmed tube placed through the pars plana. On postoperative day one, her anterior chamber had reformed and IOP was 14 mmHg. At postoperative week one, her IOP was 13 mmHg and she developed large serosanguinous choroidals. It's common after a sudden pressure drop for fluid to collect in the

suprachoroidal space. In case these effusions had an inflammatory component the patient was treated with high-dose steroids, both oral (prednisone) and topical (prednisolone acetate).

Normally, the conjunctival surgical incisions would begin to scar and heal over time, but a high steroid dose can inhibit healing. This likely contributed to the split incision seen in Figure 2. If

you look carefully, you can see the purple 8-0 Vicryl suture is still intact in the conjunctiva after cheese-wiring through the anterior edge of the conjunctiva. Surgical repair was performed. Intraoperatively, an additional patch graft was placed but there wasn't enough conjunctival mobility to achieve closure (*Figure 3*).

### Case Example: Procedure

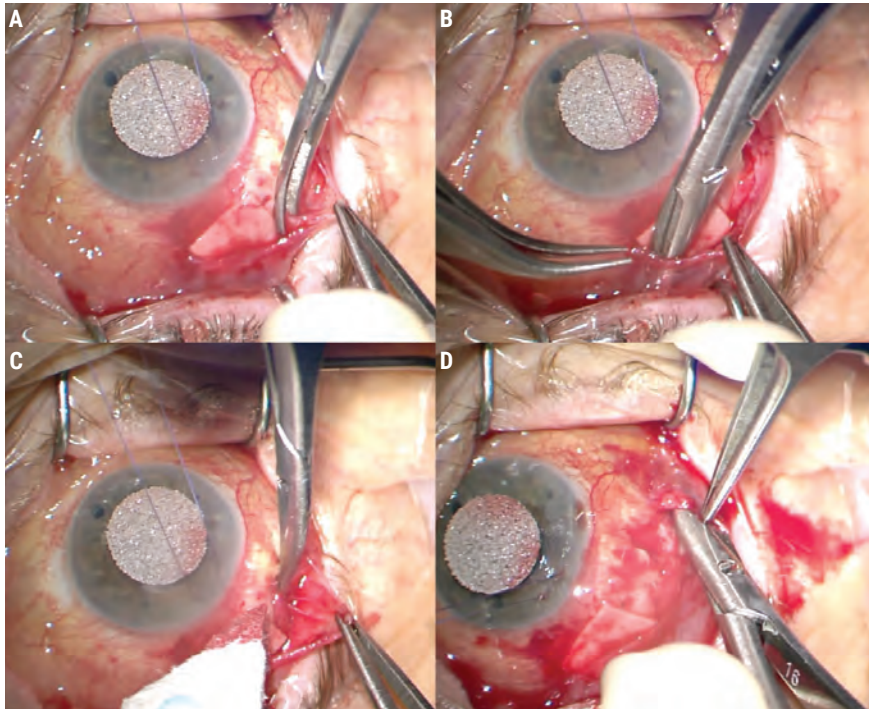
In this patient, Tenon's capsule has scarred down to the underlying sclera, to the tube and to the patch graft. My goal is to try to mobilize the conjunctiva by dissecting it off Tenon's capsule. This will create enough redundancy to enable the conjunctiva to come forward to the incision line in a tension-free way.

I start by finding the plane to separate conjunctiva off from underlying Tenon's capsule. Using tying forceps and Wescott scissors, I perform a combination of blunt and sharp dissection (*Figure 4A*). Pulling the conjunctiva over the scissors (*Figure 4B*) ensures direct visualization so you won't cut through the conjunctiva inadvertently and create a buttonhole.

Be sure to test the mobility of the tissue as you work (*Figures 4C-D*). Dissect broadly and work until the conjunctiva comes up to the incision line in a tension-free way (*Figure 5A*). If you close the conjunctiva under tension, it'll pull itself apart again.

Using a CS160-8 needle, I then place a few anchoring sutures with 9-0 Vicryl monofilament through the posterior lip of the conjunctiva to secure it anteriorly to the sclera (*Figure 5B*). These initial sutures help to relieve any tension hanging on the incision. Finally, I use the same suture in a running fashion to close the conjunctiva (*Figures 5C-D*). (A video of this procedure is available in the online version of this article at [reviewofophthalmology.com](http://reviewofophthalmology.com).)

At postop day 10, the patient's



**Figure 4.** Blunt and sharp dissection is used to separate Tenon's capsule from the conjunctiva (A). Pulling the conjunctiva over the scissors will help avoid creating a buttonhole (B). Test the tissue's mobility periodically (C) and dissect broadly (D).

visual acuity was 20/60 and her pressure was 3 mmHg with a deep anterior chamber. Conjunctival closure remained intact.

In some cases, there's inadequate conjunctival tissue to cover the defect. In this situation, the clinician can consider circumferential relaxing incisions posteriorly in the fornix, pedicle flaps or autologous conjunctival patch grafts.<sup>6</sup>

### Conjunctival Incisions

The two most commonly used conjunctival incisions for Ahmed

valve placement are shown in Figure 6. The patient in the case example had their tube placed using the incision shown in red. This is a circumferential incision, usually placed 3 to 5 mm behind the limbus. The incision shown in green is a limbal peritomy with radial relaxing incisions at each end. Importantly, the incision type itself doesn't affect dehiscence likelihood,<sup>4</sup> but rather, the type of incision matters in terms of what happens in the event the incision splits open after surgery.

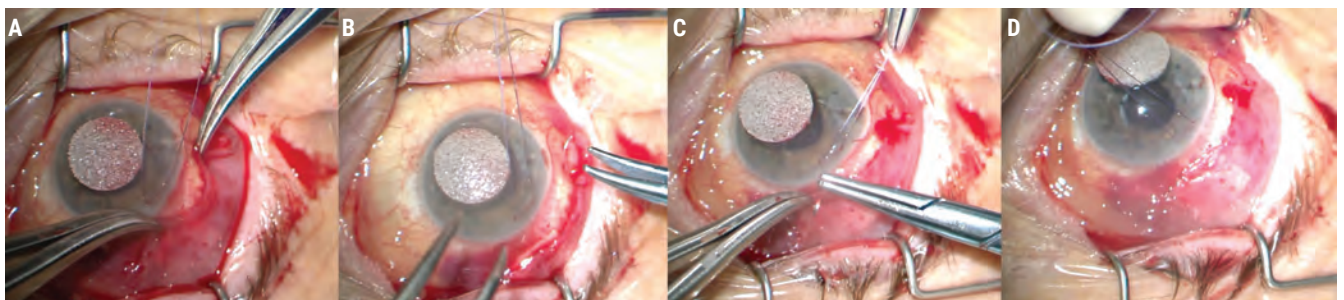
Accessing the plate and placing the tube using a circumferential incision involves less tissue dissection. However, if the incision splits open, this type of incision exposes the tube implant or plate beneath it (Figure 7A). On the other hand, if the radial relaxing incisions open up, there's only bare sclera underneath them (Figure 7B). I see these open up every once in a while, and the native conjunctiva typically heals in very nicely. Oral doxycycline may be used for conservative management of conjunctival retraction without the need for the surgery.<sup>7</sup>

When placing tubes, I prefer using a limbal peritomy with radial relaxing incisions. I tunnel the tube, so it runs across the surface of the sclera (dotted line, Figures 6 and 7) and enters the anterior chamber through a scleral tunnel about 3 mm from the limbus. This ensures that if the conjunctiva retracts from the limbus a bit, it won't expose the tube, only native sclera or sometimes the scleral graft beneath it.

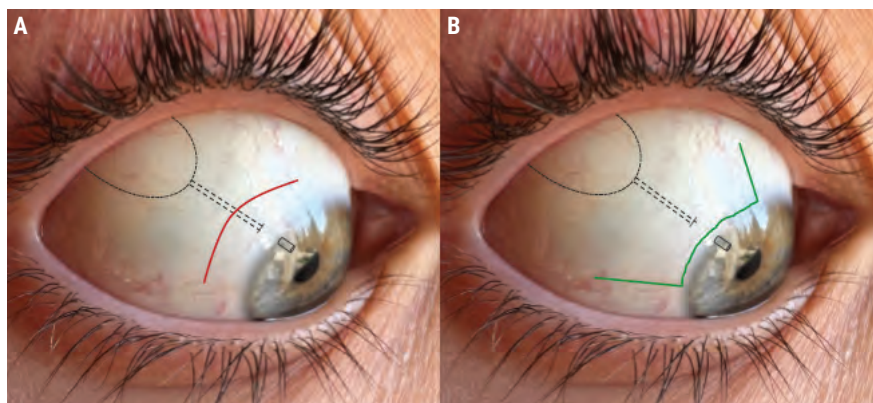
### Pearls for Success

Conjunctival dehiscence repair often involves working with friable and/or scarred-down tissue. Here are some pearls to ensure good closure:

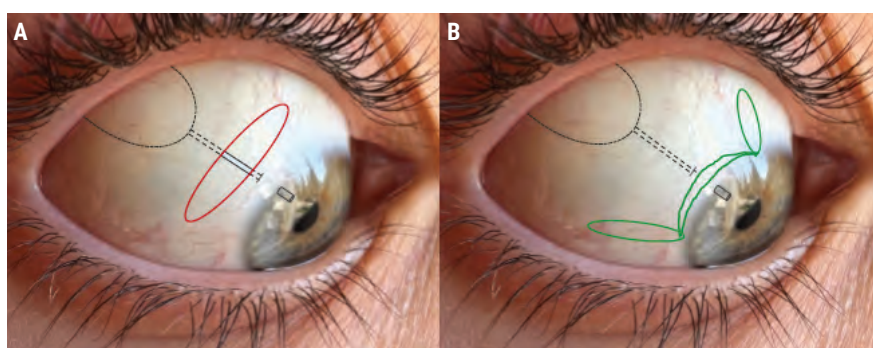
- **Loosen the speculum and traction suture.** When performing surgical maneuvers on the top part of the eye, the traction suture



**Figure 5.** Continue dissecting until the conjunctiva comes up to the incision line in a tension-free manner (A). Place anchoring sutures at the posterior lip of the conjunctiva to secure it to the sclera and relieve tension on the incision (B). Suture the conjunctiva in place (C). The conjunctiva should close without tension (D).



**Figure 6.** A diagram of Ahmed glaucoma valve placement with a circumferential incision (A, red) and a limbal peritomy with radial relaxing incisions at each end (B, green).



**Figure 7.** If conjunctival dehiscence occurs with a circumferential incision (A, red), the underlying tube implant or plate may become exposed, requiring immediate repair. A limbal peritomy with relaxing incisions (B, green) won't expose hardware since there's only bare sclera beneath it. These dehiscences will often heal on their own.

pulls the eye down and speculum holds the eye open. However, this puts the conjunctiva under a lot of stress and can make it very difficult to advance to the limbus. Loosening the speculum and loosening the traction suture to let the eye return to a more neutral position will make a difference when it comes to mobilizing the conjunctiva up to the limbus or incision.

• **Widely mobilize the conjunctiva.** Be sure to use meticulous blunt and sharp dissection when mobilizing tissue. You may need to dissect widely to get the conjunctiva to come up to the limbus. As I mentioned previously, a tension-free closure is key for repairing dehiscence. If you have to pull hard on the tissue to get the conjunctiva to come up, it's likely to pull itself apart later.

• **Avoid cautery when possible.**

Cautery causes tissue to shrink. For obvious reasons, this is inadvisable if you already have barely enough tissue to close the wound.

• **Use monofilament suture for closure.** In the case example, 8-0 Vicryl was used following the pars plana vitrectomy and tube placement. This is a braided suture, and it's a popular choice because it's strong and flexible. I've found it can be irritating to the conjunctiva, however. In Figure 3, the tissue is quite red around the sutures.

Monofilament suture, on the other hand, is a single filament as the name suggests. It's stiffer and the suture knot tails can be more uncomfortable for the patient. However, there are advantages to this type of suture when it comes to repairing the conjunctiva. As a single filament, it's smooth and

pulls through tissue easily without cutting or abrading. Therefore, monofilament sutures are much less likely to cheese-wire through the tissue. They also seem not to inflame the conjunctiva as much as a braided suture, where the rough, braided texture can collect debris and cause inflammation. I've found that with monofilament suture the conjunctiva tends to be quieter.

• **Use postoperative steroids conservatively.** Don't stymie the healing process. Allowing the tissue to heal and scar in place will help to avoid any future retraction or dehiscence.

In summary, if the conjunctiva falls apart, it's important to keep the following in mind: separate the conjunctiva from Tenon's capsule, ensure you've done a broad enough dissection with sufficient mobility and ensure the closure is tension free. ◀

1. Gedde SJ, Scott IU, Tabandeh H, et al. Late endophthalmitis associated with glaucoma drainage implants. *Ophthalmology* 2001;108:7:1323-1327.
2. Panda S, Khurana M, Vijaya L, George R, Balekudaru S. Comparison of conjunctiva-related complications between scleral and corneal patch grafts in Ahmed glaucoma valve implantation. *Indian J Ophthalmol* 2023;71:3:881-887.
3. Chaku M, Netland PA, Ishida K, Rhee DJ. Risk factors for tube exposure as a late complication of glaucoma drainage implant surgery. *Clin Ophthalmol* 2016;10:547-553.
4. Geffen N, Buys Y, Smith M, et al. Conjunctival complications related to Ahmed glaucoma valve insertion. *J Glaucoma* 2014;23:2:109-114.
5. Miraftebi A and Nilforushan N. Wound dehiscence and device migration after subconjunctival bevacizumab injection with Ahmed glaucoma valve implantation. *J Ophthalmic Vis Res* 2016;11:1:112-115.
6. Lawrence SD, Netland PA. Inadequate conjunctival coverage. In: Feldman RM, Bell NP, eds. *Complications of Glaucoma Surgery*. New York, NY: Oxford University Press, 2013, pp. 258-264.
7. Gupta P, Senthil S, Srirampur A, Mittal P. Role of oral doxycycline in the management of conjunctival dehiscence following glaucoma drainage device. *Int Surg J* 2017;4:7:2369.

**ABOUT THE AUTHOR**



**Dr. Eisengart** is a glaucoma specialist at the Cleveland Clinic Cole Eye Institute in Ohio. He has no related financial disclosures.



EDITED BY CARL REGILLO, MD,  
AND YOSHIHIRO YONEKAWA, MD

RETINAL INSIDER

# Pearls for Posterior IOFB Management

*A discussion of the various types of intraocular foreign bodies, and how best to diagnose and treat IOFB injuries to the retina.*

CHLOE Y. LI, MD, JIN KYUN OH, MD, JENNIFER ADEGHATE, MD, AHMET HONDUR, MD, AND ROYCE CHEN, MD  
NEW YORK CITY

Ocular trauma represents a significant cause of visual morbidity associated with both individual loss of quality-of-life and a societal health burden. Annually, over 15,000 workers are injured in the United States alone due to eye trauma, with an associated \$300-million dollar per year cost in treatment and lost productivity.<sup>1,2</sup> Among the most devastating forms of ocular trauma are intraocular foreign bodies, which occur secondary to penetrating eye injury by a high-velocity object.<sup>3,4</sup> IOFBs constitute one of a handful of ophthalmic emergencies and even with prompt identification and treatment can lead to devastating vision loss or blindness.<sup>3,4</sup> Here, we'll discuss the nature of various IOFB injuries and provide diagnostic and management tips to help you achieve the best outcomes.

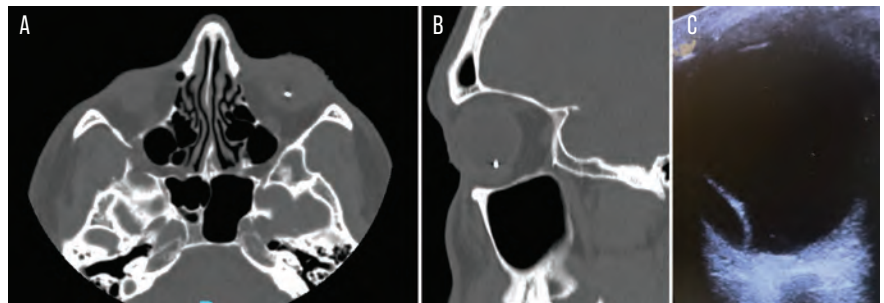
## IOFB Injury Background

The morbidity associated with IOFBs is closely tied to several characteristics including the mechanism of injury and material composition of the foreign body. The most ubiquitous cause of IOFB reported globally is hammering, especially metal-on-metal,

followed closely by use of power tools and weapons or explosives.<sup>5-8</sup> These mechanisms of injury typically introduce metallic IOFBs which can often lead to secondary chronic inflammatory responses such as chalcosis or siderosis bulbi in the case of copper or iron foreign bodies respectively.<sup>9,10</sup> Organic IOFBs such as animal hairs, vegetable matter, or insect parts, in contrast, introduce contaminants and lead to higher rates of fulminant endophthalmitis.<sup>8,11,12</sup> Other characteristics such as object shape, size, and trajectory can also impact prognosis. Sharp, regularly shaped foreign bodies

tend to cause less damage to the eye than those that are irregularly shaped or blunt.<sup>13,14</sup> Similarly, those that travel shorter distances within the eye are less harmful than those that ricochet or penetrate further posteriorly.<sup>15</sup>

Several studies have explored the evolving socioeconomic burden of IOFBs on a regional and international scale. Despite increasing awareness and actionable policies in countries such as the United Kingdom and Hong Kong, which have mandated protective eyewear in the workplace, the overall incidence of IOFB has been increasing since 2008, and the disability-adjusted life-years lost to IOFBs have also increased by nearly 50 percent since the early 1990s.<sup>16,17</sup> Greater than 90 percent of patients who present with IOFBs are young working class males between the ages of 21 and 35, coinciding with previously described increased rates of trauma in this age group as well as a higher prevalence of manual labor and military service.<sup>5,16-18</sup> Estimates

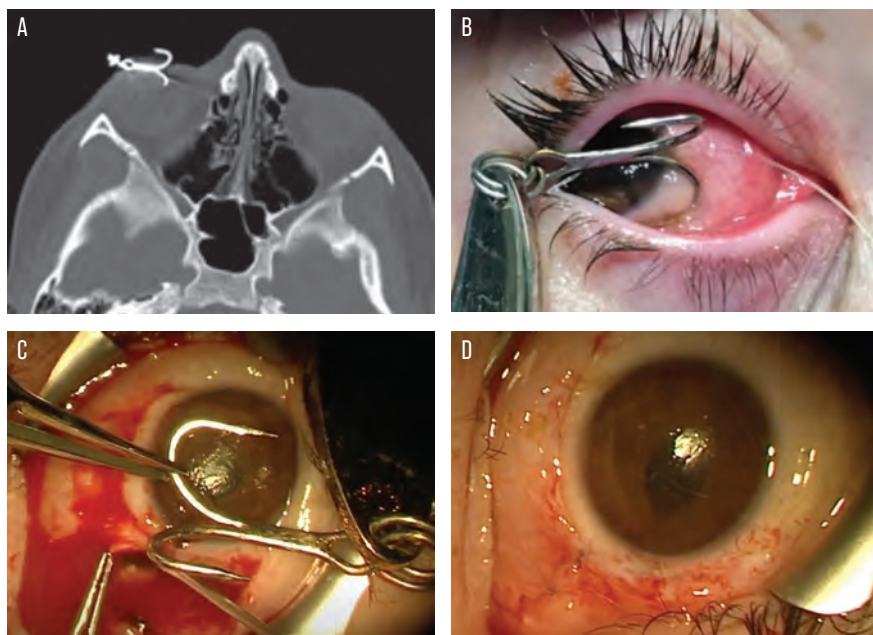


**Figure 1.** A case of an occult IOFB. A 28-year-old man presented 11 days after “feeling something get in [his] eye” while hammering wood and metal at work. On day one after injury, he had undergone dilated fundus exam at another facility and was diagnosed with vitreous hemorrhage and choroid rupture. A CT scan wasn't performed. Ten days later, he presented to our emergency room with severe pain and vision loss, and underwent CT orbits which showed a metallic IOFB in the left eye (A, axial view; B, sagittal view; C, axial ultrasound scan showing hyperechoic area representing IOFB). By the time of presentation, he had developed *Bacillus thuringiensis* endophthalmitis. Despite systemic and intravitreal antibiotics, as well as attempted vitrectomy with IOFB removal, the eye was enucleated.

This article has no commercial sponsorship.

**Dr. Regillo** is the director of the Retina Service of Wills Eye Hospital, a professor of ophthalmology at Thomas Jefferson University School of Medicine and the principle investigator for numerous major international clinical trials.

**Dr. Yonekawa** is an assistant professor of ophthalmology at Sidney Kimmel Medical College at Thomas Jefferson University. He serves on the Education Committee of the American Society of Retina Specialists and on the Executive Committee for the Vit Buckle Society, where he is also the vice president for academic programming.



**Figure 2. Case of fishhook IOFB. A 12-year-old girl presented immediately after a multi-pronged fishhook flew into her right eye. CT appearance of fishhook (A). Preoperative appearance of the fishhook IOFB (B). Intraoperative appearance of IOFB with inferior scleral laceration (C). Immediate postoperative appearance of eye (D). On postoperative day two, the visual acuity in this eye was 20/70, pinholing to 20/25. Luckily for her, the fishhook prong entered at the limbus and exited at the pars plana, sparing both the cornea and retina. Amazingly, she entered and won a golf chipping tournament just two weeks after the injury! Visual acuity at POM1 returned to 20/20.**

of protective eye equipment use among workers in high-risk occupations such as construction varies from as low as 6 percent up to 20 percent, representing a significant proportion of potentially preventable injury.<sup>3,4,19</sup> The development of practical policy changes is crucial to address this rising incidence of IOFBs.

A significant percentage of IOFBs are located in the posterior segment of the eye (reports place the incidence at between 42 and 69 percent).<sup>5,20</sup> Posterior IOFBs require vitreoretinal surgical intervention for removal of IOFB, prevention of complications such as sympathetic ophthalmia and siderosis, and globe salvage.<sup>21,22</sup>

### Diagnostic Evaluation

Posterior IOFB can present as an obvious penetrating injury, with or without concurrent open globe injury (OGI), or as an occult injury.<sup>8,13,15</sup> See Figure 1 for an example of occult IOFB, and Figure 2 for an obvious

penetrating injury. Urgent ophthalmic examination of any patient with concern for IOFB is appropriate.

First, obtain a thorough history, including details on how, where and when the initial injury occurred. Review the patient's baseline vision, history of ocular disease and surgery, and medical history. Perform visual acuity testing, pupillary examination, extraocular movement examination, non-contact tonometry, slit lamp examination and dilated fundus examination, taking care to avoid any exertion of pressure on the globe, as IOFB is frequently associated with OGI.

Obvious signs of OGI such as full-thickness corneal or scleral laceration, positive Seidel test or expulsion of uveal contents should prompt urgent surgical exploration, as delay in primary repair is associated with worse visual outcome and a higher risk of endophthalmitis.<sup>23–25</sup> Though you should consider the possibility of

IOFB in any patient with OGI, some mechanisms of OGI are associated with higher risk of IOFB than others: Patients with mechanisms of injury involving high-velocity projectile objects (e.g., gunshots, explosive devices, blast injuries and motor vehicle accidents), grinding or hammering of metallic or organic objects, or shattering of objects close to the face are considered at higher risk of IOFB.<sup>13,15,26,27</sup>

Patients aren't always aware that they've experienced a penetrating ocular injury, and there's not always an obvious entry wound or globe rupture.<sup>13</sup> Many cases of delayed diagnosis of posterior IOFB have been reported,<sup>28,29</sup> often with poor visual outcome due to siderosis<sup>30</sup> or endophthalmitis.<sup>31</sup> Clinicians should maintain a high index of suspicion of IOFB in patients who report any history of injury involving the high-risk mechanisms described above on their initial evaluation. In the setting of a high-risk injury, presence of focal traumatic cataract, peaked pupil, focal iris transillumination defect, positive Seidel test, hemorrhagic chemosis, fresh hyphema or vitreous hemorrhage, or fresh retinal tear or detachment suggest the presence of IOFB, even in the absence of globe rupture.<sup>8,21,27</sup>

Orbital imaging can be critical in establishing IOFB diagnosis, especially in cases where IOFB is suspected but there's no globe rupture or clinically visible IOFB. Computed tomography of the orbits, in thin slices (less than 1.5 mm), is preferred for IOFB and OGI diagnosis, as it's readily available in the emergency setting, requires little cooperation from the patient, and doesn't require handling of the globe.<sup>21,32</sup> Orbital CT imaging is highly sensitive for IOFB, and can detect metallic IOFBs larger than 0.06 mm<sup>3</sup> and glass IOFBs larger than 1.8 mm.<sup>3,33</sup> Organic IOFBs, such as wood, plastic or clay, are more difficult to detect on CT than metallic IOFBs, but CT still surpasses other modalities in ability to detect these.<sup>34</sup>

**TABLE 1. SUMMARY OF VISUAL OUTCOMES IN POSTERIOR SEGMENT IOFBs**

Paper	Number of eyes	Country of origin	% in highest final VA category	% in moderate final VA category	% VA in worst final VA category	Factors associated with worse VA
Hapca et al., 2022 <sup>43</sup>	56	Romania	VA >20/40	VA between 20/40 and 20/200	VA less than 20/200	Worse initial VA, retinal (vs. vitreous) IOFB, RD at presentation, endophthalmitis
			19.6%	26.8%	53.6%	
Vingopoulos et al., 2021 <sup>20</sup>	24	USA	VA >20/80	VA between 20/80 and 20/200	VA <20/200	Not analyzed for posterior IOFBs only, but among all IOFBs posterior IOFB significantly associated with worse vision
			54.2%	0%	45.8%	
Rozon et al., 2021 <sup>47</sup>	54	Canada	VA >20/40	VA between 20/40 and 20/200	VA <20/200	Worse initial VA, older age, complications following primary repair (endophthalmitis, retinal tear, RD, PVR)
			50%	2%	49%	
Mukkamala et al., 2016 <sup>44</sup>	31	USA	VA >20/40*	VA between 20/40 and 20/400	VA between CF and LP	Worse initial VA, RD or RT (not statistically significant associations)
			29%	61%	37%	
Choovuthayakorn et al., 2011 <sup>41</sup>	77	Thailand	VA >20/40	VA between 20/40 and 20/200	VA <20/200	Presence of RAPD, RD, endophthalmitis
			36.4	15.6	48	

These authors' percentages do not add to 100 percent in their original report.

Magnetic resonance imaging isn't recommended for acute evaluation of IOFB because of the preponderance of IOFBs are metallic, with vastly different ferromagnetism depending on composition. MRIs are also difficult to obtain in a timely manner in the emergency setting.

If CT imaging is unavailable, plain radiographs of the orbit can detect metallic IOFBs in 70 to 90 percent of cases, with a reported sensitivity of 96 percent and specificity of 99 percent.<sup>35</sup> Plain X-rays are limited by their inability to detect any non-metallic

IOFB. Ultrasonography, including high-frequency ultrasound biomicroscopy, can be considered as an adjunctive or alternative method of evaluation for IOFB if there's low concern for globe rupture.

### Surgical Management

Following are the main considerations at the various stages of surgery for IOFBs:

- **Surgical timing.** Timing of IOFB removal remains controversial and inconsistent, with conflicting results in the literature.<sup>25,36-40</sup> The most impor-

tant factor in timing of IOFB removal is the presence or risk for endophthalmitis. In the presence of endophthalmitis, immediate IOFB removal is recommended at the time of primary globe repair. Organic IOFBs are highly associated with endophthalmitis, while high-velocity projectiles infrequently lead to endophthalmitis, owing to sterility from the heat they generate.<sup>37</sup> Multiple other ocular and systemic factors can affect the optimal timing for surgical intervention. Factors related to general health status of the patient, such as the presence of

life-threatening injuries and the ability to tolerate surgery, may prohibit operating immediately. Furthermore, in cases where resources aren't available for concurrent IOFB removal and globe repair, a reasonable alternative is to temporize with primary globe repair and intravitreal antibiotics until the patient is transferred for IOFB removal.<sup>25</sup>

The location of the IOFB in the posterior segment may also affect timing of removal. There's an obvious indication for prompt removal if the IOFB was associated with vitreous hemorrhage, retinal break or retinal detachment. In cases without endophthalmitis or vitreoretinal pathology, delaying repair by a few days after primary closure may not adversely affect visual outcomes; however, there remains an increased risk of proliferative vitreoretinopathy development with prolonged exposure to the IOFB. Hence, even in eyes with a low risk of endophthalmitis, there's been an increasing trend for early vitrectomy within a few days after injury.<sup>25,41</sup> Outside of combat scenarios where a majority of IOFBs are sterile, high-velocity projectiles, the composition and sterility of IOFBs are challenging to predict. Therefore in our institution, we prefer to remove the IOFB as soon as possible after the inciting trauma.

• **Antibiotic prophylaxis and choice of anesthesia.** In all cases, start intravenous antibiotics emergently. Also, because of the high risk of endophthalmitis associated with posterior IOFB, administer intravitreal vancomycin and ceftazidime. Coverage for pathogens typically encountered in IOFB such as staphylococcus, streptococcus, *Bacillus*, *Clostridium* and *Pseudomonas* species is crucial.<sup>36</sup> Be sure to obtain cultures, and determine and update the patient's tetanus status. Traditionally, general anesthesia has been preferred over local anesthesia for open globe injuries primarily to avoid the risk of extrusion of ocular contents due to factors that can increase the transmural and intraocular pres-

sure, such as the volume of the local anesthetic, the instrumentation used for the local anesthesia and potential orbital hemorrhage. However, induction of general anesthesia can also elevate the intraocular pressure, and any bucking or coughing during intubation may elevate the intraocular pressure to a greater extent than local anesthesia. Therefore, local anesthesia with monitored anesthesia care (MAC) is becoming more frequent with IOFB surgery.

• **Surgical approaches and considerations.** The goals of surgery are to restore ocular integrity, remove the IOFB, address any retinal pathology and treat or prevent endophthalmitis. While no two cases will be alike, planning ahead for the surgical approach and any potentially required instrumentation is key to a safe and successful surgery intraoperatively. The external approach using electromagnets for removal of posterior-segment IOFBs has mostly become obsolete, and pars plana vitrectomy has become the preferred technique. The instrument size for PPV depends on surgeon's preference, and 23- or 25-gauge are commonly used.

When repairing the entry wound, place the infusion line where you can easily see it. A 6-mm infusion cannula or an anterior-chamber maintainer can be helpful in cases of poor visualization of the infusion cannula due to choroidal detachment, vitreous hemorrhage or lenticular opacity. In cases with small entry wounds, the infusion line can be cautiously opened and closed to maintain intraocular pressure. In larger, irregular wounds, however, we typically restore IOP and anatomy with viscoelastics and wound control before opening the infusion. Corneal wounds are typically closed with 10-0 nylon suture, limbal wounds with 9-0 nylon and scleral wounds with 8-0 nylon. A conjunctival peritomy and exploration may be necessary to determine the extent of the laceration. Care must be taken to prevent extrusion of intraocular structures during open globe repair. At

this point, you can place an encircling scleral buckle in cases of concurrent retinal detachment, or can consider placing one as prophylaxis against retinal detachment or PVR.

Next, address any media opacity in the anterior segment due to the injury. Wash out hyphema, if present. In the case of traumatic cataract, perform phacoemulsification or pars plana lensectomy, either with the vitrector for soft lenses (as is the case in many young IOFB patients) or with the fragmatome. Often, the patient may be left aphakic with plans for a staged secondary intraocular lens placement.<sup>38</sup>

When proceeding to vitrectomy for IOFB removal, consider the need for the optimal placement of additional sclerotomies for the fragmatome or for IOFB removal. Perform a complete vitrectomy with induction of posterior vitreous detachment, if necessary. Use triamcinolone to visualize the vitreous, if needed. Free the IOFB from vitreous traction, and shave the vitreous base. Remove any membranes or scar tissue overlying the IOFB. Then, depending on the size and shape of the IOFB, fashion the route of removal; this may be an existing sclerotomy, a separate pars plana sclerotomy or a scleral tunnel in aphakic eyes. Using the initial entry wound is typically not an ideal exit strategy. Instead, it's preferable to create a separate exit wound that's usually larger than what would appear to be required for the size of the IOFB. A common point of failure in IOFB removal is making too small an exit wound. In these cases, the IOFB may become dislodged from the forceps and fall back upon the retina, causing further damage. You can preplace sutures around sclerotomies to augment rapid closure of the wound immediately after the removal of IOFB.

It's worth considering the use of perfluorocarbon liquid to protect the macula from slippage and dropping of the IOFB or to allow the IOFB to float anteriorly. This strategy may be helpful with non-metallic



IOFBs; however, metallic IOFBs are typically denser than perfluorocarbon liquid and usually don't float. PFCL shouldn't be used in these circumstances.

A variety of instrumentation is available to grasp and remove an IOFB, depending on its size, shape and ferromagnetic properties. You can use a magnet to lift the IOFB from the retinal surface, but this usually requires passing the IOFB in a hand-shake maneuver to forceps in order to grasp it more securely. The straight diamond-dusted forceps are the most widely available and, hence, most commonly used forceps. The Wilson, Machemer, Rappazzo and basket forceps are also useful instruments, but aren't widely available. For irregularly-shaped IOFBs that may not be easily grasped with forceps, consider using a lasso device, such as the Flex-Loop, or one fashioned from Prolene suture threaded as a loop through a cannula. Whatever the tool used to remove the IOFB, the goal should be to remove the IOFB successfully on the first attempt.

Once the IOFB is removed, suture the exit wound immediately and perform a careful peripheral retinal exam, particularly in the sector of removal. Secure any retinal defect at the site of the IOFB embedment with laser retinopexy, which may also be performed prior to removal of the foreign body. If the IOFB has impacted deeper tissues, i.e. the retinal pigment epithelium/choroid, a retinchoroidectomy may be performed to limit scarring and PVR. Depending on the number and location of any retinal breaks and the risk for PVR, you can pursue tamponade with gas or silicone oil. At the end of the case, antimicrobial prophylaxis with intravitreal vancomycin, ceftazidime and amphotericin (especially in cases of organic matter) is recommended.

Postoperative follow-up is focused on monitoring for sequelae of posterior segment IOFB including endophthalmitis, retinal detachment and PVR. With demonstrated stabil-

ity, further visual rehabilitation with silicone oil removal, secondary lens implantation and refraction can be considered.

## Outcomes and Prevention

Among all patients with IOFB, posterior IOFB is significantly associated with higher risk of endophthalmitis, higher rate of RD and reduced final VA as compared to anterior segment IOFB.<sup>20,42</sup> Among those with posterior IOFB, the most consistent factor predictive of functional final VA is presenting VA.<sup>3,4,12,19,20,26,43,44</sup> In posterior IOFB, larger IOFB size is also associated with worse final visual outcome, possibly because a more massive IOFB has higher kinetic energy as it enters the eye and is more likely to cause retinal injury.<sup>45</sup> Unsurprisingly, the presence of relative afferent pupillary defect, endophthalmitis, RD or PVR concomitant with IOFB or following primary posterior IOFB removal are associated with worse final visual outcome.<sup>12,41,46,47</sup> Table 1 summarizes recent case series of posterior segment IOFBs and final visual outcomes, as well as factors associated with worse final visual outcomes.

Given the significant morbidity associated with IOFBs, the best way to improve outcomes is actually to prevent and/or reduce the incidence of such injuries. The development of policies such as those mandated by the Occupational Safety and Health Administration in the United States or the UK Health and Safety at Work Act were important initial interventions to increase the availability of protective eye equipment for workers; however, despite these policy changes in the 20th century, the incidence of IOFBs has increased, and many injured patients still report not using protection.<sup>16,17,48</sup> This suggests that additional education and prevention should be emphasized on both a regional and institutional level. Several studies have evaluated potential educational approaches with mixed results; approaches included the distribution of educational brochures,

personal safety glass fittings, group meetings and both positive reinforcement and discipline.<sup>49-51</sup>

Ophthalmologists, optometrists and emergency medicine providers who often treat these patients also play a significant role in the prevention of injury, both through education and the prescription of polycarbonate glasses in high-risk patients.<sup>16</sup> Notably, behavioral studies demonstrated that a prior history of occupational eye injury drastically increased the use of full-time eye protection from 20 percent to 100 percent, suggesting workers may also be able to educate their peers regarding the necessity of eye protection.<sup>52</sup>

Besides the prevention of IOFB-associated injury, the improvement of surgical outcomes is contingent upon the early recognition and treatment of IOFBs, which typically involves a multidisciplinary team consisting of ophthalmologists, optometrists, emergency room personnel and primary care providers. Education of non-ophthalmic personnel by the ophthalmology community can increase awareness of concerning signs and symptoms and ultimately reduce time to appropriate care.<sup>53</sup> Finally, the training of the next generation of ophthalmic surgeons, as well as refinement of surgical techniques and technology, remain crucial to increase the availability and success of surgical care.

In conclusion, posterior IOFB is an ophthalmic emergency requiring urgent evaluation, early diagnosis and timely vitreoretinal intervention. CT imaging of the orbits is the most sensitive and specific imaging modality for identifying posterior IOFB. Initial intervention should include administration of intravitreal and systemic antimicrobial prophylaxis, including tetanus vaccination. When available, most vitreoretinal specialists now favor early PPV with removal of posterior IOFB, as this is likely associated with lower rates of endophthalmitis and PVR.

Outcomes after posterior IOFB are highly variable. Better presenting

visual acuity, a smaller IOFB, lack of retinal detachment or injury, and lack of endophthalmitis are predictive of better final visual outcome.

The vast majority of posterior IOFB injuries, as well as OGIs, result from work-related or combat-related injuries among young men. Education of the public, as well as individuals at high risk of IOFB, and encouragement to enact worker eye safety protocols may reduce the incidence of IOFB. ◀

1. S. Bureau of Labor Statistics. Survey of occupational injuries and illnesses data. In: U.S. Bureau of Labor Statistics; 2020.
2. Forrest KYZ, Cali JM. Epidemiology of lifetime work-related eye injuries in the U.S. population associated with one or more lost days of work. *Ophthalmic Epidemiology* 2009;16:3:156-162.
3. Greven CM, Engelbrecht NE, Slusher MM, Nagy SS. Intraocular foreign bodies. *Ophthalmology* 2000;107:3:608-612.
4. Ehlers JP, Kunimoto DY, Ittoop S, Maguire JI, Ho AC, Regillo CD. Metallic intraocular foreign bodies: Characteristics, interventions, and prognostic factors for visual outcome and globe survival. *American Journal of Ophthalmology* 2008;146:3:427-433.e2.
5. Liu CCH, Tong JMK, Li PSH, Li KKW. Epidemiology and clinical outcome of intraocular foreign bodies in Hong Kong: A 13-year review. *Int Ophthalmol* 2017;37:1:55-61.
6. Armstrong MFJ. A review of intraocular foreign body injuries and complications in N. Ireland from 1978-1986. *Int Ophthalmol* 1988;12:2:113-117.
7. Bourke L, Bourke E, Cullinane A, O'Connell E, Idrees Z. Clinical outcomes and epidemiology of intraocular foreign body injuries in Cork University Hospital, Ireland: An 11-year review. *Ir J Med Sci* 2021;190:3:1225-1230.
8. Loporchio D, Mukkamala L, Gorukanti K, Zarbin M, Langer P, Bhagat N. Intraocular foreign bodies: A review. *Survey of Ophthalmology* 2016;61:5:582-596.
9. O'Duffy D, Salmon JF. Siderosis bulbi resulting from an intralenticular foreign body. *American Journal of Ophthalmology* 1999;127:2:218-219.
10. Rao NA. Chalcosis in the human eye: A clinicopathologic study. *Arch Ophthalmol* 1976;94:8:1379.
11. Bhagat N, Nagori S, Zarbin M. Post-traumatic infectious endophthalmitis. *Survey of Ophthalmology* 2011;56:3:214-251.
12. Jonas JB, Knorr HLJ, Budde WM. Prognostic factors in ocular injuries caused by intraocular or retrobulbar foreign bodies. *Ophthalmology* 2000;107:5:823-828.
13. Kuhn F, Pieramici D. Intraocular foreign bodies. In: *Ocular Trauma: Principles and Practice*. New York: Thieme, 2002:235-263.
14. Potts AM, Distler JA. Shape factor in the penetration of intraocular foreign bodies. *American Journal of Ophthalmology* 1985;100:1:183-187.
15. Lit ES, Young LHY. Anterior and posterior segment intraocular foreign bodies. *International Ophthalmology Clinics* 2002;42:3:107-120.
16. Jin G, Zou M, Zhang Y, et al. Time trends, associations and global burden of intraocular foreign bodies. *Br J Ophthalmol* 2022;106:3:435-439.
17. Yuan M, Lu Q. Trends and disparities in the incidence of intraocular foreign bodies 1990–2019: A global analysis. *Front Public Health* 2022;10:858455.
18. Imrie FR, Cox A, Foot B, MacEwen CJ. Surveillance of intraocular foreign bodies in the UK. *Eye* 2008;22:9:1141-

- 1147.
19. Zhang Y, Zhang M, Jiang C, Qiu HY. Intraocular foreign bodies in China: Clinical characteristics, prognostic factors, and visual outcomes in 1421 eyes. *American Journal of Ophthalmology* 2011;152:1:66-73.e1.
20. Vingopoulos F, Wang Y, Grob S, et al. Open-globe injury with intraocular foreign body. *Journal of VitreoRetinal Diseases* 2021;5:4:288-294.
21. Jung HC, Lee SY, Yoon CK, Park UC, Heo JW, Lee EK. Intraocular foreign body: Diagnostic protocols and treatment strategies in ocular trauma patients. *JCM* 2021;10:9:1861.
22. Parke DW, Flynn HW, Fisher YL. Management of intraocular foreign bodies: A clinical flight plan. *Canadian Journal of Ophthalmology* 2013;48:1:8-12.
23. Blanch RJ, Bishop J, Javidi H, Murray PI. Effect of time to primary repair on final visual outcome after open globe injury. *Br J Ophthalmol* 2019;103:10:1491-1494.
24. Zhang Y, Zhang MN, Jiang CH, Yao Y, Zhang K. Endophthalmitis following open globe injury. *British Journal of Ophthalmology* 2010;94:1:111-114.
25. Keil JM, Zhao PY, Durrani AF, et al. Endophthalmitis, visual outcomes, and management strategies in eyes with intraocular foreign bodies. *Clin Ophthalmol* 2022;16:1401-1411.
26. Gopal L, Banker AS, Deb N, et al. Management of glass intraocular foreign bodies. *Retina* 1998;18:3:213-220.
27. Upshaw JE, Brenkert TE, Losek JD. Ocular foreign bodies in children. *Pediatric Emergency Care* 2008;24:6:409-414.
28. Yonekawa Y, Qian CX, Patel AV, Kim LA, Elliott D. Occult perforating globe injury caused by intraocular foreign body. *Ophthalmic Surg Lasers Imaging Retina* 2016;47:12:1162-1163.
29. Kaushik S, Ichhpjani P, Ramasubramanian A, Pandav SS. Occult intraocular foreign body: Ultrasound biomicroscopy holds the key. *Int Ophthalmol* 2008;28:1:71-73.
30. Casini G, Sartini F, Louidice P, Benini G, Menchini M. Ocular siderosis: A misdiagnosed cause of visual loss due to ferrous intraocular foreign bodies—epidemiology, pathogenesis, clinical signs, imaging and available treatment options. *Doc Ophthalmol* 2021;142:2:133-152.
31. Nicora SD, Irimescu I, Călinici T, Cristian C. Outcome and prognostic factors for traumatic endophthalmitis over a 5-Year period. *Journal of Ophthalmology* 2014;2014:1-7.
32. Zhou Y, DiScalafani M, Jeang L, Shah AA. Open globe injuries: Review of evaluation, management, and surgical pearls. *Ophthalmology* 2022;16:2545-2559.
33. Tate E, Cupples H. Detection of orbital foreign bodies with computed tomography: Current limits. *American Journal of Roentgenology* 1981;137:3:493-495.
34. Modjtahedi BS, Rong A, Bobinski M, McGahan J, Morse LS. Imaging characteristics of intraocular foreign bodies: A comparative study of plain film X-ray, computed tomography, ultrasound, and magnetic resonance imaging. *Retina* 2015;35:1:95-104.
35. Saeed A, Cassidy L, Malone DE, Beatty S. Plain X-ray and computed tomography of the orbit in cases and suspected cases of intraocular foreign body. *Eye* 2008;22:11:1373-1377.
36. Ahmed Y, Schimmel AM, Pathengay A, Colyer MH, Flynn HW. Endophthalmitis following open-globe injuries. *Eye* 2012;26:2:212-217.
37. Colyer MH, Weber ED, Weichel ED, et al. Delayed intraocular foreign body removal without endophthalmitis during operations Iraqi Freedom and Enduring Freedom. *Ophthalmology* 2007;114:8:1439-1447.
38. Jabłoński M, Winiarczyk M, Biela K, et al. Open globe injury (OGI) with a presence of an intraocular foreign body (IOFB)—Epidemiology, management, and risk factors in long term follow-up. *JCM* 2022;12:1:190.
39. Liu Y, Wang S, Li Y, Gong Q, Su G, Zhao J. Intraocular foreign bodies: Clinical characteristics and prognostic factors influencing visual outcome and globe survival in 373 eyes. *Journal of Ophthalmology* 2019;2019:1-7.
40. Anguita R, Moya R, Saez V, et al. Clinical presenta-

- tions and surgical outcomes of intraocular foreign body presenting to an ocular trauma unit. *Graefes Arch Clin Exp Ophthalmol* 2021;259:1:263-268.
41. Choovuthayakorn J, Hansapinyo L, Ittipunkul N, Patikulasila D, Kunavisarut P. Predictive factors and outcomes of posterior segment intraocular foreign bodies. *Eye* 2011;25:12:1622-1626.
42. Liang Y, Liang S, Liu X, Liu D, Duan J. Intraocular foreign bodies: Clinical characteristics and factors affecting visual outcome. *Journal of Ophthalmology* 2021;2021:1-9.
43. Hapca MC, Muntean GA, Drăgan IAN, Vesa Ștefan C, Nicora SD. Outcomes and prognostic factors following pars plana vitrectomy for intraocular foreign bodies—11-Year retrospective analysis in a tertiary care center. *JCM* 2022;11:15:4482.
44. Mukkamala LK, Soni N, Zarbin MA, Langer PD, Bhagat N. Posterior segment intraocular foreign bodies: A 10-Year review. *Ophthalmology Retina* 2017;1:4:272-277.
45. Woodcock MGL, Scott RAH, Huntbach J, Kirkby GR. Mass and shape as factors in intraocular foreign body injuries. *Ophthalmology* 2006;113:12:2262-2269.
46. Sziájtó Z, Gaál V, Kovács B, Kuhn F. Prognosis of penetrating eye injuries with posterior segment intraocular foreign body. *Graefes Arch Clin Exp Ophthalmol* 2007;246:1:161-165.
47. Rozon JP, Lavertu G, Hébert M, et al. Clinical characteristics and prognostic factors of posterior segment intraocular foreign body: Canadian experience from a tertiary university hospital in Quebec. *Journal of Ophthalmology* 2021;2021:1-7.
48. U.S. Dept. of Labor, Occupational Safety and Health Administration. *Occupational Health OSHA Technical Manual*. For sale by the Superintendent of Documents, U.S. Government Printing Office; 1990.
49. Lipscomb HJ. Effectiveness of interventions to prevent work-related eye injuries. *American Journal of Preventive Medicine* 2000;18:4:27-32.
50. Mancini G. Prevention of work related eye injuries: Long term assessment of the effectiveness of a multicomponent intervention among metal workers. *Occupational and Environmental Medicine* 2005;62:12:830-835.
51. Shah A, Blackhall K, Ker K, Patel D. Educational interventions for the prevention of eye injuries. *Cochrane Injuries Group*, ed. *Cochrane Database of Systematic Reviews*. Published online October 7, 2009. doi:10.1002/14651858.CD006527.pub3
52. Blackburn JL, Levitan EB, MacLennan PA, Owsley C, McGwin G. Changes in eye protection behavior following an occupational eye injury. *Workplace Health Saf* 2012;60:9:393-400.
53. Gupta A, Tripathy K. Intraocular foreign body. In: *StatPearls*. StatPearls Publishing; 2023. [online publication] Accessed March 21, 2023. <http://www.ncbi.nlm.nih.gov/books/NBK576415/>.

ABOUT THE AUTHORS



**Chloe Y Li, MD, MA, and Jin Kyun (Luke) Oh, MD** are ophthalmology residents at Columbia University Medical Center.

**Jennifer Adeghate, MD, and Ahmet Hondur, MD**, are fellows in vitreoretinal surgery at Columbia University Medical Center.

**Royce W.S. Chen, MD**, is an associate professor of ophthalmology at Columbia University Medical Center.

# Combo Treatment for Herpes Stromal Keratitis

**W**hen used together with an antiviral such as acyclovir, corticosteroid treatments could be more effective for herpes stromal keratitis compared with monotherapy of an antiviral or corticosteroid, researchers say.

Among classifications of herpes simplex keratitis, herpes stromal keratitis is a leading cause of irreversible corneal scarring, thinning, neovascularization and infectious blindness worldwide. Disease outcomes including vision loss, neovascularization and angiogenesis may progressively worsen after each recurrence. The standard treatment for herpes stromal keratitis includes antiviral medications in combination with corticosteroids, which addresses both the viral and immunomodulatory pathogenicity of the condition by reducing inflammation and inhibiting herpes simplex virus replication in the corneal stroma. Researchers recently conducted a systematic review to identify and compare interventions for treating herpes stromal keratitis and patient outcomes. They found that corticosteroids and antivirals managed the condition most effectively only when used concurrently. Results fared better than using either as monotherapy.

Two independent reviewers screened 168 records and used seven papers for data extraction. The research team examined both the conventional treatment with corticosteroids and antivirals and potential alternatives such

as flurbiprofen, cyclosporine A and tacrolimus by their treatment success rate, best-corrected visual acuity, resolution time of successful treatment, time to failure, IOP and adverse events.

Patients with herpes stromal keratitis who received prednisolone phosphate and acyclovir showed a higher treatment success rate and significantly longer time to failure compared with patients receiving only acyclovir. No difference in resolution time was found between oral and topical acyclovir. Between groups receiving dexamethasone and flurbiprofen, resolution occurred in 93 percent and 67 percent of patients and BCVA (log-MAR) improved from 1.0 to 0.30 and 0.48, respectively. BCVA improved in both cyclosporine A and its control (prednisolone) groups. A tacrolimus treatment group showed greater improvement in best-corrected visual acuity compared with its control (prednisolone) group.

“These interventions could be potential novel approaches to the management of herpes stromal keratitis and allow health practitioners and patients—especially those who are unsuccessful with the standard treatment—to have access to alternative treatment plans that could be equally effective and potentially safer with fewer side effects,” the researchers wrote in their paper in *Ophthalmic Epidemiology*.

*Ophthalmic Epidemiol.* May 15, 2023. [Epub ahead of print].  
Li X, Nayeni M, Malvankar-Mehta MS.

## Calcium Channel Blockers Linked to Glaucoma

A recent meta-analysis published in *Ophthalmology* examined associations of four categories of systemic medications—antihypertensives, lipid-lowering drugs, antidepressants and antidiabetic agents—with glaucoma prevalence and IOP in 11 population-based cohort studies of the European Eye Epidemiology consortium. The team found significant associations between use of calcium channel blockers, one class of antihypertensive studied, and increased glaucoma prevalence. However, nonselective and selective beta-blockers were associated with lower IOP. Use of other antihypertensive medications, lipid-lowering medications, antidepressants or antidiabetic medications was not associated with glaucoma prevalence or lower IOP.

A total of 143,240 participants were included in the glaucoma analyses and 47,177 participants in the IOP analyses. Antihypertensive drugs assessed included beta-blockers, diuretics, calcium channel blockers, alpha-agonists, angiotensin-converting enzyme inhibitors and angiotensin II receptor blockers. Associations with antidiabetic medications were examined in diabetic participants only.

In the meta-analyses, use of calcium channel blockers was associated with a higher prevalence of glaucoma (odds ratio [OR]: 1.23). This association was stronger for monotherapy of calcium channel blockers with direct cardiac effects (OR: 1.96). Use of systemic beta-blockers was associated with a lower IOP (-0.33 mmHg). Monotherapy of both selective (-0.45 mmHg) and nonselective (-0.54 mmHg) systemic beta-blockers was associated with lower IOP. There was a sug-

gestive association between use of high-ceiling diuretics and lower IOP ( $-0.30$  mmHg) but not when used as monotherapy.

“It is possible that systemic beta-blockers do not reduce the risk of glaucoma per se, but limit the detection of glaucoma given that elevated IOP is often a trigger for diagnosing glaucoma,” the authors noted in their paper. “The blood pressure-lowering effect of systemic beta-blockers may thus balance out the IOP-lowering effect on glaucoma risk, explaining the null association between use of systemic beta-blockers and glaucoma prevalence.”

The researchers also found that nocturnal systemic hypotension may be associated with increased risk of glaucoma progression. “This may thus explain the association between calcium channel blockers and increased glaucoma prevalence, if calcium channel blockers are preferentially taken at bedtime,” they proposed.

Because time of medication use was not known in the studies examined, they were not able to provide evidence for this hypothesis.

“A potentially harmful association of calcium channel blockers for glaucoma is particularly noteworthy, as this is a commonly prescribed class of medication,” the researchers concluded in their paper. “If further studies confirm a causal nature for this association, this may inform alternative treatment strategies for hypertensive patients with, or at risk of, glaucoma.”

*Ophthalmology*. May 5, 2023.

[Epub ahead of print].

Vergroesen JE, Schuster AK, Stuart KV, et al.

## Minimizing Systematic Bias in IOL Power Calculations

Scientists developed a simplified method to optimize lens constants to zero the Mean Prediction Error of an intraocular calculation formula, without the need to program the formula itself, by exploring the influence of IOL and corneal power on the refractive impact of variations in effective lens position.

They looked at retrospective data from 8,878 patients with cataracts with pre- and postoperative measurements available using four IOL models and six IOL power calculation formulas.

The scientists used a schematic eye model to study the impact of small variations in effective lens position on the postoperative spherical equivalent refraction. They investigated the impact of keratometry and IOL power (P) on SE and used a theoretical thick lens model to devise a formula to zero the average prediction error of an IOL power calculation formula. This was achieved by incrementing the predicted effective lens position, which could then be translated into an increment in the intraocular lens constant. This method was tested on documented real-life postoperative datasets, using different intraocular lens models and single-constant optimized IOL calculation formulas.

Here are some of the findings from the paper:

- For small variations in ELP, an exponential relationship was found between IOL power and the resultant postoperative refractive variation.
- The ELP adjustment necessary to zero the mean prediction error equated to a ratio between the mean prediction error and the mean of the following expression:  $0.0006*(P^2+2K*P)$  on the considered datasets.
- The accuracy of the values obtained using this formula was confirmed on documented postoperative datasets, and on published and non-published lens-calculation formulas.

Scientists concluded that the proposed method would enable surgeons without special expertise to optimize an intraocular lens constant to nullify the mean prediction error on a documented dataset without coding the different formulas. They added that the influence of indi-

(Continued from p. 15)

## Steering Clear of Kickbacks

patients). Remuneration includes anything of value ... in the Federal health care programs, paying for referrals is a crime. The statute covers the payers of kickbacks—those who offer or pay remuneration—as well as the recipients of kickbacks.<sup>3</sup>

“When making referrals to, or receiving referrals from, a provider outside your group, avoid any situation where one party is receiving compensation for more than the value of care that was provided to the patient.”

The penalties under the Anti-Kickback Statute can be severe. The Centers for Medicare and Medicaid Services notes that violators can face penalties of up to \$50,000 per instance plus three times the amount of the remuneration.

When making referrals to, or receiving referrals from, a provider outside your group, avoid any situation where one party is receiving compensation for more than the value of the care that was provided to the patient.

In conclusion, while the Stark Law and AKS are not new, practice administrators and physicians may not fully understand how they apply. It's crucial to take steps to protect the practice. If you're concerned in any way about a specific referral, legal or financial arrangements that might violate either of these important regulations, get advice from an attorney who is well-versed in this area. It could be money well spent. ◀

1. OIG. Compliance. Physician Education. A Roadmap for New Physicians. Fraud & Abuse Laws. <https://oig.hhs.gov/compliance/physician-education/01laws.asp>.  
2. Fraud and Abuse. Physician Self Referral. <https://www.cms.gov/Medicare/Fraud-and-Abuse/PhysicianSelfReferral/index.html?redirect=physicianselfreferral/>.  
3. OIG. Comparison of the Antikickback Statute and Stark Law. <https://oig.hhs.gov/compliance/provider-compliance-training/files/StarkandAKSChartHandout508.pdf>.

vidual eyes was proportional to the squared power of the implanted intraocular lens.

*Am J Ophthalmol* 2023; May 5. [Epub ahead of print].

Gatinel D, Debellemanière G, Saad A, et al.

## Diabetes and Fuchs' Endothelial Corneal Dystrophy

New data showed that female sex, European ancestry and multimorbidity are associated with an increased risk of Fuchs' endothelial corneal dystrophy. These findings, which were recently published in *Cornea*, also highlight a relationship between diabetes and Fuchs' dystrophy.

The researchers, who aimed to assess risk for demographic variables and other health conditions associated with FECD, developed a case-control algorithm based on structured electronic health record data. Accuracy of the algorithm

was confirmed by reviewing charts at three Veterans Affairs Medical Centers.

In this analysis, the algorithm was applied to the Department of Veterans Affairs Million Veteran Program cohort. Sex, genetic ancestry, comorbidities, diagnostic phecodes and laboratory values were extracted for these individuals. In their report, the investigators determined the association of these risk factors with a Fuchs' endothelial dystrophy diagnosis via single-variable and multiple-variable logistic regression models.

Data showed that female sex, European genetic ancestry and a greater number of comorbidities is associated with an increased risk of Fuchs' dystrophy. Of 1,417 diagnostic phecodes evaluated, the study authors reported that 15 percent (n=213) had a significant association with Fuchs'. This encompassed

ocular and nonocular conditions, including diabetes.

Five of 69 laboratory values (7.2 percent) were associated with Fuchs. The connection between diabetes and an increased FECD risk was supported by endocrine/metabolic clinic encounter codes and altered patterns of laboratory values.

"In the future, it will be important to better understand the relationship between Fuchs' dystrophy and diabetes mellitus. Insights regarding this relationship may identify opportunities for slowing Fuchs' progression," the study authors noted in their paper. "We anticipate that our case-control algorithm will open the door for further Fuchs' endothelial corneal dystrophy gene discovery." ◀

*Cornea*. May 12, 2023.

[Epub ahead of print].

Nealon CL, Halladay CW, Gorman BR, et al.

## ADVERTISER INDEX

This advertiser index is published as a convenience and not as part of the advertising contract. Every care will be taken to index correctly. No allowance will be made for errors due to spelling, incorrect page number, or failure to insert.

Alcon Surgical	31, 3
<a href="http://www.alconordicsurgicalproducts.com">www.alconordicsurgicalproducts.com</a>	
Allergan	8
<a href="http://hcp.xengelstent.com/cases">hcp.xengelstent.com/cases</a>	
Apellis	16-18
<a href="http://www.apellis.com">www.apellis.com</a>	
Bruder Healthcare Company	47
(888) 827-8337	
<a href="mailto:eyes@bruder.com">eyes@bruder.com</a>	
<a href="http://www.bruder.com">www.bruder.com</a>	
Glaukos	13
(800) 452-8567	
<a href="http://www.glaukos.com">www.glaukos.com</a>	
Horizon	37
<a href="http://www.TEDImpact.com">www.TEDImpact.com</a>	
Icare USA	Cover Tip
(888) 422-7313	
<a href="mailto:infoUSA@icare-world.com">infoUSA@icare-world.com</a>	
<a href="http://www.icare-world.com/USA">www.icare-world.com/USA</a>	

Imprimis Pharmaceuticals, Inc.	7
(858) 704-4040	
<a href="http://www.imprimispharma.com">www.imprimispharma.com</a>	
Novartis Pharmaceuticals	Cover 2
<a href="http://www.novartis.com">www.novartis.com</a>	
Ocular Therapeutix	41, 42
<a href="http://www.ocutx.com">www.ocutx.com</a>	
Oculus, Inc.	21
(888) 519-5375	
<a href="mailto:ads@oculususa.com">ads@oculususa.com</a>	
<a href="http://www.pentacam.com">www.pentacam.com</a>	
Olleyes	25
info@olleyes.com	
<a href="http://www.olleyes.com">www.olleyes.com</a>	
Reichert Technologies	54
(888) 849-8955	
<a href="http://www.reichert.com">www.reichert.com</a>	
Tarsus	11
<a href="http://www.tarsusrx.com">www.tarsusrx.com</a>	
Thea Pharma	Cover 3
<a href="http://www.acellfx.com">www.acellfx.com</a>	
Thea Pharma	Cover 4
<a href="http://www.ivizia.com/ecp">www.ivizia.com/ecp</a>	
Vital Tears	23
<a href="http://www.vitaltears.org">www.vitaltears.org</a>	



EDITED BY BONNIE SKLAR, MD



WILLS EYE RESIDENT CASE REPORT

# *A patient presents with a year-long history of decreased vision, eye pain and photophobia.*

LEO M. HALL, MD, MS, AND JAMES P. DUNN, MD  
PHILADELPHIA

## Presentation

A 47-year-old white female reported a one-year history of decreased vision, pain, and photophobia in the left eye. The right eye was asymptomatic. She was evaluated at an outside hospital and diagnosed with presumed non-necrotizing anterior scleritis and anterior uveitis of the left eye. She was referred to the Wills Eye Hospital Uveitis Clinic for further management.

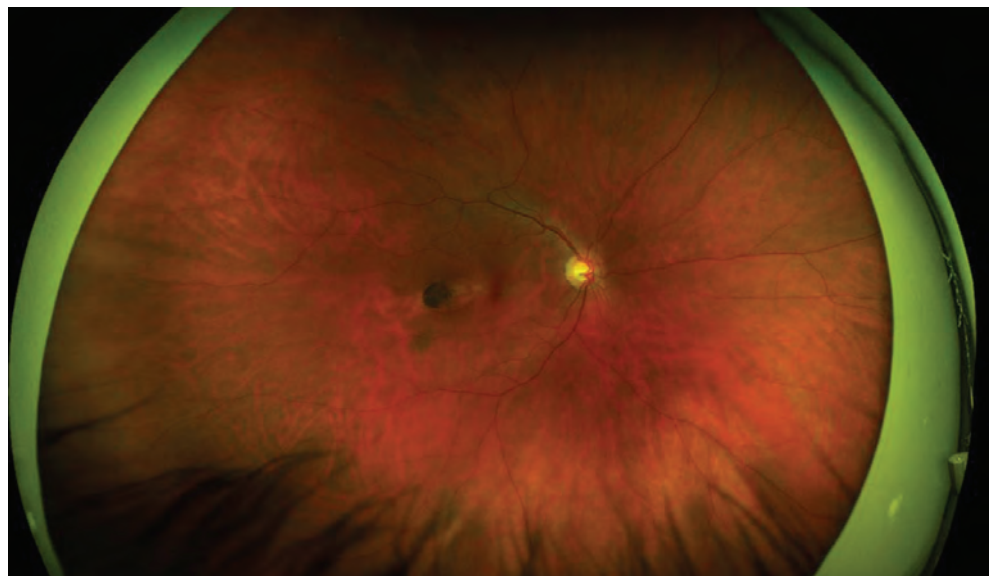
## History

Past medical history was notable for iron deficiency anemia and hypothyroidism. She denied history of autoimmune conditions, although prior work-up did demonstrate an elevated p-ANCA. Her surgical history was notable for tonsillectomy in 1996 and Cesarean section in 2003. She had never smoked, nor did she drink alcohol. She had received two Moderna COVID vaccinations. She was taking prednisone 40 mg daily by mouth and methotrexate 15 mg weekly by mouth, supplemented with folic acid 1 mg daily by mouth.

## Examination

Upon presentation to the WEH Uveitis Service, visual acuity was 20/20 in the right eye, and hand motion in the left eye. The right pupil was round, brisk and reactive, and the left pupil was irregular and non-reactive. Extraocular motility was full in both eyes. Confrontational visual fields were full OD and restricted OS with superior and infero-temporal loss. Intraocular pressure was 14 mmHg and 8 mmHg OD and OS, respectively.

Anterior examination of the right eye was normal. The left eye was found to have scleral thickening with superonasal



**Figure 1.** Optos imaging of the right fundus showed an ovoid lesion oriented obliquely towards the foveola. This lesion was located temporally in the macula.

tenderness and conjunctival hyperemia. There was diffuse corneal stromal thickening and haze temporally, with deep stromal haze and vascularization from 9 o'clock to 1 o'clock. The anterior chamber was deep with no cell or flare. There were 360 degrees of posterior synechiae, and a white cataract was present.

Dilated examination OD showed clear media, sharp disc margins with a cup-to-disc ratio of 0.6, and an oval, well-demarcated atrophic chorioretinal scar in the temporal macula measuring about 1.5 x 0.5 disc diameters, oriented towards the fovea (*Figure 1*). Dilated examination OS was limited by the white cataract.

**What's your diagnosis? What further work-up would you pursue? The diagnosis appears below.**

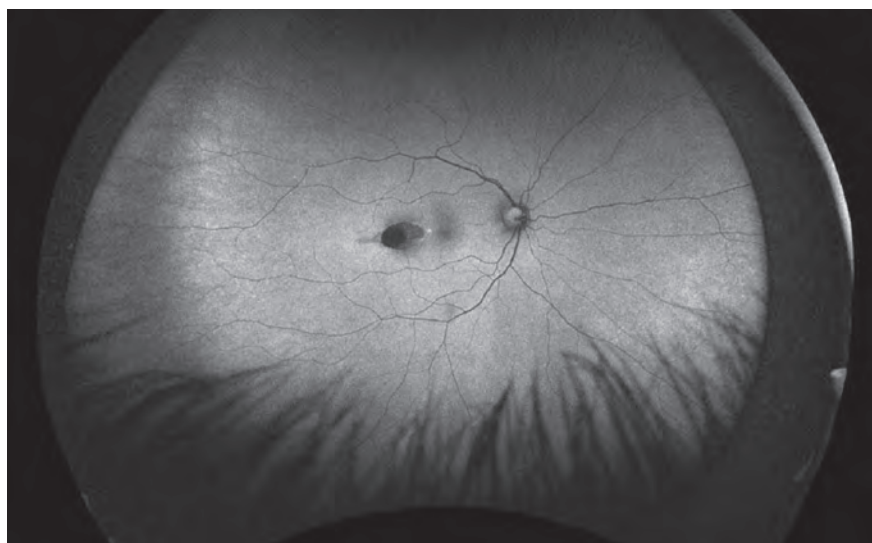### Work-up, Diagnosis and Treatment

The patient was clinically diagnosed with scleritis with corneal involvement of the left eye. B-scan ultrasonography revealed possible choroidal thickening. The patient was continued on prednisone and methotrexate, in anticipation of transition to infliximab.

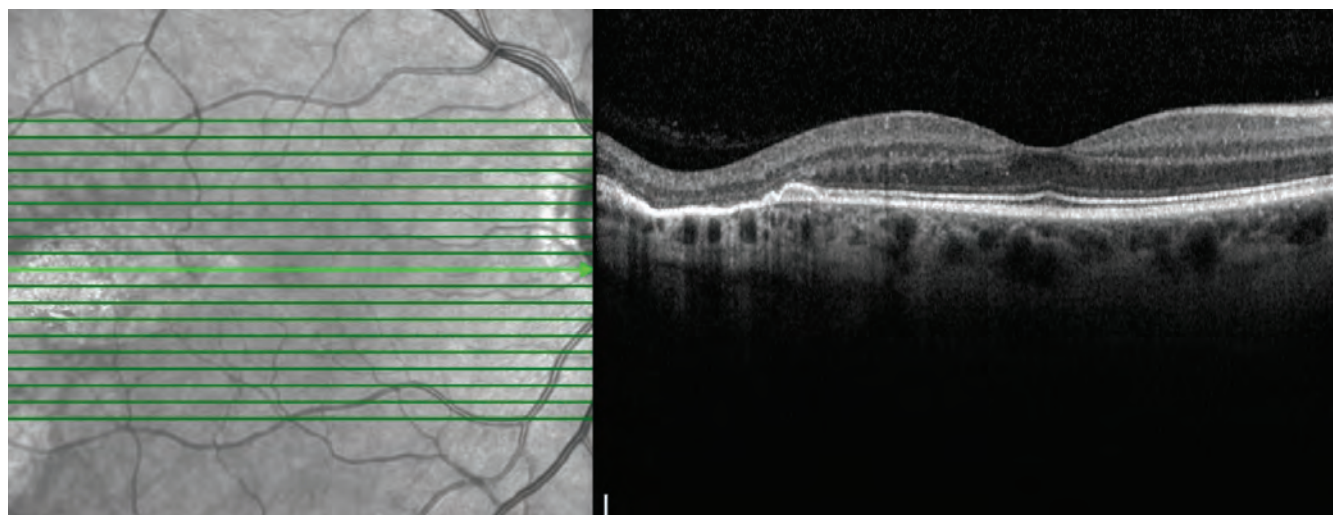
Additional retinal imaging was performed on the right eye. Fundus autofluorescence identified a hyper-autofluorescent, ovoid lesion temporal to the right fovea (*Figure 2*). OCT imaging through the temporal lesion revealed a well-demarcated region of chorioretinal atrophy in the temporal macula pointing toward the fovea with corresponding atrophy and disruption of the EZ/RPE complex; there was no subretinal fluid (*Figure 3*).

Based on these imaging findings, she was diagnosed with incidental torpedo maculopathy of the right eye. Because

the patient was asymptomatic, observation without treatment was deemed appropriate.



**Figure 2. Fundus autofluorescence of the right eye. There was a hyper-autofluorescent, ovoid lesion temporal to the right fovea.**



**Figure 3. Optical coherence tomography imaging of the right eye through the temporal lesion. There was an oval, well-demarcated chorioretinal atrophy with corresponding atrophy and disruption of the EZ/RPE complex; there was no subretinal fluid.**

## Discussion

Torpedo maculopathy—also referred to as solitary hypopigmented nevus of the retinal pigment epithelium, paramacular albinotic spot syndrome or paramacular coloboma<sup>1-4</sup> is a rare, non-vision threatening, RPE and choriocapillaris anomaly. First described in 1971 by Schlernitzauer and Green, and later characterized by Roseman and Gass in 1992, torpedo maculopathy received its apt name in recognition of its ovoid form, which is directed along the temporal raphe toward the foveola.<sup>4</sup> One published report within a pediatric population estimated the overall prevalence of torpedo maculopathy at 2 per 100,000, although this prevalence is likely an underestimation, because torpedo maculopathy is often asymptomatic and often presents itself as an incidental finding, as in our patient.<sup>5</sup>

The cause of torpedo maculopathy remains contested. It's been hypothesized that torpedo maculopathy arises from aberrant ganglion cell maturation along the horizontal raphe. Other researchers reported that it manifests from persistent defects in the RPE development at the temporal fetal bulge.<sup>2,6</sup> It's also been proposed that the torpedo lesion may arise during the embryologic scleral modification that occurs to accommodate the insertion of the long temporal posterior ciliary artery and nerve, both of which course temporally and anteriorly through the suprachoroidal space and the choroid.<sup>7</sup>

When found on ophthalmic examination, torpedo maculopathy appears as a unilateral, hypopigmented, torpedo-like lesion located in the temporal retina. In the majority of 10 cases collated by Carol Shields, MD, and her co-authors, the torpedo-like lesion assumed a sharp nasal tip directed within 1 mm proximate to the foveola; the temporal edge sometimes assumed either a rounded or a frayed tail appearance.<sup>6</sup> Fluorescein angiography characterization of torpedo lesions indicates a window defect attributable to RPE atrophy.<sup>8</sup> OCT-angiography has also been described as a means of detailing RPE atrophy, and has the added benefit of being able to map the underlying choriocapillaris and outer choroidal vasculature.<sup>9</sup>

Some authors have alleged that different subtypes of torpedo maculopathy exist. One report defined two types of torpedo maculopathy, as detailed by OCT imaging.<sup>8</sup> Type 1 torpedo maculopathy is characterized by outer retinal (as defined by interdigitation and ellipsoid zones) attenuation without retinal excavation, whereas Type 2 torpedo maculopathy incorporates outer retinal attenuation and retinal excavation; in both types, the inner retina is intact.

In contrast, Type 3 torpedo maculopathy comprises excavated inner layers, retinal thinning and inner retinal hyper-reflective spaces, with no subretinal cleft.<sup>10</sup>

Although many cases of torpedo maculopathy are asymptomatic, there are reported cases of clinical significance. Multiple reports have demonstrated that patients with torpedo maculopathy may present with scotomas.<sup>7,11</sup> One report hypothesized that these scotomas arise from RPE dysfunction, which in turn leads to improper photoreceptor function.<sup>7</sup> Of those cases presenting with scotomas, one of two cases additionally presented with shallow neurosensory serous retinal detachments.<sup>11</sup> Additionally, another group reported associated choroidal neovascularization.<sup>12</sup>

The management of torpedo maculopathy is often limited to observation. For larger lesions, specifically those with “fish-tails,” as described in one study, serial fundus photography and macular threshold perimetry have been suggested.<sup>13</sup> In the rare case of associated choroid neovascularization, anti-VEGF treatment was successful.<sup>12</sup>

Torpedo maculopathy is an eponymous retinal and RPE finding sometimes found on dilated fundus examination. Our case highlights its benign and incidental nature; nonetheless, given reports detailing photoreceptor and RPE atrophy, and in seldom cases, choroidal neovascularization, close observation with fundus photography and macular threshold perimetry may be recommended. ◀

1. Roseman RL, Gass JDM. Solitary hypopigmented nevus of the retinal pigment epithelium in the macula. *Archives of Ophthalmology* 1992;110:10:1358-1359.

2. Pian D, Ferrucci S, Anderson SF, Wu C. Paramacular coloboma. *Optom Vis Sci* 2003;80:8:556-563.

3. Schlernitzauer DA, Green WR. Peripheral retinal albinotic spots. *Am J Ophthalmol* 1971;72:4:729-732.

4. Daily M. Torpedo maculopathy or paramacular spot syndrome. Paper presented at: New Dimensions in Retina Symposium 1993.

5. Shirley K, O'Neill M, Gamble R, Ramsey A, McLoone E. Torpedo maculopathy: Disease spectrum and associated choroidal neovascularisation in a paediatric population. *Eye* 2018;32:8:1315-1320.

6. Shields CL, Guzman JM, Shapiro MJ, Fogel LE, Shields JA. Torpedo maculopathy at the site of the fetal “bulge”. *Archives of Ophthalmology* 2010;128:4:499-501.

7. Golchet PR, Jampol LM, Mathura JR, Daily MJ. Torpedo maculopathy. *British Journal of Ophthalmology* 2010;94:3:302-306.

8. Wong EN, Fraser-Bell S, Hunyor AP, Chen FK. Novel optical coherence tomography classification of torpedo maculopathy. *Clinical & Experimental Ophthalmology* 2015;43:4:342-348.

9. Ali Z, Shields CL, Jasani K, Aslam TM, Balaskas K. Swept-source optical coherence tomography angiography findings in torpedo maculopathy. *Ophthalmic Surg Lasers Imaging Retina* 2017;48:11:932-935.

10. Tripathy K, Sarma B, Mazumdar S. Commentary: Inner retinal excavation in torpedo maculopathy and proposed type 3 lesions in optical coherence tomography. *Indian J Ophthalmol* 2018;66:8:1213-1214.

11. Sanabria MR, Coco RM, Sanchidrian M. OCT findings in torpedo maculopathy. *Retin Cases Brief Rep* 2008;2:2:109-111.

12. Jurjevic D, Böni C, Barthelmes D, et al. Torpedo maculopathy associated with choroidal neovascularization. *Klinische Monatsblätter für Augenheilkunde* 2017;234:4:508-514.

13. Su Y, Gurwood AS. Neurosensory retinal detachment secondary to torpedo maculopathy. *Optometry* 2010;81:8:405-407.



START WITH OCULAR SURFACE PROTECTION  
**ON THE PATH TO  
RESTORATION**




**ACELLFX**   
Acellular Amniotic Membrane

Amniotic membrane image not to scale, enhanced to show detail.

AcellFX is a human amniotic membrane that provides a protective environment for repair of the cornea and conjunctiva,\* allowing re-cellularization to occur and the ocular surface to return to a healthier state<sup>1-3</sup>

Find out more about the amniotic membrane made specifically for eye care professionals at **AcellFX.com**

**CPT CODE 65778:**  
**Placement of amniotic membrane on the ocular surface without sutures**



**References:** 1. Walkden A. Amniotic membrane transplantation in ophthalmology: an updated perspective. *Clin Ophthalmol.* 2020;14:2057-2072. 2. Craig JP, Nichols KK, Akpek EK, et al. TFOS DEWS II definition and classification report. *Ocul Surf.* 2017;15(3):276-283. 3. Jones L, Downie LE, Korb D, et al. TFOS DEWS II management and therapy report. *Ocul Surf.* 2017;15(3):575-628.

\*There are no specific FDA indications for the product.

This information does not guarantee payment and is not legal advice.

It is the provider's responsibility to check for proper coding and billing.

Before use, please refer to Information for Use (IFU) package insert.

From the makers of the #1-prescribed dry eye brand in Europe\*

## Covering the spectrum of

# Dry Eye Relief

Over-the-counter iVIZIA® lubricant eye drops deliver a unique combination of immediate and long-lasting relief and ocular surface protection in a preservative-free formulation.

- Advanced formulation offers a combination of povidone (active), hyaluronic acid (HA), and trehalose
- HA and trehalose increased tear film thickness for up to 240 minutes
- Proprietary, multi-dose bottle

### Chronic Dry Eye Patient Usage Study†:

Up to  
**8 hours**  
of relief

as well as improved comfort during computer work, reading, and driving<sup>1</sup>

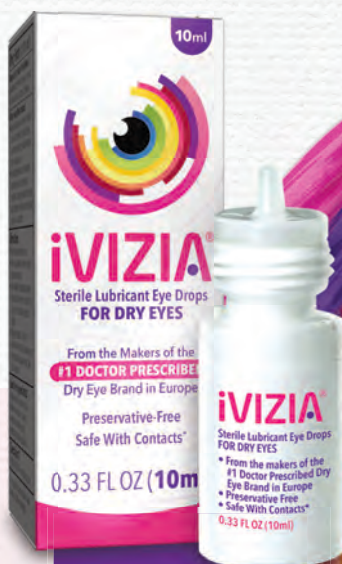**84%**

of users reported iVIZIA worked better than their previous eye drops<sup>1</sup>



Scan here.

Recommend iVIZIA and request samples by visiting [iVIZIA.com/ECP](https://www.ivizia.com/ECP).



Safe for use with contact lenses‡

\*Prescription market data, Dec. 2022 – S01K without cyclosporine.

†In a chronic dry eye patient usage study, participants from a variety of socioeconomic backgrounds answered questions about iVIZIA. There were 203 chronic dry eye patients, ranging from ages 28-80, who used their current eye drops before switching to iVIZIA for 30 days.<sup>1</sup>

‡To limit blurriness when using contact lenses, remove contacts, apply drops, then insert contacts.

Reference: 1. Data on file.

Copyright ©2023 Thea Pharma Inc. | Similasan | All Rights Reserved. | PRC-IED-1030-v2 04.2023



Made by

Distributed by

