

Wills Eye Resident Series: A 20-year-old with bilateral amblyopia and renal failure, p. 71

REVIEW[®] *of* OPHTHALMOLOGY

August 2022 • reviewofophthalmology.com

Clinical advice you can trust

REFRACTIVE/CATARACT RUNDOWN

A Primer on LASIK Monovision

PAGE 18

TECHNOLOGY UPDATE

New Ways to Address Amblyopia

PAGE 24

GLAUCOMA MANAGEMENT

Gene Therapy and Glaucoma

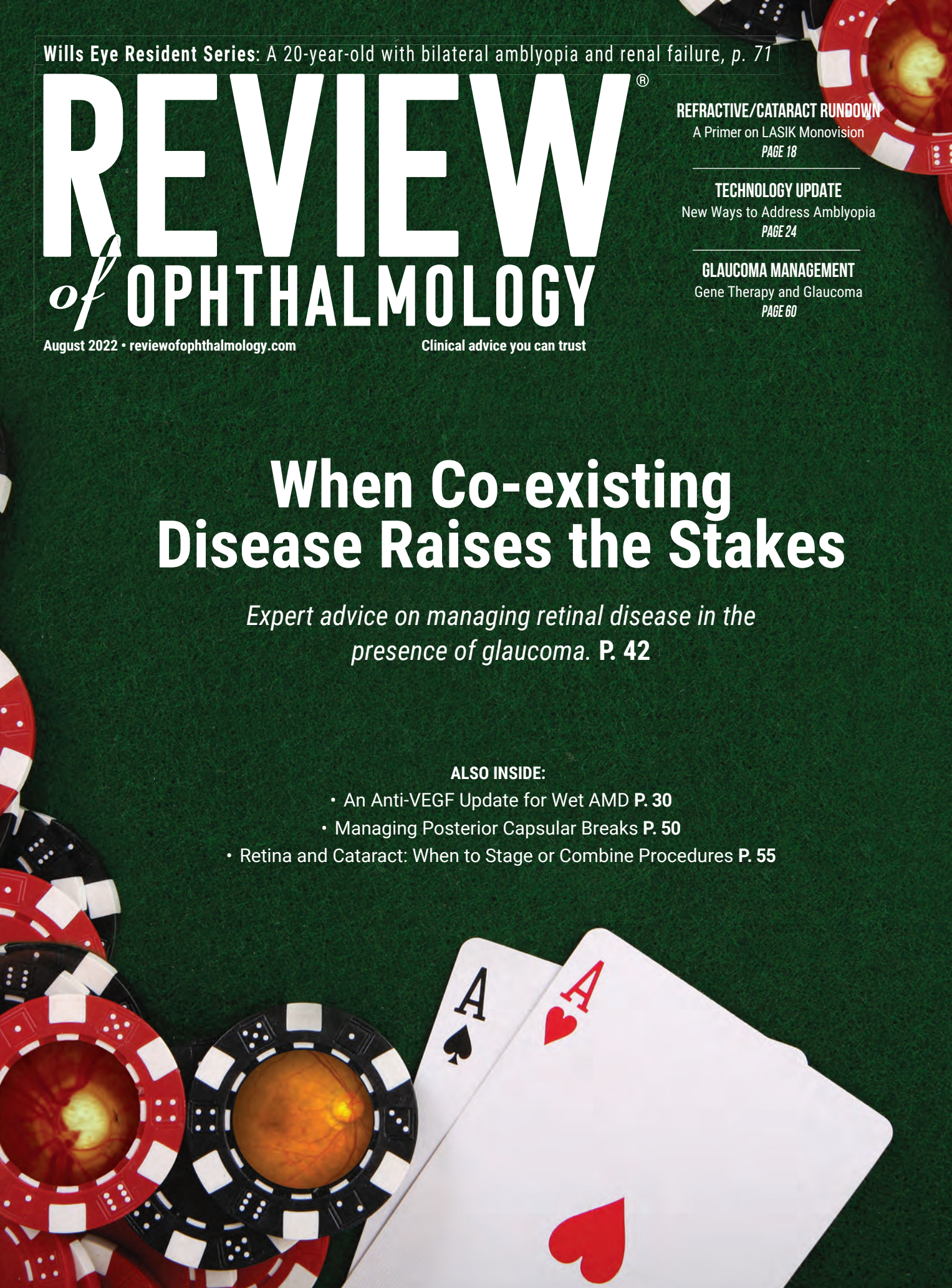PAGE 60

When Co-existing Disease Raises the Stakes

*Expert advice on managing retinal disease in the
presence of glaucoma. P. 42*

ALSO INSIDE:

- An Anti-VEGF Update for Wet AMD P. 30
- Managing Posterior Capsular Breaks P. 50
- Retina and Cataract: When to Stage or Combine Procedures P. 55

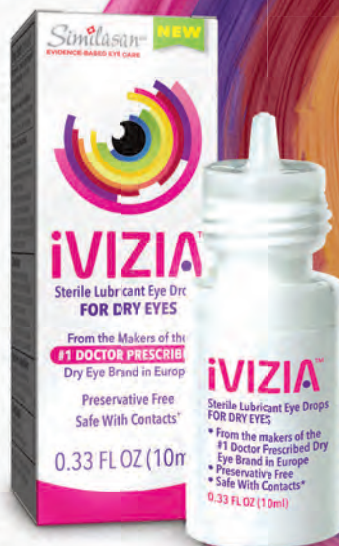

New from the makers of the #1-prescribed dry eye brand in Europe*

Covering the spectrum of Dry Eye Relief

Introducing preservative-free iVIZIA™ lubricant eye drops for the comprehensive combination of lasting relief and ocular surface protection.¹⁻⁶

- Trehalose provides bioprotection, osmoprotection, and rehydration¹⁻⁴
- Hyaluronic acid (HA) and povidone deliver lubrication with long-lasting relief⁵⁻⁶
- Increased tear film thickness for up to 240 minutes⁷
- Preservative free
- Proprietary multi-dose bottle design for calibrated dosing and contamination protection
- Suitable for all dry eye sufferers, including contact lens wearers†



Help patients see dry eye relief differently. Recommend iVIZIA OTC.

Request samples and learn more by scanning the QR code or visiting iVIZIA.com/ECP.



*Prescription market data, Sept. 2021 – S01K without cyclosporine.

†To limit blurriness when using contact lenses, remove contacts, apply drops, then insert contacts.

References: **1.** Chen W, Zhang X, Liu M, et al. Trehalose protects against ocular surface disorders in experimental murine dry eye through suppression of apoptosis. *Exp Eye Res.* 2009;89(3):311-318. **2.** Aragona P, Colosi P, Rania L, et al. Protective effects of trehalose on the corneal epithelial cells. *ScientificWorldJournal.* 2014;2014:717835. **3.** Chiambaretta F, Doan S, Labetoulle M, et al. A randomized, controlled study of the efficacy and safety of a new eyedrop formulation for moderate to severe dry eye syndrome. *Eur J Ophthalmol.* 2017;27(1):1-9. **4.** Liu Z, Chen D, Chen X, et al. Trehalose induces autophagy against inflammation by activating TFEB signaling pathway in human corneal epithelial cells exposed to hyperosmotic stress. *Invest Ophthalmol Vis Sci.* 2020;61(10):26. **5.** US FDA Department of Health and Human Services. Ophthalmic drug products for over-the-counter human use. Updated October 21, 2021. Accessed January 19, 2022. <https://www.accessdata.fda.gov/scripts/cdrh/cfdocs/cfcfr/CFRSearch.cfm?CFRPart=349>. **6.** Jones L, Downie LE, Korb D, et al. TFOS DEWS II management and therapy report. *Ocul Surf.* 2017;15(3):575-628. **7.** Schmidl D, Schmetterer L, Witkowska KJ, et al. Tear film thickness after treatment with artificial tears in patients with moderate dry eye disease. *Cornea.* 2015;34(4):421-426.

New from the makers of the #1-prescribed dry eye brand in Europe*

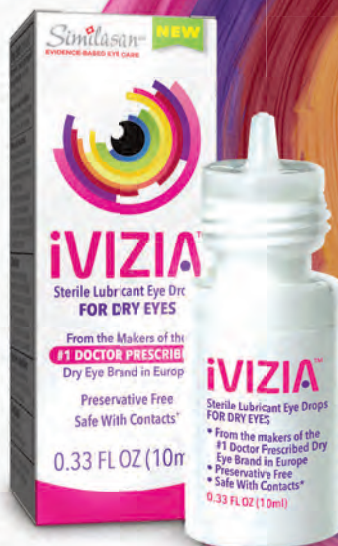Covering the spectrum of Dry Eye Relief

Introducing preservative-free iVIZIA™ lubricant eye drops for the comprehensive combination of lasting relief and ocular surface protection.¹⁻⁶

- Trehalose provides bioprotection, osmoprotection, and rehydration¹⁻⁴
- Hyaluronic acid (HA) and povidone deliver lubrication with long-lasting relief⁵⁻⁶
- Increased tear film thickness for up to 240 minutes⁷
- Preservative free
- Proprietary multi-dose bottle design for calibrated dosing and contamination protection
- Suitable for all dry eye sufferers, including contact lens wearers†

Help patients see dry eye relief differently. Recommend iVIZIA OTC.

Request samples and learn more by scanning the QR code or visiting [iVIZIA.com/ECP](https://www.iVIZIA.com/ECP).



*Prescription market data, Sept. 2021 – S01K without cyclosporine.

†To limit blurriness when using contact lenses, remove contacts, apply drops, then insert contacts.

References: **1.** Chen W, Zhang X, Liu M, et al. Trehalose protects against ocular surface disorders in experimental murine dry eye through suppression of apoptosis. *Exp Eye Res.* 2009;89(3):311-318. **2.** Aragona P, Colosi P, Rania L, et al. Protective effects of trehalose on the corneal epithelial cells. *ScientificWorldJournal.* 2014;2014:717835. **3.** Chiambaretta F, Doan S, Labetoulle M, et al. A randomized, controlled study of the efficacy and safety of a new eyedrop formulation for moderate to severe dry eye syndrome. *Eur J Ophthalmol.* 2017;27(1):1-9. **4.** Liu Z, Chen D, Chen X, et al. Trehalose induces autophagy against inflammation by activating TFEB signaling pathway in human corneal epithelial cells exposed to hyperosmotic stress. *Invest Ophthalmol Vis Sci.* 2020;61(10):26. **5.** US FDA Department of Health and Human Services. Ophthalmic drug products for over-the-counter human use. Updated October 21, 2021. Accessed January 19, 2022. <https://www.accessdata.fda.gov/scripts/cdrh/cfdocs/cfcfr/CFRSearch.cfm?CFRPart=349>. **6.** Jones L, Downie LE, Korb D, et al. TFOS DEWS II management and therapy report. *Ocul Surf.* 2017;15(3):575-628. **7.** Schmidl D, Schmetterer L, Witkowska KJ, et al. Tear film thickness after treatment with artificial tears in patients with moderate dry eye disease. *Cornea.* 2015;34(4):421-426.

Aetna Backs Down on Pre-certification for Cataract

After surgeons and their professional organizations mobilized and barraged Aetna with a laundry list of horror stories and complaints stemming from the insurer's attempt to require pre-certification for cataract surgery, Aetna eventually rescinded this unpopular new policy.

"There's a tremendous feeling of relief," says Parag Parekh, MD, an ophthalmologist in State College, Pennsylvania, and chair of the American Society of Cataract and Refractive Surgery Governmental Relations Committee. "There was concern that prior authorization policies for ophthalmic procedures would spread to other insurers. That would mean more bureaucracy that wouldn't improve patient care. The task of caring for patients and restoring their sight becomes more difficult when excessive paperwork is required."

Dr. Parekh says pre-authorization requirements are always problematic for patients and practices. "It's one thing when you meet the patient in the office for a consult, and then the surgery is several weeks later. You have time to get this [paperwork] done in this insistence. However, there are procedures done on the same day, so requiring prior authorization on a laser procedure like YAG would turn one visit into two. This becomes a significant inconvenience for the patient, who is typically older, can't see well, and needs a relative to drive them to their appointment.

There may also be additional charges for the patient (and insurer) since there will now be two visits instead of one.

Aetna's policy regarding cataract prior authorization went into effect July 1 of last year and immediately began to cause problems. "This played out in so many frustrating ways," says Dr. Parekh. "First, before the July 1 start date for Aetna's prior authorization requirement on all cataract surgeries, providers could not receive approval because Aetna's electronic prior authorization system, which providers were encouraged to use, was not yet working. In fact, the portal informed providers prior authorization is not required for cataract surgery. As a result, many practices had to reschedule July patients for their surgery because they could not obtain timely approval. ASCRS and the American Academy of Ophthalmology estimated that about 20,000 surgeries had to be rescheduled. Second, the insurer required you to put paperwork above patients by mandating prior authorization on all cataract procedures. There was already a backlog of patients due to COVID-19, as well as a cohort of baby boomer patients who needed care, so this policy did nothing but exacerbate the current backlog.

Even when a surgeon followed all the proper steps, just the fact that there were extra hoops to jump through could be a problem in and of itself. "We'd file the paperwork and

pick a date for the surgery on consultation with the patient," recalls Dr. Parekh, "and the patient's family member would take off work that day in order to drive the patient to and from the surgery. However, if we didn't hear back from Aetna, we'd have to cancel the surgery. Now the family member who had arranged for a day off from work would have to go back and ask to take one off at a later date."

Dr. Parekh says that, theoretically, prior authorization might make sense in some instances, such as when the physician is deciding whether a patient needs an expensive test or not. "Cataract surgery is black-and-white," he says. "It is a natural part of aging, and most Americans 65 years or above will undergo the sight-restoring surgery at some point in their lives. Countless studies demonstrate the positive impact cataract surgery will have on a patient's quality of life. If the insurer denies the surgery, a patient's vision will get worse—maybe they fall and break a hip or have a car crash. Cataract surgery is proven to bring so much value to our patient's lives and this why it's so important they have timely access to care."

"In the end," Dr. Parekh continues, "Aetna approved every prior-authorization request we filed for cataract surgery. So, it's not as if they can say their policy avoided

(Continued on p. 9)

ENOUGH IS ENOUGH

There's a better way.

Providing the best care and achieving professional fulfillment—that's what matters. *We know these days it's hard.* Between rising costs, declining reimbursements, staffing challenges, regulations, and billing complexity—seems like there's just not enough time. But the right technology can help. Imagine a single EHR and PM platform with mobile transcription, easier ophthalmic-specific workflows, and efficient billing. Plus, a better way to engage patients. All from a partner who'll be there for the long-haul.

Make it better:
nextgen.com/better-OP

BELIEVE IN BETTER.®

© 2022 NXGN Management, LLC. All Rights Reserved. NextGen is a registered trademark of NXGN Management, LLC. All other names and marks are the property of their respective owners.



Market Segmentation 101

MATTHEW CHAPIN

Andover, Mass.

Naturally, one of the key questions from a potential investor evaluating a business plan is, "What's the potential market for the new proposed product?" This drives future sales projections, potential return on investment and how to define the target product profile. It may be easy to ride the excitement of a new product, maybe even a disruptive technology, and be tempted to default to broad sweeping statements to represent the potential market of a new product, such as "The new AMD agent will target the \$10 billion market in the key territories," or "This surgical product will be used in each of the 4 million cataract surgeries performed per year in the U.S.," or that "This new myopia product will have a market representing approximately 30 percent of the global population." In evaluating and supporting business pitches from new physician entrepreneurs, I've seen a wide range in how the potential market is initially described. This installment of the column will take a brief look at market segmentation, and some specific approaches to how to drill down to find a proper market model.

In Clayton Christensen's book "The Innovator's Dilemma," he discusses business approaches for sustaining technologies into markets with existing products compared with going into markets with disruptive technologies. Thus in some cases truly disruptive technologies may have a market size that is difficult to precisely predict. However even then, one can at least characterize current customer needs and behaviors to contextualize the market.

For the sake of this discussion, here we'll break down the design of the market summary into a model with four main buckets: 1) Defining the total market. 2) Segmenting the population(s) within the disease/condition. 3) Comparison of our product to existing products. 4) What factors will drive adoption. Drilling down into these four layers should help calculate a credible estimate for the usage level of our new product.

• **Defining the Total Market.** Here, you should start, of course, with the total prevalence and incidence of the disease or condition your product aims to treat. But ask yourself: Are you capturing it completely? Is

the high-level estimate based on the number of formal diagnoses, scripts written or reported signs/symptoms from patients, and is this fully recognizing the potential market?

Examples of situations where the total market may go beyond initial estimates based on the number of diagnoses include cases such as: a novel product, diagnostic test or treatment for earlier stages of diabetic retinopathy that would target patients seen by non-eye-care physicians; a disease like dry eye in which formal diagnoses only estimate a minor portion of the total number of patients that actually suffer from the condition; a product that addresses progression from earlier stages of AMD, prior to evidence of significant changes in standard vision tests, that is evaluated in a trial with a novel, more sensitive visual function endpoint; and allergic conjunctivitis, in which most patients with



nasal allergy don't even associate themselves with a condition they'd label an eye allergy, yet they still report ocular symptoms.

• **Segment the Population.** The total market can then be broken down into sub-categories. This can be done by such determinants as stage of disease (early, moderate, late/progressed), etiology, patient-reported outcomes, etc. Also, determine at which point in the disease progression you intend to capture the patient. For example, is the product intended for preventing or delaying a surgical procedure, to capture surgical cases to improve outcomes, or for a specific subgroup of patients post-surgery (such as a high-risk population for a recurring condition requiring another surgery or procedure).

In a field like dry eye or a condition with a cosmetic aspect such as redness, you may need to further examine the number of patients that not only are identified by a doctor, but those that self-treat with OTC products,

and those that would purchase a new product if available, but aren't satisfied or even using existing options. In such patients, the sales of current standard of care isn't going to fully represent the market potential, and you need to characterize what segment your product is targeting.

Another prime example is a product that addresses dry AMD prior to the development of geographic atrophy. In this case is the focus patients who have intermediate disease and are at risk of progressing to GA, or those at earlier stages of disease? And, if it's aimed at earlier stages in which visual acuity isn't significantly reduced, what type of treatment burden in terms of route of administration and frequency will a patient accept, and how does that inform the size of the target patient population?

• **Comparison to Existing Products.** Is the product intended to replace the current standard of care as a new primary therapy, to be used as adjunctive therapy to improve outcomes, or is it to be a secondary therapy for failures or suboptimal responders? Where does the new product realistically fit in the current treatment continuum? A perfect example is a new retinal product: Where does it fit in the wet AMD/DME market among existing VEGFs, the now-approved bispecific faricimab, new products with novel mechanisms, and existing and forthcoming sustained-release options? A specific niche can still represent a significant market size, and defining this niche early will drive your clinical trial designs.

Also, you need to consider existing generics in your product's therapeutic area. Is the effect of the new product enough to drive use (but also insurance reimbursement coverage from payers) away from existing inexpensive generic products (e.g., a new IOP agent released amid the availability of generic once-daily prostaglandins)? You'll need to focus the target market estimate of the specific population of patients on whom a physician will choose to use the new product over the existing standard of care.

• **What Will Drive Adoption?** With a surgical product, for example, some considerations include: What will it take for a doctor to adjust the current standard surgical procedure for a new product, or incorporate a new product

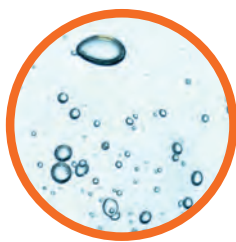
(Continued on p. 9)

NEW

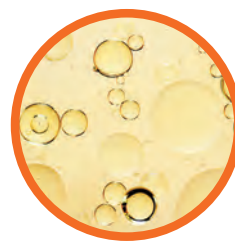


HELP YOUR PATIENTS GO FROM
DRY EYES
TO EXTRA LONG-LASTING
HYDRATION¹⁻⁸

Introducing blink[®] triple care — the first and only over-the-counter eye drop with both hyaluronate and a nano-emulsion lipid within the unique formula.⁹⁻¹⁰ Here's how our **DUAL ACTION MOISTURE SEAL TECHNOLOGY**⁵⁻⁸ works:



HYALURONIC ACID
binds moisture and helps
boost hydration³⁻⁵



LIPID NANO EMULSION
helps protect against tear
evaporation¹¹ to lock in moisture⁵⁻⁸

The result is **3-in-1 Extended Relief**¹⁻⁸ for both Aqueous-Deficient and Evaporative Dry Eyes¹²:



Instantly Soothes¹⁻⁸



Extra Long-Lasting Hydration¹⁻⁸



Locks in Moisture⁵⁻⁸

References: 1. Wasmanski AD and Kislán T. Cross-Over Evaluation of Polyethylene Glycol 400 (PEG-400) 0.4% and 0.25% Artificial Tears in Mild Dry Eye Patients. *Invest. Ophthalmol. Vis. Sci.* 2010;51(13):6263. 2. Montani G. Intrasubject Tear Osmolarity Changes with Two Different Types of Eye Drops. *Optom. Vis. Sci.* 2013;90(4): 372-377. doi: 10.1097/OPX.0b013e318288bdbe 3. Laurent TC. Structure of Hyaluronic Acid. In: EA Balazs (Ed.), *Chemistry and Molecular Biology of Intracellular Matrix*. Academic Press, London, 1970:703-732. 4. Aragona P, Papa V, Micali A, et al. Long Term Treatment with Sodium Hyaluronate-Containing Artificial Tears Reduces Ocular Surface Damage in Patients with Dry Eye. *Br. J. Ophthalmol.* 2002;86(2):181-184. doi: 10.1136/bjo.86.2.181. 5. Prabhasawat P, Tesavibul N, Kasetzuwan K. Performance Profile of Sodium Hyaluronate in Patients with Lipid Tear Deficiency: Randomised, Double-Blind, Controlled, Exploratory Study. *Br. J. Ophthalmol.* 2007;91(1):47-50. doi: 10.1136/bjo.2006.097691. 6. Zheng X, Goto T, Shiraishi A, et al. In vitro efficacy of ocular surface lubricants against dehydration. *Invest. Ophthalmol. Vis. Sci.* 2013;32(9):1260-1264. doi: 10.1097/j.ico.0b013e31829cfd44. 7. Maissa C, Guillon M, Simmons P, et al. Effect of castor oil emulsion eyedrops on tear film composition and stability. *Contact Lens Anterior Eye.* 2010;33(2):76-82. doi: 10.1016/j.clae.2009.10.005. 8. Craig JP, Nichols KK, Akpek EK, et al. TFOS DEWS II Definition and Classification Report. *The Ocular Surface.* 2017;15(3):276-283. 9. US Dry Eye OTC Product Comparison. 10. IRI US 2020 Dry Eye Share Competitive Report. 11. JJV Data on File 2020. Blink Triple Care Lubricating Eye Drops - Consolidated, Approved Claims List. 12. 2012. Lemp, Miachael A. Distribution of Aqueous-Deficient and Evaporative Dry Eye in a Clinic-Based Patient Cohort: A Retrospective Study

Important Safety Information: Blink[®]Tears, Blink GelTears[®] and Blink[®] Triple Care drops are for the temporary relief of burning, irritation and discomfort due to dryness of the eye or exposure to wind or sun, and may be used as a protectant against further irritation. Patients should stop use and contact their eye care practitioner if they experience eye pain, changes in vision, continued redness or irritation of the eye, or if the condition worsens or persists for more than 72 hours.

© Johnson & Johnson Surgical Vision, Inc. 2022. PP2022CN4045

CONTRIBUTORS

CHIEF MEDICAL EDITOR

Mark H. Blecher, MD

CONTACT LENSES

Penny Asbell, MD

CORNEA / ANTERIOR SEGMENT

Thomas John, MD

GLAUCOMA MANAGEMENT

Peter Netland, MD, PHD
Kuldev Singh, MD

MEDICARE Q & A

Paul M. Larson, MBA

PEDIATRIC PATIENT

Janine Collinge, MD

PLASTIC POINTERS

Editor Emeritus:

Anna P. Murchison, MD, MPH

REFRACTIVE SURGERY

Arturo S. Chayet, MD

RETINAL INSIDER

Carl Regillo, MD, FACS
Yoshihiro Yonekawa, MD

TECHNOLOGY UPDATE

Steven T. Charles, MD
Michael Colvard, MD

WILLS RESIDENT CASE SERIES

Rakhi Melvani, MD

ADVISORY BOARD

PENNY A. ASBELL, MD, MEMPHIS, TENN.

BRANDON AYRES, MD, PHILADELPHIA

SURENDRA BASTI, MD, CHICAGO

WILLIAM I. BOND, MD, PEKIN, ILL.

ALAN N. CARLSON, MD, DURHAM, N.C.

Y. RALPH CHU, MD, EDINA, MINN.

ADAM J. COHEN, MD, CHICAGO

JANINE COLLINGE, MD, FARMINGTON, CONN.

UDAY DEVGAN, MD, FACS, LOS ANGELES

ERIC DONNENFELD, MD, ROCKVILLE CENTRE, N.Y.

DANIEL S. DURRIE, MD, KANSAS CITY, MO.

ROBERT EPSTEIN, MD, MCHENRY, ILL.

ROBERT D. FECHTNER, MD, NEWARK, N.J.

WILLIAM J. FISHKIND, MD, TUCSON, ARIZ.

BRIAN FRANCIS, MD, Los Angeles

JAMES P. GILLS, MD, TARPON SPRINGS, FLA.

HARRY GRABOW, MD, SARASOTA, FLA.

DOUGLAS K. GRAYSON, MD, NEW YORK CITY

DAVID R. HARDTEN, MD, MINNEAPOLIS

SARA J. HAUG, MD, PHD, DURANGO, COLO.

KENNETH J. HOFFER, MD, SANTA MONICA, CALIF.

JACK T. HOLLADAY, MD, MSEE, HOUSTON

JOHN D. HUNKELER, MD, KANSAS CITY, MO.

THOMAS JOHN, MD, TINLEY PARK, ILL.

ROBERT M. KERSHNER, MD, MS, PALM BEACH GARDENS, FLA.

GUY M. KEZIRIAN, MD, PARADISE VALLEY, ARIZ.

SUMITRA KHANDELWAL, MD, HOUSTON

TERRY KIM, MD, DURHAM, N.C.

BRAD KLIGMAN, MD, MANHASSET, N.Y.

TOMMY KORN, MD, SAN DIEGO

DAVID A. LEE, MD, HOUSTON

FRANCIS S. MAH, MD, LA JOLLA, CALIF.

NICK MAMALIS, MD, SALT LAKE CITY

EDWARD MANCHE, MD, PALO ALTO, CALIF.

MIKE S. MCFARLAND, MD, PINE BLUFF, ARK.

JEFFREY B. MORRIS, MD, MPH, ENCINITAS, CALIF.

KEVIN MILLER, MD, LOS ANGELES

MAJID MOSHIRFAR, MD, DRAPER, UTAH

MARLENE R. MOSTER, MD, PHILADELPHIA

ROBERT J. NOECKER, MD, FAIRFIELD, CONN.

ROBERT OSHER, MD, CINCINNATI

MARK PACKER, MD, WEST PALM BEACH, FLA.

CHRISTOPHER J. RAPUANO, MD, PHILADELPHIA

AUGUST READER III, MD, SAN FRANCISCO

TONY REALINI, MD, MPH, MORGANTOWN, W.V.

KENNETH J. ROSENTHAL, MD, GREAT NECK, N.Y.

ERIC ROTHCHILD, MD, DELRAY BEACH, FLA.

SHERI ROWEN, MD, BALTIMORE

JAMES J. SALZ, MD, LOS ANGELES

INGRID U. SCOTT, MD, MPH, HERSHEY, PA.

JOEL SCHUMAN, MD, PITTSBURGH

GAURAV SHAH, MD, ST. LOUIS

DAVID R. STAGER JR., MD, DALLAS

KARL STONECIPHER, MD, GREENSBORO, N.C.

JAMES C. TSAI, MD, NEW YORK CITY

VANCE THOMPSON, MD, SIOUX FALLS, S.D.

FARRELL C. TYSON, MD, CAPE CORAL, FLA.

R. BRUCE WALLACE III, MD, ALEXANDRIA, LA.



BUSINESS OFFICES

19 CAMPUS BOULEVARD, SUITE 101
NEWTOWN SQUARE, PA 19073
SUBSCRIPTION INQUIRIES (877) 529-1746
(USA ONLY); OUTSIDE USA, CALL (847) 763-9630

BUSINESS STAFF

PUBLISHER

MICHAEL HOSTER

(610) 492-1028 MHOSTER@JOBSON.COM

SENIOR MANAGER, STRATEGIC ACCOUNTS

MICHELE BARRETT

(610) 492-1014 MBARRETT@JOBSON.COM

REGIONAL SALES MANAGER

JONATHAN DARDINE

(610) 492-1030 JDARDINE@JOBSON.COM

DIGITAL MARKETING MANAGER

MATT EGGER

(610) 492-1029 MEGGER@JOBSON.COM

CLASSIFIED ADVERTISING

(888) 498-1460

PRODUCTION MANAGER

FARRAH APONTE

212-274-7057 FAPONTE@JOBSON.COM

PRODUCTION MANAGER

KAREN LALLONE

(610) 492-1010 KLALLONE@JOBSON.COM

SUBSCRIPTIONS

\$63 A YEAR, \$99 (U.S.) IN CANADA,
\$158 (U.S.) IN ALL OTHER COUNTRIES.

SUBSCRIPTIONS E-MAIL:

REVOPHTHALMOLOGY@CAMBEYWEST.COM

CIRCULATION

PO BOX 71, CONGERS, NY 10920-0071

(877) 529-1746

OUTSIDE USA: (845) 267-3065

SENIOR CIRCULATION MANAGER

HAMILTON MAHER

(212) 219-7870 hmaher@jhihealth.com

CEO, INFORMATION GROUP SERVICES

MARC FERRARA

SENIOR VICE PRESIDENT, OPERATIONS

JEFF LEVITZ

VICE PRESIDENT, HUMAN RESOURCES

TAMMY GARCIA

VICE PRESIDENT, CREATIVE SERVICES & PRODUCTION

MONICA TETTAMANZI

CORPORATE PRODUCTION DIRECTOR

JOHN ANTHONY CAGGIANO

VICE PRESIDENT, CIRCULATION

JARED SONNERS

395 Hudson Street, 3rd Floor,
New York, NY 10014

REVIEW OF OPHTHALMOLOGY (ISSN 1081-0226; USPS No. 0012-345) is published monthly, 12 times per year by Jobson Medical Information, 395 Hudson Street, 3rd Floor, New York, NY 10014. Periodicals postage paid at New York, NY and additional mailing offices. Postmaster: Send address changes to Review of Ophthalmology, PO Box 71, Congers, NY 10929-0071. Subscription Prices: US One Year \$63.00, US Two Year \$112.00, Canada One Year \$99.00, Canada Two Year \$181.00, Int'l One Year \$158.00, Int'l Two Year \$274.00. For subscription information call (877) 529-1746 (USA only); outside USA, call (845) 267-3065. Or email us at revophtalmology@cambeywest.com. Canada Post: Publications Mail Agreement #40612608. Canada Returns to be sent to Bleuchip International, P.O. Box 25542, London, ON N6C 6B2.

(Continued from p. 6)

Market Segmentation 101

that'll add cost to an already packaged surgical cost? How will the surgeon get the product in their hands for a procedure, and is there a difference between an ambulatory surgical center vs. a larger academic hospital setting? Does the product increase speed or quality? Decrease surgical complications? Or is it meant only for high-risk patients who are undergoing that surgery? How will a surgeon select the appropriate patient?

Performing even some basic market research in the form of surveys of your colleagues can help your business pitch. This doesn't always require hiring an expensive outside firm, especially for the earlier stage initial pitches during seed fundraising. In order to ensure you have the appropriate number and spread of physicians as part of your market survey, be mindful of the type of physicians and practices to whom you're speaking. You may be interviewing physicians that are early adopters, or work at a solo or group practices versus a large institutional centers or have an unusually high or low level of patient flow. This will help characterize not only the ultimate size of the market, but the speed of adoption, and will help define your sales ramp in the first several years after your product is launched.

There are times when an initial development plan and regulatory approval may initially address a specific slice of the market, followed by

development for broader segments. If this is the case, you should define the market projections in that first category, followed by projections for the stages of product roll out and the different phases of the product's life cycle. With the above core elements, you should be able to build at least a basic market model that consists of the number of patients and sales projections, focusing on the percentage of the specific subpopulation of patients in the target market segment. Being conservative at this step, rather than inflating your projections by assuming just the broad market with all segments, can actually help build credibility with investors. These considerations also highlight the importance of defining the target product profile (TPP), which we've discussed in previous columns. We can't stress enough the importance of starting with the TPP and defining target/ideal criteria for each category therein, as well as the minimally acceptable criteria. The exercise of defining the TPP will help drive the clinical trial design, get specific on patient population for enrollment in trials, and ultimately provide support your market model. ◀

Mr. Chapin is a senior vice president of the Asset Development & Partnering Group at Ora. The company offers drug, biologic and device consulting; preclinical and clinical research execution, regulatory and development strategy to support its clients and partners. Review and comments on this column were provided by Aron Shapiro, partner in the same group at Ora. The author welcomes your comments or questions regarding product development. Please send correspondence to mchapin@oraclinical.com or visit oraclinical.com.

(Continued from p. 4)

Aetna Pre-certification

unnecessary cataract surgery. We jumped through their hoops—which was wasteful—but they approved it all anyway. The extra busywork didn't benefit anyone.”

In response to the onerous policy, according to an official ASCRS statement on the saga, it and the AAO started a public relations campaign to try to inform the public about the negative impact this policy had on doctors, as well as the dangers of delayed and denied care for Aetna beneficiaries. The eye groups also met with Aetna, questioning the policy's necessity.

“We met with Aetna multiple times asking for the justification for this,” recalls Dr. Parekh. “We were asking for the data and informing them about how terrible the rollout was. For instance, last June, after we had heard that pre-authorization was going to be required starting July 1st, our staff began looking ahead at our July cataract surgeries to identify patients had Aetna so we could start calling the insurer for pre-approval. In June, Aetna said, ‘Don't worry about it, no authorization is required.’ But then, on July 1st, suddenly they turned around and said, ‘Yes, that person you called about last week needs prior authorization.’”

Dr. Parekh explained to the insurer that each call for prior authorization took upwards of 30 minutes, since all the data needed to be given to the representative. “So,

(Continued on p. 14)

CENTURION® VISION SYSTEM IMPORTANT PRODUCT INFORMATION

CAUTION: Federal (USA) law restricts this device to sale by, or on the order of, a physician.

As part of a properly maintained surgical environment, it is recommended that a backup IOL injector be made available in the event the AutoSert® IOL Injector Handpiece does not perform as expected.

INDICATION: The CENTURION® Vision System is indicated for emulsification, separation, irrigation, and aspiration of cataracts, residual cortical material and lens epithelial cells, vitreous aspiration and cutting associated with anterior vitrectomy, bipolar coagulation, and intraocular lens injection. The AutoSert® IOL Injector Handpiece is intended to deliver qualified AcrySof® intraocular lenses into the eye following cataract removal.

The AutoSert® IOL Injector Handpiece achieves the functionality of injection of intraocular lenses. The AutoSert® IOL Injector Handpiece is indicated for use with the AcrySof® lenses SN60WF, SN6AD1, SN6AT3 through SN6AT9, as well as approved AcrySof® lenses that are specifically indicated for use with this inserter, as indicated in the approved labeling of those lenses.

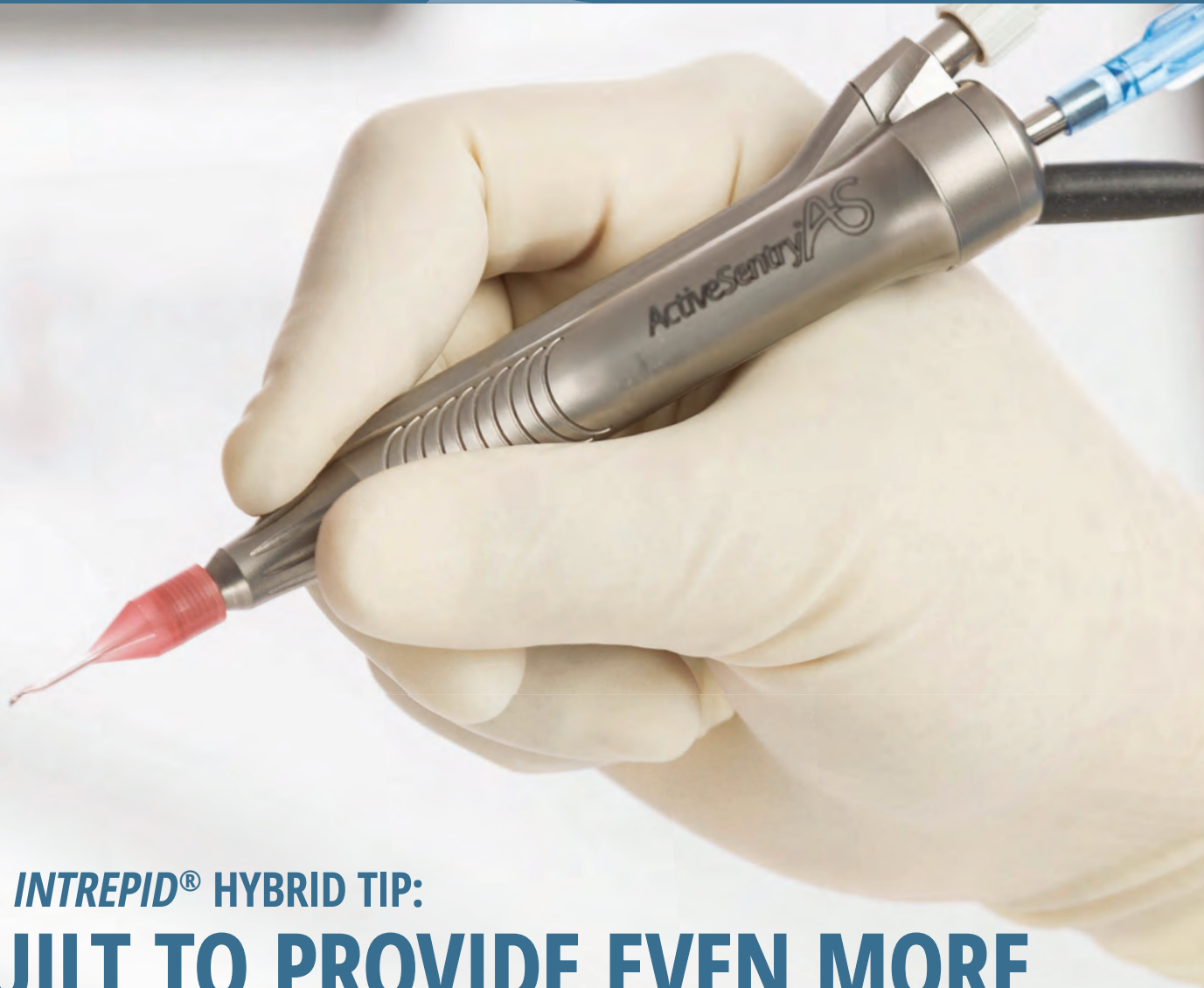WARNINGS: Appropriate use of CENTURION® Vision System parameters and accessories is important for successful procedures. Use of low vacuum limits, low flow rates, low bottle heights, high power settings, extended power usage, power usage during occlusion conditions (beeping tones), failure to sufficiently aspirate viscoelastic prior to using power, excessively tight incisions, and combinations of the above actions may result in significant temperature increases at incision site and inside the eye, and lead to severe thermal eye tissue damage.

Good clinical practice dictates the testing for adequate irrigation and aspiration flow prior to entering the eye. Ensure that tubings are not occluded or pinched during any phase of operation.

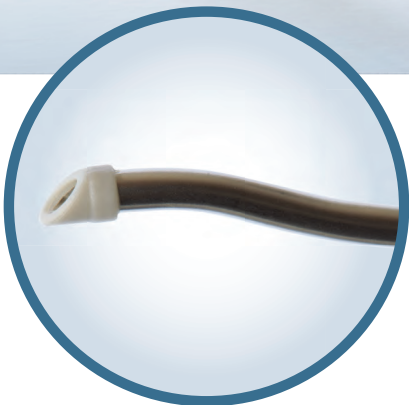The consumables used in conjunction with ALCON® instrument products constitute a complete surgical system. Use of consumables and handpieces other than those manufactured by Alcon may affect system performance and create potential hazards.

AEs/COMPLICATIONS: Inadvertent actuation of Prime or Tune while a handpiece is in the eye can create a hazardous condition that may result in patient injury. During any ultrasonic procedure, metal particles may result from inadvertent touching of the ultrasonic tip with a second instrument. Another potential source of metal particles resulting from any ultrasonic handpiece may be the result of ultrasonic energy causing micro abrasion of the ultrasonic tip.

ATTENTION: Refer to the Directions for Use and Operator's Manual for a complete listing of indications, warnings, cautions and notes.



THE *INTREPID*® HYBRID TIP: BUILT TO PROVIDE EVEN MORE PROTECTION DURING PHACO



With the **INTREPID® Hybrid Tip**, Alcon updated its proven INTREPID® BALANCED Tip and added a rounded polymer edge designed to reduce the risk of capsular tears and designed to improve patient safety in the OR.¹



FEATURES

Vol. 29, No. 8 • August 2022

Catch Up on the Latest News
Read *Review's* weekly newsletter
online at reviewofophthalmology.com.

42 Managing Retina in the Presence of Glaucoma

Managing retina problems in the setting of glaucoma raises the stakes. Here's how to play it safe.

Christopher Kent, Senior Editor

30 An Anti-VEGF Update For Wet AMD

Retina specialists discuss TREX, retreatment and their early experiences with the latest agents.

Christine Leonard
Senior Associate Editor

50 Managing a Posterior Capsule Break

Vitrectomy tips to help you come through this unexpected event unscathed.

Liz Hunter, Senior Editor

55 Retina and Cataract: When to Stage or Combine Procedures

When approaching these procedures, surgeons say that patient education and setting realistic expectations are the keys to success.

Michelle Stephenson
Contributing Editor

DEPARTMENTS

August 2022

4 News

16 EDITOR'S PAGE

Insurer, Heal Thyself

Walter Bethke
Editor in Chief

18 REFRACTIVE/CATARACT RUNDOWN

The Staying Power of Monovision LASIK

This refractive procedure remains effective and popular for presbyopia correction—in the right candidates.

Liz Hunter, Senior Editor

22 THE FORUM

Life's a Beach, or Not

Mark H. Blecher, MD
Chief Medical Editor



24 TECHNOLOGY UPDATE

New Ways to Address Amblyopia

Traditional approaches to diagnosis and treatment have been less-than-ideal. New high-tech options may change that.

Christopher Kent, Senior Editor

60 GLAUCOMA MANAGEMENT

Gene Therapy and Glaucoma: An Update

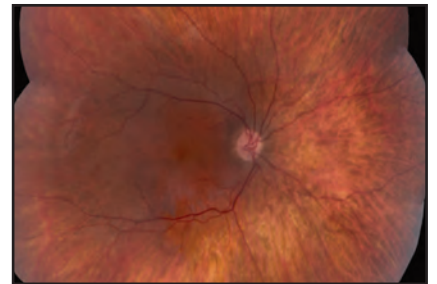
Advances in genetic manipulation are showing promise for mitigating glaucomatous damage and preserving sight.

Ahmara G. Ross, MD, PHD

67 PRODUCT NEWS

68 RESEARCH REVIEW

Outdoor Activities and Myopia Development



71 WILLS EYE RESIDENT CASE SERIES

A 20-year-old presents with bilateral amblyopia and chronic renal failure.

Kaylene Carter, MD, and
Tamara Vrabec, MD

73 AD INDEX

VISIT US ON SOCIAL MEDIA

Facebook

www.facebook.com/RevOphth

Twitter

twitter.com/RevOphth

Instagram

[@revophth](https://www.instagram.com/revophth)



SEE THINGS DIFFERENTLY

WITH EXCEPTIONAL CLARITY.



The **CLAREON® COLLECTION** of IOLs make the choice astoundingly clear. Alcon's most advanced lens design in one portfolio has evolved to meet cataract patients' needs, reliably.^{1,2} So if you're looking to give patients exceptional clarity that lasts, look no further.^{3,4}

Learn more at [ClareonIOL.com](https://www.alcon.com/ClareonIOL.com)

*Defined as modified Miyata grade 0, <25mv /mm² over 3 years (n=138), and over 9 years (n=20), respectively.

References: **1.** Clareon® IOL Directions for Use. **2.** Das KK, Werner L, Collins S, Hong X. In vitro and schematic model eye assessment of glare or positive dysphotopsia-type photic phenomena: Comparison of a new material IOL to other monofocal IOLs. *J Cataract Refract Surg.* 2019;45(2):219-227. **3.** Oshika T, Fujita Y, Inamura M, Miyata K. Mid-term and long-term clinical assessments of a new 1-piece hydrophobic acrylic IOL with hydroxyethyl methacrylate. *J Cataract Refract Surg.* 2020 May;46(5):682-687. **4.** Maxwell A, Suryakumar R. Long-term effectiveness and safety of a three-piece acrylic hydrophobic intraocular lens modified with hydroxyethyl-methacrylate: an open-label, 3-year follow-up study. *Clin Ophthalmol.* 2018;12:2031-2037.

(Continued from p. 9)

Aetna Pre-certification

we met with Aetna to explain the absurdity of this, and ask them to get their internet portal working, and to just tighten up their procedures for prior authorization.

“To decide on prior authorization, Aetna wasn’t even asking the right questions regarding cataract surgery,” Dr. Parekh continues. “If you want to have a prior authorization plan, there are certain things you need to ask the surgeon about: One is visual function, and the other is glare. For instance, as we know, with a high-contrast image in good lighting, a patient’s vision can be decent. But when that person is driving at night their vision significantly plummets. However, Aetna’s representatives weren’t even asking these things when deciding on the appropriate time to do surgery. On some occasions where we’d get denied and have to talk to a doctor to plead our case, the doctor they made available wasn’t an ophthalmologist. For all

these reasons, during our meetings with Aetna we’d try to explain to them that they needed a program grounded in clinical care.”

In response to relentless pressure from ophthalmologists, the American Academy of Ophthalmology, ASCRS and Rep. Mariannette Miller-Meeks, MD (R-IA) and Sen. Rand Paul (R-KY), Aetna has pulled the pre-authorization policy for cataract surgery in 48 states—only Georgia and Florida surgeons are still required to get pre-authorization for Medicare Advantage patients, for reasons that aren’t entirely clear.

Dr. Parekh is pleased with the outcome overall, however. “I am very happy to see this policy overturned, especially for my patients,” he says. “My commitment is to provide the best care, and I will continue to advocate on behalf of my patients to ensure timely access to care.”

Risk Factors for Astigmatism in Children with Chalazia

A study of chalazia in children found different characteristics can be risk factors for astigmatism.

The study included 398 patients (6 months to 6 years

old) divided into a chalazion group (n=491 eyes) and a control group (n=305 eyes). The researchers classified the chalazia by site, size and number and analyzed each patient’s refractive status.

They found that the incidence, type, astigmatism and refractive mean in the chalazion group significantly differed from the control group.

Findings in affected eyes included:

- **Incidence:** The middle-upper eyelid was 50 percent (the highest) and the medial-upper eyelid was 42 percent.
- **Type:** There were more medium (54.5 percent) and large (54.7 percent) chalazia than in controls (27.2 percent).
- **Astigmatism:** With multiple chalazia, the astigmatism incidence with two masses was 56 percent. The difference wasn’t significant in chalazia with ≥ 3 masses. “Astigmatism vector analysis can intuitively show the differences between groups,” the researchers noted in their paper. “The results are the same as refractive astigmatism.”
- **Refractive mean:** The medial-upper, middle-upper and medial-lower eyelid were higher than the control group. The 3 mm to 5 mm and >5 mm groups were higher than the control group and <3 mm group. The >5 mm group was larger than the 3 mm to 5 mm group. The researchers pointed out that this suggests “that the risk of astigmatism was higher when the size of the masses was >5 mm.”

The researchers concluded that chalazia in children can easily lead to astigmatism, particularly against-the-rule astigmatism and oblique astigmatism. The identified chalazia in the middle-upper eyelid, those ≥ 3 mm in size and multiple chalazia (especially two masses) as risk factors for astigmatism. ◀

IMPORTANT PRODUCT INFORMATION: CLAREON® FAMILY OF IOLS

CAUTION: Federal law restricts these devices to sale by or on the order of a physician.

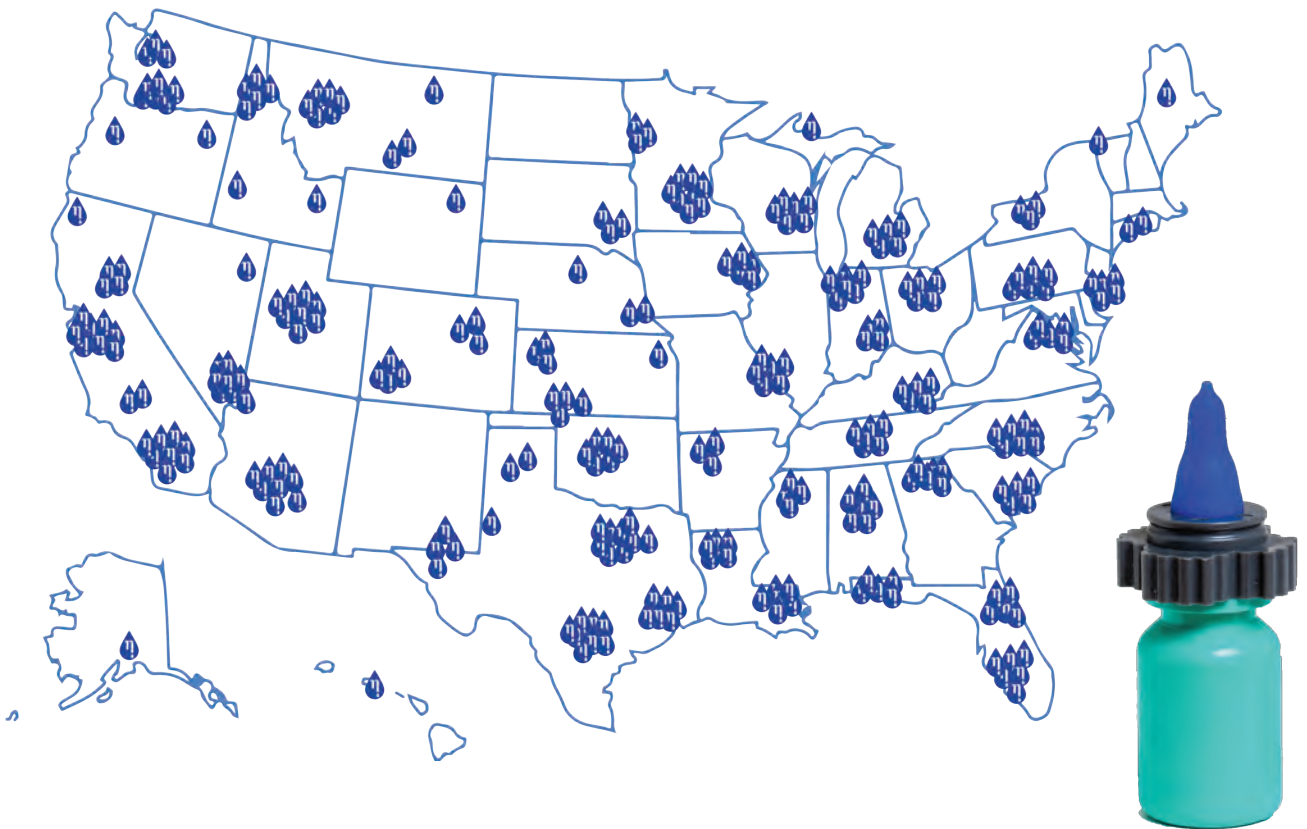INDICATIONS: The family of Clareon® intraocular lenses (IOLs) includes the **Clareon® Aspheric Hydrophobic Acrylic** and **Clareon® Aspheric Toric IOLs**, the **Clareon® PanOptix® Trifocal Hydrophobic IOL**, **Clareon® PanOptix® Toric**, **Clareon® Vivivity™ Extended Vision Hydrophobic Posterior Chamber IOL** and **Clareon® Vivivity™ Toric IOLs**. Each of these IOLs is indicated for visual correction of aphakia in adult patients following cataract surgery. In addition, the **Clareon® Toric IOLs** are indicated to correct pre-existing corneal astigmatism at the time of cataract surgery. The **Clareon® PanOptix®** lens mitigates the effects of presbyopia by providing improved intermediate and near visual acuity, while maintaining comparable distance visual acuity with a reduced need for eyeglasses, compared to a monofocal IOL. The **Clareon® Vivivity™** lens mitigates the effects of presbyopia by providing an extended depth of focus. Compared to an aspheric monofocal IOL, the lens provides improved intermediate and near visual acuity, while maintaining comparable distance visual acuity. All of these IOLs are intended for placement in the capsular bag.

WARNINGS/PRECAUTIONS: General cautions for all Clareon® IOLs: Careful preoperative evaluation and sound clinical judgment should be used by the surgeon to decide the risk/benefit ratio before implanting any IOL in a patient with any of the conditions described in the Directions for Use that accompany each IOL. Physicians should target emmetropia, and ensure that IOL centration is achieved. **For the Clareon® Aspheric Toric, PanOptix® Toric and Vivivity™ Toric IOLs**, the lens should not be implanted if the posterior capsule is ruptured, if the zonules are damaged, or if a primary posterior capsulotomy is planned. Rotation can reduce astigmatic correction; if necessary lens repositioning should occur as early as possible prior to lens encapsulation. **For the Clareon® PanOptix® IOL**, some visual effects may be expected due to the superposition of focused and unfocused multiple images. These may include some perceptions of halos or starbursts, as well as other visual symptoms. As with other multifocal IOLs, there is a possibility that visual symptoms may be significant enough that the patient will request explant of the multifocal IOL. A reduction in contrast sensitivity as compared to a monofocal IOL may be experienced by some patients and may be more prevalent in low lighting conditions. Therefore, patients implanted with multifocal IOLs should exercise caution when driving at night or in poor visibility conditions. Patients should be advised that unexpected outcomes could lead to continued spectacle dependence or the need for secondary surgical intervention (e.g., intraocular lens replacement or repositioning). As with other multifocal IOLs, patients may need glasses when reading small print or looking at small objects. Posterior capsule opacification (PCO), may significantly affect the vision of patients with multifocal IOLs sooner in its progression than patients with monofocal IOLs. **For the Clareon® Vivivity™ IOL**, most patients implanted with the Vivivity™ IOL are likely to experience significant loss of contrast sensitivity as compared to a monofocal IOL. Therefore, it is essential that prospective patients be fully informed of this risk before giving their consent for implantation of the **Clareon® Vivivity™ IOL**. In addition, patients should be warned that they will need to exercise caution when engaging in activities that require good vision in dimly lit environments, such as driving at night or in poor visibility conditions, especially in the presence of oncoming traffic. It is possible to experience very bothersome visual disturbances, significant enough that the patient could request explant of the IOL. In the parent AcrySof® IQ Vivivity™ IOL clinical study, 1% to 2% of AcrySof® IQ Vivivity™ IOL patients reported very bothersome starbursts, halos, blurred vision, or dark area visual disturbances; however, no explants were reported. Prior to surgery, physicians should provide prospective patients with a copy of the Patient Information Brochure available from Alcon informing them of possible risks and benefits associated with these IOLs.

ATTENTION: Reference the Directions for Use labeling for each IOL for a complete listing of indications, warnings and precautions.

NANO DROPPER

Don't let your clinic and patients get left behind.



Since our launch in June 2020, amidst a global pandemic, we have incorporated **hundreds of clinics** around the country into our partner clinic network. Each clinic has elevated the standard of care for their patients. **Are you ready to join in?**

Use discount code
REVIEWOPHTHO10 for 10%
off your first order!

The Nanodropper is the only FDA-listed, volume-reducing adaptor for eyedrop bottles designed to deliver precisely the amount of fluid the eye can absorb. Smaller drops reduce the waste and cost of in-clinic and Rx formulations while minimizing local and systemic side effects.

www.nanodropper.com | support@nanodropper.com | (507) 405-5676

Editor in Chief
Walter Bethke
(610) 492-1024
wbethke@jobson.com

Senior Editor
Christopher Kent
(212) 274-7031
ckent@jobson.com

Senior Editor
Liz Hunter
(610) 492-1025
ehunter@jobson.com

Senior Associate Editor
Christine Leonard
(610) 492-1008
cleonard@jobson.com

Associate Editor
Leanne Spiegle
(610) 492-1026
lspiegle@jobson.com

Chief Medical Editor
Mark H. Blecher, MD

Senior Art Director
Jared Araujo
(610) 492-1032
jaraujo@jobson.com

Graphic Designer
Lynne O'Connor
(267) 566-6007
lyoconnor@webmd.net

International coordinator, Japan
Mitz Kaminuma
Reviewophthamo@aol.com

Business Offices
19 Campus Boulevard, Suite 101
Newtown Square, PA 19073
(610) 492-1000
Fax: (610) 492-1039

Subscription inquiries:
United States — (877) 529-1746
Outside U.S. — (845) 267-3065
E-mail:
revophthalmology@cambeywest.com
Website: www.reviewofophthalmology.com



WALTER C. BETHKE, EDITOR IN CHIEF
EDITOR'S PAGE

Insurer, Heal Thyself

From the late 1940s and into the 1980s, Edward Rosenbaum, MD, was part of a thriving internal medicine and rheumatology practice in the Pacific Northwest, and he founded the University of Oregon Medical School's (now Oregon Health & Science University) Division of Arthritis and Rheumatic Diseases in 1950. He was on top of the world—until a diagnosis of throat cancer in 1985 stopped him in his tracks. For the first time, he was no longer in control. Instead of being the captain of the ship—the doctor—he was now just a cork bobbing in the vast, dark sea of the medical system—the patient. The experience opened his eyes to the inhumane way patients are sometimes treated.

“I have heard it said that to be a doctor, you must first be a patient,” he wrote in an account of his experience titled, “A Taste of My Own Medicine.” “In my own case, I practiced medicine for 50 years before I became a patient. It wasn't until then that I learned that the physician and the patient are not on the same track. The view is entirely different when you are standing at the side of the bed from when you are lying in it. If I could go back, I would do things very differently in my own practice than I did.”

The CEOs and the other executives of health insurance companies that impose unnecessary regulations on physicians and patients, specifically requirements for pre-authorization for cataract surgery, are a lot like Dr. Rosenbaum in the early '80s. I wish there were some way for them to switch places with ophthalmologists for a time, and have to deal with hours

spent on the phone with an insurance company in an effort to get authorization for a patient's cataract surgery, or fill out a mountain of paperwork for a surgery that should be routine, only to have it blithely rejected because a vowel was out of place in a name (and then have to wade through a time-consuming appeals process to correct it). Or maybe they would have to deal with an emergency retinal detachment/cataract surgery procedure in which the cataract gets denied, as recounted by the AAO's David Glasser, MD, last year when the Aetna pre-authorization program was being rolled out. After going through all this, I wonder if their feelings would change on the matter.

Of course, they will be on the other side of the fence one day: Everyone, if they live long enough, gets a cataract, and becomes a patient. How would the executives feel at that point, when their insurer denies the care that's been deemed proper by their physician? In fact, maybe that's what happened in Aetna's case, considering it has rescinded the pre-authorization requirement for cataract surgery in most states: A member of its board of directors probably developed a cataract and, after 20 minutes dealing with the pre-authorization hassle, said, “Uh, this is stupid. Drop it.”

Though other insurers appear to be following Aetna's original lead and initiating pre-authorization requirements of their own, let's hope they also follow Aetna's eventual path and scrap them just as quickly.

— Walter Bethke
Editor in Chief

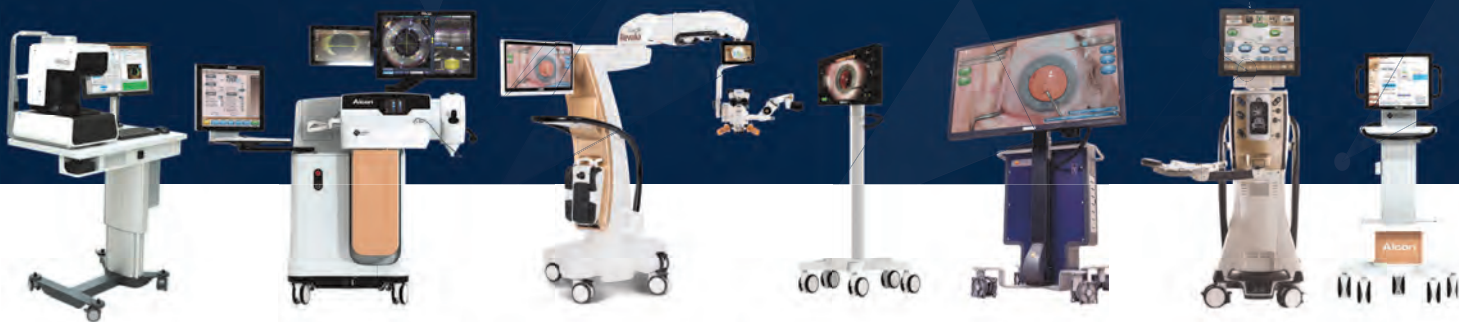Your practice working smarter

Work more efficiently.¹⁻⁵ Prepare from
anywhere. Get next-level accuracy.[†]

SMART Solutions seamlessly connects your compatible data systems, diagnostic devices, and surgical equipment to streamline processes and help you optimize patient outcomes. From the office to the OR, SMART Solutions paves the way for improved accuracy and efficiency so your practice can run at its best.

Explore ways to work smarter at
www.alconsmartsolutions.com.

[†]Enabled with integrated Image Guidance by ALCON®



© 2022 Alcon Inc. 03/22 US-DHS-2200018 | Please see the equipment product manuals for Important Product Information.

References

1. Alcon Data on File, 2020.
2. Blaylock JF, Hall B. Astigmatic results of a diffractive trifocal toric IOL following intraoperative aberrometry guidance. *Clin Ophthalmol*. 2020;14:4373-4378. doi:10.2147/OPTH.S285711
3. Cionni RJ, Dimalanta R, Breen M, Hamilton C. A large retrospective database analysis comparing outcomes of intraoperative aberrometry with conventional preoperative planning. *J Cataract Refract Surg*. 2018;44(10):1230-1235. doi:10.1016/j.jcrs.2018.07.016
4. Van Vliet EJ, Bredehoff E, Sermeus W, Kop LM, Sol JCA, Harten WH. Exploring the relation between process design and efficiency in high-volume cataract pathways from a lean thinking perspective. *Int J Qual Health Care*. 2011;23(1):83-93. doi:10.1093/intqhc/mzq071
5. Håkansson I, Lundström M, Stenevi U, Ehinger B. Data reliability and structure in the Swedish National Cataract Register. *Acta Ophthalmol Scand*. 2001;79(5):518-523. doi:10.1034/j.1600-0420.2001.790519.x



EDITED BY ARTURO CHAYET, MD

REFRACTIVE/CATARACT RUNDOWN

The Staying Power of Monovision LASIK

This refractive procedure remains effective and popular for presbyopia correction—in the right candidates.

LIZ HUNTER
SENIOR EDITOR

Even as patients have more options than ever to correct symptoms of presbyopia, whether with newly approved drops or IOLs, their satisfaction with monovision LASIK hasn't waned. The procedure is as popular as ever with patients, provided they meet the right criteria. Experts say that patient selection is critical for successful outcomes.

A study of 590 patients with refractive lens exchange and 609 patients with monovision LASIK,¹ showed a significant statistical difference in patient satisfaction, depending on their level of myopia. More than 94 percent of those with moderate to high myopia favored monovision LASIK, versus 79.1 percent for refractive lens exchange. The study showed that there was no significant difference in patient satisfaction within the other refractive categories.

Chair time and preoperative expectations are not to be overlooked, and we spoke with some veteran refractive surgeons who offered their insight on patient selection, targets and outcomes.

Prepping the Patient

Discussions about presbyopia treatment may begin as early as a pa-

tient's late 30s, according to Kathryn M. Hatch, MD, director of refractive surgery at Mass Eye & Ear, and an assistant professor of ophthalmology at Harvard Medical School.

"I start talking about presbyopia with patients who may be approaching it in the coming decade. It's good for all patients to know what it is because in general, presbyopia is a different issue from other refractive errors like myopia, astigmatism and hyperopia," Dr. Hatch says. "Certainly, patients in their 40s and older who already need some sort of reading correction are finding out their options."

J. Bradley Randleman, MD, a professor of ophthalmology at the Cole Eye Institute of the Cleveland Clinic Foundation, says anyone over age 40 is a potential candidate for monovision LASIK. "By that point, a vast majority of us need near, or at least intermediate and distance vision, interchangeably most of the time," he says. "Short of restoring accommodation—which we just can't do currently, and may never be able to do—we're going to have a vast majority of the population who needs something for multiple distances, and that's the starting criteria."

There are some sets of patients that can be eliminated early on in the screening process, he continues. "People who don't have optimal

equal vision in both eyes may not be candidates, so someone with amblyopia doesn't tend to do as well with monovision," says Dr. Randleman. "We also make sure to screen for any history of strabismus or some sort of -phoria or -tropia where dissociating their refractive error would increase the risk of them developing double vision."

A person's occupation and daily activities may also make them think twice about the procedure. "Pilots, commercial drivers, athletes—they all need a certain level of acuity while doing their jobs. That doesn't mean they can't have monovision, but they would need to have it partially, if not fully, corrected," Dr. Randleman advises. "Somebody who's doing real near tasks all the time isn't going to tolerate even a small amount of undercorrection or a small amount of monovision, but somebody who's doing primarily distance-related activities, may not really notice a big change in their functional near vision until a little bit later."

The most obvious group of patients eligible for monovision LASIK would be those who already have some level of monovision in their contact lenses, says Dr. Hatch. "Someone who is already undercorrecting their myopia and over the age of 45 would be the ideal person to get monovision LASIK immediately."

Discussing expectations and putting the patient in a contact lens trial can influence the treatment plan.

"It's important for people to understand that having LASIK, even with monovision LASIK, sometimes pushes patients into readers a little bit earlier," Dr. Hatch says. "Someone who might be a low myope

This article has no commercial sponsorship.

Dr. Chayet is considered a pioneer in refractive and cataract surgery, and is the medical director of the Codet Vision Institute in Tijuana, Mexico. He is a clinical investigator for RxSight, LensGen and ForSight Vision6.

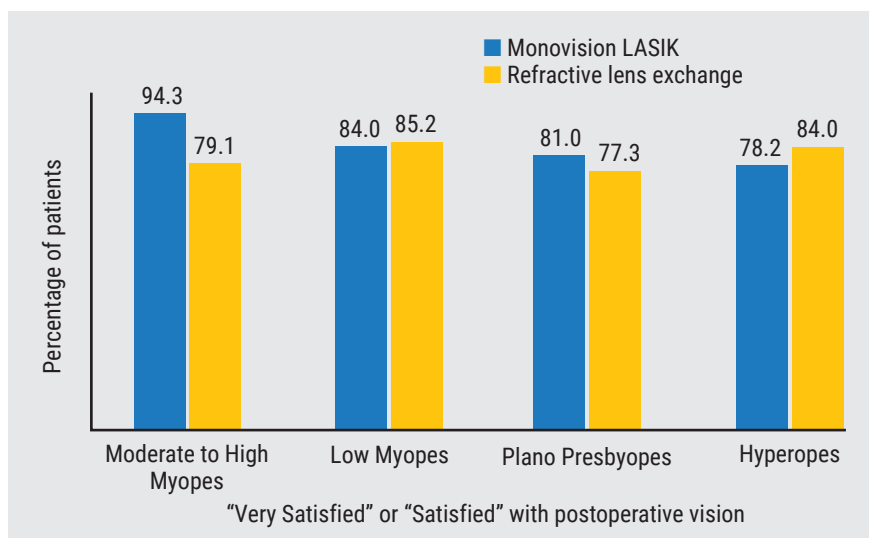


Figure 1. Monovision LASIK continues to have high patient satisfaction rates in the right candidates.¹

and only wears glasses for distance correction might not necessarily understand right away that if we correct both eyes for distance they’ll need reading glasses immediately. There has to be some significant discussion with those patients, because it can be very disconcerting for a low myope to suddenly need correction to see their watch or their phone.”

Dr. Randleman says every procedure has its inherent trade-offs. “That’s just the reality as we age. The better we make your distance vision the worse we make your near, and vice versa. By definition, the eye that we leave myopic isn’t going to see quite as well as the other eye now,” he says. “If their distance vision feels blurred all of the time, then they’re not tolerating monovision. Nighttime vision may be a little more impaired, so a good monovision patient might have a light pair of glasses in the car that they wear occasionally. Same goes for near. We want you to be able to pick up a menu and read it, but if you’re going to sit down and read a novel, you may end up wanting both eyes to be clear for that, so you might have a pair of readers that you use for specific activities.”

These scenarios lead to a trial period of the monovision in contact lenses. “For a monovision trial, we’ll

typically send them home with their homework assignment, if you will, because we really want to see how this option will work in their environment, not just in our office or on our eye chart,” Dr. Randleman says.

Dr. Hatch says she likes her patients to undergo the trial for at least a week to see how they tolerate it. “Some patients love it and others say they couldn’t get used to it, but even in those patients, I come up with ways to adjust the targets that’ll work for them,” she says.

Mini-monovision is the New Normal

Vision needs have evolved with the advent of handheld devices, and as a result, the refractive targets for monovision LASIK procedures have also changed.

“We really have three or more ranges of vision: distance; intermediate; and true near,” says Dr. Randleman. “Most of our world now is in the distance and intermediate categories. Computer screens, smartphones and menus tend to be intermediate, and refractive surgeons don’t do quite as much true monovision anymore—when one eye is set for real, functional near and the other is set for distance. Much more commonly we’re doing a distance target and an intermediate target.

“When I started in the early 2000s, a true monovision target was more like a -2.5 D,” Dr. Randleman continues. “I can’t remember the last time I targeted a patient with that much myopia. Now, the average person in their 40s is going to be around -0.75 D in the near target, unless their specific needs or profession dictates otherwise. Patients in their 50s will generally push up to potentially a -1.5 D. Usually, somewhere between -0.75 D and -1.25 D is more than adequate.”

These ranges were typically referred to as “mini-monovision” or “micro-monovision,” he says, but are the norm for monovision procedures currently.

Dr. Hatch has been targeting mini-monovision for patients who say they don’t want monovision LASIK. “I’ve had many patients over the years say they didn’t want the procedure, and then they end up with full correction in both eyes,” she says, recalling a 48-year-old patient who didn’t like the feeling of having one eye undercorrected. “I suggested we do a full correction but in the non-dominant eye we would do a slight undercorrection, a -0.25 D to -0.50 D, so it wouldn’t be enough to notice a huge difference with both eyes open. At least she would see her watch, dashboard and basic things at intermediate level, although ultimately she’d need reading glasses.”

Dr. Hatch says she refers to this as a “slight age adjustment” with patients. “I’ll tell people I’m going to do a slight age adjustment in their non-dominant eye to ensure they don’t end up overcorrected,” she says. “They may not have a crisp 20/20 for distance, they might be 20/25, but their other eye is 20/20. They really can tolerate that very well. Even though some patients say they don’t want monovision, I’m doing this age adjustment, because who wants to put on glasses to look at their watch?”

Enhancements may be common with certain patients undergoing

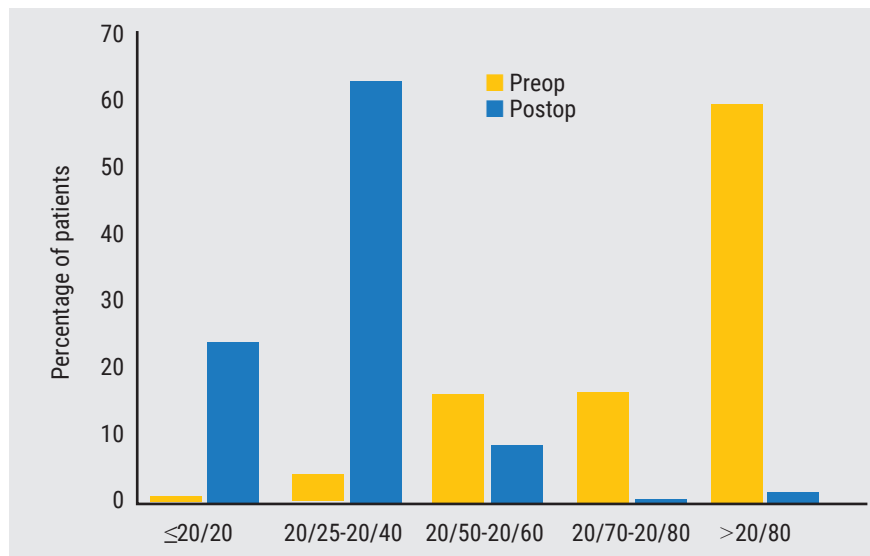


Figure 2. One study showed near acuity improved to 20/40 or better in more than 88 percent of patients who underwent monovision LASIK.³

monovision, Dr. Hatch continues. “If you end up not nailing the distance eye, then you have two eyes undercorrected, so you may need to be prepared for enhancements, especially if you’re dealing with higher myopes,” she says. “Achieving your refractive target is extra important.”

Refractive surgeons may even want to consider doing one eye at a time, particularly in low myopes. “You treat the dominant eye first to get the distance and let people try it,” Dr. Hatch says. “I’d much rather do the eyes separately than be in a situation where patients feel regretful and then I have to do some sort of reversal laser procedure.”

Dr. Randleman agrees. “In patients who are hyperopic, we have to overtreat them. Then, if they don’t like monovision, we have to essentially undo that with a different type of ablation, so I’m much more keen on really making certain we like that strategy before doing those surgeries,” he says, which further emphasizes the importance of testing and trials.

“Every patient is so different, it’s literally impossible to predict ahead of time,” Dr. Randleman avers. “We have these broad ranges, but we refine them based on how much difference between the two eyes the patient can tolerate.”

Outcomes and Patient Satisfaction

Postoperatively, patients will experience many of the initial side effects that are common with any LASIK procedure, says Dr. Randleman, including increased glare and halos at night or in dark situations. Side effects have been shown to be more prevalent in monovision hyperopes.² “Patients can also have a little bit of dryness early on, and that will take away some of the crispness of the vision until it recovers. When you add monovision, you need to give it a little bit of time to figure out which of those factors is really an issue and which ones are just part of early healing,” he says.

Monovision will take a bit longer to adjust to, he continues. “It’s not uncommon for people to be aware of the fact that they’re seeing distance with one eye and near with the other, but the ultimate goal is for that to become integrated to the point where they’re just seeing,” says Dr. Randleman. “We don’t want patients to be particularly mindful of which eye is functioning at which distance in the long term. It’s an unconscious process that just has to happen.”

Some patients can be fully recovered within one week, while others may be slower. “If they’re still notic-

ing some differences at three months, but they recognize it’s getting better week after week, then they’re just on the slow side of recovery. That’s not unheard of,” Dr. Randleman says. “But if it’s still awful with no improvement, then we may be looking at reversing the monovision.”

He recommends another contact lens trial in this situation to determine if it’s really the monovision causing the issues.

Monovision LASIK continues to show positive results in patients. One study of presbyopic emmetropic patients showed near acuity improved to 20/40 or better in 88.9 percent of patients with recorded postoperative near reading acuity, and the UCVA in the distant eye was 20/20 or better in 89.8 percent and 20/25 or better in 98.3 percent.²

Dr. Randleman says the number of patients who like this procedure is quite high. “Other options, such as a multifocal contact or progressive glasses, can still be a little distorting optically,” he says. “They all change the optics a bit more than monovision. Monovision is simply your normal optical process, but with a specific focal point, so you’re not changing anything about the function of the eye.

“Secondly, it’s much easier in my estimation for someone to work around a part-time need for glasses or contacts, as opposed to working around tolerance issues with multifocality,” Dr. Randleman adds. “That’s why I think monovision will continue to be often used.” ◀

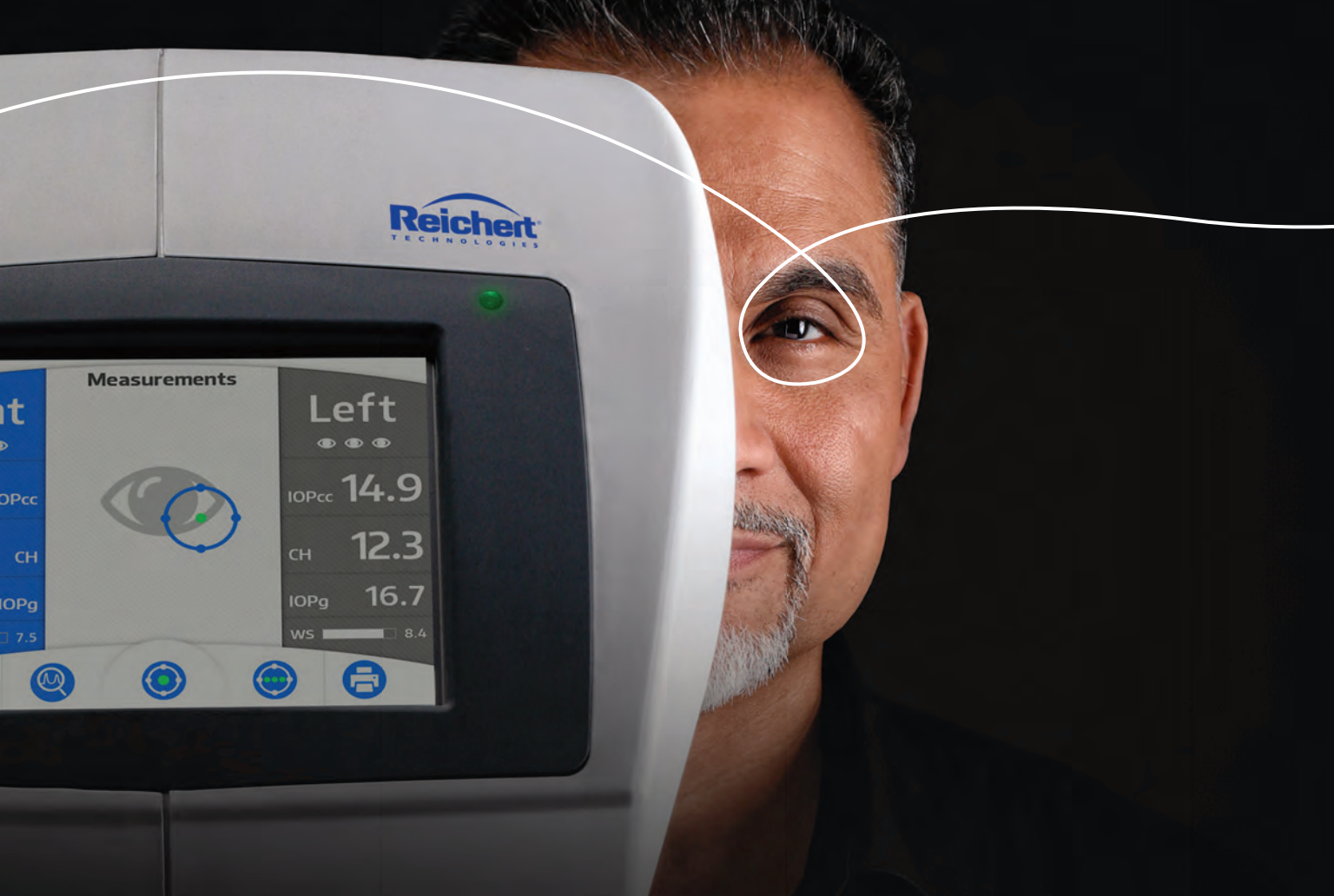1. Schallhorn SC, Teenan D, Venter JA, Schallhorn JM, Hettlinger KA, Hannan SJ, Pelouskova M. Monovision LASIK versus presbyopia-correcting IOLs: comparison of clinical and patient-reported outcomes. *J Refract Surg* 2017;1,33:11:749-758.

2. Goldberg, DB. Comparison of myopes and hyperopes after laser in situ keratomileusis monovision. *J Cataract Refract Surg* 2003;Sep;29:9:1695-701.

3. Peng MY, Hannan S, Teenan D, Schallhorn SJ, Schallhorn JM. Monovision LASIK in emmetropic presbyopic patients. *Clin Ophthalmol* 2018;12:1665-1671.

DISCLOSURES

Dr. Randleman and Dr. Hatch report no relevant financial disclosures



MEASURE BEYOND PRESSURE WITH CORNEAL HYSTERESIS.

Only **Ocular Response Analyzer® G3** measures **Corneal Hysteresis (CH)** and **Corneal Compensated IOP (IOPcc)** using patented technology to assess the unique corneal biomechanical properties of your patient. Corneal Hysteresis has shown to be an independent risk factor and more predictive of glaucoma development and progression than CCT or IOP¹⁻³. Using biomechanics, IOPcc is less influenced by corneal properties than Goldmann applanation tonometry⁴.

LEARN MORE



WATCH THE VIDEOS AT
[REICHERT.COM/ORA](https://www.reichert.com/ora)

Reichert
AMETEK

passionate about eye care



Life's a Beach, Or Not

Musings on life, medicine and the practice of ophthalmology.

MARK H. BLECHER
CHIEF MEDICAL EDITOR

Right about now most of you are thinking of vacation—one you already took or one that's coming up. After having to deal with all the complications and challenges involved in practicing our chosen profession, a well-earned vacation gives us a chance to relax, do something different, or just go somewhere else to achieve a state of refreshing calm.

Vacation, however, means different things to different people. For some, it can simply involve not going into the office or the OR. For others, it might be a two-week trek through a national park or days spent lying on a beach. While most of us will do each of those things at some point, we have preferences for where we can best recharge, and where we feel the most relaxed and comfortable.

In my head, I break it down to either a cultural vacation—think visiting the great cities of Europe—or a relaxing vacation, either at home or some other calming spot. For the latter, my compulsive need to categorize requires me to decide on either the beach or mountains. You may think that this is an obvious duality. One has sand, the other trees. But it's much more Freudian than that—for me, anyway.

I decided on the locale that best suited me more than 30 years ago,

when I wanted to find a weekend retreat from my urban professional life in the Northeast. Not being a city boy by upbringing or temperament, I needed somewhere to get away from people, noise and distractions. So: mountains or beach. And no, Jersey Shore, I'm not talking about you: Too many people, too much noise and distractions. Aside from the local lack of quiet beach options, there's another reason I wasn't interested in being by the ocean: It's disturbing, unsettling. Yes, I'm one of those rare people with thalassophobia (your word for the day): "Fear of large bodies of water." In researching for this piece, I couldn't find any specific cause for this phobia, unlike my arachnophobia, which was a result of putting my 5-year-old foot into a slipper with a spider in it. (I only recently stopped shaking out my shoes before putting them on.)

It's not like I'm scared to be on a beach; I just don't find it comforting. Yes, the sound of the waves can be pleasant. The air can be refreshing. The water can be a pretty shade of blue. But ... all that water, stretching out to the horizon, and the thought of not knowing how deep it is or what might be in it (shiver). The feeling of staring at infinity. I've read that perhaps my problem is the lack of anything to organize, the unknowable state of the ocean and, most important, my inability to exert control over it—all derivatives of my

somewhat OCD/ADHD personality. But I think it's deeper than that. If I really sit down and think about it, the feeling I get in my gut when I'm near the sea is more primal, more 'end of the earth,' and, therefore, more disturbing.

Now, don't get me wrong, I still go to the beach. Being somewhere different is fun. I can appreciate the beauty of Bora Bora. And I'm not afraid of water; I love lakes, even big ones. OK, maybe standing on a Chicago pier and looking out over the immensity of Lake Michigan is creepy. The other piece of my phobia is that beaches are flat and, not infrequently, the land beside them is flat, also. Now I'm talking about you, New Jersey. All that flat sand feels exposed, vulnerable. So, perhaps there's a touch of agoraphobia in me, too.

Having said all this, you can likely guess where I've spent my weekends. Forests are the ultimate cocoon for me. Quiet, protective and able to breathe life back into me. Though I don't live in a forest, the more trees around me the better. Now, I AM looking at you, New Jersey—specifically the hills, valleys and streams of northwest New Jersey. Yes, though it may be surprising to some, New Jersey can be bucolic, quiet and very, very green. It can also be comforting, even if hiking through a forest is way more work than simply lying on the sand.

I hope all of you will have the opportunity to get some time to disengage—if not completely unplug—this summer, and come back to tackle the world refreshed. Ironically, after penning this paean to sylvan spaces, I'm going to get ready for my annual pilgrimage to Cape Cod.

I'm just not going to go to the beach. ◀

PROGRESSION IN GEOGRAPHIC ATROPHY IS RELENTLESS AND IRREVERSIBLE¹⁻⁴

While GA progression may appear to move slowly, it can affect your patients faster than you think^{1,4-6}

The consequences of Geographic Atrophy (GA) are too critical to be ignored⁷⁻⁹



IN A MEDIAN OF ONLY 2.5 YEARS, GA lesions encroached on the fovea according to a prospective AREDS study (N=3640)^{2*}



2 OUT OF 3 PATIENTS lost the ability to drive in a median time of <2 years according to a retrospective study (n=523)^{10†}

GA lesions can lead to visual impairment even before they reach the fovea^{1,5,6}



See the effect of GA progression on your patients

*Data sourced from the Age-related Eye Disease Study (AREDS) Report #26—a long-term, multicenter, prospective study examining progression of GA area in a cohort of 3640 patients with signs of early and more advanced forms of AMD.

†A retrospective cohort analysis (N=1901) of a multicenter electronic medical record database examining disease burden and progression in patients in the United Kingdom with bilateral GA secondary to AMD.

BCVA=best-corrected visual acuity.

References: 1. Boyer DS et al. *Retina*. 2017;37:819-835. 2. Lindblad AS et al, and AREDS Research Group. *Arch Ophthalmol*. 2009;127(9):1168-1174. 3. Holz FG et al. *Ophthalmology*. 2014;121(5):1079-1091. 4. Sunness JS et al. *Ophthalmology*. 2007;114(2):271-277. 5. Kimel M et al. *Invest Ophthalmol Vis Sci*. 2016;57(14):6298-6304. 6. Sadda SR et al. *Retina*. 2016;36(10):1806-1822. 7. Singh RP et al. *Am J Ophthalmic Clin Trials*. 2019;(1):1-6. doi:10.25259/ajoc-9-2018. 8. Sivaprasad S et al. *Ophthalmol Ther*. 2019;8(1):115-124. 9. Patel PJ et al. *Clin Ophthalmol*. 2020;14:15-28. 10. Chakravarthy U et al. *Ophthalmology*. 2018;125:842-849.

Apellis

Intended for US HCP only.
© 2022 Apellis Pharmaceuticals, Inc.
All rights reserved. 2/22 US-GA-2200004 V1.0



EDITED BY MICHAEL COLVARD, MD
AND STEVE CHARLES, MD

TECHNOLOGY UPDATE

New Ways to Address Amblyopia

Traditional approaches to diagnosis and treatment have been less-than-ideal. New high-tech options may change that.

CHRISTOPHER KENT
SENIOR EDITOR

Traditional therapies for amblyopia have limited effectiveness, are uncomfortable and can be hard on both the patients and their families. For these reasons, both clinicians and researchers alike have been working on better treatments that help avoid the drawbacks of past therapies.

Today, advanced technology is allowing the development of new ways to diagnose and treat amblyopia. Here are some new technologies that are showing promise.

The Nature of the Problem

Amblyopia can be the result of many different factors. Conditions causing it can include myopia, hyperopia, astigmatism, strabismus or cloudiness in the crystalline lens. The vision in the underused eye then gets worse as the brain suppresses its visual input. Left untreated, this can lead to long-term deficits in vision.

Amblyopia is currently the leading cause of preventable monocular vision loss, affecting about 3 percent of all children in the United States.¹⁻³ In addition to impaired perception in the underused eye, amblyopia causes a loss of stereopsis and depth perception,⁴ a reading speed about 25 percent slower than

other children,⁵ impaired motor skills and loss of dexterity,⁶⁻¹¹ lower self-confidence¹²⁻¹⁴ and lower self-reported quality of life.¹⁵

The Traditional Approach

On the positive side, studies have demonstrated that repeated early screening of children for amblyopia dramatically decreases its prevalence (compared to waiting until children start school to begin screening).¹⁶⁻¹⁸ Also, studies have also shown that initiating therapy before age 3 causes a 70-percent reduction in amblyopia prevalence.¹⁶⁻¹⁸

Conventional treatment has included eye patching or blurring atropine eye drops, intended to minimize the use of the stronger eye and force the child to use the weaker eye. Drawbacks include that these approaches don't train the eyes to work together; they produce notoriously poor compliance; and they can stigmatize the child among his or her peers. In addition, these approaches fail to restore normal visual function in a significant percentage of children.

Furthermore, traditional means of diagnosing amblyopia have relied on detecting vision problems that sometimes lead to amblyopia, rather than detecting amblyopia itself. Data suggests that one in every five children has at least one risk factor

for amblyopia, but only one in 40 children actually has amblyopia. As a result, only one out of every eight children referred for further evaluation—based on having a risk factor—actually has amblyopia. (That's a false positive rate of about 87 percent.) This results in very high rates of unnecessary referrals for treatment.

Eileen E. Birch, PhD, an adjunct professor of ophthalmology at the University of Texas Southwestern Medical Center, and director of the Crystal Charity Ball Pediatric Vision Laboratory, part of the Retina Foundation of the Southwest, points out that most pediatricians and vision screening programs still rely on visual acuity charts to test for amblyopia. "One problem with that approach is that only a third of 3-year-old children and half of 4-year-old children can complete the test," she says. "Sometimes automated tests are used, but they're also less than ideal because they detect hyperopia and anisometropia instead of amblyopia. Only a small fraction of those testing positive for hyperopia or anisometropia actually have amblyopia. Many pediatricians don't even attempt to screen for amblyopia because the false-positive rate is so high."

New Tech for Diagnosis

The Blinq Pediatric Vision Scanner (Rebion, Boston) is a handheld device that uses a laser probe to detect abnormal bifoveal fixation, an early sign of amblyopia. This technique, called neural performance scanning, has been cleared by the FDA for microstrabismus and amblyopia screening.

The Blinq device is held 14 inches from the child's eyes. The child fixates on a smiley face while

This article has no commercial sponsorship.

Dr. Colvard is a surgeon at the Colvard-Kandavel Eye Center in Los Angeles and a clinical professor of ophthalmology at the Keck School of Medicine of the University of Southern California. **Dr. Charles** is the founder of the Charles Retina Institute in Germantown, Tennessee.



The Blinq Pediatric Vision Scanner (Rebion) detects abnormal bifoveal fixation as small as one degree. The device provides a “pass” or “refer” signal after testing. Unlike traditional amblyopia screening tests, Blinq has a low false-positive rate, the company says.

the device scans both retinas in just over two seconds; it can detect a misalignment between the foveas as small as one degree. The device calculates a binocularity score and gives a “pass” or “refer” signal after the two-second test, so there’s no need to interpret numerical data.

One major selling point for the Blinq device is its low false positive rate—especially compared to previous methods used to scan for amblyopia, such as visual acuity charts looking for refractive error. Using Blinq, false positives from testing young children have been 15 percent or lower in some clinical studies. For example, in one clinical trial testing the previous iteration of the device (the Pediatric Vision Scanner), 300 children 2 to 5 years of age, with no known eye problems, were scanned.¹⁹ Six children who had been determined by a specialist’s exam to have amblyopia were all correctly identified by the device. That study found a false positive rate of 15 percent, using this earlier iteration of the device. (That rate dropped to 9 percent when uncooperative children were omitted from the dataset.)

Another prospective study published in 2021 using the new Blinq device evaluated 193 individuals ranging in age from 1 to 20 years.²⁰ In this population, sensitivity was

100 percent and specificity was 91 percent. In a subanalysis of children aged 2 to 8 years in this study (n=92), sensitivity was 100 percent and specificity was 89 percent. However, a study conducted in Belgium involving 101 children between ages 2 and 8, published this spring, found a specificity of only 73.1 percent.²¹

Dr. Birch explains that detecting amblyopia directly is what makes Blinq so promising. “Because of the unique architecture of the Henle fibers in the fovea, retinal birefringence scanning using polarized light can detect whether fixation is steady or eccentric,” she says. “Steady fixation causes frequency doubling in the reflected signal, with a dominant frequency of 200 Hz in the returning light. Unsteady fixation, caused by amblyopia, produces little or no birefringence, with little or no 200-Hz frequency light in the reflected signal.”

Dr. Birch says that her group conducted two studies in which 400 preschool children (2 to 6 years of age) were screened using a birefringence scanner at three pediatric care practices.²² “We compared our results to those of a gold-standard comprehensive exam done by a pediatric ophthalmologist,” she says. “Scanning with birefringence had 97-percent sensitivity and 90-percent specificity. This was a significantly lower false-

positive rate than that produced by the automated scanners that check for risk factors only.”

High-tech Eyeglasses

CureSight, from NovaSight (Airport City, Israel) is a binocular, eye-tracking-based, digital vision-treatment system designed for patients ages 4 to 9 suffering from amblyopia. The child watches any streamed video content of choice through red and blue glasses. CureSight blurs the visual center of the image that’s being shown to the stronger eye using real-time image processing, based on the momentary gaze position being captured by the eye tracker. The company says that the blurred center of vision of the stronger eye forces the brain to complete the image using the details available to the amblyopic eye. This gets the patient’s visual system in the habit of relying more on the weaker eye, while training the two eyes to work together. CureSight is designed to be used at home, under the remote supervision of an eye-care provider and NovaSight’s Monitoring Center.

This spring, NovaSight announced data from a multicenter, randomized, controlled trial of the system. The study involved 103 kids aged 4 to 9, done at six medical centers; it compared the visual improvement achieved by CureSight



CureSight (NovaSight) lets a child watch any video content through special glasses. Using eye tracking to monitor the child's gaze, the system blurs the visual center of the image being seen by the stronger eye, forcing the brain to incorporate information from the weaker eye.

treatment to that produced by eye patching. Findings included:

- The CureSight system was shown to be noninferior to eye patching for amblyopia treatment.
- BCVA improvement at week 16 was larger in the CureSight group than in the patching control group.
- No serious adverse events were observed in either treatment arm.
- Mean adherence to the CureSight protocol, as measured by the CureSight's eye tracking system, was 93 percent at week 16 (n=43). (Adherence to patching is notoriously limited.)
- Ninety-three percent of parents reported that they're likely to choose the CureSight digital treatment over patching.

"During the study, binocular visual acuity and stereo acuity improved significantly in both the CureSight and patching groups," says Tamara Wygnanski-Jaffe, MD, head of the Pediatric Ophthalmology and Strabismus Service at The Goldschleger Eye Institute of the Sheba Medical Center in Israel. (She participated in the CureSight clinical trial and is an unpaid member of the NovaSight advisory board.) "Distance visual acuity in the amblyopic

eye improved similarly in both groups. However, vision improvement in eyes treated with patching plateaued at week 12, while children treated with CureSight kept improving through week 16."

Dr. Wygnanski-Jaffe points out that patching, although effective, has several inherent shortcomings. "Patching only achieves low adherence, in part because it's uncomfortable," she notes. "In contrast, binocular therapy with CureSight takes place in the patient's home, with an unlimited variety of streamed content chosen by the child or parents. Furthermore, unlike some binocular treatments for amblyopia that include VR headsets and tablet games, CureSight isn't limited by interpupillary distance or fitting issues, and it doesn't require the use of cumbersome goggles."

Dr. Wygnanski-Jaffe points out that CureSight is essentially a remote patient monitoring system. "Prescribing physicians have access to CureSight's dedicated cloud platform, which allows them to monitor patients' progress remotely," she explains. "Furthermore, a dedicated monitoring center observes the progress of each patient's treatment

and the extent of compliance. If it detects low compliance, it contacts the patient's guardians to ensure that the child proceeds with the treatment as prescribed."

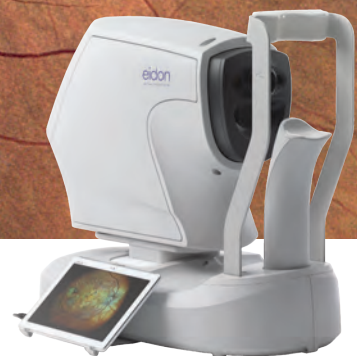Dr. Wygnanski-Jaffe says the company is planning to increase the device's flexibility to allow it to treat adult amblyopes. "A small feasibility study has shown promising results, and NovaSight is planning to initiate a larger study," she explains. "Meanwhile, the company is working on developing the second generation of the CureSight device, which will be designed to treat cases of strabismic amblyopia by shifting the two images in the screen plane to cope with the momentary deviation angle between the eyes."

The CureSight system currently has the CE mark and has recently applied for a 510K FDA approval.

Virtual Reality Goggles

Luminopia One (from Luminopia in Cambridge, Massachusetts) is a new prescription digital therapy software for kids 4 to 7 years old who have amblyopia associated with anisometropia and/or mild strabismus. Luminopia One works by visually modifying any of a library of popular

The next level of iCare



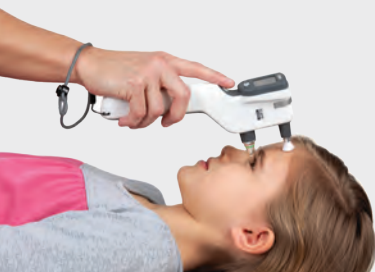iCare EIDON

Eidon Ultra-Widefield:
200 degrees of **imaging**

iCare's unique combination of sharpness and TrueColor now offers a wider view of the retina. From 120° with a single image capture, up to 200° using the mosaic function, helps detect subtle signs of pathology in the periphery.*

- + Rich in details from center to periphery
- + Imaging through media opacities

* Ultra-Widefield imaging is available with the optional EIDON UWF Module.



iCare IC200

200 degrees of
tonometry

- + Supine, reclined & seated positions
- + No corneal disruptions

- + Suitable for every patient
- + Single use probes to exceed infection control guidelines



For more information, scan,
call 888.422.7313, or email
infoUSA@icare-world.com
www.icare-world.com/USA

For better perception **icare**



Luminopia One (Luminopia) allows a child to watch any of a library of popular kid-friendly TV shows and movies. The visuals have been processed to require the brain to combine the images during viewing.

TV shows and movies for a young patient to watch through a virtual reality headset. The software alters the images seen by each eye in a way that requires the brain to combine the images, strengthening visual processing, promoting increased use of the weaker eye and encouraging the eyes to work together.

The system was developed in collaboration with leading clinicians and researchers at Boston Children's Hospital and MIT. Available videos for use with Luminopia One include more than 700 hours of popular and educational content from media companies such as Sesame Workshop and Nickelodeon. Meanwhile, a cloud-based platform tracks the child's usage, monitoring adherence to treatment. As a result, parents can control what the child is watching and track how their child is doing.

The company has conducted multiple clinical trials of Luminopia One working with hospitals and research institutions across the United States, including a prospective, randomized, controlled Phase III trial. In that trial, 105 children with amblyopia

aged 4 to 7 were enrolled at 21 sites, randomized 1:1 to treatment or a control group.²³ Those in the treatment group used the system at home one hour a day, six days a week for 12 weeks (the protocol recommended for standard patients).

At 12 weeks, amblyopic eye visual acuity improved by 1.8 lines (95% CI, 1.4-2.3 lines; $n = 45$) in the treatment group; in the control group visual acuity improved by 0.8 lines (95% CI, 0.4-1.3 lines; $n = 45$), a significant difference ($p=0.0011$). Eighty-four percent of children in the treatment group had previously undergone treatment with patching or atropine drops, but the treatment efficacy of Luminopia One was still significant in this subgroup. No serious adverse events were reported. (The pilot studies using this technology have also shown efficacy in older children and adolescents, for whom eye-patching and atropine eye drops are largely ineffective.)

"Until now, clinically available amblyopia treatments have involved blocking or blurring the stronger eye to make the brain pay more atten-

tion to the amblyopic, or 'lazy' eye," notes David G. Hunter, MD, PhD, ophthalmologist-in-chief at Boston Children's Hospital and professor and vice chair of ophthalmology at Harvard Medical School, and a scientific advisor to Luminopia.

"Unfortunately, neither of these approaches actively promotes the two eyes working together. Instead of blocking one eye to favor the other, Luminopia One lets the child watch movies that are modified so the amblyopic eye sees some parts of the image while the fellow eye sees the other parts. The brain has to put the pieces together to create complete images."

According to Dr. Hunter, Luminopia One has several helpful features, including:

- The Luminopia One device doesn't place colored filters over the eyes. This means that both the amblyopic eye and the fellow eye see the full spectrum of color.
- Luminopia One's headset-based approach creates a controlled environment free of distractions for the child.

- The virtual reality headset presents images at optical infinity, avoiding any issues related to accommodation (which can be limited in amblyopic eyes) or convergence.

"Most kids love to use Luminopia One, since their 'assignment' is to watch whatever movie they want to watch for an hour per day," Dr. Hunter notes. "In one case, a child brought the device to school for Show and Tell. This is in contrast to the social stigma and bullying that can hinder eye-patching compliance."

Dr. Hunter points out a few things of interest that emerged from the clinical trials. "Most of the patients in these trials had already maxed out on patching, yet improvement resumed once they started treating with Luminopia One," he says.

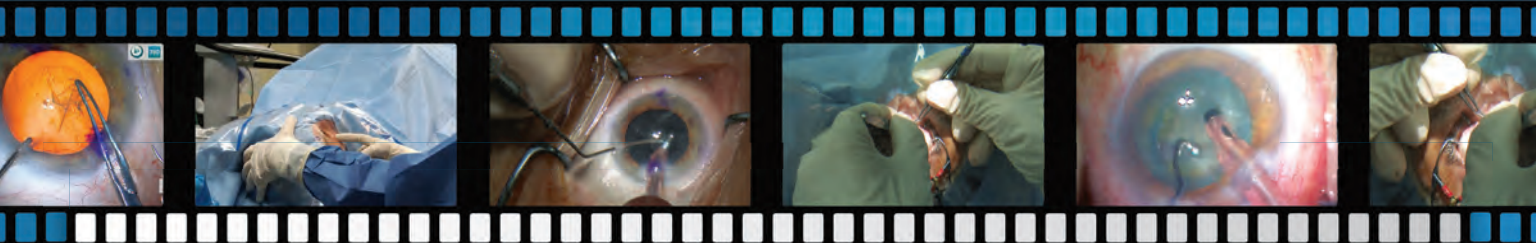
(Continued on p. 58)



Monthly

MACKOOL ONLINE CME

CME SERIES | SURGICAL VIDEOS



To view CME video
go to:

www.MackoolOnlineCME.com

Episode 80:

“Postoperative Negative Dysphotopsia (ND) and Glare/Halo After First-Eye Diffractive Multifocal IOL Implantation”

Surgical Video by:
Richard J. Mackool, MD

Video Overview:

The patient had cataract-implant surgery in her non-dominant eye 6 months earlier, and developed severe dysphotopsia. The decision has been made to proceed with cataract-implant surgery in the patient’s dominant eye, delaying the decision as to whether or not the dysphotopsia in the first eye remains bothersome and requires the exchange procedure.

MackoolOnlineCME.com MONTHLY Video Series



Richard J. Mackool, MD

I am happy to announce an exciting addition as we continue into our seventh year of Mackool Online CME. This year, with the generous support of several ophthalmic companies, my son Dr. RJ Mackool and I will share the honor of presenting our surgical cases to you. Together we will continue to demonstrate the technologies and techniques that we find to be most valuable to our patients, and that we hope are helpful to many of our colleagues.

I will continue to narrate all of the cases, even as we share the surgical duties and thereby expand the variety of the cases that we bring to you. As before, one new surgical video will be released monthly, allowing our colleagues the opportunity to earn CME credits or just observe the case. New viewers are able to obtain additional CME credit by reviewing previous videos that are located in our archives.

I thank the many surgeons who have told us that they have found our CME program to be valuable and instructive; I appreciate your comments, suggestions and questions. Thanks again for joining us on Mackool Online CME.



CME Accredited Surgical Training Videos Now Available Online: www.MackoolOnlineCME.com

Richard Mackool, MD, a world renowned anterior segment ophthalmic microsurgeon, has assembled a web-based video collection of surgical cases that encompass both routine and challenging cases, demonstrating both familiar and potentially unfamiliar surgical techniques using a variety of instrumentation and settings.

This educational activity aims to present a series of Dr. Mackool’s surgical videos, carefully selected to address the specific learning objectives of this activity, with the goal of making surgical training available as needed online for surgeons motivated to improve or expand their surgical repertoire.

Learning Objective

After completion of this educational activity, participants should be able to:

- utilize a surgical approach for the second eye following multiple dysphotopsia complaints after diffractive multifocal IOL implantation in the first eye.

Satisfactory Completion - Learners must pass a post-test and complete an evaluation form to receive a certificate of completion. You must listen to/view the entire video as partial credit is not available. If you are seeking continuing education credit for a specialty not listed below, it is your responsibility to contact your licensing/certification board to determine course eligibility for your licensing/certification requirement.



Accreditation Statement - In support of improving patient care, this activity has been planned and implemented by Amedco LLC and Review Education Group. Amedco LLC is jointly accredited by the Accreditation Council for Continuing Medical Education (ACCME), the Accreditation Council for Pharmacy Education (ACPE), and the American Nurses Credentialing Center (ANCC), to provide continuing education for the healthcare team.

JOINTLY ACCREDITED PROVIDER™
INTERPROFESSIONAL CONTINUING EDUCATION

Physicians (ACCME) Credit Designation - Amedco LLC designates this enduring material activity for a maximum of .25 AMA PRA Category 1 Credits™. Physicians should claim only the credit commensurate with the extent of their participation in the activity

Jointly provided by:




Supported by an unrestricted independent
medical educational grant from:



Additionally Supported by:



In Kind Support:



Video and Web Production by:
JR Snowden, Inc

AN ANTI-VEGF UPDATE FOR WET AMD

Retinal specialists discuss TREX, retreatment and their early experiences with the latest agents.

CHRISTINE LEONARD
SENIOR ASSOCIATE EDITOR

Ophthalmology's journey with anti-VEGF injections for neovascular age-related macular degeneration is an embodiment of the old saw, "The devil's in the details." At first blush, the anti-VEGF mainstays—bevacizumab, ranibizumab and aflibercept—are revolutionary, effective treatments for the disease. Once you start to implement them, however, you've got a raft of new issues to deal with: You have to maximize disease control, improve vision and maintain a stable macula by finding a treatment interval and drug with sufficient durability that also accounts for the real-world obstacles patients face coming to the clinic. Fortunately, there are several newly available nAMD treatment options that aim to contend with some of these hurdles: a bi-specific agent; a ranibizumab-eluting implant; and ophthalmology's first biosimilar.

Here, retina specialists share how they meet these treatment goals, describe how they overcome these obstacles to care, and detail some of

the newest anti-VEGF agents in the armamentarium.

Finding an Interval

"When I started my career, there weren't many great treatments available for nAMD," says Ian C. Han, MD, an associate professor at the Institute for Vision Research, Department of Ophthalmology and Visual Sciences at the University of Iowa Hospital and Clinics. "Now there are many different ways to preserve vision.

"I often tell patients that the best-case scenario is if they come in for their routine retinal exam and we find signs of early nAMD that the patient doesn't even notice," he continues. "It's a bit interesting trying to tell a patient they need to embark on treatment when they still may be 20/20 and have no symptoms, but the earlier you begin treatment, the better you're off downstream."

Treat and extend is currently the main protocol used for nAMD treatment. "We have more data now on the consequences of central subfield thickness fluctuation, so I think physicians are realizing they can have

better disease control and better outcomes with treat and extend instead of *pro re nata*," says Arshad M. Khanani, MD, of Sierra Eye Associates in Reno. "Fluctuations in CST lead to worse outcomes, so it's important to have a treatment protocol that keeps the retina dry and stable instead of allowing these fluctuations, as was the case with PRN."

"PRN was never a great idea," agrees David M. Brown, MD, of Retina Consultants of Texas. "I call it 'progressive retinal neglect.' It never made sense to wait for a hemorrhage to recur before treating. However, treat and extend is a misnomer of sorts. We all do fixed dosing at some interval; treat and extend is just a way of figuring out what an individual patient's fixed interval will be.

"Typically, we give two or three loading doses, and if the patient doesn't have any active disease—i.e., no fluid or hemorrhage on OCT—then we extend it a few weeks. Say at six weeks, if they're dry, we might give the patient another shot and try eight weeks. Eventually you extend until you get fluid and then back off to the interval at which they stay dry.

This article has no commercial sponsorship.

Dr. Brown is a consultant for Samsung, Regeneron, Genentech and Novartis. Dr. Khanani is a consultant for Regeneron, Genentech and Novartis. Drs. Haddock, Han and Chhablani have no relevant financial disclosures.

TABLE 1. BIOSIMILAR CANDIDATES FOR LUCENTIS (RANIBIZUMAB)

Drug	Company	Indication	Status
FYB201	Formycon-Bioeq-Coherus	nAMD	FDA decision anticipated Q3 2022
Xlucane	Xbrane Biopharm-Bausch and Lomb	nAMD, DME	FDA decision anticipated Q3-Q4 2022
LUBT010	Lupin	nAMD	Phase III

This approach gets us to a personalized fixed dosing interval as quickly as possible.”

This is the main benefit of treat and extend, according to experts. Rather than lumping all patients into one basket with PRN or monthly injections, this protocol tailors the treatment to optimize disease control. Additionally, “We know that many patients don’t like to come to the clinic every month, or they aren’t able to for a variety of reasons, and this leads to poor disease control and vision loss,” says Dr. Khanani. “Patients need to be compliant with whatever treatment protocol they’re using, but with fewer injections, we have better overall compliance because of the decreased treatment burden.”

Some evidence has suggested that more frequent dosing may yield slightly better visual outcomes, but a Cochrane review found the difference to be clinically negligible.¹ The review found that patients receiving monthly injections had slightly better vision at one year compared with those receiving as-needed (average: seven) or modified as-needed/treat-and-extend injections (average: nine). Endophthalmitis was thought to be more common with monthly injections.

Agent Selection

Which anti-VEGF agent is best suited for which patient? There’s no clear answer, experts say, as aflibercept, ranibizumab and bevacizumab are all effective at slowing disease progression. “It’s a tough decision and there’s no perfect answer,” says Luis J. Haddock, MD, an assistant professor of ophthalmology at the University of Miami, Bascom Palmer Eye Institute. “Maybe in the future, we’ll be able to predict whether a

certain patient will respond best to a specific drug based on OCT findings. Prior studies have shown that all of the anti-VEGF agents are effective in treating the disease, some perhaps more so than others. It comes down to clinical findings, pathology and how often the patient can come back to the clinic. If a patient comes to me already on a certain medication and they’re doing well, I may not switch them. With new patients, I often try bevacizumab first and monitor the effect. Most patients respond well.”

“I and most of my partners at the University of Iowa generally start with bevacizumab,” says Dr. Han. “Though it’s off-label, it has a long track record, is the least expensive, has a good safety profile and works well for the majority of patients. Most anti-VEGF treatments will work well for most people. Other practices may decide to start with a different medication, but the upshot is that most work well regardless of what you pay.”

“Choice of agent sometimes depends on a patient’s insurance and socio-economic status,” Dr. Brown points out. “Most insurance companies now have a few step edits, where they want us to start with bevacizumab, which is our weakest agent. It’s made by compounding pharmacies, so it doesn’t have the same consistency as the branded agents, but if a patient is doing well on bevacizumab, we often stay with it.”

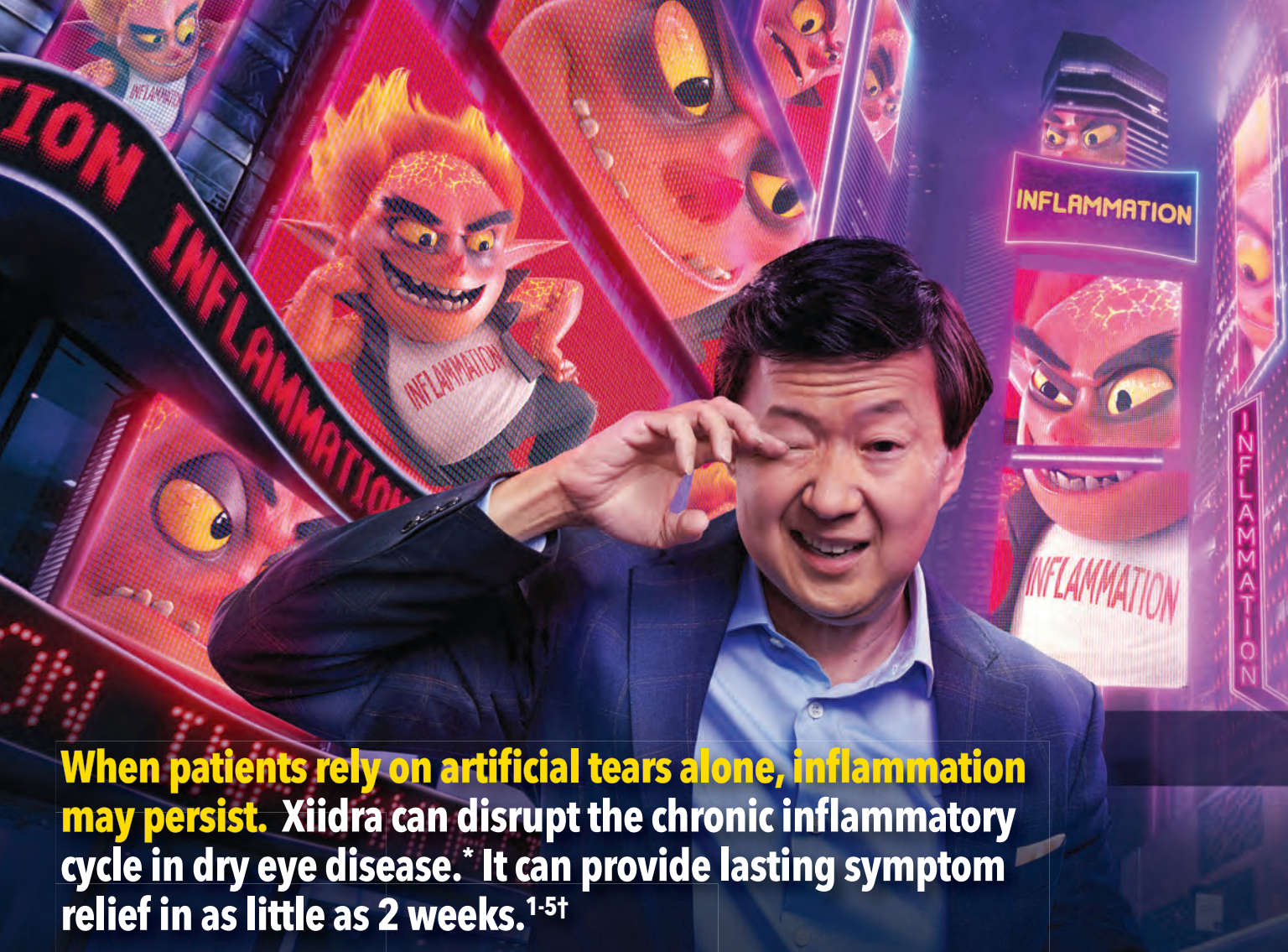If coverage isn’t an issue, Dr. Khanani says he starts patients on faricimab because it has good efficacy and durability. He also points out that patient education is important when discussing AMD treatment. “We make sure they understand that nAMD is a lifetime disease with no cure, though we have a treatment,” he says. “Then we review the cur-

rently available agents and what’s approved by their insurance. We make sure they understand that no agent will obviate the need for injections. It’s more along the lines of which agent will maximize treatment intervals. In that case, the patients need to understand that they can’t miss their visits—they really need to come for every injection, otherwise they could end up with vision loss. Patients are a big part of decision-making, and together we decide how they want to proceed. But of course, as the physician, it’s my goal to give my patients a durable agent so we can decrease their treatment burden.”

As you know, brolocizumab is no longer considered a first-line treatment for nAMD due to the intraocular inflammation events seen in some patients. Dr. Han says brolocizumab has been an instructive medication for the field. “Brolocizumab and faricimab are the newest drugs since aflibercept, which still seems new but was actually FDA-approved more than a decade ago in 2011,” he says. “This highlights the advantages of innovation—we can potentially have a drug that works better for some patients, especially those who have had a limited response to other available drugs on the market. Many drugs coming down the pipeline are also targeting other molecules and pathways associated with blood vessel growth to have greater effect or durability of effect.

“That said, I’m very hesitant to use brolocizumab and have only used it rarely,” he continues. “The possibility of severe inflammation resulting in vision loss and retinal vasculitis isn’t a trivial one to consider. Unfortunately, drugs can make it to market even after rigorous clinical trials and still have safety signals turn up after approval. You always have to be a bit cautious whenever a new drug comes out because the real world is different from a clinical trial.

“There are some patients who may have had frequent injections and tried every available drug and can be



When patients rely on artificial tears alone, inflammation may persist. Xiidra can disrupt the chronic inflammatory cycle in dry eye disease.* It can provide lasting symptom relief in as little as 2 weeks.^{1-5†}

*Xiidra blocks LFA-1 on T cells from binding with ICAM-1 that may be overexpressed on the ocular surface in dry eye disease and may prevent formation of an immunologic synapse which, based on in vitro studies, may inhibit T-cell activation, migration of activated T cells to the ocular surface, and reduce cytokine release. The exact mechanism of action of Xiidra in DED is not known.^{1,2,5}

†The safety and efficacy of Xiidra were assessed in four 12-week, randomized, multicenter, double-masked, vehicle controlled studies (N=2133). Patients were dosed twice daily. The mean age was 59 years (range, 19-97 years). The majority of patients were female (76%). Use of artificial tears was not allowed during the studies. The study end points included assessment of signs (based on Inferior fluorescein Corneal Staining Score [ICSS] on a scale of 0 to 4) and symptoms (based on patient-reported EDS on a visual analogue scale of 0 to 100). Effects on symptoms of dry eye disease: a larger reduction in EDS favoring Xiidra was observed in all studies at day 42 and day 84. Xiidra reduced symptoms of eye dryness at 2 weeks (based on EDS) compared to vehicle in 2 out of 4 clinical trials. Effects on signs of dry eye disease: at day 84, a larger reduction in ICSS favoring Xiidra was observed in 3 out of the 4 studies.¹

Indication

Xiidra® (lifitegrast ophthalmic solution) 5% is indicated for the treatment of signs and symptoms of dry eye disease (DED).

Important Safety Information

- Xiidra is contraindicated in patients with known hypersensitivity to lifitegrast or to any of the other ingredients.



Novartis Pharmaceuticals Corporation
East Hanover, New Jersey 07936-1080



KEN JEONG,
REAL DRY EYE PATIENT.

Important Safety Information (cont)

- In clinical trials, the most common adverse reactions reported in 5-25% of patients were instillation site irritation, dysgeusia and reduced visual acuity. Other adverse reactions reported in 1% to 5% of the patients were blurred vision, conjunctival hyperemia, eye irritation, headache, increased lacrimation, eye discharge, eye discomfort, eye pruritus and sinusitis.
- To avoid the potential for eye injury or contamination of the solution, patients should not touch the tip of the single-use container to their eye or to any surface.
- Contact lenses should be removed prior to the administration of Xiidra and may be reinserted 15 minutes following administration.
- Safety and efficacy in pediatric patients below the age of 17 years have not been established.

For additional safety information about XIIDRA[®], please refer to the brief summary of Full Prescribing Information on adjacent page.

References: **1.** Xiidra [package insert]. East Hanover, NJ: Novartis Pharmaceuticals Corp; June 2020. **2.** Bron AJ, de Paiva CS, Chauhan SK, et al. TFOS DEWS II Pathophysiology Report. *Ocul Surf.* 2017;15(3):438-510. **3.** US Food and Drug Administration. Code of Federal Regulations, Title 21, Volume 5 (21CFR349). Accessed May 25, 2021. <https://www.accessdata.fda.gov/scripts/cdrh/cfdocs/cfcfr/CFRSearch.cfm?CFRPart=349&showFR=1> **4.** Jones L, Downie LE, Korb D, et al. TFOS DEWS II Management and Therapy Report. *Ocul Surf.* 2017;15(3):575-628. **5.** Pflugfelder SC, Stern M, Zhang S, Shojaei A. LFA-1/ICAM-1 interaction as a therapeutic target in dry eye disease. *J Ocul Pharmacol Ther.* 2017;33(1):5-12.

XIIDRA, the XIIDRA logo and ii are registered trademarks of Novartis AG.

Xiidra® (lifitegrast ophthalmic solution), for topical ophthalmic use

Initial U.S. Approval: 2016

BRIEF SUMMARY: Please see package insert for full prescribing information.

1 INDICATIONS AND USAGE

Xiidra® (lifitegrast ophthalmic solution) 5% is indicated for the treatment of the signs and symptoms of dry eye disease (DED).

4 CONTRAINDICATIONS

Xiidra is contraindicated in patients with known hypersensitivity to lifitegrast or to any of the other ingredients in the formulation [see *Adverse Reactions (6.2)*].

6 ADVERSE REACTIONS

The following serious adverse reactions are described elsewhere in the labeling:

- Hypersensitivity [see *Contraindications (4)*]

6.1 Clinical Trials Experience

Because clinical trials are conducted under widely varying conditions, adverse reaction rates observed in clinical trials of a drug cannot be directly compared to rates in the clinical trials of another drug and may not reflect the rates observed in practice.

In five clinical trials of DED conducted with lifitegrast ophthalmic solution, 1401 patients received at least one dose of lifitegrast (1287 of which received lifitegrast 5%). The majority of patients (84%) had less than or equal to 3 months of treatment exposure. One hundred-seventy patients were exposed to lifitegrast for approximately 12 months. The majority of the treated patients were female (77%). The most common adverse reactions reported in 5%-25% of patients were instillation-site irritation, dysgeusia, and reduced visual acuity.

Other adverse reactions reported in 1%-5% of the patients were blurred vision, conjunctival hyperemia, eye irritation, headache, increased lacrimation, eye discharge, eye discomfort, eye pruritus, and sinusitis.

6.2 Postmarketing Experience

The following adverse reactions have been identified during post-approval use of Xiidra. Because these reactions are reported voluntarily from a population of uncertain size, it is not always possible to reliably estimate their frequency or establish a causal relationship to drug exposure.

Rare serious cases of hypersensitivity, including anaphylactic reaction, bronchospasm, respiratory distress, pharyngeal edema, swollen tongue, urticaria, allergic conjunctivitis, dyspnea, angioedema, and allergic dermatitis have been reported. Eye swelling and rash have also been reported [see *Contraindications (4)*].

8 USE IN SPECIFIC POPULATIONS

8.1 Pregnancy

Risk Summary

There are no available data on Xiidra use in pregnant women to inform any drug-associated risks. Intravenous (IV) administration of lifitegrast to pregnant rats, from pre-mating through gestation day 17, did not produce

teratogenicity at clinically relevant systemic exposures. Intravenous administration of lifitegrast to pregnant rabbits during organogenesis produced an increased incidence of omphalocele at the lowest dose tested, 3 mg/kg/day (400-fold the human plasma exposure at the recommended human ophthalmic dose [RHOD], based on the area under the curve [AUC] level). Since human systemic exposure to lifitegrast following ocular administration of Xiidra at the RHOD is low, the applicability of animal findings to the risk of Xiidra use in humans during pregnancy is unclear [see *Clinical Pharmacology (12.3) in the full prescribing information*].

Data

Animal Data

Lifitegrast administered daily by IV injection to rats, from pre-mating through gestation day 17, caused an increase in mean pre-implantation loss and an increased incidence of several minor skeletal anomalies at 30 mg/kg/day, representing 5,400-fold the human plasma exposure at the RHOD of Xiidra, based on AUC. No teratogenicity was observed in the rat at 10 mg/kg/day (460-fold the human plasma exposure at the RHOD, based on AUC). In the rabbit, an increased incidence of omphalocele was observed at the lowest dose tested, 3 mg/kg/day (400-fold the human plasma exposure at the RHOD, based on AUC), when administered by IV injection daily from gestation days 7 through 19. A fetal no observed adverse effect level (NOAEL) was not identified in the rabbit.

8.2 Lactation

Risk Summary

There are no data on the presence of lifitegrast in human milk, the effects on the breastfed infant, or the effects on milk production. However, systemic exposure to lifitegrast from ocular administration is low [see *Clinical Pharmacology (12.3) in the full prescribing information*]. The developmental and health benefits of breastfeeding should be considered, along with the mother's clinical need for Xiidra and any potential adverse effects on the breastfed child from Xiidra.

8.4 Pediatric Use

Safety and efficacy in pediatric patients below the age of 17 years have not been established.

8.5 Geriatric Use

No overall differences in safety or effectiveness have been observed between elderly and younger adult patients.

Distributed by:
Novartis Pharmaceuticals Corporation
One Health Plaza
East Hanover, NJ 07936
T2020-87

switched over to brolocizumab with a more efficacious response in terms of visual acuity or exudation,” he says. “Brolocizumab is a powerful drug, and it came to market because it had an advantage over the standard of care. Still, the risk-benefit ratio is difficult to take, especially compared to the long safety track record of the existing drugs and the severity of the complications.”

Dr. Haddock says he unfortunately experienced some of the inflammation and vasculitis-related adverse events described in the literature. “I didn’t feel comfortable continuing to use that medication when we have other agents that perhaps have a similar overall efficacy and haven’t been shown to have those effects,” he says. “In general, the medication has shown efficacy and potency and works in the disease—I had patients in whom it worked very well—but with those concerns in mind, my personal preference is to not use it.”

Dr. Khanani considers brolocizumab a fourth-line agent for patients who have persistent disease with vision loss. “Patients who are on aflibercept with poor response will now likely switch to faricimab, and if they still don’t respond, then brolocizumab would be a fourth-line option,” he says.

If your patient is receiving brolocizumab injections, experts say continuous monitoring is crucial, though the warning signs would be similar to any other anti-VEGF agent (e.g., signs of post-injection inflammation, photophobia, decreased vision). “Brolocizumab is really powerful in terms of disease control, so if the patient is willing to take the risk, we monitor them closely and instruct them to call us right away if any new symptoms occur,” Dr. Khanani says. “Every time they come to the clinic, we perform a dilated eye exam and look for signs of

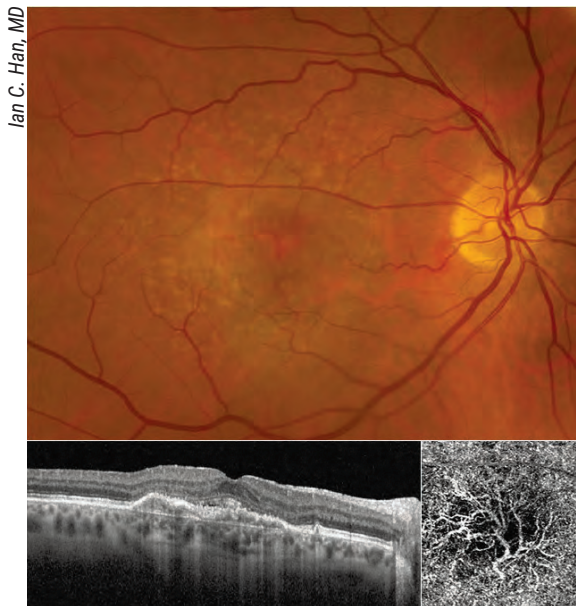

Figure 1. An otherwise healthy woman in her 60s first noted blurry vision and distortion in her right eye more than a year ago and was diagnosed with nAMD.

The fundus photo shows numerous drusen characteristic of AMD absent of any subretinal blood. (The CNV is not obvious in the photo.) OCT line scan (bottom left) shows elevation of the retinal pigment epithelium and thin overlying subretinal fluid, consistent with a subfoveal (“type 1”) CNV. OCT angiography (3 x 3-mm fovea-centered “ORCC” outer retinal to choriocapillaris slab) shows a prominent CNV with mature-appearing vasculature and surrounding choriocapillaris loss. This patient has maintained excellent (20/25) vision with anti-VEGF therapy on a treat-and-extend regimen.

inflammation. If they have any signs of inflammation, I stop using brolocizumab there. That’s what prevents a bad episode down the road.”

He says the results of a real-world safety-outcomes study published in *JAMA Ophthalmology* that he was a part of found that the main risk factors with brolocizumab were a history of retinal artery occlusion and a history of inflammation.² The cohort study included nAMD patients in the IRIS Registry and Komodo Healthcare Map databases; it reported an intraocular inflammation and/or retinal vascular occlusion incidence rate of 2.4 percent.

Patients who had IOI and/or RO in the 12 months before receiving their first brolocizumab injection had the highest observed risk rate for IOI and/or RO in the early months after their

first injection. “We would exclude these patients,” Dr. Khanani says. “There’s also some data suggesting that inflammation is more common in females.” The estimated incidence rate in women compared with men was 2.9 and 3 percent vs. 1.3 and 1.4 percent in the IRIS and Komodo groups, respectively. (The study authors pointed out that the identified risk factors can’t be used as predictors of IOI and/or RO events and their causality with brolocizumab can’t be assessed using this study.)

Imaging for Retreatment

When deciding when to retreat an nAMD patient, retina specialists rely on optical coherence tomography as their primary imaging modality. In addition to OCT findings such as subretinal fluid, subretinal hyperreflective material, atrophic changes and choroidal findings, vision changes and disease resistance factor into the treatment decision.

“When deciding when to retreat, I typically look at subretinal and intraretinal fluid and the size of the retinal pigment epithelium and try to take everything into consideration,” says Dr. Haddock. “I also use OCTA to better visualize the size of the choroidal neovascularization and where it’s located to determine which patients can tolerate a little more fluid.”

Dr. Haddock also considers the patient history and whether they’ve previously undergone a treat-and-extend regimen. “It’s important to know their parameters and what they can tolerate,” he explains. “Patients with a small area of subretinal fluid, even if it’s central, may have stable vision and no new bleeding, and they may be okay to remain at a certain interval rather than shortening it. I would tolerate a little bit of subretinal fluid rather than intraretinal fluid because there’s enough evidence to suggest to that intraretinal fluid may predict worse overall outcomes.”

TABLE 2. BIOSIMILAR CANDIDATES FOR EYLEA (AFLIBERCEPT)

Drug	Company	Indication	Status
MYL-1701P	Viatriis (Mylan-Momenta)	DME	FDA decision anticipated Q3-Q4 2022
CHS-201	Coherus Biosciences	nAMD	BLA submission
FYB203	Formycon-Bioeq	nAMD	Phase III
SB15	Samsung Bioepis-Biogen	nAMD	Phase III
SOK583A1	Sandoz	nAMD	Phase III
ABP 938	Amgen	nAMD	Phase III
ALT-L9	Alteogen	nAMD	Phase I

“I’ll often couple OCT with OCTA to follow the abnormal vascular complex when deciding when to retreat,” Dr. Han says. “Our goal is to resolve any pathologic changes we see, such as intraretinal and subretinal fluid. We treat until the fluid goes away or stabilizes.”

While OCTA isn’t the standard of care for monitoring nAMD, it’s a valuable technology complementary to the existing imaging modalities, proponents say. Dr. Han says he likes to be able to correlate structural and vascular features in a three-dimensional fashion through OCTA. In fact, his current research focuses on multimodal imaging for studying the physiologic mechanisms of retinal disease, including abnormal blood vessel changes, which he says aren’t always so straightforward.

“There are some gray zones concerning these blood vessels,” Dr. Han explains. “There’s evidence that even persistent subretinal fluid might not be a bad thing. Patients with persistent subretinal fluid might actually have very little choroidal vasculature under the fovea where it counts most for central vision, and the choroidal neovascular net that we deem pathologic may actually be a secondary response to tissue thinning or vascular loss (Figure 1). We might not want complete regression of the choroidal neovascularization since it may be supplying nutrients to the fovea. The persistence of that fluid may be representative of the fluid clearance or transition as opposed to actual activity of the blood vessels. Many of these patients can maintain very good

vision, even with some fluid on OCT. Ultimately, treatment depends on a lot of different factors for individual patients.”

OCT should be performed at every visit, or monthly, until the fluid has dried, says Jay Chhablani, MD, an associate professor of ophthalmology at the University of Pittsburgh Eye Center. “Many physicians don’t do an OCT during the loading doses or the first three months, but I like to get an OCT every visit just to better understand the response. Looking at the initial response helps you when you go back to look at later changes. So, I would say get an OCT every month until you decide they’re dry and extend it to two or three months follow-up.”

To Switch or Not to Switch?

If your patient seems to be a non-responder, first rule out any other disease that may have been missed in the beginning of the treatment, says Dr. Chhablani. “To rule out a retinal pigment epithelial rip, we use fundus autofluorescence,” he says. “This modality won’t help you every time you need to redefine the treatment interval, but it can help you differentiate nAMD from other causes of neovascularization.

“We don’t ask for fluorescein angiography much since it’s an invasive test,” he continues, “but if I suspect my patient isn’t responding well due to a polypoidal choroidal vasculopathy, I’ll definitely ask for an indocyanine green angiography along with fluorescein angiography, and review all of the patient’s pictures to see if

there’s any other associated disease. If the patient has PCV, I’d offer a combination treatment of photodynamic therapy along with anti-VEGF.

“Not many U.S. physicians get ICGA done since they feel PCV isn’t very common here, but patients do get it,” he adds. “ICGA is something we want to push forward in the next generation of residents and fellows so we can better understand the prevalence of PCV in a white population.”

If your nAMD patient has persistent fluid despite monthly therapy or cannot be extended from a monthly regimen (i.e., if fluid recurs after extending), it’s time to proceed up the pathway to a stronger agent, says Dr. Brown. “Most of our agents all work by blocking VEGF,” he says. “Aflibercept has more anti-VEGF blockade than ranibizumab, which has more anti-VEGF blockade than bevacizumab. Faricimab, which was recently approved, has even more anti-VEGF blockade and also blocks Ang2, which may be particularly important in vascular diseases such as diabetes and retinal vein occlusion.”

Additional switching considerations may include where in the retina the patient’s disease first presented, the amount of fibrosis, fluid and disease activity, and the patient’s response to the prior medication, adds Dr. Haddock. “If I see a patient having a slow response, I may give them more time,” he says. “If they have no response, I’m more likely to switch agents. Typically, after three injections, I have a good idea of who’s a responder, who’s responding at the rate I anticipated and who has potential of responding with another medication. After three or four injections, I’d make the decision taking those factors into consideration.”

“If your patient can’t afford to switch to a different agent or doesn’t have access to the newer medications, then a double dose of aflibercept works well, or more frequent anti-VEGF,” says Dr. Chhablani. “You can also combine bi-weekly injections, e.g., aflibercept and alternate with

bevacizumab every 14 days.”

Some recent studies using simulated switch protocols have suggested that switching agents may not necessarily give patients better outcomes. Dr. Chhablani points out, however, that there are a lot of factors we’re still unable to evaluate in studies, and simulation studies can’t match those. The sub-analyses in question are those of the HARBOR trial,³ CATT and DRCR.net trials⁴ and the ARIES trial.⁵ These studies noted that without a true randomized control group continuing the original treatment, it’s not possible to know whether any improvement is due to the new treatment or not. They identified trial patients who would otherwise be considered for switching drugs in the first several months of treatment and followed them as they continued their original treatment. All three trials, which had company sponsorship, reported visual gains and some improvement in retinal thickness.

“What kind of imaging findings were being treated? How did the patients respond to treatment? These are very important questions,” Dr. Chhablani says. “I have seen in dermatology literature that if a patient becomes resistant to or a non-responder to a certain drug, they give the patient a holiday period and then reintroduce the same drug and the patient responds again. So, some of these things may still be possible, but I’d say that when treating your individual patients, you should certainly consider switching drugs.”

Powerful Newcomers

It’s an exciting time to be in retina with several new treatments available and in the pipeline, retina specialists say. Here are the three most recent arrivals to the retinal disease armamentarium:

• **Vabysmo.** Faricimab-svoa (Vabysmo, Genentech) is a bi-specific antibody that was approved for nAMD and DME treatment in May. It binds both VEGF-A and angiopoietin2. Faricimab is given in four loading doses

followed by maintenance dosing every two, three or four months for nAMD. In the Phase III trials, intraocular inflammation rates were consistent with aflibercept-treated eyes.

“Based on TENAYA and LUCERNE, we found that a subset of patients can last 16 weeks on faricimab, and eight out of 10 patients can last 12 weeks or longer,” says Dr. Khanani, who was one of the clinical investigators. “There are patients who may need more frequent treatment, and they’ll be able to receive faricimab frequently to control their disease.

“Though there are great agents available, we have an unmet need for durability,” Dr. Khanani continues. “Patients don’t gain vision the way they should in the real world because of the treatment burdens, so having a dual mechanism of action that goes after a well-established target and another pathway is exciting. We’re not increasing the burden of injection and we’re maximizing treatment durability this way.”

Dr. Khanani is also part of the AVONELLE-X extension study, which is assessing the outcomes with faricimab for all patients, in particular those switching from aflibercept. “We’re looking for any safety signals that patients are responding better versus which characteristics indicate a patient may need more treatment,” he says. “We’re learning a lot about the drug.”

Dr. Khanani presented faricimab’s two-year data at the ASRS Meeting this year. The data show that almost 80 percent of patients receiving faricimab were able to be treated every three months or longer; and more than 60 percent of patients were able to be treated at four-month intervals, which represented a more than 15-percent increase since the primary one-year analysis. These patients also had vision gains comparable to patients receiving aflibercept every two months. Faricimab patients received an average of 10 injections over two years and aflibercept patients received an average of 15 injections over the

same time period. The study found no new safety signals.

Dr. Haddock began using faricimab a few months ago and says the early results have been encouraging (*Figure 2*). “I’m still in the stage of seeing how my patients are responding and figuring out what role faricimab will play in their overall management, but there have been good responses so far,” he says. “I haven’t seen any episodes or events that aren’t typical of other anti-VEGF agents.”

“I think it’ll be interesting to see how other physicians use faricimab,” says Dr. Han. “The Phase III trials were encouraging. I’d say I’m a cautious adopter of new treatments. The trial was set up as a non-inferiority comparison to aflibercept, but this was based on a particular protocol in a particular patient composition, so how that plays out in the real world remains to be seen. We haven’t used it yet here at the University of Iowa, but we’re in the process of getting a hospital formulary and insurance coverage for it.”

Dr. Han says he’s excited the field has begun exploring pathways beyond VEGF. “A bi-specific drug is cool to describe, but it also acknowledges that vascular growth, development and stabilization are dynamic and complex processes,” he says. “Angiogenesis, which involves not only new blood vessel growth but also blood vessel remodeling and stabilization is important for life because blood goes everywhere. Life is about balance—growing new blood vessels and then stabilizing them. The challenge presented by neovascularization isn’t necessarily that blood vessels are growing in response to something, which is the body’s typical response to lack of blood flow or injury. That in and of itself isn’t bad, but these blood vessels can grow in the wrong position or be poorly constructed at first, and that’s really a secondary complication or consequence of neovascularization, if you will. Other pathways contribute to this growth, development and stabilization that aren’t currently being

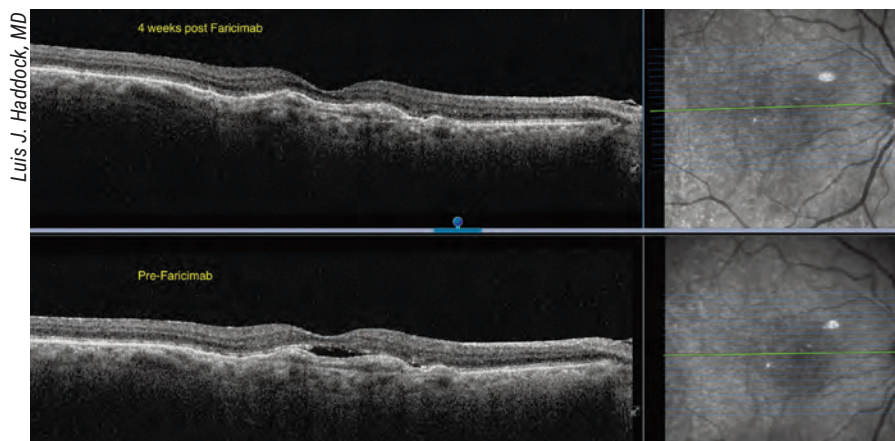


Figure 2. A 74-year-old female on chronic anti-VEGF treatment for nAMD of the right eye without fluid resolution. OCTA shows a subfoveal choroidal neovascular membrane. Fluid resolution and improvement on OCT were noted four weeks after injection of faricimab. VA improved from 20/100 to 20/80.

addressed with anti-VEGF therapy, which is essentially monotherapy for one molecule. To target more than one molecule to return the body to balance is exciting.”

• **Susvimo.** Formerly known as the Port Delivery System with ranibizumab, Susvimo (Genentech) provides continuous delivery of the drug. It’s indicated for patients who’ve previously responded to at least two intravitreal injections of an anti-VEGF agent. “We’re always looking for new ways to deliver drugs, including existing drugs like ranibizumab, and to increase their durability and effect,” says Dr. Han. “Social determinants of health, unfortunately, impact patients’ treatment. While they aren’t medical, they still must factor into medical decision-making. A longer delivery system is an important innovation for nAMD.”

Dr. Khanani’s practice was the first to implant the device in a hospital setting. “The implant is a surgical device that helps to control disease and decrease the treatment burden to every six months,” he explains. “Because it’s a surgery, there are risks associated with it, so the first thing we need to do is ensure the surgery is done properly so we don’t end up with complications, and patients need to be monitored. Any adverse events must be treated aggressively and quickly. It’s not a first-line treatment option, but it is a good option for a subset of

patients who really don’t like injections or need frequent injections.”

When monitoring patients who have a ranibizumab implant, it’s important to watch them closely in the postop period and ensure the surgical site heals well so there’s no conjunctival retraction or erosion, experts say. Once the site has healed, follow-ups can be extended, but Dr. Khanani emphasizes the importance of educating patients about reporting any issues promptly.

“If a patient has a conjunctival issue and calls us right away, we can repair it, but if they don’t come in right away, they could end up with a complication such as endophthalmitis,” he says. “We monitor them one day, one week and one month after. Once they hit six months and their disease is well controlled and they don’t need any supplemental injections, it’s reasonable to follow those patients every six months just for a refill or exchange procedure.”

At Dr. Han’s midwestern practice, many of his patients drive a good distance to come to the clinic. “We have some limitations with travel distance for many patients who need injections, so many are in favor of an option that lasts longer,” he notes. “But many are perfectly happy to stick with a treatment they know and trust rather than try something new.”

“I’ve discussed the implant with

some of my patients and they seem to have more fear of surgery than injections,” says Dr. Haddock. “I think a lot will depend on the physicians—how comfortable we feel with the procedure and how strongly encouraged we are by the results in order to present it to our patients as an option. I don’t think this will be my primary choice for most people, but those who have difficulty coming in for injections are probably the ideal candidates right now. There’s the possibility of a slight increase in infection rates over the lifetime of the implant compared with injections. I’m still seeing where it fits into my armamentarium.”

Dr. Haddock hasn’t used the ranibizumab implant yet, but he’s in the process of getting trained. “Genentech has online modules and also provides in-house training,” he says. “So far, it’s a very nice setup. I think they knew from the beginning that in order to introduce a surgical procedure they really needed to spend time creating good training. There are good surgical training modules and people to teach us the techniques.”

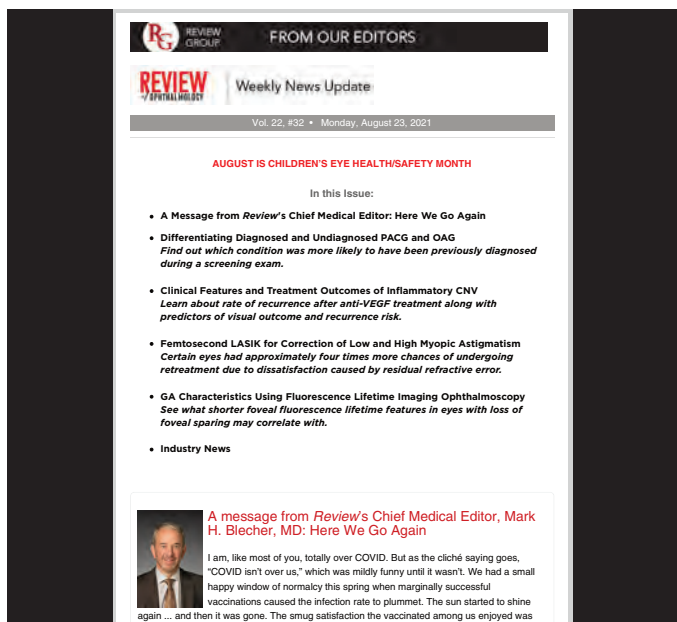Dr. Brown notes that the implant’s warning label, saying that up to 2 percent of patients get endophthalmitis, or one out of 50, has limited its market access. “Additionally, its current drug eluting levels often don’t cover those who need the most frequent injections,” he says. “In other words, the patients who really want to have this implant are the ones who have to have an injection every month, but this probably doesn’t provide enough anti-VEGF blockade to accommodate those patients.”

Dr. Brown implanted about 35 of the devices in the clinical trial. “The patients who need only one refill every six months are very happy,” he says. “They absolutely love it. And again, the ones who aren’t happy are those who were getting an injection every month and then, after undergoing a surgery for the implant, find the implant still isn’t enough and they have to continue getting injections.”

• **Byooviz.** Biosimilars are biologi-



Read the Latest from our Editors



If you aren't already a subscriber, please be sure to sign up for our recurring e-journal, *Review of Ophthalmology Weekly News Update*.

Join the thousands of MDs and ophthalmic industry readers who turn to us each week to see a curated digest of the latest, most relevant clinical studies and industry news. You'll also receive monthly hot-takes from *Review's* Chief Medical Editor, Mark Blecher, MD.

Visit: **JMI | Newsletter Signup**
www.jhihealth.com/globalemail/

to sign up for *Review of Ophthalmology Weekly News Update*, and other e-newsletters distributed by Jobson Medical Information.

REVIEW OF OPHTHALMOLOGY WEEKLY NEWS UPDATE:

Reaches 9,000 MDs weekly

Content: Clinical information & Industry news

Metrics: 21.5% average opens

FOR ADVERTISING OPPORTUNITIES, PLEASE CONTACT

Michael Hoster: Mhoster@jobson.com
610-492-1028

Michele Barrett: Mbarrett@jobson.com
215-519-1414

Jon Dardine: Jdardine@jobson.com
610-492-1030

HOW MUCH DOES SUSVIMO COST COMPARED WITH RANIBIZUMAB INJECTIONS?

A cost-analysis study published in *JAMA Ophthalmology* in June reported that Susvimo with one refill cost more than intravitreal ranibizumab or aflibercept injections if the patient needed less than or equal to approximately 11 or 10 injections, respectively, within the first year.⁸ If fewer than 4.4 and 3.8 injections are needed per refill, then intravitreal ranibizumab or aflibercept costs less.

The cost analysis was based on a model using trial data and Medicare reimbursement rates. The break-even point with Susvimo with one refill was 10.8 ±1.3 ranibizumab injections, 9.3 ±1.1 aflibercept injections or 34.5 ±4.2 bevacizumab injections. In the study, the initial implant insertion was estimated to cost \$12,239, with a refill costing \$8,240. A ranibizumab 0.5 mg injection was estimated to cost \$1,742.

The cost analysis was based on a model using trial data and Medicare reimbursement rates. The break-even point with Susvimo with one refill was 10.8 ±1.3 ranibizumab injections, 9.3 ±1.1 aflibercept injections or 34.5 ±4.2 bevacizumab injections. In the study, the initial implant insertion was estimated to cost \$12,239, with a refill costing \$8,240. A ranibizumab 0.5 mg injection was estimated to cost \$1,742.

cal products that are highly similar to a reference product and have no clinically meaningful differences in terms of safety, purity and potency.⁶ In the United States, biosimilar uptake remains slow. Though there are 35 approved biosimilars to 11 reference drugs, only 21 of these are on the market.⁷ It's estimated that biosimilars could save more than \$133 billion by 2024 if uptake increases. Experts say that biosimilars will create cost-savings by launching at a discounted price, which will in turn cause the reference biologic product's price to go down in response to competition (see Table 1).

Byooviz (ranibizumab-nuna, Samsung Bioepis/Biogen) is the first biosimilar in ophthalmology, referencing Lucentis. The drug launched on July 1 in the United States after receiving FDA approval last year. It's priced at \$1,130 for a single-use 0.5-mg vial, or 40 percent lower than Lucentis.

Not all retina specialists are eager to adopt a biosimilar, however. "Biosimilars have a minimal role in my practice," says Dr. Khanani, citing established anti-VEGF agents with long safety records. "Unless the payers [mandate step therapy] through biosimilars, I don't see myself using biosimilars in my practice at this point."

"It'll be interesting to see how effective biosimilars really are, and how others will be priced and marketed in the future," says Dr. Haddock. "I haven't had any experience with biosimilars so far. The excitement is perhaps about the reduced price, but we have reservations about manufacturing changes, as even a slight one could have serious effects. We've seen this happen with other molecules where changing a little bit can have serious effects in the eye. I'm not overly excited about it."

Dr. Brown, who worked with Samsung Bioepis on the biosimilar trials, says he's not concerned about the manufacturing because "Samsung has a robust biosimilar program and factory in Korea." The company's portfolio currently contains five biosimilars in addition to ranibizumab, including those for etanercept, infliximab, adalimumab, trastuzumab and bevacizumab.

Dr. Brown says Byooviz and future biosimilars will put more pressure on insurance companies to manage costs. Despite that, he points out, "We don't know how much of an effect [on the market] it's going to have because it's a biosimilar of Lucentis, which has been out now for 15 years and has been supplanted, especially in DME, by Eylea. So there aren't as many patients on Lucentis to switch over to Byooviz. Insurance companies could add a step edit, which would push more doctors to get comfortable with the biosimilar, but how excited are insurance companies going to be about putting a separate step edit between Avastin and Eylea or Vabysmo or even Lucentis? There's certainly more cost-savings with \$75 Avastin than \$1,130 Byooviz.

"I think what will really make a difference in the biosimilar market is an aflibercept biosimilar to compete with Eylea, which is the current market leader," he continues (see Table 2). "I think there will be a cautious entry into the biosimilar market, but I'm hopeful we won't see troubles like with brolocizumab, and we'll certainly be diligent as we would be with any new agent."

"One concern is that Lucentis is currently marketed in two doses, 0.5 mg for AMD and 0.3 mg for DME, but Byooviz is only approved for AMD," Dr. Brown says. "In some parts of the country, AMD is a large part of the market, consisting mainly of older white folks. Here in south Texas, about half of our patients have diabetes, and Byooviz doesn't have that indication, so that will hurt its uptake."

The American Academy of Ophthalmology supports the use of biosimilars, specifically those approved for ophthalmic indications. They say choice of treatment should remain between the treating ophthalmologist and their patient; they don't support step therapy programs.⁷

"This is an exciting time for treating nAMD," Dr. Haddock says. "We have several new treatments, and biosimilars are being introduced. There's a lot to consider when deciding which treatments to use, but fortunately for patients, our latest treatments last longer, reduce the number of injections, reduce overall risk and maintain vision. I look forward to a future of individualized treatment driven by multiple treatment options." ◀

- Li E, Donati S, et al. Treatment regimens for administration of anti-vascular endothelial growth factor agents for neovascular age-related macular degeneration: Review. *Cochrane Database of Systematic Reviews* 2020;5:CD012208.
- Khanani AM, et al. Safety outcomes of brolocizumab in neovascular age-related macular degeneration: Results from the IRIS Registry and Komodo Healthcare Map. *JAMA Ophthalmol* 2022;120:1:20-28.
- Zarbin M, Tsuboi M, Hill LF, et al. Simulating an anti-vascular endothelial growth factor switch in neovascular age-related macular degeneration. *Ophthalmology* 2019;126:849-855.
- Ferris FL 3rd, et al. Evaluating effects of switching anti-vascular endothelial growth factor drugs for age-related macular degeneration and diabetic macular edema. *JAMA Ophthalmol* 2017;135:2:145-149.
- Tuerksever C, et al. Hypothetical switch of anti-vascular endothelial growth factor in neovascular age-related macular degeneration: An ARIES post hoc analysis. *Ophthalmol Ther*. [Epub January 23, 2022].
- FDA. Biosimilarity and Interchangeability: Additional draft Q&As on biosimilar development and the BPCI Act. Accessed July 11, 2022. <https://www.fda.gov/media/143847/download>.
- American Academy of Ophthalmology. Biosimilars Forum: Unlocking the potential of biosimilars for treating retinal vascular disease, June 10, 2022. Webinar.
- Sood S, et al. Cost of ranibizumab port delivery system vs intravitreal injections for patients with neovascular age-related macular degeneration. *JAMA Ophthalmology*. [Epub June 16, 2022].

A PUBLICATION BY **REVIEW**
OF OPHTHALMOLOGY

RETINA[®] SPECIALIST



KEEP UP WITH CUTTING-EDGE SCIENCE IN RETINA

Retina Specialist focuses on the latest advances in the diagnosis, medical management and surgical treatment of diseases of the retina, along with practical, real-world advice from leading clinicians and other experts on managing the successful retina practice.

Watch for issues in:

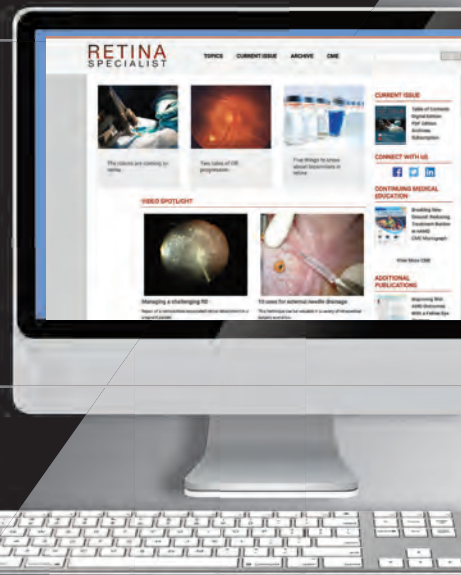- JANUARY/FEBRUARY
- MARCH/APRIL
- MAY/JUNE
- JULY/AUGUST
- SEPTEMBER/OCTOBER
- NOVEMBER/DECEMBER

WEBSITE

RETINA-SPECIALIST.COM

RETINA ONLINE

Each month, Medical Editor Philip Rosenfeld, MD, PhD, and our editors provide you with this timely and easily accessible report to keep you up to date on important information affecting the care of patients with vitreoretinal disease.



FOR INQUIRIES CONTACT

RETINASPECIALIST@JOBSON.COM

ADVERTISING OPPORTUNITIES

MICHAEL HOSTER • PUBLISHER • 610-492-1028 • MHOSTER@JOBSON.COM

MICHELE BARRETT • 215-519-1414 • MBARRETT@JOBSON.COM

JONATHAN DARDINE • 610-492-1030 • JDARDINE@JOBSON.COM

FOLLOW US

@RetSpecMag

RetinaSpecialistMag

MANAGING RETINA IN THE PRESENCE OF GLAUCOMA

Managing retinal problems in the setting of glaucoma raises the stakes. Here's how to play it safe.

CHRISTOPHER KENT
SENIOR EDITOR

As every retina specialist knows, many retina patients have glaucoma in addition to their retinal problems. Furthermore, addressing retinal problems can impact intraocular pressure, potentially putting such patients at risk.

Michael A. Klufas, MD, part of the Retina Service of Wills Eye Hospital and an assistant professor of ophthalmology at Thomas Jefferson University in Philadelphia agrees that the conditions frequently overlap. “As retina specialists, some of the conditions we treat are associated with glaucoma and/or elevated intraocular pressure,” he says. “Those include retinal vein occlusions, retinal detachments and diabetic retinopathy, which can be associated with neovascular glaucoma. In addition, the periodic injections we give many of our patients may cause intraocular pressure fluctuations. IOP can sometimes trend higher in patients who’ve had multiple injections, so I have to be alert for that possibility to

make sure the patient doesn’t lose vision from glaucoma. Furthermore, some of the surgeries we perform, such as repairing a chronic retinal detachment, can cause IOP to increase.”

Here, retina specialists discuss the issues that may arise in this situation and share their tips for how best to proceed.

Checking for Glaucoma

Given that retinal procedures can have a serious impact on vision in a glaucoma patient—and not every patient with glaucoma has been diagnosed—many retina specialists say they routinely check their patients for evidence of the disease.

“Every time a patient comes in we look for signs of glaucoma,” says David S. Boyer, MD, a partner at Retina-Vitreous Associates Medical Group in Los Angeles and an adjunct clinical professor at the Keck School of Medicine of the University of Southern California. “We encounter glaucoma patients or suspects nearly every day. We may note increased cupping, an abnormal nerve

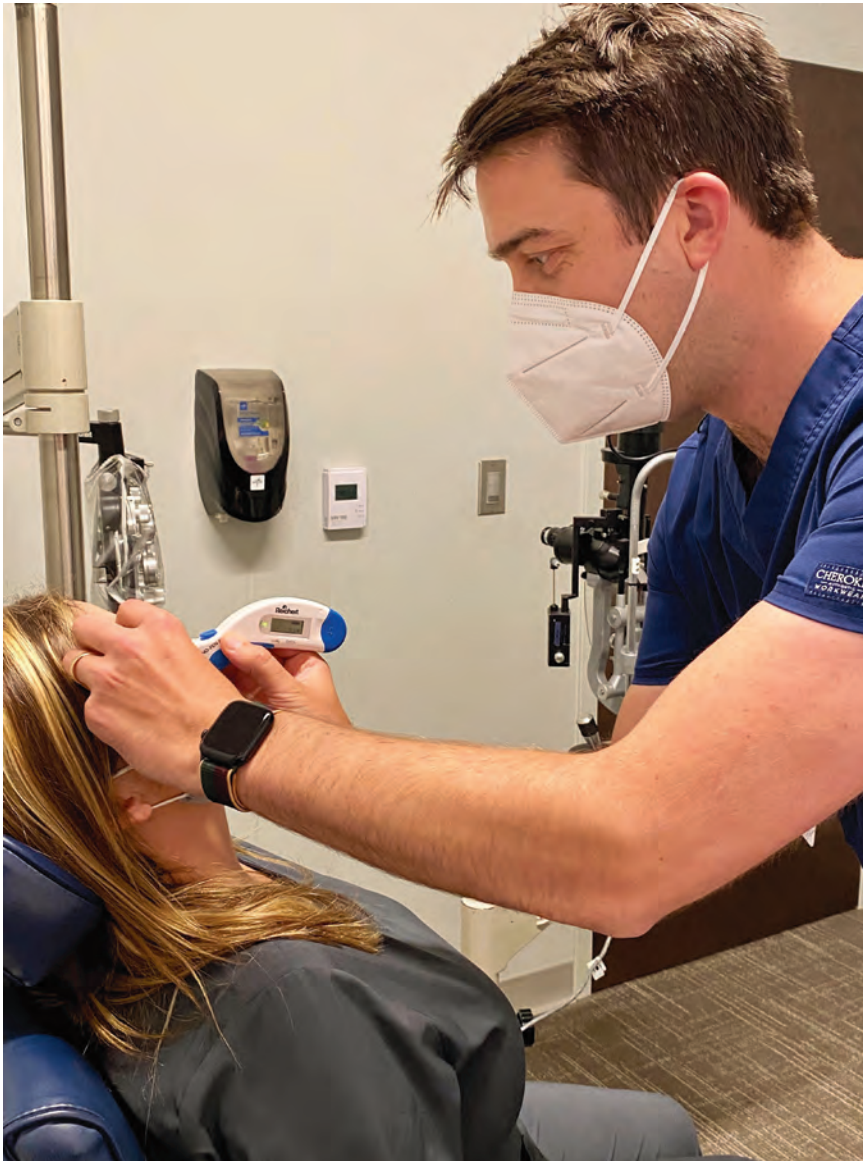fiber layer or very high intraocular pressure. Any of these will point me in the direction of having someone else involved who can follow the patient on an ongoing basis and do a more thorough glaucoma exam to determine whether the patient requires treatment.”

Noting that giving repeated injections may cause a pressure problem in some patients, Dr. Boyer says he always gets an OCT of the nerve fiber layer before he starts treatment. “No major study has verified this association, but getting an OCT of the nerve fiber layer at the outset gives me a good baseline for comparison later in case a problem arises.”

Adam Pflugrath, MD, a retinal surgeon at Jerve Eye Group in Greenville, South Carolina, believes that checking retina patients for the presence of glaucoma is incredibly important. “As retina doctors, we see patients more often than most—especially injection patients,” he points out. “As a result, we have a lot more data about both intraocular pressure and optic nerve head as-

This article has no commercial sponsorship.

Dr. Klufas is a consultant for Genentech, Allergan, RegenexBio and Alimera, and a speaker for Genentech and Regeneron. Drs. Boyer and Pflugrath report no relevant financial disclosures.



Surgeons say that when a glaucoma patient comes in with pressure already elevated, the first thing they do is recheck the pressure to make sure the measurement was accurate. Some doctors prefer to use a Tonopen for this purpose; others favor the iCare tonometer.

assessment.

“Every time I get an OCT of the macula I look at the infrared image of the nerve for any changes, just to see what’s going on,” he says. “I’ll pull up the last image and look to see if there are any changes. We can also use other options such as an RNFL scan, or some of the new metrics, like the Bruch’s membrane opening minimum-rim-width or area assessment, to track any changes.”

Dr. Pflugrath notes that he generally doesn’t rely on the OCT software-generated analysis, regard-

ing whether signs of progression exist. “The software is good, but often you have to redraw the lines for the RNFL to get a more accurate measurement,” he points out. “Sometimes the machine misses the layer of the retina you want to evaluate. A brief look at the infrared image is a good quick assessment. In fact, you see more optic nerve head cupping when you look at the infrared image than you would looking at the slit lamp. Furthermore, taking that picture gives you another data point to assess later.

“Automated perimetry isn’t reliable in this population,” he adds. “Patients who’ve had prior pan-retinal photocoagulation laser for diabetes or vein occlusion, or who can’t maintain fixation because of macular edema or macular degeneration, aren’t going to perform as well on that test. We have the technology to get more objective measurements, so we might as well use it.”

If you find evidence suggestive of glaucoma, how should you proceed? Dr. Klufas says his decision about whether to recommend a glaucoma screening depends on a number of factors. “I look at the cup-to-disc ratio, whether the patient has a family history of glaucoma, and the IOP,” he explains. “If they have no risk factors and the cup-to-disc ratio is normal, I’m not sure they need a glaucoma screening. If they have a family history, but no other factors, I’d recommend getting the screening.

“Usually, if I suggest getting screened for glaucoma, the patient asks how soon to see someone about that,” he adds. “If their vision is fine, I’ll suggest doing it any time in the next six months, but I tell them not to wait for a year or two and risk permanent vision loss.”

Elevated Pressure, Pre-injection

Most glaucoma patients need to have a low pressure to minimize the likelihood of progression. Occasionally, a glaucoma patient or suspect will show up for a retinal injection with their IOP already elevated.

Dr. Klufas says he may proceed with the injection despite an elevated IOP. “It depends on the pressure,” he notes. “If it’s 30 mmHg or less, I’ll typically just do the injection. Most of the intravitreal injections we do are 0.05 cc of volume, which the eye typically tolerates very well. Once I’ve done the injection I’ll recheck the pressure and confirm that the patient’s vision isn’t declining or blacked out, which would indicate very high pressure.”

Doctors note other points:

- **Double-check the IOP yourself.** Drs. Pflugrath and Klufas both double-check the IOP if it's been measured as being elevated. "Often it was just spuriously high," Dr. Klufas notes. "If I'm not sure the measurement was accurate, I tell the patient to breathe normally while I recheck it."

- **Consider the reason for the elevated IOP.** "I'd probably proceed with an intravitreal injection, as long as the reason for the elevated eye pressure was just open-angle glaucoma, as opposed to residual lens material, bleeding secondary to trauma, or certain types of inflammation," says Dr. Pflugrath.

- **Consider making a paracentesis to avoid a pressure spike.** "Doing a paracentesis immediately after the injection should help reduce the risk of pressure elevation," says Dr. Pflugrath. "However, I don't do this for every patient; I assess the optic nerve and IOP and decide if their optic nerve can handle the transient rise in pressure. Then I proceed with the injection using a 30-ga. needle."

Dr. Klufas says he would generally only create a paracentesis in the presence of high pressure if the injection was urgent. "I'd consider a paracentesis if the patient, for example, has only one eye and if we don't treat the neovascular macular degeneration the eye could get a bleed and vision loss."

Dr. Klufas points out that some doctors inject a larger volume of drug based on the theory that more medication may allow increased duration of action. "I don't believe this has ever been demonstrated in randomized, controlled studies," he says. "However, if you do inject a larger volume, performing the anterior chamber paracentesis might make sense. It's an easy step to add on, and it's less painful than the intravitreal injection. In any case, If I do perform an anterior chamber paracentesis, I explain to the patient

that the pressure problem needs to be addressed long term, which the paracentesis won't do."



If the patient has glaucoma, or we suspect he has glaucoma, there's a good chance we're not going to use steroids ... I think the issue is steroid response even more than glaucoma, because some patients who don't have glaucoma will go on to develop high pressure.

—David S. Boyer, MD



Dr. Boyer says he rarely creates a paracentesis. "I know that some doctors do anterior chamber taps fairly often, but I haven't found the need for it," he explains. "If I think the patient is going to have a pressure elevation of any magnitude, I may add some drops beforehand, or do a little bit of ocular massage. For the most part, 0.05 ml of fluid isn't going to cause a significant pressure increase."

- **Consider injecting a different agent.** Dr. Pflugrath notes that another way to minimize the risk associated with post-injection IOP spikes is to use a longer-lasting anti-VEGF agent that requires fewer injections. "In retina patients with glaucoma or RNFL thinning, I prefer to use a more durable agent, if possible, whether that's an intravitreal steroid or some of the newer anti-VEGF agents that can last more than four to six weeks," he explains.

- **Start a glaucoma drop, or send the patient back to the referring doctor.** "Once I recheck the pressure, I'd review the medications the patient is on," says Dr. Pflugrath.

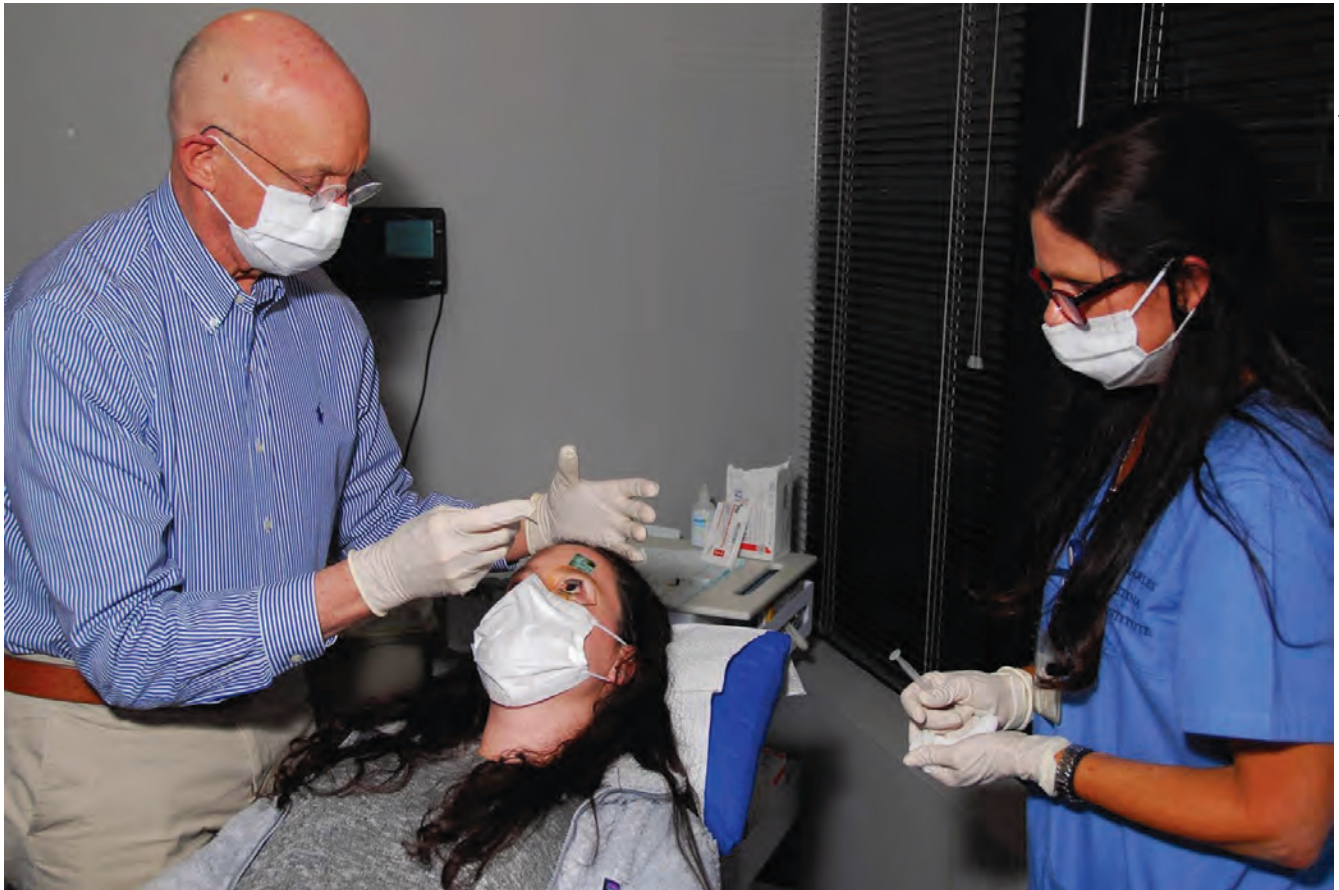"If the pressure is in the high 20s or 30s, I'd probably add a drop, if that's feasible, and let the referring doctor know.

"Depending on how high the pressure is, I might send the patient back to the other doctor to get it under control," says Dr. Boyer. "If I see significant alterations at the level of optic nerve and the nerve fiber layer is compromised, then I may conclude that they need additional medication. If that's the case, I'll either call the other doctor or start the medication and ask the patient to see their doctor within the week, so they can get that taken care of."

Dr. Klufas adds one point worth considering when performing an injection, regardless of whether or not the pressure is elevated. "Conserving conjunctiva is something to consider when treating a glaucoma patient," he says. "I try to use conjunctiva away from the limbus, in case a glaucoma surgeon needs to do a procedure later."

Elevated Pressure, Pre-surgery

Doctors note that the considerations are somewhat different if the patient has come in for an invasive procedure and the pressure is already elevated. "In terms of proceeding with retinal surgery when the patient's IOP is elevated, that would depend on how elevated the pressure was, and the cause," says Dr. Pflugrath. "If this pressure is significantly elevated, I might postpone surgery to get the IOP under better control. If the pressure was minimally elevated, by only a few points and not requiring additional medication, then I might proceed with the surgery. On the other hand, if it was an elective procedure and the pressure was significantly elevated over baseline, I'd discuss additional medications or have them touch base with their glaucoma provider to see what could be done to lower the pressure more effectively before doing the procedure.



Surgeons say they'd often proceed with an injection despite elevated IOP—if the pressure wasn't too elevated, and the reason was open-angle glaucoma, rather than other causes such as trauma or inflammation. Some surgeons make a paracentesis after the injection if transient high pressure is especially risky for the eye, though it's more common to start a glaucoma drop and/or send the patient back to the referring doctor to get the pressure under control. In any case, careful post-injection monitoring is always called for.

“In cases in which lens particles or a hemorrhage are causing the elevated IOP, I'd proceed with the surgery,” he adds. “If there was a retinal detachment, I'd go ahead with the surgery as well. However, you don't usually see elevated pressure in that situation.”

If the patient was in the office for a procedure such as a retinal laser rather than an injection, Dr. Klufas says whether he'd postpone the procedure would depend on a number of factors. “I wouldn't postpone a laser procedure intended to treat a retinal hole,” he notes. “That shouldn't affect the pressure. But if it's an invasive incisional, surgical procedure, my decision about proceeding would depend on how healthy the optic nerve looks. Someone with advanced glaucoma

can lose all of their vision if the pressure reaches 40 mmHg, or whatever would be considered high for them, and the pressure can go up and down intraoperatively during retinal surgery.

“For that reason,” he continues, “if it's elective surgery, I might say ‘Your vision is still pretty good, so let's leave your eye alone.’ On the other hand, if it's a retinal detachment that needs to be fixed or the patient might lose vision, postponing wouldn't be an option. In that situation, I might take steps to make sure the pressure is normal before, during and after the surgery.

“Overall,” he adds, “the decision is pretty much patient-dependent, based largely on how healthy the optic nerve is.”

Managing the Steroid Dilemma

Because steroids can trigger an elevation in IOP in some individuals, a retina specialist may face a dilemma when steroids are the obvious—or necessary—treatment for a retinal concern. Surgeons say these strategies help ensure a positive outcome:

- **See if the patient is a steroid responder.** “If the patient has glaucoma, or we suspect he has glaucoma, there's a good chance we're not going to use steroids,” says Dr. Boyer. “If we do use them, we're going to first try to see if the patient is a steroid responder, beyond just having glaucoma. I think the issue is steroid response even more than glaucoma, because some patients who don't have glaucoma will go on to develop high pressure. You can't really use steroids for those patients,

NOTING AND TREATING PARTICULATE GLAUCOMA

Adam Pflugrath, MD, a retinal surgeon at Jerve Eye Group in Greenville, South Carolina, points out that particles left in the eye may lead to inflammation, which in turn can cause increased aqueous viscosity that can lead to elevated pressure. Particles left in the eye can also clog the trabecular meshwork directly, leading to the same outcome.

“Retained lens particles following cataract surgery or lensectomy can cause this, as can silicone droplets and particles of perfluorocarbon liquid that weren’t removed,” he says.

“This isn’t something most doctors think about when faced with elevated IOP, but retained particles are easily visible. Silicone oil floats to the top of the eye, while perfluorocarbon liquid and lens particles fall to the bottom of the anterior chamber, so you can see them at the slit lamp.

“If the patient’s pressure is high as a result, you need to increase the steroids,” he notes. “If I see one of these cases in the office, I give the patient a periocular steroid to help lower the inflammation. Large lens particles, in particular, can be highly inflammatory. The steroid will help to soften up the particles and break some of them down, and it will help to keep the IOP from spiking due to the particles or the inflammation.

“Of course,” he adds, “if you’re dealing with very large retained lens particles, you’ll also need to do a vitrectomy to remove them from the posterior and anterior segments.”

—CK

unless the pressure elevation is mild and you can easily treat them with drops. Of course, if we do know the patient has glaucoma, I’d definitely be cautious.

“If I feel that steroids are necessary, I’d give the patient a trial of topical drops and monitor the patient for pressure elevation before giving any intravitreal injections,” he continues. “The drops may not even be the same steroid drug, but there may be enough of a correlation to get a sense of whether an injection is likely to elicit a pressure increase. Then, if the drops cause a pressure increase, you can stop the drops. If the drops don’t raise the pressure, I’ll probably do the injection with a steroid that has a short half-life and watch the patient very carefully.”

• **Check the patient frequently postop.** “Whenever I give an intravitreal steroid I have the patient come back five or six weeks later to make sure they’re not a steroid responder,” Dr. Boyer says. “In my experience, that’s usually when the peak pressure occurs.

“Unfortunately, even though you may not see a steroid response the first, second or third time you give the injection, it can happen on the

sixth time,” he continues. “So we try to bring the patients back every time. If the pressure does rise, usually we can treat them with a glaucoma medication and the steroid response will subside after two or three months. Of course, if the patient initially comes in with severe glaucoma we’ll be much more concerned, because if the pressure goes up, we don’t have as many options left to treat the patient. We’d be less likely to use a steroid in that situation.”

Dr. Klufas points out that the timing of pressure elevation can vary with different medications. “Some may cause a pressure elevation two weeks later; some may cause it four to six weeks later,” he notes. “As a result, there’s no foolproof schedule for monitoring the patient. However, if the patient already has a tube or bleb, the pressure should ideally remain OK—especially if the patient has a tube.”

• **Consider placing the steroid in the suprachoroidal space.** Dr. Boyer notes that placing the steroid in the suprachoroidal space could conceivably lower the risk of a pressure increase. “Our practice participated in the original studies of Xipere, a

triamcinolone acetonide injectable suspension designed to go into the suprachoroidal space,” he explains. “It didn’t seem to cause the pressure rises I would have expected. However, I don’t have enough patient experience to be able to say unequivocally that this is true.”

• **Consider switching to anti-VEGF drugs.** “If the condition we’re treating is cystoid macular edema or inflammatory disease and we can’t use steroids because of the inflammation, we tend to switch to using anti-VEGF drugs,” says Dr. Boyer. “In many cases, those drugs will get rid of the edema without causing the pressure to rise.”

• **Treat prophylactically to prevent steroid-related IOP elevation.** Dr. Pflugrath admits that using steroids when a patient is a known steroid responder is sometimes unavoidable. “That’s a challenging situation,” he says. “For example, you might have a steroid responder who has chronic edema that just won’t go away. I’ll often prophylactically put that patient on a topical glaucoma drop, if they’re not already on one, to minimize any potential post-steroid IOP spike and any fluctuations in IOP.”

Dr. Pflugrath notes that in this situation he wouldn’t prescribe a prostaglandin as a first-line agent. “I’m trying to avoid putting a financial burden on the patient,” he explains. “They could have to fork over hundreds of dollars for a drop, if their insurance won’t cover it, so I try to start with a generic dual agent—whatever will be least expensive for the patient. For example, dorzolamide/timolol is a readily available generic drop. The dual nature of the drop is also helpful because many of these patients have never used a glaucoma drop. If I ask them to use something more than twice a day, they may not be compliant.”

Dr. Klufas says he doesn’t generally prescribe a glaucoma drop when giving steroids. “Steroids don’t always cause glaucoma, so it may not be necessary to do that routinely,”

he says. “However, if I give a periocular steroid, I tell the patient that I’ll need to check the pressure regularly. Some of those patients may end up needing a glaucoma drop, and one in a few hundred may need glaucoma surgery, so I warn patients about that possibility before proceeding with a steroid injection.”

• **Consider using the Susvimo port delivery system.** Dr. Pflugrath believes the new Susvimo port delivery system implant for diabetics and macular degeneration patients (Genentech) may help to minimize IOP spikes. “A lot of patients with diabetes or macular degeneration also have glaucoma,” he notes. “When you place an implant in these patients, you don’t see the same post-injection IOP spikes because the patients rarely require further injections.

“The problem,” he adds, “is that if the patient has had glaucoma surgery, or has advanced glaucoma that may require a shunt, you’re limited as to where you can place the implant and still have adequate conjunctival covering to minimize any potential infection risk.”

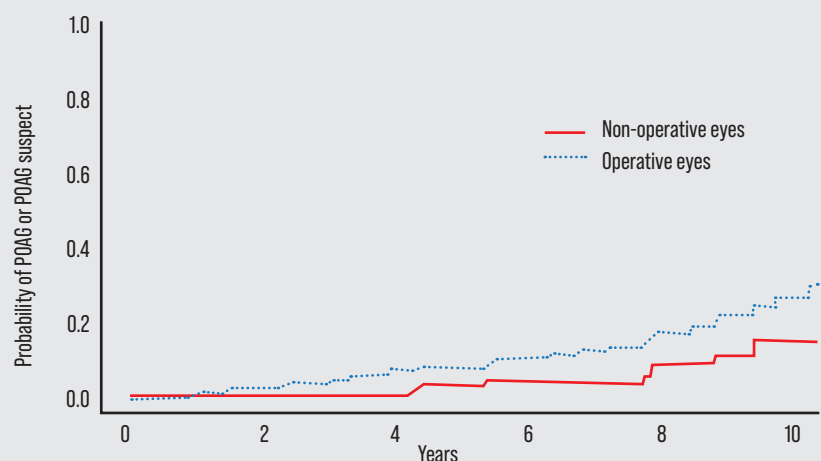
• **Choose a less-potent steroid.** “We have different choices in terms of which steroid we use,” notes Dr. Klufas. “There are some steroids like FML (fluoromethalone ophthalmic suspension) or Lotemax or Alex, that are less potent than other options such as Durezol.”

• **Consult with a glaucoma specialist before proceeding.** Dr. Klufas says that if he plans to inject a steroid intraocularly or periocularly and he’s concerned about the patient, he’ll consult with a glaucoma specialist before proceeding. “In my experience, they’ll usually tell me it’s fine to proceed, as long as the patient is being monitored appropriately after the injection,” he says.

If a Tube or Bleb is Present

“Obviously if you’re giving injections, you have to stay away from any existing trabeculectomy bleb

LATE-ONSET GLAUCOMA FOLLOWING VITRECTOMY



In addition to issues of pressure elevation during and immediately after a vitrectomy, studies suggest that patients are at increased risk of developing open-angle glaucoma in the years following the procedure. For example, one study published in 2018 by Mansukhani et al followed 277 patients who had a vitrectomy in one eye.¹ The risk of developing POAG in the operative eye after multiple years was significantly greater than in the non-operative eye, suggesting that long-term monitoring of these patients is justified.

or tube shunt,” says Dr. Boyer. “You don’t want to precipitate any breakdown of a functioning drainage system or cause a leak, even with a small needle. So if a tube or bleb is located superiorly, where I normally give my injections, I’ll go inferotemporally for the injection. I always stay away from tubes and trabs.”

Dr. Pflugrath also says he’d avoid the quadrants that contain the bleb or tube. “Typically, I do most of my injections inferotemporally, to minimize scarring in the superior conjunctiva,” he explains. “That way, if the patient needs a future glaucoma surgery, it won’t interfere with it.”

Dr. Pflugrath points out that the presence of a tube or prior trabeculectomy in this situation is good, in that it lowers the risk of a postop pressure spike. “A post-injection IOP spike has been shown to decrease the retinal nerve fiber layer thickness,” he points out. “If the patient has a condition like diabetic macular edema, vein occlusion or chronic uveitis with macular edema, and needs a steroid injection, having a tube or a prior trabeculectomy makes me worry less about having steroid-induced glaucoma. Their

aqueous is already bypassing the trabecular meshwork.

“If they haven’t had a tube or trabeculectomy or some other shunt procedure, I’m more likely to do an anterior chamber paracentesis with an intravitreal injection and use a different size needle—27-ga. or 30-ga. instead of 32-ga.—to minimize post-injection IOP spikes,” he continues. “That helps, because the larger-diameter needle allows a little more leakage until the sclerotomy closes. It’s a safety valve of sorts.”

Glaucoma and Vitrectomy

“Depending on the degree of damage seen at the nerve, you don’t want to have high pressures during a vitrectomy, and you don’t want to leave the patient with high pressure,” says Dr. Boyer. “I’ve seen people lose vision because of that. For example, a colleague came to me seeking a second opinion after a vitrectomy he underwent caused him to lose vision, secondary to increased IOP during his surgery.”

Dr. Pflugrath says that when performing a vitrectomy in a patient with glaucoma, he chooses the location for the ports based on both

current and future considerations. “If the patient has had a filtering procedure, you obviously don’t want to put the port in through the bleb or near the tube,” he says. “I typically do a lot more of my trocar placements closer to the equator, as opposed to the traditional 10:00 and 2:00 placement. In addition, if the patient has more severe glaucoma and I’m sitting superiorly, I’ll put things closer to the equator to avoid causing any conjunctival damage or scarring, in case the patient needs to have glaucoma surgery in the future.

“One other consideration in this situation is that I’ll lower my infusion pressure during the vitrectomy,” he adds. “And, I’ll keep an eye on the optic nerve head and the blood vessels. I want to avoid any arterial pulsations. Pulsations imply that the pressure’s too high in the eye, potentially decreasing the blood flow. So, if I see any, I’ll lower the infusion pressure until they go away, to optimize blood flow and minimize nerve head damage.”

“The use of steroids following the vitrectomy is also a concern,” Dr. Klufas adds. “I usually give a steroid injection at the end of a case, but in a case like this I might forgo that, or just give a smaller amount, putting them only on topical steroids drops instead. Of course, the drops could elevate the pressure too, but they can be stopped.”

Glaucoma and a Gas Bubble

Dr. Pflugrath says that when a glaucoma patient requires surgery that calls for a gas bubble to hold the repaired tissue in place, it’s important to make sure the IOP isn’t too elevated after the bubble is created. “If it’s elevated, you need to adjust the IOP in the OR before the patient leaves,” he says. “Ideally, you’re using an isoexpansile gas concentration that will minimize any potential IOP elevation that first day, while the eye is patched and the patient’s not getting any eye drops. You want a good gas fill without an

SILICONE OIL IN AVASTIN SYRINGES

Michael A. Klufas, MD, part of the Retina Service of Wills Eye Hospital and an assistant professor of ophthalmology at Thomas Jefferson University in Philadelphia, notes a problem that has cropped up when injecting off label intravitreal Avastin to address macular degeneration or other vitreoretinal conditions. “Sometimes the syringes are contaminated with silicone oil, just because of the way the compounded Avastin is prepared,” he explains. “The oil lubricates the plunger, but that oil can be injected into the eye. Sometimes a big oil bubble gets injected and patients may experience a visually significant floater.

“Patients who’ve had three shots of Avastin from syringes contaminated with silicone oil will almost always have some small oil droplets in the vitreous cavity, which could potentially lead to glaucoma in some patients,” he notes. “Doctors don’t look for it all the time, but it’s there.

“You can still buy Avastin in insulin-type needles,” he continues. “It’s very convenient because it’s an all-in-one thing; you just pull the cap off and inject the medication. From a sterility standpoint it’s good, because you don’t have to put the needle on yourself, and it’s cheaper, too, because you can pull more doses out of the compounded Avastin vial. Unfortunately, silicone oil contamination has been reported with all kinds of intravitreal medications, and compounded Avastin has the highest rate of silicone oil contamination when repackaged into certain types of syringes that aren’t silicone-free.”

Dr. Klufas points out that silicone-free preparations are now available. “Most practices have transitioned,” he says. “They’re more expensive, but to me the silicone oil contamination is a problem worth addressing. Unfortunately, with the pandemic it’s been harder to get the silicone-oil-free syringes, due to supply chain problems.

“At this point, we still use a silicone-free preparation, but now we have to place a needle on the syringe ourselves,” he concludes. “That’s a sterility concern for some doctors, and the needle may not be as secure on the syringe, as compared to a silicone-oil-free syringe that has the needle built in. This isn’t ideal.”

—CK

overflow.”

He notes that using a gas bubble offers plenty of opportunity to unintentionally generate excess IOP. “Make sure you’re using the correct concentration of gas,” he says. “You want to get as close to an isoexpansile mixture as you can,” he says. “Gas expansion and overflow-related pressure problems are potentially blinding, irreversible complications that are avoidable if you get the right concentration.

“A common mistake, for example, is to record the number of cubic centimeters of gas needed in your protocol notes, but fail to recalculate if a different, smaller syringe ends up being used for the procedure,” he notes. “Another mistake is believing that severe proliferative retinopathy should be addressed with a higher concentration of gas; there’s no evidence to support that idea. Finally, make sure the IOP isn’t elevated at

the time of closing.”

He adds one other potentially devastating mistake. “Sometimes a doctor will prescribe postop pain medication, as needed, for a patient with a gas bubble,” he says. “If the patient is in pain, it could indicate that the gas concentration is incorrect, rather than being simple postoperative surgical pain. If oral medications mask that pain, the patient may return to your office with serious vision loss and optic nerve ischemia.”

“Generally, I try to avoid expansile gases in a glaucoma eye,” says Dr. Klufas. “Sometimes I dilute the gas a little bit more than I would otherwise, to avoid any chance of expansile gas. Of course, even if the concentration is correct, you can still have pressure issues postoperatively. One option is to have the anesthesiologist give Diamox, either orally or intravenously, at the end of the case

to keep the pressure on the lower side. Too low a pressure isn't good either, of course, but sometimes that medication can lower it just enough to avoid a problem."

Dr. Boyer notes another issue. "If the patient has had a filtering operation, you don't want the gas bubble to go into the anterior chamber and block it," he says.

Glaucoma and Silicone Oil

Dr. Klufas doesn't favor the use of silicone oil as a first option in a patient with severe glaucomatous vision loss. "There's definitely a higher morbidity with silicone oil in this situation," he says. "Doctors have reported optic neuropathies with this treatment, so it's not my preferred option in a patient who already has some vision loss from glaucoma. The silicone oil doesn't usually cause glaucoma directly, but there are reports of oil causing damage to the optic nerve, as well as secondary glaucoma. And, even when you remove the oil in the future, there are always little droplets left in the eye that can clog the trabecular meshwork and lead to glaucoma. Nevertheless, sometimes there's no other option and silicone oil is required.

"If I do have the option, I'd choose the gas," he says. "It will cause temporary changes in the intraocular pressure, but it reabsorbs over time."

Dr. Pflugrath points out that it's crucial to avoid over-injecting silicone oil. "Always use a tactile pressure check to make sure the eye isn't overinflated," he says. "Oil can't compress, and glaucoma medications won't be able to offset a pressure increase caused by excess silicone oil."

"If there's a tube in the posterior segment, silicone oil would be contraindicated because you're going to block the tube," notes Dr. Boyer. "Then the pressure will go up. If the tube is in the anterior chamber, you could be fine as long as oil bubbles don't go into the anterior chamber. And if a patient without a tube developed a pressure increase with sili-

cone oil present, the surgeon would still have the anterior chamber available to put a tube in. So, I'd avoid using oil if a tube was in the posterior chamber. Otherwise, I wouldn't be too concerned about it."

“The reality is, our practice isn't set up to fully evaluate or manage glaucoma. I think it's better to put the patient back in the hands of someone who can follow them and do the appropriate testing on an ongoing basis.”

—David S. Boyer, MD

Dr. Pflugrath points out another potential problem that can affect retina patients who have glaucoma: Conditions that make the aqueous more viscous—including flare caused by silicone oil—can cause IOP to rise simply because more viscous fluid doesn't drain as well. "Inflammation will increase viscosity quite a bit," he says. "VEGF will also. Anything that causes high protein content will lead to more viscous fluid that raises the pressure. Conversely, treating the cause of that with an anti-VEGF injection or a steroid will help lower the IOP.

"You can also see this in patients with silicone oil who have a lot of flare," he continues. "Flare is a marker of proteinaceous changes, making the anterior chamber fluid more viscous. So, if a patient has silicone oil in place and you can't take it out, and they have a lot of flare in the anterior chamber and the IOP's going up, a periocular steroid injection can help. It can get rid of the flare and inflammatory particles and lower the viscosity of the aqueous, which will, in turn, lower the IOP."

Working With a Glaucoma Colleague

Dr. Klufas says that working with a

glaucoma specialist in many of these cases makes sense. "It's definitely valuable to be able to comanage a patient so that we can combine our expertise to address any vision-threatening problems," he says. "For example, when dealing with the nuances of recent glaucoma medications, it's often helpful to have the patient be seen by a glaucoma doctor who prescribes these medications frequently and is well-acquainted with their side effects.

"For example, if the patient has asthma or a heart problem, timolol isn't ideal," he notes. "In retina we're often worried about inflammation, and prostaglandins like Xalatan or Latanoprost may cause inflammation. Some people get follicular conjunctivitis from brimonidine. And, there are new drops like Vyzulta and Rhopressa. I'm up to date on all of the latest anti-VEGF compounds; that's my area of expertise. But doctors who work with these new glaucoma drops every day have much more experience with them than I do.

"The other issue is practice workflow," he adds. "I can prescribe a drop, but my practice is treating macular degeneration and diabetic retinopathy. Our workflow is set up to take care of injection and retina patients. In contrast, a general eye care doctor or glaucoma specialist is set up to manage glaucoma. There's safety in being managed by a doctor who treats glaucoma all day, every day."

Dr. Boyer agrees. "The reality is, our practice isn't set up to fully evaluate or manage glaucoma," he says. "For example, we don't have the ability to measure corneal thickness. I think it's better to put the patient back in the hands of someone who can follow them and do the appropriate testing on an ongoing basis." ◀

1. Mansukhani SA, Barkmeier AJ, Bakri SJ, et al. The risk of primary open angle glaucoma following vitreoretinal surgery—a population-based study. *Am J Ophthalmol* 2018;193:143–155.

MANAGING A POSTERIOR CAPSULAR BREAK

Vitrectomy tips to help you come through this unexpected event unscathed.

LIZ HUNTER
SENIOR EDITOR

As one of the rarer complications in cataract surgery, a posterior capsular break can rattle even the most experienced surgeon. How they react to this event, when vitreous is prolapsing, sets the course for completing the surgery and successfully implanting an IOL. However, there is no standard when it comes to addressing this complication, and anterior segment surgeons find themselves divided between a limbal-based or pars plana vitrectomy.

No matter which side of the debate you fall on, there seems to be increasing awareness of the advantages of knowing both approaches. We spoke with several experts who shared their pearls and experiences to better prepare you for your next unplanned vitrectomy.

Risk Factors and Reactions

A posterior capsular tear can occur at almost any step of surgery, but is most common during the last stages of nuclear emulsification.¹ At this

stage, most of the nuclear material is gone and the bag is no longer open, making it more prone to collapse. Looking for and recognizing abnormalities preoperatively with a careful history and exam will help surgeons prepare for this complication.

Neil J. Friedman, MD, adjunct clinical professor, department of ophthalmology at Stanford University School of Medicine and partner at Mid-Peninsula Ophthalmology Medical Group in Menlo Park, California, says recognizing risk factors beforehand allows surgeons to modify surgical techniques to reduce the likelihood of this complication. “Risk factors for capsular breaks include conditions that may weaken the capsule or zonules (i.e., pseudoexfoliation syndrome, ocular trauma, ectopia lentis, posterior polar cataract, previous vitrectomy or intravitreal injections) as well as those that limit visualization of the capsule (i.e., poor pupillary dilation, intraoperative floppy iris syndrome, mature cataract, corneal opacity or edema),” he says.

“Surgeons should always be atten-

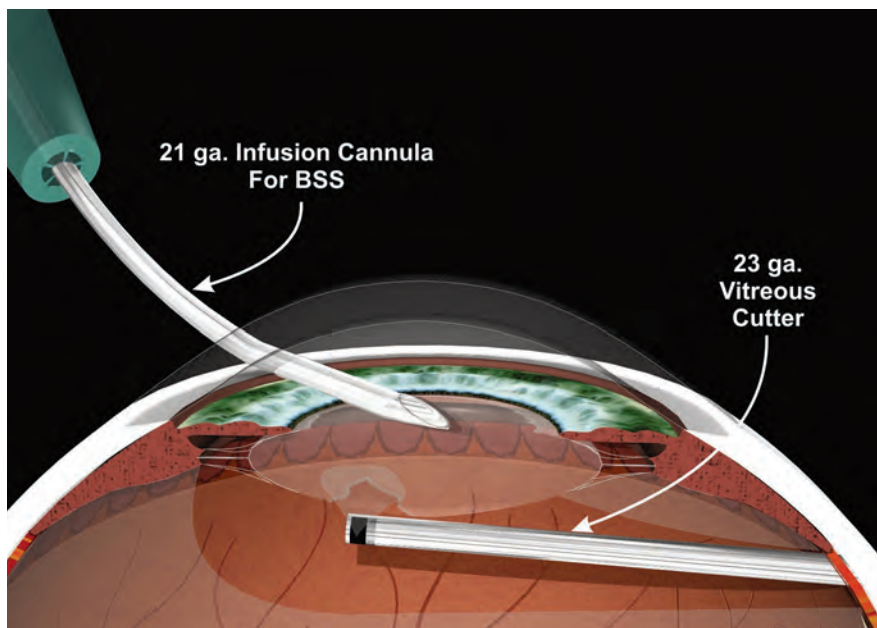
tive to the warning signs of capsular rupture while performing hydrodissection, phacoemulsification, cortical cleanup and IOL insertion, and be prepared to respond accordingly,” Dr. Friedman continues.

Nearly every surgeon remembers the first time this happened to them, likely during their residency. “I first broke the capsule during senior year of residency after approximately 20 uncomplicated cataract cases,” Dr. Friedman says. “I don’t recall the specifics, but I do remember that after the lens nucleus had been removed, I was staring at a large posterior capsular rent with vitreous prolapsing to the scleral tunnel incision. The attending surgeon guided me through the correct steps to complete the case, and the patient subsequently did well with a sulcus IOL.”

That calm, measured response makes a difference. “When you encounter a rupture, you’re likely to have a moment of disbelief and denial somewhat. Your heart just sinks and there are two common reactions: one is to just keep going as if nothing happened; and the

This article has no commercial sponsorship.

Dr. Friedman, Dr. Oetting and Dr. Khandelwal report no relevant financial disclosures.



Steve Charles, MD

The benefits of a pars plana vitrectomy with sideport infusion include less endothelial damage than trans-limbal vitrectomy, better anterior chamber stability, and the fact that residual lens cortex can be removed, proponents say.

other is to come out of the eye—and those are both wrong,” explains Sumitra Khandelwal, MD, associate professor of ophthalmology at Baylor College of Medicine, Cullen Eye Institute, and medical director for the Lions Eye Bank of Texas.

She says surgeons have to get past that moment of disbelief and take the necessary steps to control the situation. “What you don’t want to do is ignore a complication and keep going and then accidentally do something like phacoemulsifying vitreous, which is very, very bad for the patient,” she advises.

Dr. Friedman says the most common mistake is to remove all instruments from the eye without first pressurizing the anterior chamber with OVD. “If the surgeon suddenly removes the irrigating instrument (i.e., phaco probe or I/A handpiece), the anterior chamber collapses and the vitreous moves forward,” he says. “This results in extension of the capsular tear, vitreous prolapse, possible vitreous loss through the wound and possible posterior migration of remaining nuclear material. This sequence of events makes the

remainder of surgery more difficult and increases the risk of postoperative complications.”

Dr. Khandelwal agrees, saying, “The first steps you need to take are to stabilize the eye with dispersive viscoelastic to tamponade the vitreous, turn off your irrigation and come out of the eye, making sure it’s pressurized, and then examine the situation.”

“The patient can have a very successful outcome with a posterior capsule tear,” says Thomas A. Oetting, MS, MD, clinical professor of ophthalmology and visual sciences at University of Iowa Health Care. “Surgeons should slow down and be careful not to put traction on the vitreous, which has likely prolapsed more anterior into the field of surgery. The amount of remaining nucleus will play a big role in the flow of the rest of the surgery. When only a small amount of nuclear material remains, the anterior segment surgeon can usually complete the case.”

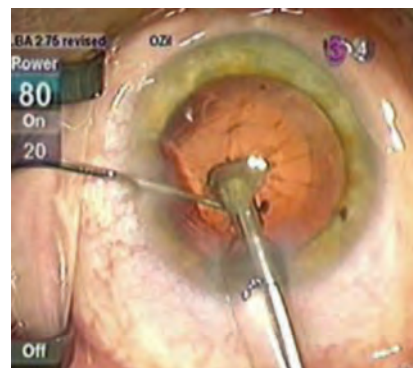
Determining Your Approach

That leads us to the controversy of the limbal-based approach versus

pars plana vitrectomy. Each comes with inherent risks, says Dr. Friedman. “The controversy is regarding safety. An anterior vitrectomy increases the risk of retinal tear, which can lead to retinal detachment. Therefore, it’s important to minimize traction on the vitreous base (i.e., avoid pulling vitreous by using slow movements, high cutting rate and low aspiration/vacuum settings). With the pars plana approach, it’s also necessary to avoid vitreous incarceration in the sclerotomy site,” he says.

Comfort level is also important. After all, as Dr. Khandelwal says, “the time to try new things is not in the middle of a complication.” For this reason, most anterior segment surgeons opt for the limbal-based vitrectomy. “When anterior segment surgeons learn to do intraocular surgery, they’re very focused on the anterior chamber and the wounds are at the cornea, which makes complete sense because that’s where you do your cataract moves,” she says. “There’s no guideline out there saying that’s the incorrect approach. And quite frankly, in most people’s hands, that’s the safest approach because they’re very comfortable with it.”

Dr. Khandelwal warns, though, that the vitreous is like a little Pandora’s box. “Vitreous goes from the back of the eye to the front of the eye if your instruments are in the



Lisa Brothers Arbesser, MD

The spider-like appearance on the posterior capsule could signify a break and require a vitrectomy.

Brandon Ayres, MD, and Sumitra Khandelwal, MD

	Advantages	Disadvantages
Limbal Anterior Vitrectomy	<ul style="list-style-type: none"> Incision familiar to anterior segment surgeon Small incision size Minimal additional equipment Topical anesthetic 	<ul style="list-style-type: none"> Draws vitreous into anterior chamber Cannot remove vitreous behind IOL Fluid flow is anterior
Pars Plana Vitrectomy	<ul style="list-style-type: none"> Posterior fluid flow Allows removal of vitreous from behind IOL or lens Doesn't draw vitreous into anterior chamber Vitreoractor can support dislocating IOL or lens fragments 	<ul style="list-style-type: none"> Requires pars plana incision and/or trocar Additional training may be required Difficult with topical anesthesia Potential for improper placement of trocar

Limbal-based Anterior Vitrectomy Tips

If limbal-based vitrectomy is in your comfort zone, Dr. Friedman offers the following tips:

- Close the existing cataract incision (hydration or suture) and use the appropriately sized MVR blade to create incisions that don't leak;
- Separate the infusion from the vitrector handpiece. The vitrector should initially be set to "cut/I/A" with the highest cutting rate and a low aspiration rate to safely remove vitreous;
- After removing all vitreous above the posterior capsule plane, the vitrectomy setting can be changed to "I/A cut" to aspirate any cortical material in the capsule. If additional vitreous enters the area during cortical removal, then the setting can be switched back to "cut / I/A" to continue the vitrectomy. Alternatively, cortex can be manually aspirated with a cannula using a dry technique (i.e., OVD repeatedly injected to maintain space without irrigation);
- An intracameral steroid (i.e., triamcinolone acetonide [Triessence or Kenalog]) can be injected to better visualize the vitreous; and
- Avoid sweeping the wound with a spatula or using a Weck-Cel spear to check for the presence of vitreous loss from wounds, because these maneuvers cause excessive vitreous traction.

Perks of Pars Plana

Dr. Khandelwal says she prefers the pars plana approach because you're entering your ports 3 mm posterior to the limbus. "You're actually behind the lens and behind the area where the posterior capsule is. Instead of letting the vitreous come to the front of the eye, you're stopping it and cutting it at a plane where it'll stay back," she says. "That's why it's a much more efficient approach."

Good visualization is key. "You

front, so you're almost constantly pulling vitreous out if you're not careful during the limbal-based approach," she says.

Regardless of location, the vitrectomy must be bimanual, not coaxial, Dr. Friedman says. "The infusion line is separated from and placed above the cutting instrument to minimize vitreous hydration and further prolapse," he explains. "The infusion (attached to a cannula, bimanual I/A handpiece, or anterior chamber maintainer) is placed through a corneal paracentesis and the cutting probe is placed either through a separate watertight corneal sideport incision or through the pars plana 3.5 mm posterior to the limbus. Always keep the tip of the vitrector in view.

"The advantage of the pars plana approach is the position of the instrument relative to the vitreous (i.e., below to pull vitreous posteriorly, instead of from above, which risks pulling vitreous anteriorly)," he notes. "If there's a large amount of vitreous prolapse, the pars plana approach usually provides a more complete, safer and quicker removal. In addition, a spatula or OVD cannula placed through the pars plana incision can be used to elevate nuclear fragments using the posterior assisted levitation (PAL) or VisCoat trap technique, respec-

tively. For a small, isolated knuckle of herniated vitreous, I believe the anterior approach through the cornea is easier, faster and equally effective."

It's Dr. Khandelwal's opinion that every anterior segment surgeon should be comfortable with both the limbal-based and pars plana approach to anterior vitrectomy. "The pars plana approach is just not taught that much, but the goal is for everyone to be comfortable with the anatomy and where to insert the trocar for a pars plana approach," she says.

Dr. Oetting says there are specific instances that may exceed the anterior segment surgeon's skill set. "Sometimes, the entire nucleus simply drops into the vitreous chamber," he notes. "This complication often occurs at the time of hydrodissection, especially if the capsule was compromised from a pre-existing injury from past surgery, trauma or needle injury. The anterior segment surgeon shouldn't chase the nucleus back. The surgeon should simply leave the nucleus posterior and continue with the anterior vitrectomy, cortical clean up and IOL placement. Retina surgeons will later perform a pars plana vitrectomy and lensectomy to remove the posterior segment lens material."

One MIGS device* Two implant-free procedures. Three points of resistance.

Go for three.



Efficacy matters, choose OMNI®

Effectively target all three points of resistance with the OMNI® Surgical System to lower IOP in patients with POAG.

- 1 Trabecular Meshwork
- 2 Schlemm's Canal
- 3 Collector Channels



LEARN MORE

VISIT OMNISURGICAL.COM

*IMPORTANT PRODUCT INFORMATION

INDICATIONS FOR USE: The OMNI® Surgical System is indicated for canaloplasty (microcatheterization and transluminal viscodilation of Schlemm's canal) followed by trabeculotomy (cutting of trabecular meshwork) to reduce intraocular pressure in adult patients with primary open-angle glaucoma.

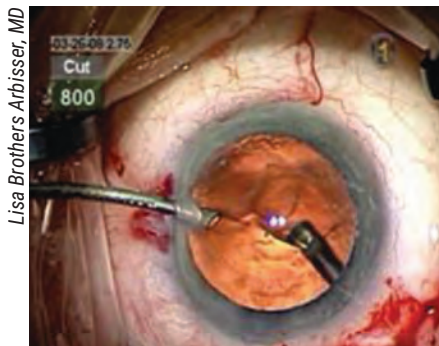
CONTRAINDICATIONS: Do not use the OMNI® Surgical System in any situations where the iridocorneal angle is compromised or has been damaged (e.g., from trauma or surgery), since it may not be possible to visualize the angle or to properly pass the microcatheter. Do not use the OMNI® Surgical System in patients with angle recession; neovascular glaucoma; chronic angle closure; narrow-angle glaucoma; traumatic or malignant glaucoma; or narrow inlet canals with plateau iris. Do not use the OMNI® Surgical System in quadrants with previous MIGS implants.

Please refer to the full Instructions For Use, available at omnisurgical.com, for warnings, precautions, and adverse event information.

should never go back there if you're not sure you can see your ports because you may inadvertently cut something," says Dr. Khandelwal. "It's much more dangerous to cut something near the retina than it is to cut something in the anterior segment. Retina surgeons can go really far posterior—they've got excellent microscope devices that can give them a really good view.

"Companies make certain trocars that are specific to anterior segment surgeons with just the specific things you need, so you don't have to pull up the whole retina tray anymore," Dr. Khandelwal adds. "You can also just use an MVR blade to insert it, but the key is to measure back to where you need to insert it to visualize your ports, and then to use techniques similar to the limbal approach. If you have the correct instruments, it's always better to do a pars plana approach."

There's always an opportunity to reverse course. "If you start the pars plana vitrectomy and realize you



After removing all vitreous above the posterior capsule plane, the vitrectomy setting can be changed to "I/A/cut" to aspirate any cortical materials in the capsule.

don't feel comfortable, you can switch back to a limbal-based approach," Dr. Khandelwal says. "Nothing says you have to use the pars plana incision you made, but no matter which way you do the vitrectomy, you want to close your wounds."

Placing the IOL and Postoperative Care

Dr. Oetting says the status of the

remaining capsule drives placement of the IOL. "If the anterior capsule is also torn but the zonules are solid, surgeons can often place a sulcus-based three-piece IOL," he says. "If the IOL doesn't seem stable, it can be sutured to the iris immediately or later. If the anterior capsule is also torn and the zonules are weak, then the capsule will offer little support."

"A single-piece posterior chamber IOL may be secure in the capsular bag if there's a small capsule tear, particularly if it's central and can be stabilized by creating a posterior capsulorhexis," says Dr. Friedman. "The IOL optic can also be captured anteriorly or posteriorly through the anterior or posterior capsulorhexis, respectively. If a lens can't safely be implanted in the bag but there is sufficient anterior capsular support, then a three-piece IOL can be placed in the sulcus, preferably with optic capture through an intact capsulorhexis. If

(Continued on page 70)

One MIGS device*. Two implant-free procedures. Three points of resistance.

Go for three.



Efficacy matters, choose OMNI®

Effectively target all three points of resistance with the OMNI® Surgical System to lower IOP in patients with POAG.

- 1 Trabecular Meshwork
- 2 Schlemm's Canal
- 3 Collector Channels



VISIT OMNISURGICAL.COM

*IMPORTANT PRODUCT INFORMATION

INDICATIONS FOR USE: The OMNI® Surgical System is indicated for canaloplasty (microcatheterization and transluminal viscodilation of Schlemm's canal) followed by trabeculotomy (cutting of trabecular meshwork) to reduce intraocular pressure in adult patients with primary open-angle glaucoma.

CONTRAINDICATIONS: Do not use the OMNI® Surgical System in any situations where the iridocorneal angle is compromised or has been damaged (e.g., from trauma or surgery), since it may not be possible to visualize the angle or to properly pass the microcatheter. Do not use the OMNI® Surgical System in patients with angle recession; neovascular glaucoma; chronic angle closure; narrow-angle glaucoma; traumatic or malignant glaucoma; or narrow inlet canals with plateau iris. Do not use the OMNI® Surgical System in quadrants with previous MIGS implants.

Please refer to the full Instructions For Use, available at omnisurgical.com, for warnings, precautions, and adverse event information.

©2022 Sight Sciences, Inc. 3/22 OM-0000-US.v1



LEARN MORE



RETINA AND CATARACT: WHEN TO STAGE OR COMBINE PROCEDURES

When approaching these procedures, surgeons say that patient education and setting realistic expectations are the keys to success.

MICHELLE STEPHENSON
CONTRIBUTING EDITOR

When patients need both cataract and retina surgery, the procedures can be performed in combination or using a staged approach. The combined procedure, phacovitrectomy, provides several advantages for patients and retina specialists.

According to Christina Weng, MD, MBA, a retina specialist on faculty at Baylor College of Medicine in Houston, there are two categories of situations in which surgeons might consider a combined approach. The first situation is out of necessity. “For example, I can’t fix a retinal detachment if a dense cataract is obscuring the view,” she notes. “However, the more common situation is when there are two pathologies that can be addressed electively, such as an epiretinal membrane and a cataract. In these scenarios, it can be challenging to discern which symptoms are from the cataract and which are from the epiretinal membrane, but if both are likely contributing to the patient’s

visual impairment, combined surgery is a terrific option.”

Dr. Weng believes that concurrent management of anterior and posterior segment pathology can often help patients achieve their best visual outcomes sooner. “If you stage the surgery, there’s always the risk that patients will have an outcome that falls short of their expectations,” she says. “While there are some risks with combined surgery, both modern-day cataract and retina surgery are very safe. I find that most patients are more than happy to have a two-in-one surgery to optimize their visual acuity, especially in a cataract surgery era where patients’ expectations are so high.”

According to Andrew Kao, MD, who is in practice in Bakersfield, California, one benefit of a combined procedure is potentially less cost to the health system overall. “In that situation, if a patient has a retinal problem and has already had intravitreal injections or some sort of vitrectomy in the past, it does increase the risk of a retained lens fragment or a posterior capsular

rupture during cataract surgery,” he says. “For example, during my residency, I was performing a cataract procedure first, and then half the lens fell to the back of the eye. The patient was already going to have a vitrectomy that day, so then the retina specialist just stepped in a little earlier, removed the remaining lens and then did the retina procedure.”

Combined procedures also have some downsides, one of which is scheduling, says Tom Stone, MD, who is in practice in Louisville, Kentucky. “My biggest referring cataract group operates at a different surgery center than I do, so even if I wanted to do a combined case with one of their surgeons, I couldn’t,” he says. “I also think it’s inefficient to perform a combined procedure with another surgeon. They are either taking up your OR time by doing a cataract or you’re taking up their OR time by doing a retina case. I also find that a combined surgery is sometimes unnecessary. I almost always have the cataract surgeon do his surgery first, and in cases of borderline macular

This article has no commercial sponsorship.

Dr. Weng is a consultant for Alcon, Alimera Sciences, Allergan/AbbVie, Novartis, DORC, Regeneron, Regeneron and Genentech. **Dr. Devgan** is the owner of CataractCoach.com, a free teaching website. **Dr. Kao** is a consultant for and receives research funding from Johnson & Johnson Vision. **Dr. Stone** has no relevant financial interests to disclose.

disease, patients will be happy with their vision after cataract surgery alone, and not need vitrectomy.”

According to Uday Devgan, MD, who is in practice in Los Angeles, another critical factor is making sure the capsulorhexis overlaps the optic for a full 360 degrees. “If the capsulorhexis is too big, it may be best to wait at least a month to allow the capsular bag to “shrink-wrap” down to hold the lens firmly in place,” he explains.

Dr. Devgan also notes that retinal surgeons often use a gas bubble in the vitreous cavity to hold the retina in place. This gas can stay inside the vitreous cavity for weeks or longer. “If you just do a combined case in the same sitting, that gas bubble may end up pushing the IOL out of the capsular bag,” he warns.

When he performs combined cases, Dr. Devgan prefers to perform the cataract surgery first. “This gives the retina surgeon a much better view,” he says. “Remember that the retina surgeon has to look through either your cataract or your IOL in order to see the retina. Additionally, because the human lens is so thick, it can make access to the vitreous base or the edge of the retina very difficult because your instrument has to go across the eye and not hit that thick lens. Once you have a thin IOL in the eye, access to the vitreous base and the retinal periphery is easier.”

Staged Procedures

Dr. Kao, who works in a private practice setting, typically performs staged procedures. “Our local retina group refers cataract patients to us,” he says. “We do the cataract first, and then once the patient heals, he or she goes back to the retina surgeon. In an academic practice, it’s much easier to perform a combined procedure.”

He adds that a staged procedure is easier for the eye because there is less inflammation overall, and the eye has a chance to heal between

the procedures. “One of the complications of cataract surgery is corneal edema, so if you do the cataract procedure first and allow the eye to heal for a couple of weeks, the retina surgeon will have a much easier time doing the retinal procedure. If you do a combined procedure and the view becomes compromised for some reason, the retina surgery becomes more difficult,” he says.

Additionally, physicians say that certain conditions can benefit from performing staged procedures rather than combined ones.

“**In every case where I’m considering combined surgery, I also present the option of doing it staged. That way, patients will feel reassured that they’re making the most informed decision possible and are playing an active role in their own care.**

— *Christina Weng, MD*

”

“For example, I was recently consulted by one of our local retina colleagues about a patient who had retinal detachment surgery and silicone oil in the eye. The oil needs to stay in the eye for at least six months, but the cataract is already pretty advanced, and the retina specialist is having a difficult time seeing into the back of the eye. He would like me to perform cataract surgery first with the oil still in the eye, and then once the patient reaches six months with the oil in the eye, the retina specialist will perform the silicone oil removal. That course of action would be safer overall for the patient,” Dr. Kao says.

Pearls for Surgery

Dr. Kao recommends a hydrophobic acrylic IOL for cataract patients who also have a retinal condition. “We want to avoid silicone IOLs in those patients because, if a patient needs silicone oil in the future, the vision can be compromised due to fogging of the IOL or adherence of the silicone oil to the IOL,” he says.

Dr. Devgan recommends a monofocal IOL. He advises to avoid lenses that have rings in them, like trifocal or multifocal lenses, because those will compromise some of the vision quality, and these patients may already have a compromised macula.

Dr. Weng recommends teasing out the symptoms as best as you can. “Although it’s impossible to definitively attribute a certain symptom to a specific pathology, it is important for the treating surgeon to tease out the symptoms,” she says. “If a patient presents with a cataract and a very mild epiretinal membrane, and he or she says, ‘I’m having decreased night vision’ or ‘I’m having a lot of glare,’ these are symptoms much more consistent with a cataract versus an epiretinal membrane, which typically presents with blurry vision or metamorphopsia. In situations like that, it may be a better decision to take a staged approach where you remove the cataract and then see how the patient does before you do anything with the epiretinal membrane.”

She adds that there’s an art to making these decisions, and she lets every patient know all the options so that shared decision-making can be practiced. “In every case where I’m considering combined surgery, I also present the option of doing it staged,” Dr. Weng says. “That way, patients will feel reassured that they’re making the most informed decision possible and are playing an active role in their own care.”

Another argument for performing combined surgery is that a vitrectomy can accelerate cataract

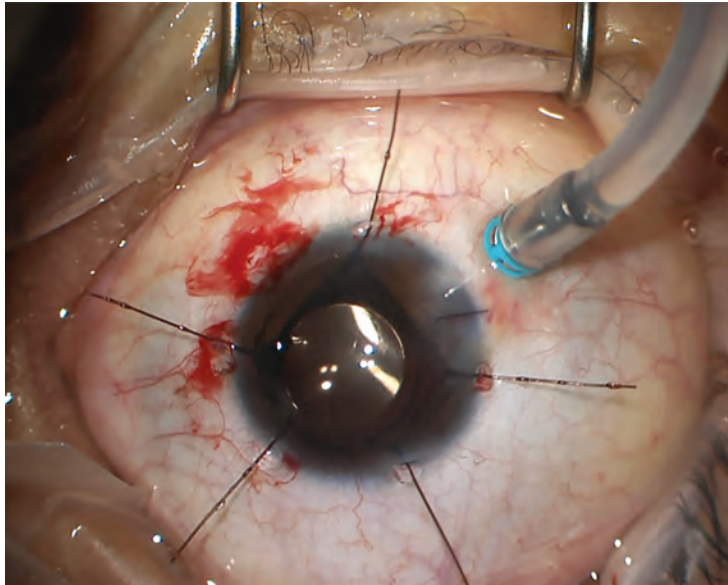
progression within two years. “For many of our elderly patients who are already coming in with a cataract at baseline, it can be beneficial to combine the vitrectomy and cataract surgery so that they can avoid an inevitable second surgery down the road,” she says.

To increase the chances of success in combined cases, Dr. Weng prioritizes communication with her co-surgeon. “Before we even step into the operating room, I like to speak with him or her about trocar placement, wound location, and order of steps,” she says. “That way, the surgical territory is mapped out and neither encroaches upon the other’s space.”

She also has a pearl for retina surgeons: “Most of us use 5- to 10-cc retrobulbar blocks to anesthetize our patients,” Dr. Weng says. “For combined cases, it’s important to remember to limit the volume injected in order to avoid excess posterior pressure. I’ll typically inject 3 cc and then immediately apply pressure to the globe afterwards. Then, I save the rest of the block so that it can be used to supplement anesthesia if needed once the cataract has been taken out.”

Another tip is to consider placing the infusion line at the start of the case. Dr. Weng typically has the cataract surgeon perform his or her procedure first, and then she performs the retina surgery. However, she notes that when trocars are placed during vitrectomy, the globe pressure can be transiently increased to 70 mmHg.

“Obviously, when we’re working alone, this transient pressure spike isn’t as concerning because we don’t



Combined cataract and tractional retinal detachment surgery. Note the corneal suture, which was placed after the cataract extraction. Additionally, the inferotemporal trocar-cannula was pre-placed at the start of the surgery (infusion line was attached later). Both of these elements enhance globe stability, surgeons say.

generally have open wounds,” she says. “But in combined cases where there may be multiple pre-existing wounds (like a 3-mm corneal wound) by the time the field is turned over to me, I prefer to pre-place my infusion line. This way, when I’m ready to start my portion, I simply attach the infusion line without having to worry about globe collapse or prolapse of intraocular contents.”

Dr. Weng highly recommends suturing all wounds in combined cases. Even if a cataract wound might normally be stable without a suture, the retina surgeon may significantly elevate the globe pressure via infusion line placement, scleral depression, or intentionally increasing the infusion pressure for hemostasis. A simple 10-0 nylon suture through the corneal wound, and maybe even the paracenteses, can protect globe stability. “Similarly, I also recommend that retina specialists suture all their sclerotomies,” she adds. “There’s often many wounds by the end of these combined cases, and

you really want to limit the chance of hypotony or other postoperative complications.”

Dr. Devgan advises cataract surgeons to make a longer incision that seals well. “Additionally, sometimes it is easier and more accurate to do the lens calculations before the vitrectomy,” he says. “If the vitreous is removed, the new intraocular lens will tend to sit a little deeper in the eye. So, if I’m doing cataract surgery on a patient who already had a vitrectomy, I actually need to change my lens calculations a bit by adding a little bit to the IOL power. So, in general, lens calculations are a

little bit easier in an eye where you do the cataract first.”

It is also important to check the placement of the IOL. If the vitrectomy is done as the second procedure, Dr. Weng says that the IOL can potentially shift out of place as a result of the manipulation of the eye. “Before I close up on my end, I’ll invite my cataract colleague to come back in and take a quick look,” she says. “If he or she isn’t available, I take a quick look myself to make sure that the intraocular lens is still well-centered.”

The last thing to remember is to counsel the patient and let him or her know that the healing process may be a little bit longer. “In combined surgeries, there can be a bit more injection and inflammation of the globe, which can slightly prolong visual recovery,” Dr. Weng says. “Patients who have had previous cataract surgery in their other eye might be expecting to see well the next day, so I try to prepare patients appropriately so that they have realistic expectations.” ◀

Christina Weng, MD

(Continued from p. 28)


“Furthermore, these gains were achieved with treatment ‘doses’ much lower than those used for patching: one hour per day, six days a week for Luminopia One, versus two to six hours per day—up to 12 hours per day in some cases—seven days a week for eye patching. I don’t think any other digital treatment has shown this kind of efficacy.”

What about limitations? “The VR goggles can be heavy for the youngest children,” Dr. Hunter acknowledges. “However, Luminopia has updated the design so that kids can lie down while watching the programs. Also, treatment using Luminopia One is likely to cost more than patching. However, because it’s been proven to be an effective therapy, I expect it will ultimately be covered by insurance. Meanwhile, for the physician, it should be as simple as prescribing a drug or drop through your electronic health records system, or even using a paper prescription.”

Luminopia One achieved FDA de novo premarket approval for prescription use last fall; the Luminopia One product launch is scheduled for later this year. Meanwhile, the company is developing a series of other devices intended to treat multiple neuro-visual disorders using similar technology, and negotiating with regional and national insurers to obtain coverage for Luminopia One as a pharmacy benefit.

Hope for Amblyopic Adults?

Other recent treatment approaches have been aimed at adults with amblyopia. (Conventional eye patching is generally ineffective for adults.) The only one currently approved by the FDA is RevitalVision, approved for use by patients age 9 and older. This is a prescription “vision-training” software that uses visual exercises involving Gabor patches to stimulate the brain’s visual cortex. The company says that it takes



RevitalVision, FDA-approved for patients 9 years of age and older, gives the patient visual exercises using Gabor patches that gradually improve the brain’s visual processing, increasing visual acuity, contrast sensitivity and stereo acuity, the company says.

advantage of brain plasticity to improve the visual cortex’s processing of incoming visual data in amblyopic adults. The company notes that in contrast to most therapies, this is aimed at the visual cortex rather than the eyes.

Treatment involves 40 training sessions done on a home computer, completed over a period of three months with three to four sessions per week that last 30 minutes on average. The sessions are customized to accommodate the visual ability and working speed of the patient, with results remotely monitored by an eye-care professional.

According to the company, randomized, controlled clinical studies have shown that adults undergoing treatment have an average improvement of 2.5 lines on a visual acuity chart, a 100-percent improvement in contrast sensitivity and significant improvement in stereo acuity. The company also says the technology has been shown to improve vision in other conditions such as congenital nystagmus, and helps patients who are having difficulty neuroadapting after cataract surgery. ◀

1. Friedman DS, Repka MX, Katz J, et al. Prevalence of amblyopia and strabismus in White and African American children aged 6 through 71 months the Baltimore Pediatric Eye Disease Study. *Ophthalmology* 2009;116:2128–34.e1–2.

2. Giordano L, Friedman DS, Repka MX, et al. Prevalence of refractive error among preschool children in an urban population: The Baltimore Pediatric Eye Disease Study. *Ophthalmology* 2009;116:739–46.e1–4.
3. Multi-Ethnic Pediatric Eye Disease Study. Prevalence of amblyopia and strabismus in African American and Hispanic children ages 6 to 72 months in the Multi-Ethnic Pediatric Eye Disease Study. *Ophthalmology* 2008;115:1229–36.e1.
4. Birch EE, Kelly KR, Giaschi DE. Fellow eye deficits in amblyopia. *J Binocul Vis Ocul Motil* 2019;69:116–125.
5. Kelly KR, Jost RM, De La Cruz A, Birch EE. Amblyopic children read more slowly than controls under natural, binocular reading conditions. *J AAPOS* 2015;19:515–520.
6. Kelly KR, Morale SE, Beauchamp CL, et al. Factors associated with impaired motor skills in strabismic and anisometropic children. *Invest Ophthalmol Vis Sci* 2020;61:43.
7. Webber A. The functional impact of amblyopia. *Clin Expl Optom* 2018;101:443–450.
8. O’Connor AR, Birch EE, Anderson S, Draper H. The functional significance of stereopsis. *Invest Ophthalmol Vis Sci* 2010;51:2019–2023.
9. Grant S, Suttle C, Melmoth DR, et al. Age- and stereovision-dependent eye-hand coordination deficits in children with amblyopia and abnormal binocularity. *Invest Ophthalmol Vis Sci* 2014;55:5687–5701.
10. Niechwiej-Szwedo E, Goltz HC, Colpa L, et al. Effects of reduced acuity and stereo acuity on saccades and reaching movements in adults with amblyopia and strabismus. *Invest Ophthalmol Vis Sci* 2017;58:914–921.
11. Webber A, Wood JM, Gole GA, Brown B. The effect of amblyopia on fine motor skills in children. *Invest Ophthalmol Vis Sci* 2008;49:594–603.
12. Birch EE, Castañeda YS, Cheng-Patel CS, et al. Self-perception of school-aged children with amblyopia and its association with reading speed and motor skills. *JAMA Ophthalmol* 2019;137:167–173.
13. Webber A, Wood JM, Gole GA, Brown B. Effect of amblyopia on self-esteem in children. *Optom Vis Sci* 2008;85:1074–1081.
14. Birch EE, Castañeda YS, Cheng-Patel CS, et al. Self-perception in children aged 3 to 7 years with amblyopia and its association with deficits in vision and fine motor skills. *JAMA Ophthalmol* 2019;137:499–506.
15. Hatt SR, Leske DA, Castañeda YS, et al. Understanding the impact of residual amblyopia on functional vision and eye-related quality of life using the PedEyeQ. *Am J Ophthalmol* 2020;218:173–181.
16. Williams C, Northstone K, Howard M, et al. Prevalence and risk factors for common vision problems in children: Data from the ALSPAC study. *Br J Ophthalmol* 2008;92:959–64.
17. Williams C, Harrad R. Amblyopia: Contemporary clinical issues. *Strabismus* 2006;14:43–50.
18. Williams C, Harrad RA, et al. Screening for amblyopia in preschool children: Results of a population-based, randomised controlled trial. *Ophthalmic Epidemiol* 2001;8:279–95.
19. Shah SS, Jimenez JJ, Rozema EJ, et al. Validation of the Pediatric Vision Scanner in a normal preschool population. *J AAPOS* 2021;25:4:216.e1-216.e4.
20. Bosque LE, Yamarino CR, Salcedo N, et al. Evaluation of the Blinq Vision Scanner for detection of amblyopia and strabismus. *J AAPOS* 2021;25:4:214.e1-214.e7.
21. Devlieger A, Youssefi A, Cordonnier M. Evaluation of the Blinq Vision Screener in the detection of amblyopia and strabismus in children. *Transl Vis Sci Technol* 2022;11:4:10.
22. Jost RM, Stager Jr D, Dao L, et al. High specificity of the Pediatric Vision Scanner in a private practice pediatric primary care setting. *Journal of AAPOS* 2015;19:521–5.
23. Xiao S, Anjeli A, Wu HC, et al. Randomized controlled trial of a dichoptic digital therapeutic for amblyopia. *Ophthalmology* 2022;129:1:77–85.

COMING IN SEPTEMBER TO

REVIEW
of OPTHALMOLOGY

CORNEAL DISEASE SUPPLEMENT

SECTIONS AND AUTHORS:

A Review of the Diagnosis and Management of Blepharitis

Charles Bouchard, MD, chair of ophthalmology at Loyola University Medical Center in Chicago

An expert shares his best practices when evaluating and treating patients for this condition. This will cover a lot of the issues surrounding meibomian-gland-deficiency-based dry eye.

How to Evaluate and Manage Patients with Corneal Disease Who Are Interested in Presbyopic IOLs

Asim Piracha, MD, associate professor at the University of Louisville's Department of Ophthalmology and Visual Sciences

The author reviews corneal conditions that might be contraindications—and why—as well as those that can be treated and possibly allow a patient to receive a presbyopic lens.

An Update on Cutting-edge Corneal Transplant Techniques

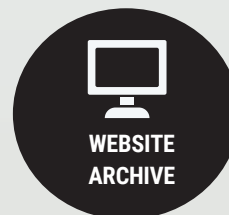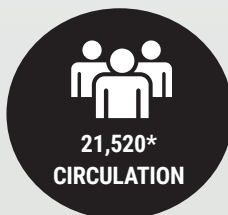
Thomas John, MD, our cornea section editor and clinical associate professor, Loyola University at Chicago.

The article will explore the latest results with exciting new methods such as Descemet's-stripping Only (DSO) and the injection of cultured endothelial cells.

The Use of Artificial Intelligence in Corneal Disease Management

Christine Leonard, Senior Associate Editor

Artificial intelligence is making waves in subspecialties like retina and glaucoma, and now there's a buzz about it in cornea, too. Here, experts discuss the latest work on the use of AI for diagnosing and managing corneal disease.



*Source: BPA circ. statements for the 6-month period ending January 2022

For advertising opportunities, contact your Review representative today:

Michele Barrett
(215) 519-1414
mbarrett@jobson.com

Jon Dardine
(610) 492-1030
jdardine@jobson.com

Michael Hoster
(610) 492-1028
mhoster@jobson.com



EDITED BY KULDEV SINGH, MD, MPH,
AND PETER A. NETLAND, MD, PHD

GLAUCOMA MANAGEMENT

Gene Therapy and Glaucoma: An Update

Advances in genetic manipulation are showing promise for mitigating glaucomatous damage and preserving sight.

AHMARA G. ROSS, MD, PHD
PHILADELPHIA

Traditional models of treating glaucoma have centered on the one factor we know reduces the risk of progression for most patients: lowering intraocular pressure. However, with the advent of gene therapy as a potentially viable way to preserve vision, new modalities for managing glaucoma may soon become available.

As a researcher and clinician, I'm very interested in finding ways to keep retinal ganglion cells and neurons alive, and gene therapy is showing promise as a way to do that. However, many clinicians aren't well-acquainted with this technology, for two reasons. First, it's not widely used in practice right now because of the limited patient populations eligible for the few gene therapy treatments that have been approved by the U.S. Food and Drug Administration. Second, many clinicians haven't studied this topic since medical school.

With that in mind, I'd like to provide a brief review of the concepts behind gene therapy; discuss the use of gene therapy in current human trials; and review a neuroprotective therapy currently in development that's relevant to glaucoma management. The latter, which we're

working on in our lab, is in the pre-clinical development phase but is quickly moving into the clinical phase.

Gene Therapy: The Basics

Every cell in our body contains genes made up of DNA, the genetic material that humans and almost every other organism uses to multiply themselves, as well as to multiply the cells that make up their bodies. Some of the DNA encodes information that allows the genes to construct proteins; those proteins help to build the body and help it function. The catch is that mutations in our genes can develop over time or be inherited. Those mutations may then create abnormal proteins that can impact our bodies and our health.

A classic example is one most of us learned about in medical school: sickle cell anemia. In this disease, an inherited mutation causes a subtle change in the way a key protein in red blood cells is folded. That, in turn, alters the way the cells are shaped, causing them to act differently, resulting in the disease.

Gene therapy involves introducing, removing or changing genetic material within cells to repair or compensate for the loss of function in a gene. Altering genetic material allows us to increase or overexpress

proteins that will fight a disease, or even produce new proteins for this purpose. We've been doing this in the laboratory for a while now by using what's called "small interfering RNA," or siRNA, to interfere with the expression of specific genes, preventing them from forming proteins.

This is the science that allowed the creation of the COVID-19 vaccines. These vaccines included genetic material that taught our cells to make a protein resembling the spikes on the COVID virus. That protein was sufficient to get our immune systems to generate a defensive response that allowed us to avoid getting tremendously sick from the coronavirus.

As you can see, the idea of producing new proteins or modified proteins to fight disease is already at the cutting edge of vaccine therapy—and we're getting closer to using similar technology to treat and potentially cure eye diseases.

Approaches to Gene Therapy

Gene therapy can be used to treat human disease via:

- **Gene replacement.** Jean Bennett, MD, PhD, is a pioneer in this approach. She created Luxturna, the first licensed gene therapy for Leber's Congenital Amaurosis (LCA), a rare, inherited eye disorder. (I had the good fortune to be mentored by Dr. Bennett here at the University of Pennsylvania.) This approach replaces a mutated gene that's not working with a working gene.

- **Gene silencing.** This approach delivers messenger RNA that stops the production of a protein.

- **Gene editing.** This uses the so-called CRISPR technology, which has been written about a lot lately. (CRISPR stands for "clustered

This article has no commercial sponsorship.

Dr. Singh is a professor of ophthalmology and chief of the Glaucoma Division at Stanford University School of Medicine. Dr. Netland is Vernah Scott Moyston Professor and Chair at the University of Virginia in Charlottesville.

VECTORS USED FOR GENE THERAPY

Viral Vectors			Non-viral Vectors		
RNA Viruses	DNA Viruses		DNA Material		Protein
Retroviruses	Adenovirus	Adeno-associated Virus	Liposomes	"Naked" DNA	Cell-based Therapy

regularly interspaced short palindromic repeats.” It uses repeated letters of the genetic code to tell an enzyme exactly where to cut a strand of DNA.) The CRISPR technique uses a guide RNA to potentially alter a gene within the patient’s genome. It’s a very effective technique, and we’ll likely see more of it used in relation to treating human disease.

- **Gene addition.** This technique causes overexpression of a gene that can positively impact a disease state. This technique is useful when a protein is already being made, but we need more of it so that cells can survive or prevent the disease altogether. We’re working on some treatments involving this approach here at the University of Pennsylvania.

Getting Material into the Cells

The other part of this that’s important to understand is the methods we use to introduce this genetic material into the cells. Genetic material is delivered by what we call vectors, courier particles that carry the new genetic information to the cells.

Currently, we primarily use two kinds of vectors:

- **Viral vectors.** These can be RNA viruses, such as retroviruses, or DNA viruses, which would include adenoviruses and adeno-associated viruses. These viruses introduce our genetic material into a cell in much the same way a standard virus would. (In our lab we’re using mostly adeno-associated viruses, because adenoviruses cause some immune-system-related problems not seen with adeno-associated viruses. We deliver the adeno-associated virus material via an intraocular injection.)

- **Nonviral vectors.** These can be

DNA-related material such as liposomes, “naked” DNA or simple proteins, an approach that’s also referred to as “cell-based therapy.” The genetic material that we got from the COVID vaccines was delivered in liposome form, for example.

As a point of clarification, retroviruses (one of the viral vector options) are a type of RNA virus that can take RNA and turn it into DNA. For example, HIV is a retrovirus that can do this. This ability contradicts one of the central dogmas many of us learned in biology class, that DNA is stable and can generate RNA, which then creates proteins, while RNA generally can’t be turned back into DNA. In actuality, some retroviruses can transform RNA back into DNA, and some can even insert that DNA into your genome. (We don’t use those in our lab, because it’s hard to control where the genes end up in your genome. We wouldn’t want this to cause a loss of function in some area unrelated to the disease we’re trying to treat. It’s more straightforward to deliver stable DNA using an adeno-associated virus or adeno-virus.)

Once you get the material to the cells, there are several ways in which the vector can interact with the genetic material. The choice you make in this area helps to answer other important questions. For example, once the material gets into the cell, do you want it to be turned on in every cell in your body (referred to as “ubiquitous” delivery), or only in certain specific cells (“cell-specific” delivery)?

This is managed by what’s called the promoter sequence, a sequence of genetic information that sits in

front of the therapeutic gene. It’s like a very specific key to a door that enables the process to be turned on or off, regulating whether the cell starts generating mRNA and protein. If the key doesn’t fit, the door won’t open. The promoter can be a master key, starting the process in every cell, or a specific key that only starts it in one particular type of cell. This gives us a way to control which cells end up producing the protein.

Of course, additional cell selectivity can be achieved by proximity—where you inject the gene therapy. (This is a key part of what makes Luxturna an effective therapy.) This is an important factor when injecting things into the eye, because the eye is a tremendously immunoprivileged organ; there’s very little crossover into the body.

Our Work Protecting Cells

As noted earlier, our lab is working on genetic treatments that may help preserve vision in glaucoma patients, using adeno-associated viruses to deliver genetic material to retinal ganglion cells. We’re using this method to get the cells to produce a protein that’s been shown to be protective of ganglion cells: SIRT1.

The preclinical studies of our treatment were done using an animal model. One of our early experiments, intended to demonstrate the validity of this approach, involved delivering genetic material designed to make cells in the retina produce a fluorescent green protein not normally produced by these cells. To introduce the material into a rodent eye, we’d cut down the conjunctiva and insert our vector material into a small syringe; then we’d insert the

needle just under the lens, being careful not to hit it. At first, we were able to get about 42 percent of the cells to produce the protein using this approach. Since then, we've been able to increase the percentage of cells producing the desired protein significantly.

In any case, part of the importance of this experiment is that the cells expressing the protein can be counted. That's crucial, because that allows us to quantify the strength of the vector, and to test it for safety; we can see if the vector is reaching the cells we want it to reach. In this case, we wanted the vector to reach cells in the retinal ganglion cell layer, and histological studies have demonstrated that very few cells outside the RGC layer ended up producing the fluorescent green protein.

Of course, the green fluorescent protein won't cure any human disease, but there are proteins that we can use to influence human disease, such as SIRT1. My senior mentor and main collaborator, Kenneth S. Shindler, MD, PhD, has conducted numerous studies demonstrating SIRT1's ability to keep RGCs alive in the face of injury from optic neuritis and optic nerve crush.¹⁻⁷ So we thought: What if we could make these cells create more SIRT1 using gene therapy in a cell-specific manner? Our hope was that the retinal ganglion cells expressing SIRT1 would be able to avert some of the damage caused by injuries to the optic nerve.

Our studies demonstrated that the treatment did cause the ganglion cells to increase their production of SIRT1, as much as a thousandfold. So the next question was, would this be protective if the intraocular pressure was raised?

To find out, we injected microbeads into the anterior chamber of the eye; the beads then ended up in the iridocorneal angle, blocking fluid access to the trabecular meshwork. This caused the pressure to rise, and as their IOP was sustained and elevated, the mice began to lose vision, just as people do. (Importantly, that loss of vision correlates very well with the loss of retinal ganglion cells, giving us a structure/function correlation.) We also had a control group of mice that received BSS instead of microbeads. Then, some mice received our therapeutic injection, while others received a sham injection consisting of the genetic material that causes the production of green fluorescent proteins—which has no therapeutic capacity—instead of SIRT1.

The therapy was indeed successful, as shown in the graphs. The mice with elevated pressure that didn't receive therapy lost vision over time, but those receiving the genetic treatment had prolonged visual capacity. Counting the surviving retinal ganglion cells also showed the same result; more RGCs survived when the eye received the genetic therapy. That suggests two things: first, that RGCs are responsible for maintaining vision in the eye,

and second, that our genetic SIRT1 therapy can be protective against IOP-related cell damage.

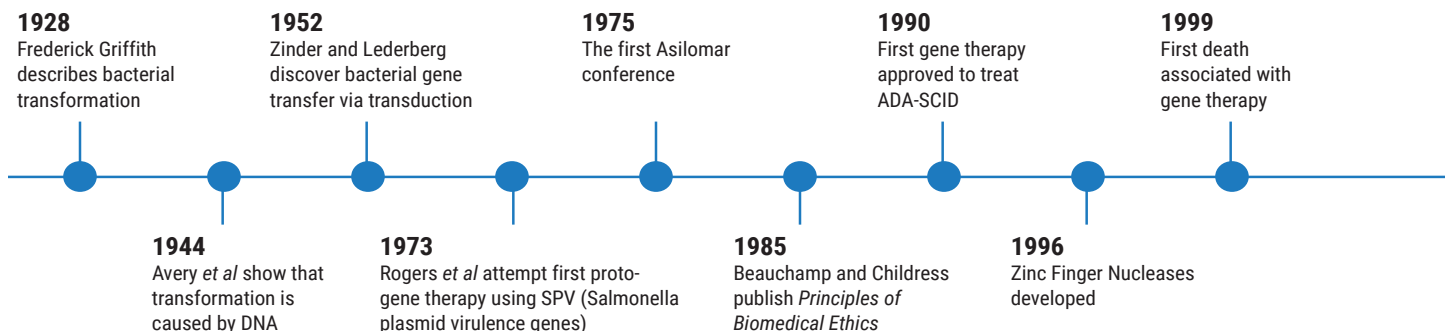
Further confirmation was provided by measuring axon density in the eyes. The axons are the fibers that take the information from the retinal ganglion cells to the brain. Normally, the axons are numerous, dense and healthy. The mice that received microbeads without our therapy showed a loss of axon density, while those receiving the therapy showed a reduced level of axon damage. (These data have been submitted for publication.)

Just Getting Started

For a while now, gene therapy has represented a true paradigm shift in the treatment of optic neuropathies. So far, the impact has been limited; the successful treatment of Leber's, for example, only affects a small number of patients. (The disease is terrible, but it's not a common optic neuropathy.) However, treatments addressing more common optic neuropathies like glaucoma, ischemic optic neuropathy and inflammatory optic neuropathies are in the works. Our lab has shown that using genetic modification to enhance SIRT1 production can be very effective at preventing ganglion cell loss and degeneration in multiple models of optic nerve disease, and many other efforts along similar lines are currently under way.

However, these options are still in the preclinical stage, and we want to proceed with caution. The history

A BRIEF HISTORY OF GENE THERAPY



CURRENT CLINICAL TRIALS FOR OPTIC NERVE DISEASE

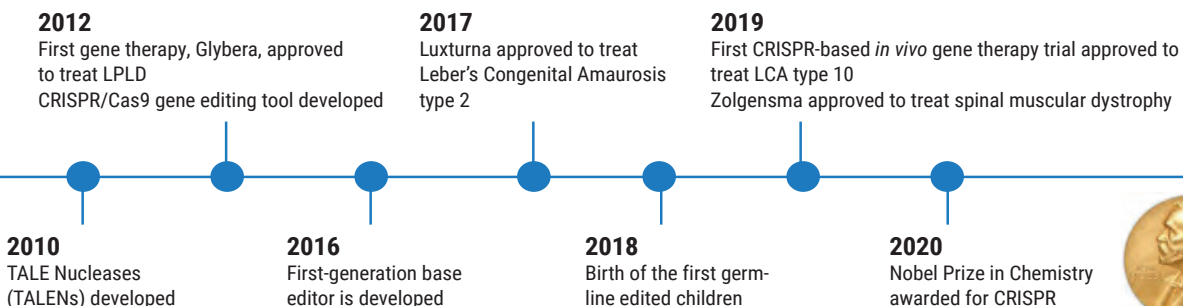
Trials	Eye-specific Diagnosis	Location	Trial Summary	Phase	Trial Endpoints
Dual Intravitreal Implantation of NT-501 Encapsulated Cell Therapy for Glaucoma	Glaucoma	Stanford University	To determine the safety and efficacy of dual NT-501 CNTF encapsulated cell therapy (ECT) on visual impairment related to glaucoma	Phase II	Endpoints: visual fields, structure measurement of GCIPL and RNFL
Study of NT-501 Encapsulated Cell Therapy for Glaucoma Neuroprotection and Vision Restoration	Glaucoma	Stanford University	To determine efficacy of NT-501 CNTF encapsulated cell therapy on visual impairment from glaucoma	Phase II	Endpoints: visual fields, structure measurement of GCIPL and RNFL
RESCUE and REVERSE Long-term Follow-up	Leber's Congenital Optic Neuropathy	GenSight Biologics	To assess the long-term and efficacy of GS010 and quality of life in subjects with LHON due to the G11778A mitochondrial mutation in patients five years post treatment	Phase III	Adverse events, BCVA and HVF
Safety Study of an Adeno-associated Virus Vector for Gene Therapy of Leber's Hereditary Optic Neuropathy	Leber's Congenital Optic Neuropathy	National Eye Institute	To study the potentially toxic effects of scAAV2-P1ND4v2 in patient with LHON and the G11778A mitochondrial gene mutation	Phase I	Assessment of toxicity

of this field illustrates why this is so important. Gene therapy has been successfully used to treat human disease back as far as 1990, but nine years later, the first death connected with gene therapy occurred. This caused everyone to backpedal. As a result of that death, many regulations were put in place to ensure a greater level of safety for patients.

Partly for that reason, the next gene therapy—Glybera (alipogene

tiparvovec), designed to reverse lipoprotein lipase deficiency that can cause severe pancreatitis—wasn't approved until 2012. This was followed by another five-year gap before Luxturna was approved to treat LCA Type 2 retinal degeneration in 2017. Those circumstances have led us to create more careful, thorough trials before we use a gene therapy in humans, to make sure it's both safe and effective.

This brings us to a very practical clinical issue. Many clinicians have worked with patients who've had the terrible experience of losing vision because of optic neuropathies or glaucoma. Today, as awareness of gene therapy has grown, patients in this situation almost always ask if there's a clinical trial they can get into. Unfortunately, there are individuals out there conducting "clinical trials" that aren't approved



or monitored, giving hope to these patients while putting them at risk.

For that reason, part of our job is to help steer these patients in the right direction. If you're looking for a trial that has regulatory oversight, I recommend visiting asgct.org/clinicaltrials, a database showing currently active clinical trials. For example, there are currently two clinical trials relating to glaucoma, both out of Stanford, and two for Leber's hereditary optic neuropathy, the RESCUE and REVERSE trials. The people in those trials are very stringently selected, to ensure that no harm can come to them, and the data can be used to monitor meaningful effects.

So, when patients come to me asking about studies or investigators they've heard about in which healthy eyes are being injected with genes or cell-based therapies, I go to this website to make sure the study

has been submitted. If it hasn't, then I have to have another kind of conversation with the patient. I have to explain that some trials out there are not necessarily safe, and not in the best interests of the patient. Some patients may be adamant about proceeding, but at least I can warn them about the risk they may be taking.

We're on the verge of a new era in treatment for glaucoma and other optic neuropathies. These emerging genetic technologies for treatment are going to move us beyond just prescribing a drop to lower the pressure. Within a few years our focus may shift to strategies that help to keep those vision-providing retinal cells happy and alive. That's a revolution we can all look forward to. ◀

1. Ross AG, McDougald DS, Khan RS, et al. Rescue of retinal ganglion cells in optic nerve injury using cell-selective AAV mediated delivery of SIRT1. *Gene Ther* 2021;28:5:256-264.
2. McDougald DS, Dine KE, Zezulin AU, Bennett J, Shindler KS. SIRT1 and NRF2 gene transfer mediate distinct neuroprotective effects upon retinal ganglion cell survival and function in experimental optic neuritis. *Invest Ophthalmol Vis Sci* 2018;59:3:1212-1220.

3. Zuo L, Khan RS, Lee V, et al. SIRT1 promotes RGC survival and delays loss of function following optic nerve crush. *Invest Ophthalmol Vis Sci* 2013;54:7:5097-102.

4. Khan RS, Fonseca-Kelly Z, Callinan C, et al. SIRT1 activating compounds reduce oxidative stress and prevent cell death in neuronal cells. *Front Cell Neurosci* 2012;6:63.
5. Shindler KS, Ventura E, Rex TS, Elliott P, Rostami A. SIRT1 activation confers neuroprotection in experimental optic neuritis. *Invest Ophthalmol Vis Sci* 2007;48:8:3602-9.
6. Khan RS, Dine K, Das Sarma J, Shindler KS. SIRT1 activating compounds reduce oxidative stress mediated neuronal loss in viral induced CNS demyelinating disease. *Acta Neuropathol Commun* 2014;2:3.
7. Ross AG, Chaqour B, McDougald DS, et al. Selective upregulation of SIRT1 expression in retinal ganglion cells by aav-mediated gene delivery increases neuronal cell survival and alleviates axon demyelination associated with optic neuritis. *Biomolecules* 2022;12:6:830.

ABOUT THE AUTHOR



Dr. Ross is an assistant professor of ophthalmology and neurology at the University of Pennsylvania and Scheie Eye Institute, in the divisions of glaucoma and neuro-ophthalmology. She's received research funding from the National Institutes for Health and Gyroscope Therapeutics, recently acquired by Novartis.

REVIEW of OPHTHALMOLOGY

OPHTHALMIC Product Guide



Hold your mobile device over the code to view reviewofophthalmology.com/publications/archive.



E-BLAST PRODUCT SHOWCASE!

In addition to mailing the print edition and hosting the digital versions of the Product Guide on our website, we will be blasting each company's listings to our MD email database! Each company will have a designated product showcase deployment day following distribution of the print editions, providing an additional opportunity to receive more information on all the items you want!

Innovative products to enhance your practice

Experience *Review's* Product Guide in print or digital. Simply select the products, devices or services you'd like to be contacted about for more information.





“ I didn't realize
STARS
were little dots that twinkled ”

—Misty L, *RPE65* gene therapy recipient

**WE'RE SEEING
AMAZING RESULTS.
AND SO ARE THEY.**

At the Foundation Fighting Blindness our mission is everybody's vision. Our work shines a light on the darkness of inherited retinal diseases (IRDs).

We're the world's leading organization searching for treatments and cures. We need your help to fuel the discovery of innovations that will illuminate the future for so many. We have robust disease information, a national network of local chapters and support groups, local educational events, and our My Retina Tracker® Registry to help keep your patients connected with clinical and research advancements.

Help accelerate our mission
by donating at ECPs4Cures.org.

**FOUNDATION FIGHTING
BLINDNESS**

FightingBlindness.org



I was only seeing light flashes early on, but light

FLASHES

when you've not seen anything for
so many years—it was wonderful

—Keith H, retinal prosthesis recipient

**WE'RE SEEING
AMAZING RESULTS.
AND SO ARE THEY.**

At the Foundation Fighting Blindness our mission is everybody's vision. Our work shines a light on the darkness of inherited retinal diseases (IRDs).

We're the world's leading organization searching for treatments and cures. We need your help to fuel the discovery of innovations that will illuminate the future for so many. We have robust disease information, a national network of local chapters and support groups, local educational events, and our My Retina Tracker® Registry to help keep your patients connected with clinical and research advancements.

Help accelerate our mission
by donating at ECPs4Cures.org.

**FOUNDATION FIGHTING
BLINDNESS**

FightingBlindness.org

PRODUCT NEWS

New items on the market to improve clinical care and strengthen your practice.

► CONTACT LENSES

B+L Launches Revive Custom Soft Contact Lenses

With the goal of providing a more individualized vision-correcting solution to a broad range of patients, Bausch + Lomb recently launched a new family of customizable soft contact lenses called Revive. The product line includes spherical, toric, multifocal and multifocal toric options.

Revive lenses are made of a non-ionic material that helps resist protein deposits, B+L says, allowing for up to three months of daily wear; the replacement schedule is at the discretion of the doctor. The company explains that the customizable parameters include lens diameter, base curve and power, all of which can be adjusted as needed until the optimal fit is achieved.

Toric lens versions include what B+L calls “dual elliptical stabilization,” a process for ballasting that adds material with more forethought toward achieving the optimal shape and position than traditional “slab-off” designs. The company says this aids in orientation and rotational stability.

For multifocal fits, the near-zone diameter is customizable from 1.8 mm to 3 mm to account for small-pupil patients or other circumstances where a non-standard design is desired.

For more information, visit bauschsvp.com.

B+L's new BioTrue Hydration Plus Multi-purpose Solution

A growing number of people today are opting to use natural products to manage their well-being, for reasons such as ingredient transparency and the potential for reduced side effects. Several eyecare companies offer contact lenses and solutions that cater to lens wearers in search of a more natural and preservative-free option, one example being Bausch + Lomb's BioTrue line.

The company recently launched a new addition to BioTrue's product portfolio called Hydration Plus Multi-purpose Solution, which B+L says matches the pH of healthy tears and keeps lenses moist for 12 hours.

Compared with BioTrue Multi-purpose Solution, the formula in Hydration Plus contains 25 percent more hyaluronan, a moisturizer found in tears that helps the lenses to maintain moisture, the company explains in the press release. It's also made up of a unique combination of other ingredients including potassium, an electrolyte and erythritol, an antioxidant that protects hyaluronan against free radicals, all of which help to maintain

ocular surface homeostasis, says B+L. The solution is now available in a multi-dose, eco-friendly bottle.

For more information, visit biotrue.com.

► THERAPEUTICS

Help for Vernal Keratoconjunctivitis

Vernal keratoconjunctivitis is uncomfortable for young patients and can damage the ocular surface if left untreated. A variety of steroids and antihistamines are typically prescribed to manage the rare condition. A new contending therapeutic—Verkazia—is a cyclosporine 0.1% emulsion that blocks the release of pro-inflammatory cytokines, thereby suppressing the immune system and reducing inflammation, manufacturer Santen says.

Clinical trials of Verkazia demonstrated improvements in corneal inflammation (keratitis score) and ocular itching, the company said. The company also noted that the most common side effects, occurring in more than 5 percent of patients, typically during instillation, were eye pain (12 percent) and eye itch (8 percent).

In addition to providing vernal keratoconjunctivitis patients with symptomatic relief, Verkazia may also mitigate their chances of developing vision-threatening complications such as shield ulcers, according to Santen.

For more information, visit verkazia.com.

► VITRECTOMY TECH

Upgrades to B+L's Stellaris Elite Vision Enhancement System

Users of Bausch + Lomb's Stellaris Elite machine are getting some new tweaks that might help them in their vitreoretinal surgical cases, the company says.

In the first of what it says will be a series of efficiency-enhancing upgrades to its Stellaris Elite system, Bausch + Lomb has increased the maximum vacuum setting and enhanced the trocar/cannula removable valve caps. The company says the vacuum increase from 600 to 660 mmHg will provide a 10-percent boost in vacuum capabilities and an approximately 8-percent increase in vitreous removal efficiency.

The enhancements to the removable valve caps increase the central thickness of the valve by 33 percent, with a reduction of each segment of the tri-slit profile, the device's maker says. B+L believes that these changes, which became available in July, will improve the machine's fluidic stability during delicate surgical maneuvers.

For more information, visit bauschsurgical.com.

Outdoor Activities and Myopia Development

Scientists evaluated the efficacy of time outdoors per school day over two years on myopia onset and shift, as part of a prospective, cluster-randomized, examiner-masked, three-arm trial.

They included 6,295 students ages 6 to 9 from 24 primary schools in Shanghai, China, stratified and randomized by school in a 1:1:1 ratio to control (n=2,037), test I (n=2,329) or test II (n=1,929) group.

An additional 40 or 80 minutes of outdoor time was allocated to each school day for test I and II groups. Children in the control group continued their habitual outdoor time. Objective monitoring of outdoor and indoor time, and light intensity each day was measured with a wrist-worn device during the second-year follow-up.

Main outcome measures included the two-year cumulative incidence of myopia (defined as cycloplegic spherical equivalent [SE] of ≤ -0.5 diopters at the right eye) among the students without myopia at baseline and changes in SE and axial length (AL) after two years.

Here are some of the findings:

- The unadjusted two-year cumulative incidence of myopia was 24.9 percent for controls, 20.6 percent for the test I group, and 23.8 percent for test II group.
- The adjusted incidence decreased by 16 percent [Incidence Risk Ratio (IRR)=0.84; CI, 0.72 to 0.99; $p=0.035$] in test I and 11 percent (IRR=0.89; CI, 0.79 to 0.99; $p=0.041$) in test II when compared

with the control group.

- The test groups showed less myopic shift and axial elongation compared with the control group:
 - test I: -0.84 D and 0.55 mm;
 - test II: -0.91 D and 0.57 mm;
 - control: -1.04 D and 0.65 mm.
- No significant difference was found in the adjusted incidence of myopia and myopic shift between the two test groups.
- The test groups had similar outdoor time and light intensity (test I: 127 \pm 30 minutes/day and 3,557 \pm 970 lux/minute; test II: 127 \pm 26 minutes/day and 3,662 \pm 803 lux/minute), but significantly more outdoor time and higher light intensity compared with the control group (106 \pm 27 minutes/day and 2,984 \pm 806 lux/minute).
- Daily outdoor time of 120 to 150 minutes at 5,000 lux/minutes or cumulative outdoor light intensity of 600,000 to 750,000 lux significantly reduced the IRR by 17 to 31 percent.

Scientists wrote that increasing outdoor time reduced the risk of myopia onset and myopic shifts, especially in nonmyopic children. They added that the protective effect of outdoor time was related to the duration of exposure as well as light intensity. Finally, they noted, the dose-response effect between test I and test II wasn't observed probably due to insufficient outdoor time achieved in the test groups, suggesting that proper monitoring on the compliance of outdoor intervention is critical to see the protective effect.

Ophthalmology 2022. June 29.

[Epub ahead of print].

XiaHe X, Sankaridurg P, Wang J, et al.

GCC Thinning and Vision QOL

Researchers wrote that faster structural changes may be associated with worse vision-related quality of life in patients with glaucoma. As such, they evaluated the association between the rate of ganglion cell complex (GCC) thinning and the Visual Function Questionnaire in glaucoma.

This retrospective analysis of a longitudinal cohort was designed in October 2021. Patients were enrolled from the Diagnostic Innovations in Glaucoma Study and the African Descent and Glaucoma Evaluation Study. Two hundred thirty-six eyes of 118 patients with diagnosed or suspected glaucoma were followed up with imaging for a mean of 4.1 years from September 2014 to March 2020.

The Visual Function Questionnaire was evaluated using the 25-item National Eye Institute Visual Function at the last follow-up visit. GCC thickness was derived from macular optical coherence tomography scans and averaged within three circular areas (3.4 degrees, 5.6 degrees and 6.8 degrees from the fovea) and superior and inferior hemiregions. Linear mixed-effects models were used to investigate the association between the rate of GCC thinning and Rasch-calibrated Visual Function Questionnaire score.

The mean (SD) age was 73.2 (8.7) years, 65 participants (55.1 percent) were female, and 53 participants (44.9 percent) were African American. Race was self-reported by the participants. Here were some of the findings:

- Mean composite Rasch-cal-

brated National Eye Institute Visual Function Questionnaire score was 50.3 (CI, 45.9 to 54.6).

- A faster annual rate of global GCC thinning in the better eye was associated with a higher disability reflected by the composite National Eye Institute Visual Function Questionnaire score (-15 [CI, -28.4 to -1.7] per 1 μm faster; $p=0.03$).

- When stratified by degrees from the fovea, the 5.6-degree and 6.8-degree areas were associated with the composite National Eye Institute Visual Function Questionnaire Rasch-calibrated score (-14.5 [CI, -27 to -2] per 1 μm faster; $R^2=0.201$; $p=0.03$; and -23.7 [CI, -45.5 to -1.9] per 1 μm faster; $R^2=0.196$; $p=0.02$, respectively), and -8 (CI, -16.8 to 0.8) per 1 μm faster for the 3.4-degree area ($R^2=0.184$; $p=0.07$) after adjusting for confounding factors.

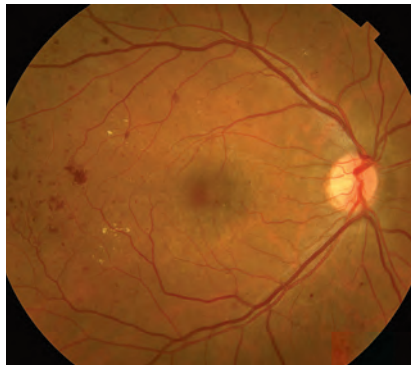
Researchers wrote that the findings suggested that faster and sectoral central location of ganglion cell complex thinning provided useful information in determining the risk of vision-related quality of life in glaucoma. They added that monitoring macular structure may be useful for determining the risk of functional impairment in glaucoma.

JAMA Ophthalmol 2022. June 4. [Epub ahead of print].

Nishida T, Moghimi S, Mohammadzadeh, et al.

RUBY Trial: Mixed Results of Combination Therapy for DME

When paired with aflibercept, nesvacumab, an investigational human antibody that inhibits angiopoietin 2 (Ang2), has shown no additional visual benefits in patients with diabetic macular edema after 36 weeks, according to published results of the Phase



DME proved to be a tough opponent to an aflibercept-nesvacumab combo.

II RUBY randomized trial, funded by Regeneron Pharmaceuticals and Bayer HealthCare.¹

The reported efficacy, and subsequent Food and Drug Administration approval, of the bispecific antibody faricimab has generated interest in retinal treatments that target both the Ang2 and vascular endothelial growth factor pathways.

Despite the visual acuity findings, the RUBY study authors, led by David M. Brown, MD, said that a combination using a high dose of nesvacumab with aflibercept showed a signal of greater efficacy in reducing central subfield thickness than intravitreal aflibercept injections (IAI) alone. Dr. Brown is with the Retina Consultants of Texas in Houston, and also consults for Regeneron.

The trial randomized 302 eyes 1:2:3 to nesvacumab 3 mg and aflibercept 2 mg (low dose, LD/IAI), nesvacumab 6 mg plus aflibercept 2 mg (high dose, HD/IAI) or IAI 2 mg at baseline and weeks four and eight. The LD/IAI arm continued at q8 weeks; the HD/IAI arm was rerandomized at week 12 to q8- or q12-week dosing; and the IAI arm continued on q8- or q12-week dosing or switched HD/IAI combination q8

weeks through week 32.

At week 12, improvements in best-corrected visual acuity for the LD/IAI and HD/IAI and IAI arms were 6.8, 8.5 and 8.8 letters, respectively. Changes at 36 weeks were similar.

CST changes (standard deviation) at week 12 for the three respective arms were -169.4 (155.86), -184 (143.69) and -174.6 μm (160.36, $p=0.0183$ HD/IAI vs. IAI). At week 36, the changes were:

- -210.4 μm for the LD/IAI arm ($p=0.004$);
- -223.4 μm for the q8-week HD/IAI arm ($p=0.0365$);
- -193.7 μm for the q12-week HD/IAI arm ($p=0.0454$);
- -161.9 μm for the IAI q8-week arm (no p value);
- -210.4 μm for the IAI q12-week arm ($p=0.9266$); and
- -203.7 μm for the IAI to HD/IAI arm ($p=0.4116$).

Other key 36-week outcomes reported for the LD/IAI, HD/IAI and q12-week IAI arms were:

- Proportion of eyes with complete resolution of fluid at the foveal center: 75.6 ($p=0.2029$), 86.4 ($p=0.0188$) and 70.8 percent ($p=0.5604$).
- Proportion of eyes with CST ≤ 300 μm : 66.7 ($p=0.0125$), 72.7 ($p=0.0041$) and 54.2 percent ($p=0.3139$).

- Proportion of eyes with a more than two-step improvement in Diabetic Retinopathy Severity Scale score: 26.7 ($p=0.8896$); 34.1 (HD/IAI q8-week, $p=0.5021$), 34 (HD/IAI q12-week, $p=0.5273$) and 25.5 percent ($p=0.8683$).

Over the 32-week treatment period, the mean number of intravitreal injections administered was 7.2 ± 0.92 for LD/IAI q8 weeks; 5.9 ± 0.35 for HD/IAI q8 weeks; 5.1 ± 0.58 for HD/IAI q12

weeks; 5.9 ± 0.45 for IAI q8 weeks; 4.8 ± 0.63 for IAI q12 weeks; and 5.8 ± 0.44 for IAI converted to HD/IAI q8 weeks.

Rates of ocular adverse events were similar across the three treatment protocols throughout the 36-week study, with one or more ocular AD reported in 30 percent in the LD/IAI patients, 31 percent in the HD/IAI arm and 25.7 percent in the IAI patients. The most common AE was conjunctival hemorrhage, reported in 8, 2 and 7.2 percent of patients, respectively. Two serious ocular AEs were reported in the HD/IAI group: a case of iridocyclitis and another of retinal artery occlusion, which the authors considered related to the study treatment.

Researchers acknowledged that findings of the RUBY study contrast with those of the BOULEVARD study of faricimab (10), a bispecific antibody targeting Ang2 and vascular endothelial growth factor that showed significantly greater improvements in BCVA compared with ranibizumab monotherapy. They gave a number of reasons for the RUBY findings, including how treatment-naïve patients were distributed across treatment arms. They also noted the ocular and systemic safety profiles of nesvacumab/IAI was in line with IAI monotherapy.

While RUBY didn't show any additive benefit in vision with nesvacumab, the anatomic signals were noteworthy. "The indication of positive anatomic effects may warrant further investigation of the role of anti-Ang2 agents in combination with anti-VEGF therapy," Dr. Brown and colleagues wrote. ◀

1. Brown DM, Boyer DS, Csaky K, et al, on behalf of the RUBY Investigators. Intravitreal nesvacumab (antiangiopoietin 2) plus aflibercept in diabetic macular edema: Phase 2 RUBY randomized trial. *Retina* 2022;42:1111.

2. Sahni J, Patel SS, Dugel PU, et al. Simultaneous inhibition of angiopoietin-2 and vascular endothelial growth factor-A with faricimab in diabetic macular edema: BOULEVARD Phase 2 randomized trial. *Ophthalmology* 2019;126:1155.

(Continued from page 54)

there's not enough capsular support, then, depending on surgeon preference, you can place a three-piece posterior chamber IOL in the sulcus with suture fixation (to the iris or scleral) or intrascleral haptic fixation (glued or Yamane technique), or you can implant a flexible, open-loop anterior chamber IOL."

The final steps of the surgery have a major influence on patient recovery.

"Anytime you have to do an unplanned vitrectomy, you want to make sure to suture your wounds and pressurize the eye, making sure the pressure control is adequate, whether that be with drops or Diamox," Dr. Khandelwal says. "You also want to make sure that you do a good, dilated exam looking at the peripheral retina. If, for some reason, you feel this patient's high-risk or you're concerned about fragments of a cataract in the back, it's very important to refer early to a retina specialist so they can intervene."

Dr. Friedman concurs. "In terms of managing remaining nuclear material, the surgeon should elevate any nuclear material from the capsule into the anterior chamber and consider inserting a Sheets glide to prevent posterior migration," he says. "Low-flow phaco can be used to remove small pieces, whereas it may be necessary to enlarge the wound or create a scleral tunnel incision to manually extract large pieces. Don't attempt to retrieve nuclear fragments that have dislocated into the vitreous cavity. These should be removed at a later date by a retina specialist. Always keep the anterior chamber well-formed with additional OVD as needed, and resume anterior vitrectomy whenever vitreous migrates anteriorly.

"Patients should also be made aware of the surgical complication and possible longer visual recovery," he concludes.

Final Pearls

When confronted with this compli-

cation, experts offer the following pearls:

- recognize the potential for vitreous prolapse;
- prevent the anterior chamber from collapsing by injecting a dispersive OVD to stabilize the eye and tamponade the vitreous before removing the automated handpiece;
- stop irrigation;
- consider Triessen or dilute Kenalog to visualize the vitreous;
- if vitreous is present, use bimanual anterior vitrectomy with high cut settings;
- a limbal approach requires two paracenteses but may bring vitreous to the anterior chamber; keep the irrigator anterior to the iris plane while positioning the vitrector posteriorly to cut, prior to movement to the anterior chamber;
- pars plana requires a scleral incision 3 to 4 mm posterior to the limbus using a blade or a trocar;
- be sure your incision and settings match the gauge of your vitrector;
- extract any lens fragments remaining in the anterior segment, and remove all prolapsed vitreous;
- once vitreous has been cleared, use viscoelastic to keep the anterior chamber stabilized and proceed with the next steps for surgery;
- at the end of the case, check for remaining vitreous using dilute Kenalog or Miostat to bring the pupil down, or an air bubble may be warranted;
- implant an IOL in the most appropriate location and make sure it's secure; and
- suture the wounds properly.

Ultimately, planning ahead will be the key to success, and knowing both techniques will ensure you're prepared if vitreous loss occurs during cataract surgery. ◀

1. Prasad S, Little B, Osher R. Anterior vitrectomy masterclass. September, 2011. Congress of the European Society of Cataract and Refractive Surgery. Vienna, Austria. Accessed June 22, 2022. https://www.es CRS.org/vienna2011/programme/handouts/IC-48/IC48_Prasad_handout.pdf.



EDITED BY RAKHI MELVANI, MD

WILLS EYE RESIDENT CASE REPORT

A 20 year old presents with bilateral amblyopia and chronic renal failure.

KAYLENE CARTER, MD AND TAMARA VRABEC, MD
PHILADELPHIA

Presentation and Initial Examination

A 20-year-old male presented to the retina clinic with blurred vision in both eyes. He had been diagnosed with bilateral amblyopia by several eye-care providers during childhood who documented normal eye examination with reduced visual acuity recorded as 20/80 OU at age 3 and 20/50 OU at age 5.

Medical History

Past medical history was notable for delayed speech, delayed motor development and autism spectrum disorder as a child, and mild bilateral sensorineural hearing loss and hypertension during adolescence. Within six months of presentation, evaluation for extreme fatigue revealed anemia secondary to chronic renal failure. He had no surgical history. Family history was significant for hearing loss in his father and both grandfathers, and mild hearing loss in his mother. He denied alcohol, tobacco and illicit drug use.

Exam

Best corrected visual acuity was 20/40 in the right eye and 20/30 in the left. Pupillary examination was normal. Confrontational visual fields and extraocular movements were full. Intraocular pressures were within normal limits OU.

Slit lamp biomicroscopic examination of the anterior segments was normal. Dilated fundus exam was notable for mild disc pallor, central atrophy of the macula, and a blunted foveal reflex OU (*Figures 1 and 2*).

Figure 1. Fundus photo montage of the right eye revealed central atrophy of the macula, a blunted foveal reflex, and mottled depigmentation with mild vascular attenuation in the periphery. Fundus photo of the left eye appeared similar (not pictured).

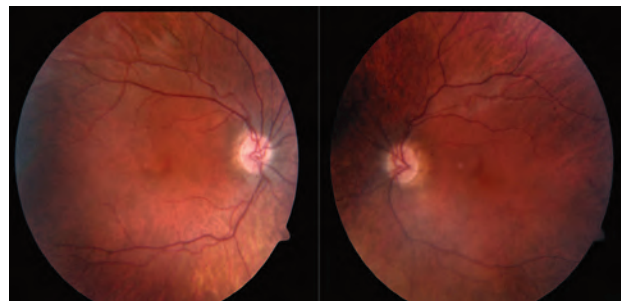
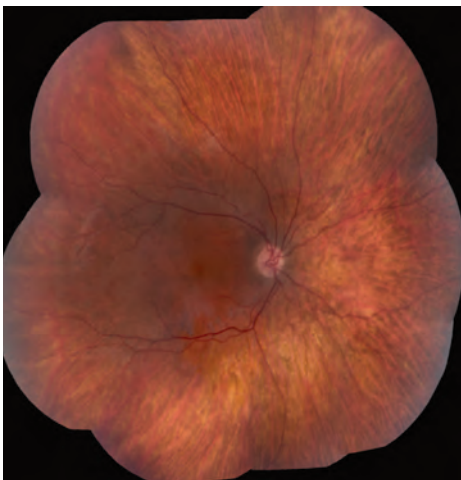

Figure 2. Fundus photos of the posterior pole show mild disc pallor and central atrophy of the macula.

What's your diagnosis? What further work-up would you pursue? The diagnosis appears on p. 72.

Work-up, Diagnosis and Treatment

Fundus autofluorescence (FAF) was unremarkable (Figure 3). Macular optical coherence tomography revealed outer retinal atrophy with relative sparing of the fovea (Figure 4). OCT of the optic nerve revealed bilateral temporal retinal nerve fiber layer thinning (Figure 5). Humphrey visual field 24-2 testing demonstrated diffuse suppression with scattered paracentral defects bilaterally (Figure 6). Electroretinography photopic and scotopic waveforms and multifocal electroretinography wavelet amplitude throughout the macula were reduced to 25 percent of normal in both eyes.

Review of serology revealed serum creatinine had risen steadily from 1.2 to 3.4 mg/dL over the past three years. Renal function studies, including 24-hour urine albumin (49.8 mg/24 hr) and albumin/creatinine ratio (81 mg/g), were elevated. Renal ultrasound was remarkable for reduced kidney size.

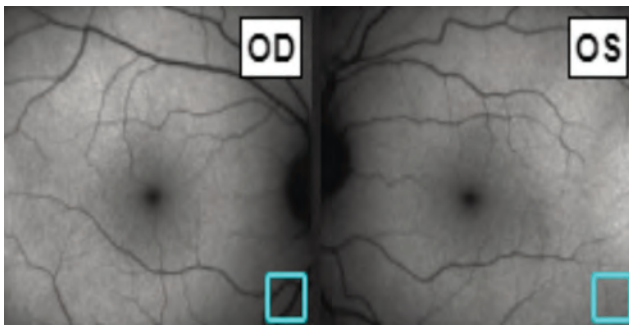


Figure 3. Fundus autofluorescence was unremarkable.

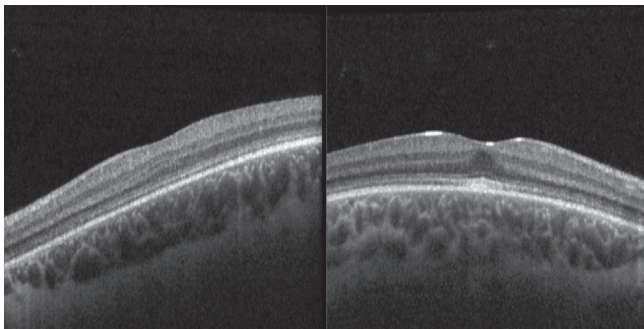


Figure 4. OCT demonstrating outer retinal atrophy with relative sparing of the fovea.

Discussion

Senior Loken syndrome is a rare autosomal recessive disorder marked by retinal degeneration and renal failure characterized by inflammation and fibrosis, known as nephronophthisis.¹ Its prevalence is approximately 1 in a million people worldwide.¹ Senior Loken syndrome

Based on clinical history, examination, multi-modal imaging and lab work, an inherited retinitis pigmentosa syndrome was suspected. Whole genome exome sequencing revealed biallelic pathogenic variants of the NPHP1 gene which confirmed the diagnosis of Senior Loken Syndrome.

The patient and his family attended genetic counseling, and the diagnosis was shared with the patient's nephrologist. The patient is preparing for dialysis while awaiting renal transplantation. He is following with audiology and ophthalmology for periodic examinations.

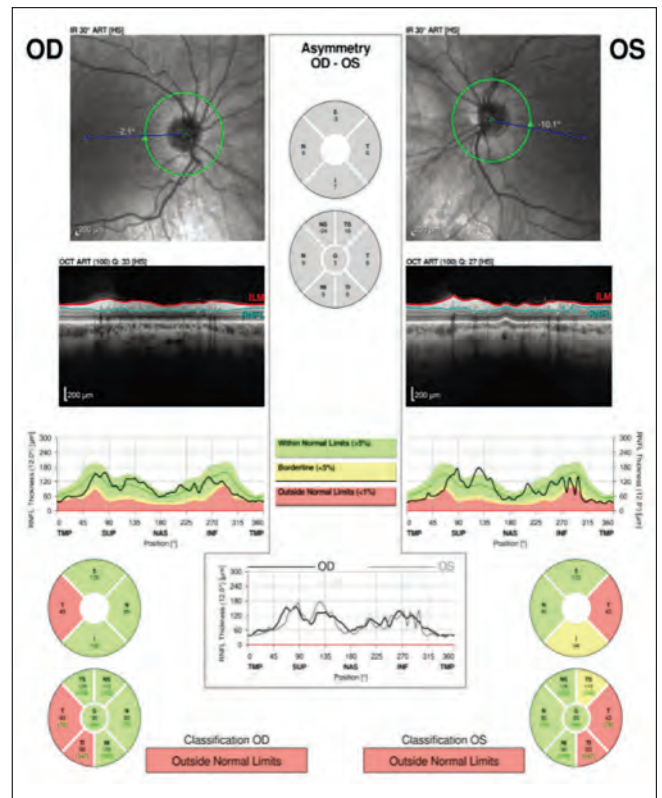
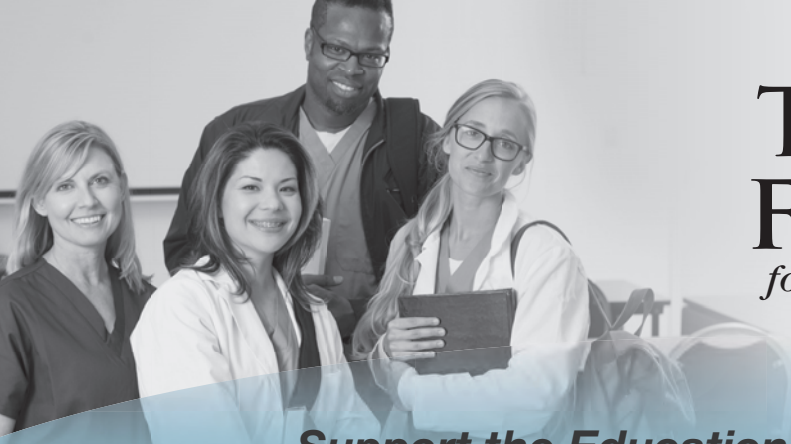

Figure 5. OCT of the optic nerve demonstrating bilateral temporal retinal nerve fiber layer atrophy.




Figure 6. HVF 24-2 showing diffuse reduction with scattered paracentral defects.



THE RICK BAY FOUNDATION

for Excellence in Eyecare Education

Support the Education of Future Healthcare & Eyecare Professionals

Scholarships are awarded to advance the education of students in both **Optometry** and **Ophthalmology**, and are chosen by their school based on qualities that embody Rick's commitment to the profession, including integrity, compassion, partnership and dedication to the greater good.

INTERESTED IN BEING A PARTNER WITH US?

www.rickbayfoundation.org

(Contributions are tax-deductible in accordance with section 170 of the Internal Revenue Code.)

ABOUT RICK

Rick Bay served as the publisher of *The Review Group* for more than 20 years. To those who worked for him, he was a leader whose essence was based in a fierce and boundless loyalty. To those in the industry and the professions he served, he will be remembered for his unique array of skills and for his dedication to exceeding the expectations of his customers, making many of them fast friends.



THE RICK BAY FOUNDATION
for Excellence in Eyecare Education

(The Rick Bay Foundation for Excellence in Eyecare Education is a nonprofit, tax-exempt organization under section 501(c)(3) of the Internal Revenue Code.)

ADVERTISER INDEX

This advertiser index is published as a convenience and not as part of the advertising contract. Every care will be taken to index correctly. No allowance will be made for errors due to spelling, incorrect page number, or failure to insert.

Alcon Laboratories	17
.....	www.alconsmartsolutions.com
Alcon Laboratories	9 & 10
.....	www.alcon.com
Alcon Laboratories	13 & 14
.....	www.clareon10L.com
Apellis	23
.....	www.apellis.com
Genentech	Cover 3
.....	www.VABYSMO-HCP.com
Genentech	Cover 4
.....	www.VABYSMO-HCP.com
Icare USA	27
.....	(888) 422-7313
.....	infoUSA@icare-world.com
.....	www.icare-world.com/USA

Johnson & Johnson	7
.....	www.jnjvisionpro.com
Nanodropper	15
.....	(507) 405-5676
.....	support@nanodropper.com
.....	www.nanodropper.com
Nextgen.....	5
.....	www.nextgen.com/1-ophth
Novartis Pharmaceuticals	32 - 34
.....	www.novartis.com
Regeneron Pharmaceuticals, Inc.	Covertip
.....	www.regeneron.com
Reichert Technologies.....	21
.....	www.reichert.com/ora
Sight Sciences.....	53 - 54
.....	info@sightsciences.com
.....	www.omnisurgical.com
Thea Pharma	Cover 2
.....	www.ivizia.com/ecp
Thea Pharma	3
.....	www.ivizia.com/ecp

is categorized as a ciliopathy owing to malfunction of cilia, the microtubule-based organelles that extend from cell surfaces and facilitate molecular signaling.² The NPHP genes encode cilia-associated proteins called nephrocystins, which are found in the cilium of photoreceptors and renal cells.³ These proteins are necessary for photoreceptor outer segment formation,⁴ and thus miscoding results in the diminished visual acuity in Senior Loken syndrome.

Patients commonly develop visual symptoms in the first decade of life, and may experience progressive visual impairment and nyctalopia. The majority have a mild retinal phenotype predominantly affecting cones with relative sparing of the fovea, although the retinal presentation can range from a severe Leber's congenital amaurosis to typical retinitis pigmentosa.⁴ There may be no obvious structural changes on physical exam, as in this patient's childhood eye examinations. However, OCT can reveal reduced reflectivity, a granular appearance of the ellipsoid zone, loss of the interdigitation zone and mild outer retinal thinning.⁵

Renal symptoms typically occur before visual symptoms in Senior Loken syndrome; renal function becomes impaired due to inflammation and fibrosis as a result of damage to the ciliated epithelial cells of the nephron and collecting duct.⁶ Renal ultrasound may reveal interstitial fibrosis and corticomedullary cysts.⁷ Polyuria, polydipsia and fatigue are common initial symptoms, followed later by anemia and uremia.⁸

Senior Loken syndrome may be differentiated clinically from other ciliopathies including Alport Syndrome, Joubert Syndrome and Bardet-Biedl Syndrome. Alport syndrome features hematuria with progressive nephropathy in addition to sensorineural hearing loss,

anterior lenticonus and abnormal retinal pigmentation.⁹ In Joubert Syndrome, cerebellar vermis and brainstem hypoplasia, infantile hypotonia, and oculomotor apraxia accompany nephronophthisis and retinal dystrophy.¹⁰ Bardet-Biedl syndrome is typified by post-axial polydactyly, truncal obesity, renal abnormalities and retinitis pigmentosa.¹¹ Dozens of other ciliopathies exist, with wide-ranging systemic effects, including cardiac defects, cognitive impairment, hydrocephalus, craniofacial defects, skeletal abnormalities, polydactyly, liver and pancreatic cysts, and genital defects.¹²

“ Although there's no specific treatment for nephronophthisis, ongoing management by nephrology is critical for managing secondary complications of renal failure and planning dialysis and or transplant which are often required by mid to late adolescence. ”

Treatment for Senior Loken syndrome is primarily supportive. Patients should undergo periodic ophthalmologic assessment with low-vision services as necessary. Although there's no specific treatment for nephronophthisis, ongoing management by nephrology is critical for managing secondary complications of renal failure and planning dialysis and or transplant which are often required by mid to late adolescence. Genetic counseling should be offered to the patient and family. Referral to ENT is

indicated to identify and remediate hearing loss. Furthermore, referral to psychology for establishment and management of ongoing individualized education plans based on visual and hearing limitations as early as possible is important to optimize classroom education and can be life-changing.

In summary, we describe a patient with clinical, examination and multi-modal testing findings of retinitis pigmentosa in addition to systemic features of chronic kidney disease and hearing loss, which raised suspicion for a ciliopathy. Genetic testing confirmed the diagnosis of Senior Loken syndrome. ◀

1. Senior-Løken syndrome. MedlinePlus. Accessed June 1, 2012. medlineplus.gov/genetics/condition/senior-loken-syndrome/.

2. Goetz SC, Anderson KV. The primary cilium: A signaling centre during vertebrate development. *Nat Rev Genet* 2010;11:5:331-44.

3. Hildebrandt F, Otto E. Molecular genetics of nephronophthisis and medullary cystic kidney disease. *J Am Soc Nephrol* 2000;11:9:1753-1761.

4. Jiang ST, Chiou YY, Wang E, Chien YL, Ho HH, Tsai FJ, Lin CY, Tsai SP, Li H. Essential role of nephrocystin in photoreceptor intraflagellar transport in mouse. *Human Molecular Genetics* 2009;18:9:1566-1577.

5. Birtel J, Spital G, Book M, Habbig S, Bäumner S, Riehmer, Beck BB, Rosenkranz D, Bolz HJ, Dahmer-Heath M, Herrmann P, König J, Issa PC. NPHP1 gene-associated nephronophthisis is associated with an occult retinopathy. *Kidney International* 2021;100:5:1092-1100.

6. Deane JA, Verghese E, Martelotto LG, Cain JE, Galtseva A, Rosenblum ND, Watkins DN, Ricardo SD. Visualizing renal primary cilia. *Nephrology (Carlton)* 2013;18:3:161-8.

7. Aguilera A, Rivera M, Gallego N, Nogueira J, Ortuno J. Sonographic appearance of the juvenile nephronophthisis-cystic renal medulla complex. *Nephrol Dial Transplant* 1997;12:625-26.

8. Amarpreet K, et al. Senior Loken Syndrome. *Journal of clinical and diagnostic research* 2016;10:11:SD03-SD04.

9. Laurence H, Knebelmann B, Gubler MC. Alport Syndrome: Clinical Features. In: Turner NN, Lameire N, Goldsmith DJ, Winearls CG, Himmelfarb J, Remuzzi G, eds. *Oxford Textbook of Clinical Nephrology*. Oxford: Oxford University Press, 2015.

10. Joubert M, Eisenring JJ, Robb JP, Andermann F. Familial agenesis of the cerebellar vermis. A syndrome of episodic hyperpnea, abnormal eye movements, ataxia and retardation. *Neurology* 1969;19:813-25.

11. Forsythe E, Beales PL. Bardet-Biedl syndrome. *Eur J Hum Genet* 2013;21:1:8-13.

12. Lee JE, Gleeson JG. Emerging genetics of the ciliopathies. *Genome Med* 2011;3:9:59.

VABYSMO™ (faricimab-svoa) injection, for intravitreal use

This is a brief summary. Before prescribing, please refer to the full Prescribing Information

1 INDICATIONS AND USAGE

VABYSMO is a vascular endothelial growth factor (VEGF) and angiopoietin 2 (Ang-2) inhibitor indicated for the treatment of patients with:

1.1 Neovascular (wet) Age-Related Macular Degeneration (nAMD)
1.2 Diabetic Macular Edema (DME)
4 CONTRAINDICATIONS
4.1 Ocular or Periocular Infections

VABYSMO is contraindicated in patients with ocular or periocular infections.

4.2 Active Intraocular Inflammation

VABYSMO is contraindicated in patients with active intraocular inflammation.

4.3 Hypersensitivity

VABYSMO is contraindicated in patients with known hypersensitivity to faricimab or any of the excipients in VABYSMO. Hypersensitivity reactions may manifest as rash, pruritus, urticaria, erythema, or severe intraocular inflammation.

5 WARNINGS AND PRECAUTIONS
5.1 Endophthalmitis and Retinal Detachments

Intravitreal injections have been associated with endophthalmitis and retinal detachments [see *Adverse Reactions* (6.1)]. Proper aseptic injection techniques must always be used when administering VABYSMO. Patients should be instructed to report any symptoms suggestive of endophthalmitis or retinal detachment without delay, to permit prompt and appropriate management [see *Dosage and Administration* (2.6) and *Patient Counseling Information* (17)].

5.2 Increase in Intraocular Pressure

Transient increases in intraocular pressure (IOP) have been seen within 60 minutes of intravitreal injection, including with VABYSMO [see *Adverse Reactions* (6.1)]. IOP and the perfusion of the optic nerve head should be monitored and managed appropriately [see *Dosage and Administration* (2.6)].

5.3 Thromboembolic Events

Although there was a low rate of arterial thromboembolic events (ATEs) observed in the VABYSMO clinical trials, there is a potential risk of ATEs following intravitreal use of VEGF inhibitors. ATEs are defined as nonfatal stroke, nonfatal myocardial infarction, or vascular death (including deaths of unknown cause).

The incidence of reported ATEs in the nAMD studies during the first year was 1% (7 out of 664) in patients treated with VABYSMO compared with 1% (6 out of 662) in patients treated with aflibercept [see *Clinical Studies* (14.1)].

The incidence of reported ATEs in the DME studies during the first year was 2% (25 out of 1,262) in patients treated with VABYSMO compared with 2% (14 out of 625) in patients treated with aflibercept [see *Clinical Studies* (14.2)].

6 ADVERSE REACTIONS

The following potentially serious adverse reactions are described elsewhere in the labeling:

- Hypersensitivity [see *Contraindications* (4)]
- Endophthalmitis and retinal detachments [see *Warnings and Precautions* (5.1)]
- Increase in intraocular pressure [see *Warnings and Precautions* (5.2)]
- Thromboembolic events [see *Warnings and Precautions* (5.3)]

6.1 Clinical Trial Experience

Because clinical trials are conducted under widely varying conditions, adverse reaction rates observed in the clinical trials of a drug cannot be directly compared to rates in other clinical trials of the same or another drug and may not reflect the rates observed in practice.

The data described below reflect exposure to VABYSMO in 1,926 patients, which constituted the safety population in four Phase 3 studies [see *Clinical Studies* (14.1, 14.2)].

Table 1: Common Adverse Reactions (≥ 1%)

Adverse Reactions	VABYSMO		Active Control (aflibercept)	
	AMD N=664	DME N=1262	AMD N=622	DME N=625
Conjunctival hemorrhage	7%	7%	8%	6%
Vitreous floaters	3%	3%	2%	2%
Retinal pigment epithelial tear ^a	3%		1%	
Intraocular pressure increased	3%	3%	2%	2%
Eye pain	3%	2%	3%	3%
Intraocular inflammation ^b	2%	1%	1%	1%
Eye irritation	1%	1%	< 1%	1%
Ocular discomfort	1%	1%	< 1%	< 1%
Vitreous hemorrhage	< 1%	1%	1%	< 1%
^a AMD only				
^b Including iridocyclitis, iritis, uveitis, vitritis				

Less common adverse reactions reported in < 1% of the patients treated with VABYSMO were corneal abrasion, eye pruritus, lacrimation increased, ocular hyperemia, blurred vision, eye irritation, sensation of foreign body, endophthalmitis, visual acuity reduced transiently, retinal tear and rhegmatogenous retinal detachment.

6.2 Immunogenicity

The immunogenicity of VABYSMO was evaluated in plasma samples. The immunogenicity data reflect the percentage of patients whose test results were considered positive for antibodies to VABYSMO in immunosays. The detection of an immune response is highly dependent on the sensitivity and specificity of the assays used, sample handling, timing of sample collection, concomitant medications, and underlying disease. For these reasons, comparison of the incidence of antibodies to VABYSMO with the incidence of antibodies to other products may be misleading.

There is a potential for an immune response in patients treated with VABYSMO. In the nAMD and DME studies, the pre-treatment incidence of anti-faricimab antibodies was approximately 1.8% and 0.8%, respectively. After initiation of dosing, anti-faricimab antibodies were detected in approximately 10.4% and 8.4% of patients with nAMD and DME respectively, treated with VABYSMO across studies and across treatment groups. As with all therapeutic proteins, there is a potential for immunogenicity with VABYSMO.

8 USE IN SPECIFIC POPULATIONS
8.1 Pregnancy
Risk Summary

There are no adequate and well-controlled studies of VABYSMO administration in pregnant women.

Administration of VABYSMO to pregnant monkeys throughout the period of organogenesis resulted in an increased incidence of abortions at intravenous (IV) doses 158 times the human exposure (based on C_{max}) of the maximum recommended human dose [see *Animal Data*]. Based on the mechanism of action of VEGF and Ang-2 inhibitors, there is a potential risk to female reproductive capacity, and to embryo-fetal development. VABYSMO should not be used during pregnancy unless the potential benefit to the patient outweighs the potential risk to the fetus.

All pregnancies have a background risk of birth defect, loss, and other adverse outcomes. The background risk of major birth defects and miscarriage for the indicated population is unknown. In the U.S. general population, the estimated background risk of major birth defects is 2%-4% and of miscarriage is 15%-20% of clinically recognized pregnancies.

Data
Animal Data

An embryo fetal developmental toxicity study was performed on pregnant cynomolgus monkeys. Pregnant animals received 5 weekly IV injections of VABYSMO starting on day 20 of gestation at 1 or 3 mg/kg. A non-dose dependent increase in pregnancy loss (abortions) was observed at both doses evaluated. Serum exposure (C_{max}) in pregnant monkeys at the low dose of 1 mg/kg was 158 times the human exposure at the maximum recommended intravitreal dose of 6 mg once every 4 weeks. A no observed adverse effect level (NOAEL) was not identified in this study.

8.2 Lactation
Risk Summary

There is no information regarding the presence of faricimab in human milk, the effects of the drug on the breastfed infant, or the effects of the drug on milk production. Many drugs are transferred in human milk with the potential for absorption and adverse reactions in the breastfed child.

The developmental and health benefits of breastfeeding should be considered along with the mother's clinical need for VABYSMO and any potential adverse effects on the breastfed child from VABYSMO.

8.3 Females and Males of Reproductive Potential Contraception

Females of reproductive potential are advised to use effective contraception prior to the initial dose, during treatment and for at least 3 months following the last dose of VABYSMO.

Infertility

No studies on the effects of faricimab on human fertility have been conducted and it is not known whether faricimab can affect reproduction capacity. Based on the mechanism of action, treatment with VABYSMO may pose a risk to reproductive capacity.

8.4 Pediatric Use

The safety and efficacy of VABYSMO in pediatric patients have not been established.

8.5 Geriatric Use

In the four clinical studies, approximately 60% (1,149/1,929) of patients randomized to treatment with VABYSMO were ≥ 65 years of age. No significant differences in efficacy or safety of faricimab were seen with increasing age in these studies. No dose adjustment is required in patients 65 years and above.

17 PATIENT COUNSELING INFORMATION

Advise patients that in the days following VABYSMO administration, patients are at risk of developing endophthalmitis. If the eye becomes red, sensitive to light, painful, or develops a change in vision, advise the patient to seek immediate care from an ophthalmologist [see *Warnings and Precautions* (5)].

Patients may experience temporary visual disturbances after an intravitreal injection with VABYSMO and the associated eye examinations [see *Adverse Reactions* (6)]. Advise patients not to drive or use machinery until visual function has recovered sufficiently.

VABYSMO™ [faricimab-svoa]

Manufactured by:

Genentech, Inc.

A Member of the Roche Group

1 DNA Way

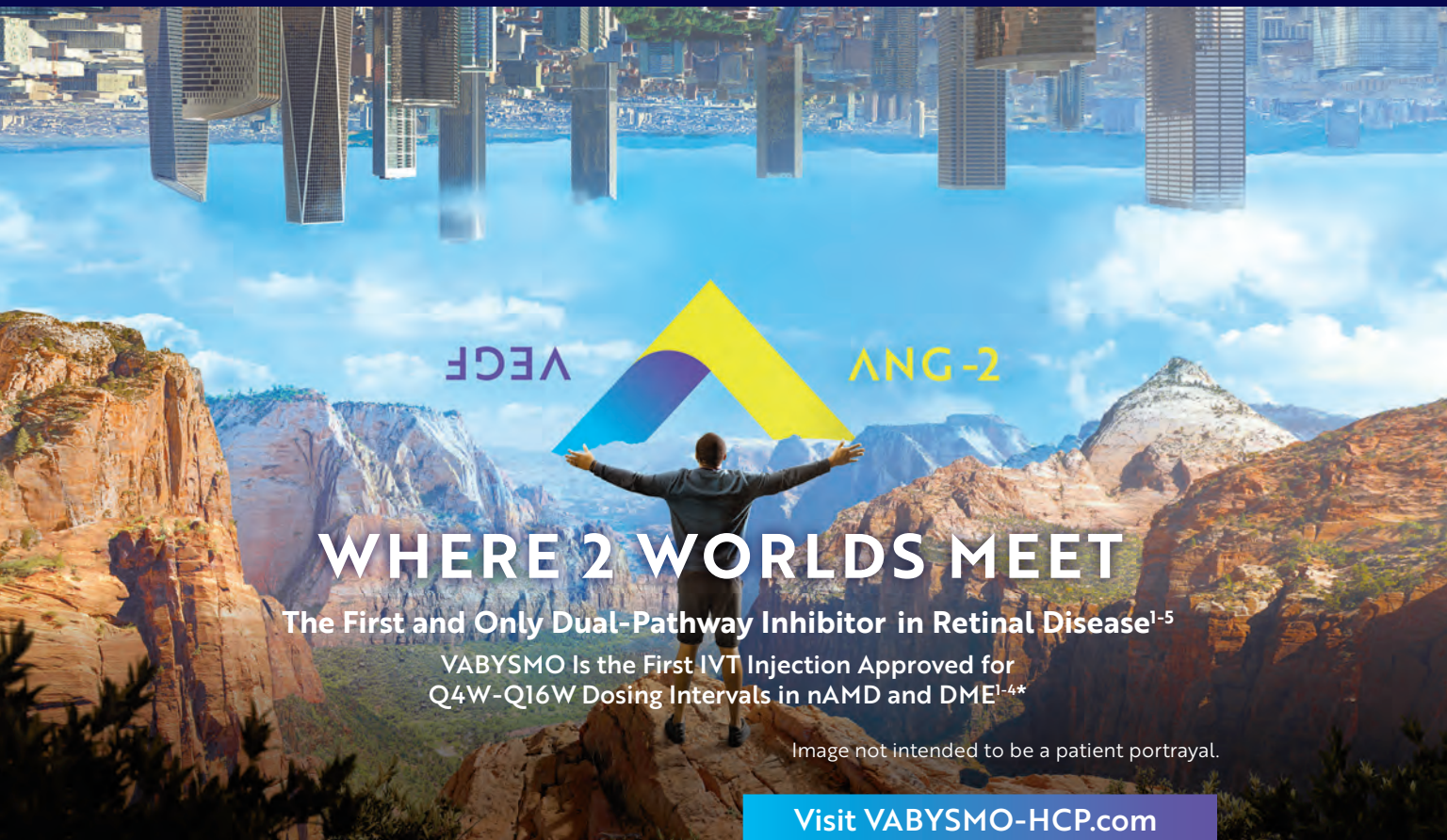South San Francisco, CA 94080-4990

U.S. License No.: 1048

VABYSMO is a trademark of Genentech, Inc.

©2022 Genentech, Inc.

M-US-00013249(v1.0) 2/22



WHERE 2 WORLDS MEET

The First and Only Dual-Pathway Inhibitor in Retinal Disease¹⁻⁵

VABYSMO Is the First IVT Injection Approved for
Q4W-Q16W Dosing Intervals in nAMD and DME^{1-4*}

Image not intended to be a patient portrayal.

Visit VABYSMO-HCP.com

INDICATIONS

VABYSMO (faricimab-svoa) is a vascular endothelial growth factor (VEGF) inhibitor and angiopoietin-2 (Ang-2) inhibitor indicated for the treatment of patients with Neovascular (Wet) Age-Related Macular Degeneration (nAMD) and Diabetic Macular Edema (DME).

IMPORTANT SAFETY INFORMATION

Contraindications

VABYSMO is contraindicated in patients with ocular or periocular inflammation, in patients with active intraocular inflammation, and in patients with known hypersensitivity to faricimab or any of the excipients in VABYSMO.

Warnings and Precautions

- Endophthalmitis and retinal detachments may occur following intravitreal injections. Patients should be instructed to report any symptoms suggestive of endophthalmitis or retinal detachment without delay, to permit prompt and appropriate management.
- Increases in intraocular pressure have been seen within 60 minutes of an intravitreal injection.
- There is a potential risk of arterial thromboembolic events (ATEs) associated with VEGF inhibition.

Adverse Reactions

The most common adverse reaction (≥5%) reported in patients receiving VABYSMO was conjunctival hemorrhage (7%).

You may report side effects to the FDA at (800) FDA-1088 or www.fda.gov/medwatch. You may also report side effects to Genentech at (888) 835-2555.

Please see Brief Summary of VABYSMO full Prescribing Information on the following page.

*Dosing Information:

In nAMD, the recommended dose for VABYSMO is 6 mg (0.05 mL of 120 mg/mL solution) IVT Q4W for the first 4 doses, followed by OCT and visual acuity evaluations 8 and 12 weeks later to inform whether to extend to: 1) Q16W (weeks 28 and 44); 2) Q12W (weeks 24, 36, and 48); or 3) Q8W (weeks 20, 28, 36, and 44).

In DME, the recommended dose for VABYSMO is 6 mg (0.05 mL of 120 mg/mL solution) IVT Q4W for ≥4 doses until CST is ≤325 μm (by OCT), followed by treat-and-extend dosing with 4-week interval extensions or 4- to 8-week interval reductions based on CST and visual acuity evaluations through week 52. Alternatively, VABYSMO can be administered IVT Q4W for the first 6 doses, followed by Q8W dosing over the next 28 weeks.

Although VABYSMO may be dosed as frequently as Q4W, additional efficacy was not demonstrated in most patients when VABYSMO was dosed Q4W vs Q8W. Some patients may need Q4W dosing after the first 4 doses. Patients should be assessed regularly and the dosing regimen reevaluated after the first year.

CST=central subfield thickness; IVT=intravitreal; OCT=optical coherence tomography; Q4W=every 4 weeks; Q8W=every 8 weeks; Q12W=every 12 weeks; Q16W=every 16 weeks.

References: 1. VABYSMO [package insert]. South San Francisco, CA: Genentech, Inc; 2022. 2. Beovu® (brolucizumab) [package insert]. East Hanover, NJ: Novartis; 2020. 3. Eylea® (afibercept) [package insert]. Tarrytown, NY: Regeneron Pharmaceuticals, Inc; 2021. 4. LUCENTIS® (ranibizumab) [package insert]. South San Francisco, CA: Genentech, Inc; 2018. 5. SUSVIMO™ (ranibizumab injection) [package insert]. South San Francisco, CA: Genentech, Inc; 2022.