

Wills Eye Resident Series: An 18-year-old has to contend with very high refractive error. p .71

# REVIEW<sup>®</sup> of OPHTHALMOLOGY

May 2022 • reviewofophthalmology.com • Clinical advice you can trust

## MEDICARE Q & A

The Fate of Telemedicine  
PAGE 16

## TECHNOLOGY UPDATE

New Ways to Monitor Glaucoma  
PAGE 20

## RETINAL INSIDER

The Impact of the Gut Microbiome  
PAGE 60

## Practices Bounce Back from the

— Sanitization Protocols

New from the makers of the #1-prescribed dry eye brand in Europe\*

## Covering the spectrum of


# Dry Eye Relief

Introducing preservative-free iVIZIA™ lubricant eye drops for the comprehensive combination of lasting relief and ocular surface protection.<sup>1-6</sup>

- Trehalose provides bioprotection, osmoprotection, and rehydration<sup>1-4</sup>
- Hyaluronic acid (HA) and povidone (active) deliver lubrication with long-lasting relief<sup>5,6</sup>
- Increased tear film thickness for up to 240 minutes<sup>7</sup>
- Preservative free
- Proprietary multi-dose bottle design for calibrated dosing and contamination protection
- Suitable for all dry eye sufferers, including contact lens wearers†

Help patients see dry eye relief differently. Recommend iVIZIA OTC.

**Request samples and learn more by scanning the QR code or visiting [iVIZIA.com/ECP](http://iVIZIA.com/ECP).**



\*Prescription market data, Sept. 2021 – S01K without cyclosporine.

†To limit blurriness when using contact lenses, remove contacts, apply drops, then insert contacts.

## Covering the spectrum of *Eye Care*

The comprehensive iVIZIA product line includes eyelid hygiene products:

**iVIZIA Eyelid Cleansing Wipes**—with no preservatives, parabens, soaps, or perfumes for sensitive eyelids

**iVIZIA Micellar Eyelid Cleanser**—with a micellar BAK-free formulation

**iVIZIA Eyelid Cleansing Gel**—using proprietary Steri-Free® Technology and dispensed via the Mega Airless Pump



**References:** **1.** Chen W, Zhang X, Liu M, et al. Trehalose protects against ocular surface disorders in experimental murine dry eye through suppression of apoptosis. *Exp Eye Res.* 2009;89(3):311-318. **2.** Aragona P, Colosi P, Rania L, et al. Protective effects of trehalose on the corneal epithelial cells. *ScientificWorldJournal.* 2014;2014:717835. **3.** Chiambaretta F, Doan S, Labetoulle M, et al. A randomized, controlled study of the efficacy and safety of a new eyedrop formulation for moderate to severe dry eye syndrome. *Eur J Ophthalmol.* 2017;27(1):1-9. **4.** Liu Z, Chen D, Chen X, et al. Trehalose induces autophagy against inflammation by activating TFEB signaling pathway in human corneal epithelial cells exposed to hyperosmotic stress. *Invest Ophthalmol Vis Sci.* 2020;61(10):26. **5.** US FDA Department of Health and Human Services. Ophthalmic drug products for over-the-counter human use. Updated October 21, 2021. Accessed January 19, 2022. <https://www.accessdata.fda.gov/scripts/cdrh/cfdocs/cfcfr/CFRSearch.cfm?CFRPart=349>. **6.** Jones L, Downie LE, Korb D, et al. TFOS DEWS II management and therapy report. *Ocul Surf.* 2017;15(3):575-628. **7.** Schmidl D, Schmetterer L, Witkowska KJ, et al. Tear film thickness after treatment with artificial tears in patients with moderate dry eye disease. *Cornea.* 2015;34(4):421-426.



Wills Eye Resident Series: An 18-year-old has to contend with very high refractive error. *p* .71

# REVIEW<sup>®</sup> *of* OPHTHALMOLOGY

May 2022 • reviewofophthalmology.com • Clinical advice you can trust

## MEDICARE Q & A

The Fate of Telemedicine  
PAGE 16

## TECHNOLOGY UPDATE

New Ways to Monitor Glaucoma  
PAGE 20

## RETINAL INSIDER

The Impact of the Gut Microbiome  
PAGE 60

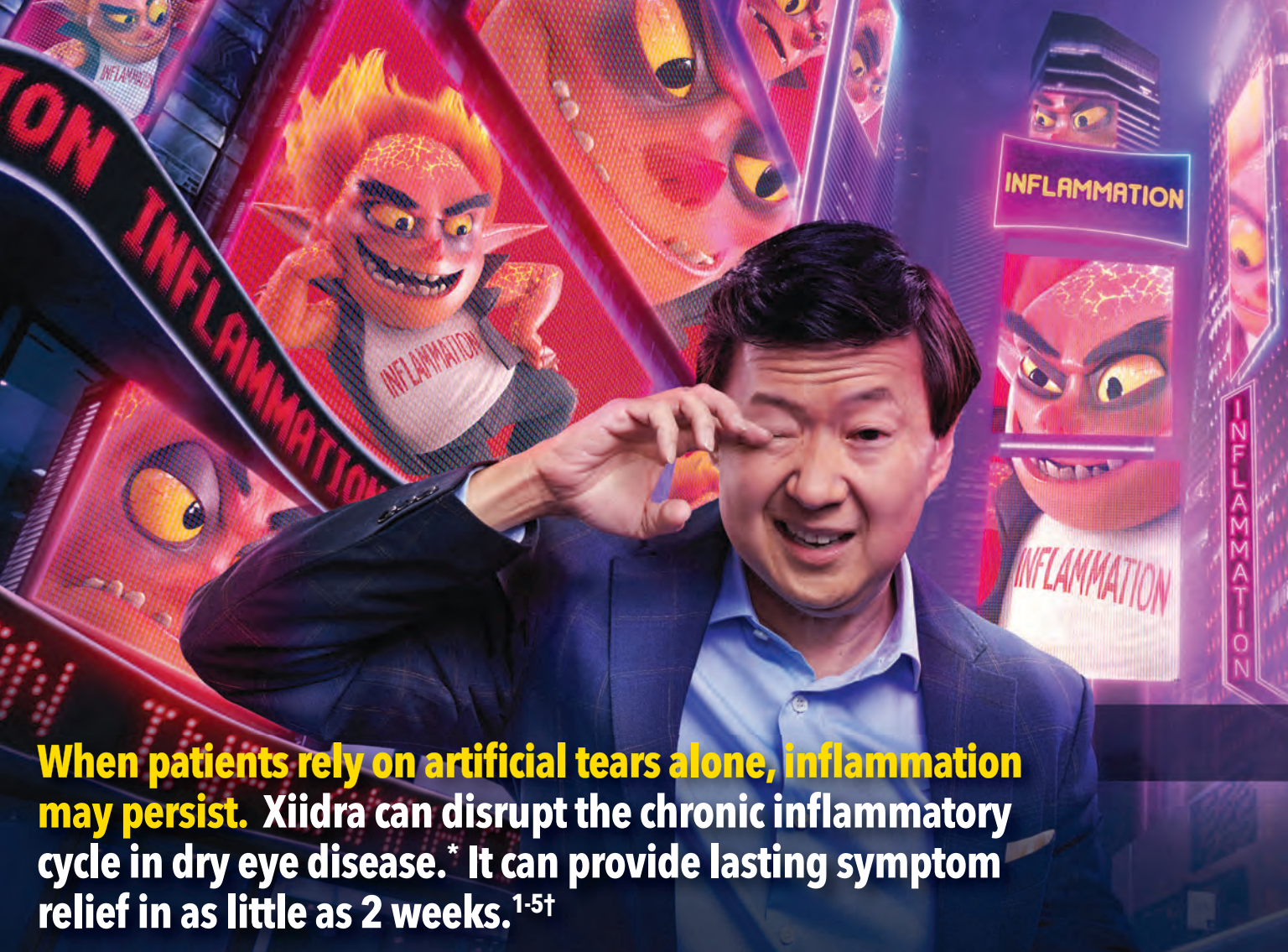## Practices Bounce Back from the Pandemic

*Physicians and managers discuss  
the pandemic-induced changes  
that are here to stay. P. 26*

- Sanitization Protocols
- Staff Retention
- Exam Enhancements
- And more ...

### ALSO INSIDE:

- Gene Therapy for Inherited Retinal Disease **P. 36**
- The Best Approach for Narrow-angle Patients **P. 42**
- The Glaucoma Medication Pipeline, 2022 **P. 46**
- An Update on Private Equity in Ophthalmology **P. 50**



**When patients rely on artificial tears alone, inflammation may persist. Xiidra can disrupt the chronic inflammatory cycle in dry eye disease.\* It can provide lasting symptom relief in as little as 2 weeks.<sup>1-5†</sup>**

\*Xiidra blocks LFA-1 on T cells from binding with ICAM-1 that may be overexpressed on the ocular surface in dry eye disease and may prevent formation of an immunologic synapse which, based on in vitro studies, may inhibit T-cell activation, migration of activated T cells to the ocular surface, and reduce cytokine release. The exact mechanism of action of Xiidra in DED is not known.<sup>1,2,5</sup>

†The safety and efficacy of Xiidra were assessed in four 12-week, randomized, multicenter, double-masked, vehicle controlled studies (N=2133). Patients were dosed twice daily. The mean age was 59 years (range, 19-97 years). The majority of patients were female (76%). Use of artificial tears was not allowed during the studies. The study end points included assessment of signs (based on Inferior fluorescein Corneal Staining Score [ICSS] on a scale of 0 to 4) and symptoms (based on patient-reported EDS on a visual analogue scale of 0 to 100). Effects on symptoms of dry eye disease: a larger reduction in EDS favoring Xiidra was observed in all studies at day 42 and day 84. Xiidra reduced symptoms of eye dryness at 2 weeks (based on EDS) compared to vehicle in 2 out of 4 clinical trials. Effects on signs of dry eye disease: at day 84, a larger reduction in ICSS favoring Xiidra was observed in 3 out of the 4 studies.<sup>1</sup>

### Indication

Xiidra® (lifitegrast ophthalmic solution) 5% is indicated for the treatment of signs and symptoms of dry eye disease (DED).

### Important Safety Information

- Xiidra is contraindicated in patients with known hypersensitivity to lifitegrast or to any of the other ingredients.



**Novartis Pharmaceuticals Corporation**  
East Hanover, New Jersey 07936-1080





**KEN JEONG,**  
REAL DRY EYE PATIENT.

  
(lifitegrast  
ophthalmic solution) 5%  
**Dry eyes deserve a change**

### Important Safety Information (cont)

- In clinical trials, the most common adverse reactions reported in 5-25% of patients were instillation site irritation, dysgeusia and reduced visual acuity. Other adverse reactions reported in 1% to 5% of the patients were blurred vision, conjunctival hyperemia, eye irritation, headache, increased lacrimation, eye discharge, eye discomfort, eye pruritus and sinusitis.
- To avoid the potential for eye injury or contamination of the solution, patients should not touch the tip of the single-use container to their eye or to any surface.
- Contact lenses should be removed prior to the administration of Xiidra and may be reinserted 15 minutes following administration.
- Safety and efficacy in pediatric patients below the age of 17 years have not been established.

**For additional safety information about XIIDRA<sup>®</sup>, please refer to the brief summary of Full Prescribing Information on adjacent page.**

**References:** **1.** Xiidra [package insert]. East Hanover, NJ: Novartis Pharmaceuticals Corp; June 2020. **2.** Bron AJ, de Paiva CS, Chauhan SK, et al. TFOS DEWS II Pathophysiology Report. *Ocul Surf.* 2017;15(3):438-510. **3.** US Food and Drug Administration. Code of Federal Regulations, Title 21, Volume 5 (21CFR349). Accessed May 25, 2021. <https://www.accessdata.fda.gov/scripts/cdrh/cfdocs/cfcr/CFRSearch.cfm?CFRPart=349&showFR=1> **4.** Jones L, Downie LE, Korb D, et al. TFOS DEWS II Management and Therapy Report. *Ocul Surf.* 2017;15(3):575-628. **5.** Pflugfelder SC, Stern M, Zhang S, Shojaei A. LFA-1/ICAM-1 interaction as a therapeutic target in dry eye disease. *J Ocul Pharmacol Ther.* 2017;33(1):5-12.

**XIIDRA, the XIIDRA logo and ii are registered trademarks of Novartis AG.**

## **Xiidra® (lifitegrast ophthalmic solution), for topical ophthalmic use**

**Initial U.S. Approval: 2016**

**BRIEF SUMMARY: Please see package insert for full prescribing information.**

### **1 INDICATIONS AND USAGE**

Xiidra® (lifitegrast ophthalmic solution) 5% is indicated for the treatment of the signs and symptoms of dry eye disease (DED).

### **4 CONTRAINDICATIONS**

Xiidra is contraindicated in patients with known hypersensitivity to lifitegrast or to any of the other ingredients in the formulation [see *Adverse Reactions (6.2)*].

### **6 ADVERSE REACTIONS**

The following serious adverse reactions are described elsewhere in the labeling:

- Hypersensitivity [see *Contraindications (4)*]

#### **6.1 Clinical Trials Experience**

Because clinical trials are conducted under widely varying conditions, adverse reaction rates observed in clinical trials of a drug cannot be directly compared to rates in the clinical trials of another drug and may not reflect the rates observed in practice.

In five clinical trials of DED conducted with lifitegrast ophthalmic solution, 1401 patients received at least one dose of lifitegrast (1287 of which received lifitegrast 5%). The majority of patients (84%) had less than or equal to 3 months of treatment exposure. One hundred-seventy patients were exposed to lifitegrast for approximately 12 months. The majority of the treated patients were female (77%). The most common adverse reactions reported in 5%-25% of patients were instillation-site irritation, dysgeusia, and reduced visual acuity.

Other adverse reactions reported in 1%-5% of the patients were blurred vision, conjunctival hyperemia, eye irritation, headache, increased lacrimation, eye discharge, eye discomfort, eye pruritus, and sinusitis.

#### **6.2 Postmarketing Experience**

The following adverse reactions have been identified during post-approval use of Xiidra. Because these reactions are reported voluntarily from a population of uncertain size, it is not always possible to reliably estimate their frequency or establish a causal relationship to drug exposure.

Rare serious cases of hypersensitivity, including anaphylactic reaction, bronchospasm, respiratory distress, pharyngeal edema, swollen tongue, urticaria, allergic conjunctivitis, dyspnea, angioedema, and allergic dermatitis have been reported. Eye swelling and rash have also been reported [see *Contraindications (4)*].

### **8 USE IN SPECIFIC POPULATIONS**

#### **8.1 Pregnancy**

##### Risk Summary

There are no available data on Xiidra use in pregnant women to inform any drug-associated risks. Intravenous (IV) administration of lifitegrast to pregnant rats, from pre-mating through gestation day 17, did not produce

teratogenicity at clinically relevant systemic exposures. Intravenous administration of lifitegrast to pregnant rabbits during organogenesis produced an increased incidence of omphalocele at the lowest dose tested, 3 mg/kg/day (400-fold the human plasma exposure at the recommended human ophthalmic dose [RHOD], based on the area under the curve [AUC] level). Since human systemic exposure to lifitegrast following ocular administration of Xiidra at the RHOD is low, the applicability of animal findings to the risk of Xiidra use in humans during pregnancy is unclear [see *Clinical Pharmacology (12.3) in the full prescribing information*].

##### Data

##### Animal Data

Lifitegrast administered daily by IV injection to rats, from pre-mating through gestation day 17, caused an increase in mean pre-implantation loss and an increased incidence of several minor skeletal anomalies at 30 mg/kg/day, representing 5,400-fold the human plasma exposure at the RHOD of Xiidra, based on AUC. No teratogenicity was observed in the rat at 10 mg/kg/day (460-fold the human plasma exposure at the RHOD, based on AUC). In the rabbit, an increased incidence of omphalocele was observed at the lowest dose tested, 3 mg/kg/day (400-fold the human plasma exposure at the RHOD, based on AUC), when administered by IV injection daily from gestation days 7 through 19. A fetal no observed adverse effect level (NOAEL) was not identified in the rabbit.

#### **8.2 Lactation**

##### Risk Summary

There are no data on the presence of lifitegrast in human milk, the effects on the breastfed infant, or the effects on milk production. However, systemic exposure to lifitegrast from ocular administration is low [see *Clinical Pharmacology (12.3) in the full prescribing information*]. The developmental and health benefits of breastfeeding should be considered, along with the mother's clinical need for Xiidra and any potential adverse effects on the breastfed child from Xiidra.

#### **8.4 Pediatric Use**

Safety and efficacy in pediatric patients below the age of 17 years have not been established.

#### **8.5 Geriatric Use**

No overall differences in safety or effectiveness have been observed between elderly and younger adult patients.

Distributed by:  
Novartis Pharmaceuticals Corporation  
One Health Plaza  
East Hanover, NJ 07936  
T2020-87



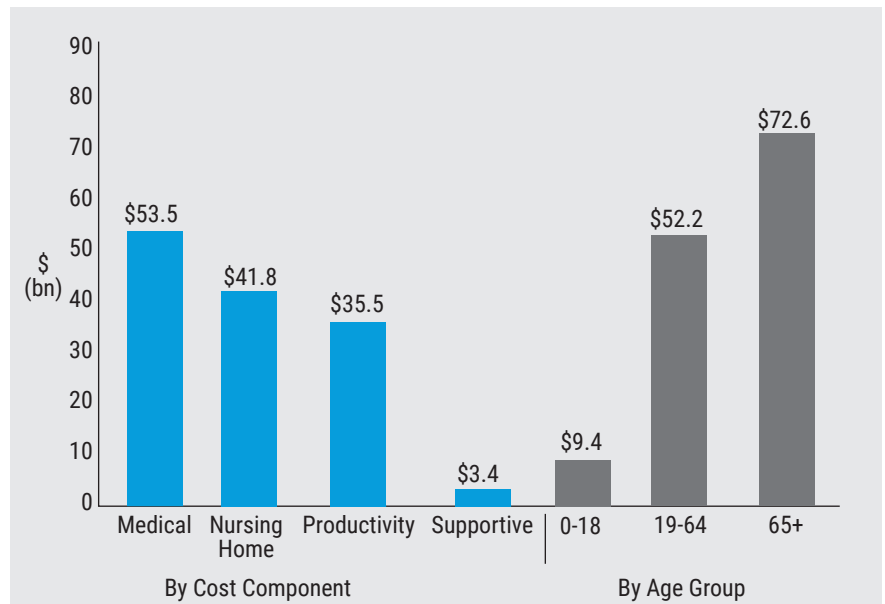
## Vision Loss Study Breaks Down National Cost Burden

Vision loss and blindness pose a significant economic burden on the United States.

Public health researchers at the National Opinion Research Center (NORC) at the University of Chicago confirmed the substantial economic hardship in a recently published cost estimate for the year 2017 and indicated that vision-loss resource allocation will likely differ by state due to the varied composition of per-person costs.

In the study, which was supported by a research contract from the Centers for Disease Control and Prevention's Vision Health Initiative, the researchers analyzed secondary data sources including the American Community Survey, American Time Use Survey, Bureau of Labor Statistics, Medical Expenditure Panel Survey, National and State Health Expenditure Accounts and National Health Interview Survey. Study participants included those who answered "yes" to the question, "Are you blind or do you have serious difficulty seeing even with glasses?"

"Based on that, we estimated that the total burden was \$134.2 billion," says David B. Rein, PhD, a program area director overseeing public health analytics at NORC's Public Health department. "Of this, most of the costs were direct costs totaling \$98.7 bn and indirect costs totaling \$35.5 bn. The largest components of total costs were incremental nursing home costs (\$41.8 bn), other medical



This graph shows the total cost of vision loss or blindness by burden component and age group in billions of dollars. (Source: Rein DB et al. 2022.)

costs including glasses and contact lenses and home health care (\$30.9 bn) and reduced labor force participation (\$16.2 bn)."

The total costs per person were fairly high at \$16,840 per affected person per year. "The sources of these costs varied by age group," he says. "For children 18 and younger, the main costs were associated with informal care provided by parents or caregivers who were spending extra time caring for children. For adults ages 19 to 64, the main costs came from reduced labor force participation, and for older adults (65 and older) the main costs were increased placement in nursing homes.

"State variations in costs were driven by regional differences in health care and nursing home costs, and by the age distribution of the state's population," Dr. Rein continues. "New York, Connecticut, Massachusetts, Rhode Island and Vermont had the highest costs per person with vision loss. The highest and lowest total burdens were seen in California (\$13.5 bn) and Wyoming (\$191 million), respectively." For more information on the cost breakdown by state and category, visit [cdc.gov/visionhealth/economics](https://cdc.gov/visionhealth/economics).

"We did our best to create this estimate, but there's a lot of variability and uncertainty," he notes. "We

feel good about the choices we made in estimating the burden, but it's plausible that the true burden could be as low as \$76 bn or as high as \$218 bn, based on different structural assumptions in the model, which we explain in the paper. This study measured costs only among people who report they are blind or have severe difficulty seeing even when wearing glasses. This likely underestimates the number of people with any type of vision loss in the country. We only measured costs associated with vision loss and blindness to get a clearer picture of the vision loss burden; we didn't estimate the costs for the care of all eye diseases that haven't resulted in vision loss, or the costs of routine eye care."

Dr. Rein notes two major differences between this study and previous NORC estimates from 2006 and 2013. "In the present study, we looked only at costs associated with vision loss and blindness, and we didn't attempt to estimate any medical care costs for vision or eye conditions that hadn't yet resulted in vision loss or blindness," he explains. "Additionally, we expanded the definition of vision loss to include all those who reported they were blind or had serious difficulty seeing, even with glasses, regardless of whether that vision impairment is correctable. Uncorrected refractive error is a large source of vision impairment in the United States and ignoring its impact will lead to underestimation of the true burden.

"It's difficult to make an exact

comparison among studies," he continues, "but it seems we're estimating higher costs than we did in the past—certainly compared to our 2006 estimate, which was limited primarily to medical care costs associated with four major vision and eye conditions. What we've shown in the present study is that there's a substantial cost associated with vision impairment and blindness itself."

Dr. Rein says prevention is key. "The policy change that would have the biggest bang for the buck would be increased efforts to identify and treat uncorrected refractive error," he says. "There are large potential savings in this—not just for medical care but in potentially averting productivity losses and reduced informal care—and of course the intangible but equally important benefits of improving people's day-to-day vision. Ensuring routine eye exams and eye health services are available and accessible to everyone regardless of income or insurance status or where they live would be another policy change that, while incurring costs upfront, will potentially save costs in the long run."

How might the COVID-19 pandemic have impacted these 2017 cost estimates? "We're all waiting on the data to see what happened with COVID," says Dr. Rein. "I think one major change would be the prevalence of vision loss in different populations. There's evidence that at least some people avoided necessary care during the pandemic who would otherwise have gotten

it. Some of this avoidance may have resulted in irreversible vision loss.

"There's also some evidence that severe SARS-CoV-2 infections can result in vision problems, and there are other vision problems that may be associated with long COVID," he says. "That would increase the number of individuals reporting vision problems in the years to come, and costs would be higher. On the other hand, COVID also hit the elderly population with the highest rates of mortality, especially among those in nursing homes, so the overall burden might decrease.

"Increased screen time associated with the pandemic may also be contributing to increases in myopia, especially among children," he adds. "However, we need to wait for additional surveys, claims datasets and EHR records that can give us better data on these questions."

Ultimately, Dr. Rein says this study helps to quantify the magnitude of the problem of vision loss and blindness in the United States. "The economic burden of vision loss is greater than many other conditions that also often get more attention," he says. "Ophthalmologists and optometrists can dramatically improve their patients' quality of life. Our study shows that eye care can also have the potential to reduce the economic burden of vision loss on society as a whole."

Rein DB, Wittenborn JS, Zhang Ping, et al. The economic burden of vision loss and blindness in the United States. *Ophthalmology* 2022;129:369-78.

(Continued on p. 17)

## INDUSTRY BRIEFS

### First Installment of *The Video Journal of Cataract, Refractive & Glaucoma Surgery* Now Available

The new video journal, titled "Great Lectures!" is now available. The videos feature lectures from Dr. Ehud Assia from Israel, who gave the ESCRS Binkhorst Lecture; Mr. Richard Packard from England, who gave the Choyce Lecture to the UKISCRS; and Dr. Michael Snyder, who recently delivered the Kelman Lecture at the 2021 AAO meeting.

The *Video Journal* is a free member benefit of virtually every cataract society, and a new one is released quarterly. To view the lectures free of charge, visit [www.vjcrs.com](http://www.vjcrs.com).

### Allergan Announces Topline Results for New Vuity Regimen

Presbyopia drop Vuity is already approved for q.d. dosing, but Allergan is investigating the potential of a b.i.d. regimen. The company says the Phase III VIRGO trial met its primary efficacy endpoint, improving near vision without compromising distance vision on day 14.



WHAT'S NEXT FOR YOUR POST-MIGS PATIENTS  
WITH UNCONTROLLED IOP?

# In Your Hands, XEN<sup>®</sup> Can Make a Difference



SEE WHAT XEN<sup>®</sup> GEL STENT CAN DO  
FOR POST-MIGS PATIENTS



Scan code or visit  
[hcp.xengelstent.com](http://hcp.xengelstent.com)

Not actual patients.

IOP = intraocular pressure. MIGS = minimally invasive glaucoma surgery.

## INDICATIONS

The XEN<sup>®</sup> Glaucoma Treatment System (XEN<sup>®</sup> 45 Gel Stent preloaded into a XEN<sup>®</sup> Injector) is indicated for the management of refractory glaucomas, including cases where previous surgical treatment has failed, cases of primary open-angle glaucoma, and pseudoexfoliative or pigmentary glaucoma with open angles that are unresponsive to maximum tolerated medical therapy.

## IMPORTANT SAFETY INFORMATION CONTRAINDICATIONS

XEN<sup>®</sup> Gel Stent is contraindicated in angle-closure glaucoma where angle has not been surgically opened, previous glaucoma shunt/valve or conjunctival scarring/pathologies in the target quadrant, active inflammation, active iris neovascularization, anterior chamber intraocular lens, intraocular silicone oil, and vitreous in the anterior chamber.

## WARNINGS

XEN<sup>®</sup> Gel Stent complications may include choroidal effusion, hyphema, hypotony, implant migration, implant exposure, wound leak, need for secondary surgical intervention, and intraocular surgery complications. Safety and effectiveness in neovascular, congenital, and infantile glaucoma has not been established. Avoid digital pressure following implantation of the XEN<sup>®</sup> Gel Stent to avoid the potential for implant damage.

## PRECAUTIONS

Examine the XEN<sup>®</sup> Gel Stent and XEN<sup>®</sup> Injector in the operating room prior to use. Monitor intraocular pressure (IOP) postoperatively and if not adequately maintained, manage appropriately. Stop the procedure immediately if increased resistance is observed during implantation and use a new XEN<sup>®</sup> system. Safety and effectiveness of more than a single implanted XEN<sup>®</sup> Gel Stent has not been studied.

## ADVERSE EVENTS

The most common postoperative adverse events included best-corrected visual acuity loss of  $\geq 2$  lines ( $\leq 30$  days 15.4%;  $> 30$  days 10.8%; 12 months 6.2%), hypotony IOP  $< 6$  mm Hg at any time (24.6%; no clinically significant consequences were associated, no cases of persistent hypotony, and no surgical intervention was required), IOP increase  $\geq 10$  mm Hg from baseline (21.5%), and needling procedure (32.3%).

Caution: Federal law restricts this device to sale by or on the order of a licensed physician. For the full Directions for Use, please visit [www.allergan.com/xen/usa.htm](http://www.allergan.com/xen/usa.htm) or call 1-800-678-1605. Please call 1-800-433-8871 to report an adverse event.



© 2022 AbbVie. All rights reserved. All trademarks are the property of their respective owners.  
US-XEN-220026 02/2022 015342

**XEN**<sup>®</sup>  
G E L S T E N T

A Powerful, Proven Procedure

## CONTRIBUTORS

### CHIEF MEDICAL EDITOR

Mark H. Blecher, MD

### CONTACT LENSES

Penny Asbell, MD

### CORNEA / ANTERIOR SEGMENT

Thomas John, MD

### GLAUCOMA MANAGEMENT

Peter Netland, MD, PHD  
Kuldev Singh, MD

### MEDICARE Q & A

Paul M. Larson, MBA

### PEDIATRIC PATIENT

Janine Collinge, MD

### PLASTIC POINTERS

Anna P. Murchison, MD, MPH

### REFRACTIVE SURGERY

Arturo S. Chayet, MD

### RETINAL INSIDER

Carl Regillo, MD, FACS  
Yoshihiro Yonekawa, MD

### TECHNOLOGY UPDATE

Steven T. Charles, MD  
Michael Colvard, MD

### WILLS RESIDENT CASE SERIES

Rakhi Melvani, MD

## ADVISORY BOARD

**PENNY A. ASBELL, MD**, MEMPHIS, TENN.

**BRANDON AYRES, MD**, PHILADELPHIA

**SURENDRA BASTI, MD**, CHICAGO

**WILLIAM I. BOND, MD**, PEKIN, ILL.

**ALAN N. CARLSON, MD**, DURHAM, N.C.

**Y. RALPH CHU, MD**, EDINA, MINN.

**ADAM J. COHEN, MD**, CHICAGO

**JANINE COLLINGE, MD**, FARMINGTON, CONN.

**UDAY DEVGAN, MD, FACS**, LOS ANGELES

**ERIC DONNENFELD, MD**, ROCKVILLE CENTRE, N.Y.

**DANIEL S. DURRIE, MD**, KANSAS CITY, MO.

**ROBERT EPSTEIN, MD**, MCHENRY, ILL.

**ROBERT D. FECHTNER, MD**, NEWARK, N.J.

**WILLIAM J. FISHKIND, MD**, TUCSON, ARIZ.

**BRIAN FRANCIS, MD**, Los Angeles

**JAMES P. GILLS, MD**, TARPON SPRINGS, FLA.

**HARRY GRABOW, MD**, SARASOTA, FLA.

**DOUGLAS K. GRAYSON, MD**, NEW YORK CITY

**DAVID R. HARDTEN, MD**, MINNEAPOLIS

**SARA J. HAUG, MD, PHD**, DURANGO, COLO.

**KENNETH J. HOFFER, MD**, SANTA MONICA, CALIF.

**JACK T. HOLLADAY, MD, MSEE**, HOUSTON

**JOHN D. HUNKELER, MD**, KANSAS CITY, MO.

**THOMAS JOHN, MD**, TINLEY PARK, ILL.

**ROBERT M. KERSHNER, MD, MS**, PALM BEACH GARDENS, FLA.

**GUY M. KEZIRIAN, MD**, PARADISE VALLEY, ARIZ.

**TERRY KIM, MD**, DURHAM, N.C.

**BRAD KLIGMAN, MD**, MANHASSET, N.Y.

**TOMMY KORN, MD**, SAN DIEGO

**DAVID A. LEE, MD**, HOUSTON

**FRANCIS S. MAH, MD**, LA JOLLA, CALIF.

**NICK MAMALIS, MD**, SALT LAKE CITY

**EDWARD MANCHE, MD**, PALO ALTO, CALIF.

**MIKE S. MCFARLAND, MD**, PINE BLUFF, ARK.

**JEFFREY B. MORRIS, MD, MPH**, ENCINITAS, CALIF.

**KEVIN MILLER, MD**, LOS ANGELES

**MARLENE R. MOSTER, MD**, PHILADELPHIA

**ANNA P. MURCHISON, MD, MPH**, PHILADELPHIA

**ROBERT J. NOECKER, MD**, FAIRFIELD, CONN.

**ROBERT OSHER, MD**, CINCINNATI

**MARK PACKER, MD**, WEST PALM BEACH, FLA.

**CHRISTOPHER J. RAPUANO, MD**, PHILADELPHIA

**AUGUST READER III, MD**, SAN FRANCISCO

**TONY REALINI, MD, MPH**, MORGANTOWN, W.V.

**KENNETH J. ROSENTHAL, MD**, GREAT NECK, N.Y.

**ERIC ROTHCHILD, MD**, DELRAY BEACH, FLA.

**SHERI ROWEN, MD**, BALTIMORE

**JAMES J. SALZ, MD**, LOS ANGELES

**INGRID U. SCOTT, MD, MPH**, HERSHEY, PA.

**JOEL SCHUMAN, MD**, PITTSBURGH

**GAURAV SHAH, MD**, ST. LOUIS

**DAVID R. STAGER JR., MD**, DALLAS

**KARL STONECIPHER, MD**, GREENSBORO, N.C.

**JAMES C. TSAI, MD**, NEW YORK CITY

**VANCE THOMPSON, MD**, SIOUX FALLS, S.D.

**FARRELL C. TYSON, MD**, CAPE CORAL, FLA.

**R. BRUCE WALLACE III, MD**, ALEXANDRIA, LA.



### BUSINESS OFFICES

19 CAMPUS BOULEVARD, SUITE 101  
NEWTOWN SQUARE, PA 19073  
SUBSCRIPTION INQUIRIES (877) 529-1746  
(USA ONLY); OUTSIDE USA, CALL (847) 763-9630

### BUSINESS STAFF

PUBLISHER

**MICHAEL HOSTER**

(610) 492-1028 MHOSTER@JOBSON.COM

SENIOR MANAGER, STRATEGIC ACCOUNTS

**MICHELE BARRETT**

(610) 492-1014 MBARRETT@JOBSON.COM

REGIONAL SALES MANAGER

**JONATHAN DARDINE**

(610) 492-1030 JDARDINE@JOBSON.COM

CLASSIFIED ADVERTISING

(888)-498-1460

PRODUCTION MANAGER

**FARRAH APONTE**

212-274-7057 FAPONTE@JOBSON.COM

PRODUCTION MANAGER

**KAREN LALLONE**

(610) 492-1010 KLALLONE@JOBSON.COM

SUBSCRIPTIONS

\$63 A YEAR, \$99 (U.S.) IN CANADA,  
\$158 (U.S.) IN ALL OTHER COUNTRIES.

SUBSCRIPTIONS E-MAIL:

REVOPHTHALMOLOGY@CAMBEYWEST.COM

### CIRCULATION

PO BOX 71, CONGERS, NY 10920-0071

(877) 529-1746

OUTSIDE USA: (845) 267-3065

SENIOR CIRCULATION MANAGER

**HAMILTON MAHER**

(212) 219-7870 hmaher@jhihealth.com

CEO, INFORMATION GROUP SERVICES

**MARC FERRARA**

SENIOR VICE PRESIDENT, OPERATIONS

**JEFF LEVITZ**

VICE PRESIDENT, HUMAN RESOURCES

**TAMMY GARCIA**

VICE PRESIDENT, CREATIVE SERVICES & PRODUCTION

**MONICA TETTAMANZI**

CORPORATE PRODUCTION DIRECTOR

**JOHN ANTHONY CAGGIANO**

VICE PRESIDENT, CIRCULATION

**JARED SONNERS**

395 Hudson Street, 3rd Floor,  
New York, NY 10014

REVIEW OF OPHTHALMOLOGY (ISSN 1081-0226; USPS No. 0012-345) is published monthly, 12 times per year by Jobson Medical Information, 395 Hudson Street, 3rd Floor, New York, NY 10014. Periodicals postage paid at New York, NY and additional mailing offices. Postmaster: Send address changes to Review of Ophthalmology, PO Box 71, Congers, NY 10929-0071. Subscription Prices: US One Year \$63.00, US Two Year \$112.00, Canada One Year \$99.00, Canada Two Year \$181.00, Int'l One Year \$158.00, Int'l Two Year \$274.00. For subscription information call (877) 529-1746 (USA only); outside USA, call (845) 267-3065. Or email us at revophtalmology@cambeywest.com. Canada Post: Publications Mail Agreement #40612608. Canada Returns to be sent to Bleuchip International, P.O. Box 25542, London, ON N6C 6B2.



## BRIEF SUMMARY OF PRESCRIBING INFORMATION

This Brief Summary does not include all the information needed to use LOTEMAX® SM safely and effectively. See full prescribing information for LOTEMAX® SM.

## LOTEMAX® SM (loteprednol etabonate ophthalmic gel) 0.38%

For topical ophthalmic use

Initial U.S. Approval: 1998

### INDICATIONS AND USAGE

LOTEMAX® SM is a corticosteroid indicated for the treatment of post-operative inflammation and pain following ocular surgery.

### DOSAGE AND ADMINISTRATION

Invert closed bottle and shake once to fill tip before instilling drops. Apply one drop of LOTEMAX® SM into the conjunctival sac of the affected eye three times daily beginning the day after surgery and continuing throughout the first 2 weeks of the post-operative period.

### CONTRAINDICATIONS

LOTEMAX® SM, as with other ophthalmic corticosteroids, is contraindicated in most viral diseases of the cornea and conjunctiva including epithelial herpes simplex keratitis (dendritic keratitis), vaccinia, and varicella, in mycobacterial infection of the eye and fungal diseases of ocular structures.

### WARNINGS AND PRECAUTIONS

**Intraocular Pressure (IOP) Increase:** Prolonged use of corticosteroids may result in glaucoma with damage to the optic nerve, defects in visual acuity and fields of vision. Steroids should be used with caution in the presence of glaucoma. If this product is used for 10 days or longer, intraocular pressure should be monitored.

**Cataracts:** Use of corticosteroids may result in posterior subcapsular cataract formation.

**Delayed Healing:** The use of steroids after cataract surgery may delay healing and increase the incidence of bleb formation. In those diseases causing thinning of the cornea or sclera, perforations have been known to occur with the use of topical steroids. The initial prescription and renewal of the medication order should be made by a physician only after examination of the patient with the aid of magnification such as slit lamp biomicroscopy and, where appropriate, fluorescein staining.

**Bacterial Infections:** Prolonged use of corticosteroids may suppress the host response and thus increase the hazard of secondary ocular infections. In acute purulent conditions of the eye, steroids may mask infection or enhance existing infection.

**Viral Infections:** Employment of a corticosteroid medication in the treatment of patients with a history of herpes simplex requires great caution. Use of ocular steroids may prolong the course and may exacerbate the severity of many viral infections of the eye (including herpes simplex).

**Fungal Infections:** Fungal infections of the cornea are particularly prone to develop coincidentally with long-term local steroid application. Fungus invasion must be considered in any persistent corneal ulceration where a steroid has been used or is in use. Fungal cultures should be taken when appropriate.

**Contact Lens Wear:** Contact lenses should not be worn when the eyes are inflamed.

### ADVERSE REACTIONS

Because clinical trials are conducted under widely varying conditions, adverse reaction rates observed in the clinical trials of a drug cannot be directly compared to rates in the clinical trials of another drug and may not reflect the rates observed in practice. Adverse reactions associated with ophthalmic steroids include elevated intraocular pressure, which may be associated with infrequent optic nerve damage, visual acuity and field defects, posterior subcapsular cataract formation, delayed wound healing and secondary ocular infection from pathogens including herpes simplex, and perforation of the globe where there is thinning of the cornea or sclera. There were no treatment-emergent adverse drug reactions that occurred in more than 1% of subjects in the three times daily group compared to vehicle.

### USE IN SPECIAL POPULATIONS

**Pregnancy:** Risk Summary: There are no adequate and well controlled studies with loteprednol etabonate in pregnant women. Loteprednol etabonate produced teratogenicity at clinically relevant doses in the rabbit and rat when administered orally during pregnancy. Loteprednol etabonate produced malformations when administered orally to pregnant rabbits at doses 4.2 times the recommended human ophthalmic dose (RHOD) and to pregnant

rats at doses 106 times the RHOD. In pregnant rats receiving oral doses of loteprednol etabonate during the period equivalent to the last trimester of pregnancy through lactation in humans, survival of offspring was reduced at doses 10.6 times the RHOD. Maternal toxicity was observed in rats at doses 1066 times the RHOD, and a maternal no observed adverse effect level (NOAEL) was established at 106 times the RHOD. The background risk of major birth defects and miscarriage for the indicated population is unknown. However, the background risk in the U.S. general population of major birth defects is 2 to 4%, and of miscarriage is 15 to 20%, of clinically recognized pregnancies. Data: *Animal Data.* Embryofetal studies were conducted in pregnant rabbits administered loteprednol etabonate by oral gavage on gestation days 6 to 18, to target the period of organogenesis. Loteprednol etabonate produced fetal malformations at 0.1 mg/kg (4.2 times the recommended human ophthalmic dose (RHOD) based on body surface area, assuming 100% absorption). Spina bifida (including meningocele) was observed at 0.1 mg/kg, and exencephaly and craniofacial malformations were observed at 0.4 mg/kg (17 times the RHOD). At 3 mg/kg (128 times the RHOD), loteprednol etabonate was associated with increased incidences of abnormal left common carotid artery, limb flexures, umbilical hernia, scoliosis, and delayed ossification. Abortion and embryofetal lethality (resorption) occurred at 6 mg/kg (256 times the RHOD). A NOAEL for developmental toxicity was not established in this study. The NOAEL for maternal toxicity in rabbits was 3 mg/kg/day. Embryofetal studies were conducted in pregnant rats administered loteprednol etabonate by oral gavage on gestation days 6 to 15, to target the period of organogenesis. Loteprednol etabonate produced fetal malformations, including absent innominate artery at 5 mg/kg (106 times the RHOD); and cleft palate, agnathia, cardiovascular defects, umbilical hernia, decreased fetal body weight and decreased skeletal ossification at 50 mg/kg (1066 times the RHOD). Embryofetal lethality (resorption) was observed at 100 mg/kg (2133 times the RHOD). The NOAEL for developmental toxicity in rats was 0.5 mg/kg (10.6 times the RHOD). Loteprednol etabonate was maternally toxic (reduced body weight gain) at 50 mg/kg/day. The NOAEL for maternal toxicity was 5 mg/kg. A peri-/postnatal study was conducted in rats administered loteprednol etabonate by oral gavage from gestation day 15 (start of fetal period) to postnatal day 21 (the end of lactation period). At 0.5 mg/kg (10.6 times the clinical dose), reduced survival was observed in live-born offspring. Doses  $\geq$  5 mg/kg (106 times the RHOD) caused umbilical hernia/incomplete gastrointestinal tract. Doses  $\geq$  50 mg/kg (1066 times the RHOD) produced maternal toxicity (reduced body weight gain, death), decreased number of live-born offspring, decreased birth weight, and delays in postnatal development. A developmental NOAEL was not established in this study. The NOAEL for maternal toxicity was 5 mg/kg.

**Lactation:** There are no data on the presence of loteprednol etabonate in human milk, the effects on the breastfed infant, or the effects on milk production. The developmental and health benefits of breastfeeding should be considered, along with the mother's clinical need for LOTEMAX® SM and any potential adverse effects on the breastfed infant from LOTEMAX® SM.

**Pediatric Use:** Safety and effectiveness of LOTEMAX® SM in pediatric patients have not been established.

**Geriatric Use:** No overall differences in safety and effectiveness have been observed between elderly and younger patients.

### NONCLINICAL TOXICOLOGY

**Carcinogenesis, Mutagenesis, Impairment of Fertility:** Long-term animal studies have not been conducted to evaluate the carcinogenic potential of loteprednol etabonate. Loteprednol etabonate was not genotoxic *in vitro* in the Ames test, the mouse lymphoma tk assay, or in the chromosomal aberration test in human lymphocytes, or *in vivo* in the mouse micronucleus assay. Treatment of male and female rats with 25 mg/kg/day of loteprednol etabonate (533 times the RHOD based on body surface area, assuming 100% absorption) prior to and during mating caused preimplantation loss and decreased the number of live fetuses/live births. The NOAEL for fertility in rats was 5 mg/kg/day (106 times the RHOD).

**Distributed by:** Bausch + Lomb, a division of  
Bausch Health US, LLC, Bridgewater, NJ 08807 USA  
**Manufactured by:** Bausch & Lomb Incorporated, Tampa, FL 33637 USA  
U.S. Patent Number: 10,596,107

LOTEMAX is a trademark of Bausch & Lomb Incorporated or its affiliates.  
© 2021 Bausch & Lomb Incorporated or its affiliates.

Based on 9669601 (Folded) 9669701 (Flat)  
LSM.0032.USA.21

Revised: 4/2020  
Issued: 2/2021

# LOTEMAX<sup>®</sup> SM

(loteprednol etabonate ophthalmic gel) 0.38%

CHOOSE BAUSCH + LOMB'S MOST ADVANCED CORTICOSTEROID DROP

# POWER

with SUBMICRON TECHNOLOGY

SOPHISTICATED<sup>1-3</sup>

STRONG<sup>4</sup>

STABLE<sup>2</sup>

## Indication

LOTEMAX<sup>®</sup> SM (loteprednol etabonate ophthalmic gel) 0.38% is a corticosteroid indicated for the treatment of post-operative inflammation and pain following ocular surgery.

## Important Safety Information

- LOTE<sup>®</sup>MAX<sup>®</sup> SM, as with other ophthalmic corticosteroids, is contraindicated in most viral diseases of the cornea and conjunctiva including epithelial herpes simplex keratitis (dendritic keratitis), vaccinia, and varicella, and also in mycobacterial infection of the eye and fungal diseases of ocular structures.
- Prolonged use of corticosteroids may result in glaucoma with damage to the optic nerve, defects in visual acuity and fields of vision. Steroids should be used with caution in the presence of glaucoma. If LOTE<sup>®</sup>MAX<sup>®</sup> SM is used for 10 days or longer, IOP should be monitored.
- Use of corticosteroids may result in posterior subcapsular cataract formation.
- The use of steroids after cataract surgery may delay healing and increase the incidence of bleb formation. In those with diseases causing thinning of the cornea or sclera, perforations have been known to occur with the use of topical steroids. The initial prescription and renewal of the medication order should be made by a physician only after examination of

the patient with the aid of magnification such as slit lamp biomicroscopy and, where appropriate, fluorescein staining.

- Prolonged use of corticosteroids may suppress the host response and thus increase the hazard of secondary ocular infections. In acute purulent conditions, steroids may mask infection or enhance existing infections.
- Employment of a corticosteroid medication in the treatment of patients with a history of herpes simplex requires great caution. Use of ocular steroids may prolong the course and may exacerbate the severity of many viral infections of the eye (including herpes simplex).
- Fungal infections of the cornea are particularly prone to develop coincidentally with long-term local steroid application. Fungus invasion must be considered in any persistent corneal ulceration where a steroid has been used or is in use. Fungal cultures should be taken when appropriate.
- Contact lenses should not be worn when the eyes are inflamed.
- There were no treatment-emergent adverse drug reactions that occurred in more than 1% of subjects in the three times daily group compared to vehicle.

You are encouraged to report negative side effects of prescription drugs to the FDA. Visit [www.fda.gov/medwatch](http://www.fda.gov/medwatch) or call 1-800-FDA-1088.

Please see Brief Summary of full Prescribing Information on adjacent page.

**References:** 1. Phillips E, Coffey MJ, Shower M. Viscoelastic and dissolution characterization of submicron loteprednol etabonate ophthalmic gel, 0.38%. Poster presented at: 2015 ARVO Annual Meeting; May 4, 2015; Denver, Colorado. 2. Data on file. Bridgewater, NJ: Bausch & Lomb Incorporated. 3. Cavet ME, Glogowski S, DiSalvo C, Richardson ME. Ocular pharmacokinetics of submicron loteprednol etabonate ophthalmic gel, 0.38% following topical administration in rabbits. Poster presented at: 2015 ARVO Annual Meeting; May 4, 2015; Denver, Colorado. 4. LOTE<sup>®</sup>MAX<sup>®</sup> SM [prescribing information]. Bridgewater, NJ: Bausch & Lomb Incorporated.

LOTEMAX is a trademark of Bausch & Lomb Incorporated or its affiliates.  
© 2022 Bausch & Lomb Incorporated or its affiliates. All rights reserved. LSM.0003.USA.22

**BAUSCH + LOMB**



# FEATURES

Vol. 29, No. 5 • MAY 2022

**Catch Up on the Latest News**  
Read *Review's* weekly newsletter  
online at [reviewofophthalmology.com](http://reviewofophthalmology.com).

26

## Outfitting Your Practice For the Future

Of all the pandemic-induced changes, which will become part of the new normal's modus operandi?

*Christine Leonard, Senior Associate Editor*

36

## Gene Therapy for Inherited Retinal Disease

A look at the results ophthalmic researchers and companies are generating as they explore genetic therapies for these difficult-to-treat conditions.

*Ankur Sudhir Gupta, MD, MS, and  
Glenn C. Yiu, MD, PhD*

42

## The Best Approach for Narrow-angle Patients

The age of the patient is one of the many factors to consider when treating patients with narrow angles, experts say.

*Michelle Stephenson,  
Contributing Editor*

46

## The Glaucoma Medication Pipeline, 2022

Catching up on the status of four eye drops being developed to target the disease.

*Leanne Spiegle, Associate Editor*

50

## Update: Private Equity In Ophthalmology

Many surgeons offer positive reports—but proceeding with caution is advised.

*Christopher Kent, Senior Editor*



# DEPARTMENTS

MAY 2022

## 5 News

---

## 14 EDITOR'S PAGE Spring Forward *Walter Bethke* Editor in Chief

---

## 16 MEDICARE Q & A Post-pandemic, Whither Telemedicine? When the public health emergency eventually ends, will telemedicine maintain its level of prominence? *Paul M. Larson, MBA, MMSc, COMT*

---

## 18 THE FORUM Look But Don't Touch *Mark H. Blecher, MD* Chief Medical Editor

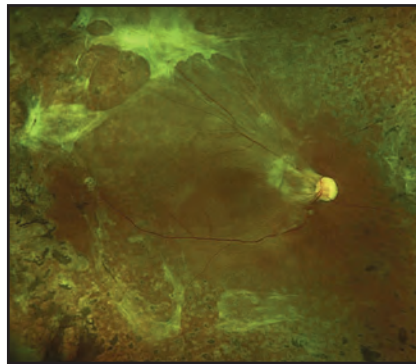


## 20 TECHNOLOGY UPDATE Promising New Ways to Monitor Glaucoma

New technologies are showing promise for more accurate monitoring—and predicting of—progression.

*Christopher Kent, Senior Editor*

---



## 60 RETINAL INSIDER The Gut Microbiome's Impact on the Retina The gut microbiome is being shown to have effects on many disease states, and retinal conditions are no exception. *Jason Xiao, Jason Zhang, Shivam Amin, MD, Urooba Nadeem, MD, Hugo Barba and Dimitra Skondra, MD, PhD*

## 65 GLAUCOMA MANAGEMENT Prostaglandins and IOP: What's Really Going On?

Evidence suggests that these drugs cause a long-term IOP reduction in some patients. Here's the latest.

*Douglas Rhee, MD*

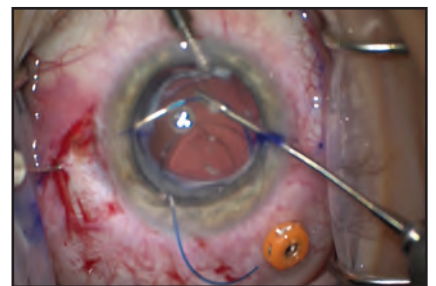
---

## 69 PRODUCT NEWS

---

## 71 WILLS EYE RESIDENT CASE SERIES An 18-year-old male has to contend with a very high refractive error.

*Collin Rozanski, MD, and  
Douglas Wisner, MD*



## 73 AD INDEX & CLASSIFIEDS

 VISIT US ON SOCIAL MEDIA

Facebook

[www.facebook.com/RevOphth](https://www.facebook.com/RevOphth)

Twitter

[twitter.com/RevOphth](https://twitter.com/RevOphth)

EVO

Visian ICL™

WOW

Now FDA approved.



**Editor in Chief**

**Walter Bethke**  
(610) 492-1024  
wbethke@jobson.com

**Senior Editor**

**Christopher Kent**  
(212) 274-7031  
ckent@jobson.com

**Senior Editor**

**Liz Hunter**  
(610) 492-1025  
ehunter@jobson.com

**Senior Associate Editor**

**Christine Leonard**  
(610) 492-1008  
cleonard@jobson.com

**Associate Editor**

**Leanne Spiegle**  
(610) 492-1026  
lspiegle@jobson.com

**Chief Medical Editor**

**Mark H. Blecher, MD**

**Senior Art Director**

**Jared Araujo**  
(610) 492-1032  
jaraujo@jobson.com

**Senior Graphic Designer**

**Matt Egger**  
(610) 492-1029  
megger@jobson.com

**International coordinator, Japan**

**Mitz Kaminuma**  
Reviewophthalgo@aol.com

**Business Offices**

19 Campus Boulevard, Suite 101  
Newtown Square, PA 19073  
(610) 492-1000  
Fax: (610) 492-1039

**Subscription inquiries:**

United States – (877) 529-1746  
Outside U.S. – (845) 267-3065  
E-mail:  
revophthalmology@cambeywest.com  
Website: www.reviewofophthalmology.com



# Spring Forward

**A**s I write this, it's nearly the end of Holy Week for us Catholics, which culminates in the celebration of Easter.

Besides its specific, important meaning for Christians, for centuries the time of the year surrounding what would become known as Easter was special to non-Christians as well. Though it's disputed, some hold that the term Easter is derived from the pre-Christian goddess Eostre, who represented the dawn, and the hope that accompanies a new spring.<sup>1</sup> Looking back over the past two years, a hopeful, new dawn would be welcome ...

At this time in 2020, almost to the day, I had sequestered myself in our house's basement; over the previous several days I'd developed some symptoms consistent with the then mysterious new disease COVID-19. COVID tests were difficult to come by, so rather than take any chances, I was staying away from the wife and kids, seeing my doctor via telemedicine. On Easter itself—which we spent alone since gatherings were scary ventures early in the pandemic—my wife dropped off dinner on a table in another room for me, and I ate it by myself, waving to my family. Luckily, the next day, the test that I was able to get came back negative, and I could rejoin the land of the living. It was an unnerving, scary time.

The spring of 2020 was a scary time for ophthalmology too, and ophthalmologists' practices probably felt like they'd also been rel-

egated to a basement filled with things like forced closures, employee furloughs and layoffs, and the complete stoppage of many of their go-to surgical procedures. It was a living nightmare, and it was hard to see a way through it all, or envision what the future was going to look like.

Thankfully—though it took a couple of years—we're finally beginning to see those first rays of dawn peek over the horizon. In fact, incredibly, surviving the crucible of the pandemic may have taught some practices how to make things even better. "Our [patient satisfaction] reviews have never been better," says a clinical practice manager interviewed for our cover story on page 26. "We feel more prepared to adapt if something similar to the pandemic happens in the future; we'll still be able to maintain a decent flow of patients."

Though I could do without anything similar to the pandemic, the sentiment is significant: Ophthalmology weathered the storm.

This year, whatever your personal beliefs are, let's hope that the spring's promised renewal is more than just symbolic, and instead represents the dawn of better days.

— *Walter Bethke*  
*Editor in Chief*

1. All About Eostre—The Pagan Goddess of Dawn.  
<http://www.arcane-alchemy.com/blog/2020/3/5/all-about-eostre-the-pagan-goddess-of-dawn>.





# SEE THINGS DIFFERENTLY

WITH EXCEPTIONAL CLARITY.



The CLAREON® COLLECTION of IOLs make the choice astoundingly clear. Alcon's most advanced lens design in one portfolio has evolved to meet cataract patients' needs, reliably.<sup>1,2</sup> So if you're looking to give patients exceptional clarity that lasts, look no further.<sup>3,4\*</sup>

Learn more at [Clareon.com](https://www.clareon.com)

\*Defined as modified Miyata grade 0, <25mv/mm<sup>2</sup> over 3 years (n=138), and over 9 years (n=20), respectively.

## IMPORTANT PRODUCT INFORMATION: CLAREON® FAMILY OF IOLS

**CAUTION:** Federal law restricts these devices to sale by or on the order of a physician.

**INDICATIONS:** The family of Clareon® intraocular lenses (IOLs) includes the **Clareon® Aspheric Hydrophobic Acrylic** and **Clareon® Aspheric Toric IOLs**, the **Clareon® PanOptix® Trifocal Hydrophobic IOL**, **Clareon® PanOptix® Toric**, **Clareon® Vivity™ Extended Vision Hydrophobic Posterior Chamber IOL** and **Clareon® Vivity™ Toric IOLs**. Each of these IOLs is indicated for visual correction of aphakia in adult patients following cataract surgery. In addition, the **Clareon® Toric IOLs** are indicated to correct pre-existing corneal astigmatism at the time of cataract surgery. The **Clareon® PanOptix®** lens mitigates the effects of presbyopia by providing improved intermediate and near visual acuity, while maintaining comparable distance visual acuity with a reduced need for eyeglasses, compared to a monofocal IOL. The **Clareon® Vivity™** lens mitigates the effects of presbyopia by providing an extended depth of focus. Compared to an aspheric monofocal IOL, the lens provides improved intermediate and near visual acuity, while maintaining comparable distance visual acuity. All of these IOLs are intended for placement in the capsular bag.

**WARNINGS/PRECAUTIONS: General cautions for all Clareon® IOLs:** Careful preoperative evaluation and sound clinical judgment should be used by the surgeon to decide the risk/benefit ratio before implanting any IOL in a patient with any of the conditions described in the Directions for Use that accompany each IOL. Physicians should target emmetropia, and ensure that IOL centration is achieved. **For the Clareon® Aspheric Toric, PanOptix® Toric and Vivity™ Toric IOLs**, the lens should not be implanted if the posterior capsule is ruptured, if the zonules are damaged, or if a primary posterior capsulotomy is planned. Rotation can reduce astigmatic correction; if necessary lens repositioning should occur as early as possible prior to lens encapsulation. **For the Clareon® PanOptix® IOL**, some visual effects may be expected due to the superposition of focused and unfocused multiple images. These may include some perceptions of halos or starbursts, as well as other visual symptoms. As with other multifocal IOLs, there is a possibility that visual symptoms may be significant enough that the patient will request explant of the multifocal IOL. A reduction in contrast sensitivity as compared to a monofocal IOL may be experienced by some patients and may be more prevalent in low lighting conditions. Therefore, patients implanted with multifocal IOLs should exercise caution when driving at night or in poor visibility conditions. Patients should be advised that unexpected outcomes could lead to continued spectacle dependence or the need for secondary surgical intervention (e.g., intraocular lens replacement or repositioning). As with other multifocal IOLs, patients may need glasses when reading small print or looking at small objects. Posterior capsule opacification (PCO), may significantly affect the vision of patients with multifocal IOLs sooner in its progression than patients with monofocal IOLs. **For the Clareon® Vivity™ IOL**, most patients implanted with the Vivity™ IOL are likely to experience significant loss of contrast sensitivity as compared to a monofocal IOL. Therefore, it is essential that prospective patients be fully informed of this risk before giving their consent for implantation of the **Clareon® Vivity™ IOL**. In addition, patients should be warned that they will need to exercise caution when engaging in activities that require good vision in dimly lit environments, such as driving at night or in poor visibility conditions, especially in the presence of oncoming traffic. It is possible to experience very bothersome visual disturbances, significant enough that the patient could request explant of the IOL. In the parent AcrySof® IQ Vivity™ IOL clinical study, 1% to 2% of AcrySof® IQ Vivity™ IOL patients reported very bothersome starbursts, halos, blurred vision, or dark area visual disturbances; however, no explants were reported. Prior to surgery, physicians should provide prospective patients with a copy of the Patient Information Brochure available from Alcon informing them of possible risks and benefits associated with these IOLs.

**ATTENTION:** Reference the Directions for Use labeling for each IOL for a complete listing of indications, warnings and precautions.

**References:** **1.** Clareon® IOL Directions for Use. **2.** Das KK, Werner L, Collins S, Hong X. In vitro and schematic model eye assessment of glare or positive dysphotopsia-type photic phenomena: Comparison of a new material IOL to other monofocal IOLs. *J Cataract Refract Surg.* 2019;45(2):219-227. **3.** Oshika T, Fujita Y, Inamura M, Miyata K. Mid-term and long-term clinical assessments of a new 1-piece hydrophobic acrylic IOL with hydroxyethyl methacrylate. *J Cataract Refract Surg.* 2020 May;46(5):682-687. **4.** Maxwell A, Suryakumar R. Long-term effectiveness and safety of a three-piece acrylic hydrophobic intraocular lens modified with hydroxyethyl-methacrylate: an open-label, 3-year follow-up study. *Clin Ophthalmol.* 2018;12:2031-2037.

**Alcon**

© 2022 Alcon Inc. 02/22 US-CLI-2100004

 Clareon. IOL Family





# Post-pandemic, Whither Telemedicine?

*When the official public health emergency eventually ends, will telemedicine maintain its level of prominence?*

Special coverage and payment provisions for telemedicine put into place due to the pandemic in the United States in 2020 remain in effect as you read this, but how long will it stay that way? What happens if the special coverage and payment provisions go away? It's a common question as we near the next possible renewal date, so let's dive in!

**Q** The public health emergency, although very challenging in terms of taking care of my patients in a new way. I never would have thought of telemedicine before COVID—but I use it regularly now. How could the government change what they cover and pay for via telemedicine?

**A** With all the lockdowns in force, in order to help patients and providers deliver care at the beginning of the COVID-19 pandemic, under the Public Health Service Act, Section 319, then-Secretary of Health and Human Services, Alex Azar, had the authority to declare a public health emergency (PHE) when a severe disease has become a significant threat to U.S. citizens.

This PHE, for the virus that causes COVID-19, SARS-CoV-2, was first

declared on January 31, 2020. PHEs remain in effect for 90 days unless renewed or terminated before then.

Secretary Azar renewed it until the change of administration, and current Secretary Xavier Becerra has maintained the status quo. As I write this, the current PHE for COVID-19 has been extended for another 90 days. Going forward, it helps to know that in January 2021 the Biden Administration committed in writing to give governors 60 days' notice before terminating the PHE early. So, when the next deadline nears,

if the president hasn't notified the governors, you know we have at least another 60 days.

This federal PHE allowed the HHS Secretary (the cabinet-level position that oversees Medicare) to grant Medicare the ability to invoke waivers of certain rules under Section 1135 of the Social Security Act. One of the most important pieces for us in eye care was that we gained a lot of flexibility in terms of how Medicare covered telemedicine. They also

changed some of the ways we file claims (place of service and modifiers), which resulted in payments that have been equal to how physicians would have been paid if they used the same CPT codes in the office. That's the long version of how the relaxed TM rules came into play.

**Q** What happens if the PHE declaration expires or is terminated?

**A** It's true that practices would have to go back to less flexibility on telemedicine if that happens. There are lots of things that would change, but in terms of 2022, ophthalmology is safe for telemedicine claims and payments under Medicare Part B for quite a while. The House of Representatives passed HR 2471 (the "Consolidated Appropriations Act, 2022"), and the Senate agreed. This bill was passed into law when the president signed it on March 15, 2022. This law had the effect of unlinking the TM provisions from the PHE. Among other things, it makes the current special rules remain in effect until 151 days after the expiration of the PHE. As of this writing, when you add that 151-day period to the 60 days' notice referenced above, it's apparent that practices will keep things status quo and continue to deliver and be paid for care at the current rates via audio-only or video for a while after the Public Health Emergency's expiration date. It seems inconceivable to me that CMS would initiate a harsh change at any time this year.

**Q** If I have not used TM a lot, is there a list of services I can look at to consider if it makes patient-care and financial sense?

**A** Yes, CMS publishes a list every year. You can find the current



2022 list on the CMS site inside the ZIP file at [www.cms.gov/Medicare/Medicare-General-Information/Telehealth/Telehealth-Codes](http://www.cms.gov/Medicare/Medicare-General-Information/Telehealth/Telehealth-Codes). Once you download and open the compressed “List of Telehealth Services for Calendar Year 2022” file, there are two files in the folder: One is an EXCEL file with the list of 2022 codes allowed, and the other has the same information, but in a less-familiar format. Importantly, it includes all the usual office-visit codes we use daily to file claims for outpatient care (Eye codes 92002-92014 and Evaluation and Management codes 99202-99215). Practices also gained the ability to use time-based telephone (audio-only) codes 99441-99443 and some of the “Online digital evaluation and management” codes 99421-99423. For our usual EM outpatient codes 99202-99215, with TM we can use time or the usual rules for code level selection. There are many other

codes on the approved TM list, but they’re less commonly used in eye care.

**Q My state let their special PHE declaration expire. What does that mean for my Medicare claims?**

**A** As I write this, only 20 of the states and territories still have a PHE declaration in force, but that has no effect at all on Medicare’s relaxed coverage and payment for TM, since its guidance applies to all states, even those like yours.

**Q How should I file TM claims if I haven’t done it before?**

**A** CMS changed the Place of Service from the usual 02 (Telemedicine) to 11 under the PHE. This had the effect of improving payment over the “facility payment rate,” which was far less. As of April 1, 2022, some Medicare contractors have indicated they’ll revert to

processing with place code 02. Most claim lines will use modifier 95 on each claim line filed and done via TM under these special rules, but be sure to check. Private payers might use different modifiers and approve different codes, but so far that’s not common. CPT introduced a new modifier, 93, but that hasn’t been widely adopted.

**Q What’s slated to happen in 2023 related to TM? Will we get to keep this flexibility?**

**A** For Medicare and other Federal payers, we just don’t know this early in 2022. The wide adoption of TM during the COVID-19 pandemic does make it seem that Medicare can’t go back to the old, highly restrictive rule from a couple of years ago where only certain codes were covered under special circumstances. Details about payment are also unknown at this point. ◀

## REVIEW NEWS

*(Continued from p. 6)*

# Risk Factors for Tube-shunt Revisions

Glaucoma drainage devices reduce intraocular pressure by creating an alternate drainage route for aqueous humor to bypass the diseased trabecular meshwork. Despite their benefits, GDDs are not without complications, such as tube exposures, that may necessitate repeat surgery. Researchers at Massachusetts Eye and Ear were able to elucidate subtle associations between both demographic and clinical characteristics and GDD removal or revision surgery by using data from the IRIS Registry. Dry-eye disease and chronic angle-closure glaucoma were associated with a higher risk of GDD revision or removal surgery, while factors such as diabetes, history of smoking and unknown/unreported race and ethnicity were associated with a lower risk of repeat GDD surgery.

The Registry noted 44,330 distinct patients who underwent at least one

GDD implantation, 7.6 percent of whom underwent subsequent GDD revision or removal surgery within six years. This incidence was lower than previously reported rates. Stratified risk analyses demonstrated that unknown race/ethnicity (HR: 0.83/0.68), diabetes (HR: 0.84) and history of smoking (HR: 0.86) decreased the risk of GDD revision, while chronic angle-closure glaucoma (HR: 1.32) and dry-eye disease (HR: 1.30) were associated with increased rates of GDD revision. Asian and black patients were noted to have a decreased risk of GDD removal, while Hispanic patients were at increased risk for GDD revision.

Factors associated with a decreased average time (in days) from original GDD surgery to revision/removal included male sex, unknown race and right-eye laterality. Factors associated with an increased average time

to GDD revision/removal included a history of a past eye procedure and active smoker status. Patients with diabetes were found to have GDD revision/removal earlier during their follow-up period compared with patients without diabetes.

“Although current evidence on risk factors associated with GDD revision or removal surgery is conflicting, the power provided by the enormity and diversity of the IRIS Registry may provide a more accurate representation of the factors associated with repeat GDD surgery,” the authors concluded in their paper. “Thus, it is helpful to consider the aforementioned factors when determining the prognosis of GDD surgery and choice for treatment.” ◀

Hall NE, Chang EK, Samuel S, et al. Risk factors for glaucoma drainage device revision or removal using the IRIS Registry. *Am J Ophthalmol.* April 2, 2022. [Epub ahead of print].



# Look But Don't Touch

*Musings on life, ophthalmology and the practice of medicine.*

**MARK H. BLECHER**  
CHIEF MEDICAL EDITOR

So many things changed as a result of the pandemic—and they won't be going back. The idea that we should physically distance ourselves from each other, socially or workwise, has pretty much become a permanent change to our lives. From standing six feet away while in line at the grocery to consulting with colleagues, it's likely we'll never think of physical space the same way again.

The problem—OK, one of many problems—is that medicine usually involves the “laying on of hands.” In internal medicine it's almost become quaint to actually perform a physical exam when you can now scan and test for everything. It's a bit different in ophthalmology. While we're not usually palpating a liver, we are touching an eyelid at some point, frequently almost nose-to-nose across the slit lamp. We went from being almost the least-contact specialty in medicine to one of the most, since it's quite difficult to do a full eye exam from across the room—or across town. At least it used to be.

That said, we all were forced to rethink the whole concept of proximity to our patients since the onset of COVID. It wasn't easy. Sure, you could get someone else to be close



Getty

to your patient to take a fundus photo, or have a patient FaceTime their own eye, but is that really an eye exam? Will that replace a “real” in-person exam? The answer to this question depends on what you're trying to achieve and diagnose. In the absence of being able to be up close and personal, this was all we had for non-emergent care. Health insurers and the government facilitated telemedicine, whatever it meant, by permitting and paying for remote care. Most of us adapted and implemented some form of this as needed. But is it adequate, and is it still valid now that we are hopefully into the endemic phase of COVID? How much of a place will telemedicine have going forward, and is this the future of medical exams? It's clear it can work for screening and for the follow-up for some conditions, but how will that integrate with everything else we do?

Our medical colleagues have it

easier. Do you really need to physically see your GI doc to follow up on your reflux? It's not like they're going to massage your esophagus. And do you need an in-person follow-up for your high blood pressure? These physicians were inclined to move to telemedicine anyway, and now it's a large part of what they do. Not so easy for us ophthalmologists. We've automated our exams a lot, but this usually requires a tech-savvy patient. You can't refract. It's tough to check a pupil. Forget a tight-slit-beam exam of the anterior chamber. And the parts of the exam that we can do digitally are usually administered by someone who has to put themselves “at risk” by being in the same room as the patient, such as when taking a fundus photograph.

Clearly, as technology improves, we'll be able to remotely examine a patient more completely and with greater detail. Self-administering eye-exam modules exist, in which the patient puts their head into a machine that refracts, photographs and checks intraocular pressure—and they'll only get better. But we have a long way to go to replace an in-person exam, not only for visualizing all the detail necessary for a good exam, but for creating that relationship with a patient that's at the heart of medicine.

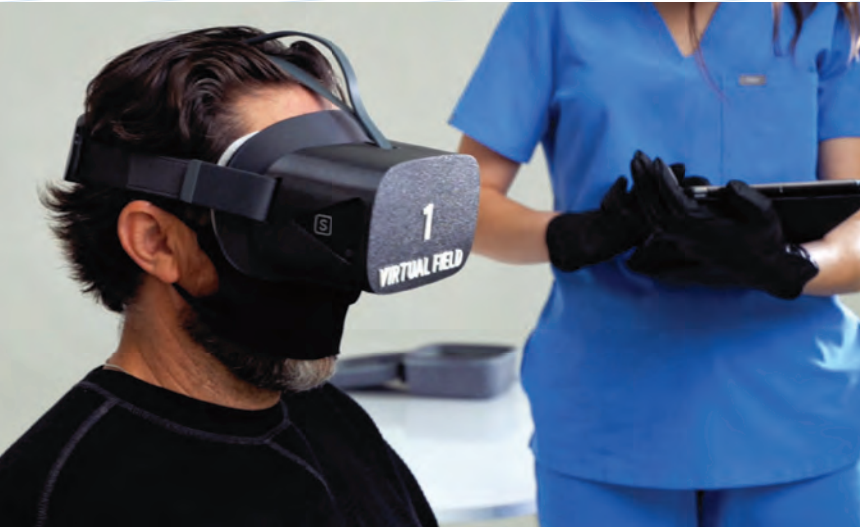I, like most ophthalmologists, love technology, and making life easier for our patients is always a good thing. Telemedicine can help. But while we will move this forward, we must be cautious of the unintended effects on quality of care and disruption to the delivery of care. We must take care to use this burgeoning technology to reshape our practices so this trend enhances, rather than degrades, what we're able to do. ◀



# NEW! VIRTUAL FIELD

THE VIRTUAL REALITY VISUAL FIELD THAT YOUR PATIENTS WILL LOVE

The Virtual Field provides greater efficiencies with reduced testing time and the ability to test multiple patients at once. The unit is easy to clean and no eye patch is needed for testing. Plus, the lightweight, mobile design enables patients to be tested comfortably and from anywhere with wifi access.



## FEATURES

- Progression analysis
- Monocular or binocular testing
- Access results from any laptop, tablet, or mobile device
- Audio instructions and error prompts in 34 languages
- Download reports as PDF/JPG files for upload into any EHR
- Qualifies for ADA tax credit

## SAVES MONEY

- Qualifies for ADA tax credit
- More affordable than traditional perimeters
- Lower maintenance costs

## SAVES TIME

- Reduced testing time
- Test multiple patients at once
- Audio instructions free up your technicians
- Easier to clean than traditional perimeters
- No eye patch necessary



## INCREASED ACCESSIBILITY

- Mobile and lightweight design
- Ability to test anywhere with wifi
- More manageable for wheelchair patients.



Contact us to learn more about this innovative technology.

**800-LOMBART | LOMBARTINSTRUMENT.COM**





EDITED BY MICHAEL COLVARD, MD  
AND STEVEN CHARLES, MD

## TECHNOLOGY UPDATE

# Promising New Ways to Monitor Glaucoma

*New technologies are showing promise for more accurate monitoring—and predicting of—progression.*

**CHRISTOPHER KENT**  
SENIOR EDITOR

**D**iagnosing glaucoma and detecting progression are challenging assignments. But as technology moves relentlessly forward, new ways to achieve these goals continue to appear. Here are three recently developed options that are showing great potential.

### Detecting Dying Cells

As you know, retinal ganglion cell loss is an early indication of glaucomatous damage. The two most common methods of monitoring for glaucomatous damage—visual fields and OCT—don't normally detect damage until a fair amount of damage has already occurred (especially visual fields, which require 20 to 40 percent of retinal cells to be damaged before it's detectable). Thus, finding alternate ways to detect signs of damage is desirable as a means to allow earlier treatment of patients at risk.

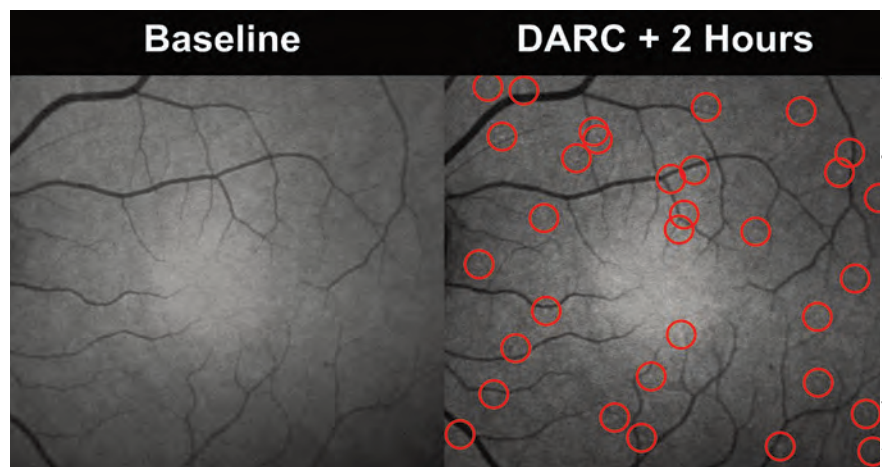
One unique way to determine the condition of a patient's retinal cells is called DARC (Detection of Apoptosing Retinal Cells). When retinal cells are in early stages of apoptosis, they externalize a cell membrane phospholipid called phosphatidylserine. Annexin A5 is a protein that has a high affinity for phosphati-

dyserine. In the DARC technique, developed by Francesca Cordeiro, a professor of ophthalmology at the UCL Institute of Ophthalmology and chair of ophthalmology at Imperial College in London, fluorescently labeled annexin attaches to the phosphatidylserine being externalized by cells in early stages of apoptosis. This makes them visible, so they can be imaged and measured using confocal scanning laser ophthalmoscopy. This gives researchers a way to quantify the number of retinal cells that are starting to die, *in vivo*.<sup>1-6</sup> Originally, the DARC annexin was given intravenously; they're now developing a way to ap-

ply it intranasally. (In multiple trials, involving 129 patients, intravenous annexin was found to be safe and well-tolerated.)

As you might imagine, one challenge when evaluating the condition of the retina using DARC is counting the marked cells in the captured images. Counting them manually is time-consuming, labor-intensive and shows considerable inter- and intra-operative variability.<sup>2</sup> In response, Prof. Cordeiro's group has developed a system using artificial intelligence to do the counting. Comparison of manual and automated counts using 66 DARC images showed that the automated counts were accurate and highly comparable to manual counting, while being faster and more reproducible. In another more recent study involving 60 images and the use of convolutional neural networks, an algorithm demonstrated 85.7-percent sensitivity and 91.7-percent specificity compared to manual counting.<sup>4</sup>

Also, this study found a significantly greater DARC count in pa-



ICORR, Imperial College Healthcare NHS Trust, Western Eye Hospital

**Two hours after the administration of fluorescent annexin, bright spots can be detected in the cSLO imaging of a patient's retina. These spots correspond to cells externalizing phosphatidylserine and therefore undergoing stressful conditions. The spots have been automatically identified by a convolutional neural network algorithm and circled in red.**

**This article has no commercial sponsorship.**

**Dr. Colvard** is a surgeon at the Colvard-Kandavel Eye Center in Los Angeles and a clinical professor of ophthalmology at the Keck School of Medicine of the University of Southern California. **Dr. Charles** is the founder of the Charles Retina Institute in Germantown, Tennessee.



tients who later progressed on OCT ( $p=0.0044$ ). This result was based on a small sample of patients, and so will need to be confirmed by larger studies in the future. Researchers in one of the studies<sup>4</sup> also looked at baseline age, central corneal thickness, blood pressure, visual field mean deviation, visual field index and average RNFL thickness; none of these was found to be a significant predictor of future progression. (However, they did find one OCT parameter that significantly correlated with future progression [ $p=0.045$ ]: the baseline topographically correspondent abnormal sectors on OCT RNFL and BMO-MRW imaging.)


The DARC approach has been in development for two decades, and it recently completed Phase II clinical trials. Although originally tested in models of preclinical glaucoma and optic neuropathy, it's also being tested as a potential tool for monitoring geographic atrophy, macular degeneration, Alzheimer's, Parkinson's and diabetes, as well as to assess the efficacy of therapies.

"DARC is an exciting new technology which is capable of delivering personalized medicine for eye diseases and beyond," says Prof. Cordeiro. "Being able to not only treat diseases before major impairment of function, but also monitor the efficacy of treatment, will help to minimize the impact of disease on the patient's quality of life."

"In addition to improvements to patient health care, DARC can accelerate the progress of clinical trials," she adds. "It can be used to enrich patient populations in studies by identifying individuals expressing high retinal cell stress. Furthermore, the DARC signal can be used as a clinical endpoint to assess the degree to which treatment was able to reduce apoptosis in the eye."

### Counting Cells: Adaptive Optics

The current clinical use of OCT to diagnose or monitor glaucoma progression is based upon measuring



**Combining OCT with adaptive optics makes it possible to do an actual retinal cell count *in vivo*. Above: En face (XY) and cross-sectional (XZ and YZ) slices illustrating soma detection and segmentation results in healthy vs. glaucomatous eyes. (Reprinted from Soltanian-Zadeh 2021<sup>7</sup> with permission from The Optical Society.)**

the thickness of retinal layers, as a stand-in for the number of healthy retinal cells. Clearly this is an imperfect substitute for an actual cell count, which may explain (at least in part) the well-known lack of perfect correlation between functional visual field measurements and OCT measurements.

Researchers are now developing ways to do an actual count of cells present in *in vivo* images of the retina, using adaptive optics, which improves the limited resolution of standard imaging systems. The use of this approach has been limited by the time-consuming and subjective process of manual marking, which has made it impractical for clinical use and large studies. Thus, researchers are now pursuing the use of AI to automate this process.

A recent paper from Professor Sina Farsiu, of Duke University in Durham, North Carolina, and colleagues provided an update on this

work.<sup>7</sup> The group is using what's called "weakly supervised deep learning," or WeakGCSEg, to train AI to segment and measure ganglion cell layer somas via adaptive-optics OCT images. ("Weakly supervised" refers to "weak annotations"—human click-points used in the training process to obtain the segmentation masks with minimal effort.)

Their results indicate that WeakGCSEg is at least as good as human experts at this operation, and superior to other AI networks that have been tried to date. It achieved high detection performance and precise soma diameter estimates. The amount of time saved compared to manual marking was significant; manual marking took between seven and eight hours per volume; WeakGCSEg took less than three minutes per volume. Furthermore, their system was able to achieve high performance regardless of the imaging device used, or the presence of



# WHAT COULD SHE SEE THIS YEAR?

 **EYLEA**<sup>®</sup>  
(aflibercept) Injection  
For Intravitreal Injection

*Inspired by a real patient  
with DME.*



**375  
MATH  
TESTS**

## **IMPORTANT SAFETY INFORMATION CONTRAINDICATIONS**

- EYLEA is contraindicated in patients with ocular or periocular infections, active intraocular inflammation, or known hypersensitivity to aflibercept or to any of the excipients in EYLEA.

## **WARNINGS AND PRECAUTIONS**

- Intravitreal injections, including those with EYLEA, have been associated with endophthalmitis and retinal detachments. Proper aseptic injection technique must always be used when administering EYLEA. Patients should be instructed to report any symptoms suggestive of endophthalmitis or retinal detachment without delay and should be managed appropriately. Intraocular inflammation has been reported with the use of EYLEA.
- Acute increases in intraocular pressure have been seen within 60 minutes of intravitreal injection, including with EYLEA. Sustained increases in intraocular pressure have also been reported after repeated intravitreal dosing with VEGF inhibitors. Intraocular pressure and the perfusion of the optic nerve head should be monitored and managed appropriately.
- There is a potential risk of arterial thromboembolic events (ATEs) following intravitreal use of VEGF inhibitors, including EYLEA. ATEs are defined as nonfatal stroke, nonfatal myocardial infarction, or vascular death (including deaths of unknown cause). The incidence of reported thromboembolic events in wet AMD studies during the first year was 1.8% (32 out of 1824) in the combined group of patients treated with EYLEA compared with 1.5% (9 out of 595) in patients treated with ranibizumab; through 96 weeks, the incidence was 3.3% (60 out of 1824) in the EYLEA group compared with 3.2% (19 out of 595) in the ranibizumab group. The incidence in the DME studies from baseline to week 52 was 3.3% (19 out of 578) in the combined group of patients treated with EYLEA compared with 2.8% (8 out of 287) in the control group; from baseline to week 100, the incidence was 6.4% (37 out of 578) in the combined group of patients treated with EYLEA compared with 4.2% (12 out of 287) in the control group. There were no reported thromboembolic events in the patients treated with EYLEA in the first six months of the RVO studies.

EYLEA is a registered trademark of Regeneron Pharmaceuticals, Inc.

**REGENERON**

© 2021, Regeneron Pharmaceuticals, Inc. All rights reserved.  
777 Old Saw Mill River Road, Tarrytown, NY 10591

# EYLEA ACHIEVED RAPID, SUSTAINED OUTCOMES IN DME

Demonstrated efficacy outcomes in VISTA and VIVID, phase 3 anti-VEGF trials in DME (N=862)<sup>1</sup>

Mean change in BCVA (ETDRS letters) at Year 1 from baseline<sup>1-5,\*</sup>

	Initial Gains (Month 5)		Primary Endpoint (Year 1)		Prespecified Exploratory Endpoint (Year 3)	
	VISTA	VIVID	VISTA	VIVID	VISTA	VIVID
EYLEA Q4	<b>+10.3</b> (n=154)	<b>+9.3</b> (n=136)	<b>+12.5</b> (n=154)	<b>+10.5</b> (n=136)	<b>+10.4</b> (n=154)	<b>+10.3</b> (n=136)
EYLEA Q8 <sup>†</sup>	<b>+9.9</b> (n=151)	<b>+9.3</b> (n=135)	<b>+10.7</b> (n=151)	<b>+10.7</b> (n=135)	<b>+10.5</b> (n=151)	<b>+11.7</b> (n=135)
Control	<b>+1.8</b> (n=154)	<b>+1.8</b> (n=132)	<b>+0.2</b> (n=154)	<b>+1.2</b> (n=132)	<b>+1.4</b> (n=154)	<b>+1.6</b> (n=132)

$P < 0.01$  vs control at Year 1.

The analyses of these exploratory endpoints were not multiplicity protected and are descriptive only.

Year 2 data was consistent with results seen in Year 1.<sup>5</sup>

**VISTA and VIVID study designs:** Two randomized, multicenter, double-masked, controlled clinical studies in which patients with DME (N=862; age range: 23-87 years, with a mean of 63 years) were randomized and received: 1) EYLEA 2 mg Q8 following 5 initial monthly doses; 2) EYLEA 2 mg Q4; or 3) macular laser photocoagulation (control) at baseline and then as needed. From Week 100, laser control patients who had not received EYLEA rescue treatment received EYLEA as needed per re-treatment criteria. Protocol-specified visits occurred every 28 ( $\pm 7$ ) days.<sup>1</sup>

In both clinical studies, the primary efficacy endpoint was the mean change from baseline in BCVA at Week 52, as measured by ETDRS letter score.<sup>1</sup>

\*Last observation carried forward; full analysis set.

<sup>†</sup>Following 5 initial monthly doses.

**SEE WHAT EYLEA COULD DO FOR YOUR PATIENTS WITH DME AT [HCP.EYLEA.US](http://HCP.EYLEA.US)**

anti-VEGF, anti-vascular endothelial growth factor; BCVA, best-corrected visual acuity; ETDRS, Early Treatment Diabetic Retinopathy Study; Q4, every 4 weeks; Q8, every 8 weeks.

## ADVERSE REACTIONS

- Serious adverse reactions related to the injection procedure have occurred in <0.1% of intravitreal injections with EYLEA including endophthalmitis and retinal detachment.
- The most common adverse reactions ( $\geq 5\%$ ) reported in patients receiving EYLEA were conjunctival hemorrhage, eye pain, cataract, vitreous detachment, vitreous floaters, and intraocular pressure increased.
- Patients may experience temporary visual disturbances after an intravitreal injection with EYLEA and the associated eye examinations. Advise patients not to drive or use machinery until visual function has recovered sufficiently.

## INDICATIONS

EYLEA® (aflibercept) Injection 2 mg (0.05 mL) is indicated for the treatment of patients with Neovascular (Wet) Age-related Macular Degeneration (AMD), Macular Edema following Retinal Vein Occlusion (RVO), Diabetic Macular Edema (DME), and Diabetic Retinopathy (DR).

**References:** 1. EYLEA® (aflibercept) Injection full U.S. Prescribing Information. Regeneron Pharmaceuticals, Inc. August 2019. 2. Korobelnik JF, Do DV, Schmidt-Erfurth U, et al. Intravitreal aflibercept for diabetic macular edema. *Ophthalmology*. 2014;121(11):2247-2254. doi:10.1016/j.ophtha.2014.05.006 3. Brown DM, Schmidt-Erfurth U, Do DV, et al. Intravitreal aflibercept for diabetic macular edema: 100-week results from the VISTA and VIVID studies. *Ophthalmology*. 2015;122(10):2044-2052. doi:10.1016/j.ophtha.2015.06.017 4. Data on file. Regeneron Pharmaceuticals, Inc. 5. Heier JS, Korobelnik JF, Brown DM, et al. Intravitreal aflibercept for diabetic macular edema: 148-week results from the VISTA and VIVID studies. *Ophthalmology*. 2016;123(11):2376-2385. doi:10.1016/j.ophtha.2016.07.032

Please see Brief Summary of Prescribing Information on the following page.

04/2021  
EYL.21.03.0211



**BRIEF SUMMARY**—Please see the EYLEA full Prescribing Information available on HCP.EYLEA.US for additional product information.

**1 INDICATIONS AND USAGE**

EYLEA is a vascular endothelial growth factor (VEGF) inhibitor indicated for the treatment of patients with:

**Neovascular (Wet) Age-Related Macular Degeneration (AMD), Macular Edema Following Retinal Vein Occlusion (RVO), Diabetic Macular Edema (DME), Diabetic Retinopathy (DR).**

**4 CONTRAINDICATIONS**

**4.1 Ocular or Periocular Infections**

EYLEA is contraindicated in patients with ocular or periocular infections.

**4.2 Active Intraocular Inflammation**

EYLEA is contraindicated in patients with active intraocular inflammation.

**4.3 Hypersensitivity**

EYLEA is contraindicated in patients with known hypersensitivity to aflibercept or any of the excipients in EYLEA. Hypersensitivity reactions may manifest as rash, pruritus, urticaria, severe anaphylactic/anaphylactoid reactions, or severe intraocular inflammation.

**5 WARNINGS AND PRECAUTIONS**

**5.1 Endophthalmitis and Retinal Detachments**

Intravitreal injections, including those with EYLEA, have been associated with endophthalmitis and retinal detachments [see *Adverse Reactions (6.J)*]. Proper aseptic injection technique must always be used when administering EYLEA. Patients should be instructed to report any symptoms suggestive of endophthalmitis or retinal detachment without delay and should be managed appropriately [see *Patient Counseling Information (17)*].

**5.2 Increase in Intraocular Pressure**

Acute increases in intraocular pressure have been seen within 60 minutes of intravitreal injection, including with EYLEA [see *Adverse Reactions (6.J)*]. Sustained increases in intraocular pressure have also been reported after repeated intravitreal dosing with vascular endothelial growth factor (VEGF) inhibitors. Intraocular pressure and the perfusion of the optic nerve head should be monitored and managed appropriately.

**5.3 Thromboembolic Events**

There is a potential risk of arterial thromboembolic events (ATEs) following intravitreal use of VEGF inhibitors, including EYLEA. ATEs are defined as nonfatal stroke, nonfatal myocardial infarction, or vascular death (including deaths of unknown cause). The incidence of reported thromboembolic events in wet AMD studies during the first year was 1.8% (32 out of 1824) in the combined group of patients treated with EYLEA compared with 1.5% (9 out of 595) in patients treated with ranibizumab; through 96 weeks, the incidence was 3.3% (60 out of 1824) in the EYLEA group compared with 3.2% (19 out of 595) in the ranibizumab group. The incidence in the DME studies from baseline to week 52 was 3.3% (19 out of 578) in the combined group of patients treated with EYLEA compared with 2.8% (8 out of 287) in the control group; from baseline to week 100, the incidence was 6.4% (37 out of 578) in the combined group of patients treated with EYLEA compared with 4.2% (12 out of 287) in the control group. There were no reported thromboembolic events in the patients treated with EYLEA in the first six months of the RVO studies.

**6 ADVERSE REACTIONS**

The following potentially serious adverse reactions are described elsewhere in the labeling:

- Hypersensitivity [see *Contraindications (4.3)*]
- Endophthalmitis and retinal detachments [see *Warnings and Precautions (5.1)*]
- Increase in intraocular pressure [see *Warnings and Precautions (5.2)*]
- Thromboembolic events [see *Warnings and Precautions (5.3)*]

**6.1 Clinical Trials Experience**

Because clinical trials are conducted under widely varying conditions, adverse reaction rates observed in the clinical trials of a drug cannot be directly compared to rates in other clinical trials of the same or another drug and may not reflect the rates observed in practice.

A total of 2980 patients treated with EYLEA constituted the safety population in eight phase 3 studies. Among those, 2379 patients were treated with the recommended dose of 2 mg. Serious adverse reactions related to the injection procedure have occurred in <0.1% of intravitreal injections with EYLEA including endophthalmitis and retinal detachment. The most common adverse reactions (≥5%) reported in patients receiving EYLEA were conjunctival hemorrhage, eye pain, cataract, vitreous detachment, vitreous floaters, and intraocular pressure increased.

**Neovascular (Wet) Age-Related Macular Degeneration (AMD).** The data described below reflect exposure to EYLEA in 1824 patients with wet AMD, including 1223 patients treated with the 2-mg dose, in 2 double-masked, controlled clinical studies (VIEW1 and VIEW2) for 24 months (with active control in year 1).

Safety data observed in the EYLEA group in a 52-week, double-masked, Phase 2 study were consistent with these results.

**Table 1: Most Common Adverse Reactions (≥1%) in Wet AMD Studies**

Adverse Reactions	Baseline to Week 52		Baseline to Week 96	
	EYLEA (N=1824)	Active Control (ranibizumab) (N=595)	EYLEA (N=1824)	Control (ranibizumab) (N=595)
Conjunctival hemorrhage	25%	28%	27%	30%
Eye pain	9%	9%	10%	10%
Cataract	7%	7%	13%	10%
Vitreous detachment	6%	6%	8%	8%
Vitreous floaters	6%	7%	8%	10%
Intraocular pressure increased	5%	7%	7%	11%
Ocular hyperemia	4%	8%	5%	10%
Corneal epithelium defect	4%	5%	5%	6%
Detachment of the retinal pigment epithelium	3%	3%	5%	5%
Injection site pain	3%	3%	3%	4%
Foreign body sensation in eyes	3%	4%	4%	4%
Lacrimation increased	3%	1%	4%	2%
Vision blurred	2%	2%	4%	3%
Intraocular inflammation	2%	3%	3%	4%
Retinal pigment epithelium tear	2%	1%	2%	2%
Injection site hemorrhage	1%	2%	2%	2%
Eyelid edema	1%	2%	2%	3%
Corneal edema	1%	1%	1%	1%
Retinal detachment	<1%	<1%	1%	1%

Less common serious adverse reactions reported in <1% of the patients treated with EYLEA were hypersensitivity, retinal tear, and endophthalmitis.

**Macular Edema Following Retinal Vein Occlusion (RVO).** The data described below reflect 6 months exposure to EYLEA with a monthly 2 mg dose in 218 patients following central retinal vein occlusion (CRVO) in 2 clinical studies (COPERNICUS and GALILEO) and 91 patients following branch retinal vein occlusion (BRVO) in one clinical study (VIBRANT).

**Table 2: Most Common Adverse Reactions (≥1%) in RVO Studies**

Adverse Reactions	CRVO		BRVO	
	EYLEA (N=218)	Control (N=142)	EYLEA (N=91)	Control (N=92)
Eye pain	13%	5%	4%	5%
Conjunctival hemorrhage	12%	11%	20%	4%
Intraocular pressure increased	8%	6%	2%	0%
Corneal epithelium defect	5%	4%	2%	0%
Vitreous floaters	5%	1%	1%	0%
Ocular hyperemia	5%	3%	2%	2%
Foreign body sensation in eyes	3%	5%	3%	0%
Vitreous detachment	3%	4%	2%	0%
Lacrimation increased	3%	4%	3%	0%
Injection site pain	3%	1%	1%	0%
Vision blurred	1%	<1%	1%	1%
Intraocular inflammation	1%	1%	0%	0%
Cataract	<1%	1%	5%	0%
Eyelid edema	<1%	1%	1%	0%

Less common adverse reactions reported in <1% of the patients treated with EYLEA in the CRVO studies were corneal edema, retinal tear, hypersensitivity, and endophthalmitis.

**Diabetic Macular Edema (DME) and Diabetic Retinopathy (DR).** The data described below reflect exposure to EYLEA in 578 patients with DME treated with the 2-mg dose in 2 double-masked, controlled clinical studies (VIVID and VISTA) from baseline to week 52 and from baseline to week 100.

**Table 3: Most Common Adverse Reactions (≥1%) in DME Studies**

Adverse Reactions	Baseline to Week 52		Baseline to Week 100	
	EYLEA (N=578)	Control (N=287)	EYLEA (N=578)	Control (N=287)
Conjunctival hemorrhage	28%	17%	31%	21%
Eye pain	9%	6%	11%	9%
Cataract	8%	9%	19%	17%
Vitreous floaters	6%	3%	8%	6%
Corneal epithelium defect	5%	3%	7%	5%
Intraocular pressure increased	5%	3%	9%	5%
Ocular hyperemia	5%	6%	5%	6%
Vitreous detachment	3%	3%	8%	6%
Foreign body sensation in eyes	3%	3%	3%	3%
Lacrimation increased	3%	2%	4%	2%
Vision blurred	2%	2%	3%	4%
Intraocular inflammation	2%	<1%	3%	1%
Injection site pain	2%	<1%	2%	<1%
Eyelid edema	<1%	1%	2%	1%

Less common adverse reactions reported in <1% of the patients treated with EYLEA were hypersensitivity, retinal detachment, retinal tear, corneal edema, and injection site hemorrhage.

Safety data observed in 269 patients with nonproliferative diabetic retinopathy (NPDR) through week 52 in the PANORAMA trial were consistent with those seen in the phase 3 VIVID and VISTA trials (see Table 3 above).

**6.2 Immunogenicity**

As with all therapeutic proteins, there is a potential for an immune response in patients treated with EYLEA. The immunogenicity of EYLEA was evaluated in serum samples. The immunogenicity data reflect the percentage of patients whose test results were considered positive for antibodies to EYLEA in immunoassays. The detection of an immune response is highly dependent on the sensitivity and specificity of the assays used, sample handling, timing of sample collection, concomitant medications, and underlying disease. For these reasons, comparison of the incidence of antibodies to EYLEA with the incidence of antibodies to other products may be misleading.

In the wet AMD, RVO, and DME studies, the pre-treatment incidence of immunoreactivity to EYLEA was approximately 1% to 3% across treatment groups. After dosing with EYLEA for 24-100 weeks, antibodies to EYLEA were detected in a similar percentage range of patients. There were no differences in efficacy or safety between patients with or without immunoreactivity.

**8 USE IN SPECIFIC POPULATIONS**

**8.1 Pregnancy Risk Summary**

Adequate and well-controlled studies with EYLEA have not been conducted in pregnant women. Aflibercept produced adverse embryofetal effects in rabbits, including external, visceral, and skeletal malformations. A fetal No Observed Adverse Effect Level (NOAEL) was not identified. At the lowest dose shown to produce adverse embryofetal effects, systemic exposures (based on AUC for free aflibercept) were approximately 6 times higher than AUC values observed in humans after a single intravitreal treatment at the recommended clinical dose [see *Animal Data*].

Animal reproduction studies are not always predictive of human response, and it is not known whether EYLEA can cause fetal harm when administered to a pregnant woman. Based on the anti-VEGF mechanism of action for aflibercept, treatment with EYLEA may pose a risk to human embryofetal development. EYLEA should be used during pregnancy only if the potential benefit justifies the potential risk to the fetus.

All pregnancies have a background risk of birth defect, loss, or other adverse outcomes. The background risk of major birth defects and miscarriage for the indicated population is unknown. In the U.S. general population, the estimated background risk of major birth defects and miscarriage in clinically recognized pregnancies is 2-4% and 15-20%, respectively.

**Data**

**Animal Data**

In two embryofetal development studies, aflibercept produced adverse embryofetal effects when administered every three days during organogenesis to pregnant rabbits at intravenous doses ≥3 mg per kg, or every six days during organogenesis at subcutaneous doses ≥0.1 mg per kg.

Adverse embryofetal effects included increased incidences of postimplantation loss and fetal malformations, including anasarca, umbilical hernia, diaphragmatic hernia, gastroschisis, cleft palate, ectrodactyly, intestinal atresia, spina bifida, encephalomenocele, heart and major vessel defects, and skeletal malformations (fused vertebrae, sternabrae, and ribs; supernumerary vertebral arches and ribs; and incomplete ossification). The maternal No Observed Adverse Effect Level (NOAEL) in these studies was 3 mg per kg. Aflibercept produced fetal malformations at all doses assessed in rabbits and the fetal NOAEL was not identified. At the lowest dose shown to produce adverse embryofetal effects in rabbits (0.1 mg per kg), systemic exposure (AUC) of free aflibercept was approximately 6 times higher than systemic exposure (AUC) observed in humans after a single intravitreal dose of 2 mg.

**8.2 Lactation Risk Summary**

There is no information regarding the presence of aflibercept in human milk, the effects of the drug on the breastfed infant, or the effects of the drug on milk production/excretion. Because many drugs are excreted in human milk, and because the potential for absorption and harm to infant growth and development exists, EYLEA is not recommended during breastfeeding.

The developmental and health benefits of breastfeeding should be considered along with the mother's clinical need for EYLEA and any potential adverse effects on the breastfed child from EYLEA.

**8.3 Females and Males of Reproductive Potential Contraception**

Females of reproductive potential are advised to use effective contraception prior to the initial dose, during treatment, and for at least 3 months after the last intravitreal injection of EYLEA.

**Infertility**

There are no data regarding the effects of EYLEA on human fertility. Aflibercept adversely affected female and male reproductive systems in cynomolgus monkeys when administered by intravenous injection at a dose approximately 1500 times higher than the systemic level observed humans with an intravitreal dose of 2 mg. A No Observed Adverse Effect Level (NOAEL) was not identified. These findings were reversible within 20 weeks after cessation of treatment.

**8.4 Pediatric Use**

The safety and effectiveness of EYLEA in pediatric patients have not been established.

**8.5 Geriatric Use**

In the clinical studies, approximately 76% (2049/2701) of patients randomized to treatment with EYLEA were ≥65 years of age and approximately 46% (1250/2701) were ≥75 years of age. No significant differences in efficacy or safety were seen with increasing age in these studies.

**17 PATIENT COUNSELING INFORMATION**

In the days following EYLEA administration, patients are at risk of developing endophthalmitis or retinal detachment. If the eye becomes red, sensitive to light, painful, or develops a change in vision, advise patients to seek immediate care from an ophthalmologist [see *Warnings and Precautions (5.1)*].

Patients may experience temporary visual disturbances after an intravitreal injection with EYLEA and the associated eye examinations [see *Adverse Reactions (6)*]. Advise patients not to drive or use machinery until visual function has recovered sufficiently.

**REGENERON**

Manufactured by:  
Regeneron Pharmaceuticals, Inc.  
777 Old Saw Mill River Road  
Tarrytown, NY 10591

EYLEA is a registered trademark of Regeneron Pharmaceuticals, Inc.  
© 2020, Regeneron Pharmaceuticals, Inc.  
All rights reserved.

Issue Date: 08/2019  
Initial U.S. Approval: 2011

Based on the August 2019 EYLEA® (aflibercept) Injection full Prescribing Information.

EYL.20.09.0052



pathology or retinal eccentricity.

Other findings included:

- soma diameters in glaucoma subjects' eyes were larger than in healthy eyes;
- there was a strong linear correlation between local ganglion cell layer density and measured thickness. (Thickness values measured by clinical OCT don't usually correlate well with local cell density.)
- They found an increase in the correlation between structure and function (as measured by visual field) for glaucoma patients when using WeakCGSeg instead of OCT thickness measurements.

In future studies, the authors hope to investigate the structure-function relationship at different levels of disease using the WeakCGSeg system. In the meantime, they hope this system may make large-scale, multisite clinical trials feasible, leading to a much greater potential understanding of diseases involving retinal pathology.

### New Iterations of Perimetry

Measuring a patient's visual function with perimetry has always been a crucial part of diagnosing and monitoring glaucoma. However, despite improvements in the test over time, including the current availability of multiple variations in testing patterns, test strategy and stimulus size, the standard test requires a patient to come to the office and stare into a machine for several minutes. As every ophthalmologist knows, this isn't anyone's favorite testing experience. And in terms of collecting meaningful data, there can be problems with patient attention span, fatigue and understanding the instructions, among other issues. Furthermore, such tests are only given twice a year at most, under ordinary circumstances, for a number of reasons (including the necessity of the patient coming to your office to take the test).

With the advent of digital technology, new options for testing the

visual field are being developed that don't require coming to the office or sticking one's face into a stationary machine. In particular, visual field testing can now be done using a computer tablet or a virtual reality headset. The disadvantage of these options is the possibility of collecting less-accurate data; the offsetting factor is that because such testing can be done outside the office—and is easier and more fun for the patient—the testing can be repeated much more frequently. Statistically speaking, having significantly more low-resolution data may be just as useful as having less frequent high-resolution data.

In terms of testing with a tablet, one of the best known is the Melbourne Rapid Fields Test, available as a free iPad app called “visualFields easy” (<https://itunes.apple.com/us/app/visualfields-easy/id495389227>). The test uses a moving fixation target to test up to 30 degrees of the visual field. Clinical studies have indicated that it has good test-retest repeatability and correlates well with Humphrey visual field testing.<sup>8</sup>

An obvious limitation of using a tablet for this kind of testing is the inability to control the distance from the eye to the screen, as well as having no way to monitor the patient's level of accurate fixation. Testing using a virtual reality headset can solve those problems using gaze tracking. Essentially, the stimulus can be shown at the appropriate position relative to fixation no matter where the patient is looking. (Gyroscopes account for head movement.) Other advantages include improved user engagement because of the immersive environment, and the ability to test one eye at a time without patching the other eye.

A number of these devices are now available, including the Visu-ALL from Olleyes ([olleyes.com](http://olleyes.com)), which can also test visual acuity, color vision, and contrast sensitivity; Vivid Vision ([seevidly.com](http://seevidly.com)); Vir-

tual Field (Virtual Field/Lombart); BioFormatix's VirtualEye Perimeter ([bioformatix.com/perimetry.html](http://bioformatix.com/perimetry.html)); MicroMedical Devices' PalmScan VF2000 ([micromedinc.com/our-devices/palmscan-vf2000-visual-field-perimeter](http://micromedinc.com/our-devices/palmscan-vf2000-visual-field-perimeter)); and Elisar's eCloud Perimeter ([elisar.com](http://elisar.com)). Another device under development is the nGoggle, a virtual reality headset that includes embedded EEG sensors that can detect when the patient is seeing the stimulus, eliminating the need for the patient to use a manual device such as a clicker to indicate that a stimulus was seen ([ngoggle.com/product](http://ngoggle.com/product)).

Felipe A. Medeiros, MD, PhD, Distinguished Professor of Ophthalmology, director of clinical research and vice chair for technology at Duke University, notes that, to the best of his knowledge, these new alternatives all lack long-term validation of their potential ability to detect glaucoma progression over time. “Studies such as the Vingrys study<sup>8</sup> of the tablet-based visual field software have demonstrated good agreement with the Humphrey test and good reproducibility,” he notes. “These devices may enable more frequent testing, which would be a very welcome addition, but they still need validation as tools for detection of progression.” ◀

1. Cordeiro MF, Hill D, Patel R, Corazza P, et al. Detecting retinal cell stress and apoptosis with DARC: Progression from lab to clinic. *Prog Retin Eye Res* 2022;86:100976.
2. Bizrah M, Dakin SC, Guo L, Rahman F, et al. A semi-automated technique for labeling and counting of apoptosing retinal cells. *BMC Bioinformatics* 2014;15:169.
3. Guo L, Cordeiro MF. Assessment of neuroprotection in the retina with DARC. *Prog Brain Res* 2008;173:437-50.
4. Normando EM, Yap TE, Maddison J, et al. A CNN-aided method to predict glaucoma progression using DARC (Detection of Apoptosing Retinal Cells). *Expert Rev Mol Diagn* 2020;7:737-748.
5. Normando EM, Dehabadi MH, Guo L, et al. Real-time imaging of retinal cell apoptosis by confocal scanning laser ophthalmoscopy. *Methods Mol Biol* 2015;1254:227-37.
6. Yap TE, Davis BM, Guo L, et al. Annexins in Glaucoma. *Int J Mol Sci* 2018;19:4:1218.
7. Soltanian-Zadeh S, Kurokawa K, Liu Z, et al. Weakly supervised individual ganglion cell segmentation from adaptive optics OCT images for glaucomatous damage assessment. *Optica* 2021;8:5:642-651.
8. 6. Prea SM, Kong YXG, Mehta A, et al. Six-month longitudinal comparison of a portable tablet perimeter with the Humphrey Field Analyzer. *Am J Ophthalmol* 2018;190:9-16.

# OUTFITTING YOUR PRACTICE FOR THE FUTURE

Of all the pandemic-induced changes, which will become part of the new normal's modus operandi?

**CHRISTINE LEONARD**  
SENIOR ASSOCIATE EDITOR

For many, the COVID-19 pandemic has been a wake-up call for practices to rethink their operations and efficiency. Doctors and staff alike have devised creative alternatives to meet the needs of the new normal. But what will ophthalmology practices look like in the near future? In this article, we'll take a closer look at some pandemic-induced changes that may be here to stay.

## Patients' Pull

James C. Tsai, MD, MBA, a glaucoma specialist and president of the New York Eye and Ear Infirmary of Mount Sinai, Icahn School of Medicine at Mount Sinai, says the pandemic has brought on a sort of paradigm shift in which patients have more influence on how things are done at doctors' offices.

"Practices have become more conscious of when waiting rooms are packed or busy," he says. "Patients prefer a socially distanced practice

and want more time with their doctor. Many are requesting to reduce the number of times they have to come into our office, which is in New York City. Before, patients would often combine a visit to a practitioner

“

**The pandemic has brought on a sort of paradigm shift in which patients have more influence on how things are done at doctors' offices.**

—James C. Tsai, MD, MBA

”

with lunch in the city or a Broadway show, but they're not doing that right now. Many who live outside the city want to see a local practitioner. Some have their diagnostic tests done at our satellite offices and then do telemedicine with a specialist. I think there may be a swing back to more community-based care.

"These patient desires have been challenging to incorporate," he continues. "Prior to the pandemic, most

offices were set up as very high-volume practices, and now there's this move to minimize the number of patient visits at the office and offer more telemedicine and remote monitoring. This seems to be the case for most medical specialties.

"Practices used to pack their clinic days, but we're recognizing that that's not what patients want," he says. "At least for the time being, they want to be socially distanced from other patients. This change in patient expectations is coming at an inopportune time, with the CMS reimbursement cuts. The natural response to reimbursements cuts in the past has been to ramp up patient volume, but we might not be able to rely on that as a solution post-COVID."

Nikola Ragusa, MD, a glaucoma and cataract surgeon at the Bronx Eye Center in New York, says he's been working longer hours and seeing fewer patients since his practice began scheduling longer appointment slots. "We'll probably have to maintain this type of schedule for a while," he says. "We book patients

This article has no commercial sponsorship.

Drs. Chang, Kolomeyer, and Tsai, and Ms. Esau, Cartwright, Jacobs and Mahlum report no relevant financial ties to anything discussed in this article. Dr. Ragusa is the co-founder of Pulse, a telemedicine app.

every 15 or 30 minutes, whereas before we were booking patients every 10 minutes or less, and sometimes did double-booking. We just can't do that anymore.

"Honestly, patients like it," he says. "They like coming in and being seen right away. I kind of like it too. It's a little less hectic. We're generating less revenue, but it makes for a nicer experience. I spend more time talking with patients and don't feel as if I need to rush to the next one. Because of the staffing shortage, I do some of the technical work myself as well, which leads to even more patient time. The patients have been appreciative. I can take a history while I'm taking their fundus photos or talk to them about other issues. By that time, I have a pretty thorough picture of what's going on with them. So, while I'm doing more work, there's also been a positive aspect to all this."

### Shorter Wait Times

"Our practice closed for a month when the case numbers were high in March 2020," says Saralee Esau, OSC, COA, clinical manager of Empire Eye and Laser Center in Bakersfield, California. "Our management team began using Zoom to communicate, and we made a reopening plan for our staff and patients."

This plan included fully implementing a lean-methodology-based scheduling system for all of their providers. Derived from Taiichi Ohno's Toyota Production System, lean manufacturing focuses on reducing times within a production system; in a health-care setting, this approach targets areas of inefficiency to improve aspects such as patient waiting times.

Ms. Esau says that implementing a lean scheduling system had been a goal of the company for a while, but the pandemic prompted them to transition sooner. "With this system, we take several factors into consideration when booking appointments, such as the time it takes for a patient to check in at the front desk, the time it takes



Empire Eye and Laser Center

**Daniel Chang, MD, says Empire Surgery Center in Bakersfield, California, now requires both staff and patients to wear masks in the OR.**

to get their chart ready, to screen and work them up for a particular exam, to dilate them, and then for the provider to come in and see the patient. Once we began accounting for all of these factors, our office flow became smoother, and we limited patient wait times. We're trying to have our templates reflect reasonable times that still push our staff to be as efficient as possible."

During the pandemic, Ms. Esau says this approach helped her practice comply with social distancing while still allowing the practice to see sufficient patient numbers to stay open. She says they'll continue using the lean system. "We knew it would change our patient volume, but building the time the support staff needs to spend with the patient into the schedule has enabled us to exceed our productivity while also creating a positive experience for our patients. Our reviews have never been better. We feel more prepared to adapt if something similar to the pandemic happens in the future; we'll still be able to maintain a decent flow of patients."

"We realized that wait times improve if we avoid putting a patient

back in the waiting room between testing and evaluation," says Natasha Kolomeyer, MD, a glaucoma specialist at Wills Eye Hospital and an assistant professor of ophthalmology at Sidney Kimmel Medical College at Thomas Jefferson University in Philadelphia. "This change involved empowering and training our technicians to care for patients from beginning to end, including testing and making appointments. Additionally, to minimize the amount of time required for patient workup, our technicians have also begun 'pre-charting.' This helps if there's a wait for an empty room. Online forms and the patient portal have also decreased the amount of administrative time."

Like many other practices, Virginia Eye Consultants, a member of Eye Care Partners, in Norfolk, Virginia, has limited the number of people accompanying a patient during the visit. "This helped to reduce the amount of time patients spend in the clinic," says practice administrator Teresa Cartwright, COT. "In the past, we allowed several companions, and they usually all had questions for the doctor, which would result in longer wait times and our clinic schedule becoming backed up. We make exceptions if patients need support when changing locations within the clinic and understanding the clinical decision or exam, especially those with mental or physical disabilities.

"We've also limited the number of pharmaceutical representatives coming into the clinic," Ms. Cartwright continues. "Sometimes we'd have four in one day. Now we're staggering their times and having them notify us when they'll be in the area, so we don't have all the doctors' schedules backed up throughout the day."

### Mobile Testing Devices

Drive-through clinics have largely gone by the wayside, but some of the portable devices used in those clinics, such as handheld tonometers and virtual reality visual field headsets, are still in use on occasion. "At

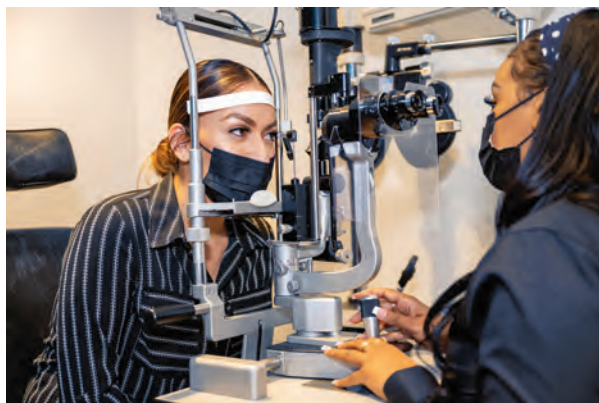

Wills Eye, we've started to use virtual reality perimetry for some patients, since it allows patients to take a visual field test while they remain in the exam room," Dr. Kolomeyer says. Wills Eye uses the VisuALL (Olleyes) and has been a site for the company's research projects. Protocols such as 10-2, 24-2, 24-2c and 30-2 are available with VisuALL's visual field perimeter. According to the company, testing time is about three minutes for threshold and 45 seconds for screening.

"We've found it useful in patients who are wheelchair-bound, have positioning issues when using the standard perimeter, have other reasons for poor reliability and in cases when the other perimeters are backed up," she notes. "Frequency of use varies among physicians, and some use it more than others. I find the printouts easy to read, but I'm concerned that the progression analysis will be deficient compared to standard perimetry at this time. Overall, I'm positively surprised by its utility amongst the spectrum of glaucoma patients."

### Safety Precautions

Dr. Tsai says there's been greater patient awareness of and demand for sanitation procedures since the pandemic's onset. "I think the patients like to see us incorporating routine intensive cleaning," he says. "They wonder if there are viral pathogens lurking in the exam room. I don't believe that patients thought of these issues as much in the past. Our practice is careful to demonstrate to our patients that we're using good sanitation and safety practices. We make sure providers wash their hands in front of patients, so they know we're serious about minimizing risk. We also use disposable tips on our Goldmann applanation tonometers whenever possible to reduce the risk of cross-infection."



Many practices say they'll continue using slit lamp shields and disposable tonometer tips. Pictured: Vanessa Watkin, surgery scheduling coordinator (left) and Saralee Esau, OSC, COA, clinical manager (right) of Empire Eye and Laser Center.

Empire Eye and Laser Center

"I think most people know not to come in if they aren't feeling well," Dr. Ragusa says. "The patients are extremely courteous and don't want to infect anyone, so we've actually been seeing a lot of patients pre-screening themselves and calling in if they're symptomatic in any way. We've been rescheduling them. During the winter months there's always more patients rescheduling."

In addition to intensive cleaning protocols and self-screening, many say that slit lamp shields are likely to remain. "Slit lamp shields are just generally a good idea," says Ms. Esau. "We're probably going to use them long-term."

Before the pandemic, Daniel Chang, MD, a cataract and refractive surgeon at Empire Eye and Laser Center and Empire Surgery Center, says only staff wore masks in the OR. Now, patients do too. "We've also decided to retain the use of patient and staff masking throughout the entire surgery center instead of just in the OR," he adds. "Not smelling patients' breath for the last two years has been an added bonus. The same goes for being at the slit lamp in clinic, when we're only about 12 inches away from patients' faces. The state and local mandates still require that we have patients and staff mask in the clinic, but we'll probably make that optional when regulations allow."

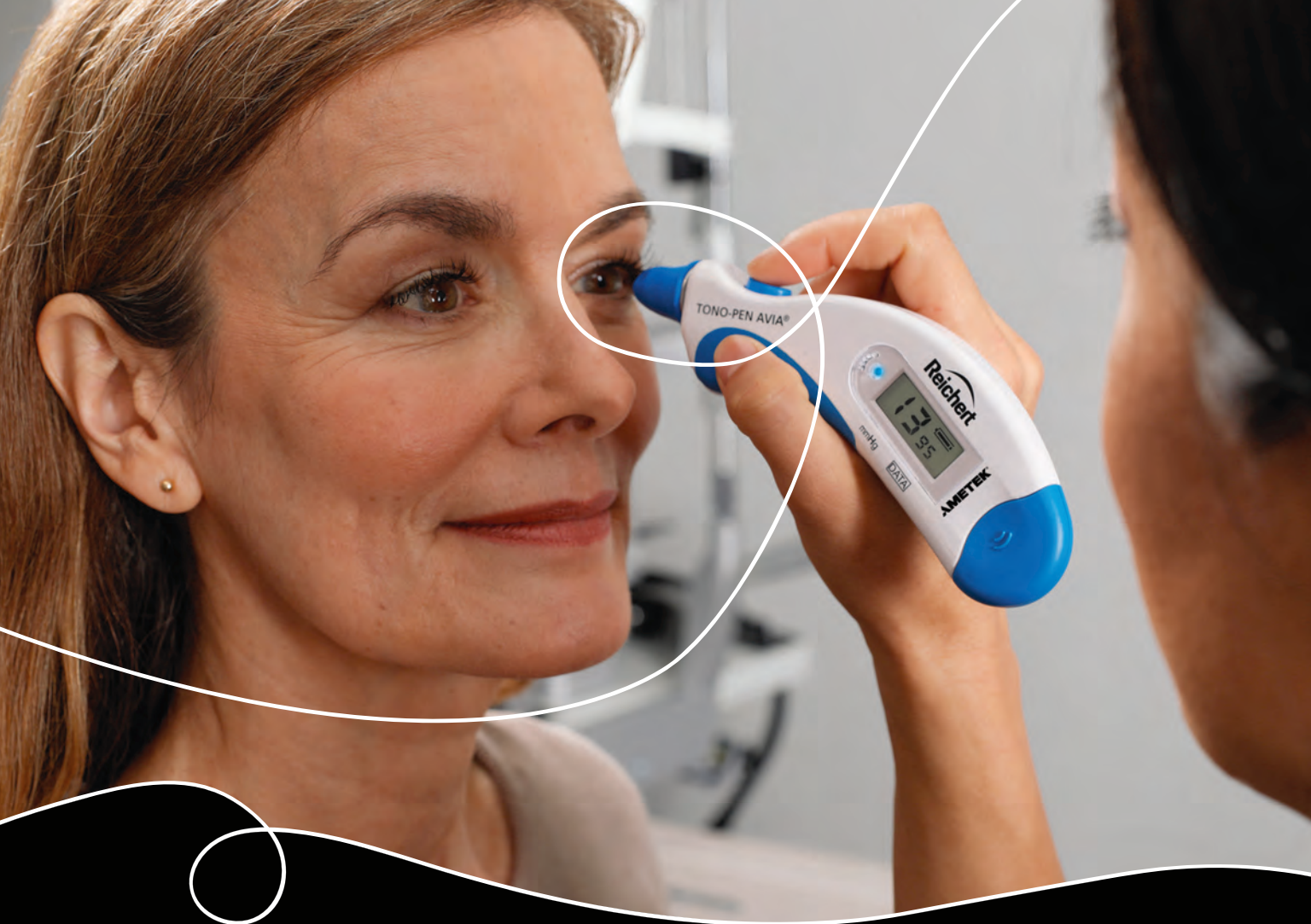Though a rare occurrence, if a patient needs to see the doctor urgently—e.g., if their pressure hasn't come down or they have a corneal ulcer—and they're symptomatic or COVID-19-positive, Ms. Cartwright says the doctors at her practice suit up in full PPE and see the patient outside, using portable slit lamps and tonometers. "This doesn't happen often, but we're prepared," she says. "Afterwards, we have a trash can in place for them to take off the PPE and dispose of it.

It's all taken to the dumpster. The doctors wash their hands, put on new masks, and both doctors and technicians change their lab coats before re-entering the clinic. Afterwards, the doctor will call the patient, finish the exam later and document in the chart."

To ensure patients wear masks properly when entering the facility, Virginia Eye Consultants maintains a greeter at its largest location and surgery center. "Our greeters are often retired individuals who are looking to work a few hours a week part time. Currently, our greeter is a retired Navy veteran who wanted to work a few hours each week to get out of the house," says Ms. Cartwright. "They direct patients to the proper subspecialty for their appointments, and they don't let patients enter if they refuse to wear a mask. This has helped us a lot. The greeters prevent patients from having arguments with the front desk staff. We supply a mask if needed. Now, the front desk staff don't have to take time away from their work and the other patients, and staff members don't have to hear arguments. The greeters also assist with accepting packages, so we can avoid admitting non-patients into the building. This limits potential exposure."

### Telemedicine

Telemedicine facilitated continu-



# MEASURE QUICKLY AND CONFIDENTLY WITH TONO-PEN®.

The most technician-trusted handheld tonometer just got better. The ready-to-use and calibration-free **Tono-Pen AVIA®**, now features **Quick-Tap®** Measurement Mode, giving you more confidence with fewer measurements. For proper performance of your Tono-Pen®, use genuine Reichert® engineered **Ocu-Film®+** Tip Covers.

ORDER NOW



WATCH HOW QUICK  
[REICHERT.COM/TONOPENAVIA](https://www.reichert.com/tonopenavia)

**Reichert**  
TECHNOLOGIES

*passionate about eye care*

**AMETEK®**



© 2022 AMETEK, Inc. & Reichert, Inc. (04-2022) · Tono-Pen, Tono-Pen AVIA, Quick-Tap, and Ocu-Film are registered trademarks of Reichert, Inc. · Tono-Pen is designed & assembled in USA.

ity of care for patients during the throes of the pandemic, but most agree it isn't quite ready to replace in-office visits. "We haven't found it as helpful in ophthalmology," says Dr. Tsai. "At-home monitoring technologies and vision-testing devices aren't ready for prime time yet, and there's too much room for error when patients test themselves in their own homes. We can't confidently confirm the reliability of those tests."

"We conducted some virtual visits by phone and video during the pandemic, but we haven't incorporated them into more routine care," notes Dr. Kolomeyer. "There's a possibility we may adopt a hybrid model in the future for patients who are stable and established."

As long as there's still demand, Ms. Esau says her practice will continue offering telemedicine to patients. "We relied heavily on telemedicine to provide care to patients and maintain our productivity during the pandemic," she says. "We continue to offer it, though demand has declined."

Nevertheless, proponents say there's untapped potential in telemedicine that may be advantageous in the new normal. Dr. Ragusa, who is the co-founder of a telemedicine platform for small- and mid-sized private practices called Pulse, says that though demand for telemedicine in general has fallen off in the eye-care space since the height of the pandemic, it hasn't gone away completely.

"I believe there's a role for telemedicine—real-time vision exams and provider-patient communication—that hasn't been used appropriately," he says. "Telemedicine has the ability to reduce patient waiting times, increase practice revenue and improve workflow, if the practice is willing to invest the time necessary to educate the patients, staff and providers. Education is really the key. Patients still inquire about it at my practice just from seeing the poster I have in the waiting room, and that



Olleyes

**Wills Eye's Natasha Kolomeyer, MD, says the VisuaALL virtual reality headset enables patients who have difficulty using a standard perimeter to take their exam in the waiting room.**

shows me there's an interest on the patient's end."

"Telehealth postop visits have helped our clinic flow considerably," says Ms. Cartwright. "Our physicians each perform about 30 cataract surgery procedures per day. Having the day-one postop visit by telehealth for straightforward cataract surgery patients has made a significant difference in clinic flow.

"We also hired a part-time retired optometrist who works about four to five hours each day calling patients. Patients are administered Diamox following surgery (if appropriate—no sulfa allergies or kidney problems) to aid in lowering intraocular pressure. As a precautionary measure, the surgeon orders brimonidine twice daily in the operative eye for the first week as an added layer of protection to ensure there are no pressure spikes."

### Remote Work

The pandemic catapulted many practices into adopting flexible working arrangements. Jessica Mahlum, who manages the Center for Ophthalmic Optics and Lasers (COOL) Lab at the Casey Eye Institute, Oregon Health & Science University, says the lab and university has adopted a flexible work-from-home policy that's allowed staff to social distance while continuing to stay productive. She says, "Many staff members agree that the policy provides a better work-life balance. Besides the initial bumps of the

unknown, it's been a great adaptation to a rapidly changing culture."

Some practices have shifted their administrative employees to full-time remote workers and have begun creating more remote positions. Ms. Esau says, "We didn't consider remote positions before the pandemic, but now we're actively pursuing them because we found that doing the administrative work remotely enables us to dedicate more time to patients while they're in our office." She says tasks such as medication refills, prior authorizations, triage and emergency calls, insurance verification for surgery and scheduling office visits are well-suited to remote work.

"Our former clinic manager is now in the process of creating positions across the country for people to essentially be their own call centers for our office from their own homes," she continues. "With people in multiple time zones, we can be efficient during more hours of the day. We also hope to add a remote quality-assurance position to review exam and chart notes; ensure accurate coding, documentation and billing; review medication and prescription histories; and ensure standard procedures are being followed. We hope this will create opportunities for people who've lost employment or those who can't work outside the home."

### Video Meetings

Administrative and management staff report that using Zoom and other online video communication services to conduct meetings has eased the burden of mutual scheduling. "Our management team used to meet in person for everything, and at times, it was challenging to gather everyone together in one place," says Ms. Esau. "We're a big team. Leaving support staff whom you're supervising, in order to attend a meeting offsite, was especially challenging. Zoom is useful for making quick decisions. We've also found that using it enables everyone to have access to meetings. It's made it easier



NOW AVAILABLE

**Verkazia®**  
cyclosporine ophthalmic  
emulsion 0.1%

# Year-round control for VKC<sup>1</sup>

The first and only topical cyclosporine FDA-approved to treat vernal keratoconjunctivitis (VKC) in children and adults<sup>1</sup>



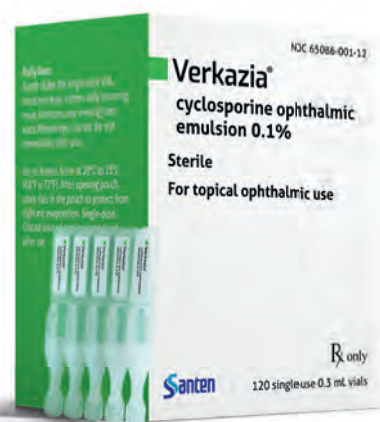**Reduction in itching and keratitis scores** as early as month 1<sup>1</sup>



**Additional reductions in photophobia, mucous discharge, and tearing** observed over 4 months in the pivotal multicenter trial<sup>2</sup>



**Established 12-month safety profile** with low rates of mild-to-moderate adverse events<sup>1,3</sup>



Harness the highest concentration of cyclosporine available in an eye drop.<sup>1,4</sup> Visit [verkazia.com](http://verkazia.com) to learn more

## INDICATIONS AND USAGE

Verkazia® (cyclosporine ophthalmic emulsion) 0.1% is a calcineurin inhibitor immunosuppressant indicated for the treatment of vernal keratoconjunctivitis in children and adults.

## IMPORTANT SAFETY INFORMATION

### WARNINGS AND PRECAUTIONS

#### Potential for eye injury and contamination:

To avoid the potential for eye injury and contamination, advise patient not to touch the vial tip to the eye or other surfaces.

## ADVERSE REACTIONS

The most common adverse reactions reported in greater than 5% of patients were eye pain (12%) and eye pruritus (8%), which were usually transitory and occurred during instillation.

You are encouraged to report adverse reactions of prescription drugs to Santen at **1-855-7-SANTEN** (1-855-772-6836). Or you may contact the U.S. Food and Drug Administration (FDA) directly. Visit [www.fda.gov/medwatch](http://www.fda.gov/medwatch) or call 1-800-FDA-1088.

Please see Brief Summary on adjacent page and Full Prescribing Information at [verkazia.com](http://verkazia.com).

**REFERENCES:** 1. Verkazia [package insert]. Emeryville, CA: Santen Inc.; 2021. 2. Leonardi A, Doan S, Amrane M, et al; for VEKTIS Study Group. A randomized, controlled trial of cyclosporine A cationic emulsion in pediatric vernal keratoconjunctivitis: the VEKTIS study. *Ophthalmology*. 2019;126(5):671-681. doi:10.1016/j.ophtha.2018.12.027 3. Bremond-Gignac D, Doan S, Amrane M, et al; for VEKTIS Study Group. Twelve-month results of cyclosporine A cationic emulsion in a randomized study in patients with pediatric vernal keratoconjunctivitis. *Am J Ophthalmol*. 2020;212:116-126. doi:10.1016/j.ajo.2019.11.020 4. US Department of Health and Human Services. *Orange Book: Approved Drug Products With Therapeutic Equivalence Evaluations*. 42nd ed. US Government Publishing Office; 2022. Accessed March 16, 2022. <https://www.fda.gov/media/71474/download>



# Verkazia®

## cyclosporine ophthalmic emulsion 0.1%

### BRIEF SUMMARY OF PRESCRIBING INFORMATION

#### INDICATIONS AND USAGE

Verkazia ophthalmic emulsion (0.1% (1mg/mL) cyclosporine) is indicated for the treatment of vernal keratoconjunctivitis (VKC) in children and adults.

#### GENERAL DOSING INFORMATION

Contact lenses should be removed before applying Verkazia and may be reinserted 15 minutes after administration.

If a dose is missed, treatment should be continued as normal, at the next scheduled administration.

If more than one topical ophthalmic product is being used, administer the eye drops at least 10 minutes apart to avoid diluting products. Administer Verkazia 10 minutes prior to using any eye ointment, gel or other viscous eye drops.

#### DOSAGE AND ADMINISTRATION

Instill one drop of Verkazia, 4 times daily (morning, noon, afternoon, and evening) into each affected eye.

Treatment can be discontinued after signs and symptoms are resolved and can be reinitiated if there is a recurrence.

#### CONTRAINDICATIONS

None.

#### WARNINGS AND PRECAUTIONS

##### Potential for Eye Injury and Contamination

To avoid the potential for eye injury or contamination, advise patients not to touch the vial tip to the eye or other surfaces.

#### ADVERSE EVENTS

**Table 1: Adverse Reactions Reported in ≥ 1% of Patients Receiving Verkazia**

	(N=135)
Eye Disorders	
Eye pain <sup>a</sup>	12%
Eye pruritus <sup>b</sup>	8%
Ocular discomfort <sup>c</sup>	6%
Visual acuity reduced	5%
Ocular hyperemia	4%
Systemic	
Cough	5%
Headache	4%
Upper respiratory tract infection	2%

a Including eye pain and instillation site pain  
b Including eye pruritus and instillation site pruritus  
c Including foreign body sensation and ocular discomfort

#### USE IN SPECIFIC POPULATIONS

##### Pregnancy

###### Risk Summary

There are no adequate and well-controlled studies of Verkazia administration in pregnant women to inform a drug-associated risk. Oral administration of cyclosporine to pregnant rats or rabbits did not produce teratogenicity at clinically relevant doses [see *Data*].

###### Data

###### Animal Data

Oral administration of cyclosporine oral solution (USP) to pregnant rats or rabbits was teratogenic at maternally toxic doses of 30 mg/kg/day in rats and 100 mg/kg/day in rabbits, as indicated by increased pre- and postnatal mortality, reduced fetal weight and

skeletal retardations. These doses (normalized to body weight) were approximately 320 and 2150 times higher than the daily maximum recommended human ophthalmic dose (MRHOD) of 0.015 mg/kg/day, respectively.

No adverse embryofetal effects were observed in rats or rabbits receiving cyclosporine during organogenesis at oral doses up to 17 mg/kg/day or 30 mg/kg/day, respectively (approximately 185 and 650 times higher than the MRHOD, respectively).

An oral dose of 45 mg/kg/day cyclosporine (approximately 485 times higher than MRHOD) administered to rats from Day 15 of pregnancy until Day 21 postpartum produced maternal toxicity and an increase in postnatal mortality in offspring. No adverse effects in mothers or offspring were observed at oral doses of up to 15 mg/kg/day (160 times greater than MRHOD).

##### Pediatric Use

Verkazia's safety and effectiveness has been established in patients from 4 through 18 years of age.

#### NONCLINICAL TOXICOLOGY

##### Carcinogenesis, Mutagenesis, Impairment of Fertility

###### Carcinogenesis

Systemic carcinogenicity studies were carried out in male and female mice and rats. In the 78-week oral (diet) mouse study, at doses of 1, 4, and 16 mg/kg/day, evidence of a statistically significant trend was found for lymphocytic lymphomas in females, and the incidence of hepatocellular carcinomas in mid-dose males significantly exceeded the control value. The low dose in mice is approximately 5 times greater than MRHOD.

In the 24-month oral (diet) rat study, conducted at 0.5, 2, and 8 mg/kg/day, pancreatic islet cell adenomas significantly exceeded the control rate in the low dose level. The hepatocellular carcinomas and pancreatic islet cell adenomas were not dose related. The low dose in rats is approximately 5 times greater than MRHOD.

###### Mutagenesis

In genetic toxicity tests, cyclosporine has not been found to be mutagenic/genotoxic in the Ames Test, the V79-HGPRT Test, the micronucleus test in mice and Chinese hamsters, the chromosome-aberration tests in Chinese hamster bone-marrow, the mouse dominant lethal assay, and the DNA-repair test in sperm from treated mice. Cyclosporine was positive in an in vitro sister chromatid exchange (SCE) assay using human lymphocytes.

###### Impairment of Fertility

Oral administration of cyclosporine to rats for 12 weeks (male) and 2 weeks (female) prior to mating produced no adverse effects on fertility at doses up to 15 mg/kg/day (160 times higher than MRHOD).

#### CLINICAL STUDIES

The safety and efficacy of Verkazia for the treatment of VKC was evaluated in two randomized, multi-center, double-masked, vehicle-controlled, clinical trials (VEKTIS Study; NCT01751126 and NOVATIVE Study; NCT00328653).

A total of 168 and 118 patients were enrolled in the VEKTIS and NOVATIVE studies for the efficacy analyses, respectively. Patients' age ranged from 4 through 17 years (mean age 9 years) in VEKTIS and 4 through 21 years (mean age 9 years) in NOVATIVE, with most patients being between 4 and 11 years of age (76% in VEKTIS and 80% in NOVATIVE) and male (79% in VEKTIS and 81% in NOVATIVE). Most of the patients had both limbal and tarsal forms of VKC (65% in VEKTIS and 74% in NOVATIVE). In both studies, patients had experienced VKC for a mean of 3 years prior to enrollment and all patients had a history of at least one recurrence of VKC in the year prior to study entry.

#### STORAGE AND HANDLING

Do not freeze Verkazia. Store at 20°C to 25°C (68°F to 77°F). After opening the aluminum pouch, the single-dose vial should be kept in the pouch to protect from light and avoid evaporation. Any opened individual single-dose vial with any remaining emulsion should be discarded immediately after use.

for individuals to contribute, and we can record meetings for those who can't make it. Sometimes people Zoom in from vacation because they don't want to miss things, so it's nice to have that option. We do balance video meetings with in-person meetings though. Some conversations are just better in person."

Zoom has also found its way into the hiring process. "We're now offering first-round interviews by Zoom," Ms. Esau says. "This helps the management team use their time more efficiently as well as conduct more interviews than before. It's convenient for out-of-town applicants."

### In Search of Staff

Ophthalmic staff have been hard to come by for a long time, but the pandemic brought about unprecedented scarcity. "Many technicians have moved or changed jobs during the pandemic, and some have retired," says Dr. Tsai. "It's certainly made it difficult to increase patient volume coming back from the pandemic due to increased staff turnover."

He says his practice has been reaching out to more potential job candidates. "We've also been asking our technicians if they know of any friends or colleagues who'd be interested in working for us. We've proactively raised salaries. We value our technical staff, and the last thing we want is for them to feel underappreciated and to start looking elsewhere."

"I've been looking to hire someone at a very competitive wage, but there just don't seem to be many people around," Dr. Ragusa says. "Some people come in and say they're interested, and then you never hear from them again—even those without ophthalmic technician training. It's just hard to find anybody."

Because the United States has only 30 accredited technician training programs scattered throughout 16 states and the cost of education can



Empire Eye and Laser Center

**Practices say that patients are more conscious of social distancing and prefer less crowded waiting areas now. Pictured: Angie Ramirez, patient service representative, at Empire Eye and Laser Center.**

be prohibitive for a high school or community college graduate, some practices and doctors have created their own programs to help meet the demand for trained staff. Palm Beach State College's program, founded by Robert M. Kershner, MD, MS, FACS, offers an Associate in Science degree in Ophthalmic Medical Technology. The program accepts about 15 students per year and includes two clinical rotations at a variety of externship sites. Dr. Kershner says most program graduates find employment at Bascom Palmer Eye Institute in Miami.

Dr. Kolomeyer says Wills Eye's new technician training program has been successful. The program consists of 10 evening sessions over the course of five weeks. It's fairly affordable at \$500, which includes training materials. (For comparison, some ophthalmic medical technician training programs at universities cost around \$11,000, plus applicable fees, books and supplies.) In the Wills Eye program, students learn how to perform clinical duties, preliminary eye exams and diagnostic procedures to assist the ophthalmologists. All graduates are guaranteed an interview at Wills Eye and receive a bonus after one year if

hired. "We try our best to ensure our employees feel appreciated, and we allow them to step into leadership roles as they arise," she says.

Empire Eye and Laser uses a collaborative style of in-house staff training that helped to withstand pandemic absences. New hires are trained by their department manager and by more senior employees from the same department. Ms. Esau says that cross-training and shadowing in multiple departments across the company enables new hires to gain a well-rounded view of Empire's mission and processes. "It worked well for us during the pandemic too," she notes. "Training can be easily affected with just a few absent employees, but with our collaborative approach it's not just one person providing training. Thankfully, we have a very solid and happy employee base, so we haven't had many of the pandemic-related staffing woes that others have had."

Virginia Eye Consultants recently set up an intensive, regimented staff training program. "We hired a Certified Ophthalmic Technician to train staff in all areas, from the front desk to testing technicians and work-up technicians, to onboarding staff in



the surgery center,” Ms. Cartwright says.

“If a staff member becomes certified as a COA or COT, they receive a dollar increase in pay as an added incentive,” she continues. “Across the board, and over the past two years, we’ve had multiple pay reviews. We’ll give staff a pay increase later this month. Other incentives include a bonus structure for nurses in the surgery center. We try to maintain and keep our pay level competitive and consistent with other ophthalmic practices across the country to ensure we’re retaining good, well-trained staff without losing them to other facilities. We also have early sign-on bonuses for optometrists and ophthalmologists who commit to staying with us for two years. Hopefully we’ll get back to where we were before the pandemic.”

One unique training alternative is the web-based, digital-learning platform called Alchemy Vision, which was founded in 2021 to specifically address the staffing and training challenges faced by ophthalmology practices across the country now. Founder and CEO Flora Azucena says that Alchemy Vision provides structured learning using up-to-date materials tailored to the individual’s level of experience and knowledge.

Alchemy Vision’s Entry curriculum is usually incorporated into a new hire’s onboarding process, but it’s suitable for any staff member. “Education is at the heart of what we do,” she says. “Staff receive college-level education from world-class faculty, including Mitchell C. Shultz, MD, I. Paul Singh, MD, Nicole Fram, MD, Eduardo Besser, MD, and Felicia Lew, OD. In about eight to 12 weeks, staff will have learned enough about ophthalmology to be efficient and effective.

“Many practices train new hires in-house with good outcomes, but no two technicians train the same way, and a good technician isn’t necessarily a great instructor,” she

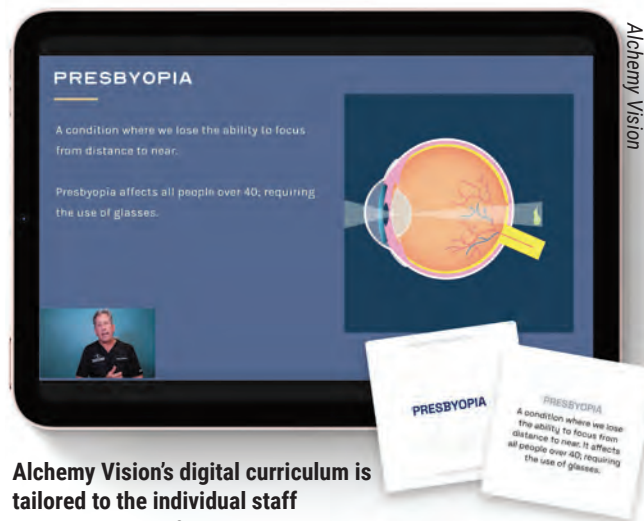
notes. “They may also find themselves overwhelmed with the addition of training on top of high patient volume.”

“Frankly, staffing and retaining staff is a challenge right now, and this platform has really been a savior for us,” says Carrie Jacobs, COE, CPSS, executive vice president of operations at Chu Vision Institute.

(Her practice has no financial interest in Alchemy Vision.) She says that the program has been a great teaching tool for any staff member new to ophthalmology, from front desk staff to nurses. “The quality is excellent and engaging. There are live weekly deep-dive presentations that take topics to the next level. It’s also accountable. The learning is self-paced, but we as leaders are able to set expectations and benchmarks that are necessary for achieving the goal.”

Ms. Azucena describes Alchemy Vision’s subscription model as, “A Hulu subscription for training your entire technician staff.” Training five employees costs \$249 per month; the cost for 10 employees is \$349. She says customized packages are available for practices with more than 10 technicians. “We train technicians working in small private practice locations with fewer than five technicians and higher-volume practices with dozens of locations such as Mercy Eye,” Ms. Azucena says. “We also recently launched a pilot program with Kaiser Permanente in Los Angeles.”

Alchemy Vision’s Elevate, a new patient-centered solutions model launching in beta-mode this month, trains advanced communication skills to patient counselors, surgery coordinators and more experienced



Alchemy Vision’s digital curriculum is tailored to the individual staff member’s level of experience and knowledge.

technicians. “We’re living at a time of volume-oriented medicine, where economic and management pressures force doctors to see more patients per unit of time,” Ms. Azucena says. “We’re teaching skills necessary to be specialized members of the eye-care team, from patient cycle time and building rapport to giving directions for specific products. Many patients need more clarification about their medications than the doctor has time to give. We’re partnering with manufactures to ensure staff receive instruction on the most up-to-date FDA labeling.” (To inquire about becoming a beta-testing site, visit [alchemyvision.com/beta](http://alchemyvision.com/beta).)

The pandemic and resulting outside-the-box thinking have led to some rapid changes in practice operations and care delivery. The patient-care landscape is different now. Dr. Tsai says, “We have to be cognizant of advances in remote monitoring and telemedicine, and we have to continue to innovate.”

“I’m grateful that we were able to navigate through the pandemic the way we have,” says Ms. Esau. “Hopefully it doesn’t take another pandemic for new ideas to come.”

1. International Council of Accreditation for Allied Ophthalmic Education Programs. Find A Program. [http://www.icaccreditation.org/find\\_a\\_program/find\\_a\\_program.html](http://www.icaccreditation.org/find_a_program/find_a_program.html). Accessed March 25, 2022.

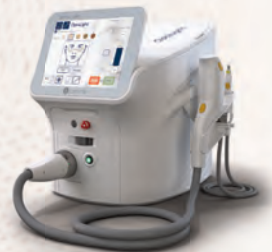Doctors,  
grow your  
practice with  
OptiLight  
for dry eyes.

Mandy Moore

## OptiLight | A Bright Solution for Dry Eyes

Introducing OptiLight by Lumenis, the first and only light therapy for dry eye disease management. OptiLight with patented OPT™ technology is a quick, in-office treatment that can elevate and scale your practice while significantly improving your patient's signs of dry eyes.

**Visit our website to learn more.**



[information.lumenis.com/optilight](https://information.lumenis.com/optilight)

Copyright © 2021-2022 Lumenis Be Ltd. All Rights Reserved  
PB-00043050 Rev A

Visit our website  
to learn more





# GENE THERAPY FOR INHERITED RETINAL DISEASE

A look at the results ophthalmic researchers and companies are generating as they explore genetic therapies for these difficult-to-treat conditions.



**ANKUR SUDHIR GUPTA, MD, MS**  
DANVILLE, PA.  
**GLENN C. YIU, MD, PHD**  
SACRAMENTO

Inherited retinal diseases (IRDs) are typically caused by single-gene mutations and are historically classified by clinical features, imaging and electroretinography. The advent of low-cost genetic testing now enables more precise and granular classification of IRDs, which can also guide prognosis and management if the causative mutation is identified.<sup>1</sup> More than 300 such diseases have been identified, and cumulatively they affect approximately 200,000 people in the United States and 4.5 million people worldwide.<sup>2,3</sup> On the treatment side, the field of gene therapy has advanced significantly in recent years, with many clinical trials in various stages under way, including 47 that are currently recruiting, 25 beginning soon and 72 that have been completed.<sup>4</sup>

Here, we survey recent progress in gene therapies for several classes

of IRDs, including photoreceptor disorders such as retinitis pigmentosa and Leber congenital amaurosis, macular dystrophies including Stargardt disease and X-linked retinoschisis, as well as choroidal dystrophies such as choroideremia.

## An Overview of Gene Therapy

The term gene therapy commonly refers to gene replacement, where a normal, functional copy of a gene is introduced by way of a delivery vector to replace a mutated gene in a targeted population of cells. This approach is commonly used for recessive IRDs where neither of the two mutated alleles can produce functional gene products. In contrast, dominant IRDs may require therapies that inactivate the mutant protein or gene at the DNA level using gene-editing technologies like CRISPR.

The challenges of developing gene therapies vary with different IRDs, based on differences in the therapeutic transgene, the intended target cell type and clinical course, among many other factors. Viral

vectors such as adenovirus, adeno-associated virus (AAV) and lentivirus differ in their gene-carrying capacity, cellular tropism, immunogenicity and mutagenicity. Different routes of administration, including intravitreal, subretinal and suprachoroidal, provide different biodistribution and may differentially trigger host immune responses to viral particles in different compartments surrounding ocular barriers (See Figure 1).<sup>5</sup> Finally, the clinical course may dictate the window of opportunity for which gene therapy can be effective, before photoreceptor atrophy leads to irreversible blindness.

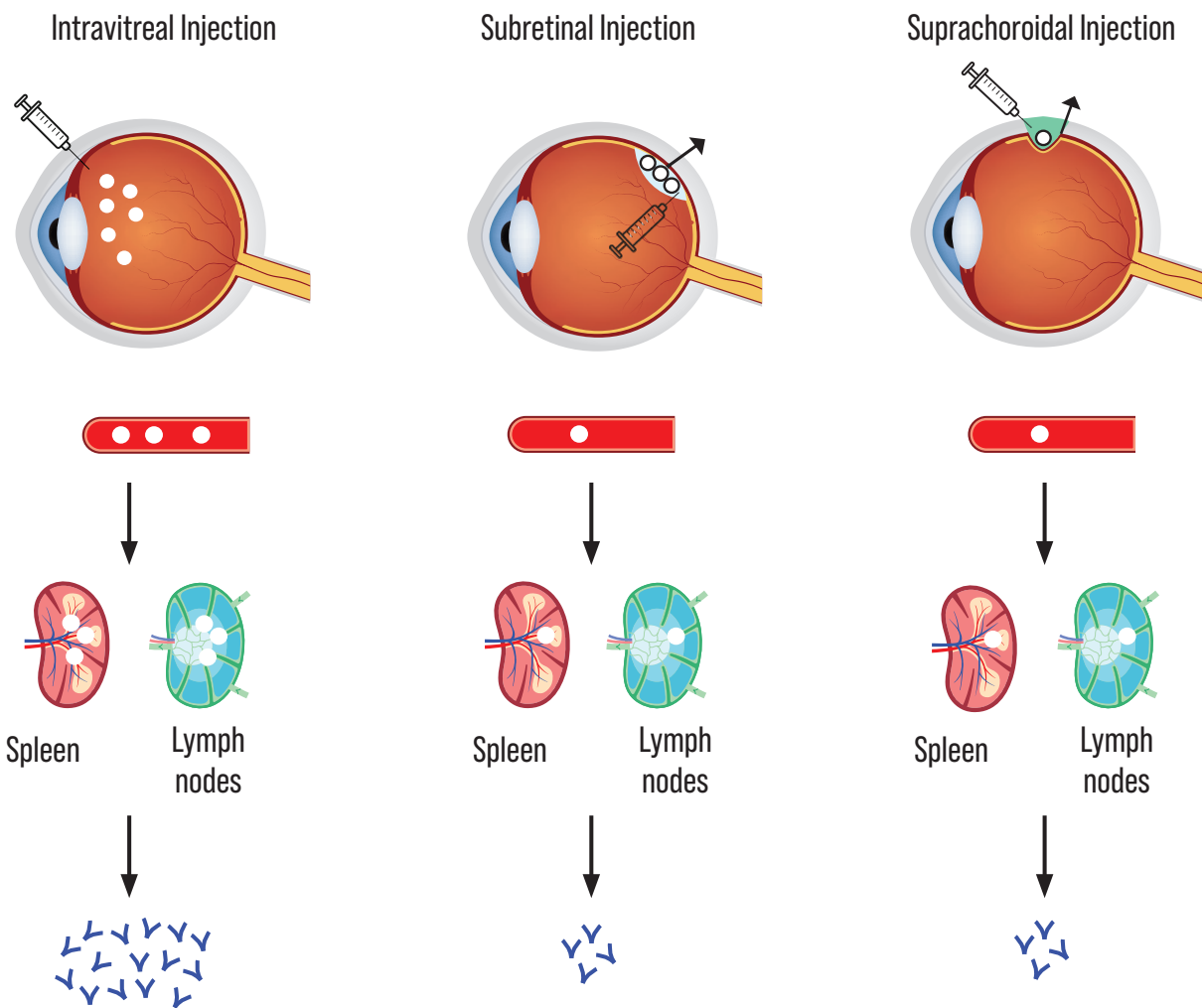
## Leber Congenital Amaurosis

The first major success for retinal gene therapy was in the treatment of Type 2 LCA, an autosomal recessive IRD that occurs in one in 80,000 births, and is associated with mutations in the GUCY2D, CEP290 and RPE65 genes.<sup>7</sup> RPE65 is involved in the production of 11-cis-retinal during phototransduction, and accounts for 5 to 10 percent of LCA cases. Voretigene neparvovec-

This article has no commercial sponsorship.

Dr. Yiu is an associate professor at the University of California, Davis. He receives research support from Clearside, Iridex and Genentech. He consults for Abbvie, Adverum, Alimera, Anlong, Bausch & Lomb, Clearside, Endogena, Genentech, Gyroscope, Intergalactic, Iridex, NGM Bio, Regeneron, Thea, Topcon and Zeiss. Dr. Gupta is a PGY3 Ophthalmology Resident at Geisinger Health System. He has no disclosures.





	Intravitreal	Subretinal	Suprachoroidal
Retinal transgene expression	Variable	High	Variable
Scleral transgene expression	Low	Low	High
AAV egress to circulation	High	Low	Low
Cellular immune response to transgene	Low	Low	High?*
Humoral Nab response to AAV	High	Low	Low

\*for foreign transgene, unknown for native transgenes

**Figure 1. Routes of viral vector delivery. Effects of different routes of viral vector delivery on transgene expression, egress to circulation and immune response. AAV indicates "adeno-associated virus"; Nab, "neutralizing antibodies."**<sup>6</sup>

ryl (Luxturna, Spark Therapeutics, Philadelphia) is an AAV2 that delivers RPE65 via subretinal injection which demonstrated safety and benefit in Phase III studies and was approved by the FDA in 2017 for patients with biallelic RPE65-mediated IRDs.<sup>8,9</sup>

Given the challenge of measuring improvements in functional vision in IRD patients, where visual acuity

alone cannot suffice, a novel ambulatory navigation maze was devised as an end point in addition to light sensitivity and visual fields. Recent studies suggest that long-term functional improvements persist to at least three to four years after gene augmentation with VN; of note, no deleterious immune responses were observed.<sup>8</sup> However, 18 eyes of 10 patients who underwent subretinal

VN were recently noted to develop perifoveal chorioretinal atrophy, identified around five months after treatment and persisting for at least a year during early follow-up.<sup>10</sup> This unexpected outcome resulted in some patients experiencing a scotoma, but very few had significant changes in visual acuity or other functional measures.

Another follow-up study followed

77 eyes of 41 patients and found that central foveal thickness decreased slightly in both children and adults, as the fovea was detached by VN in 62 eyes (81 percent). There was no statistically significant vision change for the adults, whereas there was a trend of improvement for children that reached statistical significance at some time points. At the last follow-up, 29 percent of the pediatric eyes improved by at least two lines.<sup>11</sup>

In 2022, a study of 27 eyes of 14 patients examined postoperative complications and longitudinal changes in photoreceptor function. The most common postoperative issues included elevation in intraocular pressure (59 percent), persistent intraocular inflammation (15 percent), and vitreous opacities (26 percent) that resolved over months, providing longitudinal real-world evidence of VN safety and efficacy consistent with the original clinical trial results.<sup>12</sup>

Type 10 LCA is caused by mutations in the CEP290 gene that result in a splicing error in the mRNA transcript of a protein which forms the primary cilium and plays an important role in photoreceptors. In October 2019, an antisense oligonucleotide designed to correct the splicing error was investigated in a Phase I/II clinical trial of 10 subjects in whom vision improved by several lines at three months, and the improvements in visual acuity were retained after six months with a second dose.<sup>13</sup>

Separately, in March 2020, the first in-human ophthalmic application of *in vivo* gene editing using a CRISPR-Cas system commenced to evaluate AGN-151587 (EDIT-101, Allergan; NCT03872479) delivered via subretinal injection in 18 patients. Early results have demonstrated both safety and efficacy in the first cohort, and the trial is on target to be completed in 2024.<sup>14</sup>

## Choroideremia

Choroideremia (CHM) is an X-linked recessive IRD that occurs in

one in 50,000 males, and presents with night blindness and gradual vision loss beginning in childhood. The CHM gene encodes the Rab escort protein 1 (REP1) essential for intracellular vesicular transport, and loss of function results in cell death and the gradual deterioration of the retinal pigment epithelium, photoreceptors and the choroid.<sup>15</sup>



Several novel pharmacologic therapies are currently being developed to decrease A2E formation in the visual cycle.



In Phase I/II trials, subretinal AAV2-REP1 improved visual acuity in some patients, although there were a few cases of adverse events. Among six patients, there were two cases of retinal hole over non-functional retina<sup>16</sup> and one case of localized intraretinal immune response.<sup>17</sup> Sequential bilateral treatment using AAV2-REP1 was tested in the GEMINI open-label Phase II trial (NCT03507686) from Biogen (Cambridge, Massachusetts), and it appeared safe. However, the pivotal Phase III STAR trial which randomized one eye per subject to low dose, high dose or control groups (NCT03496012) didn't meet the primary endpoint of proportion of participants with a  $\geq 15$  ETDRS letter improvement from baseline at month 12, although the safety results were consistent with previous studies. Recently, Spark Therapeutics initiated a Phase I/II study of unilateral subretinal administration of the AAV2-hCHM vector in choroideremia subjects with BCVA  $>20/200$  in the study eye (NCT02341807). More recently, using adaptive optics, one group showed that the cone photoreceptor

mosaic resettled on the RPE following resolution of the subretinal bleb at one month post-injection, remaining intact in eight of nine study participants without widespread cone loss across the retained area of central retina targeted by the retinal detachment, which suggests that cone photoreceptors don't drop out as a consequence of mechanical or acute inflammatory changes in response to subretinal AAV2-hCHM.<sup>18</sup>

## Stargardt Disease

As the most common macular dystrophy worldwide, with a prevalence of one in 10,000 people, Stargardt disease is an autosomal recessive disease that results from loss-of-function mutations in the ABCA4 gene-encoding ATP-binding cassette A4 transporter. This protein clears toxic lipofuscin-component A2E from photoreceptors; its absence leads to progressive retinal degeneration with characteristic light-yellow pisciform flecks that's accompanied by a sharp initial decline in central vision followed by a slow progressive decline. Visual acuity typically remains relatively preserved for several decades, rarely declining beyond 20/400. Nonsense mutations cause early onset disease in childhood with more severe atrophy, whereas missense variants are usually adult-onset, often sparing the fovea.<sup>19</sup>

Several novel pharmacologic therapies are currently being developed to decrease A2E formation in the visual cycle.<sup>19</sup> With its high prevalence and broad phenotypic spectrum, ABCA4 is also an attractive target for gene therapy. Given the size of the ABCA4 gene (6.8kb), lentiviral or nanoparticle vectors are needed to deliver the payload. A Phase I/II clinical trial (NCT01367444) investigating subretinal lentiviral delivery of ABCA4 using SAR422459 from Oxford Biomedica demonstrated positive early safety data, but was terminated prematurely due to loss of sponsorship. A long-term follow-

# VisuALL ETS

eye tracking system



**The future of eye care is comprehensive and simple, with less strain on the practice and the patients.**

All diagnostic eye measurements are only a few clicks away.

**That future is now.**

VISUAL FIELD  
+  
COLOR VISION  
+  
VISUAL ACUITY  
+  
PUPILOMETRY  
+  
EXTRAOCULAR MOTILITY



350 Springfield Ave, Suite 200 Summit, NJ 07901  
sales@olleyes.com / 1-855-OLLEYES (1-855-655-3937)

[www.olleyes.com](http://www.olleyes.com)



up study of patients who received this treatment (NCT01736592) is currently ongoing.<sup>20</sup>

### X-Linked Retinitis Pigmentosa

Retinitis pigmentosa is characterized by progressive vision loss due to abnormalities of photoreceptor cells or retinal pigment epithelial cells, with a prevalence of 1 in 4,000. While three genes—RHO, USH2A, and RPGR—account for about 30 percent of all RP cases, a total of 87 individual disease-causing genes have been identified to date. Although RP can be inherited in all three major Mendelian patterns, X-linked RP generally has an earlier onset and worse prognosis.

Due to the large number of causative genes and phenotypic variance in RP, clinical findings, onset and progression may differ considerably. Typically, the disease begins with damage and loss of rod cells, leading to nyctalopia, defective dark adaptation and peripheral visual field loss, which is then followed by eventual secondary loss of cones, causing central visual loss.<sup>21</sup>

For X-linked RP caused by mutations in RPGR, a recombinant AAV2/5 vector MGT009 (Mereira/Janssen) has been designed to subretinally deliver functional copies of the gene in males with XLRP. In a Phase I/II dose escalation trial, four patients in the intermediate-dose cohort achieved clinically-meaningful improvements in visual field progression at 12 months, while those in the low- and intermediate-dose cohorts (n=6) also achieved significant improvements in their vision-guided mobility maze evaluation. There were no reports of dose-limiting events, although signs of inflammation were observed in two of three patients in the high-dose cohort, who were successfully managed with steroids.<sup>22</sup> Plans to proceed with a Phase III trial are under way (NCT04671433).

Similarly, AGTC-501 (AGTC) is a recombinant AAV2 administered

by subretinal injection for RPGR-related XLRP patients. Preliminary results showed that the therapy was well-tolerated across a wide dose range with minimal adverse effects. At 12 months, four out of eight patients were considered responders, and a planned Phase II/III will randomize 63 participants to compare two doses in the future.

### X-Linked Retinoschisis

XLRS has a prevalence of 1 in 5,000 to 20,000, and is associated with mutations of the RS1 gene that encodes the membrane protein retinoschisin, involved in retinal cell layer organization and cell adhesion, as well as ion-channel mediated fluid balance.<sup>23</sup> Male patients typically present within the first two decades of life with predominantly central vision loss. The macular schisis creates the appearance of radial folds emanating from the fovea, and may eventually extend to the peripheral retina. Visual acuity is decreased in XLRS, but may remain relatively stable for long periods of time. There's no current treatment for XLRS, and management is focused on preserving vision and addressing complications such as recurrent retinal detachment and vitreous hemorrhage.

Intravitreal injections are the preferred approach for gene therapy delivery, since the retina is predisposed to retinal detachment with subretinal injections leading to decreased structural integrity. AAV-encoding RS1 has been proven safe and effective in preclinical trials using RS1-knockout mice and macaques.<sup>24, 25</sup> Two ongoing Phase I/II clinical trials are investigating the safety of intravitreal AAV8 (NCT02317887) and AAV2 (NCT02416622). Early data suggest that eyes treated with intravitreal AAV8 exhibit concerning signs of inflammation, possibly due to a baseline proinflammatory state in XLRS.<sup>26</sup> Advances in distinguishing the phenotypic variability of

this disease may help improve trial design and timing of interventions. For example, measuring the integrity or length of photoreceptor outer segments on SD-OCT may help identify the optimal candidates for treatment.<sup>27</sup>

In conclusion, gene therapy can be a promising approach to treating IRDs, but challenges remain in vector design, mode of delivery and host immunity. New generations of AAV enable better penetration into the retina and potentially lower immunogenicity. Suprachoroidal injections using microneedles enable in-office delivery of gene therapies without the need for invasive vitreo-retinal surgery. However, different modes of AAV delivery may elicit differential host immune responses that can trigger intraocular inflammation, causing permanent damage if not properly managed.

While much of the research to date has focused on gene augmentation, other emerging genetic therapies include RNA interference (RNAi) using siRNA or antisense oligonucleotide therapy, CRISPR/Cas9-based gene editing and base editing, and translational readthrough-inducing drugs. With large numbers of clinical trials under way, more advances in gene therapy technology are needed to guide a safe, steady path forward in this exciting new area of therapy. ◀

1. Pulido JS, Procopio R, Davila HJ, Bello N, Ku C, Pennesi ME, Yang P, Nagiel A, Mahroo OA, Aleman TS et al. Inherited retinal disease panels—caveat emptor—truly know your inherited retinal disease panel. *Retina* 2022;42:1:1-3.
2. Benati D, Patrizi C, Recchia A: Gene editing prospects for treating inherited retinal diseases. *J Med Genet* 2020;57:7:437-444.
3. RetNet. <https://sph.uth.edu/retnet/disease.htm>. Accessed March 28, 2022.
4. ClinicalTrials.gov. <https://clinicaltrials.gov/ct2/results?term=inherited+Retinal&Search=Clear&age%20y=&gndr=&rsjt=>. Accessed March 28, 2022.
5. Yiu G, Chung SH, Mollhoff IN, Nguyen UT, Thomasy SM, Yoo J, Taraborelli D, Noronha G. Suprachoroidal and subretinal injections of AAV using transscleral microneedles for retinal gene delivery in nonhuman primates. *Mol Ther Methods Clin Dev* 2020;16:179-191.
6. Mehta N, Robbins DA, Yiu G. Ocular inflammation and treatment emergent adverse events in retinal gene therapy. *Int Ophthalmol Clin* 2021;61:3:151-177.
7. Tsang SH, Sharma T. Leber congenital amaurosis. *Adv*

Exp Med Biol 2018;1085:131-137.

8. Maguire AM, Russell S, Chung DC, Yu ZF, Tillman A, Drack AV, Simonelli F, Leroy BP, Reape KZ, High KA et al. Durability of voretigene neparvovec for biallelic RPE65-mediated inherited retinal disease: Phase 3 results at 3 and 4 years. *Ophthalmology* 2021;128:10:1460-1468.

9. Maguire AM, Russell S, Wellman JA, Chung DC, Yu ZF, Tillman A, Wittes J, Pappas J, Elci O, Marshall KA et al. Efficacy, safety, and durability of voretigene neparvovec-rzyl in RPE65 mutation-associated inherited retinal dystrophy: Results of Phase 1 and 3 trials. *Ophthalmology* 2019;126:9:1273-1285.

10. Gange WS, Sisk RA, Besirli CG, Lee TC, Havunjian M, Schwartz H, Borchert M, Sengillo JD, Mendoza C, Berrocal AM et al. Perifoveal chorioretinal atrophy after subretinal voretigene neparvovec-rzyl for RPE65-mediated Leber congenital amaurosis. *Ophthalmol Retina* 2022;6:1:58-64.

11. Sengillo JD, Gregori NZ, Sisk RA, Weng CY, Berrocal AM, Davis JL, Mendoza-Santiesteban CE, Zheng DD, Feuer WJ, Lam BL. Visual acuity, retinal morphology, and patients' perceptions after voretigene neparvovec-rzyl for RPE65-associated retinal disease. *Ophthalmol Retina* 2022;6:4:273-283.

12. Deng C, Zhao PY, Branham K, Schlegel D, Fahim AT, Jayasundera TK, Khan N, Besirli CG. Real-world outcomes of voretigene neparvovec treatment in pediatric patients with RPE65-associated Leber congenital amaurosis. *Graefes Arch Clin Exp Ophthalmol*. Jan 10, 2022 (online article).

doi: 10.1007/s00417-021-05508-2. (Online ahead of print)

13. Cideciyan AV, Jacobson SG, Drack AV, Ho AC, Charnig J, Garafalo AV, Roman AJ, Sumaroka A, Han IC, Hochstedler MD et al. Effect of an intravitreal antisense oligonucleotide on vision in Leber congenital amaurosis due to a photoreceptor cilium defect. *Nat Med* 2019;25:2:225-228.

14. Philippidis A. Editas early data for CRISPR therapy EDIT-101 shows efficacy "signals" in two patients. <https://www.genengnews.com/news/editas-early-data-for-crispr-therapy-edit-101-shows-efficacy-signals-in-two-patients/>. Online article. Accessed April 11, 2022.

15. Lam BL, Davis JL, Gregori NZ. Choroideremia gene therapy. *Int Ophthalmol Clin* 2021;61:4:185-193.

16. Lam BL, Davis JL, Gregori NZ, MacLaren RE, Girach A, Verriotto JD, Rodriguez B, Rosa PR, Zhang X, Feuer WJ. Choroideremia gene therapy Phase 2 clinical trial: 24-Month results. *Am J Ophthalmol* 2019;197:65-73.

17. Dimopoulos IS, Hoang SC, Radziwon A, Binczyk NM, Seabra MC, MacLaren RE, Somani R, Tennant MTS, MacDonald IM. Two-year results after AAV2-mediated gene therapy for choroideremia: The Alberta experience. *Am J Ophthalmol* 2018;193:130-142.

18. Morgan JIW, Jiang YY, Vergilio GK, Serrano LW, Pearson DJ, Bennett J, Maguire AM, Aleman TS. Short-term assessment of subfoveal injection of adeno-associated virus-mediated hCHM gene augmentation in choroideremia using adaptive optics ophthalmoscopy. *JAMA Ophthalmol* 2022. Mar 10:e220158.

doi: 10.1001/jamaophthalmol.2022.0158. (Online ahead of print)

19. Lu LJ, Liu J, Adelman RA. Novel therapeutics for Stargardt disease. *Graefes Arch Clin Exp Ophthalmol* 2017;255:6:1057-1062.

20. Parker MA, Erker LR, Audo I, Choi D, Mohand-Said S, Sestakauskas K, Benoit P, Appelqvist T, Krahmer M, Segaut-Prevost C et al. Three-year safety results of SAR422459 (EIAV-ABCA4) gene therapy in patients with ABCA4-associated Stargardt disease: An open-label dose-escalation phase I/IIa clinical trial, cohorts 1-5. *Am J Ophthalmol* 2022. Mar 3;S0002-9394(22)00069-1. doi: 10.1016/j.ajo.2022.02.013. (Online ahead of print)

21. Verbakel SK, van Huet RAC, Boon CJF, den Hollander AI, Collin RWJ, Klaver CCW, Hoyng CB, Roepman R, Klevering BJ. Non-syndromic retinitis pigmentosa. *Prog Retin Eye Res* 2018;66:157-186.

22. Johnson & Johnson Corporate communication. Interim six-month data of RPGR gene therapy shows significant vision improvement in patients living with X-Linked Retinitis Pigmentosa. <https://www.jnj.com/interim-six-month-data-of-rpgr-gene-therapy-shows-significant-vision-improvement-in-patients-living-with-x-linked-retinitis-pigmentosa>. Accessed April 11, 2022.

23. Shughoury A, Ciulla TA, Bakall B, Pennesi ME, Kiss S, Cunningham ET, Jr. Genes and gene therapy in inherited retinal disease. *Int Ophthalmol Clin* 2021;61:4:3-45.

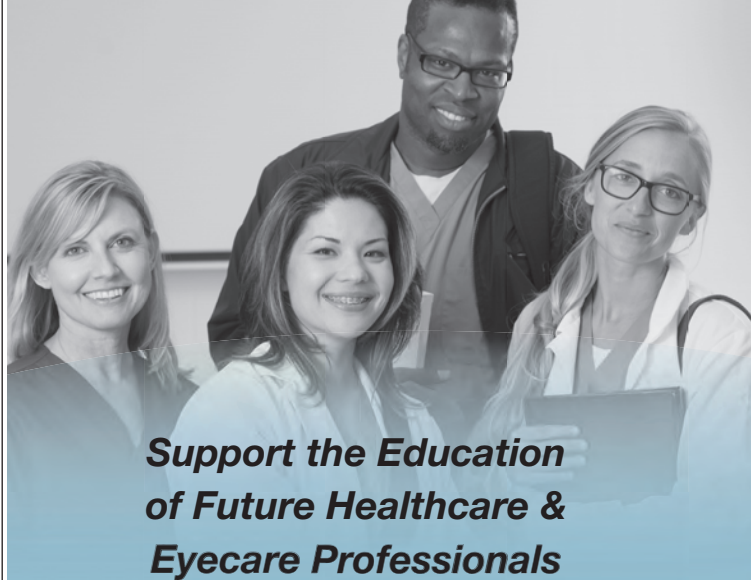24. Ou J, Vijayasarathy C, Ziccardi L, Chen S, Zeng Y, Marangoni D, Pope JG, Bush RA, Wu Z, Li W et al. Synaptic pathology and therapeutic repair in adult retinoschisis mouse by AAV-RS1 transfer. *J Clin Invest* 2015;125:7:2891-2903.

25. Ye GJ, Budzynski E, Sonnentag P, Miller PE, Sharma AK, Ver Hoeve JN, Howard K, Knop DR, Neuringer M, McGill T et al. Safety and biodistribution evaluation in cynomolgus macaques of rAAV2YF-CB-hRS1, a recombinant adeno-associated virus vector expressing retinoschisin. *Hum Gene Ther Clin Dev* 2015;26:3:165-176.

26. Mishra A, Vijayasarathy C, Cukras CA, Wiley HE, Sen HN, Zeng Y, Wei LL, Sieving PA. Immune function in X-linked retinoschisis subjects in an AAV8-RS1 Phase I/IIa gene therapy trial. *Mol Ther* 2021;29:6:2030-2040.

27. Hahn LC, van Schooneveld MJ, Wesseling NL, Florijn RJ, Ten Brink JB, Lissenberg-Witte BI, Strubbe I, Meester-Smoor MA, Thiadens AA, Diederens RM et al. X-Linked retinoschisis: Novel clinical observations and genetic spectrum in 340 patients. *Ophthalmology* 2022;129:2:191-202.

28. Mishra A, Sieving PA. X-linked retinoschisis and gene therapy. *Int Ophthalmol Clin* 2021;61:4:173-184.



**Support the Education  
of Future Healthcare &  
Eyecare Professionals**

# THE RICK BAY FOUNDATION

*for Excellence in Eyecare Education*

Scholarships are awarded to advance the education of students in both **Optometry** and **Ophthalmology**, and are chosen by their school based on qualities that embody Rick's commitment to the profession, including integrity, compassion, partnership and dedication to the greater good.

**INTERESTED IN BEING  
A PARTNER WITH US?**

[www.rickbayfoundation.org](http://www.rickbayfoundation.org)


*(Contributions are tax-deductible in accordance with section 170 of the Internal Revenue Code.)*

## ABOUT RICK

Rick Bay served as the publisher of *The Review Group* for more than 20 years.

To those who worked for him, he was a leader whose essence was based in a fierce and boundless loyalty.

To those in the industry and the professions he served, he will be remembered for his unique array of skills and for his dedication to exceeding the expectations of his customers, making many of them fast friends.



**THE RICK BAY FOUNDATION**  
*for Excellence in Eyecare Education*

*(The Rick Bay Foundation for Excellence in Eyecare Education is a nonprofit, tax-exempt organization under section 501(c)(3) of the Internal Revenue Code.)*

# THE BEST APPROACH FOR NARROW-ANGLE PATIENTS

The age of the patient is one of the many factors to consider when treating patients with narrow angles, experts say.

**MICHELLE STEPHENSON**  
CONTRIBUTING EDITOR

**P**rimarily angle-closure glaucoma affects 20 million people worldwide and is a leading cause of irreversible blindness. Because the crystalline lens plays a major role, some argue, lens extraction is a useful intervention. Another option, of course, is laser peripheral iridotomy.

According to Alliance, Ohio's, Richard Lehrer, MD, there are five factors to consider in patients with narrow angles. "In these patients, I consider the following: whether they have elevated pressure; the presence of a cataract; their age; whether they have any visual dysfunction due to cataract; and whether I think on gonioscopy their angle is occludable. If the person is a young patient with very little cataract, no visual dysfunction, no nerve damage, and no elevated pressure, usually I would lean toward an iridotomy. But, if the patient is a little bit older, has an incipient cataract, has any sign of disc changes or a family history of glaucoma, and has

any visual dysfunction that could be attributed to cataract, I would definitely lean toward cataract surgery."

He adds that there are some rare people who have a very crowded anterior segment. In these patients, removing the cataract and implanting an IOL doesn't necessarily relieve the narrow angle. "These would be patients who have plateau iris and similar configurations," he says. "In those cases, especially if they have glaucoma, I might even recommend doing endocyclophotocoagulation at the same time in order to shrink the ciliary body and create a lot more space in the eye. Having a peripheral iridotomy present in those patients can be helpful, in addition to taking out the cataract."

## When to Consider an Iridotomy

If a patient presents with anatomically narrow angles and a clear lens, and is relatively young with no angle structures seen on gonioscopy, Duke University's Sanjay Asrani, MD, recommends proceeding with a prophylactic laser iridotomy.

"However, the ZAP study found a low risk of an angle closure event

when patients have anatomically narrow angles, so it may not be necessary to proceed with the prophylactic laser iridotomy," Dr. Asrani explains. "But, this study has some caveats. It was done in a purely Chinese population, and it was primarily looking at events such as an angle-closure attack or synechiae in the angle. Additionally, it didn't assess for vascular events, and it was a general population, not the population that presents to an eye clinic. Having said that, the population that we deal with in the United States is likely different. Our population has a higher possibility of borderline blood sugar, which leads to a higher lens thickness because of sorbitol that enters the lens. The other is that our population here in the United States is more likely to take over-the-counter medications that have anticholinergic side effects that can lead to angle closures, in contrast to the Chinese population that doesn't frequently take over-the-counter medications. So, there are some significant differences between the population that was studied in that study versus ours."

The ZAP study is a randomized

This article has no commercial sponsorship.

Drs. Asrani, Francis and Lehrer have no relevant financial interests to disclose.

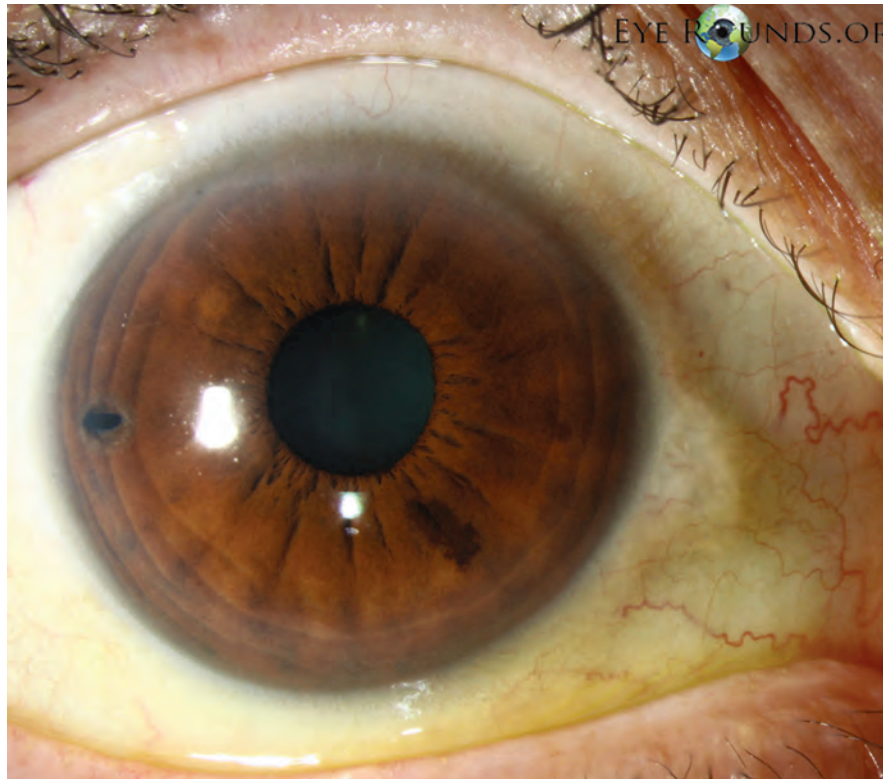


controlled trial in which bilateral primary angle-closure suspects aged 50 to 70 years were enrolled at the Zhongshan Ophthalmic Center in Guangzhou, China.<sup>1</sup> Eligible patients received laser peripheral iridotomy in one randomly selected eye, and the other eye didn't receive treatment.

The study included 889 treated eyes and 889 untreated eyes, and the primary outcome was incident primary angle-closure disease as a composite endpoint of elevation of intraocular pressure, peripheral anterior synechiae, and acute angle-closure during 72 months of follow-up in an intention-to-treat analysis between treated eyes and contralateral controls. The incidence of the primary outcome was 4.19 per 1,000 eye-years in treated eyes compared with 7.97 per 1,000 eye-years in untreated eyes. A primary outcome event occurred in 19 treated eyes and in 36 untreated eyes.<sup>1</sup>

The ZAP study found that laser PIs had a modest, albeit significant, prophylactic effect. Because of the low incidence rate of outcomes that have no immediate threat to vision, the benefit of prophylactic laser peripheral iridotomy was limited, and the researchers concluded that the use of widespread prophylactic laser peripheral iridotomy for primary angle-closure patients isn't recommended.

Dr. Lehrer notes that, even though the ZAP study found that doing laser may not necessarily reduce the risk of going on to develop narrow-angle glaucoma, most ophthalmologists lean toward treatment versus observation if they think the angle really is occludable. "I determine that by gonioscopy, usually in a dark room," he explains. "Many people use scanning technology with OCT and other modalities, like UBM and Scheimpflug imaging. This can be very helpful in showing us which angles are truly occludable. So, if you definitely have an occludable angle, and the patient is in the dark-room situation, and he or



**A relatively young patient with narrow angles and a clear lens is a good candidate for a peripheral laser iridotomy, experts say.**

*Photo courtesy of Kurt Chamberlain MS, Justin Risma, MD, Wallace L. Alward, MD, and Brice Critser, CRA.*

she has never had an angle-closure attack, then I would definitely lean toward treatment.

"If they've had an angle-closure attack in one eye already," Dr. Lehrer continues, "I think they need preventive treatment in their other eye, once the narrow-angle-attack eye has been taken care of. It's a whole different ballgame once they've already had a narrow angle attack, or if they have symptoms consistent with intermittent narrow angle attacks."

Dr. Asrani agrees. "At academic medical centers, we keep seeing patients coming in with acute attacks of glaucoma, which aren't as rare as that study would lead us to believe," he says. "So, a procedure that might prevent an angle-closure attack or that might prevent intermittent angle closure, which can lead to trabecular meshwork damage in the long-run and can ultimately raise pressures in the

future, is a good idea. Therefore, I typically recommend a laser prophylactic iridotomy to such patients. Of course, I'm not talking about people who are just borderline occludable. In those cases, I might wait and watch."

He explains that there's a significant possibility of trabecular damage in the long run due to intermittent angle closure, especially in patients who have large pupils and a phacomorphic component. "So, these patients may not have synechiae, which is irreversible evidence of scarring in the trabecular meshwork, but, periodically, the iris damaging the trabecular meshwork cells can lead to raised intraocular pressure many years down the line," Dr. Asrani says.

### **When to Consider Cataract Surgery**

According to Brian Francis, MD, in practice at the Doheny Eye Insti-

tute in Los Angeles, most ophthalmologists agree that cataract surgery is best for patients with narrow angles and a visually significant cataract or a cataract that's borderline visually significant. "Obviously, it will anatomically cure the narrow angle, so it's more of a permanent cure than an iridotomy, and you get the added advantage of improving vision, especially if the patient has a visually significant cataract," he says. "Generally, these patients are hyperopic, so you can improve the quality of their vision because they're no longer hyperopic. You can make them emmetropic. You can even give them a multifocal lens to improve their near vision, as well. So there's a lot to be said for doing the surgery, especially if the patient has a nearly significant or visually significant cataract."

He adds that there has been controversy surrounding whether these patients require a peripheral iridotomy before undergoing cataract surgery. "I don't believe they do," Dr. Francis avers. "Some doctors believe that if the patient is dilated for cataract surgery, he or she could potentially go into angle closure. I don't think that's necessarily valid. If you dilate someone and take him or her directly to the operating room, you should be able to control for that. A young patient with no cataract is a little bit more controversial. In these patients, you can consider an iridotomy instead of a clear lens extraction, basically. But, again, there is something to be said for lens extraction in these patients because you're going to make their quality of vision better by making them emmetropic instead of hyperopic. If someone has an iridotomy and is still narrow or still has high pressures, I think that's an indication for taking out the lens, even if it's a clear lens extraction."

Dr. Asrani says that he doesn't typically perform clear lens extractions for patients with borderline pressure and/or evidence of mild

glaucoma. "However, there are exceptions in which I see that one eye already has severe glaucomatous damage, and the eyes obviously have what is called a very high lens vault, which is a big phacomorphic component of the glaucoma, and they're already not adequately controlled on practical glaucoma medications," he explains. "I'll go ahead and recommend a clear lens extraction in those cases. But, in general, I do not, because after I remove the cataract, in all cases I can't be sure that I'll be able to achieve glaucoma or pressure control because I don't know the level of the underlying damage of the trabecular meshwork that's already there. I don't want to recommend a clear lens extraction only to realize, after taking the lens out, that the pressure is still uncontrolled because there's already irreversible trabecular meshwork damage."

In the EAGLE study, clear-lens extraction showed greater efficacy and was more cost-effective than laser peripheral iridotomy.<sup>2</sup> The researchers determined that it should be considered an option for first-line treatment.

The EAGLE study enrolled patients from 30 hospital eye services in five countries. Patients were assigned to undergo clear-lens extraction or receive standard care with laser peripheral iridotomy and topical medical treatment. Eligible patients were aged 50 years or older, didn't have cataracts, and had newly diagnosed primary angle closure with intraocular pressure 30 mmHg or greater or primary angle-closure glaucoma.

Of the 419 participants enrolled, 155 had primary angle closure, and 263 had primary angle-closure glaucoma. Two hundred eight patients were assigned to clear-lens extraction, and 211 were assigned to standard care. Additionally, 351 (84 percent) had complete data on health status, and 366 (87 percent) had complete data on intraocular

pressure. The mean health status score, assessed with the European Quality of Life-5 Dimensions questionnaire, was 0.052 higher and mean intraocular pressure was 1.18 mmHg lower after clear-lens extraction than after standard care.<sup>2</sup>

"There's pretty compelling evidence that taking out the lens is basically curing the problem, so it's preferable in most cases, unless the patient is young, has no cataract at all, has 20/20 vision, and isn't at high risk for angle closure," says Dr. Francis. "Then, it makes sense to do an iridotomy until the patient reaches that point or needs his or her cataract done. I also think it's important to tell patients that an iridotomy isn't curative. The iridotomy will change the anatomy and will help prevent angle closure but, over time, you'll get progressive narrowing of the angle due to enlargement of the lens from cataract formation, so they're going to eventually need surgery at that point. The PI just buys you time. In many cases, it can buy you several decades before you need surgery."

Cataract surgery has significantly improved in the past 20 years, and the lens designs have also improved. "You can argue that the lens designs will be even better 10 years from now, so if you can postpone a patient's cataract surgery and do an iridotomy to cover the next 10 years, the patient may end up doing even better," Dr. Francis muses. "It's an interesting conversation. There's no real right or wrong answer, but I think the tide is shifting a little bit more toward lens extraction." ◀

1. He M, Jiang Y, Huang S, et al. Laser peripheral iridotomy for the prevention of angle closure: A single-centre, randomized controlled trial. *Lancet* 2019;393:10181:1609-1618.

2. Azuara-Blanco A, Burr J, Ramsay C, et al. EAGLE study group. Effectiveness of early lens extraction for the treatment of primary angle-closure glaucoma (EAGLE): A randomized controlled trial. *Lancet* 2016;388:10052:1389-1397.

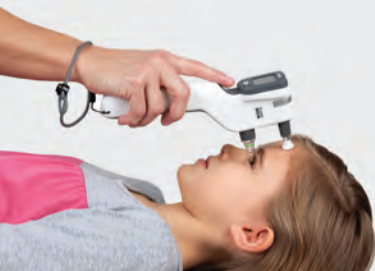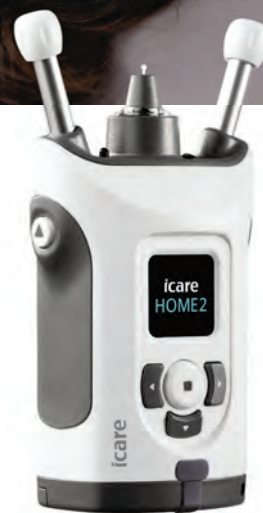# 24-hour at home tonometry

JUST LAUNCHED

## iCareHOME2

Glaucoma management based on real-world IOP data

- + **NEW!** IOP measurements taken in supine, reclined or seated positions
- + **NEW!** New smart light guide for easy positioning
- + **NEW!** Interactive display screen
- + **NEW!** Comprehensive IOP reports



## iCare IC200

200 degrees of  
tonometry

- + Supine, recline & seated positions
- + No corneal disruptions
- + Suitable for every patient
- + Single use probes to exceed infection control guidelines



For more information, scan,  
call 888.422.7313, or email  
infoUSA@icare-world.com  
[www.icare-world.com/USA](http://www.icare-world.com/USA)

For better perception **icare**



# THE GLAUCOMA MEDICATION PIPELINE, 2022

Catching up on the status of four eye drops being developed to target the disease.

LEANNE SPIEGLE  
ASSOCIATE EDITOR

Even when a business is running smoothly, sometimes it can pay to re-engineer the way things are done—or look at the same old processes in a new, fresh way—in an effort to get even better results. Similarly, clinicians who treat glaucoma get very good results with their current medication options. But would it be useful to take a different approach and try to make use of different molecular pathways in the eye to give a positive jolt to outcomes? Currently, prostaglandin analogs are the most prescribed drug class for lowering intraocular pressure in glaucoma patients. Though PGAs work well, some patients may find they need combination therapies or multiple prescriptions to achieve desirable outcomes, which can make adherence even more of a challenge than usual.

Currently, only one of the glaucoma medications far along in the drug-development pipeline is a prostaglandin. The remaining therapeutics in the pipeline attempt to re-engineer

clinicians' approach to treatment, and feature novel mechanisms of action intended to tackle the disease differently than any of the interventions used today.

To learn about some of the innovative IOP-lowering drugs you may soon be able to offer your patients, read on.

## NCX 470 (Nicox SA)

The PGA that has shown promise in clinical trials thus far is NCX 470, formed from a nitric oxide-donating compound. A previous animal study demonstrated the solution's superiority over bimatoprost in lowering IOP and treating both glaucoma and ocular hypertension.<sup>1</sup> More recently in 2021, the company reported the outcomes of the dose-response Phase II trial (Dolomites), which showed that patients on the novel drug experienced significantly greater IOP lowering effects than those on latanoprost.

In the Phase II trials, topical NCX 470 was administered using 0.065% concentration, while the commonly prescribed concentration of 0.005% was used for latanoprost. The company reported that NCX 470 was

superior at all time points over the 28-day period and effectively lowered patients' IOP levels by up to 1.4 mmHg more than latanoprost.

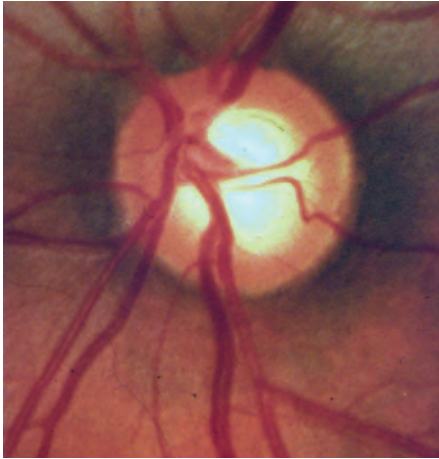
"NCX 470 is a nitric oxide-donating prostaglandin analog similar to Vyzulta," says James C. Tsai, MD, MBA. "It could be slightly stronger than Vyzulta, which itself offers approximately 1 mmHg better pressure reduction than latanoprost, but I don't believe that the 1.4 mmHg reduction with NCX 470 versus latanoprost will be a huge difference compared to Vyzulta's effects."

The once-daily dosed drop is currently being evaluated in two multi-regional Phase III clinical trials, known as Mont Blanc and Denali, which are expected to enroll 670 patients each. The primary objective is to demonstrate whether the efficacy of the 0.1% solution surpasses that of latanoprost 0.005% for reducing IOP in glaucoma patients. Investigators anticipate that the higher drop concentration than that previously used in trials may offer even greater IOP-lowering benefits without increased risk.

The company expects to publish

This article has no commercial sponsorship.

Dr. Solá-Del Valle is a member of the Glaucoma Service at Mass Eye and Ear in Boston, where he specializes in glaucoma care and the surgical treatment of glaucoma. He has consulted for Allergan. Dr. Tsai is the president of New York Eye and Ear Infirmary of Mount Sinai. There, he also serves as the Delafield-Rodgers Professor of Ophthalmology at the Icahn School of Medicine and System Chair of Ophthalmology for the Mount Sinai's Health System. Dr. Tsai serves as a consultant for Eyenovia, ReNetX Bio and Smartlens.



**Researchers are experimenting with different pathways for treating glaucoma medically.**

the results from the Mont Blanc trial in the first quarter of 2023, and results from the Denali trial are expected by the end of that same year.

### **Cromakalim prodrug 1 (CKLP1)**

One of two prospective medications to use a new mechanism of action involving the reduction of episcleral venous pressure (EVP) is cromakalim prodrug 1 (CKLP1), an ATP-sensitive potassium channel opener being studied by a group of researchers from the United States and the United Kingdom. Glaucoma specialists like Dr. Tsai are particularly excited about the prospect of a drop that, for the first time ever, may offer patients clinical results equal to what used to be possible only through surgical intervention.

“If you lower the EVP by 2 mmHg, then the eye pressure is lowered by 2 mmHg,” explains Dr. Tsai. “If you’re working with a drug that reduces the aqueous flow or aqueous outflow, it’s not the same one-to-one relationship as EVP reduction. That’s why we in the glaucoma community are so excited about these new medications that target EVP.”

Dr. Tsai explains that with prostaglandins, there’s often a floor effect on IOP that prevents the pressure level from going below that of the EVP. “Right now with medication therapy, you can’t get a patient’s IOP to be under 8 to 10 mmHg,” he says. “But, with these drugs that are able

to reduce EVP, we might be able to achieve pressures lower than that without having to perform surgery.” This eliminates the potential complications of surgery and replaces them with a medication that’s just taken once a day and can be discontinued if there’s an issue, Dr. Tsai adds.

Though this IOP-lowering drug has yet to be tested on humans, a study published last year observed its effect on large normotensive animals and found that CKLP1 was able to significantly lower IOP by 18.9 percent in monkeys and 16.7 percent in dogs compared with control eyes.<sup>2</sup> The drug was also shown to have no effect on the animals’ systemic blood pressure.

### **Omidenepag isopropyl (Omd, Santen)**

This drug has been sold in Japan and other parts of Asia since 2018 but is still in the process of gaining FDA approval.

Omd is a selective, non-prostaglandin, prostanoid EP2 receptor agonist. Its safety and efficacy have been shown in various studies, one which found that Omd 0.002%, alone or administered concomitantly with timolol 0.5%, resulted in sustained IOP reduction through 52 weeks in Japanese patients with open-angle glaucoma or ocular hypertension.<sup>3</sup>

Another recent clinical trial including 190 patients concluded that Omd 0.002% was well-tolerated and noninferior to latanoprost 0.005% in reducing IOP in patients with ocular hypertension or primary open-angle glaucoma.<sup>4</sup> Though no serious side effects were reported, the most common side effect observed was conjunctival hyperemia, an interesting finding considering it’s often associated with prostaglandin agents. Although 24.5 percent of subjects reported hyperemia, not all the research agrees on the frequency of its occurrence.

The most recent study of the drug was published this past March and, according to the authors, found that “Omd showed an IOP-lowering ef-

fect in eyes with various types of glaucoma and using various therapeutic regimens in real-world clinical practice.”<sup>5</sup> Out of the 827 patients who participated in the study, 14 percent experienced some form of an adverse reaction, the most common being hyperemia (7.6 percent—much less common than observed in the previous study). There were also no serious side effects reported.<sup>5</sup> Based on these positive outcomes, the study authors say that Omd has the potential to be a first-line treatment for glaucoma.

“Because it’s a non-prostaglandin, it doesn’t have the same side effect profile as a prostaglandin would,” says David Solá-Del Valle, MD. “For instance, it doesn’t seem to have cystoid macular edema, periorbital atrophy or the periorbital pigmentation side effect profile. I have a growing group of patients who get all these side effects from latanoprost even though their IOP is good, so it would be nice to have the option to switch them to Omd. I’m very excited about it.” He mentions the added benefit of once nightly administration, which may also improve adherence to treatment and help reduce damage to the ocular surface.

The FDA accepted the New Drug Application in February 2021 and is currently conducting the review process to investigate the drug as a treatment for patients with glaucoma and ocular hypertension.

### **QLS-101 (Qlaris Bio)**

Further along in the pipeline than CKLP1, QLS-101 is the second ATP-sensitive potassium channel opener intended to target the reduction of EVP. The drug is currently in a Phase II clinical trial (Study QC-201) that’s testing three different concentrations vs. timolol maleate preservative free 0.5% in a cohort of 84 patients with POAG or ocular hypertension.

“QLS-101 is a novel ATP-sensitive potassium channel modulator administered as a topical eye drop,” says Dr. Tsai. “It works similar to CKLP1, in that it reduces EVP and widens out-

flow channels and episcleral vessels distal to the trabecular meshwork.”

In addition to potentially serving as an alternative noninvasive treatment to surgery, both QLS-101 and CKLP1 may also spare patients from the side effects seen with prostaglandins. Results from Study QC-201 will help define treatment outcomes and the risk of adverse events for one of the first drugs to use this new mechanism of action.

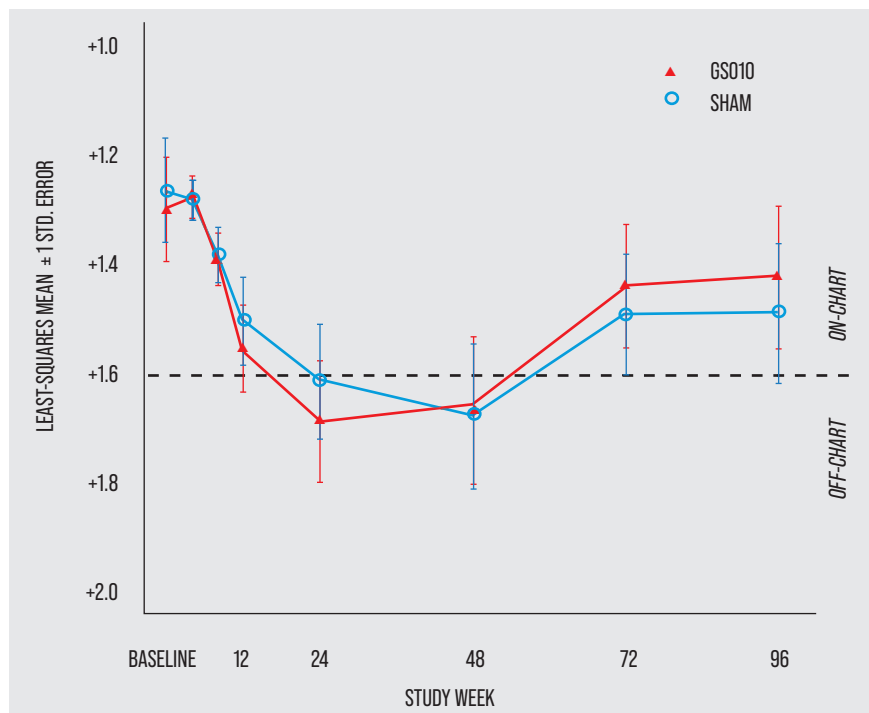
### GS010 (rAAV2/2-ND4, GenSight)

Though not specifically formulated or indicated for treating glaucoma, GenSight is investigating the potential role of GS010 in treating recent vision loss in patients with Leber hereditary optic neuropathy (LHON). The positive results so far show promise for the future of gene- and cell-based treatments for other neuro-ophthalmic conditions, including glaucoma.

The first Phase III trials of this novel gene therapy were recently completed in 2020 (RESCUE and REVERSE trials). The drug, administered via a one-time unilateral intravitreal injection, is specifically made for those with a G11778A mutation in the mitochondrial ND4 gene who sustained a recent loss of vision (within the previous six months for the patients in the clinical trial).

In the REVERSE trial, participants were randomly assigned to receive a sham injection in one eye and an injection of GS010 in the other. The results showed that visual improvement was sustained through the 96-week follow-up period in both eyes. At the conclusion of the trial, eyes treated with GS010 demonstrated a mean improvement in best-corrected visual acuity of -0.31 logMAR, while eyes treated with the sham injection showed a mean improvement of -0.26 logMAR. The insignificant difference in visual outcomes between the two groups meant that the primary endpoint wasn't met, though 78 percent of subjects did show bilateral improvement in vision.<sup>6</sup>

The RESCUE trial produced



**This graph shows the time course of BCVA (in logMAR) of patients with LHON who participated in the 96-week RESCUE trial evaluating the developing gene therapy, GS010.**

comparable results; the difference of the change in BCVA from baseline between GS010-treated and sham-treated eyes was -0.01 logMAR, which fell short of the primary endpoint of a difference of at least -0.30 logMAR. The average BCVA of study participants decreased through week 24 and then peaked before plateauing up until week 48. By the end of the trial at week 96, eyes treated with sham injections shared a similar outcome to those treated with GS010.<sup>7</sup>

Though the therapeutic needs validation through additional research, these two Phase III trials have laid the groundwork for future studies to investigate the role of this modality in treating various forms of optic nerve disease.

In conclusion, there are several noninvasive therapeutic options you can look forward to possibly offering your patients in the future, including the topical formulations NCX 470, CKLP1, OMDI and QLS-101. In addition, other nonsurgical options such as gene therapy are showing positive preliminary results in clinical research. Not only do most of these glaucoma

treatments have promising side-effect profiles, but some physicians say they may be able to provide patients with visual outcomes comparable to or better than those of minimally invasive glaucoma surgeries. ◀

1. Impagnatiello F, Bastia E, Almirante N, et al. Prostaglandin analogues and nitric oxide contribution in the treatment of ocular hypertension and glaucoma. *Br J Pharmacol* 2019;176:8:1079-1089.
2. Roy Chowdhury U, Kudgus RA, Holman BH, et al. Pharmacological profile and ocular hypotensive effects of cromakalim produg 1, a novel atp-sensitive potassium channel opener, in normotensive dogs and nonhuman primates. *J Ocul Pharmacol Ther* 2021;37:5:251-260.
3. Aihara M, Lu F, Kawata H, Iwata A, Odani-Kawabata N. Twelve-month efficacy and safety of omidenepag isopropyl, a selective EP2 agonist, in open-angle glaucoma and ocular hypertension: The RENGE study. *Jpn J Ophthalmol* 2021;65:6:810-819.
4. Aihara M, Lu F, Kawata H, Iwata A, Odani-Kawabata N, Shams NK. Omidenepag isopropyl versus latanoprost in primary open-angle glaucoma and ocular hypertension: The phase 3 AYAME Study [Published correction appears in *Am J Ophthalmol* 2021 Nov;231:211]. *Am J Ophthalmol* 2020;220:53-63.
5. Miki A, Miyamoto E, Ishida N, Shii D, Hori K; LESPOIR Research Group. Efficacy and safety of omidenepag isopropyl 0.002% ophthalmic solution: A retrospective analysis of real-world data in Japan *Adv Ther*. [Epub March 14, 2022].
6. Yu-Wai-Man P, Newman NJ, Carelli V, et al. Bilateral visual improvement with unilateral gene therapy injection for Leber hereditary optic neuropathy. *Sci Transl Med* 2020;12:573:eaaz7423.
7. Newman NJ, Yu-Wai-Man P, Carelli V, et al. Efficacy and safety of intravitreal gene therapy for Leber hereditary optic neuropathy treated within six months of disease onset. *Ophthalmology* 2021;128:5:649-660.

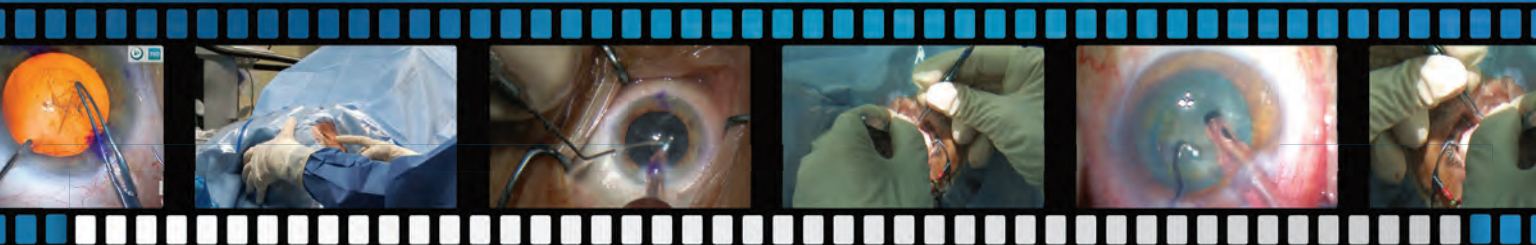




Monthly

# MACKOOL ONLINE CME

## CME SERIES | SURGICAL VIDEOS



To view CME video  
go to:

[www.MackoolOnlineCME.com](http://www.MackoolOnlineCME.com)

### Episode 77: “The Frail Patient and the Suspect Zonule”

Surgical Video by:  
Richard J. Mackool, MD

#### Video Overview:

An extremely frail, elderly patient undergoes phacoemulsification performed on her only sighted eye.

## MackoolOnlineCME.com MONTHLY Video Series



Richard J. Mackool, MD

I am happy to announce an exciting addition as we continue into our seventh year of Mackool Online CME. This year, with the generous support of several ophthalmic companies, my son Dr. RJ Mackool and I will share the honor of presenting our surgical cases to you. Together we will continue to demonstrate the technologies and techniques that we find to be most valuable to our patients, and that we hope are helpful to many of our colleagues.

I will continue to narrate all of the cases, even as we share the surgical duties and thereby expand the variety of the cases that we bring to you. As before, one new surgical video will be released monthly, allowing our colleagues the opportunity to earn CME credits or just observe the case. New viewers are able to obtain additional CME credit by reviewing previous videos that are located in our archives.

I thank the many surgeons who have told us that they have found our CME program to be valuable and instructive; I appreciate your comments, suggestions and questions. Thanks again for joining us on Mackool Online CME.



**CME Accredited Surgical Training Videos Now Available Online:** [www.MackoolOnlineCME.com](http://www.MackoolOnlineCME.com)

Richard Mackool, MD, a world renowned anterior segment ophthalmic microsurgeon, has assembled a web-based video collection of surgical cases that encompass both routine and challenging cases, demonstrating both familiar and potentially unfamiliar surgical techniques using a variety of instrumentation and settings.

This educational activity aims to present a series of Dr. Mackool's surgical videos, carefully selected to address the specific learning objectives of this activity, with the goal of making surgical training available as needed online for surgeons motivated to improve or expand their surgical repertoire.

#### Learning Objective

*After completion of this educational activity, participants should be able to:*

- address increased incidence of zonular laxity in frail patients.

**Satisfactory Completion** - Learners must pass a post-test and complete an evaluation form to receive a certificate of completion. You must listen to/view the entire video as partial credit is not available. If you are seeking continuing education credit for a specialty not listed below, it is your responsibility to contact your licensing/certification board to determine course eligibility for your licensing/certification requirement.



**Accreditation Statement** - In support of improving patient care, this activity has been planned and implemented by Amedco LLC and Review Education Group. Amedco LLC is jointly accredited by the Accreditation Council for Continuing Medical Education (ACCME), the Accreditation Council for Pharmacy Education (ACPE), and the American Nurses Credentialing Center (ANCC), to provide continuing education for the healthcare team.

JOINTLY ACCREDITED PROVIDER™  
INTERPROFESSIONAL CONTINUING EDUCATION

**Physicians (ACCME) Credit Designation** - Amedco LLC designates this enduring material activity for a maximum of .25 AMA PRA Category 1 Credits™. Physicians should claim only the credit commensurate with the extent of their participation in the activity

Jointly provided by:




Supported by an unrestricted independent  
medical educational grant from:



Additionally Supported by:



In Kind Support:



Video and Web Production by:  
JR Snowdon, Inc

# UPDATE: PRIVATE EQUITY IN OPHTHALMOLOGY

Many surgeons say they've had a positive experience—but proceeding with caution is advised.

**CHRISTOPHEHR KENT**  
SENIOR EDITOR

One of the most striking trends in American health care in recent years has been the injection of private equity into the system. The private equity model centers around increasing the value of purchased practices for eventual resale to a second private equity buyer, who hopes to repeat the process for another eventual resale, often referred to as “the second bite of the apple.”

According to a 2021 report from the American Antitrust Institute<sup>1</sup>, estimated annual private equity deals in American health care tripled from \$41.5 billion in 2010 to \$119 billion in 2019. And a report from the American Medical Association found that in 2018 the number of doctors who were employed by a company surpassed the number who owned their own practices for the first time.<sup>2</sup>

Not surprisingly, placing health care into a model that focuses on expansion and profitability can be dangerous, with the potential to make patient care secondary to the financial concerns of investors backing

the private equity purchases. So far, ophthalmologists who have decided to participate report mostly positive experiences. But even when all goes well, the private equity explosion is reshaping the look of health care in the United States by propelling the formation of larger and larger health care groups. And, the trend is still on the upswing.

“After a very brief COVID-related pause, private equity in the ophthalmologist space is still on a steady churn,” notes John Pinto, president of J. Pinto & Associates, an ophthalmic practice management consulting firm. “The most desirable practices are getting multiple pitches every year. Even smaller practices are often taking calls from companies inquiring about their interest.”

Mr. Pinto points out that most of the private equity deals happening in ophthalmology right now are still primary transactions, not a second go-round. “The focus is also still on beachhead practices—those that are large and regionally important and have a strong ASC component,” he says. “That’s what you’d expect at this stage in the relatively young development of private equity in

ophthalmology. It’s basically walking the same trail that all of us did back in the 1990s, when the first version of Wall Street and ophthalmology’s dance took place with the physician practice management companies.”

Here, we’ll share first-hand stories and advice from ophthalmologists who’ve now been involved in the private equity process for several years, with additional perspectives offered by outside experts. (*For more on this topic, check out “Is a Private Equity Deal Right for You?” in the April and May 2018 issues of Review.*)

## Stepping Into the Fray

Retinal specialist Daniel M. Miller, MD, PhD, vice chair of the medical executive board for EyeCare Partners and former chief medical officer for the Cincinnati Eye Institute, has been involved with private equity for a number of years. His organization, CEI Vision Partners, was assembled in the initial private equity firm purchase and recently went through the “second bite of the apple,” when it was sold to a second private equity firm.

“I joined Cincinnati Eye Institute in 2006,” Dr. Miller explains. “At

*This article has no commercial sponsorship.*

Drs. Miller, Sheppard and Lindstrom are participants in private equity operations. Mr. Pinto has no financial ties to any private equity firms.



**Overall, assets under private equity management in 2010 were estimated at \$1.7 trillion. Recent projections suggest that number may reach \$9 trillion by 2025. (Source: Preqin)**

the time, it was one of the largest private multispecialty ophthalmology companies in the U.S. It was 100-percent physician-owned, with multiple surgery centers and a large number of partners. During my first decade at CEI we were very successful and continued to have steady growth in the northern Kentucky, southwest Ohio and western Indiana markets. We had a top-shelf executive team, great physician leadership and a culture of partnership between the physician leaders and the executive leadership.

“Around that time, hospitals began acquiring primary care physicians and subspecialists,” he recalls. “Although most of this didn’t involve ophthalmologists, we felt a little threatened by this trend. So, we started thinking about strategies to enlarge our footprint. One of the things we decided to do was start a management services organization—an MSO—that was just physician-owned. We found some like-minded groups in our region who were willing to join us. The goal wasn’t really to make it a revenue-generator, but to provide shared services among the participating organizations, broaden our influence in the region, and eventually do some joint contracting and strategic moves.

“That turned out to be a good model,” he says. “We learned a lot

about providing services to other ophthalmology practices, and it got us thinking about expanding beyond our region. However, we also learned that there are limitations to that model. We didn’t have the capital to drive the acquisition of additional practices.”

Dr. Miller notes that a few years later the private equity wave began to pick up steam. “During that period of time, we were constantly getting called by capital investors and private equity groups,” he says. “However, at the time we didn’t see that fitting into our strategic objectives. But after working with our MSO, we started to look at the situation differently. We realized that given our size and what was happening in medicine, expanding our footprint was going to be an important long-term strategy.

“So, we took a deep dive into looking at private equity,” he continues. “Over the preceding years we’d received so many calls that we had a Rolodex of private equity groups that were interested in ophthalmology. Using that resource, our CEO led us through a competitive process, in which we considered more than 30 private equity groups as potential partners. We whittled that list down to 10 companies, and then did a formal vetting process. In 2018, we partnered with Revelstoke Capital

Partners, out of Colorado, forming CEI Vision Partners, a.k.a. CVP.”

Dr. Miller notes that one of the most positive aspects of working with Revelstoke was that they kept CEI’s executive leadership intact. “We already had a successful ophthalmology CEO and VPs managing the key functions of our company, and an experienced physician leadership team that Revelstoke was willing to invest in,” he says. “For their part, they added some new key positions: they brought in a chief financial officer, a chief operating officer, a VP of payor contracting and a VP in charge of revenue cycle management. We already had more than 400 employees and multi-state surgery centers, so these were things we really needed to scale our company to a higher level. The new additions helped position us for that level of growth.”

Dr. Miller says the partnership with Revelstoke worked out very well. “Our choice of Revelstoke in our first transaction was very fortuitous,” he says. “They really upheld their part of the bargain in terms of what we were hoping to achieve with growth and expanding our business. And, we had shared strategic goals that we worked very hard to achieve. We were able to add many excellent practices to our organization, such as Virginia Eye Consultants in the mid-Atlantic, and we were able to grow throughout Ohio with mergers and acquisitions. The company grew to be quite large.”

### **More Private Equity Journeys**

Richard L. Lindstrom, MD, founder and attending surgeon emeritus at Minnesota Eye Consultants in Bloomington, Minnesota, has seen the results of his group’s purchase by private equity firm Unifeye Vision Partners. (Their group hasn’t been through a second purchase yet.) Dr. Lindstrom says that overall, he’s happy with the way the new ownership arrangement has worked out. “I wouldn’t have done anything differ-



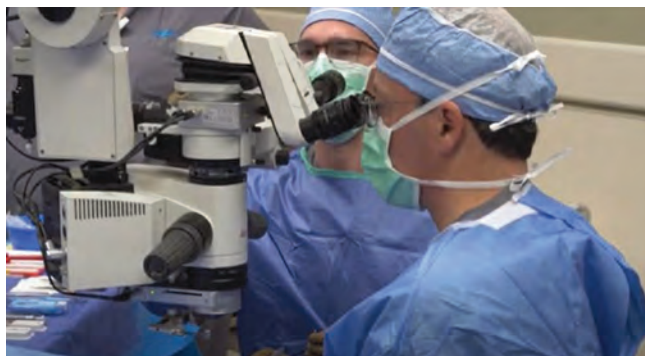ent in hindsight,” he notes. Asked if everyone in the practice is satisfied with the current situation, he points out that in a large group practice there are always differences of opinion. “But objectively, everyone is doing well,” he says.

Dr. Lindstrom says one of the biggest advantages of having private equity backing was pandemic related. “When we were partially shut down by COVID-19 for extended periods, our practice losses were covered by our private equity partner,” he explains. “I estimate that we would have required a capital call for several hundred thousand dollars per partner to cover these losses without our private equity partner. They covered all losses.”

John D. Sheppard, MD, MMSc, FACS president of Virginia Eye Consultants, medical director of EyeCare Partners MidAtlantic Ophthalmology, and a professor of ophthalmology at Eastern Virginia Medical School, has also experienced the private equity phenomenon first-hand. Dr. Sheppard’s practice, Virginia Eye Consultants, joined CEI Vision Partners in early 2019, and is now part of EyeCare Partners. As a result, Dr. Sheppard has had the opportunity to experience the private equity process through a second sale.

“At the time of the first merger, the difference between our practice and Cincinnati Eye Institute was that CEI was already very large and had more or less reached equilibrium,” he explains. “In contrast, our practice was growing about 20 percent a year. So, we were growing intrinsically, while they were consolidating and growing by acquisition.”

Dr. Sheppard says the merger worked well, for a number of reasons. “Our two practice cultures were very well-matched,” he says. “We were able to avoid duplica-



Cincinnati Eye Institute

**Daniel M. Miller, MD, PhD, above, says his practice’s partnership with private equity has been positive so far, in large part because the partners they’ve chosen have had a shared vision for the future and similar values and priorities.**

tion of management. We had many shared committees. Also, becoming bigger brought us cost savings. For example, our surgical packs immediately went to half price when we became a much bigger entity. That was just one of many welcome changes.”

Dr. Sheppard notes that both practices were able to learn from the experiences of the other. “Their doctors visited us and we visited them,” he says. “Despite both of us being leading regional and national practices, we still had a great deal to learn from each other. It’s been a nice marriage of two like-minded practices.”

Dr. Sheppard says being part of a larger organization has helped with managing a number of issues, including hiring. “The biggest problem all of us have been having is maintaining adequate staffing,” he says. “This is a national issue. Because we’ve joined forces with other practices, we’re able to pool resources involving recruiting, personnel management and human relations. Instead of having busy doctors trying to recruit staff and other doctors, we have a professional team, including an administrator, a recruiter and a doctor, who do that for a living. They seek out and vet doctors, ophthalmic technicians, surgical techs, registered nurses, front desk personnel and other staff members. This allows us to do the

best possible job of screening, vetting and hiring.”

Dr. Sheppard notes that Virginia Eye Consultants didn’t acquire any other practices before it joined CEI. “We’ve done several regional mergers since then, and we’re working on several more,” he says.

## The Second Sale

At the end of 2021, CEI Vision Partners’ anticipated second sale took place when it was acquired by

EyeCare Partners. “Because of the strength of our partnership and our position in the national ophthalmology community, we were an ideal subsequent merger partnership for the folks at EyeCare Partners,” Dr. Sheppard explains. “EyeCare Partners was primarily optometry-focused; merging with them created an organization with strength in both ophthalmology and optometry. We’re now both the biggest ophthalmology group in the country and the biggest optometry group in the country. The current wave of collaboration between the two professions is reflected here by parallel organizations within ECP of equal proportion, equal importance and equal structure.”

Dr. Miller says this was a strategic move for his group. “ECP was part of our process years earlier when we were first looking at companies to partner with,” he explains. “We thought highly of their team back then, but it wasn’t the right time for us to partner with them. At that point their optometry business was much larger than their ophthalmology business, for example. But in the following years ECP made tremendous advances in both their optometry and ophthalmology platforms.

“Their current leadership is really impressive, and it was a great cultural fit for us, in terms of shared vision, values and priorities,” he continues. “That made it mutually beneficial



## 3RD YEAR OPHTHALMOLOGY RESIDENT **WET LAB PROGRAMS**

Dear CSE 3rd-Year Resident Program Director and Coordinator,

We would like to invite you to review the upcoming 3rd-Year CSE Ophthalmology Resident CME Programs and Wet Labs for 2022 in Fort Worth, Texas. The programs offer a unique educational opportunity for third-year residents by providing the chance to meet and exchange ideas with some of the most respected thought leaders in ophthalmology. The programs are designed to provide your residents with **in-depth didactic program and state-of-the-art wet lab experience with one-on-one wet lab guidance from faculty**. The courses also serve as an opportunity for your residents to network with residents from other programs.

After reviewing the material, it is our hope that you will select and encourage your residents to attend one of these educational activities, which are CME accredited to ensure fair balance.

Best regards,

Kendall Donaldson, MD, MS; Yousuf Khalifa, MD and Mitchell P. Weikert, MD, MS

### SAVE THE DATE

~~JULY 29–30, 2022~~  
(FRIDAY–SATURDAY)

**Course Director**  
Mitchell P. Weikert, MD, MS  
**REGISTER FOR WAIT LIST**

**AUGUST 26–27, 2022**  
(FRIDAY–SATURDAY)

**Course Director**  
Kendall Donaldson, MD, MS

**SEPTEMBER 16–17, 2022**  
(FRIDAY–SATURDAY)

**Course Director**  
Yousuf Khalifa, MD

Registration open [www.ReviewEdu.com/CSE3rdYr2022](http://www.ReviewEdu.com/CSE3rdYr2022)

Courses are restricted to **US-based 3rd-year residents enrolled in a US-based ophthalmology resident program and within their third year at the time of the course**. There is no registration fee for these activities. Air, partial ground transportation in Fort Worth, hotel accommodations and modest meals will be provided through an educational scholarship for qualified participants.

**Satisfactory Completion** – Learners must complete an evaluation form to receive a certificate of completion. Your chosen sessions must be attended in their entirety. Partial credit of individual sessions is not available. If you are seeking continuing education credit for a specialty not listed below, it is your responsibility to contact your licensing/certification board to determine course eligibility for your licensing/certification requirement.



JOINTLY ACCREDITED PROVIDER™  
INTERPROFESSIONAL CONTINUING EDUCATION

**Accreditation Statement** – In support of improving patient care, this activity has been planned and implemented by Amedco LLC and Review Education Group. Amedco LLC is jointly accredited by the Accreditation Council for Continuing Medical Education (ACCME), the Accreditation Council for Pharmacy Education (ACPE), and the American Nurses Credentialing Center (ANCC), to provide continuing education for the healthcare team.

**Physicians (ACCME) Credit Designation** – This live activity has been approved for **AMA PRA Category 1 Credit(s)™**.

For more information visit the registration site above or  
call Denette Holmes at 866-627-0714 or email [dholmes@postgradhealthed.com](mailto:dholmes@postgradhealthed.com)

Jointly provided by

Supported by an independent  
medical education grant from **Alcon**



## THE ASC FACTOR

“Private equity firms are discovering, as companies did back in the 1990s, that the ASC component is really critical to making this work,” notes John Pinto, president of J. Pinto & Associates. “Stable ASC profits and comparatively low enterprise complexity are in keeping with a corporate environment—much more so than the massive complexity and volatility of the underlying practices themselves. That’s why I believe that in the years ahead, many of these private equity companies will disgorge the practices they’ve assembled, but hold on to the ASCs. That’s what happened in the 90s. The best known of those companies is NovaMed; it was rolling up ophthalmology practices, but then decided to disgorge its practices and just stick with the ASC components. NovaMed became a surgery-center company, like AmSurg, instead of remaining in the practice management space.

“A lot of the reason for this,” he continues, “comes down to what the corporate world refers to as ‘the hedgehog principle.’ A surgery center is a very well-defined, discrete business enterprise. There are many complexities, but those are narrow compared to the administrative and management leadership complexities found in an ophthalmology practice. It’s 10 times easier to run a surgery center than it is to run an ophthalmology practice, just in terms of the number of moving parts and things that can go wrong.”

Why didn’t the private equity firms simply start by going after ASCs? “Private equity companies that entered the ophthalmology sector were basically just taking a chapter out of what had happened in dermatology, veterinary medicine and other health-care-related rollups,” Mr. Pinto explains. “They said, ‘Let’s be in that business.’ These were entities that didn’t have much of an ASC presence, so they didn’t think about it. In addition, the ASC business was already populated by companies like AmSurg and local health-care systems, so there didn’t seem to be much runway to take a private equity approach to that.

“I’m not saying that all of the current 40-plus private equity firms in ophthalmology are going to get boiled down one day to being ASC companies,” he adds. “But a significant number of them are finding that the vagaries and challenges of running a medical practice are not to their liking.”

—CK

to both organizations to make a deal happen at the end of last year. A significant part of that was that Rev-elstoke shared our vision for what a future transaction might look like.

“We’re now almost halfway through our first year of integrating with ECP, and it’s gone extremely well,” he adds.

Dr. Miller attributes the success of this process in part to consistent leadership over time. “CEI was lucky to have great executive leadership and an intact executive team for decades,” he says. “A lot of our success had to do with that physician-executive partnership. When we looked to partner with private equity, we had a very clear vision of what we wanted to accomplish, and what we wanted that private equity partnership to look like. That ended up honing our decision about who we partnered with, and who would

support our mission.”

Dr. Sheppard notes that one aspect of this process that’s made him very happy is getting to work with many ophthalmologists he’s known for years in the new organization. “Some long-established professional friendships are now among my partners,” he explains. “For me, private equity times two has been a wonderful experience. This is truly a world-class organization.”

In terms of carrying these advantages further, Dr. Sheppard believes it would make sense for the organization to create a third division for their ambulatory surgery centers. “EyeCare Partners now has 31 surgical centers,” he notes. “That’s a very different management and personnel challenge.”

Mr. Pinto says that secondary recapitalization is a very real prospect for many of these private-equity-

based groups. “Some of the 40-plus private equity firms out there will be undertaking that, but only a few of those secondary transactions have occurred,” he says. “The modus operandi of private equity firms is to hold on to these gathered up practices for four to seven years before disgorging them back into the market, so we’re probably several years away from seeing what the real impact of that will be.”

## What About the Downsides?

The surgeons we’ve spoken to largely report positive experiences as a result of partnering with private equity. However, they’ve noted a few downsides:

- **Adjusting to massive change.**

“Going down this road requires change, and for doctors who are creatures of habit, it’s disruptive,” Dr. Miller points out. “However, what we’ve seen is that the advantages of making this change are logarithmic, not just additive.”

- **Giving up control.**

Dr. Miller notes that giving up control to a larger business entity can be a big issue. “For doctors in a smaller group who’ve had the ability to manage every aspect of their business, it’s hard to adjust to the culture of having an executive team, and reporting structures, and changing parts of your business to follow the established policies and procedures of a much larger business.

“However, I’d counter with the point that in most cases, physicians from smaller practices are freed from having to manage aspects of the business that aren’t patient-care-facing,” he says. “Doctors in a smaller practice are used to managing HR issues, front desk issues, call center issues, revenue cycle issues, payer issues, staffing issues, insurance issues and so on. But as the smaller company integrates into the larger entity, they no longer have to do that. That can be very freeing. Yes, it’s an adjustment, and you might not like the way that some things



are now done. But things have to be done in a way that works across a much larger organization.”

• **Dealing with a huge bureaucracy.** Dr. Sheppard says working with layers of bureaucracy can be frustrating. “To make decisions, such as a new hire, new office or new equipment, you have to go upward through three layers of bureaucracy,” he explains. “Previously, we only had one layer to deal with to get various types of transactions approved and accomplished.”

• **Having every purchase evaluated.** Dr. Lindstrom says that having another decision-maker at the table primarily focused on the economics of each decision has been challenging. “Not every doctor can request any new ‘toy’ they want, without careful analysis of the potential return-on-investment before purchase,” he says. “However, this is also the biggest upside of the current arrangement. We make much wiser decisions regarding investment and capital allocation than we did before.”

• **The new owner’s management style.** Mr. Pinto says he’s encountered doctors near retirement who regretted making the deal. “The regret isn’t usually financial,” he says. “Complaints are usually more along the lines of how the practice is now being managed by the corporate overseer.

“There’s a whole box full of things they don’t like,” he continues.

“Some are trivial irritants. For example, one client who left a private equity setting told us about having two receptionists, one of whom had a stapler that broke. The receptionist had to put in a requisition form to get a new \$15 stapler. The requisition was not approved, with the private equity firm saying, ‘Use your desk-mate’s stapler so we don’t have to buy a second one.’

“There are also gross examples of practices that have been mismanaged—practices with strong financial and volumetric performance



**The Cincinnati Eye Institute partnered with a private equity firm in 2018, and has now been through the “second bite of the apple.” The second purchase, by Eye Care Partners, has made them part of the largest ophthalmology group in the United States.**

pre-transaction that fell down,” he continues. “Of course, some of this is multifactorial, because we’ve been going through a pandemic.”

Mr. Pinto adds that unhappiness between partners can go both ways. “I’m sure that for every story about a doctor being unhappy with his management company, there’s a private equity executive who has a similarly frustrating story about a doctor who wasn’t reasonable, while the firm was doing all that it could to operate in a difficult environment,” he says.

### **Is This a Pyramid Scheme?**

It’s not hard to see potential future problems with the private equity model, which depends on finding ways to make companies more profitable so they can be sold to another firm, which will then repeat this in hopes of selling an even more profitable company or group to the next buyer in line ... *ad infinitum*.

“Many have called private equity transactions a kind of pyramid or Ponzi scheme, aggregating values together and then selling them to the next greater fool,” notes Mr. Pinto. “The private equity model—which sometimes works and sometimes doesn’t—is that you take a comparatively small business, like a \$10-million eye clinic, and you introduce a few easy profit-enhancement activities. Some of them are revenue enhancers, some are cost-containers. You do that with a collection of

\$10-million practices, in a service region that has the same payor cohort. You now have a large enough provider base to be able to drive a better deal with private payors.

“If you put those ingredients together in a pot and stir it up, there’s an argument for saying that you might be able to take a \$10 million practice with a 30-percent profit margin and turn it into a practice with a 32- or 35- or 38-percent profit margin,” he continues. “If you get a whole bunch of those practices together, and you’re able to execute your plan, then the cohort of practices that you bought for seven or eight times earnings is now one much larger company with some regional control and pricing power. That cohort is now worth 10 or 12 times earnings. The people who buy that for 10 or 12 times earnings believe they can take 20 practices and aggregate them with another 20 or 30 or 50 practices and end up with a company with a billion dollars in revenue. They’ll be able to turn that into a public company, or sell it to a public company. In a typical environment it might now be worth 15 to 20 times earnings.

“At each level, as you grow in scale and make even small changes in profitability, there’s a strong amount of leverage occurring,” he says. “All along the way that benefits the doctor-owners who got the original deal done. It benefits the

## BEWARE OF BAD APPLES

In recent years, as the reach of private equity has expanded within American health care, disturbing signs of abuse have begun to appear. It's increasingly common to read reports of doctors and staff members in different medical fields being fired and/or filing lawsuits about policies put in place by private equity firms that undercut patient care. (Private equity is private; most transactions are not reported to regulatory agencies, so there's little oversight.)

Examples now appear in the news multiple times a year:

- Hospital emergency rooms have been purchased by a number of private equity firms because of their profitability. Some ER doctors have objected to excessive cuts in patient care, requesting that additional staff be hired, with the result that they've been fired. (A number of lawsuits regarding these practices have been brought and won, but with negligible financial consequences for the firms involved.) Meanwhile, many examples of "surprise" ER bills attributed to private equity owner policies have threatened to bankrupt patients, making the news.

- In the field of dermatology—popular with private equity firms—studies have shown that increasing profits by using more "physician extenders" has led to a decline in patient care.<sup>3,5</sup>

- Many states have laws that bar corporations from practicing medicine, but those laws have generally remained unenforced. The American Academy of Emergency Medicine Physician Group recently filed a lawsuit against one of the largest private equity firms for running emergency rooms in California, as being a violation of these laws. The lawsuit is not seeking monetary damages; instead, it's asking the court to stop the firm from running emergency rooms in the state. (Similar lawsuits have been brought—and won—against private equity firms operating in the field of dermatology.)

So far, few signs of this kind of trouble have appeared in the field of ophthalmology. But the possibility of profit-driven care replacing patient-driven care needs to be taken seriously.

"Obviously, when you have more than 40 private equity companies engaged in this in the field of ophthalmology, half are doing an above-average job and half are doing a below-average job," John Pinto, president of J. Pinto & Associates, notes. "In my role as advisor to the profession, I don't hear from doctors who are happy about their private equity environment; I hear from the

*(continued on facing page)*

primary private equity firm, and it benefits the second private equity firm, or other recapitalizing entity. The profits daisy-chain on up."

But given that this is based upon ever-expanding profitability, won't someone eventually end up getting burned? "If this keeps going," Mr. Pinto replies, "at some point in the chain of events, some business entity is probably going to fail in its mission and the buyers will have their heads handed to them."

In terms of whether requiring endless increases in profitability is realistic, Dr. Lindstrom points out that increasing profitability is necessary whether a practice is part of a private equity situation or not. "The external environment requires this of every practice if it's to remain viable in the current external environment," he says. "Today, bankruptcy and failure can, and do, occur in ophthalmology practices."

## How Far Can This Go?

Mr. Pinto points out that aside from the philosophical and ethical questions about this financial model, there are upcoming economic chal-

lenges that also threaten to undermine its success. Two in particular are worth noting:

- **Rising interest rates.** "The next challenge coming around the corner for private equity firms is that interest rates are rising," he notes. "This is a very interest-rate-sensitive industry. This means that either the private equity firms will have to be more selective about the deals that they do, or doctors will have to accept a lower earnings multiple, because the numbers will be squeezed to death. If you combine that with the trend of generally falling profitability in ophthalmology, caused by fixed and falling fees and now a sharp rise in operating costs, it's going to be a much greater challenge in the next four years than it's been in the past four years. The term in the finance industry is 'margin impairment.' The past four years could be characterized as a kind of 'golden age' for private equity, the pandemic notwithstanding."

Will that cause a big drop off in new offers? "I wouldn't characterize it as an upcoming massive drop off, but I think there will be a lot

more selectivity," says Mr. Pinto. "And, the consequence of private equity firms being more selective and paying less in the years ahead is that they'll have a smaller number of doctors willing to go forward with the transaction."

- **Receding financial goals.** "A big private equity motivator for the doctor close to retirement," says Mr. Pinto, "is, 'Wouldn't it be great to get those last few million dollars out of my practice and into my retirement account? Then I'll be financially independent.' Unfortunately, right now we're looking down the barrel of a reset in equity markets and a drop in stock portfolio values. If and when that occurs, the average doctor will have a larger gap to close before they're financially independent. So, they're going to need a bigger check from a private equity transaction in the future than they require today."

So: How is this likely to end? "In the idealized world of those who are consolidating practices today, 15 years from now you may have three, four or five private or publicly traded ophthalmology megafirms,

doctors who are unhappy. An unhappy partnership isn't terribly common, but it does happen. Most private equity folks are well-educated, thoughtful, well-informed business people. But I just finished a 100-hour expert-witness assignment, working through a dispute between a doctor and his management company. These things can ricochet off in very unpleasant ways."

John D. Sheppard, MD, MMSc, FACS president of Virginia Eye Consultants and medical director of EyeCare Partners MidAtlantic Ophthalmology, says the focus should be on productivity, not profitability. "The more productive you are and the better job you do, the more money you'll make," he notes. "The only way we've made serious cuts in overhead is by reducing the number of administrators as a result of consolidating management. That's part of the reason we entered into this new world. We haven't made any compromises in our ability to deliver clinical care."

Asked about media reports of private equity running practices into the ground for profit, Dr. Sheppard says that's not going to happen in their organization. "Our mergers were carefully vetted," he says. "Everybody's anxious to do a good job. However, you have to put in the work [up front]. If you don't research carefully enough

to weed out the bad guys, you could get hurt."

Daniel M. Miller, MD, PhD, vice chair of the medical executive board for EyeCare Partners and former chief medical officer for the Cincinnati Eye Institute, points out that bad choices are made by people in every kind of situation, not just private equity. "I think it's important to remember that there will always be bad apples," he says. "I've seen bad things happen under almost any type of business arrangement you can imagine, so I'm sure such things have happened with some private equity firms. The point is that those are outliers, and all of them will fail to be successful in the long run if they're not providing ethical, high-quality patient care, along with a great culture for their staff and employees."

"The two private equity companies I've been involved with have not in any way been interested in thwarting our ability to provide medical care," he adds. "They're extremely supportive of high-quality and highly ethical care, and they don't have any interest in influencing physician decision-making around great care. Following any other pattern would be really damaging, not only to the culture of the company, but also to the core values of the company."

—CK

with billions of dollars of market capitalization," Mr. Pinto explains. "If a patient dropped into Peoria or Dallas, she might have several major, national eye-care brands to choose from. Of course, there will always be independent practices out there, and some aligned with the health-care systems, in every market."

EyeCare Partners is now the biggest ophthalmology and optometry organization in the United States. Is it possible to carry the increasing profitability model even further? "I'm pretty sure there will eventually be a third bite," says Dr. Sheppard. "To accomplish that, we don't necessarily have to get bigger; just better. And, we may simply become part of a different organization. However, we will be getting bigger, because we're growing through intrinsic improvements in efficiency, hiring new doctors and acquiring new outstanding practices."

## Avoiding the Pitfalls

Surgeons and outside experts say these strategies can help ensure a positive outcome when setting up a private equity deal:

• ***Be clear about where your practice stands and what your future goals are.*** Dr. Miller says friends and colleagues frequently ask about the pros and cons of partnering with private equity. "I tell them that what really matters when making decisions about your business—whether you're a two-person practice or a mega-group like CEI—is: What's your vision for the future of your practice? What are your key objectives? You need to spend a lot of time thinking about this," he notes, "because if you don't, you can get lost about the direction you need to move your company in."

"Deciding whether this is the right option for you comes down to knowing your strengths and weaknesses, and being aware of the opportunities and threats to your business," he continues. "You really need to understand your local market. And then you need to think about the strategic and cultural positioning of your practice, and what your near-term goals for the next five to 10 years are, and what your longer-term goals are for the legacy of your practice."

"Looking carefully at these issues will help illuminate what your best path may be," he continues. "This will lead some practices to want to partner with a larger entity. For others, it may make the most sense to stay independent, or partner with a dominant health system in a closed-off market, or partner with other independent providers in your region. It will vary by practice and market."

• ***Get good counsel before going through the process.*** Mr. Pinto says this is absolutely critical. "You need to know what you're going to be doing," he says. "You need to read the transaction documents carefully. You need to know what that management services agreement is going to bond you to. This is an exercise very few physicians have undertaken before, so it's important to get good counsel to take you through the process."

• ***Make sure you'll be able to maintain your practice culture in the new arrangement.*** "It's key to spend a lot of time thinking about the culture and ethics of your practice, and the quality of care you provide, and make sure that whatever entity you



partner with shares those cultural values, ethics and quality goals,” says Dr. Miller. “You can’t walk that part back. Financial and operational things can be fixed, but those other things have to be aligned for a partnership to work.”

• **Make sure the younger doctors in your practice will benefit from the merger.** Many private equity transactions clearly stand to benefit doctors in the practice who are close to retirement; it’s not always clear that younger doctors have as much reason to cheer about the change. However, some doctors going through the process say this can be offset by structuring the deal appropriately.

“I think it’s really critical that young ophthalmologists get to have an ownership stake in the company, and that there’s a long-term financial interest in being an equity stakeholder in the company,” says Dr. Miller. “Our company is experiencing tremendous growth, and we expect that to continue over the next 20 years. So young ophthalmologists that find the right cultural fit are likely to enjoy significant financial growth over the course of their career.”

Dr. Miller says their private equity setup hasn’t deterred the younger doctors. “We’ve been able to continue to recruit outstanding, top-tier ophthalmologists from the best residency and fellowship training programs in the country,” he says. “The reason is that we have a great culture; we have great staff facilities and resources. The younger physicians in our group want to be involved in the full gamut of ophthalmology care.

“On the financial side, I do think there’s increased competition for recruiting younger doctors,” he continues. “One factor that makes a difference is the kind of equity opportunity you can offer younger doctors. For a young doctor who is just joining our company and establishing an equity position, this can be pretty significant.

“We set [our private equity deal] up so that everyone gets the same benefits,” Dr. Sheppard says. “It’s good for both the younger doctors and the older ones. In the first merger there were half a dozen junior doctors in our practice and more than 40 in our sister practice. Nobody left because of the merger. We had 100-percent retention.”

• **Be willing to give up practice control, and make sure you’ll reach your financial goals.** Mr. Pinto says his advice for those thinking of selling their practice has been the same since the 1990s when consolidation began to pick up steam. “You should only consider selling your practice, whether it’s to a larger local practice or a hospital system or a private equity firm, if two conditions are met,” he says. “First, the net proceeds after taxes and withholds should take you past your personal financial finish line. Second, make sure that you’re very clear that you will no longer be in control of the practice.

“When we start talking to a new client about what should they do in respect to a new private equity deal they’ve been offered, it’s not a discussion about Wall Street and finance,” he continues. “It’s about those two areas: being able to give up control, and where are you in terms of your personal finances. We’ve had a number of clients come to us saying they’d hate to yield control to another party. They’re not good candidates for a private equity deal. Others will still be years and years away from their financial finish line, even after they get paid for the private equity deal. They’re not good candidates either.

“Ironically, we also get calls from doctors who are many times past their financial finish line,” he says. “They need \$500,000 to retire comfortably, and they’ve got \$15 million in the bank. Those doctors are also probably not good candidates for a private equity deal, because it’s not going to change the way they live. They’re just going to give up control

of their practice without getting any counter-balancing change in their financial security or lifestyle.”

• **Don’t assume stock options will be valuable in the future.** “We tell our clients that when they’re negotiating their private equity transactions and calculating what they’re going to receive, they should completely discount the stock they reinvest in,” says Mr. Pinto. “Often, 20 to 25 percent of the proceeds of the original sale will be pushed back across the table to the private equity firm so the doctor can be an investor in the conglomeration of practices. But we always tell clients to assume that they won’t realize any value from that in the future. The reality is, it’s impossible to know what value it will have down the line.”

Dr. Sheppard offers three general pieces of advice for doctors considering going down the private equity path. “First, hire a salaried—not percentage-based—professional to guide you through the process,” he says. “Second, find ways to ethically maximize your EBITDA (earnings before interest, taxes, depreciation and amortization). Third, make sure you have a succession plan in place.”

## The Road Ahead

So: How widespread in ophthalmology is this phenomenon likely to become? Mr. Pinto doesn’t expect to see many more private equity firms appearing in the eye-care space in the next few years. “The 40-plus firms that are out there today are going to slowly consolidate as part of the so-called ‘second bite of the apple’ transactions,” he says. “It’s still too early to know how all of this will settle out. But my prediction is that no more than 15 or 20 percent of the 7,000 or so private ophthalmology practices are going to join the private equity enterprise model.

“Private equity has been a wonderful development for doctors at a certain stage of their career,” he

*(Continued on p. 68)*

# RETINA SPECIALIST



## KEEP UP WITH CUTTING-EDGE SCIENCE IN RETINA

*Retina Specialist* focuses on the latest advances in the diagnosis, medical management and surgical treatment of diseases of the retina, along with practical, real-world advice from leading clinicians and other experts on managing the successful retina practice.

### Watch for issues in:

- JANUARY/FEBRUARY
- MARCH/APRIL
- MAY/JUNE
- JULY/AUGUST
- SEPTEMBER/OCTOBER
- NOVEMBER/DECEMBER

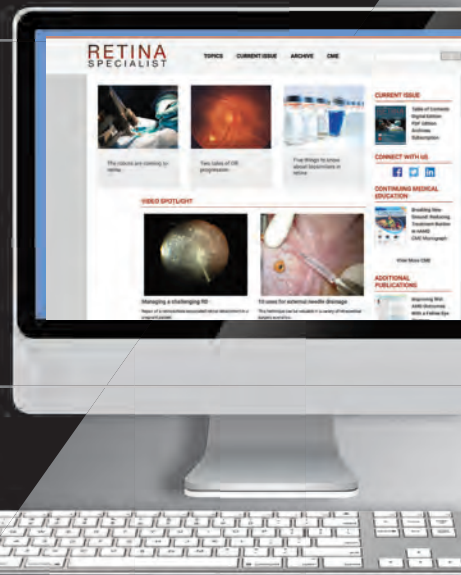### WEBSITE

[RETINASPECIALIST.COM](http://RETINASPECIALIST.COM)



### RETINA ONLINE

Each month, Medical Editor Philip Rosenfeld, MD, PhD, and our editors provide you with this timely and easily accessible report to keep you up to date on important information affecting the care of patients with vitreoretinal disease.



### FOR INQUIRIES CONTACT

[RETINASPECIALIST@JOBSON.COM](mailto:RETINASPECIALIST@JOBSON.COM)

### ADVERTISING OPPORTUNITIES

MICHAEL HOSTER • PUBLISHER • 610-492-1028 • [MHOSTER@JOBSON.COM](mailto:MHOSTER@JOBSON.COM)

MICHELE BARRETT • 215-519-1414 • [MBARRETT@JOBSON.COM](mailto:MBARRETT@JOBSON.COM)

JONATHAN DARDINE • 610-492-1030 • [JDARDINE@JOBSON.COM](mailto:JDARDINE@JOBSON.COM)

### FOLLOW US

@RetSpecMag

RetinaSpecialistMag



EDITED BY CARL REGILLO, MD,  
AND YOSHIHIRO YONEKAWA, MD

## RETINAL INSIDER

# The Gut Microbiome's Impact on the Retina

*The gut microbiome is being shown to have effects on many disease states, and retinal disease is no exception.*

JASON XIAO, JASON ZHANG, SHIVAM AMIN, MD,  
UROOBA NADEEM, MD, HUGO BARBA AND DIMITRA  
SKONDRA, MD, PHD  
CHICAGO

The gut microbiome consists of a wide collection of archaea, eukaryotes, viruses and bacteria that play significant roles in human health and disease. Housed in the gastrointestinal tract and shaped by environmental/lifestyle factors, including geography, diet and medications, these commensal microorganisms are directly involved in numerous physiological functions, including nutrition, host immunity, drug metabolism and endocrine signaling.<sup>1</sup> Yet, despite the microbiome's overwhelming presence, our understanding of its dynamic interactions—particularly in diseased states—has only recently begun to grow.

The acceleration of next-generation analysis techniques has revealed direct connections between the microbiome and various disease pathologies. Improper microbiota composition and function (gut dysbiosis) has been linked with neurological, cardiovascular, respiratory and metabolic diseases, among others.<sup>2-5</sup> These axes extend to the eye as well. Evidence has connected the microbiome with various retinal dis-

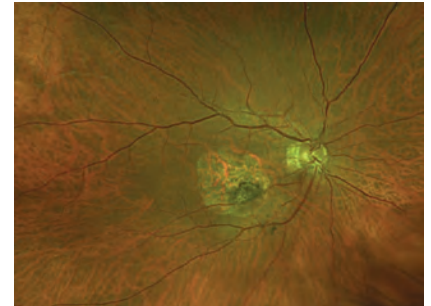
eases, including age-related macular degeneration, diabetic retinopathy, retinopathy of prematurity, retinal artery occlusion and retinal dystrophies.<sup>6-11</sup>

In this review, we'll examine the current knowledge surrounding the gut microbiota's role in these retinal diseases in order to foster a better understanding of the various diseases' mechanisms, and to potentially develop more targeted preventive and therapeutic interventions.

## Age-Related Macular Degeneration

As is commonly known, age-related macular degeneration has both exudative and non-exudative subtypes.<sup>12</sup> Development of AMD depends on a number of risk factors, including age, genetic susceptibility and environmental influences such as diet and smoking. These components subsequently drive AMD pathogenesis through inflammation, oxidative stress and aberrant neovascularization. Although integrating these heterogeneous risk factors and mechanisms remains challenging, recent human and animal studies suggest that the gut microbiome plays a key role in reconciling the impact of these components.

Studies of gut dysbiosis have



**Figure 1. Right fundus with advanced dry AMD. The gut microbiome may play a key role in the impact of diet on AMD.**

revealed significant changes in bacterial composition and diversity between states of health and AMD. Comparing a cohort of human neovascular AMD (nAMD) and control patients, Bern, Switzerland's Martin Zinkernagel, MD, and colleagues identified compositional and functional variations between the groups' intestinal microbiomes.<sup>6</sup> Among the results, AMD patients were found to be enriched in the genus *Oscillibacter*, a microbial population implicated in high fat diets (HFD) and increased gut permeability. Furthermore, AMD patients were found to have an increase in the ratio of Firmicutes to Bacteroidetes—a known hallmark of obesity and a factor associated with exacerbation of choroidal neovascularization.<sup>13,14</sup> In concordance with human studies, increased Firmicutes was also found in mice deficient in complement factor C3, a factor associated with AMD and negative retinal function.<sup>15-17</sup> This was further supported by Changsha, China's Yun Li, MD, and colleagues, who identified changes in the fecal microbiota of CNV mouse models, including altered metabolites in bile acid biosynthesis

This article has no commercial sponsorship.

**Dr. Regillo** is the director of the Retina Service of Wills Eye Hospital, a professor of ophthalmology at Thomas Jefferson University School of Medicine and the principle investigator for numerous major international clinical trials.

**Dr. Yonekawa** is an assistant professor of ophthalmology at Sidney Kimmel Medical College at Thomas Jefferson University. He serves on the Education Committee of the American Society of Retina Specialists and on the Executive Committee for the Vit Buckle Society, where he is also the vice president for academic programming.



and elevations in proinflammatory bacteria.<sup>18</sup>

The distinct microbial profiles identified in preclinical and clinical models of AMD highlight a link between the microbiome and eye health. Through our and others' work, this connection has been further reaffirmed by studies of diet-induced gut dysbiosis. In wild-type mice, Tuft's University's Sheldon Rowan, PhD, and his group found that administering high-glycemic-index diets promoted a pathogenesis similar to non-exudative AMD, including photoreceptor degeneration, sub-RPE membranous debris and lipofuscin accumulation.<sup>19</sup> These effects were arrested or even reversed if mice were switched to lower glycemic diets. Meanwhile, Quebec's Elisabeth MMA Andriessen and co-workers studied the impact of HFD in a mouse model of CNV, demonstrating an increase in CNV growth in HFD subjects compared to their regular-diet counterparts.<sup>14</sup> Importantly, subsequent administration of oral antibiotics resulted in persistent weight gain but slowed CNV progression. With weight gain uncoupled from other factors, this suggested that direct alterations in the gut microbiome, and not obesity, were responsible for the choroidal angiogenesis.

These results closely align with previous analyses of dietary patterns in the Age-Related Eye Disease Studies trial. Trial participants with greater consumption of Western-style diets, including red meat and high-fat dairy products, showed significantly higher odds of AMD progression compared to leaner vegetable-based diets.<sup>20</sup> Subsequently, as a result of the AREDS and AREDS2 trials, a number of anti-oxidants were identified to reduce risk of AMD progression.<sup>21</sup> Although the protective mechanisms of these compounds aren't fully understood, the presence of specific intestinal microbiota are fundamental to the bioavailability of many

of the compounds. Furthermore, the profiled enhancement in gut microbiota alpha diversity (species richness and evenness) following AREDS supplementation suggests an important therapeutic role for the gut microbiome.<sup>8</sup>

The impact of diet-induced gut dysbiosis on AMD extends to the transcriptional level as well. Using high-throughput RNA sequencing, our team profiled the retinal transcriptomes of GF, or germ-free (i.e., lacking a microbiota) mice.<sup>22</sup> Compared to control counterparts, absence of the gut microbiome resulted in significant differentially expressed genes (DEGs) in the retina, including vascular endothelial growth factor, AMP-activated protein kinase (AMPK), and proliferator-activated receptor gamma coactivator 1-alpha (PGC1A)—all of which have been implicated in AMD pathogenesis through aberrant neovascularization and cellular toxicity.<sup>23–25</sup> Furthermore, we've previously shown that HFD consumption alters the retinal transcriptome both in the absence and presence of the microbial organ, with a unique signature profiled in each group. Among the differences include a number of genes associated with AMD pathologies, including those involved in the complement cascade, coagulation cascade and retinal inflammation.<sup>26,27</sup>

Given the role of gut microbiota in regulating innate and adaptive immunity, evidence has emerged linking genetic susceptibility, gut microbiota and inflammatory disease processes.<sup>28,29</sup> In relation to AMD specifically, Bern's Denise Zysset-Burri, PhD, and colleagues recently showed that the bacteria *Negativicutes* was more abundant in patients with nAMD, and positively correlated with complement gene CFH, an AMD-risk allele.<sup>15</sup> Moreover, AMD patient gut microbiomes showed microbial gene-enrichment in various purine signaling pathways, which have been implicated in several retinal neovascular diseases.<sup>30,31</sup>

Similarly, the Casey Eye Institute's Phoebe Lin, MD, PhD, and co-authors showed that a calculated AMD risk score correlated with ARMS2 and CFH risk alleles, as well as inversely correlated with gut microbiome alpha diversity in AMD patients.<sup>32</sup> While no causal relationship has yet been established, this finding raises interesting possibilities between gut dysbiosis, complement dysregulation and AMD.

Beyond the complement cascade, dysregulation of several immune cell types, including microglia, macrophages and T-cells, has been identified in individuals with AMD.<sup>33–35</sup> Similarly, it's well-established that the gut microbiome influences both local and systemic immunity, extending to peripheral systems.<sup>36–38</sup> In part, it's thought that metabolite signaling from gut microbiota alters immune homeostasis. GF mouse experiments demonstrate that absence of microbiota leads to global deficits in microglial composition and maturation, which can be partially restored with introduction of gut microbiota and their metabolic products such as short-chain fatty acids (SCFAs).<sup>14</sup> Additional mouse studies have shown that gut dysbiosis alters permeability of the intestinal epithelium, resulting in chronic, system inflammation with associated elevation of IL-6, TNF- $\alpha$  and IL-1 $\beta$ .<sup>39</sup>

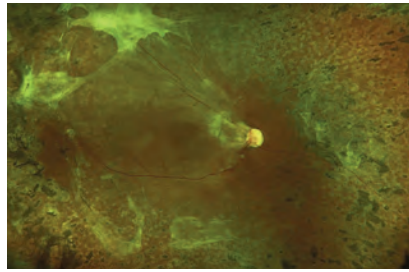
These changes in gut microbiota have demonstrated far-reaching effects in retinal tissue. Yokohama, Japan's Yuji Morita and colleagues demonstrated that administering the probiotic *Lactobacillus paracasei* KW3110 in aging mice reduced proinflammatory cytokine production in macrophages and age-related loss of retinal cells.<sup>40</sup> They then showed that *L. paracasei* KW3110 reduced photoreceptor degeneration in a mouse model of light-induced retinopathy and was associated with an increased shift in M2-like macrophages, which is considered an anti-inflammatory phenotype. These

studies demonstrate that alterations in gut microbiota can affect systemic immunity and inflammation. Collectively, these studies of the gut microbiome highlight the exciting yet complex relationship between diet, gut dysbiosis and AMD pathogenesis, necessitating further studies.

## Diabetic Retinopathy

Approximately one-third of individuals diagnosed with diabetic retinopathy have vision-threatening disease.<sup>41</sup> The number of adults with DR was estimated to be 103.1 million worldwide in 2020, with a projected increase to 160.5 million adults in 2045.<sup>42</sup> As it correlates with diabetes status, risk factors of DR include hyperglycemia, hypertension, smoking and dyslipidemia.<sup>43</sup> The chronic hyperglycemia causes shifts in cellular metabolism and the release of growth factors, resulting in sorbitol accumulation, oxidative stress, activation of protein kinase C, and increased non-enzymatic protein glycation. These pathologic changes impair visual function by means of capillary leakage, occlusion and sequelae of retinal ischemia, including neovascularization and vitreous hemorrhage.<sup>44</sup>

Given the metabolic and inflammatory nature of diabetes, many associations exist between the gut microbiome and the prevalence and progression of type 2 diabetes mellitus (T2DM).<sup>45,46</sup> Interestingly, several studies have identified independent changes in the gut microbiome between individuals with diabetes and those with concurrent DR. For instance, one study found that while both groups have different gut microbial compositions relative to healthy controls, such as increased levels of *Bifidobacterium* and *Lactobacillus*, the DR group had lower levels of *Pasteurellaceae* and *Firmicutes* compared to the non-DR group.<sup>47</sup> Similarly, Hyderabad, India's Taraprasad Das, MD, and his group reported that individuals with T2DM compared to those



**Figure 2. Patient with a quiescent PDR. Given the metabolic nature of diabetes, researchers say it has many associations with the gut microbiome.**

with T2DM and DR had significant differences in gut microbiome composition at the genera level.<sup>48</sup> They further noted the DR group had decreased *Lactobacillus* and *Actinobacteria*, and increased *Shigella*, which together suggest a potential decline in anti-inflammatory and probiotic bacteria.

There are several proposed mechanisms for how gut microbiota may impact DR pathophysiology. In addition to changes that occur locally in the gastrointestinal tract, alterations in gut microbiota may influence host immunity and metabolism systemically. For instance, elevation of bacterial products, such as lipopolysaccharide (LPS), has been shown to exacerbate retinal endothelial injury in mice with pre-existing risk factors such as hyperglycemia.<sup>49</sup> Furthermore, differential levels of metabolites processed by gut microbiota, including SCFAs, bile acids and lipids have been observed in patients with T2DM compared to healthy controls, which may also contribute to DR pathobiology.<sup>50</sup> One study in patients with diabetes showed that those with concurrent PDR had different gut bacteria compositions with significant differences in fecal metabolites, specifically in pathways of arachidonic acid and microbial metabolism.<sup>51</sup>

In diabetic db/db mice, intermittent fasting was shown to alter gut microbiota composition, increasing *Firmicutes* and decreasing *Bacteroidetes* and *Verrucomicrobia*, with

an associated reduction in clinical markers of DR such as acellular capillaries and leukocyte infiltration.<sup>52</sup> Elevation of the bile acid metabolite tauroursodeoxycholate (TUDCA), a neuroprotective molecule, was observed, which was consistent with *Firmicutes*' ability to modulate bile acid metabolism. Another microbial metabolite associated with DR in patients is trimethylamine-N-oxide, which is derived from dietary choline.<sup>53</sup>

Preclinical experiments have begun investigating gut microbiota modulation to target DR. Administering recombinant *Lactobacillus paracasei* in mice with DR has shown to reduce retinal capillary cell loss, inflammatory cytokine production and gliosis.<sup>54,55</sup> While no gut microbiome-centered interventions have been tested specifically for DR in humans, promising results are seen in clinical trials involving diet modulation and fecal microbiota transplantation, resulting in controlled blood sugar and insulin production, thereby potentially affecting DR development.<sup>56,57</sup>

In conclusion, visual impairment caused by DR is closely tied with diabetes pathophysiology, and together they share associated changes in gut microbiota composition and metabolic pathways, which ultimately can affect systemic metabolism and inflammation. Studies also show distinct microbiota profiles between patients with diabetes alone compared to patients with concurrent DR, which may suggest unique contributions of gut microbiota in DR pathology and require further investigation.

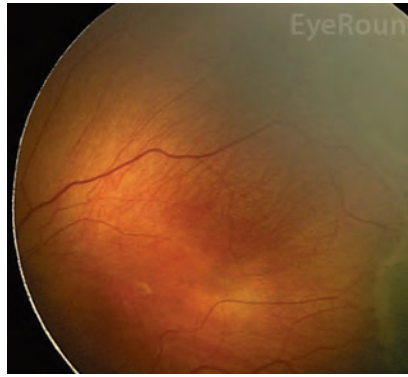## Retinopathy of Prematurity

Classically, the pathogenesis of this disease of premature and low-weight infants<sup>58,59</sup> occurs in two successive phases: an ischemic phase in which normal retinal vasculature fails to develop; followed by a vasoproliferative phase in which abnormal neovascularization occurs.

Various diseases of prematurity, including ROP, have been associated with microbial imbalances. For instance, preterm infants may have less microbiome diversity and potentially more pathogenic strains of bacteria.<sup>60-63</sup> Furthermore, overall gut microbiome composition is heavily influenced by gestational age (GA) at birth, mode of delivery (i.e., Cesarean section or vaginal birth) and infant diet (i.e., breast milk or formula fed), highlighting various stages at which dysbiosis may occur.<sup>64-68</sup>

We recently analyzed fecal samples from preterm infants with type I ROP needing treatment and similarly-matched high-risk preterm infants without ROP. Infants with severe ROP had significant enrichment of the bacteria family *Enterobacteriaceae* at 28 weeks postmenstrual age, which includes pathogens such as *Escherichia coli*, *Salmonella* and *Shigella*.<sup>69</sup> Meanwhile, the microbiota of infants without ROP showed enrichment of metabolic pathways involved in oxidative phosphorylation, amino acid synthesis and degradation, and bacterial metabolites known to be beneficial to human health.<sup>69</sup> In a similar study conducted in Australia, fecal samples were analyzed from preterm infants (born <32 weeks GA and weighing <1,500 g) who received probiotics while hospitalized in the intensive care unit. Upon admission, infants with ROP had a lower diversity of organisms and a greater abundance of *Staphylococcus* species.<sup>70</sup> Though preliminary, the results of these two studies suggest that early gut dysbiosis with overpopulation of pathogenic bacteria and consequential poor development of metabolic pathways may contribute to ROP development in prenatal infants.<sup>7,69,70</sup>

These findings are supported by our knowledge that important risk factors for ROP also influence gut microbiome composition. Maternal age, smoking status, gestational diabetes and hypertension during pregnancy have all been associated with ROP

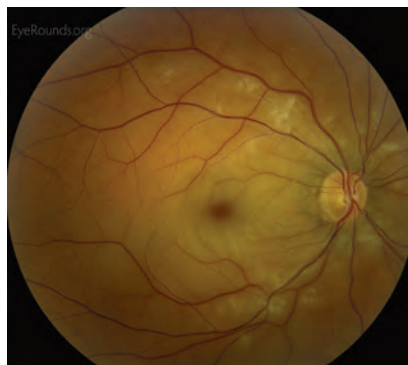

**Figure 4. Stage 3 retinopathy of prematurity. Preliminary studies found gut dysbiosis in infants with ROP.** Image: Mai AP, Scruggs BA, Kemp PS. Retinopathy of prematurity. Accessed April 11, 2022. <https://webeye.ophth.uiowa.edu/eyeforum/cases/286-retinopathy-of-prematurity.htm>

and neonatal gut microbiome alterations.<sup>71</sup> Also, necrotizing enterocolitis and neonatal sepsis are independent risk factors for ROP, and also are associated with changes in the neonatal gut microbiome.<sup>71</sup> At the diet level, human breast milk is known to protect against ROP.<sup>72,73</sup> This may be mediated by increasing IGF-1 levels, which are regulated by the gut microbiome and serve as a protective factor against ROP's development.<sup>69,71,72</sup>

### Central Retinal Artery Occlusion

In non-arteritic retinal artery oc-



**Figure 3. An acute CRAO. Patients with RAO have demonstrated alterations in their gut microbiomes.** Image: Phillips D, Starkweather A. Central retinal artery occlusion. Accessed April 11, 2022. <https://webeye.ophth.uiowa.edu/eyeforum/atlas/pages/CRAO/index.htm>

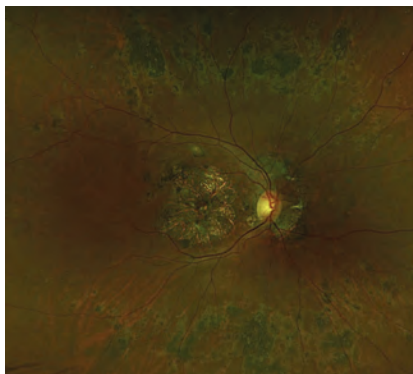
clusion a thromboembolic plaque occludes either the central retinal artery or a branch retinal artery, leading to vision loss from inner retinal ischemia, atrophy and possible neovascularization.<sup>74</sup> Given that RAO occurs in conjunction with systemic atherosclerosis, RAO risk factors are similar and include smoking, diet, exercise, hypertension and hypercholesterol.<sup>75,76</sup> Stroke, cardiovascular disease and atherosclerosis have all been associated with alterations in the gut microbiome.<sup>77,78</sup> Although the exact relationship is unknown, the gut microbiome influences circulating levels of lipids, insulin resistance, adipocyte fat storage and systemic inflammation.<sup>79-83</sup> Furthermore, studies show that bacterial DNA is present within atherosclerotic plaques and that the source may be a dysbiotic gut microbiome.<sup>84,85</sup>

Only one study to date has investigated the relationship between the gut microbiome and RAO development.<sup>86</sup> Comparing the gut metagenomes of patients with non-arteritic RAO and matched healthy controls, patients with RAO had significant alterations in their gut microbiota composition, suggesting a role of gut dysbiosis in RAO pathogenesis. Additionally, levels of trimethylamine-N-oxide (TMAO), a pro-atherogenic, gut-derived metabolite that interferes with cholesterol transport, was increased in patients with RAO.<sup>86-88</sup> Collectively, these findings suggest that an important but unknown relationship could exist between the gut microbiome and the development of RAO and other atherosclerotic diseases.

### Retinal Dystrophies

A limited but emerging body of research has associated gut microbiome composition with retinal dystrophies, particularly retinitis pigmentosa. In a mouse model of RP, researchers noted a pattern of gut dysbiosis correlated with classic markers of RP functional decline. Decreases in visual acuity





**Figure 5. Fundus photo of a patient with a presumed retinal dystrophy with positive USH2A and PEX16 mutations, demonstrating a large central area of atrophy in the macula and chorioretinal lesions. A mouse model of retinal dystrophy showed a pattern of gut dysbiosis.**

and retinal responsiveness to light were accompanied by decreases in microbiome diversity, enrichment in *Bacteroides caecimuris*, and a complete absence of *Rikenella spp.*, *Muribaculaceae spp.* and *Bacilli spp.*<sup>9</sup> Although the significance of these compositional changes has yet to be determined, these shifts implicate a link between RP and dysbiosis.

Previous studies reveal possible explanations for these findings. The well-documented inflammatory nature of RP strongly suggests that concomitant changes between microbial composition and RP progression are mediated partly by an inflammatory response.<sup>89-91</sup> It's been shown that LPS-induced peripheral inflammation exacerbates inflammatory and apoptotic states seen in P23H rats, which is another RP model.<sup>92</sup> This resulted in not only a reduction in cone photoreceptors, but also an increase in microglial activation and gliosis. Related to this, human patients with intestinal barrier dysfunction demonstrated a correlative increase in plasma LPS-positive bacterial extracellular vesicles.<sup>93</sup> This further supports the notion that gut dysbiosis can lead to various systemic inflammatory and pathogenic effects and may modulate phenotypical severity of retinal dystrophy.

A recent study shed further light on the purported mechanistic relationship between gut dysbiosis and RP-induced degeneration. RP mice fed a HFD for two to three weeks had accelerated pathologic retinal degeneration as measured by retinal responsiveness, photoreceptor degeneration and second-order neuron connectivity.<sup>94</sup> These changes were associated with a similar reduction in gut microbiome diversity, as well as increases in pro-inflammatory bacteria and inflammatory modulators including GSK3 $\beta$ , STAT3 and NF- $\kappa$ B. This degeneration was further exacerbated by increased oxidative stress. Thus, these changes highlight the detrimental impact of a Western HFD in retinal dystrophies and the possible role of gut dysbiosis in this progression.

The idea that diet impacts the modulation and progression of retinal diseases such as RP is not new. A previous study showed that RP patients with high omega-3 intake ( $\geq 0.20$  g/day) had significantly slower rates of decline in distance and retinal visual acuities compared to control counterparts.<sup>95</sup> Additionally, ketogenic diets were shown to promote neuroprotection and enhanced visual function in mouse models of RP.<sup>96</sup> Collectively, these findings, alongside previous literature, support the need to incorporate diet awareness into patient education and disease management. However, further research is needed to distill the precise mechanistic role of the microbiome in retinal dystrophies.

In conclusion, over the past several decades, there's been an increased interest in how our microbial organ contributes to health and disease. Indeed, gut dysbiosis has been strongly associated with a host of local gastrointestinal and distant organ system issues, including cardiovascular, pulmonary and central nervous systems issues. Recent studies have been developing the notion of a gut microbiome-retina axis, in which the gut microbiome could play a fundamental role in retinal disease.

In this review, we discussed how the gut microbiome is associated with AMD, RAO, ROP, DR and retinal dystrophies, as well as how dysbiosis may contribute to their pathogenesis. While the exact mechanisms aren't fully understood, the impact of the gut microbiome in altering systemic inflammation, host immunity and metabolic signaling is significant, and may well directly contribute to ocular health and disease. Further studies on the gut microbiome-retina axis may not only improve our understanding of retinal diseases, but also help identify new screening tools and therapeutics that will advance clinical care. ◀

*(Ed. note: The list of citations is available with the online version at [reviewofophthalmology.com](http://reviewofophthalmology.com).)*

*Corresponding author:*

Dimitra Skondra, MD, PhD

Email: [ds Kondra@bsd.uchicago.edu](mailto:ds Kondra@bsd.uchicago.edu)

5841 S. Maryland Avenue, S426m  
MC2114, Chicago, IL 60637  
Office: 773-702-3937  
Fax: 773-702-0830

#### ABOUT THE AUTHORS



**Mr. Xiao** is a medical student at the University of Chicago Pritzker School of Medicine. **Mr. Zhang** is a second-year medical student at the University of Chicago Pritzker School of Medicine. Mr. Xiao and Mr. Zhang contributed equally as first authors.



**Dr. Amin** is a second year (PGY-3) ophthalmology resident at the University of Chicago Medical Center.



**Dr. Nadeem** is a fellow in the Department of Pathology at the University of Chicago.



**Mr. Barba** is a research assistant at the department of ophthalmology of The University of Chicago and a graduate student in the Physical Science Division of The University of Chicago.



**Dr. Skondra** is an associate professor of ophthalmology and visual science, and director of the J. Terry Ernest Ocular Imaging Center at the University of Chicago Medical Center.



EDITED BY KULDEV SINGH, MD, MPH,  
AND PETER A. NETLAND, MD, PHD

## GLAUCOMA MANAGEMENT

# Prostaglandins and IOP: What's Really Going On?

*Evidence suggests that these drugs cause a long-term IOP reduction in some patients. Here's the latest.*

**DOUGLAS RHEE, MD**  
CLEVELAND

**P**rostaglandin analogues are the first-line choice for addressing elevated intraocular pressure in a glaucoma patient or suspect (provided that there are no contraindications or preexisting allergies to any of the components). Given the once-a-day dosing, significant IOP reduction and very low systemic side-effect profile that we usually associate with a prostaglandin, this makes sense. However, some patients appear to have a positive response that's maintained for some time after the drug is discontinued—something we don't see with other pressure-lowering medications. Here, I'd like to share some of the evidence that this really does happen in some patients, and offer some possible explanations for it.

### Is This Phenomenon Real?

Many doctors find it hard to accept the idea that a medication might have an effect even after it's discontinued. I'm sure that's true in part because it doesn't happen in every patient. Furthermore, the way data from some clinical trials is reported may obscure the phenomenon, because outcomes from all patients are averaged together. However, there is data that supports the existence of

this phenomenon—and many physicians managing glaucoma (including me) have also seen it first-hand.

Consider the data from one Allergan-sponsored study, headed by Randy Craven, MD.<sup>1</sup> This Phase I/II, prospective, 24-month, dose-ranging, paired-eye controlled clinical trial evaluated the efficacy and safety of the bimatoprost SR sustained-release implant (Durysta, Allergan) over a 24-month period, compared to topical bimatoprost 0.03% applied daily in the fellow eye. An unexpected finding was that some patients showed a sustained IOP reduction in the trial eye, long after the bimatoprost implant had dissolved. At one year, 40 percent of eyes still had an IOP significantly lower than baseline; at two years, 28 percent still exhibited this phenomenon. (The implant typically dissolves in three to four months.)

I personally saw this happen a couple of years ago when I treated a patient I'd diagnosed with primary open-angle glaucoma. His pre-treatment pressure was 24 mmHg; I was able to get his pressure down to 14 mmHg using topical medications, including bimatoprost, without needing any surgery. Several years later, we enrolled that patient in a clinical trial and washed him out. To our surprise, he failed to meet the entry criteria for the trial because his

pressure only went up to 19 mmHg after the washout—not back to his original pressure of 24 mmHg. We were left scratching our heads and wondering what happened.

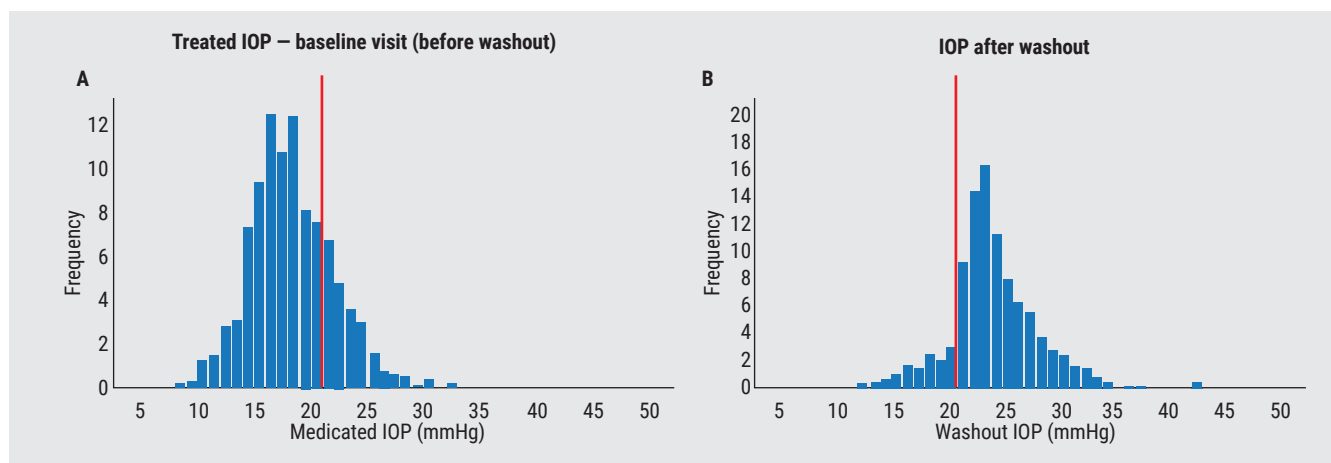
Others have observed this as well. A study headed by Henri Jampel, MD, looked at IOP in 1,400 eyes in the HORIZON and COMPASS trials.<sup>2</sup> These patients had been managing their IOP with up to four medications prior to the trials; even before washout, a fair number were still above 21 mmHg. But after the washout for these studies, many of them remained below 21 mmHg. (*See graph, p. 66.*)

An even more scientific study of this phenomenon is a prospective, randomized, controlled study conducted by Cynthia Hutnik, MD, and her group in Toronto.<sup>3</sup> They took a group of patients that were using PGA monotherapy—a single prostaglandin. These patients were confirmed to have high IOPs at baseline—between 21 and 38 mmHg. They'd been on topical PGA therapy for more than six months. The patients were randomized into two groups: One group was washed out for up to six weeks, while the control group was not.

The control group's mean IOP didn't change at all, and as expected, the washed-out group's mean IOP went up after the prostaglandin monotherapy was stopped. However, the mean doesn't tell the whole story; if you look at the scatter-plot (*see graph, p. 67*), a large number of patients actually kept their IOP below 21 after washout. So, it seems clear that the treatment caused some sort of permanent—or at least semi-permanent—change. We know it lasted at least longer than six weeks. And, this was seen after using topical

This article has no commercial sponsorship.

Dr. Singh is a professor of ophthalmology and chief of the Glaucoma Division at Stanford University School of Medicine. Dr. Netland is Vernah Scott Moyston Professor and Chair at the University of Virginia in Charlottesville.



**A 2020 study by Johnson and Jampel<sup>2</sup> looked at 1,400 eyes that were supposed to enroll in the HORIZON and COMPASS studies (for the Hydrus and CyPass devices). Patients were on 0 to 4 medications before washout. After washout, many eyes remained below 21 mmHg.**

prostaglandin drops, not a sustained-release implant.

### Mechanisms We Know About

All of this raises the question: What exactly are prostaglandins doing that might account for this? One mechanism has been well-established. Work from multiple studies, nicely summarized in a review article from Duke's Daniel Stamer, PhD, and colleagues<sup>4</sup> that includes some work done by our group, has shown that prostaglandins change the ratio of matrix metalloproteinases (MMPs) to tissue inhibitors of matrix metalloproteinases (TIMPs) in the trabecular meshwork and ciliary body, as well as in scleral fibroblasts.

MMPs are enzymes that break down extracellular matrix, thus allowing enhanced aqueous outflow. TIMPs are kinetic inhibitors of MMPs; they block the active sites on the relevant molecules and thus prevent them from downgrading the matrix. So, the extent of extracellular matrix degradation—and increased outflow—is determined by the ratio of MMPs to TIMPs. (In fact, an imbalance in the MMP/TIMP ratio may be involved in the elevated IOP often associated with glaucoma.) By changing that ratio in favor of MMPs, prostaglandins allow more breakdown of the matrix and greater outflow, thus lowering IOP.

Normally, the ratio of MMPs to

TIMPs causes some outflow through the trabecular meshwork. But what some of our group's work has shown is that although prostaglandins alter the amount of extracellular matrix breakdown in both the trabecular meshwork and the ciliary body, the amount of change is greater in the ciliary body.<sup>5,6</sup> Because prostaglandins seem to affect the ciliary body more than the trabecular meshwork, the ciliary body becomes more permeable, and the amount of outflow through the ciliary body ends up becoming greater than the outflow through the trabecular meshwork.

All these assertions are well-established by about 35 years of research.

Using a sustained-release device to dispense bimatoprost adds some complexities to this equation. First, it's been demonstrated that when the bimatoprost SR implant is in place, it achieves high target tissue concentrations.<sup>7</sup> Our group and others have shown that the effect of bimatoprost is dose-dependent.<sup>5,6,8,9</sup> In essence, the more prostaglandin you give, the more effect on the MMPs you get. Another change when using sustained release is that the patient doesn't get the pulsed dosing provided by topical drops; instead the patient gets continuous dosing. That may confer some advantage and/or an additional mechanism of action.

It's reasonable that increased porosity of the matrix tissue could

remain after the change in the ratio of MMPs to TIMPs has returned to baseline. Yes, we're talking about living tissue that changes and may regenerate, but that regeneration could take some time to occur.

### What Else Might Be Going On?

Despite these advances in our understanding of prostaglandins, there's plenty more that remains to be discovered. Questions include: Why is this effect more noticeable with the bimatoprost implant than with topical prostaglandin drops? And, why is this lingering effect only seen in some patients, not all?

Some answers to these questions have been suggested by Dr. Stamer in an abstract from the 2021 Association for Research in Vision and Ophthalmology meeting.<sup>10</sup> (We participated in some of this work, but Dr. Stamer was the primary investigator. In the interest of disclosure, Dr. Stamer has received research funding from Allergan.) His work showed that:

- Bimatoprost and bimatoprost free acid (BFA)—the latter being the metabolized version of bimatoprost that impacts tissues inside the eye when only topical drops are used—have different effects on MMP gene expression in cells cultured from human outflow tissues (i.e., trabecular meshwork, ciliary body and scleral cells). Levels of bimatoprost seen



with an implant caused a dramatic upregulation of MMP-1 in trabecular meshwork cells and ciliary cells, compared to the impact of the levels of BFA seen with topical drops.

- Bimatoprost and BFA had different effects on MMP gene expression. The implant's high levels of bimatoprost altered the expression of 11 partially overlapping genes in trabecular meshwork and ciliary muscle cells, including a dramatic upregulation in MMP-1 in trabecular meshwork cells. Typical levels of BFA seen with the use of topical drops only significantly altered the expression of two genes.

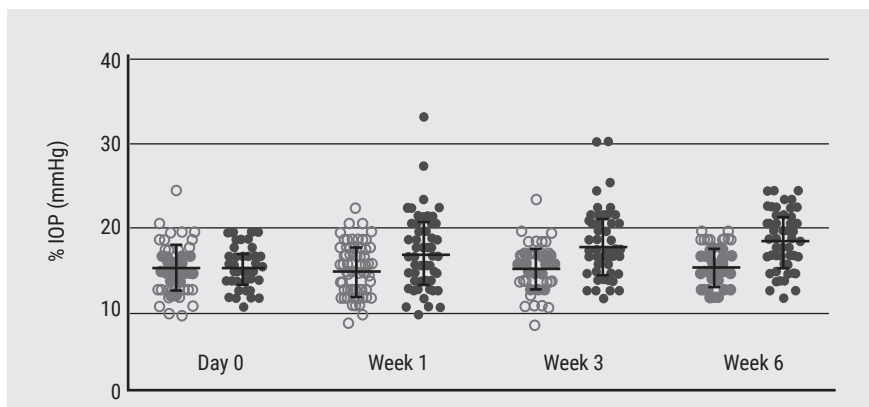
- There were noticeable differences in the response of different cell strains from different individuals. This may partly explain the differences in individual long-term responses to prostaglandins—i.e., why some people get the sustained effect and others don't.

- A key difference was seen in the MMP-1 expression changes found in glaucomatous cells vs. normal cells. Implant levels of bimatoprost didn't affect most genes differently in glaucomatous vs. normal cells, but the expression of MMP-1 and MMP-10 increased dramatically in glaucomatous cells compared to normal cells.

## The Lymphatic Factor

There's another possible explanation for the IOP-lowering effect of prostaglandins, which we're now investigating. Some time ago, I attended a presentation given by Elke Lütjen-Drecoll, MD, at the annual ARVO meeting.<sup>11</sup> She'd given topical bimatoprost to monkeys for one year. On histology, she observed spaces in the ciliary muscle tissue, particularly surrounding large blood vessels. When she went to higher magnification using electron microscopy, she found that these spaces were long, straight running tubes, incompletely lined with endothelial-like cells, making them likely to persist.

I remember her asking the audience—a group of established



**Another 2020 study<sup>3</sup> looked at patients who had been on PGA monotherapy for more than six months. Before treatment, IOPs ranged from 21 to 38 mmHg. After washout, mean IOP for these eyes did go up, but the majority continued to have an IOP below 21 mmHg.**

trabecular meshwork and outflow molecular biologists—what they thought about this. There was dead silence in the room. I was stunned that these experts didn't know what to make of this, and her observation stuck with me.

What she observed sounded to me very much like lymphatics. While this isn't widely known, at least two papers have shown the presence of lymphatics in ciliary body tissue.<sup>12,13</sup> Prior to 2000, it wasn't known that lymphatics existed in the eye, so these papers broke new ground.

In any case, the possibility that such a phenomenon would be connected to improved aqueous outflow isn't hard to imagine. Thus, our group's current hypothesis is that the bimatoprost free acid induces lymphangiogenesis, or something akin to it, creating the endothelial-lined passages observed by Dr. Lütjen-Drecoll. Furthermore, we suspect that PGAs induce lymphatic vessel formation, as opposed to simply increasing flow through existing lymphatics. (Of course, if true, this would be in addition to factors such as the altered ratio of MMPs and TIMPs, and the gene expression uncovered in Dr. Stamer's work.)

Our research in this area is still in its early stages. We're looking for protein markers associated with lymphangiogenesis following the extended use of prostaglandins, and

so far, in a very small sample of two eyes, we have indeed found them. Our preliminary data also suggests that there may be a dose-response effect for some of these proteins. In addition, we're dosing mice to see if we can identify a sub-population that exhibits this prolonged effect. If histological findings confirm what we've seen in human cells, that would convincingly support the lymphatic hypothesis.

Again, this work is in its early stages, so it's impossible to predict what the ultimate outcome of the study will be.

## A Work in Progress

So: What do we know so far?

- After the use of prostaglandins, prolonged IOP reduction is seen in some patients, even after washout.

- PGAs cause a dose-dependent response that induces a change in the ratio of MMPs and TIMPs in trabecular meshwork tissue, ciliary body smooth muscle cells and scleral fibroblasts, favoring extracellular matrix turnover. This leads to enhanced uveoscleral and conventional outflow (favoring the uveoscleral pathway).

- Prostaglandins' effect on gene expression of MMPs is variable in different individuals. This may explain the long-term IOP-lowering effect seen in some patients but not others. Expression of MMP-1 may be responsible.

• Although this remains unproven at this point, we believe that bimatoprost induces lymphangiogenesis in some patients, contributing to the persistent IOP-lowering effect seen in those individuals.

Now that it's clear that some patients will experience an ongoing pressure reduction after cessation of a prostaglandin, an obvious unmet need is to be able to identify which patients will have this sustained response. In the meantime, as clinicians, we certainly don't want to tell patients not to take their drops because there's a chance they might continue to work.

I believe it's fair to say that this ongoing work reinforces our belief that prostaglandin analogues are an excellent first-line topical agent (provided that there are no contraindications or preexisting allergies to any of the components), with the potential for residual effect. That effect merits further study, especially

with regard to the sustained-release bimatoprost implant. ◀

1. Craven ER, Walters T, Christie WC, et al. 24-month Phase I/II clinical trial of bimatoprost sustained-release implant (bimatoprost SR) in glaucoma patients. *Drugs* 2020;80:2:167-179.
2. Johnson TV, Jampel H. Intraocular pressure following prerenaltonization glaucoma medication washout in the HORIZON and COMPASS trials. *Am J Ophthalmol*. 2020;216:110-120
3. Lim CW, Diaconita V, Liu E, et al. Effect of 6-week washout period on intraocular pressure following chronic prostaglandin analogue treatment: a randomized controlled trial. *Can J Ophthalmol* 2020;55:2:143-151.
4. Weinreb RN, Robinson MR, Dibas M, Stamer WD. Matrix metalloproteinases and glaucoma treatment. *J Ocul Pharmacol Ther* 2020;36:4:208-228.
5. Oh DJ, Martin JL, Williams AJ, et al. Analysis of expression of matrix metalloproteinases and tissue inhibitors of metalloproteinases in human ciliary body after latanoprost. *Invest Ophthalmol Vis Sci* 2006;47:3:953-63.
6. Oh DJ, Martin JL, Williams AJ, et al. Effect of latanoprost on the expression of matrix metalloproteinases and their tissue inhibitors in human trabecular meshwork cells. *Invest Ophthalmol Vis Sci* 2006;47:9:3887-95.
7. Seal JR, Robinson MR, Burke J, et al. Intracameral sustained-release bimatoprost implant delivers bimatoprost to target tissues with reduced drug exposure to off-target tissues. *J Ocular Pharm Ther* 2019;35:1:50-57.
8. Weinreb RN, Lindsey JD, et al. Prostaglandin FP agonists alter metalloproteinase gene expression in sclera. *Invest Ophthalmol Vis Sci* 2004;45:4368-4377.
9. Yamada H, Yoneda M, Goshio M, et al. Bimatoprost,

latanoprost, and tafluprost induce differential expression of matrix metalloproteinases and tissue inhibitor of metalloproteinases. *BMC Ophthalmology* 2016;16:26.

10. Perkumas K, Rhee DJ, Stamer DW. Differential effects of bimatoprost vs. bimatoprost free acid on outflow cell MMPs. *Invest Ophthalmol Vis Sci* 2021;62:551.
11. Richter M, Krauss AH, Woodward DF, Lütjén-Drecoll E. Morphological changes in the anterior eye segment after long-term treatment with different receptor selective prostaglandin agonists and a prostamide. *Invest Ophthalmol Vis Sci*. 2003;44:10:4419-26.
12. Yucler YH, Johnston meibomian gland, Ly T, et al. Identification of lymphatics in the ciliary body of the human eye: A novel "uveolymphatic" outflow pathway. *Exp Eye Res* 2009;89:5:810-819.
13. Tam AL, Gupta N, Zhang Z, et al. Latanoprost stimulates ocular lymphatic drainage: An in vivo nanotracer study. *Trans Vis Sci Tech* 2013;2:5:3.

**ABOUT THE AUTHOR**

**Dr. Rhee** is a professor of ophthalmology and chair of the Department of Ophthalmology and Visual Sciences at University Hospitals Cleveland Medical Center, director of the Eye Institute at University Hospital and a professor at the Case Western Reserve University School of Medicine. He would like to thank Hyunpil Lee, PhD, Brian Liu, Blake Boehm and Anoushks Gidh, also at CWRU, for their help with the preparation of this work. Dr. Rhee is a consultant for Allergan and Aerie, is a speaker for Bausch + Lomb, and performs data and safety monitoring for Ocular Therapeutix.



*(Continued from p. 58)*

notes. “It’s provided them with the ability to extract as much as twice the value they would have obtained from a doctor-to-doctor or doctor-to-institution succession transaction. But for many others—doctors at earlier stages in their professional life—it’s been quite disconcerting. I’m beginning to pick up a countercurrent, even as private equity percolates along. We’re seeing more doctors who are interested in starting up their own practice, because they decide that a private equity or health-system job is not going to be to their liking. Or, they’ve already been in a private equity context and now want to get out on their own and be private and independent again.”

Mr. Pinto points out that this consolidation has been happening for more than a generation. “Solo practices have aggregated into two-doctor practices; some of those

aggregated into five-doctor practices and some merged into local health-care systems,” he says. “Some practices sold out their single-specialty practice to a multi-specialty clinic. The general trend, for more than a generation, has been toward aggregation into larger and larger operating units. Private equity is a catalyst for more of that, and it will continue to be a catalyst in the years ahead. But it should be seen as a continuation of an old trend—not something that’s new and different. And I believe strongly that in our lifetime there will never be a situation in which traditional, private, independent practice is untenable.”

Dr. Lindstrom notes that private equity isn’t for everyone. “If you’re very happy, very financially successful, somewhat buffered from the most challenging external environment headwind and not planning for growth that would require significant personal or personally guaranteed investment, why make a change of any

kind?” he asks. “Practices with these characteristics are usually smaller and in the exurbs or rural areas.

“On the other hand,” he adds, “if you’re in a more challenging urban environment which requires sophisticated management, and you want to grow meaningfully, a private equity financial partner can be a great partner.” ◀

1. Scheffler RM, Alexander LM, Godwin JR. Soaring private equity investment in the healthcare sector: Consolidation accelerated, competition undermined, and patients at risk. <https://publichealth.berkeley.edu/wp-content/uploads/2021/05/Private-Equity-I-Healthcare-Report-FINAL.pdf>. Accessed April 7, 2022.
2. Kane CK. Policy Research Perspectives. <https://www.ama-assn.org/system/files/2019-07/prp-fewer-owners-benchmark-survey-2018.pdf>. Accessed April 7, 2022.
3. Anderson AM, Marsumoto M, Saul MI, et al. Accuracy of skin cancer diagnosis by physician assistants compared with dermatologists in a large health care system. *JAMA Dermatol* 2018;154:5:569-573.
4. Creadore A, Desai S, Li SJ, et al. Insurance acceptance, appointment wait time, and dermatologist access across practice types in the us. *JAMA Dermatol* 2021;157:2:181-188.
5. Konda S, Francis J, Motaparthy K, et al. Future considerations for clinical dermatology in the setting of 21st century American policy reform: Corporatization and the rise of private equity in dermatology. *J Am Acad Dermatol* 2019;81:1:287-296.e8.

# PRODUCT NEWS

New items on the market to improve clinical care and strengthen your practice.

## ▶ TONOMETERS

### ***IOP Measurement Comes Home***

Icare USA announced FDA 510(k) clearance for its next-generation self-tonometer, the iCare Home2. The company says the tonometer is designed for additional ease of use in measuring patients' real-world intraocular pressure outside of normal clinic hours. A smart-light guide and interactive display screen means most patients can utilize the iCare Home2 on their own, the device's maker adds. iCare Home2's new design enables IOP measurements to be taken while the patient is supine, reclined or sitting, iCare says. For more information, visit [icare-world.com/us/product/icare-home2](http://icare-world.com/us/product/icare-home2).

## ▶ DRY-EYE THERAPY

### ***A New Option for MGD Sufferers***

Physicians now have an additional tool in their in-office dry-eye armamentarium. Alcon's Systane iLux is a meibomian gland dysfunction thermal pulsation system that uses new imaging technology to capture infrared photos and high-definition videos of the meibomian glands. The company says physicians can use the iLux to tailor MGD treatment to individual patients in eight- to 12-minute sessions and customize heat and compression along the treatment zone. Additionally, iLux stores meibomian gland images for disease tracking and comparison over time. The company points out that by enabling patients to see their MGD for themselves in high-definition video, iLux may bolster patient relationships and treatment credibility. For information, visit [alcon.com](http://alcon.com).



## ▶ LENS-BASED SURGERY

### ***The EVO Visian ICL Debuts***

In March, the Staar EVO Visian ICL was granted FDA approval for the correction of myopia and myopia with astigmatism. Staar says the EVO Visian ICL offers a lens-based alternative for the correction/reduction of refractive error in patients who currently use glasses or contact lenses for distance vision correction.

The EVO Visian is implanted in the posterior chamber directly behind the iris and in front of the natural crystalline lens. Due to a new design feature, no peripheral iridotomy is necessary, as was the case with previous lens iterations. The implantable collamer lens has already been

in use outside the United States with good outcomes, the company says. One advantage Staar points out is that the EVO lens doesn't cause dry eye.

The EVO Visian ICL is available for the correction or reduction of myopic astigmatism in patients with spherical equivalents ranging from -3 to -20 D, with astigmatism from 1 D to 4 D at the spectacle plane; with an anterior chamber depth of at least 3 mm when measured from the corneal endothelium to the anterior surface of the crystalline lens; and a stable refractive history (defined as not varying more than 0.5 D for one year prior to implantation). Staar adds that it will soon be training and certifying surgeons for EVO use. For more information, visit [discovericl.com](http://discovericl.com).



### ***New Clareon Line of IOLs Available***

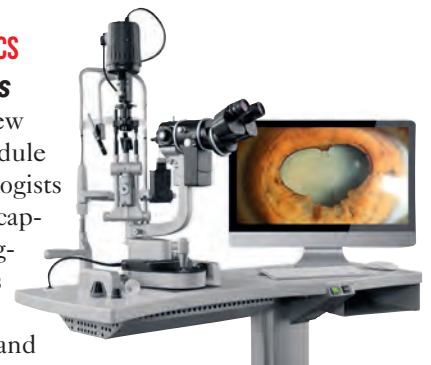
Alcon recently launched its Clareon family of IOLs. The company says that Clareon uses the company's newest, most advanced IOL material, to "deliver consistent visual outcomes and exceptional clarity." Alcon says this clarity is born from a glistening-free IOL material that has very low levels of haze and subsurface nanoglistenings.

Clareon Monofocal, Clareon PanOptix, Clareon PanOptix Toric, Clareon Vivity and Clareon Vivity Toric IOLs are now available in the United States. The lenses are inserted using the reusable Clareon Monarch IV Delivery System. The company says that the Clareon Monofocal is also available in the next-generation automated, single-use delivery system, AutoMe. Read more at [alcon.com/media-release/alcon-strengthens-leadership-iol-innovation-launch-clareon-portfolio-us](http://alcon.com/media-release/alcon-strengthens-leadership-iol-innovation-launch-clareon-portfolio-us).

## ▶ IMAGING & DIAGNOSTICS

### ***Push-button Images***

Haag-Streit says its new slit lamp Imaging Module 910 offers ophthalmologists the ability to quickly capture high-quality images. The company says the module doesn't require any software and





is ready to go by just turning a knob, so it won't slow down exams. Images are captured by pressing the camera trigger button.

The Imaging Module 910 includes a camera sensor and smart features such as a performant auto-exposure mode and automatic aperture control to ensure good illumination in all images. Its image-selection algorithm chooses the best image in order to cut down on time. There are two modes to choose from: standalone and EyeSuite. In the standalone mode, images are stored directly in the practice's EMR system. In the EyeSuite mode, image editing tools and features are available. For information, visit [haag-streit.com](http://haag-streit.com).

► CONTACTS

**A Contact Lens that Fights Allergy**

Johnson & Johnson Vision says its newest contact lens innovation offers patients both vision correction and relief from ocular allergic itch. The FDA-approved Acuvue Theravision contact lenses are the first and only medication-releasing contact lenses for preventing ocular itch due to allergic conjunctivitis, the company says. Each contact lens contains 19 mcg of the antihistamine ketotifen. Johnson & Johnson Vision says these daily disposable contact lenses are suitable for patients with 1 D or less of astigmatism.



In the Phase III clinical studies, Acuvue Theravision demonstrated a clinically and statistically significant reduction in ocular itch beginning at three minutes after insertion. The effect lasted up to 12 hours. The company notes that these lenses aren't suitable for those with red or

irritated eyes. For information, visit [acuvuetheravision.com](http://acuvuetheravision.com).

► SURGICAL TRAINING

**Go VR Before the OR**

Alcon's Fidelis Virtual Reality Ophthalmic Surgical Simulator is a portable VR tool for cataract surgeons-in-training. Its virtual operating room provides haptic feedback to simulate the tactile experience of cataract surgery, the company says. Alcon adds that the real-time simulator can be used from any location around the world, increasing access to surgical training in regions with limited resources. Participants can also join virtual instruction and training sessions.



The portable Fidelis includes a VR headset, two haptic engines, an integrated Centurion footswitch, a realistic OR environment with Alcon equipment, remote connectivity for multiple users and instructors within the same virtual OR, and real-time feedback and performance tracking in order to improve technique.

Alcon says the first Fidelis VR simulators will be used in the company's phaco department program and will enter teaching and residency programs later this year. The Fidelis will also provide VR ocular anatomy and physiology education for other eye-care professionals. For information, visit [AlconExperienceAcademy.com](http://AlconExperienceAcademy.com).

► RETINAL THERAPY

**Xipere Takes a New Approach to Treatment**

Bausch + Lomb and Clearside Biomedical recently announced the

U.S. commercial launch of Xipere, a triamcinolone acetonide injectable suspension that was FDA approved in October 2021 for suprachoroidal use for the treatment of macular edema associated with uveitis. The therapy is administered using Clearside's suprachoroidal space Microinjector. In the clinical studies, the most common ocular side effects were increased intraocular pressure and eye pain, and the most common non-ocular side effect was headache.



Bausch + Lomb explains that the suprachoroidal space expands upon injection, which enables targeted drug delivery to the posterior structures. The company also points out that since the suprachoroidal administration technique differs from traditional intraocular administration, it's currently offering Xipere training. For information, visit [xipere.com](http://xipere.com). For training, visit [xipere.com/hcp/xipere-training](http://xipere.com/hcp/xipere-training).

► PHACO

**Take Control with Quatera 700**

If you've been looking for a different approach to phaco, Zeiss thinks its new phaco machine, the Quatera 700, is worth a look.

The Quatera features a pump called the Quattro, which Zeiss describes as a synchronized fluid exchange system that directly measures and simultaneously controls both infusion and aspiration volumes in real-time. It actively compensates for incision leakage volume. The system also puts the microscope view on the phaco screen, so everyone in the OR gets the same view as the surgeon, which Zeiss says, "allows nurses to anticipate upcoming surgical steps more quickly." And a "power-on-demand" feature activates ultrasound only when necessary, the company adds.

For information, visit [www.zeiss.com/quatera](http://www.zeiss.com/quatera). ◀



EDITED BY RAKHI MELVANI, MD

**WILLS EYE RESIDENT CASE REPORT**

# *An 18-year-old male has to contend with a very high refractive error.*

**COLLIN ROZANSKI, MD, AND DOUGLAS WISNER, MD**  
PHILADELPHIA

## **Presentation and Initial Work-up**

An 18-year-old white male presented with 10 years of high refractive error requiring high correction spectacles. The patient reported that he had previously tried contact lenses and couldn't tolerate them. He reported that he was going to college in the coming months and felt socially isolated because of the strength of his spectacles.

Ocular examination demonstrated best corrected visual acuity with correction of 20/20-2, J3 in his right eye and 20/30, J1 in his left eye. His current spectacle prescription was +9.50 + 1.50 x 088 in the right eye and +10.75 + 0.50 x 085 in the left eye. Pupils were 6 mm in the right and 6.5 mm in the left and equally reactive to light and accommodation. There was no afferent pupillary defect. Intraocular pressures were 10 and 15 mmHg in the right and left eyes, respectively. Confrontation visual fields were full in both eyes. Extraocular motility was full bilaterally.

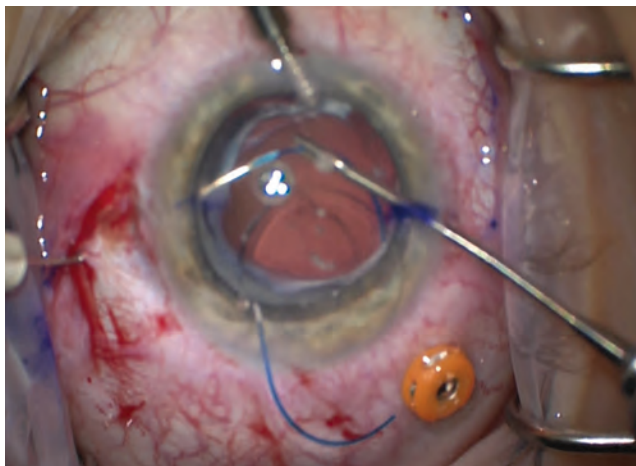
Adnexal, eyelid, conjunctival and corneal exams were unremarkable. The anterior chamber exam in the right eye was notable for vitreous strands to the cornea, but was otherwise quiet. The left eye's anterior chamber was quiet. The lens exam demonstrated aphakia with a capsular opening of 6 mm and a Sommerings ring cataract in the right eye; and aphakia with a capsular opening of 4.5 mm, Elshnig pearls and capsular remnant in the left eye.

## **Medical History**

Past ocular history included idiopathic panuveitis associated with eosinophilia over 10 years ago which necessitated pars plana vitrectomy followed by cataract extraction in both eyes. The patient also had congenital glaucoma in both eyes, more severe in the left eye than the right, requiring a goniotomy in the left eye eight years prior. The idiopathic eosinophilia had been quiet, and the patient had been off of systemic medications for more than five years. Social and family history were both unremarkable. The patient's currently prescribed ocular medications included latanoprost before bedtime and brimonidine twice a day, both in the left eye, which he last used more than three years ago, as the patient had been lost to follow-up.

***What is your diagnosis? What further work-up would you pursue? The diagnosis appears on p. 72.***

## Work-up, Diagnosis and Treatment



**Figure 1. The haptics are docked into thin-walled, 30 gauge needles with microinstruments before being externalized.**

Additional in-office testing was obtained including optical coherence tomography of the macula and optic nerve which were both normal other than mild thinning of the left optic nerve. Humphrey visual field 30-2 stimulus III was normal in both eyes. Surgical preoperative testing demonstrated mild with-the-rule astigmatism in both eyes and mild internal optical aberrations in both eyes. Ancillary laboratory testing, including complete blood count with differential, erythrocyte sedimentation rate, C-reactive protein, angiotensin converting enzyme, perinuclear anti-neutrophil cytoplasmic antibodies (P-ANCA), cytoplasmic anti-neutrophil cytoplasmic antibodies (C-ANCA), rheumatoid factor and QuantiFeron gold tests, were obtained. These tests were all normal.

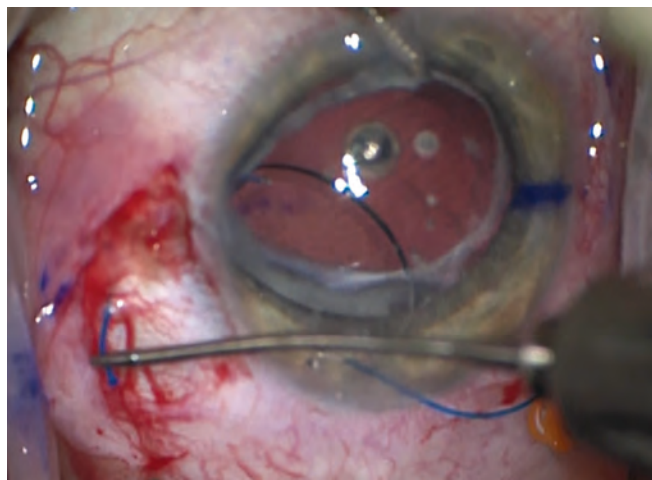
The patient was observed for one year, during which his intraocular pressures were normal off drops and his anterior and posterior chambers remained quiet. Surgical options for this patient included sulcus fixation with posterior optic capture, anterior chamber intraocular

## Discussion

In patients with adequate capsular support the preferred approach is almost always to maintain the capsule and secondarily implant an intraocular lens. For a variety of reasons this support may not exist, at which point the surgeon must consider other appropriate means of IOL fixation. As mentioned, the options available to the anterior segment surgeon include AC IOLs, iris-sutured posterior chamber IOLs and scleral-fixed IOLs. Each of these has different benefits and risks which should be carefully considered prior to surgical intervention.

AC IOL implantation, in comparison to other aphakic

lenses, iris-sutured posterior chamber IOLs and scleral-fixed IOLs. The left eye underwent surgery with an attempt at placement of a sulcus IOL with posterior optic capture, but this was unsuccessful due to the nature of the residual capsule, so the decision was made to proceed with intrascleral haptic fixation using the Yamane technique.<sup>1</sup> The haptics were externalized with thin-walled, 30-gauge TSK needles (*Figure 1*) and cauterized to create anchoring bulbs (*Figure 2*). The left eye remained quiet with normal intraocular pressures for two months at which point the right eye underwent the same procedure. Of note, this patient had thick Tenon's and conjunctiva, so the surgeon created a peritomy for ease of haptic placement. Final best-corrected visual acuity in both eyes was 20/20, intraocular pressures were normal, and anterior chambers and vitreous were quiet two months following the right eye surgery. Final spectacle correction was +0.25 + 1.50 x 087 + 2.50 in the right eye and -0.150 + 1.50 x 093 + 2.50 in the left eye. The patient and his parents reported dramatic improvement in his social interactions and quality of life.



**Figure 2. Low-tension cautery is used to create a terminal bulb on the end of the haptic, such that it will stay external to the eye.**

lens options, is a relatively simple procedure for the surgeon. That said, the question of their long-term safety is a concern. Corneal endothelial decompensation is an especially concerning consequence that may occur in up to half of eyes over the course of the 12 years following surgery, according to one study.<sup>2</sup> They also require a larger surgical incision and close patient follow-up, given the proximity to angle structures and resulting concern for secondary inflammation and glaucoma.<sup>3,4</sup> Uncontrolled vitreous loss during surgery and subsequent sequelae is another significant concern.

Further posteriorly, iris-sutured IOLs permit a smaller



**Career Opportunities**

**OPHTHALMOLOGIST**  
Danbury, CT

Ophthalmologist to share office with long standing Ophthalmologist in Danbury, CT. High quality equipment. \$1850 per month or adjoining office without equipment- \$1500 per month.

203-545-3539 or 203-748-2020  
email [mehrimd@aol.com](mailto:mehrimd@aol.com)



**Do you have Products and Services for sale?**

CONTACT US TODAY  
FOR CLASSIFIED ADVERTISING  
Toll free: 888-498-1460  
E-mail: [sales@kerhgroup.com](mailto:sales@kerhgroup.com)



**REVIEW**  
of OPHTHALMOLOGY

# Targeting Ophthalmologists?

**CLASSIFIED ADVERTISING WORKS**

---

Contact us today  
for classified advertising:  
Toll free: **888-498-1460**  
E-mail: [sales@kerhgroup.com](mailto:sales@kerhgroup.com)

**KERHGROUP**

## ADVERTISER INDEX

*This advertiser index is published as a convenience and not as part of the advertising contract. Every care will be taken to index correctly. No allowance will be made for errors due to spelling, incorrect page number, or failure to insert.*

<b>Alcon</b> .....	<b>15</b>	<a href="http://www.clareon.com">www.clareon.com</a>	<b>Lumenis</b> .....	<b>35</b>	<a href="http://www.information.lumenis.com/optilight">www.information.lumenis.com/optilight</a>
<b>Allergan</b> .....	<b>7</b>	<a href="http://hcp.xengelstent.com">hcp.xengelstent.com</a>	<b>Novartis Pharmaceuticals</b> .....	<b>2, 3 &amp; 4</b>	<a href="http://www.novartis.com">www.novartis.com</a>
<b>Apellis</b> .....	<b>75</b>	<a href="http://www.pre-lesion.com">www.pre-lesion.com</a>	<b>Olleyes</b> .....	<b>39</b>	(855) 655-3937 <a href="mailto:sales@olleyes.com">sales@olleyes.com</a> <a href="http://www.olleyes.com">www.olleyes.com</a>
<b>Bausch + Lomb</b> .....	<b>9 &amp; 10</b>	<a href="http://www.lotemaxsm.com">www.lotemaxsm.com</a>	<b>Regeneron Pharmaceuticals, Inc.</b> .....	<b>22, 23 &amp; 24</b>	<a href="http://hcp.eylea.us">hcp.eylea.us</a>
<b>Glaukos</b> .....	<b>76</b>	<a href="http://www.glaukos.com">www.glaukos.com</a>	<b>Reichert Technologies</b> .....	<b>29</b>	<a href="http://www.reichert.com/tonopenavia">www.reichert.com/tonopenavia</a>
<b>iCare</b> .....	<b>45</b>	(888) 422-7313 <a href="mailto:infoUSA@icare-world.com">infoUSA@icare-world.com</a> <a href="http://www.icare-world.com/usa">www.icare-world.com/usa</a>	<b>Santen Inc. USA</b> .....	<b>31 &amp; 32</b>	(855) 772-6836 <a href="http://www.verkazia.com">www.verkazia.com</a>
<b>Lombart : Advancing Eyecare</b> .....	<b>19</b>	(800) LOMBART <a href="http://www.lombartinstrument.com">www.lombartinstrument.com</a>	<b>STAAR</b> .....	<b>13</b>	<a href="http://www.staar.com">www.staar.com</a>
			<b>Thea Pharmaceuticals</b> .....	<b>Cover Tip</b>	<a href="http://www.ivizia.com/ECP">www.ivizia.com/ECP</a>

incision. They share the inflammatory risk seen with AC IOLs, but given their more posterior location they don't carry the same risk of endothelial decompensation seen with AC IOLs. However, their anatomical location does bring increased risk for iris chafing, with resultant pigment dispersion and secondary glaucoma, as well as irregular pupils or pupillary dysfunction.<sup>3,5</sup>

In order to avoid corneal endothelium, angle and iris structures, the surgeon can employ scleral-fixation techniques. These are technically more challenging procedures but, especially in pediatric patients like ours, the benefits may outweigh the risks. IOLs may be fixated to the sclera either with or without sutures.<sup>3</sup> Sutured fixation techniques have been considered an effective method to approach the aphakic pediatric eye, although long-term adverse effects related to the sutures have been reported, including suture erosion and breakage with resultant IOL dislocation.<sup>6</sup> This adverse event has been seen most commonly with 10-0 polypropylene suture fixated IOLs.<sup>4</sup> The mechanism of breakage has been found to be secondary to the sharp edges of IOL positioning holes cutting the sutures and subsequent IOL subluxation.<sup>7</sup> Breakage of polypropylene sutures led to the search for a more reliable material such as Gore-Tex. Gore-Tex sutures may have a favorable safety profile for multiple reasons (they're braided and have a higher tensile strength than comparable monofilaments). Gore-tex is off-label, but has been used successfully for over a decade now. However, longer-term studies would need to be done to follow the performance of such alternative suture types over multiple decades.<sup>8</sup>

Various methods of sutureless scleral fixation techniques have recently become increasingly popular, given concerns about long-term

suture reliability, especially in pediatric patients in whom IOL longevity is critical. Fixation by means of fibrin glue is one such method. One study followed forty-one eyes of 33 pediatric patients in which IOL haptics were externalized through partial-thickness scleral flaps which were then closed with fibrin glue. Within the mean follow-up of 17.5 months, two IOLs underwent decentration with an otherwise favorable side-effect profile.<sup>9</sup>

More recently, a flanged technique developed by Dr. Yamane and his co-workers, which was used in our case, has gained popularity.<sup>1,10</sup> This technique uses thin-walled, 30-gauge needles to externalize IOL haptics through the sclera, with subsequent cauterization of the externalized haptics. This creates a terminal bulb on the haptics, preventing them from regressing back into the globe. This technique is commonly referred to as intrascleral haptic fixation (ISHF), or the double-needle technique. The original study of the technique in 2017 detailed 100 eyes of 97 consecutive patients over 36 months and included complications of iris capture in eight eyes (8 percent), vitreous hemorrhage in five eyes (5 percent), and cystoid macular edema in one eye (1 percent).<sup>1</sup>

Since its original publication, multiple variations on this flanged technique have been proposed, including modifications to needle docking, trocar-assisted docking, flattened flanges, refixation and double-flanged techniques.<sup>10</sup> These variations have varying technical difficulties and require further study but are based on the principle of externalizing IOL haptics with subsequent cauterization. One benefit of this technique is that the experienced surgeon may readily modify the IOL position or explant the IOL by simply amputating the terminal bulb, internalizing the haptic or

suture and adjusting as needed. This is of particular importance in a patient with a long lifetime ahead.

The pediatric aphakic patient has a number of options which continue to evolve as surgeons seek to optimize patient outcomes. Anterior chamber and iris-sutured IOLs may be technically easier but come with the risk of contact with anterior chamber structures such as corneal endothelium, angle and the iris. Scleral-fixated techniques seek to avoid these structures but may present additional technical challenges. They also require careful preoperative planning to select the technique which the surgeon can comfortably perform, but presents the best potential outcome for the patient. ◀

1. Yamane S, Sato S, Maruyama-Inoue M, Kadonosono K. Flanged intrascleral intraocular lens fixation with double-needle technique. *Ophthalmology* 2017;124:8:1136-1142.
2. Tang Y, Xu J, Chen J, Lu Y. Long-term destiny of corneal endothelial cells in anterior chamber intraocular lens-implanted eyes. *J Ophthalmol* 2020;Dec 24 (online article). doi:10.1155/2020/5967509
3. Terveen DC, Fram NR, Ayres B, Berdahl JP. Small-incision 4-point scleral suture fixation of a foldable hydrophilic acrylic intraocular lens in the absence of capsule support Presented at the ASCRS Symposium on Cataract, IOL and Refractive Surgery, San Diego, California, USA, April 2015. *J Cataract Refract Surg* 2016;42:2:211-216.
4. Karasavvidou EM, Wilde C, Zaman A, Orr G, Kumudhan D, Panos GD. Surgical management of paediatric aphakia in the absence of sufficient capsular support. *J Ophthalmol*. 2021;Dec 4 (online article). doi:10.1155/2021/2253486
5. Condon GP, Masket S, Kranemann C, Crandall AS, Ahmed IK. Small-incision iris fixation of foldable intraocular lenses in the absence of capsule support. *Ophthalmology* 2007;114:7:1311-1318.
6. Cheung CSY, VanderVeen DK. Intraocular lens techniques in pediatric eyes with insufficient capsular support: Complications and outcomes. *Semin Ophthalmol* 2019;34:4:293-302.
7. Parekh P, Green WR, Stark WJ, Akpek EK. Subluxation of suture-fixated posterior chamber intraocular lenses. A clinicopathologic study. *Ophthalmology* 2007;114:2:232-237.
8. Khan MA, Gupta OP, Smith RG, et al. Scleral fixation of intraocular lenses using Gore-Tex suture: Clinical outcomes and safety profile. *Br J Ophthalmol* 2016;100:5:638-643.
9. Kumar DA, Agarwal A, Prakash D, Prakash G, Jacob S, Agarwal A. Glued intrascleral fixation of posterior chamber intraocular lens in children. *Am J Ophthalmol* 2012;153:4:594-601.
10. Yamane S, Ito A. Flanged fixation: Yamane technique and its application. *Curr Opin Ophthalmol* 2021;32:1:19-24.

# Apellis is exploring the role of complement in Geographic Atrophy<sup>1</sup>

## C3 is the linchpin of complement overactivation in GA.<sup>2-7</sup>

All three complement pathways converge at C3 and it drives multiple downstream effects — inflammation, opsonization, and formation of the membrane attack complex — all of which can ultimately lead to retinal cell death. Increased levels of complement activity have been found not just in the lesion itself, but also in the area just outside the lesion, known as the pre-lesion.<sup>2-9</sup>



Scan the code to explore new territory with us at [pre-lesion.com](https://pre-lesion.com)




Apellis

1. Katschke KJ Jr, et al. *Sci Rep*. 2018;8(1):13055. 2. Mastellos DC, et al. *Trends Immunol*. 2017;38(6):383-394. 3. Ricklin D, et al. *Immunol Rev*. 2016;274(1):33-58. 4. Heesterbeek TJ, et al. *Ophthalmol Vis Sci*. 2020;61(3):18. 5. Seddon JM, et al. *Nat Genet*. 2013;45:1266-1370. 6. Yates JRW, et al. *N Engl J Med*. 2007;357(6):553-561. 7. Smailhodzic D, et al. *Ophthalmology*. 2012;119(2):339-346. 8. Boyer DS, et al. *Retina*. 2017;37:819-835. 9. Park DH, et al. *Front Immunol*. 2019;10:1007.



iStent  
inject® W



# POWERFUL PREDICTABLE PROVEN

## GO FOR THE #1 MIGS DEVICE WORLDWIDE\*

**Powerful technology** for sustained intraocular pressure and medication reduction. **Predictable outcomes** from a truly tissue-sparing procedure. All on a **proven platform** with the most clinical evidence of any MIGS device.

**Experience the latest evolution of the iStent® legacy of excellence in your practice.**

\*Based on units sold.

### **iStent inject® W IMPORTANT SAFETY INFORMATION**

**INDICATION FOR USE.** The iStent inject® W Trabecular Micro-Bypass System Model G2-W is indicated for use in conjunction with cataract surgery for the reduction of intraocular pressure (IOP) in adult patients with mild to moderate primary open-angle glaucoma. **CONTRAINDICATIONS.** The iStent inject W is contraindicated in eyes with angle-closure glaucoma, traumatic, malignant, uveitic, or neovascular glaucoma, discernible congenital anomalies of the anterior chamber (AC) angle, retrolental tumor, thyroid eye disease, or Sturge-Weber Syndrome or any other type of condition that may cause elevated episcleral venous pressure. **WARNINGS.** Gonioscopy should be performed prior to surgery to exclude congenital anomalies of the angle, PAS, rubeosis, or conditions that would prohibit adequate visualization of the angle that could lead to improper placement of the stent and pose a hazard. **MRI INFORMATION.** The iStent inject W is MR-Conditional, i.e., the device is safe for use in a specified MR environment under specified conditions; please see Directions for Use (DFU) label for details. **PRECAUTIONS.** The surgeon should monitor the patient postoperatively for proper maintenance of IOP. The safety and effectiveness of the iStent inject W have not been established as an alternative to the primary treatment of glaucoma with medications, in children, in eyes with significant prior trauma, abnormal anterior segment, chronic inflammation, prior glaucoma surgery (except SLT performed > 90 days preoperative), glaucoma associated with vascular disorders, pseudoexfoliative, pigmentary or other secondary open-angle glaucomas, pseudophakic eyes, phakic eyes without concomitant cataract surgery or with complicated cataract surgery, eyes with medicated IOP > 24 mmHg or unmedicated IOP < 21 mmHg or > 36 mmHg, or for implantation of more or less than two stents. **ADVERSE EVENTS.** Common postoperative adverse events reported in the iStent inject® randomized pivotal trial included stent obstruction (6.2%), intraocular inflammation (5.7% for iStent inject vs. 4.2% for cataract surgery only), secondary surgical intervention (5.4% vs. 5.0%) and BCVA loss  $\geq$  2 lines  $\geq$  3 months (2.6% vs. 4.2%). **CAUTION:** Federal law restricts this device to sale by, or on the order of, a physician. Please see DFU for a complete list of contraindications, warnings, and adverse events.

Glaukos®, iStent®, and iStent inject® W are registered trademarks of Glaukos Corporation. All rights reserved. ©2022 PM-US-0782

GLAUKOS