

Wills Eye Resident Series: An Elderly Man Presents with Chronic Scleritis, p .79

REVIEW[®] *of* OPHTHALMOLOGY

September 2021 • reviewofophthalmology.com • Clinical advice you can trust

REFRACTIVE/CATARACT

Responding to Refractive Surprises

PAGE 19

MEDICARE Q & A

Medicare Mid-year Update

PAGE 26

RETINAL INSIDER

Posterior Segment Open Globe Injuries

PAGE 74

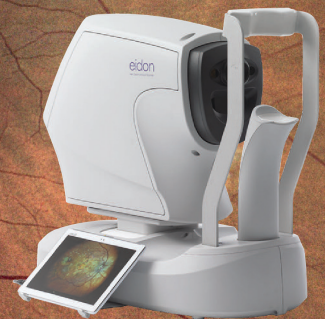Issue Focus: Dry Eye

GETTING TO

iCare EIDON AF

Ultra-high resolution
retinal imaging

- + Rich in details from center to periphery
- + Imaging through media opacities



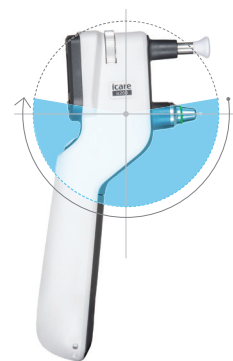
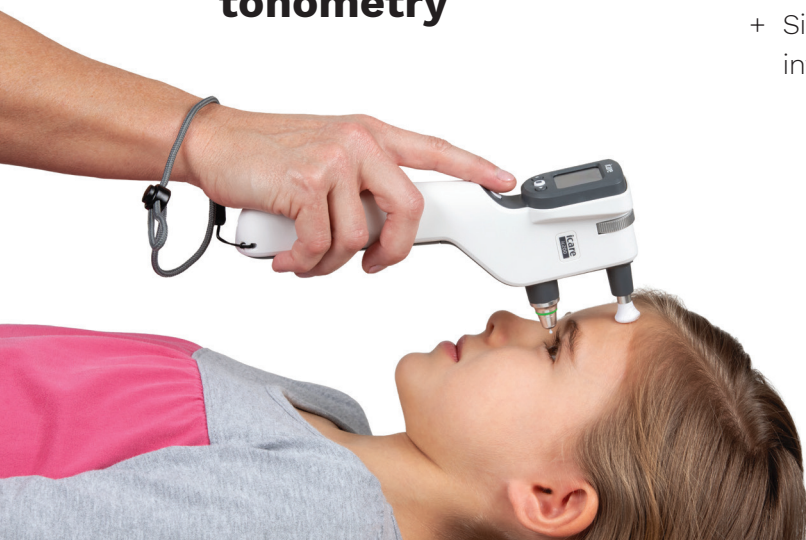
For more information, scan,
call 888.422.7313, or email
infoUSA@icare-world.com
www.icare-world.com/USA

For better perception **icare**

iCare IC200

200 degrees of tonometry

- + Supine, elevated & seated operation
- + No corneal disruptions
- + Suitable for every patient
- + No drops, air, or calibration needed
- + Single use probes to exceed infection control guidelines



For more information, scan,
call 888.422.7313, or email
infoUSA@icare-world.com
www.icare-world.com/USA

For better perception **icare**

Wills Eye Resident Series: An Elderly Man Presents with Chronic Scleritis, p .79

REVIEW[®] of OPTHALMOLOGY

September 2021 • reviewofophthalmology.com • Clinical advice you can trust

REFRACTIVE/CATARACT

Responding to Refractive Surprises
PAGE 19

MEDICARE Q & A

Medicare Mid-year Update
PAGE 26

RETINAL INSIDER

Posterior Segment Open Globe Injuries
PAGE 74

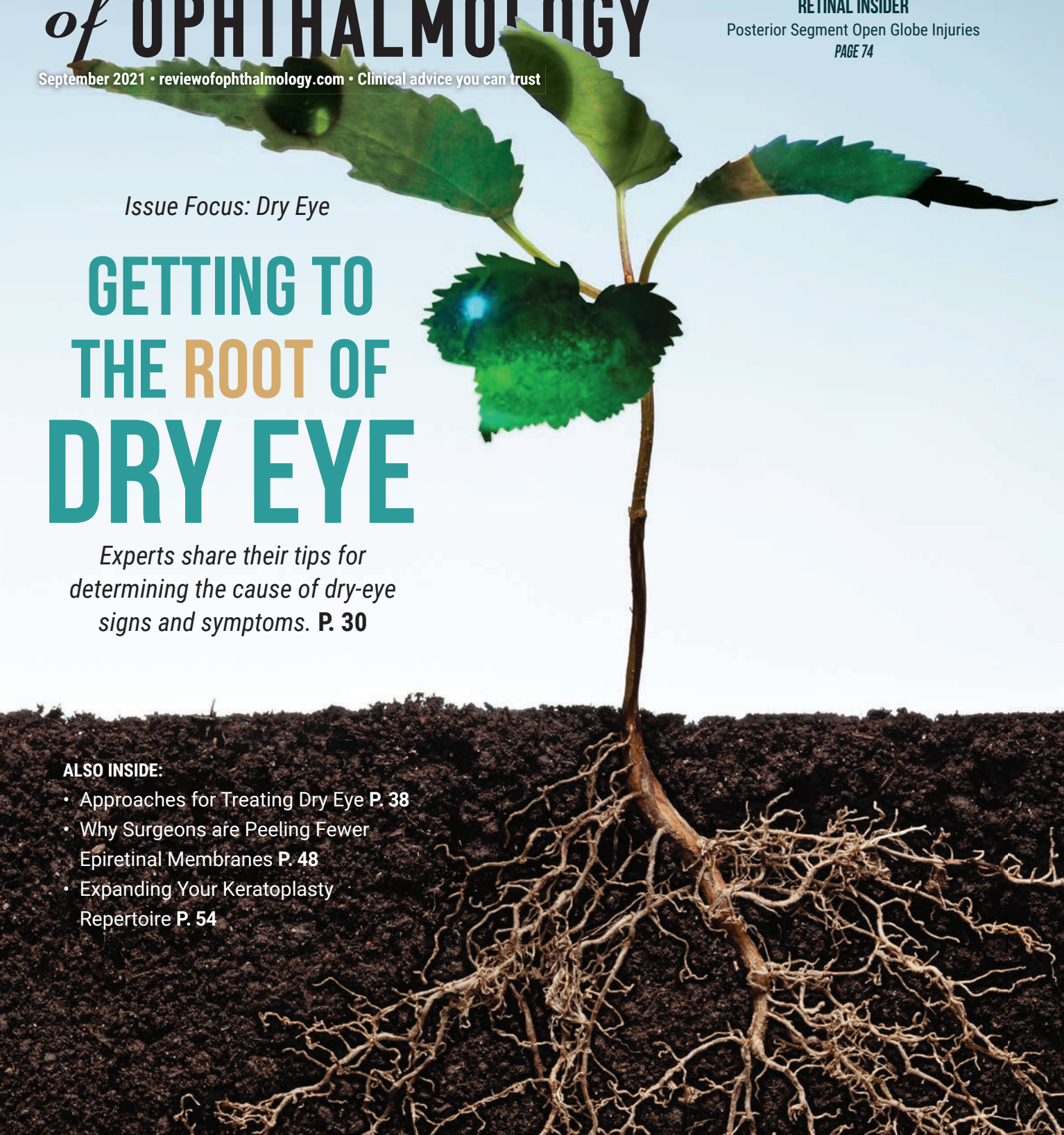Issue Focus: Dry Eye

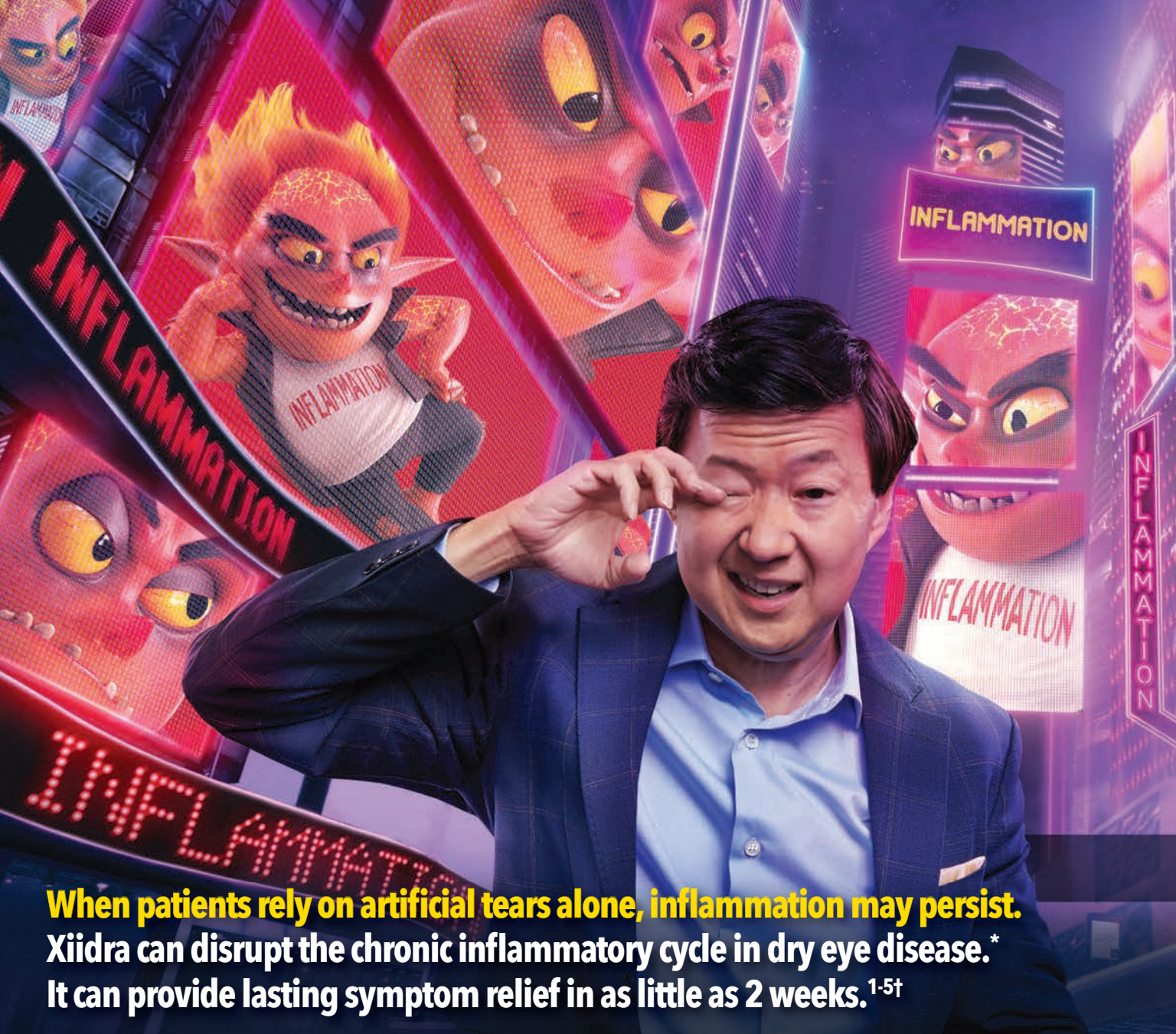GETTING TO THE ROOT OF DRY EYE

*Experts share their tips for
determining the cause of dry-eye
signs and symptoms. P. 30*

ALSO INSIDE:

- Approaches for Treating Dry Eye P. 38
- Why Surgeons are Peeling Fewer Epiretinal Membranes P. 48
- Expanding Your Keratoplasty Repertoire P. 54





When patients rely on artificial tears alone, inflammation may persist. Xiidra can disrupt the chronic inflammatory cycle in dry eye disease.* It can provide lasting symptom relief in as little as 2 weeks.^{1-5†}

*Xiidra blocks LFA-1 on T cells from binding with ICAM-1 that may be overexpressed on the ocular surface in dry eye disease and may prevent formation of an immunologic synapse which, based on in vitro studies, may inhibit T-cell activation, migration of activated T cells to the ocular surface, and reduce cytokine release. The exact mechanism of action of Xiidra in DED is not known.^{1,2,5}

†The safety and efficacy of Xiidra were assessed in four 12-week, randomized, multicenter, double-masked, vehicle controlled studies (N=2133). Patients were dosed twice daily. The mean age was 59 years (range, 19-97 years). The majority of patients were female (76%). Use of artificial tears was not allowed during the studies. The study end points included assessment of signs (based on Inferior fluorescein Corneal Staining Score [ICSS] on a scale of 0 to 4) and symptoms (based on patient-reported EDS on a visual analogue scale of 0 to 100). Effects on symptoms of dry eye disease: a larger reduction in EDS favoring Xiidra was observed in all studies at day 42 and day 84. Xiidra reduced symptoms of eye dryness at 2 weeks (based on EDS) compared to vehicle in 2 out of 4 clinical trials. Effects on signs of dry eye disease: at day 84, a larger reduction in ICSS favoring Xiidra was observed in 3 out of the 4 studies.¹

Indication

Xiidra® (lifitegrast ophthalmic solution) 5% is indicated for the treatment of signs and symptoms of dry eye disease (DED).

Important Safety Information

- Xiidra is contraindicated in patients with known hypersensitivity to lifitegrast or to any of the other ingredients.



Novartis Pharmaceuticals Corporation
East Hanover, New Jersey 07936-1080



KEN JEONG,
REAL DRY EYE PATIENT.


xiidra®
(lifitegrast
ophthalmic solution)5%
Dry eyes deserve a change

Important Safety Information (cont)

- In clinical trials, the most common adverse reactions reported in 5-25% of patients were instillation site irritation, dysgeusia and reduced visual acuity. Other adverse reactions reported in 1% to 5% of the patients were blurred vision, conjunctival hyperemia, eye irritation, headache, increased lacrimation, eye discharge, eye discomfort, eye pruritus and sinusitis.
- To avoid the potential for eye injury or contamination of the solution, patients should not touch the tip of the single-use container to their eye or to any surface.
- Contact lenses should be removed prior to the administration of Xiidra and may be reinserted 15 minutes following administration.
- Safety and efficacy in pediatric patients below the age of 17 years have not been established.

For additional safety information about XIIDRA®, please refer to the brief summary of Prescribing Information on adjacent page.

References: 1. Xiidra [package insert]. East Hanover, NJ: Novartis Pharmaceuticals Corp; June 2020. 2. Bron AJ, de Paiva CS, Chauhan SK, et al. TFOS DEWS II Pathophysiology Report. *Ocul Surf.* 2017;15(3):438-510. 3. US Food and Drug Administration. Code of Federal Regulations, Title 21, Volume 5 (21CFR349). Accessed May 25, 2021. <https://www.accessdata.fda.gov/scripts/cdrh/cfdocs/cfcfr/CFRSearch.cfm?CFRPart=349&showFR=1> 4. Jones L, Downie LE, Korb D, et al. TFOS DEWS II Management and Therapy Report. *Ocul Surf.* 2017;15(3):575-628. 5. Pflugfelder SC, Stern M, Zhang S, Shojaei A. LFA-1/ICAM-1 interaction as a therapeutic target in dry eye disease. *J Ocul Pharmacol Ther.* 2017;33(1):5-12.

XIIDRA, the XIIDRA logo and ii are registered trademarks of Novartis AG.

XIIDRA® (lifitegrast ophthalmic solution), for topical ophthalmic use
Initial U.S. Approval: 2016

BRIEF SUMMARY: Please see package insert for full prescribing information.

1 INDICATIONS AND USAGE

Xiidra® (lifitegrast ophthalmic solution) 5% is indicated for the treatment of the signs and symptoms of dry eye disease (DED).

4 CONTRAINDICATIONS

Xiidra is contraindicated in patients with known hypersensitivity to lifitegrast or to any of the other ingredients in the formulation [see *Adverse Reactions* (6.2)].

6 ADVERSE REACTIONS

The following serious adverse reactions are described elsewhere in the labeling:

- Hypersensitivity [see *Contraindications* (4)]

6.1 Clinical Trials Experience

Because clinical trials are conducted under widely varying conditions, adverse reaction rates observed in clinical trials of a drug cannot be directly compared to rates in the clinical trials of another drug and may not reflect the rates observed in practice.

In five clinical trials of DED conducted with lifitegrast ophthalmic solution, 1401 patients received at least one dose of lifitegrast (1287 of which received lifitegrast 5%). The majority of patients (84%) had less than or equal to 3 months of treatment exposure. One hundred-seventy patients were exposed to lifitegrast for approximately 12 months. The majority of the treated patients were female (77%). The most common adverse reactions reported in 5%-25% of patients were instillation-site irritation, dysgeusia, and reduced visual acuity.

Other adverse reactions reported in 1%-5% of the patients were blurred vision, conjunctival hyperemia, eye irritation, headache, increased lacrimation, eye discharge, eye discomfort, eye pruritus, and sinusitis.

6.2 Postmarketing Experience

The following adverse reactions have been identified during post-approval use of Xiidra. Because these reactions are reported voluntarily from a population of uncertain size, it is not always possible to reliably estimate their frequency or establish a causal relationship to drug exposure.

Rare serious cases of hypersensitivity, including anaphylactic reaction, bronchospasm, respiratory distress, pharyngeal edema, swollen tongue, urticaria, allergic conjunctivitis, dyspnea, angioedema, and allergic dermatitis have been reported. Eye swelling and rash have also been reported [see *Contraindications* (4)].

8 USE IN SPECIFIC POPULATIONS

8.1 Pregnancy

Risk Summary

There are no available data on Xiidra use in pregnant women to inform any drug-associated risks. Intravenous (IV) administration of lifitegrast to

pregnant rats, from pre-mating through gestation day 17, did not produce teratogenicity at clinically relevant systemic exposures. Intravenous administration of lifitegrast to pregnant rabbits during organogenesis produced an increased incidence of omphalocele at the lowest dose tested, 3 mg/kg/day (400-fold the human plasma exposure at the recommended human ophthalmic dose [RHOD], based on the area under the curve [AUC] level). Since human systemic exposure to lifitegrast following ocular administration of Xiidra at the RHOD is low, the applicability of animal findings to the risk of Xiidra use in humans during pregnancy is unclear [see *Clinical Pharmacology* (12.3) in the full prescribing information].

Data

Animal Data

Lifitegrast administered daily by IV injection to rats, from pre-mating through gestation day 17, caused an increase in mean pre-implantation loss and an increased incidence of several minor skeletal anomalies at 30 mg/kg/day, representing 5,400-fold the human plasma exposure at the RHOD of Xiidra, based on AUC. No teratogenicity was observed in the rat at 10 mg/kg/day (460-fold the human plasma exposure at the RHOD, based on AUC). In the rabbit, an increased incidence of omphalocele was observed at the lowest dose tested, 3 mg/kg/day (400-fold the human plasma exposure at the RHOD, based on AUC), when administered by IV injection daily from gestation days 7 through 19. A fetal no observed adverse effect level (NOAEL) was not identified in the rabbit.

8.2 Lactation

Risk Summary

There are no data on the presence of lifitegrast in human milk, the effects on the breastfed infant, or the effects on milk production. However, systemic exposure to lifitegrast from ocular administration is low [see *Clinical Pharmacology* (12.3) in the full prescribing information]. The developmental and health benefits of breastfeeding should be considered, along with the mother's clinical need for Xiidra and any potential adverse effects on the breastfed child from Xiidra.

8.4 Pediatric Use

Safety and efficacy in pediatric patients below the age of 17 years have not been established.

8.5 Geriatric Use

No overall differences in safety or effectiveness have been observed between elderly and younger adult patients.

Distributed by:
Novartis Pharmaceuticals Corporation
One Health Plaza
East Hanover, NJ 07936
T2020-87

Study Sheds Light on the Effect Of Postop Astigmatism

In the August issue of the *Journal of Cataract and Refractive Surgery*, researchers from California and the United Kingdom combined to quantify the effect of postoperative astigmatism on the uncorrected distance visual acuity of cataract surgery patients. The investigators say this is the first large-sample study with enough statistical power to investigate the independent effect of low amounts of astigmatism in these patients.

In the retrospective case series, the researchers entered postoperative data from 17,152 dominant eyes of patients who had undergone either cataract surgery or refractive lens exchange. They looked at the effect of residual astigmatism on the three-month postop monocular UDVA, as well as patient satisfaction.

The investigators found that, compared with eyes with no residual astigmatism, the odds of not achieving 20/20 vision in eyes with low levels of postop cylinder (0.25 to 0.50 D) increased by 1.7 and 1.9 ($p < 0.0001$) in monofocal and multifocal IOLs, respectively.

For residual astigmatism of 0.75 to 1 D, the odds of not achieving 20/20 vision compared with eyes with no astigmatism was 6.1 for monofocal and 6.5 for multifocal IOLs ($p < 0.0001$).

The effect of residual astigmatism on satisfaction was more evident at the 0.75 to 1 D level, where the odds of not being satisfied with vision increased by a factor of 2.0 and 1.5 in patients with monofocal and multifocal IOLs, respectively ($p < 0.0001$).

The study's corresponding author,

San Diego's Steven C. Schallhorn, MD, says a couple of things stood out to him from the data.

"The study showed how even very low levels of astigmatism can affect outcomes," he says, referring to the odds ratio of nearly 2.0 of not getting 20/20 vision with low astigmatism. "The evolution of our understanding of this is interesting: Twenty or 30 years ago, if you were at 1 D of residual astigmatism or less postoperatively, that was good, especially with extracapsular cataract extraction. We don't have that acute sense of how important it is to manage astigmatism unless it's very high—meaning 2 or 3 D or more. [This study showed] that our threshold, our clinical acumen and our understanding of the preop workup of astigmatism need to step

(Continued on p. 11)

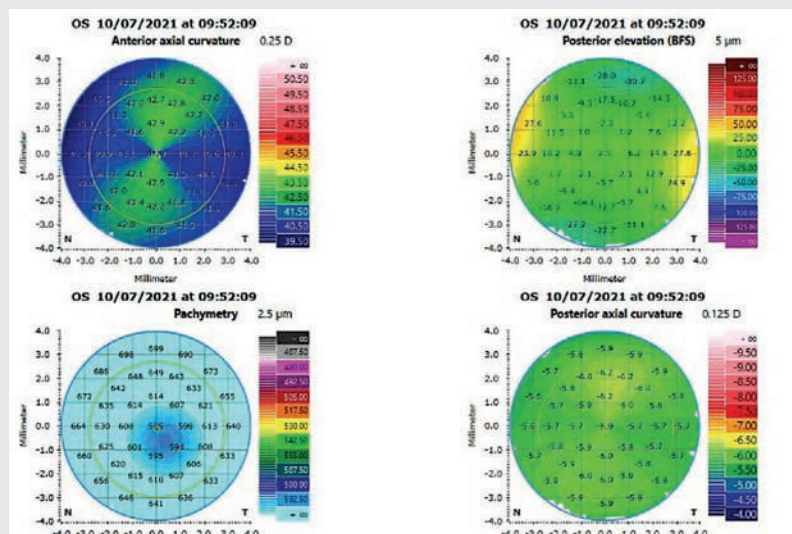
ERRATA

Michael Patterson, DO, a comprehensive ophthalmologist at Eye Centers of Tennessee, was incorrectly identified in July's "Increasing Premium IOLs (and Service)."

An incorrect corneal topography map array was published on page 22 of the August Refractive/Cataract Rundown. The correct maps are shown to the right.

The August article, "Scratching the Surface of Abnormal Corneas" erroneously listed amiodarone keratopathy among the conditions treatable with epithelial debridement.

Review regrets the errors.



CONTRIBUTORS

CHIEF MEDICAL EDITOR

Mark H. Blecher, MD

CONTACT LENSES

Penny Asbell, MD

CORNEA / ANTERIOR SEGMENT

Thomas John, MD

GLAUCOMA MANAGEMENT

Peter Netland, MD, PHD
Kuldev Singh, MD

MEDICARE Q & A

Paul M. Larson, MBA

PEDIATRIC PATIENT

Janine Collinge, MD

PLASTIC POINTERS

Anna P. Murchison, MD, MPH

REFRACTIVE SURGERY

Arturo S. Chayet, MD

RETINAL INSIDER

Carl Regillo, MD, FACS
Yoshihiro Yonekawa, MD

TECHNOLOGY UPDATE

Steven T. Charles, MD
Michael Colvard, MD

WILLS RESIDENT CASE SERIES

Rakhi Melvani, MD

ADVISORY BOARD

PENNY A. ASBELL, MD, MEMPHIS, TENN.

BRANDON AYRES, MD, PHILADELPHIA

SURENDRA BASTI, MD, CHICAGO

WILLIAM I. BOND, MD, PEKIN, ILL.

ALAN N. CARLSON, MD, DURHAM, N.C.

Y. RALPH CHU, MD, EDINA, MINN.

ADAM J. COHEN, MD, CHICAGO

JANINE COLLINGE, MD, FARMINGTON, CONN.

UDAY DEVGAN, MD, FACS, LOS ANGELES

ERIC DONNENFELD, MD, ROCKVILLE CENTRE, N.Y.

DANIEL S. DURRIE, MD, KANSAS CITY, MO.

ROBERT EPSTEIN, MD, MCHENRY, ILL.

ROBERT D. FECHTNER, MD, NEWARK, N.J.

WILLIAM J. FISHKIND, MD, TUCSON, ARIZ.

BRIAN FRANCIS, MD, Los Angeles

JAMES P. GILLS, MD, TARPON SPRINGS, FLA.

HARRY GRABOW, MD, SARASOTA, FLA.

DOUGLAS K. GRAYSON, MD, NEW YORK CITY

DAVID R. HARDTEN, MD, MINNEAPOLIS

SARA J. HAUG, MD, PHD, DURANGO, COLO.

KENNETH J. HOFFER, MD, SANTA MONICA, CALIF.

JACK T. HOLLADAY, MD, MSEE, HOUSTON

JOHN D. HUNKELER, MD, KANSAS CITY, MO.

THOMAS JOHN, MD, TINLEY PARK, ILL.

ROBERT M. KERSHNER, MD, MS, PALM BEACH GARDENS, FLA.

GUY M. KEZIRIAN, MD, PARADISE VALLEY, ARIZ.

TERRY KIM, MD, DURHAM, N.C.

BRAD KLIGMAN, MD, MANHASSET, N.Y.

TOMMY KORN, MD, SAN DIEGO

DAVID A. LEE, MD, HOUSTON

FRANCIS S. MAH, MD, LA JOLLA, CALIF.

NICK MAMALIS, MD, SALT LAKE CITY

EDWARD MANCHE, MD, PALO ALTO, CALIF.

MIKE S. MCFARLAND, MD, PINE BLUFF, ARK.

JEFFREY B. MORRIS, MD, MPH, ENCINITAS, CALIF.

KEVIN MILLER, MD, LOS ANGELES

MARLENE R. MOSTER, MD, PHILADELPHIA

ANNA P. MURCHISON, MD, MPH, PHILADELPHIA

ROBERT J. NOECKER, MD, FAIRFIELD, CONN.

ROBERT OSHER, MD, CINCINNATI

MARK PACKER, MD, WEST PALM BEACH, FLA.

CHRISTOPHER J. RAPUANO, MD, PHILADELPHIA

AUGUST READER III, MD, SAN FRANCISCO

TONY REALINI, MD, MORGANTOWN, W.V.

KENNETH J. ROSENTHAL, MD, GREAT NECK, N.Y.

ERIC ROTHCHILD, MD, DELRAY BEACH, FLA.

SHERI ROWEN, MD, BALTIMORE

JAMES J. SALZ, MD, LOS ANGELES

INGRID U. SCOTT, MD, MPH, HERSHEY, PA.

JOEL SCHUMAN, MD, PITTSBURGH

GAURAV SHAH, MD, ST. LOUIS

DAVID R. STAGER JR., MD, DALLAS

KARL STONECIPHER, MD, GREENSBORO, N.C.

JAMES C. TSAI, MD, NEW YORK CITY

VANCE THOMPSON, MD, SIOUX FALLS, S.D.

FARRELL C. TYSON, MD, CAPE CORAL, FLA.

R. BRUCE WALLACE III, MD, ALEXANDRIA, LA.



BUSINESS OFFICES

19 CAMPUS BOULEVARD, SUITE 101
NEWTOWN SQUARE, PA 19073
SUBSCRIPTION INQUIRIES (877) 529-1746
(USA ONLY); OUTSIDE USA, CALL (847) 763-9630

BUSINESS STAFF

PUBLISHER

MICHAEL HOSTER

(610) 492-1028 MHOSTER@JOBSON.COM

EXECUTIVE DIRECTOR

JAMES HENNE

(610) 492-1017 JHENNE@JOBSON.COM

REGIONAL SALES MANAGER

MICHELE BARRETT

(610) 492-1014 MBARRETT@JOBSON.COM

REGIONAL SALES MANAGER

JONATHAN DARDINE

(610) 492-1030 JDARDINE@JOBSON.COM

CLASSIFIED ADVERTISING

(888)-498-1460

PRODUCTION MANAGER

FARRAH APONTE

212-274-7057 FAPONTE@JOBSON.COM

PRODUCTION MANAGER

KAREN LALLONE

(610) 492-1010 KLALLONE@JOBSON.COM

SUBSCRIPTIONS

\$63 A YEAR, \$99 (U.S.) IN CANADA,
\$158 (U.S.) IN ALL OTHER COUNTRIES.

SUBSCRIPTIONS E-MAIL:

REVOPHTHALMOLOGY@CAMBEYWEST.COM

CIRCULATION

PO BOX 71, CONGERS, NY 10920-0071

(877) 529-1746

OUTSIDE USA: (845) 267-3065

SENIOR CIRCULATION MANAGER

HAMILTON MAHER

(212) 219-7870 hmaher@jhihealth.com

CEO, INFORMATION GROUP SERVICES

MARC FERRARA

SENIOR VICE PRESIDENT, OPERATIONS

JEFF LEVITZ

VICE PRESIDENT, HUMAN RESOURCES

TAMMY GARCIA

VICE PRESIDENT, CREATIVE SERVICES & PRODUCTION

MONICA TETTAMANZI

CORPORATE PRODUCTION DIRECTOR

JOHN ANTHONY CAGGIANO

VICE PRESIDENT, CIRCULATION

JARED SONNERS

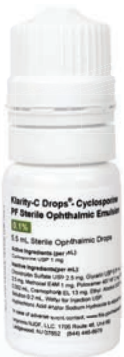395 Hudson Street, 3rd Floor,

New York, NY 10014

Klarity-C Drops®

NO PRIOR AUTHORIZATIONS

First 30-Day Supply*



Klarity-C Drops (Preservative-Free)
Cyclosporine 0.1% Ophthalmic Emulsion**
\$59.00 per month

Start Your Patients Today for Just \$1*

Visit: imprimisrx.com/totaltears/ or scan the QR code to learn more



*Only available on new prescriptions. Cannot be combined with other discounts. Automatic refill set up is required. Months supply can vary based on the dosing regimen prescribed by the doctor. Full details of program eligibility are available by contacting ImprimisRx

**For professional use only. ImprimisRx Pharmacy specializes in customizing medications to meet unique patient and practitioner needs. ImprimisRx dispenses only to individually identified patients with valid prescriptions. No compounded medication is reviewed by the FDA for safety or efficacy. ImprimisRx does not compound essential copies of commercially available products. References available upon request.

Total Tears, Klarity-C Drops and ImprimisRx are registered trademarks of Harrow Health, Inc.
©2021 ImprimisRx. All Rights Reserved. IMPO0528 Rev2 8/21

imprimis **Rx**®

Considerations for Ex-U.S. Partnering

MATTHEW CHAPIN, MD
Andover, Mass.

The ophthalmic drug market was estimated to be ~\$40 billion in 2020,¹ with about 40 percent of that attributed to North America. This highlights the significant portion of the market outside of the United States. One just needs to perform a simple online search to see the number of business deals that were done in ophthalmology over the past year, with an impressive number occurring in China alone. As such, there's a big opportunity available for partnering outside of the United States, especially in Asia.

As a new entrepreneur, or start-up company, you should at least consider what your strategy is to capture value in this large ex-U.S. segment, which may be in your near or long-term plans. For some companies, pursuing licensing outside of the United States is something that becomes part of later discussions, once clinical data or even approval is obtained in the U.S. In other cases, an ex-U.S. deal may be a critical component of early-to-mid-stage financing with either direct investment from a partner, or with incoming license fees. There are, of course, many considerations across business structure, financing, regulatory, etc., when looking at an international deal. Here, however, we're going to focus on a few key pearls regarding development outside of the United States.

Clinical Development and Regulatory Responsibility

When entering into a deal with an international partner, it's always a good practice to understand the other party's objectives, needs and motivations. This ensures a good deal for everyone.

Motivation for a partner may, for example, be to gain access to your late-stage/commercial-stage asset that's already de-risked for them, from their perspective of bridging development into that new territory. In that case, development in the United States may already be completed or finishing up, and it's truly a focused regional deal, with each company being responsible for its own remaining development and commercial activities in

each respective country.

In other cases, the ex-U.S. company may have a desire to get involved in a global development program. This may be in order to be most efficient with development in that region. For example, they may want to leverage minutes from FDA meetings in the United States with local regulatory authorities. Similarly, the ability to use global clinical data for registration in that country may help reduce the size or number of studies, and avoid the need to repeat activities in that specific country. The interest in being part of a global program may also be for managing perceptions in that country, and to demonstrate that the regional company is a global "player." There may be different ways to address this second point, but we've seen situations in which "conducting a global



program" may be interpreted differently by different companies.

If you're in early discussions with a company for international rights, and they want to have a global program, make sure you're clear whether that means that they'll run their development in parallel, sharing information such as toxicology, manufacturing, clinical protocols, and maybe even using the same protocol as a template but keeping it a separate trial; or that the company wants a true global study with sites in both the United States and that region under one protocol. Before agreeing that each company covers its activities in its own country, be sure to understand this nuance. Either scenario is feasible—there's not a right or wrong answer—and which one you choose depends on your situation, the needs of the program, and

the capabilities of each company involved.

Running two separate protocols, of course, implies two processes that can be somewhat de-linked on two timelines. But if manufacturing is intended to supply both studies with product, or ongoing/future toxicology studies feed into both, then timelines will need to be aligned. Further, if the desire is a single global protocol conducted in multiple countries, generally speaking there will be one company designated as the sponsor. This company has the ultimate responsibility for duties such as contracting with investigative sites, taking point with the local regulatory authorities and engaging the appropriate contract research organization or vendor(s). If you have a U.S. study on a specific timeline and plan, you need to manage and be aware if a local ex-US partner you engage with is looking for a global study as part of the deal, since this can impact U.S. timelines. Also, be sure to define who has primary and supportive responsibilities.

You may also consider structuring the financial terms to match the data package used for submissions. For example, if your data in the United States helps your partner submit for marketing earlier, or saves a study in that territory, you can consider how that additional value is recognized for you as part of your deal.

You also want to avoid overlapping activities, such as a common toxicology study requirement or procurement of an active drug powder or manufactured supplies that both partners need. Also, if there is indeed sharing of data between the United States and that country, consider the time, cost and responsibility for any translation work necessary.


If the study is actually a global trial, there needs to be early alignment on regulatory meetings, with the same protocol submitted to the FDA and the other country's regulatory authority, with the proper integration and review of feedback and/or changes. Be as specific as possible on what support is being provided by each party. For example it's very easy to say that one party will "support" the other on

(Continued on p. 11)

IN THE BATTLEGROUND OF DRY EYE...

When
Dry
Eye
Flares
strike,

fight
back
first
with
fast.



- EYSUVIS is **THE FIRST AND ONLY FDA APPROVED SHORT TERM (up to two weeks) RX TREATMENT** for the signs and symptoms of Dry Eye Disease
- EYSUVIS **RAPIDLY REDUCED*** Dry Eye signs and symptoms in the largest clinical development program in Dry Eye (N=2871)¹
- EYSUVIS **TARGETS OCULAR SURFACE INFLAMMATION**, an underlying pathology of Dry Eye
- EYSUVIS is formulated with AMPPLIFY[®] Drug Delivery Technology, designed to **ENHANCE OCULAR SURFACE TISSUE DISTRIBUTION AND PENETRATION**^{2,3}
- EYSUVIS had a **LOW INCIDENCE OF INTRAOCULAR PRESSURE ELEVATION** (similar to vehicle) and was well-tolerated in clinical trials⁴
–Please see Warning on Intraocular Pressure Increase below

*The safety and efficacy of EYSUVIS was assessed in 4 multicentered, randomized, double-masked, placebo-controlled trials in 2871 patients with documented Dry Eye. Patients received either EYSUVIS or vehicle 4 times a day for at least 2 weeks. Patients taking EYSUVIS showed significant reduction in the symptoms of Dry Eye (ocular discomfort) as early as Day 4 after starting treatment (versus vehicle). Symptoms continued to improve up to the end of the treatment period (Day 15). Patients taking EYSUVIS also showed significant reduction in signs of Dry Eye (conjunctival hyperemia) at Day 15 versus vehicle.

INDICATION

EYSUVIS is a corticosteroid indicated for the short-term (up to two weeks) treatment of the signs and symptoms of dry eye disease.

IMPORTANT SAFETY INFORMATION

Contraindication:

EYSUVIS, as with other ophthalmic corticosteroids, is contraindicated in most viral diseases of the cornea and conjunctiva including epithelial herpes simplex keratitis (dendritic keratitis), vaccinia, and varicella, and also in mycobacterial infection of the eye and fungal diseases of ocular structures.

Warnings and Precautions:

Delayed Healing and Corneal Perforation: Topical corticosteroids have been known to delay healing and cause corneal and scleral thinning. Use of topical corticosteroids in the presence of thin corneal or scleral tissue may lead to perforation. The initial prescription and each renewal of the medication order should be made by a physician only after examination of the patient with the aid of magnification, such as slit lamp biomicroscopy, and, where appropriate, fluorescein staining.

Intraocular Pressure (IOP) Increase: Prolonged use of corticosteroids may result in glaucoma with damage to the optic nerve, as well as defects in visual acuity and fields of vision. Corticosteroids should be used with caution in the presence of glaucoma. Renewal of the medication order should be made by a physician only after examination of the patient and evaluation of the IOP

Cataracts: Use of corticosteroids may result in posterior subcapsular cataract formation.


EYSUVIS[®]
(loteprednol etabonate
ophthalmic suspension) 0.25%

THE FAST FLARE FIGHTER

Bacterial Infections: Use of corticosteroids may suppress the host response and thus increase the hazard of secondary ocular infections. In acute purulent conditions, corticosteroids may mask infection or enhance existing infection.

Viral Infections: Use of a corticosteroid medication in the treatment of patients with a history of herpes simplex requires great caution. Use of ocular corticosteroids may prolong the course and may exacerbate the severity of many viral infections of the eye (including herpes simplex).

Fungal Infections: Fungal infections of the cornea are particularly prone to develop coincidentally with long-term local corticosteroid application. Fungus invasion must be considered in any persistent corneal ulceration where a corticosteroid has been used or is in use.

Adverse Reactions:

The most common adverse drug reaction following the use of EYSUVIS for two weeks was instillation site pain, which was reported in 5% of patients.

Please see Brief Summary of Prescribing Information for EYSUVIS on the next page.

References: **1.** Holland E, Nichols K, Foulks G, et al. Safety and efficacy of KPI-121 ophthalmic suspension 0.25% for dry eye disease in four randomized controlled trials. Presented at: AAO 2020: November 13-15, 2020; virtual meeting. **2.** Schopf L, Enlow E, Popov A, et al. Ocular pharmacokinetics of a novel loteprednol etabonate 0.4% ophthalmic formulation. *Ophthalmol Ther.* 2014;3(1-2):63-72. **3.** Popov A. Mucus-penetrating particles and the role of ocular mucus as a barrier to micro- and nanosuspensions. *J Ocul Pharmacol Ther.* 2020;36(6): 366-375. **4.** Korenfeld M, Nichols KK, Goldberg D, et al. Safety of KPI-121 ophthalmic suspension 0.25% in patients with dry eye disease: a pooled analysis of 4 multicenter, randomized, vehicle-controlled studies. *Cornea.* 2020. In press.

**EYSUVIS (loteprednol etabonate ophthalmic suspension) 0.25%,
for topical ophthalmic use**

BRIEF SUMMARY OF FULL PRESCRIBING INFORMATION

INDICATIONS AND USAGE

EYSUVIS is a corticosteroid indicated for the short-term (up to two weeks) treatment of the signs and symptoms of dry eye disease.

CONTRAINDICATIONS

EYSUVIS, as with other ophthalmic corticosteroids, is contraindicated in most viral diseases of the cornea and conjunctiva including epithelial herpes simplex keratitis (dendritic keratitis), vaccinia, and varicella, and also in mycobacterial infection of the eye and fungal diseases of ocular structures.

WARNINGS AND PRECAUTIONS

Delayed Healing and Corneal Perforation—Topical corticosteroids have been known to delay healing and cause corneal and scleral thinning. Use of topical corticosteroids in the presence of thin corneal or scleral tissue may lead to perforation. The initial prescription and each renewal of the medication order should be made by a physician only after examination of the patient with the aid of magnification, such as slit lamp biomicroscopy, and, where appropriate, fluorescein staining.

Intraocular Pressure (IOP) Increase—Prolonged use of corticosteroids may result in glaucoma with damage to the optic nerve, as well as defects in visual acuity and fields of vision. Corticosteroids should be used with caution in the presence of glaucoma. Renewal of the medication order should be made by a physician only after examination of the patient and evaluation of the IOP.

Cataracts—Use of corticosteroids may result in posterior subcapsular cataract formation.

Bacterial Infections—Use of corticosteroids may suppress the host response and thus increase the hazard of secondary ocular infections. In acute purulent conditions of the eye, corticosteroids may mask infection or enhance existing infection.

Viral Infections—Use of corticosteroid medication in the treatment of patients with a history of herpes simplex requires great caution. Use of ocular corticosteroids may prolong the course and may exacerbate the severity of many viral infections of the eye (including herpes simplex).

Fungal Infections—Fungal infections of the cornea are particularly prone to develop coincidentally with long-term local corticosteroid application. Fungus invasion must be considered in any persistent corneal ulceration where a corticosteroid has been used or is in use. Fungal cultures should be taken when appropriate.

Risk of Contamination—Do not allow the dropper tip to touch any surface, as this may contaminate the suspension.

Contact Lens Wear—The preservative in EYSUVIS may be absorbed by soft contact lenses. Contact lenses should be removed prior to instillation of EYSUVIS and may be reinserted 15 minutes following administration.

ADVERSE REACTIONS

Adverse reactions associated with ophthalmic corticosteroids include elevated intraocular pressure, which may be associated with infrequent optic nerve damage, visual acuity and field defects, posterior subcapsular cataract formation, delayed wound healing and secondary ocular infection from pathogens including herpes simplex, and perforation of the globe where there is thinning of the cornea or sclera.

Clinical Trials Experience—Because clinical trials are conducted under widely varying conditions, adverse reaction rates observed in the clinical trials of a drug cannot be directly compared to rates in the clinical trials of another drug and may not reflect the rates observed in practice.

The most common adverse reaction observed in clinical trials with EYSUVIS was instillation site pain, which was reported in 5% of patients.

USE IN SPECIFIC POPULATIONS

Pregnancy—**Risk Summary**: There are no adequate and well controlled studies with loteprednol etabonate in pregnant women. Loteprednol etabonate produced teratogenicity at clinically relevant doses in the rabbit and rat when administered orally during pregnancy. Loteprednol etabonate produced malformations when administered orally to pregnant rabbits at doses 1.4 times the recommended human ophthalmic dose (RHOD) and to pregnant rats at doses 34 times the RHOD. In pregnant rats receiving oral doses of loteprednol etabonate during the period equivalent to the last trimester of pregnancy through lactation in humans, survival of offspring was reduced at doses 3.4 times the RHOD. Maternal toxicity was observed in rats at doses 347 times the RHOD, and a maternal no observed adverse effect level (NOAEL) was established at 34 times the RHOD.

The background risk in the U.S. general population of major birth defects is 2 to 4%, and of miscarriage is 15 to 20%, of clinically recognized pregnancies.

Data—Animal Data: Embryofetal studies were conducted in pregnant rabbits administered loteprednol etabonate by oral gavage on gestation days 6 to 18, to target the period of organogenesis. Loteprednol etabonate produced fetal malformations at 0.1 mg/kg (1.4 times the recommended human ophthalmic dose (RHOD) based on body surface area, assuming 100% absorption). Spina bifida (including meningocele) was observed at 0.1 mg/kg, and exencephaly and craniofacial malformations were observed at 0.4 mg/kg (5.6 times the RHOD). At 3 mg/kg (41 times the RHOD), loteprednol etabonate was associated with increased incidences of abnormal left common carotid artery, limb flexures, umbilical hernia, scoliosis, and delayed ossification. Abortion and embryofetal lethality (resorption) occurred at 6 mg/kg (83 times the RHOD). A NOAEL for developmental toxicity was not established in this study. The NOAEL for maternal toxicity in rabbits was 3 mg/kg/day.

Embryofetal studies were conducted in pregnant rats administered loteprednol etabonate by oral gavage on gestation days 6 to 15, to target the period of organogenesis. Loteprednol etabonate produced fetal malformations, including absent innominate artery at 5 mg/kg (34 times the RHOD); and cleft palate, agnathia, cardiovascular defects, umbilical hernia, decreased fetal body weight and decreased skeletal ossification at 50 mg/kg (347 times the RHOD). Embryofetal lethality (resorption) was observed at 100 mg/kg (695 times the RHOD). The NOAEL for developmental toxicity in rats was 0.5 mg/kg (3.4 times the RHOD). Loteprednol etabonate was maternally toxic (reduced body weight gain) at 50 mg/kg/day. The NOAEL for maternal toxicity was 5 mg/kg.

A peri-/postnatal study was conducted in rats administered loteprednol etabonate by oral gavage from gestation day 15 (start of fetal period) to postnatal day 21 (the end of lactation period). At 0.5 mg/kg (3.4 times the clinical dose), reduced survival was observed in live-born offspring. Doses \geq 5 mg/kg (34 times the RHOD) caused umbilical hernia/incomplete gastrointestinal tract. Doses \geq 50 mg/kg (347 times the RHOD) produced maternal toxicity (reduced body weight gain, death), decreased number of live-born offspring, decreased birth weight, and delays in postnatal development. A developmental NOAEL was not established in this study. The NOAEL for maternal toxicity was 5 mg/kg.

Lactation—There are no data on the presence of loteprednol etabonate in human milk, the effects on the breastfed infant, or the effects on milk production. The developmental and health benefits of breastfeeding should be considered, along with the mother's clinical need for EYSUVIS and any potential adverse effects on the breastfed infant from EYSUVIS.

Pediatric Use—Safety and effectiveness in pediatric patients have not been established.

Geriatric Use—No overall differences in safety and effectiveness have been observed between elderly and younger adult patients.

NONCLINICAL TOXICOLOGY

Carcinogenesis, Mutagenesis, Impairment of Fertility—Long-term animal studies have not been conducted to evaluate the carcinogenic potential of loteprednol etabonate. Loteprednol etabonate was not genotoxic *in vitro* in the Ames test, the mouse lymphoma thymidine kinase (tk) assay, in a chromosome aberration test in human lymphocytes, or *in vivo* in the single dose mouse micronucleus assay. Treatment of male and female rats with 25 mg/kg/day of loteprednol etabonate (174 times the RHOD based on body surface area, assuming 100% absorption) prior to and during mating caused pre-implantation loss and decreased the number of live fetuses/live births. The NOAEL for fertility in rats was 5 mg/kg/day (34 times the RHOD).

**For a copy of the Full Prescribing Information, please visit
www.EYSUVIS.com.**

Manufactured for:
Kala Pharmaceuticals, Inc.
Watertown, MA 02472

Part # 2026R02

Marks designated by [™] or [®] are owned by Kala Pharmaceuticals, Inc.
Patented. www.kalarx.com/patents

© 2020 Kala Pharmaceuticals, Inc. All rights reserved.

October 2020

Kala[®]

US-EYS-2000115

Partnering Ex-U.S.

(Continued from p. 8)

regulatory submissions and meetings in the other country. This can lead to misunderstandings on what exactly is needed by each party, and again highlights the importance of having a plan fleshed out in advance. Think through the specific regulatory requirements in each territory and how they'll be fulfilled.

The process requires an early understanding of the proper project timelines, and an identification of rate-limiting steps, in order to drive the protocol to completion in each territory. Creating a detailed roles-and-responsibilities matrix is useful for such functions as regulatory, clinical, formulation, preclinical, manufacturing (of the active drug, and the finished product), medical writing and submissions.

The clinical plan, of course, needs to closely tie into manufacturing and toxicology. The goal is to arrange things up front in order to avoid potential confusion later. If supplies are coming from one partner, for example, make sure to think through scenarios that could occur if the trial in the ex-United States territory becomes larger, to avoid being caught off-guard with requests for additional supplies of the active drug (powder) or formulated product. In other cases, the partner might have a specific requirement to run a longer study in its country, requiring a longer duration of toxicology.

How different scenarios could impact the supply of the active pharmaceutical product is a critical issue to understand to ensure you've covered different possibilities and potential needs. In a situation in which each partner is responsible for its own manufacturing, make sure vendors understand this in order to avoid overlap and confusion.

Data Sharing and Intellectual Property

A key benefit to development in another territory is the ability to generate more data. Remember, there should be a structure in place for sharing all data, especially safety findings, and a pharmacovigilance plan in place for commercial product so that all parties across different countries have appropriate visibility on safety information. Any work in other areas will need to be summarized and submitted as part of your FDA submission in the United States for meetings, the Investigational New Drug application and, ultimately, the New Drug Application. The sharing will

need to be reciprocal. It's also an opportunity to have discussions with the FDA concerning how much of the data from controlled, randomized trials in other territories could possibly be used to supplement the NDA. In some cases, depending on the demographics and the disease, this may reduce the number of patients needed in the United States. The ex-U.S. partner may perform additional animal work, formulation, etc., and it's wise to ensure you have rights to this information, with considerations regarding your ability to file patent applications in your retained territories, or at least benefit from patent filings in those areas.

We hope this brief column on ex-U.S. development gave you a couple of useful pearls. This is just the tip of the iceberg, however, and the other considerations for these kinds of international deals could fill another article. These special considerations include:

- sub-licensing rights in a territory;
- intellectual property;
- new formulations;
- combination products (and different situations for combination with generic available products vs. internal proprietary compounds one party may have); and
- new incorporation of third-party IP.

The key to the process is to define who is doing what as clearly and specifically as possible. Of course, one also needs to balance all this with deal momentum and the fact that, in drug and device development, things often don't go as planned, and there may need to be adjustments and amendments. It all begins with a solid working relationship and partnership.

Mr. Chapin is a senior vice president of the Asset Development & Partnering Group at Ora, which offers drug, biologic and device consulting; preclinical and clinical research execution; and development strategy and support, in an effort to promote new client and partner initiatives. Review and comments on this column were provided by Aron Shapiro, partner in the same group at Ora. The author welcomes your comments or questions regarding product development. Please send correspondence to mchapin@oraclinical.com or visit oraclinical.com.

1. Independent research report prepared by Research and Markets. Ophthalmology Drugs Global Market Report 2021: COVID-19 Impact and Recovery to 2030.

Residual Astigmatism After Surgery

(Continued from p. 5)

up a notch."

The second take-home point from the study was more surprising, because it dealt with sphere in postop visual acuity and intraocular lens selection, rather than simply astigmatism.

"In an analysis that was done looking at the role of sphere, the interesting part is that we as surgeons have a tendency to select an IOL on the myopic side of things," he notes. "In other words, if we have a choice, we often straddle zero on the myopic side. For instance, if you have to decide if you want to implant a 20-D lens that'll make the patient +0.20 or a 20.5-D lens that'll make him -0.34, there's a tendency to choose the lens that leaves the patient on the minus side (of course, this is for an eye in which you want to hit emmetropia). So, we tend to select the lens that straddles zero on the minus side. This study, however, showed that, in those types of situations, you're definitely better off on the hyperopic side than the myopic."

In the study, with monofocal IOLs, the odds ratio of not achieving 20/20 uncorrected postop with 0.25 to 0.50 D of residual hyperopic sphere was 1.1, vs. an odds ratio of 5.3 with the same amount of residual myopic sphere ($p < 0.0001$). With multifocal lenses, at that low level of postop sphere, the odds ratios of not seeing 20/20 were 1.1 (hyperopic sphere) and 5 (myopic) ($p < 0.0001$).

"This was a very unique, interesting finding," Dr. Schallhorn says. "It's kind of understandable if you're putting in a MF lens, because they have near adds that the patients can work through. If you're myopic, distance is blurred no matter what. You have too much optical power. That's a factor, and also applies for monofocals. And the refraction is in minus cylinder, so any residual astigmatism will come into play also."

(Continued on p. 28)

SafeSite™

Single-Use Instruments

REDUCE RISK

- Improved safety for patients and staff
- Sterile / No cross-contamination
- Reduced risk and liability

SAVE TIME & MONEY

- Reduced surgical prep times
- No reprocessing or sterilization
- No risk of loss or damage

RELIABLE

- Always a new instrument
- Consistent procedure to procedure
- No maintenance required



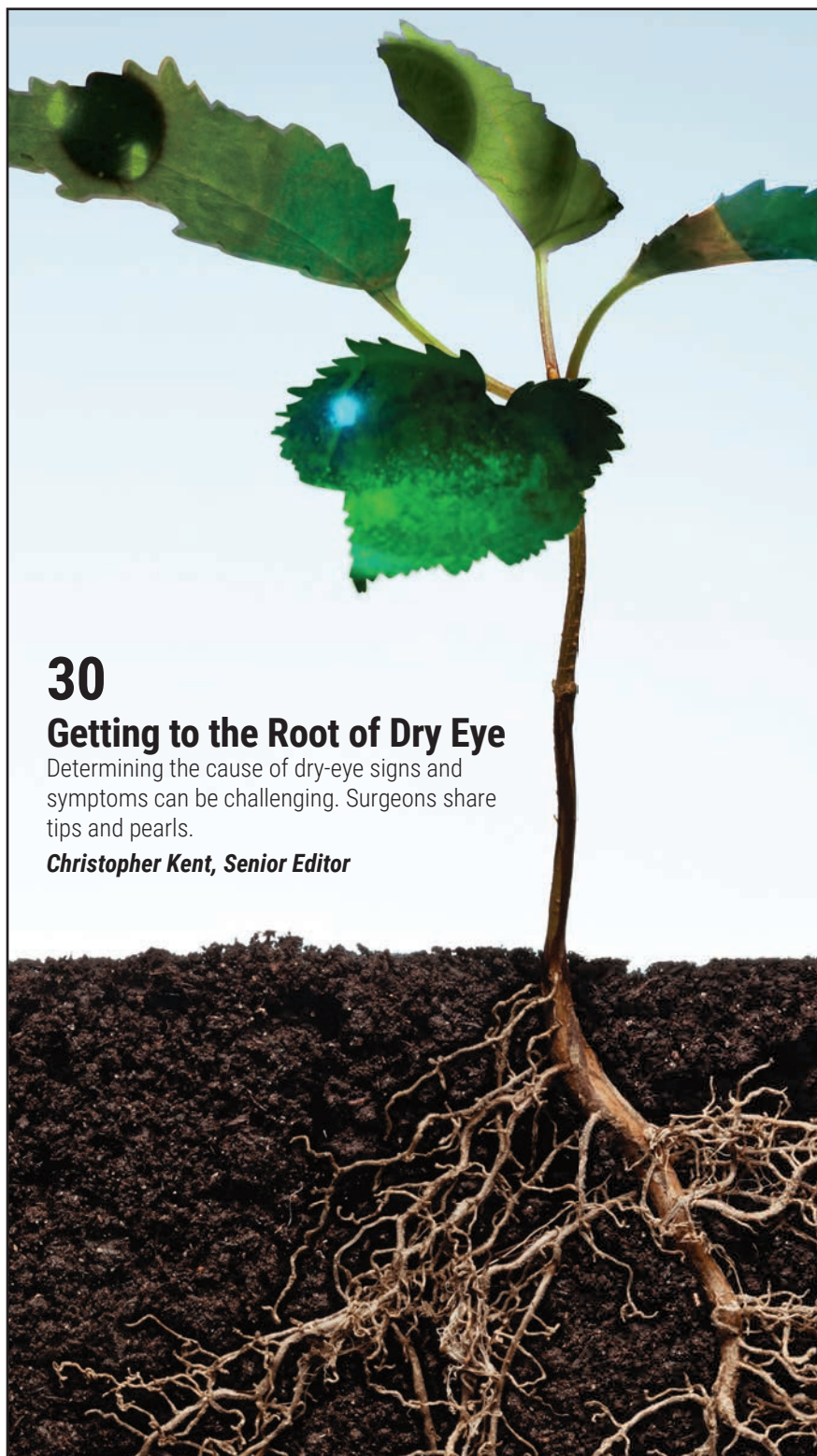
Contact a Stephens Sales Rep.
to discuss your needs today!



FEATURES

Vol. 28, No. 9 • SEPTEMBER 2021

Catch Up on the Latest News
Read *Review's* weekly newsletter
online at reviewofophthalmology.com.



30 Getting to the Root of Dry Eye

Determining the cause of dry-eye signs and symptoms can be challenging. Surgeons share tips and pearls.

Christopher Kent, Senior Editor

38 Approaches and Methods for Treating Dry Eye: 2021

As the population of dry-eye patients continues to grow, so do the available options for intervention.

Leanne Spiegle, Associate Editor

48 Why Surgeons Are Peeling Fewer ERMs

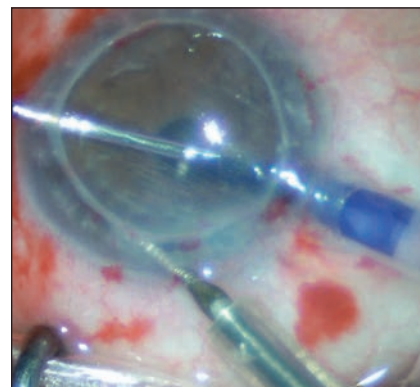
Watchful waiting is now often putting this procedure on hold. Veteran vitreoretinal surgeons explain what's critical for you to know.

Sean McKinney, Senior Editor

54 Expanding Your Keratoplasty Repertoire

A round-up of the most recent innovations in corneal transplantation.

*Christine Leonard
Senior Associate Editor*

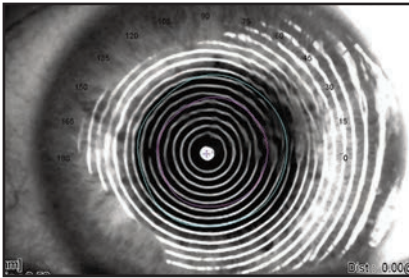


DEPARTMENTS

SEPTEMBER 2021

5 News

16 Editor's Page (Pre)Certifiably Annoying *Walter Bethke, Editor in Chief*



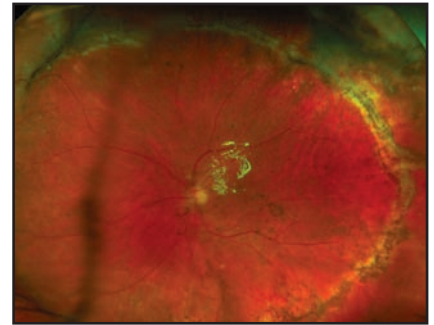
19 REFRACTIVE/CATARACT RUNDOWN Responding to Refractive Surprises Helpful tips on how to proceed when the first eye catches you off guard. *Sean McKinney, Senior Editor*

25 THE FORUM The Next Generation Musings on life, ophthalmology and the practice of medicine. *Mark H. Blecher, MD, Chief Medical Editor*

26 MEDICARE Q & A A Look at 2021's Mid-year Changes What you need to know about the Quality Payment Program and the proposed Medicare Physician Fee Schedule rule. *Paul M. Larson, MBA, MMSc, COMT, COE, CPC, CPMA*

62 GLAUCOMA MANAGEMENT Managing Bleb Dysesthesia This occasional side effect of trabeculectomy can undermine a patient's quality of life. Here's how to address it. *Elyse J. McGlumphy, MD*

68 CORNEA/ANTERIOR SEGMENT Ocular Surface Tumor Diagnostics Experts evaluate the best imaging modalities for assessing suspicious lesions. *By Mike Zein, MD, MS, Mak Djulbegovic, MSc, Anat Galor, MD, MSPH, Laila E. Teira, MD and Carol L. Karp, MD*



74 RETINAL INSIDER Managing Posterior Segment Injuries Expert tips on how to evaluate and manage open globe injuries to the retina and associated structures. *Elyse Tom, MD and Yewlin E. Chee, MD*

79 WILLS EYE RESIDENT CASE SERIES An Elderly Man Presents With Chronic Scleritis *Sarah Amanullah, MD, J.P. Dunn, MD, and Adam DeBusk, MD*

81 CLASSIFIEDS & AD INDEX

 VISIT US ON SOCIAL MEDIA

Facebook www.facebook.com/RevOphth
Twitter twitter.com/RevOphth

BE THE



TO ENGAGE PATIENTS & PROPEL YOUR PRACTICE

Caring for your patients. Thriving as a business. That's what matters. And to make that happen, you need a single integrated technology platform—not disparate solutions. Better workflows. Revenue capture. Claims and insurance processing. Interoperability. Plus... a superior way to engage with patients. All from one trusted source, who will be there for the life of your practice.

See what an integrated technology platform can do for you: NextGen.com/1-opth

BELIEVE IN BETTER.®

© 2021 NXGN Management, LLC. All Rights Reserved. NextGen is a registered trademark of NXGN Management, LLC. All other names and marks are the property of their respective owners.



nextgen
healthcare

Editor in Chief

Walter Bethke
(610) 492-1024
wbethke@jobson.com

Senior Editor

Christopher Kent
(212) 274-7031
ckent@jobson.com

Senior Editor

Sean McKinney
(610) 492-1025
semckinney@jobson.com

Senior Associate Editor

Christine Leonard
(610) 492-1008
cleonard@jobson.com

Chief Medical Editor

Mark H. Blecher, MD

Senior Art Director

Jared Araujo
(610) 492-1032
jaraujo@jobson.com

Senior Graphic Designer

Matt Egger
(610) 492-1029
megger@jobson.com

International coordinator, Japan

Mitz Kaminuma
Reviewophthalgo@aol.com

Business Offices

19 Campus Boulevard, Suite 101
Newtown Square, PA 19073
(610) 492-1000
Fax: (610) 492-1039

Subscription inquiries:

United States – (877) 529-1746
Outside U.S. – (845) 267-3065
E-mail:
revophthalmology@cambeywest.com
Website: www.reviewofophthalmology.com



WALTER C. BETHKE, EDITOR IN CHIEF

EDITOR'S PAGE

(Pre) Certifiably Annoying

In the spring, Aetna surprised ophthalmologists by announcing that cataract surgery would, as of July 1, require the insurer's pre-certification before surgeons could perform it. In a subsequent message to its providers, Aetna said the move was made because it "helps our members avoid unnecessary surgery." When pressed on this, the company cited that 4 to 5 percent of cataract surgeries were unnecessary, a number that's about 2 to 3 percentage points above what ophthalmologists estimate it to be.¹

Aetna's impressions of ophthalmologists' approach to surgery doesn't jibe with the one I've formed over the years; instead of avidly performing unnecessary surgeries, ophthalmic surgeons do everything they can to avoid invasive treatments. For examples of this, look no further than this month's articles.

In this month's feature on retina specialists' approach to epiretinal membranes (p. 48), these physicians are very circumspect when it comes to peeling, and look at the problem from every possible angle before going into the OR. "To me, though, a patient's symptoms and the impact of ERM on his or her activities of daily living are much more important than a specific visual acuity threshold," says Houston retina specialist Charles Wykoff. "If patients are bothered by their vision, and I think it's attributable to an ERM, then I believe it's reasonable to consider mentioning surgery to them. If they aren't bothered by the ERM, then I typically leave it alone,

even if their vision is decreased. It's hard to make asymptomatic patients happier."

Likewise, cornea specialists are actively working on alternatives to performing traditional endothelial transplants, as illustrated by the feature on p. 54. In the technique known as Descemet's Stripping Only, which is mainly useful in patients with Fuchs' endothelial corneal dystrophy, the surgeon removes the central diseased area, and the healthy peripheral endothelial cells shift to help clear the cornea. And insurers should be really happy about one particular aspect of the surgery: "It's also a cost-effective surgery because there's no expensive corneal tissue involved," says NYU corneal specialist Kathryn Colby, MD, PhD.

The other corneal transplant approach, pioneered by Kyoto, Japan's, Shigeru Kinoshita, MD, PhD, is another minimally-invasive procedure in which cultured human corneal endothelial cells are simply injected into the anterior chamber. The cells then migrate to where they need to be on the cornea. So far, the results are promising.

In the end, let's hope that Aetna and other insurers take a step back and get to know the specialty of ophthalmology that you and I are familiar with, rather than the one on their balance sheets.

— *Walter Bethke*
Editor in Chief

1. Aetna's Prior Authorization Plan Spawns Opposition. Review of Ophthalmology Aug 2021;5.

Neurotrophic keratitis is a degenerative disease that warrants immediate attention¹

oxervate® 
(cenegermin-bkbj ophthalmic solution) 0.002% (20 mcg/mL)

OXERVATE is the first FDA-approved pharmacologic treatment that targets the root pathogenesis of neurotrophic keratitis (NK)²

Cenegermin-bkbj, the active ingredient in FDA-approved OXERVATE, is structurally identical to the human nerve growth factor (NGF) protein made in ocular tissues.³

Endogenous NGF is a protein involved in the differentiation and maintenance of neurons and is believed to support corneal integrity through three mechanisms (in preclinical models): corneal innervation, tear secretion, and epithelial cell growth.³⁻⁵

In clinical studies, with a single 8-week course of therapy:

- Up to 72% of patients with NK achieved complete corneal healing^{*†2}
- 80% of patients who achieved complete corneal healing remained completely healed at 1 year (REPARO trial)⁶

OXERVATE is a recombinant human nerve growth factor indicated for the treatment of neurotrophic keratitis.

Important Safety Information

WARNINGS AND PRECAUTIONS

Patients should remove contact lenses before applying OXERVATE and wait 15 minutes after instillation of the dose before reinsertion.

ADVERSE REACTIONS

The most common adverse reaction in clinical trials that occurred more frequently with OXERVATE was eye pain (16% of patients). Other adverse reactions included corneal deposits, foreign body sensation, ocular hyperemia, ocular inflammation, and increase in tears (1%-10% of patients).

Please see additional Important Safety Information on accompanying page and full Prescribing Information, including patient information, at [OXERVATE.com/prescribing-information](https://www.oxervate.com/prescribing-information).

You may report side effects to FDA at 1-800-FDA-1088 or www.fda.gov/medwatch. You may also report side effects to Dompé at 1-833-366-7387 or Usmedinfo@dompe.com.

 **TREAT NK TODAY**
[OXERVATE.com/HCP](https://www.oxervate.com/HCP)

*Study NGF0212 (REPARO): 52 patients per group; European patients with NK in one eye; 72% of patients completely healed; key findings were after 8 weeks of treatment; 6 times daily; vehicle response rate 33.3%.² Study NGF0214: 24 patients per group; US patients with NK in one or both eyes; 65.2% completely healed; vehicle response rate 16.7%.^{2,7}

†Complete corneal healing was defined as the absence of staining of the corneal lesion and no persistent staining in the rest of the cornea after 8 weeks of OXERVATE treatment.²

References: 1. Sacchetti M, Lambiase A. Diagnosis and management of neurotrophic keratitis. *Clin Ophthalmol*. 2014;8:571-579. 2. OXERVATE (cenegermin-bkbj) ophthalmic solution 0.002% (20 mcg/mL) [US package insert]. Boston, MA: Dompé U.S. Inc.; 2019. 3. Voelker R. New drug treats rare, debilitating neurotrophic keratitis. *JAMA*. 2018;320:1309. 4. Mastropasqua L, Massaro-Giordano G, Nubile M, Sacchetti M. Understanding the pathogenesis of neurotrophic keratitis: the role of corneal nerves. *J Cell Physiol*. 2017;232:717-724. 5. Muzi S, Colafrancesco V, Somelli F, et al. Nerve growth factor in the developing and adult lacrimal glands of rat with and without inherited retinitis pigmentosa. *Cornea*. 2010;29:1163-1168. 6. Data on file. Dompé U.S. Inc.; 2021. NGF0212. 7. Pflugfelder SC, Massaro-Giordano M, Perez VL, Hamrah P, Deng SX, Espandar L, et al. Topical recombinant human nerve growth factor (cenegermin) for neurotrophic keratopathy. *Ophthalmology*. 2020;127:14-26.



Brief Summary of Safety

Consult the full Prescribing Information for complete product information.

INDICATIONS AND USAGE

OXERVATE™ (cenegermin-bkbj) ophthalmic solution 0.002% is indicated for the treatment of neurotrophic keratitis.

DOSAGE AND ADMINISTRATION

Contact lenses should be removed before applying OXERVATE and may be reinserted 15 minutes after administration.

If a dose is missed, treatment should be continued as normal, at the next scheduled administration.

If more than one topical ophthalmic product is being used, administer the eye drops at least 15 minutes apart to avoid diluting products. Administer OXERVATE 15 minutes prior to using any eye ointment, gel or other viscous eye drops.

Recommended Dosage and Dose Administration

Instill one drop of OXERVATE in the affected eye(s), 6 times a day at 2-hour intervals for eight weeks.

ADVERSE REACTIONS

Clinical Studies Experience Because clinical studies are conducted under widely varying conditions, adverse reaction rates observed in the clinical studies of a drug cannot be directly compared to rates in the clinical studies of another drug and may not reflect the rates observed in practice.

In two clinical trials of patients with neurotrophic keratitis, a total of 101 patients received cenegermin-bkbj eye drops at 20 mcg/mL at a frequency of 6 times daily in the affected eye(s) for a duration of 8 weeks. The mean age of the population was 61 to 65 years of age (18 to 95). The majority of the treated patients were female (61%). The most common adverse reaction was eye pain following instillation which was reported in approximately 16% of patients. Other adverse reactions occurring in 1-10% of OXERVATE patients and more frequently than in the vehicle-treated patients included corneal deposits, foreign body sensation, ocular hyperemia, ocular inflammation and tearing.

USE IN SPECIFIC POPULATIONS

Pregnancy

Risk Summary There are no data from the use of OXERVATE in pregnant women to inform any drug associated risks.

Administration of cenegermin-bkbj to pregnant rats or rabbits during the period of organogenesis did not produce adverse fetal effects at clinically relevant doses. In a pre- and postnatal development study, administration of cenegermin-bkbj to pregnant rats throughout gestation and lactation did not produce adverse effects in offspring at clinically relevant doses.

Animal Data

In embryofetal development studies, daily subcutaneous administration of cenegermin-bkbj to pregnant rats and rabbits throughout the period of organogenesis produced a slight increase in post-implantation loss at doses greater than or equal to 42 mcg/kg/day (267 times the MRHOD). A no observed adverse effect level (NOAEL) was not established for post-implantation loss in either species.

In rats, hydrocephaly and ureter anomalies were each observed in one fetus at 267 mcg/kg/day (1709 times the MRHOD). In rabbits, cardiovascular malformations, including ventricular and atrial septal defects, enlarged heart and aortic arch dilation were each observed in one fetus at 83 mcg/kg/day (534 times the MRHOD). No fetal malformations were observed in rats and rabbits at doses of 133 mcg/kg/day and 42 mcg/kg/day, respectively. In a pre- and postnatal development study, daily subcutaneous administration of cenegermin-bkbj to pregnant rats during the period of organogenesis and lactation did not affect parturition and was not associated with adverse toxicity in offspring at doses up to 267 mcg/kg/day. In parental rats and rabbits, an immunogenic response to cenegermin-bkbj was observed. Given that cenegermin-bkbj is a heterologous protein in animals, this response may not be relevant to humans.

Lactation

There are no data on the presence of OXERVATE in human milk, the effects on breastfed infant, or the effects on milk production. The developmental and health benefits of breastfeeding should be considered, along with the mother's clinical need for OXERVATE, and any potential adverse effects on the breastfed infant from OXERVATE.

Pediatric Use

The safety and effectiveness of OXERVATE have been established in the pediatric population. Use of OXERVATE in this population is supported by evidence from adequate and well-controlled trials of OXERVATE in adults with additional safety data in pediatric patients from 2 years of age and older [see *Clinical Studies* (14)].

Geriatric Use

Of the total number of subjects in clinical studies of OXERVATE, 43.5 % were 65 years old and over. No overall differences in safety or effectiveness were observed between elderly and younger adult patients.

NONCLINICAL TOXICOLOGY

Carcinogenesis and Mutagenesis Animal studies have not been conducted to determine the carcinogenic and mutagenic potential of cenegermin-bkbj.

Impairment of fertility Daily subcutaneous administration of cenegermin-bkbj to male and female rats for at least 14 days prior to mating, and at least 18 days post-coitum had no effect on fertility parameters in male or female rats at doses up to 267 mcg/kg/day (1709 times the MRHOD). In general toxicology studies, subcutaneous and ocular administration of cenegermin-bkbj in females was associated with ovarian findings including persistent estrus, ovarian follicular cysts, atrophy/reduction of corpora lutea, and changes in ovarian weight at doses greater than or equal to 19 mcg/kg/day (119 times the MRHOD).





EDITED BY ARTURO CHAYET, MD

REFRACTIVE/CATARACT RUNDOWN

Responding to Refractive Surprises

Helpful tips on how to proceed when the first eye catches you off guard.

SEAN MCKINNEY
SENIOR EDITOR

Cataract surgeons have been trying to avoid, or at least minimize, off-target first-eye outcomes for decades. To this day, however, none can point to textbook solutions that work on every patient. “Things are different today than they were 10 to 15 years ago, when we didn’t have multifocals or the femtosecond laser,” says Doug Grayson, MD, a cataract and glaucoma surgeon at Omni Ophthalmic Management Consultants, a multi-practice group headquartered in Iselin, New Jersey. “We didn’t use PRK for postop touch-ups, and patients weren’t paying for lenses. Therefore, patients didn’t have the same level of precise expectations.” Dr. Grayson and other surgeons also point to an evolving environment—highlighted by new technology, lens-calculation formulas and insights on pathology—that continues to raise the bar surgeons need to meet.

“We’re trying to predict on an order of millimeters how the lens implant will settle within the eye’s capsular bag,” says Jesse Richman, MD, a cataract surgeon at the Kremen Eye Center in Cherry Hill, New Jersey. “If the postoperative effective lens position is a smidge to the left,

you could have more of a myopic result than you intended. If you go a smidge to the right, a hyperopic result. It’s so miniscule, but that’s what can make a difference that’ll produce a result that you and your patient don’t want.”

What are your first steps when confronted by a refractive surprise? These and other surgeons may help you consider new ones by sharing their strategies in this report.

Strategies to Consider

Kathryn M. Hatch, MD, director of the refractive surgery service at Massachusetts Eye & Ear, and an assistant professor of ophthalmology at Harvard Medical School, says she avoids rushing to conclusions about a refractive surprise.

“When the eye’s healed, then you can tell if you have a true refractive surprise,” she says. “You want to make sure your biometry and other preoperative measurements were ideal. If you don’t have good biometry—if the eye’s dry or some other issue is a factor—that may be affecting your outcome.”

Dr. Hatch also revisits the formula she’s used, considers the implications of long and short eyes and determines if previous refractive surgery might be affecting her results. “I also look for consistency,” she says. “I want

to confirm that my IOLMaster 700 measurements reflect tight numbers, rather than, say, three different axes for astigmatism. All of my patients undergo corneal topography and an OPD-III scan. The mire rings on the scan can confirm consistent keratometry values and tell me, for example, if dry eye is a factor, reflected in spots on the rings.” (See Figure 1 on page 20.)

Dr. Hatch also relies on intraoperative aberrometry, using the Optiwave Refractive Analysis System (Alcon), to safeguard against surprises. “ORA is important,” she says. “Not only does it provide extra measurements I can compare to preop measurements while the patient’s still phakic on the table, it offers real-time measurements that include the incision and everything else that I’ve done to the eye up to that point.”

In the event of a refractive surprise, Dr. Hatch mines her data and typically identifies one revealing measurement that influences her approach to the second eye. “If you’re trying to target a different distance but the patient ends up somewhat nearsighted, there may be some advantages to proceeding with the second eye,” she says. “I tell the patient that we can go back and do something with the first eye, if that becomes necessary.”

She establishes realistic preop expectations for her patient, especially if she’ll be working on a post-refractive-surgery eye or implanting a premium IOL. “It’s important to keep in mind that patients receiving premium lenses want near correction,” she notes. “After standard cataract surgery, a refractive surprise may not be a big deal to the patient who expects to wear glasses anyway.”

Customized Lens Constants

Like most surgeons, Dr. Hatch

This article has no commercial sponsorship.

Dr. Chayet is considered a pioneer in refractive and cataract surgery, and is the medical director of the Codet Vision Institute in Tijuana, Mexico. He is a clinical investigator for RxSight, LensGen and ForSight Vision6.

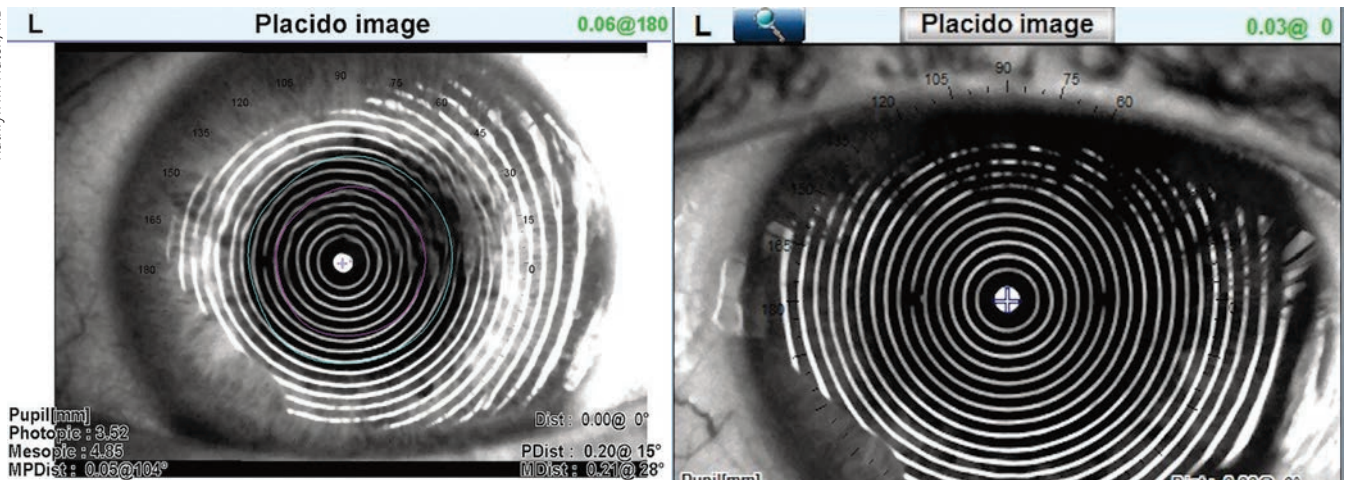


Figure 1. The placido image of an OPD-Scan III shown on the left reveals the likely cause of a post-cataract-surgery patient's refractive surprise—the wavy rings of dry eye, compared to the normal presentation of rings shown in the image to the right.

makes a patient-specific lens-constant adjustment or a formula-specific adjustment. “How I proceed depends on the eye,” she says. “We use our formula to determine where we think the effective lens position will be, but sometimes it doesn’t end up where we expect it to be. Often, that’s why we get refractive surprises. We also have outliers who don’t necessarily follow the formula. They might end up minus when I was targeting them at plano. I may target the next eye a little more plus so I can get them closer to plano with the second eye. Highly myopic patients with long eyes will typically end up better off a little nearsighted, as opposed to a patient who’s extremely farsighted who won’t like that adjustment. So your response is going to be determined by the type of surprise and patient.”

For patients who’ve undergone RK or high-myopic/high-hyperopic LASIK, she notes that the eyes tend to be highly aberrated and extra challenging. “They may take longer to recover, and surgery sometimes results in a refractive surprise,” she says. “Unfortunately, a lot of these patients are used to having really good vision, so they have very high expectations for their postop vision.”

When the First Lens Must Go

Dr. Grayson says he almost always feels compelled to exchange the lens in the first eye after a refractive surprise. “I think the more modern viewpoint is not to necessarily deal with the second eye differently than the first eye, but to deal with the first eye to get it optimal, meeting the patient’s expectations,” he says. “When a patient isn’t completely happy with the first eye, I’ve found that it’s very difficult to tell that patient, ‘Okay. We’ll just take care of that with the second eye.’”

Some surgeons try to avoid lens exchanges and take simple problem-solving approaches. Dr. Richman describes a recent example in his practice involving a 77-year-old male with a 3+ cataract and BCVA of 20/100. “On the IOLMaster 700, an IOL with a power of 18 D appeared to be the best option for this patient,” he explains. (See *Figure 2 on page 21.*) “According to the formula I used, I expected a result of -0.16, or as close to 20/20 as I could get. If I had put in a 19-D lens and the formula was correct, the patient would’ve ended up with -0.81, meaning more near vision but distance vision that wasn’t as sharp.”

After removing the cataract from the right eye without complications, he discovered the following mani-

fest refraction: +0.50 -0.50 x 65 (SE +0.25). “With a spherical equivalent of +0.25, I’d missed by +0.41 D,” he notes. “Some surgeons facing this type of error might say, ‘Let me take the full amount by which I was off and apply it as a fudge factor, or personalized A-constant, to the other eye,’ concluding that they’ll be off by the same amount in the second eye if they don’t use this fudge factor. However, most of the peer-reviewed papers on this type of postoperative challenge recommend that you correct for about half of your error.”

With this guideline in mind, he implanted a 19-D IOL in his patient’s left eye, even though his IOLMaster 700 reading on that eye suggested he could implant an 18.5-D lens to achieve a +0.04 D result. “However, I’d missed by +0.41 D on the right eye, and the IOLMaster was telling me a 19-D lens would get me to -0.30, which meant I would get pretty close to the same error and, therefore, I should get close to zero using the 19-D lens,” explains Dr. Richman. The postop manifest refraction—proving him right—was +0.25 -0.50 x 30 (SE plano).

“This is just how I do it,” he says. “Because lenses come in half-diopter increments, sometimes you just

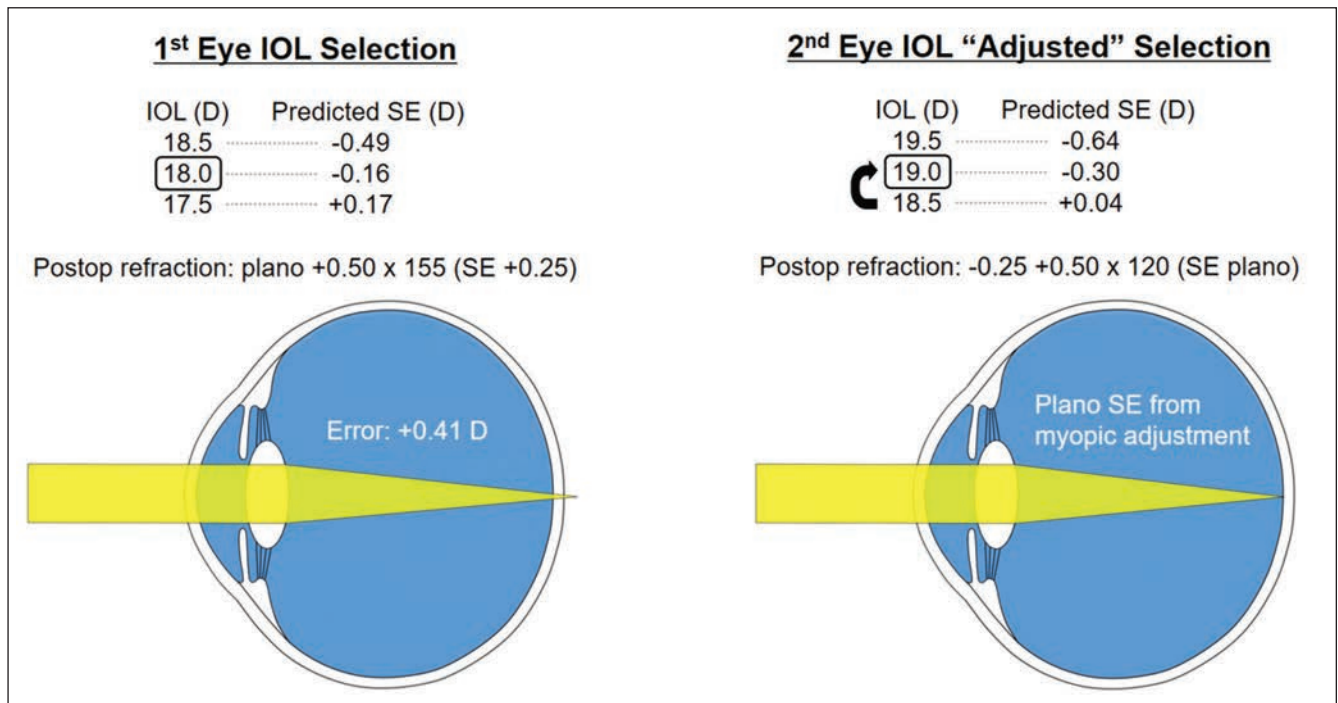


Figure 2. For this patient’s first eye (left), an 18-D IOL was selected, based on a formula that predicted postop vision with a spherical equivalent of -0.16. As shown, however, the postop refraction revealed a hyperopic error of +0.41 D. To compensate for the error, an 19-D IOL was selected for the second eye, despite the prediction by the formula that an 18.5-D lens would get the patient closer to plano. This adjustment worked, resulting in a postop SE of plano.

have to decide what makes the most sense.”

Systematic Approaches

Thomas Chi, MD, a Northeast Ohio surgeon at Midwest Vision Partners in Medina, Ohio, categorizes refractive surprise patients as follows:

- 1. truly unhappy;
- 2. slightly disappointed but potentially accepting; and
- 3. indifferent and seemingly satisfied.

“The truly unhappy patient may require surgical intervention, such as corneal refractive surgery (LASIK, PRK), an IOL exchange or a piggy-back IOL,” he says.

He groups the potential causes of surprise into three categories:

- An error could have affected data input or communications among surgical team members.
- Ocular conditions, such as corneal surface disease (including dry-eye disease, anterior basement membrane disease, superficial punctate keratitis and keratoconus), retinal conditions

(such as epiretinal membrane and staphylomas) or compromised zonular integrity (pseudoexfoliation) could be implicated. “Ocular surface conditions need to be treated before taking any repeat measurements of the second eye,” he adds.

- Imprecise biometry and keratometry measurements must be considered. “We’ve used many of the biometry checklists (axial length, keratometry, etc.) of Warren Hill, MD, and others to confirm that certain biometry data fall within a certain range and in line with the other eye,” he explains. “We limit the number of staff members who perform these measurements to avoid variabilities.”

Since optimizing their A-constants with IOLMaster 700’s biometry, Dr. Chi says he and his colleagues lean toward using patient-based adjustments with the same surgical technique—while striving to achieve the following during the second surgery:

- performing a capsulorhexis of 5 to 5.5 mm to enable a sufficient circumference overlapping the rhexis

with a 6-mm optic, after completion of irrigation and wound hydration; and

- minimizing zonular stress, using effective hydrodissection and/or delamination while employing a phaco tilt technique or femtosecond laser lens fragmentation.

If the target is an emmetropic result and a patient ends up myopic (-0.75 to -1.25 D) or if the target is slight myopia and the patient ends up emmetropic, Dr. Chi says he places an appropriately powered contact lens over the first eye and shows the patient how the intended result would appear.

“Sometimes the patient changes his or her mind and prefers to leave the unintended vision as it is,” says Dr. Chi. “When it comes to refractive surprises, as always, what works can vary widely.” ◀

DISCLOSURES

Dr. Hatch is a consultant for Johnson & Johnson Vision. None of the other interviewed surgeons have relationships with makers of products mentioned in this article.

WHAT COULD SHE SEE THIS YEAR?

 **EYLEA**[®]
(aflibercept) Injection
For Intravitreal Injection



**304
BINGO
CARDS**

*Inspired by a real patient
with Wet AMD.*

IMPORTANT SAFETY INFORMATION CONTRAINDICATIONS

- EYLEA is contraindicated in patients with ocular or periocular infections, active intraocular inflammation, or known hypersensitivity to aflibercept or to any of the excipients in EYLEA.

WARNINGS AND PRECAUTIONS

- Intravitreal injections, including those with EYLEA, have been associated with endophthalmitis and retinal detachments. Proper aseptic injection technique must always be used when administering EYLEA. Patients should be instructed to report any symptoms suggestive of endophthalmitis or retinal detachment without delay and should be managed appropriately. Intraocular inflammation has been reported with the use of EYLEA.
- Acute increases in intraocular pressure have been seen within 60 minutes of intravitreal injection, including with EYLEA. Sustained increases in intraocular pressure have also been reported after repeated intravitreal dosing with VEGF inhibitors. Intraocular pressure and the perfusion of the optic nerve head should be monitored and managed appropriately.
- There is a potential risk of arterial thromboembolic events (ATEs) following intravitreal use of VEGF inhibitors, including EYLEA. ATEs are defined as nonfatal stroke, nonfatal myocardial infarction, or vascular death (including deaths of unknown cause). The incidence of reported thromboembolic events in wet AMD studies during the first year was 1.8% (32 out of 1824) in the combined group of patients treated with EYLEA compared with 1.5% (9 out of 595) in patients treated with ranibizumab; through 96 weeks, the incidence was 3.3% (60 out of 1824) in the EYLEA group compared with 3.2% (19 out of 595) in the ranibizumab group. The incidence in the DME studies from baseline to week 52 was 3.3% (19 out of 578) in the combined group of patients treated with EYLEA compared with 2.8% (8 out of 287) in the control group; from baseline to week 100, the incidence was 6.4% (37 out of 578) in the combined group of patients treated with EYLEA compared with 4.2% (12 out of 287) in the control group. There were no reported thromboembolic events in the patients treated with EYLEA in the first six months of the RVO studies.

EYLEA is a registered trademark of Regeneron Pharmaceuticals, Inc.

REGENERON

© 2021, Regeneron Pharmaceuticals, Inc. All rights reserved.
777 Old Saw Mill River Road, Tarrytown, NY 10591

PROVEN VISUAL OUTCOMES AT YEAR 1 IN THE VIEW STUDIES

Fewer injections with EYLEA Q8 vs ranibizumab Q4

Demonstrated in the largest phase 3 anti-VEGF trials completed to date in Wet AMD (N=2412)¹⁻³

Proportion of patients who maintained vision (<15 ETDRS letters lost of BCVA) at Year 1 from baseline^{1-3,*}

	Primary Endpoint (Year 1)	
	VIEW 1	VIEW 2
EYLEA Q4	95% (12.5 injections [†])	95% (12.6 injections [†])
EYLEA Q8 [‡]	94% (7.5 injections [†])	95% (7.7 injections [†])
ranibizumab Q4	94% (12.1 injections [†])	95% (12.7 injections [†])

*Last observation carried forward; full analysis set.

[†]Safety analysis set.

[‡]Following 3 initial monthly doses.



Vision was maintained at Year 1 with ≈5 fewer injections with EYLEA Q8 vs ranibizumab Q4

EYLEA was clinically equivalent to ranibizumab.

VIEW 1 and VIEW 2 study designs: Two multicenter, double-masked clinical studies in which patients with Wet AMD (N=2412; age range: 49-99 years, with a mean of 76 years) were randomized to receive: 1) EYLEA 2 mg Q8 following 3 initial monthly doses; 2) EYLEA 2 mg Q4; 3) EYLEA 0.5 mg Q4; or 4) ranibizumab 0.5 mg Q4. Protocol-specified visits occurred every 28 (±3) days.¹ In both studies, the primary efficacy endpoint was the proportion of patients with Wet AMD who maintained vision, defined as losing <15 letters of visual acuity at Week 52, compared with baseline.¹

SEE WHAT EYLEA COULD DO FOR YOUR PATIENTS WITH WET AMD AT HCP.EYLEA.US

anti-VEGF, anti-vascular endothelial growth factor; BCVA, best-corrected visual acuity; ETDRS, Early Treatment Diabetic Retinopathy Study; Q4, every 4 weeks; Q8, every 8 weeks.

ADVERSE REACTIONS

- Serious adverse reactions related to the injection procedure have occurred in <0.1% of intravitreal injections with EYLEA including endophthalmitis and retinal detachment.
- The most common adverse reactions (≥5%) reported in patients receiving EYLEA were conjunctival hemorrhage, eye pain, cataract, vitreous detachment, vitreous floaters, and intraocular pressure increased.
- Patients may experience temporary visual disturbances after an intravitreal injection with EYLEA and the associated eye examinations. Advise patients not to drive or use machinery until visual function has recovered sufficiently.

INDICATIONS

EYLEA® (aflibercept) Injection 2 mg (0.05 mL) is indicated for the treatment of patients with Neovascular (Wet) Age-related Macular Degeneration (AMD), Macular Edema following Retinal Vein Occlusion (RVO), Diabetic Macular Edema (DME), and Diabetic Retinopathy (DR).

References: 1. EYLEA® (aflibercept) Injection full U.S. Prescribing Information. Regeneron Pharmaceuticals, Inc. August 2019. 2. Data on file. Regeneron Pharmaceuticals, Inc. 3. Heier JS, Brown DM, Chong V, et al; for the VIEW 1 and VIEW 2 Study Groups. Intravitreal aflibercept (VEGF Trap-Eye) in wet age-related macular degeneration. *Ophthalmology*. 2012;119(12):2537-2548. doi:10.1016/j.ophtha.2012.09.006

Please see Brief Summary of Prescribing Information on the following page.

03/2021
EYL.21.02.0019



BRIEF SUMMARY—Please see the EYLEA full Prescribing Information available on HCP.EYLEA.US for additional product information.

1 INDICATIONS AND USAGE

EYLEA is a vascular endothelial growth factor (VEGF) inhibitor indicated for the treatment of patients with:

Neovascular (Wet) Age-Related Macular Degeneration (AMD), Macular Edema Following Retinal Vein Occlusion (RVO), Diabetic Macular Edema (DME), Diabetic Retinopathy (DR).

4 CONTRAINDICATIONS

4.1 Ocular or Periorbital Infections

EYLEA is contraindicated in patients with ocular or periorbital infections.

4.2 Active Intraocular Inflammation

EYLEA is contraindicated in patients with active intraocular inflammation.

4.3 Hypersensitivity

EYLEA is contraindicated in patients with known hypersensitivity to afibercept or any of the excipients in EYLEA. Hypersensitivity reactions may manifest as rash, pruritus, urticaria, severe anaphylactic/anaphylactoid reactions, or severe intraocular inflammation.

5 WARNINGS AND PRECAUTIONS

5.1 Endophthalmitis and Retinal Detachments

Intravitreal injections, including those with EYLEA, have been associated with endophthalmitis and retinal detachments [see *Adverse Reactions* (6.1)]. Proper aseptic injection technique must always be used when administering EYLEA. Patients should be instructed to report any symptoms suggestive of endophthalmitis or retinal detachment without delay and should be managed appropriately [see *Patient Counseling Information* (17)].

5.2 Increase in Intraocular Pressure

Acute increases in intraocular pressure have been seen within 60 minutes of intravitreal injection, including with EYLEA [see *Adverse Reactions* (6.1)]. Sustained increases in intraocular pressure have also been reported after repeated intravitreal dosing with vascular endothelial growth factor (VEGF) inhibitors. Intraocular pressure and the perfusion of the optic nerve head should be monitored and managed appropriately.

5.3 Thromboembolic Events

There is a potential risk of arterial thromboembolic events (ATEs) following intravitreal use of VEGF inhibitors, including EYLEA. ATEs are defined as nonfatal stroke, nonfatal myocardial infarction, or vascular death (including deaths of unknown cause). The incidence of reported thromboembolic events in wet AMD studies during the first year was 1.8% (32 out of 1824) in the combined group of patients treated with EYLEA compared with 1.5% (9 out of 595) in patients treated with ranibizumab; through 96 weeks, the incidence was 3.3% (60 out of 1824) in the EYLEA group compared with 5.2% (19 out of 595) in the ranibizumab group. The incidence in the DME studies from baseline to week 52 was 3.3% (19 out of 578) in the combined group of patients treated with EYLEA compared with 2.8% (8 out of 287) in the control group; from baseline to week 100, the incidence was 6.4% (37 out of 578) in the combined group of patients treated with EYLEA compared with 4.2% (12 out of 287) in the control group. There were no reported thromboembolic events in the patients treated with EYLEA in the first six months of the RVO studies.

6 ADVERSE REACTIONS

The following potentially serious adverse reactions are described elsewhere in the labeling:

- Hypersensitivity [see *Contraindications* (4.3)]
- Endophthalmitis and retinal detachments [see *Warnings and Precautions* (5.1)]
- Increase in intraocular pressure [see *Warnings and Precautions* (5.2)]
- Thromboembolic events [see *Warnings and Precautions* (5.3)]

6.1 Clinical Trials Experience

Because clinical trials are conducted under widely varying conditions, adverse reaction rates observed in the clinical trials of a drug cannot be directly compared to rates in other clinical trials of the same or another drug and may not reflect the rates observed in practice.

A total of 2980 patients treated with EYLEA constituted the safety population in eight phase 3 studies. Among those, 2379 patients were treated with the recommended dose of 2 mg. Serious adverse reactions related to the injection procedure have occurred in <0.1% of intravitreal injections with EYLEA including endophthalmitis and retinal detachment. The most common adverse reactions (≥5%) reported in patients receiving EYLEA were conjunctival hemorrhage, eye pain, cataract, vitreous detachment, vitreous floaters, and intraocular pressure increase.

Neovascular (Wet) Age-Related Macular Degeneration (AMD). The data described below reflect exposure to EYLEA in 1824 patients with wet AMD, including 1223 patients treated with the 2-mg dose, in 2 double-masked, controlled clinical studies (VIEW1 and VIEW2) for 24 months (with active control in year 1). Safety data observed in the EYLEA group in a 52-week, double-masked, Phase 2 study were consistent with these results.

Table 1: Most Common Adverse Reactions (≥1%) in Wet AMD Studies

Adverse Reactions	Baseline to Week 52		Baseline to Week 96	
	EYLEA (N=1824)	Active Control (ranibizumab) (N=595)	EYLEA (N=1824)	Control (ranibizumab) (N=595)
Conjunctival hemorrhage	25%	28%	27%	30%
Eye pain	9%	9%	10%	10%
Cataract	7%	7%	13%	10%
Vitreous detachment	6%	6%	8%	8%
Vitreous floaters	6%	7%	8%	10%
Intraocular pressure increased	5%	7%	7%	11%
Ocular hyperemia	4%	8%	5%	10%
Corneal epithelium defect	4%	5%	5%	6%
Detachment of the retinal pigment epithelium	3%	3%	5%	5%
Injection site pain	3%	3%	3%	4%
Foreign body sensation in eyes	3%	4%	4%	4%
Lacrimation increased	3%	1%	4%	2%
Vision blurred	2%	2%	4%	3%
Intraocular inflammation	2%	3%	3%	4%
Retinal pigment epithelium tear	2%	1%	2%	2%
Injection site hemorrhage	1%	2%	2%	2%
Eyelid edema	1%	2%	2%	3%
Corneal edema	1%	1%	1%	1%
Retinal detachment	<1%	<1%	1%	1%

Less common serious adverse reactions reported in <1% of the patients treated with EYLEA were hypersensitivity, retinal tear, and endophthalmitis.

Macular Edema Following Retinal Vein Occlusion (RVO). The data described below reflect 6 months exposure to EYLEA with a monthly 2 mg dose in 218 patients following central retinal vein occlusion (CRVO) in 2 clinical studies (COPERNICUS and GALILEO) and 91 patients following branch retinal vein occlusion (BRVO) in one clinical study (VIBRANT).

Table 2: Most Common Adverse Reactions (≥1%) in RVO Studies

Adverse Reactions	CRVO		BRVO	
	EYLEA (N=218)	Control (N=142)	EYLEA (N=91)	Control (N=92)
Eye pain	13%	5%	4%	5%
Conjunctival hemorrhage	12%	11%	20%	4%
Intraocular pressure increased	8%	6%	2%	0%
Corneal epithelium defect	5%	4%	2%	0%
Vitreous floaters	5%	1%	1%	0%
Ocular hyperemia	5%	3%	2%	2%
Foreign body sensation in eyes	3%	5%	3%	0%
Vitreous detachment	3%	4%	2%	0%
Lacrimation increased	3%	4%	3%	0%
Injection site pain	3%	1%	1%	0%
Vision blurred	1%	<1%	1%	1%
Intraocular inflammation	1%	1%	0%	0%
Cataract	<1%	1%	5%	0%
Eyelid edema	<1%	1%	1%	0%

Less common adverse reactions reported in <1% of the patients treated with EYLEA in the CRVO studies were corneal edema, retinal tear, hypersensitivity, and endophthalmitis.

Diabetic Macular Edema (DME) and Diabetic Retinopathy (DR). The data described below reflect exposure to EYLEA in 578 patients with DME treated with the 2-mg dose in 2 double-masked, controlled clinical studies (VIVID and VISTA) from baseline to week 52 and from baseline to week 100.

Table 3: Most Common Adverse Reactions (≥1%) in DME Studies

Adverse Reactions	Baseline to Week 52		Baseline to Week 100	
	EYLEA (N=578)	Control (N=287)	EYLEA (N=578)	Control (N=287)
Conjunctival hemorrhage	28%	17%	31%	21%
Eye pain	9%	6%	11%	9%
Cataract	8%	9%	19%	17%
Vitreous floaters	6%	3%	8%	6%
Corneal epithelium defect	5%	3%	7%	5%
Intraocular pressure increased	5%	3%	9%	5%
Ocular hyperemia	5%	6%	5%	6%
Vitreous detachment	3%	3%	8%	6%
Foreign body sensation in eyes	3%	3%	3%	3%
Lacrimation increased	3%	2%	4%	2%
Vision blurred	2%	2%	3%	4%
Intraocular inflammation	2%	<1%	3%	1%
Injection site pain	2%	<1%	2%	<1%
Eyelid edema	<1%	1%	2%	1%

Less common adverse reactions reported in <1% of the patients treated with EYLEA were hypersensitivity, retinal detachment, retinal tear, corneal edema, and injection site hemorrhage. Safety data observed in 269 patients with nonproliferative diabetic retinopathy (NPDR) through week 52 in the PANORAMA trial were consistent with those seen in the phase 3 VIVID and VISTA trials (see Table 3 above).

6.2 Immunogenicity

As with all therapeutic proteins, there is a potential for an immune response in patients treated with EYLEA. The immunogenicity of EYLEA was evaluated in serum samples. The immunogenicity data reflect the percentage of patients whose test results were considered positive for antibodies to EYLEA in immunoassays. The detection of an immune response is highly dependent on the sensitivity and specificity of the assays used, sample handling, timing of sample collection, concomitant medications, and underlying disease. For these reasons, comparison of the incidence of antibodies to EYLEA with the incidence of antibodies to other products may be misleading.

In the wet AMD, RVO, and DME studies, the pre-treatment incidence of immunoreactivity to EYLEA was approximately 1% to 3% across treatment groups. After dosing with EYLEA for 24-100 weeks, antibodies to EYLEA were detected in a similar percentage range of patients. There were no differences in efficacy or safety between patients with or without immunoreactivity.

8 USE IN SPECIFIC POPULATIONS

8.1 Pregnancy

Risk Summary

Adequate and well-controlled studies with EYLEA have not been conducted in pregnant women. Afibercept produced adverse embryofetal effects in rabbits, including external, visceral, and skeletal malformations. A fetal No Observed Adverse Effect Level (NOAEL) was not identified. At the lowest dose shown to produce adverse embryofetal effects, systemic exposures (based on AUC for free afibercept) were approximately 6 times higher than AUC values observed in humans after a single intravitreal treatment at the recommended clinical dose [see *Animal Data*].

Animal reproduction studies are not always predictive of human response, and it is not known whether EYLEA can cause fetal harm when administered to a pregnant woman. Based on the anti-VEGF mechanism of action for afibercept, treatment with EYLEA may pose a risk to human embryofetal development. EYLEA should be used during pregnancy only if the potential benefit justifies the potential risk to the fetus.

All pregnancies have a background risk of birth defect, loss, or other adverse outcomes. The background risk of major birth defects and miscarriage for the indicated population is unknown. In the U.S. general population, the estimated background risk of major birth defects and miscarriage in clinically recognized pregnancies is 2-4% and 15-20%, respectively.

Data

Animal Data

In two embryofetal development studies, afibercept produced adverse embryofetal effects when administered every three days during organogenesis to pregnant rabbits at intravenous doses ≥3 mg per kg, or every six days during organogenesis at subcutaneous doses ≥0.1 mg per kg.

Adverse embryofetal effects included increased incidences of postimplantation loss and fetal malformations, including anasarca, umbilical hernia, diaphragmatic hernia, gastrochisis, cleft palate, ectrodactyly, intestinal atresia, spina bifida, encephalocele, heart and major vessel defects, and skeletal malformations (fused vertebrae, sternbrae, and ribs; supernumerary vertebral arches and ribs; and incomplete ossification). The maternal No Observed Adverse Effect Level (NOAEL) in these studies was 3 mg per kg. Afibercept produced fetal malformations at all doses assessed in rabbits and the fetal NOAEL was not identified. At the lowest dose shown to produce adverse embryofetal effects in rabbits (0.1 mg per kg), systemic exposure (AUC) of free afibercept was approximately 6 times higher than systemic exposure (AUC) observed in humans after a single intravitreal dose of 2 mg.

8.2 Lactation

Risk Summary

There is no information regarding the presence of afibercept in human milk, the effects of the drug on the breastfed infant, or the effects of the drug on milk production/excretion. Because many drugs are excreted in human milk, and because the potential for absorption and harm to infant growth and development exists, EYLEA is not recommended during breastfeeding. The developmental and health benefits of breastfeeding should be considered along with the mother's clinical need for EYLEA and any potential adverse effects on the breastfed child from EYLEA.

8.3 Females and Males of Reproductive Potential

Contraception

Females of reproductive potential are advised to use effective contraception prior to the initial dose, during treatment, and for at least 3 months after the last intravitreal injection of EYLEA.

Infertility

There are no data regarding the effects of EYLEA on human fertility. Afibercept adversely affected female and male reproductive systems in cynomolgus monkeys when administered by intravenous injection at a dose approximately 1500 times higher than the systemic level observed in humans with an intravitreal dose of 2 mg. A No Observed Adverse Effect Level (NOAEL) was not identified. These findings were reversible within 20 weeks after cessation of treatment.

8.4 Pediatric Use

The safety and effectiveness of EYLEA in pediatric patients have not been established.

8.5 Geriatric Use

In the clinical studies, approximately 76% (2049/2701) of patients randomized to treatment with EYLEA were ≥65 years of age and approximately 46% (1250/2701) were ≥75 years of age. No significant differences in efficacy or safety were seen with increasing age in these studies.

17 PATIENT COUNSELING INFORMATION

In the days following EYLEA administration, patients are at risk of developing endophthalmitis or retinal detachment. If the eye becomes red, sensitive to light, painful, or develops a change in vision, advise patients to seek immediate care from an ophthalmologist [see *Warnings and Precautions* (5.1)]. Patients may experience temporary visual disturbances after an intravitreal injection with EYLEA and the associated eye examinations [see *Adverse Reactions* (6)]. Advise patients not to drive or use machinery until visual function has recovered sufficiently.

REGENERON

Manufactured by:
Regeneron Pharmaceuticals, Inc.
777 Old Saw Mill River Road
Tarrytown, NY 10591

Issue Date: 08/2019
Initial U.S. Approval: 2011

Based on the August 2019
EYLEA® (afibercept) Injection full
Prescribing Information.

EYL20.09.0052

EYLEA is a registered trademark of Regeneron Pharmaceuticals, Inc.
© 2020, Regeneron Pharmaceuticals, Inc.
All rights reserved.



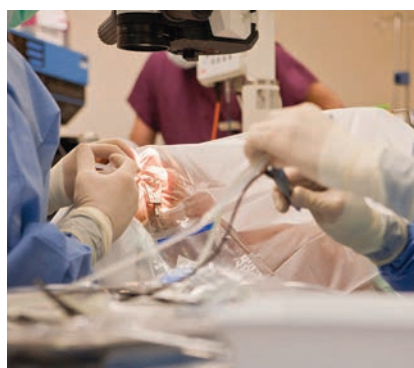
The Next Generation

Musings on life, ophthalmology and the practice of medicine.

MARK H. BLECHER
CHIEF MEDICAL EDITOR

A colleague of mine, an amazing and inspirational surgeon, once said, “You only have so many Julys in you.” He was referencing, of course, the annual changeover of second-year residents to surgical third-year residents and the stress involved with taking new surgeons into the OR. No matter how your local institution handles its resident training, the third and final year of residency is the heavy surgical year. At Wills, we have a large number of surgeons, both academic and in private practice, who participate in the surgical training of our residents. Some have the stomach for July surgery, some don’t. I have not had that concern. Maybe it’s because I have no restraint when it comes to yanking the resident out of the chair should it appear necessary. Patient outcomes shouldn’t take a back seat to teaching. We can do both, but it’s more work. Need it be?

It does bear some discussion of the history and the future of resident surgical education. I remember once worrying that a better medically educated populous would rebel at the idea of surgeons-in-training doing their surgery. An article out of the British NHS a few years ago documented that, when presented with a choice of having their surgery performed by a resident or an attending, patients chose the latter. Not surprising. However, if we teaching attendings are doing our



Getty Images

jobs, should this be an issue?

There has certainly been a lot written about how to train residents to perform surgery, specifically cataract surgery. We owe a debt of gratitude to Uday Devgan and his Cataract Coach series of videos, including his most recent post addressing exactly this topic, as well as to those of you out there in the trenches quietly teaching cataract surgery, resident by resident. But there remains a wide range of opinions on the best and, shall we say, “least traumatic” method to get our new surgeons to a point of competency.

Of course, the tried-and-true approach begins with didactic training, moving on to wet labs, videos and surgical simulators. All of this helps of course, and as we’ve seen at Wills the simulators train certain steps, such as capsulotomy, very well. But a simulator isn’t an eye, and there are many small considerations that only repetition under expert guidance can convey. Many residencies introduce the steps and techniques of surgery one by one, making for

a gradual entry that requires the resident to master each step before moving on. Other programs present the opportunity to do the entire procedure from the get go. Which is better? We really don’t know. And better for whom? The resident? The attending? The patient? How do we achieve the ideal balance?

It’s a tough question, and one that likely we’ll never answer since there are so many variables at play. Every patient and cataract is different, so quantity is essential in order for residents to get a broad experience of what they’ll face in practice. Every attending is different in teaching style and effectiveness. And, of course, every resident is different in terms of attitude, level of engagement, motor skills and proprioceptive ability. It amazes me that we now don’t routinely test our resident applicants for visual acuity, depth perception, color vision and manual dexterity. We used to, but in our brave new world it could be considered discriminatory. (Sigh.) I’ve sent more than one resident up to Pediatrics to be checked for depth perception after a tough case—or, alternatively, suggested a career in neuro ophthalmology. In the end, though, we graduate just about every one of them with the education and numbers they need, and with, at the very least, a decent OR skill set. While I consider our resident training in cataract surgery to be highly successful, it still seems like a medieval apprenticeship, requiring so much individual and personal engagement. This is kind of puzzling in this age of technology, but after 35 years of training residents, it’s still very gratifying.

So bring on July—and August too. I think I have a few more of them left in me. ◀



A Look at 2021's Mid-year Changes

What you need to know about the Quality Payment Program and the proposed Medicare Physician Fee Schedule rule.

Mid-year changes aren't often significant. This year, however, there are some things providers should know in two specific areas: the Quality Payment Program (QPP) and the proposed rule for the 2021 Medicare Physician Fee Schedule (MPFS).

Q Do any of these changes go into effect right away?

A Yes. In fact, in the QPP 2021 arena, a couple of the changes are retroactive to January. One of the QPP changes affects those who file for QPP Quality measures via claims in the area of diabetes.

The claims-based filers should know that although CMS announced changes in codes for some diabetes measures in the Final Rule for 2020 MPFS and many doctors began to properly use them, CMS acknowledged in July that it never actually activated the new codes after mandating their use, so those practices and providers who actually reported the "unactivated" codes on their claims would be unable to get credit for the two affected measures. CMS' July action to help providers was to suppress the scoring for those two diabetes measures for 2021 claims-based reporting.

Scoring for other types of reporting ("Registry" is the most common

methodology in ophthalmology) is unaffected by this suppression and reporting of these measures will be scored normally.

The two measures of note are:

- Measure 1: Diabetes: Hemoglobin A1c (HbA1c) Poor Control (less than 9%)

- This is not common for eye providers to do, but some have used it.

- Measure 117: Diabetes: Eye Exam

- This is a quite common measure for all types of eye-care providers.

Practices who report either of the above measures via claims won't be given any score in them. If you reported the more common measure # 117, your denominator is reduced by 10 points (from the more normal 60 down to 50 if you had six quality measures). Additionally, CMS noted that those affected will not have to find an alternative measure due to the lateness in the year when CMS

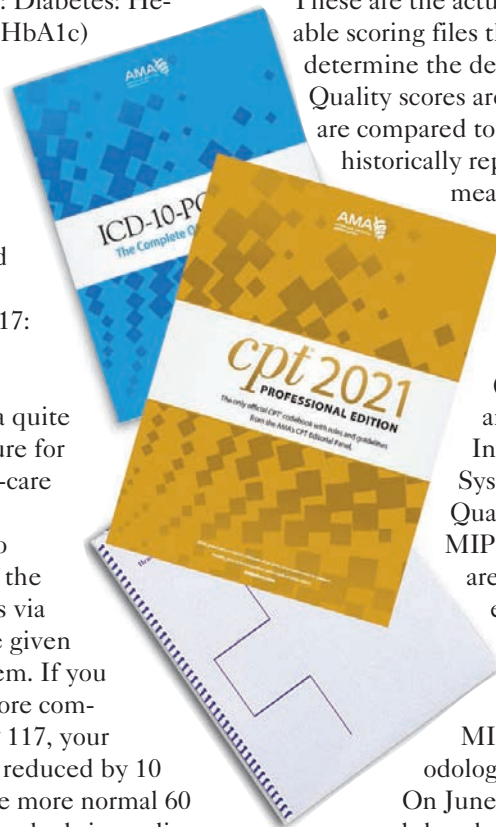
acknowledged its error. With fewer measures, though, there may be less room for error to hit the proper scores to avoid a penalty in 2023 (what you do in 2021 affects you two years later). More practices might need to select the hardship exception due to COVID-19, which is available to claim until December 31, 2021 at 8 PM Eastern time.

Q What is the other CMS change to QPP for 2021, and how might it affect my QPP score?

A This important change relates to a CMS mid-year update to the Historical Benchmark files. These are the actual publicly-available scoring files that CMS uses to determine the deciles in which the Quality scores are given (providers are compared to others who have historically reported the same measure in a prior

year). It has the potential to affect every provider, since all types of reporting (Claims, Registry, and Merit-based Incentive Payment System Clinical Quality Measures, or MIPS CQM) methods are included. Most eye doctors report via Registry and some via claims; not many do the MIPS CQM methodology.

On June 10, CMS reported that they had recalculated the deciles for the Historical Benchmark files. In no case did a score in any quality measure go "up a decile" so as to improve the score



DRY EYELAND™

Journey to a world

WHERE A LOSS OF TEAR FILM
HOMEOSTASIS LEADS TO DRY EYE¹



When it comes to dry eye disease and the loss of tear film homeostasis, there's a broader integrated system that needs exploring. We call it Dry Eyeland.^{2,3}

Come travel this anatomical landscape, where:

- Loss of tear film homeostasis is the unifying characteristic of all dry eye¹
- The parasympathetic nervous system plays a major role in tear film homeostasis²
- The lacrimal functional unit (LFU) is far more than just the lacrimal gland³

Allow us to be your guide to dry eye—visit DryEyeland.com to see the sights.
Because a whole world awaits beyond the ocular surface.



References: 1. Craig JP, Nelson JD, Azar DT, et al. *Ocul Surf.* 2017;15(4):802-812. 2. Efron N, Jones L, Bron AJ, et al. *Invest Ophthalmol Vis Sci.* 2013;54(11):TFOS98-TFOS122. 3. *Ocul Surf.* 2007;5(2):75-92.

© 2021 Oyster Point Pharma, Inc. Oyster Point™, the Oyster Point logo and Dry Eyeland™ are trademarks of Oyster Point Pharma, Inc. OP-COM-000101

you might get. In all cases, a score on a measure you reported moved down a decile, so your achieved points go down as a result.

This can be a difficult area to understand, so here's an example: Your score on a percentage basis might be 85 percent on a measure before the CMS update to the file, so this fell in the 5th decile when compared to everyone who reported that measure via that method. Now, that same 85 percent will be in the 4th decile—your max score just decreased a whole point. The effect of the loss of a single point doesn't seem significant at first, but this loss is now magnified, since your score in every measure goes down a decile from the original level. This could mean your practice now gets six fewer total points in Quality—and the maximum score was already only 60/60.

Once again, providers might need to decide to take the hardship exception if they don't achieve the minimum for penalty avoidance (it was 45 in 2020 but hit 60 in 2021).

Q What are the mid-year changes to 2021 CPT Category III codes?

A As always, some Category III codes went into effect in July; we wrote about those in the "What's New for 2021" Medicare Q & A in *Review's* February 2021 issue. They're unlikely to have coverage and payment at this time.

Q I've heard that some of the proposed payments for new surgery codes that go into effect in January 2022 are going to affect ophthalmology quite adversely. What are those?

A Perhaps the two most important codes for the average eye surgeon to be aware of are new codes 669X1 and 669X2 (these "X codes" aren't the real codes we'll use in January, but rather a "placeholder" for now). We'll know the real codes in a few months. These two codes are combination codes for cataract/IOL with an *ab-interno*

insertion of aqueous drainage device without reservoir. 669X1 is for use with these minimally-invasive glaucoma surgery devices and a complex cataract/IOL; 669X2 is for these same MIGS but with "regular" cataract/IOL surgery. The code descriptors are quite long, but they'll take the place of the current two-code pair we're using in 2021 (with two separate payments), replacing them with a single code with cataract/IOL and applicable MIGS procedures (e.g., iStent and Hydrus are among the minimally-invasive glaucoma surgeries that fit here).

In January 2022, you'll only file for a single code. (669X2 applies in 2022 instead of what's currently done in 2021: 66984 and 0191T)

Payments for the new single code proposed by CMS are abysmally lower than the sum of the payments for the current two codes.

Q What can I do to alleviate the potential hit to my practice from these codes?

A The Medicare Physician Fee Schedule Proposed Rule always causes a great deal of consternation, and some years are worse than others for our specialty. If you're not already doing these procedures and don't plan to, the change won't affect you at all.

Your professional societies are well aware of the proposed changes in reimbursement and how they might adversely affect both providers and facilities. Make your opinion known to your representatives and keep track of developments here. It's very likely—but not guaranteed—that the big hit proposed will be mitigated a bit, so perhaps the sky is not falling. If you don't speak up, however, you'll have to accept the final result. It might be prudent to revisit your current MIGS surgery choices. It's better to be prepared and ready for the change if you really do have options.

As the famous motto goes: Be prepared. ◀

REVIEW NEWS

Residual Astigmatism After Surgery
(Continued from p. 11)

Going forward, Dr. Schallhorn says that the study's results point to the possible need for not only increased vigilance regarding preoperative refractive errors, but possibly an enhancement in the tools surgeons use.

"We have to pay more attention to corneal astigmatism in the preop workup, even low values less than 1 D," he says. "We need to improve our management of it. We have to have better technology for that."

Study Questions Blue-light Blocking

Researchers from Taiwan say that blue-light-filtering IOLs may not offer any tangible benefit over non-filtering IOLs in reducing patients' risk for AMD development.¹

The cohort study included 186,591 patients who had bilateral cataract surgery between 2008 and 2013 and were followed for up to 10 years. Of these patients, 11.3 percent had BF-IOL implants, while the remaining 88.7 percent got conventional IOLs.

The incidence rate of AMD after surgery was 11.59 per 1,000 person-years. There was no significant difference in AMD incidence rates between patients with BF-IOLs and those with non-filtering lenses. The incidence rate of non-exudative AMD and exudative AMD (per 1,000 person-years) was 9.95 and 1.22 for the BF-IOL group, and 11.13 and 1.44 for the non-BF-IOL group, respectively.

Once baseline characteristics were adjusted between the groups, the lack of evidence supporting the photoprotective benefits of BF-IOLs became clear, the researchers say. ◀

1. Lee JS, Li PR, Hou CH, et al. Effect of blue light-filtering intraocular lenses on age-related macular degeneration: A nationwide cohort study with 10-year follow-up. *Am J Ophthalmol*. 2021. [Epub ahead of print].

SIZE MATTERS



NANO DR[◊]PPER

95% of Eye Doctors say Bigger is **NOT** Better*

*Ask us how less is more for your patients
...and your clinic's bottom line*

www.nanodropper.com | support@nanodropper.com | (507) 405-5676

Use discount code REVIEWOPHTHO10 for 10% off your first order!

*According to a survey conducted by Nanodropper in April 2021 out of the 300+ eyecare professionals, more than 95% said their patients would benefit from smaller eyedrops.

GETTING TO THE ROOT OF DRY EYE

Determining the cause of dry-eye signs and symptoms can be challenging. Surgeons share tips and pearls.

CHRISTOPHER KENT
SENIOR EDITOR

Today, ophthalmologists are well aware that dry eye is a serious issue; it has ramifications not just for patient quality of life, but also for the success of ocular surgery. Nevertheless, it can be challenging to treat effectively, in part because so many different factors can cause its symptoms, and conservative management with over-the-counter tears doesn't address root causes.

In order to have any hope of addressing those, the ophthalmologist has to start by correctly diagnosing the underlying reason for the problem. Here, with that in mind, experts with extensive experience diagnosing the cause of dry eye share their advice for most effectively getting to the root of the problem.

Confirming Dry Eye

Because confirming dry eye is important (especially if you want to be reimbursed for your time and effort) you first need to know what will serve as confirmation.

“The staging developed by the DEWS 1 and 2 Dry Eye Reports says that if your patient has any ocular surface disease-associated symptoms—even if you don't find anything on your exam—that is, by definition, Stage-1 dry eye,” explains Francis Mah, MD, a specialist in cornea, external disease and refractive surgery, currently practicing at Scripps Clinic in La Jolla, California. “That's one reason it's so important to take a thorough history. If the patient has any type of symptomatology that can be tied to dry eye, that patient, by definition, has dry eyes.”

David R. Hardten, MD, director of cornea at Minnesota Eye Consultants and adjunct professor of ophthalmology at the University of Minnesota, thinks of dry-eye patients as falling into two categories: those who come in to address a dry-eye complaint, and those who come in for some other reason and say, “Oh, by the way, I'm having these symptoms ...”

“When patients come in for other reasons, I listen for complaints like

tired eyes, fluctuating vision, burning, stinging and/or irritation,” he says. “Depending upon the degree of concern the patient has about those symptoms—and the severity of whatever other problem you're dealing with—you can approach this diagnostically in a variety of ways. Digging into the history is probably the best way to proceed. That can help you decide whether that patient needs to have dry eye addressed further; how much you need to do to diagnose the nature of the problem; and, if you've already started dry-eye therapy, whether to adjust it or try something different.”

One way to elicit dry-eye symptoms is to ask your patients to fill out a questionnaire. “Questionnaires are useful because patients will sometimes not complain to you about problems they're having, such as difficulty reading, while a questionnaire may reveal the problem,” notes Dr. Mah. “In addition, if a questionnaire is positive for a dry-eye complaint, then you can suggest a point-of-care test, which could be reimbursable.

“We use a variant of the SPEED

This article has no commercial sponsorship.

Dr. Hardten consults for Johnson & Johnson Vision. Dr. Mah is a member of the medical advisory board for TearLab, and a consultant for Allergan, Sun pharmaceuticals, Kala Pharmaceuticals and Novartis. Dr. Koffler reports no financial ties to any product discussed here.

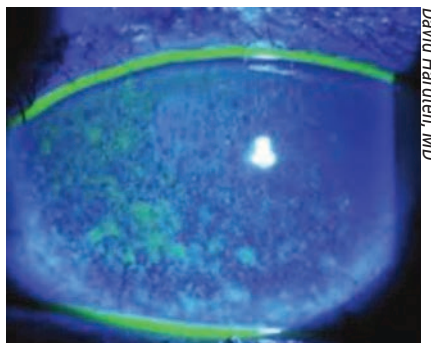
questionnaire that's been edited by the American Society of Cataract and Refractive Surgery's Corneal Clinical Committee," he notes.¹ "Patients can fill it out while sitting in the waiting room or dilating. Or, you can include it in the packet of information the patient receives prior to the office visit."

Not every practice uses questionnaires routinely. "We don't give every patient that comes in a dry-eye questionnaire," Dr. Hardten explains. "We just make sure not to ignore signs or symptoms when we find them. Even then, if the patient isn't bothered, I wouldn't do much in terms of treatment. However, if the patient is already being treated for dry eye, we give them a questionnaire to fill out at every visit."

Making the Exam Count

"Your exam is probably more important than the currently available point-of-care tests when it comes to the diagnosis of dry eye," notes Dr. Mah. "Pushing on the meibomian glands to assess the oils, measuring the tear breakup time, looking at the overall tear meniscus, and corneal and conjunctival vital dye staining; those are all very important components of dry-eye diagnosis."

"When we see the kind of patient who mentions dry-eye symptoms in passing," says Dr. Hardten, "we ask questions like: 'Do you notice the problem mostly first thing in the morning?' If so, that suggests that the problem may relate to nocturnal lagophthalmos—sleeping with the eyes partly open. (If you suspect nocturnal lagophthalmos, you can just ask the patient to close the lids gently and then look for exposure or separation of the lids.) Are the symptoms minimal in the morning but get worse over the course of the day? If the patient says yes, the problem could be aqueous tear deficiency, ocular rosacea, blepharitis or evaporative-type dry eye. Burning or stinging can indicate aqueous



Here, corneal staining reveals signs of dry eye in a patient.

deficiency or rosacea components of dry eye; foreign-body sensation and tearing can occur with both of these scenarios. Burning and stinging is probably a little bit more common with ocular rosacea—the blepharitis component of dry eye. But it can occur in either type of dry-eye disease.

"If you're managing a patient who's come in for a checkup or because of glaucoma, and this is the first time they've mentioned a dry-eye symptom, fluorescein staining is one of the easiest ways to get a read on the patient's condition," he continues. "It's a quick way to look at the tear-film breakup time. You put some fluorescein in and look for staining of the cornea—and the conjunctiva, although that's harder to see. Also, look for punctate erosions and punctate keratopathy.

"There are also some pictorial methods for looking at and measuring tear-film breakup time," he adds. "Those can give you a more numerical analysis than simply putting in fluorescein and looking at the eye. This can be done, for example, with a placido disc topography unit, some of which have specific tear-film protocols. In our clinic we have an HD Analyzer, which analyzes the scattering of light off the cornea after the patient blinks. I find it to be quite useful."

Spotting Subtler Symptoms

It's also important not to overlook some less-often-recognized

symptoms. "Most doctors associate complaints like foreign body sensation, irritation, discomfort and redness with dry eyes," Dr. Mah points out. "However, fluctuating and occasional blurry vision can also be symptoms of dry eye.

"It's crucial to listen carefully to the patient during your exam," he continues. "Fluctuating vision is not a cataract issue! I'll often do a cataract surgery evaluation, and the patient will say 'I'm really having problems with reading; sometimes I can read really well, other times I can't.' Or they'll say, 'I'll start reading and have to stop after 20 minutes.' That's a dry-eye problem.

"Another symptom that can be confusing is excessive tearing," he points out. "Of course, that can be caused by a more organic issue such as a naso-lacrimal duct obstruction. But often, especially when it's associated with foreign-body sensation, tearing is a symptom of dry eye.

"I'm sure a lot of eye-care specialists don't want to get drawn into treating dry-eye disease," he adds. "Many surgical practices would rather just treat surgical patients. However, if you want better outcomes and happier patients you need to take a little bit more of a holistic approach and try to identify dry eyes and actively manage them."

Meibomian Gland Dysfunction

"Meibomian gland disease and dry-eye symptoms go hand in hand," says Bruce Koffler, MD, a cornea and external disease specialist in private practice with Huffman and Huffman, based in Lexington, Kentucky. Dr. Koffler's practice includes a clinic entirely devoted to treating dry eye. "We keep up with the newest instrumentation and therapies," he says. "In fact, most of the research we do relates to the ocular surface and dry eye.

"The meibomian glands put healthy oil onto the ocular surface to mix with the aqueous component

and make a better, longer-lasting tear, so if the glands have a problem, the tear film has a problem,” he points out. “The formula I learned years ago is: 50 percent of patients with meibomian gland disease have dry-eye symptoms; and 50 percent of dry-eye patients have meibomian gland disease. Meibomian gland disease is certainly very common in our practice.”

Dr. Koffler says he examines the meibomian glands in every patient that has dry-eye signs or symptoms. “I look for increased plugging of the glands and increased vascularization of the blood vessels around the glands,” he explains. “I always take a Q-tip and do a little expression. I tell the patient I’m going to exert a little bit of pressure on the lid margin—not the eyeball.

“It’s very diagnostic when you gently squeeze the glands and nothing comes out, or you see a toothpaste-like, yellow, purulent discharge,” he explains. “That’s diagnostic of increased *Staph* activity in the glands, leading to infection, toxin production and irritation of the ocular surface. Eventually it leads to ocular surface problems, as demonstrated by superficial punctate keratitis of the corneal or conjunctival surface, or filamentary keratitis.

“A lot of these patients are ocular or dermatologic rosacea patients,” he adds. “They need constant therapy. They have problems with the changing seasons, particularly in the spring, summer and fall here in Kentucky where we have a lot of pollen. We’re very much aware of how these allergens affect the eye and the lid margins. These patients have what I call a recovery season in the winter, when I work hard to try to get those oil glands open, reduce the neovascularization, and try to recover to be in better shape for the spring season.”

MGD vs. Aqueous Deficiency

Dr. Hardten says that when a patient mentions dry-eye symptoms in

DRY EYE AND ALLERGY

“If allergy is a component of the dry-eye problem, there’s usually a significant amount of itch,” notes David R. Hardten, MD, director of cornea at Minnesota Eye Consultants. “However, patients can have mixtures of aqueous deficiency, meibomian gland dysfunction and ocular allergy that lead to a constellation of symptoms that need to be addressed from a treatment standpoint. That means you have to sort out the diagnostics.”

Dr. Hardten notes that when you’re checking the lower lid to assess the meibomian glands, you can also look for papillae. “These are characteristic of allergic eye disease,” he explains. “They’re typically minimal in ocular rosacea, blepharitis, meibomian gland dysfunction and aqueous-deficient dry eye. Papillae are harder to see on the back of the lower lid than on the back of the upper lid, but it’s more work to flip the upper lid. So in an ‘Oh, by the way,’ type of dry-eye complaint situation, it may not be worth flipping the upper eyelid to check. On the other hand, if you’re asking ‘Why didn’t this dry-eye treatment work?’ then flipping the upper eyelid to look for papillae can be quite helpful for distinguishing the symptoms that occur with allergy.”

—CK

passing, he usually starts by treating with lid hygiene and artificial tears. “These can help with both aqueous insufficiency and meibomian gland dysfunction or ocular rosacea,” he notes. “But if the patient comes back and they’re doing those things and still having trouble, that’s when I try to distinguish between meibomian gland dysfunction and aqueous deficiency in a more sophisticated way. I think most cases are a combination of the two, but usually one is a little bit more predominant.

“A good way to start is to look at the lashes and lids and meibomian glands,” he continues. “It’s often very helpful to use a Q-tip to slightly roll the lower lid out and push on the meibomian glands. You can see whether the material the glands are making is present, and if it’s present, whether it’s clear or turbid.”

“For me, at least, the two tests that I use most often to help with diagnosis are tear osmolarity and meibomian gland imaging,” he says. “If you find significant rosacea, the tear osmolarity test can help you sort out whether the dry eye is mostly aqueous deficiency or mostly evaporative. If the measured tear osmolarity falls below the threshold I’ve set, I consider that to be a case of mostly evaporative dry eye. If the tear osmolarity is high—say, over 310 milliosmoles—or if there’s

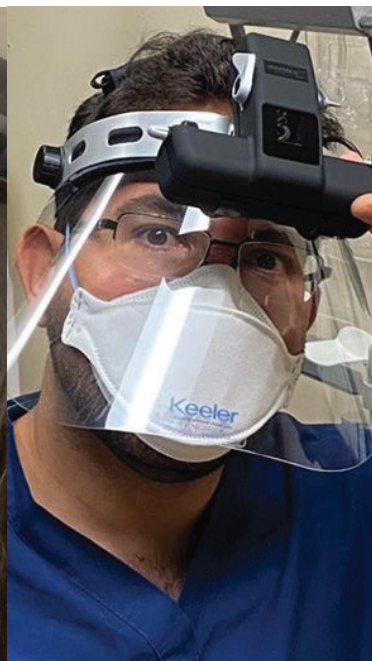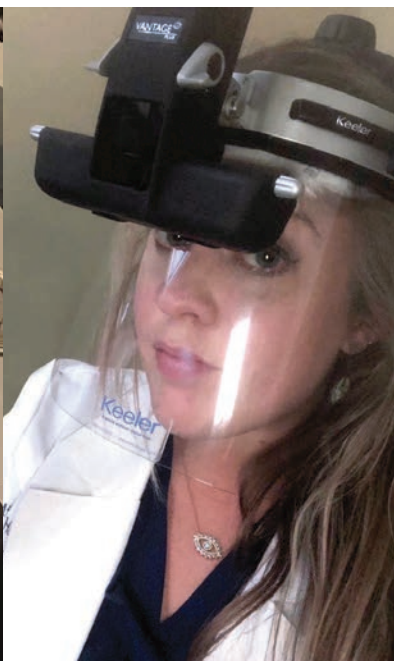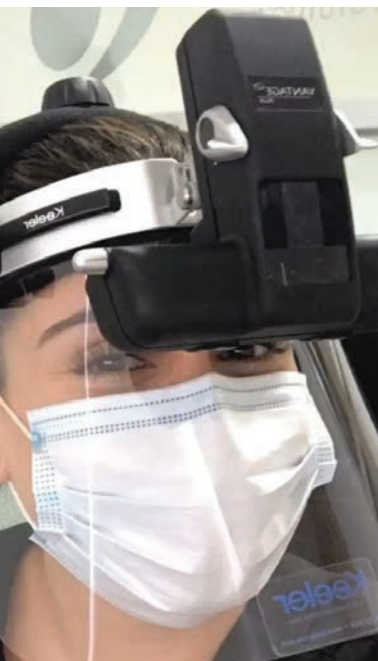a big difference between the two eyes—that’s more characteristic of a patient who has significant aqueous deficiency.

“Incidentally,” he adds, “some doctors refer to a lower tear osmolarity measurement as being ‘normal.’ I don’t think that’s a good way to characterize it. I see the measurement threshold as a way to distinguish between two causes of dry-eye symptoms, rather than a normal vs. abnormal tear film. I call it ‘mostly evaporative dry eye,’ not ‘normal.’

“The other test that helps a lot is meibomian gland imaging,” he continues. “Imaging helps me determine the amount of pathology that’s present in ocular rosacea or meibomian gland dysfunction. It’s helpful in determining the degree of gland dropout, and the degree of truncation of the glands or narrowing of the orifices near the exit. It’s a true diagnostic test, as opposed to just pushing on the lid margin—although that’s still extremely useful. A number of instruments can do this kind of imaging. For example, TearScience’s LipiView provides an infrared picture of the meibomian glands. The Oculus Keratograph can do the same thing. LipiView can also look at the thickness of the lipid layer in the tears.

“The other thing we look for is collarettes in the scurf the patient

Helping Heroes See Clear And Stay Safe



The Vantage BIO is great for ROP screening! It's lightweight, has settings for different pupil sizes, a cool, white LED light and the longest battery ever!!"

Dra. Paulina Ramirez Neria



I'm a big fan of the All Pupil BIO. I had issues with other models so when I started [my practice], I knew the All Pupil would be my go-to BIO...I greatly appreciate the new custom fit Keeler BIO shields as an added safety layer."

Dr. Annie Bacon



I chose my [Vantage Plus] for the optics and value...with other brands, I had difficulty focusing up close during my dilated fundus exams. [The oculars] made my eyes feel more relaxed, and I felt like my view was better."

Dr. Michelle Hammond



[I've] been seeing emergent and urgent cases every day during the COVID19 pandemic. I really like [the Vantage BIO] because [it's a] very good quality and provides a super clear view."

Dr. Reza Moradi

Choose one of the programs below when you purchase a BIO*
(Expires September 30, 2021)

*this program is valid for our wireless indirects: All Pupil II and Vantage Plus

1



RECEIVE A

\$850

credit towards any PPE

2

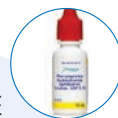24-MONTH

0%

lease as low as \$128/month*

*All Pupil II: \$127.92/month; Vantage Plus: \$155/month (shipping and taxes not included).

3



RECEIVE

10 FREE

bottles of phenylephrine
2.5%, 15mL

***Leasing may also be combined with the PPE credit OR the phenylephrine option.**

Contact us at 800-523-5620 or customerservice@keelerusa.com to learn more or place your order. This promo cannot be combined with any other Keeler offers.

Keeler
— A world without vision loss —

www.keelerusa.com • 3222 Phoenixville Pike - Bldg. #50 • Malvern, PA 19355
Tel No: 1-610-353-4350 • Toll Free: 1-800-523-5620 • Fax: 1-610-353-7814

A Halma company

might have along the lashes, indicating a Demodex infestation,” he adds. “If the signs are present, we address this with tea tree oil treatment.”

The Point-of-care Tests

A number of these tests are available. Surgeons offer these observations about the most popular ones:

- **Osmolarity testing.** Dr. Koffler says he finds osmolarity testing (such as the test produced by TearLab) to be helpful. “Patients who have a high osmolarity score are likely to have dry eye,” he notes. “However, like the Schirmer’s strip, the osmolarity test has to be done properly by an experienced technician, using the proper equipment. Doing the test takes some time and effort, but I do find it helpful.

“Because there’s a Medicare code, we can’t charge the patient if the insurance doesn’t cover the test expenses adequately,” he adds. “Nevertheless, it’s worth doing in select patients, especially if you’re having trouble making the diagnosis.”

- **Testing for matrix metalloproteinase 9 (MMP-9).** “The InflammDry test is a point-of-care test that’s reimbursed in most situations,” says Dr. Mah. “It’s a colorimetric, yes-or-no test that’s similar to a pregnancy test: If you see a mark, it’s positive; if you don’t see a mark, it’s negative.

“The molecule being measured, MMP-9, has been associated with inflammation around the eye,” he notes. “That means this test isn’t really specific for dry eye, but it will tell you if there’s significant inflammation in the tear film. If there’s inflammation, it could be the result of allergy, blepharitis, aqueous insufficiency or some other issue. This test can definitely be helpful with a diagnosis, especially if you can rule out some of the other inflammatory conditions that might explain the inflammation. And it’s useful for patient education.”

Dr. Hardten says he also some-



Bruce Koffler, MD

Schirmer’s test: After numbing the cornea, instilling a little fluorescein makes the result much easier to read.

times uses the InflammDry test. “If I have a patient on cyclosporine or lifitegrast, but they’re still complaining and their InflammDry is still positive, that’s when I consider using topical steroids,” he explains.

- **Schirmer’s test.** This test has been around for many years; some practices still rely on it; others have mixed feelings about its value.

Dr. Mah says he’s not very enthusiastic about the Schirmer’s test. “It’s very inconsistent,” he notes. “In my experience, unless the reading is close to zero, or the test is part of a clinical trial, or the patient is being evaluated specifically for Sjogren’s disease, it’s not very helpful in the diagnosis of dry eye.”

For those practices that still rely on Schirmer’s, Dr. Koffler offers several tips to ensure useful readings. “First, I instill a little drop of Ophthalmic (proparacaine) for numbing before using the Schirmer’s strip, to reduce the amount of reflex tearing that can occur, which can make the test unreliable,” he says. “Second, because it’s sometimes hard to see where the wet zone ends on the strip, I put in a little fluorescein before doing the test; that stains the strip and makes it easier to read when the test is complete. Third, make sure the test is done by a tech-

nician who is experienced at doing it, to ensure a reliable result.”

- **Meibography.** “Meibography is good because it’s very visual and educational for the patient,” Dr. Mah explains. “You can tell whether the glands are present or absent, and whether there’s some knock-out or atrophy. Meibomian gland problems don’t really have much to do with the quantity of aqueous in the tear film, but they have a lot to do with the quality of the tear film and with ocular surface disease. Meibography is very helpful in terms of diagnosing the problem, educating patients and gaining compliance.”

- **Topography.** “Another sign that your patient has dry eye can be detected via topography,” notes Dr. Mah. “The scan will have little areas of dropout that show up as small blotches here and there, or blank areas that can’t be read. It’s almost impossible for a cornea to actually be that irregular. So if you see that kind of irregularity on a topography scan, one of the first things that should go through your mind is that you’re looking at a dry eye. You don’t need topography to diagnose dry eye, but it can confirm your suspicions and help the patient understand that the dry-eye problem is real, how it might cause fluctuating or blurry vision, and that it requires treatment.”

Today, the plethora of tests intended to help the diagnosis of dry eye has expanded to include specialty options that are part of more complex instruments capable of measuring multiple factors. For example, Dr. Koffler says he also uses the JENVIS Pro Dry Eye Report available with the Oculus Keratograph 5M instrument when diagnosing patients for dry eye. (He has no financial connection to the company or product.)

“The report has multiple components,” he explains. “It gives you an ocular redness score, a tear-lake-volume evaluation and tear-film breakup time, and it images the meibomian glands. It isn’t the high-

est quality imaging I've seen, but you can tell whether the glands are healthy and lined up, or very erratic, scarred-over or plugged. The instrument then creates a report that you can review and share with the patient. It has a scoring wheel showing all of the components it measured. It shows the patient whether they're in the dry eye 'danger zone,' indicated by red vs. green, and you can repeat the report on a six-month or yearly basis, to show patients how they're improving."

How many of these tests should a practice aim to have? "Everyone has to do the best they can within the bounds of what's practical for them," notes Dr. Koffler. "When you're in private practice you can only purchase the equipment you can afford."

Ultimately, how carefully you do your exam and history may trump the number of tests you're able to offer. "The reality is, right now, we don't have a really great *sine qua non* test to diagnose dry eye," Dr. Mah observes. "It's not like strep throat, where it doesn't matter what your exam findings are; if you get a positive strep test, the patient has strep throat. We haven't reached that point with our dry-eye tests, so the exam is still very, very important."

Tips for the Exam & Testing

These suggestions can help make the most of your patient work-up:

- **Always check the meibomian glands.** "Checking the meibomian glands during your exam is essential," says Dr. Mah. "Many patients come to see me after being put on one of the four commercial, FDA-approved products for treating dry eyes; they haven't gotten any better. When I do my exam of those patients and push on the meibomian glands or do meibography, I find meibomian gland problems that haven't been addressed. That's why the patient isn't feeling better."

"It's a simple test to do—visualizing and pushing on the glands to

TESTING FOR SYSTEMIC DISEASE

"When you suspect dry eye, the patient should be asked about possible systemic diseases that might produce dry-eye signs and symptoms," says Bruce Koffler, MD, a cornea and external disease specialist in private practice in Lexington, Kentucky. "I would ask, 'Do you have any history of collagen-vascular diseases? Rheumatoid arthritis? Mucous membrane issues?' These questions can lead your investigation in a very different direction."

Francis Mah, MD, a specialist in cornea, external disease and refractive surgery practicing at Scripps Clinic in La Jolla, California, says a thorough history may suggest the possibility of a systemic problem. "If the patient has complaints about dry mouth, issues with eating dry foods and is constantly chewing gum, that might suggest Sjogren's disease," he notes. "If your patient has joint problems or muscle aches and pains, that may indicate a systemic problem such as lupus or rheumatoid arthritis that has associated dry eye. Those are typically patients who should be tested."

David R. Hardten, MD, director of cornea at Minnesota Eye Consultants, says he may start to consider the possibility of a systemic condition if a Schirmer's test indicates a very low quantity of aqueous. "I mostly reserve Schirmer's test for times when I'm considering punctal occlusion," he notes. "If the Schirmer's test is very high, I may decide not to use punctal occlusion. If it's very low, I might start to look for autoimmune conditions like Sjogren's, lupus and rheumatoid arthritis, which are associated with significant aqueous deficiency. In that situation I also may consider blood tests or a mucosal membrane biopsy."

"I usually leave the decision about testing for systemic conditions up to the primary care doctor or rheumatologist, since I'm in a very large multi-specialty group practice," adds Dr. Mah. "In the meantime, I tell the patient that a systemic problem doesn't mean I'll treat their dry eyes any differently; getting those tests done is mainly about improving their quality of life—and those tests may actually extend their life."

—CK

assess the quality of the meibum," he continues. "It doesn't take much time, and it's not like a Schirmer's test where the results can be equivocal. It's not uncomfortable for the patient. Most important, it gives you a lot of information about the patient's condition that can dramatically impact the success of your treatment."

- **Consider doing both corneal and conjunctival staining.** "We incorporate both of these into our dry-eye testing," says Dr. Koffler. "We've done a lot of dry-eye research using both fluorescein strips and lissamine green strips. Lissamine green stains the conjunctiva better. Sometimes I'll see conjunctival staining that I don't see on the cornea, particularly at three and nine o'clock. I believe that's a good sign of a dry-eye problem. So, I encourage lissamine green conjunctival staining as an additional, affordable, easy-to-do test."

- **Make sure tear-film breakup**

time is measured by an experienced observer. "There's a learning curve associated with this," Dr. Koffler points out. "The better you get at doing it, the more valuable it is."

- **Ask patients key questions about their history yourself.** "Today, the history is often taken by a technician," notes Dr. Koffler. "However, when I see the patient I repeat some of the key questions, such as those pertaining to other systemic health issues like rheumatoid arthritis. I do that because patients sometimes give me a different answer than they gave the technician! The reason isn't clear, but it happens frequently, and it can make a big difference in your diagnosis."

- **Look for debris in the tear film.** Dr. Koffler finds this to be a useful sign of dry eye. "When you're looking at someone at the slit lamp, if you see a lot of floating debris in the tear film in addition to particles of mucous, that's a good diagnostic sign for dry eye," he explains.

“Things are landing on the eye’s surface, but they’re not being washed away because there isn’t good tear flow. Increased debris in the tear film is a neat diagnostic tool that many doctors aren’t aware of.”

• **Look for filaments on the cornea.**

“We don’t see filamentary keratitis too often, but it’s very diagnostic of possible dry eye,” notes Dr. Koffler. “Of course, there are other possible causes of filaments that we sometimes see post-surgery, or with superficial limbal keratitis. But if you see filaments and you can eliminate those other possibilities, that’s pretty highly diagnostic of the aqueous form of dry eye.”

• **Check for conjunctivochalasis.**

“My favorite way to look for conjunctivochalasis is to gently press the lower lid up against the globe, put a little bit of pressure on it and move it up and down,” says Dr. Hardten. “If the conjunctiva overhangs the lid, it may be interfering with the flow of the tears on the surface of the eye. This might need to be addressed separately.”

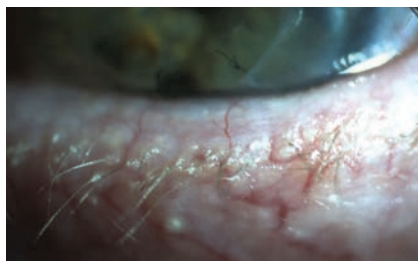Other Strategies for Success

These strategies can also help ensure a successful outcome:

• **Test all cataract and refractive patients for dry eye.**

“If a patient comes in without dry-eye complaints, these tests won’t be reimbursed,” Dr. Mah notes. “However, if the patient is being refracted for cataract surgery or refractive surgery, I’d argue it’s worth doing those tests anyway.”

“One study found that upwards of 80 percent of patients coming in for cataract surgery evaluation were asymptomatic—but did have signs of dry-eye disease,” he continues.³ “It would be nice to identify these patients prior to surgery, to make sure you have the best possible biometry. Furthermore, if you treat those dry-eye signs, you’ll minimize any chance of fluctuating vision and less-than-ideal outcomes after surgery ... not to mention complaints of



David Hardten, MD

A case of ocular rosacea and blepharitis.

dry eye postoperatively.”

• **Remember that dry eye can be a bigger problem than the cataract.**

“If a patient has a 20/200 cataract and a little bit of staining, I take the cataract out and tell them they have dry eye and deal with it,” says Dr. Hardten. “On the other hand, if your patient is 20/20-minus and has to stop reading after 15 minutes because of discomfort, pay attention to those symptoms. Don’t take the cataract out first; treat the dry eye and blepharitis and poor blink response. That’s what’s causing the worst of the patient’s symptoms.”

• **Don’t use the dry-eye tests when other tests have just been run.**

“All patients coming into our practice for a cataract or refractive surgery work-up, as well as any patient coming in for a dry-eye evaluation or ocular surface complaint, are tested for dry eye,” notes Dr. Mah. “If the patient isn’t in for any of those reasons, but I pick up something in the history suggestive of dry eye, we could theoretically do some testing after my exam. However, any drops or testing they’ve already undergone could alter the dry-eye test results. In that situation I may ask the patient to return to have those tests done.”

• **Think of the exam workup as a stress test for the cornea.**

“The work-up cataract surgery patients receive when they come in is kind of a stress test,” Dr. Hardten points out. “Before I see them, they’ve had their pressure checked and they’ve sat for a while with dilating drops in their eye. If their cornea looks pristine and topography looks regular, then they’re probably not going to get into trouble with the cataract surgery

and I don’t go looking excessively for dry eye. On the other hand, if the cornea doesn’t look very good by the time they get to me, then they’ve failed the stress test.”

“For that reason, if their topography and tear film look a little smudgy when I do the cataract surgery evaluation, I’ll ask about dry-eye symptoms,” he continues. “A patient like that isn’t going to hold up well after you do your cataract surgery and make incisions and put them on some toxic drops. That’s the patient who will come back and say ‘My eyes didn’t get better with the cataract surgery,’ and complain about it. So you don’t want to ignore the condition of their tear film after the clinic work-up.”

• **Don’t be cavalier about telling patients they have dry-eye disease.**

Dr. Koffler observes that many surgeons don’t think twice about diagnosing a patient with dry eye. “You have to consider the patient’s perspective,” he says. “You’re telling the patient he has a disease that most likely won’t go away, and it’s probably going to get worse with time. A meibomian gland issue is treatable, but aqueous dry eye isn’t a curable disease.”

“I see patients who are upset and miserable because they’ve been told they have dry eye,” he continues. “But when I examine them, I don’t find any dry eye. Meanwhile, they carry that diagnosis to other doctors who may accept it without checking. We shouldn’t give out that diagnosis unless we’re pretty sure about it. If you’re not sure, refer to a doctor who’s more involved with managing dry eye.” ◀

1. Starr CE, Gupta PK, Farid M, et al. An algorithm for the preoperative diagnosis and treatment of ocular surface disorders. *J Cat Refract Surg* 2019;45:5:669-684.

2. Lemp, M. Distribution of aqueous-deficient and evaporative dry eye in a clinic-based patient cohort: A retrospective study. *Cornea* 2012;31:5:472-8.

3. Gupta PK, Drinkwater OJ, VanDusen KW, et al. Prevalence of ocular surface dysfunction in patients presenting for cataract surgery evaluation. *JCRS*. 2018;44:9:1090-1096.

new!

thera
tears®

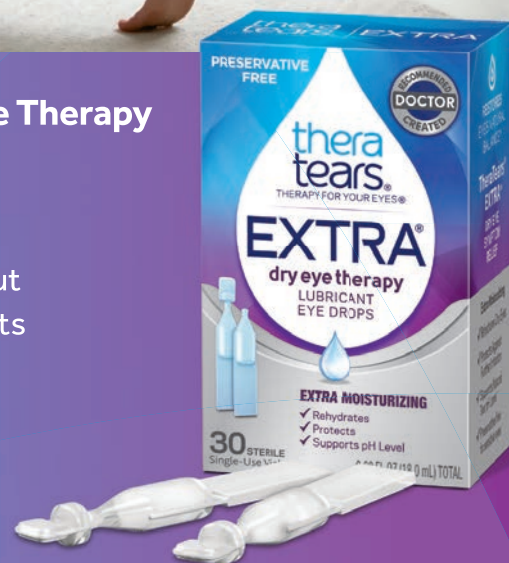EXTRA®
PRESERVATIVE FREE

PRESERVE THEIR
MOMENTS
WITHOUT
PRESERVATIVES

The Extraordinary Relief of TheraTears® EXTRA® Dry Eye Therapy
Enhanced with Trehalose is Now Preservative Free

Trehalose is a natural disaccharide found in some plants with moisture retention properties, helping organisms survive without water as an excipient. In ophthalmic products, Trehalose supports and enhances:¹

- ✓ Protection of corneal cells from desiccation
- ✓ Restoration of osmotic balance to the ocular surface
- ✓ Maintenance of homeostasis of the corneal cells



Learn about our complete line of dry eye therapy products at theratears.com

AKORN | EYE CARE

Reference: 1. Jones L, et al. TFOS DEWS II Management and Therapy Report. *The Ocular Surface*. 2017;15:575-628.



M20-036-00A

APPROACHES AND METHODS FOR TREATING DRY EYE: 2021

As the population of dry eye patients continues to grow, so do the available options for intervention.

LEANNE SPIEGLE
ASSOCIATE EDITOR

Any eye-care professional or patient will tell you that the treatment of dry eye has changed and evolved drastically over the years. Not only have treatments advanced, but research has uncovered more potential causes and triggers of dry eye and ocular inflammation. While the common condition can be overwhelming to treat with its many variables and management options, identifying a cause is always the first step, followed by the trial-and-error of different treatment methods.

Here, we'll hear from the experts about the various ways to approach dry-eye treatment and the methods and interventions they've found to be the most effective for their patients.

Approaching the Options

There are three things to consider before deciding on a treatment plan for your dry eye patient, according to Esen Akpek, MD, a professor of

ophthalmology and rheumatology at Johns Hopkins University School of Medicine, and director of the Ocular Surface Disease and Dry Eye Clinic at the Wilmer Eye Institute in Baltimore. Dr. Akpek says the three considerations include patient-reported symptoms and concerns, clinical signs and disease severity.

"First of all, we need to recognize that dry eye is a symptomatic disease, in that we have to address the patient's concerns. Patient-reported outcomes are very important," Dr. Akpek notes. "The second thing that we have to address is the clinical signs because they have implications. Clinical signs might have to do with blurring of vision or fluctuating vision, especially cellular erosion and short breakup time. Both the patient concern and clinician-measured clinical signs need to be addressed at the same time.

"The next thing is to determine the severity of the disease," she adds. "All the treatment guidelines or suggestions are based on the severity, but usually, there's a discordance between the patient-reported

and clinician-measured severity. So, you have to start by determining which one to address and how."

Robert Latkany, MD, a corneal specialist and refractive surgeon at the Dry Eye Center of New York City, agrees with Dr. Akpek that some patients may need to be treated based on clinically measured disease severity, while others may find even mild symptoms intolerable or disruptive to daily life and be more eager to find a solution for immediate relief.

"If someone is miserable but their eyes don't even look bad, I would call that something that needs urgency, but is that a severe case? Not necessarily," Dr. Latkany explains. "That's the problem with this condition. You've got three subgroups: You have the one that looks terrible but doesn't feel too bad, just a little bit dry. I'm still going to treat that person kind of aggressively. Next, you have the patient who doesn't look that bad, but feels terrible. In the interest of keeping the patient, I'm going to try to make this person happy and treat their symptoms,

This article has no commercial sponsorship.

Dr. Rapuano is a consultant for Bio-Tissue, Dompé, Glaukos, Kala, Oyster Point, Sun Ophthalmics, Tarsus and TearLab. Dr. Akpek is a consultant for Novolique and an investigator for Ocular Therapeutix. Dr. Bunya and Dr. Latkany report no financial interest in any of the products mentioned.

A BRIEF SUMMARY OF DRY-EYE OPTIONS

Artificial Tears		
Blink Moisturizing	J&J Vision	A hypo-osmolar viscoelastic formula that mimics human tears to restore the tear film and provide relief from dry-eye symptoms by regulating osmolarity levels.
Retain HPMC	Ocusoft	A hypromellose ophthalmic solution 0.3% that relieves dry-eye symptoms by resembling natural tears.
Freshkote	Eyevance	Supports the eye's tear film with antimicrobials and a blend of polyvinyl alcohol 2.7% and povidone 2%, which results in high oncotic pressure on the ocular surface to draw excess water from epithelial cells. Preservative-free.
Systane Complete	Alcon	Provides hydration and tear evaporation protection to relieve dry-eye symptoms. Nano-sized droplets form a protective matrix across the eye's surface. Preservative-free options are also available.
Soothe XP Emollient	Bausch + Lomb	Restores the lipid layers with mineral oils to seal in moisture and protect against irritation.
Advanced Eye Relief	Bausch + Lomb	Glycerin 0.3% and propylene glycol 1% replenish tears and prevent irritation.
Refresh Optive Mega-3	Allergan	Restores the lipid layer with a natural oil blend and relieves MGD symptoms. Includes carboxymethylcellulose sodium 0.5%, glycerin 1% and polysorbate 80 0.5%. Preservative-free.
Refresh Celluvisc	Allergan	A preservative-free artificial tear gel that contains carboxymethylcellulose sodium 1%.
TheraTears	TheraTears	A hypotonic, electrolyte-balanced formula that replicates healthy tears.
Optase	Scope	A three-step regimen for dry eye, blepharitis and MGD that includes a moist-heat mask, eyelid cleansing wipes, dry-eye spray and a preservative-free eye drop.
For Treating Inflammation & Promoting Tear Production		
Restasis	Allergan	A prescription ophthalmic emulsion (cyclosporine 0.05%) that increases the eye's natural ability to produce tears and reduces inflammation.
Xiidra	Novartis	A prescription drop (lifitegrast ophthalmic solution 5%) that targets the source of dry-eye inflammation.
Klarity-C	ImprimisRx	A preservative-free cyclosporine ophthalmic emulsion 0.1%.
Cequa	Sun Ophthalmics	A cyclosporine ophthalmic solution 0.09%; this prescription drop increases tear production using nano micellar technology.
StimulEyes	M2 Biologics	Uses hyaluronic acid and anti-inflammatory cytokines in an effort to improve symptoms.
Klarity-L	ImprimisRx	A preservative-free loteprednol ophthalmic suspension 0.5%.
Lotemax	Bausch + Lomb	A loteprednol etabonate ophthalmic suspension 0.5% often used off-label for treating dry eye.
Alrex	Bausch + Lomb	A loteprednol etabonate ophthalmic suspension 0.2%.
Inveltys	Kala Pharmaceuticals	A loteprednol etabonate ophthalmic suspension 1% often used off-label for treating dry eye.
Eysuvis	Kala Pharmaceuticals	A loteprednol etabonate ophthalmic suspension 0.25%.
RegenerEyes	RegenerEyes LLC	Contains cytokines, growth factors and chemokines to treat dry eye.
Genesis 2.0, ACE and Renaissance	Ocular Science	Three amnion-derived eyedrops with a proprietary combination of cytokines, growth factors and molecules to relieve dry-eye symptoms.

otherwise they're going to bail and go to someone else. But, I'm not in as much of a rush to treat that patient, because they don't really look that bad. Lastly, you have the patient who both looks and feels terrible. For that person, you've got to get going with treatment quickly, because that's truly the most severe."

Address the Underlying Causes

For many patients, dry-eye symptoms may be improved or relieved by simply identifying and removing the factors that are exacerbat-

ing inflammation or abnormal tear production. Encourage anyone with sudden-onset dry eye to review any new products they've used or been exposed to lately to help identify a possible allergy or irritant.

"The natural stuff is huge, but often neglected," explains Dr. Latkany. "I'll get someone who says their eyes are burning, so I ask them, 'Have you used any new moisturizers or a new sunblock or makeup product?' and they answer, 'Oh, well yeah, I've been using this product...' So, I ask them to do me a favor and do nothing except stop

using that one product. Two weeks later, they'll come back and say, 'Doc, I'm all better,' whereas this person could have been plugged, put on Restasis or Xiidra, had Lipi-Flow or intense pulsed light treatment, you name it. Sometimes, you just have to say, 'Hey, just stop that, and let's see what happens.'"

Finding the cause of dry eye to determine the best treatment options requires consistent questioning of the patient about their symptoms, lifestyle and habits. "It's so critical to get the information out of the patient," says Dr. Latkany.

A BRIEF SUMMARY OF DRY-EYE OPTIONS

For Blepharitis & Lid Hygiene		
BlephEx	BlephEx	A painless in-office device that helps maintain and clean the eyelid margins. Removes bacteria, biofilm and bacterial toxins. Replacement tips available.
Ocusoft Lid Scrub	Ocusoft	Contains a non-irritating formula that removes dirt, oil, debris and pollen from the eyelids.
Sterilid	TheraTears	An eyelid cleanser for removing external irritants from lids and lashes.
Cliradex	Tissue-Tech	A tea tree-oil-based cleanser that relieves symptoms associated with Demodex, blepharitis, MGD, rosacea, dry eye, chalazion and other lid margin diseases. Comes in towelettes and light foam. Preservative-free.
I-Lid 'N Lash Pro	I-MED Pharma	A professional-use hydrating cleansing gel with 20% tea tree oil for removing ocular debris and intensive cleaning of the lids and lashes. Available in a 50-mL metered dose pump.
TheraPearl Eye Mask	Bausch + Lomb	A hot-and-cold therapy that helps to alleviate dry eye.
For Meibomian Gland Dysfunction		
LacryStim IPL	Quantel Medical	Intense pulsed light system that uses a unique wavelength spectrum and train of pulses to stimulate the lachrymal and meibomian glands, reduce inflammation and improve tear film quality.
LipiFlow	J&J Vision	Delivers therapeutic pulsation energies to meibomian glands to liquefy and evacuate meibum.
iLux	Alcon	A handheld, portable device that targets the meibomian glands with light-based heat and compression under direct visualization in less than 12 minutes.
TearCare	SightSciences	An open-eye, blink-associated device suite that delivers consistent thermal energy to lid structure.
eyeXpress	Holbar Medical Products	An eye hydration system for in-office therapy.
MiBo Thermoflo	MiBo Medical Group	Treats dry eye by delivering consistent, emissive heat and ocular massage to the meibomian glands.
NuLids	NuSight Medical	An at-home treatment for dry eye and lid hygiene. An oscillating tip stimulates the meibomian glands and cleans away debris.
OptiLight	Lumenis	Intense pulsed light system FDA-approved for the management of dry-eye disease due to MGD.
Avenova	NovaBay Pharmaceuticals	A hypochlorous acid wash 0.01% for long-term hygiene management of MGD.
Epi-C PLUS	Espansione Group	A no-gel IPL with low-level laser therapy approved for dermatological use in the U.S.
TempSure	Cynosure	A 4-MHz radiofrequency device for reducing wrinkles around the eyes and forehead, sometimes used off-label for treating MGD.
Punctal Plugs		
Vera180	Lacrivera	Synthetic, absorbable lacrimal plugs (poly-p-dioxanone) designed to provide temporary occlusion for approximately 180 days. Available in sizes of 0.2 to 0.5 mm.
Soft Plug Extended Duration	Oasis Medical	A short-term plug (less than three months). Available in sizes of 0.2 to 0.5 mm. Also available: absorbable collagen and permanent intracanalicular plugs.
Scleral Lenses & Amniotic Membrane		
PROSE	BostonSight	A gas-permeable prosthetic device that reduces dry-eye symptoms of pain and light sensitivity and supports ocular surface healing.
DigiForm	TruForm Optics & Contamac	A scleral lens made of material with a low wetting angle to alleviate dry-eye symptoms, corneal distortion and surface irregularities. Also available in Optimum Extra and Optimum Extreme.
Onefit	Blanchard Contact Lenses	A scleral lens to help alleviate end-of-day dryness symptoms and intolerance of environmental effects with soft lenses. Provides a thin fluid cushion over the eye.
Boston IV	Bausch + Lomb	A rigid, gas-permeable contact lens with a non-stick surface that resists dirt and debris. B+L says it's an economical choice for vision correction and dry eye. Other options such as the Boston XO2, XO, EO and ES have B+L's Tangible Hydra-PEG coating technology, which increases surface water retention and lubricity and minimizes deposits on the lens.
Prokera	Tissue-Tech	A cryopreserved amniotic membrane that can serve as a biological bandage for severe dry eye and help restore the corneal epithelium.
AmbioDisk	Katena	A 12-mm sutureless dehydrated amniotic membrane for in-office applications. May be used to treat severe dry eye and ocular surface diseases.
BioDOptix	BioD	A dehydrated, extracellular membrane allograft derived from human amniotic tissue for use as a scaffold for ocular repair.
Oxervate	Dompe	An ophthalmic solution (0.002%) containing a recombinant nerve growth factor that supports corneal innervation.



LOMBART

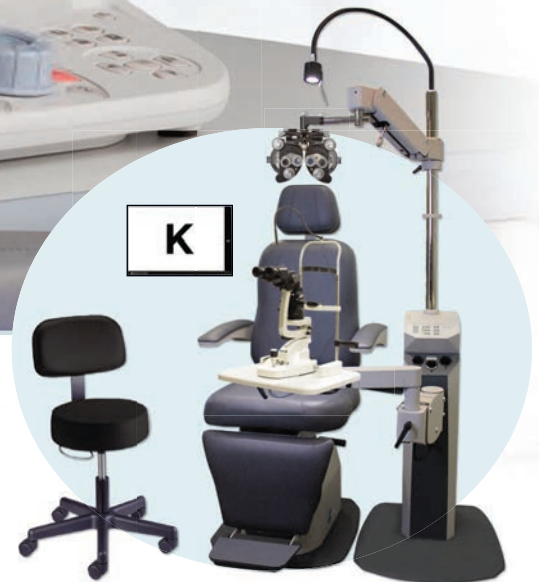ADVANCING EYECARE™

Your One-Stop Equipment Solution.

- CLASSICAL LANE EQUIPMENT
- HIGH-TECH DIAGNOSTIC EQUIPMENT
- NEW & PRE-OWNED EQUIPMENT
- SUPPLIES & ACCESSORIES
- EQUIPMENT REPAIRS & MAINTENANCE
- EQUIPMENT PROTECTION PLANS
- EQUIPMENT FINANCING
- AND MORE!

Contact us today!

1-800-LOMBART
LOMBARTINSTRUMENT.COM



COMPLETE LANE PACKAGES STARTING AT JUST \$14,495

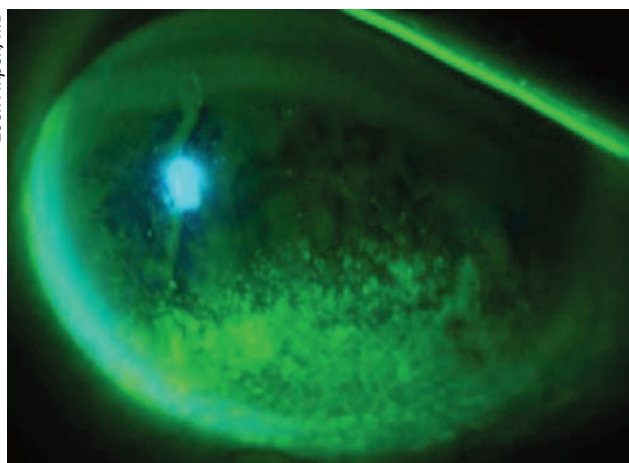
HAAG-STREIT • HEINE • KEELER • MARCO • REICHERT • RELIANCE • S4OPTIK • TOPCON • WELCH-ALLYN • & MORE

“Sometimes, you won’t get it from a technician, and sometimes, I don’t get it my own questioning the first exam. I might get it the second exam, or the third exam. But don’t neglect the history—that’s huge.”

One suggestion Dr. Latkany gives for patients with allergies that may be contributing to or causing dry eye is to invest in an air purifier for their home or bedroom. If the person sleeps with their eyes open, suggest a humidifier to increase the moisture in the room, or tell the person to wear an eye mask or goggles while sleeping and see if their symptoms improve. “For the patient with lagophthalmos who has dryness and scratches caused from that, I’m going to say ‘Hey, try this Refresh P.M. ointment for the next three nights and see how you feel in the morning.’ Maybe I’ll try two things, and suggest the eye mask and the ointment,” says Dr. Latkany. He recommends, however, not to try manual therapies and medicated drops all at the same time to be able to gauge individual effectiveness and avoid unnecessary intervention.

Other underlying conditions contributing to dryness that may be worth testing for include neurotrophic keratitis (NK), which Dr. Akpek notes could even be caused by the continuous inflammation of the eye. “One thing I recently started doing for my dry eye patients is routinely checking corneal sensation. I’ve actually found that decreased corneal sensation isn’t very uncommon among patients with severe dry central cornea, and especially if they say they aren’t in pain, my mind goes to NK. If I test them and they do have decreased corneal sensation, I’ll prescribe the appropriate treatment, which is a recombinant nerve growth factor,” says Dr. Akpek. Oxervate is the

Esen Akpek, MD



Confluent inferior corneal fluorescein staining in patient with dry eye and lagophthalmos due to Bells’ palsy.

newest FDA-approved recombinant nerve growth factor therapy to treat NK.

Vatinee Bunya, MD, an associate professor of ophthalmology at Penn Medicine and co-director of the Penn Dry Eye and Ocular Surface Center, urges ophthalmologists to screen patients for another potential underlying cause of eye dryness and irritation: Sjogren’s Syndrome. “Sjogren’s is very underdiagnosed,” Dr. Bunya warns. “The majority of Sjogren’s patients have dryeye symptoms, and as eye care providers, we’re the first ones to see them. Just asking about the presence of symptoms such as dry mouth or fatigue could help you detect underlying Sjogren’s Syndrome.”

Whether it be environmental, underlying or systemic, aqueous deficiency or meibomian gland dysfunction, pinpointing the cause of dry eye will help you narrow down treatment options and guide you and your patient’s next steps.

Topical Therapy

When avoidance of environmental triggers falls short, here’s the latest thinking on topical options.

• **Artificial tears.** Tried-and-true artificial tears still hold up as the first thing to prescribe a patient complaining of dry-eye symptoms in almost every mild to moderate case

(though if symptoms are mild and recurring, also continue to investigate the potential role of environmental factors).

It’s important to recommend preservative-free drops to patients who will be using them on a daily basis to prevent adverse reactions. Eye drops with preservatives are only safe for occasional patient use; in other words, for people who don’t have frequent eye dryness and probably aren’t in your office.

Dr. Bunya says that she always advises patients to start the treatment process by using preservative-free drops consistently but notes that patient compliance may be an issue for some.

“For patients with mild dry eye, usually I’ll recommend preservative-free artificial tears that come in individual vials,” Dr. Bunya says. “It’s important that they’re preservative-free because bottled tears have preservatives in them, and they can actually cause dry eyes if you use them frequently. Usually, I’ll start treatment by telling patients to use the drops two to four times each day to start, even if their eyes feel okay. Often, patients will only use the drops if their eyes are bothering them, but then it’s hard to get the eyes to start feeling better once they are already irritated. So, a lot of times, even just starting with twice a day, every day for a few weeks is a helpful first step.”

Dr. Akpek adds that in cases where preserved drops must be used, non-benzalkonium chloride (BAK) drops are the safer option to help prevent vision damage or worsening of symptoms.

• **Prescription drops.** For the patients who need more relief than artificial tears can provide, physicians will often turn to a prescription medication targeting inflammation. Restasis (cyclosporine ophthalmic emulsion) 0.05%, Xiidra (lifitegrast

Apellis is exploring the role of complement in Geographic Atrophy¹

C3 is the linchpin of complement overactivation in GA.²⁻⁷

All three complement pathways converge at C3 and it drives multiple downstream effects — inflammation, opsonization, and formation of the membrane attack complex — all of which can ultimately lead to retinal cell death. Increased levels of complement activity have been found not just in the lesion itself, but also in the area just outside the lesion, known as the pre-lesion.²⁻⁹

Scan the code to explore new territory with us at pre-lesion.com



Apellis

1. Katschke KJ Jr, et al. *Sci Rep*. 2018;8(1):13055. 2. Mastellos DC, et al. *Trends Immunol*. 2017;38(6):383-394. 3. Ricklin D, et al. *Immunol Rev*. 2016;274(1):33-58. 4. Heesterbeek TJ, et al. *Ophthalmol Vis Sci*. 2020;61(3):18. 5. Seddon JM, et al. *Nat Genet*. 2013;45:1266-1370. 6. Yates JRW, et al. *N Engl J Med*. 2007;357(6):553-561. 7. Smailhodzic D, et al. *Ophthalmology*. 2012;119(2):339-346. 8. Boyer DS, et al. *Retina*. 2017;37:819-835. 9. Park DH, et al. *Front Immunol*. 2019;10:1007.

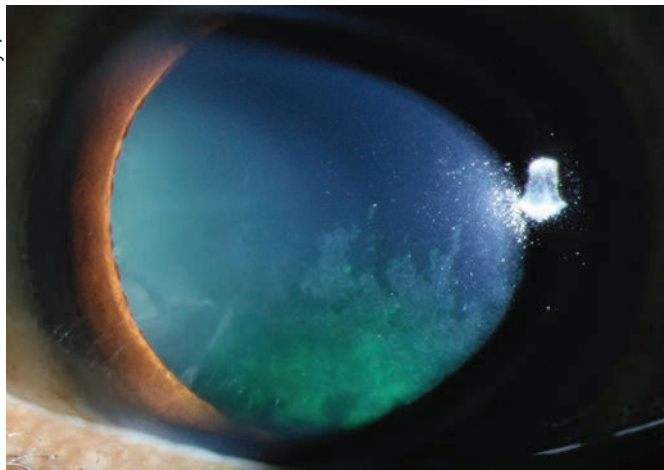
ophthalmic solution) and Cequa (cyclosporine ophthalmic solution) 0.09% are the three non-steroidal anti-inflammatory drops for dry eye. The most recent FDA-approved drop, Eysuvis (loteprednol etabonate ophthalmic suspension) 0.25%, is an ocular corticosteroid approved for short-term treatment of dry eye.

Though most ophthalmologists are familiar with the effectiveness of Restasis and Xiidra, in terms of the drugs that arrived in recent years, Cequa, when compared to vehicle at almost three months in two randomized, prospective studies, induced a statistically significantly higher percentage of eyes with increases of at least 10 mm from baseline in Schirmer's wetting.¹ For Eysuvis' part, in prospective, randomized trials, it reduced ocular discomfort throughout the trial period, with a statistically significant improvement reduction of discomfort in the treatment group at day 15.²

Dr. Latkany notes that there are some adverse events to be aware of. "None of these prescription drugs is a home run," he says. "All have side effects that prevent a significant percentage of patients from successfully using them. From burning, pain and blurry vision for Restasis, Xiidra and Cequa, to elevated eye pressure and cataracts for Eysuvis, they have to be monitored carefully. That said, they do offer relief for some patients, whether used individually or in combination with each other." If used in combination, experts advise that patients wait at least 10 to 15 minutes between each product's instillation. Dr. Latkany says he avoids prescribing the three non-steroidal drops to patients with ocular rosacea and dry eye, as they tend to have higher failure rates due to negative side effects.

Though drops offer short-term

Vatinee Bunya, MD



If corneal staining persists after treatment, clinicians will intensify the therapy.

relief for many, relying on any of them to treat symptoms long-term is unrealistic and could even make eyes worse, Dr. Akpek explains.

"Treating dry eye with only topical medication is counterintuitive. Every time you put topical eye drops on the ocular surface, you disrupt the homeostasis of the actual tear film and dilute the good tears that patients might produce. So, I think systemic or local treatments work better in the long run."

Punctal Plugs

For patients who aren't responding well enough to drops and are experiencing excess tear duct drainage, punctal plugs are still one of the more effective and least invasive treatment options available for chronic dry-eye cases. Punctal occlusion is usually done fairly early in treatment for patients with moderate dry eye who don't find sufficient relief from topical medications alone.

"If you have solid evidence in the office that the patient has low tear production (for example, a decreased tear lake or a low Shirmers test), then I would have a low threshold for trying punctal occlusion," says Dr. Bunya. "Contact lens wearers especially tend to respond well to it."

Dr. Latkany says that he'll put punctal plugs in quicker for some patients than others, but that each

case has to be handled based on a patient's symptom severity and comorbidities. "For that purely aqueous deficient patient, I'll start off with two lower plugs," he says. "If the two lower plugs aren't enough, I'll do two upper plugs. But in my grand pool of patients, that is not the most common patient, for sure. Even though I only see dry-eye patients, it's a mixed-bag; for example, someone who's aqueous deficient who also has allergies or rosacea, I'll treat that patient differently

(address the allergy and treat inflammation to see if symptoms improve before considering plugs). But, I will only ever treat with one thing at a time to understand what is working and what's not."

Christopher J. Rapuano, MD, Chief of Wills Eye Hospital's Cornea Service, says that although he's usually not hesitant to plug lower tear ducts, he's apprehensive about plugging upper tear ducts because he's found that they aren't as comfortable for the patient.

Meibomian Gland Dysfunction

Inflammation in patients with anterior blepharitis and meibomian gland dysfunction must be addressed first and foremost, as it's the root cause of MGD and ocular discomfort.

The initial approach to addressing mild dry eye due to meibomian gland dysfunction is by instructing the patient to clean their eyelids, especially if they haven't been doing so already. Dr. Latkany believes this is a crucial part of a patient's personal eye health and that a consistent cleaning regime could have a large impact on the frequency and severity of dry-eye symptoms.

"I often use the analogy of cleaning your gums and your teeth," Dr. Latkany says. "You have to floss, and you have to brush teeth every day. Then, when you go to the

dentist, they do a little better or a job than you are doing at home. But, you can't come to me every six months and have me clean your eyelids if you haven't been doing it at home and keeping up with the maintenance." He recommends setting aside 10 minutes to instruct your patients on how to clean their eyelids at home and increase the chance that they might comply if they know how to do it properly.

Dr. Bunya also emphasizes the importance of lid cleaning for dry eye patients of all severities, which she suggests can be done using diluted baby shampoo or over-the-counter cleansers. In addition, she recommends treating mild to moderate dryness by advising patients to apply warm compresses over their eyes twice a day for five minutes at a time.

Dr. Rapuano says that patients with mild to moderate dry eye can be prescribed erythromycin antibiotic ointment to apply to lids at bedtime as the next step when drops and regular lid cleanings aren't sufficient. "Erythromycin kills two birds with one stone; it lubricates the eyes overnight to help address any aqueous deficiency contributing to the dry eye, and secondly, it functions to kill any kind of bacterial overgrowth on the eyelids," Dr. Rapuano explains. "It's also a mild anti-inflammatory, and it decreases the lipid composition in the oil glands so they work a little better."

Dr. Rapuano does note that "azithromycin works better than erythromycin, but logistically, it's harder to get: it's more expensive, insurance doesn't want to cover it and it's only FDA-approved for a two-week course."

It could be helpful to screen MGD patients for new or existing rosacea, a skin condition that can clog up the oil glands in the eyelids (ocular rosacea). Daily eyelid cleanings or using topical antibiotics can be useful in mild to moderate cases, and devices like LipiFlow may be necessary for more severe ones.

"Certainly, if they have a lot of blepharitis or rosacea, consider oral doxycycline or oral azithromycin," says Dr. Bunya.


Dr. Rapuano also says doxycycline is a solid next step once the MGD patient has tried both erythromycin and azithromycin. "I'm not a huge fan of systemic antibiotics long-term for a relatively limited problem, but for some people, doxycycline is very helpful," he says. "I'll do a medium dose for two weeks and then cut that dose in half for another four or six weeks and see how they do." He notes that sometimes people will find symptom relief after a six- or eight-week course of doxycycline, while others may need to stay on it for months or even years to achieve desired relief.

LipiFlow and TearCare are two thermal eyelid procedures that can be considered for those with severe dry eye caused by MGD. "They work through a combination of a heating of the eyelids to soften up the oils and then a massaging of the lens to clean out the oil glands

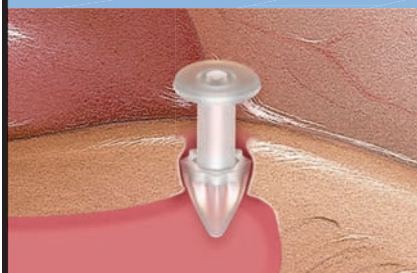
One of Lacrimedics' newest family members



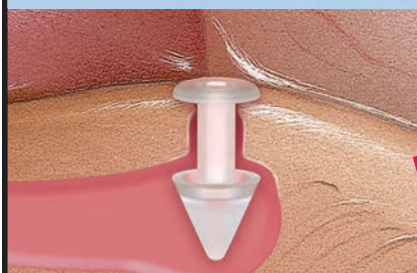
Proven Occlusion Therapy. Enough Said.



Collapsible tip provides ease of insertion, improved patient comfort, and superior retention.



Two sterile plugs per box (4 sizes available). Each plug is individually mounted on an insertion tool and packaged in a separate tray.



SPECIAL PRICING \$49.00

(Valid through October 31, 2021)

To order:



Lacrimedics

(800) 367-8327

E-mail: info@lacrimedics.com

www.lacrimedics.com

©2021 Lacrimedics, Inc.

THE DREAM STUDY: OMEGA-3 CALLED INTO QUESTION

Penny Asbell, MD, director of the Hamilton Eye Institute in Tennessee, recently challenged the claim that over-the-counter omega-3 fatty acid dietary supplements play a role in reducing dry eye. Along with a research team, she conducted the Dry Eye Assessment and Management (DREAM) study in May 2018 and found that compared to the group taking omega-3 supplements, patients receiving the olive-oil placebo had similar mean change rates for conjunctival staining, corneal staining, tear breakup time, Schirmer's test scores and adverse events.¹

Though the results were striking, the study received pushback for a couple of reasons, one being that most participants were simultaneously continuing other treatment interventions throughout its duration. The DREAM research team aimed to conduct a study that was considered "real-world," meaning that outside factors could've snuck in and swayed results; however, this is just speculation at this point. One argument against the validity of the findings has already been debunked: Namely, that the placebo in the study, refined olive oil, could have a therapeutic effect on dry eye. The researchers say that the low dosage given to participants and the oil refinement process exclude it from offering sufficient health-promoting benefits, so it's unlikely that's the explanation for the similar results between the omega-3 pills and the olive-oil placebo.

Clearly, as the DREAM Study has shown, the question of whether omega-3 supplements are effective in improving dry eye is a topic requiring further research. However, there's no denying that a diet rich in fruits, vegetables and plant-based foods could benefit all patients, especially those dealing with dry eye. A 2020 study linked higher consumption of vegetables and vegetarian protein alternatives with lower severity of dry eye.²

1. Hussain M, Shtein RM, Pistilli M, et al. The dry eye assessment and management (dream) extension study - a randomized clinical trial of withdrawal of supplementation with omega-3 fatty acid in patients with dry eye disease. *Ocul Surf.* 2020;18:1:47-55.

2. Flanagan J, Huang B, Tavakoli S, et al. Is dry eye related to diet? *Invest Ophthalmol Vis Sci* 2020;61:7:330.

and remove blockages," explains Dr. Rapuano. "I've done both of those with great success in some patients, medium success in most patients and zero success in some patients."

Intense pulsed light therapy is a relatively new treatment for MGD. "It uses bright light to treat abnormal blood vessels in the superficial skin to decrease the inflammation of the eyelids," explains Dr. Rapuano. However, most of these therapeutic procedures aren't covered by insurance and can be costly. Dr. Bunya says she "[tends] to try a lot of the other treatments before recommending LipiFlow or intense pulsed light, just because those are usually an out-of-pocket expense for the patient."

Severe Dry Eye

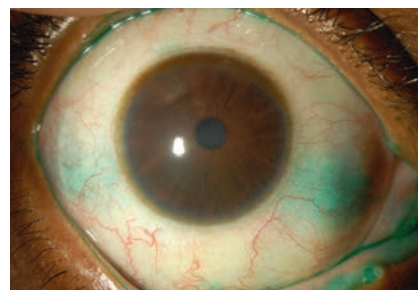There are many therapies currently available for severe dry eye, but success rates depend on the cause and severity of symptoms and a person's eye anatomy. Some popular techniques to treat severe cases include autologous serum eye drops (ASEDs), scleral lenses and various procedures, such as the few men-

tioned above (LipiFlow, TearCare and intense pulsed light therapy).

Autologous serum eye drops contain ingredients found in natural tears that can't be replicated by artificial ones including antibodies, albumin, Vitamin A and epidermal growth factors. The serum eye drops are made using a very small amount of the patient's blood drawn during a brief appointment.

"Especially in the last couple of years, you can see that patients are responding well to the serum," Dr. Bunya observes. "They tend not to have a lot of side effects because it's made from their own blood. I've started to prescribe autologous serum drops sooner, even in patients with moderate dry eye, and have had great success with that." A downside to serum drops, however, is that they're another treatment not often covered by insurance.

Scleral or bandage contact lenses are both options to consider for moderate to severe dry-eye patients. Scleral lenses, such as the PROSE lens, "are filled with tears, and then the patient puts it in, and it bathes the eye with tears all day long," Dr.



Christopher Rapuano, MD

This dry-eye patient has a moderate amount of lissamine green dye staining nasally and temporally. Note the silicone punctal plug in the left lower tear duct.

Rapuano explains. Typically more affordable for patients, soft bandage contact lenses reinforce damaged tissues and protect the nerve endings from abrasion caused by eyelids.

Dr. Rapuano adds that steroid drops could be helpful in short-term cases of severe dry eye but may do more harm than good when used to treat chronic conditions such as aqueous deficiency.

Lateral tarsorrhaphy is an advanced treatment option available for certain patients with severe evaporative dry eye. "If you have a patient whose eyes are really open, you can do a permanent tarsorrhaphy where you actually stitch the eyes partly close, so that there's not as much evaporation," explains Dr. Rapuano. "We typically do that for some older or rheumatoid arthritis patients, but it's a pretty dramatic treatment choice."

To find the most success treating today's large population of dry eye patients, physicians advise moving in a stepwise fashion, trying one method at a time and then supplementing with others in cases of unimproved symptoms or higher severity. ◀

1. Goldberg DF, Malhotra RP, Schechter BA, et al. A Phase 3, randomized, double-masked study of OTX-101 ophthalmic solution 0.09% in the treatment of dry eye disease. *Ophthalmology* 2019;126:9:1230-7.

2. Holland E, Nichols K, Foulks G, et al. Safety and efficacy of KPI-121 ophthalmic suspension 0.25% for dry eye disease in four randomized controlled trials. Presented at: AAO 2020: November 13-15, 2020; virtual meeting.



Emerald

powered by *Inami*

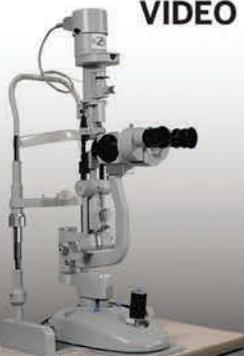SLIT LAMP RE-INVENTED

The soul of the Slit Lamp is its optic. The Ezer Emerald offers an optic of ultra-high definition only comparable with the most prestigious brand in the market, and at a much more accessible cost. Such a combination was made possible thanks to our incredible engineers and the high-quality standards of fabrication at our facilities in Japan.

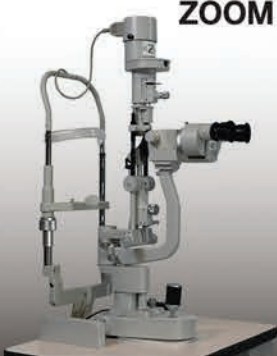

TRY IT YOURSELF

VIDEO



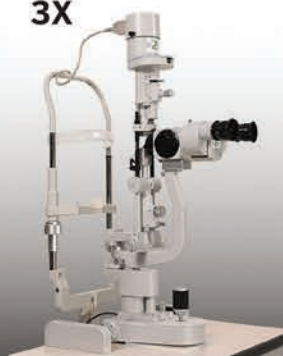ZOOM



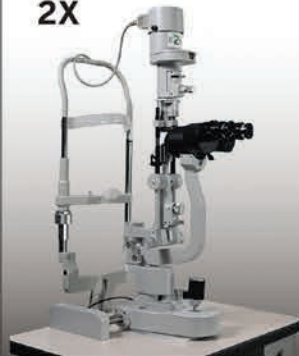5X



3X



2X



WHY SURGEONS ARE PEELING FEWER ERMS

Watchful waiting is now often putting this procedure on hold. Veteran vitreoretinal surgeons explain what's critical for you to know.

SEAN MCKINNEY
SENIOR EDITOR

Not long ago, vitreoretinal surgeons routinely peeled epiretinal membranes, even removing the internal limiting membranes as well. But most surgeons generally take a more conservative approach today. As you may know, the tendency is to spare the ILM, to hold off on performing ERM peels in many cases and to rule out potential adverse effects related to comorbidities before deciding when and how to proceed.

Here, veteran vitreoretinal surgeons discuss their current and evolving approaches.

Scope of the Problem

The incidence of epiretinal membranes varies widely, depending on co-existing pathologies, regions of the world studied and diagnostic testing used to identify ERMs. Spectral-domain coherence tomography has opened the door to much wider recognition in recent years, identifying the greatest number

of affected patients in the United States to date, including up to 34 percent of eyes examined during the 20-year follow-up of the Beaver Dam Eye Study population¹ and a range of 2.2 to 11 percent in eyes with no pre-existing pathologies that were examined before cataract surgeries in two separate studies.^{2,3}

“**Patient symptoms and an ERM's impact on activities of daily living are more important than visual thresholds.**”
—Charles Wykoff, MD

Risk factors for ERM remain the same, of course, including increasing age, uveitis, ocular inflammatory diseases and retinal pathologies, such as posterior vitreous detachment, retinal breaks, retinal vein occlusions and diabetic retinopathy.^{4,5}

“Epiretinal membranes are common and most patients identified with OCT don't need intervention,” says Charles Wykoff, MD, PhD, di-

rector of research at Retina Consultants of Houston, and deputy chair of ophthalmology for the Blanton Eye Institute at the Houston Methodist Hospital.

Dr. Wykoff says he lets a patient's symptoms and vision guide his management strategy. “That's a key point to keep in mind,” he says. “So if a patient is asymptomatic and functioning normally, without any problems, my inclination is generally to observe. If the patient is symptomatic—experiencing symptoms that could include metamorphopsia, crooked lines, haze over vision, a cellophane-like manifestation over their vision or even just blurry vision—at that point I would think about a surgical intervention.”

Dr. Wykoff acknowledges that debate among retinal specialists on using visual acuity thresholds to determine when to peel a membrane continues. “To me, though, using a patient's symptoms and the impact of ERM on his or her activities of daily living are much more important than a specific visual acuity threshold,” he says. “If patients are

This article has no commercial sponsorship.

Dr. Wykoff is a consultant for Genentech and Regeneron and does research for both companies. Drs. Haug, Shakoore and Mathias report no relevant financial disclosures.

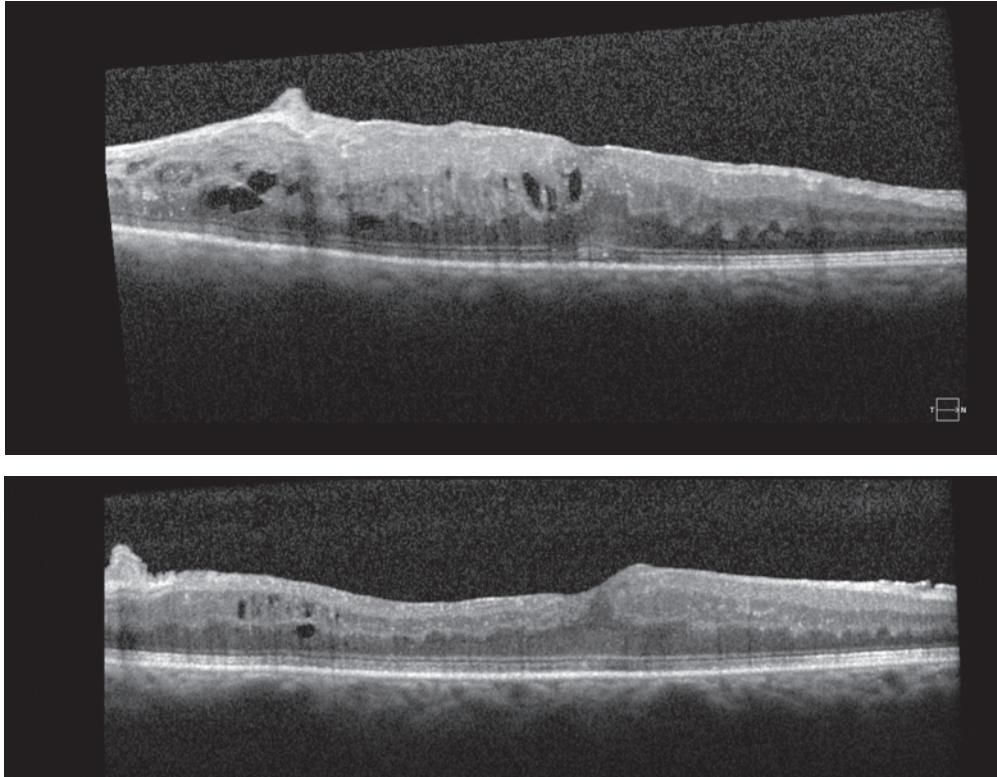


Figure 1. The first OCT scan (top) shows a preop, dense epiretinal membrane in a patient whose vision is 20/80. One month after an epiretinal membrane peel, the postop OCT scan (bottom) shows an improving macular contour. The patient's vision is 20/25.

bothered by their vision, and I think it's attributable to an ERM, then I believe it's reasonable to consider mentioning surgery to them. If they aren't bothered by the ERM, then I will typically leave the ERM alone, even if their vision is decreased. It's hard to make asymptomatic patients happier."

Even if the architecture of the macula looks meaningfully distorted in the presence of an ERM, and the patient's vision measurement is decreased, Dr. Wykoff sticks to his practice of observation, provided the patient is functional and content with his or her vision.

"Now, I definitely discuss the option of intervention with the patient, and I show the pictures, so that he or she knows what's going on," he notes. "But as I said, the patient's symptoms drive my decision-making here."

Akbar Shakoor, MD, a retinal

and uveitis specialist at the John A. Moran Eye Center, and assistant professor of ophthalmology at the University of Utah, agrees with Dr. Wykoff's approach. He considers qualitative *and* quantitative measurements of vision before deciding if an ERM peel is appropriate.

"Generally, I try to avoid doing a membrane peel when vision is 20/30 or better," says Dr. Shakoor, who's also an associate professor of ophthalmology and program director of the uveitis fellowship program at the University of Utah. "Of course, I'm not going to suggest surgery to a patient whose vision is 20/30 or better or if the patient isn't bothered by poor vision. The vision could be almost anything, really, but if the patient isn't bothered by his or her vision, I'm only going to make it worse by doing surgery."

This can be especially true when an ERM manifests as an isolated

condition.

Dr. Wykoff notes that many of these cases seen in practice are idiopathic. "Idiopathic ERMs are probably related to migrating glial cells or migrating fibroblasts that, for unknown reasons, become attracted to the inner retinal surface and then proliferate and form contractile tissue," he says. "Many of these cases are most likely related to retinal pigment epithelial cells that have migrated to the anterior surface of the neurosensory retina and have proliferated there. The reason they begin to proliferate there is unknown. Certainly, there are also important risk factors for ERM—such as retinal tears, retinal breaks, history of trauma—that we also always need to consider."

Role of Comorbidities

Retinal specialist Marc Mathias, MD, an assistant professor of ophthalmology at the University of Colorado, says many comorbidities play an increasingly significant role in triaging patients with ERMs.

"For example, in a glaucoma patient, I'm a little more hesitant to go ahead and do an ERM peel," he notes. "I usually discuss such a case with the glaucoma specialist who's taking care of the patient to find out how significant the glaucoma is and what effects an ERM peel might create. In relatively moderate glaucoma, an ERM peel can be realistic, and the outcomes are good. However, I've gotten away from peeling the ERM in moderate cases of glaucoma. The risks of ganglion cell layer thinning and decreasing vision are too great if you do an ILM peel on these patients. For advanced glaucoma, meanwhile, I try to avoid

surgery at all costs. The same goes for age-related macular degeneration, another significant underlying disease that raises risk factors.

With a diabetic patient, however, Dr. Mathias initiates a different type of conversation.

“Medications won’t improve that patient’s diabetic macular edema,” he says. “Those are the cases when an ERM peel can be more reasonable and I usually proceed with the procedure.”

At first glance, Dr. Shakoor doesn’t like accepting the label of idiopathic ERM, as common as it may be. He approaches ERM patients with what he considers a healthy degree of skepticism, seeking answers to questions.

“You’ll find that a lot of these patients actually do have an underlying process,” he says. “You want to look specifically for inflammatory or vascular disease. Specifically, I want to find out if the patient has uveitis or retinal vasculitis. Does he or she have a history of endophthalmitis? I want to know if a vein occlusion is involved. How about microvascular disease? Does the patient have diabetes? Those are the issues you should explore.

“If there’s an active disease process going on, including uveitis, then it should be controlled before a decision is made on whether to do a surgical procedure such as an ERM peel,” he says.

Failing to identify another active process will increase the chance of ERM recurrence or a recurrence of inflammation that leads to other structural damage, he points out. “If you have a patient who has any inflammation, bringing that inflammation under control before surgery is very important,” he adds. “You don’t want to operate on eyes affected by

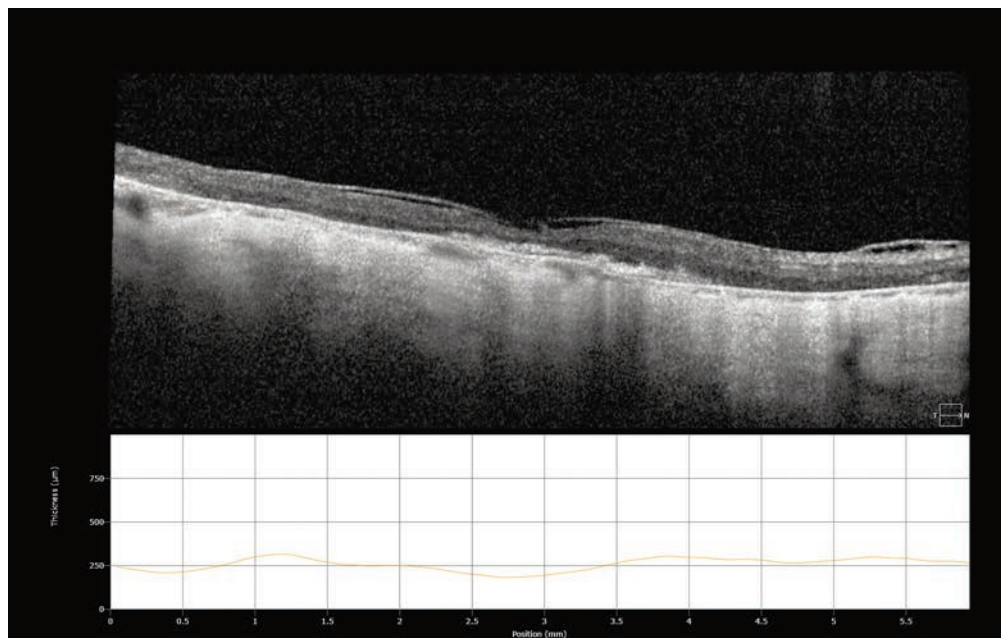


Figure 2. This OCT scan shows a macula with an epiretinal membrane as well as subretinal fibrosis related to exudative age-related macular degeneration. The patient wasn’t suitable for surgery.

an inflammatory process.”

Sara J. Haug, MD, PhD, a retinal specialist at Southwest Eye Consultants in Durango, Colorado, and surrounding areas, says the phakic status of patients can also play an important role in her selection of candidates for an ERM peel.

“If the patient is over 50 and phakic, I can almost guarantee you that the patient will develop a cataract six months to a year after my ERM surgery,” she says. “Therefore, I may be more amenable to doing surgery on a pseudophakic patient who’s more of a borderline case than I would a phakic patient.”

Dr. Shakoor adds this additional perspective: “I think you need to consider the degree of vision loss that a cataract contributes and the degree of vision loss that an ERM contributes,” he says. “It may just be that once the cataract is removed, the patient’s vision improves to the point at which poor vision won’t be a significant issue anymore.”

Dr. Shakoor also looks at patients’ OCT scans for evidence of outer retinal disease. “Besides signs of macular degeneration, you may see RPE loss,” he explains. “If you see any

of these processes, you still might be able to do a membrane peel. But then you have to temper your patients’ expectations. I’ll tell them: ‘You have this epiretinal membrane and it may be causing some distortion. But you also have these other conditions. So your vision may consequently be limited to some extent by the other processes.’ The last thing your patient wants to hear is that the membrane is gone, that the macula looks good but that he or she will see no better than before the ERM peel was removed. It’s always important to talk your patient through these processes and the prognosis.”

Despite the trend away from peeling the ERM in many cases, Dr. Haug carefully evaluates each affected patient to recognize when a peel might still be needed.

“The OCT scan can sometimes be misleading, indicating the vision is better than it is, for example,” says Dr. Haug. “I’ve seen some 20/20 eyes peeled because you have some distortion. There’s going to be a lot of debate about this. Every surgeon has his or her own threshold. The threshold that I use is at about the 20/40 mark. When you hit 20/40 and



THE RICK BAY FOUNDATION

for Excellence in Eyecare Education

www.rickbayfoundation.org

Support the Education of Future Healthcare & Eyecare Professionals



About Rick

Rick Bay served as the publisher of *The Review Group* for more than 20 years.



To those who worked for him, he was a leader whose essence was based in a fierce and boundless loyalty.

To those in the industry and the professions he served, he will be remembered for his unique array of skills and for his dedication to exceeding the expectations of his customers, making many of them fast friends.

Scholarships are awarded to advance the education of students in both **Optometry** and **Ophthalmology**, and are chosen by their school based on qualities that embody Rick's commitment to the profession, including integrity, compassion, partnership and dedication to the greater good.

Interested in being a partner with us?

Visit www.rickbayfoundation.org

(Contributions are tax-deductible in accordance with section 170 of the Internal Revenue Code.)



THE RICK BAY FOUNDATION®
for Excellence in Eyecare Education

(The Rick Bay Foundation for Excellence in Eyecare Education is a nonprofit, tax-exempt organization under section 501(c)(3) of the Internal Revenue Code.)

A TREND OF HIS OWN?

The trend among retinal specialists may be to hold off on peeling the ERM unless it's significantly disrupting vision, affecting activities of daily living or making the patient unhappy. However, Marc Mathias, MD, sometimes takes a more individualized approach.

"As I've become more comfortable with doing surgery in my career, my threshold for performing this procedure has lowered a little bit," says Dr. Mathias. "It involves focusing on how we may be able to improve the patient's experience and vision, and how that patient's life is being affected, rather than focusing on straight cut-offs or thresholds that we might've followed in the past."

He offers an example. "For a patient who has really good visual acuity, say 20/25, but also significant metamorphopsia, I might've been a little hesitant to consider surgical intervention in the past. But now, based on my experience, I may be comfortable proceeding with surgery. I'm more inclined to take this approach after discussing procedures with patients who may have acceptable visual acuity but also have complaints that you can't objectively measure. I also see patients with good visual acuity whose retinal architecture is quite distorted. I'll remove the ERM because the patient is complaining of metamorphopsia. We've had a relatively high degree of success in terms of improving functional vision in these patients."

Dr. Mathias says he still relies heavily on objective means of evaluation, however. "Before proceeding with any case, I do try to coordinate my findings with OCT," he says. "We've encountered patients whose testing reveals no distorted anatomy at all, and they're complaining of metamorphopsia. I can get a little more hesitant to peel those patients."

One conservative approach to surgery that Dr. Mathias shares with his colleagues involves patients who have wildly unrealistic expectations that can't be tamed by serious preop counseling. "We will see patients who are expecting a result they might get after cataract surgery or LASIK," he notes. "Many of them are expecting perfection, and it's a challenge to communicate to them that we're operating on the sensitive tissue of the retina. We're modifying the architecture, treating traction and maculopathy, not replacing anything. These patients can be difficult in a different way."

your patient's vision is bothering him or her in everyday life, and I also see a pretty good membrane, then I feel pretty confident about moving ahead with the peel."

Dr. Shakoor sometimes relies on waiting periods to see if symptoms get better before performing a peel. "After all, every surgery has risks," he notes. "You don't want to end up in a situation in which the patient was not keen on undergoing surgery and feels he was coerced into surgery after he or she ends up with a bad outcome. This sort of preoperative questioning and assessment of the patient can be more important than the surgery itself."

During the preop period, Dr. Shakoor says he covers every aspect of the procedure and the possible outcomes—right up until he's at the patient's bedside before he performs the procedure.

"I discuss the possible need for postop steroids after surgery to control macular edema, for example," he says. "I want to manage their expecta-

tations realistically, emphasizing that this isn't like cataract surgery, after which you will see beautifully the next day. After this procedure, it may take weeks or even months before patients start to notice improvement. Or their vision may not end up being as good as we had hoped. Their final outcome won't be known until about six months down the road. Some patients will get back to 20/20 and others will only get to 20/30 and may still experience distortion. These conversations are very important to have and they're the reasons why I always emphasize informed consent. You could say I am more aggressive with informed consent and than I am with surgery."

ILM: To Peel or Not to Peel

Peeling the internal limiting membrane was once a routine part of peeling the ERM. "Peeling the ILM with the ERM has always given us a sense of security," explains Dr. Haug. "There's plenty of evidence that peeling the ILM will reduce recur-

rence of the ERM by 10 to 15 percent or more. But the latest evidence also says peeling the ILM can lead to thinning of the retina, although I personally don't think it can lead to major problems."

In a 2019 Preferred Practice Pattern published by the American Academy of Ophthalmology, a review of 10 studies compared the results of isolated ERM removal to the results of combined ERM and ILM removal.⁶ Five of the studies found that peeling the ILM with the ERM led to a lower incidence of recurrent ERM, although removing ILM was also associated with loss of inner retinal tissue.

"Most of us are less aggressive about when we peel the ILM these days," says Dr. Haug. "In my mind, I'm least likely to peel the ILM if the patient has macular degeneration. Sometimes, though, you can't help peeling the ILM because the ILM and ERM will come off together. You can stain and see where you haven't removed the ILM and decide whether or not you want to remove all of it. The exception to this tendency against peeling the ILM would be in patients with diabetes. When a patient has diabetes, we're more likely to peel the ILM."

Case-by-Case Basis

Dr. Shakoor says he doesn't have a firm opinion on whether it's best to peel the ILM. He approaches the issue on a case-by-case basis.

"If you peel the ILM, the upside is that you have the reduced chance of recurrence of the ERM," he says. "The downside of doing an ILM peel is that you risk damaging the retinal nerve fiber layer, even if you're a very good surgeon. The ILM is a structure that is completely apposed to the retinal nerve fiber layer. However, if you can carefully and successfully remove the ILM, the risks of doing the ERM peel only and the ERM and ILM peel together are both the same, so three months down the road, both patients should be happy."

Dr. Shakoor peels the ILM in cases of inflammatory disease because he believes it reduces the incidence of cystoid macular edema and inflammation in the future. “Not everyone believes that, but that is my belief,” he says.

Like other retinal specialists, he also routinely peels the ILM in diabetic patients because he feels it helps decrease the re-emergence of diabetic macular edema. “It limits—but doesn’t eliminate—your need for further treatment,” he says. “Also, in the presence of an ERM, when a macular hole also exists, then it’s a no-brainer to peel the ILM.”

Dr. Wykoff says he continues to remove the ILM routinely, adding, “I tend to remove just a small area of the ILM centrally.” His practice is guided by an extensive evaluation of ERM peels performed by him and his colleagues.

“The rate of recurrence was low in both groups but appeared to be lower in the group in which we removed the ILM,” he says. “So I feel I’m trying to get rid of the problem instead of allowing it to come back. But whether or not we should peel the ILM remains an important, unanswered question. Does removing the ILM interfere with visual function? I think the field would really benefit if prospective data provided guidance on that issue.” ◀

1. Meur SM, Myers CE, Klein BE, et al. The epidemiology of vitreoretinal interface abnormalities as detected by spectral-domain optical coherence tomography: The Beaver Dam Eye Study. *Ophthalmology* 2015;122:787-795.
2. Klein BR, Brown EN, Casden RS. Preoperative macular spectral-domain optical coherence tomography in patients considering advanced-technology intraocular lenses for cataract surgery. *J Cataract Refract Surg* 2016;42:4:537-541.
3. Zafar S, Siddiqui MAR, Shahzad R, et al. Swept-source optical coherence tomography to screen for macular pathology in eyes having routine cataract surgery. *J Cataract Refract Surg* 2017;3:3:324-327.
4. Bu SC, Kuijjer R, Li XR, et al. Idiopathic epiretinal membrane. *Retina* 2014;34:12:2317-2335.
5. Cheung N, Tan SP, Lee SY, et al. Prevalence and risk factors for epiretinal membrane: The Singapore epidemiology of eye disease study. *Br J Ophthalmol* 2017;101:3:371-37.
6. Idiopathic Epiretinal Membrane and Vitreomacular Traction Preferred Practice Pattern, American Academy of Ophthalmology; 2019;167-169.



Hold your mobile device over the code to view reviewofophthalmology.com/publications/archive.

Innovative products to enhance your practice

Experience *Review's* Product Guide in print or digital. Simply select the products, devices or services you'd like to be contacted about for more information.

www.reviewofophthalmology.com/publications/archive

NEW IN 2021:

E-BLAST PRODUCT SHOWCASE!

This year, in addition to mailing the print edition and hosting the digital versions of the Product Guide on our website, we will be blasting each company's listings to our MD email database! Each company will have a designated product showcase deployment day following distribution of the print editions, providing an additional opportunity to receive more information on all the items you want!



EXPANDING YOUR KERATOPLASTY REPERTOIRE

A round-up of the most recent innovations in corneal transplantation.

CHRISTINE LEONARD
SENIOR ASSOCIATE EDITOR

It's an exciting time to be in the cornea field. Surgeons are working with thinner and thinner tissue, and in some cases, no tissue at all. With cell-injection therapies on the horizon, there's a lot to look forward to. Here are some of the latest innovations in transplant techniques.

Simplifying Graft Unrolling

DMEK offers fast visual recovery, good final vision and a low rejection rate (1 percent, compared to 5 to 14 percent in DSAEK),¹ but the procedure has a steep learning curve, owing mainly to the thin 10- μ m grafts.

"There are multiple ways to inject and unscroll a DMEK graft," says Marjan Farid, MD, a clinical professor of ophthalmology and director of the cornea, cataract and refractive surgery program and the ocular surface disease program at UC Irvine School of Medicine. "Surgeons should use whichever technique is most predictable and works best in their own hands."

One method that aims to simplify graft delivery and soften DMEK's learning curve is the pull-through technique.² "Most corneal surgeons learn DSAEK first, so adapting the pull-through technique to DMEK reduces the technical difficulties associated with the procedure," says Angeli Christy Yu, MD, a cornea fellow at Ospedali Privati Forlì in Forlì, Italy. "The pull-through technique involves bimanual delivery of the graft under low-flow irrigation, which allows for graft insertion in a controlled manner. Since the tissue's natural tendency is to open endothelium-out, trifolding the graft endothelium-in facilitates the spontaneous unfolding of the graft within the anterior chamber, with minimal manipulation required."

The technique's developer, Massimo Busin, MD, director of the corneal unit at Ospedali Privati Forlì and a professor of ophthalmology at the University of Ferrara, Italy, says that trifolded endothelium-in DMEK is suitable for complicated cases, but in most instances, such as in eyes with a poor surgical view, complex ocular

anatomy or lower visual potential, he prefers ultra-thin DSAEK. "You can achieve excellent outcomes with either procedure," he says. "However, DMEK is associated with faster visual rehabilitation. It also significantly reduces the risk of immunologic rejection due to the smaller amount of tissue, but it's associated with higher rates of graft detachment requiring rebubbling."

To perform the technique, Professor Busin first prepares a scleral tunnel and extends it into the clear cornea. After performing descemetorhexis under air, he creates an inferior peripheral iridotomy. The donor tissue is pre-marked, pre-stripped, stained with trypan blue and punched to 8.25 mm. He uses DMEK forceps (Moria, Antony, France) and trifolds the tissue, endothelium-in. Then he transfers the graft via a sterile soft contact lens (Sooft, Montegiorgio, Italy) and pulls it into the floor of the BSS-filled IOL cartridge funnel. He seals the cartridge with a silicone plug and rotates it to ensure the floor becomes the ceiling of the cartridge funnel as it's inserted through the

This article has no commercial sponsorship.

Dr. Farid is a consultant for Allergan, Bausch + Lomb, BioTissue, CorneaGen, Dompe, Tarsus, Orasis, Johnson & Johnson Vision, KALA, Novartis, Sun Pharmaceutical and Zeiss. Dr. Okumura is the co-founder and a board member of ActualEyes and has received honoraria for lectures and consulting from Kowa, Astellas Pharma and Santen. He holds several pending patents related to cultured corneal endothelial cells. Drs. Colby, Busin, Yu, John, Narang, Oganessian, Cennamo and Mencucci have no relevant financial disclosures.

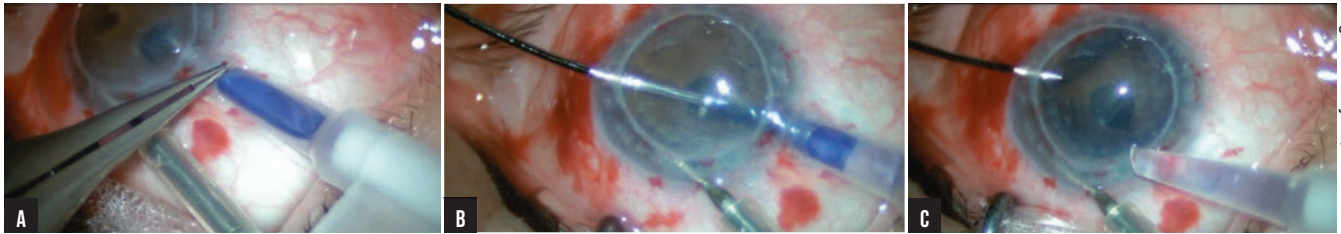


Figure 1. Trifolded DMEK graft insertion. (A) The IOL cartridge is inserted through a scleral tunnel incision. (B) Under continuous, low-flow irrigation, the edge of the DMEK graft is carefully grasped using dedicated anatomic forceps. (C) The trifolded endothelium-in DMEK graft is delivered bimanually into the AC and allowed to spontaneously unfold.

scleral tunnel incision (*Figure 1A*). Under low-flow continuous irrigation through a dedicated anterior chamber maintainer (Moria SA), he grasps the edge of the DMEK graft (*Figure 1B*) and bimanually delivers it into the AC, allowing for spontaneous unfolding (*Figure 1C*). He then injects air to attach the graft to the recipient cornea and inserts a 30-gauge needle obliquely to inject additional air to achieve complete air-fill. “I close the conjunctiva with cauterization,” he says. “The incisions can be left sutureless.”

Thomas John, MD, a clinical associate professor at Loyola University Chicago, says that time and staining may be a factor in graft unrolling. “We found that staining the donor Descemet’s membrane graft with trypan blue (Vision Blue 0.06%, DORC) may decrease DM elasticity and increase its stiffness,”³ he says. “Initially, the stained graft is often difficult to unroll, but if you wait a bit after staining, unrolling usually becomes easier.”

One study reported that grafts can be safely and effectively stained with 0.06% trypan blue for up to five minutes, but longer staining times with higher concentrations, such as 0.15%, resulted in decreased endothelial cell density approaching statistical significance.⁴

Dr. John adds that using a ball-tipped instrument on the outer corneal surface can also aid graft unrolling. He designed his own. “Applying the ball-tip on the patient’s outer cornea displaces fluid within the AC. The fluid currents you create by depressing the cornea help in

unfolding the DM,” he says.

A Technique for DMEK In Complex Eyes

Many surgical modifications for DMEK are emerging to address complicated eyes, such as those with glaucoma drainage devices (GDD). Failure rates in these eyes after DMEK and DSEK at 24 months are high, and experts believe this may be due to mechanical damage to the donor tissue caused by intermittent or constant touch between the tube shunt and graft.

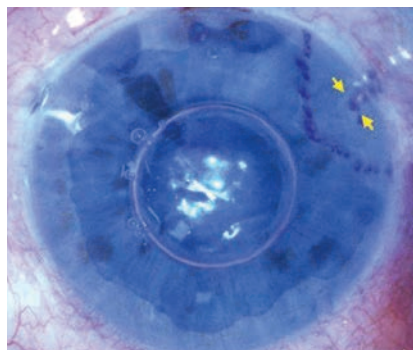
One new technique called three-quarter DMEK was described in a case series published last year by Gerrit Melles, MD, PhD, of the Netherlands Institute for Innovative Ocular Surgery, and colleagues.⁵ It’s intended for eyes with pseudophakic bullous keratopathy and GDD. The approach uses a ‘mega graft,’ a large-diameter graft modified into a $\frac{3}{4}$ shape. “We developed this technique to better facilitate graft positioning onto the recipient posterior stroma, while optimizing the spatial separation between the graft and silicone tube,” explains Oganeg Oganegyan, MD, PhD, of the Helmholtz Moscow Institute of Eye Diseases. “Using a mega graft (11 to 12 mm) may compensate for the missing tissue quarter, in terms of absolute cell numbers, especially since large-diameter grafts include the corneal periphery, where ECD is supposedly higher.”

When harvesting the graft, the trabecular meshwork remains intact and is pulled together with the mega graft. Dr. Oganegyan positions the donor tissue stromal surface-down on a soft

contact lens and dissects two triangle-shaped portions to remove a quarter of tissue. During the procedure, he creates an 11- to 12-mm descemetorhexis, except in the area at least 1.5 to 2 mm to each side of the shunt and its tip. In Dr. Oganegyan’s technique, the graft is stained with typan blue and aspirated into an 18-gauge intravenous catheter attached to a 2-ml syringe filled with BSS. After injecting the graft into the AC, he uses indirect manipulation from the outer cornea to position the graft centrally, endothelium-side down, and partially unrolls it to achieve visualization of the site with the quarter missing. “We use gentle taps with a cannula to rotate the graft into the proper position (*Figure 2*). After it’s completely unfolded, we pressurize the AC with a 100-percent air fill, which is left unreleased.”

In a case series of Dr. Oganegyan’s technique, no intraoperative or postop complications were noted.⁵ Average central ECD was $1,093 \pm 74$ cells/mm² at 12 months postop, demonstrating a decrease of 58 percent from preop values. BCVA increased from count-fingers to 20/60 at 12 months, and three-quarter DMEK remained stable with clear corneas up to 24 months.

Another DMEK technique for complex eyes was described by Professor Donald Tan, MBBS, FRCOphth(UK), a founder of the Singapore National Eye Center. His hybrid DMEK technique is intended for eyes with tube shunts, trabeculectomy, aphakia, aniridia and previous vitrectomy or keratoplasty.⁶ H-DMEK involves a bimanual pull-through technique using



Oganes Oganesyan, MD, PhD

Figure 2. The three-quarter DMEK mega graft (11 to 12 mm) is placed centrally, with the missing quarter positioned at the tube shunt location. This graft shape is thought to reduce endothelial cell loss by avoiding direct contact with the drainage device.

DSAEK-prepared donor stroma as a carrier, the EndoGlide Ultrathin DSAEK donor insertion device and an endothelium-in configuration. The case series he described in 2019 included 85 eyes with bullous keratopathy, FECD or failed grafts.⁶ H-DMEK was performed in 37 complex eyes. Four required rebubbling for graft detachment. Graft failure occurred in two cases. Overall endothelial cell loss was 32.2 ± 20.5 percent at six months.

Ultra-thin DSAEK

Ultra-thin DSAEK is a recent development that uses grafts thinner than 100 μm to provide improved visual results. “The procedure is potentially more predictable than DMEK, with a lower risk of misfolding and rebubbling (15- vs. 3-percent rate),” says Rita Mencucci, MD, a professor at the School of Ophthalmology at the University of Florence, Italy. “We might call it ‘ultimate DSAEK’ because it implies the benefits of a ‘simple’ DSAEK with results comparable to DMEK.”

She and her colleague Michela Cennamo, MD, point out that UT-DSAEK’s requirements are similar to those of DMEK. A normal anterior segment without iris abnormalities, previous tube shunt surgery, IOL issues, an unstable AC or corneal issues is ideal.

“There’s a magic formula for UT-DSAEK, and that’s to keep it simple,” says Dr. Mencucci. “I use very basic DSAEK instrumentation—an inverted Price-Sinsky hook to perform descemetorhexis, a scraper to remove the endothelium and a Busin glide with a pull-through technique to insert the graft. In UT-DSAEK, you don’t have to change surgical maneuvers, in comparison to DSAEK.”

Dr. Mencucci says carefully controlling the turbulence of the fluids in the AC will help avoid loss of correct graft orientation. “The crucial moment for UT-DSAEK is right after graft injection,” she says. “Be careful that the graft doesn’t flip. It’s difficult to find the correct orientation of an upside-down UT-DSAEK graft.”

The literature regarding visual outcomes in UT-DSAEK compared to DMEK is controversial. “Some studies report better visual outcomes after DMEK and other studies have found similar BCVA between the two,” says Dr. Cennamo. “In our study comparing outcomes in fellow eyes, we found similar BCVA at 12 months postop.⁷ Moreover, we found that posterior corneal aberrations were significantly lower after DMEK than UT-DSAEK, while anterior aberrations didn’t differ significantly.”

“With regard to postop endothelial cell count, ECD loss rate was

higher after DMEK,” Dr. Mencucci says. “This is probably caused by increased handling of DMEK tissue during surgery. However, ECD wasn’t significantly different between the two groups. DMEK outperforms UT-DSAEK in contrast sensitivity, especially in mesopic conditions and at intermediate spatial frequencies. For its quicker postop recovery and similar or better VA and lower rejection rates, I prefer DMEK even though its adoption is still limited in complicated cases.”

A Novel Corneal Layer

Pre-Descemet’s EK is a new technique pioneered by Harminder Dua, MD, FRCS, of Queens Medical Centre in Nottingham, U.K.⁸ It’s based on his team’s discovery of a novel corneal layer: pre-Descemet’s layer. In PDEK, the surgeon harvests a donor graft from PDL by creating a type-1 bubble, staining the inside of the bubble with trypan blue to mark the graft edges and then cutting around it to harvest the graft.

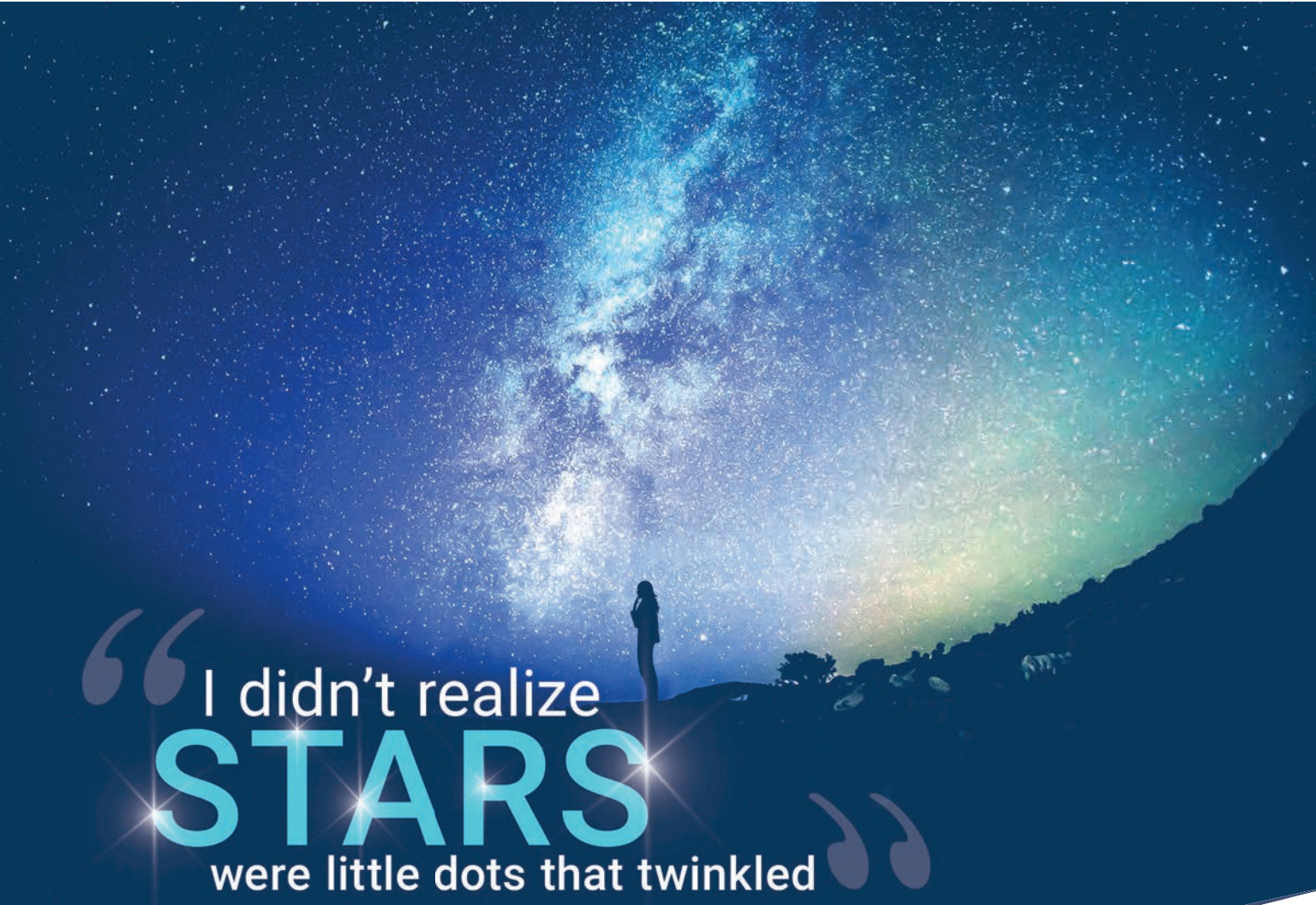
Any patient requiring EK for a corneal disorder is well-suited for PDEK, including eyes with pseudophakic bullous keratopathy with dense corneal scarring at the mid-stroma level (*Figure 3*), says Priya Narang, MS, director of the Narang Eye Care & Laser Centre in Ahmedabad, India. “There are no clear-cut contraindications

A Tool for Real-time Visualization

Intraoperative-OCT is an emerging technology that enables surgeons to visualize the cornea and anterior segment landscape in real time during surgery. “When you need higher optical resolution or your visual identification of tissue is compromised—say the view through the recipient cornea is limited due to corneal edema or some intraoperative bleeding—then i-OCT is very helpful,” says Thomas John, MD, of Chicago. “It’s also useful for titrating your air bubbles to achieve a more uniform attachment and visualization of the DM attachment contour to the inner surface of the recipient cornea. If you have i-OCT, it’s better to use it than to find gaps between the donor and recipient cornea at the slit lamp the next day and take the patient back to the OR to inject more air and optimize the donor-recipient interface.”

Marjan Farid, MD, of UC Irvine School of Medicine, says i-OCT is especially useful for surgeons doing lamellar corneal transplantation, whether it’s an EK or DALK procedure. “To be able to see the layers of the cornea and ensure the tissue orientation is correct or that there’s no interface fluid or irregularity is a real advantage,” she says. “Hopefully we’ll see it integrated more and more as it develops.”

—CL



“ I didn't realize
STARS
were little dots that twinkled ”

—Misty L, *RPE65* gene therapy recipient

**WE'RE SEEING
AMAZING RESULTS.
AND SO ARE THEY.**

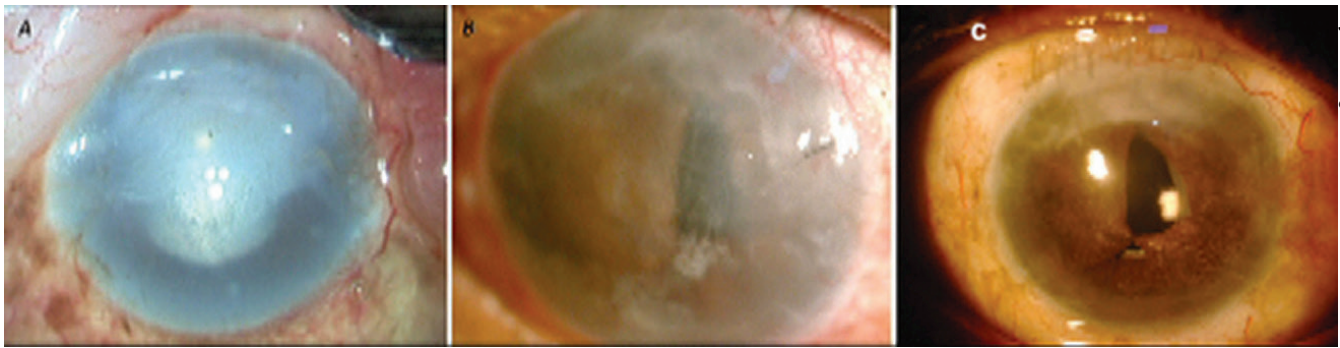
At the Foundation Fighting Blindness our mission is everybody's vision. Our work shines a light on the darkness of inherited retinal diseases (IRDs).

We're the world's leading organization searching for treatments and cures. We need your help to fuel the discovery of innovations that will illuminate the future for so many. We have robust disease information, a national network of local chapters and support groups, local educational events, and our My Retina Tracker® Registry to help keep your patients connected with clinical and research advancements.

Help accelerate our mission
by donating at ECPs4Cures.org.

**FOUNDATION
FIGHTING
BLINDNESS**

FightingBlindness.org



Priya Narang, MS

Figure 3. Pre-Descemet’s endothelial keratoplasty (PDEK). (A) Preop image of pseudophakic bullous keratopathy with corneal scarring. (B) One month after IOL explantation and glued IOL fixation, followed by PDEK and pupilloplasty. (C) Four months postop, with 20/40 vision.

tions for PDEK, but failure to create a type-1 bubble in the donor graft could be considered one clinical situation in which PDEK can’t be performed,” she notes. “If pre-cut PDEK donor grafts are available, there’s no issue of donor tissue loss.

“One of the major advantages with PDEK is that it allows for the use of infant and young donor tissue,” she adds. “This indirectly allows us to use a graft that has a relatively higher endothelial cell count, compared to grafts from older donors used in DMEK procedures. PDEK also obviates the need for microkeratomes in obtaining donor lenticules, making it a pocket-friendly and surgeon-dependent technique. Another advantage is the additional splinting effect of the PDEK graft, due to the presence of PDL. This facilitates easier handling of the graft with a more controlled, easier unrolling in the AC.” A more detailed description of this technique can be found in *Review’s* June 2020 issue, or online at bit.ly/Cornea_00.

Descemet’s Stripping Only

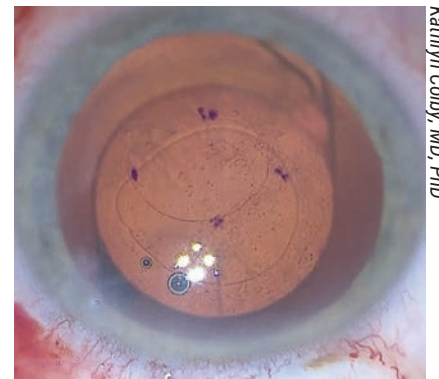
While there will always be a place for keratoplasty procedures, more methods that involve less tissue, or even no tissue at all—like Descemet’s Stripping Only—are emerging. Kathryn Colby, MD, PhD, the Elisabeth J. Cohen Professor and chair of the Department of Ophthalmology at NYU Grossman School of Medicine, performed her first DSO case in January 2014 after seeing a growing body of evidence for

corneal endothelial regeneration and spontaneous clearance in Fuchs’.⁹⁻¹¹ In 2016, she published a case series of 11 patients (13 eyes) treated with her new technique.

DSO is indicated for mild to moderate FECD, but Dr. Colby says she’s heard case reports of the technique being used in other types of focal corneal edema, such as herpetic corneal edema. “It won’t work for pseudophakic bullous keratopathy because the patient must have an adequate amount of peripheral endothelium,” she notes. “The best candidates will have central guttae affecting 4 to 5 mm of the central cornea and an unaffected peripheral endothelium. If a patient has guttae all the way out to the periphery, I don’t offer DSO but instead do an EK.”

There are several ways to remove the endothelium. Dr. Colby begins with a 2- to 3-mm clear or near-clear corneal incision, then marks the amount she plans to remove on the anterior surface of the cornea (*Figure 4*). “Right now, I use the Gorovoy forceps [Morial],” she says. “The blunt tip makes it very easy to do a controlled tear of the appropriate size. We know now that a smooth-edge tear helps endothelial cell migration.”

Other options include a reverse Sinsky hook, MST forceps or the I/A handpiece, she says. “I used the reverse Sinsky before the Gorovoy forceps were available. Some surgeons use the I/A handpiece to pull the endothelium off once they make a break through the endothelium



Kathryn Colby, MD, PhD

Figure 4. Kathryn Colby, MD, PhD, marks on the anterior cornea the amount she plans to remove in Descemet’s Stripping Only.

and create an edge.”

The postoperative healing time for DSO is slightly longer than for DMEK or DSAEK, at about three to six weeks, but Dr. Colby says this downside is well-compensated for by the procedure’s benefits. “Every patient is swollen afterwards and their vision is blurry until the endothelium heals, but there’s no risk of rejection and no need for chronic steroids with DSO,” she explains. “It’s also a cost-effective surgery because there’s no expensive corneal tissue involved. Deepinder K. Dhaliwal, MD, of the University of Pittsburgh Eye Center, published a study comparing DMEK and DSO in 2018. She reported that both procedures resulted in good vision, and that DSO’s healing time was longer, but DMEK had more complications, namely rebubbling. There’s no rebubbling after DSO because there’s no tissue.”

Dr. Colby says the more recently

published DSO case series are seeing much higher clearance rates than earlier cases, with the use of smooth-edge tears and ROCK inhibitors.

Help from ROCK Inhibitors

ROCK inhibitors stand to play an important role in endothelial procedures. “Greg Maloney, MBBS, MMed, FRCSC, of the Sydney Eye Hospital in Australia, rescued a couple of slow-to-clear DSO patients in 2016 with the ROCK inhibitor ripasudil [Glanatec, Kowa],” Dr. Colby says. “Since then, I’ve been telling my DSO patients about ROCK inhibitors. I can’t prescribe ripasudil because it’s not approved in the U.S., but if my patients choose to get it online, I can follow them while they’re using it. Most tend to choose it; they use it four times daily.”

Ripasudil is a 0.4% hydrochloride hydrate that’s been approved for use in glaucoma and ocular hypertension in Japan since 2014. Netarsudil (Rhopressa, Aerie), another ROCK inhibitor, is an amino-isoquinolone amide that received FDA approval in December 2017 but isn’t available yet.

“We have a multicenter, multinational trial (K-321: NCT04250207) going on now for ripasudil, sponsored by the manufacturer Kowa,” adds Dr. Colby, who serves as the U.S. chair for the trial through a research contract with NYU. “We recently completed enrollment and anticipate some topline results by the end of the year. Assuming they’re positive, we’ll go forward with a Phase III trial next year.”

When applied to cultured human corneal endothelial cells, ROCK inhibitors modulate their adhesion to the substrate, says Naoki Okumura, MD, PhD, of the department of biomedical engineering at Doshisha University, Kyoto City, Japan. “Human CECs recovered from a

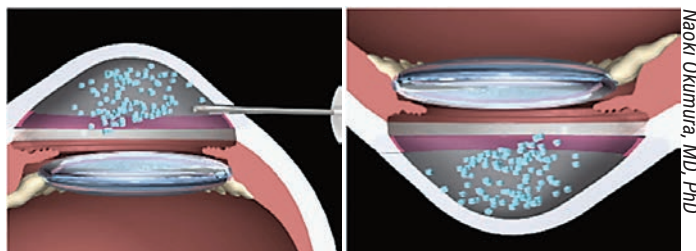


Figure 5. After cell injection, the patient lies face down to encourage the cells to adhere to the stroma.

Naoki Okumura, MD, PhD

culture plate undergo dissociation-induced Rho/ROCK/MLC signaling activation, which results in impairment of cell adhesion,” he explains. “The ROCK inhibitor enhances cell adhesion by counteracting the dissociation-induced activation of this signaling pathway.”

Cell Injection Therapy

Cell injection is one of the developing cell-based approaches to corneal endothelial disorders that makes use of *in vitro* cultured hCECs. In place of a donor tissue transplant, these cultured cells are injected into the eye with the goal of adhering to and clearing the cornea.

“Cell injection has multiple benefits,” says Dr. Farid. “With one donor cornea, you can potentially treat thousands of diseased corneas. In a worldwide shortage of donor corneas, this is a huge step and an advance in terms of making tissue available to patients who wouldn’t have access in the past.

“Cell injection will also simplify the procedure,” she says. “Instead of a full EK procedure, we could inject cells into the anterior chamber and position the patient face-down for a few hours while the cells adhere and start to clear the cornea.”

Dr. Okumura is currently developing pharmaceutical and tissue-engineering treatments for corneal endothelial dysfunction, including cell injection therapy. He says that in addition to enhancing cell adhesion, the ROCK inhibitor Y-27632 demonstrates other effects on cultured hCECs, including promotion of proliferation and suppression of apoptosis.

“In 2013, we initiated a first-in-human clinical trial of cell-based therapy at the Kyoto Prefectural University of Medicine,” he says. “By 2017, thirty-five patients with corneal endothelial decompensation had undergone cultured hCEC-injection therapy.

We reported the clinical results of the first 11 cases in 2018.¹² All 11 eyes recovered corneal transparency. After two years, all patients exhibited improved visual acuity, with VA better than 0.8 decimal (20/25 Snellen) in nine of 11 patients.”

He says that any cells for clinical use should be cultured in a cell processing center to ensure safety and efficacy. “Some companies will probably develop cultured hCEC products,” he says. “Then they’ll ship them to the hospital as ready-to-use products.”

Aurion Biotech, a newly launched division of CorneaGen devoted to developing Shigeru Kinoshita, MD, PhD’s cell injection therapy, announced the results of its proof-of-concept IOTA trial at the ASCRS Meeting in Las Vegas in July. Cells from two donors were used to treat 50 patients with corneal endothelial disease in El Salvador. Ed Holland, MD, the company’s chief medical advisor, reported that the minimally-invasive procedure yielded improved visual acuity and central corneal thickness.¹³ The company says this therapy has the potential to treat up to 100 eyes with endothelial cells from a single donor and involves a recovery period of only a few hours.

One major benefit of cell injection therapy compared to transplant procedures is that it won’t require donor-recipient matching. Human CECs are considered universal donors because the cornea is avascular; without blood present, there’s no need for a specific donor blood type, which will expand the pool of potential recipients. In the Aurion

Eye Banks and the Tissue Issue

Eye banks and the pre-prepared tissue they offer have become indispensable to many corneal surgeons. “I consider eye-bank-prepared tissue superior to surgeon-prepared tissue,” says Marjan Farid, MD, of UC Irvine School of Medicine. “Surgeons don’t prepare tissue day in and day out, and they can potentially introduce more errors into the process. Tissue prepared by an eye-bank technician decreases surgeon variability and improves predictability and surgical time. Now eye banks are pre-loading DMEK and DSAEK tissue into cannulas like the Geuder cannula or the Endoserter, which makes the surgery more straightforward,” she says. “It saves time injecting the tissue into the AC and unscrolling it.”

Eye banks do important work, but in many countries, they’re limited by inadequate supply. It’s estimated that globally, there’s only one corneal graft available for every 70 eyes.¹⁵ Descemet’s Stripping Only and cell injection therapies that require no donor tissue or can repurpose a single donor to treat multiple patients may be what’s needed to address the shortage, but those therapies aren’t suitable for every case.

In cases where a transplant is required, researchers are investigating using smaller grafts. Quarter DMEK, described last year by Gerrit Melles, MD, PhD, and his colleagues, has the potential to quadruple endothelial graft availability, according to researchers in the Netherlands.¹⁶ They reported positive one- and two-year clinical outcomes, where all 19 eyes reached a BCVA of $\geq 20/40$ at six months, 95 percent of eyes (n=18) reached $\geq 20/25$ and 42 percent of eyes (n=9) reached $\geq 20/20$. BCVA remained stable at two years. Mean donor ECD decreased from $2,842 \pm 139$ cells/mm² before implantation to 913 ± 434 cells/mm² at six months, representing a 68-percent decrease. ECD decreased by 70 and 74 percent at 12 and 24 months, respectively. Eight eyes required rebubbling due to visually significant graft detachment. While more work is needed to improve graft preparation and surgical technique, the researchers are hopeful that this method may boost endothelial graft access.

“We know from previous case reports that eyes receiving only a small portion of donor tissue with healthy donor endothelial cells can clear up, demonstrating cell migration,” says Thomas John, MD, of Chicago. “If you divide one donor DM into two, you’ve already doubled your donor pool. Techniques like this may be useful, especially in parts of the world experiencing shortages of donor corneal tissue, but in the U.S., these aren’t necessarily needed at this time. Additionally, there are regulatory requirements that need to be fulfilled. Eye banks track one donor tissue to a single recipient, so segmenting grafts would require additional steps and tracking requirements. A smaller graft will also take longer to clear the cornea, since you must wait for the cells to migrate and populate the bare areas of the recipient cornea.”

—CL

procedure, the patient’s diseased epithelium is removed by polishing; then cultured hCECs are injected into the anterior chamber and the patient lies face-down for three hours to encourage cellular adhesion to the stroma (*Figure 5*).

This may not be as simple as it sounds, however. “A challenge of cell injection will be localization to the inner corneal surface,” says Dr. John. “Cells may disperse into the AC angle, the TM or even the posterior segment.”

While Dr. Kinoshita’s group uses face-down positioning to encourage

endothelial cell migration, others developing cell injection therapies are using alternate techniques. One potential approach to cell localization is a form of magnetic cell delivery, proposed by Jeffrey L. Goldberg, MD, PhD, a professor and chair of ophthalmology at Stanford University. He’s developed a novel method of cell delivery that involves cultured hCECs labeled with magnetic nanoparticles. These cells are injected into the anterior chamber, and the patient wears a magnetic eye patch to attract the cells toward the central cornea.¹⁴ Dr. Goldberg’s

company, Emmetrope Ophthalmics, is developing the therapy. Its IND application for EO2002 was accepted by the FDA in September 2020. ◀

1. Sarnicola C, Farooq AV, Colby K. Fuchs endothelial corneal dystrophy: Update on pathogenesis and future directions. *Eye & Contact Lens* 2019;45:1-10.
2. Busin M, Leon P, Scoria V, Ponzin D. Contact lens-assisted pull-through technique for delivery of tri-folded (endothelium-in) DMEK grafts minimizes surgical time and cell loss. *Ophthalmology* 2016;123:476-83.
3. John T, Patel A, Vasavada A, et al. Effect of trypan blue on Descemet membrane elasticity. *Cornea* 2016;35:11:1401-3.
4. Majmudar PA, Johnson L. Enhancing DMEK success by identifying optimal levels of trypan blue dye application to donor corneal tissue. *Cornea* 2017;36:2:217-221.
5. Oganeyan O, Makarov P, Grdikanyan A, et al. Three-quarter DMEK in eyes with glaucoma draining devices to avoid secondary graft failure. *Acta Ophthalmol* 2020. [Epub ahead of print].
6. Woo JH, Htoon HM, Tan D. Hybrid descemet membrane endothelial keratoplasty (H-DMEK): Results of a donor insertion pull-through technique using donor stroma as carrier. *Br J Ophthalmol* 2020;104:10:1358-62.
7. Mencucci, et al. Ultrathin Descemet stripping automated endothelial keratoplasty versus Descemet membrane endothelial keratoplasty: A fellow-eye comparison. *Eye and Vis* 2020;7:25. [Epub May 6, 2020].
8. Agarwal A, Dua HS, Narang P, et al. Pre-Descemet’s endothelial keratoplasty (PDEK). *Br J Ophthalmol* 2014;98:1181-85.
9. Dirisamer M, Yeh R, Melles G, et al. Recipient endothelium may relate to corneal clearance in descemet membrane endothelial transfer. *Am J Ophthalmol* 2012;154:2:290-6.
10. Koenig SB. Long-term corneal clarity after spontaneous repair of iatrogenic descemetorhexis in a patient with Fuchs dystrophy. *Cornea* 2013;32:6:886-8.
11. Shah RD, Randleman JB, Grossniklaus HE. Spontaneous corneal clearing after Descemet’s stripping without endothelial replacement. *Ophthalmology* 2012;119:2:256-60.
12. Kinoshita S, Koizumi N, et al. Injection of cultured cells with a ROCK inhibitor for bullous keratopathy. *N Engl J Med* 2018;378:995-1003.
13. Holland E. FAQ Corneal Endothelial Cell Therapy. Presented at ASCRS in Las Vegas. July 20, 2021.
14. Moysidis SN, Alvarez-Delfin K, Peschansky VJ, et al. Magnetic field-guided cell delivery with nanoparticle-loaded human corneal endothelial cells. *Nanomedicine* 2015;11:3:499-509.
15. Gain P, Jullienne R, He Z, et al. Global survey of corneal transplantation and eye banking. *JAMA Ophthalmol* 2016;143:2:167-73.
16. Birbal RS, Ni Dhubhghaill S, Baydoun L, et al. Quarter-Descemet membrane endothelial keratoplasty: One- to two-year clinical outcomes. *Cornea* 2020;39:3:277-82.



I was only seeing light flashes early on, but light

FLASHES

when you've not seen anything for
so many years—it was wonderful

—Keith H, retinal prosthesis recipient

**WE'RE SEEING
AMAZING RESULTS.
AND SO ARE THEY.**

At the Foundation Fighting Blindness our mission is everybody's vision. Our work shines a light on the darkness of inherited retinal diseases (IRDs).

We're the world's leading organization searching for treatments and cures. We need your help to fuel the discovery of innovations that will illuminate the future for so many. We have robust disease information, a national network of local chapters and support groups, local educational events, and our My Retina Tracker® Registry to help keep your patients connected with clinical and research advancements.

Help accelerate our mission
by donating at ECPs4Cures.org.

**FOUNDATION
FIGHTING
BLINDNESS**

FightingBlindness.org



EDITED BY KULDEV SINGH, MD, MPH,
AND PETER A. NETLAND, MD, PHD

GLAUCOMA MANAGEMENT

Managing Bleb Dysesthesia

This occasional side effect of trabeculectomy can undermine a patient's quality of life. Here's how to address it.

ELYSE J. MCGLUMPHY, MD
BALTIMORE

Although trabeculectomy is less-often performed than it once was, due to a vastly expanded pool of glaucoma surgical options, it's still one of the most prominent and enduring procedures in glaucoma. One potential drawback of a bleb-producing procedure like trabeculectomy is the possibility of bleb-associated discomfort, or dysesthesia. This can happen shortly after surgery or many years later. It's something glaucoma providers should be able to recognize and treat to optimize patient care and quality of life.

Here, I'd like to discuss some of the causes of bleb dysesthesia and the seven different approaches (beyond simple, conservative treatment) that surgeons commonly use to address this type of problem.

Understanding Dysesthesia

Unfortunately, there's no exact definition of bleb dysesthesia. In general, you can think of it as a spectrum of symptoms, including ocular discomfort, that patients may feel after filtering surgery. Those symptoms include tearing, pain, ocular surface irritation (for example, foreign-body sensation) and/or persistently fluctuating vision—es-

pecially when the patient blinks.

Which patients are most likely to end up with a bleb dysesthesia complaint? Donald Budenz, MD, at Bascom Palmer did a study investigating this question;¹ he found that factors often associated with complaints of bleb dysesthesia included:

- younger age;
- a superonasal bleb;
- poor lid coverage of the bleb; and
- bubble formation at the bleb-cornea margin when the patient blinks (this is more likely to occur when there's a steeper angle where the cornea ends and the bleb starts).

Surprisingly, having a very high bleb wasn't a significant risk factor. Corneal dellen (focal thinning in the cornea) can also cause a lot of irritation; it's more likely to occur in patients with a poor tear film or pre-existing dry eye and a superonasal bleb.

Fortunately, it's rare that patients experience symptoms severe enough to require invasive intervention after trabeculectomy or any bleb-forming procedure. Nevertheless, it does occasionally happen, and, it can occur at any time postoperatively, from months to many years after the original surgery.

Helping the Patient

When a patient first comes in com-

plaining of bleb dysesthesia, I want to know how long it's been since they had the surgery. If it's only been two or three months, I'm likely to wait to do anything to modify the bleb because it might remodel as the eye heals and forms scar tissue. But if a patient comes in and says she had the bleb surgery 15 years ago and has had symptoms for the past five years, I'll begin with conservative treatments such as artificial tears or gel formulations. If those conservative measures fail and a patient has had long-standing symptoms, that's a patient who's more likely to need surgery. The chances of the bleb remodeling at that point are quite low.

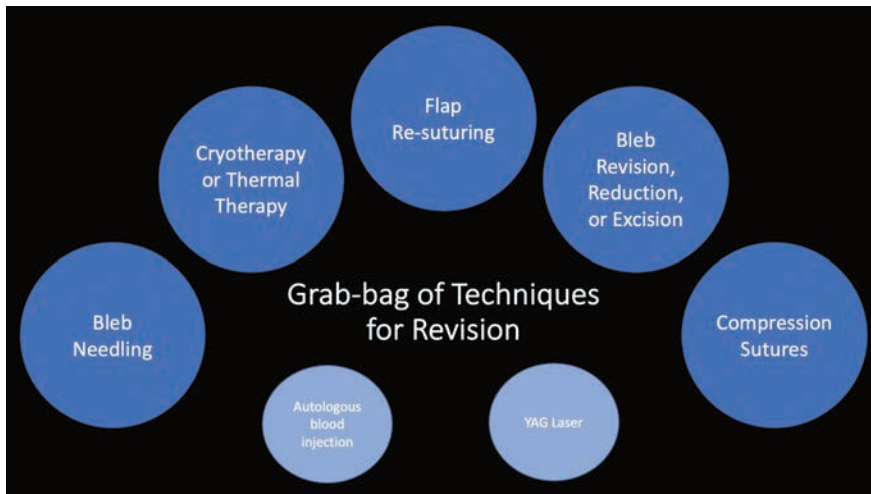
In many cases, conservative management with tears or gels will be sufficient; they help to smooth out the ocular surface and give the patient relief from the symptoms. Some physicians will prescribe NSAID drops as an additional non-surgical option. I don't use this approach for several reasons: NSAIDs don't target the problem; patients often have discomfort when using the drops; and long-term use can be associated with unwanted side-effects. Use of a bandage contact lens may be helpful for reducing patient symptoms and compressing the bleb, but this is typically only a short-term solution.

Less-invasive treatments such as thermal laser application and autologous blood injection have been used for treatment of bleb dysesthesia. Personally, I don't use these methods as I feel the outcomes are less predictable than those achieved with a more refined surgical approach.

If your patient fails conservative treatment, often the next step is surgical revision, and there's no single

This article has
no commercial
sponsorship.

Dr. Singh is a professor of ophthalmology and chief of the Glaucoma Division at Stanford University School of Medicine. Dr. Netland is Vernah Scott Moyston Professor and Chair at the University of Virginia in Charlottesville.



approach that's always best. That's partly because there are so many different causes of bleb dysesthesia. It could be the result of a very diffuse bleb; it can be caused by a dellen formation (a focal dehydration in the cornea, which causes a lot of irritation); it could be because the bleb is very nasal, which is often poorly tolerated, or because the bleb is overhanging on to the cornea; and/or the result of fluctuating vision. Furthermore, there could be a component of overfiltration, leaving the intraocular pressure on the low end; that will certainly impact how you choose to address the situation. So there's no single "best way" to address bleb dysesthesia. The result is a grab-bag of possible treatments hoping to achieve a similar outcome: a functional surgery that's well-tolerated by the patient.

Surgical Approach Options

Once conservative treatment has failed to provide relief, surgery may be the next step. While there are many approaches to surgical treatment, one of these seven options may help:

- **Bleb needling.** In some cases posterior scarring causes a very anterior bleb to be thin-walled and form a small pocket of fluid which can often overhang onto the cornea. This encapsulation can also interfere with bleb function, causing an

elevated IOP. In this situation, bleb needling is a great way to encourage the bleb to be more diffuse and low-lying, and it can also help to reduce elevated IOP by breaking up some of that scar tissue and encouraging posterior flow.

If you do bleb needling for dysesthesia, it's important to inject an antimetabolite such as mitomycin-C or 5-FU at the same time. If you don't, the posterior scarring is likely to return.

- **Flap resuturing.** Some blebs that cause discomfort for the patient may be very large; this is often accompanied by overfiltering, and may be associated with a low IOP as well. In that situation, I like to take down the conjunctiva and resuture the flap to reduce the amount of aqueous flowing through the flap. This helps to reduce the bleb size and may help resolve the patient's dysesthesia, as well as any excessively low IOP.

- **Compression sutures.** Another way to deal with a really large, diffuse bleb is by putting in compression sutures. There are many successful techniques for placing compression sutures. One technique developed by Paul Palmberg, MD, for accomplishing this is very popular. Using a 9-0 or 10-0 nylon, the surgeon makes a mattress suture from the cornea over the bleb to the episcleral or Tenon's, parallel to the bleb; the suture, or sutures,

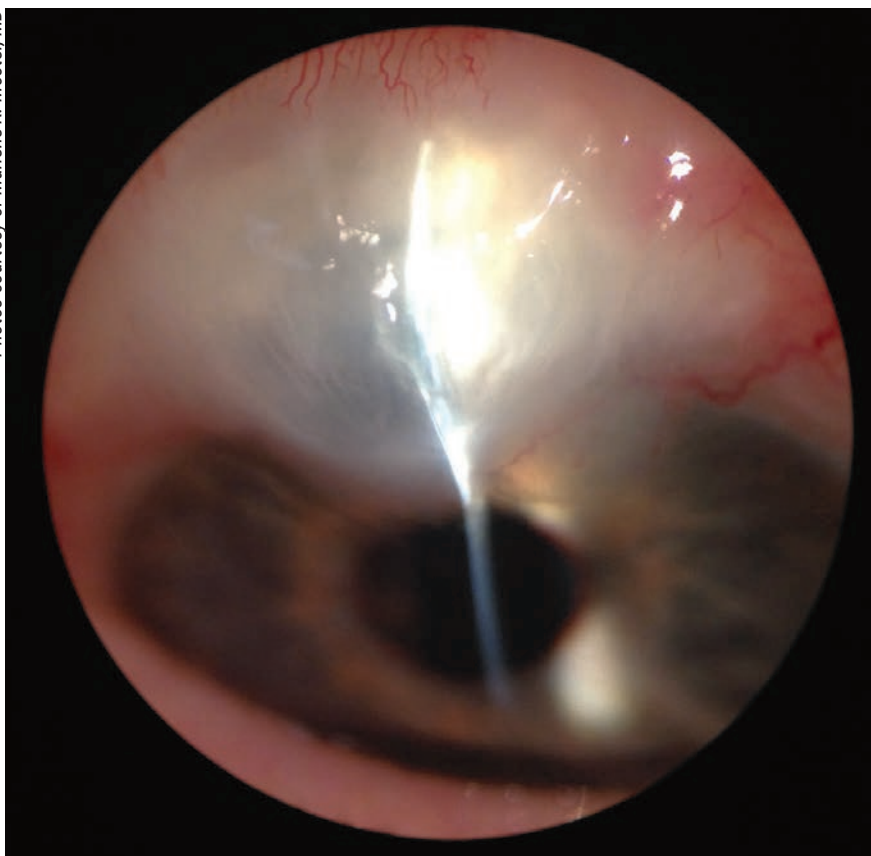
compress the bleb.² The hope here is that you're going to create an adhesion between the conjunctival bleb tissue and the underlying tissue, limiting the extent of the bleb. You can remove the sutures one to four weeks after the surgery. (This approach can also help with bleb overfiltration.)

- **Cryotherapy.** This technology can be helpful for bleb remodeling. I like to use this technique for blebs with significant nasal extension. One technique is to create a window in the conjunctiva in the nasal area where the bleb has extended. The surgeon can then use cryotherapy to secure down the edge of the window, encouraging adhesion to the underlying sclera. The scarring that results helps to limit the nasal extension.^{3,4} There are other creative ways to use cryotherapy alone or in combination with suturing techniques to limit the breadth of the bleb.

- **Surgical excision.** Another useful approach, especially when the bleb is very anterior, thin-walled, avascular, high and irritating to the patient, is to excise all of the bleb tissue and then pull healthy conjunctiva forward and suture it down. The hope is that this approach will allow for a more diffuse bleb.

- **Autologous blood injection.** This technique, sometimes used to address a late-onset bleb leak, isn't very popular today; in fact, I don't personally know of any surgeons that still inject autologous blood for bleb dysesthesia. It's thought that injection of blood encourages a fibrotic response and thereby limits flow and perhaps could encourage scarring.⁵ In my experience, surgery is a more refined and controlled way to address bleb issues. Furthermore, autologous blood injection could cause bleb failure.

- **YAG laser.** Like autologous blood injection, this isn't often used to address bleb issues today. Using a continuous-wave multimode (frequency-doubled) neodymium-YAG laser, creating a thermal response



A thin-walled cystic conjunctival bleb with corneal overhang. This could be addressed via bleb revision with excision of the corneal overhang and resection of the avascular tissue, with anteriorization and suturing of posterior, healthy conjunctiva to the limbus.

in the tissue, the laser is applied in a grid-like pattern over the bleb to encourage the tissue to shrink down. (Note: It's difficult to remodel and shrink tissue in the bleb without use of methylene blue or gentian violet ink—applied with a surgical marking pen on the dry bleb surface—as a chromophore for the laser, which enables adequate absorption of laser energy in the bleb.) This approach can be effective as a way to lower the height of the bleb or remodel steep edges. (In this situation, surgical revision is an alternative to laser revision of the bleb.)

Another option is to completely close the existing bleb and perform a different type of pressure-lowering surgery instead. I've had some patients request this option; because of long-standing discomfort, they don't want any type of bleb-forming procedure. This could mean suturing

the flap shut, excising the avascular tissue and possibly putting a corneal or scleral patch graft over the old flap site.

“**One problem when managing bleb dysesthesia is that it's hard to predict the outcome.**”

Closing down a trabeculectomy can result in a dramatic rise in IOP, so this will need to be considered in surgical planning. If you don't immediately do another IOP-lowering procedure, the next day you're going to see that patient with a very high pressure. Most of the time, you may have to do an additional IOP lowering surgery at the same time as, or soon after, you close down the existing bleb. In my practice, I'd typically

consider placement of a tube shunt at that time.

Which surgery you choose to replace the trabeculectomy in this situation depends on numerous factors, including how bad the glaucoma is and how low the pressure needs to be. In most cases, if the patient has serious glaucoma, I switch to a tube or some other non-bleb-forming procedure. (Some surgeons might consider implanting a XEN shunt, which can produce a more posterior bleb; in theory that might be associated with less discomfort. But at this point I don't think we have enough data to know whether a XEN bleb would be less likely to cause bleb dysesthesia.)

Does Treatment Work?

One problem when managing bleb dysesthesia is that it's hard to predict the outcome; every case is different and the management varies tremendously. (This also makes it difficult when you want to study the treatments and outcomes.)

One way we can address this is to look at large sets of data; this can give us a general idea of the outcomes of such procedures. There are some large studies that look at bleb revisions and show subgroup analyses of the revisions that were done to address bleb dysesthesia. We've learned some useful information from these studies that can help us guide our patients when we're counseling them regarding surgical options for treatment:

— *Retrospective studies suggest that 50 to 100 percent of patients treated for bleb dysesthesia achieve success.* This means it may be safe to suggest that at least half of your patients are likely to get relief following treatment.⁶

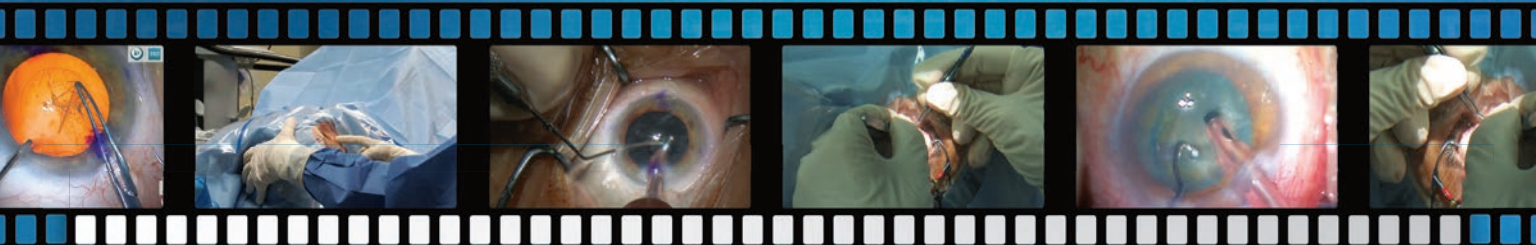
— *In patients who have a bleb revision, 9 to 15 percent are going to need more surgery to lower the pressure.* That's actually pretty encouraging; even though you're modifying the original surgery, not that many of these people go on to need more



Monthly

MACKKOOOL ONLINE CME

CME SERIES | SURGICAL VIDEOS



To view CME video
go to:

www.MackkoolOnlineCME.com

Episode 69: "The Extremely Deep Anterior Chamber"

Surgical Video by:
Richard J. Mackkool, MD

Video Overview:

An extremely myopic eye with an increased anterior chamber depth that reduces visibility of the nucleus receives an intravitreal injection to overcome the problem.

MackkoolOnlineCME.com MONTHLY Video Series



Richard J. Mackkool, MD

We are excited to continue into our sixth year of Mackkool Online CME. With the generous support of several ophthalmic companies, I am honored to have our viewers join me in the operating room as I demonstrate the technology and techniques that I have found to be most valuable, and that I hope are helpful to many of my colleagues. We continue to edit the videos only to either change camera perspective or to reduce down time - allowing you to observe every step of the procedure.

As before, one new surgical video will be released monthly, and physicians may earn CME credits or just observe the case. New viewers are able to obtain additional CME credit by reviewing previous videos that are located in our archives.

I thank the many surgeons who have told us that they have found our CME program to be interesting and instructive; I appreciate your comments, suggestions and questions. Thanks again for joining us on Mackkool Online CME.



CME Accredited Surgical Training Videos Now Available Online: www.MackkoolOnlineCME.com

Richard Mackkool, MD, a world renowned anterior segment ophthalmic microsurgeon, has assembled a web-based video collection of surgical cases that encompass both routine and challenging cases, demonstrating both familiar and potentially unfamiliar surgical techniques using a variety of instrumentation and settings.

This educational activity aims to present a series of Dr. Mackkool's surgical videos, carefully selected to address the specific learning objectives of this activity, with the goal of making surgical training available as needed online for surgeons motivated to improve or expand their surgical repertoire.

Learning Objective

After completion of this educational activity, participants should be able to:

- perform a surgical option to reduce an anterior chamber that is overly deep.

Satisfactory Completion - Learners must pass a post-test and complete an evaluation form to receive a certificate of completion. You must listen to/view the entire video as partial credit is not available. If you are seeking continuing education credit for a specialty not listed below, it is your responsibility to contact your licensing/certification board to determine course eligibility for your licensing/certification requirement.



JOINTLY ACCREDITED PROVIDER™
INTERPROFESSIONAL CONTINUING EDUCATION

Physicians - In support of improving patient care, this activity has been planned and implemented by Amedco LLC and Review Education Group. Amedco LLC is jointly accredited by the Accreditation Council for Continuing Medical Education (ACCME), the Accreditation Council for Pharmacy Education (ACPE), and the American Nurses Credentialing Center (ANCC), to provide continuing education for the healthcare team

Credit Designation Statement - Amedco designates this enduring material activity for a maximum of .25 AMA PRA Category 1 Credits™. Physicians should claim only the credit commensurate with the extent of their participation in the activity.

Jointly provided by:




Supported by an unrestricted independent
medical educational grant from:



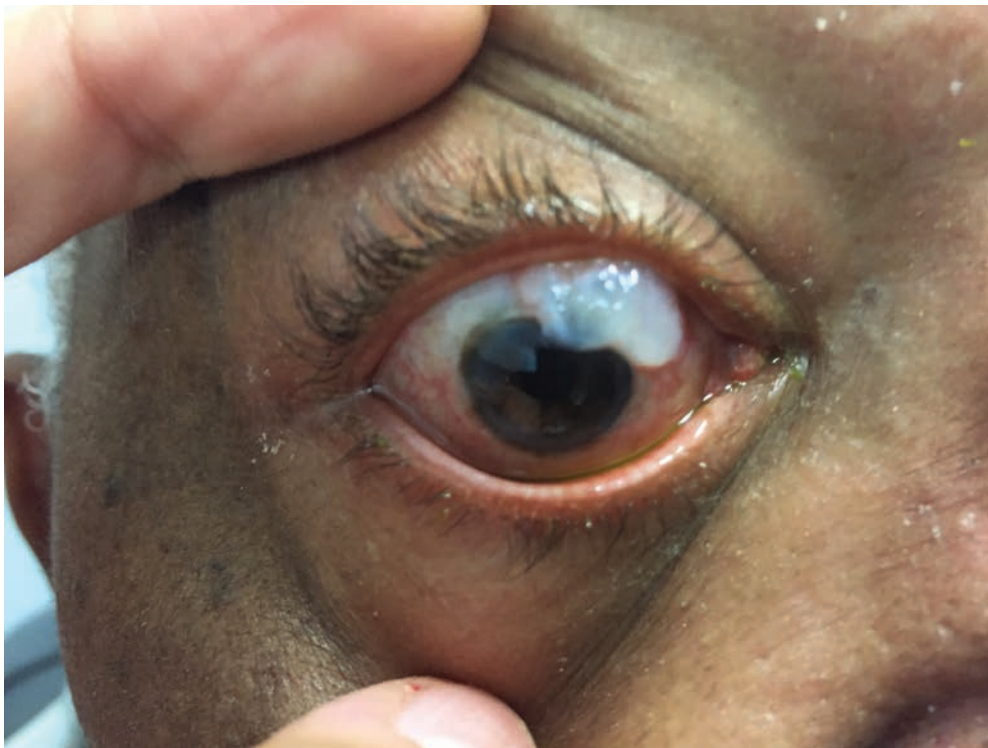
Additionally Supported by:



In Kind Support:



Video and Web Production by:
JR Snowden, Inc



A patient with a tall, anterior, thin-walled nasal bleb causing bleb dysesthesia. This could be addressed via needling to encourage posterior flow and nasal bleb revision with suturing or cryotherapy.

surgery. (This is obviously not applicable when you shut down the original trabeculectomy.⁶)

— *Occasionally, patients who undergo revision for dysesthesia will require a re-revision when the first revision isn't successful.* Some of the retrospective data suggests a little over 10 percent of patients may undergo a second revision for dysesthesia.⁷ (Patients may be more reluctant to undergo a second revision.)

— *Most encouraging, the majority of patients who undergo revision for bleb dysesthesia experience little to no change in vision from the original procedure.*⁷ In fact, some patients may experience a slight improvement in vision, which may be due to a reduction in astigmatism. So you can be somewhat reassured that you're not compromising the patient's visual acuity by going in there and modifying the bleb.

Note that these results were obtained by experienced surgeons. Having experience helps the surgeon choose among the many

options and combinations of treatments for the patient's specific bleb problem. It's an art to choose the best approach, because—as noted earlier—there's no single cookie-cutter treatment for this problem that will work for every patient.

One Final Thought

With any patient in this situation, it's important to manage expectations. You need to explain that your goal is to reduce their symptoms, and that more than 50 percent of patients do get relief, but the other half may continue to have symptoms. In short, your patient needs to understand that there's a chance the surgery could fail to help them, and they might need further surgery later on, either to lower the pressure or to relieve symptoms.

In any case, glaucoma can be a challenging diagnosis for patients, and it's important for us to listen to our patients and do what we can to improve their quality of life as a part of the treatment of their disease. We

can often get the pressure lower, but we always have to remember that we're treating the person, not just the eye. In most cases, the patient will get some relief as a result of your efforts, and you may improve their glaucoma control as well. ◀

1. Budenz DL, Hoffman K, Zacchei. Glaucoma filtering bleb dysesthesia. *Am J Ophthalmol* 2001;131:5:626-30.
2. Palmberg P, Zacchei AC. Compression sutures - A new treatment for leaking or painful filtering blebs. *Investigative Ophthalmology and Visual Science* 1996;37:3: S444.
3. El-Harazi SM, Fellman RL, Feldman RM, Dang YNT, Chuang Z. Bleb window cryopexy for the management of oversized, misplaced blebs. *Journal of Glaucoma* 2001;10:1:47-50.
4. Tabet R, Feldman RM, Bell NP, Lee DA. "Bleb window"-pexy for the management of symptomatic, oversized blebs. *Journal of Glaucoma* 2009;18:7:546-551.
5. Smith MF, Magauran RG 3rd, Betchkal J, Doyle JW. Treatment of postfiltration bleb leaks with autologous blood. *Ophthalmol* 1995;102:6:868-71.
6. Radhakrishnan S, Quigley HA, Jampel HD, et al. Outcomes of surgical bleb revision for complications of trabeculectomy. *Ophthalmology* 2009;116:9:1713-8.
7. Cardakli N, Weinreb SF, Jefferys ScM JL, Quigley HA. Long-term functional outcomes of trabeculectomy revision surgery. *Ophthalmol Glaucoma* 2019;2:4:240-250.

Further reading:

- Anis S, Ritch R, Shihadeh W, Liebmann J. Surgical reduction of symptomatic, circumferential, filtering blebs. *Arch Ophthalmol* 2006;124:6:890-4.
- Cardakli N, Friedman DS, Boland MV. Unplanned return to the operating room after trabeculectomy. *Am J Ophthalmol* 2020;219:132-140.
- La Borwit SE, Quigley HA, Jampel HD. Bleb reduction and bleb repair after trabeculectomy. *Ophthalmology* 2000;107:4:712-8.
- Morgan JE, Diamond JP, Cook SD. Remodeling the filtration bleb. *British Journal of Ophthalmology* 2002;86:8:872-875.
- Roesch M, Brown RH. Remodeling filtering blebs with the neodymium: YAG laser. *Ophthalmology* 1996;103:1700-1705.
- Sanders R, MacEwen CJ, Haining WM. Trabeculectomy: Effect of varying surgical site. *Eye (Lond)* 1993;7(Pt 3):440-3.
- Soong HK, Quigley HA. Dellen associated with filtering blebs. *Arch Ophthalmol* 1983;101:3:385-7.

ABOUT THE AUTHOR



Dr. McGlumphy is an assistant professor of ophthalmology at Johns Hopkins School of Medicine in Baltimore. She has no financial interest in any product mentioned in this article.

A PUBLICATION BY **REVIEW**
OF OPHTHALMOLOGY

RETINA SPECIALIST

Retina Specialist focuses on the latest advances in the diagnosis, medical management and surgical treatment of diseases of the retina, along with practical, real-world advice from leading clinicians and other experts on managing the successful retina practice.

KEEP UP WITH CUTTING-EDGE SCIENCE IN RETINA.

Watch for issues in:

- JANUARY/FEBRUARY
- MARCH/APRIL
- MAY/JUNE
- JULY/AUGUST
- SEPTEMBER/OCTOBER
- NOVEMBER/DECEMBER



FOR INQUIRIES CONTACT
RETINASPECIALIST@JOBSON.COM

ADVERTISING OPPORTUNITIES

MICHAEL HOSTER • PUBLISHER • 610-492-1028 • MHOSTER@JOBSON.COM

JIM HENNE • 610-492-1017 • JHENNE@JOBSON.COM

MICHELE BARRETT • 215-519-1414 • MBARRETT@JOBSON.COM

JONATHAN DARDINE • 610-492-1030 • JDARDINE@JOBSON.COM

www.retina-specialist.com



@RetSpecMag



RetinaSpecialistMag



EDITED BY THOMAS JOHN, MD

CORNEA/ANTERIOR SEGMENT

Ocular Surface Tumor Diagnostics

Experts evaluate the best imaging modalities for assessing suspicious lesions.

BY MIKE ZEIN, MD, MS, MAK DJULBEGOVIC, MSC, ANAT GALOR, MD, MSPH, LAILA E. TEIRA, MD AND CAROL L. KARP, MD
MAIMI

Tumors of the ocular surface and the anterior segment of the eye may result from a wide range of conditions. Benign or malignant lesions may originate from several cell types, forming epithelial, melanocytic, lymphoid, fibrous and many other lesions.¹ It's important to determine the etiology and malignant potential of a lesion for appropriate diagnosis and treatment guidance. Tissue biopsy is the gold standard for establishing a diagnosis, but imaging-based modalities have been developed that can aid the clinician in assessing these tumors prior to histopathological confirmation.

The four most commonly used modalities are high-resolution anterior segment optical coherence tomography (HR-OCT), OCT angiography, ultrasound biomicroscopy and *in-vivo* confocal microscopy (IVCM).¹⁻³ While useful, each technology has strengths and weaknesses that must be considered when examining ocular surface lesions. Here, we'll highlight the pros and cons and discuss how these technologies can be incorporated in the evaluation of a patient with an ocular surface tumor.

High-resolution AS-OCT

Anterior segment optical coherence

tomography provides high-resolution cross-sectional images of the anterior segment tissue through optical scattering created by low-coherence interferometry.⁴ Since its first iteration by David Huang, MD, PhD, and colleagues, HR-OCT technology has progressed to resolutions of 5 to 10 μm and scan depths up to 2 to 7 mm. Ultrahigh-resolution anterior segment OCT provides even higher resolution of 2 to 5 μm .⁵⁻⁷

• **Advantages.** In today's ophthalmic practice, HR-OCT provides an in-office, non-invasive diagnostic modality with readily available results, allowing for an "optical biopsy" that often mirrors the pathologic changes seen on histopathology.^{5,7,8} This is useful in clinical decision making. For example, in a lesion with classic clinical and OCT features of ocular surface squamous neoplasia (OSSN), treatment with topical chemotherapy may be initiated. In a lesion with features of melanoma, the surgeon should defer an incisional biopsy and instead plan a treatment with an excision biopsy with wide margins and adjuvant cryotherapy.

Anterior OCT is most useful for differentiating epithelial lesions from subepithelial ones. For example, when evaluating a pigmented conjunctival lesion, the detection of thickened hyperreflective epithelium, with an abrupt transition from normal to

abnormal epithelium, points towards a diagnosis of pigmented OSSN as opposed to a conjunctival melanoma (CM).⁸ Conversely, the clinician can identify that a non-pigmented conjunctival lesion with a thin epithelium and a lesion noted under the epithelium is most likely not an OSSN and, if there's a hyperreflective subepithelial mass, that it may be an amelanotic melanoma.

Furthermore, HR-OCT images can detect or rule out the presence of tumors, particularly OSSN, in eyes with co-morbidities, such as limbal stem cell deficiency or a history of herpetic keratitis.⁹ HR-OCT can also help the clinician monitor treatment response, since it can detect subclinical disease. This helps avoid early termination of topical chemotherapy.² HR-OCT has also been used preoperatively to improve tumor visualization and provide a blueprint prior to surgical excision and direct biopsy localization.¹⁰ Fortunately, there's a short learning curve for interpreting images. Even novice users can correctly identify a variety of ocular surface lesions with moderate sensitivity and high specificity.¹¹

• **Disadvantages.** HR-OCT can be limited by shadowing in thick, keratinized or pigmented lesions. As such, the features and depth of these lesions are difficult to assess.¹² Furthermore, HR-OCT isn't able to examine tissue on a cellular level, and thus it can't identify cellular atypia or invasion into deeper structures. The former limits its ability to distinguish squamous metaplasia from OSSN, complexion-associated melanosis (CAM) from primary acquired melanosis (PAM) and conjunctival lymphoma from benign reactive lymphoid hyperplasia (BRLH). While sometimes in squamous cell carci-

This article has no commercial sponsorship.

Dr. John is a clinical associate professor at Loyola University at Chicago and is in private practice in Oak Brook, Tinley Park and Oak Lawn, Illinois. He has a small equity interest in, is consultant/advisor to, and has received lecture fees and grant support from Bio-Tissue and Tissue Tech. He can be reached at 708-429-2223; email: tjconference@gmail.com.

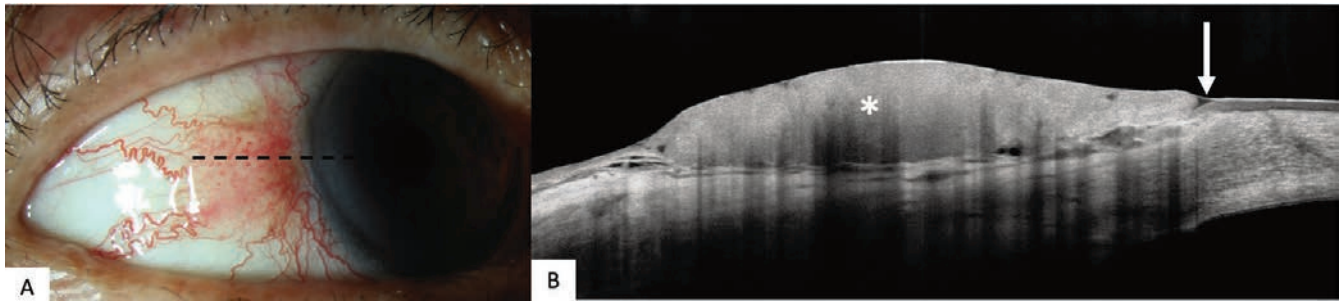


Figure 1. (A) Clinical slit lamp photo of ocular surface squamous neoplasia on the temporal conjunctiva of the right eye with papillomatous, gelatinous and opalescent features. (B) High-resolution anterior segment optical coherence tomography image of ocular surface squamous neoplasia demonstrating classic features of a hyperreflective and thickened epithelium (asterisk) and an abrupt transition between abnormal and normal epithelium (arrow).

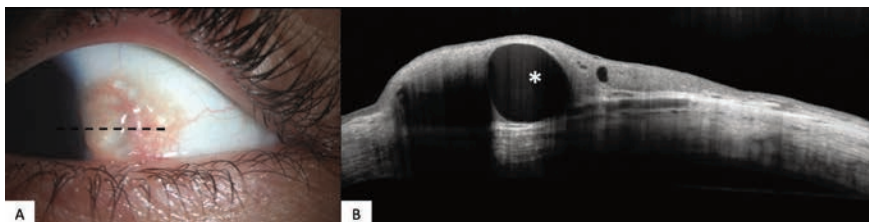


Figure 2. (A) Clinical slit lamp photo of a longstanding non-pigmented conjunctival nevus on the temporal aspect of the left eye. (B) High-resolution OCT image of a conjunctival nevus with characteristic features of an intralesional cyst (asterisk).

noma a connection to the underlying subepithelial mass is visualized, the ability to evaluate invasion isn't reliable.¹²⁻¹⁴ Ultimately, tissue is needed to examine structures on a cellular level and distinguish between these entities.^{2,15}

• **Imaging findings.** Numerous tumors that arise on the ocular surface have distinguishing features on HR-OCT. OSSN is characterized by a thickened and hyperreflective epithelium with an abrupt transition between normal and abnormal epithelium (*Figure 1*).¹⁶ Using a custom-built, ultra-high-resolution OCT machine, with 2-3 μm of resolution, we found that an epithelial thickness of greater than 142 μm distinguished OSSN from pterygia with 94-percent sensitivity and 100-percent specificity.^{17,18} Further studies by our group with a commercially available HR-OCT (RTVue, Optovue, Fremont, California) showed a sensitivity and specificity of 100 percent with an epithelial thickness cut-off of 120 μm for differentiating OSSN and pterygia.¹⁴ More recently, it was shown that another commer-

cially available device (Spectralis SD-OCT, Heidelberg Engineering, Heidelberg, Germany) can demonstrate a sensitivity and specificity of 100 percent for distinguishing OSSN from pterygia, with a cut-off of 141 μm .¹⁸

Melanocytic lesions also have several distinguishing features on HR-OCT. Intralesional cysts are a helpful feature that point towards a conjunctival nevus (*Figure 2*). In addition, basal epithelium hyperreflectivity is a feature shared by conjunctival CAM and PAM.^{14,19} A differentiating feature of nevi is the lack of cysts seen in CAM and PAM.¹²⁻¹⁴ CM on HR-OCT generally has a thin, uniform hyperreflective epithelium and, similar to PAM, lacks cysts. Unlike PAM, CM has a subepithelial hyperreflective mass and greater intensity of posterior shadowing (*Figure 2C*).^{14,20} Conjunctival lymphoma appears as a homolous, hyporeflective, subepithelial lesion surrounded by a hyperreflective band of tissue superior to the mass. BRLH appears similar to conjunctival lymphoma but has more of

a granular appearance, with small, hyperreflective stippled dots within the mass.^{14,21}

OCT Angiography

OCTA non-invasively collects numerous scans at a wide range of angles to create a three-dimensional image of the anatomy, vasculature and blood flow of the anterior segment.^{2,22-26} OCTA was originally designed to evaluate retinal pathology; it requires an adapter lens to image the anterior segment and the tumors that may arise in the iris, cornea, conjunctiva and sclera.^{26,27}

• **Advantages.** OCTA is a relatively recent technology with the first report of OCTA used in the anterior segment in 2015.²⁸ As a non-invasive tool for imaging vascular tissue, it has the benefit of no side effects or reactions secondary to injected dyes used in traditional angiography.^{29,30} OCTA is also able to detect certain features of OSSN that can't be detected clinically or with HR-OCT—most notably vascularization patterns within, adjacent to and under the tumor.³¹

• **Disadvantages.** A limitation of OCTA is that it produces images with artifacts, which can limit interpretation of the image. The most prevalent types of artifacts are associated with eye motion, projections and low OCT signal.²²⁻²⁴ The frequency and severity of artifacts, such as segmentation artifacts, may depend on the OCTA device used, while others such as eye motion may depend on patient factors (e.g., ex-

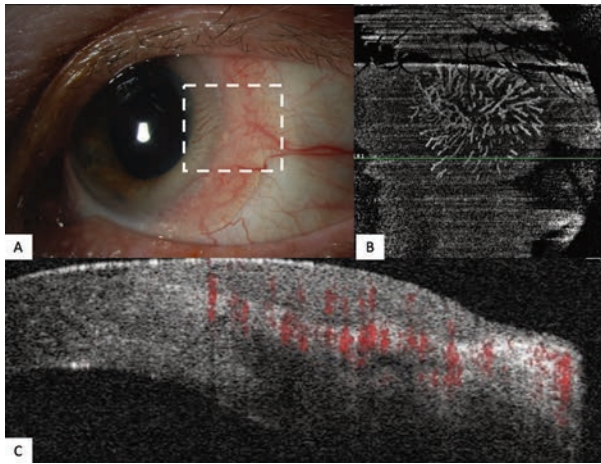


Figure 3. (A) Clinical slit lamp photo of an ocular surface squamous neoplasia on the temporal conjunctiva of the left eye with opalescent and gelatinous features. (B) OCTA image (dashed box) displaying a superficial segment of the OSSN demonstrating the vascular “sea fan” architecture of the tumor. (C) B-scan of the OSSN with zones highlighted in red demonstrating the vascular flow characteristics of the lesion. Note the thickened hyperreflective epithelium.

cessive eye movements in a patient with Parkinsonism).²⁴ Awareness of potential artifacts is key to interpreting OCTA images. Hopefully, future software and faster scanning will ameliorate some of these issues.

• **Imaging findings.** Compared to HR-OCT, the literature on ocular surface tumor findings with OCTA is limited. However, one case series comparing OCTA findings in two OSSN lesions vs. one pterygium lesion described a highly “zigzag vessel pattern” in OSSN, compared to a “straight vessel pattern” in the pterygium.³¹ One study used OCTA to determine tumor total density (percent of blood vessels within the entire tumor) and vessel area density (VAD, percent of blood vessels within 2.14 mm²) in the tumor, the surrounding tissue and the contralateral eye.³² It found that VAD was highest within the conjunctival tumors, followed by the subepithelial tissue adjacent to tumors and then by tissue 200 μm below the tumor. Another group examined features of melanocytic lesions on OCTA and reported more vessel tortuosity in CM compared to PAM and conjunctival nevi.³³ While these features haven’t been used to

diagnose a lesion, they do provide adjuvant findings that aren’t always apparent clinically. OCTA’s use on ocular surface tumors is still in its infancy, and it’s not yet clear how the detection of the vessels will help with diagnosis and monitoring.^{8,21,24,26} Nevertheless, it provides highly detailed images that aren’t clinically apparent, and it’s currently helping to elucidate the pathophysiology of tumorigenesis (Figure 3).

Ultrasound Biomicroscopy

UBM applies high-frequency ultrasound waves to biological tissue such as the anterior segment to obtain a cross-sectional image.^{1-3,34} Quantitative A-scan (lesions >2 mm) and standardized B-scan measurements related to anatomy and pathology of the conjunctiva, cornea, iridocorneal angle, iris, zonules, ciliary body and lens can be obtained using UBM.³⁴ Both 25 MHz and 50 MHz ultrasound waves can be used to examine the ocular surface. Higher frequencies (50 MHz) provide better resolution of the anatomy from the anterior chamber to the capsular area, and lower frequencies (25 MHz) provide lower resolution but wider and deeper fields of view of structures spanning the cornea to the retrocapsular area.^{1-3,34}

• **Advantages.** The primary benefit

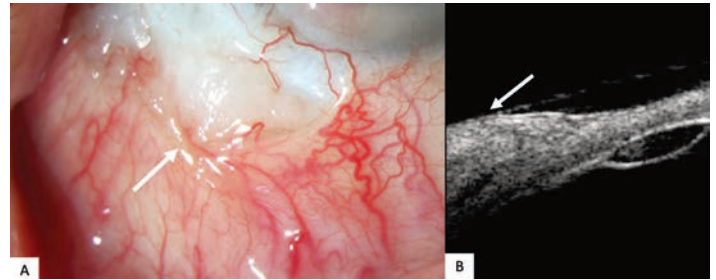


Figure 4. (A) Clinical slit lamp photo of a squamous cell carcinoma on the inferotemporal conjunctiva of the right eye (arrow). Patient is post prior surgical resection. (B) Ultrasound biomicroscopy 50 MHz B-scans demonstrating a dome-shaped, well-outlined lesion with an irregular internal appearance and mildly echoic features over the temporal sclera (arrow).

of UBM is its ability to penetrate opaque tumors and partially overcome posterior shadowing, which commonly affects HR-OCT. It also provides high-resolution imaging of dense and thick lesions.¹⁻³ UBM has been shown to be superior to HR-OCT, in terms of visualizing tumor margins. In a case series of 200 anterior segment tumors, UBM demonstrated mild superiority in identifying the anterior margin (90 vs. 82 percent) and significant superiority in identifying the posterior margin (90 vs. 29 percent) of the lesion.³⁵ Due to its ability to effectively probe large lesions, UBM is an excellent tool to assess for occult intraocular invasion and metastasis, which can present as blunting of the anterior chamber angle and uveal thickening.^{2,3} With respect to melanocytic tumors that are often thick and pigmented, UBM can often image the deep margin.^{1,2} In this regard, UBM has potential as a non-invasive tool for estimating tumor thickness prior to surgical intervention. A small case series demonstrated the relative agreement (difference of 0- to 0.5-mm thickness) compared to Breslow thickness.³⁶

• **Disadvantages.** While UBM can often delineate the margins and extent of large tumors, it doesn’t yield high-resolution views of the interior aspects of the lesion and often can’t visualize thin tumors well.¹ It’s also unable to differentiate among different tumors, as HR-OCT can (Figure 4). Furthermore, UBM, unlike

HR-OCT and OCTA, requires an eyebath in a reclined position and tissue contact, and the machine requires more technical familiarity.¹⁻³ Access to UBM is generally limited to large tertiary centers.

• **Imaging findings.** On UBM, the stromal component and the intra-ocular extension of the tumors (if present) have variable echogenicity.^{2,37} This is true for a variety of tumors and, as such, no specific, unique intral-lesional findings have been described that distinguish OSSN from CM.³⁵ In addition, there's a lack of literature describing the characteristics of conjunctival lymphoma on UBM. However, intraocular lymphomas have been described as hypoechoic in the anterior and posterior chambers of the eye.³⁸ Future studies are needed to best delineate the internal echoic features of conjunctival tumors on UBM.

In-Vivo Confocal Microscopy

In-vivo confocal microscopy is an imaging tool that allows for morphological and quantitative analysis of ocular surface tissue at a microscopic and cellular level, with up to 800x magnification and impressive resolution.³⁹ Current iterations of IVCM cite resolutions of 4 μm (axial) and 2 μm (lateral).⁴⁰ Since the 1990s, IVCM has emerged as a useful diagnostic tool in the repertoire of corneal specialists.⁴¹

• **Advantages.** IVCM has also been used to examine cellular features of OSSN. Features include anterior and middle layers of epithelium containing hyperreflective pleomorphic squamous cells, superficial stroma laden with nuclear mitotic figures, and a clear transition between normal and neoplastic epithelium and pleomorphic cells.⁴² Furthermore, IVCM has been used to evaluate cellular response to topical chemotherapy in OSSN, with detection of reduced epithelial cell reflectivity, a less-defined transition between normal and abnormal tissue and fragmentation of abnormal cell clusters (Figure 5).⁴² IVCM has also been shown to differentiate

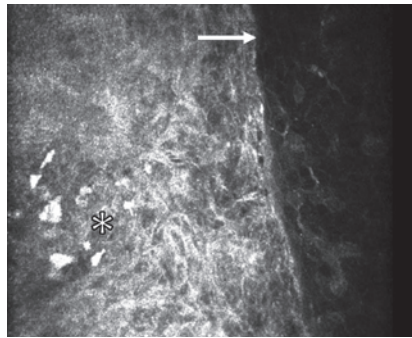


Figure 5. (A) *In vivo* confocal microscopy image of ocular surface squamous neoplasia. Note the sharply demarcated hyperreflective lesion with visible hyperreflective cell nuclei (asterisk). The junction between normal and abnormal tissue is abrupt (arrow).

between PAM with and without atypia. Differentiating features include a large network of dendritic cells and hyperreflective granules throughout all layers of the epithelium in PAM with atypia, and smaller dendritic cells and hyperreflective granules limited to the basal epithelium in PAM without atypia.^{43,44} IVCM hasn't been shown to differentiate lymphomatous lesions from inflammatory lesions, with similar findings of highly reflective small round cells diffusely arranged in epithelium and subepithelium in both.^{1,43}

• **Disadvantages.** IVCM has several factors which limit its use in the assessment of ocular surface lesions. One limitation is its small field of view, which represents only a small portion of the lesion in one plane at each point. Furthermore, the currently available software hasn't been able to define landmarks that can aid the clinician in determining what part of the lesion is being imaged. In addition, studies have shown that both malignant and benign lesions may have cellular changes; because of this, IVCM can't be used in isolation to diagnose a particular lesion.^{2,43} Cellular-level detail is also obscured in lesions with a hyperkeratinized component.^{45,46} Like UBM, contact with tissue is required, as is technical expertise in order to capture the images and interpret them.

• **Imaging findings.** A number of studies have attempted to characterize tumors of the ocular surface using IVCM. Several OSSN features have been described on IVCM. One study described dysplastic cells, with nuclear mitotic figures and nests of vortex cells in the superficial layers of the stroma.⁴⁷ Another study reported hyperreflective pleomorphic cells and an absence of sub-basal corneal nerves in OSSN-involved epithelium. Finally, a third study described OSSN as having a "starry sky" appearance with enlarged, irregular and hyperchromatic nuclei with bright dots in the basal cell.⁴² However, benign lesions such as pterygia, pinguecula and papilloma were also found to contain similar cellular irregularities, with one case series of 60 patients demonstrating a sensitivity and specificity of 38.5 percent and 66.7 percent, respectively, when comparing OSSN to benign conjunctival lesions.⁴⁸

The appearance of pigmented lesions has also been described on IVCM. Conjunctival nevi exhibited collections of uniform, medium-sized stromal cells along, with pseudocyst-like structures. PAM with atypia features large dendritic cells and hyperreflective cells throughout the epithelium, whereas PAM without atypia has smaller dendritic cells and hyperreflective cells limited to the basal epithelium. CM has large cells with prominent nuclei and nucleoli, with invasion signified by hyperreflectivity in the subepithelial layers.⁴⁴ Conjunctival lymphoma features on IVCM include a normal epithelium and copious, small, tightly-packed hyperreflective cells in a cyst-like space, correlating with lymphocytes in the stromal tissue.^{43,49}

In conclusion, the arsenal of diagnostic imaging modalities at the ocular-surface oncologist's disposal are numerous and versatile in their strengths and weaknesses. All four have been used, in various situations, as adjuncts to the diagnosis, management and follow-up of patients with

ocular surface tumors, and all can aid clinicians in examining lesions to a far greater extent than is possible with the slit lamp alone. ◀

Correspondence: ckarpp@med.miami.edu; Bascom Palmer Eye Institute, University of Miami, Miller School of Medicine, 900 NW 17th Street, Miami, FL 33136, USA

- Nanji AA, et al. Updates in ocular surface tumor diagnostics. *Int Ophthalmol Clin* 2017; 57:3:47-62.
- Venkateswaran N, Sripawadkul W, Karp CL, The role of imaging technologies for ocular surface tumors. *Curr Opin Ophthalmol* 2021; 32:4: 369-378.
- Ong SS, Vora GK, Gupta PK. Anterior segment imaging in ocular surface squamous neoplasia. *J Ophthalmol* 2016; 2016:5435092 [Epub].
- Izatt JA, et al. Micrometer-scale resolution imaging of the anterior eye in vivo with optical coherence tomography. *Arch Ophthalmol* 1994;112:12:1584-9.
- Ang M, et al. Anterior segment optical coherence tomography. *Prog Retin Eye Res* 2021;66:132-156.
- Venkateswaran N, et al. High resolution anterior segment optical coherence tomography of ocular surface lesions: A review and handbook. *Expert Review of Ophthalmology* 2021;16:2:81-95.
- Huang D, et al. Optical coherence tomography. *Science* 1991;254:5035:1178-81.
- Thomas BJ, et al. Ultra high-resolution anterior segment optical coherence tomography in the diagnosis and management of ocular surface squamous neoplasia. *Ocul Surf* 2014;12:1:46-58.
- Atallah M, et al. Role of high resolution optical coherence tomography in diagnosing ocular surface squamous neoplasia with coexisting ocular surface diseases. *The Ocul Surf* 2017;15:4:688-695.
- Karp CL, et al. Use of high-resolution optical coherence tomography in the surgical management of ocular surface squamous neoplasia: A pilot study. *Am J Ophthalmol* 2019;206:17-31.
- Yim M, et al. Ability of novice clinicians to interpret high-resolution optical coherence tomography for ocular surface lesions. *Can J Ophthalmol* 2018;53:2:150-154.
- Shousha MA, et al. Diagnosis of ocular surface lesions using ultra-high-resolution optical coherence tomography. *Ophthalmology* 2013;120:5:883-91.
- Alzahrani YA, et al. Primary acquired melanosis: Clinical, histopathologic and optical coherence tomographic correlation. *Ocul Oncol Pathol* 2016;2:3:123-7.
- Nanji AA, et al. High-resolution optical coherence tomography as an adjunctive tool in the diagnosis of corneal and conjunctival pathology. *Ocul Surf* 2015;13:3:226-35.
- Tanenbaum RE, et al. Classification, diagnosis, and management of conjunctival lymphoma. *Eye and Vision* 2019;6:1:22.
- Venkateswaran N, et al. Optical coherence tomography for ocular surface and corneal diseases: A review. *Eye Vis (Lond)* 2018;5:13.
- Kieval JZ, et al. Ultra-high resolution optical coherence tomography for differentiation of ocular surface squamous neoplasia and pterygia. *Ophthalmology* 2012;119:3:481-6.
- Lozano García I, et al. High resolution anterior segment optical coherence tomography for differential diagnosis between corneo-conjunctival intraepithelial neoplasia and pterygium. *Arch Soc Esp Oftalmol (Engl Ed)* 2020;95:3:108-113.
- Shields CL, et al. Anterior segment optical coherence tomography of conjunctival nevus. *Ophthalmology* 2011;118:5:915-9.
- Koç I, Kıratlı H. Current management of conjunctival melanoma part 1: Clinical features, diagnosis and histopathology. *Turk J Ophthalmol* 2020;50:5:293-303.
- Venkateswaran N, et al. The use of high resolution anterior segment optical coherence tomography for the characterization of conjunctival lymphoma, conjunctival amyloidosis and benign reactive lymphoid hyperplasia. *Eye Vis (Lond)*;2019:6:17.
- de Carlo TE, et al. A review of optical coherence tomography angiography (OCTA). *Int J Retina Vitreous* 2015.1:5.
- Pichi F, Roberts, Neri. The broad spectrum of application of optical coherence tomography angiography to the anterior segment of the eye in inflammatory conditions: A review of the literature. *J Ophthalmic Inflamm Infect* 2019;91:18.
- Anvari P, et al. Artifacts in optical coherence tomography angiography. *J Ophthalmic Vis Res* 2021;162:271-286.
- Siddiqui Y, Yin J. Anterior segment applications of optical coherence tomography angiography. *Semin Ophthalmol* 2019;34:4:264-269.
- Lee WD, et al. Optical coherence tomography angiography for the anterior segment. *Eye Vis (Lond)* 2019;6:4.
- Tan ACS, et al. An overview of the clinical applications of optical coherence tomography angiography. *Eye (Lond)* 2018;32:2:262-286.
- Ang M, et al. Optical coherence tomography angiography for anterior segment vasculature imaging. *Ophthalmology* 2015;122:9:1740-7.
- López-Sáez MP, et al. Fluorescein-induced allergic reaction. *Ann Allergy Asthma Immunol* 1998;81:5:428-30.
- Hope-Ross M, et al. Adverse reactions due to indocyanine green. *Ophthalmology* 1994;101:3:529-33.
- Nampe K, et al. Comparison of ocular surface squamous neoplasia and pterygium using anterior segment optical coherence tomography angiography. *Am J Ophthalmol Case Rep* 2020; 20:100902.
- Liu Z, et al. Role of optical coherence tomography angiography in the characterization of vascular network patterns of ocular surface squamous neoplasia. *Ocul Surf* 2020;18:4:926-935.
- Brouwer NJ, et al. Anterior segment octa of melanocytic lesions of the conjunctiva and iris. *Am J Ophthalmol* 2021;222:137-147.
- Martin R. Cornea and anterior eye assessment with slit lamp biomicroscopy, specular microscopy, confocal microscopy, and ultrasound biomicroscopy. *Indian J Ophthalmol* 2018;66:2:195-201.
- Bianciotto C, et al. Assessment of anterior segment tumors with ultrasound biomicroscopy versus anterior segment optical coherence tomography in 200 cases. *Ophthalmol* 2011;1187:1297-302.
- Ho VH, et al. Ultrasound biomicroscopy for estimation of tumor thickness for conjunctival melanoma. *J Clin Ultrasound* 2007;35:9:533-537.
- Finger PT, et al. High-frequency ultrasono-
- graphic evaluation of conjunctival intraepithelial neoplasia and squamous cell carcinoma. *Arch of Ophthalmol* 2003;121:2:168-172.
- Pavlin CJ, Harasiewicz K, Foster FS. Ultrasound biomicroscopy of anterior segment structures in normal and glaucomatous eyes. *Am J Ophthalmol* 1992;113:4:381-389.
- Cruzat A, Qazi Y, Hamrah. In vivo confocal microscopy of corneal nerves in health and disease. *Ocul Surf* 2017;15:1:15-47.
- Bille JF, ed. High Resolution Imaging in Microscopy and Ophthalmology: New Frontiers in Biomedical Optics. Cham: Springer, 2019.
- Cavanagh HD, et al. Confocal microscopy of the living eye. *CLAO J* 1990;16:1:65-73.
- Zarei-Ghanavati M, et al. Changes in in vivo confocal microscopic findings of ocular surface squamous neoplasia during treatment with topical interferon alfa-2b. *Ocul Surf* 2018;16:2:235-241.
- Cinotti E, et al. Handheld reflectance confocal microscopy for the diagnosis of conjunctival tumors. *Am J Ophthalmol* 2015;159:2:324-33.e1.
- Messmer EM, et al. In vivo confocal microscopy of pigmented conjunctival tumors. *Graefes Arch Clin Exp Ophthalmol* 2006;244:11:1437-45.
- Parozzani R, et al. In vivo confocal microscopy of ocular surface squamous neoplasia. *Eye (Lond)* 2011;25:4:455-60.
- Xu Y, et al. The clinical value of in vivo confocal microscopy for diagnosis of ocular surface squamous neoplasia. *Eye (Lond)* 2012;26:6:781-7.
- Liang QF, et al. Histopathology manifestation and imaging characteristics of in vivo confocal microscopy for diagnosis of ocular surface squamous neoplasia. *Zhonghua Yan Ke Za Zhi* 2018;54:9:652-660.
- Nguena MB, et al. Diagnosing ocular surface squamous neoplasia in East Africa: Case-control study of clinical and in vivo confocal microscopy assessment. *Ophthalmology* 2014;121:2:484-91.
- Pichierrri P, et al. In vivo confocal microscopy in a patient with conjunctival lymphoma. *Clin Exp Ophthalmol* 2008;36:1:67-9.

DISCLOSURES



Dr. Zein is a cornea research fellow at Bascom Palmer and with the McKnight Vision Research Center. He holds a Master's of Vision Science and Investigative Ophthalmology.



Mr. Djulbegovic is an MD candidate at the University of Miami Miller School of Medicine. He holds a MSc in Bioinformatics and Computational Biology.



Dr. Galor is a professor of ophthalmology at Bascom Palmer and a staff physician at the Miami VAMC.



Dr. Teira is a senior ophthalmic echographer in the Ocular Oncology Service at Bascom Palmer and a retina specialist.



Dr. Karp is a professor of ophthalmology, the Richard K. Forster Chair in Ophthalmology and the Dr. Ronald & Alicia Lepke Endowed Professorship in Cornea and Ocular Surface Diseases at Bascom Palmer Eye Institute, at the University of Miami Miller School of Medicine.



The authors declare that they have no conflict of interest.

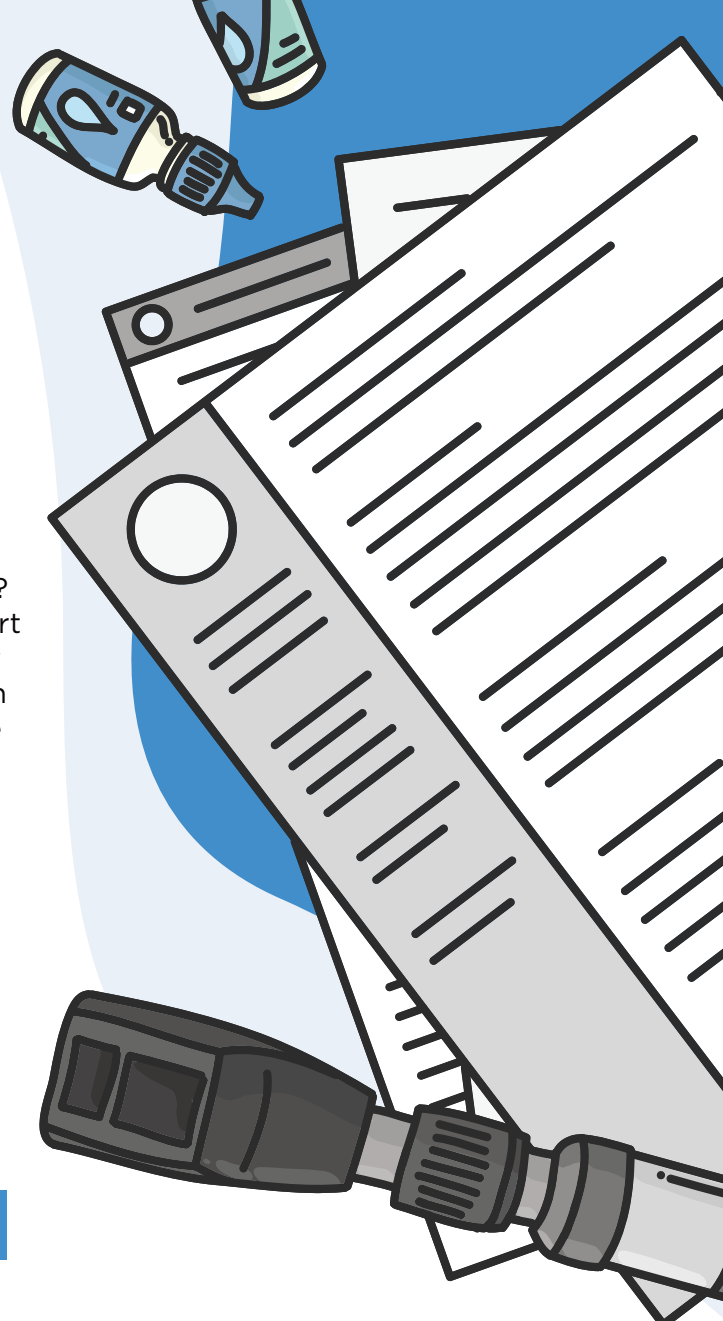

Recruiting Services for Practices that Need to Hire Fast

Is your team struggling to post, source, and screen? Let Eyes On Eyecare do the heavy lifting! Our expert recruiters have helped practices across the country fill open positions quickly and cost-effectively. With a proprietary network of 60,000 ECPs, we'll ensure that your role will reach the right candidates.

FAIR, TRANSPARENT PRICING

- ✓ Flat-rate pricing
- ✓ Guaranteed employee retention
- ✓ No exclusivity clause
- ✓ No upfront fees; you only pay if you hire



Working in the eyecare industry is a rewarding experience. ODs want to find a practice they can call home for the long term and appreciate our efforts to find them a great fit.



- Priti Gohil
TalentAcquisition Specialist,
Eyes On Eyecare



- Christine Carder
TalentAcquisition Specialist,
Eyes On Eyecare

It's exciting to see optometrists find great jobs and clients make a great hire. I love knowing I've helped both sides find an ideal match.

Learn more at eyesoneyecare.com/recruiting

PROUD PARTNER OF JOBS ON OPTICAL GROUP





EDITED BY CARL REGILLO, MD,
AND YOSHIHIRO YONEKAWA, MD

RETINAL INSIDER

Managing Posterior Segment Injuries

Expert tips on how to evaluate and manage open globe injuries to the retina and associated structures.

ELYSE TOM, MD

ST. LOUIS

YEWLIN E. CHEE, MD

SEATTLE

Open globe injuries are a significant cause of vision loss worldwide, and the wide variety of presentations and severities can make them a challenge to manage. These injuries may be categorized as rupture, penetrating, perforating or an intraocular foreign body injury, and can lead to complications such as retinal detachment and traumatic endophthalmitis.¹

While posterior segment open globe injuries have been associated with poorer outcomes, with appropriate management at each stage of repair it's possible to improve vision for many patients with these injuries.² In this article, we'll delve into the steps for evaluating and treating posterior segment trauma.

Initial Evaluation

When a patient presents with an open globe injury, a detailed history may offer important clues about the nature and extent of the ocular damage. The mechanism of injury, including whether a blunt or sharp object caused the trauma, will help determine whether the injury resulted in a rupture or laceration. It's

essential to assess for the possibility of an intraocular foreign body; injuries from fireworks, explosives, nail guns, hammering metal and firearms are associated with an increased risk of IOFB injury. The velocity and size of the object and the material of the IOFB may help with preoperative planning. If the patient needed to pull the object out of the eye, there's an increased risk of a posterior strike site and posterior segment trauma, even if the entry wound is only present anteriorly.

Once you've obtained a detailed history, conduct a thorough examination. Check visual acuity carefully, and note the presence or absence of an afferent pupillary defect. VA has been found to be the most important determinant of final visual outcome in penetrating eye injuries.³ Checking intraocular pressure is usually avoided to prevent expulsion of intraocular contents. On exam, 360-degree bullous subconjunctival hemorrhage and no posterior view warrants exploration, due to concern for an occult rupture.

Anterior segment findings of potential posterior segment IOFB include focal cataract or iris transillumination defect associated with a full-thickness corneal wound. Attempt to perform a dilated fundus

exam, without scleral depression, to assess for posterior pathology and IOFB. Avoid putting pressure on the globe, since this could lead to further prolapse of intraocular contents. Assessment for endophthalmitis is also essential for preoperative planning; significant anterior chamber and/or vitreous inflammation is concerning and warrants intravitreal injection of antibiotics.

A computed tomography scan of the orbits with thin cuts is the imaging modality of choice to assess for an IOFB (*Figure 1*) and can sometimes support the diagnosis of an open globe injury, although a normal CT does not rule out the possibility of a full-thickness wound. An occult rupture on CT often appears as flattening of the posterior scleral contour.⁴ Other signs of open globe on CT include intraocular air or frank globe deformity. Magnetic resonance imaging may be more sensitive in detecting wood or plastic IOFB, but is generally avoided due to the risk of metallic IOFB causing further damage.⁵ It's also preferable to avoid B-scan ultrasound, to minimize pressure on the globe. The clinician should then place a fox shield over the eye, start broad-spectrum systemic antibiotics, determine tetanus vaccination status and place the patient on bedrest to minimize pressure on the globe.

Primary Closure of an Open Globe

An open globe should be repaired within 24 hours of the injury to decrease the risk of traumatic endophthalmitis. Ideally, if there's an IOFB you should remove it at the time of the primary surgery. The

This article has no commercial sponsorship.

Dr. Regillo is the director of the Retina Service of Wills Eye Hospital, a professor of ophthalmology at Thomas Jefferson University School of Medicine and the principle investigator for numerous major international clinical trials.

Dr. Yonekawa is an assistant professor of ophthalmology at Sidney Kimmel Medical College at Thomas Jefferson University. He serves on the Education Committee of the American Society of Retina Specialists and on the Executive Committee for the Vit Buckle Society, where he is also the vice president for academic programming.

goal of the initial surgery is to have watertight closure of all wounds in a manner that will allow you to complete a secondary vitrectomy, if necessary. It's preferable, if necessary, to use general anesthesia rather than periocular anesthesia, to minimize pressure on the globe. During induction, succinylcholine can cause contraction of extraocular muscles, and therefore should be avoided.

When repairing a corneal laceration, close it with sutures that are at least 90 percent deep in order to minimize posterior wound gape and postoperative corneal edema. Corneal glue may not provide strong enough closure and may hinder your view of the posterior segment. Perform a conjunctival peritomy to identify all scleral wounds. Unless prolapsed tissue is obviously contaminated or necrotic, reposition it with an instrument, such as an iris or cyclodialysis spatula, rather than excising it. Cut prolapsed vitreous flush against the globe to limit vitreoretinal traction and prevent incarceration. Closure of wounds from anterior to posterior will minimize the prolapse of intraocular contents. Don't engage the underlying retinal or uveal tissue with scleral passes, in order to limit incarceration. If you can't visualize the posterior-most edge of a zone-3 wound, you can leave it to close by secondary intention rather than disinserting extraocular muscles, as it can be difficult to isolate muscles for scleral buckle placement during the secondary surgery after they're reinserted. The operative note must be detailed, including the location and length of the wound and whether a complete closure was achieved, so the secondary vitrectomy can be planned appropriately.

Management of an Intraocular Foreign Body

Ideally, you should remove IOFBs

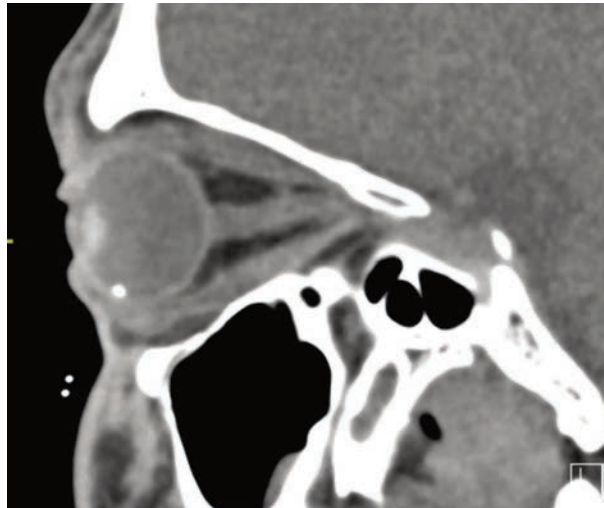


Figure 1. CT scan of orbit with an intraocular foreign body.

from the eye within 24 hours of the injury, at the time of primary closure.

First, close the entry wound to ensure that the eye will maintain adequate intraocular pressure during the IOFB removal. Then, perform a 23- or 25-gauge vitrectomy with elevation of the posterior hyaloid in order to decrease traction on the retina during IOFB removal. Prior to the object's removal, you can use endolaser to surround the IOFB, since the visualization necessary to perform the laser might be limited by any intraocular hemorrhage that occurs because of manipulation of the IOFB.

For a magnetic IOFB extraction, you can use external magnets, intraocular forceps, soft-tip cannulas, the vitreous cutter and intraocular magnets.⁶ When there's good visualization of the retina and the intravitreal foreign body, an external magnet held over a pars plana sclerotomy may be effective. However, the results are often best when the IOFB is removed with vitrectomy and an intraocular magnet,⁷ especially when visualization of the retina and IOFB is poor. It may be helpful to bring the IOFB anteriorly with an intraocular magnet and then transfer to a foreign body forcep that you can pull through a limbal or sclerotomy wound.⁸ If the IOFB has a lower

specific gravity than perfluorocarbon liquid, PFO can also be used to lift the IOFB off of the retina for easier atraumatic grasping and may also protect the macula in case the IOFB is dropped.⁹ Make sure that the wound through which the IOFB will be removed is large enough to allow its passage. You can also inject intravitreal antibiotics—usually vancomycin and ceftazidime—at the time of IOFB removal for endophthalmitis prophylaxis.¹⁰

Postoperative Care After Primary Closure

If the patient's vision is no light perception, the clinician should recheck it carefully with the brightest setting on the indirect ophthalmoscope to confirm this finding, as these eyes generally are poor candidates for subsequent intervention. Initiate a cycloplegic agent and frequent topical steroids to control postoperative inflammation. At each postop visit, especially when there is a limited view, perform a B-scan ultrasound to assess for vitreous or retinal traction, retinal detachment and/or hemorrhagic choroidal detachments. When there's significant vitreous hemorrhage, proliferative vitreoretinopathy and tractional retinal detachments commonly develop later in the course of recovery, so you should pursue prophylactic vitrectomy in these cases even in the absence of retinal detachment on B-scan. Refer these patients to a retina specialist within the first week so that they can be evaluated in a timely fashion.

Secondary Vitrectomy: Indications and Timing

Many open globe injury eyes require secondary vitrectomy due to posterior segment complications. Indications for a secondary vitrectomy include persistent media opacity, progressive vitreoretinal traction, retinal detachment and

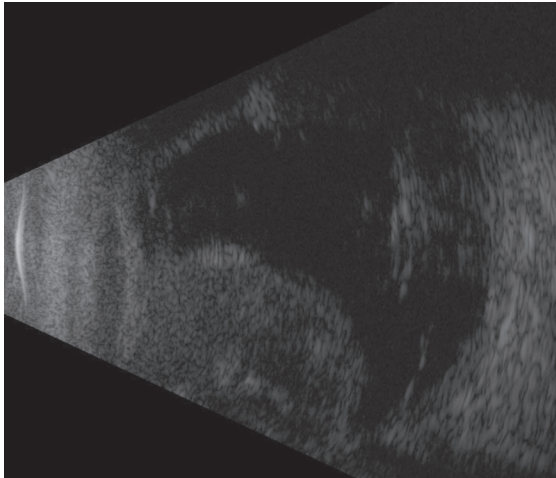


Figure 2a: Solid hemorrhagic choroidal detachments one day after open globe injury.

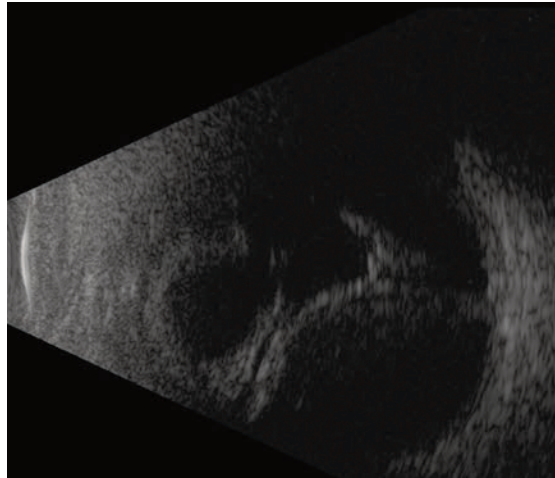


Figure 2b: Liquefied hemorrhage choroidal detachments 10 days after open globe injury.

endophthalmitis. Visual acuity usually needs to be light perception or better to warrant additional surgery. The only exception is if the eye has massive hemorrhagic choroidal detachments, since this is the one situation where the vision can actually improve from NLP.¹¹

Favorable outcomes have been associated with recovery of light perception after initial closure and secondary vitrectomy in one to two weeks.¹² Surgery within seven to 14 days allows adequate time for healing of the primary wounds, and also decreases the chance of encountering significant membrane proliferation during the secondary surgery. If there are hemorrhagic choroidal detachments, it's best to wait until they're liquefied on B-scan before proceeding with secondary surgery, so that they can be thoroughly drained (*Figures 2a and 2b*).

Secondary Vitrectomy Procedure

The main goals of the secondary vitrectomy are to clear the ocular media by either removing vitreous hemorrhage and/or cataract; to remove the scaffold from the scleral laceration site; to remove the posterior hyaloid; and to identify and treat retinal tears or detachment.⁶

The first step involves placing the infusion cannula. If there's vitreous

hemorrhage that prevents a view of the pars plana cannulas, initiate the infusion with an anterior chamber maintainer. To avoid subretinal or suprachoroidal placement, consider using a 6-mm long infusion cannula at the pars plana, rather than the traditional 4-mm cannula, particularly if there's a known history of choroidal hemorrhage. In the presence of choroidal hemorrhages, a preoperative B-scan ultrasound should be used to assess for liquification of the choroidal hemorrhages and the location of the preferential drainage site, which should be the quadrant where the choroidal hemorrhage is the highest. You can drain the blood through a scleral incision while concurrently infusing balanced salt solution or air. A long radial sclerotomy is the preferred method, as it allows for drainage of residual clots as well.

Unless there are large choroidal hemorrhages, adjuvant placement of a scleral buckle is usually indicated. Traumatic retinal detachment is often associated with multiple retinal breaks and has a higher risk for PVR. An encircling band will support the vitreous base and can decrease the risk of future retinal detachment. In the case of a known preoperative total funnel retinal detachment where there's a higher likelihood of needing a 360-degree

retinectomy, the surgeon can hook and isolate the extraocular muscles and then perform the vitrectomy. If a 360-degree retinectomy is ultimately needed, then the buckle can be deferred. However, if there's peripheral retina that will benefit from support, then

the buckle can be placed easily, since the conjunctival peritomy and muscle isolation have already been completed.

In addition, if the lens is opacified or has been dislocated, it'll need to be removed for adequate posterior segment visualization. To decrease the likelihood of anterior loop PVR, perform a lensectomy with total removal of the capsule. You can remove the lens with the vitrectomy probe or a fragmentation device through the pars plana.⁶

Once you've cleared the view to the posterior segment, you can then initiate the core vitrectomy, starting anteriorly and moving posteriorly. The main initial goal of the core vitrectomy is to find a plane between the retina and the hyaloid that can then be extended. A preoperative B-scan ultrasound may be helpful in identifying an area in the periphery where the retina appears attached and the hyaloid appears elevated.

If a natural space between retina and hyaloid isn't apparent on B-scan, consider gradually using the cutter to remove more superficial vitreous hemorrhage, then burrowing down layer by layer towards the retina in a limited area where, if an inadvertent retinal break were created, it would be supported by the buckle and/or tamponade agent. Assess the peripheral retina for any



3RD YEAR RESIDENT

PROGRAMS & WET LAB

Dear CSE 3rd-Year Resident Program Director and Coordinator,

We would like to invite you to review the upcoming 3rd-Year Ophthalmology Resident Programs and Wet Labs for 2021. The programs offer a unique educational opportunity for third-year residents by providing the chance to meet and exchange ideas with some of the most respected thought leaders in ophthalmology. The programs are designed to provide your residents with a state-of-the-art didactic and wet lab experience. The programs also serve as an opportunity for your residents to network with residents from other programs.

After reviewing the material, it is our hope that you will select and encourage your residents to attend one of these educational activities, which are CME accredited to ensure fair balance. Residents will select one of three dates for the live, **virtual** didactic program and one of three dates for the in-person, hands-on wet lab in Fort Worth.

Best regards,

Yousuf Khalifa, MD, Mitchell P. Weikert, MD, MS and Kendall Donaldson, MD

THIRD-YEAR RESIDENT LIVE, VIRTUAL DIDACTIC PROGRAMS

JULY 31, 2021

(SATURDAY)
MEETING HAS EXECUTED

Course Director
Yousuf Khalifa, MD

AUGUST 7, 2021

(SUNDAY)
MEETING HAS EXECUTED

Course Director
Mitchell Weikert, MD, MS

AUGUST 14, 2021

(SUNDAY)
MEETING HAS EXECUTED

Course Director
Kendall Donaldson, MD

THIRD-YEAR RESIDENT WET LABS

**AUGUST 28 OR
AUGUST 29**

**SEPTEMBER 25 OR
SEPTEMBER 26**

**OCTOBER 2 OR
OCTOBER 3**
MEETING IS FULL

Register Now: www.ReviewEdu.com/CSE3rdYr2021

Courses are restricted to US-based 3rd-year residents enrolled in a US-based ophthalmology resident program and within their third year at the time of the course. There is no registration fee for these activities. Air, ground transportation in Fort Worth, hotel accommodations and modest meals will be provided through an educational scholarship for qualified participants.

Satisfactory Completion – Learners must complete an evaluation form to receive a certificate of completion. Your chosen sessions must be attended in their entirety. Partial credit of individual sessions is not available. If you are seeking continuing education credit for a specialty not listed below, it is your responsibility to contact your licensing/certification board to determine course eligibility for your licensing/certification requirement.



JOINTLY ACCREDITED PROVIDER
INTERPROFESSIONAL CONTINUING EDUCATION

Physicians – In support of improving patient care, this activity has been planned and implemented by Amedco LLC and Postgraduate Healthcare Education. Amedco LLC is jointly accredited by the Accreditation Council for Continuing Medical Education (ACCME), the Accreditation Council for Pharmacy Education (ACPE), and the American Nurses Credentialing Center (ANCC), to provide continuing education for the healthcare team

Credit Designation Statement – This activity has been approved for **AMA PRA Category 1 Credits™**.

For more information visit the registration site above or
call Denette Holmes at 866-627-0714 or email dholmes@postgradhealthed.com

Supported by an independent
medical education grant from **Alcon**

Jointly provided by



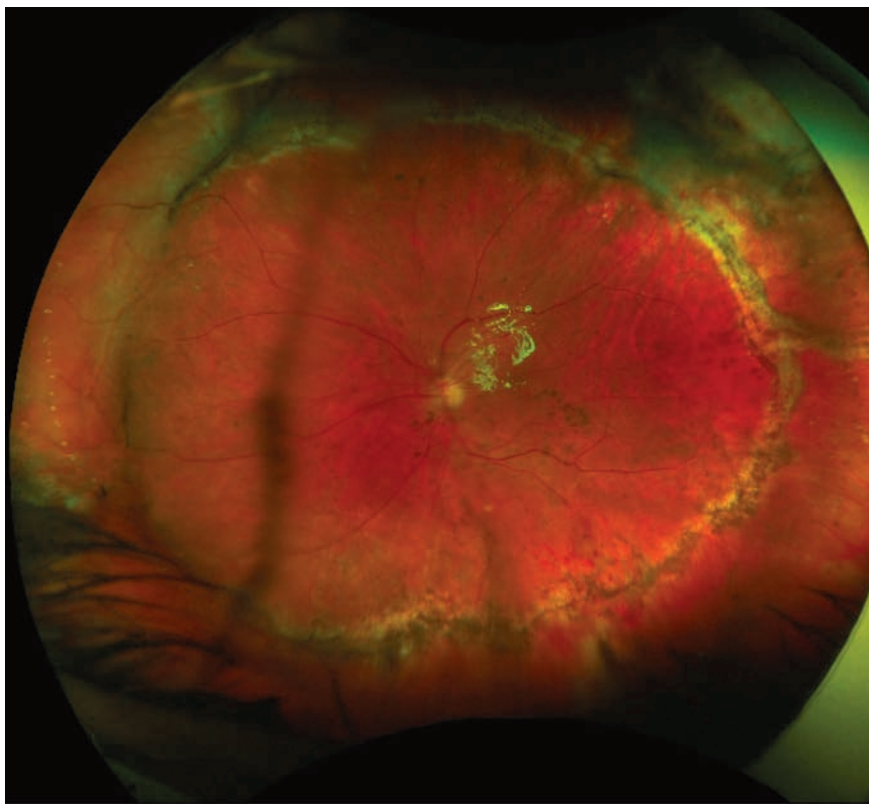

Figure 3. Widefield fundus photo after an open globe injury and secondary vitrectomy to repair traumatic retinal detachment. The scleral buckle contour can be seen supporting the nasal retina, and the 270-degree retinectomy edge can be seen superiorly, temporally and inferiorly.

retinal tears or detachments and treat with endophotocoagulation. It's important to remove all preretinal membranes and assess for areas of retinal incarceration, the location of which can be predicted based on the laceration site noted in the primary repair. Once you've identified any retinal incarceration, perform a retinectomy to release it.

When proliferative vitreoretinopathy causes retinal foreshortening, a large retinectomy may be required to reattach the retina (*Figure 3*). The retina can be flattened with perfluorocarbon liquid or fluid-air exchange with subsequent laser to the retinectomy edge.¹³

When deciding between gas versus silicone oil tamponade, consider using silicone oil, particularly with larger retinectomies and in eyes with anterior membrane proliferation. If the patient is aphakic with oil fill, you must perform an inferior

peripheral iridotomy.

If the eye is aphakic and aniridic with oil fill, place silicone oil retention sutures across the plane of the iris to keep oil away from the cornea. Lastly, instruct the patient to position face down postoperatively.

Patient Counseling

Open globe injuries are a traumatic experience for everyone involved—patients, caretakers and surgeons. Patient counseling is a crucial component of the management of eye trauma and is essential in preparing the patient for the long journey to recovery and rehabilitation.

Patients naturally wish to know what their vision will be like after surgery, but it's difficult to predict this with any certainty. When counseling patients, then, it's important to strike a balance: Avoid being overly pessimistic, since some eyes can regain meaningful vision, but

set realistic expectations. Most eyes with poor vision prior to secondary vitrectomy have limited vision postoperatively as well. However, there is a chance for improvement, and the best results will only be achieved if you enter each case mentally prepared to repair the eye to the best of your ability and to be meticulous about the repair at each step of the process. ◀

1. Kuhn F, et al. The Birmingham Eye Trauma Terminology System (BETT). *Journal Français d'Ophthalmologie* 2004;27:2:206–10.
2. Rahman I, et al. Open Globe Injuries: Factors predictive of poor outcome. *Eye* 2006;20:12:1336–41.
3. Sternberg P Jr, et al. Multivariate analysis of prognostic factors in penetrating ocular injuries. *American Journal of Ophthalmology* 1984;98:4: 467–72.
4. Sevel D, et al. Value of computed tomography for the diagnosis of a ruptured eye. *Journal of Computer Assisted Tomography* 1983;7:5:870–75.
5. Modjtahedi B, et al. Imaging characteristics of intraocular foreign bodies. *Retina* 2015;35:1:95–104.
6. Schachat AP, Recchia FM, Sternberg P. Chapter 114: Surgery for Ocular Trauma Principles and Techniques of Treatment. In: *Ryan's Retina E-Book*. Elsevier Health Sciences, 2018. 2081-2106.
7. Mester V, Kuhn F. Ferrous intraocular foreign bodies retained in the posterior segment: Management options and results. *International Ophthalmology* 1998;22:6:355–62.
8. Sborgia G, et al. 25-gauge vitrectomy in open eye injury with retained foreign body. *Journal of Ophthalmology* Jan. 2017;3161680.
9. Guevara-Villarreal DA, Rodríguez-Valdés PJ. Posterior segment intraocular foreign body: Extraction surgical techniques, timing, and indications for vitrectomy. *Journal of Ophthalmology*;Nov 2016.Article ID: 2034509.
10. Ahmed Y, et al. Endophthalmitis following open-globe injuries. *Eye* 2012;26:2:212–17.
11. Chee YE, Kanoff JM, Elliott D. Remarkable visual recovery after severe open globe injury. *AJO Case Reports* 2016;3:34.
12. Feng K, et al. Case-control study of risk factors for no light perception after open-globe injury. *Retina* 2011;31:10:1988–96.
13. Shalaby, Khaled Abdel-Galil. Relaxing retinotomies in the management of retinal detachment with severe proliferative vitreoretinopathy (PVR). *Clinical Ophthalmology* 2010 Oct 5;4:1107-14.

ABOUT THE AUTHORS



Dr. Chee is an assistant professor of ophthalmology at the University of Washington in Seattle.



Dr. Tom is a vitreoretinal surgery fellow at the Retina Institute in St. Louis.



EDITED BY RAKHI MELVANI, MD

WILLS EYE RESIDENT CASE REPORT

A case of chronic scleritis brings a patient to Wills' Uveitis Clinic.

SARAH AMANULLAH, MD, J.P. DUNN, MD, AND ADAM DEBUSK, MD
PHILADELPHIA

Presentation

A 76-year-old Caucasian gentleman presented to an outside optometrist with redness, blurred vision and pain in his left eye that had been present for nearly two months. He was initially diagnosed with a non-specific conjunctivitis and treated with topical antibiotic drops. The left eye redness and pain didn't resolve, however, and he sought a second opinion several weeks later with a community ophthalmologist, who diagnosed him with scleritis and prescribed prednisolone acetate 1% four times per day. The topical steroid, however, didn't provide the patient with any relief. He was referred to the Wills Eye Hospital Uveitis Clinic for further evaluation of his "treatment-resistant scleritis."

Medical History

The patient, a retired schoolteacher, had a past ocular history that was significant for primary open angle glaucoma, treated in both eyes with latanoprost drops once per day in the evening and timolol drops twice per day. His medical history was significant for hypertension, for which he was taking metoprolol succinate 25 mg per day, and hypercholesterolemia, for which he was taking atorvastatin 10 mg per day. He also took aspirin 81 mg per day as primary prevention. The medical history also included prostate cancer in remission.

Past surgical history included cataract extraction with placement of a posterior chamber intraocular lenses in both eyes and a repair of an abdominal hernia. Family history was noncontributory. Socially, the patient reported drinking one alcoholic drink per day, but denied tobacco and illicit substance use. Review of systems was positive for chronic floaters, occasional transient diplopia, "sinus-type" headache behind his left eye and recent trauma (he fell down the stairs without trauma to head or loss of consciousness).

Exam

The patient's vision was 20/20 OD and 20/20-2 OS. Pupils were round, equally reactive to light, and didn't reveal an afferent pupillary defect. Intraocular pressure was within normal limits, though slightly higher in the affected eye (16 mmHg OD, 20 mmHg OS). Visual fields were full to confrontation and Ishihara color plates were full.

Anterior segment exam of the left eye at the slit lamp revealed corkscrew injection of blood vessels without scleritis or ciliary flush (*Figure 1*). The cornea was clear without keratic precipitates, edema or infiltrate. The anterior chamber was deep and quiet and there was no blood in Schlemm's canal on gonioscopy. The iris was flat without nodules or poste-

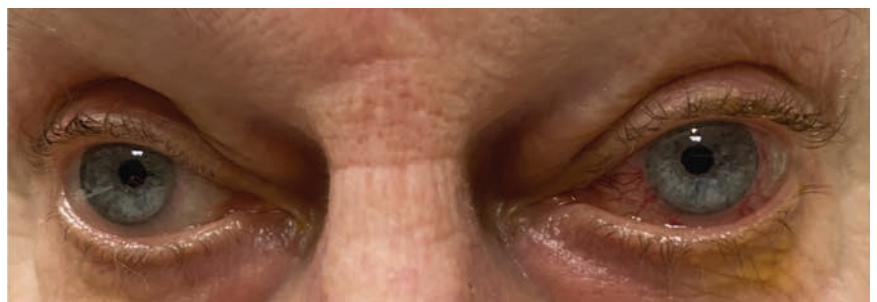

Figure 1. External photograph revealing corkscrew injection of conjunctival vessels of the left eye.

rior synechiae. There were focal radial transillumination defects at 5 o'clock. There was a PCIOL with trace posterior capsule opacification. Slit lamp exam of the right eye was normal.

Dilated fundus exam of the left eye revealed two clumped intraretinal hemorrhages in the inferotemporal macula (*Figure 2*). The vitreous was clear, the optic nerve sharp and pink, the retinal vessels were of normal caliber and course, and the periphery was flat without lesions. Dilated exam of the right eye was normal. A stethoscope revealed no bruit over the orbit.

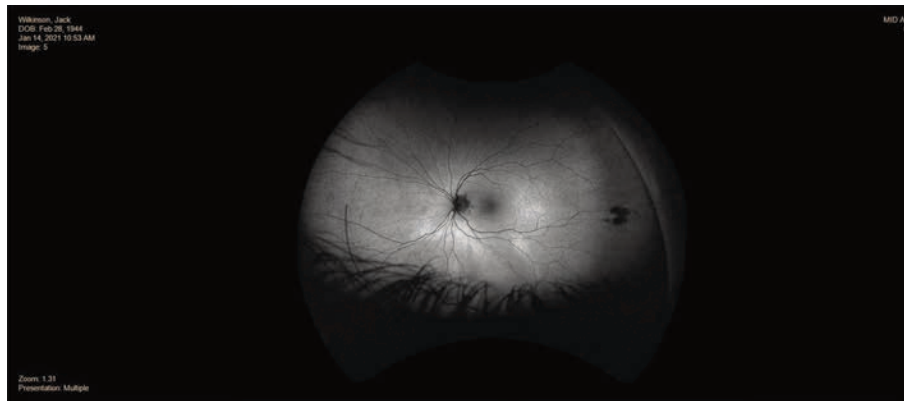


Figure 2. Fundus autofluorescence of the left eye showing clumped intraretinal hemorrhages in the inferotemporal macula.

Work-up, Diagnosis and Treatment

At this point, the patient was brought to Wills Eye's Neuro-ophthalmology Clinic. Further examination revealed a proptosis of 5-mm difference (Hertel Base 100: 16 OD, 21 OS). Oculomotor exam found flick of left hypertropia in primary, 2 prism diopters in left gaze, 3 PD in downgaze, flick in right gaze and 0 PD in upgaze.

Differential diagnosis included vascular lesions (such as carotid cavernous fistula, orbital arteriovenous malformation), thrombus, tumor (primary versus metastasis), thyroid eye disease and other orbital inflammatory processes. The location of the lesion had been narrowed at this point to the orbit or the cavernous sinus.

The patient underwent MRI and MRA the same day in the Wills Emergency Room. MRI revealed enlarged

extraocular muscles with sparing of the tendinous insertions (consistent with thyroid-associated orbitopathy) but no features of cavernous carotid fistula, no acute infarct, no intracranial hemorrhage and no aneurysm in the Circle of Willis.

The patient also underwent carotid and orbital doppler ultrasound testing. The carotid ultrasound was within normal limits. The orbital ultrasound revealed an arterialized left superior ophthalmic vein, consistent with dural-cavernous arteriovenous malformation or carotid-cavernous fistula (*Figure 3*). The neurosurgical service was then consulted, promptly performed cerebral angiography and confirmed the diagnosis of a Barrow Classification Type-D carotid-cavernous fistula.

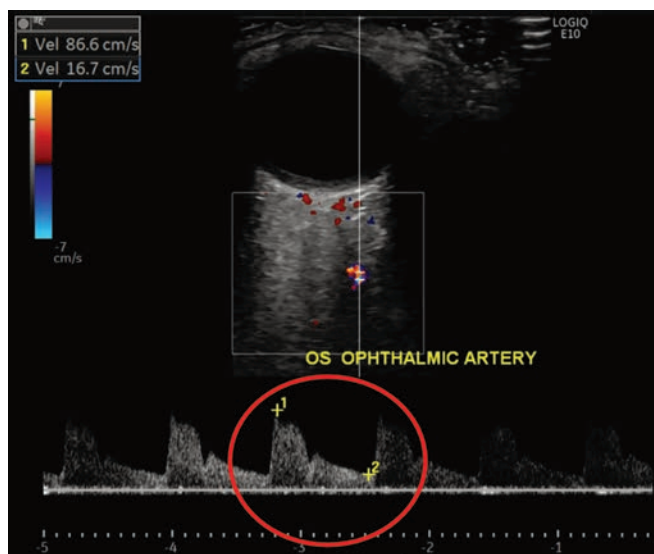


Figure 3a. Orbital doppler ultrasound showing the normal waveform of the left ophthalmic artery.

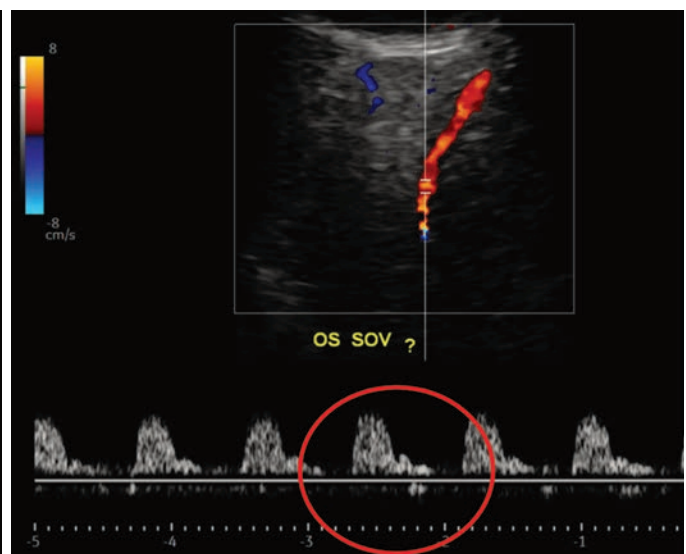


Figure 3b. Orbital doppler ultrasound showing the abnormal arterialized waveform of the left superior ophthalmic vein.

Career Opportunities

OPHTHALMOLOGIST
Danbury, CT

Ophthalmologist to share office with long standing Ophthalmologist in Danbury, CT. High quality equipment. \$1850 per month or adjoining office without equipment- \$1500 per month.

203-545-3539 or 203-748-2020
email mehrimd@aol.com



Do you have Products and Services for sale?

CONTACT US TODAY
FOR CLASSIFIED ADVERTISING
Toll free: 888-498-1460
E-mail: sales@kerhgroup.com



REVIEW
of OPHTHALMOLOGY

Targeting Ophthalmologists?

CLASSIFIED ADVERTISING WORKS

Contact us today
for classified advertising:
Toll free: **888-498-1460**
E-mail: sales@kerhgroup.com

KERHGROUP

ADVERTISER INDEX

This advertiser index is published as a convenience and not as part of the advertising contract. Every care will be taken to index correctly. No allowance will be made for errors due to spelling, incorrect page number, or failure to insert.

Akorn Consumer Health.....	37	Lacrimedics, Inc.....	45
..... www.theratears.com	(800) 367-8327	
Apellis.....	43 info@lacrimedics.com	
..... www.pre-lesion.com	 www.lacrimedics.com	
Dompe.....	17 & 18	Lombart : Advancing Eyecare.....	41
..... www.oxervate.com/HCP	(800) Lombart	
EyePoint Pharmaceuticals.....	Regional Insert www.lombartinstrument.com	
.....(833) 393-7646		Modernizing Medicine.....	83
..... www.dexycu.com/eyepointassist	(561) 235-7502	
Icare USA.....	Cover Tip www.modmed.com	
.....(888) 422-7313		Nanodropper.....	29
..... www.icare-world.com/USA	(507) 405-5676	
Imprimis Pharmaceuticals, Inc.....	7 support@nanodropper.com	
..... www.imprimisrx.com	 www.nanodropper.com	
Kala Pharmaceuticals.....	9	Nextgen.....	15
..... www.eysuvis.com	 www.nextgen.com/1-ophth	
Kala Pharmaceuticals.....	10	Novartis Pharmaceuticals.....	2 - 4
..... www.eysuvis.com	 www.xiidra.com	
Keeler Instruments.....	33	Oyster Point.....	27
.....(800) 523-5620	 www.oysterpointrx.com	
..... www.keelerusa.com		Regener-Eyes.....	84
	(877) 206-0706	
	 www.regenereyes.com	
		Regeneron Pharmaceuticals, Inc.....	22 - 24
	 hco.eylea.us	
		Stephen's Instruments.....	12
	(800) 354-7848	
	 info@stephensinst.com	
	 www.stephensinst.com	
		US Ophthalmic.....	47
	 www.usophthalmic.com	

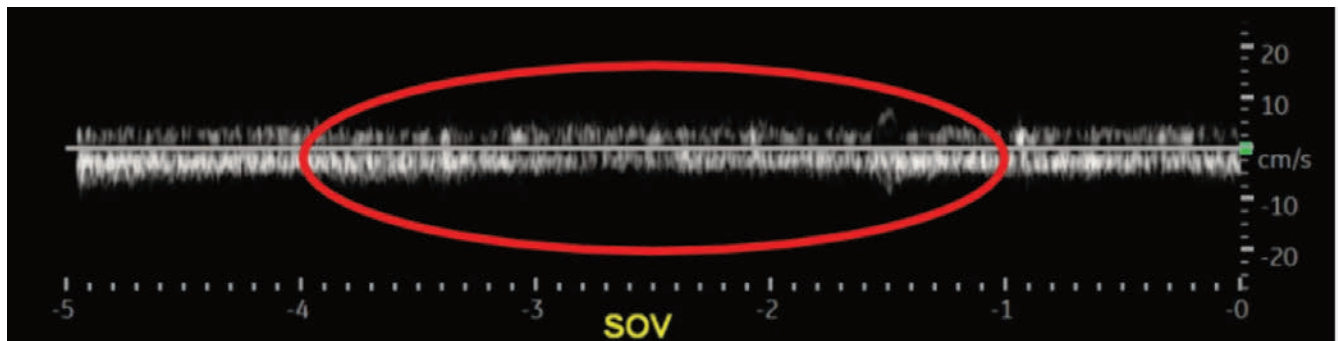


Fig 3c. Orbital doppler ultrasound showing a normal waveform of the right superior ophthalmic vein (the patient's unaffected eye) for reference.

Discussion

Carotid-cavernous fistulas are potentially life-threatening conditions that often present first to the ophthalmologist. The classic triad includes pulsatile exophthalmos, orbital bruit and chemosis,¹ but the presentation can vary significantly. Symptoms can include diplopia, orbital/retro-orbital pain, headache, pulsatile tinnitus, vision loss and facial paresthesia. Signs also vary widely and include:

- eyelid edema (sometimes leading to ptosis);
- proptosis;
- ocular misalignment of any pattern;
- elevated IOP (sometimes with resultant glaucoma in the setting of elevated episcleral venous pressure, angle closure or neovascularization);
- injection;
- chemosis;
- conjunctival arterialization (the classic “corkscrew vessels”);
- disc edema;
- optic neuropathy;
- dilated retinal veins;
- retinal hemorrhages;
- central retinal vein occlusion; and
- choroidal detachment.^{1,2}

Broadly, CCFs are categorized by their flow: high flow (direct connection between the internal carotid artery and cavernous sinus) versus low flow (connections between the meningeal branches of the internal or external carotid artery and the cavernous sinus).²

The diagnosis of CCF is greatly aided by orbital doppler, with a sensitivity of 97 percent (compared to 44 percent for CT and 58 percent for MRI).³ The typical imaging findings include an arterial wave form, an enlarged superior ophthalmic vein, or reversal of flow. Its utility is most noted in CCFs with anterior drainage (through the

superior ophthalmic vein).

The treatment goal in CCFs is to occlude the fistula and maintain carotid artery blood flow. Conservative management includes compression of the ipsilateral carotid artery and jugular vein with the contralateral hand several times per day for four to six weeks.¹ This conservative treatment is only appropriate for low-flow

fistulas. Interventional management of CCFs includes endovascular, surgical or radiosurgical treatment. Endovascular is typically the treatment of choice and is 80- to 90-percent successful.⁴ If endovascular interventions fail, surgical treatment is attempted. Radiosurgical treatment is quite effective but has a latency period of several months.⁴

Symptom resolution ranges from hours and days to weeks and months depending on the severity and chronicity of the fistula.¹ There is also a transient worsening that approximately 40 percent of patients experience prior to symptom resolution.⁵

The neurosurgical team elected conservative management for our patient. He's improving clinically with less pain, proptosis and no further diplopia. Ophthalmologists are typically the first physicians to whom CCF patients present, and it's important to have a high degree of suspicion in a patient with a unilateral condition that's treatment-resistant and has a possible etiology of elevated venous pressure posteriorly. ◀

“CCFs are characterized by their flow: Either high flow (direct connection between the internal carotid and cavernous sinus) or low (connections between the meningeal branches of the internal or external carotid and cavernous sinus).”

1. Elias JA, Goldstein H, Connolly ES Jr, Meyers PM. Carotid-cavernous fistulas. *Neurosurg Focus* 2012;32:5:E9.

2. Tan AC, Farooqui S, Li X, Tan YL, Cullen J, Lim W, Leng SL, Looi A, Tow S. Ocular manifestations and the clinical course of carotid cavernous sinus fistulas in Asian patients. *Orbit* 2014;33:1:45-51.

3. Srinivasan A, Biro NG, Murchison AP, Sergott RC, Moster ML, Jabbour PM, Bilyk JR. Efficacy of orbital color doppler imaging in the diagnosis of carotid cavernous fistulas. *Ophthalmic Plast Reconstr Surg* 2017;33:5:340-344.

4. Tjoumakaris SI, Jabbour PM, Rosenwasser RH. Neuroendovascular management of carotid cavernous fistulae. *Neurosurg Clin N Am* 2009;20:4:447-52.

5. Sergott RC, Grossman RI, Savino PJ, Bosley TM. The syndrome of paradoxical worsening of dural-cavernous sinus arteriovenous malformations. *Ophthalmology* 1987;94:3:205-212.



Glaucoma vs Retina
Does your EHR know the difference?



Still preparing charts before patient visits?



Tired of working in separate systems?



Need the practice insights to help make better decisions?

SEE WHY PRACTICES ARE MAKING THE CHANGE TO modmed[®] OPHTHALMOLOGY



Innovation-Focused

AI. The cloud. Dictation. Touchscreens. Our suite keeps you moving forward.



Intelligent Technology

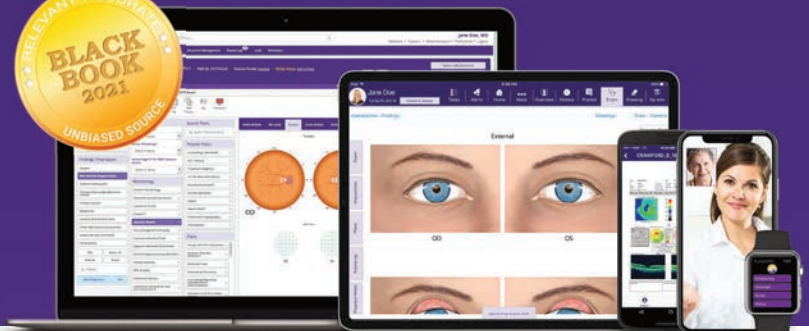
Power-up with subspecialty focused workflows, in-depth analytics and auto-suggested ICD-10 coding.



Award-Winning Service*

From implementation to go-live and every day after, our team is there for you.

MAKE THE SWITCH TO THE #1 EHR**



Visit modmed.com/OPH-Advantage or call 561.235.7502



MODERNIZING MEDICINE

Chill out your patients

