

Wills Eye Resident Series: A 5-year-old girl with a suspicious “pink” eye, p.78

REVIEW[®]

of OPHTHALMOLOGY

March 2021 • reviewofophthalmology.com • Clinical advice you can trust

PLASTICS POINTERS

Lower-lid Bleph Techniques
PAGE 22

GLAUCOMA MANAGEMENT

Virtual Reality-based Field Testing
PAGE 64

RETINAL INSIDER

How to Tackle Complex Macular Holes
PAGE 70

BE PREPARED FOR ANYTHING

*Surgeons give you the tools you need
to handle tough cataract cases.*

- Secondary IOL Fixation:
Know Your Options **P. 34**
- E-Survey: Surgeons' Favorite
Cataract Techniques **P. 42**
- Extracting Cataracts in Uveitic
Glaucoma **P. 48**

ALSO INSIDE:

- Planning Your Diabetic
Retinopathy Treatments **P. 56**
- Med-School Education:
Teaching the Teachers **P. 60**



UPNEEQ

Give Ptosis Patients an EYE-OPENING Lift
With a Daily Drop of Upneeq® (oxymetazoline hydrochloride ophthalmic solution), 0.1%¹

The only FDA-approved prescription eyedrop proven to lift upper eyelids in adults with acquired blepharoptosis (low-lying lids)¹

Learn more at Upneeq.com.

INDICATION

Upneeq® (oxymetazoline hydrochloride ophthalmic solution), 0.1% is indicated for the treatment of acquired blepharoptosis in adults.

IMPORTANT SAFETY INFORMATION

WARNINGS AND PRECAUTIONS

- Alpha-adrenergic agonists as a class may impact blood pressure. Advise Upneeq patients with cardiovascular disease, orthostatic hypotension, and/or uncontrolled hypertension or hypotension to seek medical care if their condition worsens.
- Use Upneeq with caution in patients with cerebral or coronary insufficiency or Sjögren's syndrome. Advise patients to seek medical care if signs and symptoms of potentiation of vascular insufficiency develop.
- Upneeq may increase the risk of angle closure glaucoma in patients with untreated narrow-angle glaucoma. Advise patients to seek immediate medical care if signs and symptoms of acute narrow-angle glaucoma develop.
- Patients should not touch the tip of the single patient-use container to their eye or to any surface, in order to avoid eye injury or contamination of the solution.

ADVERSE REACTIONS

Adverse reactions that occurred in 1-5% of subjects treated with Upneeq were punctate keratitis, conjunctival hyperemia, dry eye, blurred vision, instillation site pain, eye irritation, and headache.

DRUG INTERACTIONS

- Alpha-adrenergic agonists, as a class, may impact blood pressure. Caution in using drugs such as beta blockers, anti-hypertensives, and/or cardiac glycosides is advised. Caution should also be exercised in patients receiving alpha adrenergic receptor antagonists such as in the treatment of cardiovascular disease, or benign prostatic hypertrophy.
- Caution is advised in patients taking monoamine oxidase inhibitors which can affect the metabolism and uptake of circulating amines.

To report SUSPECTED ADVERSE REACTIONS or product complaints, contact RVL Pharmaceuticals at 1-877-482-3788. You may also report SUSPECTED ADVERSE REACTIONS to the FDA at 1-800-FDA-1088 or www.fda.gov/medwatch.

Please see next page for Brief Summary of full Prescribing Information.

Reference: 1. Upneeq® (oxymetazoline hydrochloride ophthalmic solution), 0.1%. [Prescribing Information].

RVL
PHARMACEUTICALS, INC.

Distributed by: RVL Pharmaceuticals, Inc.
Bridgewater, NJ 08807
Customer Service 1-866-600-4799
Upneeq is a registered trademark of RVL Pharmaceuticals, Inc.
©2021 RVL Pharmaceuticals, Inc.
PM-US-UPN-0197 01/21

Learn more at Upneeq.com



UPNEEQ®
(oxymetazoline hydrochloride ophthalmic solution), 0.1%*

*Each mL of Upneeq contains 1 mg of oxymetazoline hydrochloride, equivalent to 0.09 mg (0.09%) of oxymetazoline free base.

Eye-Opening Possibilities

UPNEEQ® (oxymetazoline hydrochloride ophthalmic solution), 0.1%, for topical ophthalmic use

*Each mL of UPNEEQ contains 1 mg of oxymetazoline hydrochloride, equivalent to 0.09 mg (0.09%) of oxymetazoline free base.

BRIEF SUMMARY: The following is a brief summary only; see full Prescribing Information at <https://www.upneeq.com/Upneeq-PI.pdf> for complete information.

1 INDICATIONS AND USAGE

UPNEEQ is indicated for the treatment of acquired blepharoptosis in adults.

2 DOSAGE AND ADMINISTRATION

Contact lenses should be removed prior to instillation of UPNEEQ and may be reinserted 15 minutes following its administration. If more than one topical ophthalmic drug is being used, the drugs should be administered at least 15 minutes between applications.

4 CONTRAINDICATIONS

None.

5 WARNINGS AND PRECAUTIONS

5.1 Potential Impacts on Cardiovascular Disease

Alpha-adrenergic agonists may impact blood pressure. UPNEEQ should be used with caution in patients with severe or unstable cardiovascular disease, orthostatic hypotension, and uncontrolled hypertension or hypotension. Advise patients with cardiovascular disease, orthostatic hypotension, and/or uncontrolled hypertension/hypotension to seek immediate medical care if their condition worsens.

5.2 Potentiation of Vascular Insufficiency

UPNEEQ should be used with caution in patients with cerebral or coronary insufficiency, or Sjögren's syndrome. Advise patients to seek immediate medical care if signs and symptoms of potentiation of vascular insufficiency develop.

5.3 Risk of Angle Closure Glaucoma

UPNEEQ may increase the risk of angle closure glaucoma in patients with untreated narrow-angle glaucoma. Advise patients to seek immediate medical care if signs and symptoms of acute angle closure glaucoma develop.

5.4 Risk of Contamination

Patients should not touch the tip of the single patient-use container to their eye or to any surface, in order to avoid eye injury or contamination of the solution.

6 ADVERSE REACTIONS

6.1 Clinical Trials Experience

Because clinical trials are conducted under widely varying conditions, adverse reaction rates observed in the clinical trials of a drug cannot be directly compared to rates in the clinical trials of another drug and may not reflect the rates observed in practice. A total of 360 subjects with acquired blepharoptosis were treated with UPNEEQ once daily in each eye for at least 6 weeks in three controlled Phase 3 clinical trials, including 203 subjects treated with UPNEEQ for 6 weeks and 157 subjects treated with UPNEEQ for 12 weeks. Adverse reactions that occurred in 1-5% of subjects treated with UPNEEQ were punctate keratitis, conjunctival hyperemia, dry eye, blurred vision, instillation site pain, eye irritation, and headache.

7 DRUG INTERACTIONS

7.1 Anti-hypertensives/Cardiac Glycosides

Alpha-adrenergic agonists, as a class, may impact blood pressure. Caution in using drugs such as beta-blockers, anti-hypertensives, and/or cardiac glycosides is advised.

Caution should also be exercised in patients receiving alpha adrenergic receptor antagonists such as in the treatment of cardiovascular disease, or benign prostatic hypertrophy.

7.2 Monoamine Oxidase Inhibitors

Caution is advised in patients taking MAO inhibitors which can affect the metabolism and uptake of circulating amines.

8 USE IN SPECIFIC POPULATIONS

8.1 Pregnancy

Risk Summary

There are no available data on UPNEEQ use in pregnant women to inform a drug-associated risk for major birth defects and miscarriage. In animal reproduction studies, there were no adverse developmental effects observed after oral administration of oxymetazoline hydrochloride in pregnant rats and rabbits at systemic exposures up to 7 and 278 times the maximum recommended human ophthalmic dose (MRHOD), respectively, based on dose comparison. [see Data]. The estimated background risks of major birth defects and miscarriage for the indicated population are unknown. All pregnancies have a background risk of birth defect, loss, or other adverse outcomes. In the U.S. general population, the estimated background risk of major birth defects and miscarriage in clinically recognized pregnancies is 2-4% and 15-20%, respectively.

Data

Animal Data

Effects on embryo-fetal development were evaluated in rats and rabbits following oral administration of oxymetazoline hydrochloride during the period of organogenesis. Oxymetazoline hydrochloride did not cause adverse effects to the fetus at oral doses up to 0.2 mg/kg/day in pregnant rats during the period of organogenesis (28 times the MRHOD, on a dose comparison basis). Oxymetazoline hydrochloride did not cause adverse effects to the fetus at oral doses up to 1 mg/kg/day in pregnant rabbits during the period of organogenesis (278 times the MRHOD, on a dose comparison basis). Maternal toxicity, including decreased maternal body weight, was produced at the high dose of 1 mg/kg/day in pregnant rabbits and was associated with findings of delayed skeletal ossification.

In a rat prenatal and postnatal development study, oxymetazoline hydrochloride was orally administered to pregnant rats once daily from gestation day 6 through lactation day 20. Maternal toxicity was produced at the high dose of 0.2 mg/kg/day (28 times the MRHOD, on a dose comparison basis) in pregnant rats and was associated with an increase in pup mortality and reduced pup body weights. Delayed sexual maturation was noted at 0.1 mg/kg/day (14 times the MRHOD, on a dose comparison basis). Oxymetazoline hydrochloride did not have any adverse effects on fetal development at a dose of 0.05 mg/kg/day (7 times the MRHOD, on a dose comparison basis).

8.2 Lactation

Risk Summary

No clinical data are available to assess the effects of oxymetazoline on the quantity or rate of breast milk production, or to establish the level of oxymetazoline present in human breast milk post-dose. Oxymetazoline was detected in the milk of lactating rats. The developmental and health benefits of breastfeeding should be considered along with the mother's clinical need for UPNEEQ and any potential adverse effects on the breastfed child from UPNEEQ.

8.4 Pediatric Use

Safety and effectiveness of UPNEEQ have not been established in pediatric patients under 13 years of age.

8.5 Geriatric Use

Three hundred and fifteen subjects aged 65 years and older received treatment with UPNEEQ (n = 216) or vehicle (n = 99) in clinical trials. No overall differences in safety or effectiveness were observed between subjects 65 years of age and older and younger subjects.

10 OVERDOSAGE

Accidental oral ingestion of topical intended solutions (including ophthalmic solutions and nasal sprays) containing imidazoline derivatives (e.g., oxymetazoline) in children has resulted in serious adverse events requiring hospitalization, including nausea, vomiting, lethargy, tachycardia, decreased respiration, bradycardia, hypotension, hypertension, sedation, somnolence, mydriasis, stupor, hypothermia, drooling, and coma. Keep UPNEEQ out of reach of children.

PATIENT COUNSELING INFORMATION

Advise the patient to read the FDA-approved patient labeling (Instructions for Use).

RVL
PHARMACEUTICALS, INC.

Manufactured for: RVL Pharmaceuticals, Inc.
Bridgewater, New Jersey 08807
©2021 RVL Pharmaceuticals, Inc.
UPNEEQ is a registered trademark of RVL Pharmaceuticals, Inc.
PM-US-UPN-0203 01/21

Tecnis Eyhance Intraocular Lenses Approved by the FDA

In February, the U.S. Food and Drug Administration approved the Tecnis Eyhance and Eyhance Toric II intraocular lenses (Johnson & Johnson Vision) for implantation in cataract patients in the United States. The new refractive surface design slightly increases the depth of focus compared to a standard monofocal. The company says this improves intermediate vision, while distance vision remains similar to that achieved with a standard monofocal. J&J Vision also states that the Eyhance lenses deliver 30 percent better image contrast in low light at 5 mm than a typical monofocal lens. At the same time, the company reports a low incidence of dysphotopsias, comparable to that associated with the previous Tecnis one-piece monofocal. Both Eyhance lenses are available in 0.5-D increments ranging from +5 D to +34 D.

At least five published studies have compared the vision gained from an Eyhance lens to the previous Tecnis monofocal.¹⁻⁵ All five

studies found better intermediate vision with the Eyhance lens. Two studies also noted greater spectacle independence with the Eyhance;^{1,2} one noted a better tolerance for residual refractive error;¹ and at least one study found better near vision, as well.⁴ The most frequently reported adverse event that occurred during the company's SENSAR clinical trial was cystoid macular edema, which occurred at a rate of

3.3 percent.

Douglas D. Koch, MD, a professor and Allen, Mosbacher and Law Chair in Ophthalmology at Baylor College of Medicine in Houston, consults for Johnson & Johnson Vision; he says he's watched and consulted on the evolution of this lens for a number of years. "It's a very interesting design that con-

(Continued on p. 12)

TECNIS EYHANCE SPECIFICATIONS

Lens design	1-piece
Available powers	+5 D to +34 D in 0.5-D increments
Diameter	6 mm
Shape	Biconvex, continuous, higher-order polynomial aspheric anterior surface
Material	UV-blocking hydrophobic acrylic
Refractive index	1.47 at 35 degrees C/95 degrees F
Edge design	Frosted continuous posterior square edge
Overall haptic diameter	13 mm
Haptic design	Offset from optics
Delivery system	Tecnis Simplicity system

IN BRIEF

Trefoil Begins Second Phase II STORM Trial

Trefoil Therapeutics began a Phase II clinical trial of its engineered Fibroblast Growth Factor-1, TTHX1114, to evaluate its safety and efficacy as a regenerative treatment for patients with Fuchs' endothelial corneal dystrophy. The STORM study, the second clinical trial of TTHX1114, is designed to assess the therapy's potential to enhance corneal recovery

and improve visual acuity in FECD patients undergoing the technique known as Descemetorhexis Without Endothelial Keratoplasty, which is also known as Descemet's Stripping Only.

Gyroscope Announces Interim Data From Phase I/II FOCUS Trial

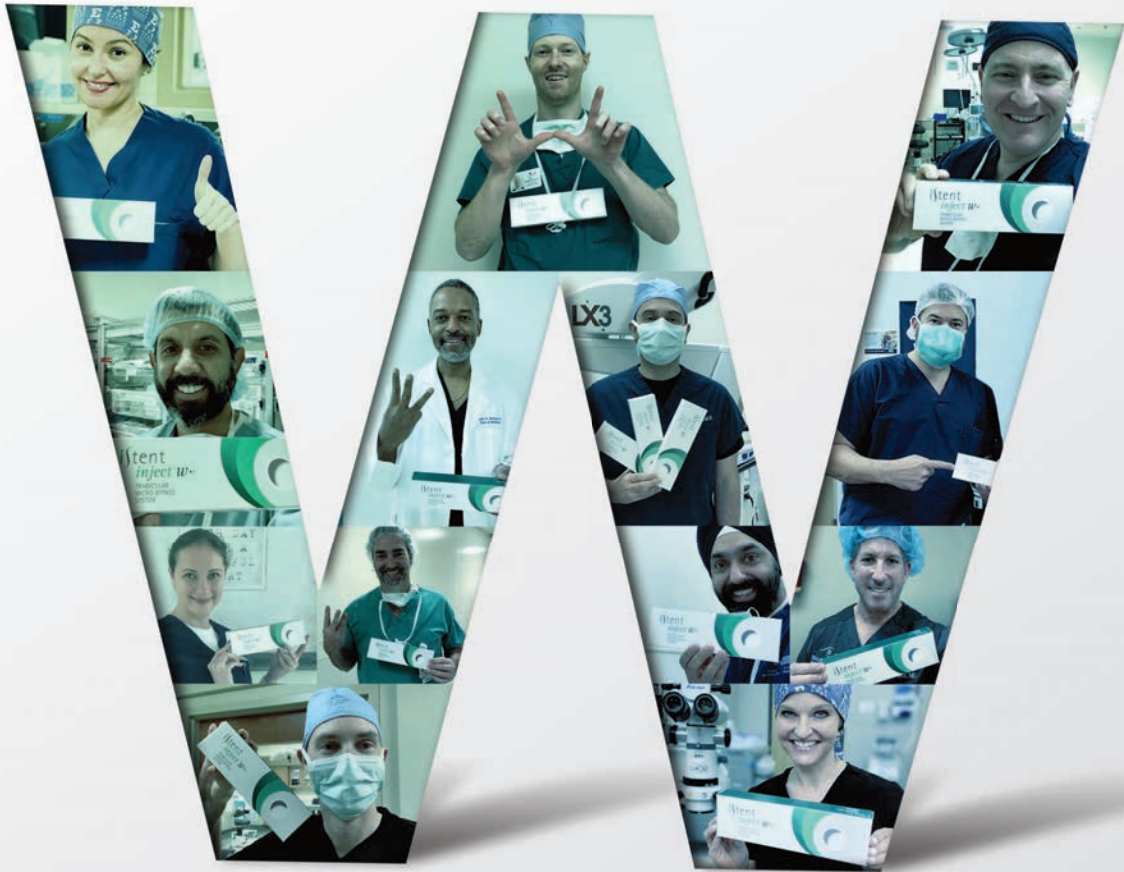Gyroscope Therapeutics announced interim safety, protein expression and biomarker data from the ongoing open-label Phase I/II FOCUS clinical trial of its investigational

gene therapy, GT005, in patients with geographic atrophy secondary to age-related macular degeneration. The company says that interim results show GT005 is well-tolerated and results in sustained increases in vitreous complement factor I levels in the majority of patients, as well as decreases in the downstream complement proteins associated with overactivation of the complement system.

RegenxBio Announces Interim

Phase I/IIa Data for RGX-314

RegenxBio reported at the Angiogenesis, Exudation, and Degeneration 2021 conference additional interim data from cohorts 4 and 5 of its RGX-314 Phase I/IIa trial for the treatment of wet AMD, and cohort 3 of its Long-Term Follow-Up (LTFU) study. The company says that patients in cohorts 4 and 5 at 1.5 years demonstrated stable visual acuity, as well as decreased central retinal thickness.



POWERFUL. PREDICTABLE. PROVEN.



Get started with micro-invasive glaucoma surgery using iStent *inject W* today.
Contact your local Glaukos rep for more information.

iStent
inject W



INDICATION FOR USE. The iStent *inject W* Trabecular Micro-Bypass System Model G2-W is indicated for use in conjunction with cataract surgery for the reduction of intraocular pressure (IOP) in adult patients with mild to moderate primary open-angle glaucoma. **CONTRAINDICATIONS.** The iStent *inject W* is contraindicated in eyes with angle-closure glaucoma, traumatic, malignant, uveitic, or neovascular glaucoma, discernible congenital anomalies of the anterior chamber (AC) angle, retrolubar tumor, thyroid eye disease, or Sturge-Weber Syndrome or any other type of condition that may cause elevated episcleral venous pressure. **WARNINGS.** Gonioscopy should be performed prior to surgery to exclude congenital anomalies of the angle, PAS, rubeosis, or conditions that would prohibit adequate visualization of the angle that could lead to improper placement of the stent and pose a hazard. **MRI INFORMATION.** The iStent *inject W* is MR-Conditional, i.e., the device is safe for use in a specified MR environment under specified conditions; please see Directions for Use (DFU) label for details. **PRECAUTIONS.** The surgeon should monitor the patient postoperatively for proper maintenance of IOP. The safety and effectiveness of the iStent *inject W* have not been established as an alternative to the primary treatment of glaucoma with medications, in children, in eyes with significant prior trauma, abnormal anterior segment, chronic inflammation, prior glaucoma surgery (except SLT performed > 90 days preoperative), glaucoma associated with vascular disorders, pseudoexfoliative, pigmentary or other secondary open-angle glaucomas, pseudophakic eyes, phakic eyes without concomitant cataract surgery or with complicated cataract surgery, eyes with medicated IOP > 24 mmHg or unmedicated IOP < 21 mmHg or > 36 mmHg, or for implantation of more or less than two stents. **ADVERSE EVENTS.** Common postoperative adverse events reported in the iStent *inject W* randomized pivotal trial included stent obstruction (6.2%), intraocular inflammation (5.7% for iStent *inject W* vs. 4.2% for cataract surgery only), secondary surgical intervention (5.4% vs. 5.0%) and BCVA loss ≥ 2 lines ≥ 3 months (2.6% vs. 4.2%). **CAUTION:** Federal law restricts this device to sale by, or on the order of, a physician. Please see DFU for a complete list of contraindications, warnings, precautions, and adverse events.

©2020 Glaukos Corporation. Glaukos and iStent *inject W* are registered trademarks of Glaukos Corporation. PM-US-0343

GLAUKOS®

CONTRIBUTORS

CHIEF MEDICAL EDITOR

Mark H. Blecher, MD

CONTACT LENSES

Penny Asbell, MD

CORNEA / ANTERIOR SEGMENT

Thomas John, MD

GLAUCOMA MANAGEMENT

Peter Netland, MD, PHD
Kuldev Singh, MD

MASTERS OF SURGERY

Taliva D. Martin, MD
Sara J. Haug, MD, PhD

MEDICARE Q & A

Paul M. Larson, MBA

PEDIATRIC PATIENT

Janine Collinge, MD

PLASTIC POINTERS

Anna P. Murchison, MD, MPH

REFRACTIVE SURGERY

Arturo S. Chayet, MD

RETINAL INSIDER

Carl Regillo, MD, FACS
Yoshihiro Yonekawa, MD

TECHNOLOGY UPDATE

Steven T. Charles, MD
Michael Colvard, MD

WILLS RESIDENT CASE SERIES

Meera D. Sivalingam, MD

ADVISORY BOARD

PENNY A. ASBELL, MD, MEMPHIS, TENN.

BRANDON AYRES, MD, PHILADELPHIA

SURENDRA BASTI, MD, CHICAGO

WILLIAM I. BOND, MD, PEKIN, ILL.

ALAN N. CARLSON, MD, DURHAM, N.C.

Y. RALPH CHU, MD, EDINA, MINN.

ADAM J. COHEN, MD, CHICAGO

JANINE COLLINGE, MD, FARMINGTON, CONN.

UDAY DEVGAN, MD, FACS, LOS ANGELES

ERIC DONNENFELD, MD, ROCKVILLE CENTRE, N.Y.

DANIEL S. DURRIE, MD, KANSAS CITY, MO.

ROBERT EPSTEIN, MD, MCHENRY, ILL.

ROBERT D. FECHTNER, MD, NEWARK, N.J.

WILLIAM J. FISHKIND, MD, TUCSON, ARIZ.

BRIAN FRANCIS, MD, Los Angeles

JAMES P. GILLS, MD, TARPON SPRINGS, FLA.

HARRY GRABOW, MD, SARASOTA, FLA.

DOUGLAS K. GRAYSON, MD, NEW YORK CITY

DAVID R. HARDTEN, MD, MINNEAPOLIS

SARA J. HAUG, MD, PHD, DURANGO, COLO.

KENNETH J. HOFFER, MD, SANTA MONICA, CALIF.

JACK T. HOLLADAY, MD, MSEE, HOUSTON

JOHN D. HUNKELER, MD, KANSAS CITY, MO.

THOMAS JOHN, MD, TINLEY PARK, ILL.

ROBERT M. KERSHNER, MD, MS, PALM BEACH GARDENS, FLA.

GUY M. KEZIRIAN, MD, PARADISE VALLEY, ARIZ.

TERRY KIM, MD, DURHAM, N.C.

BRAD KLIGMAN, MD, GARDEN CITY, N.Y.

TOMMY KORN, MD, SAN DIEGO

DAVID A. LEE, MD, HOUSTON

FRANCIS S. MAH, MD, LA JOLLA, CALIF

NICK MAMALIS, MD, SALT LAKE CITY

EDWARD MANCHE, MD, PALO ALTO, CALIF.

MIKE S. MCFARLAND, MD, PINE BLUFF, ARK.

JEFFREY B. MORRIS, MD, MPH, ENCINITAS, CALIF.

KEVIN MILLER, MD, LOS ANGELES

MARLENE R. MOSTER, MD, PHILADELPHIA

ANNA P. MURCHISON, MD, MPH, PHILADELPHIA

ROBERT J. NOECKER, MD, FAIRFIELD, CONN.

ROBERT OSHER, MD, CINCINNATI

MARK PACKER, MD, WEST PALM BEACH, FLA.

CHRISTOPHER J. RAPUANO, MD, PHILADELPHIA

AUGUST READER III, MD, SAN FRANCISCO

TONY REALINI, MD, MORGANTOWN, W.V.

KENNETH J. ROSENTHAL, MD, GREAT NECK, N.Y.

ERIC ROTHCHILD, MD, DELRAY BEACH, FLA.

SHERI ROWEN, MD, BALTIMORE

JAMES J. SALZ, MD, LOS ANGELES

INGRID U. SCOTT, MD, MPH, HERSHEY, PA.

JOEL SCHUMAN, MD, PITTSBURGH

GAURAV SHAH, MD, ST. LOUIS

DAVID R. STAGER JR., MD, DALLAS

KARL STONECIPHER, MD, GREENSBORO, N.C.

JAMES C. TSAI, MD, NEW YORK CITY

VANCE THOMPSON, MD, SIOUX FALLS, S.D.

FARRELL C. TYSON, MD, CAPE CORAL, FLA.

R. BRUCE WALLACE III, MD, ALEXANDRIA, LA.



BUSINESS OFFICES

19 CAMPUS BOULEVARD, SUITE 101
NEWTOWN SQUARE, PA 19073
SUBSCRIPTION INQUIRIES (877) 529-1746
(USA ONLY); OUTSIDE USA, CALL (847) 763-9630

BUSINESS STAFF

PUBLISHER

MICHAEL HOSTER

(610) 492-1028 MHOSTER@JOBSON.COM

EXECUTIVE DIRECTOR

JAMES HENNE

(610) 492-1017 JHENNE@JOBSON.COM

REGIONAL SALES MANAGER

MICHELE BARRETT

(610) 492-1014 MBARRETT@JOBSON.COM

REGIONAL SALES MANAGER

JONATHAN DARDINE

(610) 492-1030 JDARDINE@JOBSON.COM

CLASSIFIED ADVERTISING

(888)-498-1460

PRODUCTION MANAGER

FARRAH APONTE

212-274-7057 FAPONTE@JOBSON.COM

PRODUCTION MANAGER

KAREN LALLONE

(610) 492-1010 KLALLONE@JOBSON.COM

SUBSCRIPTIONS

\$63 A YEAR, \$99 (U.S.) IN CANADA,
\$158 (U.S.) IN ALL OTHER COUNTRIES.

SUBSCRIPTIONS E-MAIL:

REVOPHTHALMOLOGY@CAMBEYWEST.COM

CIRCULATION

PO BOX 71, CONGERS, NY 10920-0071

(877) 529-1746

OUTSIDE USA: (845) 267-3065

SENIOR CIRCULATION MANAGER

HAMILTON MAHER

(212) 219-7870 hmaher@jhihealth.com

CEO, INFORMATION GROUP SERVICES

MARC FERRARA

SENIOR VICE PRESIDENT, OPERATIONS

JEFF LEVITZ

VICE PRESIDENT, HUMAN RESOURCES

TAMMY GARCIA

VICE PRESIDENT, CREATIVE SERVICES & PRODUCTION

MONICA TETTAMANZI

CORPORATE PRODUCTION DIRECTOR

JOHN ANTHONY CAGGIANO

VICE PRESIDENT, CIRCULATION

JARED SONNERS

395 Hudson Street, 3rd Floor,
New York, NY 10014

REVIEW OF OPHTHALMOLOGY (ISSN 1081-0226; USPS No. 0012-345) is published monthly, 12 times per year by Jobson Medical Information, 395 Hudson Street, 3rd Floor, New York, NY 10014. Periodicals postage paid at New York, NY and additional mailing offices. Postmaster: Send address changes to Review of Ophthalmology, PO Box 71, Congers, NY 10929-0071. Subscription Prices: US One Year \$63.00, US Two Year \$112.00, Canada One Year \$99.00, Canada Two Year \$181.00, Int'l One Year \$158.00, Int'l Two Year \$274.00. For subscription information call (877) 529-1746 (USA only); outside USA, call (845)-267-3065. Or email us at revophthalmology@cambeywest.com. Canada Post: Publications Mail Agreement #40612608. Canada Returns to be sent to Bleuchip International, P.O. Box 25542, London, ON N6C 6B2.

BRIEF SUMMARY OF PRESCRIBING INFORMATION

This Brief Summary does not include all the information needed to use LOTEMAX[®] SM safely and effectively. See full prescribing information for LOTEMAX[®] SM.

LOTEMAX[®] SM (loteprednol etabonate ophthalmic gel) 0.38%
For topical ophthalmic use
Initial U.S. Approval: 1998

INDICATIONS AND USAGE

LOTEMAX[®] SM is a corticosteroid indicated for the treatment of post-operative inflammation and pain following ocular surgery.

DOSAGE AND ADMINISTRATION

Invert closed bottle and shake once to fill tip before instilling drops. Apply one drop of LOTEMAX[®] SM into the conjunctival sac of the affected eye three times daily beginning the day after surgery and continuing throughout the first 2 weeks of the post-operative period.

CONTRAINDICATIONS

LOTEMAX[®] SM, as with other ophthalmic corticosteroids, is contraindicated in most viral diseases of the cornea and conjunctiva including epithelial herpes simplex keratitis (dendritic keratitis), vaccinia, and varicella, in mycobacterial infection of the eye and fungal diseases of ocular structures.

WARNINGS AND PRECAUTIONS

Intraocular Pressure (IOP) Increase: Prolonged use of corticosteroids may result in glaucoma with damage to the optic nerve, defects in visual acuity and fields of vision. Steroids should be used with caution in the presence of glaucoma. If this product is used for 10 days or longer, intraocular pressure should be monitored.

Cataracts: Use of corticosteroids may result in posterior subcapsular cataract formation.

Delayed Healing: The use of steroids after cataract surgery may delay healing and increase the incidence of bleb formation. In those diseases causing thinning of the cornea or sclera, perforations have been known to occur with the use of topical steroids. The initial prescription and renewal of the medication order should be made by a physician only after examination of the patient with the aid of magnification such as slit lamp biomicroscopy and, where appropriate, fluorescein staining.

Bacterial Infections: Prolonged use of corticosteroids may suppress the host response and thus increase the hazard of secondary ocular infections. In acute purulent conditions of the eye, steroids may mask infection or enhance existing infection.

Viral infections: Employment of a corticosteroid medication in the treatment of patients with a history of herpes simplex requires great caution. Use of ocular steroids may prolong the course and may exacerbate the severity of many viral infections of the eye (including herpes simplex).

Fungal Infections: Fungal infections of the cornea are particularly prone to develop coincidentally with long-term local steroid application. Fungus invasion must be considered in any persistent corneal ulceration where a steroid has been used or is in use. Fungal cultures should be taken when appropriate.

Contact Lens Wear: Contact lenses should not be worn when the eyes are inflamed.

ADVERSE REACTIONS

Because clinical trials are conducted under widely varying conditions, adverse reaction rates observed in the clinical trials of a drug cannot be directly compared to rates in the clinical trials of another drug and may not reflect the rates observed in practice. Adverse reactions associated with ophthalmic steroids include elevated intraocular pressure, which may be associated with infrequent optic nerve damage, visual acuity and field defects, posterior subcapsular cataract formation, delayed wound healing and secondary ocular infection from pathogens including herpes simplex, and perforation of the globe where there is thinning of the cornea or sclera. There were no treatment-emergent adverse drug reactions that occurred in more than 1% of subjects in the three times daily group compared to vehicle.

USE IN SPECIAL POPULATIONS

Pregnancy: Risk Summary: There are no adequate and well controlled studies with loteprednol etabonate in pregnant women. Loteprednol etabonate produced teratogenicity at clinically relevant doses in the rabbit and rat when administered orally during pregnancy. Loteprednol etabonate

produced malformations when administered orally to pregnant rabbits at doses 4.2 times the recommended human ophthalmic dose (RHOD) and to pregnant rats at doses 106 times the RHOD. In pregnant rats receiving oral doses of loteprednol etabonate during the period equivalent to the last trimester of pregnancy through lactation in humans, survival of offspring was reduced at doses 10.6 times the RHOD. Maternal toxicity was observed in rats at doses 1066 times the RHOD, and a maternal no observed adverse effect level (NOAEL) was established at 106 times the RHOD. The background risk of major birth defects and miscarriage for the indicated population is unknown. However, the background risk in the U.S. general population of major birth defects is 2 to 4%, and of miscarriage is 15 to 20%, of clinically recognized pregnancies. Data: *Animal Data.* Embryofetal studies were conducted in pregnant rabbits administered loteprednol etabonate by oral gavage on gestation days 6 to 18, to target the period of organogenesis. Loteprednol etabonate produced fetal malformations at 0.1 mg/kg (4.2 times the recommended human ophthalmic dose (RHOD) based on body surface area, assuming 100% absorption). Spina bifida (including meningocele) was observed at 0.1 mg/kg, and exencephaly and craniofacial malformations were observed at 0.4 mg/kg (17 times the RHOD). At 3 mg/kg (128 times the RHOD), loteprednol etabonate was associated with increased incidences of abnormal left common carotid artery, limb flexures, umbilical hernia, scoliosis, and delayed ossification. Abortion and embryofetal lethality (resorption) occurred at 6 mg/kg (256 times the RHOD). A NOAEL for developmental toxicity was not established in this study. The NOAEL for maternal toxicity in rabbits was 3 mg/kg/day. Embryofetal studies were conducted in pregnant rats administered loteprednol etabonate by oral gavage on gestation days 6 to 15, to target the period of organogenesis. Loteprednol etabonate produced fetal malformations, including absent innominate artery at 5 mg/kg (106 times the RHOD); and cleft palate, agnathia, cardiovascular defects, umbilical hernia, decreased fetal body weight and decreased skeletal ossification at 50 mg/kg (1066 times the RHOD). Embryofetal lethality (resorption) was observed at 100 mg/kg (2133 times the RHOD). The NOAEL for developmental toxicity in rats was 0.5 mg/kg (10.6 times the RHOD). Loteprednol etabonate was maternally toxic (reduced body weight gain) at 50 mg/kg/day. The NOAEL for maternal toxicity was 5 mg/kg. A peri-/postnatal study was conducted in rats administered loteprednol etabonate by oral gavage from gestation day 15 (start of fetal period) to postnatal day 21 (the end of lactation period). At 0.5 mg/kg (10.6 times the clinical dose), reduced survival was observed in live-born offspring. Doses \geq 5 mg/kg (106 times the RHOD) caused umbilical hernia/incomplete gastrointestinal tract. Doses \geq 50 mg/kg (1066 times the RHOD) produced maternal toxicity (reduced body weight gain, death), decreased number of live-born offspring, decreased birth weight, and delays in postnatal development. A developmental NOAEL was not established in this study. The NOAEL for maternal toxicity was 5 mg/kg. **Lactation:** There are no data on the presence of loteprednol etabonate in human milk, the effects on the breastfed infant, or the effects on milk production. The developmental and health benefits of breastfeeding should be considered, along with the mother's clinical need for LOTEMAX[®] SM and any potential adverse effects on the breastfed infant from LOTEMAX[®] SM. **Pediatric Use:** Safety and effectiveness of LOTEMAX[®] SM in pediatric patients have not been established. **Geriatric Use:** No overall differences in safety and effectiveness have been observed between elderly and younger patients.

NONCLINICAL TOXICOLOGY

Carcinogenesis, Mutagenesis, Impairment of Fertility: Long-term animal studies have not been conducted to evaluate the carcinogenic potential of loteprednol etabonate. Loteprednol etabonate was not genotoxic *in vitro* in the Ames test, the mouse lymphoma tk assay, or in the chromosomal aberration test in human lymphocytes, or *in vivo* in the mouse micronucleus assay. Treatment of male and female rats with 25 mg/kg/day of loteprednol etabonate (533 times the RHOD based on body surface area, assuming 100% absorption) prior to and during mating caused preimplantation loss and decreased the number of live fetuses/live births. The NOAEL for fertility in rats was 5 mg/kg/day (106 times the RHOD).

LOTEMAX is a trademark of Bausch & Lomb Incorporated or its affiliates.
© 2019 Bausch & Lomb Incorporated
Bausch + Lomb, a division of Valeant Pharmaceuticals North America LLC
Bridgewater, NJ 08807 USA

LSM.0091.USA.19
Based on 9669600-9669700

Revised: 02/2019

SUBMICRON STRONG

for

POTENCY + PROVEN STRENGTH^{1,2}

2× greater inflammation clearance
as compared to vehicle^{2*}

SM TECHNOLOGY™

- Engineered with SM Technology™ for efficient penetration at a low BAK level (0.003%)^{1,3}
- ~2× greater penetration to the aqueous humor than LOTEMAX® GEL (loteprednol etabonate ophthalmic gel) 0.5%³

Clinical significance of these preclinical data has not been established.

LOTEMAX® SM

(loteprednol etabonate
ophthalmic gel) 0.38%

SMALL & MIGHTY
SUBMICRON PARTICLES

*PROVEN STRENGTH

- 30% of LOTEMAX® SM patients had complete ACC resolution vs vehicle (15%) at Day 8 [N=371, $P < 0.0001$]^{1,2†}
- 74% of LOTEMAX® SM patients were completely pain-free vs vehicle (49%) at Day 8 [N=371, $P < 0.0001$]^{1,2‡}

†Pooled analysis of Phase 3 clinical studies. Study 1: 29% LOTEMAX® SM (N=171) vs 9% vehicle (N=172). Study 2: 31% LOTEMAX® SM (N=200) vs 20% vehicle (N=199); $P < 0.05$ for all.

‡Pooled analysis of Phase 3 clinical studies. Study 1: 73% LOTEMAX® SM (N=171) vs 48% vehicle (N=172). Study 2: 76% LOTEMAX® SM (N=200) vs 50% vehicle (N=199); $P < 0.05$ for all.

Indication

LOTEMAX® SM (loteprednol etabonate ophthalmic gel) 0.38% is a corticosteroid indicated for the treatment of post-operative inflammation and pain following ocular surgery.

Important Safety Information

- LOTEMAX® SM, as with other ophthalmic corticosteroids, is contraindicated in most viral diseases of the cornea and conjunctiva including epithelial herpes simplex keratitis (dendritic keratitis), vaccinia, and varicella, and also in mycobacterial infection of the eye and fungal diseases of ocular structures.
- Prolonged use of corticosteroids may result in glaucoma with damage to the optic nerve, defects in visual acuity and fields of vision. Steroids should be used with caution in the presence of glaucoma. If LOTEMAX® SM is used for 10 days or longer, IOP should be monitored.
- Use of corticosteroids may result in posterior subcapsular cataract formation.

BAUSCH + LOMB

®/TM are trademarks of Bausch & Lomb Incorporated or its affiliates.

© 2019 Bausch & Lomb Incorporated or its affiliates. All rights reserved. Printed in USA. LSM.0206.USA.19

Important Safety Information (cont.)

- The use of steroids after cataract surgery may delay healing and increase the incidence of bleb formation. In those with diseases causing thinning of the cornea or sclera, perforations have been known to occur with the use of topical steroids. The initial prescription and renewal of the medication order should be made by a physician only after examination of the patient with the aid of magnification such as slit lamp biomicroscopy and, where appropriate, fluorescein staining.
- Prolonged use of corticosteroids may suppress the host response and thus increase the hazard of secondary ocular infections. In acute purulent conditions, steroids may mask infection or enhance existing infections.
- Employment of a corticosteroid medication in the treatment of patients with a history of herpes simplex requires great caution. Use of ocular steroids may prolong the course and may exacerbate the severity of many viral infections of the eye (including herpes simplex).
- Fungal infections of the cornea are particularly prone to develop coincidentally with long-term local steroid application. Fungus invasion must be considered in any persistent corneal ulceration where a steroid has been used or is in use. Fungal cultures should be taken when appropriate.
- Contact lenses should not be worn when the eyes are inflamed.
- There were no treatment-emergent adverse drug reactions that occurred in more than 1% of subjects in the three times daily group compared to vehicle.

You are encouraged to report negative side effects of prescription drugs to the FDA. Visit www.fda.gov/medwatch or call 1-800-FDA-1088.

Please see brief summary of Prescribing Information on adjacent page.

References: 1. LOTEMAX SM Prescribing Information. Bausch & Lomb Incorporated. 2. Data on file. Bausch & Lomb Incorporated. 3. Cavet ME, Glogowski S, Lowe ER, Phillips E. Rheological properties, dissolution kinetics, and ocular pharmacokinetics of loteprednol etabonate [submicron] ophthalmic gel 0.38%. *J Ocul Pharmacol Ther*. 2019. doi: 10.1089/jop.2019.35(5):291-300.

Discover more at
www.LOTEMAXSM.com

LOTEMAX® SM
(loteprednol etabonate
ophthalmic gel) 0.38%

FEATURES

Vol. 28, No. 3 • MARCH 2021

Catch Up on the Latest News

Read Review's Weekly Newsletter

Online at reviewofophthalmology.com

ISSUE FOCUS: CATARACT SURGERY

34

Secondary IOL Fixation: Know Your Options

Surgeons share their expertise to help expand your skillset.

Christine Leonard, Associate Editor

42

E-Survey: Favorite Cataract Techniques

Cataract surgeons weigh in on many key aspects of surgery.

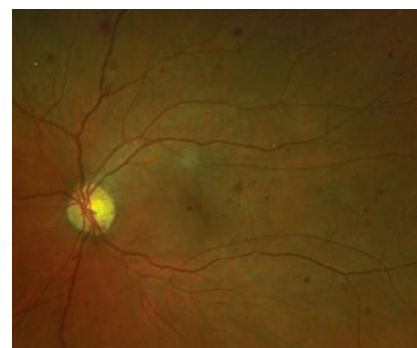Walter Bethke, Editor in Chief

48

Extracting Cataracts In Uveitic Glaucoma

These surgeries have always challenged. Here are several winning new strategies.

Sean McKinney, Senior Editor



56

Diabetic Retinopathy: Planning Your Treatment

Treatment depends on severity and ranges from observation to intravitreal injection or laser photocoagulation.

*Michelle Stephenson,
Contributing Editor*

60

Med-School Education: Teaching the Teachers

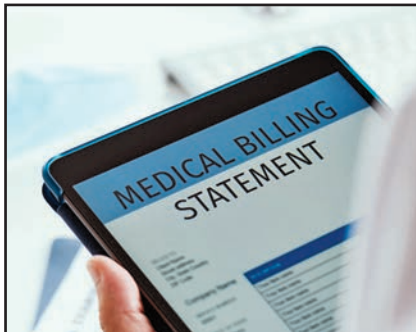A practical approach to teaching ophthalmology to medical students.

*Abdulwahab Sidiqi, Jason M. Kwok,
MD, and Kathy Y. Cao, MD*

DEPARTMENTS

MARCH 2021

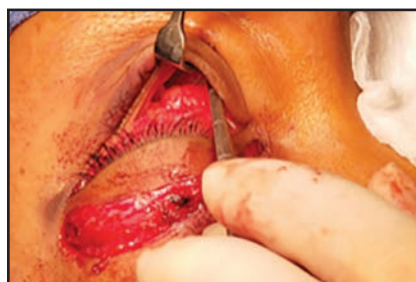4 News



17 TECHNOLOGY UPDATE Outsourced Billing: Where to Start

In-house or outsourced? Find out if hiring a billing service is right for your practice.

Christine Leonard, Associate Editor



22 PLASTIC POINTERS Excess Baggage: Lower-lid Blepharoplasty

An oculoplastics surgeon explains how to customize your approach to each patient's particular needs.

Alison H. Watson, MD

32 PRODUCT NEWS A New Surgical Instrument Rolls Out

64 GLAUCOMA MANAGEMENT Checking Visual Fields Using Virtual Reality

Many disadvantages associated with standard visual field testing may be eliminated using this novel technology.

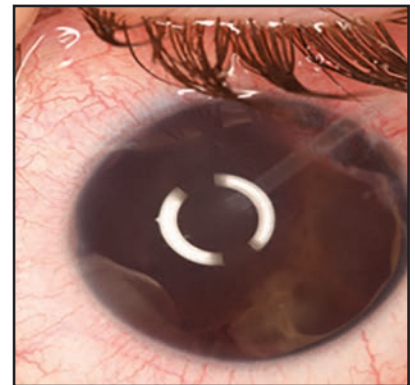
Yvonne Ou, MD

70 RETINAL INSIDER How to Manage Complex Macular Holes

Though they're a small percentage of cases, complex holes can take up a higher percentage of your time. Here's help.

Ajay E. Kuriyan, MD, MS

77 RESEARCH REVIEW Reading Performance in Glaucoma Patients



78 WILLS EYE RESIDENT CASE SERIES A 5-Year-Old Female Presents To Her Pediatrician With A “Pink” Left Eye

Patrick B. Rapuano, MD, Ralph C. Eagle Jr, MD, and Carol L. Shields, MD

79 CLASSIFIEDS/AD INDEX

 VISIT US ON SOCIAL MEDIA

Facebook

www.facebook.com/RevOphth

Twitter

twitter.com/RevOphth

WE'LL KEEP THE DOSE ON

Dextenza[®]
(dexamethasone ophthalmic insert) 0.4 mg
for intracanalicular use

**DELIVERING SUSTAINED STEROID COVERAGE,
FOR A HANDS-FREE POST-OP EXPERIENCE.**^{1,2}

DEXTENZA is designed to:

- Allow for physician-controlled administration¹
- Provide preservative-free, sustained coverage for up to 30 days²

INDICATION

DEXTENZA is a corticosteroid indicated for the treatment of ocular inflammation and pain following ophthalmic surgery.

IMPORTANT SAFETY INFORMATION CONTRAINDICATIONS

DEXTENZA is contraindicated in patients with active corneal, conjunctival or canalicular infections, including epithelial herpes simplex keratitis (dendritic keratitis), vaccinia, varicella; mycobacterial infections; fungal diseases of the eye, and dacryocystitis.

WARNINGS AND PRECAUTIONS

Prolonged use of corticosteroids may result in glaucoma with damage to the optic nerve, defects in visual acuity and fields of vision. Steroids should be used with caution in the presence of glaucoma. Intraocular pressure should be monitored during treatment.

Corticosteroids may suppress the host response and thus increase the hazard for secondary ocular infections. In acute purulent conditions, steroids may mask infection and enhance existing infection.

Use of ocular steroids may prolong the course and may exacerbate the severity of many viral infections of the eye (including herpes simplex).

Fungus invasion must be considered in any persistent corneal ulceration where a steroid has been used or is in use. Fungal culture should be taken when appropriate.

Use of steroids after cataract surgery may delay healing and increase the incidence of bleb formation.

ADVERSE REACTIONS

The most common ocular adverse reactions that occurred in patients treated with DEXTENZA were: anterior chamber inflammation including iritis and iridocyclitis (10%); intraocular pressure increased (6%); visual acuity reduced (2%); cystoid macular edema (1%); corneal edema (1%); eye pain (1%) and conjunctival hyperemia (1%).

The most common non-ocular adverse reaction that occurred in patients treated with DEXTENZA was headache (1%).

Please see brief summary of full Prescribing Information on adjacent page.

References: 1. Sawhney AS, Jarrett P, Bassett M, Blizzard C, inventors; Incept, LLC, assignee. Drug delivery through hydrogel plugs. US patent 8,409,606 B2. April 2, 2013.
2. DEXTENZA [package insert]. Bedford, MA: Ocular Therapeutix, Inc: 2019.

© 2020 Ocular Therapeutix, Inc. All rights reserved.
DEXTENZA is a registered trademark of Ocular Therapeutix, Inc. PP-US-DX-0230-V2

Ocular
Therapeutix[™]

Dextenza®

(dexamethasone ophthalmic insert) 0.4 mg
for intracanalicular use

BRIEF SUMMARY: Please see the DEXTENZA Package Insert for full prescribing information for DEXTENZA (06/2019)

1 INDICATIONS AND USAGE

DEXTENZA® (dexamethasone ophthalmic insert) is a corticosteroid indicated for the treatment of ocular inflammation and pain following ophthalmic surgery.

4 CONTRAINDICATIONS

DEXTENZA is contraindicated in patients with active corneal, conjunctival or canalicular infections, including epithelial herpes simplex keratitis (dendritic keratitis), vaccinia, varicella; mycobacterial infections; fungal diseases of the eye, and dacryocystitis.

5 WARNINGS AND PRECAUTIONS

5.1 Intraocular Pressure Increase

Prolonged use of corticosteroids may result in glaucoma with damage to the optic nerve, defects in visual acuity and fields of vision. Steroids should be used with caution in the presence of glaucoma. Intraocular pressure should be monitored during the course of the treatment.

5.2 Bacterial Infection

Corticosteroids may suppress the host response and thus increase the hazard for secondary ocular infections. In acute purulent conditions, steroids may mask infection and enhance existing infection [see Contraindications (4)].

5.3 Viral Infections

Use of ocular steroids may prolong the course and may exacerbate the severity of many viral infections of the eye (including herpes simplex) [see Contraindications (4)].

5.4 Fungal Infections

Fungus invasion must be considered in any persistent corneal ulceration where a steroid has been used or is in use. Fungal culture should be taken when appropriate [see Contraindications (4)].

5.5 Delayed Healing

The use of steroids after cataract surgery may delay healing and increase the incidence of bleb formation.

6 ADVERSE REACTIONS

The following serious adverse reactions are described elsewhere in the labeling:

- Intraocular Pressure Increase [see Warnings and Precautions (5.1)]
- Bacterial Infection [see Warnings and Precautions (5.2)]
- Viral Infection [see Warnings and Precautions (5.3)]
- Fungal Infection [see Warnings and Precautions (5.4)]
- Delayed Healing [see Warnings and Precautions (5.5)]

6.1 Clinical Trials Experience

Because clinical trials are conducted under widely varying conditions, adverse reaction rates observed in the clinical trials of a drug cannot be directly compared to rates in the clinical trials of another drug and may not reflect the rates observed in practice. Adverse reactions associated with ophthalmic steroids include elevated intraocular pressure, which may be associated with optic nerve damage, visual acuity and field defects, posterior subcapsular cataract formation; delayed wound healing; secondary ocular infection from pathogens including herpes simplex, and perforation of the globe where there is thinning of the cornea or sclera [see Warnings and Precautions (5)].

DEXTENZA was studied in four randomized, vehicle-controlled studies (n = 567). The mean age of

the population was 68 years (range 35 to 87 years), 59% were female, and 83% were white. Forty-seven percent had brown iris color and 30% had blue iris color. The most common ocular adverse reactions that occurred in patients treated with DEXTENZA were: anterior chamber inflammation including iritis and iridocyclitis (10%); intraocular pressure increased (6%); visual acuity reduced (2%); cystoid macular edema (1%); corneal edema (1%); eye pain (1%) and conjunctival hyperemia (1%).

The most common non-ocular adverse reaction that occurred in patients treated with DEXTENZA was headache (1%).

8 USE IN SPECIFIC POPULATIONS

8.1 Pregnancy

Risk Summary

There are no adequate or well-controlled studies with DEXTENZA in pregnant women to inform a drug-associated risk for major birth defects and miscarriage. In animal reproduction studies, administration of topical ocular dexamethasone to pregnant mice and rabbits during organogenesis produced embryofetal lethality, cleft palate and multiple visceral malformations [see Animal Data].

Data

Animal Data

Topical ocular administration of 0.15% dexamethasone (0.75 mg/kg/day) on gestational days 10 to 13 produced embryofetal lethality and a high incidence of cleft palate in a mouse study. A daily dose of 0.75 mg/kg/day in the mouse is approximately 5 times the entire dose of dexamethasone in the DEXTENZA product, on a mg/m² basis. In a rabbit study, topical ocular administration of 0.1% dexamethasone throughout organogenesis (0.36 mg / day, on gestational day 6 followed by 0.24 mg/day on gestational days 7-18) produced intestinal anomalies, intestinal aplasia, gastroschisis and hypoplastic kidneys. A daily dose of 0.24 mg/day is approximately 6 times the entire dose of dexamethasone in the DEXTENZA product, on a mg/m² basis.

8.2 Lactation

Systemically administered corticosteroids appear in human milk and could suppress growth and interfere with endogenous corticosteroid production; however the systemic concentration of dexamethasone following administration of DEXTENZA is low [see Clinical Pharmacology (12.3)]. There is no information regarding the presence of DEXTENZA in human milk, the effects of the drug on the breastfed infant or the effects of the drug on milk production to inform risk of DEXTENZA to an infant during lactation. The developmental and health benefits of breastfeeding should be considered along with the mother's clinical need for DEXTENZA and any potential adverse effects on the breastfed child from DEXTENZA.

8.4 Pediatric Use

Safety and effectiveness in pediatric patients have not been established.

8.5 Geriatric Use

No overall differences in safety or effectiveness have been observed between elderly and younger patients.

17 PATIENT COUNSELING INFORMATION

Advise patients to consult their surgeon if pain, redness, or itching develops.

 Ocular Therapeutix™

MANUFACTURED FOR:
Ocular Therapeutix, Inc.
Bedford, MA 01730 USA
PP-US-DX-0072-V2

REVIEW NEWS

Eyhance Intraocular Lenses Approved by FDA

(Continued from p. 4)

sists of a continuous, higher-order aspheric surface,” he explains. “The result of this design is that there is a very slight, gradual central steepening. The laboratory data the company produced shows that this new design provides about one line of additional intermediate and near vision, with the modulation transfer function [a measurement of the optical performance potential of a lens] at distance being very close to that of the standard ZCB00 lens, particularly with larger pupil sizes.”

Professor Peter Szurman, chief physician at the Sulzbach Eye Clinic of the Knappschaft Hospital Saar in Sulzbach, Germany, has implanted many of the Eyhance lenses since their approval in Europe about two years ago. (He has no financial ties to the lens or to Johnson & Johnson Vision.) “Until now, cataract patients have had to choose between a presbyopia-correcting multifocal IOL—with all its advantages and disadvantages—and a standard monofocal IOL with a limited focal range,” he notes. “The Tecnis Eyhance is a breakthrough technology because, for the first time, a high-quality monofocal IOL offers extended depth of focus. To me, the Eyhance is a high-quality option for ordinary cataract management.

“Intermediate visual acuity is difficult to measure in daily eye-care practice,” he continues. “However, from the patient’s perspective, intermediate visual acuity is very important for daily life activities, such as seeing sharply when looking at a smartphone or the dashboard while driving. There are numerous everyday activities within an arm’s length. The Tecnis Eyhance increases freedom from spectacles at this important intermediate distance and thus the quality of daily life of my patients.”

Dr. Koch notes that the Eyhance lenses aren’t classified as extended depth-of-focus lenses in the United States. “The FDA has specific criteria for what constitutes an EDOF lens, and this lens hasn’t undergone the FDA-monitored testing needed to get this classification,” he explains. “However, the lens design does provide more intermediate vision and slightly more near vision than a standard monofocal. That’s an advantage, because it will be billed as a standard monofocal lens. A patient coming in for routine cataract surgery who doesn’t want—or can’t afford—an EDOF lens can get this lens and get a little bit more near vision. That’s a

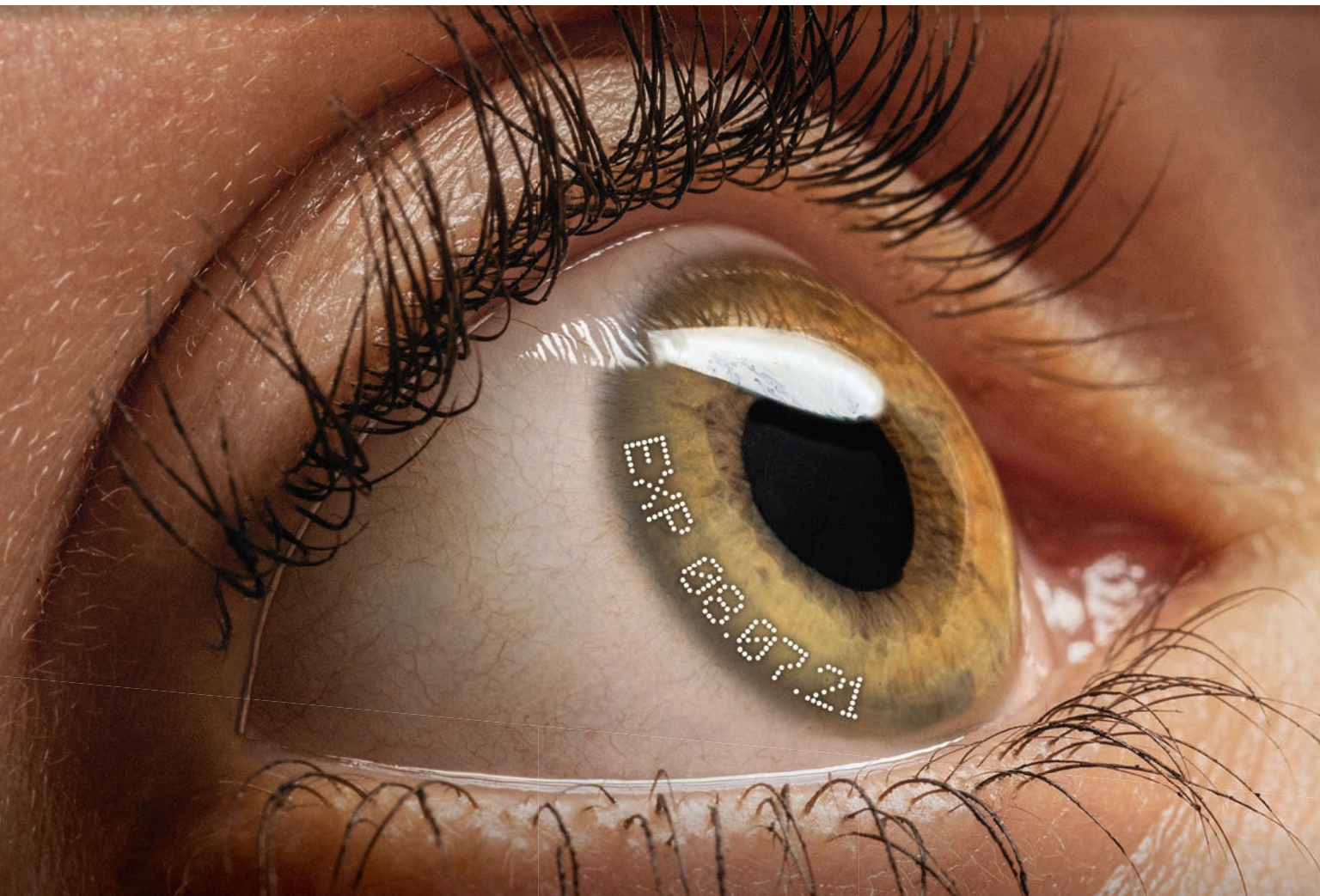(Continued on p. 16)

CORRECTION

In last month’s issue, the news report (“Alcon Vivity EDOF Lens Starts Its Rollout in the United States”) erroneously stated that the lens was available in -0.5 D increments, instead of 0.5 D increments. *Review* regrets the error.



Using Photrexa® Viscous (riboflavin 5'-phosphate in 20% dextran ophthalmic solution), Photrexa® (riboflavin 5'-phosphate ophthalmic solution), and the KXL® system, the iLink™ corneal cross-linking procedure from Glaukos is the only FDA-approved therapeutic treatment for patients with progressive keratoconus and corneal ectasia following refractive surgery.*1



GET THERE IN TIME

iLink™ is the only FDA-approved cross-linking procedure that slows or halts progressive keratoconus to help you preserve vision.

Now from **GLAUKOS**
LEARN MORE AT GLAUKOS.COM

INDICATIONS

Photrexa® Viscous (riboflavin 5'-phosphate in 20% dextran ophthalmic solution) and Photrexa® (riboflavin 5'-phosphate ophthalmic solution) are indicated for use with the KXL System in corneal collagen cross-linking for the treatment of progressive keratoconus and corneal ectasia following refractive surgery. Corneal collagen cross-linking should not be performed on pregnant women.

IMPORTANT SAFETY INFORMATION

Ulcerative keratitis can occur. Patients should be monitored for resolution of epithelial defects.

The most common ocular adverse reaction was corneal opacity (haze). Other ocular side effects include punctate keratitis, corneal striae, dry eye, corneal epithelium defect, eye pain, light sensitivity, reduced visual acuity, and blurred vision.

These are not all of the side effects of the corneal collagen cross-linking treatment. For more information, go to www.livingwithkeratoconus.com to obtain the FDA-approved product labeling.

You are encouraged to report all side effects to the FDA. Visit www.fda.gov/medwatch, or call 1-800-FDA-1088.

*Photrexa® Viscous and Photrexa® are manufactured for Avedro. The KXL System is manufactured by Avedro. Avedro is a wholly owned subsidiary of Glaukos Corporation.

REFERENCE: 1. Photrexa [package insert] Waltham, MA: Glaukos, Inc. 2016.

MA-01953A

© 2021 Glaukos Corporation. iLink™ is a trademark of Glaukos Corporation. Glaukos and Photrexa® are registered trademarks of Glaukos Corporation.



EDITORIAL STAFF

Editor in Chief**Walter Bethke**

(610) 492-1024

Senior Editor**Christopher Kent**

(212) 274-7031

ckent@jobson.com

Senior Editor**Sean McKinney**

(610) 492-1025

semckinney@jobson.com

Associate Editor**Christine Leonard**

(610) 492-1008

cleonard@jobson.com

Chief Medical Editor**Mark H. Blecher, MD****Art Director****Jared Araujo**

(610) 492-1032

jaraujo@jobson.com

Senior Graphic Designer**Matt Egger**

(610) 492-1029

megger@jobson.com

International coordinator, Japan**Mitz Kaminuma**

Reviewophtho@aol.com

Business Offices

19 Campus Boulevard, Suite 101

Newtown Square, PA 19073

(610) 492-1000

Fax: (610) 492-1039

Subscription inquiries:

United States – (877) 529-1746

Outside U.S. – (845) 267-3065

E-mail:

revophthalmology@cambeywest.com

Website: www.reviewofophthalmology.com



WALTER C. BETHKE, EDITOR IN CHIEF

EDITOR'S PAGE

There's Hope In Sight

Looking back over the past year, filled with quarantines and lockdowns, I got to thinking about the famous quote sometimes attributed to Einstein, that the definition of insanity is “doing the same thing over and over again and expecting a different result.” But can it work in reverse? Can being forced to do the same thing over and over again—like, say, sitting in the house for 12 months—and HOPING for a different result make you a little insane too?

After witnessing a large-scale, prospective, randomized, multicenter study (n=7.7 billion), it seems that yes, indeed, a pandemic lockdown can make you a wee bit crazy.

But do these effects of the pandemic have to be permanent? Is it possible for us to find a way out? If so, how?

Unfortunately, I don't have clear-cut answers to those questions, but one thing that helps a lot of people during trying times is actually—paradoxically—reaching out and helping someone else. Helping to ease others' suffering is a balm for your own, and ophthalmologists are perfectly positioned to help many people who really need it.

Specifically, blindness consistently ranks among individuals' worst fears when it comes to their health—right up there with cancer and heart disease. Though losing one's sight is truly a frightening proposition, and some diseases still resist treatment, you as an ophthalmologist—and a cataract surgeon in particular—have the ability to

restore sight that was lost, to allay what might be some patients' darkest fear.

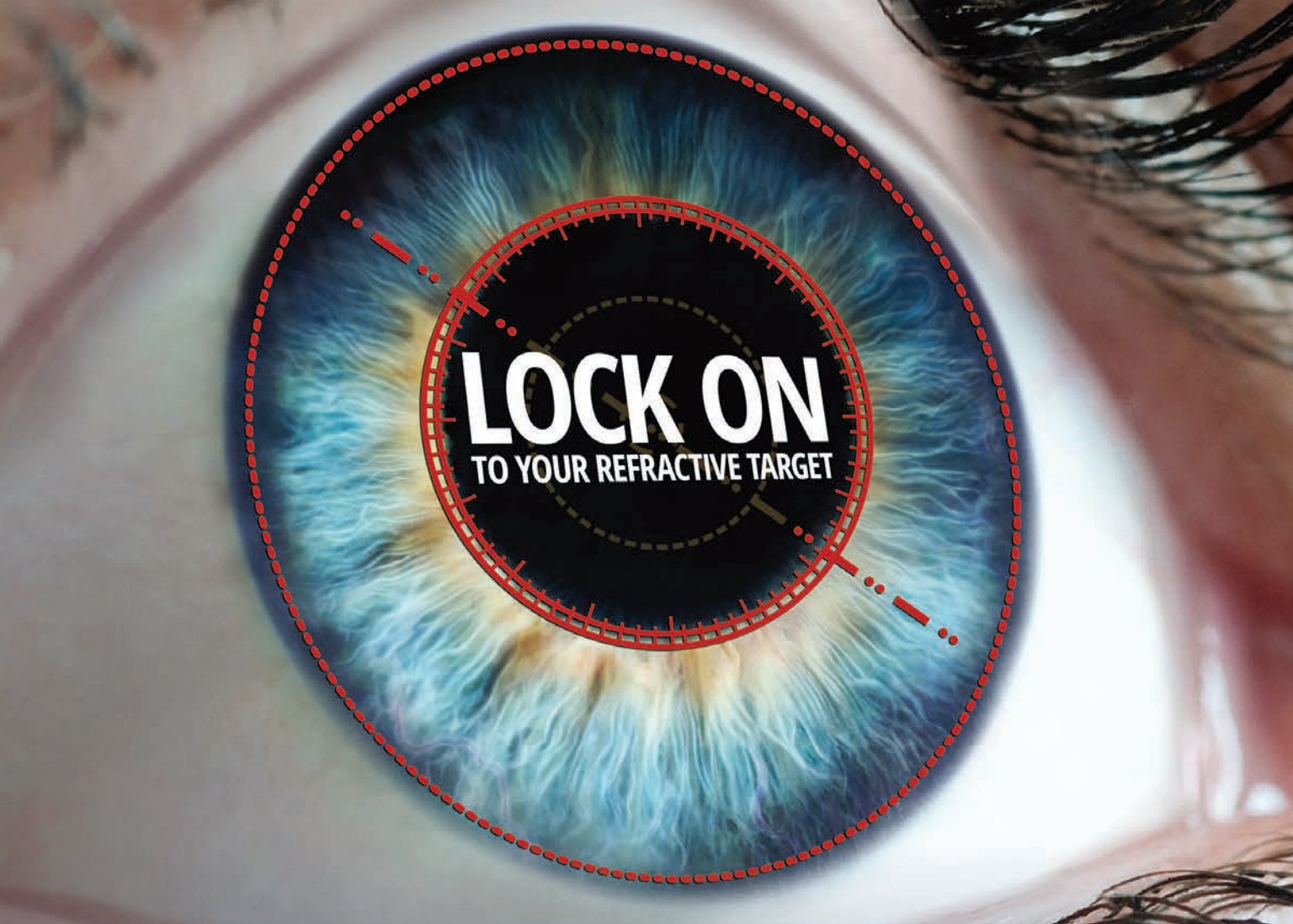But what does a cataract surgeon fear? A tough case, riddled with the potential for complications that could result in a patient losing some vision? If that's the case, then allow us to help you with this month's articles on how to be prepared for the cases in which things don't go so smoothly: You'll learn ways to handle cases of zonular weakness and malpositioned intraocular lenses; the pros and cons of key cataract surgery techniques, as told by your colleagues; and how to manage challenging, sometimes nightmare-inducing cases of cataract in the setting of uveitic glaucoma.

There's good news on the COVID front too: As I write this, just over 12 percent of the U.S. population has been vaccinated, with more joining those ranks every day. That, and the first hints of spring you're no doubt seeing as you read this, are enough to lift anyone's spirits.

It's enough to make you go out and do something different and, hopefully, get a very different result than you got in 2020.

— *Walter Bethke*
Editor in Chief





Empowered Refractive Decision Making

Total ocular refractive measurements and optimized algorithms that help you prevent refractive surprises.¹⁻⁴

References 1. ORA SYSTEM® Operator's Manual. 2015. 2. Lanchulev T, Hoffer K, Yoo S, et al. Intraoperative refractive biometry for predicting intraocular lens power calculation after prior myopic refractive surgery. *Ophthalmology*. 2014;121(1):57-60. 3. Woodcock MG, Lehmann R, Cionni RJ, et al. Intraoperative aberrometry versus standard preoperative biometry and a toric IOL calculator for bilateral toric IOL implantation with a femtosecond laser: one month results. *J Cataract Refract Surg*. 2016;42:817-825. • The purpose of the study was to compare astigmatic outcomes in patients with bilateral cataracts having toric IOL implantation with intraoperative aberrometry measurements in 1 eye and standard power calculation and a toric IOL calculator with inked axis marking in the contralateral eye. 4. Cionni ASCRS 2018 paper presentation. • Analysis of an Intraoperative Aberrometry Database: Outcomes of a Toric IOL for Low Astigmatism. The purpose of this study was to evaluate the outcomes of the ORA SYSTEM® power calculation compared to the surgeon's preoperative power calculation in eyes implanted with AcrySof® IQ T3 IOLs. This was a retrospective analysis of data from patients who underwent cataract extraction by phacoemulsification in at least one eye with the use of the ORA SYSTEM®.

Alcon

© 2021 Alcon Inc. 2/21 US-ORA-2100002



ORA SYSTEM®

Powered by AnalyzOR™ Technology

**Eyhance Intraocular Lenses
Approved by FDA**

(Continued from p. 12)

nice plus.

“I think the toric version will be a huge hit,” he adds. “Doctors can upcharge because it’s a toric, and the patient will get a little more intermediate and near vision. These lenses will also be good for patients with ocular pathology for whom you might be uncomfortable about implanting a lens that splits the light. Meanwhile, if the patient really wants even more intermediate and near vision, we still have the option of choosing an EDOF lens or multifocal or trifocal.”

In addition to the new refractive design, the lenses feature a new squared and frosted haptic intended to stabilize the lens and prevent toric lens rotation. Dr. Koch notes that the squared and frosted haptics are also used in the Tecnis Toric II (ZCU)

model. “That’s a very stable lens,” he says. “I’ve been using it for well over a year and I haven’t had a single rotation with it. I’m sure they’ll be using that haptic design in all the lenses they’re bringing to market going forward. It’s rock solid.”

Professor Szurman says that he has tended to avoid implanting toric lenses in the past because of the insufficient rotational stability of some of them. “The frosted surface texture and more squared haptic design of the Eyhance lenses are the way to go to increase rotational stability and allow more patients to benefit from toric IOLs,” he says.

Both lenses are delivered into the eye using the new Tecnis Simplicity delivery system, designed to make implantation as easy and contamination-free as possible. “The preloaded delivery system allows my assistant nurse to easily and safely prepare the IOL within seconds, with no load-

ing errors,” says Professor Szurman. “I get a ready-to-use system that shortens my OR time and allows for a smooth and controlled implantation.”

Dr. Koch says the Simplicity delivery system will also be used for the ZCB00 Tecnis lens. “As the name suggests, it’s simple to use,” he says. “You just inject a little BSS through a small portal and screw the lens in. It glides into the eye very smoothly. It’s about as foolproof as it can be.”

Asked whether he thinks this new monofocal design might result in the Eyhance intraocular lens replacing standard monofocal lenses, Dr. Koch says it’s possible. “It’s essentially like getting something for nothing,” he says. “There’s a trivial change in distance vision if the patient has a small pupil, but it’s not perceptible, per my colleagues in Europe. To provide patients with one additional line of acuity without undercutting distance vision will be a nice plus. To me, it’s a can’t-lose proposition from the patient’s standpoint.”

“It’s important to clearly communicate to our patients that the Tecnis Eyhance is not a presbyopia-correcting refractive IOL, but an enhanced monofocal IOL,” adds Professor Szurman. “In my opinion, it’s a good option for all patients who are risk-averse or unsuitable for refractive cataract surgery, but who still want to maximize their functional vision. I routinely offer the Tecnis Eyhance to all patients undergoing monofocal IOL implantation. However, I exclude patients with vision-limiting ocular conditions other than cataract.”

The Eyhance lens has been available in Europe since February 2019 and became available in Latin America and Canada in the summer of 2020. The Eyhance Toric II will be launching in Europe and Canada later this year.

ORA SYSTEM® Technology - IMPORTANT PRODUCT INFORMATION

CAUTION: Federal (USA) law restricts this device to the sale by or on the order of a physician.

INDICATIONS: Federal (USA) law restricts this device to sale by, or on the order of, a physician.

INTENDED USE: The ORA SYSTEM® technology utilizes wavefront aberrometry data to measure and analyze the refractive power of the eye (i.e. sphere, cylinder, and axis measurements) to support cataract surgical procedures.

WARNINGS AND PRECAUTIONS: The following conditions may make it difficult to obtain accurate readings using the ORA SYSTEM® technology:

- Patients having progressive retinal pathology such as diabetic retinopathy, macular degeneration, or any other pathology that the physician deems would interfere with patient fixation;
- Patients having corneal pathology such as Fuchs’, EBMD, keratoconus, advanced pterygium impairing the cornea, or any other pathology that the physician deems would interfere with the measurement process;
- Patients for which the preoperative regimen includes residual viscous substances left on the corneal surface such as lidocaine gel or viscoelastics;
- Visually significant media opacity, such as prominent floaters or asteroid hyalosis, will either limit or prohibit the measurement process; or
- Patients having received retro or peribulbar block or any other treatment that impairs their ability to visualize the fixation light.
- Use of iris hooks during an ORA SYSTEM® technology image capture will yield inaccurate measurements.

In addition:

- Significant central corneal irregularities resulting in higher order aberrations might yield inaccurate refractive measurements.
- Post refractive keratectomy eyes might yield inaccurate refractive measurement.
- The safety and effectiveness of using the data from the ORA SYSTEM® have not been established for determining treatments involving higher order aberrations of the eye such as coma and spherical aberrations.
- ORA SYSTEM® technology is intended for use by qualified health personnel only.
- Improper use of this device may result in exposure to dangerous voltage or hazardous laser-like radiation exposure. DO NOT OPERATE the ORA SYSTEM® in the presence of flammable anesthetics or volatile solvents such as alcohol or benzene, or in locations that present an explosion hazard.

ATTENTION: Refer to the ORA SYSTEM® Operator’s Manual for a complete description of proper use and maintenance, as well as a complete list of contraindications, warnings and precautions.

1. Unsal U, Sabur H. Comparison of new monofocal innovative and standard monofocal intraocular lens after

(Continued on p. 30)





EDITED BY MICHAEL COLVARD, MD,
AND STEVEN CHARLES, MD

TECHNOLOGY UPDATE

Outsourced Billing: Where to Start

In-house or outsourced? Find out if hiring a billing service is right for your practice.

BY CHRISTINE LEONARD
ASSOCIATE EDITOR

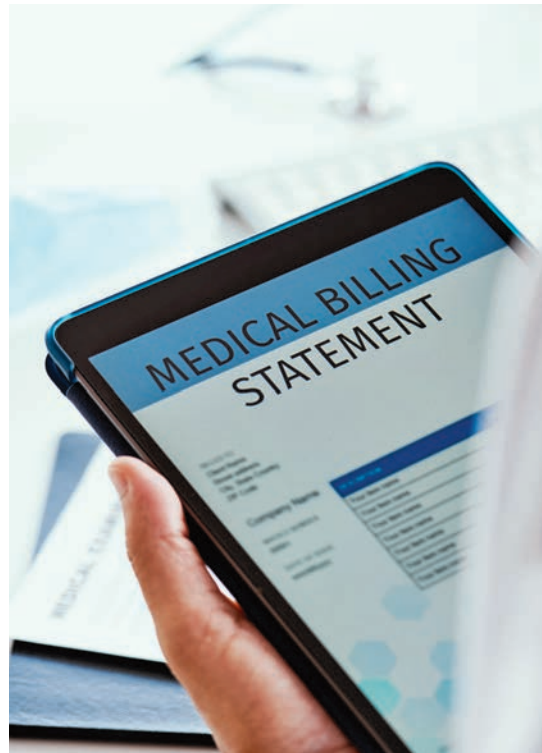Should you outsource your billing operations or keep them in-house? The answer will differ for every practice. In this month's column, you'll learn what outsourcing can offer—and its limitations—so you can decide if it's a worthwhile investment.

Keeping A Hand on the Wheel

One of the most common reasons a practice may balk at outsourcing their billing is the loss of control and oversight. However, as with any vendor a practice works with, the billing company doesn't assume the ultimate authority or take responsibility away from the administrator or lead doctor in the practice. Rather, outsourcing shifts the workload.

That being said, "It's important to establish good communication pathways with the company," says Corinne Wohl, MHSA, COE, of C. Wohl & Associates. "Many feel they won't have as much control if they outsource, but with good housekeeping and follow-up on an on-going basis, it can work."

"Just because you outsource doesn't mean the administrator and the doctors are completely released



Outsourcing often means purchasing redundancy, which benefits small practices that can't afford to lose a single member of their billing staff.

from the knowledge of how billing works," adds John Pinto, of J. Pinto & Associates. "Whenever an administrator supervises any vendor, they

need to know enough to determine whether the service is being done well."

Ms. Wohl advises her clients on what to ask their billing company to keep abreast of their account's status. Some questions include:

- What percentage of our open accounts are out over 90 days?
- What is the current time delay between the date of providing a service and the date of posting?
- What percentage of our claims are being denied, and how do those denied claims break down in terms of the reasons (e.g., demographics or mismatch with diagnosis code and service code)?

A Good Fit?

Outsourced billing can benefit smaller practices because it provides redundancy. Mr. Pinto explains, "If you have a very small practice—let's say you're a solo practice with about 500 to 600 visits per month and about \$1 million or so in collections—at the most, you'll need one full-time biller. Everything's fine if that biller is confident and working in your practice, but if you lose that one biller and there's no backup, your cash flow abruptly stops.

"When you're a larger practice, you can have a strong billing manager who supervises several billing clerks," he continues.

"Those individuals may collectively have 50 or 75 years' experience, and even if you lose one, you'll still have a fully functioning billing department, unlike a small practice where the loss of one staff member can really harm you."

Outsourcing can also decrease a young practice's overhead costs.

This article has no commercial sponsorship.

Dr. Colvard is a surgeon at the Colvard-Kandavel Eye Center in Los Angeles and a clinical professor of ophthalmology at the Keck School of Medicine of the University of Southern California. Dr. Charles is the founder of the Charles Retina Institute in Germantown, Tennessee.

“A young practice stands to gain an increase in cash flow when they outsource their billing, because they don’t have to hire their own billing staff,” says Ron Rosenberg, PA, MPH, of Practice Management Resource Group. “For a young practice, having a billing staff from the get-go means people are going to be sitting around with little to do until the clinic volume picks up.”

There are some situations where outsourcing benefits growing practices too. Kristi Henriksen Perry, Sacramento Eye Consultants’ administrator, says when she joined her practice they had outgrown their in-house billing capabilities. “We would have had to increase our billing staff to keep up, but employing more than 50 people would change the California laws that apply to our business,” she says. Her assessment of the practice showed that outsourcing was the best option.

“We set up the billing company on our EHR, and they log into our system as a third party,” Ms. Perry explains. “If we get paper EOBs or checks, we scan everything and they post it to our patient accounts.”

Her practice employs an ophthalmology-specific billing service. “We’ve found so much value working with them,” she says. “We meet biweekly and they help us understand all the Medicare changes each year and keep us up to date.”

Each billing company has its area of expertise. “Some are better versed in coding or compliance and others with charting,” Mr. Pinto says. “You’d have to be a very large practice before you have what’s called ‘depth of bench’ to handle any questions that come up. The vast majority of practices in-source their billing, but even they turn to outside coding and compliance consultants for many things. There’s a lot of complexity and it changes every year. It’s important for even the strongest of internal departments to have external expertise they can call on.”

Cloud-based Revenue Cycle Management

If you choose to outsource, the billing company will typically use whichever billing software your practice already has. Many cloud-based EHRs such as Epic come with revenue cycle management software to help your staff streamline billing operations. Here are some others to consider:

- **NextGen Office** (nextgen.com)
- **AdvancedMD** (advancedmd.com)
- **Nextech** (nextech.com)
- **Compulink** (compulinkadvantage.com)
- **athenaCollector** (athenahealth.com)

Some advantages of cloud-based software include fast connection, little to no down-time and secure data backup. You can also access patient records from anywhere.

“Cloud-based software is almost foolproof,” says Jeff Grant, president and founder of HCMA Consulting. “Once it’s set up, there are rarely any problems, whereas practices that rely on servers often have access or VPN issues. There’s down-time for maintenance and the concern of someone accidentally turning the server off or forgetting to run regular backups.”

The trade-off is the cost. “Cloud-based software requires a monthly fee to use the cloud, and these prices can vary dramatically,” says Mr. Grant. “Purchasing a new server may cost thousands of dollars and last three to four years, but it’s an up-front flat fee.”

—CL

What You Should Know

There are three kinds of outsourcing solutions: national firms, regional services and freelance individuals or small teams who manage the accounts of a few practices. “National firms may handle all types of specialties but may also be less ophthalmology-specific,” Mr. Pinto says. “The smaller firms of just one or two people don’t provide the redundancy that one often seeks by outsourcing their billing.”

Billing companies receive a percentage of the practice’s recovered funds—usually between 3 and 6 percent—but this rate isn’t always static. “There are efficiencies that allow us to charge less as we collect more,” Jeff Grant, president and founder of HCMA Consulting, says of his firm. “It doesn’t cost us twice as much to collect \$200,000 per month versus \$100,000 per month, so we’re willing to pass on the savings from the efficiencies to our client.”

Ms. Perry says the separation of

collections and patient care has been beneficial. “While a staff member may be inclined to show leniency, it’s more objective on the billing company’s part—they’re just doing their job and we can focus on providing excellent patient care,” she says.

“Be sure to watch out for billing companies that put all of their attention on the easiest 80 to 90 percent of accounts and don’t put equal effort into getting the payments for the rest,” cautions Mr. Pinto. “That’s why it’s important to ask objective questions. Subjective questions like ‘how’s it going with our accounts?’ won’t get you far.”

If you’re considering outsourcing with a billing company, here are some points to keep in mind:

- **Assess your practice first.**

“Before outsourcing, your practice should conduct an assessment of its current billing practices and performance,” says Mr. Rosenberg. “Are you collecting everything that needs

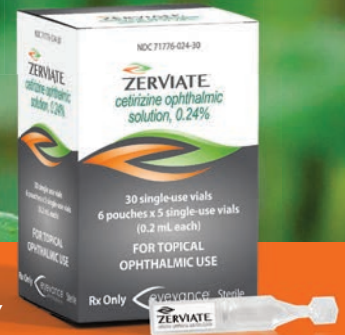NO PAZEO*? NO PROBLEM!

For ocular itch associated
with allergic conjunctivitis

INITIATE ZERVIAE®

Choose the topical prescription
treatment that delivers the
proven power of cetirizine
(active ingredient in ZYRTEC®)¹

- Provides fast-acting, long-lasting relief that lubricates with every drop^{2,3}
- Covered on most commercial and Medicare Part D plans



Available by
prescription only

Formulated with HYDRELLA™ for comfort.¹
Visit MyZERVIAE.com for more information.

References: 1. ZERVIAE [package insert]. Fort Worth, TX: Eyeavance Pharmaceuticals LLC; 2018. 2. Malhotra RP, Meier E, Torkildsen G, et al. Safety of cetirizine ophthalmic solution 0.24% for the treatment of allergic conjunctivitis in adult and pediatric subjects. *Clin Ophthalmol.* 2019;13:403-413. 3. Meier EJ, Torkildsen GL, Gomes PJ, et al. Phase III trials examining the efficacy of cetirizine ophthalmic solution 0.24% compared to vehicle for the treatment of allergic conjunctivitis in the conjunctival allergen challenge model. *Clin Ophthalmol.* 2018;12:2617-2628.

INDICATIONS AND USAGE

ZERVIAE® (cetirizine ophthalmic solution) 0.24% is a histamine-1 (H1) receptor antagonist indicated for treatment of ocular itching associated with allergic conjunctivitis.

IMPORTANT SAFETY INFORMATION

ADVERSE REACTIONS

The most commonly reported adverse reactions occurred in approximately 1%-7% of patients treated with either ZERVIAE or vehicle. These reactions were ocular hyperemia, instillation site pain, and visual acuity reduced.

Please see brief summary of Full Prescribing Information on the adjacent page.



© 2021 Eyeavance Pharmaceuticals LLC. All rights reserved.
ZERVIAE® is a registered trademark and HYDRELLA™ is a trademark of Eyeavance Pharmaceuticals LLC.
*All other trademarks are the property of their respective owners. ZER-21-AD-106-02

ZERVIA™ (cetirizine ophthalmic solution) 0.24%

Brief Summary

INDICATIONS AND USAGE

ZERVIA™ (cetirizine ophthalmic solution) 0.24% is a histamine-1 (H1) receptor antagonist indicated for treatment of ocular itching associated with allergic conjunctivitis.

DOSAGE AND ADMINISTRATION

Recommended Dosing: Instill one drop of ZERVIA™ in each affected eye twice daily (approximately 8 hours apart). The single-use containers are to be used immediately after opening and can be used to dose both eyes. Discard the single-use container and any remaining contents after administration. The single-use containers should be stored in the original foil pouch until ready to use.

CONTRAINDICATIONS

None.

WARNINGS AND PRECAUTIONS

Contamination of Tip and Solution: As with any eye drop, care should be taken not to touch the eyelids or surrounding areas with the dropper tip of the bottle or tip of the single-use container to avoid injury to the eye and to prevent contaminating the tip and solution. Keep the multi-dose bottle closed when not in use. Discard the single-use container after using in each eye.

Contact Lens Wear: Patients should be advised not to wear a contact lens if their eye is red.

ZERVIA™ should not be instilled while wearing contact lenses. Remove contact lenses prior to instillation of ZERVIA™. The preservative in ZERVIA™, benzalkonium chloride, may be absorbed by soft contact lenses. Lenses may be reinserted 10 minutes following administration of ZERVIA™.

ADVERSE REACTIONS

Clinical Trials Experience: Because clinical trials are conducted under widely varying conditions, adverse reaction rates observed in the clinical trial of a drug cannot be directly compared to rates in the clinical trials of another drug and may not reflect the rates observed in practice.

In 7 clinical trials, patients with allergic conjunctivitis or those at risk of developing allergic conjunctivitis received one drop of either cetirizine (N=511) or vehicle (N=329) in one or both eyes. The most commonly reported adverse reactions occurred in approximately 1%–7% of patients treated with either ZERVIA™ or vehicle. These reactions were ocular hyperemia, instillation site pain, and visual acuity reduced.

USE IN SPECIFIC POPULATIONS

Pregnancy

Risk Summary

There were no adequate or well-controlled studies with ZERVIA™ in pregnant women. Cetirizine should be used in pregnancy only if the potential benefit justifies the potential risk to the fetus.

Data

Animal Data

Cetirizine was not teratogenic in mice, rats, or rabbits at oral doses up to 96, 225, and 135 mg/kg, respectively (approximately 1300, 4930, and 7400 times the maximum recommended human ophthalmic dose (MRHOD), on a mg/m² basis).

Lactation

Risk Summary

Cetirizine has been reported to be excreted in human breast milk following oral administration. Multiple doses of oral dose cetirizine (10 mg tablets once daily for 10 days) resulted in systemic levels (Mean C_{max} = 311 ng/mL) that were 100 times higher than the observed human exposure (Mean C_{max} = 3.1 ng/mL) following twice daily administration of cetirizine ophthalmic solution 0.24% to both eyes for 1 week. Comparable bioavailability has been found between the tablet and syrup dosage forms. However, it is not known whether the systemic absorption resulting from topical ocular administration of ZERVIA™ could produce detectable quantities in human breast milk.

There is no adequate information regarding the effects of cetirizine on breastfed infants, or the effects on milk production to inform risk of ZERVIA™ to an infant during lactation. The developmental and health benefits of breastfeeding should be considered along with the mother's clinical need for ZERVIA™ and any potential adverse effects on the breastfed child from ZERVIA™.

Pediatric Use: The safety and effectiveness of ZERVIA™ has been established in pediatric patients two years of age and older. Use of ZERVIA™ in these pediatric patients is supported by evidence from adequate and well-controlled studies of ZERVIA™ in pediatric and adult patients.

Geriatric Use: No overall differences in safety or effectiveness have been observed between elderly and younger patients.

NONCLINICAL TOXICOLOGY

Carcinogenesis, Mutagenesis, Impairment of Fertility

Carcinogenicity
In a 2-year carcinogenicity study in rats, orally administered cetirizine was not carcinogenic at dietary doses up to 20 mg/kg (approximately 550 times the MRHOD, on a mg/m² basis). In a 2-year carcinogenicity study in mice, cetirizine caused an increased incidence of benign liver tumors in males at a dietary dose of 16 mg/kg (approximately 220 times the MRHOD, on a mg/m² basis). No increase in the incidence of liver tumors was observed in mice at a dietary dose of 4 mg/kg (approximately 55 times the MRHOD, on a mg/m² basis). The clinical significance of these findings during long-term use of cetirizine is not known.

Mutagenesis

Cetirizine was not mutagenic in the Ames test or in an *in vivo* micronucleus test in rats. Cetirizine was not clastogenic in the human lymphocyte assay or the mouse lymphoma assay.

Impairment of Fertility

In a fertility and general reproductive performance study in mice, cetirizine did not impair fertility at an oral dose of 64 mg/kg (approximately 875 times the MRHOD, on a mg/m² basis).

PATIENT COUNSELING INFORMATION

Risk of Contamination: Advise patients not to touch dropper tip to eyelids or surrounding areas, as this may contaminate the dropper tip and ophthalmic solution. Advise patients to keep the bottle closed when not in use. Advise patients to discard single-use containers after each use.

Concomitant Use of Contact Lenses: Advise patients not to wear contact lenses if their eyes are red. Advise patients that ZERVIA™ should not be used to treat contact lens-related irritation. Advise patients to remove contact lenses prior to instillation of ZERVIA™. The preservative in ZERVIA™ solution, benzalkonium chloride, may be absorbed by soft contact lenses. Lenses may be reinserted 10 minutes following administration of ZERVIA™.

Administration: Advise patients that the solution from one single-use container is to be used immediately after opening. Advise patients that the single-use container can be used to dose both eyes. Discard the single-use container and remaining contents immediately after administration.

Storage of Single-use Containers:

Instruct patients to store single-use containers in the original foil pouch until ready to use.

Rx Only

Distributed by: Eyevance Pharmaceuticals LLC, Fort Worth, TX 76102





Billing companies receive a percentage of the practice's collected revenue—usually between 3 and 6 percent.

to be collected or are you leaving money on the table?"

• *Ask for references.* "A good outsourcing company should have a lot of experience in ophthalmology or specialize in it," he says. "It should have a robust client base and be familiar with payers. Be sure to ask

for references."

• *Have the company evaluate your current billing practices.*

Besides asking for references, it's a good idea to have the billing company that's pitching for your business evaluate your current billing approaches. "They'll identify areas where your billing department is doing a good job and

where it could use improvement," says Mr. Pinto. "If you have one to three billing companies pitch for your business, you may quickly realize that one is better than the other, or you may discover as they evaluate your status that your billing depart-

ment just needs some technical or training support. Many billing companies will act as spot consultants and provide you with high-level expertise to help you do your own billing better internally."

• *Review the contract with your attorney.* "You want to make sure the exit clause is appropriate," Mr. Pinto says. "This is your cash flow—one of the most important areas of the business—and you want to ensure you're working with someone who will treat you appropriately." Likewise, be clear in your agreements that you own the data. ◀

DISCLOSURES

Mr. Pinto, Ms. Wohl, and Ms. Perry have no relevant financial disclosures. Mr. Rosenberg is a founding partner of Practice Management Resource Group, an ophthalmic billing and consulting service based in Pleasant Hill, California, and Tinley Park, Illinois. Mr. Grant is the president and founder of Healthcare Management & Automation Systems, a practice management consulting & revenue cycle management service based in Shell, Wyoming.

OPHTHALMIC Product Guide

Innovative products to enhance your practice

The **future** is in your hands.
One tap, many possibilities.

Experience the digital edition on your handheld device. Use your smart device to scan the code below or visit:

www.reviewofophthalmology.com/publications/archive



Download a QR scanner app. Launch app and hold your mobile device over the code to view www.reviewofophthalmology.com/publications/archive.





Excess Baggage: Lower-lid Rejuvenation

An oculoplastics surgeon explains how to tailor your approach to each individual patient's needs.

BY ALISON H. WATSON, MD
PHILADELPHIA

In the past, when a patient presented with lower-lid issues that required blepharoplasty, our approach was similar to just buying clothes off the rack—very limited and, often, one-size-fits-all. Now, however, our treatment paradigm is much more like having a suit custom-tailored to our exact taste and dimensions. Specifically, there's been a transformative shift from a primary focus on subtraction to the value of the addition of volume in periorbital aesthetics.¹⁻⁴ An appreciation of midfacial volume loss, gravitational descent and skin textural changes all should inform the surgeon's approach, which can then be individualized to a specific patient's facial changes.^{5,6}

Here, I'll explain the various ways you can customize patients' lower-lid blepharoplasty surgery, based on their individual ocular and facial needs.

Evaluating the Patient

Addressing any anatomic patient concern should first begin with defining the underlying causes, and lower-eyelid aesthetics is no exception.

Not all eyelids are created equal. In fact, patients may require

anything from superficial laser resurfacing or a chemical peel to address just skin textural changes, to hyaluronic acid filler or fat transfer for volume restoration, to surgical intervention with liposculpting and transposition with or without skin resection—or any combination of the above.

“

Addressing any anatomic patient concern should first begin with defining the underlying causes, and lower-eyelid aesthetics is no exception.

”

The examination should focus on understanding the particular aging changes that have resulted in the configuration that's troubling to the patient. The history should focus on understanding the patient's specific concerns about their lower eyelids. After all, what bothers the surgeon may not bother the patient, and vice versa. Therefore, establishing this relationship and understanding is essential to planning a successful cosmetic surgery.

Preoperative evaluation of the

lower eyelids requires identifying how each feature of facial aging determines the bothersome changes to the lower eyelid-midface complex. Defining how the identified clinical findings relate to the overlying and underlying anatomic changes will guide the treatment plan. Beginning with the skin and working posteriorly to the changes of the underlying bony anatomy will permit a consistent, systematic approach.⁶

Aging changes to the periorbital skin may be accentuated relative to the rest of the face due to the lack of substantial dermis in this location, along with its intimate relationship to the underlying orbicularis and associated ligaments. Skin aging becomes manifest due to a loss of hyaluronic acid, loss of collagen and loss of elastin. All of these changes contribute to reduced elasticity, and the increased laxity and wrinkling observed over time.⁷ Additional features, particularly in photodamaged skin, include irregular pigmentary changes, as well as dullness and roughness.⁷ Depending on the severity of the skin changes, intervention may involve skin resection or adjuncts to surgery, including a chemical peel or laser resurfacing.

Beneath the skin, the ligamentous structures of the lower eyelid undergo important and involuntal changes.⁶ These changes can result in lower eyelid laxity and increase the propensity for postoperative ectropion or retraction if the laxity goes unrecognized preoperatively and isn't addressed at the time of surgery.⁶ Therefore, the degree of lower eyelid laxity should be assessed preoperatively and dealt with at the time of surgery, if nec-

This article has no commercial sponsorship.

Dr. Murchison is Director of the Emergency Department at Wills Eye Hospital, associate professor of ophthalmology at Thomas Jefferson University and senior fellow at Jefferson School of Population Health. She has no financial interest in any products mentioned.

DURYSTA™

(bimatoprost implant) 10 mcg
For intracameral administration



EXTENDED IOP CONTROL

Discover the DURYSTA™ difference:

- A first-in-class, biodegradable, intracameral implant¹
- 24/7 drug release for several months^{1,2}
- Delivers drug within the eye to target tissues^{1,3}

SEVERAL MONTHS OF IOP REDUCTION WITH 1 IMPLANT¹

▶ [LEARN MORE AT DURYSTAHCP.COM](http://DURYSTAHCP.COM)

IOP=intraocular pressure.
Not an actual patient.

INDICATIONS AND USAGE

DURYSTA™ (bimatoprost implant) is indicated for the reduction of intraocular pressure (IOP) in patients with open angle glaucoma (OAG) or ocular hypertension (OHT).

IMPORTANT SAFETY INFORMATION

Contraindications

DURYSTA™ is contraindicated in patients with: active or suspected ocular or periocular infections; corneal endothelial cell dystrophy (e.g., Fuchs' Dystrophy); prior corneal transplantation or endothelial cell transplants (e.g., Descemet's Stripping Automated Endothelial Keratoplasty [DSAEK]); absent or ruptured posterior lens capsule, due to the risk of implant migration into the posterior segment; hypersensitivity to bimatoprost or to any other components of the product.

Warnings and Precautions

The presence of DURYSTA™ implants has been associated with corneal adverse reactions and increased risk of corneal endothelial cell loss. Administration of DURYSTA™ should be limited to a single implant per eye without retreatment. Caution should be used when prescribing DURYSTA™ in patients with limited corneal endothelial cell reserve.

DURYSTA™ should be used with caution in patients with narrow iridocorneal angles (Shaffer grade < 3) or anatomical obstruction (e.g., scarring) that may prohibit settling in the inferior angle.

Macular edema, including cystoid macular edema, has been reported during treatment with ophthalmic bimatoprost, including DURYSTA™ intracameral implant. DURYSTA™ should be used with caution in aphakic patients, in pseudophakic patients with a torn posterior lens capsule, or in patients with known risk factors for macular edema.

Prostaglandin analogs, including DURYSTA™, have been reported to cause intraocular inflammation. DURYSTA™ should be used with caution in patients with active intraocular inflammation (e.g., uveitis) because the inflammation may be exacerbated.

Ophthalmic bimatoprost, including DURYSTA™ intracameral implant, has been reported to cause changes to pigmented tissues, such as increased pigmentation of the iris. Pigmentation of the iris is likely to be permanent. Patients who receive treatment should be informed of the possibility of increased pigmentation. While treatment with DURYSTA™ can be continued in patients who develop noticeably increased iris pigmentation, these patients should be examined regularly.

Intraocular surgical procedures and injections have been associated with endophthalmitis. Proper aseptic technique must always be used with administering DURYSTA™, and patients should be monitored following the administration.

Adverse Reactions

In controlled studies, the most common ocular adverse reaction reported by 27% of patients was conjunctival hyperemia. Other common adverse reactions reported in 5%-10% of patients were foreign body sensation, eye pain, photophobia, conjunctival hemorrhage, dry eye, eye irritation, intraocular pressure increased, corneal endothelial cell loss, vision blurred, iritis, and headache.

Please see Brief Summary of full Prescribing Information on the following page.

References: 1. DURYSTA™ [Prescribing Information]. Irvine, CA: Allergan, Inc.; 2020. 2. Data on file, Allergan, 2020. 3. Standring S. Orbit and accessory visual apparatus. In: *Gray's Anatomy: The Anatomical Basis of Clinical Practice*. 41st ed. Philadelphia, PA: Elsevier Limited; 2016: 666-708.



DURYSTA™

(bimatoprost implant) 10 mcg
For intracameral administration

Brief Summary—Please see the DURYSTA™ package insert for full Prescribing Information

INDICATIONS AND USAGE

DURYSTA™ is a prostaglandin analog indicated for the reduction of intraocular pressure (IOP) in patients with open angle glaucoma (OAG) or ocular hypertension (OHT).

CONTRAINDICATIONS

DURYSTA™ is contraindicated in patients with active or suspected ocular or periocular infections; corneal endothelial cell dystrophy; prior corneal transplantation, or endothelial cell transplants; absent or ruptured posterior lens capsule, due to the risk of implant migration into the posterior segment; or hypersensitivity to bimatoprost or any other components of the product.

WARNINGS AND PRECAUTIONS

Corneal Adverse Reactions: The presence of **DURYSTA™** implants has been associated with corneal adverse reactions and increased risk of corneal endothelial cell loss. Administration of **DURYSTA™** should be limited to a single implant per eye without retreatment. Caution should be used when prescribing **DURYSTA™** in patients with limited corneal endothelial cell reserve.

Iridocorneal Angle: Following administration with **DURYSTA™**, the intracameral implant is intended to settle within the inferior angle. **DURYSTA™** should be used with caution in patients with narrow iridocorneal angles (Shaffer grade < 3) or anatomical obstruction (e.g., scarring) that may prohibit settling in the inferior angle.

Macular Edema: Macular edema, including cystoid macular edema, has been reported during treatment with ophthalmic bimatoprost, including **DURYSTA™** intracameral implant. **DURYSTA™** should be used with caution in aphakic patients, in pseudophakic patients with a torn posterior lens capsule, or in patients with known risk factors for macular edema.

Intraocular Inflammation: Prostaglandin analogs, including **DURYSTA™**, have been reported to cause intraocular inflammation. **DURYSTA™** should be used with caution in patients with active intraocular inflammation (e.g., uveitis) because the inflammation may be exacerbated.

Pigmentation: Ophthalmic bimatoprost, including **DURYSTA™** intracameral implant, has been reported to cause changes to pigmented tissues, such as increased pigmentation of the iris. Pigmentation of the iris is likely to be permanent. Patients who receive treatment should be informed of the possibility of increased pigmentation. The pigmentation change is due to increased melanin content in the melanocytes rather than to an increase in the number of melanocytes. While treatment with **DURYSTA™** can be continued in patients who develop noticeably increased iris pigmentation, these patients should be examined regularly.

Endophthalmitis: Intraocular surgical procedures and injections have been associated with endophthalmitis. Proper aseptic technique must always be used with administering **DURYSTA™**, and patients should be monitored following the administration.

ADVERSE REACTIONS

Because clinical trials are conducted under widely varying conditions, adverse reaction rates observed in the clinical trials of a drug cannot be directly compared to rates in the clinical trials of another drug and may not reflect the rates observed in practice.

The most common ocular adverse reaction observed in two randomized, active-controlled clinical trials with **DURYSTA™** in patients with OAG or OHT was conjunctival hyperemia, which was reported in 27% of patients. Other common ocular adverse reactions reported in 5-10% of patients were foreign body sensation, eye pain, photophobia, conjunctival hemorrhage, dry eye, eye irritation, intraocular pressure increased, corneal endothelial cell loss, vision blurred, and iritis. Ocular adverse reactions occurring in 1-5% of patients were anterior chamber cell, lacrimation increased, corneal edema, aqueous humor

leakage, iris adhesions, ocular discomfort, corneal touch, iris hyperpigmentation, anterior chamber flare, anterior chamber inflammation, and macular edema. The following additional adverse drug reactions occurred in less than 1% of patients: hyphema, iridocyclitis, uveitis, corneal opacity, product administered at inappropriate site, corneal decompensation, cystoid macular edema, and drug hypersensitivity.

The most common nonocular adverse reaction was headache, which was observed in 5% of patients.

USE IN SPECIFIC POPULATIONS

Pregnancy: There are no adequate and well-controlled studies of **DURYSTA™** administration in pregnant women to inform a drug associated risk. Oral administration of bimatoprost to pregnant rats and mice throughout organogenesis did not produce adverse maternal or fetal effects at clinically relevant exposures. Oral administration of bimatoprost to rats from the start of organogenesis to the end of lactation did not produce adverse maternal, fetal or neonatal effects at clinically relevant exposures.

In embryo/fetal developmental studies in pregnant mice and rats, abortion was observed at oral doses of bimatoprost which achieved at least 1770 times the maximum human bimatoprost exposure following a single administration of **DURYSTA™** (based on plasma C_{max} levels; blood-to-plasma partition ratio of 0.858).

In a pre/postnatal development study, oral administration of bimatoprost to pregnant rats from gestation day 7 through lactation resulted in reduced gestation length, increased late resorptions, fetal deaths, and postnatal pup mortality, and reduced pup body weight at 0.3 mg/kg/day (estimated 470-times the human systemic exposure to bimatoprost from **DURYSTA™**, based plasma C_{max} and a blood-to plasma partition ratio of 0.858). No adverse effects were observed in rat offspring at 0.1 mg/kg/day (estimated 350-times the human systemic exposure to bimatoprost from **DURYSTA™**, based on plasma C_{max}).

Lactation: There is no information regarding the presence of bimatoprost in human milk, the effects on the breastfed infants, or the effects on milk production. In animal studies, topical bimatoprost has been shown to be excreted in breast milk. Because many drugs are excreted in human milk, caution should be exercised when **DURYSTA™** is administered to a nursing woman.

The developmental and health benefits of breastfeeding should be considered, along with the mother's clinical need for **DURYSTA™** and any potential adverse effects on the breastfed child from **DURYSTA™**.

Pediatric Use: Safety and effectiveness of **DURYSTA™** in pediatric patients have not been established.

Geriatric Use: No overall differences in safety or effectiveness have been observed between elderly and other adult patients.

NONCLINICAL TOXICOLOGY

Carcinogenesis, Mutagenesis, Impairment of Fertility

Bimatoprost was not carcinogenic in either mice or rats when administered by oral gavage at doses up to 2 mg/kg/day and 1 mg/kg/day respectively for 104 weeks (approximately 3100 and 1700 times, respectively, the maximum human exposure [based on plasma C_{max} levels; blood-to-plasma partition ratio of 0.858]).

Bimatoprost was not mutagenic or clastogenic in the Ames test, in the mouse lymphoma test, or in the *in vivo* mouse micronucleus tests.

Bimatoprost did not impair fertility in male or female rats up to doses of 0.6 mg/kg/day (1770-times the maximum human exposure, based on plasma C_{max} levels; blood-to-plasma partition ratio of 0.858).

PATIENT COUNSELING INFORMATION

Treatment-related Effects: Advise patients about the potential risk for complications including, but not limited to, the development of corneal adverse events, intraocular inflammation or endophthalmitis.

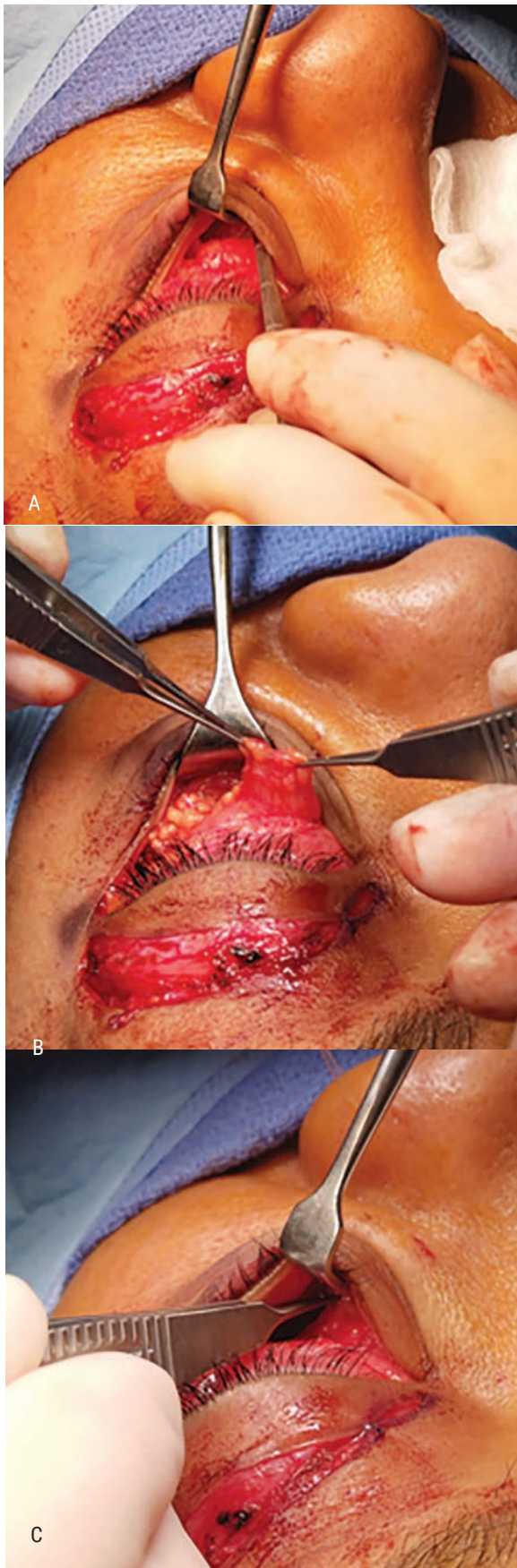Potential for Pigmentation: Advise patients about the potential for increased brown pigmentation of the iris, which may be permanent.

When to Seek Physician Advice: Advise patients that if the eye becomes red, sensitive to light, painful, or develops a change in vision, they should seek immediate care from an ophthalmologist.

Rx only



© 2020 Allergan. All rights reserved. **DURYSTA™** is a trademark of Allergan, Inc.
Patented. See: www.allergan.com/patents DUR133688 03/20 based on v1.0USPI9652



essary. To maintain optimal postoperative lower eyelid position, consider performing surgical maneuvers focused on preserving orbicularis integrity for paralysis prevention and incorporating lateral canthal tightening, if necessary.⁶ The presence of concomitant floppy eyelid syndrome may necessitate more extensive intraoperative tightening procedures such as the formation of a true lateral tarsal strip.

Managing Orbital Fat

Among the biggest shifts in recent years has been the change in the surgeon's approach to the prominent appearance of the orbital fat pads. It was previously thought that with aging comes fat herniation and prolapse. Instead, this change in contour along the eyelid-midface junction relates more to the surrounding prominences and hollows.¹⁻⁶ A combination of liposculpting and transposition of the orbital fat can be a more thoughtful and conservative approach that will prevent postoperative hollowing over the long term.^{1-6,8,9}

Figure 1 (left) demonstrates intraoperative views of a transposition lower blepharoplasty with ligament release and sub-periosteal pocket development (A), fat pedicle development (B) and the pedicle transposed into the subperiosteal space (C). Ligamentous release and pocket development can also be performed in a pre-periosteal plane. Depending on the degree of surrounding volume loss, you may need to supplement surgery with additional volume restoration through autologous fat transfer or adjunctive hyaluronic acid filler in order to optimize the contours in the region.^{8,9} A dynamic preoperative assessment of the appearance of the lower-eyelid fat in up- and down-gaze can help determine the amount of fat present, as well as aid in distinguishing fat from edema. In up-gaze, the fat will prolapse forward and become more prominent than in down-gaze. This is in contrast to chronic edema, which will remain constant with globe position. This examination is similarly useful for identifying areas of necessary fat preservation, subtraction and transposition. Gently balloting the globe can further help to reveal compartments with excess fatty tissue.

Festoons

Differentiating between fat and edema is essential to managing appropriate patient expectations, and certainly informs the planned surgical approach. Lower eyelid

Figure 1. Intraoperative views of a transposition lower blepharoplasty with ligament release and sub-periosteal pocket development (A), fat pedicle development (B), and the pedicle transposed into the subperiosteal space (C). Ligamentous release and pocket development can also be performed in a pre-periosteal plane. Depending on the degree of surrounding volume loss, supplementing surgery with additional volume restoration through autologous fat transfer or adjunctive hyaluronic acid filler may be necessary to optimize the contours in the region.

edema, particularly in the malar region, has garnered much attention due to the challenges it presents in terms of definitive management. Festoons are postulated to form as a result of changes to the surrounding ligamentous structures in the prezygomatic space.¹⁰ Specifically, edema is thought to collect in a well-demarcated triangle in the malar region due to the relative laxity of the superior orbital retaining ligament with the maintained strength of the inferior zygomatico-cutaneous ligament.¹⁰ Malar festoons are a common source of patient concern and may be the focus of their lower eyelid cosmetic goals.

The options for festoon management range from the most invasive and definitive—direct excision—to less-invasive approaches focused on the principles of sclerotherapy.

Direct festoon excision, as the name implies, involves incising around the margins of the festoon and excising it directly. This technique can be performed in isolation or as an adjunct to lower blepharoplasty. This approach has proven to be effective for festoon management,^{11,12} but is limited by patient tolerance for an aggressive approach that involves waiting for their visible incision line to fade along the relaxed skin tension lines.

An alternative surgical approach that's also proven effective involves employment of a subperiosteal midface lift in conjunction with an orbicularis muscle-skin flap.^{13,14}

Non-surgical interventions include radiofrequency approaches, thermoplasty, laser resurfacing and trichloroacetic acid chemical peels.¹³

More recently, injection of sclerosing agents has shown promise in the management of malar festoons.^{15,16} The use of intralésional tetracycline (2%) resulted in improvement in 21 patients, as determined by photo evaluation by blinded graders.¹⁵ This treatment

was noted to be well-tolerated, without any complications.¹⁵

A similar study was conducted for the investigation of the efficacy and safety of intralésional doxycycline; it demonstrated a statistically significant improvement in festoons, without complications.¹⁶ Compared to tetracycline, doxycycline has the benefit of enhanced accessibility, and it can be reconstituted in the office.¹⁶ The precise mechanism of action behind the tetracycline family of antibiotics with regard to their utility as sclerosing agents isn't fully elucidated, but they've been shown to induce collagen and fibrin deposition, leading to fibrosis.¹⁶

“**The options for festoon management range from the most invasive and definitive—direct excision—to less-invasive approaches focused on the principles of sclerotherapy.**”

Unfortunately, regardless of the treatment approach, one of the most important things to manage when it comes to festoons is the patient's expectations, because these pockets of edema can be elusive and notoriously refractory to treatment.

Dealing with Ligaments and Volume Issues

Lastly, the structural bony changes and areas of volume loss will help guide the degree of necessary fascia ligament release and volume augmentation by fat autologous grafting or postoperative hyaluronic acid filler. In one report, University of Texas Southwestern Medical Center's Joel Pessa, MD, and his colleagues identified specific changes to the skeletal facial structure that occur with aging and how

these changes affect alterations observed in the overlying soft tissue and ligamentous structures.¹⁷ Over time, they noted that the lower maxillary skeleton at the piriform becomes retrusive relative to the upper face,¹⁷ and the maxillary wall from the orbital rim to the inferior zygoma tilts further posteriorly.¹⁷ Lastly, the medial orbit becomes more anteriorly positioned.¹⁷


It's postulated that the aforementioned changes in the bony skeleton result in changes in the overlying muscles, ligaments and soft tissues, as bony changes may alter the location of tendinous insertions. For example, the malar mound and nasojugal fold (also known as the “tear trough”) are thought to be accentuated as a consequence of the positional shift in the plane of the maxillary wall.¹⁷ Tendon repositioning may also cause a change in the position of the malar and buccal fat pads.¹⁷ All of these soft tissue structures are also undergoing their own simultaneous involutational changes.

Restoring the effacement of the lower eyelid and cheek by addressing these volume changes is important for optimizing lower blepharoplasty.¹⁸ Midfacial projection ideals are defined by the golden ratio of facial aesthetics. Tel Aviv, Israel's Ran Stein, MD, co-authored a study that demonstrated the value of autologous fat grafting to the inferior orbital rim, the deep and medial fat pads, and Ristow's space as a means to optimize facial proportions in this region.¹⁸

The nasojugal and malar folds are defined by the cutaneous attachments of the orbicularis retaining ligament (ORL). The nasojugal fold begins at the inner canthus and is formed by the depression between the orbicularis oculi muscle and levator labii superioris muscle.¹⁹ The malar fold begins at the outer canthus toward the inferior aspect of the nasojugal fold.¹⁹ With age, ligaments lose strength and elas-

TREAT OCULAR INFLAMMATION
AND INFECTION, AND...

TURN ON
— RELIEF —



TobraDex® ST
(tobramycin/dexamethasone
ophthalmic suspension)
0.3%/0.05%
FORMULATED WITH XanGen™

PRESCRIBE TOBRADEX® ST to control ocular inflammation with risk of bacterial infection



Rapid relief from blepharitis/
blepharoconjunctivitis symptoms^{1,a}



XanGen™ suspension technology
provides increased viscosity
for improved ocular bioavailability
of drug and consistent delivery²



TOBRADEX ST contains half the
dexamethasone as TobraDex®,
yet similar ocular tissue exposure^{2,b}

Eligible patients could pay as little as \$45 for TOBRADEX ST
LEARN MORE AT MYTOBRADEXST.COM

Indications and Usage

For steroid responsive inflammatory ocular conditions of the palpebral and bulbar conjunctiva, cornea, and anterior segment of the globe and chronic anterior uveitis, corneal injury from chemical, radiation or thermal burns, or penetration of foreign bodies for which a corticosteroid is indicated and where the risk of superficial bacterial ocular infection is high or where there is an expectation that potentially dangerous numbers of bacteria will be present in the eye.

Important Safety Information

CONTRAINDICATIONS:

Most viral disease of the cornea and conjunctiva including epithelial herpes simplex keratitis (dendritic keratitis), vaccinia, and varicella, and also in mycobacterial infection of the eye and fungal disease of ocular structures. Hypersensitivity to any components of the medication.

WARNINGS & PRECAUTIONS:

- **IOP increase** – Prolonged use may result in glaucoma with damage to the optic nerve, defects in visual acuity and fields of vision. IOP should be monitored.
- **Aminoglycoside sensitivity** – Sensitivity to topically applied aminoglycosides may occur.
- **Cataracts** – Posterior subcapsular cataract formation may occur.
- **Delayed healing** – May delay healing and increase the incidence of bleb formation. Perforations of the cornea or sclera have occurred. Slit lamp biomicroscopy, and fluorescein staining should be conducted.
- **Bacterial infections** – May suppress host response and increase secondary ocular infections. In acute purulent conditions, steroids may mask infection or enhance existing infection. If signs and symptoms fail to improve after 2 days, the patient should be re-evaluated.

- **Viral infections** – Use with history of herpes simplex requires great caution. The course and severity of many viral infections of the eye (including herpes simplex) may be exacerbated.
- **Fungal infections** – Fungal infections of the cornea may occur and should be considered in any persistent corneal ulceration.
- **Use with systemic aminoglycosides** – Total serum concentration of tobramycin should be monitored.

ADVERSE REACTIONS:

The most frequent adverse reactions (<4%) to topical ocular tobramycin are hypersensitivity and localized ocular toxicity, including eye pain, eyelid pruritus, eyelid edema, and conjunctival hyperemia. The reactions due to the steroid component are increased intraocular pressure with possible development of glaucoma, and infrequent optic nerve disorder; subcapsular cataract; and impaired healing.

The development of secondary infection has occurred. Fungal infections of the cornea may occur. Secondary bacterial ocular infection following suppression of host responses also occurs.

Non-ocular adverse events (0.5% to 1%) included headache and increased blood pressure.

Please see Brief Summary of Full Prescribing Information on the adjacent page.

^aRandomized, investigator-masked, active-controlled, parallel-group trial conducted at 7 private practice clinical sites in the United States with 122 adult patients who had moderate to severe blepharitis/blepharoconjunctivitis.¹

^bMulticenter, double-blind, parallel-group, single-dose study of 987 patients receiving a single dose of TOBRADEX ST or TobraDex ophthalmic suspension.²

References: 1. Torkildsen GL, Cockrum P, Meier E, et al. *Curr Med Res Opin.* 2011;27(1):171-178. 2. Scoper SV, Kabat AG, Owen GR, et al. *Adv Ther.* 2008;25(2):77-88.



© 2020 Eveance Pharmaceuticals LLC. All rights reserved.
TOBRADEX® ST and XanGen™ are trademarks of Eveance Pharmaceuticals LLC.
All other trademarks are the property of their respective owners. TST-01-20-AD-04

TOBRADEX® ST (tobramycin/dexamethasone ophthalmic suspension) 0.3%/0.05%

Brief Summary

This Brief Summary does not include all the information needed to use TOBRADEX ST safely and effectively. Please see Full Prescribing Information for TOBRADEX ST at MyTobraDexST.com.

INDICATIONS AND USAGE

TOBRADEX ST is a topical antibiotic and corticosteroid combination for steroid-responsive inflammatory ocular conditions for which a corticosteroid is indicated and where superficial bacterial ocular infection or a risk of bacterial ocular infection exists.

Ocular steroids are indicated in inflammatory conditions of the palpebral and bulbar conjunctiva, cornea and anterior segment of the globe where the inherent risk of steroid use in certain infective conjunctivitis is accepted to obtain a diminution in edema and inflammation. They are also indicated in chronic anterior uveitis and corneal injury from chemical, radiation or thermal burns, or penetration of foreign bodies.

The use of a combination drug with an anti-infective component is indicated where the risk of superficial ocular infection is high or where there is an expectation that potentially dangerous numbers of bacteria will be present in the eye.

DOSAGE AND ADMINISTRATION

Recommended Dosing: Instill one drop into the conjunctival sac(s) every four to six hours. During the initial 24 to 48 hours, dosage may be increased to one drop every 2 hours. Frequency should be decreased gradually as warranted by improvement in clinical signs. Care should be taken not to discontinue therapy prematurely.

CONTRAINDICATIONS

Nonbacterial Etiology: TOBRADEX ST is contraindicated in most viral diseases of the cornea and conjunctiva including epithelial herpes simplex keratitis (dendritic keratitis), vaccinia, and varicella, and also in mycobacterial infection of the eye and fungal diseases of ocular structures.

Hypersensitivity: Hypersensitivity to any component of the medication.

WARNINGS AND PRECAUTIONS

IOP increase: Prolonged use of corticosteroids may result in glaucoma with damage to the optic nerve, defects in visual acuity and fields of vision. IOP should be monitored.

Aminoglycoside sensitivity: Sensitivity to topically applied aminoglycosides may occur.

Cataracts: May result in posterior subcapsular cataract formation.

Delayed healing: May delay healing and increase the incidence of bleb formation after cataract surgery. In those diseases causing thinning of the cornea or sclera, perforations have been known to occur with the use of topical steroids.

Bacterial infections: May suppress the host response and thus increase the hazard of secondary ocular infections. In acute purulent conditions, steroids may mask infection or enhance existing infection. If signs and symptoms fail to improve after 2 days, the patient should be re-evaluated.

Viral infections: Treatment in patients with a history of herpes simplex requires great caution. Use of ocular steroids may prolong the course and may exacerbate the severity of many viral infections of the eye (including herpes simplex).

Fungal infections: Fungal infections of the cornea are particularly prone to develop with long-term use.

Fungal invasion must be considered in any persistent corneal ulceration.

Use with systemic aminoglycosides: Use with systemic aminoglycoside antibiotics requires monitoring for total serum concentration of tobramycin.

ADVERSE REACTIONS

The most frequent adverse reactions to topical ocular tobramycin (TOBEX®) are hypersensitivity and localized ocular toxicity, including eye pain, eyelids pruritis, eyelid edema, and conjunctival hyperemia. These reactions occur in less than 4% of patients. Similar reactions may occur with the topical use of other aminoglycoside antibiotics.

Non-ocular adverse events occurring at an incidence of 0.5% to 1% included headache and increased blood pressure.

The reactions due to the steroid component are: increased intraocular pressure (IOP) with possible development of glaucoma, and infrequent optic nerve disorder; subcapsular cataract; and impaired healing.

Secondary Infection.

The development of secondary infection has occurred. Fungal infections of the cornea are particularly prone to develop with long-term use. Fungal invasion must be considered in any persistent corneal ulceration. Secondary bacterial ocular infection following suppression of host responses also occurs.

USE IN SPECIFIC POPULATIONS

Pregnancy and Nursing Mothers

There are no adequate and well controlled studies in pregnant women. TOBRADEX® ST ophthalmic suspension should be used during pregnancy only if the potential benefit justifies the potential risk to the fetus. Caution should be exercised when TOBRADEX® ST is administered to a nursing woman.

Pediatric Use: Safety and effectiveness in pediatric patients below the age of 2 years have not been established.

Geriatric Use: No overall differences in safety or effectiveness have been observed between elderly and younger patients.

Rx Only

Distributed by: Eyeavance Pharmaceuticals LLC.
Fort Worth, TX 76102



ticity, resulting in the descent of the surrounding soft tissues. This causes elongation of the vertical height of the lower eyelid and prominence of the nasojugal and malar folds.¹⁹

The orbicularis retaining ligament is responsible for the overall shape of the lower eyelid. Changes in the ORL are variable along its course and, since it's typically weakest centrally, result in more prominent bulging of the inferior orbital fat pads in this region.¹⁹ The degree of ligamentous laxity also varies among the different facial ligaments. Although the zygomatic cutaneous ligaments undergo some attenuation with age, they remain strong relative to the ORL. Therefore, descent of tissues from ORL weakness will meet the stronger zygomatic ligament, resulting in malar mound formation.¹⁹

Release of the ORL during lower-eyelid blepharoplasty makes conceptual sense from the standpoint of eliminating a physical boundary separating the lower lid from the cheek and dividing what was once a single, continuous, youthful unit.

Several authors have demonstrated the effectiveness of ORL release as an adjunct to lower-lid blepharoplasty in order to address the tear trough.^{6,20} One of the limitations of several of the articles on this technique is the lack of comparison to patients who underwent lower blepharoplasty without ORL release. In one study, however, researchers compared the efficacy and complications in patients with and without ORL release. They concluded that ligamentous release didn't enhance the aesthetic outcome and could pose an increased risk of prolonged swelling and chemosis as well as increase the risk of lid malposition.²⁰

Ultimately, successful lower-eyelid/midface rejuvenation is dependent upon a solid understanding of the patient's goals, clearly defining

and managing the patient's expectations of what can be achieved, and taking a thoughtful, systematic, and anatomy-based approach to rejuvenating the region. The advances in our understanding of the changes that occur in the face with aging have permitted a three-dimensional approach to rejuvenation, in order to optimize patient outcomes beyond what was achieved with subtractive approaches alone. Fitting the surgery to the patient's expectations and specific anatomic aging changes permits a customized surgery that addresses their aesthetic goals and functional needs, allowing them to achieve the best possible outcome. ◀

Acknowledgement: I'd like to acknowledge the profound influence of my great mentor Tanuj Nakra, MD, FACS, whose biplanar systematic approach to lower-eyelid blepharoplasty has defined the framework of my approach to lower-lid rejuvenation, and has helped me develop the methodical guide described in the article.

Dr. Watson welcomes questions and comments on the article. Please direct correspondence to:

Wills Eye Hospital, 840 Walnut Street, Suite 910, Philadelphia, PA 19107

Phone: 215-928-3171

Fax: 215-928-3454

Email: awatson@willseye.org

1. Loeb R. Fat pad sliding and fat grafting for leveling lid depressions. *Clin Plast Surg* 1981;8:757.
2. Hamra ST. Arcus marginalis release and orbital fat preservation in midface rejuvenation. *Plast Reconstr Surg* 1995;96:354-362.
3. Kossler AL, Peng GL, Yoo DB, Azzizadeh B, Massry GG. Current trends in upper and lower eyelid blepharoplasty among American Society of Ophthalmic Plastic and Reconstructive Surgery members. *Ophthal Plast Reconstr Surg* 2018;34:37-42.
4. Hartstein ME, Massry GG. The lift and fill lower blepharoplasty. *Ophthal Plast Reconstr Surg* 2012;28:213-218.
5. Goldberg RA, McCann JD, Fiaschetti D, et al. What causes eyelid bags? Analysis of 114 consecutive patients. *Plast Reconstr Surg* 2005;115:1395-402

(discussion: 1403-4).

6. Nakra T. Biplanar contour-oriented approach to lower eyelid and midface rejuvenation. *JAMA Facial Plast Surg* 2015;17:5:374-381.
7. Ganceviciene R, Liakou AI, Theodoridis A, Makrantonaki E, Zouboulis CC. Skin anti-aging strategies. *Dermato-endocrinology* 2012;4:3:308-319.
8. Cicui PM, Obagi S. Rejuvenation of the periorbital complex with autologous fat transfer: Current therapy. *J Oral Maxillofac Surg* 2008;66:8:1686-1693.
9. McCracken MS, Khan JA, Wulc AE, et al. Hyaluronic acid gel (Restylane) filler for facial rhytids: Lessons learned from American Society of Ophthalmic Plastic and Reconstructive Surgery member treatment of 286 patients. *Ophthal Plast Reconstr Surg* 2006;22:3:188-191.
10. Medelson BC, Muzaffar AR, Adams WP Jr. Surgical anatomy of the midcheek and malar mounds. *Plast Reconstr Surg* 2002;110:885-896 (discussion: 897-911).
11. Einan-Lifshitz A, Hartstein ME. Treatment of festoons by direct excision. *Orbit* 2012;31:5:303-6.
12. Bellinvia P, Klinger F, Bellinvia G. Lower blepharoplasty with direct excision of skin excess: A five-year experience. *Aesthetic Surg J* 2010;30:665-670.
13. Krakauer M, Phil M, Aakalu VK, Putterman AM. Treatment of malar festoon using modified subperiosteal midface lift. *Ophthal Plast Reconstr Surg* 2012;28:459-462.
14. Hoenig JF, Knutti D, de la Fuente A. Vertical subperiosteal mid-face-lift for treatment of malar festoons. *Aesthetic Surg J* 2011;35:522-529.
15. Perry JD, Mehta VJ, Costin BR. IntraleSIONAL tetracycline injection for treatment of lower eyelid festoons: A preliminary report. *Ophthal Plast Reconstr Surg* 2015;31:50-52.
16. Godfrey KJ, Kally P, Dunbar KE, et al. Doxycycline injection for sclerotherapy of lower eyelid festoons and malar edema: Preliminary results. *Ophthal Plast Reconstr Surg* 2019;35:474-477.
17. Pesa JE, Zadoo VP, Mutimer KL, et al. Relative maxillary retrusion as a natural consequence of aging: Combining skeletal and soft-tissue changes into an integral model of midfacial aging. *Plast Reconstr Surg* 1998;102:1:205-212.
18. Stein R, Holds JB, Wulc AE, et al. Phi, fat, and the mathematics of a beautiful midface. *Ophthal Plast Reconstr Surg* 2018;34:491-496.
19. Jordan DR, Mawn L, Anderson RL. *Surgical Anatomy of the Ocular Adnexa: A Clinical Approach*. 2nd edition. Oxford University Press, 2012:55-69.
20. Chan NJ, Nazemzadeh M, Hartstein ME, et al. Orbicularis retaining ligament release in lower blepharoplasty: Assessing efficacy and complications. *Ophthal Plast Reconstr Surg* 2018;34:155-161.

ABOUT THE AUTHOR



Dr. Watson is an oculoplastics specialist in the Oculoplastic & Orbital Surgery service at Wills Eye. She's an assistant professor at the Sidney Kimmel Medical College at Thomas Jefferson University.

**Eyhance Intraocular Lenses
Approved by FDA**

(Continued from p. 16)

phacoemulsification. *Int Ophthalmol.* 2021;41:1:273-282.
 2. Mencucci R, Cennamo M, Venturi D, et al. Visual outcome, optical quality, and patient satisfaction with a new monofocal IOL, enhanced for intermediate vision: Preliminary results. *J Cataract Refract Surg.* 2020;46:3:378-387.
 3. Eguileor B, Martinez-Indart L, Alday N, et al. Differences in intermediate vision: Monofocal intraocular lenses vs. monofocal extended depth of focus intraocular lenses. *Arch Soc Esp Ophthalmol.* 2020;95:11:523-527.
 4. Yangzes S, Kamble N, Grewal S, et al. Comparison of an aspheric monofocal intraocular lens with the new generation monofocal lens using defocus curve. *Indian J Ophthalmol.* 2020;68:12:3025-3029.
 5. Auffarth GU, Gerl M, Tsai L, et al. Clinical evaluation of a new monofocal intraocular lens with enhanced intermediate function in cataract patients. *J Cataract Refract Surg* 2021;47:2:184-91.

**Bright Light May
Help Glaucoma
Patients Sleep**

Glaucoma patients who are exposed to bright light during the day may have improved sleep and an increased melanopsin-dependent pupil response after just four weeks, a pilot

study in *Frontiers in Neurology* reports.¹

The multinational research team composed of researchers from Switzerland, the United Kingdom and New Zealand suggests the change in pupil response might indicate that melanopsin activity in viable intrinsically photosensitive retinal ganglion cells can adapt to different light levels, if sustained over a period of time.

Their study enrolled 20 glaucoma patients without severe vision loss and considered how 30 minutes of daily bright light exposure from a table-based light box placed in their homes affected pupil constriction, circadian rest-activity cycles, sleep, relaxation, alertness and mood.

Participants continuously wore an activity monitor and self-assessed sleep quality, well-being and visual comfort for several days before and during the four weeks of daily 10,000 lux polychromatic bright white light exposure.

Individuals underwent pupillometry at baseline and on the last day of

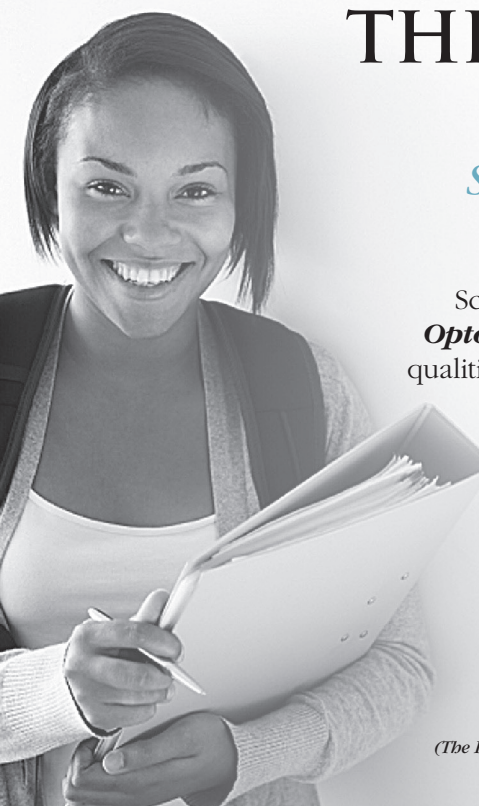the study.

Following light exposure, participants showed a much greater post-illumination pupil response and had better quality of sleep. Additionally, researchers report that they found no significant changes in the participants' 24-hour rhythms or sleep parameters.

The study demonstrated that even a relatively short duration of added light exposure in a room is beneficial and also supports the general advice that the elderly should go outside for half an hour each morning, the researchers suggest.

While glaucoma patients can never recover the vision lost from damaged retinal ganglion cells, they may be able to maintain a robust day-night cycle and concomitant good circadian entrainment which helps maintain high sleep quality, the investigators explain. ◀

1. Kawasaki A, Udry M, Wardani ME, Münch M. Can extra daytime light exposure improve well-being and sleep? A pilot study of patients with glaucoma. *Front Neurol* 2020;11:584479.



THE RICK BAY FOUNDATION

for Excellence in Eyecare Education

*Support the Education of Future Healthcare
& Eyecare Professionals*

Scholarships are awarded to advance the education of students in both **Optometry** and **Ophthalmology**, and are chosen by their school based on qualities that embody Rick's commitment to the profession, including integrity, compassion, partnership and dedication to the greater good.

Interested in being a partner with us?

Visit www.rickbayfoundation.org

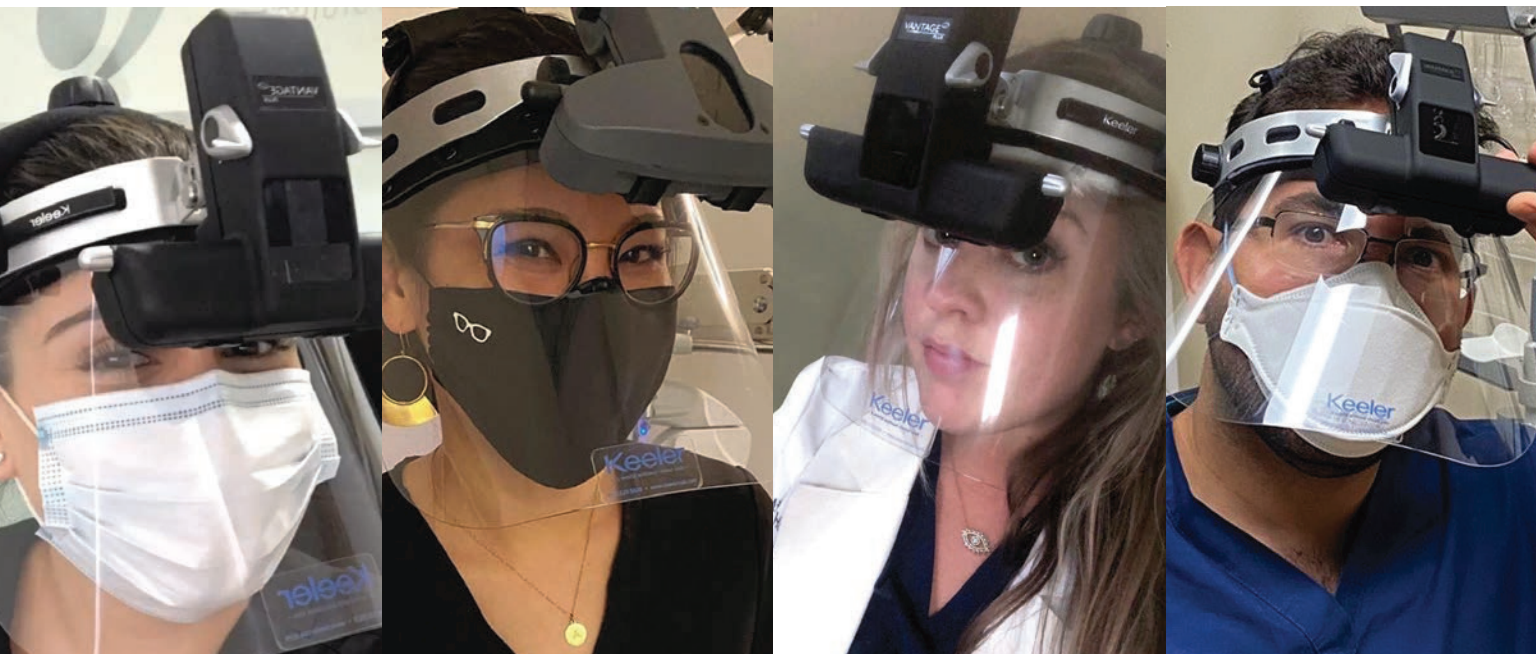(Contributions are tax-deductible in accordance with section 170 of the Internal Revenue Code.)



THE RICK BAY FOUNDATION
for Excellence in Eyecare Education

(The Rick Bay Foundation for Excellence in Eyecare Education is a nonprofit, tax-exempt organization under section 501(c)(3) of the Internal Revenue Code.)

Helping Heroes See Clear And Stay Safe



The Vantage BIO is great for ROP screening! It's lightweight, has settings for different pupil sizes, a cool, white LED light and the longest battery ever!!"

Dra. Paulina Ramirez Neria



I'm a big fan of the All Pupil BIO. I had issues with other models so when I started [my practice], I knew the All Pupil would be my go-to BIO...I greatly appreciate the new custom fit Keeler BIO shields as an added safety layer."

Dr. Annie Bacon



I chose my [Vantage Plus] for the optics and value...with other brands, I had difficulty focusing up close during my dilated fundus exams. [The oculars] made my eyes feel more relaxed, and I felt like my view was better."

Dr. Michelle Hammond



[I've] been seeing emergent and urgent cases every day during the COVID19 pandemic. I really like [the Vantage BIO] because [it's a] very good quality and provides a super clear view."

Dr. Reza Moradi

Choose one of the programs below when you purchase a BIO* between **September 1, 2020 and March 31, 2021**

*this program is valid for our wireless indirects: All Pupil II and Vantage Plus

1

RECEIVE A

\$850

credit towards any PPE



2

24-MONTH

0%

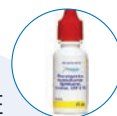lease as low as \$128/month*

*All Pupil II: \$127.92/month; Vantage Plus: \$155/month (shipping and taxes not included).

3

RECEIVE

10 FREE
bottles of phenylephrine
2.5%, 15mL



***Leasing may also be combined with the PPE credit OR the phenylephrine option.**

Contact us at 800-523-5620 or customerservice@keelerusa.com to learn more or place your order. This promo cannot be combined with any other Keeler offers.

Keeler
— A world without vision loss —

www.keelerusa.com • 3222 Phoenixville Pike - Bldg. #50 • Malvern, PA 19355
Tel No: 1-610-353-4350 • Toll Free: 1-800-523-5620 • Fax: 1-610-353-7814


A Halma company

PRODUCT NEWS

New items on the market to improve clinical care and strengthen your practice.

New World Medical's KDB Glide Now Available

Do you ever struggle to complete a goniotomy procedure as precisely as you'd like because Schlemm's canal is too narrow or irregular? A new device called the KDB Glide has been launched to provide the support you can rely on in just such a situation.

New World Medical (Rancho Cucamonga, California), maker of the market-leading Ahmed Glaucoma Valve, says that the KDB Glide is ideal for incisional goniotomy in patients whose canal has undergone morphological changes as they age.

Like the company's Kahook Dual Blade, the KDB Glide is indicated for mild, moderate or severe glaucoma. You can use it in a standalone procedure or in combination with cataract surgery. The company estimates that the product could benefit more than 4.5 million glaucoma patients in the United States.

For more information, visit <https://www.newworldmedical.com/kahook-dual-blade/>.

Make Things Easier for Low-vision Patients

If your low-vision patients find it difficult to read comfortably, help may be available.

Eschenbach Optik of America says the new Easy Reader reading stand holds reading material upright and in an ergonomically correct position to make reading more comfortable, "especially for those with visual impairment using a low-vision device." The portable stand



Eschenbach says its new upright stand can make reading more comfortable, especially for users of low-vision devices.

is lightweight (weighing 17 oz.), and is compact, folding down to 0.5 inches in thickness, which the company says makes it easy to travel with. It folds flat for storage and fits into carry-ons, totes and backpacks.

There are 10 positions to which the reading stand can be adjusted, from 5" to 6" high, and the rubber grips on the bottom of the stand keeps it in place when pressure is applied—like when using a stand magnifier—providing a stabilized reading surface.

By propping up the reading material, the stand provides a more comfortable reading position for those with macular degeneration, minimizing neck strain when using a stand magnifier. For more information, visit [eschenbach.com](https://www.eschenbach.com).

Alcon Announces Broad Retail/OTC Availability of Pataday

Alcon announced that Pataday Once Daily Relief Extra Strength (olopatadine hydrochloride ophthalmic solution 0.7%) is now available in-store and online at U.S. retailers, following its 2020 approval by the FDA for sale over-the-counter. The company says the drug is available in select stores and via online retailers, such as Amazon, Walgreens, CVS, Target and more, with widespread commercial availability to begin this month through all major drug, food and mass-market retailers. ◀



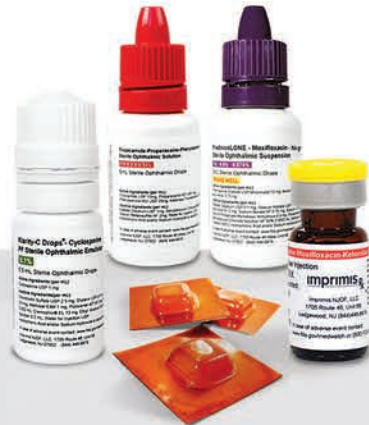New World Medical's Kahook Dual Blade is indicated for mild, moderate or severe cases of glaucoma, the company says.

BUNDLE + SAVE

SAVE UP TO \$750* ON YOUR NEXT 503B ORDER!



Chat with us at imprimisrx.com to build your PharmaPack™ today!



INJECTABLE FORMULATIONS**

Tri-Moxi® PF

Triamcinolone acetonide and moxifloxacin 9mg/0.6mg/0.6mL (15mg/1mg/mL)

Dex-Moxi® PF

Dexamethasone sodium phosphate and moxifloxacin (1mg/5mg/mL)

Dex-Moxi-Ketor® PF

Dexamethasone sodium phosphate, moxifloxacin and ketorolac tromethamine (1mg/0.5mg/0.4mg/mL)

Epi-Lido PF/SF

Epinephrine in BSS/Lidocaine hydrochloride (0.75/0.025)%

Phenyl-Lido PF/SF

Phenylephrine hydrochloride/Lidocaine hydrochloride (1.5/1)%

Moxifloxacin PF

0.8mg/0.8mL (1mg/mL)

Moxifloxacin PF

4mg/0.8mL (5mg/mL)

TOPICAL FORMULATIONS**

Mydriatic 2

Tropicamide and phenylephrine hydrochloride (1/2.5)%

Mydriatic 4

Tropicamide, proparacaine hydrochloride, phenylephrine hydrochloride, and ketorolac tromethamine (1/0.5/2.5/0.5)%

Pred-Moxi-Brom™

Prednisolone acetate, moxifloxacin, and bromfenac (1/0.5/0.075)%

Pred-Moxi-Nepaf®

Prednisolone acetate, moxifloxacin and nepafenac (1/0.5/0.1)%

Pred-Moxi®

Prednisolone acetate and moxifloxacin (1/0.5)%

Pred-Brom®

Prednisolone acetate and bromfenac (1/0.075)%

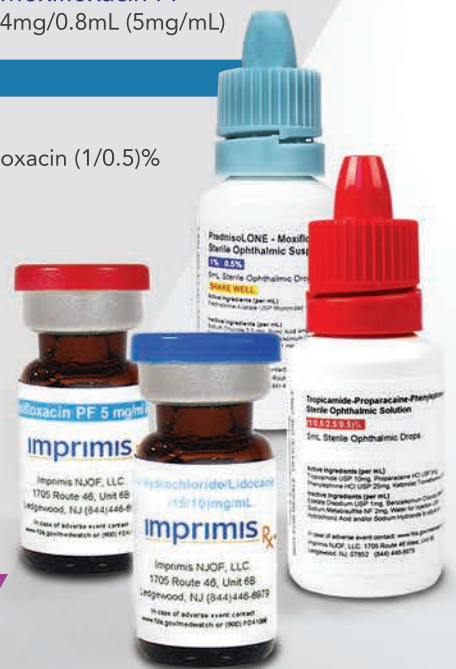Prednisolone Acetate PF 1%

Klarity-C Drops® PF

Cyclosporine 0.1% ophthalmic emulsion

Klarity Drops® PF

Glycerin and dextran based vehicle ophthalmic solution



ORAL FORMULATIONS**

MKO Melt®

Midazolam, ketamine HCl, and ondansetron (3/25/2)mg

*Offer cannot be combined with any other offers and discounts.

PF – Preservative Free SF – Sulfite Free

**For professional use only. ImprimisRx specializes in customizing medications to meet unique patient and practitioner needs. No compounded medication is reviewed by the FDA for safety or efficacy. ImprimisRx does not compound essential copies of commercially available products.

imprimis Rx®

Tri-Moxi, Dex-Moxi-Ketor, Dex-Moxi, Pred-Brom, Pred-Moxi, Pred-Moxi-Brom, Pred-Moxi-Nepaf, Klarity-C Drops, Klarity Drops, MKO Melt, PharmaPack, and ImprimisRx are trademarks of Harrow Health, Inc. ©2021 ImprimisRx. All Rights Reserved. IMPO0523 02/21



SECONDARY IOL FIXATION: KNOW YOUR OPTIONS

Surgeons share their expertise to help expand your skillset.

BY CHRISTINE LEONARD
ASSOCIATE EDITOR

When you're faced with a patient who lacks capsular support, your options for intraocular lens fixation include anterior chamber IOLs and iris- or scleral-fixated posterior chamber IOLs; you may also decide to leave the patient aphakic and refer the case. Whichever you choose, experts say it should be the option you're most comfortable with. In this article, two veteran surgeons who moderate a course managing eyes with an absence of capsular support at the American Academy of Ophthalmology meeting compare the current methods for secondary IOL implantation and offer advice for achieving successful outcomes in these tricky cases.

The Learning Curve

IOL implantation in the absence of capsular support isn't a common procedure, and the dearth of cases to practice on makes it difficult to build up a robust skillset.

Finding a mentor who's well-

versed in the technique you want to learn will provide you with valuable insights and experiences. "Every surgery has so many nuances," says Mark Gorovoy, MD, of Gorovoy MD Eye Specialists in Fort Myers, Florida. "If you're just watching videos, you'll miss a lot of those nuances. It really pays to find a mentor who can talk you through the procedure."

Sadeer B. Hannush, MD, a professor of ophthalmology at the Sidney Kimmel Medical College of Thomas Jefferson University and attending surgeon on the Cornea Service at Wills Eye Hospital in Philadelphia, recommends that surgeons learning these fixation methods familiarize themselves with one technique first and do it over and over again until they become comfortable with it and proficient in the use of the technique.

"Don't try to be a Jack-of-all-trades," he says. "Most surgeons won't have enough of these cases to do them on a regular basis. There are very few of us who do. After more than 30 years in practice and with a referral base of more than 100 ophthalmologists, I still do no more

than one or two a week. I don't think I've ever had a year with more than 100 of these cases. There just aren't that many out there. Because a comprehensive ophthalmologist doing this kind of work may have only one or two cases per year, picking a technique they're comfortable with is key. Otherwise, they should refer these cases out."

Knowing your strengths and weaknesses will ultimately benefit you. "If the lens migrates posteriorly, for example, you may have to refer it to someone who's comfortable fishing it out and taking over the case," Dr. Hannush says. "If you have access to a retinal colleague who can join you on the case, they can do the pars plana vitrectomy and float the implant up for you into a location you can reach it."

Anterior Chamber Fixation

The anterior chamber can hold an IOL, but surgeons note that it isn't an ideal location for an implant, given such close proximity to the cornea. The innovation of the flexible open-loop anterior chamber IOL has led to less inflammation

This article has
no commercial
sponsorship.

Dr. Hannush and Dr. Gorovoy have no related financial disclosures.

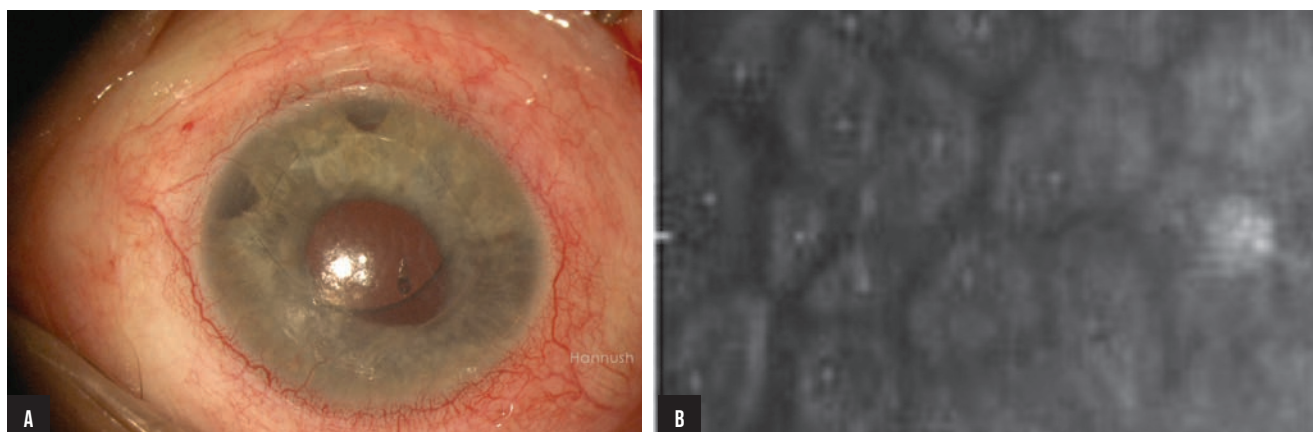


Figure 1. Ovalization of the pupil secondary to iris tuck is a potential complication of AC IOLs (A). This same patient also had a low endothelial cell count with pleomorphism and polymegathism (B).

in the angle than its predecessor, the rigid closed-loop AC IOL, but these lenses—even when properly placed—may lead to long-term complications such as endothelial decompensation, chronic inflammation, uveitis-glaucoma-hyphema (UGH) syndrome or cystoid macular edema. Additionally, because most AC IOLs are made of polymethylmethacrylate, they aren't foldable and require a scleral tunnel or a large, typically 6-mm corneal incision for insertion, which may induce astigmatism.

Though a retrospective analysis comparing AC IOLs to sutured PC IOLs found no statistically significant difference in BCVA outcomes or complications,¹ Dr. Gorovoy says he's adamant that no one receive an AC IOL today. "The angle isn't a place for a foreign body with micromovement," he says. "We've seen this over and over again. It's a relatively simple procedure if there's enough iris to support the anterior chamber lens, but there are too many issues with these implants."

Dr. Hannush almost always avoids AC IOLs, preferring scleral fixation of PC IOLs. "AC IOLs are a setup for chronic inflammation, glaucoma and corneal endothelial damage," he adds. "That being said, you shouldn't write them off completely. If the surgeon is most comfortable implanting an AC IOL and doesn't have access to a surgeon skilled in

scleral fixation, then an AC IOL may be an option, albeit not ideal, and the patient may benefit from this lens—at least in the short term. You should do what's best for the patient in your hands."

Here are some things to keep in mind when performing anterior chamber IOL placement:

- **Consider the patient's age.** Dr. Hannush says that some patients may do well with an AC IOL in the short term, especially if they're older. "Those with a limited life expectancy can be visually rehabilitated with an AC IOL, possibly for the rest of their remaining days," he says. "In my hands, the only scenario in which I might find it reasonable to implant an AC IOL is in an older (90 to 95 years), monocular patient with an intact anterior hyaloid face, an open angle 360 degrees around, and for whom I wouldn't want to extend the surgical time because of the increased risk of bleeding or other intraoperative complications. That same patient may also benefit from aphakic glasses or a contact lens."

- **Select the appropriate-sized lens.** A properly sized AC IOL is based on the white-to-white measurement. However, every patient's limbal anatomy is different, resulting in significant variations in AC IOL size estimates.²

"There's no one-size-fits-all AC IOL," says Dr. Hannush. "An un-

dersized implant will propel in the anterior chamber, and an oversized AC IOL will vault anteriorly and/or the haptics will dig into the iris or ciliary body. Very few surgery centers keep AC IOLs of various sizes on consignment anymore—most of the ones available to the surgeon are all the same size."

- **Ensure that the haptics are positioned correctly.** "The four haptics of the flexible open-loop lens should end up on the scleral spur," Dr. Hannush says. "If you're able to do intraoperative gonioscopy, that would be ideal."

Iris Fixation

In the United States, surgeons perform retropupillary iris fixation of a three-piece PC IOL. This method has the advantage of placing the IOL closer to the nodal point and rotational axis of the eye than an AC IOL.³

Abroad, anterior chamber iris-clawed or -clipped implants such as the Artisan lens (Ophtec) have been in use for decades but were never made available in the United States in powers for use in aphakic eyes. (The version of the iris-claw lens that is available in the U.S. comes in only very high negative powers [e.g., -12 D or -14 D] and is meant for phakic patients with high myopia.) These lenses are inserted through an approximately 5-mm incision, and

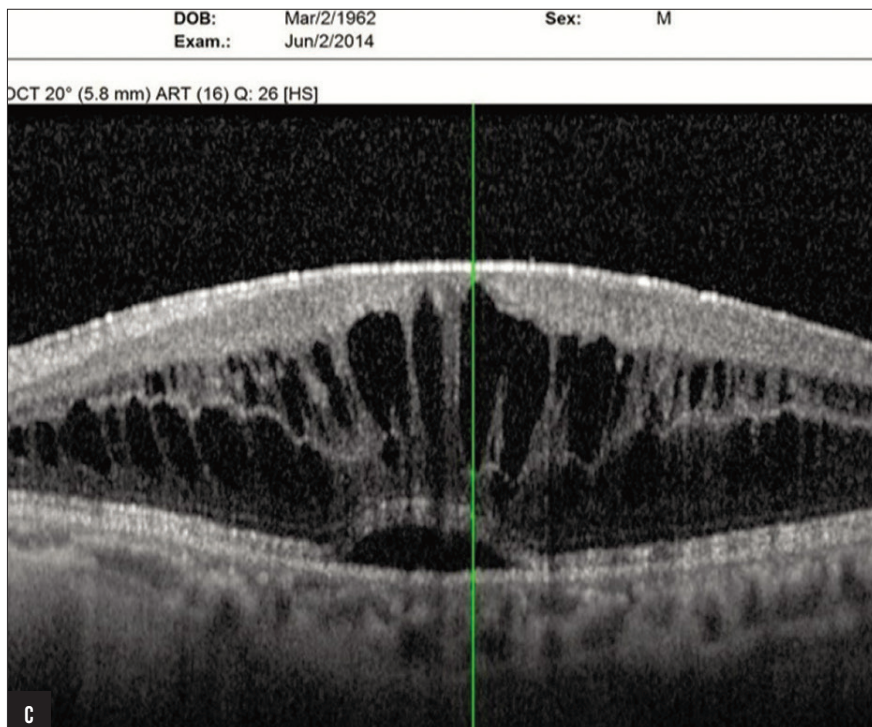


Figure 1C. The same patient (seen in Figures 1A and B) also had marked cystoid macular edema associated with the AC IOL in the left eye.

the iris is “clipped” to the implant by drawing tissue between the claws with an enclavation needle.

“One of the nice things about the retropupillary iris fixation technique is that you can put a foldable lens through a small incision,” says Dr. Hannush. “It’s also less involved than sclerally fixating an implant. You place the lens behind the iris and pass a 10-0 polypropylene suture to imbricate the haptics into the iris. There’s a potential complication of chronic inflammation when you suture an implant to a uveal structure, especially in the presence of iridodonesis, however. For this reason, I don’t favor iris fixation.”

Dr. Gorovoy agrees. “I don’t think iris-supported lenses are quite as potentially injurious to the anterior segment and eye in general as AC IOLs, but I don’t do iris-sutured IOLs. The iris isn’t the best place to be hanging any hardware.” Other complications of iris fixation include UGH syndrome and pigment dispersion from rubbing on the implant.

When performing iris-sutured fixa-

tion, surgeons say pupil anatomy and technique are key. “A good candidate for this procedure is a patient who’s aphakic, or has been rendered aphakic by complicated cataract surgery, but has a nice, round pupil,” Dr. Hannush says. “You can suture a lens on the back surface of the iris if you have no qualms about doing that. You can avoid ovalizing the pupil by suturing the haptics of the implant as peripherally as you’re comfortable with.”

Sutured Scleral Fixation

“Securing an implant to the scleral wall is a very effective—and my preferred—technique,” says Dr. Hannush. While it’s more involved than anterior chamber or iris fixation, many surgeons consider it to be the procedure of choice—with proper training.

In general, posterior chamber implants are preferable since they approximate the position of the natural lens and are less likely than anterior chamber implants to result in corneal decompensation over

time. But scleral-fixated implants also have the advantage of being suitable for almost all patients who need a secondary IOL.

“Any patient who’s going to get a secondary IOL and has no capsular support is a good candidate for scleral fixation,” Dr. Gorovoy says. “That’s the nice part of it—every eye has a sclera. We don’t depend on the iris or the angle.”

“We used to use 10-0 polypropylene suture, but that may have been too fine a suture; it would sometimes break or cheesewire after 10 to 15 years, leading to dislocated lenses,” Dr. Hannush says. “More recently we’ve been using 8-0 Gore-Tex or 9-0 polypropylene because they’re more durable.”

When considering whether to suture an implant to the sclera or not, surgeons recommend keeping the following in mind:

- **For certain patients, keep the procedure short.** “If a patient has multiple risk factors for suprachoroidal effusion or hemorrhage, such as hypertension, peripheral vascular disease or glaucoma, or if the patient is on blood thinners and can’t stop them, then I wouldn’t want to extend the procedure to sclerally fixate a PC IOL,” Dr. Hannush says. “I also wouldn’t make a large incision to implant a one-piece PMMA IOL, for all the obvious reasons.”

- **Select the appropriate lens.** Dr. Hannush says the best lenses for suturing to the sclera are one-piece PMMA lenses with eyelets on the haptics like the CZ70 BD (Alcon). “The foldable lenses don’t have eyelets on them, but you can still suture a foldable lens,” he notes.

Some surgeons have used the three-piece hydrophobic acrylic MA60AC or MA50BM (Alcon) or AR40 or ZA9003 (J&J Vision), the hydrophilic acrylic Akreos AO60 (Bausch + Lomb), the one-piece hydrophobic acrylic enVista MX60 (Bausch + Lomb) or the hydrophobic acrylic CT Lucia 602 (Zeiss). The last lens has polyvinylidene



Custom Pak[®]
SURGICAL PROCEDURE PACK

Alcon CUSTOM PAK[®]

SURGICAL PROCEDURE PACK

YOUR PROCEDURE. OUR PRIORITY.

**ALWAYS THERE. ALWAYS READY.
BECAUSE YOU DESIGNED IT THAT WAY.**

Alcon prioritizes the thing you don't need to worry about, equipping you with complete surgical packs, customized for each surgeon. Alcon Custom Pak[®] ensures that you are ready for every procedure, every time.

Your focus is on patients. We make sure it stays that way.

SEE HOW WE DO IT AT

www.myalcon.com/custompak

Alcon



fluoride (PVDF) monofilament haptics, whose strength makes them ideal for intrascleral haptic fixation, although not necessarily for suture fixation, some surgeons say. “Three-piece IOLs are better suited for ISHF than for scleral suturing,” says Dr. Hannush.

• **Bury your knots.** Suture knot erosion is easily avoided by burying the knot. “You don’t want a knot on the surface, especially if you’re using 8-0 Gore-Tex,” says Dr. Hannush. “If using 9-0 or 10-0 polypropylene, you can leave a knot on the surface of the sclera as long as the rabbit ears of the knot are long and can be tucked under conjunctiva. If the suture ends are short, they’ll erode through the conjunctiva and out of the eye, and then you’ll have direct communication between the ocular surface and the inside of the eye, which puts the patient at risk for endophthalmitis.”

Sutureless Scleral Fixation

Many surgeons have now adopted sutureless scleral fixation methods. Currently, the two most popular ways to secure a posterior chamber implant to the sclera without sutures are the glued IOL technique and the Yamane technique.

Amar Agarwal, MD, of Chennai, India, and his colleagues first described the glued IOL technique in 2007. This technique externalizes the haptics of a three-piece IOL through two sclerotomies spaced 180 degrees apart, which are then secured by tucking each haptic end into a tunnel. Glue is then applied to the haptics and the flaps are replaced over them.

In 2016, Shin Yamane, MD, of Yokohama, Japan, presented his flanged haptic technique, which requires neither glue nor sutures. The Yamane technique externalizes the haptics of a three-piece IOL through two sclerotomies and secures them by creating a flange with low-temperature cautery at the end of each haptic that prevents it from sliding

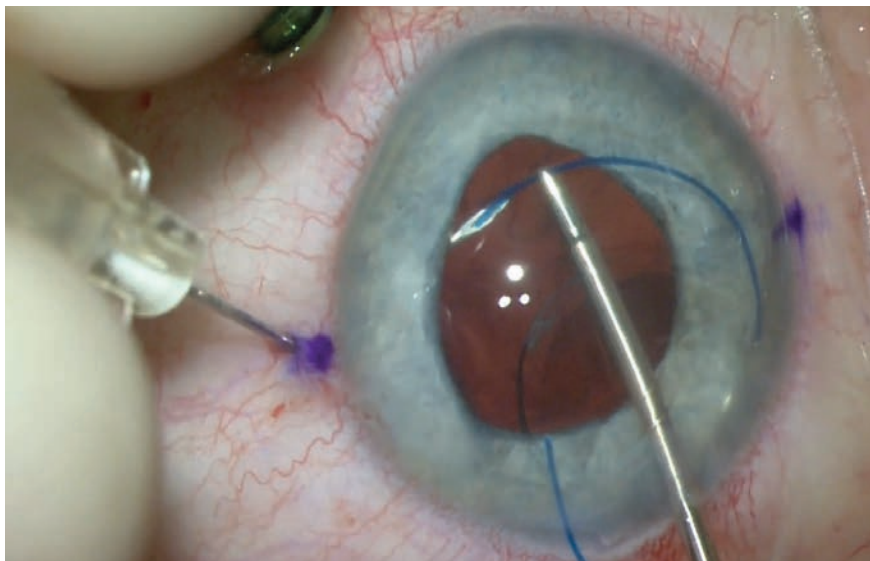


Figure 2. Intrascleral haptic fixation of a PC IOL using the Yamane technique. This technique requires familiarity with performing pars plana vitrectomy and creating scleral tunnels with a wide-bore, thin-walled, 30-gauge needle.

back into the posterior chamber.

Besides avoiding complications related to sutures, an advantage of these techniques is that they’re intended for foldable implants. Dr. Hannush notes that this reduces the risk of iris prolapse, leakage, shallowing of the anterior chamber and suprachoroidal hemorrhage, mainly because of the small size of the incision compared to that required for suture fixation of a one-piece PMMA IOL.

Additionally, sutureless techniques take less time. “While sutureless scleral fixation requires a little more skill than suturing, it results in a quicker procedure with a shorter rehabilitation period,” Dr. Hannush says. He notes that the glued IOL technique takes a little longer to perform than the Yamane technique because there’s more dissection involved. “You have to take the conjunctiva down and create scleral flaps,” he says. “Any of the three-piece hydrophobic acrylic IOLs mentioned in the previous section may be used for ISHF, but the CT Lucia 602 from Zeiss is ideal mostly because of its PVDF haptics.”

Dr. Gorovoy points out that the

Yamane technique doesn’t involve any dissection, so placement isn’t restricted by a requirement of “good real estate” that the glued IOL technique needs for flap creation. “The haptics can be near a bleb or a shunt,” he says.

“The Yamane technique is more difficult, however,” he continues. “For one, you’re threading needles through a soft eye, so you’ll need an anterior chamber maintainer or trocars. It’s also difficult to achieve centration, and you may get some tilt. Keeping your needles symmetrical is also a challenge because you’re passing blind needle tracks through the sclera. At the end of the day though, it doesn’t have to be perfect, just good.

“When done properly, it’s highly unlikely that the lens will dislocate again with the Yamane technique,” he says. “It’s by far the most secure method. This has a downside though: You won’t know how well-centered the lens is until you finish the procedure, and if you’re not happy with the centration or there’s tilt, it’s a big deal to redo. If the lens had been sutured and then decentered, you could just cut the suture and put in another.”

WIDELY AVAILABLE



Sustained Delivery with DuraSite® Technology

AKORN | EYE CARE



MyAkornEyeCare.com
for office resources



Learning these techniques is a challenge, but well worth the effort if you're able to achieve proficiency, say surgeons. Here are some strategies for good outcomes:

• **Be familiar with pars plana vitrectomy.**

"Familiarity with this technique is key for any scleral fixation method, especially sutureless," Dr. Hannush says. "You need to remove the anterior vitreous body, and this is best achieved through the pars plana."

• **Be familiar with a sutureless ISHF technique.** There are two options:

—The glued IOL technique requires familiarity with the handshake technique: "While the IOL is introduced into the anterior chamber with one hand, introduce a forceps through one sclerotomy site to grasp the leading haptic and externalize it," Dr. Hannush says. "Through the other sclerotomy site, grasp and externalize the trailing haptic by transferring it from one hand to the other."

—The Yamane technique requires familiarity with creating scleral tunnels with a wide-bore, thin-walled, 30-gauge needle that then receives the haptic of the IOL, externalizes it, then fixates it in the tunnel after creating a flange at the tip of the haptic with cautery.

• **Mark the limbus precisely at 180 degrees.** This is critical for achieving centration, especially if you're using a multifocal lens. Dr. Gorovoy performs the Yamane technique with a limbal marker of his own design. "You need a marking system so your haptic needle placement is as symmetric as possible for optimal centration," he says. "You don't want to have to

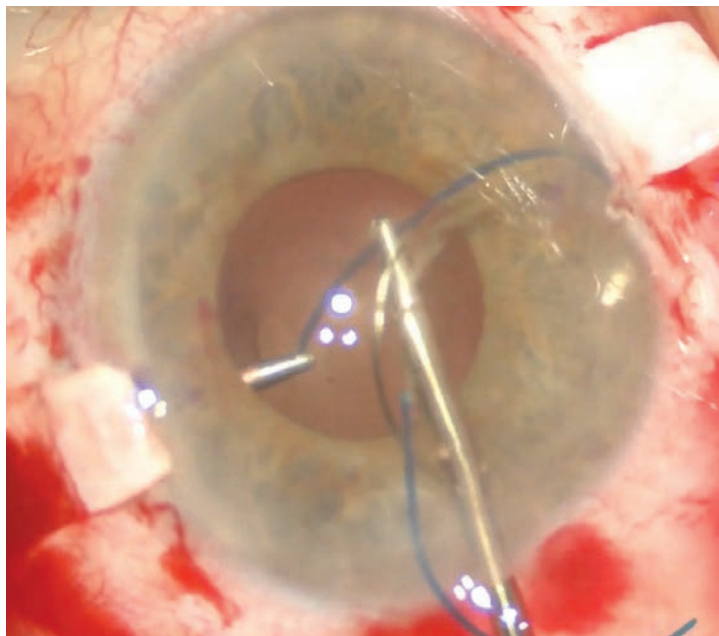


Figure 3. The handshake maneuver is used for PC IOL haptic exteriorization while performing the glued IOL fixation technique.

redo it."

• **Choose a lens with sturdy haptics.** "The glued IOL technique is more forgiving, and you can use any three-piece lens," says Dr. Hannush. "In the Yamane technique there's more haptic manipulation, so you want to have a lens with sturdy haptics. The CT Lucia 602 (Zeiss) and the AR40 (J&J Vision) are good options."

• **Ensure the haptics are secure.** "If the haptics aren't secured properly into the scleral wall, the implant will either rotate or slip into the eye and migrate posteriorly," Dr. Hannush says. He offers the following advice: "For the glued IOL technique, deliver the IOL haptics into 26-gauge scleral tunnels for fixation. After placing an air bubble in the anterior chamber, inject reconstituted fibrin sealant to close the scleral flaps and conjunctival peritomies.

"For the Yamane technique, use hand-held cautery to flatten the haptic ends into a flange—a mushroom, pear-shaped or nail-head configuration. Push the haptic back through the conjunctiva into the sclera so the flange can barely

be seen on the scleral surface.

Which Method Should You Choose?

While some methods have more serious complications than others, prospective studies haven't proven the superiority of one method over another.⁴ Experts say the procedure you choose depends not only on what you're most comfortable with, but also on the type of lens you're working with.

For Dr. Gorovoy and Dr. Hannush, a sutureless scleral fixation method is the optimal approach. "If the patient is aphakic or

rendered aphakic and has a normal iris, my go-to technique is almost always a sutureless method," Dr. Hannush says. "But if part of the iris is missing, I'd want a larger lens such as the CZ70BD, which has a 7-mm optic; this lens must be sutured. Alternatively, a sutureless foldable IOL may be combined with an artificial iris prosthesis."

Dr. Gorovoy says his choice of scleral fixation depends heavily on the type of lens involved. The most common referrals he gets now are for pseudophakic eyes with loose or dislocated PC IOLs. "We're seeing almost a mini-epidemic of late IOL dislocations now," he says. "These are patients who had cataract surgery years ago with no problems. Then years later, the implant and capsular bag—usually the whole complex—dislocates. Twenty years ago, the major referral source would have been for removing AC IOLs and putting in new scleral-supported lenses, but because fewer AC IOLs are used now, we don't see as many of those cases, thankfully. Now, it's dislocations."

He says the main reasons for this host of late dislocations are pseu-

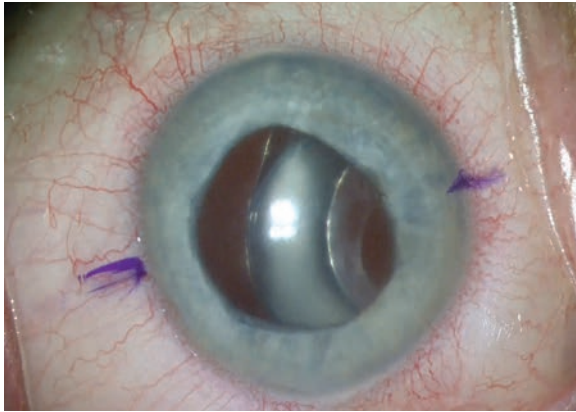


Figure 4. A subluxated one-piece acrylic PC IOL-capsular bag complex. One-piece acrylic lenses can be sutured if they're still in the bag. The thick haptics on these lenses must be wrapped by the capsule to prevent chafing.

doexfoliation syndrome and prior vitrectomy. “Many of these eyes had prior vitrectomies for retinal surgery,” he says. “It’s unclear why vitrectomy leads to later dislocation, but vitrectomized eyes behave differently. Bleeding can also be an issue for patients on anticoagulation medications.”

“When the lens is in the eye, dislocated, I’ll often use sutures because most of these lenses aren’t three-piece lenses,” Dr. Gorovoy says. “Unfortunately the trend in cataract surgery has been single-piece acrylic lenses. Those can be sutured if they’re still in the bag, but you can’t sclerally fixate them with a sutureless method.

“If I put in a new lens, I’ll almost always use the Yamane technique with three-piece lenses,” he adds. “Others favor single-piece PMMA lenses, but those require a much larger incision. The nice thing about the Yamane technique is that it’s done through an approximately 3-mm incision.”

Occasionally, patients with a subluxated lens are still happy with their vision. If that’s the case, surgery isn’t always warranted. Dr. Hannush cautions that it’s important to weigh the pros and cons of performing surgery on this group. “The first question you have to ask yourself as an examiner is, ‘Is the

IOL position affecting the patient’s vision?’ I don’t usually intervene on patients with subluxated implants if they’re asymptomatic,” he says. “The risk of surgery outweighs the risk of doing nothing. If you intervene later when they’re symptomatic, the surgery is justified. Then, you can do a lens exchange and suture or intersclerally haptic-fixate the lens to the scleral wall. I don’t usually re-fixate the

same lens; in most instances I prefer to exchange it, for many reasons, but many surgeons prefer to re-fixate the same IOL because of the perceived relative safety of this approach.”

Dr. Gorovoy is one of those surgeons. “Opening the eye with larger incisions or when using sutures puts the eye at greater risk for expulsive hemorrhage,” he cautions. “I believe it’s better to keep the eye closed than to open it up. By that principle, I try to take a dislocated IOL and keep it in the eye rather than take it out and exchange it for a new lens. Typically, I sew it to the sclera with 9-0 polypropylene and use a lassoing technique to lasso the haptic, sometimes pass it through the capsule, and secure it to the sclera.

“There are situations when you’ll have to extract the lens and put in a new one—sometimes because the current lens can’t be sutured or because it popped out of the bag and it’s a single-piece lens,” continues Dr. Gorovoy, who prefers to use the Yamane technique for a lens exchange. “We don’t want to suture single-piece lenses. Anything suture-fixated must be in the bag or be a three-piece lens or a single-piece PMMA lens, but it cannot be a single-piece acrylic lens. Acrylic lenses tend to have thick haptics, typically with square edges. If you suture them, they’ll chafe the iris

and you’ll end up with UGH syndrome. For this reason we also don’t put those lenses in the sulcus. They have to be wrapped by the capsule.”

The Future of Fixation

With today’s advanced technologies and methods, surgeons say that large refractive errors are no longer acceptable. As noted earlier, however, achieving centration can be challenging with alternative fixation of IOLs, especially when using scleral fixation methods.

“When we do these scleral techniques, the calculations we use to figure out the lens power aren’t nearly as exact as they would be with routine cataract surgery,” Dr. Gorovoy says. “We don’t know exactly where the position of the lens will end up, and many of these eyes had prior surgery and may have significant preexisting astigmatism.”

He says the light adjustable lens (RxLAL, RxSight) has potential for these cases. “I have some reservations about silicone optics in aphakic eyes, which are complicated and may end up with future retinal detachments, but the idea of sclerally fixating a lens and being able to adjust the spherical corrections is really appealing. Ideally, we’d like to have a lens that can do that but with a haptic material that’s very flexible and forgiving to get in the needle tracks—something similar to that of the Zeiss lenses’ polyvinylidene fluoride monofilament haptics. I think an advance in this direction would make a big difference.” ◀

1. Donaldson KE, Gorscak JJ, Budenz DL, et al. Anterior chamber and sutured posterior chamber intraocular lenses in eyes with poor capsular support. *J Cataract Refract Surg* 2005;31;5:903-909.
2. Hauff W. Calculating the diameter of the anterior chamber before implanting an artificial lens. *Wiener Klinische Wochenschrift* 1987;171:1-19.
3. Yazdani-Abyaneh A, Djallilian AR, Fard MA. Iris fixation of posterior chamber intraocular lenses. *J Cataract Refract Surg* 2016;42:12:1707-12.
4. Shen JF, Deng S, Hammersmith KM, et al. Intraocular lens implantation in the absence of zonular support: An outcomes and safety update. A report by the American Academy of Ophthalmology. *Ophthalmol* 2020;127:9:1234-58.



E-SURVEY: FAVORITE CATARACT TECHNIQUES

Cataract surgeons weigh in on such aspects of surgery as managing astigmatism and femto cataract.

BY WALTER BETHKE
EDITOR IN CHIEF

On our annual cataract surgery technique survey, safety and efficiency rule the day, with many surgeons choosing their nucleofractis technique and astigmatism-management method with these factors in mind. Also, surgeons who use femtosecond cataract say it enhances their results, but half of the respondents still aren't sold on it.

This year, 1,688 of the 12,055 surgeons receiving the survey opened it (14 percent open rate), and 109 completed the survey. To see how your favorite techniques compare with theirs, read on.

Phaco Technique

Surgeons shared their thoughts on the best way to break up the nucleus.

Quadrant division remained the most popular method, chosen by 38 percent of the respondents. Twenty-one percent prefer to use stop-and-chop, and 12 percent like a vertical phaco chop maneuver. The rest of the results appear in the graph on

the opposite page.

"I prefer quadrant division for its simplicity, the fact that it's tried-and-true, reliable and very rarely predisposed to complications," says a surgeon from Minnesota. Curtin G. Kelley, MD, of Columbus, Ohio, says quadrant division is "efficient and safe in nearly all cataract types."

Ligaya Prystowsky, MD, of Nutley, New Jersey, likes to use quadrant division together with other methods. "I combine it with other techniques depending on the density of cataract and zonular dehiscence. I have a good comfort level with it, since performed it for over 30 years," she says.

"Quadrant division uses less phaco energy near the cornea," says a surgeon from Michigan.

Many surgeons who like the stop-and-chop technique say it's safe and efficient. "I use stop-and-chop because it's easy when approaching any kind of cataract," says one surgeon. A surgeon from Utah likes stop-and-chop for specific maneuvers. "It gives the surgeon better control of nuclear removal with initial groove and crack, then vertical chop," he

says. A surgeon from San Antonio likes stop-and-chop's versatility. "It's good for a wide variety of lenses," he says. Another surgeon chooses stop-and-chop because it, "Lets me do a quick debulking of the nucleus, and allows more spaces for subsequent chop." A surgeon from California says, "I like stop-and-chop because of its consistency."

Ben Mackey, MD, of Corbin, Kentucky, prefers a vertical phaco chop technique. "Low phaco power is needed [with this technique] and I can chop with a small pupil and still visualize the case," he says.

Managing Astigmatism

Just like last year, a toric intraocular lens is the preferred option for astigmatism management among our respondents (chosen by 56 percent of them).

"For over a diopter of astigmatism I use a toric IOL because it's effective and predictable," says Daniel Pluznik, MD, of Washington, D.C. "For less than one diopter I use femto LRI." Jeffrey Whitman, MD, of Dallas uses the toric because, he says, "It's the most accurate for

This article has no commercial sponsorship.

getting rid of all of the astigmatism.” Many of the surgeons like the toric’s predictability. “[With it] I’m able to better predict lasting outcomes compared to an LRI,” says a surgeon from Oregon.

Dr. Prystowsky likes the options available for toric lenses. “There are more choices now with premium IOLs,” she says.

The next most popular option, a toric lens combined with femtosecond astigmatic keratotomy, was chosen by 15 percent of the surgeons.

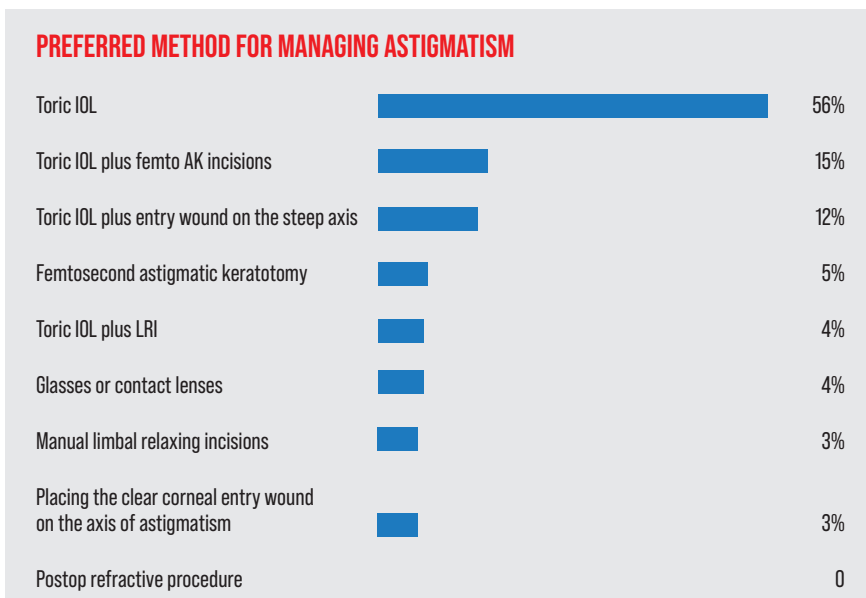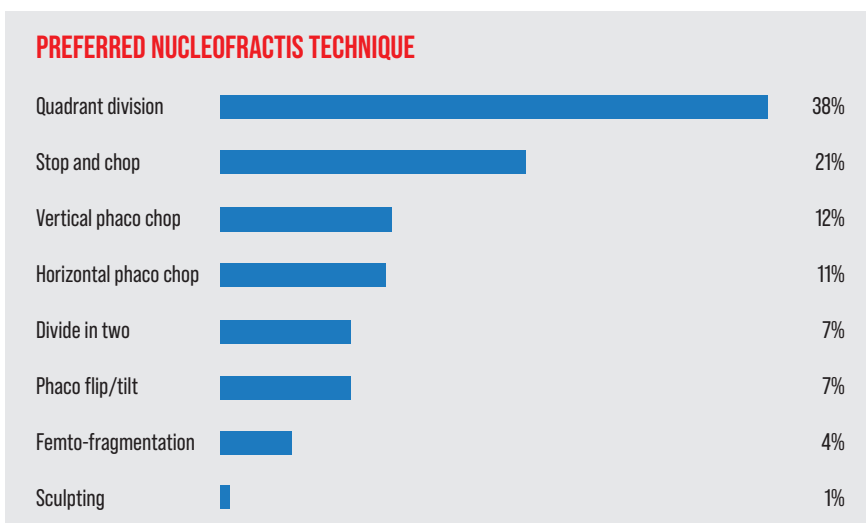
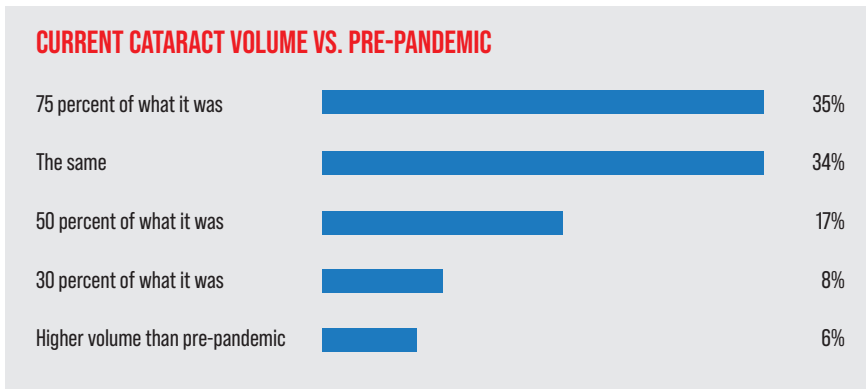
“It works well. But this does depend on the amount of astigmatism,” says a surgeon from Ohio. A surgeon from California likes an IOL with femto AK because, she says, “It’s accurate and adjustable.” A surgeon from Texas says this approach is “Great for a wide variety of treatments.”

One surgeon voices the opinion of many on the survey, saying, “I use every method depending on whether there’s a small, medium or large amount of astigmatism. You customize the treatment—there is not typically one option.”

Femto or No?

An often talked about but not often done variety of cataract surgery is femtosecond-assisted cataract. Half of the respondents don’t use the femtosecond laser in conjunction with surgery. For those who do use it, they use it mostly for correcting patients’ astigmatism (49 percent), fragmenting the nucleus (48 percent) and for creating the capsulorhexis (47 percent). (Surgeons were able to choose more than one answer regarding how they use the femtosecond, if at all) None of the surgeons on this year’s survey use the Zepto device for the creation of a capsulotomy.

Most of the surgeons (65 percent) who perform femtosecond-assisted cataract surgery say their volumes are either staying the same (45 percent) or decreasing (20 percent) in recent months. Thirty-seven percent



of the respondents say their femto-ataract volume is increasing.

Surgeons opined on why they use the femtosecond. “It’s precise, reliable, and is good for marketing

and for earning additional income,” says a surgeon from Tennessee. Alan Aker, MD, of Boca Raton, Florida, appreciates what the laser brings to his procedures. “It reduces energy



and protects the cornea—especially in patients with dense nuclei and/or low endothelial cell counts,” he says. “A perfect capsulorhexis is helpful. Our goal is to do everything to optimize a patient’s outcome and achieve 20/20 for all patients one day after surgery. We always use femto with premium IOLs.” Jimmy Hu, MD, of New York City agrees, saying, “It gives a perfect capsulotomy every time, and provides good control of astigmatism correction.”

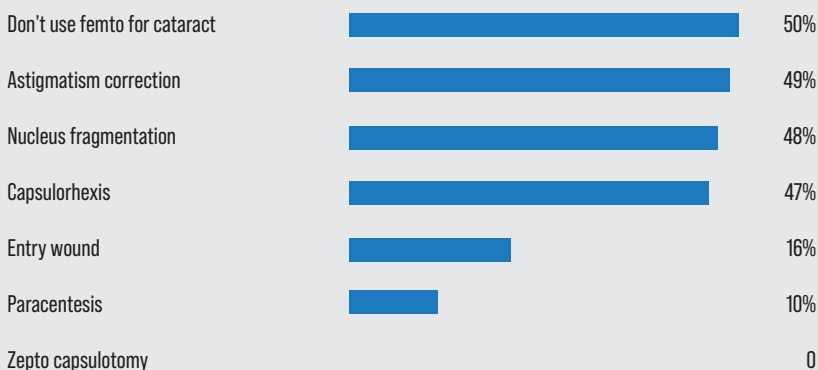Then, there is a contingent that uses femto, but also sees room for improvement. “I like the reliable LRI’s and nuclear disassembly,” says Steven Pascal, MD, of Oakland, California. “I don’t like the unreliable incisions, and the fact that it makes cortex removal exponentially more difficult.”

“It prefragments pieces during phaco but can lead to bag rupture with the bubbles in the bag it causes,” says Naja Chisty, MD, of Columbia, Missouri. A surgeon from New Orleans agrees there are pros and cons to consider. “I don’t like the cost factor,” he says. “I’d prefer to use it for all NSC of 3+ or greater. I do like the precision of the capsulorhexis and nucleus fragmentation in denser NSC.”

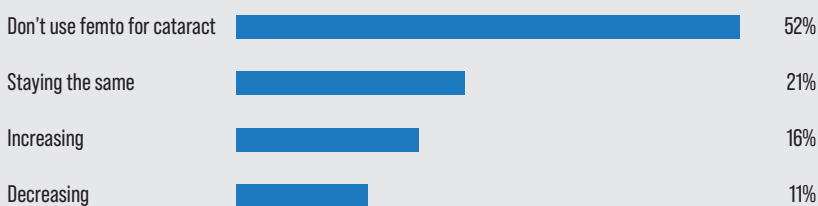
Looking down the road, 20 percent of the surgeons say they’re likely to use femtosecond cataract surgery in the future, and 11 percent say they’re “somewhat likely” to do so. Sixty-six percent say they’re unlikely to start performing it.

For the group that doesn’t plan to use it (66 percent of respondents), the femtosecond has issues that are deal-breakers for them. “It increases the risk of capsulotomy tear compared to my manual capsulorhexis technique,” says Carl Clavenna, MD, of Birmingham, Michigan. A surgeon from California says the femtosecond “is too expensive and time-consuming.” A surgeon from New Jersey agrees, saying, “I stopped after 25 cases. There was no increase in complications, but it add-

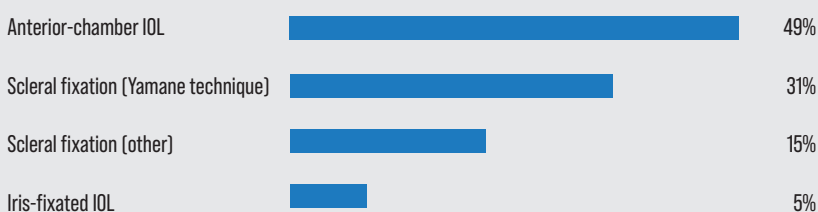
SURGEONS’ USE OF FEMTO OR ZEPTO FOR CATARACT SURGERY



SURGEONS’ FEMTO CATARACT VOLUME



PREFERRED METHOD OF IOL FIXATION WITH NO CAPSULAR SUPPORT



ed too many steps, costs and time to patient care.” An ophthalmologist from Oregon believes his current methods serve him and his patients well. “Femto cataract surgery is a solution looking for a problem,” she says. “It’s just a way to jack up the bill to compensate for sub-\$600 surgery. It’s no better or safer than conventional phaco. Patients pay for it out-of-pocket because they think it’s better and a ‘laser’ is used.” However, one surgeon appreciates femto’s efficiency. “I think it is excellent for nucleus fragmentation and capsulorhexis,” he says. Another surgeon likes femto-cataract because it “makes the surgery a little safer

and it reduces phaco energy,” but, he says, “It costs too much.”

Technique Potpourri

The survey’s respondents also shared their views on several other aspects of surgery.

• *Intraoperative wavefront aberrometry.* Fifty-seven percent of the surgeons don’t use intraoperative aberrometry to select and place intraocular lenses. Of the ones who do use it, 17 percent say it gives them excellent outcomes, 47 percent say its outcomes are good, 23 percent think they’re fair and 13 percent think the outcomes are poor.

“Intraoperative aberrometry is

The Many Benefits of a Pre-op Patient Prep Kit

Pro tips on how to help patients prepare their eyes for surgery



Neel Desai, MD
Eye Institute of West Florida



Marjan Farid, MD
University of California Irvine



Cynthia Matossian, MD
Matossian Eye

Responding to demand from eye care professionals, Bruder Healthcare recently introduced a pre-surgical prep kit containing the three core hygiene products patients need in a single, self-contained kit.

What benefits matter most to you?

Dr. Matossian: Ocular surgery results are dependent on pre-operative care. This is why it's important for patients to do their part to stabilize the ocular surface and keep lids healthy and clean.

Dr. Farid: Post-op comfort is an important goal in my practice. Patients feel dryer after surgery, but using these products before surgery, and then a week or so after surgery, really helps us get in front of that.

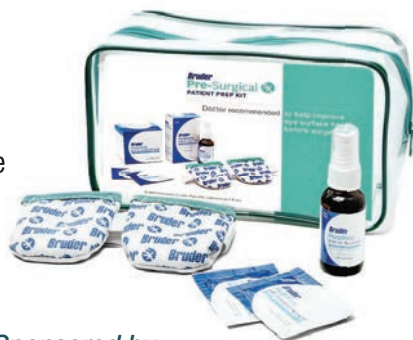Dr. Desai: By making this pre-op prep process routine, the patient is going to have a better experience overall because we are taking steps to reduce post-op dry eye, discomfort and infection while optimizing our pre-op measurements.

How do you anticipate patients will respond when you ask them to use the kit?

Dr. Matossian: Collecting multiple hygiene products online or at a pharmacy can be overwhelming and impractical for many patients preparing to undergo cataract or other corneal procedures. This kit removes that burden.

Dr. Farid: I agree; this is a significant practical benefit. This kit makes pre-op prep simple and straightforward. Now you can just say, "grab a kit on your way out."

Dr. Desai: This prep kit is a win-win-win for the patients, the practice, and the doctor.



Sponsored by

Bruder | Better. By Design.
www.brudersx.com | 888-827-8337

Which patient groups can benefit most from the kit?

Dr. Matossian: Some patients need more interventions than others, but, this kit addresses a common need. Preventing endophthalmitis and optimizing the tear film is important in every patient.

Dr. Desai: Some degree of dry eye is present in most cataract patients and preoperatively addressing ocular surface disease, particularly lid margin disease, is important in terms of preventing infections and in terms of getting more accurate biometry and a smoother post-operative course of recovery.

Dr. Farid: The prep kit is great choice for every pre-op cataract patient, regardless of the type of IOL they're getting, because we always want to optimize the ocular surface and proactively guard against infection.

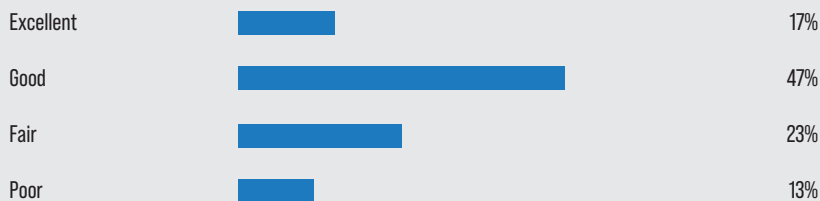
Included in the Kit

- **Bruder Hygienic Eyelid Cleansing Wipes.** These textured pre-moistened wipes contain a mild surfactant designed to remove build up, oil, dirt, pollen and desquamated skin that may cause eye irritation and infection.
- **Bruder Hygienic Eyelid Solution** (0.02% Pure Hypochlorous acid) Naturally-occurring hypochlorous acid (HOCl) has shown high efficacy against a wide range of microorganisms. Applying one to two sprays of the solution daily to closed eyes helps fight infection, reduce inflammation and bacteria, and enhance natural ability to heal.
- **The Bruder Sx Pre-Surgical Moist Heat Eye Compress.** This enhanced compress is designed specifically for the unique needs of the pre-surgical patient using EyeOnic™ fabric woven with antimicrobial silver threads. Like the original Bruder Moist Heat Eye Compress, the Sx mask is filled with self-hydrating, silver-infused, patented antibacterial MediBeads® to unclog meibomian glands and stabilize the tear film to improve pre-surgical measurements. Patients microwave the mask for 20 seconds then apply for 8-10 minutes.
- **Bruder Sx Case.** All of the essential items that pre-op patients need are neatly housed in an attractive, yet practical case that's large enough for doctors to customize by adding complimentary products, prescriptions or patient education paperwork.

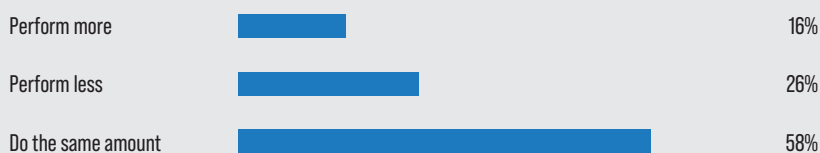
**Available now for in-office distribution
or patient referral online.**



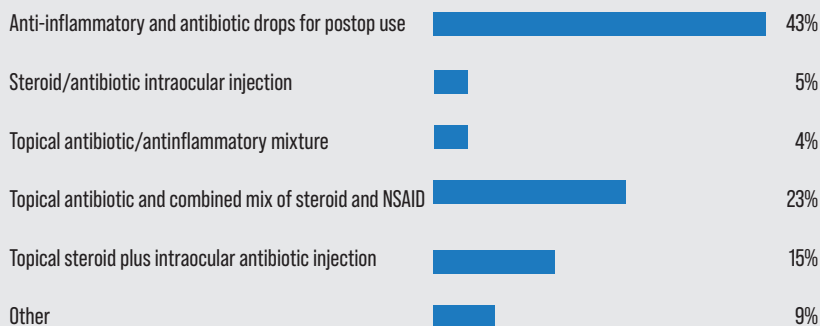
OPINION OF INTRAOPERATIVE ABERROMETRY, IF A SURGEON USES IT



SURGEONS' PLANS FOR INTRAOPERATIVE ABERROMETRY, IF THEY USE IT



POSTOPERATIVE INFLAMMATION CONTROL



good for refining sphere, especially in post-refractive cases,” says a Tennessee surgeon. “But it’s not great for the toric IOL amount, and alignment is very touchy. Overall, it’s not ‘fun’ to use.” Dr. Pascal takes issues with the technology, as well. “It helps align the axis of astigmatism,” he says. “But, on some occasions, it chooses a lens that is less accurate than if I had relied on the biometry calculations instead.” A surgeon from Kentucky agrees, saying, “It either confirms your pre-op measurements or it recommends a change which half of the time is wrong.” A surgeon from South Carolina says it may not be helpful in the cases that really need it, saying, “It still doesn’t address outliers of effective lens position.”

Chicago’s Jonathan Rubenstein, MD, however, says the technology is useful in challenging patients. “It yields increased IOL power accuracy in post-refractive-surgery patients,” he says. A Michigan surgeon appreciates intraoperative aberrometry in astigmats. “It’s very helpful in refining spherical power and lining up toric IOLs,” she says. Fellow Michigander Dr. Clavenna agrees, saying, “It helps me fine-tune the cylinder corrections.”

• *Promoting a wide pupil during surgery.* Surgeons have a variety of techniques at their disposal for managing a patient’s pupil. Here are the ones they turn to the most.

Forty-eight percent of respondents use an intracameral injection of epi-

nephine and lidocaine, 26 percent use mechanical pupillary dilation and 10 percent use Omidria (phenylephrine and ketorolac injection). Eighteen percent say they don’t take any additional steps. For those who use mechanical means to ensure dilation, most choose a Malyugin ring, with a small number saying that they rely on iris hooks.

“I’ll use a pupil expansion ring if the patient isn’t adequately dilated with meds,” says a surgeon from Oregon.

• *Surgical pearls.* The surgeons on the survey also provided their favorite tips for getting good outcomes:

— “Spend time with each patient to create a proper plan for outcomes, then keep the ultrasound energy to its lowest level for a quicker recovery.” (Curtin G. Kelley, MD)

— “Clean the back of the anterior capsule to keep the capsule periphery clear long term.”

— “With the sole exception of an expulsive hemorrhage, there is no necessity for immediate action. Take your time and be cool.”

— “Don’t overestimate your skill level. Be friends with a highly skilled surgeon, refer readily and learn. There’s very little margin for error and patients have HIGH expectations today.” (Timothy Hodges, MD, Tucson, Arizona)

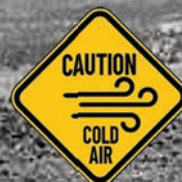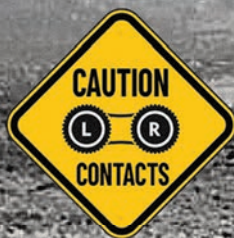— “Use a pre-chopper for speed, and lower phacoemulsification energy.” (Bill Clifford, MD, Garden City, Kansas)

— “Watch out for loose zonules. If the lens is moving as you’re grooving, increase the phaco power and be gentle.”

— “In eyes with a previous trab and 360 degrees of posterior synchiae, place Viscoat through the PI to free up iris from the lens capsule, then pierce the cyclitic membrane with a cyclodialysis spatula to allow placement of a Malyugin ring.”

Overall, one surgeon advises not to try to do too much. “Perfect is the enemy of good,” he says. ◀

FOR MOST PATIENTS, DRY EYE SYMPTOMS HAVE AN EPISODIC IMPACT



FLARES: THE SPEED BUMPS OF DRY EYE

Most patients with Dry Eye suffer from short-term, episodic exacerbations—**Dry Eye Flares**.¹⁻³

Many patients don't suffer from continuous symptoms.³

REENVISION
DRY EYE

kala
PHARMACEUTICALS

References: **1.** Brazzell RK, Zickl L, Farrelly J, et al. Prevalence and characteristics of dry eye flares: a patient questionnaire survey. Presented at: AAO 2019: October 12-15, 2019; San Francisco, CA. **2.** Brazzell RK, Zickl L, Farrelly J, et al. Prevalence and characteristics of symptomatic dry eye flares: results from patient questionnaire surveys. Poster presented at: AAOPT 2019: October 23-27, 2019; Orlando, FL. **3.** 2020 Study of Dry Eye Sufferers. Conducted by Multi-sponsor Surveys, Inc.



CATARACT EXTRACTION IN UVEITIC GLAUCOMA

These surgeries have always challenged the careful balance of controlling pressure and minimizing inflammation. Here are winning new strategies to keep in mind.

BY SEAN MCKINNEY
SENIOR EDITOR

As difficult as it may seem, performing cataract surgery on patients with uveitic glaucoma has become more manageable in recent years. Surgeons who rely on the latest approaches to these eyes are using better control of inflammation and intraocular pressure, as well as modern surgical techniques, to achieve outcomes once thought to be elusive.

This how-to update reviews current anti-inflammatory therapies, methods for controlling uveitis, the management of concurrent glaucoma, surgical principles, how to co-manage cases and how to provide successful postop care.

New Treatments

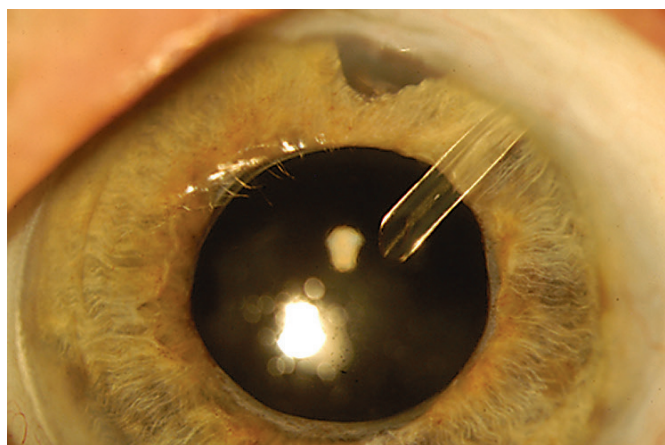
Surgeons believe that a wider range of steroid delivery options in and around the eye, as well as other immunosuppressive and immunomodulatory therapies, have increased the potential for success in these patients. They note that outcomes have also greatly improved because

of increased awareness of the importance of controlling inflammation aggressively.

“The many therapeutic options available to us start with topical steroids like Pred Forte and Durezol.

Treatments may escalate to sub-Tenon’s administration of betamethasone (Celestone) and triamcinolone

(Kenalog), followed by systemic steroid treatments, such as oral dexamethasone or prednisone,” says Mark A. Werner, MD, a glaucoma specialist and cataract surgeon from Delray Beach, Florida. “Alternative immunosuppressant therapies include conventional treatments, such as the generics methotrexate and cyclophosphamide, as well as azathioprine (Azasan, Salix; Imuran,



Deborah Loucks, CRA, COT

Figure 1. The postop view of a uveitic glaucoma patient who has undergone a phacoemulsification procedure combined with an Ahmed valve placement, corneal patch graft and sub-Tenon’s Kenalog treatment.

Prometheus). Appropriate biologic immunosuppressant therapies, for which I involve the co-managing support of a rheumatologist or uveitis specialist, include the tumor necrosis factor blockers, such as infliximab (Remicade, Janssen) and adalimumab (Humira, Abbvie).” (See “Using New Treatments Judiciously” on page 52.)

Sanjay J. Kedhar, MD, professor of

This article has no commercial sponsorship.

Dr. Werner is a speaker for Bausch + Lomb. Dr. Donnenfeld is a consultant for Allergan, Alcon, Novartis, Glaukos and Johnson & Johnson Vision. Drs. Al-Aswad and Kedhar report no relevant financial relationships with makers of products mentioned in this article.

ophthalmology at the University of California, Irvine, and director of the ocular immunology and uveitis service at the affiliated Gavin Herbert Eye Institute, emphasizes the use of the newer biologics to control inflammation most effectively and reduce uveitis-related complications during cataract surgery. “Although the older medications are good, I prioritize the use of agents such as adalimumab and infliximab,” he says.

Before formulating a treatment plan, anterior segment surgeon Eric Donnenfeld, MD, of OCLI Vision, at Island Eye Surgicenter in Westbury, New York, consults with other ophthalmologists and specialists to confirm the diagnosis of each case of uveitis, a complex and multi-faceted disease categorized according to its primary location in the eye and associated with more than 15 inflammatory conditions throughout the body. “I want to see a patient get an inflammatory workup, which could include consideration of infectious diseases, collagen vascular diseases and idiopathic diseases, such as Fuchs’ heterochromic iridocyclitis. (See *Differentiating Findings in Uveitis above*.) In most cases of uveitis, we don’t get a diagnosis because the condition is idiopathic. But if we can get a correct diagnosis, we can help patients with more focused therapy to eliminate inflammation, rather than using broad-spectrum therapy.”

Keeping Uveitis Quiet

Dr. Werner says the most important action to take in these cases is to wait. “I hold off on doing cataract surgery until at least three months after I’ve brought the patient’s inflammation completely under control,” he says. “There’s now evidence in the literature to support this classic teaching.¹ For Behçet’s disease, the recommended waiting time is six months.”

When managing these patients with steroids, Dr. Werner recommends extra vigilance in monitoring for increased IOP, mindful that you

DIFFERENTIATING FINDINGS IN UVEITIS

Doctors have recognized for years that uveitis isn’t a single entity, and so management requires multiple approaches to diagnosis and care. Here, Mark Werner, MD, a glaucoma specialist and cataract surgeon from Delray Beach, Florida, shares some examples of remarkable uveitis entities, with regards to cataract surgery.

- Fuchs’ heterochromic iridocyclitis is usually associated with a good outcome. The Amsler-Verrey sign is the occurrence of a filiform hemorrhage associated with fragile iris vessels after paracentesis at the outset of surgery. The issue can be easily resolved with viscoelastic tamponade.
- Intermediate uveitis (pars planitis) is associated with more posterior involvement, so it’s less likely to affect the anterior segment or cause posterior synechie. However, it’s associated more frequently with cystoid macular edema.
- Vogt-Koyanagi-Harada, sarcoidosis, Behçet’s and sympathetic ophthalmia are more often linked to severe posterior segment disease and may limit the visual prognosis. Counsel your patients accordingly.
- Juvenile idiopathic arthritis should be treated with aggressive suppression of inflammation. Glaucoma, hypotony and cyclitic membranes are all potential issues.
- Rheumatoid arthritis can (as observed anecdotally by Dr. Werner) be associated with poor encapsulation of drainage implants. Securing the plate well with non-absorbable sutures may be advisable when inserting a shunt.

—SM

might need to de-emphasize steroid therapy in favor of the conventional and biologic immunosuppressant therapies, requiring you to co-manage treatment with a uveitis specialist or rheumatologist.

“The patients who need these nonsteroidal treatments typically haven’t achieved good control of inflammation, despite aggressive steroid therapy,” he says. “Or they’ve experienced side effects from the steroids. This group may include patients with difficult-to-control anterior uveitis or posterior uveitis.”

Dr. Donnenfeld seeks to quiet inflammation with Durezol. “I usually go with four to six treatments per day, with a tapering dose,” he says. “This is the equivalent of using prednisolone acetate 15 or 20 times a day.”

When necessary, he switches to the other steroids mentioned above and, in the presence of posterior chamber inflammation, may resort to preoperative use of the intravitreal implants, 0.7 mg of dexamethasone (Ozurdex) and 0.18 mg of fluocinolone acetonide (Yutiq). “When these treatments are needed, I’ll seek the assistance of my retinal colleagues,” he says. “Then, when the patient is ready for surgery, I’ll perform a fastidious, meticulous, atraumatic procedure which I think is very important to minimize postoperative inflammation. I also

use aggressive postop inflammatory control after surgery.”

Dr. Donnenfeld says nonsteroidal anti-inflammatories, blocking COX-1 and COX-2, the cyclooxygenase enzymes associated with tissue damage, play a role in the perioperative period, but not in the long-term management of inflammation. “I use them a week before surgery on patients with uveitis,” he says, “as I want to eliminate any pre-existing prostaglandins that may contribute to postoperative inflammation. Postoperatively, my normal course of nonsteroidals is four weeks. When the patient needs to go out up to three months, I like using the new potent nonsteroidals, such as bromfenac (Bromday, Bausch + Lomb) and nepafenac (Ilevro, Alcon).”

In severe cases of uveitis, Lama A. Al-Aswad, MD, MPH, professor of ophthalmology and population health at NYU Langone Eye Center in New York City, says she treats her patients with “the big guns.” That means preoperative use of a steroid implant, immunosuppressant therapy (provided by a co-managing uveitis specialist) and prednisone. During cataract surgery, she says, she’ll infuse intravenous steroids in the operating room, which she administers to all uveitis patients in the OR, except those with out-of-control diabetes. “After surgery, I continue



with immunosuppressant therapy and continue to hit them with both steroids and NSAIDs,” she says. The patient will also most likely have uveitic glaucoma by then, so we’d need to manage the glaucoma as well. Our exact approach depends on the situation, of course.”

Glaucoma’s Ever-present Threat

While managing the complicated components of these cases, Dr. Kedhar cautions against overlooking the threat of glaucoma. “We must always keep in mind possible responses to steroid therapy,” he says. “In patients who have more advanced glaucoma or more severe responses to steroids, we may need to consider earlier introduction of the steroid-sparing therapies, such as Humira, Remicade and methotrexate. These treatments help control inflammation and avoid possible pressure spikes that can occur from the use of increased steroid treatment after surgery.”

He also watches for the need for glaucoma surgery. “Many of these patients may need this surgery at some point,” he notes. “It may make sense to do glaucoma surgery to help control the pressure before even performing the cataract surgery,” he says.

At the same time, he recommends not holding back on steroids, as needed, while trying to minimize risks of glaucoma. “We’ve found in our studies that we can reduce the risk of complications such as cystoid macular edema by 80 percent when we treat these patients preoperatively with oral steroids,” he observes. “I’d say that perioperative treatment with steroids is extremely important for achieving a good outcome for these patients.” Sub-Tenon’s injection or intravitreal injection of steroids just before surgery or at the time of surgery may prove to be a safe alternative for patients who can’t tolerate oral or local steroid treatment, he adds.

“Typically, with any of these treat-

Eric Donnenfeld, MD

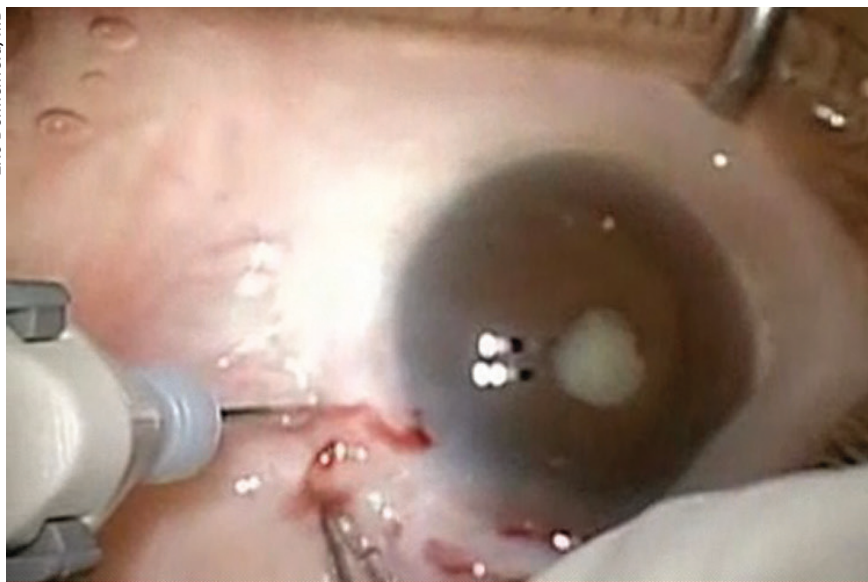

Figure 2. Patients with uveitis and glaucoma may have extremely small pupils and shallow anterior chambers. In the case shown above, a pars plana vitrectomy is needed to create anterior space to allow for removal of this patient’s Morgagnian cataract.

ments, we’d like to have the steroids working and on board for at least a few days before the surgery so that they help to minimize postoperative inflammation,” he adds.

Dr. Werner is always looking for signs of uncontrolled glaucoma. “Investigate for a history of steroid response or other episodes of increased pressure, especially after a flare-up or a previous intervention, such as cataract surgery in the fellow eye,” he says. “You may stir up inflammation with your surgery, and the patient may become too dependent on steroids for a period of time. You’ll want to look carefully at any glaucomatous damage and how effectively you’re able to control the intraocular pressure in the perioperative period.”

In these patients, he says, a flow-restricted tube shunt, such as the Ahmed valve, may be a good choice to bring the pressure down quickly. “This will also reduce the potential for the development of hypotony, which is another risk in this patient population,” he adds.

Varied Approaches

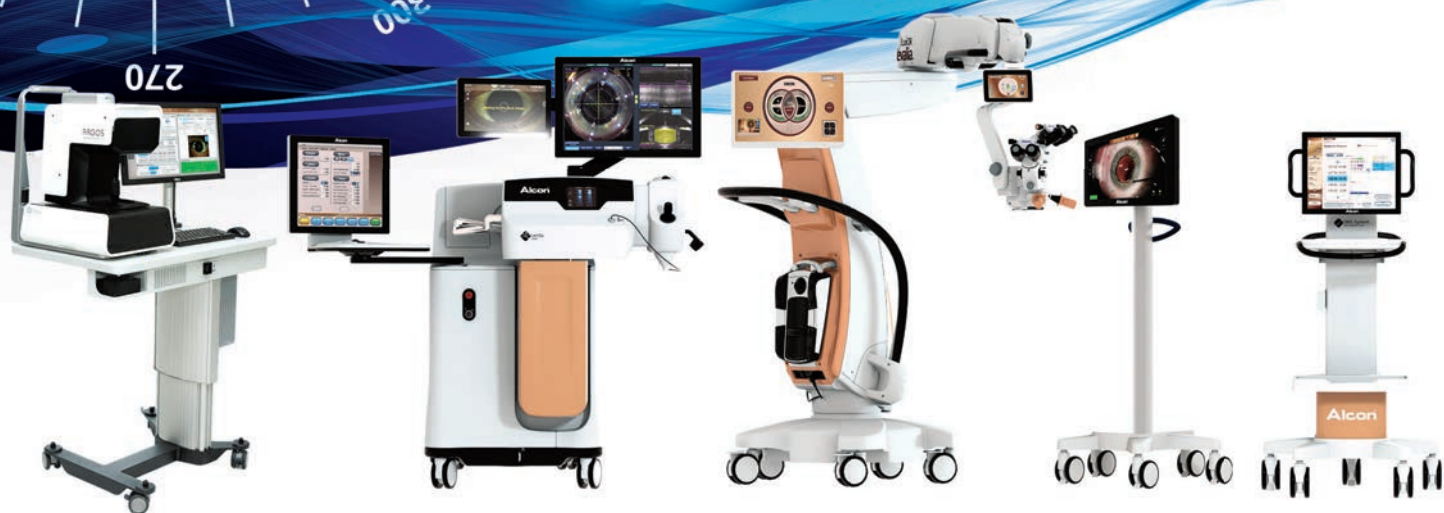Dr. Donnenfeld varies his approach

to glaucoma before surgery. “If a uveitis patient has moderate glaucoma, sometimes just managing the cataract well—performing atraumatic surgery—may be sufficient to control intraocular pressure postoperatively, especially if there’s an occlusive pupillary component,” he points out. “But if there are significant pre-existing conditions, such as visual field loss or significant intraocular pressure, a glaucoma care plan has to be incorporated at the time of cataract surgery or after the surgery. I usually do this with the aid of a glaucoma specialist in our practice.”

Dr. Donnenfeld says he’s found that a trabeculectomy tends to “scar down” unless he’s very aggressive with anti-metabolites. “My preferred therapy here is the use of tube shunts for most of these patients. However, I want to make sure the tube shunt isn’t clogged during surgery and that it’s sufficiently far enough away from the cornea that it doesn’t damage the cornea.”

In a patient with mild inflammation and a good angle, he continues, “I’ll still place a MIGS device. The MIGS can result in clogging (of the angle), so, again, I defer to the

IMAGE-GUIDED PRECISION^{1,2} POWERED BY ALCON



With **Image Guidance by Alcon®**, harness the power of **complete integration** of the cataract refractive procedure and experience intelligent planning and empowered execution with **enhanced precision at every step**.

Ask your Alcon representative for more information about Image Guidance by Alcon®.

References: 1. Whang W, Yoo Y, Kang M, et al. Predictive accuracy of partial coherence interferometry and swept-source optical coherence tomography for intraocular lens power calculation. *Sci Rep.* 2018;8(1):13732. 2. Shamma HJ, Shamma MC, Jivrajka RV, Cooke DL, Potvin R. Effects on IOL power calculation and expected clinical outcomes of axial length measurements based on multiple vs single refractive indices. *Clin Ophthalmol.* 2020;14:1511-1519.

Alcon

©2020 Alcon Inc. 12/20 US-ARB-2000104



judgment of one of our glaucoma specialists on what to do under these circumstances.”

He also emphasizes the importance of watching for steroid responders. “Sometimes, the anti-inflammatory agents can increase intraocular pressure significantly, prompting me to titrate my steroids,” he says. “In general, though, I’d rather use my glaucoma therapy to reduce the pressure than reduce my steroid therapy and run the risk of the patient developing postoperative uveitis that can make the glaucoma worse.”

As needed, he uses beta blockers as first-line postop glaucoma therapy, followed by adrenergic blockers. “I reserve prostaglandins for later in therapy,” he says. “And I’m very quick to refer these patients to a glaucoma specialist if glaucoma becomes a problem postoperatively.”

Increased IOP in these cases may also result when inflammation overwhelms the drainage system of the eye when the patient undergoes steroid treatment or because of a combination of these factors, according to Dr. Werner. “These patients may have pre-existing issues with their drainage systems, which should be considered ahead of time,” he adds.

For concerns about IOP, he continues, a tube shunt with a flow-restricted mechanism has a good track record. “That being said, there is emerging evidence that angle surgery, such as a goniotomy, may help uveitic glaucoma patients. Long-term follow-up studies may clarify the role of these procedures in the future,” he says.

Confronting the Cataract

Dr. Werner says the cataracts he extracts from these patients’ eyes are often very challenging. “The surgery may be associated with small pupils, posterior synechiae and pupillary membrane, as well as white cataracts,” he notes. “These cases often require careful preoperative plan-

ning. Also keep in mind that more manipulation during surgery may augment the postop inflammatory response.”

Macular edema can also be a concern. “I always get an OCT preoperatively for these patients,” Dr. Donnenfeld notes. “That’s when I might elicit the support of a retinal colleague, who can inject an intravitreal steroid.”

Besides managing risks posed by a cataract patient’s uveitis and glaucoma, surgeons note that customized approaches may be needed for the cataract. “A mild cataract obviously calls for different measures than a case with additional complications, such as synechiae and a small pupil,” says Dr. Al-Aswad. “I had one patient whose capsule was literally attached to the inflammation, to the point where I couldn’t separate the iris from the capsule. I had to put in a Malyugin ring in the iris and the anterior capsule at the same time to hold them in place.”

She notes that the sustained-release dexamethasone and fluocinolone implants have been very helpful to her before surgery. “Pred Forte or systemic prednisone can also help before, during and after surgery,” she adds.

Dr. Donnenfeld says he also is frequently challenged by small or irregular pupils with anterior and posterior synechiae in this setting. “Some of the most challenging cases will involve seclusio pupillae or occlusio pupillae,” he says. “I always use a peribulbar block for surgery because I never know how the cases are going to end up, and I want to make sure the patient is comfortable.”

He strives to maximally dilate these patients preoperatively. Sometimes, he adds, he’ll turn to using Healon 5 (Johnson & Johnson Vision) to create space. “I use the pupil expanders, such as an I-Ring, Malyugin ring or iris hooks, depending on the severity of the pupillary block,” says Dr. Donnenfeld, who also resorts to microforceps when

USING NEW TREATMENTS JUDICIOUSLY

When considering therapeutic options for patients with uveitis, Dr. Werner encourages physicians to consider the guidance derived from the MUST (Multicenter Uveitis Steroid Treatment) Trial.¹ Patients who underwent cataract surgery were compared to patients who received either systemic anti-inflammatory treatment or placement of the Retisert implant. More than half of patients had posterior involvement of their uveitis before cataract surgery. Both groups achieved good visual acuity overall, with no difference between groups after risk adjustment, he says. “Notably, however, the number of patients in the trial as a whole who both developed glaucoma and who required glaucoma surgery was significantly greater in the group that received the Retisert implant,” he says. “I think there is definitely an important role for the implant, but it’s critical to plan for or deal with these issues, either proactively [with a combined cataract-glaucoma surgery] in patients at high risk, or later on, if the pressure proves uncontrollable. Small studies have also demonstrated good outcomes in Retisert patients who have tube shunts inserted.”^{2,3} On the other side of this issue, he notes, is the health risk of systemic immunosuppression, which may not be apparent in clinical trial reports. “So you always have to balance risks and rewards with each patient,” Dr. Werner adds.

1. Brady CJ, Andrea C, Villanti AC, et al. Corticosteroid implants for chronic non-infectious uveitis. *Cochrane Database Syst Rev* 2016;2:2.
2. Chang IT, Gupta D, Slabaugh MA, et al. Combined Ahmed glaucoma valve placement, intravitreal fluocinolone acetonide implantation and cataract extraction for chronic uveitis. *J Glaucoma* 2016;25:10:842-846.
3. Ahmad ZM, Hughes BA, Abrams GW, et al. Combined posterior chamber intraocular lens, vitrectomy, Retisert, and pars plana tube in noninfectious uveitis. *Arch Ophthalmol* 2012;130:7:908-13.

—SM

the pupil is “completely bound down,” adding, “In these cases, I will actually perform a small peripheral iridectomy and use viscodissection under the iris and a spatula to more efficiently break up synechiae and help restore angle anatomy.”

While using Trypan Blue to improve visualization, he strives to make the capsule an effective size, avoiding capsular phimosis, and he then implants his IOL into the capsular bag. “Of course, these patients also have zonular weakness from prolonged inflammation,” he adds. “If I have any concerns about that, I’ll use

The Next Generation

Now Available!


NEW Pentacam® AXL Wave

The first device to combine Scheimpflug Tomography with
Axial Length + Total Wavefront + Refraction + Retroillumination

The new Pentacam® AXL Wave is a reliable partner for your refractive and cataract practice, creating the best prerequisites for surgery, based on pre-op metrics, and providing post-op measurements for reliable monitoring, in just one device! With high-end hardware and software for optimum treatment and satisfied patients, the new Pentacam® AXL Wave makes no compromises on quality.

Toll free 888-519-5375    
ads@oculususa.com www.pentacam.com/axl-wave





From left: Figures 3, 4 and 5. An 82-year-old female uveitic patient with long-standing rheumatoid arthritis presented with a history of chronic iridocyclitis OU, controlled on topical steroids, preperimetric glaucoma, visually significant cataracts and posterior synechiae OU. Her BCVA was 20/80 OD and 20/60 OS, and her IOP was 26 mmHg OD and 30 mmHg OS. Shown are visual fields in the left and right eyes and OCT of the RNFL OU (Figure 5). She underwent sequential phacoemulsification with lysis of synechiae, placement of an Ahmed implant (primed and ligated with 7-0 vicryl), an “orphan” trabeculectomy and sub-Tenon’s triamcinolone (20 mg) OU. Three years postop, her eyes were quiet, BCVA had improved to 20/50 to 20/70 OD, 20/25 to 20/50 OS, and IOP had decreased to 8 mmHg OD and 9 mmHg OS without topical medications.

the capsular tension ring as well. I like to use a hydrophobic acrylic lens instead of a silicone lens, which can be problematic in these patients.”

Dr. Donnenfeld says he administers a subconjunctival steroidal injection at the conclusion of each case. “If there’s a vitrectomy for some reason, I also add intraocular triamcinolone, not only to visualize the vitreous but to reduce postoperative inflammation,” he says.

“I believe this is a case in which using the implantable drug delivery systems, such as the dexamethasone intraocular suspension 9% (Dexycu, EyePoint Pharmaceuticals) or the dexamethasone ophthalmic insert 0.4% (Dextenza, Ocular Therapeutix) can really play a significant role, helping to achieve maximum anti-inflammatory effects.”

Dr. Kedhar, who also often struggles to maintain visualization when operating on these patients, relies heavily on capsular staining dyes, when necessary.

“The use of capsular staining dyes can also improve your surgical

technique in these patients,” he says. “The use of microincisions has also made a big difference to us as well. Instruments such as the Duet-style forceps from MST [MicroSurgical Technology] have enabled us to improve the surgical technique we use to remove the cataract.

“Of course, I would also agree that control of the inflammation is a paramount consideration during every one of these surgeries that we do,” he continues. “Besides immunosuppressive medications, local drug delivery of steroids, including difluprednate and the dexamethasone and fluocinolone implants, have been helpful to us. The longer-acting agents that provide the patient with more sustained control of inflammation are the most helpful in these situations.”

He notes that another positive development that’s made it possible to improve the care of these patients is the availability of better imaging modalities. “The widespread use of optical coherence tomography imaging to monitor for macular edema in

these patients, both preoperatively and postoperatively, has improved our ability to achieve good outcomes,” he says.

The Case for Clear Cornea

Dr. Kedhar says he typically uses standard clear cornea phacoemulsification surgery in these cases. Because of the surgical challenges associated with poor visualization of the capsule and the red reflex in these patients, as well as responding to miosis, or posterior synechiae contributing to a small pupil, he says that he prepares for any eventuality, keeping Malyugin rings, I-Rings, iris hooks and capsular dye at the ready.

“We also have a capsular tension ring available for these cases,” he notes. “I recommend that surgeons always have a backup lens on hand when doing these procedures, too. You may not be able to place a one-piece lens in a capsular bag in these patients, so having a three-piece lens available is important.”

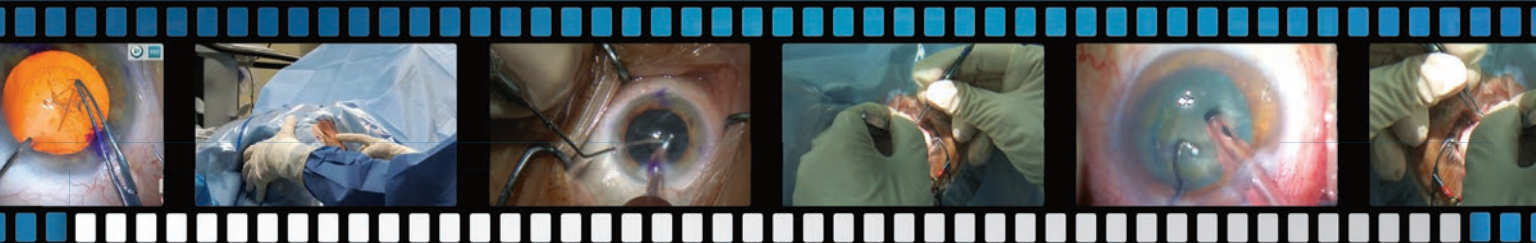
(Continued on p. 81)



Monthly

MACKOOL ONLINE CME

CME SERIES | SURGICAL VIDEOS



To view CME video
go to:

www.MackoolOnlineCME.com

Episode 63: "Deformed Pupil Repair"

Surgical Video by:
Richard J. Mackool, MD

Video Overview:

A post-traumatic pupil deformation has caused disabling glare. Two months after complex cataract-IOL surgery with suturing of a capsular tension ring to the sclera and toric IOL insertion, the pupil is repaired (sutured iridoplasty).

MackoolOnlineCME.com MONTHLY Video Series



Richard J. Mackool, MD

We are excited to continue into our sixth year of Mackool Online CME. With the generous support of several ophthalmic companies, I am honored to have our viewers join me in the operating room as I demonstrate the technology and techniques that I have found to be most valuable, and that I hope are helpful to many of my colleagues. We continue to edit the videos only to either change camera perspective or to reduce down time - allowing you to observe every step of the procedure.

As before, one new surgical video will be released monthly, and physicians may earn CME credits or just observe the case. New viewers are able to obtain additional CME credit by reviewing previous videos that are located in our archives.

I thank the many surgeons who have told us that they have found our CME program to be interesting and instructive; I appreciate your comments, suggestions and questions. Thanks again for joining us on Mackool Online CME.



CME Accredited Surgical Training Videos Now Available Online: www.MackoolOnlineCME.com

Richard Mackool, MD, a world renowned anterior segment ophthalmic microsurgeon, has assembled a web-based video collection of surgical cases that encompass both routine and challenging cases, demonstrating both familiar and potentially unfamiliar surgical techniques using a variety of instrumentation and settings.

This educational activity aims to present a series of Dr. Mackool's surgical videos, carefully selected to address the specific learning objectives of this activity, with the goal of making surgical training available as needed online for surgeons motivated to improve or expand their surgical repertoire.

Learning Objective

After completion of this educational activity, participants should be able to:

- demonstrate techniques that can be used to repair a deformed pupil and thereby eliminate glare symptomatology.

Satisfactory Completion - Learners must pass a post-test and complete an evaluation form to receive a certificate of completion. You must listen to/view the entire video as partial credit is not available. If you are seeking continuing education credit for a specialty not listed below, it is your responsibility to contact your licensing/certification board to determine course eligibility for your licensing/certification requirement.



JOINTLY ACCREDITED PROVIDER™
INTERPROFESSIONAL CONTINUING EDUCATION

Physicians - In support of improving patient care, this activity has been planned and implemented by Amedco LLC and Review Education Group. Amedco LLC is jointly accredited by the Accreditation Council for Continuing Medical Education (ACCME), the Accreditation Council for Pharmacy Education (ACPE), and the American Nurses Credentialing Center (ANCC), to provide continuing education for the healthcare team

Credit Designation Statement - Amedco designates this enduring material activity for a maximum of .25 AMA PRA Category 1 Credits™. Physicians should claim only the credit commensurate with the extent of their participation in the activity.

Jointly provided by:



Supported by an unrestricted independent
medical educational grant from:



Additionally Supported by:



In Kind Support:



Video and Web Production by:
JR Snowden, Inc

DIABETIC RETINOPATHY: PLANNING YOUR TREATMENT

Treatment depends on severity, and ranges from observation to intravitreal injection or laser photocoagulation.

BY MICHELLE STEPHENSON
CONTRIBUTING EDITOR

For years, the treatment paradigm for patients with diabetic retinopathy was fairly well-established. Recently, however, the advent of anti-vascular endothelial growth factor injections and data from studies are changing some treatment patterns. Here's a review of how retina specialists currently approach these patients, after taking into account all of the recent developments.

Treatment Philosophy

Treatment for nonproliferative diabetic retinopathy depends on severity. Assuming there's no diabetic macular edema, most cases of mild NPDR can be observed. More advanced cases—moderately severe to severe NPDR—can be considered for treatment, which typically includes intravitreal injection or laser photocoagulation.

Whether to use injection or laser, as well as the length of treatment, is up for debate. “Obviously, if you ask 10 retina specialists, I'm sure

you'll get different answers,” says Tom Stone, MD, who practices in Lexington, Kentucky. “For me, it depends on the underlying condition of the patient. If someone has kidney disease, hypertension, or if he or she smokes or is obese, these conditions will further compound the care of NPDR. I would consider anti-VEGF therapy in these patients. In other patients who have mild cases, I will just watch them and try to coordinate with their primary care physician to optimize their systemic status.”

Chicago's Jennifer Lim, MD, agrees that patients with mild cases of NPDR shouldn't be treated unless there is clinically significant edema. “This can happen in any category of diabetic retinopathy, and we make decisions based upon the location of the edema,” she says. “The Diabetic Retinopathy Clinical Research Retina Network Protocol V results¹ say that if vision is 20/20 or 20/25, patients can just be watched for worsening in terms of vision loss or thickening. If worsening occurs, then we'll institute treatment. However, if patients are mild and there's

no macular edema, we typically just follow them. If it's very mild, I'll see them once a year and just educate them about the symptoms of macular edema, such as distortion, decreased vision or developing neovascularization. It would be rare for a patient with mild NPDR without edema to develop NPDR progression within a year. We also recommend good control of glucose, blood pressure and cholesterol. I advise my patients to have a hemoglobin A1C goal of 7 or below. I also remind patients with renal issues that renal control also affects macular edema. I think those factors are really key to systemic control in these patients.”

A recent study confirmed the use of observation-only for mild cases of NPDR.¹ The study compared vision loss at two years among eyes initially managed with aflibercept, laser photocoagulation or observation and found that, among eyes with center-involved DME and good visual acuity, there was no significant difference in vision loss at two years between the three groups. The researchers concluded that observation without treatment, unless

This article has no commercial sponsorship.

Dr. Boyer has consulting relationships with Alcon, Bausch + Lomb (Valeant), Bayer, Chengdu Kanghong Biotechnology, Genentech, Novartis Ophthalmics and Regeneron. **Dr. Stone** consults for Regeneron and Genentech. **Dr. Lim** consults for Genentech, Regeneron, Alcon and Chengdu.

visual acuity worsens, may be a reasonable strategy for center-involved DME.

This randomized clinical trial was conducted at 91 sites in the United States and Canada and included 702 adults with type 1 or type 2 diabetes. All participants had one study eye with center-involved DME and visual acuity of 20/25 or better. Participants' mean age was 59 years, and 62 percent were men.

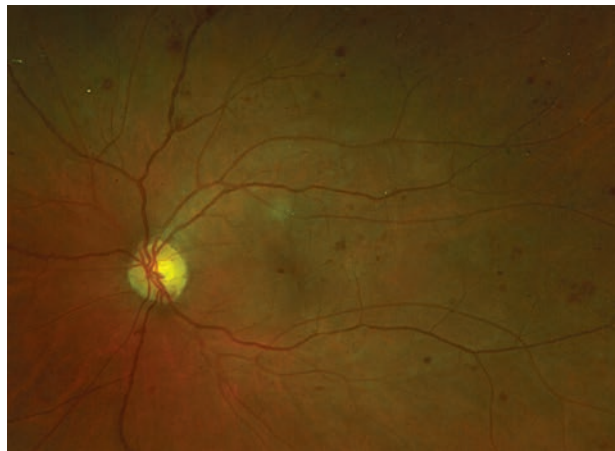
All eyes were randomly assigned to one of three groups: 226 eyes received 2 mg of intravitreal aflibercept as frequently as every four weeks; 240 eyes received focal/grid laser photocoagulation; and 236 eyes were observed. Aflibercept was required for eyes in the laser photocoagulation or observation groups that had decreased visual acuity from baseline of at least 10 letters at any visit, or a loss of five to nine letters (one to two lines) at two consecutive visits.

Of the original 702 randomized participants, 625 completed the two-year visit. For eyes with visual acuity that decreased from baseline, aflibercept was initiated in 25 percent of the laser photocoagulation group and in 34 percent of the observation group. At two years, the percentage of eyes with at least a five-letter visual acuity decrease was 16 percent in the aflibercept group, 17 percent in the laser group and 19 percent in the observation group. There was no significant difference in vision loss between groups.

Moderately Severe and Severe Cases

Even in cases without diabetic macular edema, moderately severe to severe cases of diabetic retinopathy always require treatment.

The PANORAMA study found that intravitreal aflibercept injection improved diabetic retinopathy and prevented disease progression in eyes with moderately severe to



Tom Stone, MD

Severe NPDR in a patient with significant peripheral nonperfusion on fluorescein angiography.

severe NPDR, in patients without DME.²

Patients were eligible to participate if they were at least 18 years of age and had type 1 or 2 diabetes mellitus and moderately severe to severe NPDR, absence of center-involved DME, and baseline best-corrected visual acuity of 20/40 or better in the study eye. A total of 402 eyes were randomized to three groups: 135 received intravitreal aflibercept injection (IAI) 2 mg every 16 weeks (2q16) after three monthly doses vs. one dose at an eight-week interval; 134 received IAI 2 mg every eight weeks (2q8) after five monthly doses; and 133 eyes received sham. The primary endpoint was the proportion of eyes with at least a two-step improvement in DRSS score at week 52. Data were analyzed to determine the visual and anatomic outcomes at 100 weeks.

Two-thirds (66 percent) of the patients were men, and participants had a mean age of 55.7 years. The mean baseline BCVA score was 82.4 ±6.0 letters. At week 52, 65 percent of the 2q16 eyes and 80 percent of the 2q8 eyes had at least a two-step improvement in DRSS score, compared to 15 percent of sham eyes. Additionally, 9 percent of 2q16 eyes and 15 percent of 2q8 eyes had at least a three-step improvement in DRSS score, compared to less than 1 percent of sham eyes.

Through week 52, 4 percent of 2q16 eyes and 3 percent of 2q8 eyes developed a vision-threatening complication, compared with 20 percent of sham eyes. IAI significantly reduced the risk of developing a vision-threatening complication, by 85 percent in the 2q16 group and 88 percent in the 2q8 group compared to sham. The incidence of center-involved DME was lower in the 2q16 (7 percent) and 2q8 (8 percent) groups compared with the sham group (26 percent). Additionally,

IAI significantly reduced the risk of developing center-involved DME, by 79 percent in the 2q16 group and by 73 percent in the 2q8 group.

David S. Boyer, MD, who is in practice in Los Angeles, says that this study provided a good indication of the value of anti-VEGF therapy for the treatment of high-risk NPDR without diabetic macular edema as a means to prevent further visual loss and severe vision-threatening complications. "Prior to that, we knew that diabetic retinopathy severity improves with anti-VEGF therapy, but we really didn't have a great way of following patients, or some type of cookbook that we could use. This trial really gave us a foundation regarding what to do," he says.

However, he notes that compliance with routine injection schedules can be difficult to maintain. "We all know that diabetic patients who have severe NPDR may have other medical conditions that don't allow them to come back as scheduled for these injections. In addition, diabetic patients may lose their insurance and not be able to return for that reason. In cases where we use anti-VEGF and then stop, patients worsen. So, you need a very cooperative and compliant patient to institute anti-VEGF alone. In these cases, laser treatment has an advantage. If you stop treating with a laser,

you will get some progression of the retinopathy, but you may not get the devastating loss of vision that you would get by stopping anti-VEGF therapy,” Dr. Boyer explains.

He adds that he is currently treating patients with both anti-VEGF injection and laser. “I might treat the periphery, those areas adjacent to severe non-perfusion, with laser,” he says. “I’m using less laser than I was previously, and I’m using anti-VEGF in combination with it to make sure that I’m keeping the eye under control, because laser treatment can institute some degree of macular edema. So, many times, I’ll use a combination of both entities. Once I feel comfortable that, even if the patient didn’t return, he or she won’t develop rubeosis or the eye feels stable, I may follow the patient and treat every three to four months to prevent the development of vitreous hemorrhage and other high-risk complications.”

How Long to Treat?

Dr. Boyer notes that one reason ophthalmologists are hesitant to institute anti-VEGF therapy is that they don’t know when to stop. “Do we treat every four months for the rest of the patient’s life? Do we get to a certain point where we can stop, and the clock resets, and we can watch them for a while?” he muses. “If a patient presents with an A1C of 9 or higher, I know the patient’s not going to be able to come in as often he or she needs to. This patient will get other side effects, including kidney disease. I’m more likely to treat that patient aggressively with a laser to prevent him or her from experiencing further vision loss, because the patient may not come back. On the other hand, if a patient has an A1C of 6.5 or 7 and has improved the quality of diabetic control, I might consider treating those cases with anti-VEGF, but, again, we don’t know the endpoint.”

Dr. Lim follows patients with moderate NPDR every four to six months, depending on the severity. For severe NPDR, she typically

follows patients every three to four months, again depending on severity. “There’s mild, moderate and then there’s more severe moderate,” she says. “Similarly, for severe, there’s moderately severe, and then there’s very severe. Generally, the more

“It’s hard to convince patients to get a treatment when they have no symptoms and there’s a downside in terms of risk of infection. However, if they can see that their disease is progressing from moderately severe to severe, they may agree to start therapy.”

—Jennifer Lim, MD

severe it is, the more often we see them. The PANORAMA study did show benefits for eyes with moderate NPDR to severe NPDR, in terms of limiting the progression of retinopathy and preventing complications such as anterior segment neovascularization, center-involving DME and proliferative diabetic retinopathy. The reductions are significant—60-percent to 79-percent reductions in what would have happened otherwise over the course of time. When I look at a patient and I’m trying to decide whether to start him or her on anti-VEGF, I have to take into account the patient’s risk of complications, the risk of the injection itself, the cost of the drug and the societal cost of having the patient taking off work or having someone else take off work if the patient is incapable of coming in on his or her own.”

Dr. Lim adds that the patient must be willing to return for the series of injections. “Otherwise, he or she won’t get the same benefit that we experienced in the PANORAMA clinical trial, and we saw some pretty amazing results,” she says. “So, if I have a partnership with the patient,

the patient agrees to come in for multiple injections, the patient knows and accepts the risks, and the patient is willing to undergo treatment, then we’ll go ahead and do it. However, this doesn’t happen often. It’s hard to convince patients to get a treatment when they have no symptoms and there’s a downside in terms of risk of infection. However, if they can see that their disease is progressing from moderately severe to severe, they may agree to start therapy.”

The Future

Dr. Lim believes that the use of lasers in the future will be limited mostly to PDR. “You’re basically scarring the patient’s retina,” she says. “Although there’s essentially no risk of endophthalmitis with the laser, I prefer not to create retinal scars. In some patients, depending on the degree of pigmentation in their retinal pigment epithelium, the laser scars can expand with time. The more energy you use and the more pigmentation the patient has, the more scarring will occur. I would rather inject an anti-VEGF in patients with early PDR. If there is early proliferative retinopathy and the patient is reliable, we can choose an anti-VEGF instead of laser. I would definitely not use laser for severe NPDR. I reserve its use for moderate to advanced PDR and also for preoperative use in patients who have traction retinal detachments and active PDR.”

Dr. Stone says that the only time he’d start with laser is if the patient has proliferative disease in one eye that’s been hard to control, and if he’s concerned that the patient won’t return for subsequent injections. “In these cases, I’ll preemptively do laser,” he says. ◀

1. Baker CW, Glassman AR, Beaulieu WT, et al. Effect of initial management with aflibercept vs laser photocoagulation vs observation on vision loss among patients with diabetic macular edema involving the center of the macula and good visual acuity: A randomized clinical trial. *JAMA* 2019;321:19:1880-1894.

2. Lim JI. Intravitreal aflibercept injection for nonproliferative diabetic retinopathy: Year 2 results from the PANORAMA study. *Invest Ophthalmol Vis Sci* 2020;61:7:1381.

USO
US OPHTHALMIC[®]

**A VISION THAT
INSPIRES
YOU**



The New & Easy to Use
EFC-2600
FUNDUS CAMERA

Fully Automatic
Mosaic Visualization
Anterior & Posterior Segment
45°-100° Degree Angle Visual Field

12 MEGA
PIXELS


A TEAM BY YOUR SIDE

SATISFACTION GUARANTEED

FROM ONE INDEPENDENT OWNER TO ANOTHER

WE CARE FOR OUR COMMUNITY

\$ EASY FINANCE
AVAILABLE



EZER OPHTHALMIC LINE
The Ezer Way of Life

CONTACT US FOR INFORMATION

WWW.USOPHTHALMIC.COM | PH: 1.888.881.1122
INFO@USOPHTHALMIC.COM

Follow Our Social Media Channels @USOPHTHALMIC



9990 NW 14th Street, Unit #105, Doral, FL 33172 | USA



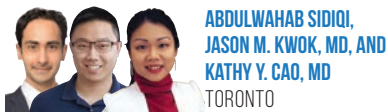SCAN TO SEE MORE!

Read all the features and benefits
this item has to offer by connecting
to our page.

While you're there, don't forget to
Request A Virtual Demo Online!

MED-SCHOOL EDUCATION: TEACHING THE TEACHERS

A practical approach to teaching ophthalmology to medical students in the clinic.



ABDULWAHAB SIDIQI,
JASON M. KWOK, MD, AND
KATHY Y. CAO, MD
TORONTO

For most physicians, the only exposure they'll ever get to clinical ophthalmology is during medical school. Unfortunately, the ophthalmology component of the undergraduate medical curriculum is limited and on the decline.¹ Compared to other specialties, learning clinical ophthalmology requires more hands-on skills development, such as learning how to use a slit lamp, so this short but valuable time must be optimized to provide foundational knowledge to all medical learners.² If you're involved with any phase of training the next generation of physicians, this article will provide several helpful tips and insights on how to make the most of this formative, precious instructional time.

Establish a Foundation

There are many barriers that make the teaching experience either difficult or ineffective for both physicians and students. First, the lack of

exposure to ophthalmology education steepens students' learning curve. Moreover, in order to learn and retain the immense practical and technical skills comprising this specialty, there has to be constant, directed practice, instead of the more hands-off, theoretical approaches found in some other specialties. Lastly, the fast-paced, large-patient-volume environment in ophthalmology clinics limits clinical learning by restricting the time that's available for teaching, providing feedback, skills observation and general orientation to the clinic.²

Interestingly, however, a comprehensive review of educational research on ambulatory education suggests that these barriers don't significantly limit teaching effectiveness. Rather, it's the specific behaviors and strategies of teachers that most impact the quality of the clinical learning experience.^{3,4}

So, what are the impactful behaviors and strategies that ophthalmologists should emulate to optimize the learning environment? Here are three primary principles to keep in mind:

- **Orientation and goal-setting.** A brief orientation goes a long way

toward fostering a good learning environment. The staff should ask students about their priorities, explain how the clinic works, provide a brief tour, and create a plan for the duration of the students' stay. This will help make students feel welcomed, while anchoring them to the new territory they're entering.

- **Clinical immersion.** The best way to make students feel engaged is to make them feel like they're part of the team. Students should be introduced to all staff and patients, and be treated like valuable members of the clinic. Moreover, learners should be provided opportunities to showcase their knowledge and skills by being offered the opportunity to conduct clinical examinations—initially under supervision, and independently thereafter.

- **Knowledge synthesis.** To help students synthesize knowledge, staff can first ask them about their background knowledge to ascertain their baseline understanding of certain concepts. Then, it's important to help the students draw connections between newly encountered clinical information and the theoretical information

This article has no commercial sponsorship.

Dr. Kwok is a resident, and Dr. Cao practices comprehensive ophthalmology, at the University of Toronto's Department of Ophthalmology and Vision Sciences. Mr. Sidiqi is a medical student at the University of Toronto.

they already know. This encourages them to use their background understanding as a scaffold to bring fundamental ophthalmology concepts to life and apply it to clinical practice.

Teaching Strategies

Clinicians should implement the three general principles listed above to inform their approach in mentoring students and building an environment conducive to learning. Once this foundation has been established, clinicians can then incorporate the following four strategies, adapted from a 1997 article by Seattle's Steven McGee, MD, and his co-workers,³ to further optimize students' knowledge integration:

- **Ask relevant questions.** Asking students questions is one of the best ways to evaluate and support their learning. Specifically, periodic questioning can help the students feel engaged throughout the rotation, motivated to enhance their knowledge, and help monitor their progress over time.³ Clinicians should provide learners with a minimum of three seconds to answer questions before interjecting. Evidently, prolonging response-time stimulates more insightful thinking, thus producing more reasonable answers.⁵

An example of a useful question might be, "This patient has optic neuritis. What are the clinical features of this condition?" or "We just saw a patient with a chemical injury of the right eye. If you saw this patient in the emergency room, what's the most important treatment you could offer him/her?"

- **Limit each patient encounter to one teaching point.** It's been shown that conveying one teaching point per patient encounter, rather than multiple, is much more valuable to students' learning.³ Beyond a single teaching point, there's an increased risk of overwhelming students and diluting the value of the teaching points. Ask yourself, "What's the one point that's most important to know for this case?" The teaching point should be

TABLE 1. EXAMPLES OF TEACHING STRATEGIES — QUOTES FROM THE OPHTHALMOLOGY CLINIC

Strategies	Example Prompts
Ask questions	"What are the signs and symptoms of angle closure glaucoma? Take some time to think about the answer." "We just saw a patient with acute vision loss. What are the clinical features of this case that make you concerned about giant cell arteritis as the cause of the vision loss?"
Have one teaching point	"We are going to focus on one teaching point per patient encounter today." "For this encounter, the main learning point is understanding the importance of AREDS2 supplements in patients with dry macular degeneration, as it can slow down the progression of this condition."
Prime students	"We are about to see a patient who is complaining of new floaters. As I chat with the patient, I want you to think about the different clinical conditions that can cause floaters."
Assign learning topics	"Today, we saw many cases of primary open-angle glaucoma, which you seem to be very interested in. I would like you to look up the Ocular Hypertension Study and list its main learning points. Alternatively, you're welcome to come up and research a learning topic that you're interested in and we can review it tomorrow after clinic."

brief and simple. This way, there will be greater emphasis on the most important take-home point, and it will be more likely to be remembered.

For example, you might say, "We just saw a patient with scleritis. The main take-home message from this encounter is that scleritis can occur secondary to an underlying autoimmune disease like rheumatoid arthritis," or "As you can see, the patient has multiple complex ocular conditions. However, what I want you to take away from this encounter is that graft-versus-host disease can affect the eye."

- **Prime your students.** You can prime students before they enter the patient room by asking them a question relevant to the case. This is a valuable psychological technique that helps elicit relevant ideas in students' minds before they face a clinical encounter.³ For example, before seeing a patient with photopsias, students

should be prompted to think about the differential diagnosis for this condition. During the clinical encounter with patients, students' minds will actively think of the differential for the case and evaluate the likelihood of each possible diagnosis. Priming helps prepare and steer students in the right direction, makes them feel much more engaged during the clinical encounter and consolidates their knowledge base.

As an example of priming a student, the instructor might say, "We're going to see a patient with an orbital floor fracture. I want you to pay close attention to the physical examination maneuvers I perform when evaluating him," or "Our next patient has primary open angle glaucoma. As I speak with her, I want you to think about the different imaging modalities we use in ophthalmology to monitor these patients closely."

- **Assign learning topics.** Students



HYDRUS[®]
MICROSTENT

CAUTION: Federal law restricts this device to sale by or on the order of a physician.

INDICATIONS FOR USE: The Hydrus Microstent is indicated for use in conjunction with cataract surgery for the reduction of intraocular pressure (IOP) in adult patients with mild to moderate primary open-angle glaucoma (POAG). **CONTRAINDICATIONS:** The Hydrus Microstent is contraindicated under the following circumstances or conditions: (1) In eyes with angle closure glaucoma; and (2) In eyes with traumatic, malignant, uveitic, or neovascular glaucoma or discernible congenital anomalies of the anterior chamber (AC) angle. **WARNINGS:** Clear media for adequate visualization is required. Conditions such as corneal haze, corneal opacity or other conditions may inhibit gonioscopic view of the intended implant location. Gonioscopy should be performed prior to surgery to exclude congenital anomalies of the angle, peripheral anterior synechiae (PAS), angle closure, rubeosis and any other angle abnormalities that could lead to improper placement of the stent and pose a hazard. **PRECAUTIONS:** The surgeon should monitor the patient postoperatively for proper maintenance of intraocular pressure. The safety and effectiveness of the Hydrus Microstent has not been established as an alternative to the primary treatment of glaucoma with medications, in patients 21 years or younger, eyes with significant prior trauma, eyes with abnormal anterior segment, eyes with chronic inflammation, eyes with glaucoma associated with vascular disorders, eyes with preexisting pseudophakia, eyes with uveitic glaucoma, eyes with pseudoexfoliative or pigmentary glaucoma, eyes with other secondary open angle glaucoma, eyes that have undergone prior incisional glaucoma surgery or cilioabative procedures, eyes that have undergone argon laser trabeculoplasty (ALT), eyes with unmedicated IOP < 22 mm Hg or > 34 mm Hg, eyes with medicated IOP > 31 mm Hg, eyes requiring > 4 ocular hypotensive medications prior to surgery, in the setting of complicated cataract surgery with iatrogenic injury to the anterior or posterior segment, and when implantation is without concomitant cataract surgery with IOL implantation. The safety and effectiveness of use of more than a single Hydrus Microstent has not been established.

ADVERSE EVENTS: Common post-operative adverse events reported in the randomized pivotal trial included partial or complete device obstruction (7.3%); worsening in visual field MD by > 2.5 dB compared with preoperative (4.3% vs 5.3% for cataract surgery alone); device malposition (1.4%); and SCVA loss of ≥ 2 ETDRS lines at 3 months (1.4% vs 1.6% for cataract surgery alone). For additional adverse event information, please refer to the Instructions for Use.

MRI INFORMATION: The Hydrus Microstent is MR-Conditional meaning that the device is safe for use in a specified MR environment under specified conditions. Please see the Instructions for Use for complete product information.

References:

1. Samuelson TW, Chang DF, Marquis R, et al; HORIZON Investigators. A Schlemm canal microstent for intraocular pressure reduction in primary open-angle glaucoma and cataract: The HORIZON Study. *Ophthalmology*. 2019;126:29-37.
2. Vold S, Ahmed II, Craven ER, et al; CyPass Study Group. Two-Year COMPASS Trial Results: Supraciliary Microstenting with Phacemulsification in Patients with Open-Angle Glaucoma and Cataracts. *Ophthalmology*. 2016;123(10):2103-2112.
3. US Food and Drug Administration. Summary of Safety and Effectiveness Data (SSED): Glaukos iStent[®] Trabecular Micro-Bypass Stent. US Food and Drug Administration website. https://www.accessdata.fda.gov/cdrh_docs/pdf8/P080030B.pdf. Published June 25, 2012.
4. US Food and Drug Administration. Summary of Safety and Effectiveness Data (SSED): iStent Inject Trabecular Micro-Bypass System. US Food and Drug Administration website. https://www.accessdata.fda.gov/cdrh_docs/pdf17/P170043b.pdf. Published June 21, 2018.

*Comparison based on results from individual pivotal trials (of those devices for which pivotal trials are available) and their respective controls and not head to head comparative studies. Other MIGS treatments have not been tested in pivotal trials.

[†]Data on file – Compared to control and includes trabeculectomy and tube shunt.



©2021 Ivantis, Inc. Ivantis and Hydrus are registered trademarks of Ivantis, Inc. All rights reserved. IM-0070 Rev A

Feature EDUCATION

coming to the clinic will undoubtedly have gaps in their knowledge. Though many gaps will be filled during clinical encounters, the remainder must be addressed outside the clinic. A great way to do this is to assign learning topics for the students to research and later review with the staff. The topics can be related to any concept in ophthalmology, but should be customized to each individual student's needs, abilities and interests.

Ideally, assigned topics should prioritize common, high-yield foundational knowledge before diverging to more niche, advanced details. Staff should even consider asking students what topics they'd like to research, thus giving them greater agency in their learning and fostering a sense of responsibility. These learning goals should be discussed and reviewed later to address any further gaps in the students' understanding, reinforce their knowledge base and commend them for their progress.

Such assigned learning topics often depend on the individual staff and what they believe are important concepts for medical students to learn. They also depend on a particular medical student's knowledge level. Again, research topics should be on general, high-yield topics rather than small, niche "factoids" that medical students wouldn't be expected to know.

Some common, high-yield foundational knowledge that medical students can learn more about independently are outlined below. Keep in mind that these assigned learning topics are broad but important concepts that medical students should know before graduating medical school (this list is not comprehensive):

— **Glaucoma:** What's the difference

between open-angle and closed-angle glaucoma?

— **Retina:** What are the clinical features of non-proliferative diabetic retinopathy and proliferative diabetic retinopathy? How do you treat cases of proliferative diabetic retinopathy?

— **Cornea:** What are the differentiating features

between a corneal abrasion and a corneal ulcer? How do you treat a corneal ulcer?

— **Neuro-ophthalmology:** What can cause papilledema? What type of investigations would you order when evaluating a patient with

papilledema?

Overall, ophthalmology can be a daunting field for many medical students, and the medical school curriculum is unable to entirely address the gaps in learning that students have. Therefore, it's up to clinicians to provide the foundational knowledge of clinical ophthalmology to students to develop their skills and competence in the field. To do this, effective teachers are paramount.

The principles discussed in this article constitute a core guide on how to teach ophthalmology. But ultimately, it's up to each ophthalmologist to hone their teaching gestalt and recognize that every great surgeon must also be a great teacher. ◀

1. Noble J, Somal K, Gill HS, Lam WC. An analysis of undergraduate ophthalmology training in Canada. *Canadian Journal of Ophthalmology* 2009;44:5:513-8.
2. Succar T, Grigg J, Beaver HA, Lee AG. A systematic review of best practices in teaching ophthalmology to medical students. *Survey of Ophthalmology* 2016;61:1:83-94.
3. McGee SR, Irby DM. Teaching in the outpatient clinic. *Journal of General Internal Medicine* 1997;12:2:S34-40.
4. Irby DM, Ramsey PG, Gillmore GM, Schaad D. Characteristics of effective clinical teachers of ambulatory care medicine. *Academic Medicine: Journal of the Association of American Medical Colleges* 1991;66:1:54-5.
5. Rowe MB. Wait time: Slowing down may be a way of speeding up! *Journal of Teacher Education* 1986;37:1:43-50.

MIGS SURGEONS GET ONE SHOT MAKE A WISE DECISION

Progression in glaucoma never stops. Neither does the need for effective IOP management. That's why your best shot in MIGS with cataract surgery is the Hydrus[®] Microstent—the one option proven in a pivotal trial to deliver:

- The greatest improvement of medication elimination^{1-4,*}
- The largest IOP reduction^{1-4,*}
- A statistically significant reduction in risk of invasive secondary glaucoma surgeries[†]

When it's time to make a decision about MIGS, give your one shot the best chance to deliver the highest quality patient outcomes.

Experience A New Confidence



©2021 Ivantis, Inc. Ivantis and Hydrus are registered trademarks of Ivantis, Inc. All rights reserved. IM-0070 Rev A



EDITED BY KULDEV SINGH, MD, MPH,
AND PETER A. NETLAND, MD, PHD

GLAUCOMA MANAGEMENT

Checking Visual Fields Using Virtual Reality

Many disadvantages associated with standard visual field testing may be eliminated using this novel technology.

BY YVONNE OU, MD
SAN FRANCISCO

Standard automated perimetry has been the gold standard for evaluating a patient's visual field for many years. The information it provides is crucial to monitoring the status of our glaucoma patients, and it often allows us to detect functional deficits before an individual notices any loss. Without this data, the disease may progress to a point at which it's difficult to help the patient maintain the good vision that's left, before the patient even realizes that a serious problem exists.

Every ophthalmologist understands that standard automated perimetry, such as a Humphrey visual field test, isn't an easy test to take—or to give. It requires the patient to remain fixated on a visual target for several minutes at a time, suppressing the foveation reflex that makes us want to look directly at a new visual stimulus. And it's not entertaining in any way that might offset the discomfort and mild stress associated with taking the test. That's undoubtedly why we've all listened to patient complaints about having to take the test. Furthermore, from the practice's perspective, it requires a fair amount of a technician's time to ensure that the patient understands how to take the test

and does so in a reliable way that produces meaningful data.

Given these realities, it should be no surprise that many researchers and companies are trying to develop an alternative way to test the visual field. During the past year, at the University of California San Francisco School of Medicine we've been developing a visual field test using virtual reality goggles in an unfunded collaboration with the company Vivid Vision. (I'm not a consultant and have no financial involvement in any product that may result; and I'm aware that several other VR visual fields are currently available.)

This project, seen as a way to allow patients to perform home testing, was in the works prior to the pandemic, but COVID has definitely shed light on the importance of being able to care for your patients remotely. Because of the pandemic, I haven't seen some of my patients for more than a year, and some are still nervous about coming in. Clearly, an affordable and effective way to test the visual field at home would offer significant benefits for glaucoma management, and not just during a pandemic. Such an option would help doctors monitor their patients in very rural areas in America and around the world, as well as in resource-poor areas, where glaucoma has an inequitable distribution, even

when times are relatively good.

Incorporating the Foveal Reflex

As I mentioned earlier, one of the challenges when taking a standard visual field test is the need for fixation—remaining visually focused on one point and suppressing the foveation reflex. Eliminating the need to do that has been a key goal of the test we're developing.

To that end, our test uses oculokinetic perimetry, which was developed many years ago by Bertil Damato, MD, PhD, an ocular oncologist. It's called oculokinetic because the eye moves, following each new visual stimulus, instead of remaining fixated on one point. Virtual reality is ideally suited for this approach because there's no restriction on the visual locations perceived by the patient. The virtual space literally surrounds the patient.

During our test, when a stimulus is flashed, you allow your foveation reflex free rein, turning your head to look at each new stimulus point. A center circular light spot marks your focal point, so the game becomes moving your head so the dot in front of you overlaps with the target stimulus. The device can tell where you're looking, so once it perceives that you're looking directly at the latest stimulus, that becomes the fixation point for the next stimulus. If the next stimulus falls in a "blind" area, the patient doesn't turn to look at it. If the patient does see it, he or she turns to look at it. Meanwhile, the device is using this data to map out the patient's visual field. The fact that the patient gets to move freely makes this test much easier and more intuitive than the gold-standard Humphrey visual field test.

If the patient is using this device

This article has no commercial sponsorship.

Dr. Singh is a professor of ophthalmology and chief of the Glaucoma Division at Stanford University School of Medicine. Dr. Netland is Vernah Scott Moyston Professor and Chair at the University of Virginia in Charlottesville.



Standard visual field testing requires patients to suppress the foveation reflex—the desire to look directly at a new visual stimulus. In contrast, in this oculokinetic virtual reality test patients look directly at any new visual stimulus they’re able to see. When the system detects that the patient is looking at it, it becomes the new fixation point. The software uses the data to map out the patient’s visual field.

at home and has Wi-Fi, the device will try to connect to the internet before conducting the test. If it’s able to connect, it will check in the company’s database to see if the doctor has made any changes to the testing plan, such as changing from a 24-2 algorithm to a 10-2 test pattern. Then, whether or not the device is able to connect to the internet, it runs the test using the most recent instructions. All of the data from each test is saved locally on the device, and is then synced with the cloud. If the patient has Wi-Fi at home, this happens immediately; if not, the patient has to bring the goggles back to the doctor’s office, where the device connects to the clinic’s Wi-Fi network and immediately uploads the data to the cloud.

One question that remains unanswered is whether the software will end up incorporated into a specific pair of virtual reality goggles, or be made available as software only, able to work with any VR goggles. The potential to run on multiple systems certainly exists, but having the software associated with a single piece of hardware also offers the advantages of consistency, as well as putting less of a burden on the patient to locate the software online and load it into a device.

It’s worth noting that there are a number of non-VR visual field tests being developed that allow the

patient to take the test on a flat computer screen or using something like an iPad. At least one of these also uses an oculokinetic perimetry test. However, these tests have a number of inherent potential problems. For example:

- It’s impossible to know for sure that the screen is at the right distance from the patient’s eyes for the stimuli to appear in the patient’s visual field at the location you think you’re testing.
- The ambient lighting conditions during the test can’t be controlled.
- You can’t be sure about the screen resolution, or the background luminance during the test. (These can be significantly different from device to device.)

Obviously, these factors are under

OTHER VIRTUAL REALITY PERIMETERS CURRENTLY AVAILABLE INCLUDE:

- **VisuALL S System perimeter** (Keeler/Olleyes) olleyes.com or keelerusa.com/visuall-s-system.html
 - **VirtualEye Perimeter** (BioFormatix) bioformatix.com/perimetry.html
 - **PalmScan VF2000 Visual Field Analyzer** (Micro Medical Devices) micromedinc.com/our-devices/palmscan-vf2000-visual-field-perimeter/
 - **Advanced Vision Analyzer** (Elisar) elisar.com.
 - **Virtual Field** (Virtual Field) [home.virtualfield.io](http://virtualfield.io)
-

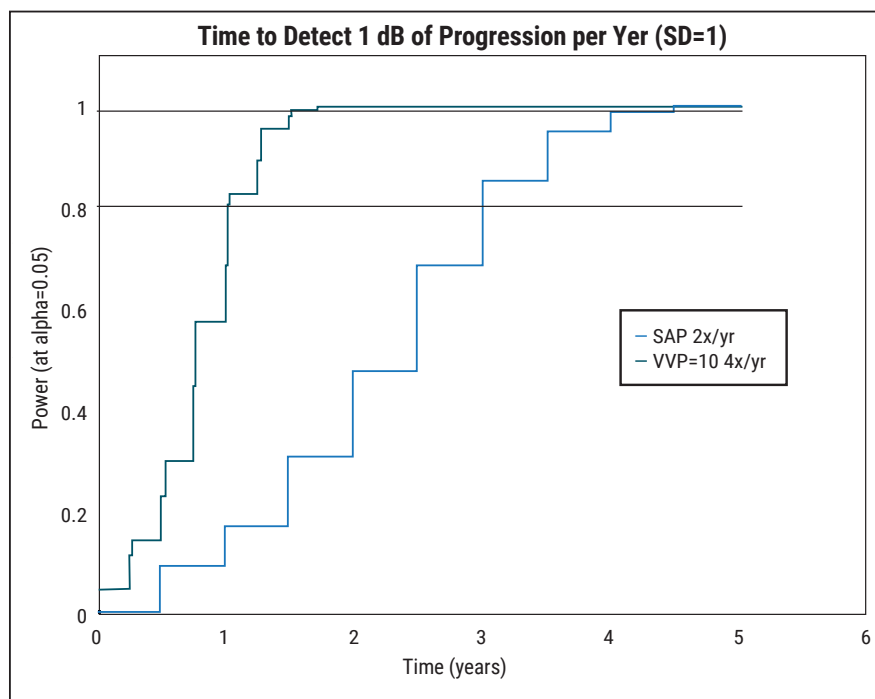
control when a patient takes the Humphrey visual field test. They can also be controlled when the test is given using virtual reality goggles.

The Power of Frequent Testing

Making visual field testing more pleasant and convenient for the patient is especially important for one reason in particular. As work done by Felipe Medeiros, MD, PhD, has demonstrated, the more often you’re able to test a glaucoma patient, the sooner you’re able to identify a fast progressor and increase your efforts to try to prevent further vision loss.

For example, suppose a patient is losing 1 dB of vision each year—a significant amount of loss. If you only do one visual field test per year, it will take you four years, on average, to realize that the patient is progressing at that rate. If you do two tests per year, you can detect that rate of loss within three years. If you do three tests per year—which is hard to do in a clinic population—you only decrease the time to detection to 2.6 years (on average). Dr. Medeiros’s suggestion for dealing with these practical constraints is to do several visual field tests when first working with the patient to establish a baseline, and then do two tests per year. Clearly, this is not ideal, but practically speaking, it’s the best we can do for most patients.

This is a key reason having a reliable visual field test that can be done outside the office—one that the patient won’t hate to take—could be a boon for patient care. Our work so far has shown that this test is easy for patients to take, even multiple times in a row. Right now we’re doing a longitudinal study where patients are taking the test 10 times per quarter, a schedule we call VVP-10. These glaucoma patients, all with existing visual field defects, were either given the device to take home or were mailed the device. They were trained to use it virtually. The test uses the same pattern of stimulus points as the Humphrey



Standard visual field testing is uncomfortable for the patient and has to be done in the office, making it difficult to do more than two tests per year. Patients don't mind doing the virtual test at a rate of 40 times per year, and it can be done at home. This increased frequency of testing can detect rapid disease progression much more quickly.

24-2, allowing us to compare the data more easily. We test each location in the visual field four times.

This test-taking schedule gives us the data from 40 tests per year, which cuts the time required to detect a fast progressor by as much as 66 percent, compared to doing two Humphrey tests every year. For example, a fast progressor, losing 1 dB per year, would be detected in three years using two Humphrey tests per year. Using our VVP-10 test and schedule, you'd detect that rate of loss in one year. (*See graph, above.*) The fact that patients don't find the test unpleasant or challenging—and they can do it at home—is crucial. (I can't imagine asking a patient to do the Humphrey test 40 times a year.)

Our data so far indicate several specific things:

- Test-retest variability is very good.
- Pointwise correlation between VVP-10 and Humphrey was quite strong. (We've submitted an abstract to ARVO discussing this data.)

- Global mean sensitivity on the Humphrey test correlated well with the fraction correct seen using VVP-10. Of course, we're not comparing the exact same thing, because the current version of VVP doesn't include a threshold test like the one included in the Humphrey test.

Regarding that last point, the Humphrey test uses a white background and a white stimulus. During the test, the stimulus is dimmed until the patient doesn't respond to it half the time. That's the patient's threshold sensitivity. Our current test uses a black stimulus on a white background and doesn't change the intensity of the stimulus, i.e., the contrast. (We're looking at incorporating a threshold test into upcoming versions of the VVP.)

VR for Other Visual Tests?

There's no question it would be convenient to have other visual tests that could also be taken using the virtual reality goggles, and I'm sure this will happen in the future

as technology advances. For now, though, measuring factors such as visual acuity is problematic, in part because the screen resolution doesn't currently match the eye's foveal resolution. The current off-the-shelf virtual reality technology can be used to measure visual acuity in eyes with poor vision—e.g., 20/70 or worse—but they can't do much better than that. Certain patients, such as those with amblyopia, can be measured to look for improvement.

Of course, current virtual reality goggles can be used for specific types of tests such as driving simulation tests. I can imagine a virtual reality test that simulates a child chasing a ball into the street in front of the car, or a pedestrian crossing a crosswalk against the light. They goggles might also be useable for binocular tests of peripheral vision such as the Esterman test.

In the meantime, other information crucial to monitoring glaucoma, such as optical coherence tomography data, could be obtainable at home soon, thanks to portable OCTs that are in development. Having OCT and visual field data without the patient having to come to the office could be a game-changer in our ability to save our patients' vision.

Stepping into the Future

The VVP system isn't commercially available, although the team is preparing a research version that will be available for preorder soon. They expect to start delivering it on a first-come, first-served basis before summer. They're hoping to enlist early adopters who are interested in contributing to the research effort.

What may lie ahead for this technology? The potential benefits of patients being able to conduct visual field tests at home are clear, but I can also see the benefit of using this in offices, where patients could take the test while waiting to see the ophthalmologist. The training module tutorial would be part of the testing experience; it could also serve to

REVIEW[®] of OPHTHALMOLOGY

Clinical advice you can trust

After 20 years, it's time for a new look!

Since its launch in 1994, you've welcomed Review into your practice, and relied on its timely, clinically-relevant information to get the best results for your patients. Today, that valuable content is still here, but in a fresh new design that showcases it better than ever.

LAYOUTS PUT CONTENT FRONT AND CENTER



New design reinforces the enduring value and impact of our content.

- Clean, contemporary style that honors our history while suiting the aesthetic of today.
- Ophthalmologists prefer print publications by a wide margin. We lean in to that, devoting more space to images, tables and graphics that augment the discussion and make Review “a keeper” in a world of throwaways.
- Full editorial spreads engage readers and aid quick reading for key highlights.
- From news briefs to in-depth features and monthly departments, Review readers stay up to date on the latest insights from top surgeons and clinicians.
- Review gives you the information you need from the various subspecialties as well as the arena of practice management—and has remained in print without interruption.

FOR AD RATES, CALL YOUR REVIEW SALES REP TODAY

Michael Hoster, Publisher

mhoster@jobson.com • 610-492-1028

Michele Barrett, Sales Representative
mbarrett@jobson.com • 215-519-1414

Jonathan Dardine, Sales Representative
jdardine@jobson.com • 610-492-1030

Dear Story MDS

WHICH MIGS FOR WHICH PATIENTS?

Type of glaucoma, disease severity, patient eye size and other factors all may influence your choice.

BY DEBORAH

WILLIAMS

With additional MDS options for managing glaucoma—especially given your eye size, angle, and disease severity—choosing the right MIGS for your patient is a complex task. This special issue provides a comprehensive overview of the various MIGS options available, including the latest in minimally-invasive glaucoma surgery (MIGS) and the role of the glaucoma surgeon in choosing the right MIGS for your patient.

The Canal-Based MIGS
MIGS are generally done in conjunction with cataract surgery. The Canal-Based MIGS, such as the iStent, are generally done in conjunction with cataract surgery. The Canal-Based MIGS, such as the iStent, are generally done in conjunction with cataract surgery.

of the eye, which is never normal and may be a sign of glaucoma.

of the eye, which is never normal and may be a sign of glaucoma. The Canal-Based MIGS, such as the iStent, are generally done in conjunction with cataract surgery.

of the eye, which is never normal and may be a sign of glaucoma. The Canal-Based MIGS, such as the iStent, are generally done in conjunction with cataract surgery.

of the eye, which is never normal and may be a sign of glaucoma. The Canal-Based MIGS, such as the iStent, are generally done in conjunction with cataract surgery.

of the eye, which is never normal and may be a sign of glaucoma. The Canal-Based MIGS, such as the iStent, are generally done in conjunction with cataract surgery.

of the eye, which is never normal and may be a sign of glaucoma. The Canal-Based MIGS, such as the iStent, are generally done in conjunction with cataract surgery.

of the eye, which is never normal and may be a sign of glaucoma. The Canal-Based MIGS, such as the iStent, are generally done in conjunction with cataract surgery.

of the eye, which is never normal and may be a sign of glaucoma. The Canal-Based MIGS, such as the iStent, are generally done in conjunction with cataract surgery.

of the eye, which is never normal and may be a sign of glaucoma. The Canal-Based MIGS, such as the iStent, are generally done in conjunction with cataract surgery.

of the eye, which is never normal and may be a sign of glaucoma.

of the eye, which is never normal and may be a sign of glaucoma. The Canal-Based MIGS, such as the iStent, are generally done in conjunction with cataract surgery.

of the eye, which is never normal and may be a sign of glaucoma. The Canal-Based MIGS, such as the iStent, are generally done in conjunction with cataract surgery.

of the eye, which is never normal and may be a sign of glaucoma. The Canal-Based MIGS, such as the iStent, are generally done in conjunction with cataract surgery.

of the eye, which is never normal and may be a sign of glaucoma. The Canal-Based MIGS, such as the iStent, are generally done in conjunction with cataract surgery.

of the eye, which is never normal and may be a sign of glaucoma. The Canal-Based MIGS, such as the iStent, are generally done in conjunction with cataract surgery.

of the eye, which is never normal and may be a sign of glaucoma. The Canal-Based MIGS, such as the iStent, are generally done in conjunction with cataract surgery.

of the eye, which is never normal and may be a sign of glaucoma. The Canal-Based MIGS, such as the iStent, are generally done in conjunction with cataract surgery.

of the eye, which is never normal and may be a sign of glaucoma. The Canal-Based MIGS, such as the iStent, are generally done in conjunction with cataract surgery.

Dear Story MDS

Cataract Surgery in Eyes With Angle Closure

These eyes present special challenges for the cataract surgeon. Here's help.

BY DEBORAH

WILLIAMS

Cataract surgery in eyes with angle closure presents unique challenges for the surgeon. This special issue provides a comprehensive overview of the various MIGS options available, including the latest in minimally-invasive glaucoma surgery (MIGS) and the role of the glaucoma surgeon in choosing the right MIGS for your patient.

Classification of Angle Closure
Whether to discuss acute angle closure or chronic angle closure, the classification of angle closure is essential for the surgeon. This special issue provides a comprehensive overview of the various MIGS options available, including the latest in minimally-invasive glaucoma surgery (MIGS) and the role of the glaucoma surgeon in choosing the right MIGS for your patient.

Preoperative Considerations
There are several preoperative considerations for the surgeon. This special issue provides a comprehensive overview of the various MIGS options available, including the latest in minimally-invasive glaucoma surgery (MIGS) and the role of the glaucoma surgeon in choosing the right MIGS for your patient.

Postoperative Considerations
There are several postoperative considerations for the surgeon. This special issue provides a comprehensive overview of the various MIGS options available, including the latest in minimally-invasive glaucoma surgery (MIGS) and the role of the glaucoma surgeon in choosing the right MIGS for your patient.

of the eye, which is never normal and may be a sign of glaucoma.

of the eye, which is never normal and may be a sign of glaucoma. The Canal-Based MIGS, such as the iStent, are generally done in conjunction with cataract surgery.

of the eye, which is never normal and may be a sign of glaucoma. The Canal-Based MIGS, such as the iStent, are generally done in conjunction with cataract surgery.

of the eye, which is never normal and may be a sign of glaucoma. The Canal-Based MIGS, such as the iStent, are generally done in conjunction with cataract surgery.

of the eye, which is never normal and may be a sign of glaucoma. The Canal-Based MIGS, such as the iStent, are generally done in conjunction with cataract surgery.

of the eye, which is never normal and may be a sign of glaucoma. The Canal-Based MIGS, such as the iStent, are generally done in conjunction with cataract surgery.

of the eye, which is never normal and may be a sign of glaucoma. The Canal-Based MIGS, such as the iStent, are generally done in conjunction with cataract surgery.

of the eye, which is never normal and may be a sign of glaucoma. The Canal-Based MIGS, such as the iStent, are generally done in conjunction with cataract surgery.

of the eye, which is never normal and may be a sign of glaucoma.

of the eye, which is never normal and may be a sign of glaucoma. The Canal-Based MIGS, such as the iStent, are generally done in conjunction with cataract surgery.

of the eye, which is never normal and may be a sign of glaucoma. The Canal-Based MIGS, such as the iStent, are generally done in conjunction with cataract surgery.

of the eye, which is never normal and may be a sign of glaucoma. The Canal-Based MIGS, such as the iStent, are generally done in conjunction with cataract surgery.

of the eye, which is never normal and may be a sign of glaucoma. The Canal-Based MIGS, such as the iStent, are generally done in conjunction with cataract surgery.

of the eye, which is never normal and may be a sign of glaucoma. The Canal-Based MIGS, such as the iStent, are generally done in conjunction with cataract surgery.

of the eye, which is never normal and may be a sign of glaucoma. The Canal-Based MIGS, such as the iStent, are generally done in conjunction with cataract surgery.

of the eye, which is never normal and may be a sign of glaucoma. The Canal-Based MIGS, such as the iStent, are generally done in conjunction with cataract surgery.

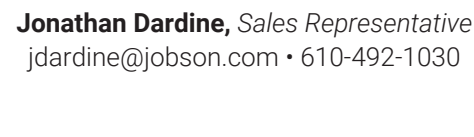
Dear Story MDS

REVIEW[®] of OPHTHALMOLOGY

Clinical advice you can trust

After 20 years, it's time for a new look!

Since its launch in 1994, you've welcomed Review into your practice, and relied on its timely, clinically-relevant information to get the best results for your patients. Today, that valuable content is still here, but in a fresh new design that showcases it better than ever.



New design reinforces the enduring value and impact of our content.

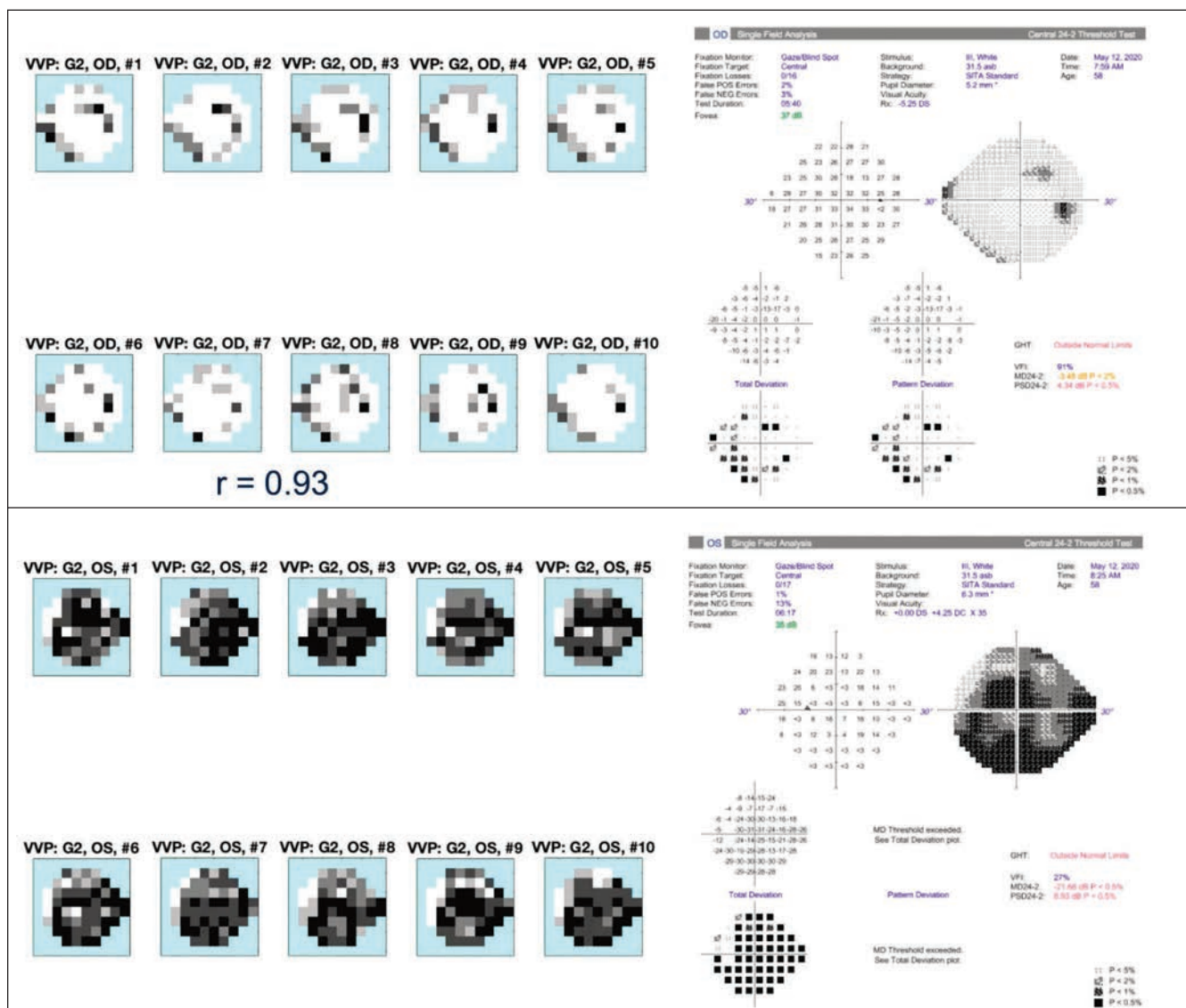
- Clean, contemporary style that honors our history while suiting the aesthetic of today.
- Ophthalmologists prefer print publications by a wide margin. We lean in to that, devoting more space to images, tables and graphics that augment the discussion and make Review “a keeper” in a world of throwaways.
- Full editorial spreads engage readers and aid quick reading for key highlights.
- From news briefs to in-depth features and monthly departments, Review readers stay up to date on the latest insights from top surgeons and clinicians.
- Review gives you the information you need from the various subspecialties as well as the arena of practice management—and has remained in print without interruption.

Michael Hoster, Publisher

mhoster@jobson.com • 610-492-1028

Michele Barrett, Sales Representative
mbarrett@jobson.com • 215-519-1414

Jonathan Dardine, Sales Representative
jdardine@jobson.com • 610-492-1030



Two examples of VVP-10 fields compared to Humphrey 24-2 fields for the same eyes. The point-by-point matches are close and the VVP-10 results are highly repeatable.

identify patients who are unable to follow the basic instructions.

One benefit of this possibility would be that a technician could administer many more tests than what’s currently feasible. I’ve seen some clinics run two to three visual field tests concurrently, but even doing this is challenging; here at UCSF, one technician can help two patients at most take the test at the same time. With VVP, I can imagine one technician administering 10 tests at the same time. Everyone in the waiting room could have virtual reality visual field goggles on, getting their visual field testing done.

This technology could also be used for real-world screening. The Humphrey test would be challenging to use for this purpose, but a simpler, more portable test like this could work. Of course, there are some visual field tests currently available that are lighter and more mobile than the Humphrey test, and those are sometimes used at eye-screening clinics. But you can’t get much smaller or more convenient than a pair of virtual-reality goggles.

We’re eager to have more doctors involved in collecting data, to help move the development of this technology forward. If you’re interested

in participating, you can sign up for a research kit at <https://seevidly.com/vvp>. Needless to say, I’m excited about the possibilities opened up by a new option like this. It’s a promising new step into a future in which we can do an even better job of preserving our patients’ vision. ◀

ABOUT THE AUTHOR



Dr. Ou is an associate professor of ophthalmology, academic director of the glaucoma division and vice chair for postgraduate education in the Department of Ophthalmology at the UCSF School of Medicine in San Francisco. She reports no financial ties to any product discussed.



“ I didn't realize
STARS
were little dots that twinkled ”

—Misty L, *RPE65* gene therapy recipient

**WE'RE SEEING
AMAZING RESULTS.
AND SO ARE THEY.**

At the Foundation Fighting Blindness our mission is everybody's vision. Our work shines a light on the darkness of inherited retinal diseases (IRDs).

We're the world's leading organization searching for treatments and cures. We need your help to fuel the discovery of innovations that will illuminate the future for so many. We have robust disease information, a national network of local chapters and support groups, local educational events, and our My Retina Tracker® Registry to help keep your patients connected with clinical and research advancements.

Help accelerate our mission
by donating at ECPs4Cures.org.

**FOUNDATION FIGHTING
BLINDNESS**

FightingBlindness.org



EDITED BY CARL REGILLO, MD,
AND YOSHIHIRO YONEKAWA, MD

RETINAL INSIDER

How to Manage Complex Macular Holes

Though they're a small percentage of cases, complex holes can take up a higher percentage of your time. Here's help.

BY AJAY E. KURIYAN, MD, MS
PHILADELPHIA

Though most macular holes can be closed successfully, it's the complicated hole presentations that can test your skills. Fortunately, surgeons and researchers have identified the factors that make MH closure more difficult, as well as techniques that can assist you in closing these more challenging holes. To benefit from their insights, read on.

What Makes a MH Complex

Macular holes can cause significantly decreased vision and symptomatic central scotomas.¹ Surgical repair with pars plana vitrectomy, inner limiting membrane peeling and gas tamponade yields closure rates of greater than 90 percent.^{2,3} However, certain risk factors for unsuccessful hole closure have been identified, including large size, myopic MHs, chronic MHs, traumatic MHs, concurrent retinal detachment, and previous unsuccessful macular hole surgery (refractory MHs).^{2,4,5}

Several techniques have been developed to increase macular hole surgery success rates in cases with the previously listed risk factors. Some of these techniques include:

- additional conventional surgical methods (broader ILM peeling and repeat fluid-gas exchange);
 - increasing retinal tissue compliance (macular detachment, retinal incisions);
 - MH scaffolds (inverted ILM flap, ILM free flap, posterior capsule flap);
 - the use of growth factors/cytokines to aid healing (placement of autologous blood/platelet rich plasma [PRP] or transforming growth factor-beta 2 [TGFβ2] into the macular hole, and macular laser);
 - pre- and subretinal amniotic membrane (AM) placement in the MH to act as both a scaffold and to release growth factors/cytokines to promote healing; and
 - tissue replacement (autologous neurosensory retinal transplant).
- Next, we'll delve into each of

these techniques in greater detail.

Additional Conventional Surgical Methods

Re-staining with indocyanine green or brilliant blue dye may identify an area of ILM that was missed during the initial peel, or reveal that a relatively small amount of ILM was initially peeled. Enlarging the previous ILM peel results in closure in 47 to 69 percent of refractory MH cases through further release of tangential traction on the hole (*Figure 1*).^{6,7} However, one study found that even in cases with anatomic improvement, there was limited visual improvement.⁶ Studies have also found that performing a fluid-gas exchange in the clinic for refractory or reopened MHs resulted in a 74 to 89 percent closure rate and improved vision.^{8,9} A benefit of this

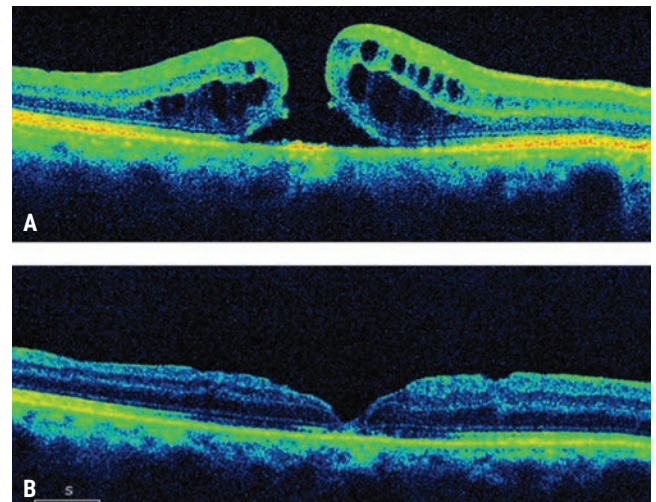


Figure 1. Wider inner limiting membrane peeling for a refractory macular hole. This patient presented with a visual acuity of 20/100 a month after failed initial macular hole surgery with ILM peeling (A). A subsequent wider ILM peel was performed with repeat gas tamponade. The macular hole closed with visual acuity improving to 20/30 (B).

This article has no commercial sponsorship.

Dr. Regillo is the director of the Retina Service of Wills Eye Hospital, professor of ophthalmology at Thomas Jefferson University School of Medicine, and the principle investigator for numerous major international clinical trials.

Dr. Yonekawa is an assistant professor of ophthalmology at Sidney Kimmel Medical College at Thomas Jefferson University. He serves on the Education Committee of the American Society of Retina Specialists, and the Executive Committee for the Vit Buckle Society, where he is also the vice president for Academic Programming.

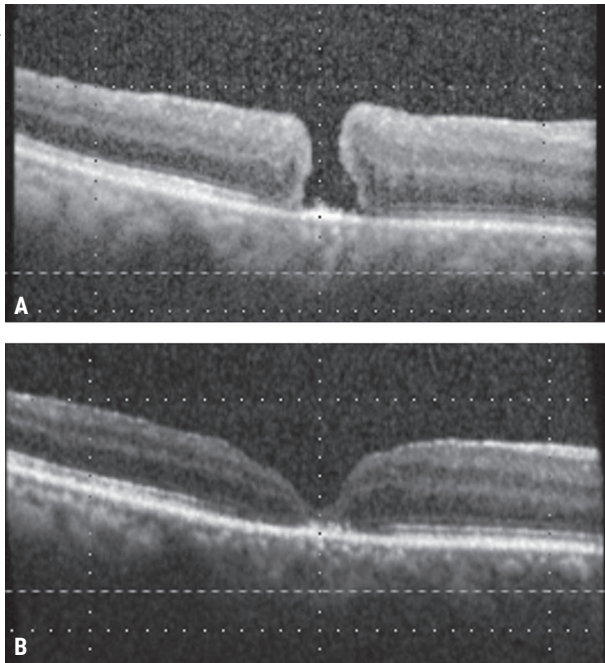


Figure 2. Macula detachment for a refractory macular hole. This patient presented with a visual acuity of 20/400 two weeks after failed initial macular hole surgery with ILM peeling (A). A macular detachment was induced, followed by fluid-air exchange and gas tamponade. The macular hole closed and vision improved to 20/150 (B).

technique is that it avoids another trip to the operating room.

Increasing Retinal Tissue Compliance

There are multiple approaches that can be employed to increase retinal tissue compliance in order to increase the likelihood of closing a complex MH.

One such approach is induction of a macular detachment.¹⁰ Small-gauge (e.g., 38-gauge) cannulas connected to the viscous fluid injection (VFI) kit can be used to perform controlled subretinal injection of BSS within the arcades to create blebs of subretinal fluid contiguous with the macular hole in all quadrants. A subsequent fluid-air exchange followed by gas tamponade has been reported to yield a 90-percent closure rate, with visual improvement in refractory or recurrent MHs (Figure 2).¹¹ In order to avoid creating additional entry sites into the retina, the University

of Toronto's Tina Felfeli, MD, and Efreim Mandelcorn, MD, developed a modification of this technique: A silicone soft-tip extrusion cannula is used to reflux fluid through the macular hole into the subretinal space.¹² The edges of the macular hole are then brushed together using passive extrusion, followed by a fluid-air exchange to drain any residual subretinal fluid through the hole, and then gas tamponade (Figure 3).

In a series of 39 complex (refractory, chronic, or ≥ 400 μm diameter) holes, this technique resulted in a 95 percent closure rate with vision improvement in 95 percent of patients.¹² Of note, these techniques are especially helpful in post-traumatic MH cases in which there is chorioretinal scarring in the extrafoveal macula that's limiting the tissue mobility.

Performing arcuate or radial full-thickness retinal incisions is an alternative approach to increasing retinal tissue compliance. Germantown, Tennessee, surgeon Steve Charles and colleagues first described the following arcuate retinotomy technique, which consists of an arcuate full-thickness incision 500 to 700 μm temporal to the

MH, followed by gas tamponade.¹³ In six patients with large, refractory MHs this technique yielded an 83 percent MH closure rate and half of patients had improved vision.¹³ Oporto, Portugal, surgeon Rita Reiss and colleagues described a variation of this technique in which the surgeon creates five radial full-thickness incisions centered on the MH, and extends them one hole diameter away from the MH border. This is followed by fluid-air exchange and gas tamponade.¹⁴ Using this technique, the investigators reported a 100-percent anatomic success rate with a mean gain of 5.6 lines of vision in seven patients with refractory MHs.¹⁴

While the techniques outlined above have demonstrated efficacy, the need to create a full-thickness neuroretinal incision—without causing any damage to the underlying retinal pigment epithelium and the choroid—makes these approaches more surgically challenging than some of the other techniques for complex MHs.

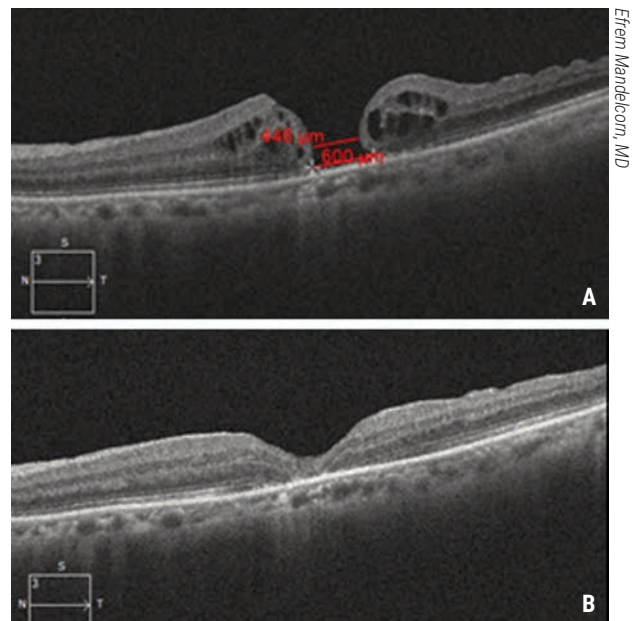


Figure 3. Macular hydrodissection for a large macular hole. This patient presented with a large macular hole and visual acuity of 20/200 (A). Vitrectomy and macular hydrodissection with a backflush cannula and gas tamponade were performed. The patient's macular hole closed and vision improved to 20/80 (B).

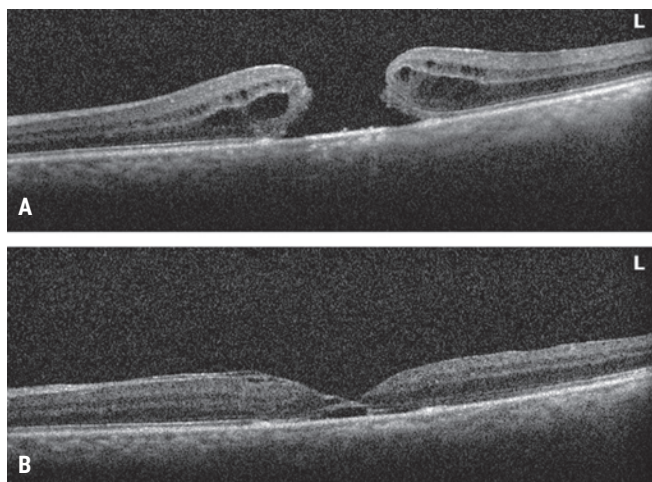


Figure 4. Inverted ILM flap for a large macular hole. This patient presented with a large macular hole and visual acuity of 20/200 (A). Vitrectomy, inverted ILM flap, fluid-air exchange and gas tamponade were performed. The patient’s macular hole closed and vision improved to 20/70 (B).

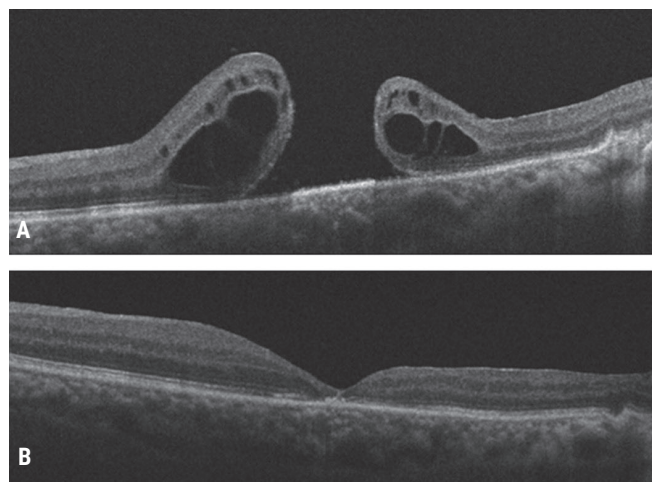


Figure 5. Free inner limiting membrane flap for a refractory, traumatic macular hole. A patient with a history of a traumatic macular hole who underwent vitrectomy, ILM peeling and gas tamponade presented with a refractory macular hole and 20/200 vision (A). He underwent ILM free flap placement into the macular hole, fluid-air exchange and gas tamponade. His macular hole closed and vision improved to 20/50 (B).

MH Scaffolds

Another approach for complex MHs is to provide a scaffold for Müller cell and tissue proliferation within the hole to aid in its closure. There are several techniques for accomplishing this, including the inverted ILM flap, ILM free flap and lens capsule flap techniques. A benefit of ILM flaps vs. capsule flaps is that, in addition to providing a scaffold, the ILM tissue may contain Müller cell fragments, which have been hypothesized to induce gliosis, which may increase rates of MH closure.^{4,15,16} The flaps also provide a “lid” to the macular hole that the retinal pigment epithelium can pump against, to help with closing the hole.

Zofia Michalewska, MD, and her colleagues in Lodz, Poland, first described the inverted ILM flap technique for large macular holes.¹⁵ In this technique, a wide ILM peel is completed with careful attention to detaching the peripheral macular ILM, while maintaining the ILM attachment around the MH.¹⁵ Subsequently, the detached ILM is inverted and placed into the MH, followed by fluid-air exchange.¹⁵

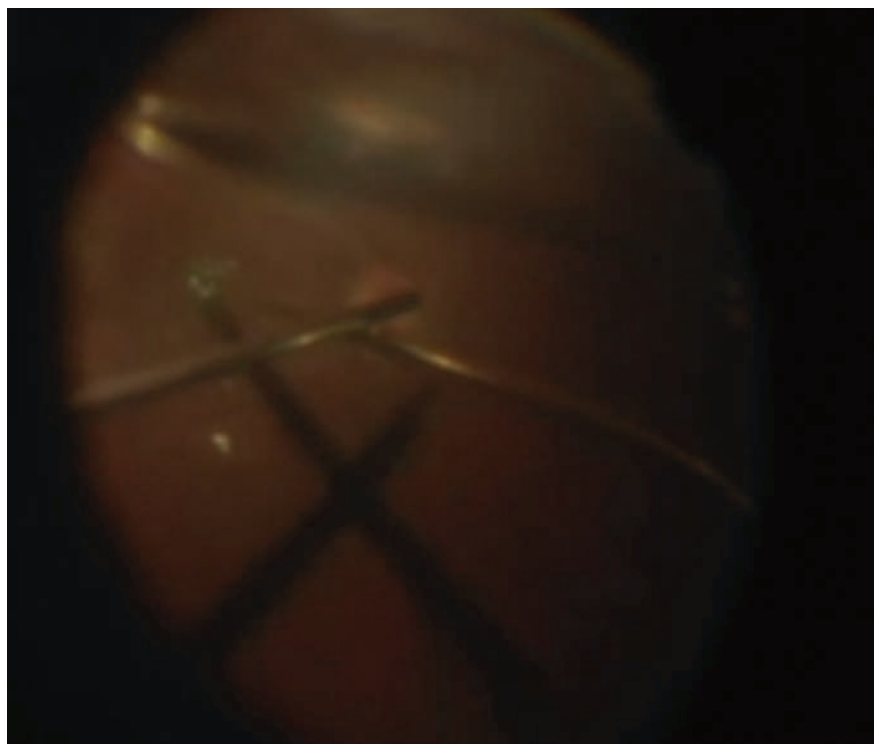


Figure 6. Bimanual technique for holding a free ILM flap in place. Chandelier illumination facilitates the bimanual technique of holding the ILM free flap over the macular hole during fluid-air exchange (see partial air fill at the top of the image).

This approach resulted in a higher rate of MH closure in patients (98 percent) compared to traditional MH surgery (88 percent), along with

better visual outcomes (Figure 4).¹⁵ In a multicenter series comparing the outcomes of traditional ILM peeling and the inverted ILM flap



Transforming the Medical Conference Experience for a Virtual World

Struggling to Transition From LIVE to Virtual Without Sacrificing the Attendee Experience?

Just like in the physical world, a spectacular digital conference takes months to plan and produce. The complexities of technology platforms and new formats can paralyze decision-making and stretch resources.

Partner with MedscapeLIVE!, the global leader in live and online medical learning, to effectively pivot your 2021 programming.

- Full-Service Event Management
- Broadcast Quality Production
- Immersive Virtual Platform
- Attendee, Sponsor, and Faculty Engagement

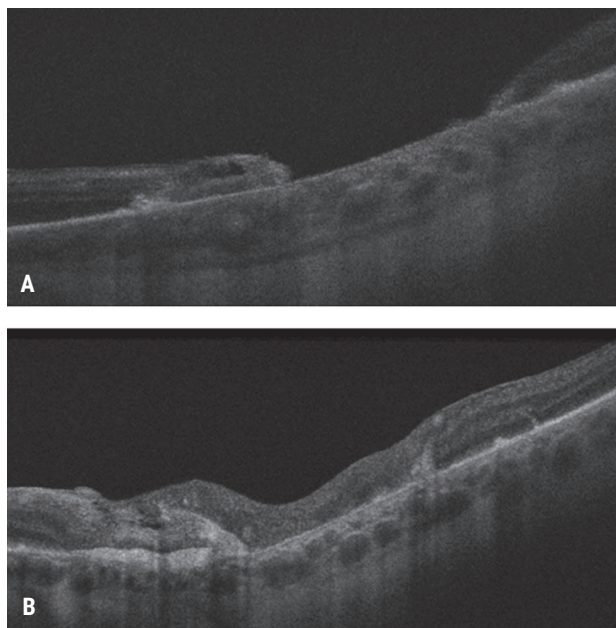


Figure 7. Autologous neurosensory retinal transplant for a large traumatic macular hole. This patient had a large traumatic macular hole with underlying choroidal atrophy secondary to an intraocular foreign body in the macula and count-finger vision (A). The patient underwent vitrectomy, inner limiting membrane peeling, autologous retina transplant into the macular hole, silicone oil tamponade for three months and silicone oil removal. The patient’s hole closed with visual acuity improving to 20/200-1 (B).

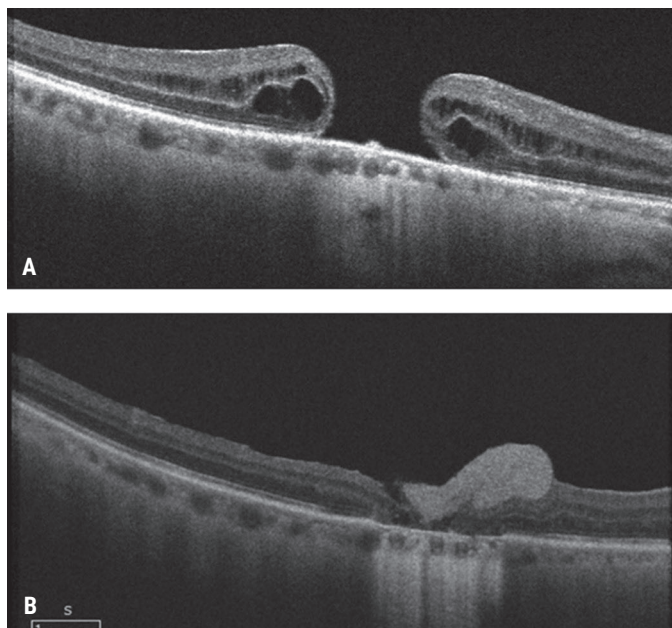


Figure 8. Pre-retinal human amniotic membrane for a chronic, large macular hole. A patient presented with a chronic macular hole of more than two years’ duration after a prior retinal detachment repair and count fingers vision (A). He underwent vitrectomy, ILM peeling and pre-retinal placement of human amniotic membrane over the macular hole and gas tamponade. As the amniotic membrane dissolved (hyperreflective preretinal material), the hole closed and the visual acuity improved to 20/150 (B).

technique for holes $\geq 800 \mu\text{m}$ in diameter, surgeons found non-statistically significantly improved hole closure (89 percent vs. 78 percent) and better vision recovery using the inverted ILM flap technique.¹⁷ A larger study of this technique found that MHs $\geq 400 \mu\text{m}$ in diameter had significantly better closure rates using the inverted ILM flap technique (96 percent) compared to conventional ILM peeling (79 percent), with better visual outcomes.

Several variations of the inverted ILM flap technique have been reported, with encouraging anatomic and visual outcomes. One such technique, the temporal inverted ILM flap technique, involves only peeling the ILM temporal to the MH, while keeping the edges of the ILM attached to the MH, and then draping the temporal ILM flap over the MH.¹⁸ The opposite approach has also been described and named the “Texas taco” technique,

in which the nasal ILM is peeled just beyond the temporal edges of the hole and then the ILM flap is draped over the MH.¹⁹

While the approaches discussed above are useful for cases that haven’t previously undergone ILM peeling, refractory MHs that didn’t close after ILM peeling aren’t amenable to them. Okayama, Japan’s Yuki Morizane, MD, co-authored a study that described the use of a free ILM flap to provide a MH scaffold in cases with a prior complete macular ILM peel (Figure 5).²⁰ They used this technique in 10 patients with refractory MHs and achieved 90-percent anatomic closure and visual improvement.²⁰ Additional studies of this technique in a small series of refractory MH patients²¹ and complex MH patients (large, chronic, and refractory MHs) found similar results.²²

In patients who have had a very wide ILM peel, the residual periph-

eral ILM may be thin and friable, rendering it difficult to obtain a suitable free flap. In such cases the use of non-ILM tissue, such as lens capsule, has been reported to be effective at accomplishing anatomic closure, and leading to improved vision.²³ One of the most challenging aspects of this technique is maintaining the free ILM or lens capsule flap in the macular hole during the fluid-air exchange. Viscoelastic agents or perfluorocarbon (PFC, Perfluoron, Alcon Laboratories) can help maintain the flap in position and limit the redundancy of the flap in the MH.^{24,25} Alternatively, chandelier illumination with a bimanual technique can be used to hold the flap in place with the forceps while performing the fluid-air exchange (Figure 6).

Growth Factors and Cytokines

Since growth factors and cytokines modulate the physiologic wound

healing response and may aid MH closure,²⁶ one approach to complex MHs involves placing these adjuncts into the MH. Bascom Palmer surgeon William Smiddy and his colleagues found that using TGFβ2 for refractory MHs led to an 83-percent closure rate with ≥3 lines of vision in 52 percent of patients.²⁷ Another prospective study utilizing this technique found a dose-response effect with further vision improvement with higher concentrations of TGFβ2.²⁸ The lack of commercially available and FDA-approved TGFβ2 for intraocular use has limited the use of this technique, however.

TGFβ2 is one of several growth factors and cytokines released by platelets. Platelet-rich plasma has been used in various fields of medicine to modulate wound healing.²⁹ For

complex MHs, autologous PRP has been studied in myopic and refractory MHs with high closure rates and improved vision.^{30,31} Obtaining PRP from a patient's peripheral blood requires special equipment, which may not be readily available at all surgical facilities, so others have looked at the use of autologous blood to aid MH closure. One study found low rates of closure in refractory MHs with autologous blood,³¹ but another found high rates of closure when combining the inverted ILM flap technique and autologous blood for large MHs.³²

Laser can induce the release of growth factors and cytokines without the placement of adjuncts into the eye. One study compared outcomes after application of laser photocoagulation at the center of MH prior to vitrectomy (three burns of 100 μm size, 0.04- to 0.1-second

duration, and 60 to 100 mW), followed by vitrectomy, ILM peeling and gas tamponade (94%), versus traditional vitrectomy, ILM peeling and gas tamponade without pre-surgical laser photocoagulation, in large MHs (≥400 μm diameter).³³ There were higher MH closure rates and significantly better visual outcomes in the complex MH patients who underwent the preoperative laser treatment.³³

The presence of lasers in most retina clinics makes this an easily accessible technique. While there are concerns about creating a scotoma from laser in the macula, the settings are low enough that a visually significant scotoma is unlikely.

Amniotic Membrane

An approach that combines the goals of providing a scaffold and modulating wound healing is the

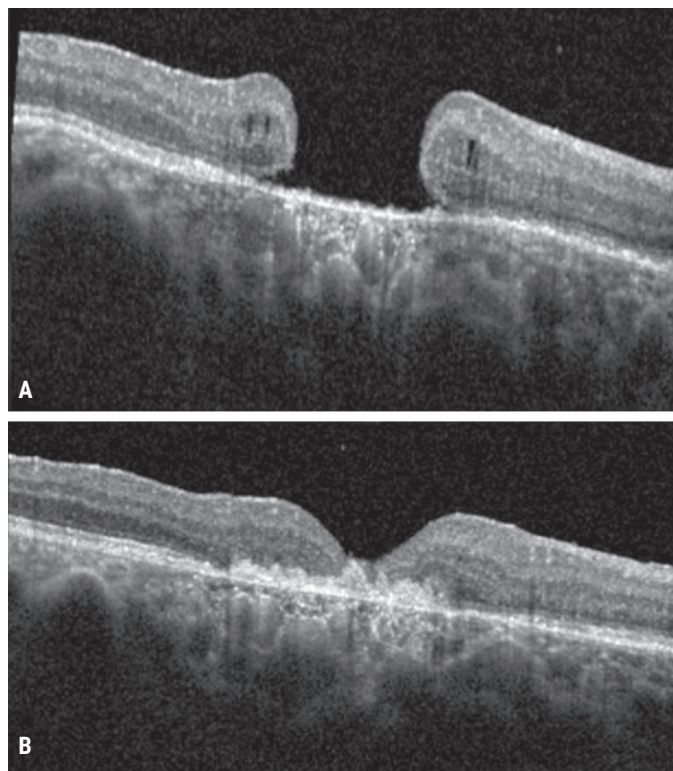


Figure 9. Subretinal human amniotic membrane for a refractory macular hole. A patient with count-fingers vision presented with a refractory macular hole after prior vitrectomy, ILM peeling and gas tamponade. A human amniotic membrane graft was placed in a subretinal position followed by gas tamponade. The patient's macular hole closed and visual acuity improved to 20/200 (B).

placement of amniotic membrane in the MH. AM has been demonstrated to be non-toxic to the retina in animal studies, acts as a scaffold for wound healing, and releases several factors that promote wound healing.^{5,34,35} Stanislao Rizzo, MD, and colleagues at the University of Florence first described placement of subretinal human AM (obtained from a tissue bank), followed by gas tamponade, in eight patients with refractory MHs, which yielded 100-percent closure and improvement of vision.³⁶ One study reported the use of commercially available human amniograft from Bio-Tissue (Tissue Tech, Miami) using sub- and pre-retinal placement approaches (Figure 7 and 8) result-

ing in successful hole closure and improved visual outcomes.⁵ For this technique, a dermal punch can be used to create the appropriately sized tissue for hole placement. It's important that the chorion ("sticky") side is facing the retinal pigment epithelium. Forceps can be used to grasp the non-chorion side and fold the AM to facilitate insertion into the vitreous cavity through a cannula. Cutting a small notch on the AM can aid the orientation of the membrane inside the eye. Once placed in or over the MH, the AM is much more adherent and is less likely to move during the fluid-air exchange than the ILM or capsule free flaps.

Tissue Replacement

Placement of peripheral autologous retina into the macular hole has shown some efficacy in refractory

MHs.³⁷ In this technique, a patch of retina is cut from the periphery of the eye and placed over the hole. The study reported an 88-percent closure rate and significantly improved vision in these patients (Figure 9).³⁷ This technique has also been successful in myopic MHs.³⁸ The use of PFO prior to the creation of the peripheral autologous graft is very helpful. The PFO should be instilled until it covers the retina peripheral to the location of the planned graft harvest site. It's recommended that the retina graft be half a disc diameter larger than the size of the MH.³⁷ This area can be marked by diathermy, followed by laser around the site. The graft can then be created with pneumatic vertical scissors and moved under the PFO to the hole. The use of fluid-air exchange and then silicone oil or gas placement, direct PFO to silicone oil exchange, and simply short term PFO tamponade have all been described.³⁸

In conclusion, traditional MH surgery is generally successful, but complex MHs can have lower success rates. There are multiple options for these complex MHs that have been found to have positive anatomic and visual outcomes. At this point, there's still a paucity of data comparing these techniques, and no single technique has been found to be superior. ◀

1. McCannel CA, Ensminger JL, Diehl NN, Hodge DN. Population-based incidence of macular holes. *Ophthalmology* 2009;116:7:1366–9.
2. Kumagai K, Furukawa M, Ogino N, Uemura A, Demizu S, Larson E. Vitreous surgery with and without internal limiting membrane peeling for macular hole repair. *Retina* 2004;24:5:721–7.
3. Sheidow TG, Blinder KJ, Holekamp N, Joseph D, Shah G, Grand MG, et al. Outcome results in macular hole surgery: An evaluation of internal limiting membrane peeling with and without indocyanine green. *Ophthalmology* 2003;110:9:1697–701.
4. Grewal DS, Fine HF, Mahmoud TH. Management of challenging macular holes: Current concepts and new surgical techniques. *Ophthalmic Surg Lasers Imaging Retina* 2016;47:6:508–13.
5. Kuriyan AE, Hariprasad SM, Fraser CE. Approaches to refractory or large macular holes. *Ophthalmic Surg Lasers Imaging Retina* 2020;51:7:375–82.
6. D'Souza MJ, Chaudhary V, Devenyi R, Kertes PJ, Lam

- W-C. Re-operation of idiopathic full-thickness macular holes after initial surgery with internal limiting membrane peel. *Br J Ophthalmol* 2011;95:11:1564–7.
7. Moisseiev E, Fabian ID, Moisseiev J, Barak A. Outcomes of repeated pars plana vitrectomy for persistent macular holes. *Retina* 2013;33:6:1137–43.
8. Johnson RN, McDonald HR, Schatz H, Ai E. Outpatient postoperative fluid–gas exchange after early failed vitrectomy surgery for macular hole. *Ophthalmology* 1997;104:12:2009–13.
9. Rao P, Lum F, Wood K, Salman C, Burugapalli B, Hall R, et al. Real-world vision in age-related macular degeneration patients treated with single anti-VEGF drug type for 1 year in the IRIS Registry. *Ophthalmology* 2018;125:4:522–528.
10. Oliver A, Wojcik EJ. Macular detachment for treatment of persistent macular hole. *Ophthalmic Surg Lasers Imaging Retina* 2011;42:6:516–8.
11. Szigiato A-A, Gilani F, Walsh MK, Mandelcorn ED, Muni RH. Induction of macular detachment for the treatment of persistent or recurrent idiopathic macular holes. *Retina* 2016;36:9:1694–8.
12. Felfeli T, Mandelcorn ED. MACULAR hole hydrodissection: Surgical technique for the treatment of persistent, chronic, and large macular holes. *Retina* 2019;39:4:743–52.
13. Charles S, Randolph JC, Neekhra A, Salisbury CD, Littlejohn N, Calzada JI. Arcuate retinotomy for the repair of large macular holes. *Ophthalmic Surg Lasers Imaging Retina* 2013;44:1:69–72.
14. Reis R, Ferreira N, Meireles A. Management of stage IV macular holes: When standard surgery fails. *Case Rep Ophthalmol* 2012;3:2:240–50.
15. Michalewska Z, Michalewski J, Adelman RA, Nawrocki J. Inverted internal limiting membrane flap technique for large macular holes. *Ophthalmology* 2010;117:10:2018–25.
16. Singh SR, Hariprasad SM, Narayanan R. Current management of macular hole. *Ophthalmic Surg Lasers Imaging Retina* 2019;50:2:61–8.
17. Narayanan R, Singh SR, Taylor S, Berrocal MH, Chhablani J, Tyagi M, et al. Surgical outcomes after inverted internal limiting membrane flap versus conventional peeling for very large macular holes. *Retina* 2019;39:8:1465–9.
18. Michalewska Z, Michalewski J, Dulczewska-Cichecka K, Adelman RA, Nawrocki J. Temporal inverted internal limiting membrane flap technique versus classic inverted internal limiting membrane flap technique: A comparative study. *Retina* 2015;35:9:1844–50.
19. Major JJ, Lampen SI, Wykoff CC, Ou WC, Brown DM, Wong TP, et al. The Texas taco technique for internal limiting membrane flap in large full-thickness macular holes: A Short-Term Pilot Study. *Retina* 2020;40:3:552–556.
20. Morizane Y, Shiraga F, Kimura S, Hosokawa M, Shiode Y, Kawata T, et al. Autologous transplantation of the internal limiting membrane for refractory macular holes. *Am J Ophthalmol* 2014;157:4:861–9.
21. Pires J, Nadal J, Gomes NL. Internal limiting membrane translocation for refractory macular holes. *Br J Ophthalmol* 2017;101:3:377–82.
22. De Novelli FJ, Preti RC, Monteiro MLR, Pelayes DE, Nóbrega MJ, Takahashi WY. Autologous internal limiting membrane fragment transplantation for large, chronic, and refractory macular holes. *Ophthalmic Res* 2016;55:1:45–52.
23. Chen S-N, Yang C-M. Lens capsular flap transplantation in the management of refractory macular hole from

- multiple etiologies. *Retina* 2016;36:1:163–70.
24. Andrew N, Chan WO, Tan M, Ebner A, Gilhotra JS. Modification of the inverted internal limiting membrane flap technique for the treatment of chronic and large macular holes. *Retina* 2016;36:4:834–7.
25. Shin MK, Park KH, Park SW, Byon IS, Lee JE. Perfluoro-n-Octane-assisted single-layered inverted internal limiting membrane flap technique for macular hole surgery. *Retina* 2014;34:9:1905–10.
26. Idrees S, Sridhar J, Kuriyan AE. Proliferative Vitreoretinopathy: A Review. *Int Ophthalmol Clin* 2019;59:1:221–40.
27. Smiddy WE, Sjaarda RN, Glaser BM, Flynn JH, Thompson JT, Hanham A, et al. Reoperation after failed macular hole surgery. *Retina* 1996;16:1:13–8.
28. Glaser BM, Michels RG, Kuppermann BD, Sjaarda RN, Pena RA. Transforming growth factor-β2 for the treatment of full-thickness macular holes: A prospective randomized study. *Ophthalmology* 1992;99:7:1162–73.
29. Foster TE, Puskas BL, Mandelbaum BR, Gerhardt MB, Rodeo SA. Platelet-rich plasma: from basic science to clinical applications. *Am J Sports Med* 2009;37:11:2259–72.
30. Figueroa MS, Govetto A, de Arriba-Palomero P. Short-term results of platelet-rich plasma as adjuvant to 23-G vitrectomy in the treatment of high myopic macular holes. *Eur J Ophthalmol* 2016;26:5:491–6.
31. Purtskhvanidze K, Frühsorger B, Bartsch S, Hedderich J, Roeder J, Treumer F. Persistent full-thickness idiopathic macular hole: Anatomical and functional outcome of vitrectomy with autologous platelet concentrate or autologous whole blood. *Ophthalmologica* 2018;239:1:19–26.
32. Lyu W-J, Ji L-B, Xiao Y, Fan Y-B, Cai X-H. Treatment of refractory giant macular hole by vitrectomy with internal limiting membrane transplantation and autologous blood. *Int J Ophthalmol* 2018;11:5:818.
33. Cho HY, Kim YT, Kang SW. Laser photocoagulation as adjuvant therapy to surgery for large macular holes. *Korean J Ophthalmol* 2006;20:2:93–8.
34. Rosenfeld PJ, Merritt J, Hernandez E, Meller D, Rosa RH, Tseng SCG. Subretinal implantation of human amniotic membrane: A rabbit model for the replacement of Bruch's membrane during submacular surgery. *Invest Ophthalmol Vis Sci* 1999;40:4:S206–S206.
35. Tseng SC, Espana EM, Kawakita T, Di Pascuale MA, Li W, He H, et al. How does amniotic membrane work? *Ocul Surf* 2004;2:3:177–87.
36. Rizzo S, Caporossi T, Tartaro R, Finocchio L, Franco F, Barca F, et al. A human amniotic membrane plug to promote retinal breaks repair and recurrent macular hole closure. *Retina*. 2019;39:S95–103.
37. Grewal DS, Charles S, Parolini B, Kadonosono K, Mahmoud TH. Autologous retinal transplant for refractory macular holes: Multicenter international collaborative study group. *Ophthalmology* 2019;126:10:1399–1408.
38. Grewal DS, Mahmoud TH. Autologous neurosensory retinal free flap for closure of refractory myopic macular holes. *JAMA Ophthalmol* 2016;134:2:229–30.

ABOUT THE AUTHOR



Dr. Kuriyan is an assistant professor of ophthalmology at Sidney Kimmel Medical College of Thomas Jefferson University. He has no relevant disclosures.

Reading Performance in Glaucoma Patients

Researchers from Brazil, the United States and Scotland aimed to determine whether patients with glaucoma with preserved central vision had impaired reading performance compared with healthy controls. The cross-sectional study included 35 patients with glaucoma and 32 similar-age controls, all with visual acuity better than 0.4 logMAR in both eyes.

Each participant had a detailed ophthalmological exam followed by a five-chart reading performance test using a Portuguese version of the Minnesota Low Vision Reading Test (MNREAD). Correlation between reading performance (reading speed) and ocular parameters was investigated.

Participants had an average age of 63 ± 12.6 years. Here are some of the findings:

- In the glaucoma group, mean deviation (MD) in the better eye was -6.29 ± 6.36 dB; in the worse eye it was -11.08 ± 0.23 dB.
- No significant difference was found in age, gender, race, education, visual acuity or systemic comorbidities between the groups.
- Participants with glaucoma had significantly slower reading speeds, with an average of 83.2 ± 25.12 words per minute compared with 102.29 ± 29.57 wpm in controls ($p=0.006$); reading speed was slower for all five charts.
- The odds of having glaucoma

increased by 1.29 (CI, 1.07 to 1.56, $p=0.009$) for each 10 wpm decrease in average reading speed, with this relationship maintained after accounting for age, level of education and sharpness of visual acuity.

Researchers found that patients with mild-to-moderate glaucoma had worse reading performance compared with similar-age controls, despite both having preserved central vision.

J Glaucoma 2021; Feb 3. [Epub ahead of print].

Ikeda MC, Bando AH, Hamada KU, et al.

Risk Factors for Fellow-Eye Treatment in Protocol T

Investigators from the Boston University School of Medicine and the Veterans Affairs Boston Healthcare System identified risk factors for needing fellow-eye treatment of diabetic retinopathy with vascular endothelial growth factor injections, in the Diabetic Retinopathy Clinical Research Network (DRCR.net) Protocol T trial, as part of a post hoc analysis of randomized clinical trial data.

Cox regression analysis was performed at 52 and 104 weeks to determine risk factors for treatment in 360 fellow eyes. Survival analysis was performed to determine mean time to treatment based upon medication used.

- Here are some of the findings:
- Of 360 fellow eyes, 142 (39.4

percent) required treatment between weeks four and 104.

- Risk factors that the authors say predicted a lower likelihood of year-one treatment included older subject age (HR=0.98; CI, 0.96 to 0.99; $p=0.02$) and higher baseline study eye ETDRS score (HR=0.98; CI, 0.97 to 0.99; $p=0.04$).

- Center-involving DME at baseline in the fellow eye was predictive of a higher treatment need at 52 weeks (HR=1.89; CI, 1.42 to 2.51, $p<0.0001$) and 104 weeks (HR=2.68; CI, 1.75 to 4.11, $p<0.0001$).

- Subjects treated in the study eye with aflibercept (HR=0.574; CI, 0.371 to 0.887, $p=0.013$) and ranibizumab (HR=0.58; CI, 0.36 to 0.94, $p=0.03$) were less likely to require first-year fellow-eye injection than subjects treated with bevacizumab, although they note that this difference was no longer statistically significant at week 104 (aflibercept HR=0.77; CI, 0.52 to 1.16; $p=0.21$; ranibizumab HR=0.66; CI, 0.43 to 1.00, $p=0.05$).

- Mean time to treatment in the study was significantly shorter in the group of patients who received bevacizumab injections (bevacizumab 25.83 weeks, aflibercept 38.75 weeks, ranibizumab 34.70 weeks [$p=0.012$]).

The study's investigators reported that bilateral treatment with intravitreal anti-vascular endothelial growth factor injections was common during the DRCR.net Protocol T study. They added that, based on their analysis, the choice of medication may impact the risk of needing fellow-eye treatment. ◀

Graefes Arch Clin Exp Ophthalmol 2021; Feb 10. [Epub ahead of print].
Ness S, Green M, Loporchio D, et al.



EDITED BY MEERA SIVALINGAM, MD, MPH

WILLS EYE RESIDENT CASE REPORT

A 5-year-old female presents to her pediatrician with a “pink” left eye.

PATRICK B. RAPUANO, MD, RALPH C. EAGLE JR, MD, AND CAROL L. SHIELDS, MD

PHILADELPHIA

Presentation

A 5-year-old female presented to her pediatrician with a “pink” left eye, which progressed to a painful eye with a dilated pupil over the next two weeks. The patient was evaluated by an optometrist who found 2+ anterior chamber cells in the left eye and initiated treatment with prednisolone acetate. Examination of the asymptomatic right eye was within normal limits.

Several days later another optometrist found that the visual acuity in the left eye was 20/25 and the intraocular pressure 40 mmHg. There was 2+ anterior chamber cells and a spiderweb-like plaque with a scalloped border on the posterior lens capsule. There were 1+ cells in the anterior vitreous and a white vitreous strand extended from the inferotemporal ora serrata to the mid-peripheral retina. The right eye remained normal.

The patient underwent an extensive work-up at an outside facility, including magnetic resonance imaging of the brain, which was read as normal, and an extensive serologic work up including CBC, BMP, ESR, ANA, tick-borne diseases panel (including Lyme), treponemal antibodies, toxoplasma, QuantiFERON gold, ACE, lysozyme, bartonella and HLA-B27, all of which were normal.

During the subsequent months, the patient had persistent inflammation and elevated intraocular pressure in the left eye, necessitating corticosteroid injections, goniosynechiolysis, and ultimately an Ahmed valve tube shunt. She was managed by ophthalmology in consultation with rheumatology and treated with methotrexate and adalimumab for recurrent episodes of inflammation. Finally, 11 months after initial presentation, the patient was referred for an additional opinion by our team.

Examination

On examination, the right eye was normal, with 20/20 acuity and 15 mmHg IOP. Acuity in the left eye was 20/200 and the IOP was 20 mmHg, despite the patient being on several glaucoma medications. The anterior segment exam revealed a white and quiet conjunctiva, clear cornea and a long tube shunt in the anterior chamber. There was complete retraction of the iris into the anterior chamber angle and the anterior and posterior surfaces of the inferonasally subluxed lens were enveloped by a translucent membrane (*Figure 1A*). The view of the posterior segment was hazy, and showed a fluffy, white membrane with occasional cysts lining the pars plana, and an optic nerve with a cup-to-disc ratio of 0.3. B-scan of the posterior segment in the left eye revealed a peripheral, solid mass (*Figure 1B*). The retina was flat.

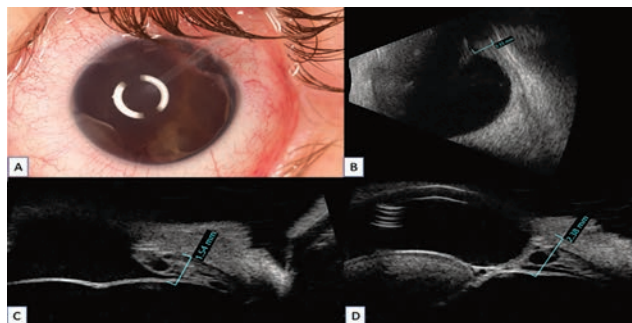


Figure 1. A) Clinical features on an external photograph. B) B-scan ultrasonography of mass with a depth of 3.33 mm. C,D) Ultrasound biomicroscopy of ciliary body mass demonstrating intratumoral cysts.

What is your diagnosis? What further workup would you pursue? The diagnosis appears on p.80.

Career Opportunities

OPHTHALMOLOGISTS
Danbury, CT

Ophthalmologists to share office with long standing Ophthalmologist in Danbury, CT. High quality equipment. \$2,250 per month or adjoining office without equipment- \$1,750 per month.

203-545-3539 or
email mehrimd@aol.com



Do you have Products and Services for sale?

CONTACT US TODAY
FOR CLASSIFIED ADVERTISING
Toll free: 888-498-1460
E-mail: sales@kerhgroup.com



Targeting Ophthalmologists?

CLASSIFIED ADVERTISING WORKS



Contact us today
for classified advertising:
Toll free: **888-498-1460**
E-mail: sales@kerhgroup.com



ADVERTISER INDEX

This advertiser index is published as a convenience and not as part of the advertising contract. Every care will be taken to index correctly. No allowance will be made for errors due to spelling, incorrect page number, or failure to insert.

Akorn Pharmaceuticals39
www.MyAkornEyeCare.com

Alcon 15 & 16
..... (800) 451-3937
..... www.Alcon.com

Alcon 37
..... (800) 451-3937
..... www.myalcon.com/custompak

Alcon 51
..... (800) 451-3937
..... www.Alcon.com

Allergan..... 23 & 24
..... www.allergan.com

Bausch + Lomb 7 & 8
..... (800) 323-0000
..... www.lotemaxsm.com

Bruder Ophthalmic Products.....45
..... (888) 827-8337
..... www.brudersx.com

EyePoint Pharmaceuticals Cover Tip
..... www.dexycu.com

Eyevance..... 19 & 20
..... (817) 677-6120
..... www.MyZerviate.com

Eyevance..... 27 & 28
..... (817) 677-6120
..... www.mytobradexst.com

Glaukos5 & 13
..... (800) 452-8567
..... www.glaukos.com

Imprimis Pharmaceuticals, Inc.33
..... (858) 704-4040
..... www.imprimisrx.com

Ivantis, Inc. 62 & 63
..... info@ivantisinc.com
..... www.ivantisinc.com

Kala Pharmaceuticals47
..... (781) 996-5252
..... info@kalarx.com
..... www.kalarx.com

Keeler Instruments 31
..... (800) 523-5620
..... www.keelerusa.com

Novartis Pharmaceuticals..... 82, 83 & 84
..... www.novartis.com

Ocular Therapeutix11 & 12
..... www.ocutx.com

Oculus, Inc......53
..... (888) 519-5375
..... ads@oculususa.com
..... www.pentacam.com/axl-wave

RVL Pharmaceuticals, Inc.23
..... (866) 600-4799
..... www.Upneeq.com

US Ophthalmic59
..... (888) 881-1122
..... info@usophthalmic.com
..... www.usophthalmic.com

Diagnosis and Management

The patient was examined under anesthesia. Anterior segment fluorescein angiography showed 360-degree neovascularization of the iris retracted into the anterior chamber angle and neovascularization within the enwrapping lenticular membrane. Anterior segment OCT demonstrated flattening of the iris surface from iris neovascularization. Ultrasound biomicroscopy was most informative, demonstrating a multicystic, wispy ciliary body mass that involved nine clock-hours and extended into the anterior chamber, enwrapping the tube shunt (*Figure 1C*). All imaging of the right eye was normal.

Based on the results of the exam and imaging, the patient was suspected to harbor a non-pigmented ciliary epithelial medulloepithelioma. MRI of

the brain and orbits revealed no evidence of extraocular extension of the tumor. Because the tumor involved at least 75 percent of the pars plana and a tube shunt was present, minimal-manipulation enucleation was performed to minimize the risk of extrascleral extension and metastasis. The globe and tube shunt were removed completely as a unit and orbital biopsies were taken. The patient tolerated the procedure well without complication.

Gross dissection of the enucleated eye was notable for a poorly circumscribed white-to-tan tumor with a fluffy translucent appearance and cystoid spaces that filled part of the posterior chamber and covered the pars plicata and the anterior half of the pars plana of the ciliary body. Several delicate strands extended from the tumor onto the peripheral retina (*Figure 2A*). Histopathology disclosed a basophilic, mitotically-active cellular tumor on the inner surface of the ciliary body that contained multiple Flexner-Wintersteiner rosettes with small central lumina (*Figure 2C*). The tumor contained pools of mucopolysaccharide and had areas with a diktyomatous appearance (*Figure 2B*). The nuclei of the tumor cells showed convincingly positive immunoreactivity for RB1 protein (*Figure 2D*), excluding retinoblastoma as a diagnosis. There was no sign of optic nerve invasion, nor evidence of extraocular tumor in the Ahmed tube shunt capsule or orbital biopsies. No heteroplasic elements were present. The final diagnosis was non-teratoid malignant ciliary body medulloepithelioma without extrascleral extension. The patient didn't require additional radiotherapy or chemotherapy.

Discussion

Medulloepithelioma is a rare tumor of the nonpigmented ciliary epithelium that occurs most frequently in children at a mean age of onset of 5 years.¹⁻³ The classic tetrad for medulloepithelioma is leukocoria, lens notch, neovascular glaucoma and a cystic ciliary body mass.^{4,5} Common findings include glaucoma in 44 percent, cataract in 46 percent, iris neovascularization in 51 percent, neoplastic cyclitic membrane in 51 percent and intratumoral cysts in 61 percent. By histopathology, 80 percent of tumors are malignant.³ When present, a neoplastic cyclitic membrane serves to distinguish medulloepithelioma from retinoblastoma and Coats disease.³ Diagnosis of this tumor is often challenging; one study demonstrated that 88 percent are misdiagnosed initially and 39 percent have undergone prior treatment for secondary effects of the tumor prior to diagnosis.³

The patient with medulloepithelioma reported here was thought to have uveitic glaucoma and was treated with systemic immunosuppressive therapy and an Ahmed tube shunt. Although medulloepithelioma typically masquerades as neovascular glaucoma,^{1,3,6,7} it also can masquerade as uveitic glaucoma.^{8,9} Medulloepithelioma has been misdiagnosed as persistent fetal vasculature (PFV) (also known as persistent hyperplastic primary vitreous [PHPV])⁹ and, in fact, 20 percent of patients diagnosed with medulloepithelioma have been found to have some degree of PFV/PHPV.² The un-

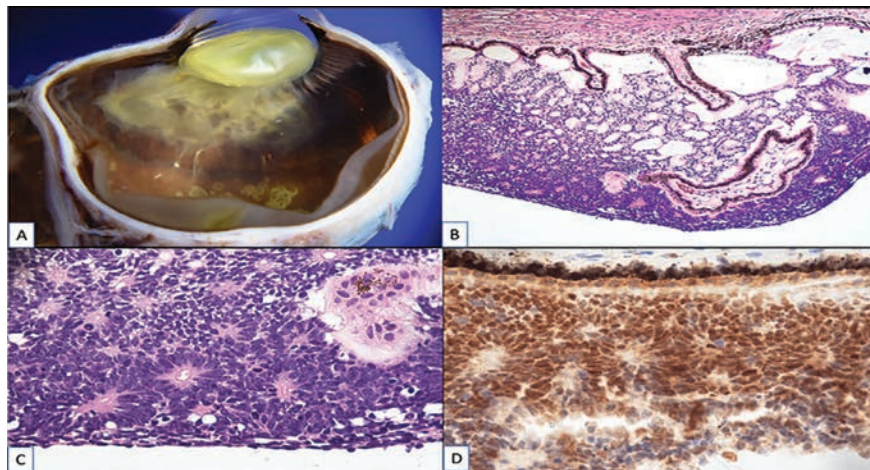


Figure 2. Pathology features: A) Gross dissection photograph showing a poorly circumscribed white to tan tumor covering the pars plicata and the anterior half of the pars plana of the ciliary body. B) Photomicrograph showing a basaloid tumor on the inner surface of the ciliary body. C) Photomicrograph showing mitotic figures and Flexner-Wintersteiner rosettes. D) Photomicrograph showing positive immunoreactivity for RB1 protein.

usual pseudo-uveitic nature of this patient's presentation may be one reason the diagnosis was delayed.

Tube shunt implantation in patients with unsuspected intraocular tumors, including medulloepithelioma, has been reported and, in some instances, the tube shunt has served as an avenue for extrascleral extension of tumor.⁶ In cases of medulloepithelioma in which a tube shunt has been implanted, the mass was difficult to visualize as it was hidden behind the iris,⁶ as was the case for the patient in this report. Anterior segment OCT and ultrasound biomicroscopy have been recommended as effective imaging modalities to identify ciliary body tumors that are hidden by the iris and not evident on clinical examination.¹ Plaque radiotherapy has been used to effectively treat localized small- to medium-sized cases of medulloepithelioma, with tumor control in 83 percent of patients and globe salvage in 67 percent of patients.¹⁰

In conclusion, ciliary body medulloepithelioma is a rare tumor of the nonpigmented ciliary epithelium that's frequently misdiagnosed on initial presentation. The classic tetrad of leukocoria, lens notch, neovascular glaucoma, and a cystic ciliary body mass may not always be present, and a high degree of suspicion is necessary in order to make the diagnosis. In cases of pediatric neovascular

glaucoma with a normal fundoscopic examination, consider medulloepithelioma in the differential diagnosis, and be sure to perform either anterior segment optical coherence tomography or ultrasound biomicroscopy to look for an occult ciliary body mass.¹ ◀

1. Tadeepalli SH, Shields CL, Shields JA, Honavar SG. Intraocular medulloepithelioma—A review of clinical features, DICER 1 mutation, and management. *Indian Journal of Ophthalmology* 2019;67:6:755-762.
2. Broughton WL, Zimmerman LE. A clinicopathologic study of 56 cases of intraocular medulloepitheliomas. *American Journal of Ophthalmology* 1978;85:3:407-418.
3. Kaliki S, Shields CL, Eagle RC, et al. Ciliary body medulloepithelioma. *Ophthalmology* 2013;120:12:2552-2559.
4. Peshtani A, Kaliki S, Eagle RC, Shields CL. Medulloepithelioma: A triad of clinical features. *Oman Journal of Ophthalmology* 2014;7:2:93.
5. Shields JA, Eagle RC, Shields CL, De Potter P. Congenital neoplasms of the nonpigmented ciliary epithelium (medulloepithelioma). *Ophthalmology* 1996;103:12:1998-2006.
6. Kaliki S, Eagle RC, Grossniklaus HE, Campbell RJ, Shields CL, Shields JA. Inadvertent implantation of aqueous tube shunts in glaucomatous eyes with unrecognized intraocular neoplasms: Report of 5 cases. *JAMA Ophthalmology* 2013;131:7:925-928.
7. Vempuluru VS, Jakati S, Krishnamurthy R, Senthil S, Kaliki S. Glaucoma as the presenting sign of intraocular tumors: Beware of the masquerading sign. *International Ophthalmology* 2020;40:7:1789-1795.
8. Chua J, Muen WJ, Reddy A, Brookes J. The masquerades of a childhood ciliary body medulloepithelioma: A case of chronic uveitis, cataract, and secondary glaucoma. *Case Reports in Ophthalmological Medicine* 2012;2012:493493-3.
9. Pushker N, Bajaj MS, Singh AK, Lokdarshi G, Bakshi S, Kashyap S. Intra-ocular medulloepithelioma as a masquerade for PHPV and panophthalmitis: A diagnostic dilemma. *Saudi Journal of Ophthalmology* 2017;31:2:109-111.
10. Ang SM, Dalvin LA, Emrich J, Komarnicky L, Shields JA, Shields CL. Plaque radiotherapy for medulloepithelioma in 6 cases from a single center. *Asia-Pacific Journal of Ophthalmology* 2019;8:1:30-35.

Cataract Extraction in Uveitic Glaucoma

(Continued from p. 54)

Before surgery, Dr. Kedhar insists on having every preop patient undergo an OCT scan. He also ensures that each patient experiences no macular edema for one month preoperatively, and is inflammation-free for at least three months before the cataract operation.

“I also try to get an endothelial cell count, if possible,” he says. “I want to look closely at the patient's cornea. Many of these patients will have chronic inflammation, endothelial dysfunction or endothelial cell loss. Besides helping to identify preoperative keratopathy, by taking these steps, I can more adequately prepare patients for the potential need for future surgery.”

Shared Success

More than most situations in eye

disease, the performance of cataract surgery in patients who have uveitic glaucoma calls for coordination among all of the subspecialties of ophthalmology and beyond.

“**More than most situations in eye disease, the performance of cataract surgery in patients who have uveitic glaucoma calls for coordination among all of the subspecialties of ophthalmology and beyond.**”

The surgeons who are doing the cataract surgery can take advantage of the expert advice, support and collaborative care efforts of glaucoma, retinal and uveitis sub-specialists, as well as rheumatologists and other medical specialists.

“The most important factor in taking the best care of these patients is communication among members of the team,” says Dr. Kedhar. “For example, if a patient has a rheumatologist on board providing treatment for uveitis, informing the rheumatologist that you're going to proceed with cataract surgery—and that it could cause a flare-up of inflammation—will allow you to come up with a strategy to manage the patient. The rheumatologist won't be caught unawares by the inflammation flaring up after the surgery. The same thing holds true for the uveitis specialist, who can provide insights into trying to manage the inflammation around the surgery. Working together lets us help these patients better than ever.” ◀

1. Mehta S, Linton M, Kempen JH. Outcomes of cataract surgery in patients with uveitis: A systematic review and meta-analysis. *Am J Ophthalmol* 2014;158:4:676-692.e7.



Not an actual patient.

*In some patients with continued daily use. One drop in each eye, twice daily (approximately 12 hours apart).³

†Xiidra is an LFA-1 antagonist for the treatment of dry eye disease. Pivotal trial data: The safety and efficacy of Xiidra were assessed in four 12-week, randomized, multicenter, double-masked, vehicle-controlled studies (N=2133). Patients were dosed twice daily. Use of artificial tears was not allowed during the studies. The study end points included assessment of signs (based on Inferior fluorescein Corneal Staining Score [ICSS] on a scale of 0 to 4) and symptoms (based on patient-reported Eye Dryness Score [EDS] on a visual analogue scale of 0 to 100).³ A larger reduction in EDS favoring Xiidra was observed in all studies at day 42 and day 84. Xiidra reduced symptoms of eye dryness at 2 weeks (based on EDS) compared to vehicle in 2 out of 4 clinical trials. Effects on signs of dry eye disease ICSS (on a scale from 0-4; 0=no staining; 4=coalescent) was recorded at each study visit. At day 84, a larger reduction in inferior corneal staining favoring Xiidra was observed in 3 of the 4 studies.³

Indication

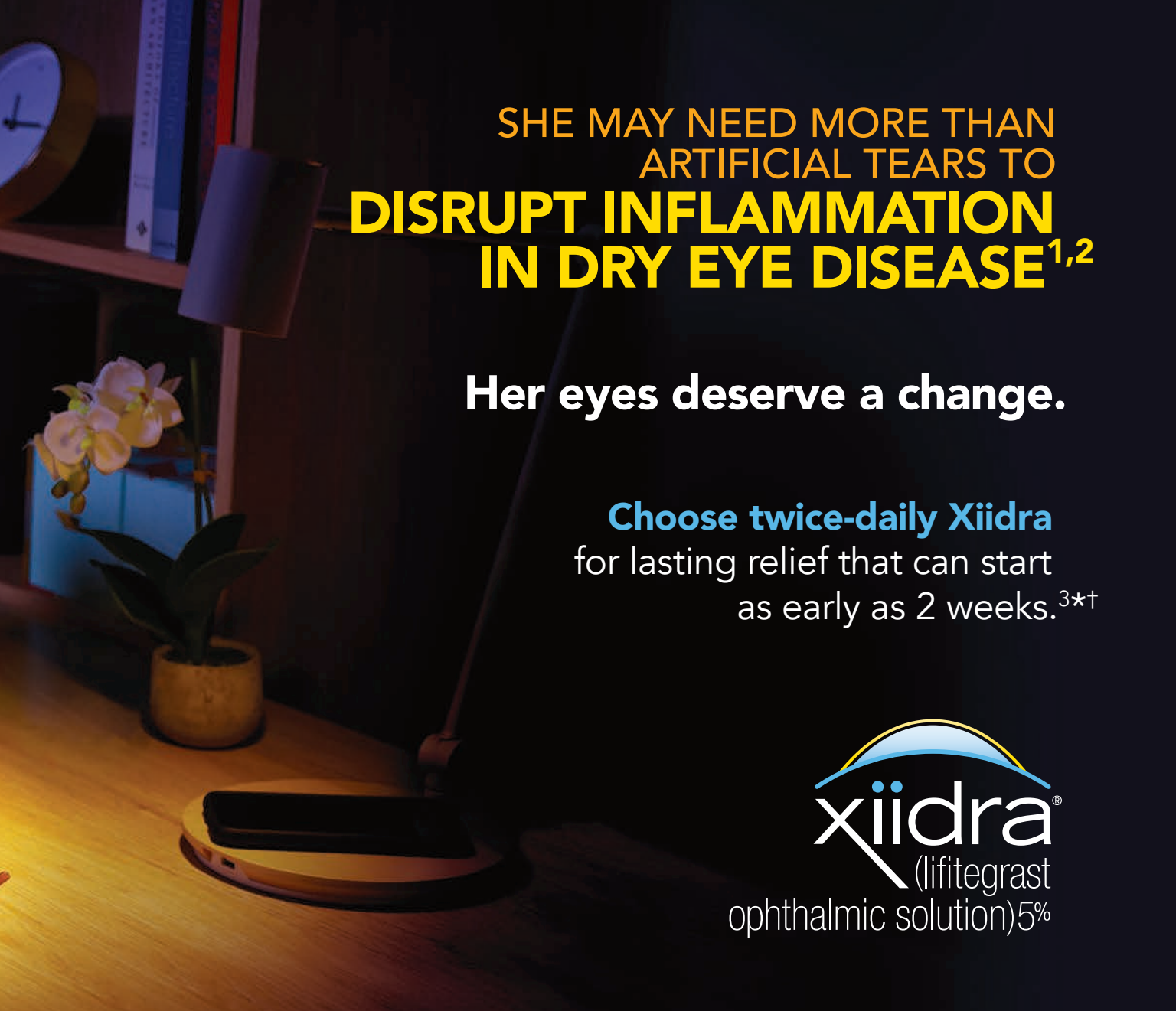
Xiidra® (lifitegrast ophthalmic solution) 5% is indicated for the treatment of signs and symptoms of dry eye disease (DED).

Important Safety Information

- Xiidra is contraindicated in patients with known hypersensitivity to lifitegrast or to any of the other ingredients.



Novartis Pharmaceuticals Corporation
East Hanover, New Jersey 07936-1080



SHE MAY NEED MORE THAN
ARTIFICIAL TEARS TO
**DISRUPT INFLAMMATION
IN DRY EYE DISEASE^{1,2}**

Her eyes deserve a change.

Choose twice-daily Xiidra
for lasting relief that can start
as early as 2 weeks.^{3*†}



xiidra[®]
(lifitegrast
ophthalmic solution)5%

Important Safety Information (cont)

- In clinical trials, the most common adverse reactions reported in 5-25% of patients were instillation site irritation, dysgeusia and reduced visual acuity. Other adverse reactions reported in 1% to 5% of the patients were blurred vision, conjunctival hyperemia, eye irritation, headache, increased lacrimation, eye discharge, eye discomfort, eye pruritus and sinusitis.
- To avoid the potential for eye injury or contamination of the solution, patients should not touch the tip of the single-use container to their eye or to any surface.
- Contact lenses should be removed prior to the administration of Xiidra and may be reinserted 15 minutes following administration.
- Safety and efficacy in pediatric patients below the age of 17 years have not been established.

For additional safety information about XIIDRA[®], please refer to the brief summary of Full Prescribing Information on adjacent page.

References: **1.** US Food and Drug Administration. Code of Federal Regulations, Title 21, Volume 5 (21CFR349). Accessed April 17, 2020. <https://www.accessdata.fda.gov/scripts/cdrh/cfdocs/cfcfr/CFRSearch.cfm?CFRPart=349&showFR=1> **2.** Jones L, Downie LE, Korb D, et al. TFOS DEWS II Management and Therapy Report. *Ocul Surf.* 2017;15(3):575-628. **3.** Xiidra [package insert]. East Hanover, NJ: Novartis Pharmaceuticals Corp; June 2020.

XIIDRA, the XIIDRA logo and ii are registered trademarks of Novartis AG.

XIIDRA® (lifitegrast ophthalmic solution), for topical ophthalmic use
Initial U.S. Approval: 2016

BRIEF SUMMARY: Please see package insert for full prescribing information.

1 INDICATIONS AND USAGE

Xiidra® (lifitegrast ophthalmic solution) 5% is indicated for the treatment of the signs and symptoms of dry eye disease (DED).

4 CONTRAINDICATIONS

Xiidra is contraindicated in patients with known hypersensitivity to lifitegrast or to any of the other ingredients in the formulation [see *Adverse Reactions* (6.2)].

6 ADVERSE REACTIONS

The following serious adverse reactions are described elsewhere in the labeling:

- Hypersensitivity [see *Contraindications* (4)]

6.1 Clinical Trials Experience

Because clinical trials are conducted under widely varying conditions, adverse reaction rates observed in clinical trials of a drug cannot be directly compared to rates in the clinical trials of another drug and may not reflect the rates observed in practice.

In five clinical trials of DED conducted with lifitegrast ophthalmic solution, 1401 patients received at least one dose of lifitegrast (1287 of which received lifitegrast 5%). The majority of patients (84%) had less than or equal to 3 months of treatment exposure. One hundred-seventy patients were exposed to lifitegrast for approximately 12 months. The majority of the treated patients were female (77%). The most common adverse reactions reported in 5%-25% of patients were instillation-site irritation, dysgeusia, and reduced visual acuity.

Other adverse reactions reported in 1%-5% of the patients were blurred vision, conjunctival hyperemia, eye irritation, headache, increased lacrimation, eye discharge, eye discomfort, eye pruritus, and sinusitis.

6.2 Postmarketing Experience

The following adverse reactions have been identified during post-approval use of Xiidra. Because these reactions are reported voluntarily from a population of uncertain size, it is not always possible to reliably estimate their frequency or establish a causal relationship to drug exposure.

Rare serious cases of hypersensitivity, including anaphylactic reaction, bronchospasm, respiratory distress, pharyngeal edema, swollen tongue, urticaria, allergic conjunctivitis, dyspnea, angioedema, and allergic dermatitis have been reported. Eye swelling and rash have also been reported [see *Contraindications* (4)].

8 USE IN SPECIFIC POPULATIONS

8.1 Pregnancy

Risk Summary

There are no available data on Xiidra use in pregnant women to inform any drug-associated risks. Intravenous (IV) administration of lifitegrast to

pregnant rats, from pre-mating through gestation day 17, did not produce teratogenicity at clinically relevant systemic exposures. Intravenous administration of lifitegrast to pregnant rabbits during organogenesis produced an increased incidence of omphalocele at the lowest dose tested, 3 mg/kg/day (400-fold the human plasma exposure at the recommended human ophthalmic dose [RHOD], based on the area under the curve [AUC] level). Since human systemic exposure to lifitegrast following ocular administration of Xiidra at the RHOD is low, the applicability of animal findings to the risk of Xiidra use in humans during pregnancy is unclear [see *Clinical Pharmacology* (12.3) in the full prescribing information].

Data

Animal Data

Lifitegrast administered daily by IV injection to rats, from pre-mating through gestation day 17, caused an increase in mean pre-implantation loss and an increased incidence of several minor skeletal anomalies at 30 mg/kg/day, representing 5,400-fold the human plasma exposure at the RHOD of Xiidra, based on AUC. No teratogenicity was observed in the rat at 10 mg/kg/day (460-fold the human plasma exposure at the RHOD, based on AUC). In the rabbit, an increased incidence of omphalocele was observed at the lowest dose tested, 3 mg/kg/day (400-fold the human plasma exposure at the RHOD, based on AUC), when administered by IV injection daily from gestation days 7 through 19. A fetal no observed adverse effect level (NOAEL) was not identified in the rabbit.

8.2 Lactation

Risk Summary

There are no data on the presence of lifitegrast in human milk, the effects on the breastfed infant, or the effects on milk production. However, systemic exposure to lifitegrast from ocular administration is low [see *Clinical Pharmacology* (12.3) in the full prescribing information]. The developmental and health benefits of breastfeeding should be considered, along with the mother's clinical need for Xiidra and any potential adverse effects on the breastfed child from Xiidra.

8.4 Pediatric Use

Safety and efficacy in pediatric patients below the age of 17 years have not been established.

8.5 Geriatric Use

No overall differences in safety or effectiveness have been observed between elderly and younger adult patients.

Distributed by:
Novartis Pharmaceuticals Corporation
One Health Plaza
East Hanover, NJ 07936
T2020-87