

Wills Eye Resident Series: A boy with a conjunctival lesion and skin abnormalities, p .71

# REVIEW<sup>®</sup> of OPHTHALMOLOGY

February 2021 • reviewofophthalmology.com

Clinical advice you can trust

## REFRACTIVE/CATARACT

Are You Lawsuit-proof?

PAGE 17

## MEDICARE Q & A

The Big Coding Changes for 2021

PAGE 24

## GLAUCOMA MANAGEMENT

Cataract Surgery and Narrow Angles

PAGE 60

## HOW TO CHOOSE THE RIGHT MIOG



**DEXYCU<sup>®</sup>**  
(dexamethasone intraocular  
suspension) 9%


*Commitment you can count on  
and a vision that looks ahead*

Clinical innovation and comprehensive  
reimbursement support



DEXYCU, the DEXYCU logo, and the EyePoint logo are registered trademarks of EyePoint Pharmaceuticals, Inc.  
©2021 EyePoint Pharmaceuticals, Inc. All rights reserved.  
480 Pleasant Street, Suite B300, Watertown, MA 02472

01/2021  
US-DEX-2100030



Focus on innovation with

**DEXYCU<sup>®</sup>**

(dexamethasone intraocular  
suspension) 9%

Learn more at [DEXYCU.com](https://www.dexycu.com)

Wills Eye Resident Series: A boy with a conjunctival lesion and skin abnormalities, p .71

# REVIEW<sup>®</sup> *of* OPHTHALMOLOGY

February 2021 • [reviewofophthalmology.com](http://reviewofophthalmology.com)

Clinical advice you can trust

## REFRACTIVE/CATARACT

Are You Lawsuit-proof?

PAGE 17

## MEDICARE Q & A

The Big Coding Changes for 2021

PAGE 24

## GLAUCOMA MANAGEMENT

Cataract Surgery and Narrow Angles

PAGE 60

## HOW TO CHOOSE THE RIGHT MIGS


*Experts share their insights on matching a particular surgery with a patient's needs. P. 28*

- Reconciling Glaucoma Care During a Pandemic P. 38
- Dry Eye: The Blepharitis Connection P. 46
- Expert Advice on Corneal Ulcers P. 52



# INTRODUCING

iStent  
inject® W



## EVOLVING DESIGN. ADVANCING PREDICTABILITY.

Featuring a wide flange at its base, the new precision engineered iStent inject® W is designed to:

- Safely and effectively control your patient's glaucoma<sup>1</sup>
- Optimize stent visualization while maintaining a truly micro-scale footprint
- Streamline implantation
- Deliver procedural predictability

Don't miss the opportunity to make a once-in-a-lifetime difference for your cataract patients with mild-to-moderate glaucoma.

[TransformMIGS.com](https://www.TransformMIGS.com) | 800.GLAUKOS (452.8567)

#### REFERENCE:

1. Samuelson TW, Sarkisian SR, Lubeck DM, et al. Prospective, randomized, controlled pivotal trial of an ab interno implanted trabecular micro-bypass in primary open-angle glaucoma and cataract. *Ophthalmology*. Jun 2019;126(6):811-821.

**INDICATION FOR USE.** The iStent inject® W Trabecular Micro-Bypass System Model G2-W is indicated for use in conjunction with cataract surgery for the reduction of intraocular pressure (IOP) in adult patients with mild to moderate primary open-angle glaucoma. **CONTRAINDICATIONS.** The iStent inject W is contraindicated in eyes with angle-closure glaucoma, traumatic, malignant, uveitic, or neovascular glaucoma, discernible congenital anomalies of the anterior chamber (AC) angle, retrolubar tumor, thyroid eye disease, or Sturge-Weber Syndrome or any other type of condition that may cause elevated episcleral venous pressure. **WARNINGS.** Gonioscopy should be performed prior to surgery to exclude congenital anomalies of the angle, PAS, rubeosis, or conditions that would prohibit adequate visualization of the angle that could lead to improper placement of the stent and pose a hazard. **MRI INFORMATION.** The iStent inject W is MR-Conditional, i.e., the device is safe for use in a specified MR environment under specified conditions; please see Directions for Use (DFU) label for details. **PRECAUTIONS.** The surgeon should monitor the patient postoperatively for proper maintenance of IOP. The safety and effectiveness of the iStent inject W have not been established as an alternative to the primary treatment of glaucoma with medications, in children, in eyes with significant prior trauma, abnormal anterior segment, chronic inflammation, prior glaucoma surgery (except SLT performed > 90 days preoperative), glaucoma associated with vascular disorders, pseudoxfoliative, pigmentary or other secondary open-angle glaucomas, pseudophakic eyes, phakic eyes without concomitant cataract surgery or with complicated cataract surgery, eyes with medicated IOP > 24 mmHg or unmedicated IOP < 21 mmHg or > 36 mmHg, or for implantation of more or less than two stents. **ADVERSE EVENTS.** Common postoperative adverse events reported in the iStent inject® randomized pivotal trial included stent obstruction (6.2%), intraocular inflammation (5.7% for iStent inject vs. 4.2% for cataract surgery only), secondary surgical intervention (5.4% vs. 5.0%) and BCVA loss  $\geq$  2 lines  $\geq$  3 months (2.6% vs. 4.2%). **CAUTION:** Federal law restricts this device to sale by, or on the order of, a physician. Please see DFU for a complete list of contraindications, warnings, precautions, and adverse events.

©2020 Glaukos Corporation. Glaukos and iStent inject are registered trademarks of Glaukos Corporation. PM-US-0202

GLAUKOS®

## Alcon Vivity EDOF Lens Starts Its Rollout in the United States

**A**lcon recently received U.S. Food and Drug Administration approval for its Vivity extended-depth-of-focus intraocular lens. The company says the device uses proprietary “X-wave technology” to bend light, enabling a wider range of vision than a monocular IOL.

While traditional diffractive presbyopia-correcting lenses split light into multiple zones of vision or into microsteps to produce an elongated zone, the non-diffractive Vivity changes the shape of the wavefront as it passes through the lens. “This wavefront-shaping optical principle creates a stretching of light which produces a sort of extended-depth-of-focus channel as it hits the retina,” says Brandon Baartman, MD, of Vance Thompson Vision in Omaha, Nebraska. He took part in the U.S. clinical trial as

**Table 1. Vivity FDA Trial, Binocular Snellen Acuity at Six Months<sup>1</sup>**

	Vivity (%)	Monofocal (%)
Uncorrected distance (20/20 or better)	61	77
Uncorrected intermediate (20/20 or better)	56	27
Uncorrected Near (20/32 or better)	67	29

a surgical fellow.

“Essentially,” he explains, “you’re taking a single point of focus and elongating it into a line by bending light using anterior surface transition elements so that not all the light enters in the same way, as it would for a monofocal, or splitting light as it would for a diffractive optic.”

The U.S. clinical trial included 220 patients who received either the SN60WF monofocal (n=113) or Vivity IOL (n=107).<sup>1</sup> Vivity demon-

strated a greater negative range of binocular defocus compared to the monofocal at six months in the U.S. and outside the country (n=282) clinical trials.<sup>2</sup> No persistent adverse events occurred within the study period in those implanted with Vivity.<sup>1</sup>

Alcon says this lens delivers “monofocal-quality distance vision with excellent intermediate and functional near vision.” Dr. Baartman says that, in the trial, the lens

*(Continued on p. 10)*

### VIVITY SPECS

Here is a summary of some of the specifications for the Acrysof IQ Vivity extended vision IOL:

**Models:** Extended Vision (DFT015) and Toric EV (DFT315, DFT415, DFT515)

**Optic:** biconvex, aspheric, wavefront-shaping

**Lens material:** hydrophobic acrylate/methacrylate copolymer with UV and blue light filtration

**Index of refraction:** 1.55

**Haptic Configuration:** StableForce modified-L haptics

**Optic diameter:** 6 mm

**Overall length:** 13 mm

**Spherical powers:** +15 D to +25 D, in 0.5 D increments

**Table 2. Cylinder Power of Vivity’s Three Toric IOLs<sup>1</sup>**

IOL Model	At IOL Plane (D)	At Corneal Plane (D)
DFT315	1.50	1.03
DFT415	2.25	1.55
DFT515	3.00	2.06

## Pearls on License Deal Structures: Field of Use

BY MATTHEW CHAPIN  
ANDOVER, MASS.

You may be a physician-entrepreneur with a novel concept for development, requiring you to acquire a license to use a technology from another company that enables you to produce your own product. Or you may be the owner of the intellectual property and there is a partner seeking to license the technology from you. In this installment of our column, we'll take the opportunity to review a few considerations related to the terms of early licensing deals that have come across our desks recently.

We feel these are worthy of review as example case studies for the early-stage entrepreneur/scientist.

This is certainly not an exhaustive review of license deal terms, but there are some key lessons which frequently arise specifically around field of use and patent costs.

The "field of use" is a defined scope, restriction or purpose placed around the use of a license. One of the key attractive elements of development in ophthalmology from a drug perspective is the use, generally speaking, of local therapy. That includes such things as eyedrops, injections, implants and sustained-release drugs that are placed directly in, on or around the eye for local delivery, in contrast to systemic delivery routes such as oral or subcutaneous injections, which can be used for multiple diseases. This gives rise to specific intellectual property around the ophthalmic product and unique considerations regarding formulation and delivery.

Thus, for many products with local ocular administration, a license deal is often specific to the niche of treating ocular disease only.

In the case of an entity looking to license and focus development on specific rights for the eye, the licensor (the one providing the technology) retains rights for areas outside the eye. The licensor may hold back these rights because it's actively developing the drug in other areas; or there may be no actual active development, but it wishes to retain those rights to recognize



future value. This will impact how the licensor values the retained rights outside the eye, and if it's willing to license the broad rights or just the ophthalmic rights. If you're on the side licensing the technology for your use (licensee), you need to balance the "ideal" scenario of having full rights—if the added price is worth the broad rights—or if you're set up to move forward outside the eye to satisfy development requirements that the licensor may place on you. Recognize that, often, the "ideal" scenario desired by the pharma company you hope to license your product to in the future is to fully control the asset.

This is true for a couple of reasons:

First, they don't want to see a separate pharma company developing the drug for other purposes in other dosage forms that may generate important safety data impacting the ophthalmic product; and, second, they want to control the off-label use of non-ocular products at other companies.

On the other hand, if you're the licensor, and your potential partner is looking for broad rights, it's important to assess the potential value outside the eye and seek a commitment that the licensee will at least use "commercially reasonable efforts" to recognize value outside the lead ocular field.

This can be done with terms that require the licensee to reach certain milestones at specific timepoints; otherwise rights will revert to you, or you'll receive a minimum payment from them as compensation.

Often, especially with platform-delivery technologies, the field of use may be defined around a specific location (e.g., retina vs anterior segment), delivery method (e.g., topical vs. injection), disease, drug or drug class. There are many ways to combine these to define a specific field of use. If you're the licensee, the key is balancing how much you may need to pay up front in order to have a sufficient circle of protection around your lead product, and to be in synch with what you'll commit to for the licensor if they ask for certain commitments for specific development milestones.

From the licensor perspective, the product has unrealized value

# COMPREHENSIVE SERVICE SOLUTIONS



## Repairs & Maintenance

Equipment repairs, lane tune-ups, cleaning, re-upholstery, and more



## Protection Plans

Extended coverage for an individual instrument



## Umbrella Policies

Comprehensive coverage for your entire practice

## GET PEACE OF MIND

with full protection, prompt service, and ongoing support

### CONVENIENT

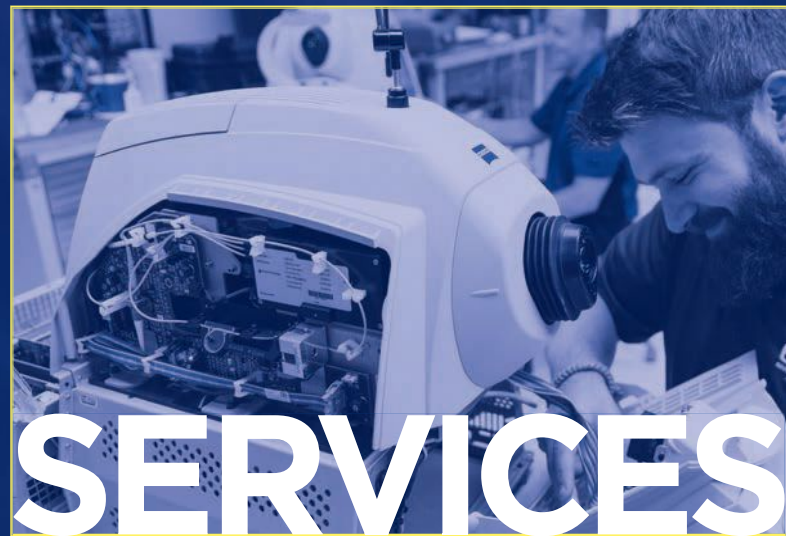Just one phone number to call for all of your repair and maintenance needs

### EXPERIENCED

Manufacturer-trained technicians who are highly experienced in diagnostic and lane equipment repairs

### AFFORDABLE

Major savings over individual service repairs from manufacturers



## WE COVER MORE SO YOU WORRY LESS

Canon • Haag-Streit • Reliance • Heidelberg • Keeler • Lombart • Marco  
Reichert • S4Optik • Topcon • Zeiss • And more!

Contact your local representative or call us directly for fast, reliable support.

# 855-777-2020

One Alliance • Six Industry Leaders • Hundreds of Years Experience

LOMBART



EMS



INNOVA

S4OPTIK

that they don't want locked up if it doesn't move forward. You also want to account for situations in which you switch tracks, develop an add-on indication or have investors that desire a certain field of use. All of this needs to be considered when defining the field of use early in the program, especially if it's relatively narrow and focused on a specific formulation or indication for the eye. In many cases, a company may initially intend to develop a product for a specific ocular location, such as the retina, but then, during the fundraising stage, realize there may be added value if a shorter anterior segment program precedes the retina work. Thus, you don't want to limit yourself with a very specific field of use.

The discussion of field of use ties in closely with coverage of patent expenses. There are multiple ways to cover filing fees, prosecution costs, maintenance fees and international registrations. Sometimes these costs are covered by the licensor, other times by the licensee. If a compound is being licensed for a specific field in ophthalmology, the licensor may request that all patent expenses be reimbursed, even though the licensee doesn't have rights outside the eye. Naturally, for the licensee the ideal scenario is to limit the patent costs around its field but, for the licensor, the ideal situation (especially if it doesn't have other funded partners at the time) is to get as much of the total patents costs covered as possible. As a licensee, if the licensor requests payment of expenses across the broad patent portfolio, you may be able to get partners to help cover these costs so you don't carry the full burden yourself. You might come across specific deal structure templates, particularly in the university setting, that have limited flexibility in some areas. This is

an area to think about early in the process so there are no surprises later in the deal discussion based on assumptions of how costs were going to be paid.

If you are the licensee, though, also consider how you're enabling the licensor's technology. Is your work the lead indication for the technology, and will the licensor be able to then show it as proof-of-concept and benefit from it in other areas? In this case, see if you can also benefit from the additional income they receive that was made possible by your work, or how you can split the patent costs. The cross-licensing of new intellectual property, often times called "improvements" in contracts, is another complex topic and takes multiple forms.

“ There are multiple ways to cover filing fees, prosecution costs, maintenance fees and international registrations. ”

The key, however, is to think through not only what happens to the IP being licensed and how costs are covered, but also what happens to the newly formed IP—whether it's generated by you, your partner, jointly or from third-party partners—and how each entity benefits and is able to leverage it in its respective fields or territories. At the end of the day, the licensor benefits from seeing the technology rolled out in a value-maximizing manner across indications and territories, and in the case in which there are different licensees in different countries, each licensor may benefit from the other, from such things as improvements in a drug's formulation.

As a final note, remember to ensure that the patents being licensed


cover the ultimate product, and decide which parts of the licensable intellectual property you need. This may seem obvious, but in some disciplines, especially ophthalmology, in addition to the compound itself there's often formulation IP, delivery IP, manufacturing process IP and method-of-use IP; and formulations may be optimized or modified through the development process. Because of this, make sure your business plan includes the possession of solid IP that covers where you're headed with the product and what you're willing to pay for it.

Whether you're the inventor, and fortunate to have the opportunity to license out your technology for development, or you're a licensee who will license-in a technology to develop yourself, we hope some of the above discussion is useful, sparks discussion and informs your thought process as you refine the details of your deal structure. While some of these suggestions are common sense, as the momentum of a deal accelerates, it's easy to lose sight of the key aspects of field of use and how it impacts your program, your partners and your overall deal terms. ◀

*Mr. Chapin is a senior vice president of corporate development and the asset development & partnering group at Ora, which offers drug, biologic and device consulting; clinical research assistance and development strategy; and support in an effort to promote new client and partner initiatives. Review and comments on this column were provided by Aron Shapiro, also a senior vice president in the corporate development group at Ora Inc. The author welcomes your comments or questions regarding product development.*

*Please send correspondence to [mchapin@oraclinical.com](mailto:mchapin@oraclinical.com) or visit [oraclinical.com](http://oraclinical.com).*



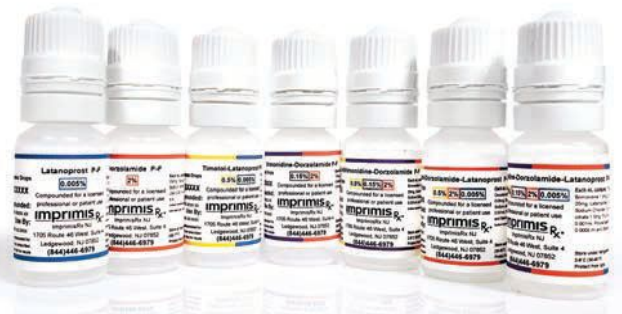

**Keep it Simple  
Keep it Preservative-Free**

## Simple Drops Preservative-Free Compounded Formulations\*

Preservative-Free Formulation*		Fill Size	Average <u>1 Month</u> Cost†	Bottle Price
LAT	Latanoprost 0.005%	7.5mL	\$25.30	\$75.90
DOR	Dorzolamide 2%	10mL	\$33.00	\$66.00
TIM-LAT®	Timolol 0.5%/Latanoprost 0.005%	5mL	\$53.90	\$107.80
BRIM-DOR®	Brimonidine 0.15%/Dorzolamide 2%	10mL	\$53.90	\$107.80
TIM-DOR-LAT®	Timolol 0.5%/Dorzolamide 2%/Latanoprost 0.005%	5mL	\$64.90	\$129.80
TIM-BRIM-DOR®	Timolol 0.5%/Brimonidine 0.15%/Dorzolamide 2%	5mL (2 bottles per shipment)	\$64.90	\$129.80 per 2 bottles
TIM-BRIM-DOR-LAT®	Timolol 0.5%/Brimonidine 0.15%/Dorzolamide 2%/Latanoprost 0.005%	5mL	\$75.90	\$151.80

Visit: [www.SimpleDrops.com](http://www.SimpleDrops.com)



Important: Patients may need to take more than one eye drop product pursuant to multiple dosing regimens, as directed by his or her prescriber, in order for the active ingredients to remain effective throughout the day.  
† 1 Month supply can vary based on the dosing regimen prescribed by the doctor

\*For professional use only. ImprimisRx specializes in customizing medications to meet unique patient and practitioner needs. ImprimisRx dispenses only to individually identified patients with valid prescriptions. No compounded medication is reviewed by the FDA for safety or efficacy. ImprimisRx does not compound essentially copies of commercially available drug products. References available upon request.

ImprimisRx, Simple Drops, Brim-Dor, Tim-Lat, Tim-Brim-Dor, Tim-Dor-Lat, Tim-Brim-Dor-Lat are registered trademarks of Harrow Health, Inc. ©2020 ImprimisRx. All rights reserved. IMPO0393 Rev3 8/20



## CONTRIBUTORS

**CHIEF MEDICAL EDITOR**  
Mark H. Blecher, MD

**CONTACT LENSES**  
Penny Asbell, MD

**CORNEA / ANTERIOR SEGMENT**  
Thomas John, MD

**GLAUCOMA MANAGEMENT**  
Peter Netland, MD, PHD  
Kuldev Singh, MD

**MASTERS OF SURGERY**  
Taliva D. Martin, MD  
Sara J. Haug, MD, PhD

**MEDICARE Q & A**  
Paul M. Larson, MBA

**PEDIATRIC PATIENT**  
Janine Collinge, MD

**PLASTIC POINTERS**  
Anna P. Murchison, MD, MPH

**REFRACTIVE SURGERY**  
Arturo S. Chayet, MD

**RETINAL INSIDER**  
Carl Regillo, MD, FACS  
Yoshihiro Yonekawa, MD

**TECHNOLOGY UPDATE**  
Steven T. Charles, MD  
Michael Colvard, MD

**WILLS RESIDENT CASE SERIES**  
Meera D. Sivalingam, MD

## ADVISORY BOARD

**PENNY A. ASBELL, MD**, MEMPHIS, TENN.

**BRANDON AYRES, MD**, PHILADELPHIA

**SURENDRA BASTI, MD**, CHICAGO

**WILLIAM I. BOND, MD**, PEKIN, ILL.

**ALAN N. CARLSON, MD**, DURHAM, N.C.

**Y. RALPH CHU, MD**, EDINA, MINN.

**ADAM J. COHEN, MD**, CHICAGO

**JANINE COLLINGE, MD**, FARMINGTON, CONN.

**UDAY DEVGAN, MD, FACS**, LOS ANGELES

**ERIC DONNENFELD, MD**, ROCKVILLE CENTRE, N.Y.

**DANIEL S. DURRIE, MD**, KANSAS CITY, MO.

**ROBERT EPSTEIN, MD**, MCHENRY, ILL.

**ROBERT D. FECHTNER, MD**, NEWARK, N.J.

**WILLIAM J. FISHKIND, MD**, TUCSON, ARIZ.

**BRIAN FRANCIS, MD**, Los Angeles

**JAMES P. GILLS, MD**, TARPON SPRINGS, FLA.

**HARRY GRABOW, MD**, SARASOTA, FLA.

**DOUGLAS K. GRAYSON, MD**, NEW YORK CITY

**DAVID R. HARDTEN, MD**, MINNEAPOLIS

**SARA J. HAUG, MD, PHD**, DURANGO, COLO.

**KENNETH J. HOFFER, MD**, SANTA MONICA, CALIF.

**JACK T. HOLLADAY, MD, MSEE**, HOUSTON

**JOHN D. HUNKELER, MD**, KANSAS CITY, MO.

**THOMAS JOHN, MD**, TINLEY PARK, ILL.

**ROBERT M. KERSHNER, MD, MS**, PALM BEACH GARDENS, FLA.

**GUY M. KEZIRIAN, MD**, PARADISE VALLEY, ARIZ.

**TERRY KIM, MD**, DURHAM, N.C.

**BRAD KLIGMAN, MD**, GARDEN CITY, N.Y.

**TOMMY KORN, MD**, SAN DIEGO

**DAVID A. LEE, MD**, HOUSTON

**FRANCIS S. MAH, MD**, LA JOLLA, CALIF.

**NICK MAMALIS, MD**, SALT LAKE CITY

**EDWARD MANCHE, MD**, PALO ALTO, CALIF.

**MIKE S. MCFARLAND, MD**, PINE BLUFF, ARK.

**JEFFREY B. MORRIS, MD, MPH**, ENCINITAS, CALIF.

**KEVIN MILLER, MD**, LOS ANGELES

**MARLENE R. MOSTER, MD**, PHILADELPHIA

**ANNA P. MURCHISON, MD, MPH**, PHILADELPHIA

**ROBERT J. NOECKER, MD**, FAIRFIELD, CONN.

**ROBERT OSHER, MD**, CINCINNATI

**MARK PACKER, MD**, WEST PALM BEACH, FLA.

**CHRISTOPHER J. RAPUANO, MD**, PHILADELPHIA

**AUGUST READER III, MD**, SAN FRANCISCO

**TONY REALINI, MD**, MORGANTOWN, W.V.

**KENNETH J. ROSENTHAL, MD**, GREAT NECK, N.Y.

**ERIC ROTHCHILD, MD**, DELRAY BEACH, FLA.

**SHERI ROWEN, MD**, BALTIMORE

**JAMES J. SALZ, MD**, LOS ANGELES

**INGRID U. SCOTT, MD, MPH**, HERSHEY, PA.

**JOEL SCHUMAN, MD**, PITTSBURGH

**GAURAV SHAH, MD**, ST. LOUIS

**DAVID R. STAGER JR., MD**, DALLAS

**KARL STONECIPHER, MD**, GREENSBORO, N.C.

**JAMES C. TSAI, MD**, NEW YORK CITY

**VANCE THOMPSON, MD**, SIOUX FALLS, S.D.

**FARRELL C. TYSON, MD**, CAPE CORAL, FLA.

**R. BRUCE WALLACE III, MD**, ALEXANDRIA, LA.



### BUSINESS OFFICES

19 CAMPUS BOULEVARD, SUITE 101  
NEWTOWN SQUARE, PA 19073  
SUBSCRIPTION INQUIRIES (877) 529-1746  
(USA ONLY); OUTSIDE USA, CALL (847) 763-9630

### BUSINESS STAFF

**PUBLISHER**  
**MICHAEL HOSTER**  
(610) 492-1028 MHOSTER@JOBSON.COM

**EXECUTIVE DIRECTOR**  
**JAMES HENNE**  
(610) 492-1017 JHENNE@JOBSON.COM

**REGIONAL SALES MANAGER**  
**MICHELE BARRETT**  
(610) 492-1014 MBARRETT@JOBSON.COM

**REGIONAL SALES MANAGER**  
**JONATHAN DARDINE**  
(610) 492-1030 JDARDINE@JOBSON.COM

**CLASSIFIED ADVERTISING**  
(888)-498-1460

**PRODUCTION MANAGER**  
**FARRAH APONTE**  
212-274-7057 FAPONTE@JOBSON.COM

**PRODUCTION MANAGER**  
**KAREN LALLONE**  
(610) 492-1010 KLALLONE@JOBSON.COM

**SUBSCRIPTIONS**  
\$63 A YEAR, \$99 (U.S.) IN CANADA,  
\$158 (U.S.) IN ALL OTHER COUNTRIES.  
SUBSCRIPTIONS E-MAIL:  
**REVOPHTHALMOLOGY@CAMBEYWEST.COM**

### CIRCULATION

PO BOX 71, CONGERS, NY 10920-0071  
(877) 529-1746  
OUTSIDE USA: (845) 267-3065

**SENIOR CIRCULATION MANAGER**  
**HAMILTON MAHER**  
(212) 219-7870 hmaher@jhihealth.com

**CEO, INFORMATION GROUP SERVICES**  
**MARC FERRARA**

**SENIOR VICE PRESIDENT, OPERATIONS**  
**JEFF LEVITZ**

**VICE PRESIDENT, HUMAN RESOURCES**  
**TAMMY GARCIA**

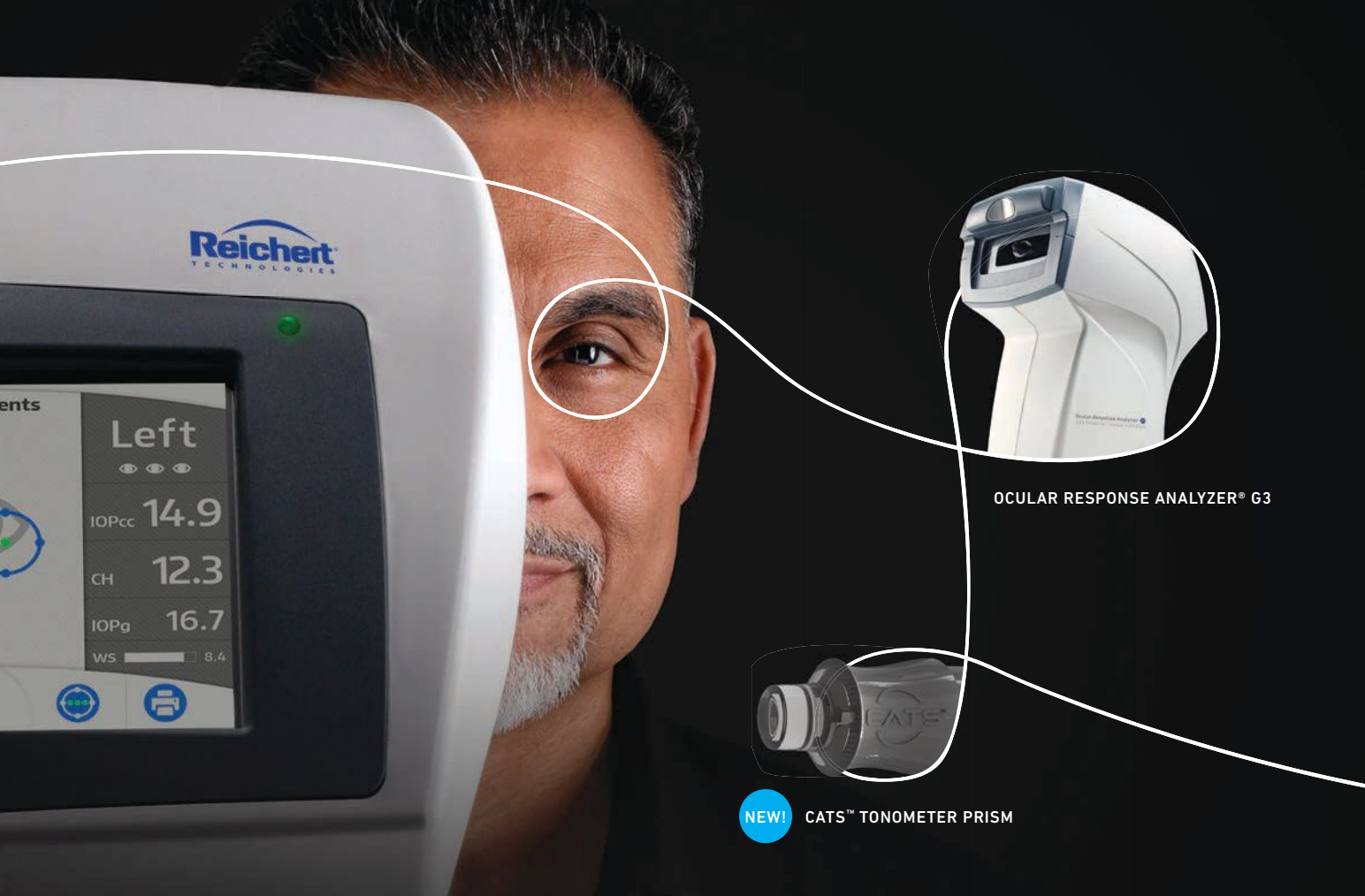**VICE PRESIDENT, CREATIVE SERVICES & PRODUCTION**  
**MONICA TETTAMANZI**

**CORPORATE PRODUCTION DIRECTOR**  
**JOHN ANTHONY CAGGIANO**

**VICE PRESIDENT, CIRCULATION**  
**JARED SONNERS**

395 Hudson Street, 3rd Floor,  
New York, NY 10014

**REVIEW OF OPHTHALMOLOGY** (ISSN 1081-0226; USPS No. 0012-345) is published monthly, 12 times per year by Jobson Medical Information, 395 Hudson Street, 3rd Floor, New York, NY 10014. Periodicals postage paid at New York, NY and additional mailing offices. Postmaster: Send address changes to Review of Ophthalmology, PO Box 71, Congers, NY 10929-0071. Subscription Prices: US One Year \$63.00, US Two Year \$112.00, Canada One Year \$99.00, Canada Two Year \$181.00, Int'l One Year \$158.00, Int'l Two Year \$274.00. For subscription information call (877) 529-1746 (USA only); outside USA, call (845)-267-3065. Or email us at revophthalmology@cambeywest.com. Canada Post: Publications Mail Agreement #40612608. Canada Returns to be sent to Bleuchip International, P.O. Box 25542, London, ON N6C 6B2.



OCULAR RESPONSE ANALYZER® G3

NEW! CATS™ TONOMETER PRISM

# FROM BETTER TO BEYOND.

Only **Ocular Response Analyzer® G3** provides a *better* pressure measurement with **Corneal Compensated IOP (IOPcc)** and measures *beyond* pressure with **Corneal Hysteresis (CH)** using patented technology to assess corneal biomechanical properties. Using biomechanics, IOPcc is less influenced by corneal properties than Goldmann applanation tonometry.<sup>4</sup> Corneal Hysteresis has shown to be an independent risk factor and more predictive of glaucoma development and progression than CCT or IOP.<sup>1-3</sup>

**CATS™ Tonometer Prism\*** is the new shape of IOP. The patented, CATS Tonometer Prism's dual-curved design significantly improves Goldmann IOP measurement accuracy, compared to a traditional Goldmann prism, by compensating for corneal biomechanics, based on peer-reviewed studies.<sup>5</sup> Your Goldmann, *better* pressure.

▶ WATCH THE VIDEOS: [PASSIONATEABOUTEYECARE.COM/GLAUCOMA](http://PASSIONATEABOUTEYECARE.COM/GLAUCOMA)



*Passionate About Eye Care!*



**AMETEK®** © 2020 AMETEK, Inc. & Reichert, Inc. (04-2020) - Ocular Response Analyzer is a registered trademark of Reichert, Inc. - Designed & assembled in USA - **References:** 1. Medeiros FA, Meira-Freitas D, Lisboa R, Kuang TM, Zangwill LM, Weinreb RN. Corneal hysteresis as a risk factor for glaucoma progression: a prospective longitudinal study. *Ophthalmology*. 2013 Aug;120(8):1533-40. 2. De Moraes CV, Hill V, Tello C, Liebmann JM, Ritch R. Lower corneal hysteresis is associated with more rapid glaucomatous visual field progression. *J Glaucoma*. 2012 Apr-May;21(4):209-13. 3. Susanna CN, Diniz-Filho A, Daga FB, Susanna BN, Zhu F, Ogata NG, Medeiros FA. Am J Ophthalmol. A Prospective Longitudinal Study to Investigate Corneal Hysteresis as a Risk Factor for Predicting Development of Glaucoma. 2018 Mar;187:148-152. doi: 10.1016/j.ajpo.2017.12.018. 4. Felipe A, Medeiros, MD and Robert N. Weinreb, MD. Evaluation of the Influence of Corneal Biomechanical Properties on Intraocular Pressure Measurements Using the Ocular Response Analyzer. *J Glaucoma* 2006;15:366-370. 5. Goldmann and error correcting tonometry prisms compared to intracameral pressure. McCafferty S, Levine J, Schwiegerling J, Enikov ET. *BMC Ophthalmol*. 2018 Jan 4;18(1):2. \*CATS™ Tonometer Prism is distributed by Reichert Technologies - CATS is a trademark of CATS Tonometer, LLC - CATS logo is a registered trademark of CATS Tonometer, LLC.

## EDITORIAL STAFF

**Editor in Chief**

**Walter C. Bethke**  
(610) 492-1024  
wbethke@jobson.com

**Senior Editor**

**Christopher Kent**  
(212) 274-7031  
ckent@jobson.com

**Senior Editor**

**Sean McKinney**  
(610) 492-1025  
semckinney@jobson.com

**Associate Editor**

**Christine Leonard**  
(610) 492-1008  
cleonard@jobson.com

**Chief Medical Editor**

**Mark H. Blecher, MD**

**Art Director**

**Jared Araujo**  
(610) 492-1032  
jaraujo@jobson.com

**Senior Graphic Designer**

**Matt Egger**  
(610) 492-1029  
megger@jobson.com

**International coordinator, Japan**

**Mitz Kaminuma**  
Reviewophtharmo@aol.com

**Business Offices**

19 Campus Blvd., Suite 101  
Newtown Square, PA 19073

**Subscription inquiries:**

United States – (877) 529-1746  
Outside U.S. – (845) 267-3065  
E-mail:  
revophthalmology@cambeywest.com  
Website: www.reviewofophthalmology.com



## REVIEW NEWS

**Alcon Launches Vivivity IOL**

*(Continued from p. 3)*

was able to meet the primary endpoint of noninferiority in BCDVA compared to the monofocal.

In terms of refractive status after surgery, Vivivity and the monofocal had very similar six-month postop manifest refractive spherical error. Mean MRSE was 0.049 D in the Vivivity group and 0.081 D in the monofocal group, and 91.6 percent of first eyes in the Vivivity group were within 0.5 D of target versus 86.5 percent in the monofocal group.<sup>1</sup>

“The most impressive outcome of the study was the difference between the Vivivity and monofocal groups in reported quality of distance and intermediate vision in dim lighting,” he says. “Eighty-three percent of patients in the Vivivity group said they had good distance and intermediate vision without glasses in dim lighting, compared to 51 percent of the monofocal group.”

Additionally, based on the FDA data from 107 Vivivity patients, Dr. Baartman says this lens had a similar dysphotopsia profile to the monofocal lens.

Dr. Baartman has used a variety of the Vivivity toric lenses, as well as the spherical lens, and he says he’s gotten good results. “It’s likely not going to give your patients 20/20 near vision, but it can offer better spectacle-free functionality for patients who are a little more sensitive to photoptic phenomena and desire excellent distance and intermediate vision.”

In mesopic conditions, Vivivity demonstrated lower monocular contrast sensitivity compared to the monofocal lens in a trial conducted outside of the United States.<sup>2</sup> Alcon includes a warning about this in the package insert. Dr. Baartman points out, however, that the

clinical relevance of this finding may be limited since binocular contrast sensitivity wasn’t tested in this trial.

“This isn’t a lens to put in everybody, because not everyone will want this type of correction,” he continues. He advises implanting this lens for those who feel OK about wearing reading glasses after surgery for near work, or for those who are too particular about their vision for a true multifocal lens: those bothered by postoperative dysphotopsias or those who do a lot of night driving.

“I think this lens has a broader application just by nature of its not being a diffractive lens,” Dr. Baartman says. “You may be able to include mild glaucoma patients who are stable at the time of cataract surgery and do a combined MIGS procedure. Another possible application, though I haven’t used it extensively for this, could be for use patients with less-than-perfect corneas, possibly post-refractive surgery corneas, and even post-radial keratotomy patients. The extended-depth-of-field channel may theoretically reduce some of the fluctuations in refractive error by creating a larger ‘landing zone’ of good-quality vision in those patients. Also, patients with mild epiretinal membrane, who might be held back by the need for a perfect macula that’s needed for a true diffractive intraocular lens to hit a home run, might benefit from this lens.” ◀

1. AcrySoft IQ Vivivity Extended Vision IOL Product information. FDA.gov. Accessed January 19, 2021. [www.accessdata.fda.gov/cdrh\\_docs/pdf/P930014S126C.pdf](http://www.accessdata.fda.gov/cdrh_docs/pdf/P930014S126C.pdf).  
2. McCabe C. Clinical outcomes of a novel non-diffractive extended vision IOL. International Society of Presbyopia. Presented December 2019. Accessed January 19, 2021.  
3. Recently-approved medical devices. FDA.gov. Accessed January 19, 2021. <https://www.fda.gov/medical-devices/recently-approved-devices/acrysoftm-iq-vivitytm-extended-vision-intraocular-lens-iol-model-dft015-acrysoftm-iq-vivitytm-toric>.

**EYSUVIS (loteprednol etabonate ophthalmic suspension) 0.25%,  
for topical ophthalmic use**

**BRIEF SUMMARY OF FULL PRESCRIBING INFORMATION**

**INDICATIONS AND USAGE**

EYSUVIS is a corticosteroid indicated for the short-term (up to two weeks) treatment of the signs and symptoms of dry eye disease.

**CONTRAINDICATIONS**

EYSUVIS, as with other ophthalmic corticosteroids, is contraindicated in most viral diseases of the cornea and conjunctiva including epithelial herpes simplex keratitis (dendritic keratitis), vaccinia, and varicella, and also in mycobacterial infection of the eye and fungal diseases of ocular structures.

**WARNINGS AND PRECAUTIONS**

**Delayed Healing and Corneal Perforation**—Topical corticosteroids have been known to delay healing and cause corneal and scleral thinning. Use of topical corticosteroids in the presence of thin corneal or scleral tissue may lead to perforation. The initial prescription and each renewal of the medication order should be made by a physician only after examination of the patient with the aid of magnification, such as slit lamp biomicroscopy, and, where appropriate, fluorescein staining.

**Intraocular Pressure (IOP) Increase**—Prolonged use of corticosteroids may result in glaucoma with damage to the optic nerve, as well as defects in visual acuity and fields of vision. Corticosteroids should be used with caution in the presence of glaucoma. Renewal of the medication order should be made by a physician only after examination of the patient and evaluation of the IOP.

**Cataracts**—Use of corticosteroids may result in posterior subcapsular cataract formation.

**Bacterial Infections**—Use of corticosteroids may suppress the host response and thus increase the hazard of secondary ocular infections. In acute purulent conditions of the eye, corticosteroids may mask infection or enhance existing infection.

**Viral Infections**—Use of corticosteroid medication in the treatment of patients with a history of herpes simplex requires great caution. Use of ocular corticosteroids may prolong the course and may exacerbate the severity of many viral infections of the eye (including herpes simplex).

**Fungal Infections**—Fungal infections of the cornea are particularly prone to develop coincidentally with long-term local corticosteroid application. Fungus invasion must be considered in any persistent corneal ulceration where a corticosteroid has been used or is in use. Fungal cultures should be taken when appropriate.

**Risk of Contamination**—Do not to allow the dropper tip to touch any surface, as this may contaminate the suspension.

**Contact Lens Wear**—The preservative in EYSUVIS may be absorbed by soft contact lenses. Contact lenses should be removed prior to instillation of EYSUVIS and may be reinserted 15 minutes following administration.

**ADVERSE REACTIONS**

Adverse reactions associated with ophthalmic corticosteroids include elevated intraocular pressure, which may be associated with infrequent optic nerve damage, visual acuity and field defects, posterior subcapsular cataract formation, delayed wound healing and secondary ocular infection from pathogens including herpes simplex, and perforation of the globe where there is thinning of the cornea or sclera.

**Clinical Trials Experience**—Because clinical trials are conducted under widely varying conditions, adverse reaction rates observed in the clinical trials of a drug cannot be directly compared to rates in the clinical trials of another drug and may not reflect the rates observed in practice.

The most common adverse reaction observed in clinical trials with EYSUVIS was instillation site pain, which was reported in 5% of patients.

**USE IN SPECIFIC POPULATIONS**

**Pregnancy—Risk Summary**—There are no adequate and well controlled studies with loteprednol etabonate in pregnant women. Loteprednol etabonate produced teratogenicity at clinically relevant doses in the rabbit and rat when administered orally during pregnancy. Loteprednol etabonate produced malformations when administered orally to pregnant rabbits at doses 1.4 times the recommended human ophthalmic dose (RHOD) and to pregnant rats at doses 34 times the RHOD. In pregnant rats receiving oral doses of loteprednol etabonate during the period equivalent to the last trimester of pregnancy through lactation in humans, survival of offspring was reduced at doses 3.4 times the RHOD. Maternal toxicity was observed in rats at doses 347 times the RHOD, and a maternal no observed adverse effect level (NOAEL) was established at 34 times the RHOD.

The background risk in the U.S. general population of major birth defects is 2 to 4%, and of miscarriage is 15 to 20%, of clinically recognized pregnancies.

**Data—Animal Data:** Embryofetal studies were conducted in pregnant rabbits administered loteprednol etabonate by oral gavage on gestation days 6 to 18, to target the period of organogenesis. Loteprednol etabonate produced fetal malformations at 0.1 mg/kg (1.4 times the recommended human ophthalmic dose (RHOD) based on body surface area, assuming 100% absorption). Spina bifida (including meningocele) was observed at 0.1 mg/kg, and exencephaly and craniofacial malformations were observed at 0.4 mg/kg (5.6 times the RHOD). At 3 mg/kg (41 times the RHOD), loteprednol etabonate was associated with increased incidences of abnormal left common carotid artery, limb flexures, umbilical hernia, scoliosis, and delayed ossification. Abortion and embryofetal lethality (resorption) occurred at 6 mg/kg (83 times the RHOD). A NOAEL for developmental toxicity was not established in this study. The NOAEL for maternal toxicity in rabbits was 3 mg/kg/day.

Embryofetal studies were conducted in pregnant rats administered loteprednol etabonate by oral gavage on gestation days 6 to 15, to target the period of organogenesis. Loteprednol etabonate produced fetal malformations, including absent innominate artery at 5 mg/kg (34 times the RHOD); and cleft palate, agnathia, cardiovascular defects, umbilical hernia, decreased fetal body weight and decreased skeletal ossification at 50 mg/kg (347 times the RHOD). Embryofetal lethality (resorption) was observed at 100 mg/kg (695 times the RHOD). The NOAEL for developmental toxicity in rats was 0.5 mg/kg (3.4 times the RHOD). Loteprednol etabonate was maternally toxic (reduced body weight gain) at 50 mg/kg/day. The NOAEL for maternal toxicity was 5 mg/kg.

A peri-/postnatal study was conducted in rats administered loteprednol etabonate by oral gavage from gestation day 15 (start of fetal period) to postnatal day 21 (the end of lactation period). At 0.5 mg/kg (3.4 times the clinical dose), reduced survival was observed in live-born offspring. Doses  $\geq$  5 mg/kg (34 times the RHOD) caused umbilical hernia/incomplete gastrointestinal tract. Doses  $\geq$  50 mg/kg (347 times the RHOD) produced maternal toxicity (reduced body weight gain, death), decreased number of live-born offspring, decreased birth weight, and delays in postnatal development. A developmental NOAEL was not established in this study. The NOAEL for maternal toxicity was 5 mg/kg.

**Lactation**—There are no data on the presence of loteprednol etabonate in human milk, the effects on the breastfed infant, or the effects on milk production. The developmental and health benefits of breastfeeding should be considered, along with the mother's clinical need for EYSUVIS and any potential adverse effects on the breastfed infant from EYSUVIS.

**Pediatric Use**—Safety and effectiveness in pediatric patients have not been established.

**Geriatric Use**—No overall differences in safety and effectiveness have been observed between elderly and younger adult patients.

**NONCLINICAL TOXICOLOGY**

**Carcinogenesis, Mutagenesis, Impairment of Fertility**—Long-term animal studies have not been conducted to evaluate the carcinogenic potential of loteprednol etabonate. Loteprednol etabonate was not genotoxic *in vitro* in the Ames test, the mouse lymphoma thymidine kinase (tk) assay, in a chromosome aberration test in human lymphocytes, or *in vivo* in the single dose mouse micronucleus assay. Treatment of male and female rats with 25 mg/kg/day of loteprednol etabonate (174 times the RHOD based on body surface area, assuming 100% absorption) prior to and during mating caused pre-implantation loss and decreased the number of live fetuses/live births. The NOAEL for fertility in rats was 5 mg/kg/day (34 times the RHOD).

**For a copy of the Full Prescribing Information, please visit  
[www.EYSUVIS.com](http://www.EYSUVIS.com).**

Manufactured for:  
Kala Pharmaceuticals, Inc.  
Watertown, MA 02472

Part # 2026R02

Marks designated by <sup>TM</sup> or <sup>®</sup> are owned by Kala Pharmaceuticals, Inc.  
Patented. [www.kalarx.com/patents](http://www.kalarx.com/patents)

© 2020 Kala Pharmaceuticals, Inc. All rights reserved.

October 2020

**Kala<sup>®</sup>**

US-EYS-2000115

The **FIRST AND ONLY FDA APPROVED SHORT-TERM**  
(up to two weeks) Rx treatment for the signs and symptoms of Dry Eye Disease

**IN THE BATTLEGROUND OF DRY EYE...**

**When Dry Eye  
Flares strike,**

**fight  
back  
first  
with  
fast.**



#### INDICATION

EYSUVIS is a corticosteroid indicated for the short-term (up to two weeks) treatment of the signs and symptoms of dry eye disease.

#### IMPORTANT SAFETY INFORMATION

##### Contraindication:

EYSUVIS, as with other ophthalmic corticosteroids, is contraindicated in most viral diseases of the cornea and conjunctiva including epithelial herpes simplex keratitis (dendritic keratitis), vaccinia, and varicella, and also in mycobacterial infection of the eye and fungal diseases of ocular structures.

##### Warnings and Precautions:

**Delayed Healing and Corneal Perforation:** Topical corticosteroids have been known to delay healing and cause corneal and scleral thinning. Use of topical corticosteroids in the presence of thin corneal or scleral tissue may lead to perforation. The initial prescription and each renewal of the medication order should be made by a physician only after examination of the patient with the aid of magnification, such as slit lamp biomicroscopy, and, where appropriate, fluorescein staining.

**Intraocular Pressure (IOP) Increase:** Prolonged use of corticosteroids may result in glaucoma with damage to the optic nerve, as well as defects in visual acuity and fields of vision. Corticosteroids should be used with caution in the presence of glaucoma. Renewal of the medication order should be made by a physician only after examination of the patient and evaluation of the IOP

**Cataracts:** Use of corticosteroids may result in posterior subcapsular cataract formation.

**Bacterial Infections:** Use of corticosteroids may suppress the host response and thus increase the hazard of secondary ocular infections. In acute purulent conditions, corticosteroids may mask infection or enhance existing infection

**Viral Infections:** Use of a corticosteroid medication in the treatment of patients with a history of herpes simplex requires great caution. Use of ocular corticosteroids may prolong the course and may exacerbate the severity of many viral infections of the eye (including herpes simplex).

**Fungal Infections:** Fungal infections of the cornea are particularly prone to develop coincidentally with long-term local corticosteroid application. Fungus invasion must be considered in any persistent corneal ulceration where a corticosteroid has been used or is in use.

##### Adverse Reactions:

The most common adverse drug reaction following the use of EYSUVIS for two weeks was instillation site pain, which was reported in 5% of patients.

Please see Brief Summary of Prescribing Information for EYSUVIS on the next page.

# FEATURES

Vol. 28, No. 2 • FEBRUARY 2021

**Catch Up on the Latest News**

Read *Review's* Weekly Newsletter

Online at [reviewofophthalmology.com](http://reviewofophthalmology.com)

## HOW TO CHOOSE THE RIGHT MIGS



**28**

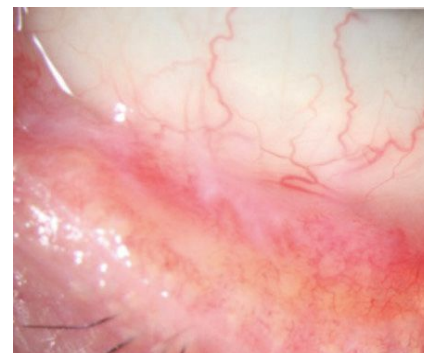
### Which MIGS for Which Patients?

The severity of glaucoma, number of current medications and other factors that help you make the best choice. **Christopher Kent, Senior Editor**

**38**

### Reconceiving Glaucoma Care

Minimizing risk, increasing efficiency and ensuring quality care during the pandemic—and beyond. **Sean McKinney, Senior Editor**

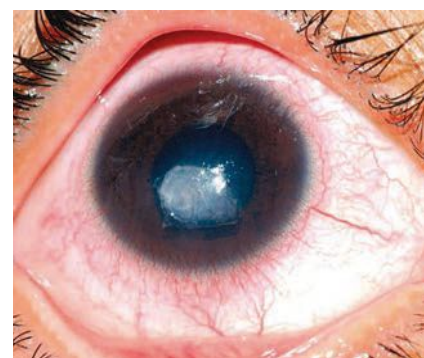

**46**

### Dry Eye: The Blepharitis Connection

How to diagnose and treat blepharitis and why patient education is key.

**Christine Leonard, Associate Editor**



**52**

### Solving the Puzzle of Corneal Ulcers

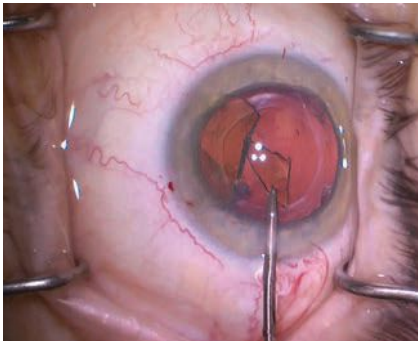
How to expect horses—but prepare for zebras—when faced with a corneal infection.

**Michelle Stephenson, Contributing Editor**

# DEPARTMENTS

FEBRUARY 2021

## 3 News



## 17 REFRACTIVE/CATARACT RUNDOWN

### Are You Lawsuit-proof?

The risk of getting sued for refractive and cataract surgery appears to be minimal—unless you're the one being sued. Find out how to play it safe.


*Sean McKinney, Senior Editor*

## 24 MEDICARE Q & A

### What's New for 2021

The new codes, changes and quality requirements you need to know about to be prepared for the coming year.

*Paul Larson, MBA, MMSc, COMT*



## 56 TECHNOLOGY UPDATE

### 5G and Ophthalmology: Ready for Prime Time?

The latest standard for wireless communication offers both advantages and potential pitfalls.

*Christopher Kent, Senior Editor*

## 60 GLAUCOMA MANAGEMENT

### Cataract Surgery in Eyes With Angle Closure

These eyes present special challenges for the cataract surgeon. Here's help.

*Michelle C. Lim, MD*

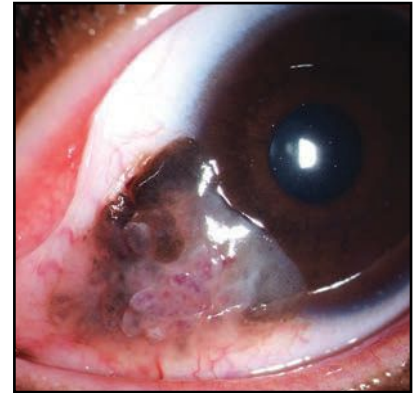## 67 RESEARCH REVIEW

### Helping Postop Aqueous Shunt Surgery Outcomes

## 68 PRODUCT NEWS

### New Diagnostic Devices And Other Tech Debut

## 70 CLASSIFIEDS/AD INDEX



## 71 WILLS EYE RESIDENT CASE SERIES

### A Boy Presents with a Conjunctival Lesion and Skin Abnormalities

*Alina Yang, MD, Tatyana Milman, MD,  
Philip W. Dockery, MD, MPH,  
Antonio Yaghy, MD, and Carol L.  
Shields, MD*

 VISIT US ON SOCIAL MEDIA

Facebook

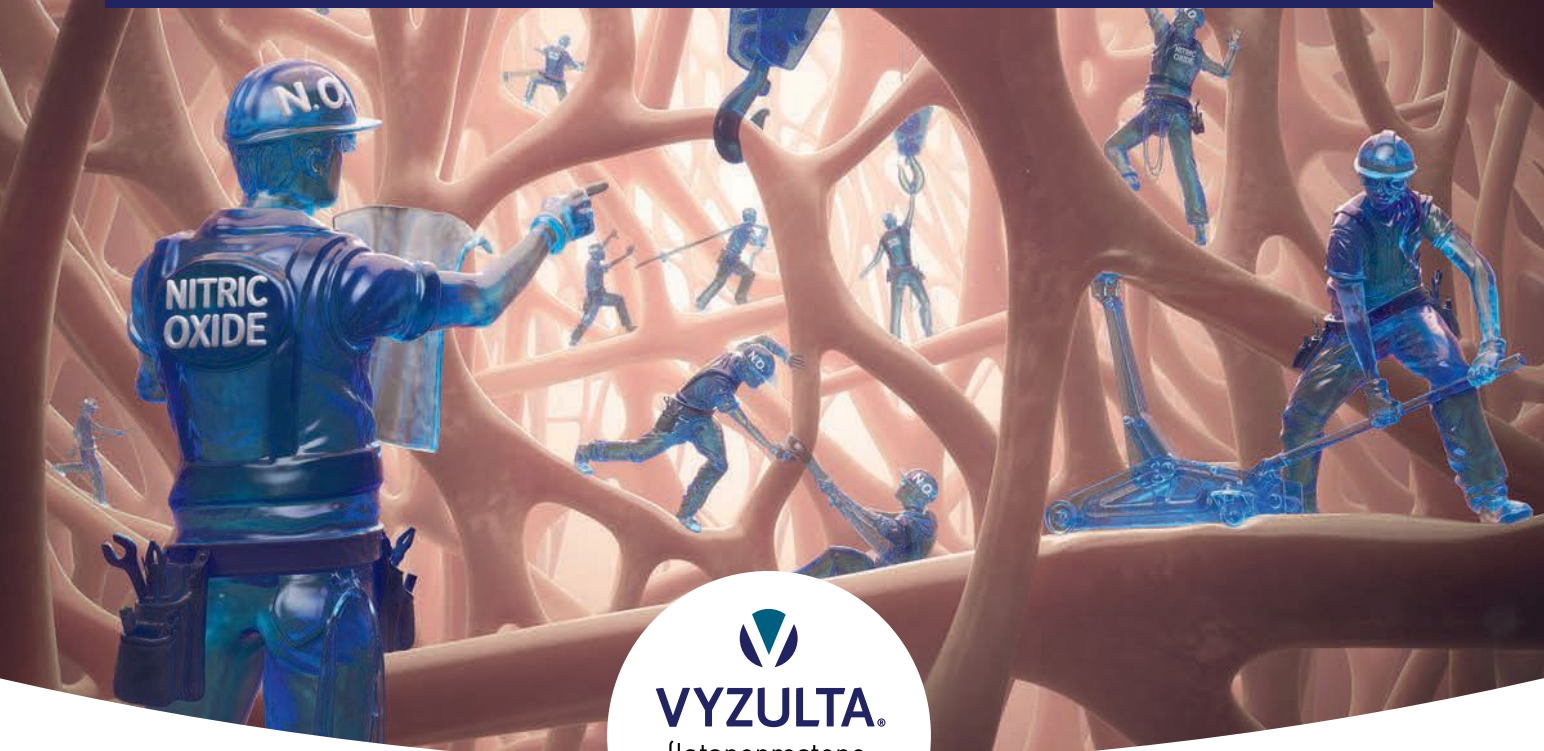[www.facebook.com/RevOphth](https://www.facebook.com/RevOphth)

Twitter

[twitter.com/RevOphth](https://twitter.com/RevOphth)



Only dual-action VYZULTA reduces intraocular pressure (IOP) by targeting the trabecular meshwork with nitric oxide and the uveoscleral pathway with latanoprost acid<sup>1</sup>



**VYZULTA**

(latanoprostene bunod ophthalmic solution), 0.024%

## EXPAND THE TRABECULAR MESHWORK WITH THE POWER OF NITRIC OXIDE<sup>2-6</sup>

### VYZULTA achieved significant and sustained long-term IOP reductions vs Timolol 0.5% in pivotal trials<sup>7</sup>

$P < 0.001$  vs baseline at all pre-specified visits over 12 months in a pooled analysis of APOLLO and LUNAR clinical trials (N=831)

### VYZULTA demonstrated safety profile in clinical trials

Only 6 out of 811 patients discontinued due to ocular adverse events in APOLLO and LUNAR clinical trials<sup>1,8,9</sup>

Visit [VYZULTANOW.com](http://VYZULTANOW.com) to see our efficacy results

### INDICATION

VYZULTA® (latanoprostene bunod ophthalmic solution), 0.024% is indicated for the reduction of intraocular pressure (IOP) in patients with open-angle glaucoma or ocular hypertension.

### IMPORTANT SAFETY INFORMATION

- Increased pigmentation of the iris and periorbital tissue (eyelid) can occur. Iris pigmentation is likely to be permanent
- Gradual changes to eyelashes, including increased length, increased thickness, and number of eyelashes, may occur. These changes are usually reversible upon treatment discontinuation
- Use with caution in patients with a history of intraocular inflammation (iritis/uveitis). VYZULTA should generally not be used in patients with active intraocular inflammation
- Macular edema, including cystoid macular edema, has been reported during treatment with prostaglandin analogs. Use with caution in aphakic patients, in pseudophakic patients with a torn posterior lens capsule, or in patients with known risk factors for macular edema

### IMPORTANT SAFETY INFORMATION cont'd

- There have been reports of bacterial keratitis associated with the use of multiple-dose containers of topical ophthalmic products that were inadvertently contaminated by patients
- Contact lenses should be removed prior to the administration of VYZULTA and may be reinserted 15 minutes after administration
- Most common ocular adverse reactions with incidence  $\geq 2\%$  are conjunctival hyperemia (6%), eye irritation (4%), eye pain (3%), and instillation site pain (2%)

For more information, please see Brief Summary of Prescribing Information on adjacent page.

**References:** 1. VYZULTA Prescribing Information. Bausch & Lomb Incorporated. 2. Cavet ME. *J Ocul Pharmacol Ther.* 2018;34(1):52-60. DOI:10.1089/jop.2016.0188. 3. Wareham LK. *Nitric Oxide.* 2018;77:75-87. DOI:10.1016/j.niox.2018.04.010. 4. Stamer DW. *Curr Opin Ophthalmol.* 2012;23:135-143. DOI:10.1097/ICU.0b013e32834ff23e. 5. Cavet ME. *Invest Ophthalmol Vis Sci.* 2015;56(6):4108-4116. 6. Kaufman PL. *Exp Eye Research.* 2008;86:13-17. DOI:10.1016/j.exer.2007.10.007. 7. Weinreb RN. *J Glaucoma.* 2018;27:7-15. 8. Weinreb RN. *Ophthalmology.* 2016;123(5):965-973. 9. Medeiros FA. *Am J Ophthalmol.* 2016;168:250-259.

## BRIEF SUMMARY OF PRESCRIBING INFORMATION

This Brief Summary does not include all the information needed to use VYZULTA safely and effectively. See full Prescribing Information for VYZULTA.

**VYZULTA®** (latanoprostene bunod ophthalmic solution), 0.024%, for topical ophthalmic use.

Initial U.S. Approval: 2017

### 1 INDICATIONS AND USAGE

VYZULTA® (latanoprostene bunod ophthalmic solution) 0.024% is indicated for the reduction of intraocular pressure (IOP) in patients with open-angle glaucoma or ocular hypertension.

### 4 CONTRAINDICATIONS

None

### 5 WARNINGS AND PRECAUTIONS

#### 5.1 Pigmentation

VYZULTA® (latanoprostene bunod ophthalmic solution), 0.024% may cause changes to pigmented tissues. The most frequently reported changes with prostaglandin analogs have been increased pigmentation of the iris and periorbital tissue (eyelid).

Pigmentation is expected to increase as long as latanoprostene bunod ophthalmic solution is administered. The pigmentation change is due to increased melanin content in the melanocytes rather than to an increase in the number of melanocytes. After discontinuation of VYZULTA, pigmentation of the iris is likely to be permanent, while pigmentation of the periorbital tissue and eyelash changes are likely to be reversible in most patients. Patients who receive prostaglandin analogs, including VYZULTA, should be informed of the possibility of increased pigmentation, including permanent changes. The long-term effects of increased pigmentation are not known.

Iris color change may not be noticeable for several months to years. Typically, the brown pigmentation around the pupil spreads concentrically towards the periphery of the iris and the entire iris or parts of the iris become more brownish. Neither nevi nor freckles of the iris appear to be affected by treatment. While treatment with VYZULTA® (latanoprostene bunod ophthalmic solution), 0.024% can be continued in patients who develop noticeably increased iris pigmentation, these patients should be examined regularly [see Patient Counseling Information (17) in full Prescribing Information].

#### 5.2 Eyelash Changes

VYZULTA may gradually change eyelashes and vellus hair in the treated eye. These changes include increased length, thickness, and the number of lashes or hairs. Eyelash changes are usually reversible upon discontinuation of treatment.

#### 5.3 Intraocular Inflammation

VYZULTA should be used with caution in patients with a history of intraocular inflammation (iritis/uveitis) and should generally not be used in patients with active intraocular inflammation as it may exacerbate this condition.

#### 5.4 Macular Edema

Macular edema, including cystoid macular edema, has been reported during treatment with prostaglandin analogs. VYZULTA should be used with caution in aphakic patients, in pseudophakic patients with a torn posterior lens capsule, or in patients with known risk factors for macular edema.

#### 5.5 Bacterial Keratitis

There have been reports of bacterial keratitis associated with the use of multiple-dose containers of topical ophthalmic products. These containers had been inadvertently contaminated by patients who, in most cases, had a concurrent corneal disease or a disruption of the ocular epithelial surface.

#### 5.6 Use with Contact Lens

Contact lenses should be removed prior to the administration of VYZULTA because this product contains benzalkonium chloride. Lenses may be reinserted 15 minutes after administration.

### 6 ADVERSE REACTIONS

The following adverse reactions are described in the Warnings and Precautions section: pigmentation (5.1), eyelash changes (5.2), intraocular inflammation (5.3), macular edema (5.4), bacterial keratitis (5.5), use with contact lens (5.6).

#### 6.1 Clinical Trials Experience

Because clinical trials are conducted under widely varying conditions, adverse reaction rates observed in the clinical trials of a drug cannot be directly compared to rates in the clinical trials of another drug and may not reflect the rates observed in practice.

VYZULTA was evaluated in 811 patients in 2 controlled clinical trials of up to 12 months duration. The most common ocular adverse reactions observed in patients treated with latanoprostene bunod were: conjunctival hyperemia (6%), eye irritation (4%), eye pain (3%), and instillation site pain (2%). Approximately 0.6% of patients discontinued therapy due to ocular adverse reactions including ocular hyperemia, conjunctival irritation, eye irritation, eye pain, conjunctival edema, vision blurred, punctate keratitis and foreign body sensation.

### 8 USE IN SPECIFIC POPULATIONS

#### 8.1 Pregnancy

##### Risk Summary

There are no available human data for the use of VYZULTA during pregnancy to inform any drug associated risks.

Latanoprostene bunod has caused miscarriages, abortion, and fetal harm in rabbits. Latanoprostene bunod was shown to be abortifacient and teratogenic when administered intravenously (IV) to pregnant rabbits at exposures  $\geq 0.28$  times the clinical dose. Doses  $\geq 20 \mu\text{g}/\text{kg}/\text{day}$  (23 times the clinical dose) produced 100% embryofetal lethality. Structural abnormalities observed in rabbit fetuses included anomalies of the great vessels and aortic arch vessels, domed head, sternebral and vertebral skeletal anomalies, limb hyperextension

and malrotation, abdominal distension and edema. Latanoprostene bunod was not teratogenic in the rat when administered IV at 150 mcg/kg/day (87 times the clinical dose) [see Data].

The background risk of major birth defects and miscarriage for the indicated population is unknown. However, the background risk in the U.S. general population of major birth defects is 2 to 4%, and of miscarriage is 15 to 20%, of clinically recognized pregnancies.

##### Data

##### Animal Data

Embryofetal studies were conducted in pregnant rabbits administered latanoprostene bunod daily by intravenous injection on gestation days 7 through 19, to target the period of organogenesis. The doses administered ranged from 0.24 to 80 mcg/kg/day. Abortion occurred at doses  $\geq 0.24$  mcg/kg/day latanoprostene bunod (0.28 times the clinical dose, on a body surface area basis, assuming 100% absorption). Embryofetal lethality (resorption) was increased in latanoprostene bunod treatment groups, as evidenced by increases in early resorptions at doses  $\geq 0.24$  mcg/kg/day and late resorptions at doses  $\geq 6$  mcg/kg/day (approximately 7 times the clinical dose). No fetuses survived in any rabbit pregnancy at doses of 20 mcg/kg/day (23 times the clinical dose) or greater. Latanoprostene bunod produced structural abnormalities at doses  $\geq 0.24$  mcg/kg/day (0.28 times the clinical dose). Malformations included anomalies of sternum, coarctation of the aorta with pulmonary trunk dilation, retroesophageal subclavian artery with absent brachiocephalic artery, domed head, forepaw hyperextension and hindlimb malrotation, abdominal distention/edema, and missing/fused caudal vertebrae.

An embryofetal study was conducted in pregnant rats administered latanoprostene bunod daily by intravenous injection on gestation days 7 through 17, to target the period of organogenesis. The doses administered ranged from 150 to 1500 mcg/kg/day. Maternal toxicity was produced at 1500 mcg/kg/day (870 times the clinical dose, on a body surface area basis, assuming 100% absorption), as evidenced by reduced maternal weight gain. Embryofetal lethality (resorption and fetal death) and structural anomalies were produced at doses  $\geq 300$  mcg/kg/day (174 times the clinical dose). Malformations included anomalies of the sternum, domed head, forepaw hyperextension and hindlimb malrotation, vertebral anomalies and delayed ossification of distal limb bones. A no observed adverse effect level (NOAEL) was established at 150 mcg/kg/day (87 times the clinical dose) in this study.

#### 8.2 Lactation

##### Risk Summary

There are no data on the presence of VYZULTA in human milk, the effects on the breastfed infant, or the effects on milk production. The developmental and health benefits of breastfeeding should be considered, along with the mother's clinical need for VYZULTA, and any potential adverse effects on the breastfed infant from VYZULTA.

#### 8.4 Pediatric Use

Use in pediatric patients aged 16 years and younger is not recommended because of potential safety concerns related to increased pigmentation following long-term chronic use.

#### 8.5 Geriatric Use

No overall clinical differences in safety or effectiveness have been observed between elderly and other adult patients.

### 13 NONCLINICAL TOXICOLOGY

#### 13.1 Carcinogenesis, Mutagenesis, Impairment of Fertility

Latanoprostene bunod was not mutagenic in bacteria and did not induce micronuclei formation in the *in vivo* rat bone marrow micronucleus assay. Chromosomal aberrations were observed *in vitro* with human lymphocytes in the absence of metabolic activation.

Latanoprostene bunod has not been tested for carcinogenic activity in long-term animal studies. Latanoprost acid is a main metabolite of latanoprostene bunod. Exposure of rats and mice to latanoprost acid, resulting from oral dosing with latanoprost in lifetime rodent bioassays, was not carcinogenic.

Fertility studies have not been conducted with latanoprostene bunod. The potential to impact fertility can be partially characterized by exposure to latanoprost acid, a common metabolite of both latanoprostene bunod and latanoprost. Latanoprost acid has not been found to have any effect on male or female fertility in animal studies.

#### 13.2 Animal Toxicology and/or Pharmacology

A 9-month toxicology study administered topical ocular doses of latanoprostene bunod to one eye of cynomolgus monkeys: control (vehicle only), one drop of 0.024% bid, one drop of 0.04% bid and two drops of 0.04% per dose, bid. The systemic exposures are equivalent to 4.2-fold, 7.9-fold, and 13.5-fold the clinical dose, respectively, on a body surface area basis (assuming 100% absorption). Microscopic evaluation of the lungs after 9 months observed pleural/subpleural chronic fibrosis/inflammation in the 0.04% dose male groups, with increasing incidence and severity compared to controls. Lung toxicity was not observed at the 0.024% dose.

U.S. Patent Numbers: 7,273,946; 7,629,345; 7,910,767; 8,058,467.

VYZULTA is a trademark of Bausch & Lomb Incorporated or its affiliates.

© 2020 Bausch & Lomb Incorporated or its affiliates.

##### Distributed by:

Bausch + Lomb, a division of

Bausch Health US, LLC

Bridgewater, NJ 08807 USA

Based on 9612403 (Folded), 9612303 (Flat) 5/2019

VYZ.0109.USA.20 Issued: 5/2020



EDITED BY ARTURO CHAYET, MD

## REFRACTIVE/CATARACT RUNDOWN

# Are You Lawsuit-proof?

*The risk of getting sued for refractive and cataract surgery appears to be minimal—unless you're the one being sued. Find out how to play it safe.*

BY SEAN MCKINNEY  
SENIOR EDITOR

**D**uring the past 10 years, 578 malpractice lawsuits related to cataract surgery have been filed, while only 55 have been brought for refractive surgery, according to Ophthalmic Mutual Insurance Company statistics. These numbers represent a fraction of the tens of millions of cataract and refractive surgeries performed during this span. However, experts who defend eye surgeons against legal action say the low numbers are no reason to let down your guard.

The experts urge you to take time-tested preventive measures to make sure you're not someday included in this exclusive but very unhappy club. "Having a suit filed against you is an experience you want to avoid if at all possible," says Gregory Tiemeier, Esq., of Tiemeier & Stich in Denver, a firm with decades of experience defending ophthalmologists in court. "The problem is that, if you get sued, you've already lost, whether you win the case or not. It's going to take a tremendous emotional toll on you and your time. It's very much a distraction and can be damaging to your reputation in the community, depending on the size of that community."

In this report, you'll learn what

typically constitutes a complaint and how to minimize the threat of one by correctly obtaining informed consent. You'll also find out ways to spot a potential suit and learn strategies you can use to effectively manage cases that might lead to a lawsuit.

### First: The Numbers

Between January 1, 2011 and December 31, 2020, OMIC recorded 21 settlements of refractive surgery lawsuits, adding up to \$2.9 million in total payments to plaintiffs. Payouts ranged from \$10,000 to \$300,000. Although the average payment of \$138,000 was relatively low compared to \$245,000 for all ophthalmic surgeries, the proportion of refractive surgery cases that resulted in settlements was relatively high, at 35 percent, compared to an average of 20 percent for all cases managed by OMIC.

For cataract surgery litigation, 119 cases (21 percent) led to settlements, totaling \$22.9 million. The average cataract surgery settlement was for \$192,865. The settlements for cataract surgery ranged from \$3,000 to \$1 million. There were three \$1 million settlements, plus one at \$900,000 and another at \$600,000.

Following are insights designed to help you prevent your liability company from having to pay any of these costs, based on the experts' responses to seven key questions.

### 1 *Anatomy of a complaint: How does one get started?*

Hans K. Bruhn, MHS, risk manager at OMIC, based on in San Francisco, says a complaint that could lead to a malpractice lawsuit begins as an incident in which a patient is unhappy about the care received. The patient may associate the problem with a lack of prudent care by you, raising key questions:

- Was the care appropriate?
- Did it meet the standard of care?
- Was the care provided in a timely manner?

"A complaint can then follow as a result of the patient's perception of these issues," says Mr. Bruhn. "If that complaint isn't managed or mitigated by the physician implementing risk-management advice and strategies, the complaint can escalate to a claim. This could be an allegation of negligent care and a written demand for money, or a lawsuit filed in the courts. Once a claim is filed, the incident involves an attorney, expenses and lot of the physician's time."

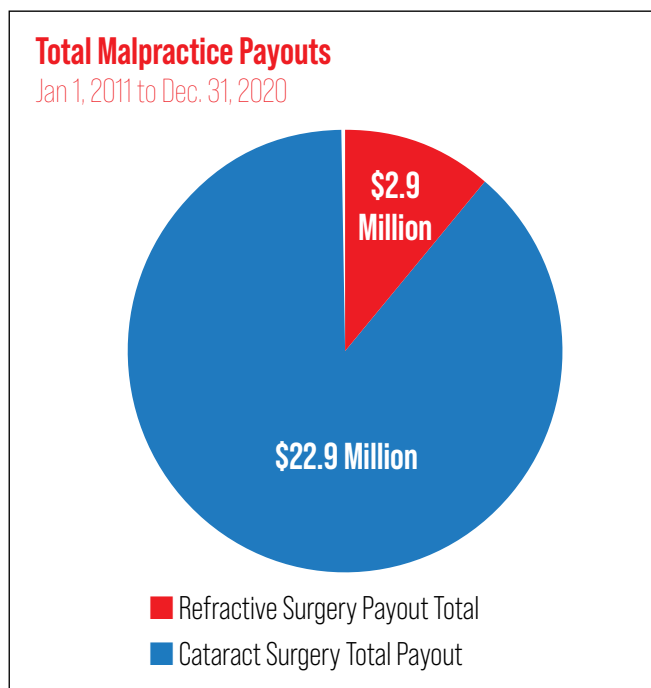
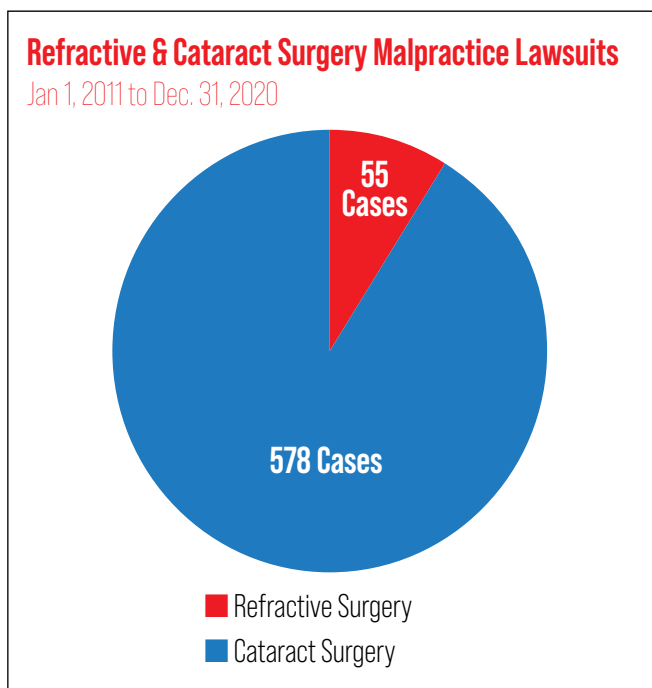
### 2 *Is deficient informed consent often to blame? What can surgeons do better?*

"The short answer is yes, deficient informed consent is often to blame," says Mr. Tiemeier. "In my experience, cataract and refractive surgeons usually create a pretty good electronic paper trail of informed consent. But that doesn't necessarily mean that the patient has received adequate information to give informed consent."

Mr. Tiemeier explains: "The recorded informed consent often shows that the surgeon has had a staff member review the surgery

This article has no commercial sponsorship.

Dr. Chayet is considered a pioneer in refractive and cataract surgery, and is medical director of the Codet Vision Institute in Tijuana, Mexico. He is a clinical investigator for RxSight, LensGen, ForSight Vision6.



**Figures 1 and 2. Malpractice lawsuits settled with unhappy cataract surgery patients during the past 10 years have cost nearly 10 times the amount paid to complaining refractive surgery patients. But the percentage of refractive surgery suits settled was 15 percent higher than the average of settlements paid on all other ophthalmic surgeries.**

with the patient and provide a consent form. The staff member says: ‘Here. Look this over and let me know if you have any questions. If you don’t, you can sign it and get it back to me,’” he says. “Sometimes, the patient will take the form home, read it and have a conversation with the surgeon or staff member the next day, discussing risks, benefits and alternatives associated with the procedure. Sometimes, however, the conversation takes place with the surgery scheduler. Nowhere in these cases will it show that the surgeon had any discussion with the patient, except perhaps on the day of surgery, when he asked the patient if he or she had any questions.”

Mr. Tiemeier says he can often defend a surgeon in this situation, even if the patient says he or she wasn’t given a chance to read the consent form. “Most juries will think the patient should’ve taken the time to read the form if they signed it,” he says. “But sometimes, more than a signature is needed. You should strive for what OMIC calls a therapeutic alliance, with the doctor and

the patient working as a team to overcome pathology.”

Patients are often examined and referred for surgery by a co-managing optometrist, he notes. All pre-operative exams and measurements may be completed (either within or outside of a practice) by someone other than the surgeon.

“If you don’t see the patient until the day of surgery, you really haven’t established an underlying sense of trust or therapeutic alliance. Most of the time, everything works out. If something doesn’t go right during surgery, though, you’ll find yourself apologizing and regretfully explaining what went wrong to a stranger. You may never have really talked to the patient, and the two of you are already in a conflict before you start the first conversation. That’s a bad way to start a therapeutic alliance.”

Mr. Tiemeier acknowledges that creating a therapeutic alliance requires extra time in your schedule and may not contribute to an efficient business model. “As the surgeon, you have to make the decision that works best for you and your

practice,” he notes. “How much time do you want to spend with the patient to build a rapport?”

To safeguard against these developments, Mr. Bruhn says you often need to strengthen the consent process. “The physician may say, ‘I’m going to do cataract surgery and it’s going to involve these risks,’” he says. “The patient says he or she understands. But what the patient understands may be completely different from what the physician is communicating. At OMIC, we strongly recommend that the physician confirm that there is an understanding of what is expected. For example, the physician can say, ‘We’ve talked about the complications that may occur. Do you understand the way that this complication might affect your daily life, if it occurs?’ Or, ‘Are you comfortable with the possible time it will take to recover from surgery or treatment, especially if there is a complication?’”

Some physicians add into the consent form an area in which the patient’s expectations of surgery or treatment are noted, in the patient’s

# UPNEEQ

Give Ptosis Patients an EYE-OPENING Lift  
With a Daily Drop of Upneeq® (oxymetazoline hydrochloride ophthalmic solution), 0.1%<sup>1</sup>

The only FDA-approved prescription eyedrop proven to lift upper eyelids in adults with acquired blepharoptosis (low-lying lids)<sup>1</sup>

Learn more at [Upneeq.com](http://Upneeq.com).

## INDICATION

Upneeq® (oxymetazoline hydrochloride ophthalmic solution), 0.1% is indicated for the treatment of acquired blepharoptosis in adults.

## IMPORTANT SAFETY INFORMATION

### WARNINGS AND PRECAUTIONS

- Alpha-adrenergic agonists as a class may impact blood pressure. Advise Upneeq patients with cardiovascular disease, orthostatic hypotension, and/or uncontrolled hypertension or hypotension to seek medical care if their condition worsens.
- Use Upneeq with caution in patients with cerebral or coronary insufficiency or Sjögren's syndrome. Advise patients to seek medical care if signs and symptoms of potentiation of vascular insufficiency develop.
- Upneeq may increase the risk of angle closure glaucoma in patients with untreated narrow-angle glaucoma. Advise patients to seek immediate medical care if signs and symptoms of acute narrow-angle glaucoma develop.
- Patients should not touch the tip of the single patient-use container to their eye or to any surface, in order to avoid eye injury or contamination of the solution.

## ADVERSE REACTIONS

Adverse reactions that occurred in 1-5% of subjects treated with Upneeq were punctate keratitis, conjunctival hyperemia, dry eye, blurred vision, instillation site pain, eye irritation, and headache.

## DRUG INTERACTIONS

- Alpha-adrenergic agonists, as a class, may impact blood pressure. Caution in using drugs such as beta blockers, anti-hypertensives, and/or cardiac glycosides is advised. Caution should also be exercised in patients receiving alpha adrenergic receptor antagonists such as in the treatment of cardiovascular disease, or benign prostatic hypertrophy.
- Caution is advised in patients taking monoamine oxidase inhibitors which can affect the metabolism and uptake of circulating amines.

**To report SUSPECTED ADVERSE REACTIONS or product complaints, contact RVL Pharmaceuticals at 1-877-482-3788. You may also report SUSPECTED ADVERSE REACTIONS to the FDA at 1-800-FDA-1088 or [www.fda.gov/medwatch](http://www.fda.gov/medwatch).**

**Please see next page for Brief Summary of full Prescribing Information.**

Reference: 1. Upneeq® (oxymetazoline hydrochloride ophthalmic solution), 0.1%. [Prescribing Information].

**RVL**  
PHARMACEUTICALS, INC.

Distributed by: RVL Pharmaceuticals, Inc.  
Bridgewater, NJ 08807  
Customer Service 1-866-600-4799  
Upneeq is a registered trademark of RVL Pharmaceuticals, Inc.  
©2021 RVL Pharmaceuticals, Inc.  
PM-US-UPN-0197 01/21

Learn more at [Upneeq.com](http://Upneeq.com)



**UPNEEQ**<sup>®</sup>  
(oxymetazoline hydrochloride ophthalmic solution), 0.1%\*

\*Each mL of Upneeq contains 1 mg of oxymetazoline hydrochloride, equivalent to 0.09 mg (0.09%) of oxymetazoline free base.

*Eye-Opening Possibilities*

**UPNEEQ® (oxymetazoline hydrochloride ophthalmic solution), 0.1%,\* for topical ophthalmic use**

\*Each mL of UPNEEQ contains 1 mg of oxymetazoline hydrochloride, equivalent to 0.09 mg (0.09%) of oxymetazoline free base.

**BRIEF SUMMARY: The following is a brief summary only; see full Prescribing Information at <https://www.upneeq.com/Upneeq-PI.pdf> for complete information.**

## 1 INDICATIONS AND USAGE

UPNEEQ is indicated for the treatment of acquired blepharoptosis in adults.

## 2 DOSAGE AND ADMINISTRATION

Contact lenses should be removed prior to instillation of UPNEEQ and may be reinserted 15 minutes following its administration.

If more than one topical ophthalmic drug is being used, the drugs should be administered at least 15 minutes between applications.

## 4 CONTRAINDICATIONS

None.

## 5 WARNINGS AND PRECAUTIONS

### 5.1 Potential Impacts on Cardiovascular Disease

Alpha-adrenergic agonists may impact blood pressure. UPNEEQ should be used with caution in patients with severe or unstable cardiovascular disease, orthostatic hypotension, and uncontrolled hypertension or hypotension. Advise patients with cardiovascular disease, orthostatic hypotension, and/or uncontrolled hypertension/hypotension to seek immediate medical care if their condition worsens.

### 5.2 Potentiation of Vascular Insufficiency

UPNEEQ should be used with caution in patients with cerebral or coronary insufficiency, or Sjögren's syndrome. Advise patients to seek immediate medical care if signs and symptoms of potentiation of vascular insufficiency develop.

### 5.3 Risk of Angle Closure Glaucoma

UPNEEQ may increase the risk of angle closure glaucoma in patients with untreated narrow-angle glaucoma. Advise patients to seek immediate medical care if signs and symptoms of acute angle closure glaucoma develop.

### 5.4 Risk of Contamination

Patients should not touch the tip of the single patient-use container to their eye or to any surface, in order to avoid eye injury or contamination of the solution.

## 6 ADVERSE REACTIONS

### 6.1 Clinical Trials Experience

Because clinical trials are conducted under widely varying conditions, adverse reaction rates observed in the clinical trials of a drug cannot be directly compared to rates in the clinical trials of another drug and may not reflect the rates observed in practice.

A total of 360 subjects with acquired blepharoptosis were treated with UPNEEQ once daily in each eye for at least 6 weeks in three controlled Phase 3 clinical trials, including 203 subjects treated with UPNEEQ for 6 weeks and 157 subjects treated with UPNEEQ for 12 weeks. Adverse reactions that occurred in 1-5% of subjects treated with UPNEEQ were punctate keratitis, conjunctival hyperemia, dry eye, blurred vision, instillation site pain, eye irritation, and headache.

## 7 DRUG INTERACTIONS

### 7.1 Anti-hypertensives/Cardiac Glycosides

Alpha-adrenergic agonists, as a class, may impact blood pressure. Caution in using drugs such as beta-blockers, anti-hypertensives, and/or cardiac glycosides is advised.

Caution should also be exercised in patients receiving alpha adrenergic receptor antagonists such as in the treatment of cardiovascular disease, or benign prostatic hypertrophy.

### 7.2 Monoamine Oxidase Inhibitors

Caution is advised in patients taking MAO inhibitors which can affect the metabolism and uptake of circulating amines.

## 8 USE IN SPECIFIC POPULATIONS

### 8.1 Pregnancy

#### Risk Summary

There are no available data on UPNEEQ use in pregnant women to inform a drug-associated risk for major birth defects and miscarriage. In animal reproduction studies, there were no adverse developmental effects observed after oral administration of oxymetazoline hydrochloride in pregnant rats and rabbits at systemic exposures up to 7 and 278 times the maximum recommended human ophthalmic dose (MRHOD), respectively, based on dose comparison. [see Data]. The estimated background risks of major birth defects and miscarriage for the indicated population are unknown. All pregnancies have a background risk of birth defect, loss, or other adverse outcomes. In the U.S. general population, the estimated background risk of major birth defects and miscarriage in clinically recognized pregnancies is 2-4% and 15-20%, respectively.

#### Data

##### Animal Data

Effects on embryo-fetal development were evaluated in rats and rabbits following oral administration of oxymetazoline hydrochloride during the period of organogenesis. Oxymetazoline hydrochloride did not cause adverse effects to the fetus at oral doses up to 0.2 mg/kg/day in pregnant rats during the period of organogenesis (28 times the MRHOD, on a dose comparison basis). Oxymetazoline hydrochloride did not cause adverse effects to the fetus at oral doses up to 1 mg/kg/day in pregnant rabbits during the period of organogenesis (278 times the MRHOD, on a dose comparison basis). Maternal toxicity, including decreased maternal body weight, was produced at the high dose of 1 mg/kg/day in pregnant rabbits and was associated with findings of delayed skeletal ossification.

In a rat prenatal and postnatal development study, oxymetazoline hydrochloride was orally administered to pregnant rats once daily from gestation day 6 through lactation day 20. Maternal toxicity was produced at the high dose of 0.2 mg/kg/day (28 times the MRHOD, on a dose comparison basis) in pregnant rats and was associated with an increase in pup mortality and reduced pup body weights. Delayed sexual maturation was noted at 0.1 mg/kg/day (14 times the MRHOD, on a dose comparison basis). Oxymetazoline hydrochloride did not have any adverse effects on fetal development at a dose of 0.05 mg/kg/day (7 times the MRHOD, on a dose comparison basis).

### 8.2 Lactation

#### Risk Summary

No clinical data are available to assess the effects of oxymetazoline on the quantity or rate of breast milk production, or to establish the level of oxymetazoline present in human breast milk post-dose. Oxymetazoline was detected in the milk of lactating rats. The developmental and health benefits of breastfeeding should be considered along with the mother's clinical need for UPNEEQ and any potential adverse effects on the breastfed child from UPNEEQ.

### 8.4 Pediatric Use

Safety and effectiveness of UPNEEQ have not been established in pediatric patients under 13 years of age.

### 8.5 Geriatric Use

Three hundred and fifteen subjects aged 65 years and older received treatment with UPNEEQ (n = 216) or vehicle (n = 99) in clinical trials. No overall differences in safety or effectiveness were observed between subjects 65 years of age and older and younger subjects.

## 10 OVERDOSAGE

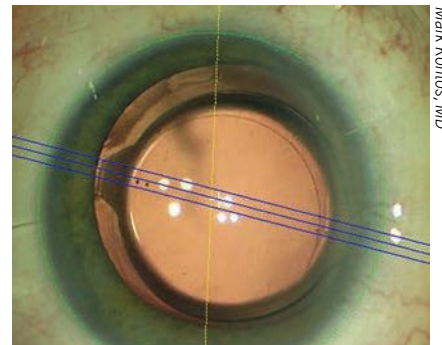
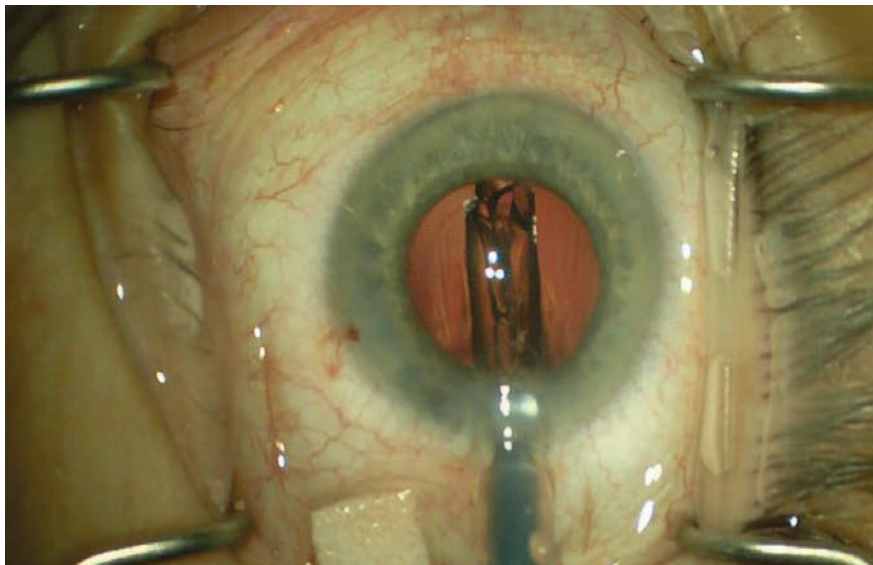
Accidental oral ingestion of topical intended solutions (including ophthalmic solutions and nasal sprays) containing imidazoline derivatives (e.g., oxymetazoline) in children has resulted in serious adverse events requiring hospitalization, including nausea, vomiting, lethargy, tachycardia, decreased respiration, bradycardia, hypotension, hypertension, sedation, somnolence, mydriasis, stupor, hypothermia, drooling, and coma. Keep UPNEEQ out of reach of children.

## PATIENT COUNSELING INFORMATION

Advise the patient to read the FDA-approved patient labeling (Instructions for Use).

**RVL**  
PHARMACEUTICALS, INC.

Manufactured for: RVL Pharmaceuticals, Inc.  
Bridgewater, New Jersey 08807  
©2021 RVL Pharmaceuticals, Inc.  
UPNEEQ is a registered trademark of RVL Pharmaceuticals, Inc.  
PM-US-UPN-0203 01/21



Mark Kontos, MD

**Figures 3 and 4.** This patient paid a premium price for a toric IOL, but he returned to the surgeon two weeks later with blurred vision. Repositioning the misaligned lens, as shown on the right, cleared up the patient's vision and ended any thoughts of a malpractice claim by the patient.

own words. Clarify these to ensure the patient's expectations are reasonable before asking the patient to sign the consent form. "You want to make sure the informed consent process confirms reasonable patient expectations," notes Mr. Bruhn.

### **3** *How does a malpractice lawsuit affect a surgeon and his or her practice, including reputation and confidence?*

The effects on your practice reputation, morale and psyche are potentially devastating, experts say. Ryan Busci, vice president of claims at OMIC, says expert ophthalmologists retained by OMIC will comb through the documentation and clinical details of your case, from the preop exam and planning to final outcome. The aggrieved patient's attorney will also hire one or more experts to closely look at your case for mistakes and oversights.

"If they haven't been involved in a lawsuit, ophthalmologists might not know or fully appreciate all of this," says Mr. Busci. "But if they have been involved in a lawsuit, they're never going to forget it."

OMIC offers guidance to affected doctors on how to cope with litigation stress. "When someone has accused a physician of negligence, it's a very personal matter," says Mr. Bruhn. "A lawsuit can be a great

stressor on all who are involved. The practice entity can be named in the suit, adding to those impacted. Because multiple parties can be named in a lawsuit, this can expose multiple limits of insurance, increasing the potential money paid to resolve a claim."

A lawsuit against you will also emerge as public information when it's filed, he notes. And, if the lawsuit is settled or a verdict paid on behalf of the physician, this information must be reported to the National Practitioner Data Bank (NPDB), a repository of medical malpractice payments. "This is why, in risk management, we work hard to prevent a suit from being filed," says Mr. Bruhn.

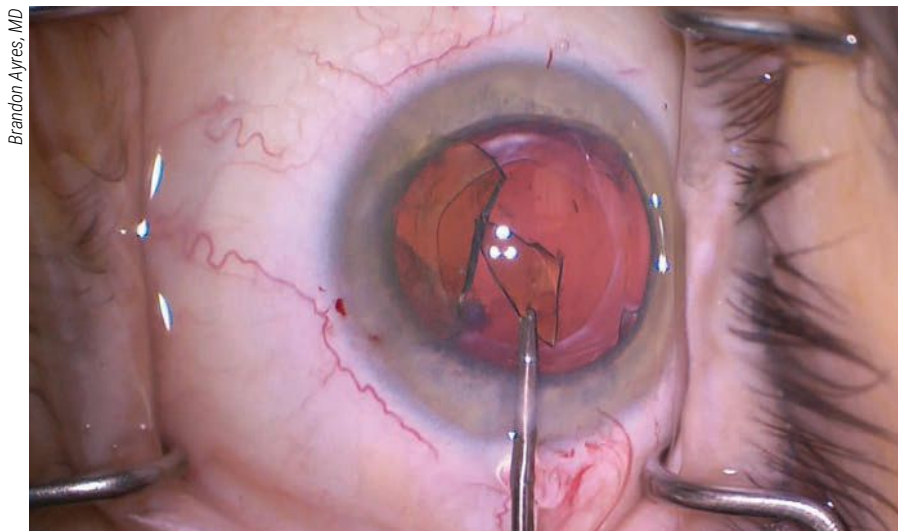
Once a claim is paid, it has the potential to damage a physician's reputation. "Sometimes, information about a claim is shared on social media, or criticisms of a physician are posted," says Mr. Bruhn. "It's not easy to see that information about yourself on Facebook or some other social media platform. It's a public forum, but because of the Health Insurance Portability and Accountability Act, a doctor can't even acknowledge that the person who's complaining has been his or her patient. All you can do is recommend the person contact the physician's office for a private discussion."

### **4** *How can you recognize the potential for a lawsuit?*

"You can definitely identify the potential for a lawsuit," says Mr. Tiemeier. "Some patients are going to be unhappy with an objective satisfactory outcome. And that has to do with shortcomings they have in their lives generally. They are often depressed, for example."

Technicians and doctors are typically not surprised by who files a lawsuit. "Watch for a patient who is particularly demanding or who never seems to be happy with anything that you do," says Mr. Tiemeier. "If a patient doesn't communicate well and seems defensive or prickly, proceed with caution. You don't have to operate on these patients. But you need to be really careful with your charting, using free texting in your EHRs to explain why you don't think surgery is advisable."

Mr. Tiemeier recalls one case involving a highly myopic patient with a long-standing cataract who experienced a retinal detachment in his good eye. The cataract was removed, despite the threat of another retinal detachment. "The surgeon did a very good job of documenting every visit while educating the patient on the risks of a very complex procedure," says Mr. Tiemeier. "Patching and additional



Brandon Ayres, MD

**Figure 5. Removing the shards of an inadequate IOL during a lens exchange can be a meticulous process. But it may not seem so burdensome if it spares you a lawsuit over a lens that has disappointed your patient, surgeons say.**

surgery were required. The careful documentation made the case very defensible. I had another case of an 11-D myope, whom the surgeon tried to correct with LASIK. There was absolutely nothing in the chart before or even after surgery about the risk of LASIK in a high myope creating the high potential for a flap complication.”

Another patient in Mr. Tiemeier’s case files was a high myope and a bond attorney who couldn’t read small type to do her job for months after LASIK. “You need to carefully consider a confluence of clinical, medical, personality, occupational and lifestyle factors before doing any procedure,” he says.

Another sign of increased risk, says Mr. Bruhn, is when patients can’t decide whether to undergo a procedure and tell you they’ll get back to you. “The patient may say he or she wants to check with another doctor,” says Mr. Bruhn. “This may be fine because, obviously, second opinions are always welcome. But there’s a point when the patient’s indecisiveness and even incorrect perceptions should signal to you that there’s potential for a problem. Ask yourself: Given the patient’s current attitude, how will the patient act after a surgical

complication? The case might be hard to manage.”

### **5** *What common liability traps should you be aware of?*

From a clinical perspective, Mr. Busci says the most common problems that lead to settlements in refractive surgery are faulty preop exams. “This can occur when doctors don’t recognize that some patients aren’t suitable candidates for a procedure,” he notes. “Cases of missed keratoconus are prevalent. Sometimes, doctors just don’t recognize that a patient has a cornea that’s not appropriate for refractive surgery.”

For cataract surgery, Mr. Bruhn says the choice or power of an IOL can lead to patient dissatisfaction. “For example, we’ve had patients complain that they didn’t select a toric lens, even though the documentation clearly shows that the patient selected that lens,” says Mr. Bruhn. The discussion and documentation need to go beyond the risks, benefits and potential complications. “This is typically handled by the physician and the scheduling coordinator at the office,” he points out. “For refractive surgery, it’s crucial to discuss patient expectations and the healing process.”

Mr. Busci notes that his com-

pany has seen a noticeable uptick in complaints and lawsuits related to the implantation of premium IOLs in recent years. How does he recommend reducing risk for these cases? “I believe many cataract surgery lawsuits come from unrealistic expectations about the capabilities of these high-technology lens implants, including the unrealistic expectation that every patient will be independent of the need for glasses postop,” he says. “The use of high-technology lenses in inappropriate candidates who have underlying corneal or retinal diseases can be another problem. Informed consent and tempering patient expectations is important preoperatively.”

Mr. Tiemeier says you should emphasize to your staff that every patient is different, even though the procedures are all the same. “Lack of awareness of the unique findings, characteristics and care plans of each patient is especially a problem when it shows up in the electronic health records,” he says. “Because of time constraints, your staff may pre-populate these records without much thought before the patient even walks into the room,” he notes. “Often things that should be changed are not. I don’t believe I’ve tried a case in three years without the electronic health records being at least part of the trial. Typically, the problem is caused by a carry-forward function conveying information from a previous exam that the technician hasn’t deleted. For example: The record says, ‘Discussed risks benefits and alternatives with the patient.’ That’s great if it appears prior to surgery. When it appears in the records for a visit after the surgery and the visit after that and the visit after that, the jury starts wondering if the surgeon ever actually had that conversation or if this was just the record being pre-populated with those words every time the patient visited the practice. That creates a credibility problem that can undermine the defense of the surgeon.”

*(Continued on p. 65)*



# A VISION THAT INSPIRES YOU



The New & Easy to Use  
**EFC-2600**  
FUNDUS CAMERA

Fully Automatic  
Mosaic Visualization  
Anterior & Posterior Segment  
45°-100° Degree Angle Visual Field

**12** MEGA  
PIXELS

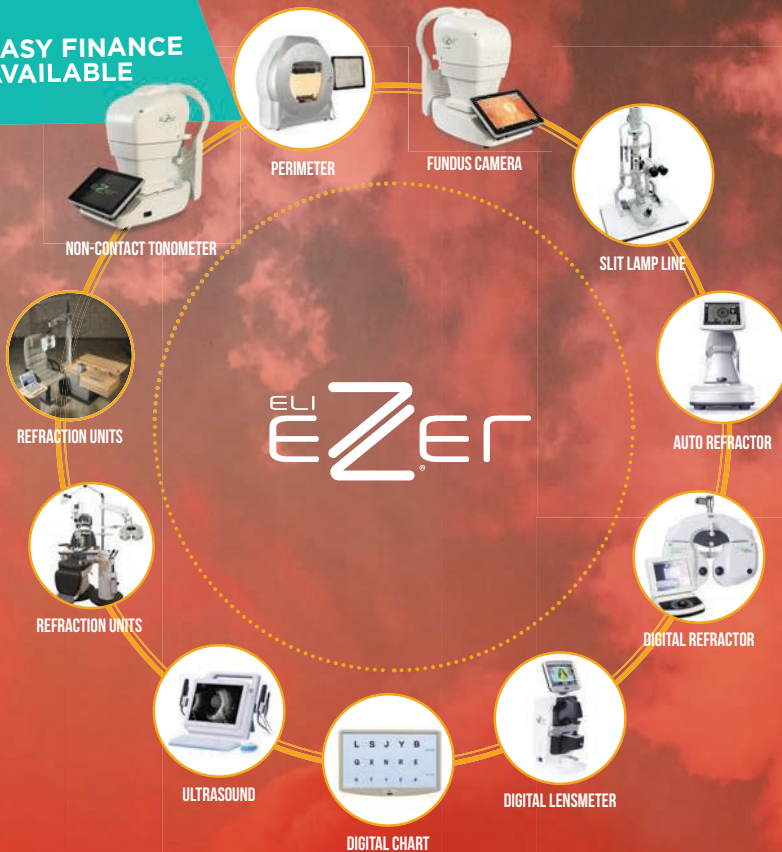
A TEAM BY YOUR SIDE

SATISFACTION GUARANTEED

FROM ONE INDEPENDENT OWNER TO ANOTHER

WE CARE FOR OUR COMMUNITY

**\$** EASY FINANCE  
AVAILABLE



## EZER OPHTHALMIC LINE

*The Ezer Way of Life*

CONTACT US FOR INFORMATION

[WWW.USOPHTHALMIC.COM](http://WWW.USOPHTHALMIC.COM) | PH: 1.888.881.1122  
[INFO@USOPHTHALMIC.COM](mailto:INFO@USOPHTHALMIC.COM)

Follow Our Social Media Channels @USOPHTHALMIC



9990 NW 14th Street, Unit #105, Doral, FL 33172 | USA



**SCAN TO SEE MORE!**

Read all the features and benefits  
this item has to offer by connecting to  
our page.

While you're there, don't forget to  
**Request A Virtual Demo Online!**



# What's New for 2021

*The new codes, changes and quality-of-care requirements you need to know about to be prepared for the year to come.*

**T**his year some new eye-care CPT codes went into effect on January 1, 2021. Though there aren't as many new codes as in years past, they're important. (As always, be sure and use codes and their related guidelines in effect for that date-of-service [DOS]).

In this installment of Medicare Q&A, we'll review the new 2021 eye-care CPT codes and some of the key things to know about them. We'll also discuss the (actual) final Medicare Physician Fee Schedule (MPFS) changes as those are significant too.

**Q What are the CPT Category I code changes that went into effect last month that might affect eye care?**

**A** Regarding exams, as we discussed in a previous article, CMS implemented a new set of rules for office or other outpatient evaluation and management services (9920x, 9921x). The definitions for E/M codes within CPT have been changed to emphasize medical decision-making and to give physicians the option to select a level of service based solely on physician time spent (uncommon for most of eye care). The actual E/M exam code numbers didn't change. Code 99201 has been deleted (but it was rarely, if ever, used by eye doctors anyway). No changes will be made to the requirements for eye codes (920xx). *(For more information on this topic, refer to our column in the November 2020 issue of Review.)*

The "finally final" 2021 MPFS published in early January assigns higher values to E/M codes than the corresponding eye codes, which strongly suggests reversing the traditional preference for eye codes over E/M codes. The differences are most stark on established patients, for whom you may wind up using different codes than you have in the past or with certain payers.

For infrequent situations where the physician spends more time tending to a patient than 60 to 74 minutes (for a new patient) or 40 to 54 minutes (for an established patient), CPT created a new add-on code, +99417, for prolonged services. The code description reads:

- Prolonged office or other outpatient E/M service(s) beyond the minimum required time of the primary procedure which has been selected using total time, requiring total time with or without direct patient contact beyond the usual service, on the date of the primary service, each 15 minutes of total time.

- List separate in addition to 99205, 99215;  
- Do not report 99417 for any time unit less than 15 minutes  
CMS didn't accept CPT's definition for +99417, so they created their own HCPCS code, G2212 instead. The code descriptor is similar but has a significant difference (note the use of the phrase "beyond the maximum" in the description):

- Prolonged office or other outpatient evaluation and management service(s) beyond the maximum required time of the primary procedure which has been selected using total time on the date of the primary service; each additional 15 minutes by the physician or qualified healthcare professional, with or without direct patient contact. (List separately in addition to CPT codes 99205 or 99215 for office or other outpatient E/M services.)

The difference between the two is the starting point for prolonged services. In the Medicare definition, you start only at the "maximum required time" for the primary procedure (level 5 exam). Of course, for Medicare claims, use the Medicare code G2212 instead of 99417.

In terms of other codes, the CPT code for UBM (anterior segment ultrasound 76513) has been revised. It's now a "unilateral or bilateral" code. On 2021 claims for reimbursement, bill it once per patient on a day, and not once per eye as it was billed in 2020.

The section of CPT devoted to remote imaging of retina was thoroughly revised (i.e., 92227, 92228) and appended (i.e., 92229).

- 92227: Imaging of retina for detection or monitoring of disease; with remote clinical staff review and report, unilateral or bilateral;
- 92228: with remote physician or other qualified health care professional interpretation and report, unilateral or bilateral;
- 92229: point-of-care automated

This article has no commercial sponsorship.

Mr. Larson is a senior consultant at the Corcoran Consulting Group and is based in Tucson, Arizona. He can be reached at [plarson@corcoranccg.com](mailto:plarson@corcoranccg.com).

analysis and report, unilateral or bilateral

These codes aren't to be reported on claims in conjunction with other in-office imaging services such as posterior segment OCT or fundus photography.

In the midst of the public health emergency due to COVID-19, CPT created 99072, covering:

- Additional supplies, materials, and clinical staff time over and above those usually included in an office visit or other non-facility service(s), when performed during a Public Health Emergency as defined by law, due to respiratory-transmitted infectious disease.

Medicare treats personal protective equipment (and therefore the code) as an incidental expense and doesn't pay for it separately.

### **Q** What about Category III CPT codes in 2021?

**A** There are new codes for remote imaging with OCT performed at home.

- 0604T: Optical coherence tomography (OCT) of retina, remote, patient-initiated image capture and transmission to a remote surveillance center, unilateral or bilateral; initial device provision, set-up and patient education on use of equipment;
- 0605T: remote surveillance center technical support, data analyses and reports, with a minimum of 8 daily recordings, each 30 days;
- 0606T: review, interpretation and report by the prescribing physician or other QHP of remote surveillance center data analyses, each 30 days

There is also a new code for eye movement analysis for concussion.

- 0615T: Eye-movement analysis without spatial calibration, with interpretation and report

There are three new codes for use when an artificial iris is implanted. While they're each for a specific phakic-or-not status, all three go with the already existing HCPCS code for the related device C1839 (iris implant).

- 0616T: Insertion of iris prosthesis, including suture fixation and repair or removal of iris, when performed; without removal of crystalline lens or intraocular lens, without insertion of intraocular lens;
- 0617T: with removal of crystalline lens and insertion of intraocular lens;
- 0618T: with secondary intraocular lens placement or intraocular lens exchange

There are two new codes to report laser trabeculostomy, with or without endoscopy, a new MIGS procedure currently in clinical trials.

- 0620T: Trabeculostomy ab interno by laser;
- 0621T: with use of ophthalmic endoscope.  
- Do not report in conjunction with 92020.

### **Q** I heard that Omidria (Omeros) still has coverage in 2021. Is that true?

**A** Yes, but it is different in a subtle way. In the final rule for the Outpatient Prospective Payment System (OPPSA), CMS stated that Omidria (J1097) qualifies as of October 1, 2020 for separate payment in ASCs, but is now under the policy for non-opioid pain surgical management.

### **Q** What about ICD-10 in 2021?

**A** New 2021 ICD-10-CM codes went into effect on October 1, 2020. Below is a list of the new and revised codes by chapter in ICD-10-CM for conditions that you might encounter:

- **Chapter 3.** Diseases of the Blood and Blood-Forming Organs and Certain Disorders Involving the Immune Mechanism (D50-D89)  
- D57: Sickle-cell. (Increased specificity)

- **Chapter 7.** Diseases of the Eye and Adnexa (H00-H59)  
- H18.5: Hereditary Corneal Dystrophies (This area includes Fuchs' and some others. All the existing codes in this area gained laterality.)  
- H55.8: Deficient smooth pursuit eye movements. (This is a 4 character code and has no laterality.)
- **Chapter 18.** Symptoms, Signs, and Abnormal Clinical and Laboratory Findings, Not Elsewhere Classified  
- R51: Headache (this can no longer be "just" a 3-character code.)
- **Chapter 19.** Injury, Poisoning and Certain Other Consequences of External Causes (S00-T88)  
- T86.84: Corneal Transplant (Every code in this set gained a 7th character for laterality.)
- **Chapter 20.** External Causes of Morbidity (V00-Y99). These codes are only required on claims if the payer demands them (Medicare does not).  
- Y77.11: Adverse incidents with contact lenses;  
- Y77.19: Adverse incidents with other ophthalmic devices.
- **Chapter 21.** Factors influencing health status and contact with health services (Z00-Z99).  
- Z03.82: Encounter for observation for suspected inserted (injected) foreign body ruled out (Gained laterality).  
- Z88: Allergy status. (Minor changes in wording.)
- **Chapter 22.** Codes for Special Purposes (U00-U85).  
- U07.0: Vaping-related disorders;  
- U07.1: COVID-19 (This code is more specific than existing code B34.2, coronavirus infection, and should be used for SARS-CoV-2 disease only.)

### **Q** What about the physician reimbursement under Medicare for 2021?

**A** The table below has a comparison of 2020 to 2021 national payment rates on some common codes after Medicare published the final physician numbers in early January that included a one-time infusion of billions of dollars and the three-year hold on implementation of the “Complex patient” add-on code G2211 into the system; before these two major changes, eye doctors would have taken a much larger hit.

PAYMENT RATES: 2021 VS. 2020			
CPT	Description	2020	2021
92014	Comprehensive eye exam, established	\$128	\$128
99204	E/M new patient level 4 exam	\$167	\$170
92012	Intermediate eye exam, established	\$90	\$91
99214	E/M established patient level 4 exam	\$110	\$131
92134	OCT retina	\$42	\$42
66984	Cataract surgery w/ IOL	\$557	\$548
92235	Fluorescein angiography of retina	\$106	\$119

The other big potential change is the “Most Favored Nation” drug model for Part B drugs used in the office. It would only affect three of our drugs, Lucentis, Eylea and Botox, but the rule is currently in abeyance due to a court order through at least January 26, 2021. (More to come later in the year.)

**Q For facilities, what are the biggest Medicare changes in 2021?**

**A** For CY 2021, Medicare increased the ASC conversion factor by 2.4 percent. While the Quality Reporting program threatens payment reductions for those not meeting the requirements, they stipulated that no ASCs will get a reduction in 2021 in light of the pandemic. (Few ASCs get the penalty anyway since they meet the Quality requirements.) CMS increased reimbursement for hospital outpatient departments by the same 2.4 percent. Most code payments are pretty flat in 2021, but blepharoplasty (15823), laser PI (66761), iStent/Hydrus (0191T) and cataract/IOL surgery all went up for each facility type.

**Q What about changes to Medicare beneficiaries' obligations and other administrative changes for my office?**

**A** The 2020 Medicare Part B deductible rose to \$203, so you'll need to collect for this greater amount beginning in January. In 2020 this was \$198. For information on the revised Advance Beneficiary Notice of Noncoverage, see the

Medicare Q&A in the September 2020 issue of *Review*.

**Q I have a lot more Part C (Medicare Advantage) patients than ever before and wondered if it's just in my area.**

**A** You're not alone; and signs point to this trend continuing. The Congressional Budget Office estimated that the enrollment will continue to rise to about 51 percent of eligible beneficiaries by 2030.

**Q I just revalidated with Medicare and, when I did, the CMS files didn't reflect the change. Is there something I missed in the new 2021 regulations?**

**A** During the pandemic, CMS hasn't enforced its regulations on revalidation. After the public health emergency (PHE) declaration ends, be sure to check your status again, because deactivations will resume soon afterwards according to Medicare. In the meantime, you can still revalidate as you noted you did, but the site won't reflect your activity. Print and save your finalized recogni-

tion. Remember that failure to revalidate once the PHE ends could result in a hold on your Medicare payments or deactivation of billing privileges.

**Q Are there any significant changes in the Quality Payment Program (QPP) or the Merit-based Incentive Payment System (MIPS) this year?**

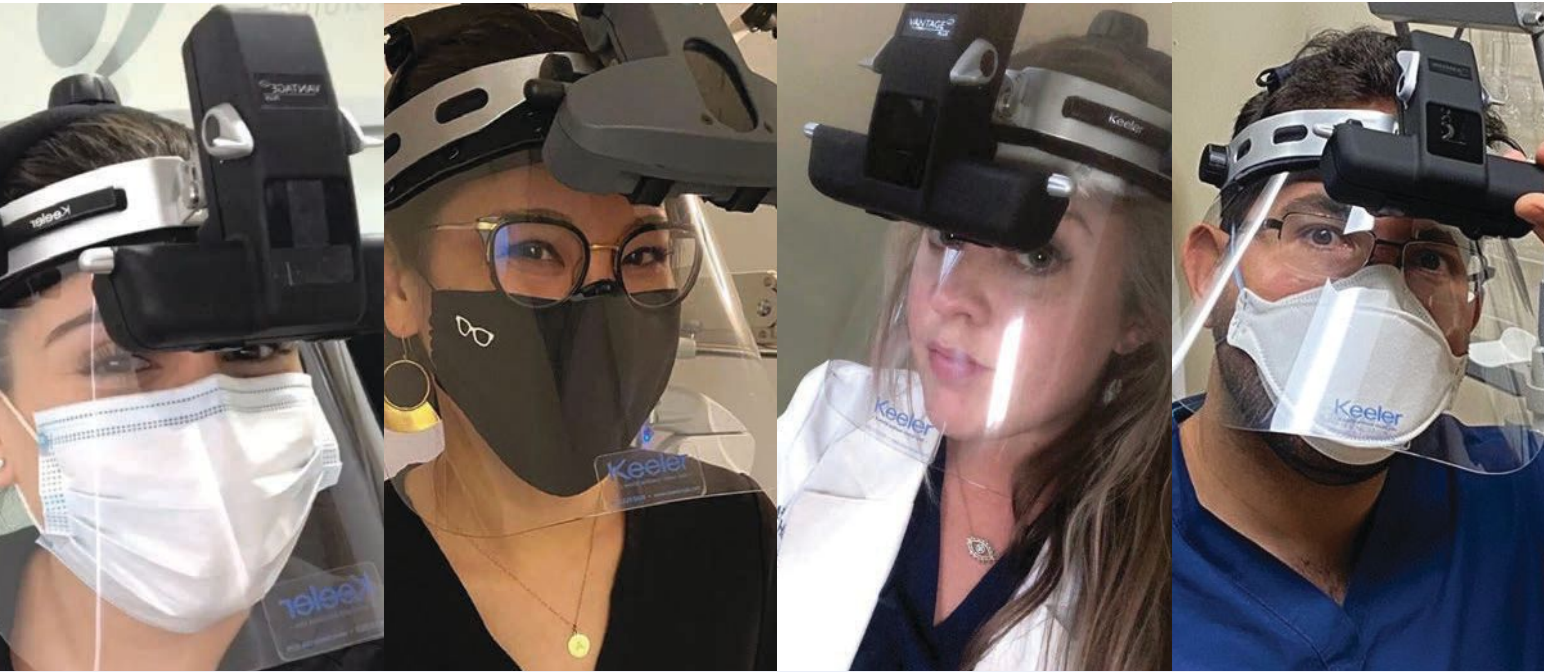**A** Yes, and they're important but mostly related to the scores you need to get.

The QPP continues and there are only modest revisions to the MIPS that most providers use. The maximum negative payment adjustment will remain at 9 percent for the Medicare payments you get in 2023 (from reporting in 2021), although the minimum composite score you need to achieve in order to avoid a penalty has risen a lot, all the way to 60 points from the 45 you needed last year. This change may make it more difficult for providers and practices to earn a bonus. Additionally, if CMS allows another MIPS Hardship exception for COVID-19, there won't be as many penalized. Also, since the MIPS program is designed to be budget-neutral, fewer penalties means those that do well won't get as much as they might otherwise.

Exceptional bonuses remain excluded from this budget-neutral calculation, but providers must achieve 85 points, which is potentially more difficult for cataract surgeons due to the Routine Cataract w/ IOL Implantation cost measure still in effect.

In MIPS, there have been changes in the weighting of the “Quality” and “Cost” measures for 2021. This year, they change from 45 percent for Quality and 15 percent for Cost to 40 percent and 20 percent, respectively. The current regulation has them both becoming 30 percent in 2022, which may make high scores and bonuses even more difficult to get. Last year, CMS put the new MIPS Value Pathways system on hold and has done so again for 2021. ◀

# Helping Heroes See Clear And Stay Safe



The Vantage BIO is great for ROP screening! It's lightweight, has settings for different pupil sizes, a cool, white LED light and the longest battery ever!!"

**Dra. Paulina Ramirez Neria**



I'm a big fan of the All Pupil BIO. I had issues with other models so when I started [my practice], I knew the All Pupil would be my go-to BIO...I greatly appreciate the new custom fit Keeler BIO shields as an added safety layer."

**Dr. Annie Bacon**



I chose my [Vantage Plus] for the optics and value...with other brands, I had difficulty focusing up close during my dilated fundus exams. [The oculars] made my eyes feel more relaxed, and I felt like my view was better."

**Dr. Michelle Hammond**



[I've] been seeing emergent and urgent cases every day during the COVID19 pandemic. I really like [the Vantage BIO] because [it's a] very good quality and provides a super clear view."

**Dr. Reza Moradi**

Choose one of the programs below when you purchase a BIO\* between **September 1, 2020 and March 31, 2021**

\*this program is valid for our wireless indirects: All Pupil II and Vantage Plus

1

RECEIVE A

**\$850**

credit towards any PPE



2

24-MONTH

**0%**

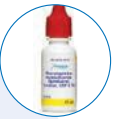lease as low as \$128/month\*

\*All Pupil II: \$127.92/month; Vantage Plus: \$155/month (shipping and taxes not included).

3

RECEIVE

**10 FREE**  
bottles of phenylephrine  
2.5%, 15mL



**\*Leasing may also be combined with the PPE credit OR the phenylephrine option.**

Contact us at 800-523-5620 or [customerservice@keelerusa.com](mailto:customerservice@keelerusa.com) to learn more or place your order. This promo cannot be combined with any other Keeler offers.

**Keeler**  
— A world without vision loss —

www.keelerusa.com • 3222 Phoenixville Pike - Bldg. #50 • Malvern, PA 19355  
Tel No: 1-610-353-4350 • Toll Free: 1-800-523-5620 • Fax: 1-610-353-7814

  
A Halma company



# WHICH MIGS FOR WHICH PATIENTS?

Type of glaucoma, disease severity, patient age, eye size and other factors all may influence your choice.

BY CHRISTOPHER KENT  
SENIOR EDITOR

**W**ith additional MIGS options for treating glaucoma appearing every year or two, it's becoming more of a challenge to decide which ones are worth adding to your surgical armamentarium—not to mention which one is most appropriate for a given patient. These questions are complicated by somewhat limited information about efficacy, especially in terms of one option versus another.

Ronald L. Fellman, MD, who practices at Glaucoma Associates of Texas and is an adjunct clinical professor of ophthalmology at North Texas Eye Research Institute and clinical associate professor emeritus at the University of Texas Southwestern Medical Center in Dallas, points out that a good way to think about the categories of MIGS procedures is to look at the outflow pathway they enhance (or create). “Right now,” he says, “the two main pathways are the conventional outflow pathway—the trabecular meshwork and Schlemm’s canal—and

the subconjunctival pathway, using devices like the Xen and the PreserFlo, which is coming soon. Creating a pathway into the suprachoroidal space is another option, but with the CyPass no longer available, that’s off the table.” In addition, many surgeons consider cyclophotocoagulation of the ciliary processes, which reduces aqueous production, to be one of the MIGS procedures.

Here, surgeons with extensive MIGS experience share their insights about deciding which MIGS is the best choice for a given glaucoma patient, and offer some thoughts regarding how many options an ophthalmologist might want to have in his or her armamentarium.

## The Canal-based MIGS

“Most MIGS are currently done in conjunction with cataract surgery,” notes Robert J. Noecker, MD, MBA, who practices at Ophthalmic Consultants of Connecticut and is an assistant clinical professor of ophthalmology at Yale and a full clinical professor at Quinnipiac University in Hamden, Connecticut. “That’s partly because procedures like

iStent and Hydrus are only approved for that, and partly because taking out the lens makes more space in the angle, which is beneficial for a lot of these patients as well.

“However, you also have to consider efficacy,” he continues. “More and more we’re seeing that the canal-based procedures like iTrack or Omni are helpful; in my experience, we get a little more efficacy when we do those procedures than when we just pop in a Hydrus or iStent. I see these as the next step up on the efficacy curve, before we give up on the angle structure and do a transscleral procedure like a Xen or the upcoming PreserFlo, or a trabeculectomy.”

“Which MIGS is more efficacious is a more difficult question to answer, because the evidence supporting them isn’t the same,” notes Brian E. Flowers, MD, who practices at Ophthalmology Associates in Fort Worth, Texas. “Some have much more robust quality data behind them than others. The ones with more supporting research can make claims about what they can do for the patient in much more precise

This article has no commercial sponsorship.

Dr. Noecker reports financial ties to BVI, Nova Eye Medical, Glaukos, Allergan, Santen, IOP Inc, Sight Sciences and Ivantis. Dr. Fellman is a consultant for Beaver-Visitec, Alcon, Sanoculis and Olleyes. Dr. Flowers has consulting relationships with Alcon, Glaukos, Ivantis, Sight Sciences and InnFocus.

fashion. Clinical trials are currently underway to try to determine the level of efficacy for Omni, but nothing's been published yet. The Kahook Dual Blade doesn't have any level-one randomized clinical trial evidence of its efficacy. On the other hand, the iStent Inject and the Hydrus both have high-level clinical evidence of their efficacy."

Dr. Fellman agrees that deciding between MIGS can be tough because of the limited comparative data. "For example, we don't know if it's better to bypass the trabecular meshwork, cleave open the trabecular meshwork, viscodilate the trabecular meshwork or put in a scaffold to prop open the canal," he says. "No study has compared all of those approaches in patients with mild, moderate and advanced glaucoma.

"The other problem is that the current FDA pathway for device approval in the canal space only involves eyes that have early to moderate glaucoma," he continues. "These eyes are very different from eyes with advanced disease. That confounds a lot of ophthalmologists who are trying to decide the best thing to do for a patient; we don't know how effective a MIGS will be in patients with different stages of glaucoma.

"It's understandable that the studies were done that way," he adds. "If you want to know whether something's going to work in the canal, you don't start by testing it on the worst cases. But it leaves a host of questions unanswered."

### Subconjunctival MIGS

"The great thing about the subconjunctival MIGS devices is that they control the amount of aqueous coming out of the anterior chamber, so that it's just enough during the early postoperative period to leave the patient with an IOP of 8 to 10 mmHg," says Dr. Fellman. "In addition, they make it possible to do filtration surgery under topical anesthesia with a minimally invasive technique.



All images: Robert J. Noecker, MD

**The Hydrus Microstent (Ivantis) stents open Schlemm's canal, helping aqueous to reach multiple outflow channels.**

That's a game-changer for many patients—especially the elderly, who can have a more rapid visual recovery with a topical anesthetic, are at less risk of bleeding while on blood thinners, and may avoid other potential complications.

"I think many comprehensive ophthalmologists are doing some type of canal-based surgery," he continues. "Glaucoma specialists are using Xen, but I'm not sure about comprehensive ophthalmologists. Using the Xen means creating a bleb, and most comprehensive ophthalmologists don't want to be bleb-ologists.

"In any case," he says, "the subconjunctival MIGS like Xen tend to be reserved for patients with more advanced disease, for at least two reasons. First, we assume the collector channels are not very salvageable by the time the disease has become advanced. Second, even if the collector channels are working, studies have shown that when you open up Schlemm's canal 360 degrees, 50 percent of the outflow resistance is still present. That's why, no matter what kind of MIGS you do in the canal, the average pressure is still about 16 mmHg, not 12. That's not low enough for some patients who have advanced disease."

This raises a question: If you're going through the sclera, why not just do a trabeculectomy? "A trabeculectomy is a brutal procedure," Dr. Noecker points out. "For better or worse, we're chopping a hole into

the eye. That tissue is never normal after that. The eye gets rather inflamed and the postoperative course is very unpredictable.

"I'd say the worst thing that can happen with a Xen is that it could fail," he continues. "In my hands, Xen patients don't get extreme hypotony. If you use the *ab interno* approach, they don't need sutures. They're very unlikely to get a leak. These are things we have to look out for all the time after a trabeculectomy. The Xen allows us to rehabilitate the patient more quickly; they can usually go back to work in a week. With a trabeculectomy, that's unlikely. The bottom line is that a Xen is a safer, less-invasive thing to do, and it can work as well as a trabeculectomy—although there's a higher risk of failure because it's a lower-flow system."

### Cyclophotocoagulation

"Technically, endoscopic cyclophotocoagulation could be considered the first MIGS," says Dr. Flowers. "However, it has a higher risk profile than the Schlemm's canal-based procedures because it causes some inflammation and has a longer visual recovery. I tend to use ECP more in cases of advanced glaucoma, although not every surgeon does."

Dr. Flowers notes that the amount of ECP treatment makes a difference in its efficacy. "I've performed ECP long enough to know that if you really want a meaningful response, you have to treat pretty heavily," he explains. "When you do treat more thoroughly, vision recovery is a little slower because there's some inflammation; in fact, it may take four weeks to recover the expected level of vision. I know that many surgeons only treat up to 270 degrees—a sort of 'ECP light' treatment. We don't have good evidence to show that the long-term effect of that is greater than the effect of cataract surgery alone."

Dr. Flowers also points out the evidence supporting adding ECP



to cataract surgery could be better. “There’s never been a prospective, randomized trial comparing cataract surgery alone to cataract surgery plus ECP,” he says. “Without that, you really don’t know how much added effect you’re getting from the ECP. The biggest trial I’m aware of was done by Stan Burke, MD, several years ago. It wasn’t randomized, but it was a large study with a lot of patients. Essentially, he found no difference between cataract surgery alone and cataract surgery plus ECP during the first three years postop. However, after three years the gain seen from the cataract surgery started to wear off, while the benefits of ECP didn’t wear off as much.

“ECP is definitely a tool in the armamentarium—possibly an underutilized tool—and I do use it in some cases,” Dr. Flowers concludes. “It clearly works; how much effect it has, and how many degrees of treatment is most appropriate is harder to answer. I do see a potentially bright future using ECP combined with other outflow MIGS procedures.”

### Anatomic Issues to Consider

When choosing a MIGS procedure for a given patient, it’s worth considering the anatomic structure of the eye, the type of glaucoma you’re trying to manage and patient-related concerns. In terms of anatomic issues, the two main factors to consider are the narrowness of the angle and the size of the eye.

#### • *The narrowness of the angle.*

“Outside of average POAG patients, patients with angles that aren’t completely open are the most common ones we encounter,” says Dr. Noecker. “If you’re going to put an iStent or Hydrus in the eye, you want to make sure the angle is open. Both procedures are only approved for use in combination with cataract surgery, which in some ways makes things a little easier, because the cataract surgery will tend to open the angle a bit.”

Dr. Flowers agrees that the impact

of a narrow angle is mitigated by whether or not you’re performing MIGS alone or in conjunction with cataract surgery. “Once you’ve done cataract surgery, the angle’s more open; then it’s not hard to perform any of the angle procedures,” he says. “If you’re talking about doing a standalone procedure without cataract surgery, you still have a few options that will be covered by insurance such as Omni and KDB, but those could be more difficult to do in a narrow angle.”



**The Kahook Dual Blade, or KDB (New World Medical) is used to create an *ab interno* goniotomy with minimal surrounding tissue damage.**

“In some cases the angle is partially closed and there are synechiae, so access to the angle isn’t great,” Dr. Noecker continues. “You can try to address that by doing something like ECP, which isn’t affected by the condition of the angle. Or, you can perform synechialysis in combination with the MIGS, or do a goniotomy-type procedure; ripping the trabecular meshwork open also removes any adhesions that are there. On the other hand, you can’t do canaloplasty and viscocanalostomy if synechiae are present.

“If it’s a young patient who’s going to remain phakic, I wouldn’t do any of the angle procedures,” he adds. “If they’re going to be pseudophakic, it’s a little bit wait-and-see, because sometimes when you take out the lens the angle opens up pretty nicely, giving you renewed access. Maybe you couldn’t do SLT in the office because the angle was so narrow, but after you remove the

lens you have a much more open angle and that’s an option. On the other hand, if the patient is 30 years old and you want to leave the eye phakic, you’d probably want to do something like a Xen rather than place something in the angle that could later become occluded.”

Dr. Fellman says that whether a narrow-angle patient is a good candidate for a canal procedure such as a GATT (gonioscopy-assisted trans-luminal trabeculotomy) depends on just how narrow and diseased the angle appears gonioscopically. (Dr. Fellman’s practice originated the GATT procedure.) “If the patient has a narrow angle that’s led to chronic angle-closure glaucoma, and you find nerve damage, field loss and PAS, which means the iris has closed off the drain, that patient’s probably not a good candidate for a GATT,” he explains. “If someone has early narrow angle, is post-iridotomy and the angle is still open, then he’s a candidate for a GATT.”


Dr. Fellman notes that one factor that influences his choice about whether to implant a Xen or perform a trabeculectomy is whether the anterior chamber is narrow, along with pupillary block. “When you do a Xen, you don’t do an iridectomy,” he explains. “For that reason, in some patients with narrow angles, extensive PAS, uncontrolled pressure and significant nerve damage, you may favor a traditional trabeculectomy over a subconjunctival MIGS.”

• *The size of the eye.* “In small eyes you want to avoid situations where you have very low pressure, because these eyes can get choroidals and aqueous misdirection pretty easily,” says Dr. Noecker. “That’s one of the advantages of MIGS—hypotony is unlikely to happen, especially with the stents and canal-based procedures. The CyPass had some chance of producing short-term hypotony via increased uveal scleral outflow, but we can’t use that tool any more. The other thing about small eyes is that sometimes



TREAT OCULAR INFLAMMATION  
AND INFECTION, AND...

**TURN ON  
RELIEF**



**TobraDex<sup>®</sup> ST**  
(tobramycin/dexamethasone  
ophthalmic suspension)  
0.3%/0.05%  
FORMULATED WITH **XanGen<sup>™</sup>**

PRESCRIBE TOBRADEX<sup>®</sup> ST to control ocular inflammation with risk of bacterial infection



Rapid relief from blepharitis/  
blepharoconjunctivitis symptoms<sup>1,a</sup>



XanGen<sup>™</sup> suspension technology  
provides increased viscosity  
for improved ocular bioavailability  
of drug and consistent delivery<sup>2</sup>



TOBRADEX ST contains half the  
dexamethasone as TobraDex<sup>®</sup>,  
yet similar ocular tissue exposure<sup>2,b</sup>

Eligible patients could pay as little as \$45 for TOBRADEX ST  
LEARN MORE AT MYTOBRADEXST.COM

## Indications and Usage

For steroid responsive inflammatory ocular conditions of the palpebral and bulbar conjunctiva, cornea, and anterior segment of the globe and chronic anterior uveitis, corneal injury from chemical, radiation or thermal burns, or penetration of foreign bodies for which a corticosteroid is indicated and where the risk of superficial bacterial ocular infection is high or where there is an expectation that potentially dangerous numbers of bacteria will be present in the eye.

## Important Safety Information

### CONTRAINDICATIONS:

Most viral disease of the cornea and conjunctiva including epithelial herpes simplex keratitis (dendritic keratitis), vaccinia, and varicella, and also in mycobacterial infection of the eye and fungal disease of ocular structures. Hypersensitivity to any components of the medication.

### WARNINGS & PRECAUTIONS:

- **IOP increase** – Prolonged use may result in glaucoma with damage to the optic nerve, defects in visual acuity and fields of vision. IOP should be monitored.
- **Aminoglycoside sensitivity** – Sensitivity to topically applied aminoglycosides may occur.
- **Cataracts** – Posterior subcapsular cataract formation may occur.
- **Delayed healing** – May delay healing and increase the incidence of bleb formation. Perforations of the cornea or sclera have occurred. Slit lamp biomicroscopy, and fluorescein staining should be conducted.
- **Bacterial infections** – May suppress host response and increase secondary ocular infections. In acute purulent conditions, steroids may mask infection or enhance existing infection. If signs and symptoms fail to improve after 2 days, the patient should be re-evaluated.

- **Viral infections** – Use with history of herpes simplex requires great caution. The course and severity of many viral infections of the eye (including herpes simplex) may be exacerbated.
- **Fungal infections** – Fungal infections of the cornea may occur and should be considered in any persistent corneal ulceration.
- **Use with systemic aminoglycosides** – Total serum concentration of tobramycin should be monitored.

### ADVERSE REACTIONS:

The most frequent adverse reactions (<4%) to topical ocular tobramycin are hypersensitivity and localized ocular toxicity, including eye pain, eyelid pruritus, eyelid edema, and conjunctival hyperemia.

The reactions due to the steroid component are increased intraocular pressure with possible development of glaucoma, and infrequent optic nerve disorder; subcapsular cataract; and impaired healing.

The development of secondary infection has occurred. Fungal infections of the cornea may occur. Secondary bacterial ocular infection following suppression of host responses also occurs.

Non-ocular adverse events (0.5% to 1%) included headache and increased blood pressure.

**Please see Brief Summary of Full Prescribing Information on the adjacent page.**

<sup>1</sup>Randomized, investigator-masked, active-controlled, parallel-group trial conducted at 7 private practice clinical sites in the United States with 122 adult patients who had moderate to severe blepharitis/blepharoconjunctivitis.<sup>1</sup>

<sup>2</sup>Multicenter, double-blind, parallel-group, single-dose study of 987 patients receiving a single dose of TOBRADEX ST or TobraDex ophthalmic suspension.<sup>2</sup>

**References:** 1. Torkildsen GL, Cockrum P, Meier E, et al. *Curr Med Res Opin.* 2011;27(1):171-178. 2. Scooper SV, Kabat AG, Owen GR, et al. *Adv Ther.* 2008;25(2):77-88.



© 2020 Eyeveance Pharmaceuticals LLC. All rights reserved.  
TOBRADEX<sup>®</sup> ST and XanGen<sup>™</sup> are trademarks of Eyeveance Pharmaceuticals LLC.  
All other trademarks are the property of their respective owners. TST-01-20-AD-04

## **TOBRADEX® ST (tobramycin/dexamethasone ophthalmic suspension) 0.3%/0.05%**

### **Brief Summary**

**This Brief Summary does not include all the information needed to use TOBRADEX ST safely and effectively. Please see Full Prescribing Information for TOBRADEX ST at MyTobraDexST.com.**

### **INDICATIONS AND USAGE**

TOBRADEX ST is a topical antibiotic and corticosteroid combination for steroid-responsive inflammatory ocular conditions for which a corticosteroid is indicated and where superficial bacterial ocular infection or a risk of bacterial ocular infection exists.

Ocular steroids are indicated in inflammatory conditions of the palpebral and bulbar conjunctiva, cornea and anterior segment of the globe where the inherent risk of steroid use in certain infective conjunctivitis is accepted to obtain a diminution in edema and inflammation. They are also indicated in chronic anterior uveitis and corneal injury from chemical, radiation or thermal burns, or penetration of foreign bodies.

The use of a combination drug with an anti-infective component is indicated where the risk of superficial ocular infection is high or where there is an expectation that potentially dangerous numbers of bacteria will be present in the eye.

### **DOSAGE AND ADMINISTRATION**

**Recommended Dosing:** Instill one drop into the conjunctival sac(s) every four to six hours. During the initial 24 to 48 hours, dosage may be increased to one drop every 2 hours. Frequency should be decreased gradually as warranted by improvement in clinical signs. Care should be taken not to discontinue therapy prematurely.

### **CONTRAINDICATIONS**

**Nonbacterial Etiology:** TOBRADEX ST is contraindicated in most viral diseases of the cornea and conjunctiva including epithelial herpes simplex keratitis (dendritic keratitis), vaccinia, and varicella, and also in mycobacterial infection of the eye and fungal diseases of ocular structures.

**Hypersensitivity:** Hypersensitivity to any component of the medication.

### **WARNINGS AND PRECAUTIONS**

**IOP increase:** Prolonged use of corticosteroids may result in glaucoma with damage to the optic nerve, defects in visual acuity and fields of vision. IOP should be monitored.

**Aminoglycoside sensitivity:** Sensitivity to topically applied aminoglycosides may occur.

**Cataracts:** May result in posterior subcapsular cataract formation.

**Delayed healing:** May delay healing and increase the incidence of bleb formation after cataract surgery. In those diseases causing thinning of the cornea or sclera, perforations have been known to occur with the use of topical steroids.

**Bacterial infections:** May suppress the host response and thus increase the hazard of secondary ocular infections. In acute purulent conditions, steroids may mask infection or enhance existing infection. If signs and symptoms fail to improve after 2 days, the patient should be re-evaluated.

**Viral infections:** Treatment in patients with a history of herpes simplex requires great caution. Use of ocular steroids may prolong the course and may exacerbate the severity of many viral infections of the eye (including herpes simplex).

**Fungal infections:** Fungal infections of the cornea are particularly prone to develop with long-term use. Fungal invasion must be considered in any persistent corneal ulceration.

**Use with systemic aminoglycosides:** Use with systemic aminoglycoside antibiotics requires monitoring for total serum concentration of tobramycin.

### **ADVERSE REACTIONS**

The most frequent adverse reactions to topical ocular tobramycin (TOBREX®) are hypersensitivity and localized ocular toxicity, including eye pain, eyelids pruritis, eyelid edema, and conjunctival hyperemia. These reactions occur in less than 4% of patients. Similar reactions may occur with the topical use of other aminoglycoside antibiotics.

Non-ocular adverse events occurring at an incidence of 0.5% to 1% included headache and increased blood pressure.

The reactions due to the steroid component are: increased intraocular pressure (IOP) with possible development of glaucoma, and infrequent optic nerve disorder; subcapsular cataract; and impaired healing.

Secondary Infection.

The development of secondary infection has occurred. Fungal infections of the cornea are particularly prone to develop with long-term use. Fungal invasion must be considered in any persistent corneal ulceration. Secondary bacterial ocular infection following suppression of host responses also occurs.

### **USE IN SPECIFIC POPULATIONS**

#### **Pregnancy and Nursing Mothers**

There are no adequate and well controlled studies in pregnant women. TOBRADEX® ST ophthalmic suspension should be used during pregnancy only if the potential benefit justifies the potential risk to the fetus. Caution should be exercised when TOBRADEX® ST is administered to a nursing woman.

**Pediatric Use:** Safety and effectiveness in pediatric patients below the age of 2 years have not been established.

**Geriatric Use:** No overall differences in safety or effectiveness have been observed between elderly and younger patients.

#### **Rx Only**

**Distributed by:** Eyevance Pharmaceuticals LLC.  
Fort Worth, TX 76102





the anterior segment is kind of crowded, and that might make us avoid implanting a stent; it could be occluded simply because there's not a lot of space in there. But this is one reason I like MGS; in some ways we're not as limited when choosing the best option for the patient.

"On the other hand, highly myopic eyes are good candidates for MGS procedures, because higher-flow surgeries like trabeculectomies sometimes cause them to develop hypotony maculopathy, and they don't bounce back," he continues. "As a first-line option, I think any of the MGS procedures are reasonable in those eyes."

Dr. Flowers says if he's choosing between non-penetrating MGS, the only eye-size-related factor he sees as possibly having an impact is the formation of PAS. "I've done enough implants like iStent and Hydrus to see some PAS form around them," he notes. "I can't provide hard evidence that this would be more likely to happen in a small eye than a large eye, but it would stand to reason.

"In general, I don't believe the size of the eye affects the functioning of the Hydrus, because it works via multiple mechanisms," he continues. "Even if the distal lumen is partially obstructed, the device is still dilating and stenting open the angle and creating flow across septae. On the other hand, if you cover up an iStent completely, it's possible it won't work anymore.

"In the end, PAS probably affects all of these implants to some extent, but I'm not sure this would be significantly different in a small eye than in a large eye," he concludes. "However, with large eyes, you may want to look to other options prior to considering a penetrating procedure like the Xen."

### The Type of Glaucoma

There's scarce published evidence suggesting that one MGS might be better than another when managing a given type of glaucoma. Neverthe-

less, many surgeons say they may adjust their choice based on the conditions associated with the specific type of glaucoma being addressed.

**“In the end, PAS probably affects all of these implants to some extent, but I’m not sure this would be significantly different in a small eye than in a large eye.”**

**—Brian E. Flowers, MD**

• **Pseudoexfoliation or pigmentary glaucoma.** "I think it's reasonable to treat these patients the same way we treat primary open-angle glaucoma patients, with the understanding that the prognosis may be a little bit worse," says Dr. Noecker. "The problems arise with these patients if we don't intervene early and the patient starts to have a more aggressive form of the disease. If we do intervene early enough, I don't believe the outcome will be much different than what you'd expect with a POAG patient.

"While these patients are usually myopes with deep angles, some of them have iris adhesions," he adds. "In that situation I'd lean toward doing a goniotomy-type procedure, to maybe facilitate putting an angle stent in. In fact, I might do that to open the angle more even if it's not possible to put a stent in."

• **Neovascular glaucoma.** "Active neovascular disease is best treated with either cyclophotocoagulation done via micropulse or ECP, or by putting in a tube shunt—or both," notes Dr. Noecker. "If it's inactive neovascular disease and there are some synechiae left behind, the angle may be scarred without hope of re-establishing trabecular flow. But if the angle isn't completely closed, and it's early in the disease course, you can try to open the angle back up and hopefully get some kind of

access to the trabecular meshwork."

Dr. Fellman says that microinvasive surgeries tend not to be helpful in neovascular glaucoma. "In these glaucomas, where you have significant breakdown of the blood/aqueous barrier, microinvasive surgery doesn't work," he says. "Those patients are better off having a traditional drainage implant surgery with a shunt such as the Ahmed, Baerveldt, Molteno or ClearPath."

• **Congenital/juvenile glaucoma.** "In many cases these patients have peripheral adhesions or many iris processes in the angle," says Dr. Noecker. "If we can open those up, these patients can do pretty well. In these cases you might want to do a goniotomy, either by itself or in conjunction with a stent."

"We've learned that younger patients do extremely well with GATT," adds Dr. Fellman. "This includes infants and patients up to their 40s who've had glaucoma for many years.

"It's well-known that infants with primary congenital glaucoma do well with a 360-degree trabeculotomy," he continues. "One reason for that is secondary canalogenesis, which is a reformation of the canal after trabeculotomy that typically occurs in patients less than a year old. They have a success rate of close to 90 percent, which is better than any other glaucoma procedure. The success rate in juvenile glaucoma is slightly less, but still very good. This is probably related to better elasticity in younger outflow systems."

• **Uveitic glaucoma.** "We have a lower expectation of success using MGS in uveitic glaucoma patients," says Dr. Noecker. "We're less likely to get the patient off of all medications and achieve physiologic target pressure. At the same time, these patients may begin to hyposecrete and develop hypotony. But certainly if the eye has a bunch of adhesions and synechiae, we're going to get away from stents. We may put in a Xen or perform a more traditional



glaucoma surgery such as a tube shunt. We'd avoid ECP or micro-pulse, because they induce more inflammation and the outcome is more unpredictable.

"The biggest question is, will the procedure do enough?" he continues. "Uveitic glaucoma is hard to treat with any approach. A patient with a lot of synechiae or adhesions as a result of the inflammation probably has low-grade iritis and could be a steroid responder. But if the angle is still pretty open, I think it's worth trying our typical algorithm. On the other hand, as you get more into the severe patients, where the disease is still active, many patients will be steroid responders. You can get caught in a situation where you need to treat their inflammation, but treating it with steroids makes their IOP go up. That's often what prompts us to do surgery."

"If a patient has preop inflammation, by definition you have a breakdown of the blood-aqueous barrier," Dr. Fellman notes. "Inflammation means that your anterior segment is revved up and may close off whatever you do. Eyes that have a breakdown of the blood-aqueous barrier are more likely to bleed and have fibrin that will block a micro-stent, so those eyes tend to do better with classic drainage implants where the inner lumen is pretty big compared to a microshunt. That's why, if there's a lot of preop inflammation, I tend to shy away from doing subconjunctival MIGS such as a Xen.

"If your patient tends to have controlled inflammation and the surgeon is committed to canal-based MIGS, you want to choose a MIGS procedure that causes the least amount of breakdown of the blood-aqueous barrier," he continues. "You're more likely to get inflammation if the patient has bleeding, as happens with a GATT procedure, than from a minimal trabeculotomy like that created with a Trabectome or Kahook Dual Blade. So you want to tailor your procedure based on how much



**The Omni Surgical System (Sight Sciences) is designed for catheterization of Sclemm's canal, followed by viscodilation and a trabeculotomy.**

inflammation the patient has preop and how much you expect postop.

"Fortunately," he adds, "inflammation isn't a long-term issue with MIGS procedures, if they're performed correctly."

### Other Considerations

Other factors that could influence a surgeon's choice of MIGS include:

- **Previous surgery.** "If the patient has previously had cataract surgery, that usually means we won't be doing an iStent or Hydrus—although there are exceptions," says Dr. Noecker. "In fact, such a patient may already have an iStent or Hydrus in the angle. Our next option is a canal-based procedure. The most benign one to do is an iTrack—an *ab interno* canaloplasty/viscocalotomy. We could also use the Omni system or do a goniotomy-based procedure like the Kahook Dual Blade.

"If the patient had other types of prior surgery, such as retinal detachment surgery, we won't do a Xen because the conjunctiva is probably scarred," he adds. "It might be worth trying a canal-based procedure, but I'd have a low threshold for putting in a tube."

Dr. Fellman notes that GATT is a good option for patients who've already had a tube or trabeculectomy. "You can still go back and open up the natural trabecular outflow system

quite successfully in these eyes," he says. "We've been surprised how well these eyes do with GATT."

- **The patient's ability to return for follow-up.** Dr. Noecker says he doesn't worry about how many years a patient may have left to live. "An older patient may live many more years, no matter what age they are," he points out. "However, you might worry about their ability to return to the office for follow-up. If the patient's going to have a hard time returning, that's where we lean toward doing a MIGS. A transscleral micropulse may be a good option because the postop care is pretty limited. There's no risk of infection.

"As is often true with glaucoma surgery, the hardest part isn't doing the surgery, it's troubleshooting postop," he adds. "You have to set yourself up for postop success. For example, if you do a Xen, you have to see the patient postop to watch out for scarring and maybe apply additional mitomycin-C. If the patient can't manage that, then the surgery is probably going to fail."

- **The patient's fears and expectations.** Dr. Fellman notes that another issue when choosing which MIGS to perform is the patient's perception of the surgery and what information they've read on the internet. "This generates anxiety and sometimes impractical expectations," he explains. "So, you have to tailor your choice of procedure not only to the patient's level of disease and anatomy, but also to their anxiety about the procedure.

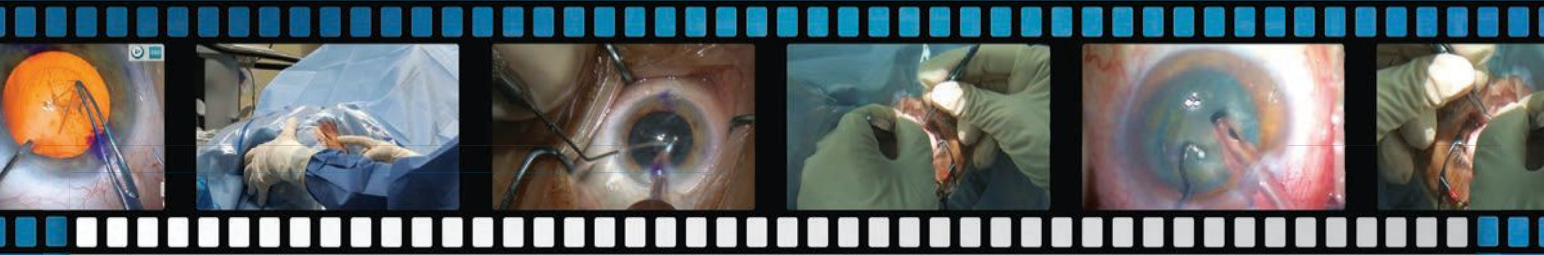"If you're not inclined to do subconjunctival MIGS and you're faced with a patient whose disease is more advanced, you can still offer a canal-based MIGS," he notes. "You'll have to make sure the patient understands that there will still be a lot of inherent resistance left in the canal system, and that a canal-based MIGS may not be sufficient to prevent further visual field damage, requiring a more aggressive subconjunctival procedure later."



Monthly

# MACKOOL ONLINE CME

## CME SERIES | SURGICAL VIDEOS



To view CME video  
go to:

[www.MackoolOnlineCME.com](http://www.MackoolOnlineCME.com)

### Episode 62: "Traumatic Subluxated Cataract"

Surgical Video by:  
Richard J. Mackool, MD

#### Video Overview:

Blunt trauma has caused a subluxated cataract with vitreous prolapse. Phacoemulsification with insertion of 2 capsule tension rings, one of them sutured to the sclera, are demonstrated.

## MackoolOnlineCME.com MONTHLY Video Series



Richard J. Mackool, MD

We are excited to continue into our sixth year of Mackool Online CME. With the generous support of several ophthalmic companies, I am honored to have our viewers join me in the operating room as I demonstrate the technology and techniques that I have found to be most valuable, and that I hope are helpful to many of my colleagues. We continue to edit the videos only to either change camera perspective or to reduce down time - allowing you to observe every step of the procedure.

As before, one new surgical video will be released monthly, and physicians may earn CME credits or just observe the case. New viewers are able to obtain additional CME credit by reviewing previous videos that are located in our archives.

I thank the many surgeons who have told us that they have found our CME program to be interesting and instructive; I appreciate your comments, suggestions and questions. Thanks again for joining us on Mackool Online CME.



**CME Accredited Surgical Training Videos Now Available Online:** [www.MackoolOnlineCME.com](http://www.MackoolOnlineCME.com)

Richard Mackool, MD, a world renowned anterior segment ophthalmic microsurgeon, has assembled a web-based video collection of surgical cases that encompass both routine and challenging cases, demonstrating both familiar and potentially unfamiliar surgical techniques using a variety of instrumentation and settings.

This educational activity aims to present a series of Dr. Mackool's surgical videos, carefully selected to address the specific learning objectives of this activity, with the goal of making surgical training available as needed online for surgeons motivated to improve or expand their surgical repertoire.

#### Learning Objective

*After completion of this educational activity, participants should be able to:*

- present complex techniques that can be used to remove a dislocated cataract while preserving the lens capsule for IOL implantation.

**Satisfactory Completion** - Learners must pass a post-test and complete an evaluation form to receive a certificate of completion. You must listen to/view the entire video as partial credit is not available. If you are seeking continuing education credit for a specialty not listed below, it is your responsibility to contact your licensing/certification board to determine course eligibility for your licensing/certification requirement.



JOINTLY ACCREDITED PROVIDER™  
INTERPROFESSIONAL CONTINUING EDUCATION

**Physicians** - In support of improving patient care, this activity has been planned and implemented by Amedco LLC and Review Education Group. Amedco LLC is jointly accredited by the Accreditation Council for Continuing Medical Education (ACCME), the Accreditation Council for Pharmacy Education (ACPE), and the American Nurses Credentialing Center (ANCC), to provide continuing education for the healthcare team

**Credit Designation Statement** - Amedco designates this enduring material activity for a maximum of .25 AMA PRA Category 1 Credits™. Physicians should claim only the credit commensurate with the extent of their participation in the activity.

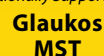
Jointly provided by:



Supported by an unrestricted independent  
medical educational grant from:

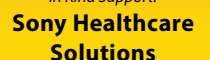


Additionally Supported by:



Crestpoint Management

In Kind Support:



Video and Web Production by:  
JR Snowden, Inc



• **The impact of COVID.** “Unfortunately, the pandemic has made it risky for patients to be in your office,” notes Dr. Fellman. “That means you might want to avoid doing a MIGS procedure that requires a lot of postoperative follow-up, such as a Xen, and lean towards a less-invasive canal-based procedure.”

## The ABCDEF System

Dr. Fellman has laid out a series of points to keep in mind when choosing a MIGS procedure, represented by the mnemonic device: ABCDEF.

“A stands for the angle, which is a good starting point,” he explains. “If you’re thinking about MIGS, look at the angle carefully with your favorite gonioscopy. This will not only help you decide what to do, it will help diagnose the correct type of glaucoma. Also, some angles are fairly complex. You’ll need to be able to identify the angle landmarks well to proceed with canal-based MIGS. ‘A’ can also stand for the patient’s age, and the patient’s level of anxiety, both of which can influence your choice of procedure.

“B stands for the blood-aqueous barrier,” he continues. “If the blood-aqueous barrier is bad for any of 100 reasons, including neovascular glaucoma or trauma or uveitis, you probably shouldn’t do a subconjunctival MIGS. However, you can carefully consider a canal-based MIGS or a classic drainage implant.

“C stands for the conjunctiva,” he says. “If the conjunctiva is scarred badly, then you don’t want to do a subconjunctival MIGS like a Xen because it will probably fail. You typically need virgin conjunctiva for this type of procedure. Unfortunately, today ‘C’ also stands for COVID. You don’t want to do a procedure where you need to see the patient every day, or every other day for postop maintenance, because you’ll expose the patient to more chances to be infected with COVID.

“D stands for the disc,” he continues. “If you have a lot of disc

damage, you have to start thinking more about subconjunctival MIGS, because even if you eliminate all the resistance in the trabecular meshwork, you’ll still have 50 percent of the outflow resistance left. Evolution has designed the outflow system to have multiple checks and balances in it that err on the side of slightly elevated pressure, to avoid hypotony at all costs. That’s why you typically don’t get a pressure of 10 mmHg when you completely open up the canal. The only way to get a larger drop in pressure will be through a subconjunctival MIGS—at least until we have an approved way to access the suprachoroidal space.”

“Unfortunately, the pandemic has made it risky for patients to be in your office. That means you might want to avoid doing a MIGS procedure that requires a lot of postoperative follow-up.

—Ronald L. Fellman, MD

Dr. Fellman points out that one of the reasons some ophthalmologists are skeptical of MIGS is that the canal-based procedures rarely produce a pressure lower than the mid-teens. “Ophthalmologists know that the episcleral venous pressure is about 10 mmHg,” he says. “So, if we bypass the trabecular meshwork or stent open the canal with the Hydrus, why isn’t the result a pressure of 10 mmHg? The problem is, there are many distal collector channels that aqueous has to go through before it gets into the episcleral veins. And, no matter what you do, Mother Nature has set up our eyes to prevent hypotony. So you’re not going to get 10 mmHg; you’re going to get a pressure in the mid-teens.

“Occasionally you can get lower pressures via a canal-based MIGS in a patient with congenital or develop-

mental glaucoma,” he notes. “That’s probably because the elasticity is better, and infant eyes undergo secondary canalogenesis and tend to recreate a more normal drainage system without scar tissue. But as we all know, when you get old, your elasticity goes out the window. Everything gets fibrotic.

“E stands for your level of expertise,” he continues. “What are you comfortable doing? Fortunately, if you decide you’d like to develop your expertise in a MIGS procedure that’s not already part of your armamentarium, you have many avenues of support, from the manufacturers, to online videos, to watching other surgeons do these procedures live.

“F stands for the field,” he concludes. “Whether a canal-based MIGS is sufficient or a subconjunctival option is more appropriate depends in part on how well the patient’s native outflow system is functioning. I find that how well patients are functioning visually correlates better with their visual field than with OCT findings on the disc. Patients who have advanced field loss tend to do better long-term with subconjunctival filtration.”

## Strategies for Success

Surgeons offer these additional suggestions when choosing a MIGS procedure:

• **First, decide what you don’t want to do.** Dr. Fellman says that this is a big part of deciding what you *do* want to do. “After doing surgeries for many years, you learn what makes people get worse and doesn’t work long-term,” he explains. “You don’t want to go down that road (especially in a monocular patient). So I first decide what not to do. That eliminates a lot of options.

“For example, suppose you have a patient on a blood thinner and you can’t stop that drug,” he continues. “You don’t want to do a GATT on that patient because in some people Schlemm’s canal contains a lot of blood. If the patient has a cataract,

you'll be more likely to choose a phaco-iStent, because you'll get the least amount of bleeding; you're bypassing the meshwork instead of cleaving it.

"You have to look at the overall systemic profile of the patient, the patient's level of anxiety and your level of expertise," he concludes. "These factors should all influence how you decide to proceed."

• **Try to leave future options open.**

Dr. Flowers says one factor that influences his choice of MIGS is making sure that any additional surgeries that may need to be done in the future are still feasible. "As a glaucoma specialist I always want to be thinking multiple surgeries ahead," he notes. "Generally speaking, nothing lasts forever. If you do a 360-degree trabeculotomy, the angle's pretty much done. You can't go back and do anything else involving the angle. On the other hand—theoretically at least—if you put in an iStent or Hydrus or perform canaloplasty,

you've only treated part of the angle. You still have more angle you can go back and treat later.

"So looking at Omni going forward, I think a lot of people may end up doing a 360-degree canaloplasty and a 180-degree trabeculotomy," he continues. "That at least leaves you with some angle to work with in the future if you need to do something else. However, it will take some time for the research to show us whether or not that's the right decision.

"Our practice is currently involved in clinical trials of the Omni procedure, as well as a Hydrus study, and we just finished our second iStent Inject study," he adds. "So, people are trying to answer these questions. The point is, when choosing a procedure, you want to be ready for the next thing. You don't want to close any doors."

"One of the nice things about MIGS is that most of them don't destroy future options," Dr. Noecker notes. "If you do a canal-based pro-

cedure, you can still do pretty much anything else after that."

• **Consider combining MIGS.**

Dr. Noecker points out that attacking a problem in more than one way is something ophthalmologists routinely do with glaucoma medications. "Some patients are OK with one medication, while others need a couple of medications to keep the pressure down. I think it's the same concept," he says.

"The risk of adding an extra MIGS procedure isn't that great," he continues. "For example, I might do an iTrack procedure to open up the canal and then put in a Hydrus to hold it open. Or, combine ECP and a stenting or canal procedure. Of course, we never know for sure what will work for an individual patient until we've tried it. But in some ways you're hedging your bets and being a little more aggressive by doing a combined procedure.


*(Continued on p. 66)*

Now introducing

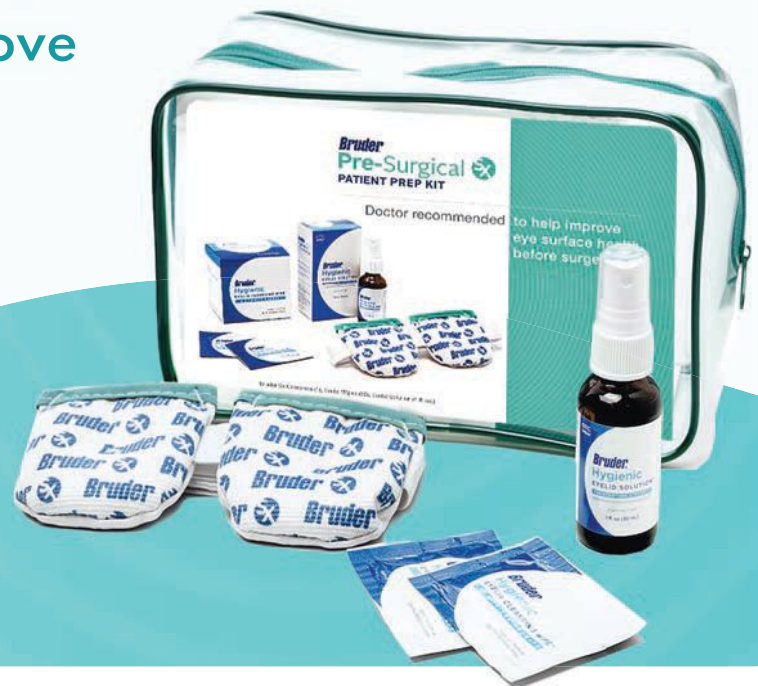## An easy to use pre-surgical prep kit designed to improve patient outcomes

The 3-step Bruder Sx Pre-Surgical Patient Prep Kit is complimentary to any pre-surgical protocol. Available for **in-office distribution** or **patient purchase** by referral online.

"The Bruder Pre-surgical Patient Prep Kit is an easy and affordable way for patients to 'tune up' the ocular surface, minimize post-op discomfort and help prevent infection."



Cynthia Matossian, MD



**Bruder**  
**Pre-Surgical**   
**PATIENT PREP KIT**

Discover what's in the kit and the science behind it at [brudersx.com/rop](https://brudersx.com/rop)

©2021 Bruder Healthcare Company Alpharetta, GA 30004



# RECONCEIVING GLAUCOMA CARE

Minimizing risk, increasing efficiency, streamlining patient flow and ensuring quality of care during the pandemic—and beyond.

BY SEAN MCKINNEY  
SENIOR EDITOR

The U.S. Department of Health and Human Services has extended its COVID-19 public health emergency declaration for a fourth consecutive time, continuing waivers that make telemedicine a bit more practical for ophthalmologists until April 21. But glaucoma specialists say they need more than this flexibility to respond to the ongoing pandemic and prepare for future public health challenges. Because of a reliance on frequent in-office testing, many of them are experimenting with a hybrid of new and borrowed strategies to safely and efficiently manage patient flow.

“The crippling thing about telemedicine for glaucoma care is that it doesn’t enable IOP checks, visual fields and OCT scans that provide the critical information we need to follow,” says Peter Netland, MD, PhD, Vernah Scott Moyston professor and chair of Ophthalmology at the University of Virginia School of Medicine in Charlottesville. “Without that, we’ll risk missing some-

thing important. What doctors are saying when they do home visits is that they’re willing to miss a certain amount of change in the patient’s status. For us, we decided early on, as a glaucoma group, that we were going to try to provide protection for ourselves and our patients through standard, acceptable approaches at the point of care. We tried telemedicine, and we saw we didn’t get all the information we needed to make sure our patients were adequately monitored.”

Although some ophthalmologists are using scaled-down telemedicine to care for glaucoma patients, most are also adapting innovative new approaches. In this article, you’ll learn how detailed pre-visit telephone screening of patients, general medical advice, expanded staff responsibilities, consolidated evaluation-and-surgery visits, public health measures, drive-by pressure checks and visual fields and responsive approaches to fragile and apprehensive elderly patients are keeping glaucoma practices on a firm footing—and how you can incorporate some of these strategies, as needed, into your practice to opti-

mize care of glaucoma patients.

## Expanding Scope of Care

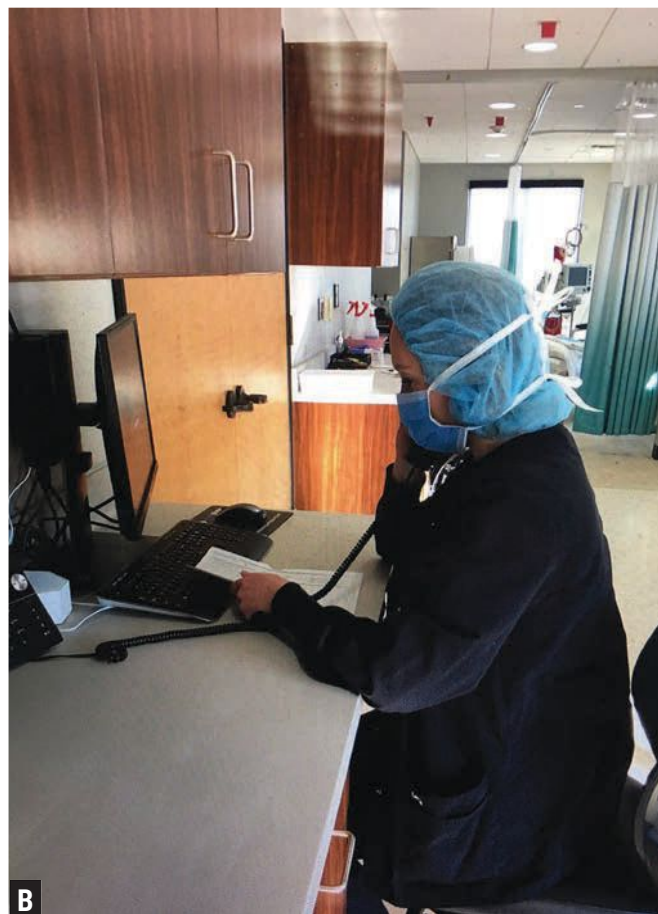
Most glaucoma patients, at the highest risk for COVID-19 infection due to their age, have recently been sheltered for long periods and may have lost friends or loved ones to the virus. When they venture from their homes or long-term care facilities to visit an ophthalmologist, they often fear the unknown as much as COVID-19, according to Brandon Baartman, MD, lead surgeon at Vance Thompson Vision in Omaha, Nebraska. This is one of the central challenges: Caring for patients most in need of a visit to your office, yet most at risk during a visit to your office. Instead of limiting these encounters to three tests, an examination of the eye and a discussion of medications and changes in vision, Dr. Baartman and his fellow specialists find themselves “putting on their general doctor hats” during these visits, he says.

“We find that we need to provide patients with an overview of COVID-19, including the symptoms and risks, and we need to go over other aspects of the virus, such as how and

This article has no commercial sponsorship.

Drs. Netland, Baartman, Ristvedt and Frenkel report no financial relationships with companies that produce products or services related to the comments they offered for this article.





**Figures 1-A and 1-B. At Vance Thompson Vision in Omaha, Nebraska, all hands are on deck as staff and nurses use telephone screening to gather glaucoma patient information usually documented during office visits. The effort has reduced the length of routine visits, increased the number of same-day procedures and, most important, cut down on time spent face-to-face and let the practice schedule more check-ups without crowding the waiting room.**

when to wear a mask,” he notes.

Even before the patient visits the center, the staff at Vance Thompson Vision visits patients’ homes by voice, conducting extensive telephone screenings and beginning patient education and assessments. “Collecting patients’ subjective history over the phone has allowed us to reduce the amount of time patients spend at our center,” says Dr. Baartman. “We can tighten up visits, save time in the pre-testing lanes and reduce clustering. Telephone screening makes sure we have all the information we need, including correct medical history and, in many cases, referring doctors’ notes. It also helps us establish a touch-point ahead of time.”

Like most practices recovering from a one-to-two-month COVID-19 shutdown last spring, the Vision

Center has needed to increase patient volume, not only to meet the lingering needs of patients whose care had been delayed, but also to shore up the center’s bottom line.

“We couldn’t go back to 100 percent right away,” Dr. Baartman notes. “There was a slower ramp-up to our peak. Towards the end of the year, we really needed to take care of a lot of patients. We had to increase our availability, which we did. For example, I went from operating two days a week to three.”

### Same-Day Procedures

Reconceiving glaucoma care in the era of COVID-19 has also meant increased emphasis on a program designed to consolidate evaluations and procedures into single visits at the Vance Thompson Vision Center,

where the focus is on surgery more than the chronic care of glaucoma patients. The result of increased consolidated visits has been more efficiency, contributing to greater safety and efficacy.

“We call this our ‘see-and-do’ program, which has really gained traction,” says Dr. Baartman. “These are the cases in which we’ve traditionally evaluated patients, sent them home and brought them back for surgery. Now, we can combine their evaluations and procedures into one visit, provided we have enough preoperative information from their referring doctors.”

Dr. Baartman adds that the practice has expanded beyond surgery. “We’re also doing more same-day selective laser trabeculectomies, some of which are bilateral SLTs, which have become

a lot more popular,” he notes.

He explains that same-day procedures have evolved into a “practice solidifier” for the center. “It’s been limiting the number of visits—the people coming in and out,” he observes. “See-and-do visits can be tricky to schedule, but they’re really meaningful for our patients and practice.”

### Chronic Care

More than 350 miles from Omaha, Dr. Baartman’s colleague Deborah Gess Ristvedt, MD, provides chronic glaucoma care for “40 years’ worth of patients” in Alexandria, Minnesota. It’s a world away from Dr. Baartman’s setting in terms of adapting to the modern realities of glaucoma care and the COVID-19 environment. “What I’ve had to do is go through every single patient and decide which ones would need to be watched more closely and which ones could be rescheduled for three months out,” Dr. Ristvedt recalls.

While completing this process, she has introduced IOP checks and portable visual fields to the practice parking lot. The IOP checks are made possible by the use of the non-contact iCare tonometer (Raleigh, North Carolina) and the visual fields are recorded on a handheld device called the Virtual Field (New York City). Some patients continue to undergo the tests while remaining in their cars.

“We’re able to use these instruments for patients who are nervous about coming into the office,” says Dr. Ristvedt. “The pressure checks have also been helpful when we want to make sure a patient is still stable, and they’ve enhanced our postoperative management, following MIGS or regular glaucoma surgery.” Checking visual fields in the parking lot has expanded the use of an instrument that’s

Deborah Ristvedt, MD



**Figure 2. To minimize person-to-person contact during COVID-19, patients use the Virtual Field (Virtual Field, New York City) in their cars outside Vance Thompson Vision in Alexandria, Minnesota. The device enables full threshold visual field testing.**

normally used in the office for patients who have disabilities or who struggle to use a regular perimeter.

“The Virtual Field is easy to use and provides accurate visual fields,” Dr. Ristvedt adds. “It’s been ideal for this new setting.”

With her focus trained on chronic care, Dr. Ristvedt has tried to use telemedicine as much as possible. “We’ve noticed that the increased use of telemedicine by primary care physicians has increased the willingness and ability of our patients to give it a try,” she notes. “However, telemedicine is particularly difficult for our patients because most of them are elderly and have a hard time opening our email message, using the screen and following the process involved, including

getting on the computer at the right time. Telemedicine is also very time-consuming.”

Nonetheless, concern that glaucoma patients could possibly not receive optimal treatment, benefit from needed treatment adjustments or, worse, go without treatment has been ever-present in the minds of Dr. Ristvedt and her colleagues. “Not being able to see patients in the way we were used to kind of opened our eyes and forced us to ask ourselves: Are we doing things in the right manner?”

After some deliberation, they decided on a hybrid approach to many patients, bringing them to the office for IOP checks, visual fields and OCT scans that included funduscopic viewing capabilities, enabling a view of the optic nerve. Being able to bill for these key tests, as well as those in the parking lot, has also enabled the practice to earn higher reimbursements that aren’t available through the use of telemedicine alone. After these abbreviated hybrid visits, Dr. Ristvedt says, “we collect the data we need and we follow up with patients by turning to telemedicine. This has really limited the time that patients spend in our office.”

On telemedicine calls, Dr. Ristvedt and her colleagues ensure patients are using drops correctly and don’t have any concerns about their therapy or care. Patients are asked to use a downloadable near card and Amsler grid to help identify changes in visual status. “Telemedicine isn’t going away,” she adds. “It will continue to improve. But for now, this limited approach is the best we can do.”

Dr. Ristvedt says the intracameral injection of bimatoprost SR (Durysta), providing six months or more of treatment without drops, has also been helpful, assuring her and her

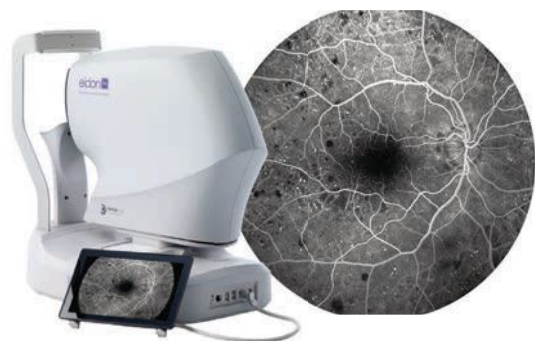# Keeping the world visible for all. Together.



## iCare EIDON FA

Ultra high resolution  
**retinal imaging**

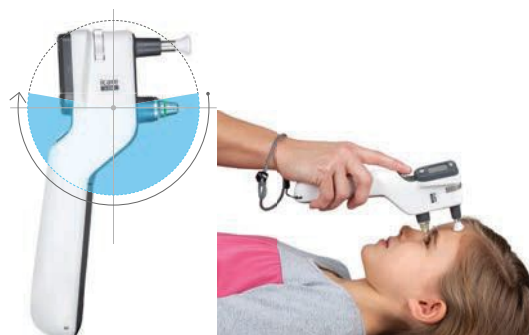- + TrueColor
- + Autofluorescence imaging
- + Wide-field view & ultra high resolution
- + Fluorescein angiography video & imaging



## iCare IC200

200 degrees of  
**tonometry**

- + Supine, elevated & seated operation
- + No corneal disruptions
- + Suitable for every patient
- + Single use probes to exceed infection control guidelines



For more information, scan,  
call 888.422.7313, or email  
[infousa@icare-world.com](mailto:infousa@icare-world.com)  
[www.icare-world.com/us](http://www.icare-world.com/us)

For better perception **icare**

colleagues that patients are continuing to receive treatment, even when they can't be examined in a timely manner. "That implant couldn't have come out at a better time," she says.

Deborah Ristvedt, MD

### Operational Challenges

Ronald Frenkel, MD, a glaucoma and retinal specialist who serves as medical director at East Florida Eye Institute in Stuart, Florida, says COVID-19 continues to present operational challenges, forcing glaucoma specialists to improvise in new ways. Many patients don't schedule or keep appointments because they're afraid of exposure to the virus, forcing his practice to reduce staff hours and manage the budget tightly, in light of reduced revenues. Patients who do come in are sometimes challenging to manage, often taking off their masks before he enters the room to examine them. "I have to tell them not to do that," he says. "We put a sign on the door, but that doesn't always work. Another thing we do is try to minimize the time spent in the exam room with the patient. We'll look at test results away from the patient and then go into the room and explain the results. This adds to the time we need to set aside for each patient, but it increases safety."

Another challenge: Masks usually don't fit perfectly, he says. "One of our biggest issues is the fogging of the diagnostic lenses we're holding up to look at the optic nerve," he continues. "If it's not the diagnostic lens fogging up, it's our own oculars or glasses. The diagnostic lenses help me identify subtle differences on the optic nerve that aren't always picked up by OCT scans or by the fundus camera. You can only use so many wipes or adjust your mask and take so many anti-fogging measures throughout the day. To me,



**Figure 3. Dr. Mathew Walker, OD, of Vance Thompson Vision in Alexandria, Minnesota, demonstrates the use of the portable iCare tonometer (Raleigh, North Carolina) to conduct parking lot IOP checks and minimize potential COVID-19 infection.**

this is a really big problem. I pride myself on being a pretty good diagnostician, but now I know that my exam is being compromised. There are no magic bullets. We just try to adapt to new situations as we go along."

### Adapting Quickly

Most practices have had to adapt quickly and expect to continue to need to do so, especially as their efforts relate to staffing and maintaining a safe environment. Even to this date, practices may be pursuing varying courses of action—possibly failing to optimally manage risk, according to Dr. Netland.

One often-overlooked issue is the potential need to modify your HVAC system, he notes. "If you don't have adequate ventilation in your rooms, air droplets will build up, creating one of

the most significant risks," he says, noting that unidirectional flow ventilation (taking droplets out of the room) or a positive pressure air flow is needed, as opposed to rooms with recirculated air or no circulation. "We're very fortunate because we have clinical engineering people who know the system we have. They also have special devices that measure airflow. If your airflow isn't appropriate, you can mitigate or correct it by adjusting ventilation settings or, for recirculated air, using air filters. If you have to think about upgrading your HVAC, that's a bigger job. But I'd suggest that it might be worth doing."

Dr. Netland is quick to acknowledge that he isn't a public health expert by any measure. "But I feel like I've had to develop public health skills that I've never had before," he says. He recommends minimizing risks in your setting by following COVID-specific guidelines from the U.S. Centers for Disease Control and Prevention ([www.cdc.gov/coronavirus/2019-ncov/index.html](http://www.cdc.gov/coronavirus/2019-ncov/index.html)) and the

American Academy of Ophthalmology ([www.aao.org/coronavirus](http://www.aao.org/coronavirus)). He's also relied on evidence-based approaches for ophthalmologists provided by the University of Pittsburgh<sup>1</sup> and the Hadassah Medical Center in Jerusalem, Israel.<sup>2</sup>

The UVA clinic, where Dr. Netland and his colleagues care for patients, is staffed by more than 150 employees. When he first implemented public health guidelines in April of 2020, almost one quarter of these employees were lost to quarantine. "Losing nearly 25 percent of your work force for two weeks represents a pretty big hit," he points out. "We suddenly didn't have a stable workforce. Since then, we've aggressively managed our patient flow and practice patterns according to the guidelines, and we've had zero quarantines. Following the

# Power and Simplicity of ROCK Inhibition



**Consistent IOP reduction, whether added to a PGA monotherapy or to a combination of therapies<sup>1,2</sup>**

**Only Rocklatan<sup>®</sup> demonstrated superior efficacy over latanoprost in registration trials at all time points<sup>3,4</sup>**

## IMPORTANT SAFETY INFORMATION FOR RHOPRESSA<sup>®</sup>

### WARNINGS AND PRECAUTIONS

**Bacterial Keratitis:** There have been reports of bacterial keratitis associated with the use of multiple-dose containers of topical ophthalmic products. These containers had been previously contaminated by patients who, in most cases, had a concurrent corneal disease or a disruption of the ocular epithelial surface.

**Contact Lenses:** Contact lenses should be removed prior to instillation of Rhopressa<sup>®</sup> and may be reinserted 15 minutes following its administration.

ONCE-DAILY  
**rhopressa<sup>®</sup>**  
(netarsudil ophthalmic solution) 0.02%

## IMPORTANT SAFETY INFORMATION FOR ROCKLATAN<sup>®</sup>

### CONTRAINDICATIONS

None.

### WARNINGS AND PRECAUTIONS

- Pigmentation changes
- Eyelash changes
- Intraocular inflammation
- Macular edema
- Herpetic keratitis
- Bacterial keratitis
- Contact lens wear

ONCE-DAILY  
**rocklatan<sup>®</sup>**  
(netarsudil and latanoprost ophthalmic solution) 0.02%/0.005%

Visit [DISCOVaerieLive.com](http://DISCOVaerieLive.com) to learn more about these innovative IOP-lowering treatments

Please refer to Brief Summary on the reverse side.

*IOP, intraocular pressure; PGA, prostaglandin analog.*



#### BRIEF SUMMARY

Consult the full Prescribing Information for complete product information.

#### INDICATIONS AND USAGE

Rhopressa® (netarsudil ophthalmic solution) 0.02% is indicated for the reduction of elevated intraocular pressure (IOP) in patients with open-angle glaucoma or ocular hypertension.

#### DOSAGE AND ADMINISTRATION

The recommended dosage is one drop in the affected eye(s) once daily in the evening.

If one dose is missed, treatment should continue with the next dose in the evening. Twice a day dosing is not well tolerated and is not recommended. If Rhopressa® is to be used concomitantly with other topical ophthalmic drug products to lower IOP, administer each drug product at least 5 minutes apart.

#### WARNINGS AND PRECAUTIONS

##### Bacterial Keratitis

There have been reports of bacterial keratitis associated with the use of multiple-dose containers of topical ophthalmic products. These containers had been previously contaminated by patients who, in most cases, had a concurrent corneal disease or a disruption of the ocular epithelial surface.

##### Use with Contact Lenses

Rhopressa® contains benzalkonium chloride, which may be absorbed by soft contact lenses. Contact lenses should be removed prior to instillation of Rhopressa® and may be reinserted 15 minutes following its administration.

#### ADVERSE REACTIONS

##### Clinical Trials Experience

Because clinical studies are conducted under widely varying conditions, adverse reaction rates observed in the clinical studies of a drug cannot be directly compared to rates in the clinical studies of another drug and may not reflect the rates observed in practice.

The most common ocular adverse reaction observed in controlled clinical studies with Rhopressa® dosed once daily was conjunctival hyperemia which was reported in 53% of patients. Six percent of patients discontinued therapy due to conjunctival hyperemia. Other common (approximately 20%) ocular adverse reactions reported were: corneal verticillata, instillation site pain, and conjunctival hemorrhage. Instillation site erythema, corneal staining, blurred vision, increased lacrimation, erythema of eyelid, and reduced visual acuity were reported in 5-10% of patients.

##### Corneal Verticillata

Corneal verticillata occurred in approximately 20% of the patients in controlled clinical studies. The corneal verticillata seen in Rhopressa®-treated patients were first noted at 4 weeks of daily dosing. This reaction did not result in any apparent visual functional changes in patients. Most corneal verticillata resolved upon discontinuation of treatment.

**For additional information, please refer to full Prescribing Information at Rhopressa.com.**

**You are encouraged to report negative side effects of prescription drugs to the FDA. Visit [www.fda.gov/medwatch](http://www.fda.gov/medwatch) or call 1-800-1088.**

U.S. Patent Nos.: 8,450,344; 8,394,826; 9,096,569; 9,415,043; 9,931,336



#### BRIEF SUMMARY

Consult the full Prescribing Information for complete product information.

#### INDICATIONS AND USAGE

Rocklatan® (netarsudil and latanoprost ophthalmic solution) 0.02%/0.005% is indicated for the reduction of elevated intraocular pressure (IOP) in patients with open-angle glaucoma or ocular hypertension.

#### DOSAGE AND ADMINISTRATION

The recommended dosage is one drop in the affected eye(s) once daily in the evening.

If one dose is missed, treatment should continue with the next dose in the evening. The dosage of Rocklatan® should not exceed once daily. Rocklatan® may be used concomitantly with other topical ophthalmic drug products to lower IOP. If more than one topical ophthalmic drug is being used, the drugs should be administered at least five (5) minutes apart.

#### CONTRAINDICATIONS

None.

#### WARNINGS AND PRECAUTIONS

##### Pigmentation

Rocklatan® contains latanoprost which has been reported to cause changes to pigmented tissues. The most frequently reported changes have been increased pigmentation of the iris, periorbital tissue (eyelid), and eyelashes. Pigmentation is expected to increase as long as latanoprost is administered.

The pigmentation change is due to increased melanin content in the melanocytes rather than to an increase in the number of melanocytes. After discontinuation, pigmentation of the iris is likely to be permanent, while pigmentation of the periorbital tissue and eyelash changes have been reported to be reversible in some patients. Beyond 5 years the effects of increased pigmentation are not known.

Iris color change may not be noticeable for several months to years. Typically, the brown pigmentation around the pupil spreads concentrically towards the periphery of the iris and the entire iris or parts of the iris become more brownish. Neither nevi nor freckles of the iris appear to be affected by treatment. While treatment with Rocklatan® can be continued in patients who develop noticeably increased iris pigmentation, these patients should be examined regularly.

##### Eyelash Changes

Rocklatan® contains latanoprost which may gradually change eyelashes and vellus hair in the treated eye; these changes include increased length, thickness, pigmentation, the number of lashes or hairs, and misdirected growth of eyelashes. Eyelash changes are usually reversible upon discontinuation of treatment.

##### Intraocular Inflammation

Rocklatan® contains latanoprost which should be used with caution in patients with a history of intraocular inflammation (iritis/uveitis) and should generally not be used in patients with active intraocular inflammation because it may exacerbate inflammation.

##### Macular Edema

Macular edema, including cystoid macular edema, has been reported during treatment with latanoprost. Rocklatan® should be used with caution in aphakic patients, in pseudophakic patients with a torn posterior lens capsule, or in patients with known risk factors for macular edema.

#### Herpetic Keratitis

Reactivation of herpes simplex keratitis has been reported during treatment with latanoprost. Rocklatan® should be used with caution in patients with a history of herpetic keratitis. Rocklatan® should be avoided in cases of active herpes simplex keratitis because it may exacerbate inflammation.

#### Bacterial Keratitis

There have been reports of bacterial keratitis associated with the use of multiple-dose containers of topical ophthalmic products. These containers had been inadvertently contaminated by patients who, in most cases, had a concurrent corneal disease or a disruption of the ocular epithelial surface.

#### Use with Contact Lenses

Contact lenses should be removed prior to the administration of Rocklatan® and may be reinserted 15 minutes after administration.

#### ADVERSE REACTIONS

##### Clinical Trials Experience

Because clinical trials are conducted under widely varying conditions, adverse reaction rates observed in the clinical trials of a drug cannot be directly compared to rates in the clinical trials of another drug and may not reflect the rates observed in clinical practice.

##### Rocklatan®

The most common ocular adverse reaction observed in controlled clinical studies with Rocklatan® was conjunctival hyperemia which was reported in 59% of patients. Five percent of patients discontinued therapy due to conjunctival hyperemia. Other common ocular adverse reactions reported were instillation site pain (20%), corneal verticillata (15%), and conjunctival hemorrhage (11%). Eye pruritus, visual acuity reduced, increased lacrimation, instillation site discomfort, and blurred vision were reported in 5-8% of patients.

Other adverse reactions that have been reported with the individual components and not listed above include:

##### Netarsudil 0.02%

Instillation site erythema, corneal staining, increased lacrimation and erythema of eyelid.

##### Latanoprost 0.005%

Foreign body sensation, punctate keratitis, burning and stinging, itching, increased pigmentation of the iris, excessive tearing, eyelid discomfort, dry eye, eye pain, eyelid margin crusting, erythema of the eyelid, upper respiratory tract infection/nasopharyngitis/influenza, photophobia, eyelid edema, myalgia/arthralgia/back pain, and rash/allergic reactions.

#### DRUG INTERACTIONS

*In vitro* drug interaction studies have shown that precipitation can occur when eye drops containing thimerosal are mixed with Rocklatan®. If such drugs are used, they should be administered at least five (5) minutes apart.

The combined use of two or more prostaglandins or prostaglandin analogs including latanoprost ophthalmic solution 0.005% is not recommended. It has been shown that administration of these prostaglandin drug products more than once daily may decrease the IOP lowering effect or cause paradoxical elevations in IOP.

**For additional information, refer to the full Prescribing Information at Rocklatan.com.**

**You are encouraged to report negative side effects of prescription drugs to the FDA. Visit [www.fda.gov/medwatch](http://www.fda.gov/medwatch) or call 1-800-FDA-1088.**

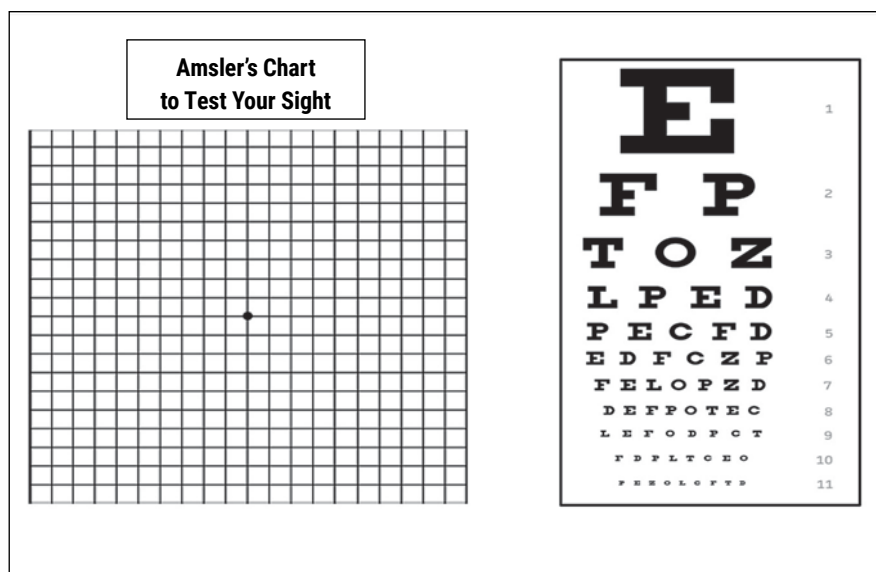
U.S. Patent Nos.: 8,450,344; 8,394,826; 9,096,569; 9,415,043; 9,931,336; 9,993,470; 10,174,017; 10,532,993; 10,588,901; 10,174,017

Manufactured for: Aerie Pharmaceuticals, Inc., Irvine, CA 92614, U.S.A.



**References:** 1. Rhopressa® (netarsudil ophthalmic solution) 0.02% Prescribing Information. Aerie Pharmaceuticals, Inc., 2019. 2. Data on file. Aerie Pharmaceuticals, Inc. 3. Rocklatan® (netarsudil and latanoprost ophthalmic solution) 0.02%/0.005% Prescribing Information. Aerie Pharmaceuticals, Inc., 2020. 4. Asrani S, Bacharach J, Holland E, et al. Fixed-dose combination of netarsudil and latanoprost in ocular hypertension and open-angle glaucoma: pooled efficacy/safety analysis of phase 3 MERCURY-1 AND -2. *Adv Ther.* 2020;37(4):1620-1631.

Rhopressa® is a registered trademark of Aerie Pharmaceuticals, Inc. Rocklatan® is a registered trademark of Aerie Pharmaceuticals, Inc. ©2020 Aerie Pharmaceuticals, Inc. All rights reserved. US-RHO-P-0268 06/20



**Figure 4.** The American Macular Degeneration Foundation's downloadable Amsler grid (available with instructions at [www.macular.org/amsler-chart](http://www.macular.org/amsler-chart)) and MD+Calc's downloadable near card (available with instructions at [www.mdcalc.com/visual-acuity-testing-snellens-chart](http://www.mdcalc.com/visual-acuity-testing-snellens-chart)) may be used by glaucoma patients in their homes to help identify possible changes in vision.

guidelines is not rocket science. You just have to learn to take simple but very important steps.”

Dr. Baartman says staffing has also presented unexpected challenges at his center. “COVID-19 has had a huge impact on our ability to staff our clinics and operating rooms,” he notes. “It wasn’t just because people were getting sick. It was because a lot of our staff have kids who couldn’t go to daycare or who have family members who were exposed to the virus. At any given moment, our staff has been down 20 percent. We’ve needed to empower employees to make independent decisions, when possible. Also, one of our core values is to be egalitarian, never letting anyone feel like he or she is above a certain role. That philosophy has served us well because people have moved into other roles when those roles have needed to be filled. We’ve developed a much stronger sense of sharing responsibility that’s helped keep us on our feet. That’s something we’ll emphasize going forward.”

## The Days Ahead

As he considers an environment in

which COVID-19 has been brought under control, Dr. Netland doesn’t envision a need to perform the same kind of screening and social distancing that his team currently uses.

“But there are some things that we want to continue with,” he says. “For instance, we’re going to continue with Zoom meetings. We’ve found they’re much more efficient. We’ll also pay more attention to patient congestion in the waiting room. As we come out of this pandemic, patients are probably going to be a little more sensitive to overcrowding. We’ll need to be more sensitive to that, too. For example, we don’t want to have five doctors or techs standing around in the same room.”

He adds that influenza and other viruses will continue on a seasonal basis. “The peak number of deaths associated with coronavirus is higher than the number from influenza,” he says. “But it’s not by that much more during the height of the flu season. The modifications to our ophthalmic equipment, the airflow and the other protections that we’ve put in place will probably be used yearly to protect us during the cycles of the other

infections that we deal with. We have mandatory influenza vaccinations at the clinic every year, but the vaccine is only 50-percent effective.”

He says the screening of patients for infection and constant sanitizing of hands, workspaces, equipment and areas touched by patients will continue. “We joke and say we’ve become alcoholics because we use so much alcohol to clean everything,” he says. “We’ll keep using wipes and hand sanitizers and cleaning the exam rooms and equipment between patient visits. The pandemic has raised our awareness of basic infection-control techniques. We want to have 100-percent compliance in all of these areas.”

Dr. Baartman envisions a future in which the doctor-patient relationship will continue to strengthen so that doctors can maintain a 360-degree assessment—one that focuses on a patient’s psychological, logistical and medical needs. Doctors and their staffs will need to be ready to continue to adapt, he adds.

“I think it would be a shame if we all went through this and didn’t learn something about ourselves, our practices and our ability to withstand the pressures of COVID-19,” says Dr. Baartman. “The most efficient way to deliver health care has become a priority, as have the best practices for staffing a clinic. We’ve learned to better understand the needs of others, including our staff and patients, while trying to accommodate and be more flexible. That’s really where I think our practice is headed. When the going gets tough, we really need to not just get going, but also to start listening to each other, better understanding needs, making changes and helping each other in any way we can.” ◀

1. Williams AM, Kalra G, Commiskey PW, et al. Ophthalmology practice during the coronavirus disease 2019 pandemic: The University of Pittsburgh experience in promoting clinic safety and embracing video visits. *Ophthalmol Ther* 2020;9:3:1-9.

2. Khaled Safadi K, Kruger JM, Chowers I, et al. Ophthalmology practice during the COVID-19 pandemic. *BMJ Open Ophthalmol* 2020;19:5:1.

# DRY EYE: THE BLEPHARITIS CONNECTION

How to diagnose and treat blepharitis and why patient education is key.

BY CHRISTINE LEONARD  
ASSOCIATE EDITOR

Just a few decades ago, blepharitis wasn't on most ophthalmologists' dry-eye radar. "They didn't realize how much it affects the tear film or patients' quality of life," says Mina Massaro-Giordano, MD, a professor of clinical ophthalmology and co-director of the Penn Dry Eye and Ocular Surface Center at the Scheie Eye Institute, University of Pennsylvania. "The pathophysiology is still poorly understood, but broadly, we understand blepharitis as eyelid inflammation. Inflammation in the lid triggers a cascade of disturbances in the bacterial flora and alters the quality of oil produced by the lid.

"Many patients just lived with miserable-looking lids and assumed they'd have to look and feel this way forever," she notes. "Now we know that if we treat the lids, this results in a better tear film, which translates to improved vision. You also need a healthy tear film to take accurate measurements for lens implantation for cataract surgery."

Blepharitis is one of the most com-

mon reasons patients seek care when they have issues with dryness or their ocular surface, says Guillermo Amescua, MD, associate professor of clinical ophthalmology and medical director of the Ocular Surface Program at the Bascom Palmer Eye Institute Ocular Surface Center. "This is due in part to the number of possible causes for the disease, which include toxins, bacteria, allergies, mites, certain dermatologic conditions or drugs, and genetics."

In this article, experts discuss their tips for diagnosing and managing blepharitis, and why patient education is vital for staving off dry eye.

## The Gland Inquisitor

Blepharitis diagnosis and treatment begins with correctly identifying the underlying cause and addressing it appropriately. "It's a clinical diagnosis," says Bennie H. Jeng, MD, a professor of ophthalmology and chair of the Department of Ophthalmology and Visual Sciences at the University of Maryland School of Medicine. "Anterior blepharitis often presents with 'dandruff' on the eye lashes or with flaky skin, whereas in posterior blepharitis, we see meibomitis, which influences

dry eye."

"In a case of seborrheic blepharitis, you'll see crustiness or exfoliated skin along the base of the eyelashes," notes Dr. Massaro-Giordano.

Additionally, *Demodex folliculorum* is a common cause but one not often addressed, Dr. Massaro-Giordano points out. "Patients can tolerate a certain number of those waxy collarettes at the base of eyelashes," she says, "but after you hit a certain threshold they can be very disturbing to the patient and need to be addressed with the appropriate treatment. Antibiotics, steroids or ointments won't get rid of mites. You need a targeted therapy for a full month to break their reproduction cycle and get rid of them."

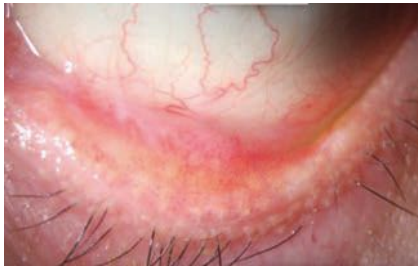
The failure of previous dry-eye treatments are sometimes the result of an undiagnosed Demodex infestation. Dr. Massaro-Giordano says she's found success with Cliradex (Bio-Tissue), an OTC preservative-free lid margin cleanser that uses 4-Terpineol, the key ingredient in tea tree oil.

For an intensive, in-office cleaning, I-Lid 'N Lash Pro (I-MED Pharma) cleansing gel with 20% tea tree oil is another option.

This article has no commercial sponsorship.

Drs. Massaro-Giordano, Jeng and Amescua have no relevant financial disclosures.





Dr. Guillermo Amescua, MD

**Ocular cicatricial pemphigoid may be the culprit behind chronic, on-and-off blepharitis.**

“In severe cases, we may prescribe an anti-parasite medication such as ivermectin, which can be taken orally,” she says. “In the dermatological world, ivermectin cream is used to decrease the mite load on the face and skin.” Dr. Massaro-Giordano says she typically prescribes oral ivermectin, 18 mg once a week, repeated three weeks later. “A 1% cream on the lids at bedtime helps as well,” she says.

“Allergies too can exacerbate or cause a subtle form of blepharitis that doesn’t receive much attention,” she adds. “I find that allergies and posterior and anterior blepharitis can coexist.”

In addition to mites and allergies, bacteria are another possible culprit. Common ones include Gram positive bacteria or *Staphylococcus*. “Many types of bacteria live on our lids, and when you have an imbalance of bacteria, the body may react to the proteins and the toxins that some of these bacteria produce,” she says. “We don’t routinely swab or culture the lids, so it’s difficult to tell which bacterium is causing the inflammation. *Staphylococcus* may coexist with several types of blepharitis, for example, but we’re not usually able to tell if it’s running the blepharitis picture.”

Dr. Amescua adds that children don’t usually complain of the same symptoms of dryness that adults do. “They tend to have a much healthier tear film,” he notes. “However, both may experience itchiness, burning, discomfort or blurring episodes. Oftentimes, children will complain of itchiness, and when the parent notices the eye becoming red, they think it’s just an allergy. It’s often blepharitis

secondary to pediatric rosacea.”

## Importance of Expression

With so many possible etiologies, there’s no single, set algorithm that doctors follow when diagnosing blepharitis. “Most diagnoses hinge on careful observation and a thorough examination,” says Dr. Massaro-Giordano. “Look for certain pathognomonic signs of blepharitis such as thickening of the lids or telangiectatic blood vessels along the eyelid margins.

“Once the lid is inflamed, that inflammation will spread to the meibomian glands,” she continues. “Look specifically at the orifices of the oil glands and see if they have an odd shape or are scarred down from past inflammation or past styes. Are they thickened? Are there many telangiectatic vessels around the openings? More importantly, what helps me tell the difference is pushing on the eyelid to see what secretions come out. Are they granular, thick or yellow? Or clear with an olive oil-like consistency?”

“When the lids become inflamed and irritated, the secretions change—melting points can change,” she says. “Healthy lids usually produce a very fluid, olive oil-like secretion, but an abnormal gland will produce a pasty secretion. It’s very likely that you won’t notice this unless you push on the glands. This helps me tell what degree of posterior blepharitis a patient might have.”

“I teach all my residents and fellows to do a manual expression of the glands during the exam,” says Dr. Amescua, whose patients are first seen by technicians for Schirmer’s and MMP-9 tests. “You can find out a lot about a patient’s condition by expressing the glands. We put in a numbing drop and press the eyelid glands with a Q-tip. If I’m not satisfied with what I find, I may do meibography to help visualize any morphologic changes in the glands.”

One other clue that may indicate posterior blepharitis is saponification of the tear film, which occurs when

bacteria living on the lids break down the oils in the tear film. “Look for soap-like deposits in the tear film, suds or foamy tears with debris along the lid margins,” says Dr. Massaro-Giordano. “Some patients will complain of a burning sensation, just as when you get soap in your eyes.”

## Patient History

Taking a thorough patient history can also help point you toward a blepharitis diagnosis. Sjogren’s syndrome or a history of dermatologic conditions may dispose a patient to blepharitis.

“It’s also important to ask how patients take care of their faces, in general,” says Dr. Massaro-Giordano. “I ask all patients: Do you clean your eyelids? When you wash your face, do you take the time to clean along the lash line? If they tell me, ‘No, I never touch my eyes when I wash my face,’ that could be a problem.”

Lid scrubs such as Ocusoft Lid Scrub (Ocusoft) and Sterilid (TheraTears) may help patients who shy away from washing near their eyes feel more comfortable with their lid hygiene. The scrubs contain non-irritating cleansers for removing ocular debris, dirt, oil and pollen. Another option for lid and gland hygiene is a hypochlorous acid wash, which kills a broad spectrum of bacteria. Ocusoft’s formulation is 0.02% hypochlorous acid solution; Avenova (Nova Bay Pharmaceuticals) is a 0.01% wash.

Preservatives in glaucoma drops may also be blepharitis culprits. If patients are experiencing significant inflammation of the lids or ocular surface from their glaucoma drops, Dr. Amescua says he discusses the possibility of switching to a preservative-free drop with the patient. Stopping the drops with close follow-up is another option, but he says, “if the glaucoma specialist who referred the patient to me says we can’t do that, then we may put the patient on an oral medication to lower the pressure and wait a few weeks to see how the patient does before reassessing.”

Another clue pointing to blepha-

ritis may be the number of eye-care providers a patient has visited for their dry-eye complaints. “Oftentimes, patients are being treated for dry eye from a symptomatic standpoint but not for the root of the problem,” says Dr. Jeng. “If the blepharitis goes untreated, the patient will continue to have undesirable dryness or dryness symptoms.”

Acne rosacea is another sign to look for, Dr. Jeng notes. “Rosacea blepharitis is a posterior blepharitis in which, just as in rosacea, the blood vessels become dilated, leading to inflammation of the lids. This causes swelling, and the swelling then chokes off the meibomian glands and obstructs the oils from entering the tear film.”

### Patient Compliance

The better patients understand both the condition and the necessary treatment, the better their compliance tends to be, experts say.

“When your patient has a significant number of Demodex mites, they’re very easy to treat,” Dr. Amescua says. “Once I identify this possibility, I pull some lashes, look at them under the microscope and show the patient. They become very compliant when they see the little mites walking around. When they come back for follow-up, they’ve almost always improved.

“If a patient has an associated skin condition such as psoriasis, their compliance is also likely to be high since they already understand the problem well and will follow the proper treatment to get better,” he adds.

The more difficult cases of compliance tend to be those involving meibomian gland stasis and dysfunction, Dr. Amescua notes. “Newly referred patients often come to me with a plastic bag of all the drops they’ve been using with no improvement,” he says. “The patients are told to do warm compresses and lid hygiene, but oftentimes they believe the true treatment is the drops. If we could develop a drop that could improve the glands, that would be wonderful, but for now it’s up to us to clearly explain to the patients the benefits of maintaining good lid hy-

giene and using mechanical or thermal treatments to improve the flow of oil.”

Even if a patient has a significant portion of their meibomian glands intact, Dr. Massaro-Giordano says she encourages patients to take proactive steps to preserve those healthy glands. “It can be challenging for clinicians to explain to patients why they need to be aggressively treating glands that appear normal,” she says. “Even if the patients aren’t bothered and the lid looks normal to me, I’ll tell them to start taking care of their lids—warm compresses, lid scrubs, sometimes a treatment—in order to preserve the integrity and function of the glands. If they don’t, it could pose a problem in the future.”

On the other hand, some patients become overzealous in their lid hygiene. “Excessive scrubbing and heat can really hurt the lid,” Dr. Massaro-Giordano says. “Warm compresses heated too hot in the microwave may damage the skin, and harsh scrubbing may inadvertently scratch the conjunctiva or cornea.”

Indeed, more isn’t always better. “Many times patients will have blepharitis but think it’s allergies and begin inundating their eyes with allergy drops,” she says. “In fact, they’re making it worse by introducing antihistamines and preservatives to the eye that may be drying it out further. Others will use artificial tears excessively, which just creates a further imbalance by washing out integral components of the tear film.

Dr. Amescua says that another downside of overzealous attention to the lids or the mistaken belief that drops are the most important treatment is an unhealthy fixation on the eyes. “Prescribing so many drops for patients tells them to think about their eyes all day—taking this drop, and then this other drop,” he explains. “They spend the whole day putting drops in and thinking about their disease. I don’t think that’s good for them psychologically.”

### Treatments

“We rely a great deal on patients be-

ing conscientious about doing their compresses and lid hygiene,” says Dr. Jeng. “Patients tend to be more compliant with drugs, but the warm compresses and scrubs are very important. I start with warm compresses, oral doxycycline or azithromycin, depending, and I go from there.”

However, Dr. Jeng says he generally doesn’t treat patients for blepharitis unless they’re symptomatic or if he’s trying to optimize their ocular surface before cataract surgery. “If you tell them to start scrubbing their eyelids, there’s a chance they may develop symptoms that make it worse,” he says. “Then you’re up the creek without a paddle because you told them to do it, and now they’re having symptoms.”

In addition to lid scrubs, cleansers and compresses, here are some other treatment options:

- **Antibiotics.** Dr. Massaro-Giordano prescribes topical azithromycin for a few weeks and has patients massage it around their lash line. She says erythromycin ointment used at night is also effective.

“Doxycycline is used for facial rosacea and can help ocular rosacea as well—not so much for its antibacterial effect but because it helps to stabilize the tear film by altering the lipids produced by the meibomian glands,” says Dr. Massaro-Giordano.

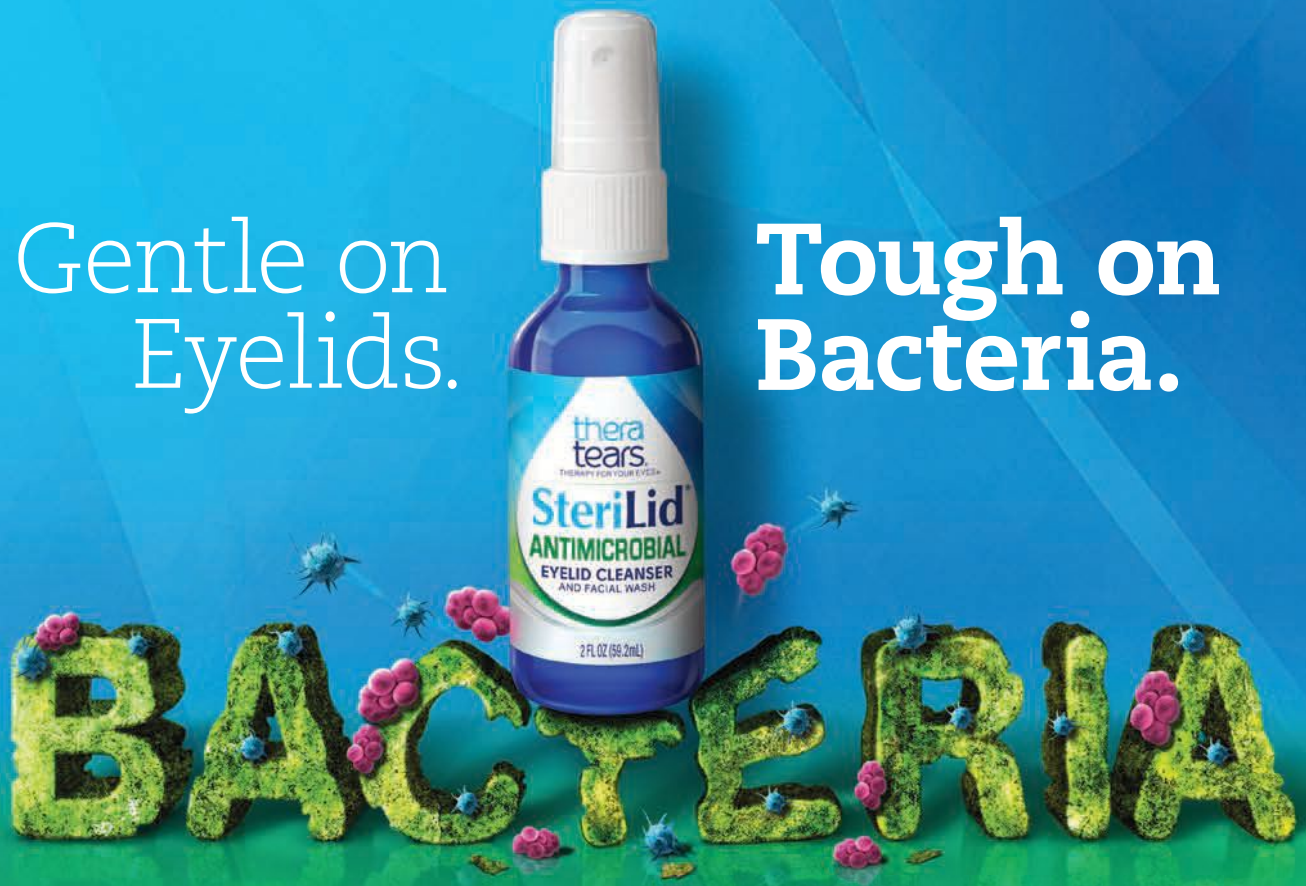While there’s no set dosage for treating blepharitis with doxycycline, she says that common dosing may include a low dose of 40 mg/day for a few months; 100 mg b.i.d. for one month; or 100 mg daily for two or three months.

Dr. Jeng adds that his doxycycline regimen consists of a tapered dose of 100 mg b.i.d. for the first month, 50 mg b.i.d. for the second month and then 50 mg q.d. “Sometimes I then go to 50 mg every other day,” he says. “I find that patients, especially those with rosacea blepharitis, also do well with the dermatologic preparation. It’s a low-dose doxycycline that’s meant to provide the benefits of the drug’s anti-inflammatory properties without the side effects of

new!

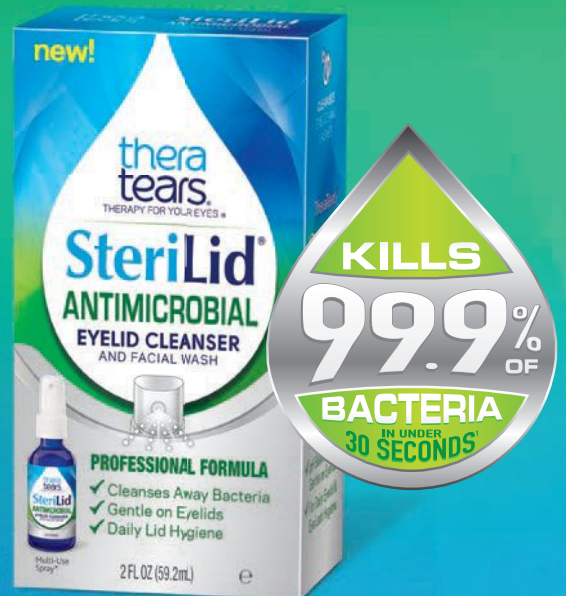Gentle on  
Eyelids.

Tough on  
Bacteria.



RECOMMEND  
THE FIRST FDA-ACCEPTED  
**ANTIMICROBIAL**  
EYELID CLEANSER

- ✓ Advanced Hypochlorous Acid (0.01%) formula for superior cleansing
- ✓ Cleanses away bacteria and irritants
- ✓ pH balanced formula is gentle on eyelids
- ✓ Effective daily eyelid and eyelash hygiene
- ✓ No rinse - soap free



Now available without a prescription at Walgreens, CVS Pharmacy®, Amazon, Rite Aid, and other retailers nationwide

Visit [theratears.com](http://theratears.com) to learn more

**AKORN** | CONSUMER HEALTH

Reference: 1. Results from an in vitro laboratory study. TheraTears® SteriLid® Antimicrobial Eyelid Cleanser and Facial Wash showed efficacy in reduction of colony forming units for eight common eyelid organisms. Data was captured at 30 and 60 seconds.

M18-069-00

doxycycline, like GI upset and sun sensitivity.”

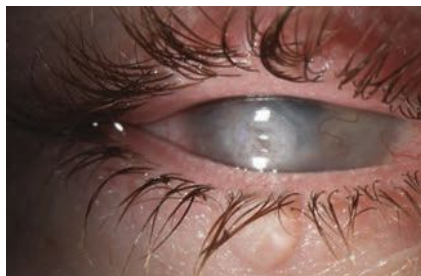“I try to avoid this antibiotic in the summer because of the increased sun sensitivity side effect,” Dr. Massaro-Giordano says. “It’s best for use in the winter, when dry eye is also more of an issue with indoor heat exposure and low humidity.”

**Steroids.** Steroids weren’t approved to treat dry eye for many years, but we now know topical steroid drops help to calm lid inflammation. Dr. Massaro-Giordano says she usually uses a short-course combination of tobramycin and dexamethasone, and/or cyclosporine drops for the long term.

In December 2020, a low-dose formulation of loteprednol etabonate, Eysuvis (Kala Pharmaceuticals), ophthalmic suspension 0.25%, was FDA-approved for use in episodic dry eye. “It can be used for two to three weeks at a time, and it’s been shown to be well-tolerated and to produce very few side effects,” says Dr. Massaro-Giordano. “With steroids, we worry about increasing IOP or cataract formation, but this new formulation has a different mechanism of action, which has little effect on IOP.” This corticosteroid is dosed at one to two drops, four times a day up to two weeks.

Dr. Jeng prescribes topical steroids drops for a short course if the lid appears inflamed, but for more serious cases, he says, “I have patients do warm compress first and follow this by putting a drop of steroid on their fingertip and scrub it into the eyelid margin. This increases penetration into the eyelid for a stronger effect than a drop in the eye would yield.”

For this treatment, the steroid and its dosage are stronger than that of a drop meant for conventional instillation, because it’s meant to go on the skin, says Dr. Jeng. “Dexamethasone or prednisolone aren’t substances you’d normally drop into the eye for ocular surface disease because they penetrate so deeply into the eye,” he says. “Normally, you want some-



Dr. Guillermo Amescua, MD

**Ocular rosacea may be treated with doxycycline or its low-dose dermatologic preparation.**

thing that penetrates less into the eye to treat the surface, but for this method, I do want penetration into the eyelid.”

**Thermal treatments.** Though warm compresses are the mainstay of many blepharitis treatment regimens, they have their limitations. “The warmth lasts only a few minutes and then the water’s cold again,” says Dr. Amescua. “They’re not always the way to go. Luckily, we have many devices such as eye masks available and procedures such as thermal pulsation to open obstructed lid glands.

“A manual expression is part of my standard office protocols, and if patients feel significant improvement, I strongly recommend they then have a treatment with the LipiFlow machine (J&J Vision), which is FDA-approved for treating posterior blepharitis,” he says. “We follow that with a series of manual expressions. I recommend they return periodically for LipiFlow.

“This intervention isn’t a cure, but it’s very helpful,” he notes. “About 80 percent of my patients notice at least an 80-percent improvement. It’s important, however, to inform patients that they shouldn’t expect a 100-percent improvement with these interventions.”

LipiFlow and other thermal treatments and low-light therapy such as LacryStim IPL (Quantel Medical), iLux (Alcon), MiBo Thermoflo (MiBo Medical Group), Epi-C PLUS (Espansione Group), TearCare (Sight Sciences) and eyeXpress (Holbar Medical Products)—some of which are used off-label—are not typically

covered by insurance.

The iTear100 (Olympic Ophthalmics), a prescription at-home neurostimulator, was recently FDA-cleared for temporarily increasing tear production. In clinical trials, mean Schirmer index was 9.4 mm (95% confidence interval [CI], 7.4 to 11.3) and baseline OSDI improved by an average of 14.4 (95% CI, 11.1 to 17.7) at 30 days. Both of these endpoints were statistically significant.<sup>1</sup>

**Probing of the lid.** Another procedure for obstructed glands involves probing the eyelid. “If some of the meibomian glands are scarred over or if there are fibrous bands of tissue over the gland orifices, you can use a specialized probe to poke through the obstruction, which allows the meibum to be released more readily,” says Dr. Massaro-Giordano. “This method was introduced by Steven Maskin, MD, in 2010 and is performed at the slit lamp with a blunt stainless steel 76 µm-diameter probe. After applying an anesthetic agent to the lids, the probe is gently introduced into the orifice, taking care not to create false passages. It’s well-tolerated by patients and can offer relief from these obstructed glands.”

**Manual cleaning.** “Mechanical debridement or microblepharoexfoliation of the lids can also be helpful to treat blepharitis,” says Dr. Massaro-Giordano. The BlephEx (BlephEx) device, which uses a specialized brush to exfoliate the lash line and clean away biofilm and bacteria, is one option. Dr. Amescua says it pairs well with Lipiflow. “It’s good for patients with significant debris on the lashes, Demodex or seborrheic blepharitis,” he says.

The at-home hygiene device NuLids (NuSight Medical) is intended to stimulate the glands and clean away debris with an oscillating brush head. The company says it includes a safety mechanism to protect the cornea that stops the brush head if too much pressure is applied.

“There are widely differing views on these technologies,” says Dr.

Jeng. “In theory, mechanical warming and massaging to clear the glands or in-office cleaning probably does have some benefit, but do I think it’s absolutely necessary? I haven’t found I’ve had to rely on these machines. The mild to moderate cases don’t necessarily need this equipment, though the patients with more severe symptoms may benefit from it. I’ve had many patients tell me that they work well, and if they want to try it that’s fine with me.”

In some cases, a patient’s symptoms don’t improve, even though the patient appears significantly better on clinical exam. “In these cases, we may not be dealing with significant blepharitis or dry-eye disease, but something that we’ve become more aware of in the past five years: chronic ocular pain syndrome,” Dr. Amescua says. “Pain becomes centralized, so we can’t treat it with drops—they won’t work. With the support of Anat Galor, MD, we’ve started an ocular pain syndrome program in collaboration with a headache and facial pain specialist that significantly helps these patients.”

“Ocular pain syndrome consists of dysregulation of the nerves serving the ocular surface,” Dr. Jeng says. “You can differentiate ocular pain syndrome from dry-eye-related pain by instilling a drop of anesthetic in the office. If the discomfort goes away, it’s probably dry eye. If it goes away only partially or not at all, then it’s time to seriously consider ocular pain syndrome. Because the pain is centrally mediated, we treat it with systemic medications such as gabapentin or pregabalin, or with antidepressants that have an effect on the nerves. However, it’s not totally understood now. Once we have a better understanding of its relationship to dry eye and blepharitis, I believe that will help us target therapies better.”

## The Future of Blepharitis Treatment

Dr. Massaro-Giordano says that the future of blepharitis treatment likely lies in combination therapy. “Evaluation of genetics and targeted therapies

are in the pipeline for patients with blepharitis,” she says.

Lately, there’s been increased interest in blepharitis and its implications for the ocular surface, says Dr. Jeng. “Many researchers are currently focused on posterior blepharitis and the resulting dry eye for preoperative ocular surface treatment. It’s become pretty standard to preemptively treat blepharitis now to get the best possible outcomes after cataract surgery.”

Dr. Amescua notes that a deeper understanding of why the meibomian glands become inflamed and how the oil becomes static will help develop more treatments. “I think in the future we’ll see more devices that are safe, effective and affordable for at-home improvement of meibomian gland function,” he adds.

## Strategies for Success

Here are some pearls for blepharitis management:

- **A good clinical exam is sufficient to make a diagnosis.** “You don’t need fancy equipment to diagnose blepharitis,” says Dr. Amescua. “A good clinical history and exam, which might include fluorescein or Lissamine green, questionnaires and manual gland expression are sufficient. If you have access to other equipment such as meibography, that’s helpful, but not necessary.”

- **Treat the root of the problem.** “This pearl is fairly obvious, but it’s important to keep in mind,” says Dr. Jeng. “Treat the blepharitis—not just the dry eye.”

- **Emphasize to the patient the importance of warm compresses and lid hygiene.** “Patients are likely to believe that drops are the most important aspect of the treatment, but if they don’t have a tear deficiency and still experience dry eye, their glands are the problem, and they won’t improve with drops,” says Dr. Amescua.

- **Chronic on-and-off blepharitis episodes may point to an autoimmune condition.** Dr. Amescua says, “If you’re dealing with a chronic dry-eye patient who’s been treated for meibomian gland disease that waxes and wanes or a patient who was on topi-

cal steroids and improved but stopped due to risk of cataract or glaucoma, it’s important to flip up and examine the eyelids to look at the conjunctiva and ensure there’s no signs of scarring, shortening of the fornix or symblepharon. One of the most common scenarios in our clinical practice is when patients with many months or years of chronic on-and-off red eye due to blepharitis end up having an autoimmune condition such as ocular cicatricial pemphigoid.”

- **Don’t miss blepharokeratoconjunctivitis in children.** “Blepharitis in children is unusual, so if you see it, don’t dismiss it,” says Dr. Jeng. “Specifically, blepharokeratoconjunctivitis is something to maintain suspicion for. It’s often asymmetric and very aggressive, and it causes serious ocular surface problems, such as corneal infections and vision loss. You have to treat this disease very aggressively: topical steroids are one option, but the mainstay is oral antibiotics—usually erythromycin. Because the disease affects young children, you don’t want to use tetracycline. The erythromycin’s anti-inflammatory properties keep things under control. Children as young as age three may develop blepharokeratoconjunctivitis, but it tends to burn itself out by the late teen years.”

- **Maintain suspicion for tumors in older patients.** “In older individuals, if you see blepharitis that looks a little strange—eyelash loss, for example—make sure to think about tumors, specifically sebaceous cell carcinoma,” warns Dr. Jeng.

Some of the telltale signs are localized swollen areas, missing eyelashes, an ulcerative appearance or a pearly border, says Dr. Massaro-Giordano. “If you have a lesion that’s refractory to the typical blepharitis treatments—warm compresses, scrubs, a short course of steroids—or it gets worse, that should raise a red flag,” she says. “It may indicate something more serious or malignant that should be biopsied.”

1. Ji MH, Moshfeghi DM, Periman L, et al. Novel extranasal tear stimulation: Pivotal study results. *Trans Vis Sci Tech* 2020;9:12:23.

# SOLVING THE PUZZLE OF CORNEAL ULCERS

How to expect horses—but prepare for zebras—when faced with a corneal infection.

BY MICHELLE STEPHENSON  
CONTRIBUTING EDITOR

Clinicians say the problem with managing corneal ulcers is the famous quote regarding medical diagnoses, “When you hear hoofbeats behind you, think horses, not zebras,” doesn’t always apply: A fungal “zebra”—though infrequent—is still a possibility. Because of this, corneal specialists have developed systematized methods for diagnosing and treating these infections. Here, experts outline their approaches to help you tackle these cases more effectively.

## Diagnosis

In the United States, the most common cause of corneal ulcers is bacteria. “In some hot and humid countries like India or Singapore, fungal ulcers might be more common than bacterial ulcers. Similarly, hot and humid areas of the United States, such as Miami and Houston, may have a lot of fungal infections, but, in general, in the United States, the cause is primarily bacteria,” says Francis Mah, MD, who is in practice

in La Jolla, California.

If a patient presents with a corneal ulcer, Laguna Hills, California’s John A. Hovanesian, MD, says the degree of the patient’s discomfort sometimes is a clue. “Bacterial ulcers tend to be more painful and more acute, while herpes simplex ulcers are less so,” he says. “With some rare organisms, like *Acanthamoeba*, the pain is classically described as much worse than you would expect by looking at the eye, because it affects the corneal nerves. History and appearance can also provide insights. For example, a very densely infiltrated ulcer with a lot of white blood cells in the cornea hints at a bacterial or fungal cause, so you would direct your thinking that way.”

According to Dr. Mah, culturing is a delicate topic as far as recommendations or standard of care. “In general, if you go across the country and talk about corneal ulcers, the majority of corneal ulcers don’t need to be cultured and probably aren’t,” he says. “Most ulcers are probably 1 mm, definitely smaller than 2 mm, and are probably associated with contact lens wear. Some of them are probably sterile. I would say, in

general, 75 percent to 90 percent of corneal ulcers are probably not being cultured, and I think it’s probably appropriate, if you include those types of corneal ulcers.”

Dr. Mah is co-chair of the American Academy of Ophthalmology’s Preferred Practice Patterns on corneas, and the PPP for bacterial keratitis<sup>1</sup> recommends that the following types of ulcers need to be cultured: those larger than 2 mm; those in the central cornea or the central visual axis; those that cause some stromal melting; those that are atypical looking; and those that are chronic and aren’t responding to treatment. “Those should definitely be cultured. Are you wrong to culture all ulcers? No. You’re definitely not wrong in culturing small, non-melting ulcers, but you’re also not wrong in not culturing them,” Dr. Mah explains.

Corneal specialist John Sheppard, who practices in Norfolk, Virginia, notes that ophthalmologists need to be prepared to obtain a wide variety of cultures, if needed. “Since the most common etiology of keratitis by far in the United States is bacteria,

This article has no commercial sponsorship.

Dr. Mah has a financial interest in Alcon, Allergan, Bausch & Lomb, Novartis, and Eyevance. Drs. Hovanesian and Sheppard have no relevant financial interests to disclose.

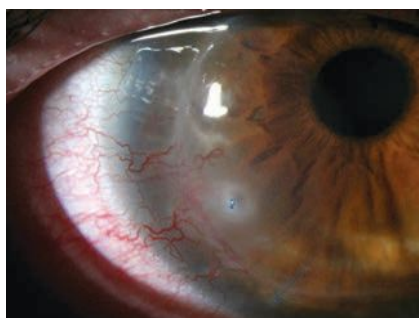we have several varieties of bacteria culture media available,” he says. “If a patient has an epithelial defect or is at high risk of infection, we’ll do a proactive sweep of the conjunctival cul-de-sac to assess the presence of pathogenic flora in the event that a problem arises and then place the patient on empirical preventive therapy. The acute, obviously infected eye, on the other hand, requires, if at all possible, a high-yield direct culture of the actual ulcer. This is done with preservative-free topical tetracaine and a Kimura spatula, which is sterile. I apply it directly onto a bacterial agar culture plate.

“Compared to other cultures obtained in the human body, the titer of organisms in the eye is log orders lower, so it’s often difficult to isolate organisms with standard media, such as a cotton swab,” he adds. “Furthermore, cotton is bacteriostatic, so we recommend calcium alginate or synthetic fiber swabs. The direct inoculation on the bacteria media gives you the highest yield. We also generally screen for fungus, which is a different type of media. We do the bacterial culture first because the fungal media contains antibacterials to allow the fungus to grow. Finally, we’ll obtain a slide for gram stain.”

Next, clinicians discuss the nuances of treating the four major causes of infectious corneal ulcers: bacteria; viruses; fungi; and parasites.

### Caused by Bacteria

According to Dr. Mah, ulcers that are typical and don’t require culturing are usually treated using a topical fluoroquinolone antibiotic. Only three of these drugs are FDA-approved for treating bacterial corneal ulcers: ofloxacin; ciprofloxacin; and levofloxacin 1.5%. Of those, only ofloxacin and ciprofloxacin are commercially available. “Others, like gatifloxacin, moxifloxacin and besifloxacin, haven’t undergone trials for FDA approval [for the treatment of ulcers],” Dr. Mah explains. “In general, they’re more potent, and



All Images: John Sheppard, MD

**Figure 1. An exposed broken prolene suture in a corneal transplant patient caused localized bacterial keratitis. This patient presented late, as evidenced by the vascularity, because the patient did not feel significant discomfort due to the anesthesia within a corneal allograft.**

there have been independent studies to show that they’re effective. Their patterns of resistance and susceptibility are probably better than ciprofloxacin and ofloxacin, so even though ciprofloxacin and ofloxacin are FDA-approved, and gati, moxi and besi aren’t, I don’t think you can go wrong in your treatment choice. I think it’s probably preferred to use moxifloxacin, gatifloxacin or besifloxacin as a first line. If you still have samples of besifloxacin, you can grab them off the shelf and get those antibiotics started.”

More severe bacterial ulcers require treatment with compounded or fortified antibiotics. “The most typical fortified antibiotics used for bacterial corneal ulcers are vancomycin (25 mg/mL or 50 mg/mL) and then tobramycin (14 mg/mL),” Dr. Mah adds.

However, fortified antibiotics aren’t always immediately available. “So, we start with what’s locally available and then switch when the compounded antibiotics become available,” Dr. Hovanesian explains. “Typically, the first thing that improves in bacterial ulcers is the symptom of pain, and the last thing that improves is the vision. Somewhere in between, we begin to see improvement in the appearance of the ulcer.”

He also cautions that some bacterial ulcers actually look a little worse

before they start to look better, particularly organisms like *pseudomonas*. “If you’re catching the ulcer on the upswing of the organism’s growth, you may effectively treat it with antibiotics, and it may actually look a little worse on the cornea for a day or two before it starts to turn around,” Dr. Hovanesian says. “We normally will see improvement in pain for patients within 24 hours of initiating appropriate therapy. This brings up the issue of compliance, which is important.”

Compliance can be challenging from the initiation of treatment. “We typically start these antibiotics in bacterial ulcers every five to 10 minutes for the first couple of hours to give a loading dose to the eye,” Dr. Hovanesian explains. “We then use them hourly around the clock for the next day or so. That’s difficult for patients. If patients don’t take the condition seriously, or even if they do take it seriously but are just distracted, they fail. During counseling, it’s important to talk about the serious nature of ulcers. We used to admit patients to the hospital for corneal ulcers if we had doubts about their ability to use their drops. We don’t do that so much anymore, but educating patients helps them understand that these little eye drops are not just to relieve their pain. They’re being used to prevent vision loss and to stop a process that will cause permanent damage. Helping patients become mentally invested in the treatment is important to get them compliant.”

In some cases, patients may need to be referred to a corneal specialist. “It’s important to have second opinions available, so it’s imperative to have a referral relationship with local cornea specialists. It’s good to set that up before you have an eye with a light spot staring at you in your slit lamp,” Dr. Hovanesian adds.

### Viral Ulcers

According to Dr. Hovanesian, viruses, such as herpes simplex, are

the second most common cause of corneal ulcers, after bacteria. While there's no cure for herpes, and the virus can reactivate, current treatments include topical or oral antivirals.

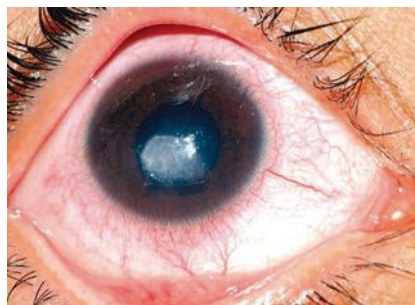Most commonly, a patient will present with a change in vision, rather than pain or discomfort. Many times, there will be a previous history of herpes keratitis. The diagnosis is typically made based on the patient's history, and the classic appearance of a dendrite. Cultures are rarely needed, due to the classic appearance.

According to Dr. Mah, treatment for epithelial herpes keratitis is debridement with a Kimura spatula, or even a Q-tip, to debulk the virus; or oral antivirals such as acyclovir or valacyclovir, or topical ones such as ganciclovir gel. "Although trifluridine is also FDA-approved, it's extremely toxic so it probably shouldn't be used since we have much better and less toxic agents," he adds.

### Fungal Ulcers

Dr. Mah explains that, if the etiology of an ulcer is trauma from vegetable matter, it's time to start thinking about fungi. These ulcers can have satellite or branching lesions, and tend to go deep instead of wide on the cornea as bacterial ulcers do, physicians say. "As far as the treatment, I usually culture them first and get some identification of the fungus," Dr. Mah says, "because the anti-fungal agents are usually a lot more toxic, and there's only one that's FDA-approved, so the majority of them have to be compounded. In general, the agents that we use for fungal keratitis are natamycin, which is FDA-approved for fungal keratitis in the United States. Amphotericin B and voriconazole can be used, but they need to be compounded."

The Mycotic Ulcer Treatment Trial (MUTT), a Phase III, double-masked, multicenter trial that randomized patients to voriconazole 1% or natamycin 5%, found that natamycin was associated with significantly better clinical and microbiological



All images: John Sheppard, MD

**Figure 2. This patient has a perforated pseudomonas corneal ulcer and ciliary flush due to inflammation in the right eye. Corneal cyanoacrylate glue was used to close the perforation.**

outcomes than voriconazole for smear-positive filamentous fungal keratitis.<sup>2</sup> Fungi become resistant to treatment much more commonly than bacteria, however, so Dr. Mah says that clinicians may want to consider covering with two agents instead of just one.

Dr. Sheppard explains that fungal ulcers are challenging because of the duration and persistence of the infection, and the necessity of early treatment. "Unfortunately, the fungal medicines are like putting battery acid in your eye, and you don't just give antifungals empirically," he says. "As a result, we may just kind of hedge, treat for bacteria, and give the patient an oral antifungal, which begins to protect the presumed but not immediately obvious fungal process and keeps the patient out of trouble until you have the gram stain back or a positive fungal culture. Of course, fungal cultures can take up to a week to grow, so that's not good. As a result, whenever we suspect *Acanthamoeba* or a fungus, both of which are quite rare, we're able to move forward and get patients treated with the right agent quickly by identifying the offending organism early with the confocal microscope. Skilled confocal imaging can also identify *Acanthamoeba* cysts in many cases. Severe infections are more common because of delayed diagnosis, or the initial therapy isn't the right one."

Polyicrobial infections must also

be suspected. For instance, the neurotrophic chronic quiescent herpetic cornea may become secondarily infected with a fungus, which presents notoriously late in this scenario due to the occasional complete lack of corneal sensation, physicians say.

### Parasitic Infections

Dr. Mah explains that *Acanthamoeba* as a cause for corneal ulcers is typically confused with herpes simplex virus and contact lens overwear. "Usually, these patients are started on antibiotics," Dr. Mah says. "Because of the confusion with HSV, they can also be put on an antiviral, like acyclovir or valacyclovir. Then, if it's persistent, and the clinician really thinks it's HSV, sometimes the patient will be put on steroid drops, which is the wrong thing to do for *Acanthamoeba*."

All treatments for *Acanthamoeba* need to be compounded. "You want to start with a biguanide," Dr. Mah explains. "The classic ones used in ophthalmology are polyhexamethylene biguanide (PHMB) and chlorhexidine. So, we want to start with at least one, if not both, of those. You can also use other agents. Brolene, for example, is available in Europe. If you can get it, it works well. Propamidine is another one used in the United States. It's an antiviral, but it has efficacy against *Acanthamoeba*. Neomycin can also be used, but it's unfortunately associated with a lot of allergy and toxicity. The best ones that we know of right now are PHMB and chlorhexidine. In general, *Acanthamoeba* is an entity that you definitely want to culture and identify because, once you identify it, you've kind of committed to weeks or months of therapy. Again, these agents are relatively toxic, and they're compounded, so you can't just go down to CVS and order them." ◀

1. <https://www.aao.org/preferred-practice-pattern/bacterial-keratitis-ppp-2018>

2. Prajna NV, Krishnan T, Mascarenhas J, et al, for the Mycotic Ulcer Treatment Trial Group. The Mycotic Ulcer Treatment Trial: A randomized trial comparing natamycin vs voriconazole. JAMA Ophthalmol. 2013;131:4:422-429.





# Transforming the Medical Conference Experience for a Virtual World

## Struggling to Transition From LIVE to Virtual Without Sacrificing the Attendee Experience?

Just like in the physical world, a spectacular digital conference takes months to plan and produce. The complexities of technology platforms and new formats can paralyze decision-making and stretch resources.

Partner with MedscapeLIVE!, the global leader in live and online medical learning, to effectively pivot your 2021 programming.

- Full-Service Event Management
- Broadcast Quality Production
- Immersive Virtual Platform
- Attendee, Sponsor, and Faculty Engagement



EDITED BY MICHAEL COLVARD, MD,  
AND STEVEN CHARLES, MD

**TECHNOLOGY UPDATE**

# 5G and Ophthalmology: Ready for Prime Time?

*The latest standard for wireless communication offers both advantages and potential pitfalls.*

BY CHRISTOPHER KENT  
SENIOR EDITOR

It's no secret that technology is advancing by leaps and bounds every year, and the technology that enables us to communicate via smartphones and the internet is no exception. In recent years most of our communications have been transmitted using what's referred to as 4G technology—the fourth generation standard for wireless telecommunications. Lately, unless you've been hiding under a rock, you've been seeing ads on television promoting the use of 5G.

For historical comparison, the first generation, which appeared in the 1980s, was able to deliver sufficient signal to carry analog voice communications. The second generation appeared in the early 1990s, with sufficient speed and bandwidth to carry digital voice transmissions and allow primitive messaging—the precursor of today's texting. In the early 2000s, 3G allowed the transmission of mobile digital data, making smartphones feasible, and a few years later 4G made mobile broadband transmission possible.

So: What's the significance of this new fifth-generation standard, and how will it affect the field of ophthalmology?

## The Benefits of 5G

5G technology should bring higher transmission speeds, lower latency (i.e., fewer delays) and greater throughput (more data transmitted at once) than was possible with 4G. This should lead to dramatically faster downloading and data sharing, and make it possible for some of today's newest "smart" technologies to communicate large amounts of data in real-time. 5G uses much-higher-frequency radio waves, which will allow many more devices to exchange data simultaneously within a given area. For example, 4G can support about 10,000 devices per square mile; 5G will be able to support about 2.5 million devices.

Recently, 4G networks have been reaching their capacity in crowded areas such as urban environments. This means that even if you have a good signal (i.e., five bars), the bandwidth may be overcrowded with digital information, making it impossible to access websites

or stream music or movies. That shouldn't happen with 5G. This will be particularly advantageous for today's smart devices, which share far more digital information than was the case even a few years ago.

Daniel Ting, MBBS, an associate professor at Duke-NUS Medical School in Singapore and head of AI and digital innovation at the Singapore Eye Research Institute, offers some perspective regarding how this may affect ophthalmologists. "Compared to 4G or 3G, 5G has a much faster speed of data transmission, lower latency and a lower power requirement," he explains. "Medical usage may benefit from 5G largely due to the speed of transmission. For example, outside of ophthalmology, 5G can be used in conjunction with robotic laparoscopic surgeries with technology such as the Da Vinci surgical system.

"In the field of ophthalmology," he continues, "5G could improve real-time remote consultation or treatment by reducing the lag-time of virtual consultations and AI-enabled diagnostic algorithms hosted in the cloud. Other possibilities such as robotic surgery aren't currently as widespread in ophthalmology as in some specialties like urology and gynecology, although the use of robotic vitrectomy was described a few years ago. However, the development of virtual and augmented


### THIRD-, FOURTH- AND FIFTH-GENERATION WIRELESS TELECOMMUNICATIONS STANDARDS

	3G	4G	5G
Deployment	2004-05	2006-10	2020
Bandwidth	2 mb per second	200 mb per second	>1 gb per second
Latency	100-500 milliseconds	20-30 milliseconds	<10 milliseconds
Average speed	144 kb per second	25 mb per second	200-400 mb per second

This article has no commercial sponsorship.

Dr. Colvard is a surgeon at the Colvard-Kandavel Eye Center in Los Angeles and a clinical professor of ophthalmology at the Keck School of Medicine of the University of Southern California. Dr. Charles is the founder of the Charles Retina Institute in Germantown, Tennessee.

FOUNDATION FIGHTING  
BLINDNESS *presents*



**HOPE** *from*  
**HOME**

A UNITED NIGHT  
TO SAVE SIGHT

**Sunday, February 28, 2021**

**7 pm ET | 6 pm CT | 5 pm MT | 4 pm PT**

*Celebrating Rare Disease Day*

Join the Foundation Fighting Blindness in kicking off our 50th anniversary year with a virtual gala hosted by Saturday Night Live alum Kevin Nealon and featuring musical entertainment by Charlie Kramer and Lachi!



Experience incredible entertainment and interactive rooms while supporting the mission of the Foundation Fighting Blindness – all from the comfort of your own home.

**[give.FightingBlindness.org/HopeFromHome](https://give.FightingBlindness.org/HopeFromHome)**

For more information, please contact  
866-732-7330 or [events@FightingBlindness.org](mailto:events@FightingBlindness.org).

*Thank you to our National Partner: Genentech, A Member of the Roche Group*

**FOUNDATION FIGHTING  
BLINDNESS**  
*Together, we're winning.*



Photo by Tomas Feres, courtesy of Wikipedia Commons

**A Vodafone cell tower in Karlsruhe, Germany, set up for 5G transmission. Because of its different parameters, this latest-generation wireless standard will require many more base towers to provide coverage in a given area than 4G transmission requires.**

realities to aid with testing and treatment, powered by the cloud and 5G technology, is another potential area in ophthalmology that could benefit from this in the future.”

### Potential Downsides

One of the practical challenges resulting from the altered parameters used in 5G data transmission is that it requires the use of far more base stations spread throughout a given area to provide all of its benefits. “The need for, and cost of, increased base stations could be a potential issue for rural areas with sparse populations,” Dr. Ting notes. “Thus, the infrastructure for 5G will need to be developed to make it practical and increase its cost-effectiveness for things like telecommunications, medical usage, cybersecurity and financial data transmission.” It also appears that the new parameters won’t allow transmission inside large buildings such as hospitals and large standalone practices, as some surgeons trying 5G have already noted.

(This may be resolvable as a practical problem by combining 5G with the latest WiFi technology, WiFi 6.)

Another issue that’s been raised as a result of the new parameters used in this technology is the possibility that it may be less secure, thanks to its increased complexity, the greater data flow and the use of more base stations than 4G wireless transmission technology required. Among other things, these factors will make it harder to check for vulnerabilities. On the upside, some say the ability to do “network slicing”—dividing up the network capacity to tailor a signal for better encryption and security—could be a boon to security.

“Network security and encryption is extremely important when data privacy is involved,” agrees Dr. Ting. “Given that the 5G applications in health care are not common as yet, we haven’t seen adverse events resulting from malicious hacker attacks so far. On the upside, 5G could be used in conjunction with blockchain technology to

increase the cybersecurity of these uses.”

So: Should ophthalmologists be in a hurry to upgrade? “At present, the use of 4G is sufficient to perform our daily activities,” notes Dr. Ting. “However, with more sophisticated technologies coming on board such as driverless cars, drones, and so-called ‘Internet of Things’ devices [Internet-connected devices that collect and transfer data over a wireless network without human intervention], the use of 5G technology could further improve their performance—if the challenges such as the need for increased base stations can be resolved.”

What about security-related concerns? “It will be important to use things like penetration tests to evaluate the strength and vulnerability of these technologies for any digital solutions or telecommunication network,” he says. “I think we should vigorously test this within research settings prior to actual clinical implementation.” ◀



“ I didn't realize  
**STARS**  
were little dots that twinkled ”

—Misty L, *RPE65* gene therapy recipient

**WE'RE SEEING  
AMAZING RESULTS.  
AND SO ARE THEY.**

At the Foundation Fighting Blindness our mission is everybody's vision. Our work shines a light on the darkness of inherited retinal diseases (IRDs).

We're the world's leading organization searching for treatments and cures. We need your help to fuel the discovery of innovations that will illuminate the future for so many. We have robust disease information, a national network of local chapters and support groups, local educational events, and our My Retina Tracker® Registry to help keep your patients connected with clinical and research advancements.

Help accelerate our mission  
by donating at [ECPs4Cures.org](https://ECPs4Cures.org).

**FOUNDATION  
FIGHTING  
BLINDNESS**

[FightingBlindness.org](https://FightingBlindness.org)



EDITED BY KULDEV SINGH, MD, MPH,  
AND PETER A. NETLAND, MD, PhD

## GLAUCOMA MANAGEMENT

# Cataract Surgery in Eyes With Angle Closure

*These eyes present special challenges for the cataract surgeon. Here's help.*

BY MICHELLE C. LIM, MD  
SACRAMENTO, CALIFORNIA

Cataract surgeons must operate on eyes with many different characteristics, and sometimes those characteristics make the surgery more challenging. A short eye with narrow angles or angle closure is a case in point.

Our understanding of the nature and consequences of a narrow angle has increased dramatically in the past 20 years. Narrow angles have been the focus of a number of clinical studies, including the Zhongshan Angle Closure Prevention (ZAP) trial that compared the value of doing a laser peripheral iridotomy to not doing an LPI in patients who are primary angle closure suspects; and the EAGLE study, which compared the impact of clear lens extraction in patients with primary angle closure with intraocular pressure 30 mmHg or greater, or primary angle-closure glaucoma, to the impact of performing a laser peripheral iridotomy.

Short eyes with narrow angles have traditionally been challenging in terms of choosing the best intraocular lens power, although today's more sophisticated formulas and biometers have made this less of an issue. But performing cataract surgery in the presence of a narrow angle can still be tricky. The good

news is, you can usually open the narrow angle significantly by removing the cataract. The bad news is, it can be technically challenging to operate in an eye with narrow angles, because the space in which you have to operate is compact.

Here, I'd like to offer some insights regarding the nature of angle closure; discuss the relative merits of performing cataract surgery vs. performing an LPI; share some strategies for improving safety and outcomes when performing cataract surgery on short, narrow-angle eyes; and share some thoughts on preventing and managing malignant glaucoma, which can occur postoperatively in some of these eyes.

### Classification of Angle Closure

Whenever we discuss narrow angles it's important to be clear about our terminology. With that in mind, I'd like to review the current recognized nomenclature relating to angle closure.

The "entry level" for angle closure is "primary angle closure suspect." This describes an eye in

which you see contact between the iris and the trabecular meshwork for at least 180 degrees or more of the angle, but the IOP is normal and you don't see any signs of peripheral anterior synechiae or glaucoma. (The extent of contact between the iris and trabecular meshwork can be determined by gonioscopy, anterior segment OCT or ultrasound biomicroscopy of the anterior segment.)

The second level is "primary angle closure." This term is used to describe an eye with 180 degrees or more of iris-trabecular touch, where either the IOP is abnormally high or you see peripheral anterior synechiae (or both). However, the patient doesn't have optic nerve damage.

The third category, which is straightforward and easy to understand, is primary angle closure glaucoma. This is a description applied to a patient with these abnormalities who does have glaucomatous damage.

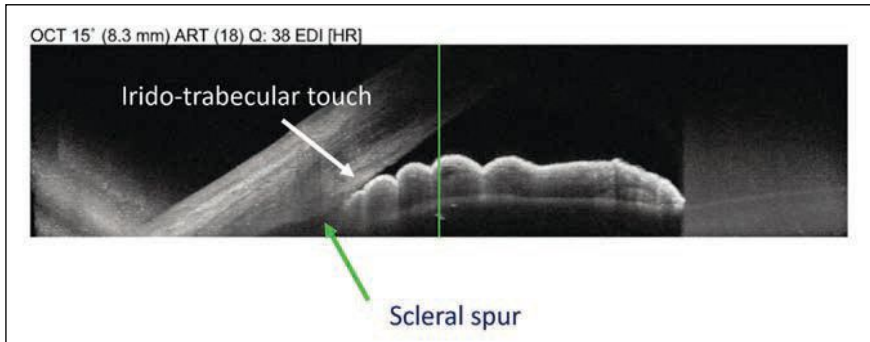
### LPI vs. Cataract Surgery

Previous studies have clearly shown that performing cataract surgery in any eye can lead to a modest pressure lowering of 2 to 4 mmHg for at least a couple of years. For example, one iStent study, involving 240 eyes with mild-to-moderate glaucoma and an IOP  $\geq 24$  mmHg, found that while eyes receiving an iStent did better than those not receiving one (72 percent of iStent eyes achieved an unmedicated IOP  $\leq 21$  mmHg

ANGLE CLOSURE NOMENCLATURE				
	Irido-trabecular contact	IOP	PAS	Glaucoma
Primary angle closure suspect	$\geq 180^\circ$	Normal	No	No
Primary angle closure	$\geq 180^\circ$	Abnormal	Yes	No
Primary angle closure glaucoma	$\geq 180^\circ$	Abnormal	Yes	Yes

This article has no commercial sponsorship.

Dr. Singh is a professor of ophthalmology and chief of the Glaucoma Division at Stanford University School of Medicine. Dr. Netland is Vernah Scott Moyston Professor and Chair at the University of Virginia in Charlottesville.



**Anterior segment optical coherence tomography image of an eye with narrow angles demonstrating irido-trabecular touch.**

at one year postop, vs. 50 percent of control eyes), half of the control eyes achieved that outcome as a result of the cataract surgery alone.<sup>1</sup> Articles reviewing multiple studies that have addressed this question report the same finding,<sup>2</sup> as did a review of data from the Ocular Hypertension Treatment Study.<sup>3</sup> In eyes with ocular hypertension, cataract removal resulted in a significant lowering of IOP ( $19.8 \pm 3.2$  mmHg vs.  $23.9 \pm 3.2$  mmHg;  $p < 0.001$ ).

Interestingly, studies have demonstrated that removing a cataract from eyes with narrow angles can result in an even greater benefit.<sup>4,5</sup> IOP reduction following cataract surgery in eyes with primary angle closure glaucoma has been reported in the range of 2 to 12 mmHg.<sup>6</sup> Many people believe the explanation for this is a change in the angle anatomy. You can clearly see the deepening of the anterior chamber and widening of the angle in these eyes once the cataract is removed. In fact, this change can be quantified using OCT. Studies have found that cataract surgery increases anterior chamber depth, the width of angle opening and the trabecular iris area.<sup>7,8</sup>

It's well known that one way to address some of the potential problems associated with a narrow angle is to perform a laser peripheral iridotomy. The supposition is that because the iris and the lens are in very close contact, pupillary block can occur, trapping fluid behind the

iris. (That's how people go into full-blown angle closure.) When you create the LPI, you're allowing aqueous humor to equilibrate on both sides of the iris. That allows the iris to flop back a little bit, pushing it away from the wall of the eye. You can often observe this happening after an LPI, although in some cases the LPI may not appear to have much effect. (At least having that hole in the iris will keep the eye from going into an angle closure attack.)

The landmark paper comparing the effectiveness of an LPI to that of cataract surgery is the EAGLE study, which came out in 2016.<sup>9</sup> One of the interesting aspects of this study is that they were able to enroll as many subjects as they did—419—because they had very strict criteria for who could be in the study. First, patients had to have primary angle closure with an IOP of 30 mmHg or higher, or primary angle closure glaucoma. (30 mmHg or higher is a pretty abnormal pressure.) Second, participants in the study couldn't have a cataract.

The participants were randomized to receive either an LPI or clear lens

extraction. A significant difference in mean IOP existed at three years postop: The CLE groups averaged a pressure of 16.6 mmHg, which was 1.18 mmHg lower than the average for the LPI group ( $p = 0.005$ ). Quality of life scores were also higher for the CLE group. In addition, patients in the CLE group required fewer glaucoma medications and less additional glaucoma surgery. The study authors concluded that clear lens extraction was more clinically effective and cost-effective than an LPI.

One caveat when interpreting the EAGLE study is to note that patients included in this randomized clinical trial were suffering from sequelae of their narrow angles. They either had significantly high IOP or definitive glaucomatous damage. Patients commonly seen by ophthalmologists have narrow angles with normal IOP, no signs of PAS and no glaucomatous damage (classification: primary angle closure suspect); they're not in the same category as the patients evaluated in the EAGLE study. Therefore, it wouldn't necessarily be appropriate to offer clear lens extraction in these cases. Also, a high proportion of EAGLE study patients were Asian; they may have less predominant pupillary block as the mechanism of their angle-closure, compared to non-Asian patients.

### Preoperative Considerations

Here are some preoperative strategies that will help ensure a good outcome when performing cataract surgery in these eyes:

- **Choose your lens power formula wisely.** The prediction of the effec-

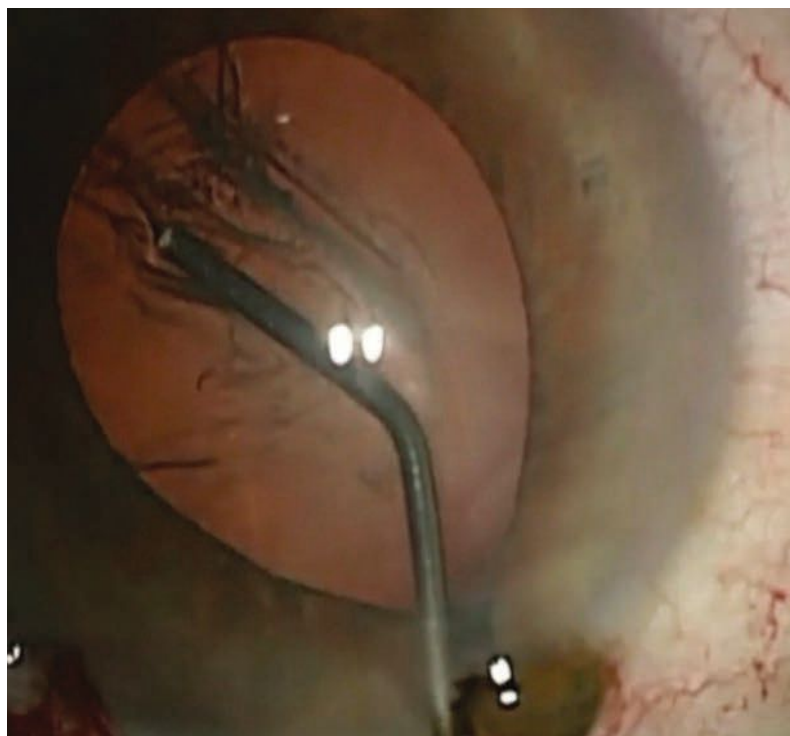
GLAUCOMA MEDICATIONS 36 MONTHS AFTER CLEAR LENS EXTRACTION OR LPI		
Medications	Clear lens extraction (n=208)	Laser peripheral iridotomy (n=211)
0	60.6% (n=126)	21.3% (n=45)
1	15.9% (n=33)	31.8% (n=67)
2	7.2% (n=15)	21.8% (n=46)
3	1.4% (n=3)	9% (n=19)
4	0.5% (n=1)	1.9% (n=4)

tive lens position in eyes with short axial length can be harder to estimate than in an eye with average axial length. Third- and fourth-generation intraocular lens formulae such as the Haigis, Holladay II and Hoffer Q are popular choices for short eyes.<sup>10</sup> The Barrett Universal II formula can also be helpful, although for very short eyes, it's advisable to review predictions from multiple formulae and choose an average for the final IOL power. (For more on use of formulas in these situations, see "IOL Power Formulas: 10 Questions Answered" in the January 2018 issue of Review.)

- **Set patient expectations.** When the eye is shorter than average, one should counsel the patient: "You have a very short eye, so our prediction of the best lens power to give you the vision you want will be less accurate. You could end up a little more farsighted or nearsighted than we intended." Without setting patient expectations appropriately, you can end up with a very unhappy patient.

- **Ask about a history of trauma and look for signs of lens instability.** If an eye has already undergone an acute angle-closure attack, the zonules may be unstable; this could cause the lens to drop during a complex cataract surgery with zonular dialysis.

Interestingly, I've always assumed that in this situation the preceding angle closure attack caused the lens to be unstable. But a study published in 2017 offers some evidence that the reverse may be true: Lens instability may have caused an acute angle closure attack.<sup>11</sup>



When dealing with a narrow angle, it's best to start your incision just inside the limbus. In this eye, iris prolapse occurred during hydrodissection due to a posteriorly placed corneal incision.

The authors of this paper present evidence that suggests that loose zonules may have allowed the lens to move forward, leading to the angle closure. They note that in eyes that had a history of acute angle closure and subsequent cataract surgery in which zonular instability was present, a longer axial length and a less-hyperopic spherical equivalent were also present. Normally, the risk of angle closure is associated with being more hyperopic and having a shorter axial length. The authors surmised that the unexpected biometrics of these eyes with loose zonules provide indirect evidence that zonular abnormality preceded the acute angle closure event.

### Intraoperative Pearls

Once you're in the OR, these protocols will increase the likelihood of a good outcome:

- **Start your incision just inside of the limbus.** An incision that begins too peripherally can increase the risk of iris prolapse (See image, above) in

an eye with a very narrow angle.

- **Create a two-step incision.** When I enter the eye to make the incision, I point the tip of the blade upwards a little bit to follow the curvature of the cornea; then I change direction and flatten out the blade before entering the anterior chamber. Emphasizing a two-step incision may help prevent iris prolapse.

- **If you use a cystotome to make your capsulorhexis, consider putting the needle on your viscoelastic syringe.**

Many surgeons use a cystotome—a bent

hypodermic needle—to tear the capsule. During the capsulorhexis, if pressure is placed on the incision, the viscoelastic can egress, leading to shallowing of the anterior chamber. This can leave you trapped in the eye with a flat chamber and a sharp needle. Having the viscoelastic syringe on the cystotome needle can make it easier to instill more gel in order to reform the anterior chamber.

- **Use dispersive viscoelastic during phacoemulsification of the lens.** It's easy to damage corneal endothelium while working in a very tight space. The dispersive viscoelastic can provide a protective coat on the endothelial side of the cornea to reduce the risk of damage.

- **Consider intravenous mannitol or acetazolamide.** Sometimes one can encounter posterior pressure in short eyes. IV mannitol or acetazolamide can be given to try to decompress that pressure.

- **Suture the corneal incision at the end of the case.** In an eye with nar-





I was only seeing light flashes early on, but light

**FLASHES**

when you've not seen anything for  
so many years—it was wonderful

—Keith H, retinal prosthesis recipient

**WE'RE SEEING  
AMAZING RESULTS.  
AND SO ARE THEY.**

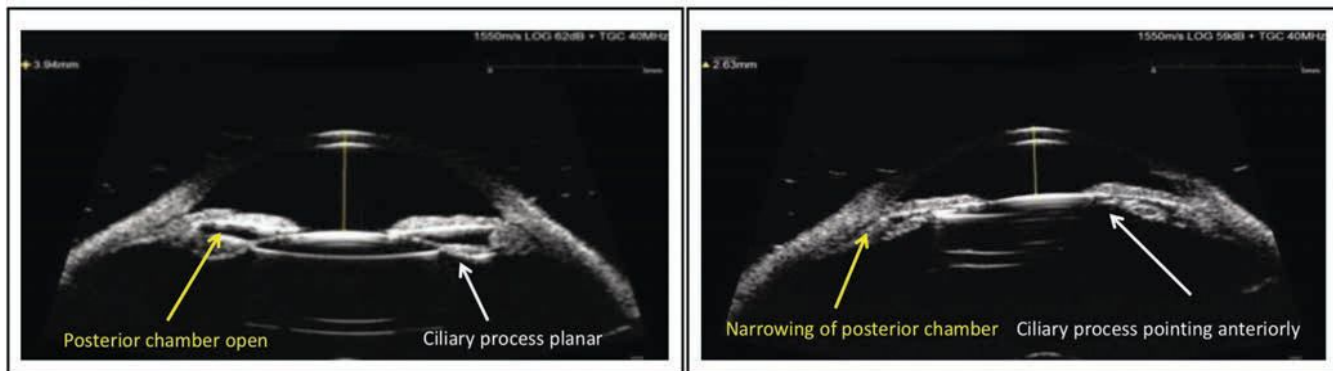
At the Foundation Fighting Blindness our mission is everybody's vision. Our work shines a light on the darkness of inherited retinal diseases (IRDs).

We're the world's leading organization searching for treatments and cures. We need your help to fuel the discovery of innovations that will illuminate the future for so many. We have robust disease information, a national network of local chapters and support groups, local educational events, and our My Retina Tracker® Registry to help keep your patients connected with clinical and research advancements.

Help accelerate our mission  
by donating at [ECPs4Cures.org](http://ECPs4Cures.org).

**FOUNDATION  
FIGHTING  
BLINDNESS**

[FightingBlindness.org](http://FightingBlindness.org)



**Malignant glaucoma vs. a healthy eye.** In this patient’s right eye (above, left), which doesn’t have malignant glaucoma, everything looks normal; the anterior chamber is deep. In the left eye (above, right), you can see that the lens, iris and ciliary body are all pushed forward. These are features of malignant glaucoma, in which the anterior chamber narrows and the ciliary processes point anteriorly. (Although this patient has had cataract surgery, the malignant glaucoma in this case was caused by trauma rather than by the cataract surgery.)

row angles, iris prolapse may occur if the corneal incision is disrupted. For example, while instilling eye drops, the patient may accidentally touch the eye with the dropper tip.

• **Consider leaving peripheral anterior synechiae alone.** Eyes that are narrow can have PAS. Many surgeons do goniosynechiolysis to try to open up the trabecular meshwork and get better outflow and lower pressure. This can be done by squeezing viscoelastic at the adhesions to try to break them, by using the cannula of the viscoelastic syringe or a blunt spatula to try to press the adhesions down and strip them away from the walls, or by using micro forceps to try and grasp the PAS.

I used to think that doing this made sense, but I recently read about two randomized clinical trials that found that goniosynechiolysis has little effect on IOP lowering.<sup>12,13</sup> In addition, the downsides of performing this additional procedure are that it may cause pigment release and bleeding in the eye, while potentially not doing much to improve the IOP outcome.

**Preventing Malignant Glaucoma**

When performing cataract surgery (or other surgeries) on narrow-angle eyes, postoperative malignant glaucoma is a potential complication, albeit a rare one. A history of angle closure or a short axial length

is known to be associated with increased risk of this complication occurring.<sup>14</sup>

This is more of a concern when the eye is extremely short. For example, a paper by Devesh Varma, MD, and colleagues looked at 20 eyes that developed malignant glaucoma after phacoemulsification surgery.<sup>15</sup> The mean axial length in these eyes was 21 ±1.4 mm. (The average eye has an axial length of approximately 23 to 24 mm.) Furthermore, the average refractive error in these eyes was +3 D.

Malignant glaucoma can occur at any time; it can occur intraoperatively, postop day one, postop week one or even later. Usually by the time the patient is a few weeks out the risk diminishes, but it can still occur. Unfortunately, diagnosing malignant glaucoma can be tricky. Signs to look for include:

• **An asymmetrically shallow anterior chamber.** The hallmark of malignant glaucoma is a shallow anterior chamber (See example, above), so failing to see a deeper anterior chamber after removing the cataract should make one at least think about malignant glaucoma as a possible explanation.

• **A myopic surprise.** If the patient is unexpectedly nearsighted, that means the lens is sitting forward of the predicted lens position. In malignant glaucoma, everything at

the lens plane gets pushed forward, including the ciliary body and the lens. (This is true whether the eye is phakic or pseudophakic.) Therefore, unexpected myopia is another warning sign.

• **High postoperative pressure.** A high postoperative pressure combined with an unexpectedly shallow anterior chamber should raise one’s suspicion for malignant glaucoma. Keep in mind however, that in rare cases, malignant glaucoma can present with a normal IOP, especially if a prior glaucoma procedure such as a trabeculectomy was performed or a glaucoma drainage device is present. The tipoff in this case would be an unexpected shallow anterior chamber.

If I suspect malignant glaucoma, I find that UBM imaging can be helpful in making the diagnosis. One should look for a shallow anterior chamber, narrowing or absence of the posterior chamber, and ciliary processes that may be rotated anteriorly.

Strategies that can help address malignant glaucoma include:

• **Consider starting the patient on atropine postoperatively as a precaution.** Doing so can decrease the risk of malignant glaucoma. This probably isn’t necessary if the angle is just a little narrow, but if the angle is very narrow preoperatively and the axial length is short, the risk is higher.

• **Don’t wait to treat.** If malignant

glaucoma is present, several maneuvers can be performed to address the problem. First, if the pressure is high, give the patient atropine to induce cycloplegia and start IOP lowering medication. Second, try disrupting the anterior face of the vitreous body with an Nd:YAG laser; this can break an attack. If neither of these options works, a vitrectomy with zonulo-hyaloidectomy is indicated.

## Forewarned is Forearmed

As with many non-average eyes, short eyes with narrow angles present challenges to the cataract surgeon. But as our understanding of these eyes continues to improve, the odds of achieving an excellent outcome are better than ever. Hopefully these tips will help your patients end up with excellent vision and minimal postoperative issues. ◀

1. Samuelson TW, Katz LJ, Wells JM, et al. US iStent

Study Group. Randomized evaluation of the trabecular micro-bypass stent with phacoemulsification in patients with glaucoma and cataract. *Ophthalmology* 2011;118:459-467.

2. Shrivastava A, Singh K. The impact of cataract surgery on glaucoma care. *Curr Opin Ophthalmology* 2014;25:1:19-25.

3. Mansberger SL, Gordon MO, Jampel H, et al, and the Ocular Hypertension Treatment Study Group. Reduction in intraocular pressure after cataract extraction: The Ocular Hypertension Treatment Study. *Ophthalmology* 2012;119:9:1826-31.

4. Lai JS, Tham CC, Chan JC. The clinical outcomes of cataract extraction by phacoemulsification in eyes with primary angle-closure glaucoma (PACG) and co-existing cataract: A prospective case series. *J Glaucoma* 2006;15:47-52.

5. Azuara-Blanco A, Burr J, Ramsay C, et al. Effectiveness of early lens extraction for the treatment of primary angle-closure glaucoma (EAGLE): A randomised controlled trial. *The Lancet* 2016;388:10052:1389-1397.

6. Trikha S, Perera SA, Husain R, Aung T. The role of lens extraction in the management of primary angle-closure glaucoma. *Curr Opin Ophthalmol* 2015;26:2:128-34.

7. Masis Solano M, Lin SC. Cataract, phacoemulsification and intraocular pressure: Is the anterior segment anatomy the missing piece of the puzzle? *Progress in Retinal and Eye Research* 2018;64:77-83.

8. Yang HS, Lee J, Choi S. Ocular biometric parameters associated with intraocular pressure reduction after cataract surgery in normal eyes. *Am J Ophthalmol* 2013;156:1:89-94.e81

9. Azuara-Blanco A, Burr J, Ramsay C, et al. Effectiveness

of early lens extraction for the treatment of primary angle-closure glaucoma (EAGLE): A randomised controlled trial. *The Lancet* 2016;388:10052:1389-1397.

10. Xia T, Martinez CE, Tsai LM. Update on Intraocular Lens Formulas and Calculations. *J Ophthalmol (Phila)* 2020;9:3:186-193.

11. Kwon J, Sung KR. Factors associated with zonular instability during cataract surgery in eyes with acute angle closure attack. *Am J Ophthalmology* 2017;183:118-124.

12. Moghimi S, Latifi G, Zandvakil N, et al. Phacoemulsification versus combined phacoemulsification and viscosynovioplasty in primary angle-closure glaucoma: A randomized clinical trial. *J Glaucoma* 2015;24:8:575-582.

13. Lee CK, Rho SS, Sung GJ, et al. Effect of goniosynechialysis during phacoemulsification on IOP in patients with medically well-controlled chronic angle-closure glaucoma. *J Glaucoma* 2015;24:6:405-409.

14. Kaplowitz K, Yung E, Flynn R, Tsai JC. Current concepts in the treatment of vitreous block, also known as aqueous misdirection. *Surv Ophthalmol* 2015;60:3:229-41.

15. Varma DK, Belovay GW, Tam DY, Ahmed IK. Malignant glaucoma after cataract surgery. *J Cat Refract Surg* 2014;40:11:1843-9.

## ABOUT THE AUTHOR



**Dr. Lim** is a professor of ophthalmology and vice-chair and medical director of the UC Davis Eye Center. Dr. Lim is an investigator for Santen and has received educational grants from Allergan.

## Are You Lawsuit-Proof?

(Continued from p. 22)

### 6 What's the best way to respond to an unhappy patient?

Mr. Bruhn recommends a prompt response. "The patient's dissatisfaction can grow if you don't respond to concerns," he says. "The physician may be reluctant to engage further or may not know how to engage. It's important that communication continue, however. The doctor should get his or her liability insurance company's advice and respond to the patient right away."

He notes that a complication doesn't necessarily represent negligent care. If there was an error, the patient should be told immediately. The message should come from the operating surgeon. "If disclosure isn't handled promptly, a records request can reveal that something wasn't done correctly," he points out. "Discovery of an undisclosed error can create a perception that there was an attempt

to hide what occurred. Continuing communication and responsiveness are very important to minimize risk."

Refunds can be used to mitigate risk. "Discuss these situations with your professional liability carrier," advises Mr. Bruhn. "Sometimes, it may be appropriate to have the patient sign a release confirming that the refund has resolved the issue. At OMIC, a release is drafted by an attorney for that patient."

### 7 How can you and your staff minimize or avoid a lawsuit?

Making sure you and your staff remain vigilant throughout a case is important, Mr. Bruhn says. "If a patient's not coming in for a follow-up appointment and repeatedly cancels appointments, that's not a good sign," he notes. "In these situations, the doctor needs to reach out and follow up with the patient to correct this non-compliant behavior. Staff may be the first to identify an unhappy patient in this situation

rather than the doctor."

Because refractive surgery is often an elective procedure, paid for out-of-pocket by the patient, you should be careful during preoperative discussions, according to Mr. Bruhn. "When a patient is paying out-of-pocket, his or her expectations can go up," he points out. "It's important in these situations that expectations are reasonable and attainable. The patient needs to understand that surgical outcomes can't be guaranteed. Surgery is complex and has risks. In some cases, there may be a need for additional care. The discussion with the patient prior to surgery is critical."

If a patient is uncertain and doesn't seem like a good candidate for a procedure, Mr. Bruhn recommends that you reconsider surgery. "If there are concerns, it's best to hold off on surgery," he says. "Seeking a second opinion may help a patient with a decision to consent to surgery." ◀



## Which MIGS for Which Patients?

(Continued from p. 37)

“The reality is, glaucoma patients do better with lower pressures; they’re less likely to have optic nerve damage,” he adds. “So, we’re always looking for an opportunity to push the pressure down another notch, especially in patients we’re more concerned about. That’s when we’re more likely to combine a couple of MIGS procedures.”

## How Many MIGS?

One factor that should influence your decision about how many MIGS to offer is the level of disease you routinely face in your practice. Clearly, the different MIGS procedures have somewhat different levels of efficacy—although the comparative efficacy has often not been established in clinical trials.

Dr. Noecker sees MIGS as falling into four categories. “Stents like the Hydrus and iStent are probably the lowest-risk thing to do, but they may be on the lower end of the efficacy spectrum,” he says. “The next step up would be the canal-based procedures and goniotomy; that category would include the iTrack, Omni system, KDB and Trabectome. When you’re opening up the canal, there’s a little more risk—a little more blood and inflammation—but also more efficacy. And, you can use these as a standalone procedure if you need to come back after the cataract is done.

“The third category is doing a transscleral or subconjunctival procedure like the Xen or PreserFlo—which we should have soon—or an ExPress shunt,” he continues. “A fourth category is reducing aqueous production. This means some sort of cyclophotocoagulation procedure, whether it’s done internally via ECP, if you’re comfortable with that, or externally with the Micropulse.

“If you treat a lot of glaucoma, I think it’s worth being able to do something from each category,” he

says. “It’s good to be able to do at least a few of these. You can refer patients out when you reach the level of complexity that you don’t want to deal with. Some comprehensive surgeons are very comfortable with the iStent and ECP. Both of those have been around for a long time. If you deal with moderate glaucoma, you probably should offer one of the canal procedures as well, and possibly the Xen-level options.”

“I think how many MIGS you should offer depends on who you are,” says Dr. Flowers. “If you’re a glaucoma specialist, I think you want to have at least one from each category in your toolbox: A Schlemm’s canal procedure; a supraciliary procedure (once one becomes available again); a way of doing cyclodestruction, either with ECP or Micropulse; and a filtering option. On the other hand, I think a general ophthalmologist should be able to perform at least one Schlemm’s canal-based procedure. One could argue that one is enough, because there’s no strong evidence of a huge difference in efficacy between them.

“Ultimately, I think people have to do the procedure they’re most comfortable with,” he concludes. “Some might argue that the iStent is easier to put in than the Hydrus, but it’s not necessarily easier to get in the exact right place. When you put in the Hydrus, you know you’re in Schlemm’s canal, whereas with the iStent Inject, you can’t be as certain. In terms of efficacy, their data was similar in randomized clinical trials. So, surgeons have to develop a comfort level with these procedures and then ultimately do the one they’re most adept at performing.”

“What most surgeons end up having in their armamentarium depends on what they’re comfortable with, and their patient population,” agrees Dr. Fellman. “If you’re mainly dealing with early glaucoma, then you may be happy with only offering the iStent, even though you’re only tapping into a few adja-

cent collector channels. That may be all you need. But if you’re treating more moderate glaucoma, then the Hydrus might be a better choice because it may access more collector channels. If you’re managing more advanced glaucoma patients, then creating a new subconjunctival drainage system should be part of your skill set.”

## It’s Always Worth Considering

“Every glaucoma surgery has a risk profile,” notes Dr. Flowers. “The reason MIGS was invented in the first place was to have a very safe surgical option to address glaucoma—safety first, efficacy second. That’s how I decide which approach I’m going to take: Which surgery has the appropriate level of risk for this particular individual? The second question is, how much efficacy do I need?”

“Every patient is unique, of course,” he continues. “If a patient has moderate nerve damage and is on three medications and the pressure is controlled, the patient doesn’t necessarily need anything—but she could certainly benefit from something. If you do a Schlemm’s canal-based procedure, be it an iStent inject or Hydrus or KDB, you’re going to improve her quality of life and have the patient on fewer medications, with almost no increased risk.”

“I believe surgeons should consider doing a MIGS procedure in every patient who’s actively being treated for glaucoma,” Dr. Noecker adds. “Among other things, if you have glaucoma you’re at greater risk of a postop IOP spike following cataract surgery—especially in cases of secondary glaucoma such as pigmentary glaucoma—and MIGS can help prevent that. You’re also more likely to be a steroid responder. A few patients may give you a reason to avoid combining MIGS with cataract surgery, but in most cases the risk is very small. I think adding a MIGS is a ‘best practice’ choice.” ◀

# Helping Postop Aqueous Shunt Surgery Outcomes

Researchers from the Bascom Palmer Eye Institute and Duke University say that the use of nylon wicks with fenestrations in nonvalved aqueous shunt surgery can help reduce intraocular pressure and glaucoma medication usage in the immediate postoperative period compared with the use of fenestrations alone.

In the retrospective study, the physicians analyzed all nonvalved aqueous shunt insertions completed by one surgeon. Patients had undergone either Baerveldt or ClearPath 350mm<sup>2</sup> aqueous shunt insertion with fenestrations only (n=37) or fenestrations with two nylon wicks (n=92). The surgeon ligated all devices with a 7-0 Vicryl (polyglactin) suture, and either four fenestrations or two fenestrations, and two 9-0 nylon wicks were placed anterior to the ligature.

The investigators collected data on visual acuity, IOP, number of glaucoma medications, and complications from the preoperative visit just before surgery, postoperative day one, week three, week five, and month two. This data was used as the primary outcome of the study.

The researchers found no difference in logMAR visual acuity between the two groups at any time point. At postoperative week three, intraocular pressure was significantly lower in the wick group (14.6 ±7.7 vs. 18.1 ±8.7 mm Hg,  $p=0.03$ ). The number of glaucoma medications used was significantly reduced in the wick group at three weeks postop (0.5 ±0.9 vs. 1.0 ±1.2,  $p=0.02$ ) and

two months after surgery (0.7 ±1.0 vs. 1.4±1.3,  $p=0.02$ ). There was no significant increase in the overall rate of complications in the wick group, but there was a higher rate of transient hyphema (28 percent vs. 8 percent,  $p=0.02$ ).

The researchers say that, as the surgeon waits for the ligature suture to dissolve after nonvalved aqueous shunt device implantation, the use of two nylon wicks with fenestrations can significantly lower intraocular pressure and medication burden.

*J Glaucoma* 2021;30:32-36.  
Swaminathan S, Quist M, Dawson L, et al.

## Low-concentration Atropine for Myopia Progression

Researchers from the Chinese University of Hong Kong and Hong Kong's Tung Wah Eastern Hospital evaluated the effect of age at treatment and other factors on the treatment response to atropine in the Low-concentration Atropine for Myopia Progression (LAMP) study, as part of a secondary analysis from a randomized trial.

Participants included 350 children, ages 4 to 12 years old (randomization was stratified by age and gender) originally assigned to receive 0.05%, 0.025%, 0.01% atropine or placebo once daily in both eyes, who completed two years of the LAMP study. In year two, the placebo group was switched to 0.05% atropine.

The change in spherical equivalent and axial length over two years were evaluated by generalized

estimating equations in each treatment group.

Other factors evaluated included age at treatment, gender, baseline refraction, parental myopia, time outdoors, diopter hours of near work and treatment compliance.

Here are some of the findings:

- In the 0.05%, 0.025%, and 0.01% atropine treatment groups, younger age of the patient was the only factor associated with spherical equivalent progression (coefficient=0.14, 0.15 and 0.20, respectively) and axial length elongation (coefficient=-0.10, -0.11 and -0.12, respectively) over two years; the younger the subject age, the poorer the response.

- At each year of age from four to 12 across the treatment groups, researchers found that the higher-concentration atropine showed a better treatment response, following a concentration-dependent effect ( $p<0.05$ ).

- The mean SE progression in 6-year-old children using 0.05% atropine (-0.90 D; CI, -0.99 to -0.82) was similar to that of 8-year-old children using 0.025% atropine (-0.89 D; CI, -0.94 to -0.83), and 10-year-old children using 0.01% atropine (-0.92 D; CI, -0.99 to -0.85).

The researchers report that all of the atropine concentrations were well-tolerated at all of the patient age groups.

The investigators found that younger age was associated with poor treatment outcomes with low-concentration atropine 0.05%, 0.025% and 0.01%. They added that, among atropine concentrations studied, younger children required the highest concentration, 0.05%, to achieve a reduction in myopic progression similar to older children on lower concentrations. ◀

*Ophthalmology* 2021;Jan 21 (epub ahead of print).

Li F, Zhang Y, Zhang X, et al.

# PRODUCT NEWS

New offerings to help improve clinical care and strengthen your practice.

## ► CONTACT LENSES

### **Alcon Launches Precision1 for Astigmatism Contact Lenses**

Alcon announced the U.S. launch of Precision1 for Astigmatism, a daily disposable, silicone hydrogel contact lens. The lens, which uses the Water Gradient Technology of Dailies Total1, features Precision Balance 8|4 lens design for a stable lens-wearing experience, the company says. The lenses feature Smartsurface Technology, a permanent micro-thin layer of moisture that steps up from 51 percent water at the core to greater than 80 percent water at the outer surface. For information, visit [professional.myalcon.com/contact-lenses/daily/precision](https://professional.myalcon.com/contact-lenses/daily/precision).

### **SynergEyes iD Hybrid Contact Lenses Launch**

SynergEyes introduced its next generation of hybrid contact lenses, SynergEyes iD, for patients with astigmatism, presbyopia, hyperopia and myopia. The company says the hybrid lenses are designed to fit patients' unique ocular anatomy, and lens choice is based on keratometric readings, HVID and refraction. A patient's corneal diameter and curvature drive the specific lens design, with new linear skirts following the shape of the sclera, SynergEyes adds. The multifocal lens uses a proprietary extended depth-of-focus design from the Brien Holden Vision Institute. For information, visit [synergieyes.com](https://synergieyes.com).

## ► DIAGNOSTIC AIDS

### **Haag-Streit Introduces Lenstar Myopia**

Haag-Streit has introduced Lenstar Myopia, consisting of the Lenstar 900 optical biometer and EyeSuite Myopia software, developed in close cooperation with myopia experts Thomas Aller, OD, and Pascal Blaser, founder and developer of myopia.care. Aside from axial length measurements, the company says Lenstar 900 offers a wide range of data including keratometry metrics for making accurate predictions about myopia's onset and progression. For information, visit [haag-streit.com/haag-streit-diagnostics/products/biometry/lenstar-myopia](https://haag-streit.com/haag-streit-diagnostics/products/biometry/lenstar-myopia).

### **US Ophthalmic Introduces Eyer Portable Retinal Camera**

US Ophthalmic has introduced the Eyer Portable Retinal Camera, which connects to a smartphone. The company says the device can "detect fundus disease at a lower cost than conventional methods." The device, which can be used for telemedicine exams, illuminates and images the

retina. It connects to a smartphone's camera, and an app sends the images over the internet to Eyer Cloud. The device further offers: panoramic images of more 110 degrees; iCloud connectivity; telemedicine capability; anterior and posterior segment imaging; and 12-megapixel images. [usophthalmic.com/products/eyer-nm-top](https://usophthalmic.com/products/eyer-nm-top).

### **Volk Releases ClearPod to Solve Mask-related Fogging**

Volk Optical has released its newest product, the ClearPod, to solve the problem of mask-related fogging during fundus exams. This patent-pending design was created in collaboration with Bradley Sacher, MD, a cataract specialist and Jeremy Wingard, MD, a glaucoma specialist at Illinois' Wheaton Eye Clinic. The ClearPod clips securely onto the Volk fundus lens and forms a barrier, directing air currents away from the lens surface and helping to stop lenses from fogging. For information, visit [volk.com/pages/clearpod](https://volk.com/pages/clearpod).

### **A New Option for Telemedicine**

Topcon recently launched its new Topcon RDx ocular telehealth software platform in the United States.

Topcon says the RDx allows practitioners to connect to their offices remotely and conduct comprehensive eye exams in real-time from virtually anywhere, without sacrificing quality. RDx connects to Topcon's CV-5000S digital phoropter, allowing practitioners to perform full refractions remotely.

In addition to the integrated face-to-face consultation dashboard, RDx automatically imports the autorefractor and lensometer data and presets the refraction starting point on the digital phoropter to optimize the exam. For information, visit [topconhealthcare.com/products/rdx](https://topconhealthcare.com/products/rdx).

## ► CORNEA

### **New Amniotic Membrane Debuts**

Keeler announced a partnership with Merakris Therapeutics, a developer of regenerative health care products. The company says its dehydrated amniotic membrane product, Opticyte Amniotic Ocular Matrix technology is based on a manufacturing process intended to retain extracellular matrix properties and structures. The company says the amniotic membrane is processed without harsh chemical reagents that may cause irritation. The Opticyte Amniotic Ocular Matrix comes in 8 mm, 10 mm, 12 mm and 14 mm circular grafts along with 1x1 cm and 1x2 cm surgical repair grafts. For information, visit [keelerusa.com/products/biologics.html](https://keelerusa.com/products/biologics.html).



# THE RICK BAY FOUNDATION

*for Excellence in Eyecare Education*

[www.rickbayfoundation.org](http://www.rickbayfoundation.org)

*Support the Education of Future Healthcare & Eyecare Professionals*



## **About Rick**

Rick Bay served as the publisher of *The Review Group* for more than 20 years.



To those who worked for him, he was a leader whose essence was based in a fierce and boundless loyalty.

To those in the industry and the professions he served, he will be remembered for his unique array of skills and for his dedication to exceeding the expectations of his customers, making many of them fast friends.

Scholarships are awarded to advance the education of students in both **Optometry** and **Ophthalmology**, and are chosen by their school based on qualities that embody Rick's commitment to the profession, including integrity, compassion, partnership and dedication to the greater good.

**Interested in being a partner with us?**

Visit [www.rickbayfoundation.org](http://www.rickbayfoundation.org)

*(Contributions are tax-deductible in accordance with section 170 of the Internal Revenue Code.)*



**THE RICK BAY FOUNDATION®**  
*for Excellence in Eyecare Education*

*(The Rick Bay Foundation for Excellence in Eyecare Education is a nonprofit, tax-exempt organization under section 501(c)(3) of the Internal Revenue Code.)*

**Career Opportunities**

**OPHTHALMOLOGISTS**

Danbury, CT

Ophthalmologists to share office with long standing Ophthalmologist in Danbury, CT. High quality equipment. \$2,250 per month or adjoining office without equipment- \$1,750 per month.

203-545-3539 or  
email [mehrimd@aol.com](mailto:mehrimd@aol.com)



**Do you have Products and Services for sale?**

CONTACT US TODAY  
FOR CLASSIFIED ADVERTISING  
Toll free: 888-498-1460  
E-mail: [sales@kerhgroup.com](mailto:sales@kerhgroup.com)



# Targeting Ophthalmologists?

**CLASSIFIED ADVERTISING WORKS**



Contact us today  
for classified advertising:  
Toll free: **888-498-1460**  
E-mail: [sales@kerhgroup.com](mailto:sales@kerhgroup.com)



## ADVERTISER INDEX

*This advertiser index is published as a convenience and not as part of the advertising contract. Every care will be taken to index correctly. No allowance will be made for errors due to spelling, incorrect page number, or failure to insert.*

Aerie Pharmaceuticals Corporate .....	43 & 44
.....	<a href="http://www.discovaerielive.com">www.discovaerielive.com</a>
Akorn Pharmaceuticals .....	49
.....	<a href="http://www.theratears.com">www.theratears.com</a>
Allergan, Inc. ....	INSERT
.....	(800) 347-4500
.....	<a href="http://www.durystahcp.com">www.durystahcp.com</a>
Bausch & Lomb .....	15 & 16
.....	<a href="http://www.vyzultanow.com">www.vyzultanow.com</a>
Bruder Ophthalmic Products .....	37
.....	(888) 827-8337
.....	<a href="mailto:eyes@bruderophthalmic.com">eyes@bruderophthalmic.com</a>
.....	<a href="http://www.bruderophthalmic.com">www.bruderophthalmic.com</a>
EyePoint Pharmaceuticals .....	Cover Tip
.....	(833) 393-7646
.....	<a href="http://www.eyepointpharma.com">www.eyepointpharma.com</a>
EyeVance .....	31 & 32
.....	(817) 677-6120
.....	<a href="http://www.eyevance.com">www.eyevance.com</a>
Glaukos .....	2
.....	(800) 452-8567
.....	<a href="http://www.glaukos.com">www.glaukos.com</a>

Icare USA .....	41
.....	(888) 389-4022
.....	<a href="http://www.icare-usa.com">www.icare-usa.com</a>
Imprimis Pharmaceuticals, Inc. ....	7
.....	(858) 704-4040
.....	<a href="http://www.imprimispharma.com">www.imprimispharma.com</a>
Kala Pharmaceuticals .....	11 & 12
.....	(781) 996-5252
.....	<a href="mailto:info@kalarx.com">info@kalarx.com</a>
.....	<a href="http://www.kalarx.com">www.kalarx.com</a>
Keeler Instruments .....	27
.....	(800) 523-5620
.....	<a href="http://www.keelerusa.com">www.keelerusa.com</a>
Lombart Instruments .....	5
.....	(800) 446-8092
.....	<a href="http://www.lombartinstrument.com">www.lombartinstrument.com</a>
Novartis Pharmaceuticals .....	74, 75 & 76
.....	<a href="http://www.novartis.com">www.novartis.com</a>
Reichert Technologies .....	9
.....	(888) 849-8955
.....	<a href="http://www.reichert.com">www.reichert.com</a>
RVL Pharmaceuticals Inc. ....	19 & 20
.....	<a href="http://www.upneeq.com">www.upneeq.com</a>
U.S. Ophthalmics .....	23
.....	(888) 881-1122
.....	<a href="http://www.usophthalmic.com">www.usophthalmic.com</a>





EDITED BY MEERA SIVALINGAM, MD, MPH

## WILLS EYE RESIDENT CASE REPORT

# A young boy presents with a pigmented conjunctival lesion and skin abnormalities.

ALINA YANG, MD, TATYANA MILMAN, MD, PHILIP W. DOCKERY, MD, MPH, ANTONIO YAGHY, MD, AND CAROL L. SHIELDS, MD  
PHILADELPHIA

### Presentation

A 7-year-old African-American boy presented with a pigmented conjunctival lesion in the left eye. The lesion had increased in size and vascularity compared to an examination six months prior.

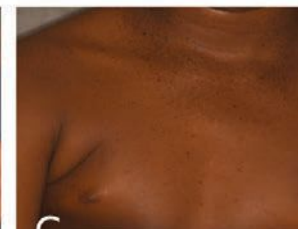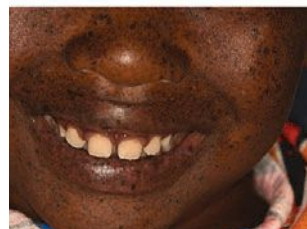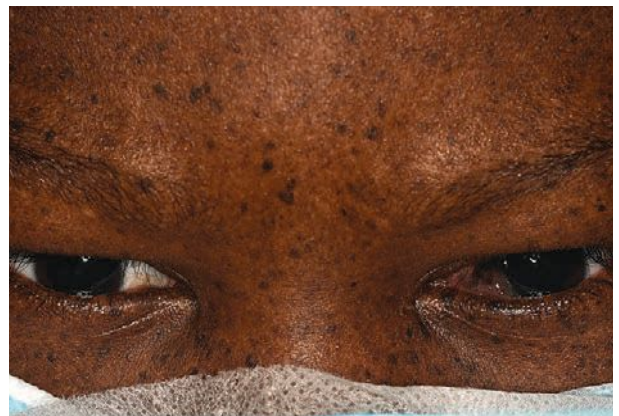### Medical History

At 3 years of age, the patient (who was adopted, precluding the assessment of his family's medical history) was referred to a pediatric ophthalmologist by his pediatrician for "constant squinting outdoors as long as he could remember," and photosensitivity in both eyes. Dry skin was noted on his initial examination, and the patient's photosensitivity was attributed to a combination of dry eye and allergic conjunctivitis. At 4 years of age, his ophthalmologist noted conjunctival pigmentation OU, as well as facial freckles. At age 5, the patient was diagnosed with a conjunctival nevus OS. At this time, the patient also underwent dermatologic evaluation for possible Peutz-Jeghers syndrome and Carney syndrome because of the numerous freckles distributed on his face, lips, torso and limbs. Genetic testing for these two conditions was ultimately negative.

Over a four-year period, the patient was managed with artificial tears, followed by ketotifen fumarate and most recently olopatadine for presumed allergic conjunctivitis. The patient continued to have persistent photosensitivity and ocular itching. During this time, he was also diagnosed with anisometropic amblyopia, myopia and astigmatism. At age 7, the conjunctival lesion OS showed growth and increased vascularity over the course of six months, prompting referral to the Ocular Oncology Service at Wills Eye Hospital. The child was otherwise healthy and meeting all developmental milestones.

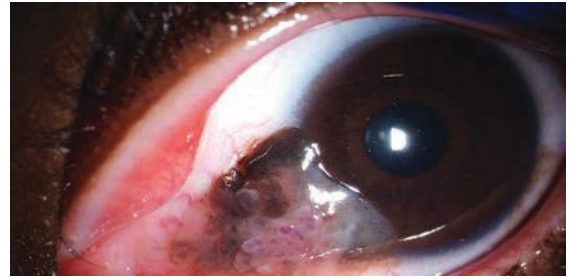
### Examination

Ocular examination demonstrated best-corrected visual acuity of 20/50 in the right eye and 20/30 in the left. Pupils were equal and reactive, with no afferent pupillary defect. Finger tension was normal OU. Extraocular motility was full. Visual fields were full to confrontation OU. External examination showed multiple facial lentiginosities (*Figure 1, A-C*). On further physical examination, these lentiginosities were also noted on the buccal mucosa, chest, back, along the shins and behind the knees, but were noted to be far more concentrated in the sun-exposed regions of the skin.



**Figure 1.** External photographs demonstrating lentiginosities scattered on the forehead and around both eyes (A), on the nose and around the mouth and on the lips (B), and on the anterior superior chest wall (C).

Slit lamp biomicroscopy OS revealed a mixed papilliform-gelatinous lesion measuring 8 mm in basal diameter and 3 mm in thickness with associated feeder vessels and pigmentation extending across the nasal conjunctiva onto the cornea (Figure 2). Scattered complex-associated melanosis was also present OU. The remaining ophthalmologic examination was unremarkable.



**Figure 2. External photograph of the left eye demonstrating the mixed papilliform-gelatinous lesion with associated feeder vessels and pigmentation.**

**What is your diagnosis? What further workup would you pursue? The diagnosis appears below.**

### Diagnosis and Management

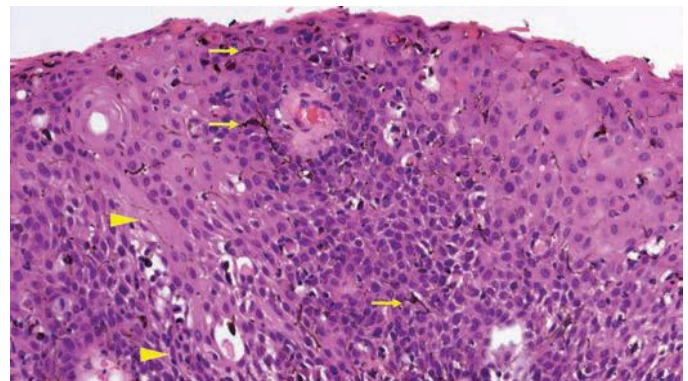
Given our patient's clinical history and examination, a differential diagnosis was constructed regarding the conjunctival lesion OS specifically, as well as potential disease complexes that could be contributing to his cutaneous presentation. Benign etiologies considered included squamous papilloma, melanocytic nevus and choristomatous lesions. Although malignant conjunctival tumors are uncommon in a young child, the rapid growth and corneal involvement, irregularity and prominent vascularity raised consideration of malignant neoplasms, such as pigmented squamous cell carcinoma and conjunctival melanoma. Other considerations included inflammatory and histiocytic-dendritic disorders, such as juvenile xanthogranuloma; or a reaction to an embedded foreign body.

Excisional biopsy of the conjunctival lesion with the "no-touch technique" was performed. All margins were treated with cryotherapy, and alcohol keratectomy was performed to eliminate tumor cells from the corneal surface. The patient was placed on neomycin/polymyxin B/dexamethasone (Maxitrol) ointment for three weeks. No intraoperative or postoperative complications were encountered in the first four months of follow-up.

Pathology revealed papillomatous-like, acanthotic, parakeratotic, dysplastic epithelium, with dysplastic cells focally replacing the entire epithelial thickness (Figure 3). Foci of hemorrhage and fibrin, as well as hyperplastic dendritic melanocytes, were noted in the dysplastic epithelium. The epithelial basement membrane remained intact. These findings were compatible with conjunctival squamous cell carcinoma *in situ* with secondary melanosis, also known as pigmented squamous cell carcinoma *in situ*.

The patient's young age at presentation with conjunctival squamous cell carcinoma was considered to be particularly noteworthy, leading to consideration of various cancer syndromes and immune dysfunction. In light of cutaneous and buccal mucosal findings, genodermatoses, such as Xeroderma Pigmentosum (XP), Carney syndrome and Peutz-Jeghers syndrome were considered. The association of conjunctival squamous cell carcinoma with a predominant sunlight-exposed skin distribution of freckles made XP a leading diagnostic consideration. Although neither Carney syndrome or Peutz-Jeghers syndrome have been previously associated with conjunctival squamous cell carcinoma, these conditions were included in the differential diagnosis because of the numerous cutaneous freckles and buccal mucosal freckling.

Genetic testing demonstrated absence of mutations in STK11, a tumor-suppressor gene implicated in Peutz-Jeghers syndrome. Testing for PRKAR1A, which has been implicated in 60 to 80 percent of cases of Carney Syndrome, was also negative. The geneticists recommended further screening and imaging, as these negative results reportedly decrease, but do not exclude, the possibility of these two disease complexes. Genetic testing for XP is currently being pursued.



**Figure 3. Histopathology of the mass showing conjunctival dysplasia with secondary melanosis. Note the acanthotic and parakeratotic epithelium (arrowheads), with dysplastic cells seen in the entire epithelial thickness. Hyperplastic dendritic melanocytes (arrows) are also scattered throughout. (Hematoxylin and eosin stain)**

## Discussion

Conjunctival ocular surface squamous neoplasia (OSSN), an umbrella term that includes conjunctival intraepithelial neoplasia (CIN), squamous cell carcinoma *in situ*, and invasive squamous cell carcinoma, is characterized by dysplastic cells involving the squamous epithelium of the conjunctiva. When the entire epithelium consists of dysplastic cells with an intact basement membrane, the lesion is called squamous cell carcinoma *in situ*.

Ocular surface squamous neoplasia can involve either the conjunctiva or the cornea, but more commonly involves both. Lesions most often arise at the nasal or temporal limbus, where they appear as gelatinous, papilliform or leukoplakic nodules, frequently associated with prominent feeder vessels. Pigmented SCC of the conjunctiva occurs infrequently.<sup>1</sup> Pigmentation in conjunctival squamous cell carcinoma generally occurs as a result of reactive (non-neoplastic) proliferation of melanocytes within the dysplastic epithelium. This phenomenon is generally seen in patients with darker skin tone and complexion-associated melanosis.

Ocular surface squamous neoplasia classically occurs in older white males. Other risk factors include extensive sun exposure, immunosuppression (e.g., HIV), vitamin A deficiency, chronic irritants, other infections or immune-dysregulated states. Based on a series of 5,002 conjunctival tumors in patients of all ages referred to an ocular oncology tertiary care center, conjunctival tumors were found to be benign (52 percent), premalignant (18 percent), or malignant (30 percent).<sup>2</sup> Comparatively, conjunctival tumors in children demonstrate malignancy in only 3 percent of cases.<sup>3</sup> A diagnosis of OSSN in a child or younger individual should raise suspicion for the possibility of underlying immunodeficiency or a cancer-predisposition syndrome. One study suggested that as many as half of patients younger than 50 with OSSN have HIV.<sup>4</sup> Patients with HIV are shown to have an increased severity of OSSN, worse prognosis and a higher chance of recurrence.<sup>5,6</sup> Ocular surface squamous neoplasia has also been associated with leukemia and lymphoma.<sup>7</sup>

Xeroderma pigmentosum is a rare disorder of defective repair of ultraviolet radiation-induced damage, characterized by photosensitivity with severe sunburns following minimal sun exposure, early development of lentiginous pigmentation and freckling on sun-exposed areas of the body, and—most concerning—a propensity for developing skin cancer at an early age. The median age at onset of skin basal cell carcinoma and squamous cell carcinoma in people with XP is approximately 8 years, more than 50 years earlier than in the general population.<sup>8</sup> Patients with XP are also at an increased risk of other cutaneous and conjunctival malignancies. In a case series from India, 14 patients with XP and bilateral OSSN presented with a median age of 12 years; all patients were less than 15 years

of age at presentation.<sup>9</sup> Additionally, 43 percent of the patients presented with invasive squamous cell carcinoma, which appeared to be aggressive with a recurrence rate of 64 percent.

Commonly reported ocular symptoms in an observational case series of 89 patients with a genetically confirmed diagnosis of XP included photophobia and dry eye.<sup>10</sup> Ophthalmic pathology manifested as ectropion, lagophthalmos, conjunctival injection, conjunctival melanosis, corneal scarring and keratopathy, pterygium and cancers of both the ocular surface and eyelids.<sup>10</sup> The authors noted that several patients had initially presented to ophthalmologists with ocular surface signs related to their XP, before any formal diagnosis of XP had been made, and that a number of children had red, photophobic eyes, which were repeatedly diagnosed as allergic eye disease.<sup>10</sup>

The prevention of cutaneous cancers through use of sunscreen, sun-protective clothing, and UV filters on eye protective equipment such as visors or glasses is paramount in these patients. Notably, ophthalmic manifestations of XP can precede the development of the more serious components of this condition. The diagnosis of XP should be considered in younger patients presenting with ocular surface dysplasia in the presence of abnormal pigmented lesions or skin freckling. ◀

*Support provided in part by the Eye Tumor Research Foundation in Philadelphia. The funders had no role in the design and conduct of the study, in the collection, analysis and interpretation of the data, and in the preparation, review or approval of the manuscript. Carol L. Shields, MD, has had full access to all the data in the study and takes responsibility for the integrity of the data. Inquiries to: Carol L. Shields, MD, Ocular Oncology Service, 840 Walnut Street, Suite 1440, Philadelphia, PA 19107. Tel: (215) 928-3105, Fax: (215) 928-1140, Email: carolshields@gmail.com.*

1. Shields CL, Manchandia A, Subbiah R, et al. Pigmented squamous cell carcinoma in situ of the conjunctiva in 5 cases. *Ophthalmol* 2008;115:10:1673.
2. Shields CL, Alset AE, Boal NS, et al. Conjunctival Tumors in 5002 Cases. Comparative analysis of benign versus malignant counterparts. The 2016 James D. Allen Lecture. *Am J Ophthalmol* 2017;173:106–133.
3. Shields CL, Sioufi K, Alset AE, et al. Clinical features differentiating benign from malignant conjunctival tumors in children. *JAMA Ophthalmol* 2017;135:215–24.
4. Karp CL, Scott IU, Chang TS, et al. Conjunctival intraepithelial neoplasia: A possible marker for HIV infection. *Arch Ophthalmol* 1996;114:257–61.
5. Gichuhi S, Macharia E, Kabiru J, et al. Risk factors for ocular surface squamous neoplasia in Kenya: A case-control study. *Trop Med Int Health* 2016;21:12:1522–1530.
6. Kamal S, Kaliki S, Mishra DK, et al. Ocular surface squamous neoplasia in 200 patients. *Ophthalmology* 2015;122:8:1688–1694.
7. Lee GA, Hirst LW. Ocular surface squamous neoplasia. *Surv Ophthalmol*. 1995;39:6:429–450.
8. Hebra F, Kaposi M. Xeroderma, parchment skin. On diseases of the skin including exanthemata. *New Sydenham Soc* 1874; 61:3:252–258.
9. Gupta N, Sachdev R, Tandon R. Ocular surface squamous neoplasia in xeroderma pigmentosum: Clinical spectrum and outcome. *Graefes Arch Clin Exp Ophthalmol* 2011;249:8:1217–1221.
10. Lim R, Sethi M, Morley AMS. Ophthalmic manifestations of xeroderma pigmentosum: A perspective from the United Kingdom. *Ophthalmology* 2017;124:1652–1661.



Not an actual patient.

\*In some patients with continued daily use. One drop in each eye, twice daily (approximately 12 hours apart).<sup>3</sup>

†Xiidra is an LFA-1 antagonist for the treatment of dry eye disease. Pivotal trial data: The safety and efficacy of Xiidra were assessed in four 12-week, randomized, multicenter, double-masked, vehicle-controlled studies (N=2133). Patients were dosed twice daily. Use of artificial tears was not allowed during the studies. The study end points included assessment of signs (based on Inferior fluorescein Corneal Staining Score [ICSS] on a scale of 0 to 4) and symptoms (based on patient-reported Eye Dryness Score [EDS] on a visual analogue scale of 0 to 100).<sup>3</sup> A larger reduction in EDS favoring Xiidra was observed in all studies at day 42 and day 84. Xiidra reduced symptoms of eye dryness at 2 weeks (based on EDS) compared to vehicle in 2 out of 4 clinical trials. Effects on signs of dry eye disease ICSS (on a scale from 0-4; 0=no staining; 4=coalescent) was recorded at each study visit. At day 84, a larger reduction in inferior corneal staining favoring Xiidra was observed in 3 of the 4 studies.<sup>3</sup>

## Indication


Xiidra® (lifitegrast ophthalmic solution) 5% is indicated for the treatment of signs and symptoms of dry eye disease (DED).

## Important Safety Information

- Xiidra is contraindicated in patients with known hypersensitivity to lifitegrast or to any of the other ingredients.



**Novartis Pharmaceuticals Corporation**  
East Hanover, New Jersey 07936-1080



SHE MAY NEED MORE THAN  
ARTIFICIAL TEARS TO  
**DISRUPT INFLAMMATION  
IN DRY EYE DISEASE<sup>1,2</sup>**

**Her eyes deserve a change.**

**Choose twice-daily Xiidra**  
for lasting relief that can start  
as early as 2 weeks.<sup>3\*†</sup>



**xiidra**<sup>®</sup>  
(lifitegrast  
ophthalmic solution)5%

### **Important Safety Information (cont)**

- In clinical trials, the most common adverse reactions reported in 5-25% of patients were instillation site irritation, dysgeusia and reduced visual acuity. Other adverse reactions reported in 1% to 5% of the patients were blurred vision, conjunctival hyperemia, eye irritation, headache, increased lacrimation, eye discharge, eye discomfort, eye pruritus and sinusitis.
- To avoid the potential for eye injury or contamination of the solution, patients should not touch the tip of the single-use container to their eye or to any surface.
- Contact lenses should be removed prior to the administration of Xiidra and may be reinserted 15 minutes following administration.
- Safety and efficacy in pediatric patients below the age of 17 years have not been established.

**For additional safety information about XIIDRA<sup>®</sup>, please refer to the brief summary of Full Prescribing Information on adjacent page.**

**References:** **1.** US Food and Drug Administration. Code of Federal Regulations, Title 21, Volume 5 (21CFR349). Accessed April 17, 2020. <https://www.accessdata.fda.gov/scripts/cdrh/cfdocs/cfcfr/CFRSearch.cfm?CFRPart=349&showFR=1> **2.** Jones L, Downie LE, Korb D, et al. TFOS DEWS II Management and Therapy Report. *Ocul Surf.* 2017;15(3):575-628. **3.** Xiidra [package insert]. East Hanover, NJ: Novartis Pharmaceuticals Corp; June 2020.

**XIIDRA, the XIIDRA logo and ii are registered trademarks of Novartis AG.**

**XIIDRA® (lifitegrast ophthalmic solution), for topical ophthalmic use**  
**Initial U.S. Approval: 2016**

**BRIEF SUMMARY: Please see package insert for full prescribing information.**

**1 INDICATIONS AND USAGE**

Xiidra® (lifitegrast ophthalmic solution) 5% is indicated for the treatment of the signs and symptoms of dry eye disease (DED).

**4 CONTRAINDICATIONS**

Xiidra is contraindicated in patients with known hypersensitivity to lifitegrast or to any of the other ingredients in the formulation [see *Adverse Reactions (6.2)*].

**6 ADVERSE REACTIONS**

The following serious adverse reactions are described elsewhere in the labeling:

- Hypersensitivity [see *Contraindications (4)*]

**6.1 Clinical Trials Experience**

Because clinical trials are conducted under widely varying conditions, adverse reaction rates observed in clinical trials of a drug cannot be directly compared to rates in the clinical trials of another drug and may not reflect the rates observed in practice.

In five clinical trials of DED conducted with lifitegrast ophthalmic solution, 1401 patients received at least one dose of lifitegrast (1287 of which received lifitegrast 5%). The majority of patients (84%) had less than or equal to 3 months of treatment exposure. One hundred-seventy patients were exposed to lifitegrast for approximately 12 months. The majority of the treated patients were female (77%). The most common adverse reactions reported in 5%-25% of patients were instillation-site irritation, dysgeusia, and reduced visual acuity.

Other adverse reactions reported in 1%-5% of the patients were blurred vision, conjunctival hyperemia, eye irritation, headache, increased lacrimation, eye discharge, eye discomfort, eye pruritus, and sinusitis.

**6.2 Postmarketing Experience**

The following adverse reactions have been identified during post-approval use of Xiidra. Because these reactions are reported voluntarily from a population of uncertain size, it is not always possible to reliably estimate their frequency or establish a causal relationship to drug exposure.

Rare serious cases of hypersensitivity, including anaphylactic reaction, bronchospasm, respiratory distress, pharyngeal edema, swollen tongue, urticaria, allergic conjunctivitis, dyspnea, angioedema, and allergic dermatitis have been reported. Eye swelling and rash have also been reported [see *Contraindications (4)*].

**8 USE IN SPECIFIC POPULATIONS**

**8.1 Pregnancy**

Risk Summary

There are no available data on Xiidra use in pregnant women to inform any drug-associated risks. Intravenous (IV) administration of lifitegrast to

pregnant rats, from pre-mating through gestation day 17, did not produce teratogenicity at clinically relevant systemic exposures. Intravenous administration of lifitegrast to pregnant rabbits during organogenesis produced an increased incidence of omphalocele at the lowest dose tested, 3 mg/kg/day (400-fold the human plasma exposure at the recommended human ophthalmic dose [RHOD], based on the area under the curve [AUC] level). Since human systemic exposure to lifitegrast following ocular administration of Xiidra at the RHOD is low, the applicability of animal findings to the risk of Xiidra use in humans during pregnancy is unclear [see *Clinical Pharmacology (12.3)* in the full prescribing information].

Data

Animal Data

Lifitegrast administered daily by IV injection to rats, from pre-mating through gestation day 17, caused an increase in mean pre-implantation loss and an increased incidence of several minor skeletal anomalies at 30 mg/kg/day, representing 5,400-fold the human plasma exposure at the RHOD of Xiidra, based on AUC. No teratogenicity was observed in the rat at 10 mg/kg/day (460-fold the human plasma exposure at the RHOD, based on AUC). In the rabbit, an increased incidence of omphalocele was observed at the lowest dose tested, 3 mg/kg/day (400-fold the human plasma exposure at the RHOD, based on AUC), when administered by IV injection daily from gestation days 7 through 19. A fetal no observed adverse effect level (NOAEL) was not identified in the rabbit.

**8.2 Lactation**

Risk Summary

There are no data on the presence of lifitegrast in human milk, the effects on the breastfed infant, or the effects on milk production. However, systemic exposure to lifitegrast from ocular administration is low [see *Clinical Pharmacology (12.3)* in the full prescribing information]. The developmental and health benefits of breastfeeding should be considered, along with the mother's clinical need for Xiidra and any potential adverse effects on the breastfed child from Xiidra.

**8.4 Pediatric Use**

Safety and efficacy in pediatric patients below the age of 17 years have not been established.

**8.5 Geriatric Use**

No overall differences in safety or effectiveness have been observed between elderly and younger adult patients.

Distributed by:  
Novartis Pharmaceuticals Corporation  
One Health Plaza  
East Hanover, NJ 07936  
T2020-87