

IS THERE AN UPTICK IN REFRACTIVE SURGERY? P. 12 • PEDIATRIC GLAUCOMA CONSIDERATIONS P. 20  
THE LATEST OPHTHALMIC PRODUCTS P. 55 • OPHTHALMOLOGY RESEARCH BRIEFS P. 56  
OPTIONS FOR COMBATING MYOPIA PROGRESSION P. 58 • WILLS EYE RESIDENT CASE REPORT P. 63

# REVIEW<sup>®</sup> of Ophthalmology

August 2020

reviewofophthalmology.com

## THE UPS AND DOWNS OF ANTI-VEGF

Treating Diabetic Retinopathy at the  
Dawn of the Disease **P. 36**

What to Do When the Sun Sets on  
Your Wet AMD Treatment **P. 28**

### ALSO INSIDE:

- The Experts' Take on Astigmatic Keratotomy **P. 42**
- Point-Counterpoint: SLT vs. Medical Therapy as First-line Treatment **P. 48**

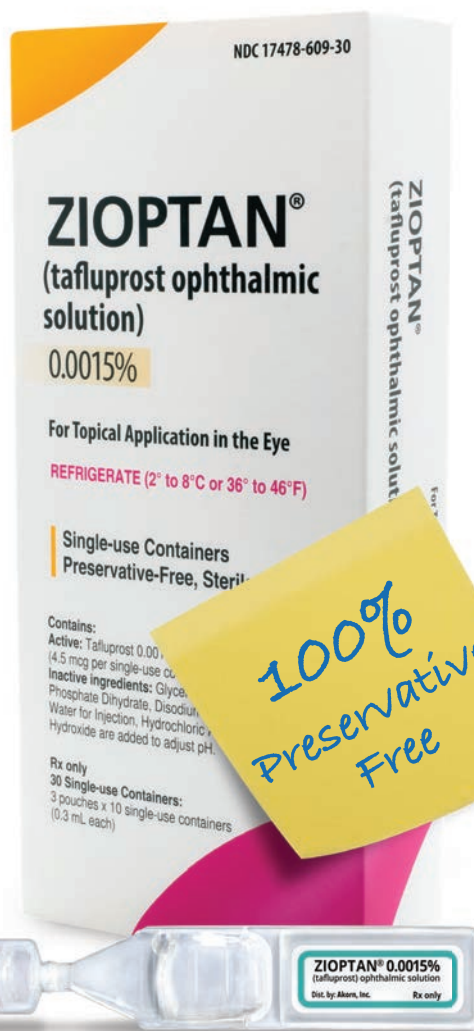# 100% PRESERVATIVE FREE Now Easier to Prescribe

## New Improved Coverage

Now a preferred brand on **Express Scripts®** Preferred Drug list

Now covered on >90% of **OPTUMRx®** Medicare Part D Plans

**ZIOPTAN®**  
(tafluprost ophthalmic solution) 0.0015%



Additional Practice Support Available At:

[MyAkornEyeCare.com](http://MyAkornEyeCare.com)

ZIOPTAN® is a registered trademark of Merck Sharp & Dohme Corp. and is used under license. ZIOPTAN® is licensed by Santen Pharmaceutical Co., Ltd. Express Scripts is a registered trademark of Express Scripts Strategic Development, Inc. OPTUMRx is a registered trademark of Optum, Inc.

©2020 Akorn, Inc. 1925 West Field Court, Suite 300 Lake Forest, IL 60045

**AKORN** | EYE CARE

JA013 Rev 6/20

# Low-carb Diet May Reduce the Risk of Some Types of POAG

A study published in the July 2020 issue of *Eye-Nature* magazine<sup>1</sup> reviewed data from 185,638 participants in three previously completed prospective cohort studies involving health professionals between the ages of 40 and 75 (the Nurses' Health Study I and II, and the Health Professionals Follow-up Study). The new study aimed to find any association between a low-carbohydrate diet and incident primary open-angle glaucoma, as well as any connection to POAG subtypes (defined by the highest untreated intraocular pressure and the pattern of visual field loss at diagnosis). The analyses were conducted by Jae Hee Kang, MD, at Harvard Medical School, with input from Louis R. Pasquale, MD, FARVO, deputy chair for ophthalmology research for the Mount Sinai Health System in New York City.

The study authors note that the neuroprotective effect of a ketogenic diet—high fat, modest protein, low carbohydrate—is well-established for epilepsy, and has been reported with other neurodegenerative diseases such as Parkinson's and Alzheimer's. Because a low-carbohydrate diet generates metabolites favorable to mitochondrial function, and the intrascleral optic nerve (the main site of glaucomatous damage) has a high mitochondrial density, the authors hypothesized that long-term reduced carbohydrate intake might be associated with a lower risk of POAG. In addition, because the maculopapillary nerve fiber layer bundles associated

with early-stage paracentral visual field loss are particularly susceptible to metabolic changes and impaired mitochondrial function, they hypothesized that this subtype of POAG might show greater benefit from this type of diet.

Using the data from the three earlier studies, the researchers analyzed subjects' self-reported diets in terms of carbohydrates, protein and fat. Once they identified individuals who ate a low-carb diet, the data were analyzed in three groups: participants whose dietary fat was primarily animal-based; those whose dietary fat was primarily plant-based; and all low-carb subjects grouped together, regardless of fat source. A reported diagnosis of POAG in 2,112 cases was confirmed by medical record review. The study authors then calculated the relative risk of POAG, adjusting for factors such as age, race and BMI.

No statistically significant association was found between the three types of low-carb diet and POAG overall. However, those subjects whose low-carb diet contained more fat and protein from vegetable sources showed a lower risk of the POAG subtype marked by initial paracentral visual field loss. The researchers

concluded that at-risk individuals who consume this type of diet could reduce their risk of early paracentral visual field loss by 20 percent.

Dr. Pasquale notes that this subtype of POAG with initial paracentral visual field loss is found in about 10 percent of POAG patients. "The optic nerve head is the prime site for optic nerve degeneration," he notes. "It has high mitochondrial content, and mitochondria prefer ketone bodies as an energy source. A low carbohydrate diet favors ketone body formation, which might help it prevent the onset of glaucoma."

Asked whether this diet might help patients who already have this subtype of glaucoma, Dr. Pasquale says this study doesn't shed any light on that question. "We don't know how a low-carbohydrate diet might affect people who already have glaucoma," he says. "Our studies are looking at disease-free populations and monitoring their diet until they get glaucoma, or until the end of a defined follow-up period. These studies are not designed to answer that question."

Regarding the data from the three preceding large-scale studies, Dr. Pasquale says he and Dr. Kang and their fellow authors stand on the shoulders of giants. "Dr. Kang and I





**Michael Hoster Succeeds James Henne as Publisher**

Jobson Medical Information has announced that Michael Hoster, a 13-year veteran of the company, has been named publisher of the Review Group of publications and services. This includes the titles *Review of Ophthalmology*, *Retina Specialist*, *Review of Optometry*, and *Review of Cornea and Contact Lenses*, as well as a host of affiliated websites, e-newsletters and other digital products designed to provide robust clinical insight and education to optometrists and ophthalmologists.



Mr. Hoster

Mr. Hoster assumed the position previously held by veteran publisher and industry icon, James Henne, since 2014. “Mike has been an instrumental player at the Review Group for 13 years, playing key roles on our editorial and sales teams,” said Marc Ferrara, president of Jobson’s Optical Group. “Of course, we will all miss Jim Henne, who has done an outstanding job leading the Review Group. Jim’s insights, leadership skills and witty charm make him a very unique leader.”

Mr. Hoster has spent his entire professional career at Jobson, beginning as an associate editor for *Review of Optometry* in 2007. He also served as the magazine’s managing editor from 2012 through 2014. Mr. Hoster later transitioned to the Review Group’s sales team in 2015. “Mike has become an extremely valuable team member over this period, and has developed a keen understanding of the markets we serve and the products we deliver,” added Mr. Ferrara.

“The Review Group has a sterling reputation for providing the most cutting-edge, clinically relevant information available to the eye-care community,” said Mr. Hoster. “Jim has been an invaluable leader to our group, a consummate mentor to me and a true inspiration to our entire company. I look forward to following in his footsteps, and working with our team in an effort to serve the needs of our readers and industry partners.”

have contributed to overall glaucoma knowledge using this cohort data for more than two decades,” he notes. “We owe thanks to the wisdom and vision of the founding investigators of those studies.” Dr. Pasquale says he and Dr. Kang next plan to repeat the analysis using artificial intelligence to quantify the paracentral visual loss.

1. Hanyuda, A., Rosner, B.A., Wiggs, J.L. et al. Low-carbohydrate-diet scores and the risk of primary open-angle glaucoma: Data from three US cohorts. *Eye* (2020). <https://doi.org/10.1038/s41433-020-0820-5>

ogists-in-training: Effective July 1, 2021, the American Board of Medical Specialties announced that all of its member boards with training programs of two or more years duration must allow for a minimum of six weeks away once during training for purposes of parental, caregiver, and medical leave, without exhausting time allowed for vacation or sick leave and without requiring an extension in training.

The ABMS added that member boards must communicate when a leave of absence “will require an official extension to help mitigate the negative impact on a physician’s career trajectory that a training extension may have, such as delaying a fellowship or moving into a full, salaried position.”

The ABMS says the organization’s new policy will offer residents and Fellows “more flexibility, reduced stress, and increased autonomy in making life decisions.” **REVIEW**

**ABMS  
Expands  
Caregiving  
Leave Policy**

Some good news for ophthalmol-

**Editor in Chief**

**Walter C. Bethke**

(610) 492-1024

wbethke@jobson.com

**Senior Editor**

**Christopher Kent**

(212) 274-7031

ckent@jobson.com

**Senior Editor**

**Sean McKinney**

(610) 492-1025

semckinney@jobson.com

**Associate Editor**

**Christine Leonard**

(610) 492-1008

cleonard@jobson.com

**Chief Medical Editor**

**Mark H. Blecher, MD**

**Art Director**

**Jared Araujo**

(610) 492-1032

jaraujo@jobson.com

**Senior Graphic Designer**

**Matt Egger**

(610) 492-1029

megger@jobson.com

**International coordinator, Japan**

**Mitz Kaminuma**

Reviewophtho@aol.com

**Business Offices**

19 Campus Boulevard, Suite 101

Newtown Square, PA 19073

(610) 492-1000

Fax: (610) 492-1039

**Subscription inquiries:**

United States — (877) 529-1746

Outside U.S. — (845) 267-3065

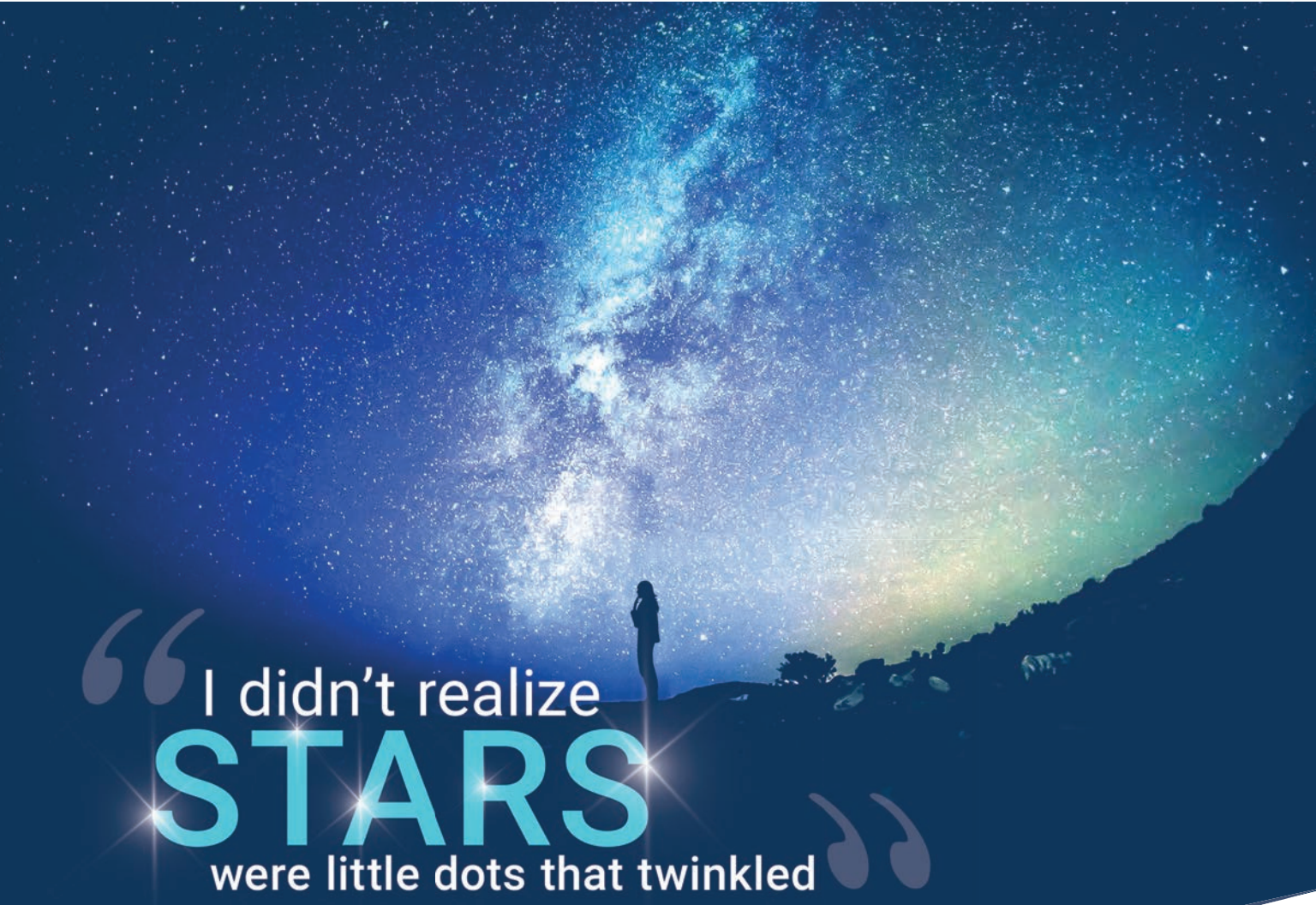
**E-mail:**

revophthalmology@cambeywest.com

**Website:** [www.reviewofophthalmology.com](http://www.reviewofophthalmology.com)







“ I didn't realize  
**STARS**  
were little dots that twinkled ”

—Misty L, *RPE65* gene therapy recipient

**WE'RE SEEING  
AMAZING RESULTS.  
AND SO ARE THEY.**

At the Foundation Fighting Blindness our mission is everybody's vision. Our work shines a light on the darkness of inherited retinal diseases (IRDs).

We're the world's leading organization searching for treatments and cures. We need your help to fuel the discovery of innovations that will illuminate the future for so many. We have robust disease information, a national network of local chapters and support groups, local educational events, and our My Retina Tracker® Registry to help keep your patients connected with clinical and research advancements.

Help accelerate our mission  
by donating at [ECPs4Cures.org](https://ECPs4Cures.org).

**FOUNDATION  
FIGHTING  
BLINDNESS**

[FightingBlindness.org](https://FightingBlindness.org)

# CONTRIBUTORS

**CHIEF MEDICAL EDITOR**

Mark H. Blecher, MD

**CONTACT LENSES**

Penny Asbell, MD

**CORNEA / ANTERIOR SEGMENT**

Thomas John, MD

**GLAUCOMA MANAGEMENT**

Peter Netland, MD, PHD  
Kuldev Singh, MD

**MASTERS OF SURGERY**

Taliva D. Martin, MD  
Sara J. Haug, MD, PhD

**MEDICARE Q & A**

Paul M. Larson, MBA

**PEDIATRIC PATIENT**

Wendy Huang, MD

**PLASTIC POINTERS**

Ann P. Murchison, MD, MPH

**REFRACTIVE SURGERY**

Arturo S. Chayet, MD

**RETINAL INSIDER**

Carl Regillo, MD, FACS  
Yoshihiro Yonekawa, MD

**TECHNOLOGY UPDATE**

Steven T. Charles, MD  
Michael Colvard, MD

**WILLS RESIDENT CASE SERIES**

Meera D. Sivalingam, MD

# ADVISORY BOARD

**PENNY A. ASBELL, MD**, MEMPHIS, TENN.

**BRANDON AYRES, MD**, PHILADELPHIA

**SURENDRA BASTI, MD**, CHICAGO

**WILLIAM I. BOND, MD**, PEKIN, ILL.

**ALAN N. CARLSON, MD**, DURHAM, N.C.

**Y. RALPH CHU, MD**, EDINA, MINN.

**ADAM J. COHEN, MD**, CHICAGO

**JANINE COLLINGE, MD**, FARMINGTON, CONN.

**UDAY DEVGAN, MD, FACS**, LOS ANGELES

**ERIC DONNENFELD, MD**, ROCKVILLE CENTRE, N.Y.

**DANIEL S. DURRIE, MD**, KANSAS CITY, MO.

**ROBERT EPSTEIN, MD**, MICHENRY, ILL.

**ROBERT D. FECHTNER, MD**, NEWARK, N.J.

**WILLIAM J. FISHKIND, MD**, TUCSON, ARIZ.

**BRIAN FRANCIS, MD**, Los Angeles

**JAMES P. GILLS, MD**, TARPON SPRINGS, FLA.

**HARRY GRABOW, MD**, SARASOTA, FLA.

**DOUGLAS K. GRAYSON, MD**, NEW YORK CITY

**THOMAS S. HARBIN, MD, MBA**, ATLANTA

**DAVID R. HARDTEN, MD**, MINNEAPOLIS

**KENNETH J. HOFFER, MD**, SANTA MONICA, CALIF.

**JACK T. HOLLADAY, MD, MSEE**, HOUSTON

**JOHN D. HUNKELER, MD**, KANSAS CITY, MO.

**THOMAS JOHN, MD**, TINLEY PARK, ILL.

**ROBERT M. KERSHNER, MD, MS**, PALM BEACH GARDENS, FLA.

**GUY M. KEZIRIAN, MD**, PARADISE VALLEY, ARIZ.

**TERRY KIM, MD**, DURHAM, N.C.

**BRAD KLIGMAN, MD**, GARDEN CITY, N.Y.

**TOMMY KORN, MD**, SAN DIEGO

**DAVID A. LEE, MD**, HOUSTON

**FRANCIS S. MAH, MD**, LA JOLLA, CALIF.

**NICK MAMALIS, MD**, SALT LAKE CITY

**EDWARD MANCHE, MD**, PALO ALTO, CALIF.

**MIKE S. MCFARLAND, MD**, PINE BLUFF, ARK.

**JEFFREY B. MORRIS, MD, MPH**, ENCINITAS, CALIF.

**KEVIN MILLER, MD**, LOS ANGELES

**MARLENE R. MOSTER, MD**, PHILADELPHIA

**ANNA MURCHISON, MD**, PHILADELPHIA

**ROBERT J. NOECKER, MD**, FAIRFIELD, CONN.

**ROBERT OSHER, MD**, CINCINNATI

**MARK PACKER, MD**, WEST PALM BEACH, FLA.

**CHRISTOPHER J. RAPUANO, MD**, PHILADELPHIA

**AUGUST READER III, MD**, SAN FRANCISCO

**TONY REALINI, MD**, MORGANTOWN, W.V.

**KENNETH J. ROSENTHAL, MD**, GREAT NECK, N.Y.

**ERIC ROTHCHILD, MD**, DELRAY BEACH, FLA.

**SHERI ROWEN, MD**, BALTIMORE

**JAMES J. SALZ, MD**, LOS ANGELES

**INGRID U. SCOTT, MD, MPH**, HERSHEY, PA.

**JOEL SCHUMAN, MD**, PITTSBURGH

**GAURAV SHAH, MD**, ST. LOUIS

**DAVID R. STAGER JR., MD**, DALLAS

**KARL STONECIPHER, MD**, GREENSBORO, N.C.

**JAMES C. TSAI, MD**, NEW YORK CITY

**VANCE THOMPSON, MD**, SIOUX FALLS, S.D.

**FARRELL C. TYSON, MD**, CAPE CORAL, FLA.

**R. BRUCE WALLACE III, MD**, ALEXANDRIA, LA.

**FRANK WEINSTOCK, MD**, CANTON, OHIO

**BUSINESS OFFICES**

19 CAMPUS BOULEVARD, SUITE 101  
NEWTOWN SQUARE, PA 19073  
SUBSCRIPTION INQUIRIES (877) 529-1746  
(USA ONLY); OUTSIDE USA, CALL (847) 763-9630

**BUSINESS STAFF**

PUBLISHER

**MICHAEL HOSTER**

(610) 492-1028 MHOSTER@JOBSON.COM

EXECUTIVE DIRECTOR

**JAMES HENNE**

(610) 492-1017 JHENNE@JOBSON.COM

REGIONAL SALES MANAGER

**MICHELE BARRETT**

(610) 492-1014 MBARRETT@JOBSON.COM

**CLASSIFIED ADVERTISING**

(888)-498-1460

PRODUCTION MANAGER

**FARRAH APONTE**

212-274-7057 FAPONTE@JOBSON.COM

PRODUCTION MANAGER

**KAREN LALLONE**

(610) 492-1010 KLALLONE@JOBSON.COM

**SUBSCRIPTIONS**

\$63 A YEAR, \$99 (U.S.) IN CANADA,  
\$158 (U.S.) IN ALL OTHER COUNTRIES.

SUBSCRIPTIONS E-MAIL:

REVOPHTHALMOLOGY@CAMBEYWEST.COM

**CIRCULATION**

PO BOX 71, CONGERS, NY 10920-0071

(877) 529-1746

OUTSIDE USA: (845) 267-3065

SENIOR CIRCULATION MANAGER

**HAMILTON MAHER**

(212) 219-7870 hmaher@jhihealth.com

CEO, INFORMATION GROUP SERVICES

**MARC FERRARA**

SENIOR VICE PRESIDENT, OPERATIONS

**JEFF LEVITZ**

VICE PRESIDENT, HUMAN RESOURCES

**TAMMY GARCIA**

VICE PRESIDENT, CREATIVE SERVICES & PRODUCTION

**MONICA TETTAMANZI**

CORPORATE PRODUCTION DIRECTOR

**JOHN ANTHONY CAGGIANO**

VICE PRESIDENT, CIRCULATION

**JARED SONNERS**



395 Hudson Street, 3rd Floor,  
New York, NY 10014

REVIEW OF OPHTHALMOLOGY (ISSN 1081-0226; USPS No. 0012-345) is published monthly, 12 times per year by Jobson Medical Information, 395 Hudson Street, 3rd Floor, New York, NY 10014. Periodicals postage paid at New York, NY and additional mailing offices. Postmaster: Send address changes to Review of Ophthalmology, PO Box 71, Congers, NY 10929-0071. Subscription Prices: US One Year \$63.00, US Two Year \$112.00, Canada One Year \$99.00, Canada Two Year \$181.00, Int'l One Year \$158.00, Int'l Two Year \$274.00. For subscription information call (877) 529-1746 (USA only); outside USA, call (845)-267-3065. Or email us at revophthalmology@cambeywest.com. Canada Post: Publications Mail Agreement #40612608. Canada Returns to be sent to Bleuchip International, P.O. Box 25542, London, ON N6C 6B2.

Let's make up for **lost time.**



In a moment when everything  
seemed to stop, time moved on.

We're still here.

Helping you focus on your  
practice. And most importantly  
your patients.

That's why we're replacing  
all expired or near-expired  
SmartLids® for free.

**Because care is the most  
important part of TearCare®.**

Learn more at  
[tearcare.com/CARES](https://tearcare.com/CARES)





# GET THE ADVANTAGE OF **SPEED**

OPHTHALMOLOGY'S FASTEST EHR & PM ALL-IN-ONE SOLUTION

**GUARANTEED TO INCREASE YOUR EFFICIENCY**  
and Bottom Line in less than **90 days!**

Our **Advantage SMART Practice**® EHR and practice management solution uses real-time data to make every part of your workflow faster.



**EHR | PM | ASC | RCM | TELEHEALTH**

 MyEyeStore | OPTICAL | PATIENT ENGAGEMENT | ON-LINE BILL PAY | ON-LINE SCHEDULING | MIPS

[WWW.COMPULINKADVANTAGE.COM/ONETAB](http://WWW.COMPULINKADVANTAGE.COM/ONETAB) | 805.716.8688





# REVIEW<sup>®</sup> of Ophthalmology

August 2020 • Volume XXVII No. 8 | [reviewofophthalmology.com](http://reviewofophthalmology.com)

## Cover Focus

---

### 28 | **An Extra Push for Wet AMD Patients**

*Sean McKinney, Senior Editor*

Conventional and not-so-conventional treatments to consider when these patients don't respond to initial anti-VEGF therapy.

### 36 | **Is It Time to Treat Presymptomatic DR?**

*Christopher Kent, Senior Editor*

Earlier treatment with anti-VEGF injections offers benefits, but many surgeons are staying the course.

## Feature Articles

---

### 42 | **The Experts' Take on Astigmatic Keratotomy**

*Christine Leonard, Associate Editor*

When it comes down to the knife or the laser, surgeon preference varies.

### 48 | **Point-Counterpoint: SLT vs. Medical Therapy**

*Robert Fechtner, MD, and Tony Realini, MD, MPH*

Two glaucoma experts debate the best way to proceed with first-line therapy for glaucoma.

# Departments

---

## 3 | Review News

### 12 | Refractive/Cataract Rundown What Downturn?

A slump in refractive surgery from COVID-19 isn't materializing—at least yet. Find out why and how to position your practice.

### 20 | Glaucoma Management Preop Considerations for Pediatric Glaucoma

Childhood glaucoma can be more serious than adult glaucoma, more challenging to diagnose and more difficult to treat.

### 55 | Product News New Forceps for Tough IOL Implantations

### 56 | Research Review Risk Factors for AMD After Cataract Surgery

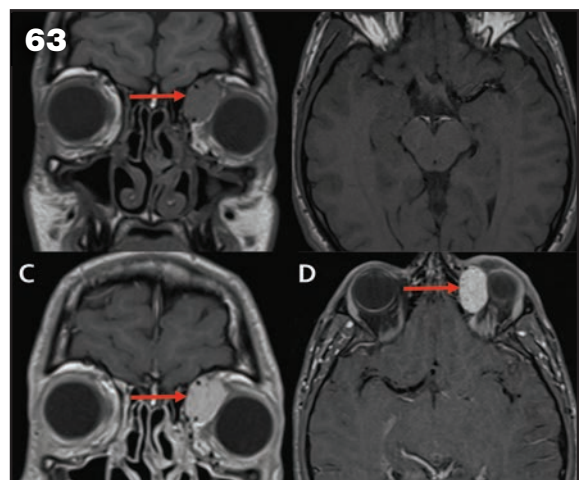
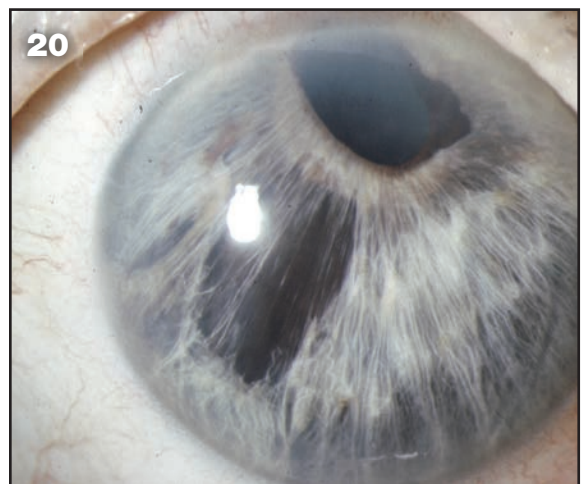
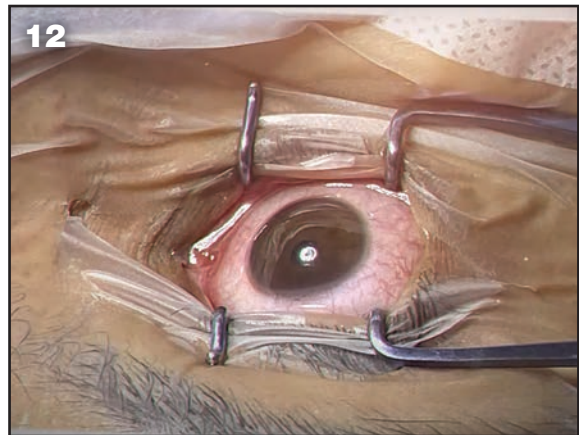
### 57 | Classifieds

### 58 | Pediatric Patient A Review of Advances in Myopia Management

Researchers and clinicians alike are working together to help stem the rising tide of myopia across the globe.

### 63 | Wills Eye Resident Case Series

### 65 | Advertiser Index







# THE RICK BAY FOUNDATION

## *for Excellence in Eyecare Education*

[www.rickbayfoundation.org](http://www.rickbayfoundation.org)

*Support the Education of Future Healthcare & Eyecare Professionals*



### **About Rick**

Rick Bay served as the publisher of *The Review Group* for more than 20 years.



To those who worked for him, he was a leader whose essence was based in a fierce and boundless loyalty.

To those in the industry and the professions he served, he will be remembered for his unique array of skills and for his dedication to exceeding the expectations of his customers, making many of them fast friends.

Scholarships are awarded to advance the education of students in both **Optometry** and **Ophthalmology**, and are chosen by their school based on qualities that embody Rick's commitment to the profession, including integrity, compassion, partnership and dedication to the greater good.

### Interested in being a partner with us?

Visit [www.rickbayfoundation.org](http://www.rickbayfoundation.org)

*(Contributions are tax-deductible in accordance with section 170 of the Internal Revenue Code.)*



**THE RICK BAY FOUNDATION®**  
*for Excellence in Eyecare Education*

*(The Rick Bay Foundation for Excellence in Eyecare Education is a nonprofit, tax-exempt organization under section 501(c)(3) of the Internal Revenue Code.)*



# What Downturn?

A slump in refractive surgery from COVID-19 isn't materializing—at least yet. Find out why and how to position your practice.

*Sean McKinney, Senior Editor*

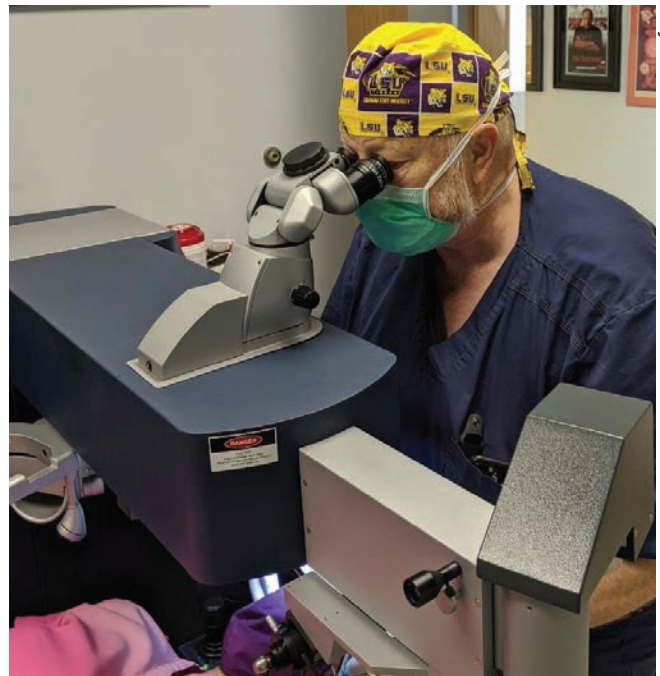**I**n May, when the last of thousands of shuttered ambulatory surgery centers reopened following COVID-19 shutdowns, popular wisdom suggested that refractive surgery procedures would be few and far between. Surgeons spoke of working the phones to get cataract patients back in the chair, mindful of the virus' potential to keep the elderly away unless they were motivated by worsening of cloudy vision. With sudden unemployment and a plummeting economy taking a toll on personal finances, patients weren't expected to pay from their pockets for such elective procedures as LASIK, SMILE and PRK.

Indications suggest that the opposite might be true, however.

"Because each state executed an individual response plan with differing restrictions, naturally the return to refractive practice has been uneven from a national perspective," says Jim Wachtman, chairman of the American Refractive Surgery Council, composed of industry representatives and medical professionals with expertise in developing, researching and using the technologies and techniques behind advanced refrac-

tive—or vision correcting—surgical procedures. "That said, early indications relating to procedure volume are encouraging. Whether or not that is from pent-up patient demand from the shutdown is yet to be determined. However, a preliminary analysis of our consumer data shows interest among prospective refractive patients which may support an uptick in procedures."

Of the six surgeons contacted for this article—hailing from California to India—all but one report unanticipated demand for surgical correction



Mary Bond

William Bond, MD, medical director of Bond Eye Associates in Peoria and Pekin, Illinois, believes that having a refractive suite in his office gives him an advantage over larger institutions that might suspend elective procedures because of future influxes of COVID-19 patients.

of vision among their patients. The one exception, Bryan Lee, MD, JD, who's in private practice at Altos Eye Physicians in Los Altos, California, and an adjunct clinical assistant pro-



**DEXYCU**<sup>®</sup>  
(dexamethasone intraocular  
suspension) 9%

**Ready to support you  
and your patients**

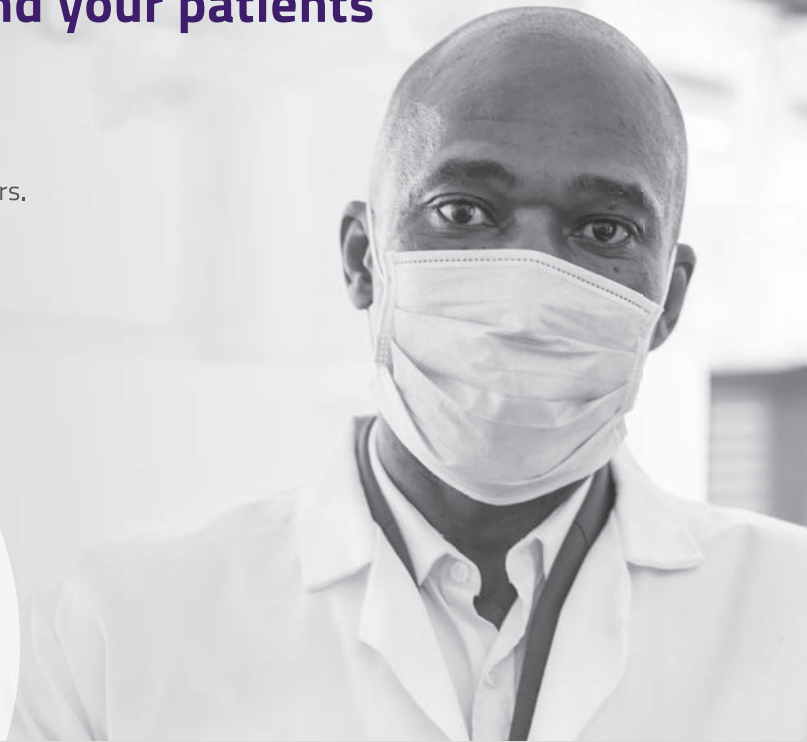*The future may seem like it's filled with questions,* but EyePoint Pharmaceuticals wants to help provide answers. You and your patients need certainty, and there may be concerns about what your practice may experience.

**You may be considering ways to help:**

Ease patient concerns about exposure

Minimize patients touching their faces

Reduce office and pharmacy visits  
for patients and caregivers



**To learn more about how DEXYCU<sup>®</sup> (dexamethasone intraocular suspension) 9% can help, visit [DEXYCU.com](https://www.dexycu.com) or call 1-833-EYEPOINT (1-833-393-7646).**

## INDICATION AND USAGE

DEXYCU<sup>®</sup> (dexamethasone intraocular suspension) 9% is indicated for the treatment of postoperative inflammation.

## IMPORTANT SAFETY INFORMATION

### CONTRAINDICATIONS

None.

### WARNINGS AND PRECAUTIONS

#### Increase in Intraocular Pressure

- Prolonged use of corticosteroids, including DEXYCU, may result in glaucoma with damage to the optic nerve, defects in visual acuity and fields of vision
- Steroids should be used with caution in the presence of glaucoma

#### Delayed Healing

- The use of steroids after cataract surgery may delay healing and increase the incidence of bleb formation
- In those diseases causing thinning of the cornea or sclera, perforations have been known to occur with the use of corticosteroids

#### Exacerbation of Infection

- The use of DEXYCU, as with other ophthalmic corticosteroids, is not recommended in the presence of most active viral diseases of the cornea and conjunctiva including epithelial herpes simplex keratitis (dendritic keratitis), vaccinia, and varicella, and also in mycobacterial infection of the eye and fungal disease of ocular structures

### WARNINGS AND PRECAUTIONS (cont'd)

#### Exacerbation of Infection (cont'd)

- Use of a corticosteroid in the treatment of patients with a history of herpes simplex requires caution and may prolong the course and may exacerbate the severity of many viral infections
- Fungal infections of the cornea are particularly prone to coincidentally develop with long-term local steroid application and must be considered in any persistent corneal ulceration where a steroid has been used or is in use. Fungal culture should be taken when appropriate
- Prolonged use of corticosteroids may suppress the host response and thus increase the hazard of secondary ocular infections. In acute purulent conditions, steroids may mask infection or enhance existing infection

#### Cataract Progression

- The use of corticosteroids in phakic individuals may promote the development of posterior subcapsular cataracts

### ADVERSE REACTIONS

- The most commonly reported adverse reactions occurred in 5-15% of subjects and included increases in intraocular pressure, corneal edema and iritis

**Please see brief summary of full Prescribing Information on adjacent page.**



**DEXYCU (dexamethasone intraocular suspension) 9%,  
for intraocular administration**

**Initial U.S. Approval: 1958**

**BRIEF SUMMARY: Please see package insert for full prescribing information.**

**1 INDICATIONS AND USAGE**

DEXYCU (dexamethasone intraocular suspension) 9% is indicated for the treatment of postoperative inflammation.

**4 CONTRAINDICATIONS**

None.

**5 WARNINGS AND PRECAUTIONS**

**5.1 Increase in Intraocular Pressure**

Prolonged use of corticosteroids including DEXYCU may result in glaucoma with damage to the optic nerve, defects in visual acuity and fields of vision. Steroids should be used with caution in the presence of glaucoma.

**5.2 Delayed Healing**

The use of steroids after cataract surgery may delay healing and increase the incidence of bleb formation. In those diseases causing thinning of the cornea or sclera, perforations have been known to occur with the use of corticosteroids.

**5.3 Exacerbation of Infection**

The use of DEXYCU, as with other ophthalmic corticosteroids, is not recommended in the presence of most active viral diseases of the cornea and conjunctiva including epithelial herpes simplex keratitis (dendritic keratitis), vaccinia, and varicella, and also in mycobacterial infection of the eye and fungal disease of ocular structures.

Employment of a corticosteroid medication in the treatment of patients with a history of herpes simplex requires caution. Use of ocular steroids may prolong the course and may exacerbate the severity of many viral infections of the eye (including herpes simplex). Fungal infections of the cornea are particularly prone to develop coincidentally with long-term local steroid application. Fungus invasion must be considered in any persistent corneal ulceration where a steroid has been used or is in use. Fungal culture should be taken when appropriate.

Prolonged use of corticosteroids may suppress the host response and thus increase the hazard of secondary ocular infections. In acute purulent conditions, steroids may mask infection or enhance existing infection.

**5.4 Cataract Progression**

The use of corticosteroids in phakic individuals may promote the development of posterior subcapsular cataracts.

**6 ADVERSE REACTIONS**

The following adverse reactions are described elsewhere in the labeling:

- Increase in Intraocular Pressure [see Warnings and Precautions (5.1)]
- Delayed Healing [see Warnings and Precautions (5.2)]
- Infection Exacerbation [see Warnings and Precautions (5.3)]
- Cataract Progression [see Warnings and Precautions (5.4)]

**6.1 Clinical Trials Experience**

Because clinical studies are conducted under widely varying conditions, adverse reaction rates observed in the clinical studies of a drug cannot be directly compared to rates in the clinical studies of another drug and may not reflect the rates observed in practice.

The following adverse events rates are derived from three clinical trials in which 339 patients received the 517 microgram dose of DEXYCU. The most commonly reported adverse reactions occurred in 5-15% of subjects and included increases in intraocular pressure, corneal edema and iritis. Other ocular adverse reactions occurring in 1-5% of subjects included, corneal endothelial cell loss, blepharitis, eye pain, cystoid macular edema, dry eye, ocular inflammation, posterior capsule opacification, blurred vision, reduced visual acuity, vitreous floaters, foreign body sensation, photophobia, and vitreous detachment.

**8 USE IN SPECIFIC POPULATIONS**

**8.1 Pregnancy**

Risk Summary

There are no adequate and well-controlled studies of DEXYCU (dexamethasone intraocular suspension) in pregnant women. Topical ocular administration of dexamethasone in mice and rabbits during the period of organogenesis produced cleft palate and embryofetal death in mice and malformations of abdominal wall/intestines and kidneys in rabbits at doses 7 and 5 times higher than the injected recommended human ophthalmic dose (RHOD) of DEXYCU (517 micrograms dexamethasone), respectively [see Data in the full prescribing information].

In the US general population the estimated background risk of major birth defects and miscarriage in clinically recognized pregnancies is 2 to 4% and 15 to 20%, respectively.

**8.2 Lactation**

Risk Summary

Systemically administered corticosteroids are present in human milk and can suppress growth, interfere with endogenous corticosteroid production, or cause other unwanted effects. There is no information regarding the presence of injected DEXYCU in human milk, the effects on breastfed infants, or the effects on milk production to inform risk of DEXYCU to an infant during lactation. The developmental and health benefits of breastfeeding should be considered, along with the mother's clinical need for DEXYCU and any potential adverse effects on the breastfed child from DEXYCU.

**8.4 Pediatric Use**

Safety and effectiveness of DEXYCU in pediatric patients have not been established.

**8.5 Geriatric Use**

No overall differences in safety or effectiveness have been observed between older and younger patients.

Manufactured for: EyePoint Pharmaceuticals US, Inc, Watertown, MA 02472

fessor of ophthalmology at Stanford University, has noticed neither increased nor decreased demand. “But refractive is a small percentage of my practice,” he adds.

Meanwhile, Eric Donnenfeld, MD, of OCLI Vision, who operates at Island Eye Surgicenter in Westbury, New York, says the number of LASIK and PRK procedures has increased by 10 to 20 percent at OCLI since he and his colleagues reopened. “For these patients, I think having their vision rehabilitated gives them a sense of control that they need in today’s environment,” he says. “They’ve lost control over a lot of their lives. And this is one thing that they can do to make their lives better and more in control.”

In this report, surgeons who have experienced recent success in this segment of their practices offer advice on how to identify and meet changing needs in your patient population.

### Why More Interest?

Surgeons cite a number of theories on why more patients are electing to undergo refractive surgery now. Below are some trends surgeons have noticed, plus advice on how you might tap into them.

- **It’s “now or never.”** Patients frustrated by being shut in during the spring may have grown concerned that future lockdowns will block their access to vision correction during the next year or so. William Bond, MD, FASC, medical director of Bond Eye Associates in Peoria and Pekin, Illinois, recommends asking patients how the lockdown has affected them, specifically how it’s affected their vision. “A lot of patients think about getting LASIK but don’t get around to making a decision,” he says. “This environment has given them a little push. I’ve certainly seen it in my practice. For a lot of people, this is like thinking about buying a car. You think

about it and you think about it and then, all of a sudden, you do it. This seems to be a time when patients are making those kinds of decisions.”

- **Eliminating glasses and contact lenses.** David R. Hardten, MD, FACS, in private practice at Minnesota Eye Consultants in Minneapolis, sees more patients than usual who are fed up with their spectacles. “They’re experiencing increased frustration from having to wear masks and shields at work and everywhere else they go,” he says. “They’re dealing with the fogging of their glasses and the tendency of others to concentrate more on their eyes (potentially making these patients more self-conscious). Overall, patients are dealing with a sense of loss of control that they want to avoid.”

Contact lenses may also be a concern for patients worried about infection spread, surgeons say. Eliminating the need to insert, adjust and remove lenses could motivate them to consider a surgical alternative. “Refractive surgery demand during the COVID-19 pandemic doesn’t seem to be waning in Minnesota,” asserts Dr. Hardten.

- **Not everyone is broke.** Surgeons note that many patients have more cash in their pockets from government grants and expanded unemployment benefits. “When they were laid off, some people ended up making more money than what they were earning when they were working,” notes Dr. Donnenfeld. “Some people have also seen their expenses reduced. No money is going out for childcare, gasoline for the car, eating at restaurants or other activities.”

### Demographic Needs

Surgeons have also succeeded by responding to the special needs of patients. For example, Yuri McKee, MD, MS, a corneal and refractive surgeon at East Valley Ophthalmol-

ogy in Mesa, Arizona, notes that he was spreading himself too thin by offering corneal refractive procedures in Mesa, populated by a high concentration of senior citizens.

“I wasn’t doing a lot of corneal refractive surgery because I was doing a lot of cataract/refractive surgery,” says Dr. McKee. “But the pandemic has kind of pushed me over the edge. Just about all I’m doing now is cataract-refractive procedures.”

The only pure refractive procedures he performs now are natural lens exchanges for occasional severe hyperopes who want to get rid of their thick glasses. The rest of his surgical base now consists entirely of cataract patients. COVID-19 has compelled him to reduce surgery from an average of four cases to two cases per hour, he says. COVID-related paperwork, mandatory COVID-19 testing in Arizona and infection control measures have slowed down the flow. He can only operate on Mondays because of all the pathology he has to manage on the other days. Nonetheless, he is satisfied with the transition to cataract-refractive surgery only.

“We made some good changes,” Dr. McKee says. “My premium conversion rate has vastly improved. I don’t know why people are choosing these options—perhaps, at a time like this, they realize that life is short and they might as well live happily.”

Dr. Yuri’s presentation has made a difference. “I don’t let any astigmatism go unnoticed by patients. I tell them: ‘Here’s your astigmatism. You can see it right here. You’re going to need to fix it one way or another. You have to fix it. The question is: How will you fix it?’ With glasses, contact lenses, LASIK or during cataract surgery?” He gives them a week to consider the options and asks them what their preference might be when they return for testing. “We never hard-sell,” he points out. “But now I’m implanting more torics than regular IOLs.”

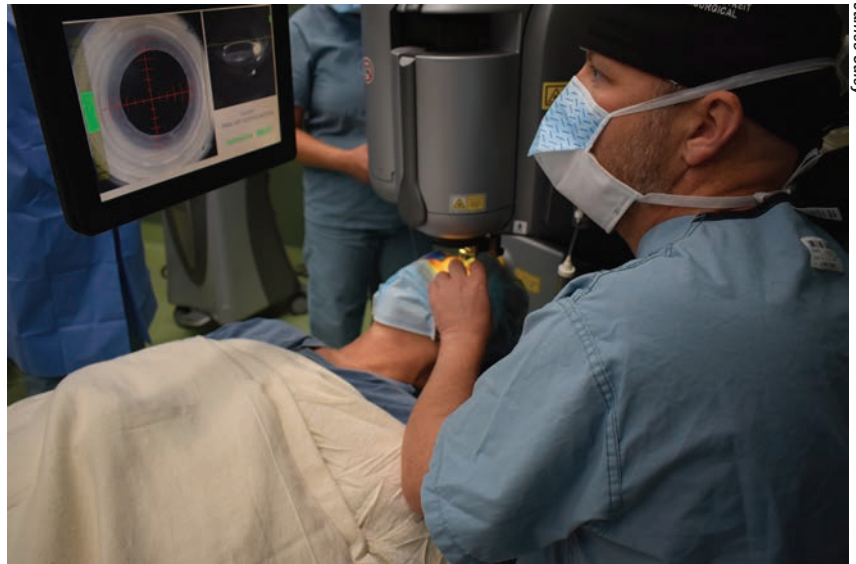
# REVIEW | Refractive/Cataract Rundown

Part of his success has made been possible by the Lensar femtosecond laser, which he uses for all patients at no charge during the capsulotomy and the first half of surgery; for an extra fee he also completes the surgery with the laser.

“There seems to be no end to the demand for these procedures,” he says. “Our only limitations now are limitations imposed by COVID-19, available surgery time and capacity. But it’s going very well for us.”

Rohit Shetty, MD, PhD, FRCS, vice chairman of Narayana Nethralaya Eye Institute in Bangalore, Karnataka, India, says he has noticed a decided shift in motivation among patients who are seeking refractive surgery at his practice. “I ask every patient why they want to undergo refractive surgery,” he says, noting that the percentage of patients choosing refractive surgery has grown by 18 to 21 percent in his practice during the past two to three months. “In the past, the reasons were related to lifestyle changes. Now I hear from just about every one of these patients that they’re making this choice because they’re working at home all the time, and many more hours, sometimes in poor lighting, always indoors, and not always in the best environments for work. They are tired of using contact lenses and spectacles, and they instead want the best vision they can get.”

Dr. Shetty says he expects this trend to continue. “COVID-19 and the constant work at home has been a wake-up call for these patients,” he says. “It’s as if they’re thinking that they don’t know what’s going to happen next, not even tomorrow, and that this uncertain time is when they should undergo a procedure that they’ve been thinking about for a long time. As long as we can tell the patient that this type of surgery is safe in the COVID-19 environment, we should see



James Culey

With his femtosecond laser, Yuri McKee, MD, is cutting an exclusive cataract-refractive surgery niche at East Valley Ophthalmology in Mesa, Arizona.

more refractive surgery procedures than we’ve ever seen before, despite the economic decline. Safety is a very important concern, however.”

## More on Safety

Above all, busier-than-expected surgeons in the United States, echoing Dr. Shetty, recommend you stick to two essential priorities:

- assuring patients that they will be safe in your surgical suite; and
- ensuring that they really will be safe, by keeping up to date on how the virus is being transmitted in different settings.

Waiting-room chairs have been significantly reduced. Patients are not moved from room to room for testing as much. Every touch point is sanitized, and surgery is practiced under as pristine conditions as possible. “We have the patient wearing a mask, which makes me happy,” says Dr. McKee. He says he has mixed feelings about the pandemic-related administrative burden associated with every patient. Unlike most states, Arizona requires ophthalmologists and other surgeons to have their

patients test negative for COVID-19 before undergoing elective procedures. “We’re certainly taking every precaution,” says Dr. McKee. “It can take seven days to get the results, so it’s been a bit of a challenge for our surgery scheduler. We’re still waiting for the delivery of a COVID-19 testing machine we ordered when the pandemic started. That will reduce testing to 15 minutes in our office.”

Dr. Hardten says helping patients find better solutions for their vision makes the use of precautions very important to him, his colleagues and staff. “We do screening for COVID-19 with a symptom list and by taking temperatures before patients enter the clinic and the laser suite,” he says. “Taping the patient’s mask to reduce fogging of any optics during the surgery is also important. Continued universal precautions, as with any surgery, are also important. So even in this time of COVID-19 spreading through our communities, we can continue to help these patients reduce their dependence on glasses and contacts.”

Exactly what measures should be taken to ensure safety has been a topic of discussion and debate among some





# Achieving IOP control

## What makes once-daily Rhopressa® different<sup>1</sup>

- ◆ **Consistent IOP reduction up to 5 mmHg** in patients across a range of baseline IOPs
- ◆ **Once-daily dosing** to simplify dosing regimens
- ◆ **Mild ocular adverse events and no known contraindications** opens up treatment options
- ◆ **Unique mechanism of action** for patients who may benefit from improved trabecular aqueous outflow

**Rhopressa® is covered for the majority of patients nationwide.<sup>2</sup>**

Visit [Rhopressa.com](http://Rhopressa.com) to learn more about this innovative IOP-lowering treatment.

IOP, intraocular pressure.

### INDICATIONS AND USAGE

Rhopressa® (netarsudil ophthalmic solution) 0.02% is indicated for the reduction of elevated intraocular pressure in patients with open-angle glaucoma or ocular hypertension.

### DOSAGE AND ADMINISTRATION

The recommended dosage is one drop in the affected eye(s) once daily in the evening.

### IMPORTANT SAFETY INFORMATION

#### WARNINGS AND PRECAUTIONS

**Bacterial Keratitis:** There have been reports of bacterial keratitis associated with the use of multiple-dose containers of topical ophthalmic products. These containers had been inadvertently contaminated by patients who, in most cases, had a concurrent corneal disease or a disruption of the ocular epithelial surface.

**Contact Lenses:** Contact lenses should be removed prior to instillation of Rhopressa® and may be inserted 15 minutes following its administration.

### ADVERSE REACTIONS

The most common ocular adverse reaction observed in controlled clinical studies with Rhopressa® dosed once daily was conjunctival hyperemia, reported in 53% of patients. Other common (approximately 20%) adverse reactions were: corneal verticillata, instillation site pain, and conjunctival hemorrhage. Instillation site erythema, corneal staining, blurred vision, increased lacrimation, erythema of eyelid, and reduced visual acuity were reported in 5-10% of patients.

The corneal verticillata seen in Rhopressa®-treated patients were first noted at 4 weeks of daily dosing. This reaction did not result in any apparent visual functional changes. Most corneal verticillata resolved upon discontinuation of treatment.

**Please see brief summary of full Prescribing Information on the adjacent page.**

**References:** **1.** Rhopressa Prescribing Information. Irvine, CA: Aerie Pharmaceuticals, Inc; 2017. **2.** MMIT:12/2018.



## RHOPRESSA® (netarsudil ophthalmic solution) 0.02%

Rx Only

### BRIEF SUMMARY

Consult the Full Prescribing Information for complete product information.

### INDICATIONS AND USAGE

RHOPRESSA® (netarsudil ophthalmic solution) 0.02% is indicated for the reduction of elevated intraocular pressure (IOP) in patients with open-angle glaucoma or ocular hypertension.

### DOSAGE AND ADMINISTRATION

The recommended dosage is one drop in the affected eye(s) once daily in the evening.

If one dose is missed, treatment should continue with the next dose in the evening. Twice a day dosing is not well tolerated and is not recommended. If RHOPRESSA is to be used concomitantly with other topical ophthalmic drug products to lower IOP, administer each drug product at least 5 minutes apart.

### WARNINGS AND PRECAUTIONS

#### Bacterial Keratitis

There have been reports of bacterial keratitis associated with the use of multiple-dose containers of topical ophthalmic products. These containers had been previously contaminated by patients who, in most cases, had a concurrent corneal disease or a disruption of the ocular epithelial surface.

#### Use with Contact Lenses

RHOPRESSA contains benzalkonium chloride, which may be absorbed by soft contact lenses. Contact lenses should be removed prior to instillation of RHOPRESSA and may be reinserted 15 minutes following its administration.

### ADVERSE REACTIONS

#### Clinical Trials Experience

Because clinical studies are conducted under widely varying conditions, adverse reaction rates observed in the clinical studies of a drug cannot be directly compared to rates in the clinical studies of another drug and may not reflect the rates observed in practice.

The most common ocular adverse reaction observed in controlled clinical studies with RHOPRESSA dosed once daily was conjunctival hyperemia which was reported in 53% of patients. Other common (approximately 20%) ocular adverse reactions reported were: corneal verticillata, instillation site pain, and conjunctival hemorrhage. Instillation site erythema, corneal staining, blurred vision, increased lacrimation, erythema of eyelid, and reduced visual acuity were reported in 5-10% of patients.

#### Corneal Verticillata

Corneal verticillata occurred in approximately 20% of the patients in controlled clinical studies. The corneal verticillata seen in RHOPRESSA-treated patients were first noted at 4 weeks of daily dosing. This reaction did not result in any apparent visual functional changes in patients. Most corneal verticillata resolved upon discontinuation of treatment.

### USE IN SPECIFIC POPULATIONS

#### Pregnancy

There are no available data on RHOPRESSA use in pregnant women to inform any drug associated risk; however, systemic exposure to netarsudil from ocular administration is low. Intravenous administration of netarsudil to pregnant rats and rabbits during organogenesis did not produce adverse embryofetal effects at clinically relevant systemic exposures.

#### Animal Data

Netarsudil administered daily by intravenous injection to rats during organogenesis caused abortions and embryofetal lethality at doses  $\geq 0.3$  mg/kg/day (126-fold the plasma exposure at the recommended human ophthalmic dose [RHOD], based on  $C_{max}$ ). The no-observed-adverse-effect-level (NOAEL) for embryofetal development toxicity was 0.1 mg/kg/day (40-fold the plasma exposure at the RHOD, based on  $C_{max}$ ).

Netarsudil administered daily by intravenous injection to rabbits during organogenesis caused embryofetal lethality and decreased fetal weight at 5 mg/kg/day (1480-fold the plasma exposure at the RHOD, based on  $C_{max}$ ). Malformations were observed at  $\geq 3$  mg/kg/day (1330-fold the plasma exposure at the RHOD, based on  $C_{max}$ ), including thoracogastroschisis, umbilical hernia and absent intermediate lung lobe. The NOAEL for embryofetal development toxicity was 0.5 mg/kg/day (214-fold the plasma exposure at the RHOD, based on  $C_{max}$ ).

#### Lactation

There are no data on the presence of RHOPRESSA in human milk, the effects on the breastfed infant, or the effects on milk production. However, systemic exposure to netarsudil following topical ocular administration is low, and it is not known whether measurable levels of netarsudil would be present in maternal milk following topical ocular administration. The developmental and health benefits of breastfeeding should be considered along with the mother's clinical need for RHOPRESSA and any potential adverse effects on the breastfed child from RHOPRESSA.

#### Pediatric Use

Safety and effectiveness in pediatric patients below the age of 18 years have not been established.

#### Geriatric Use

No overall differences in safety or effectiveness have been observed between elderly and other adult patients.

### NONCLINICAL TOXICOLOGY

#### Carcinogenesis, Mutagenesis, Impairment of Fertility

Long-term studies in animals have not been performed to evaluate the carcinogenic potential of netarsudil. Netarsudil was not mutagenic in the Ames test, in the mouse lymphoma test, or in the *in vivo* rat micronucleus test. Studies to evaluate the effects of netarsudil on male or female fertility in animals have not been performed.



Manufactured for: Aerie Pharmaceuticals, Inc., Irvine, CA 92614, U.S.A.

For more information, go to [www.RHOPRESSA.com](http://www.RHOPRESSA.com) or call 1-855-AerieRx (1-855-237-4379).

RHOPRESSA is a registered trademark of Aerie Pharmaceuticals, Inc.  
U.S. Patent Nos.: 8,450,344; 8,394,826; 9,096,569; 9,415,043

**How to Avoid SARS-CoV-2 Infection During Surgery**

Rohit Shetty, MD, PhD, FRCS, vice chairman of Narayana Nethralaya Eye Institute in Bangalore, Karnataka, India, says he believes experiments he recently led at his institution provide definitive recommendations on how to best avoid COVID-19 spread during eye surgery.

Using fluid velocimetry, scientists at the Indian Institute of Science in Bangalore analyzed surgery on artificial anterior chambers and goat eyes in a wet lab model. Fluids were stained with trypan blue to enhance visibility of particles as small as 20 µm, which were recorded with an ultra-high-resolution camera at 20,000 frames per second in a process known as shadowgraphy, commonly used in geology and other fields.

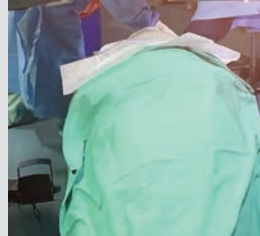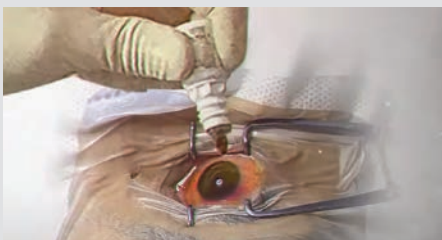During the experiments, microkeratomes used to cut LASIK flaps into the animal eyes generated 20-µm aerosol particles that sprayed up to six feet in multiple directions, while splattered 100 µm droplets fell into a collection device without potential threat of spreading infection, says Dr. Shetty. Femtosecond laser flap cuts, SMILE cuts and photoablation didn't produce aerosol sprays that could theoretically spread the virus, making these surgical techniques safer to use, the study concluded.

Below are the recommendations that the team offered based on their experiments. Step 1 can ensure a much safer surgical theater, even with the use of a microkeratome, Dr. Shetty says. 1. To control the spread of the virus, use 0.24% betadine solution. Wait 10 minutes and wash. This will neutralize the infectious effect of the aerosol, even when a microkeratome is used, Dr. Shetty says.

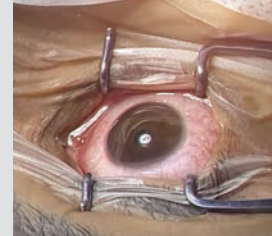
2. Completely cover the patient with a drape. This will protect the surgical area from contamination.
3. Avoid pooling on the ocular surface.
4. Ensure adequate drying of the ocular surface by using a dry sponge.
5. Use a shield that protects the body of surgeon—not just the face—from the spray in order to protect her from aerosol.
6. Remember social distancing in the surgical suite.
7. Change gloves after completing each eye.
8. Remove the patient's gown before he leaves the surgical suite to avoid cross-contamination.
9. Scrub thoroughly after surgery, then rescrub 20 minutes later for the next patients. Take a shower after operating on your last patient.

The team also evaluated the effects of phacoemulsification in terms of spreading infectious aerosol. No combination of wound size and phaco sleeve diameter produced any visible aerosol with the use of phaco operating inside the anterior chamber, Dr. Shetty says. (Photo credit: Narayana Nethralaya Eye Institute)

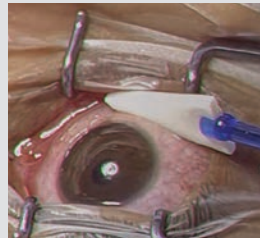1. To control viral spread, use 0.24% betadine solution. Wait 10 minutes and wash.



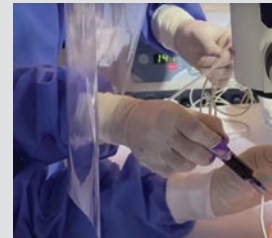2. Completely cover the patient with a drape. This will protect the surgical area from contamination.



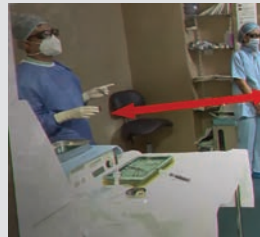3. Avoid pooling on the ocular surface.



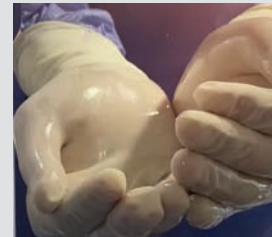4. Ensure adequate drying of ocular surface by using a dry sponge.



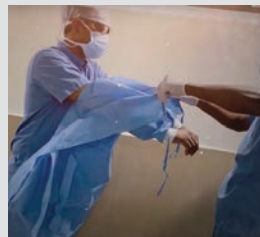
5. Use a shield that protects the body of surgeon—not just the face—from the spray in order to protect her from aerosol.



6. Remember social distancing in the surgical suite.



7. Change gloves after completing each eye.




8. Remove the patient's gown before he leaves the surgical suite to avoid cross-contamination.



9. Scrub thoroughly after surgery, then rescrub 20 minutes later for the next patient. Take a shower after operating on your last patient.

(Continued on page 34)





# Preop Considerations For Pediatric Glaucoma

Childhood glaucoma can be more serious than adult glaucoma, more challenging to diagnose and more difficult to treat.

*Allen D. Beck, MD, Atlanta*

**D**iagnosing and treating pediatric glaucoma presents many challenges that differ from those facing ophthalmologists treating adult glaucoma. For example, it's notoriously easy for an adult patient to have glaucoma without realizing it; the glaucoma is usually symptomless except for vision loss after the glaucoma has gotten pretty advanced. In contrast, very young children with glaucoma tend to display symptoms.

Because the eye is growing larger during infancy, it's somewhat stretchable, and glaucomatous pressure can cause it to enlarge. In addition, the cornea can swell and become cloudy. (Severe cloudiness may indicate a condition such as Peters' Anomaly rather than glaucoma, but like other congenital eye conditions, Peters' Anomaly can eventually lead to glaucoma.) The eye may tear, and the child may become sensitive to light. (On the positive side, the fact that early childhood glaucoma often produces symptoms can cause parents to notice that something is wrong.)

Several issues arise when we're faced with an infant or child with possible glaucoma. Those include

getting a measurement of the IOP (not always easy to do with a young child); diagnosing the problem; deciding whether to address the glaucoma with topical drops or surgery; and deciding whether—and how often—anesthesia can safely be used. Here, I'd like to share some of my experience dealing with these issues.

## Childhood Glaucomas

Primary congenital glaucoma is the most common type of childhood glaucoma. PCG is caused by a congenital anomaly, and in the United States it appears in one out of every 10,000 to 50,000 children and is usually sporadic. It's more common in some other countries where consanguineous marriage is accepted, because it's tied to an autosomal recessive gene. In that setting, PCG can appear in as many as one out of every 2,500 children.

The other type of childhood glaucoma we most often treat—though less often than PCG—is glaucoma following congenital cataract surgery. This is actually *less* common in developing countries than it is here,

simply because it's tied to the timing of the congenital cataract surgery. The later the cataract surgery is done, the less likely the patient is to have a good visual outcome—but the odds of post-surgical glaucoma decrease as well. (I'm currently working on the 10-year Infant Aphakia Treatment Study; the five-year data confirm that performing unilateral cataract removal at a younger age increases the risk of glaucoma-related adverse events.<sup>1</sup>) In developing countries, diagnosis and referral of congenital cataract is often delayed, lowering the likelihood of postsurgical glaucoma. In the United States and Europe, where childhood cataracts tend to be caught and treated earlier, glaucoma following congenital cataract surgery is pretty common.

Beyond these two types of pediatric glaucoma, there are a variety of others related to other defects of the eye. Basically, if something affects the anterior segment of the eye during development, there's usually an association with glaucoma, and some childhood glaucomas are associated with systemic diseases or syndromes. These are less common than the

first two types I described, but they do occur—and they're often more challenging to treat.

## Pediatric Glaucoma Reclassified

It's worth noting that the classification of childhood glaucoma has changed over the past decade. The previous classification system was very involved and detailed; it listed any condition that could be associated with childhood-onset glaucoma. The new classification system (*right*), created jointly by the Childhood Glaucoma Research Network and the World Glaucoma Association, is an attempt to put those conditions into larger groups, based on related mechanisms. This is especially helpful when studying pediatric glaucoma, because many of the glaucomas are so rare that you can't easily compare one to another unless you group them by related mechanisms.

The new system divides pediatric glaucoma into two types: primary and secondary. Primary childhood glaucomas include primary congenital glaucoma and juvenile open-angle glaucoma. Juvenile open-angle glaucoma is an autosomal dominant form caused by a mutation in the myocilin gene; it tends to run in families. The eye looks normal, but the fluid drainage doesn't function normally. It's very aggressive, occurring in childhood or early adulthood, and without surgical intervention it frequently results in blindness. In childhood it's less common than primary congenital glaucoma, but as noted, it often presents in early adulthood.

Secondary childhood glaucomas include:

- **Glaucomas associated with non-acquired ocular anomalies.** This category refers to a number of different front-of-the-eye disorders present at birth, such as aniridia or Axenfeld-Rieger anomaly. Roughly 50 percent of patients with an abnor-

## International Classification of Childhood Glaucomas\*

### Primary Childhood Glaucomas

Primary Congenital Glaucoma (PCG)  
Juvenile Open Angle Glaucoma (JOAG)

### Secondary Childhood Glaucomas

Glaucoma Associated with Non-acquired Ocular Anomalies  
Glaucoma Associated with Non-acquired Systemic Disease or Syndrome  
Glaucoma Associated with Acquired Condition  
Glaucoma Following Cataract Surgery

\* Created jointly by the Childhood Glaucoma Research Network and the World Glaucoma Association

mality in the front part of the eye end up with glaucoma.

- **Glaucomas associated with a non-acquired systemic disease or syndrome.** Childhood glaucoma can be associated with systemic diseases and syndromes present since birth, such as congenital rubella. In a developing country, where immunization is less widespread, congenital rubella is actually a fairly common cause of secondary glaucoma.

- **Glaucomas associated with an acquired condition.** This refers to something that happens after birth, such as trauma to the eye, uveitis or retinopathy of prematurity. (In ROP, although the baby is born prematurely, the disease develops afterwards, and it can cause a secondary angle-closure form of glaucoma.) Less-common conditions such as tumors can also be associated with childhood glaucoma.

- **Glaucoma that occurs following congenital cataract surgery.** Glaucoma following cataract surgery is technically an acquired condition, but it's so important that we made it a separate category. In these patients, the cataract is there at birth, but the surgery is done after birth. We know it's the surgery that induces the glaucoma, because if you don't operate on the cataract, glaucoma usually doesn't occur.

## Differential Diagnosis

Diagnosing childhood glaucoma

can be tricky, in part because other conditions can mimic it by making the cornea cloudy or causing symptoms such as tearing. Problems that can cause corneal clouding include birth trauma, Peters' anomaly, and sclerocornea and lysosomal storage diseases. Birth trauma can be caused by forceps delivery, and this can also mimic glaucoma. If the forceps happens to clamp across the baby's head and eye, it can damage the cornea and cause swelling. (The swelling eventually resolves, but it can lead to other problems such as amblyopia.)

Some lysosomal storage diseases, in which the patient has an absence or deficiency of an enzyme, leading to inappropriate storage of material in various cells of the body, are associated with corneal clouding. The abnormal accumulation of excess cell products can lead to cells dying and significant medical problems throughout the body, including in the brain and kidneys; these diseases usually lead to death at a young age. Fortunately, these are rare conditions. It's a challenging diagnosis to make, requiring the assistance of pediatricians and geneticists.

Other problems such as nasolacrimal duct obstruction, conjunctivitis and corneal abrasion or keratitis can cause tearing and light sensitivity that can also mimic childhood glaucoma. Nasolacrimal duct obstruction

(Continued on page 25)



**FIRST AND ONLY**

**FDA-APPROVED TREATMENT FOR THYROID EYE DISEASE**

# IT'S TIME FOR A BREAKTHROUGH IT'S TIME FOR TEPEZZA

**TEPEZZA is proven to<sup>1-4</sup>:**

- » Decrease proptosis<sup>1</sup>
- » Improve diplopia<sup>1</sup>
- » Reduce orbital pain, redness, and swelling<sup>2,3</sup>
- » Improve functional vision and patient appearance<sup>2,3</sup>

...in patients with Thyroid Eye Disease (TED), without concomitant steroids (vs placebo at Week 24).<sup>2-4</sup>

[Learn more at TEDbreakthrough.com](https://tedbreakthrough.com)

## INDICATION

TEPEZZA is indicated for the treatment of Thyroid Eye Disease.

## IMPORTANT SAFETY INFORMATION

### Warnings and Precautions

**Infusion Reactions:** TEPEZZA may cause infusion reactions. Infusion reactions have been reported in approximately 4% of patients treated with TEPEZZA. Reported infusion reactions have usually been mild or moderate in severity. Signs and symptoms may include transient increases in blood pressure, feeling hot, tachycardia, dyspnea, headache, and muscular pain. Infusion reactions may occur during an infusion or within 1.5 hours after an infusion. In patients who experience an infusion reaction, consideration should be given to premedicating with an antihistamine, antipyretic, or corticosteroid and/or administering all subsequent infusions at a slower infusion rate.

**Preexisting Inflammatory Bowel Disease:** TEPEZZA may cause an exacerbation of preexisting inflammatory bowel disease (IBD). Monitor patients with IBD for flare of disease. If IBD exacerbation is suspected, consider discontinuation of TEPEZZA.


**References:** 1. TEPEZZA (teprotumumab-trbw) [prescribing information] Horizon. 2. Douglas RS, Kahaly GJ, Patel A, et al. Teprotumumab for the treatment of active thyroid eye disease. *N Engl J Med.* 2020;382(4):341-352. 3. Smith TJ, Kahaly GJ, Ezra DG, et al. Teprotumumab for thyroid-associated ophthalmopathy. *N Engl J Med.* 2017;376(18):1748-1761. 4. Smith TJ, Kahaly GJ, Ezra DG, et al. Teprotumumab for thyroid-associated ophthalmopathy. *N Engl J Med.* 2017;376(18) (suppl):1748-1761. [https://www.nejm.org/doi/suppl/10.1056/NEJMoal614949/suppl\\_file/nejmoal614949\\_appendix.pdf](https://www.nejm.org/doi/suppl/10.1056/NEJMoal614949/suppl_file/nejmoal614949_appendix.pdf).





# TEPEZZA™

teprotumumab-trbw



Significantly greater proptosis responder rate\* (Study 2)<sup>1,2</sup>

TEPEZZA

Placebo

83%

vs

10%

TEPEZZA (n=41)

Placebo (n=42)

$P < 0.001$  at Week 24

\*Both the safety and efficacy of TEPEZZA were evaluated in 2 randomized, double-masked, placebo-controlled clinical trials (Studies 1 and 2) consisting of 171 patients with TED (84 were randomized to TEPEZZA and 87 to placebo). The primary endpoint in Studies 1 and 2 was proptosis responder rate, defined as having a  $\geq 2$ -mm reduction from baseline in proptosis in the study eye at Week 24 without deterioration ( $\geq 2$ -mm increase in proptosis) in the non-study eye.<sup>1</sup>

**Hyperglycemia:** Increased blood glucose or hyperglycemia may occur in patients treated with TEPEZZA. In clinical trials, 10% of patients (two-thirds of whom had preexisting diabetes or impaired glucose tolerance) experienced hyperglycemia. Hyperglycemic events should be managed with medications for glycemic control, if necessary. Monitor patients for elevated blood glucose and symptoms of hyperglycemia while on treatment with TEPEZZA. Patients with preexisting diabetes should be under appropriate glycemic control before receiving TEPEZZA.

### Adverse Reactions

The most common adverse reactions (incidence  $\geq 5\%$  and greater than placebo) are muscle spasm, nausea, alopecia, diarrhea, fatigue, hyperglycemia, hearing impairment, dysgeusia, headache, and dry skin.

**Please see Brief Summary of Prescribing Information for TEPEZZA on following page.**



# TEPEZZA™

## teprotumumab-trbw

For injection, for intravenous use

**Brief Summary - Please see the TEPEZZA package insert for full prescribing information.**

### INDICATIONS AND USAGE

TEPEZZA is indicated for the treatment of Thyroid Eye Disease.

### WARNINGS AND PRECAUTIONS

#### Infusion Reactions

TEPEZZA may cause infusion reactions. Infusion reactions have been reported in approximately 4% of patients treated with TEPEZZA. Signs and symptoms of infusion-related reactions include transient increases in blood pressure, feeling hot, tachycardia, dyspnea, headache and muscular pain. Infusion reactions may occur during any of the infusions or within 1.5 hours after an infusion. Reported infusion reactions are usually mild or moderate in severity and can usually be successfully managed with corticosteroids and antihistamines. In patients who experience an infusion reaction, consideration should be given to pre-medicating with an antihistamine, antipyretic, corticosteroid and/or administering all subsequent infusions at a slower infusion rate.

#### Exacerbation of Preexisting Inflammatory Bowel Disease

TEPEZZA may cause an exacerbation of preexisting inflammatory bowel disease (IBD). Monitor patients with IBD for flare of disease. If IBD exacerbation is suspected, consider discontinuation of TEPEZZA.

#### Hyperglycemia

Hyperglycemia or increased blood glucose may occur in patients treated with TEPEZZA. In clinical trials, 10% of patients (two-thirds of whom had preexisting diabetes or impaired glucose tolerance) experienced hyperglycemia. Hyperglycemic events should be controlled with medications for glycemic control, if necessary.

Monitor patients for elevated blood glucose and symptoms of hyperglycemia while on treatment with TEPEZZA. Patients with preexisting diabetes should be under appropriate glycemic control before receiving TEPEZZA.

### ADVERSE REACTIONS

The following clinically significant adverse reactions are described elsewhere in the labeling:

- Infusion Reactions [see Warnings and Precautions]
- Exacerbation of Inflammatory Bowel Disease [see Warnings and Precautions]
- Hyperglycemia [see Warnings and Precautions]

#### Clinical Trials Experience

Because clinical trials are conducted under widely varying conditions, adverse reaction rates observed in the clinical trials of a drug cannot be directly compared to rates in the clinical trials of another drug and may not reflect the rates observed in practice.

The safety of TEPEZZA was evaluated in two randomized, double-masked, placebo-controlled clinical studies (Study 1 [NCT:01868997] and Study 2 [NCT:03298867]) consisting of 170 patients with Thyroid Eye Disease (84 received TEPEZZA and 86 received placebo). Patients were treated with TEPEZZA (10 mg/kg for first infusion and 20 mg/kg for the remaining 7 infusions) or placebo given as an intravenous infusion every 3 weeks for a total of 8 infusions. The majority of patients completed 8 infusions (89% of TEPEZZA patients and 93% of placebo patients).

The most common adverse reactions (≥5%) that occurred at greater incidence in the TEPEZZA group than in the control group during the treatment period of Studies 1 and 2 are summarized in Table 1.

**Table 1. Adverse Reactions Occurring in 5% or More of Patients Treated with TEPEZZA and Greater Incidence than Placebo**

Adverse Reactions	TEPEZZA N=84 N (%)	Placebo N=86 N (%)
Muscle spasms	21 (25%)	6 (7%)
Nausea	14 (17%)	8 (9%)
Alopecia	11 (13%)	7 (8%)
Diarrhea	10 (12%)	7 (8%)
Fatigue <sup>a</sup>	10 (12%)	6 (7%)
Hyperglycemia <sup>b</sup>	8 (10%)	1 (1%)
Hearing impairment <sup>c</sup>	8 (10%)	0
Dysgeusia	7 (8%)	0
Headache	7 (8%)	6 (7%)
Dry skin	7 (8%)	0

a - Fatigue includes asthenia

b - Hyperglycemia includes blood glucose increase

c - Hearing impairment (includes deafness, eustachian tube dysfunction, hyperacusis, hypoacusis and autophony)

#### Immunogenicity

As with all therapeutic proteins, there is potential for immunogenicity. The detection of antibody formation is highly dependent on the sensitivity and specificity of the assay.

In a placebo-controlled study with TEPEZZA, 1 of 42 patients treated with placebo had detectable levels of antidrug antibodies in serum. In the same study, none of the 41 patients treated with TEPEZZA had detectable levels of antidrug antibodies in serum.

### USE IN SPECIFIC POPULATIONS

#### Pregnancy

##### Risk Summary

Based on findings in animals and its mechanism of action inhibiting insulin-like growth factor-1 receptor (IGF-1R), TEPEZZA may cause fetal harm when administered to a pregnant woman. Adequate and well-controlled studies with TEPEZZA have not been conducted in pregnant women. There is insufficient data with TEPEZZA use in pregnant women to inform any drug associated risks for adverse developmental outcomes. In utero teprotumumab exposure in cynomolgus monkeys dosed once weekly with teprotumumab throughout pregnancy resulted in external and skeletal abnormalities. Teprotumumab exposure may lead to an increase in fetal loss [see Data]. Therefore, TEPEZZA should not be used in pregnancy, and appropriate forms of contraception should be implemented prior to initiation, during treatment and for 6 months following the last dose of TEPEZZA.

If the patient becomes pregnant during treatment, TEPEZZA should be discontinued and the patient advised of the potential risk to the fetus.

The background rate of major birth defects and miscarriage is unknown for the indicated population. In the U.S. general population, the estimated background risks of major birth defects and miscarriage in clinically recognized pregnancies are 2-4% and 15-20%, respectively.

##### Data

##### Animal Data

In an abridged pilot embryofetal development study, seven pregnant cynomolgus monkeys were dosed intravenously at one dose level of teprotumumab, 75 mg/kg (2.8-fold the maximum recommended human dose [MRHD] based on AUC) once weekly from gestation day 20 through the end of gestation. The incidence of abortion was higher for the teprotumumab treated group compared to the control group. Teprotumumab caused decreased fetal growth during pregnancy, decreased fetal size and weight at caesarean section, decreased placental weight and size, and decreased amniotic fluid volume. Multiple external and skeletal abnormalities were observed in each exposed fetus, including: misshapen cranium, closely set eyes, micrognathia, pointing and narrowing of the nose, and ossification abnormalities of skull bones, sternbrae, carpals, tarsals and teeth. The test dose, 75 mg/kg of

teprotumumab, was the maternal no observed adverse effect level (NOAEL).

Based on mechanism of action inhibiting IGF-1R, postnatal exposure to teprotumumab may cause harm.

### Lactation

#### Risk Summary

There is no information regarding the presence of TEPEZZA in human milk, the effects on the breastfed infant or the effects on milk production.

### Females and Males of Reproductive Potential

#### Contraception

##### Females

Based on its mechanism of action inhibiting IGF-1R, TEPEZZA may cause fetal harm when administered to a pregnant woman (see Use in Specific Populations). Advise females of reproductive potential to use effective contraception prior to initiation, during treatment with TEPEZZA and for 6 months after the last dose of TEPEZZA.

#### Pediatric Use

Safety and effectiveness have not been established in pediatric patients.

#### Geriatric Use

Of the 171 patients in the two randomized trials, 15% were 65 years of age or older; the number of patients 65 years or older was similar between treatment groups. No overall differences in efficacy or safety were observed between patients 65 years or older and younger patients (less than 65 years of age).

### OVERDOSAGE

No information is available for patients who have received an overdosage.

### PATIENT COUNSELING INFORMATION

#### Embryo-Fetal Toxicity

Advise females of reproductive potential that TEPEZZA can cause harm to a fetus and to inform their healthcare provider of a known or suspected pregnancy.

Educate and counsel females of reproductive potential about the need to use effective contraception prior to initiation, during treatment with TEPEZZA and for 6 months after the last dose of TEPEZZA.

#### Infusion-Related Reactions

Advise patients that TEPEZZA may cause infusion reactions that can occur at any time. Instruct patients to recognize the signs and symptoms of infusion reaction and to contact their healthcare provider immediately for signs or symptoms of potential infusion-related reactions.

#### Exacerbation of Inflammatory Bowel Disease

Advise patients on the risk of inflammatory bowel disease (IBD) and to seek medical advice immediately if they experience diarrhea, with or without blood or rectal bleeding, associated with abdominal pain or cramping/colic, urgency, tenesmus or incontinence.

#### Hyperglycemia

Advise patients on the risk of hyperglycemia and, if diabetic, discuss with healthcare provider to adjust glycemic control medications as appropriate. Encourage compliance with glycemic control.

Manufactured by:  
Horizon Therapeutics Ireland DAC  
Dublin, Ireland  
U.S. License No. 2022

Distributed by:  
Horizon Therapeutics USA, Inc.  
Lake Forest, IL 60045

TEPEZZA and the HORIZON logo are trademarks owned by or licensed to Horizon.

© 2020 Horizon Therapeutics plc L-TEP-00018 03/20



(Continued from page 21)

is very common in babies and young children, but a careful exam will usually clarify the nature of the problem.

Finally, congenital optic nerve anomalies can be misleading; some look like glaucomatous damage. However, this isn't too hard to distinguish from true glaucoma, because you won't find elevated pressure or other signs of glaucoma.

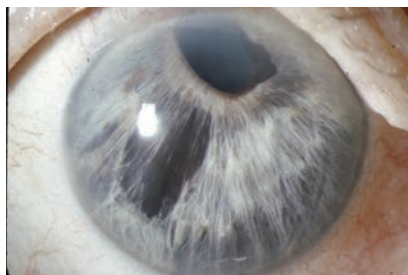Once a child is brought in to see you, measuring the intraocular pressure is key to supporting or ruling out a diagnosis. Getting the pressure measurement with a toddler—in particular, those from one to three years of age—can be very challenging because they squeeze their eyes shut and fight to prevent you from touching them. If you do force your way in to take a reading, their resistance artificially raises the pressure.

In general, measuring a feeding or sleeping infant is ideal, and a handheld rebound tonometer, such as the iCare tonometer, has been shown to reduce the likelihood of having to conduct an examination under anesthesia (EUA).<sup>2</sup> My experience agrees with that conclusion. Rebound tonometry can often be done while the child is distracted, and it doesn't require topical anesthetic drops, which burn (making the child very unhappy).

If getting the pressure is impossible, an EUA is standard of care, based on your level of suspicion. However, you'll have to take into account that general anesthesia tends to cause a decrease in IOP.

### Managing the Disease

When treating an adult for glaucoma, the options usually come down to medications, laser trabeculoplasty or surgery. Most ophthalmologists prescribe medications first, although some will consider starting with the laser. (SLT as a primary treatment in



A child with an Axenfeld-Rieger anomaly (shown above) may develop glaucoma.

adults is supported by some data in the literature.) [For more on this, see the point-counterpoint on p. 48.]

In children, laser trabeculoplasty isn't helpful. If you develop glaucoma later in life, it means your trabecular meshwork aqueous drainage had been working pretty well, but then it got a little worse, leading to increased IOP. In contrast, if you develop glaucoma early in life, things are usually pretty bad; the drain's not working well at all. For example, in juvenile open-angle glaucoma, the angle is severely dysfunctional and pressures are really high; small case series haven't demonstrated any benefit to LT in these patients. (A laser-based treatment is also harder to perform, especially in young children, where it would require anesthesia.)

For many childhood glaucomas, medication is a reasonable primary treatment, moving to surgery if the problem worsens. However, surgery is standard of care for treating primary congenital glaucoma, because it often responds very well to surgery. The effect of medication on PCG is usually insufficient.

Another aspect of managing primary congenital glaucoma is that it's associated with corneal edema. If a child has corneal edema in one eye, the result can be amblyopia, so after you address the glaucoma, you also have to address the weak vision in that eye caused by the visual blockage. Sending good visual information to the brain is essential for developing good vision, especially in the first

three months of life when the brain and retina are developing together; if that's interrupted for any reason during the first 8 to 10 years of life, a child can develop amblyopia.

Amblyopia is potentially reversible, with the use of patching, topical drops such as atropine, and putting the proper spectacle or contact lens correction in front of the eye, but it's a lot of work. Of course, if you don't address it in a timely manner, it can become impossible to reverse.

### The Anesthesia Dilemma

Relying on surgery to address primary congenital glaucoma—the most common form of childhood glaucoma—leads to an additional challenge: deciding when, and how often, to use anesthesia on your young patient. Putting a child to sleep is necessary for a surgical procedure, but sometimes we even need to do a basic exam under anesthesia because the child won't cooperate.

Given that anesthesia comes with potential risks, this raises the question of how often you should do a pediatric glaucoma exam under anesthesia. In general, it's a good idea to avoid putting any patient to sleep too many times, but the particular concern here is that there might be neurodevelopmental effects from early exposure to anesthesia—especially repeated exposure. The problem is, it's kind of a catch-22. The children that you have to put to sleep already have potential neurodevelopmental issues as a result of the glaucoma; if you *don't* put the child to sleep to address the glaucoma, you may not be protecting him from those problems anyway.

The risks associated with anesthesia can be exacerbated by other pre-existing health concerns. For example, if you're treating a child with cerebral palsy, the child already has a neurodevelopmental delay. The question is, will anesthesia have



any impact on that? Some studies have found evidence suggestive of a negative impact, but didn't confirm the association.<sup>3</sup> One study looked into the impact of a single anesthesia on otherwise healthy children younger than 36 months and found no statistically significant neurocognitive or behavioral differences later in life compared to children with no anesthesia exposure.<sup>4</sup> That's encouraging.

In my experience, it's necessary to put children with glaucoma to sleep—especially infants and very young children. Clearly anesthesia is necessary if you need to operate, and there are times when you have to put patients to sleep to examine them. Furthermore, most of the time you'll need to perform more exams down the road, and those may also require anesthesia. Ultimately, given the concerns surrounding anesthesia, you need to consider each procedure and exam carefully in the context of what's going on with that patient.

### Is Bilateral Surgery Safe?

One of the issues that comes up when treating childhood glaucoma is deciding whether or not to do bilateral surgery (assuming both eyes need treatment). Some doctors do bilateral surgery in the setting of primary congenital glaucoma, which is considered acceptable as a way to avoid additional surgeries. However, I only do bilateral surgery occasionally, for a number of reasons:

- **Doing bilateral surgery will require keeping the child asleep for a longer time.** This potentially increases the likelihood of unintended consequences. Of course, this is a trade-off; if you avoid doing a bilateral procedure, you'll have to use anesthesia again later when you perform the second surgery. (Most of the studies that look at bilateral pediatric surgery don't take into account the frequent need

to do exams under anesthesia later.) Nevertheless, it may be safer to use anesthesia for shorter periods of time. Also, if you do bilateral surgery, you lose several advantages that come with performing sequential surgery:

- **If you just operate on one eye, you can see the result before operating on the second eye.** If a problem arises, you can take steps to ensure it doesn't occur during the second surgery.

- **Doing one eye right after the other opens the door to cross-contamination.** One of the risks associated with bilateral surgery is the possibility that any issue with one eye—such as endophthalmitis—could end up also affecting the other eye, despite your best efforts to prevent it.

- **If there's a complication, you don't want both eyes disabled.** If you do surgery in both eyes and have complications in both eyes, then the child is visually impaired in both eyes until the complication is resolved. That might impact the child's function and development.

There are situations in which I'd be more likely to consider performing bilateral surgery—particularly if the child has short-term risks tied to anesthesia, such as asthma or heart problems. Also, some patients are refractory; they're not responding to treatment, and/or their visual potential is very poor or nil. Putting those patients to sleep frequently is likely to increase the risk of a medical problem, including possible neurodevelopmental issues. You shouldn't keep putting kids to sleep if they're doing poorly and the odds that you're helping them are low.

Of course, any risk associated with using anesthesia on a young patient is small. The reality is, if the anesthesia is applied and monitored properly, and the child doesn't have any other conditions that would put him or her at risk, the likelihood of any adverse outcome is very low.

### In the General Clinic

In reality, many comprehensive ophthalmologists don't see young children. In addition, most children who have a health issue of any kind, including vision, are likely to be taken to a pediatrician. From there, they may end up in the office of a pediatric ophthalmologist or an optometrist with pediatric expertise. The moment they suspect glaucoma, most will send the child to someone with pediatric glaucoma expertise.

Certainly, if you do see a young child and you suspect glaucoma, a referral is appropriate. A child with primary congenital glaucoma, whose cornea looks cloudy or edematous, is an ASAP referral. Older children who may be at risk are usually a less-urgent referral, unless the pressure is very high or the optic nerve shows a lot of damage.

The most common thing a comprehensive ophthalmologist is likely to see is a child with an enlarged cup-to-disk ratio. Many of these children don't have glaucoma; they simply have physiologic cupping, but that's a common source of referral. With an older, more cooperative child, you can get a pressure, an OCT and maybe even a visual field if you need to. Children with abnormal testing or elevated IOP should be referred for further evaluation by someone with pediatric glaucoma expertise. **REVIEW**

*Dr. Beck has received grant support from Allergan. He reports no financial interest in any product mentioned in this article.*

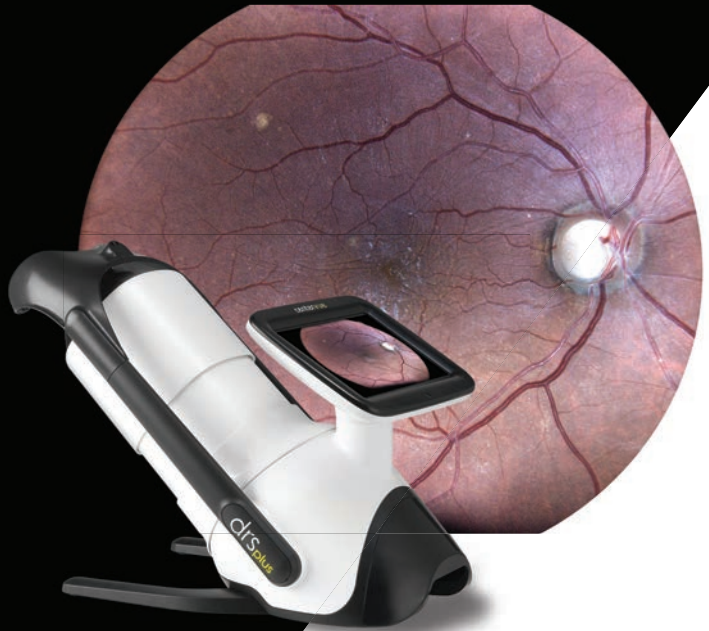1. Freedman SF, Lynn MJ, Beck AD, et al. Glaucoma-related adverse events in the first 5 years after unilateral cataract removal in the Infant Aphakia Treatment Study. *JAMA Ophthalmol* 2015;133:8:907-14.
2. Grigorian F, Grigorian AP, Olitsky SE. The use of the iCare tonometer reduced the need for anesthesia to measure intraocular pressure in children. *J AAPOS* 2012;16:6:508-10.
3. Chang TC, Cavuoto KM. Anesthesia considerations in pediatric glaucoma management. *Curr Opin Ophthalmol* 2014;25:2:118-21.
4. Sun LS, et al. Association between a single general anesthesia exposure before age 36 months and neurocognitive outcomes in later childhood. *JAMA* 2016;315:21:2312-20.

NEW!

drs<sup>plus</sup>

AUTOMATED TRUE COLOR  
RETINAL IMAGING

- + TrueColor confocal imaging
- + Fast image acquisition
- + Ultra-high resolution
- + No dilation (2.5mm pupil size)




THE NEXT GENERATION IN  
RETINA & GLAUCOMA DIAGNOSTICS



icare | centervue

Scan, call 888.422.7313, email [info@icare-usa.com](mailto:info@icare-usa.com),  
or visit [www.icarecentervue.com](http://www.icarecentervue.com)



NEW!

icare  
icare<sup>ic200</sup>

200 DEGREES OF  
TONOMETRY

- + Supine, elevated & seated operation
- + No drops, air, or calibration/  
verification needed
- + Consistent & accurate readings

# An Extra Push for Wet AMD Patients

*Sean McKinney, Senior Editor*

Conventional and not-so-conventional treatments to consider when these patients don't respond to initial anti-VEGF therapy.

Retinal specialists are pleased with the progress they've made while treating neovascular age-related macular degeneration in recent years, using anti-VEGF injections to help keep half of diagnosed patients at 20/40 or better, according to one major retrospective study.<sup>1</sup> Gone are the days of automatically using focal macular laser photocoagulation to seal leaking vessels in a primitive attempt to temporarily spare parts of the macula not yet ravaged by disease. But as physicians well know, reflecting on how far they've progressed does nothing to prepare them for how far they still must go.

The sad and challenging fact is that even with today's revolutionary drugs quieting the maculas of so many sighted success stories, some patients struggle to maintain their vision, even when faithfully following their intravitreal injection schedules. In this report, retinal specialists discuss strategies you can use for stabilizing these ever-hopeful patients before their view of their world blurs into legal blindness.

## The Basics

For now, your choices when a patient's vision isn't getting better are

bevacizumab (Avastin), ranibizumab (Lucentis), aflibercept (Eylea) and brolicizumab (Beovu). As you know, successful treatment can depend on myriad factors, including administration frequency, drug selection, schedule management, novel treatments, recognizing masquerade syndromes and confronting special challenges, such as intraretinal and subretinal fluid management and the perplexing downturns triggered by tachyphylaxis. Retinal specialists say the keys to progress can be found in how you use these anti-VEGF medications. Validated by the definitive findings of randomized, prospective trials, the treatments are paradoxically used with broad variability in many practices, depending on a clinician's experience, successes, failures and willingness to try something new.<sup>2</sup>

The continuing study of anti-VEGF therapy, at an individual level and as part of ongoing research, is what continues to drive patient care toward tomorrow, specialists say. In the words of J. Sebag, MD, FACS, FRCOphth, FARVO, a senior research scientist at the Doheny Eye Institute/UCLA and a professor of clinical ophthalmology at the David Geffen School of Medicine, UCLA: "Research and clinical trials provide the scientific basis of our approach to



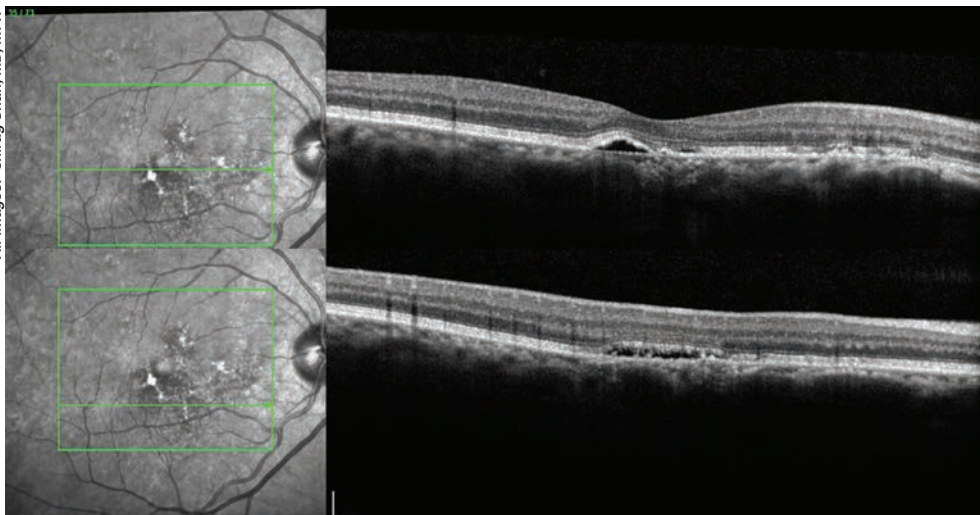


Figure 1. This patient has an occult choroidal neovascular membrane from wet AMD that responded well to anti-VEGF treatment. The subretinal fluid under his fovea has dried with treatment, although he has a persistent sliver of subretinal fluid inferior to his fovea that's not affecting his vision. His visual acuity is 20/30, with minimal symptoms.

patient care in this area of our practices. But individualizing patient care is what enables us to also practice the art of medicine.”

Most retinal specialists point out that the possibility of producing no response or a partial response with the injection of anti-VEGF medication is rare. “Virtually all patients who have neovascular AMD are sensitive to anti-VEGF therapy,” notes David Boyer, MD, senior partner at the Retina-Vitreous Associates Medical Group, based in Los Angeles and surrounding areas. Nonetheless, safeguarding against less-than-adequate results remains a high priority.

### Responding to Poor Response

If Dr. Boyer sees evidence of no response after one treatment, he immediately changes therapy. “I usually start my patients on Avastin or one of the branded medications, if needed,” he explains. “If I see that the patient isn’t doing well one month later, I make a change to Eylea or Lucentis and have the patient return in two weeks.” (Although approved dosages are monthly for Lucentis and once every two months after three months of initial treatment for Eylea, Dr. Boyer has found little difference between these two agents in these

situations.)

If he finds even the slightest response in a recalcitrant wet AMD case two weeks after the replacement treatment, he labels the patient a “poor responder” and proceeds with a customized approach to continuing to provide anti-VEGF therapy. “This disease is not like diabetes, which might not respond at all to an injection,” he points out.

Chirag Shah, MD, MPH, a partner at Ophthalmic Consultants of Boston, says he often takes a “modified stepwise approach” to patients with neovascular age-related macular degeneration who don’t respond to initial therapy, relying on a number of strategies. “In general, I start patients on Avastin because it’s an affordable and effective drug,” he says. If he’s not satisfied with the initial response, he considers switching patients to Eylea or Lucentis, each of which, he notes, has a greater pharmacological binding affinity to VEGF when compared to Avastin.

Like Dr. Boyer, he’ll also try a two-week interval, although not necessarily after only one failed treatment. “In this situation, I often alternate between Avastin and Lucentis or Eylea every two weeks, enabling twice-a-month dosing,” Dr. Shah explains. “Some insurance plans will cover

both treatments each month. For other plans, I may need to absorb the cost of Avastin and only bill for the on-label drug. In my practice, however, this approach is very uncommon and only reserved for very aggressive wet AMD cases.”

Carl Regillo, MD, chief of the retina service at Wills Eye Hospital in Philadelphia, also occasionally administers anti-VEGF agents every two weeks for challenging cases. “I do this mainly to determine whether I’m dealing with a condition that’s VEGF-responsive and to find out if the patient’s therapeutic effect is wearing off in fewer than 30 days,” he notes. “Sometimes that’s the case, but rarely. During this 30-day period, you need to ensure continuous VEGF blockade.

“Of course, there are exceptions to everything,” he continues. “You may discover a slightly better effect at week two than at week four, which implies that the medication is wearing off a little too quickly. We do this early on in the treatment of patients who aren’t responding as well as we’d hoped they would. When you’re finding significant exudation or experiencing a suboptimal response, you must first make sure you’re administering the drug as frequently as it needs to be administered. You test the waters.

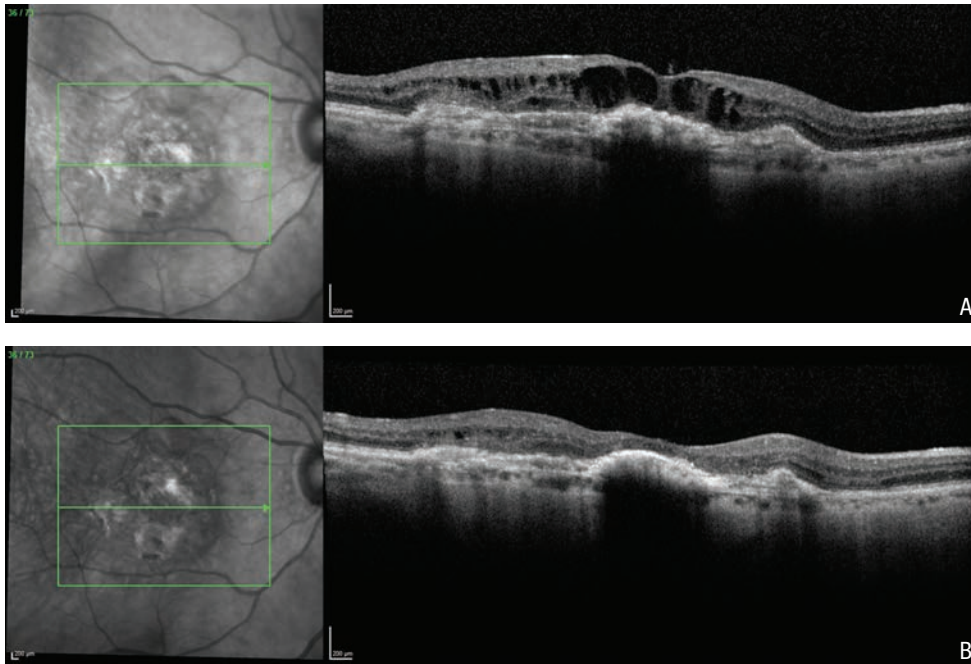


Figure 2. This patient had persistent intraretinal fluid from wet AMD, despite monthly bevacizumab injections (A), and was subsequently switched to aflibercept. After one aflibercept injection, the intraretinal fluid improved (B), as did his visual acuity, from 20/60 to 20/50.

more about the comparative effects of Beovu and Eylea from the MERLIN study (Study of Safety and Efficacy of Brolucizumab 6 mg Dosed Every 4 Weeks Compared to Aflibercept 2 mg Dosed Every 4 Weeks in Patients With Retinal Fluid Despite Frequent Anti-VEGF Injections), the results of which he expects will be released in 2021, following a COVID-19-related delay of a planned 2020 release. “The purpose of this study is to compare Eylea to Beovu in patients who aren’t responding to long-term anti-VEGF therapy,” he notes. “It’s perfectly in line with what we’re discussing here.”

But in my experience, it’s very rare that you have a patient receiving injections less than every 30 days.”

Dr. Regillo is reluctant to quantifiably describe the advantages and disadvantages of today’s wet AMD therapies. “These drugs are more alike than different,” he notes. “There’s no study that shows significant differences in efficacy, safety or even durability. Anecdotally and in practice, we appreciate and sometimes see some different effects—one may provide a little bit more drying, a little bit more durability or be a little bit longer acting, for example. But when we first start using any one of these drugs to treat a patient’s onset of AMD, we almost always see some reduction in exudation.”

When a patient’s wet AMD is well-established by a previous response to anti-VEGF therapy or the presence of neovascularization is confirmed by OCTA, Dr. Regillo uses alternative anti-VEGF medications, intensifying therapy after three or four non-

productive injections of his initial choice of medication. “Interestingly, the newer drugs do seem to have a little more of a drying effect than the earlier ones,” he notes. “Anecdotally, we’ve seen this effect progress from Avastin to Lucentis and then to Eylea. Now, Beovu seems to dry a little more than Eylea. The OCT results show a greater degree of reduction in OCT central retinal thickness.

“Subsequent subgroup analysis from phase 3 studies has shown that Beovu dried at a greater and faster degree,” he adds. “So at this stage, if the drugs I’m using don’t adequately dry up a patient’s exudation, I’ll consider using Beovu, but I’ll need to do so with great care, now that we’ve seen recent safety issues come to light with this new drug. In the context of new FDA labeling and risks that have surfaced, I’ll need to be certain I’m selecting the right patients who might benefit from this medication.” (See “Beovu Watch” on page 32.)

Dr. Sebag says he’s eager to learn

### When Persistence Pays Off

Unlike most of his peers, Dr. Sebag’s typical approach to wet AMD patients who don’t respond sufficiently to anti-VEGF therapy is to continue with injections. “The first thing I would say is that I don’t jump to conclusions, even after my patient has undergone four or five treatments,” he notes. “I usually try to go longer before concluding that a patient isn’t responding to my approach.”

Dr. Sebag recalls one patient, a frail seamstress in her 80s, who was intent on regaining visual acuity. She endured 10 injections of Lucentis over 10 months, achieving no change in her 20/200 vision. “I told her she had been a really good patient but that she was not responding,” he says. “Then I told her I really didn’t want to put her through any more duress.”

The patient pleaded for a few more injections, to which Dr. Sebag agreed. “Little by little, with con-

## S4OPTIK'S EXCEPTIONAL OPTICS

tinuing injections, her visual acuity remarkably improved to 20/20," he recalls. "She began to sew again. I was totally amazed. It taught me a lesson about how difficult it is to translate the results of clinical trials to a given individual. The only way you're going to be able to approximate the results of a clinical trial is if you're dealing with a patient who's exactly the same as the ones in the clinical trial."

Dr. Sebag now individualizes all of his treatment regimens, declining to stringently adhere to the results of when clinical challenges compel him to try a new approach. "For example: I have eight or nine patients who initially responded to monthly treatments, successfully extended, then stopped responding," he says. "I went back to monthly treatments and they still didn't get better. I proposed to them that we inject every two weeks for three to four months. So I used a half of a dozen injections to jump start their systems to see if that would work, which, anecdotally, it did. These patients received samples alternating with a standard drug treatment covered by insurance, which only pays for treatment intervals of 28 or more days. This approach seemed to get these patients back on track. They went back up to monthly injections and then once every two months."

### More Novel Approaches

Like Dr. Sebag, other specialists also use individual approaches to managing recalcitrant wet AMD patients. Below is a summary of a few:

- **Increasing doses.** A higher dose of the anti-VEGF agent can sometimes help produce a better response in suboptimal responders, according to Dr. Shah. "For me, this isn't possible when treating with Avastin," says Dr. Shah, who uses this technique as part of his modified stepwise approach to non-responders. "We get

Avastin from a compounding pharmacy and there isn't enough volume of the drug in the syringe to administer a higher dose. For Eylea and Lucentis, though, I can administer a higher dose. Instead of the standard 50 microliters, I can inject 75 or 100 microliters. Although the HARBOR study didn't show an advantage of 2 mg of Lucentis compared to the standard dose of 0.5 mg, we find that a higher dose can sometimes dry the macula better in clinical practice."<sup>3</sup>

- **Adding topical dorzolamide hydrochloride-timolol maleate (Cosopt) to the mix.** Dr. Shah says the additive effect of this topical glaucoma medication can enhance anti-VEGF therapy in recalcitrant cases, helping to decrease macular leakage. "Jason Hsu and colleagues [including Dr. Shah] found that this therapy can help in this way," says Dr. Shah, describing this third strategy in his stepwise approach to these cases.<sup>4</sup> He notes that the reasons the medication helps some patients aren't known, although Cosopt includes a carbonic anhydrase inhibitor, which could play a role, as well as a beta blocker that might help improve the effectiveness of the anti-VEGF drug at the receptor level. "Through the action of aqueous suppression, Cosopt could also potentially help reduce clearance of the anti-VEGF drug from the eye, allowing its extended presence to continue to better dry the macula," he adds.

- **Overcoming the paralysis of tachyphylaxis.** Dr. Boyer says tachyphylaxis can initially signal apparent treatment failure. "You're injecting a stable patient once every three months, then the effects of the treatment suddenly only last two-and-a-half months," he notes. "Next, it's two months and it goes down from there, losing its effect. No one knows why this occurs. In these cases, you just need to replace the medication you're using with another one. Patients will

S4OPTIK's converging binoculars allow effortless maintenance of fusion.

European craftsmanship and engineering provide reliable optics at all magnifications for confident examinations.



Vertical and compact configurations available.



## Beovu Watch

Approved for every-12-week dosing, Novartis' Beovu boasted the longest treatment interval of all intravitreal anti-VEGF injections when it was launched in October of 2019. However, retinal specialists' enthusiasm for the drug has been tempered by reports of 14 patients who developed vasculitis after Beovu injections. Subsequent retrospective investigations found the medication was associated with occlusions of retinal blood vessels at various sites, a delayed onset of uveitis in one case and the development of a retinal arteriolar occlusion with severe vision loss in another case.<sup>1,2,3</sup>

On June 11, Novartis announced that the FDA had approved an updated label with additional safety information for Beovu. Under "Warnings and Precautions" the drug's prescribing information states that "retinal vasculitis and/or retinal vascular occlusion, typically in the presence of intraocular inflammation, have been reported following Beovu injections. Patients should be instructed to report any change in vision without delay." Beovu is contraindicated in patients with active intraocular inflammation. Novartis says it's established a coalition composed of its own researchers and outside ophthalmologists to "examine the root causes and potential risk factors associated with the reported adverse events and to determine mitigation and treatment recommendations."

Chirag Shah, MD, MPH, a partner at Ophthalmic Consultants of Boston, says Beovu is "a final consideration" if wet AMD patients aren't responding to anti-VEGF therapy. "Some people would add it sooner in their algorithm," he admits. "The reason I'd consider it later in my algorithm is because of the potential side effects that we're just learning about now."

"We'd been using Beovu after its recent release," says David Boyer, MD, senior partner at the Retina-Vitreous Associates Medical Group, based in Los Angeles and surrounding areas. "It does dry better than the others. But until the inflammatory component of it has been worked out, it's very difficult to recommend that medication as a primary treatment, or until you've exhausted the other options."

J. Sebag, MD, FACS, FRCOphth, FARVO, a senior research scientist at the Doheny Eye Institute/UCLA and a professor of clinical ophthalmology at the David Geffen School of Medicine, UCLA, says he's not sure if the reports of occlusive vasculitis raise a major concern. "But the safety issue has made me feel better about not jumping on the bandwagon and being among the first to use this drug," he adds. "We'll have to see if the vasculitis is a major issue or not, and what role the drug should play in patients who aren't responding well to other anti-VEGF therapies."

Besides ruling out patients who have ocular inflammation, as recommended under the new labeling, Carl Regillo, MD, chief of the retina service at Wills Eye Hospital in Philadelphia, says he'll be very cautious about using Beovu for all future patients.

"These reports have been cause for concern, and the findings are naturally going to make us a bit more selective," Dr. Regillo says. "In terms of the types of patients we might treat with this drug, that issue remains an open question in many of our minds for the time being. Knowing that there's a possibility—no matter how small—of a patient developing vaso-occlusive side effects, we may need to consider the medication as a third-line treatment at this time because the safety profile isn't as good as it is for the drugs we've been using. So we're less inclined to introduce it earlier for patients who are doing relatively well visually."

1. Bauman CR, Spaide RF, Vajzovic L, et al. Retinal vasculitis and Intraocular inflammation after intravitreal injection of brolicizumab. *J. Ophtha* 2020; Apr 25. [Epub ahead of print].  
 2. Sara J, Haug SJ, Hien DL, Uludag G, et al. Retinal arterial occlusive vasculitis following intravitreal brolicizumab administration. *Am J Ophthalmol Case Rep* 2020; Mar 31. [Epub ahead of print].  
 3. Jain A, Chea S, Matsumiya W, et al. Severe vision loss secondary to retinal arteriolar occlusions after multiple intravitreal brolicizumab administrations. *Am J Ophthalmol Case Rep* 2020; Apr 2. [Epub ahead of print].

treat them frequently enough. So you want to make sure tachyphylaxis doesn't lead to undertreatment."

• **Managing fluid.** One of Dr. Boyer's treatment goals is to eliminate intraretinal fluid, which he notes is a dangerous threat to vision. On the other hand, "if you're treating a patient and subretinal fluid persists but the patient continues to have good vision, that's usually tolerable," says Dr. Boyer. "But you don't stop treating the patient. Reports show that subretinal fluid is not detrimental but also that patients are continuing to be treated to get rid of the fluid. In these cases, the doctors just couldn't eliminate the fluid. It's not that they gave up on treatment. You have to be careful about this, but it's true that subretinal fluid doesn't bother vision as much as intraretinal fluid. It's not affecting vision, so you're not as concerned about it."<sup>5,6</sup>

Although improvement and good visual outcomes usually go together when you're drying the macula, Dr. Regillo points out that getting the macula completely dry is not always necessary. "That being said," he continues, "when we see fluctuating fluid or decreasing vision and increasing intraretinal fluid in particular, we need to do a better job of reducing the exudation to a limited amount. We have no other choice but to switch among the anti-VEGF drugs. Whichever drug you choose first, you need to consider trying another and then trying another. At first, you should try them very frequently—every four weeks, sometimes more frequently, to see if the fluid is anti-VEGF responsive. It's possible that no agent will completely dry the macula."

• **Maximizing frequency.** When he sees unwanted regression during his evaluations, Dr. Sebag reviews the history of the patient's frequency. "If the patient hasn't responded, I find that frequency is usually the primary reason," he notes. "It seems you're

start responding again and you can actually return to the initial medication at some point, if you wish. This occurs in only 5 to 10 percent of patients. Usually, the biggest problem for wet AMD patients is that we don't

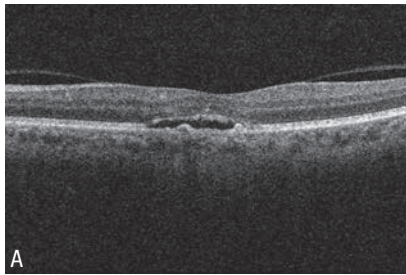
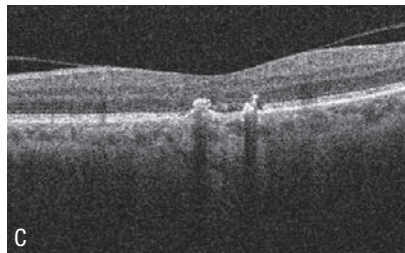
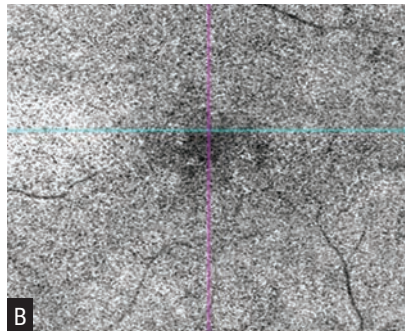


Figure 3. Pattern dystrophy can sometimes masquerade as wet AMD. This patient, who has pattern dystrophy, developed subretinal fluid (A), raising concern for choroidal neovascularization. However, OCTA ruled out choroidal neovascularization (B) and the patient was monitored thereafter. He returned six weeks later, showing spontaneous resolution of the subretinal fluid (C).



never able to maximize frequency. I usually start with monthly injections for three months in a row before I transition to injections of Eylea every two months.”

He typically prefers to eventually start patients on a treat-and-extend protocol, when possible. “It’s quite variable from patient to patient,” he notes. “No matter how you design treatment, however, a lot of factors can disrupt the schedule—patients not getting a ride to the office, patients feeling ill, conflicting doctors’ appointments. All kinds of issues can interfere with the treatment you design.”

### Masquerade Ball

The manifestations of polypoidal choroidal vasculopathy, central serous chorioretinopathy and other conditions can be present in the retina, disguised as the signs and symptoms of neovascular disease until their true identities are identified and responded to accordingly. “A number of masquerade syndromes can mimic the findings of a neovascular disease,” says Dr. Boyer. He identified the primary offenders:

- chronic central serous chorioretinopathy;
- polypoidal disease;
- adult-onset foveomacular vitelliform dystrophy;
- macular telangiectasia;
- acquired vitelliform maculopathy;
- basal laminar drusen; and
- acute exudative polymorphous vitelliform maculopathy.

“We’ve seen lesions sent to us that have resulted in totally unexpected findings,” he continues. “One turned out to be associated with lymphoma. These are the types of patients who wouldn’t respond to anti-VEGF therapy. So, when I see this, I rework them up, getting an OCTA, which I find is usually helpful in identifying some of these conditions. Of course, I always look for these unusual findings at baseline, but sometimes they’re not initially obvious.”

Macular dystrophies are among the other classic examples of these distractions that Dr. Regillo has diagnosed. “Patients may get started on anti-VEGF and the response is not seen,” he says. “So the first thing I ask myself when I don’t see any response: ‘Is the diagnosis correct?’ ICG angi-

# S4OPTIK SLIT LAMPS

## NEW LED Illumination

More than 50,000 hours of clear, cool illumination.



Easier observation of minute details.

Color temperature maintained through the full range of illumination adjustment.

# S4OPTIK

250 Cooper Ave., Suite 100 Tonawanda NY 14150

www.s4optik.com | 888-224-6012

Sensible equipment. Well made, well priced.

For today's modern office.

ography is superior to fluorescein angiography in helping us view the choroidal base for choroidal lesions. If you see the polyps and you're not seeing an adequate response to anti-VEGF therapy, then adding photodynamic therapy is a potential option for you to consider. It's very rarely used now, but it's an option in these cases."

In a "desperate situation," Dr. Boyer says he will also use PDT. "Then, though, you run the risk of creating a scar, depending on the thickness of the choroid. If the choroid is thick, you can get away with it, but if it's not, the use of PDT may not be best. And it's important to always remember that the visual results of PDT are nowhere near the level of quality that we can achieve with anti-VEGF therapy."

Dr. Shah modifies PDT to minimize risks in these cases. "As we all know, PDT involves intravenous administration of verteporfin, which is activated in the retina by a non-thermal laser," he says. "I often use half-fluence laser, which can yield a similar response to full-fluence laser but with reduced complications, such as an episode of choroidal hyperperfusion that can lead to darkening of the central vision."

## Best You Can Do

In a complex interweaving of pathologies, Dr. Boyer says that he's seen neovascularization that's led to a retinal and choroidal anastomosis. "These patients continue to leak and you unfortunately aren't going to be able to stop this leaking," he says. "The blood vessels are large and probably not sensitive to anti-VEGF factors. These patients are end-stage or patients who have had AMD for a long period of time."

In the final analysis, retinal specialists agree, the best you can do for these patients is to keep trying all therapeutic options and remain open to improvements in safety and new treatments on the R&D horizon. "We can't give up on our patients," says Dr. Sebag. "We must always find ways to keep trying to help them see better." **REVIEW**

1. Maguire MG, Martin DF, Yinggs, et al, for the Comparison of Age-related Macular Degeneration Treatments Trials (CATT) Research Group. Five-year outcomes with anti-vascular endothelial growth factor treatment of neovascular age-related macular degeneration: The comparison of age-related macular degeneration treatments trials. *Ophthalmology* 2016;123:8:1751-1761.
2. Erie JC, Barkmeier AJ, Hodge D, Mahr MA. High variation of intravitreal injection rates and Medicare anti-vascular endothelial growth factor payments per injection in the United States. *Ophthalmology* 2016;123:6:1257-62.
3. Busbee BG, Ho AC, Brown DM, et al, for the HARBOR Study Group. Twelve-month efficacy and safety of 0.5 mg or 2.0 mg ranibizumab in patients with subfoveal neovascular age-related macular degeneration. *Ophthalmology* 2013;120:5:1046-56.
4. Hsu J, Patel SN, Wolfe JD, et al. Effect of adjuvant topical dorzolamide-timolol vs placebo in neovascular age-related macular degeneration: A randomized clinical trial. *JAMA Ophthalmol* 2020;138:5:560.
5. Guymer RH, Markey CM, McAllister I, et al, for FLUID Investigators. Tolerating subretinal fluid in neovascular age-related macular degeneration treated with ranibizumab using a treat-and-extend regimen: FLUID study 24-month results. *Ophthalmology* 2019;126:5:723-734.
6. Sharma S, Toth CA, Daniel E, Grunwald JE, et al. Macular morphology and visual acuity in the second year of the comparison of age-related macular degeneration treatments trials. *Ophthalmology* 2016;123:4:865-75

(Continued from page 19)

surgeons. Dr. Shetty says he believes experiments he recently led at his institution provide definitive recommendations on how to best avoid COVID-19 spread during ophthalmic surgery. He notes that the findings of his team were validated by the Institute of Science, Department of Mechanical Engineering in Bangalore and that they match recommendations published by the World Health Organization on July 9, "Transmission of SARS-CoV-2: implications for infection prevention precautions," which can be found at: [who.int/news-room/commentaries/detail/transmission-of-sars-cov-2-implications-for-infection-prevention-precautions](https://www.who.int/news-room/commentaries/detail/transmission-of-sars-cov-2-implications-for-infection-prevention-precautions).

Dr. Shetty says he's looking forward to the publication of a paper on his team's findings that was recently accepted for publication by a research journal. (See "How to Avoid COVID-19 Infection During Surgery" on page 19.)

## Will This Apparent Uptick Last?

No one is certain how long the success that some refractive surgeons are reporting will last. Refractive surgery procedures have been on the decline in recent times, and some believe this trend will continue in the long term. Market Scope, a leading source for market data, independent perspective, and objective analysis in today's health-care marketplace, reports that 746,000 laser vision correction procedures were performed in 2019, down slightly from 2018. "We expect 2020 volumes to decrease further, although the magnitude of this decrease is still yet to be determined," says Kristen Harmon Ingenito, vice president and director of ophthalmics at Market Scope.

Meanwhile, at the practice level, at least some surgeons remain optimistic. During the recent lockdown amid the first wave of the pandemic, some surgeons were forced to stay closed for up to 10 weeks. Most don't expect that scenario to recur, meaning that ophthalmologists will have a basis of differentiation when explaining the availability of their procedures in the months ahead, even in regions where the number of COVID-19 cases may be spiking and elective procedures are put on hold in hospitals.

Dr. Bond, whose office has a Wavelight Allegretto laser in the surgical suite, believes his operations can continue in a business-as-usual fashion—with hopes that it will be a good time for business in the months ahead.

"I think we have reason to feel confident about our immediate future," he says. **REVIEW**

*Drs. Donnenfeld, Bond, McKee, Hardten and Shetty have no financial interest in any of the products discussed.*



# You've never seen anything like this.

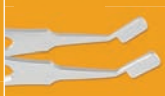See what's new in dry eye.



Natural  
blink design.



Patented  
smart system.



Ultra-precise  
clearance.

**TearCare.com**

Indications for Use: TearCare® is a tool indicated for the application of localized heat when the current medical community recommends the application of warm compress to the eyelids. Such applications would include Meibomian Gland Dysfunction (MGD), Dry Eye, or Blepharitis. TearCare® may not be right for everyone. Please see Instructions for Use or visit TearCare.com for Contraindications, Warnings and Precautions.



# Is It Time to Treat Presymptomatic DR?

*Christopher Kent, Senior Editor*

Earlier treatment with anti-VEGF injections offers benefits, but many surgeons are staying the course.

In recent years, patients with proliferative diabetic retinopathy who present with symptoms such as edema, neovascularization and hemorrhages have usually been offered treatment with anti-VEGF injections. Now, trials such as PANORAMA (Study of the Efficacy and Safety of Intravitreal Aflibercept for the Improvement of Moderately Severe to Severe Nonproliferative Diabetic Retinopathy) are providing evidence that treatment before these symptoms appear may not only reduce the severity of the disease but also reduce the risk of progressing to the more-severe, symptomatic disease.

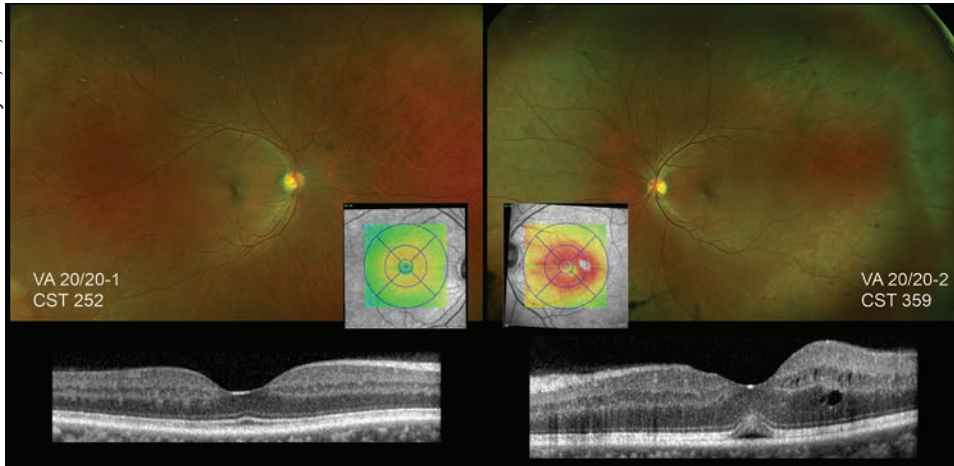
The evidence is sufficiently compelling that in May 2019 the U.S. Food and Drug Administration approved the use of aflibercept (Eylea, Regeneron) to treat all stages of diabetic retinopathy, including presymptomatic stages. As a result, some ophthalmologists have begun offering this treatment to patients in this category—but many others are hesitant to alter their protocol.

“Diabetic retinopathy is a heterogeneous disease,” notes Charles Wykoff, MD, PhD, director of research at Retina Consultants of Houston and deputy chair of ophthalmology for the Blanton Eye Institute at the Houston Methodist Hospital. “There’s diabetic

macular edema, and then there’s diabetic retinopathy broadly.

“There are two recent studies relevant to the early stages of the disease process,” he continues. “One is PANORAMA, which is the only prospective trial giving us data about nonproliferative diabetic retinopathy eyes without diabetic macular edema in the anti-VEGF era. The other trial is the Diabetic Retinopathy Clinical Research Network’s Protocol V trial, which looked at mild diabetic macular edema, when people still have relatively preserved central visual function. That trial looked at the potential value of earlier treatment with anti-VEGF injections versus laser or observation. Both of these datasets can inform clinical practice.”

“It’s an interesting time in terms of treatment for retinopathy regression,” agrees W. Lloyd Clark, MD, who practices at the Palmetto Retina Center in Columbia, South Carolina, and is an assistant clinical professor of ophthalmology at the University of South Carolina School of Medicine. “We now have data showing that two FDA-approved anti-VEGF agents—ranibizumab and aflibercept—can produce dramatic regression rates in a small subset of patients with nonproliferative diabetic retinopathy. Patients with severe nonproliferative disease receive-



Presymptomatic patients, even with fairly severe disease, have traditionally not been treated with anti-VEGF injections. Above: An asymptomatic 60-year-old female with Type 2 diabetes. Her right eye has PDR without DME, with multifocal zones of neovascularization in the mid and far periphery and extensive areas of retinal non-perfusion visualized with widefield fluorescein angiography. Her left eye has severe NPDR with center-involved DME with extensive vascular leakage revealed by widefield fluorescein angiography, but still has good visual acuity.

ing aggressive therapy appear to have, across the board, about an 80-percent chance of a two-step regression in retinopathy. We know this from multiple clinical trials—not just from PANORAMA, but from the registration trials for diabetic macular edema.

“This is very compelling data for a subset of patients who are at high risk of having vision-threatening complications in the next one to two years,” he continues. “It means we can potentially have a dramatic impact on the natural disease history in the 10 to 15 percent of the diabetic population with severe nonproliferative disease that we see in ophthalmic practice.”

Here, Drs. Wykoff and Clark discuss the trial data, the reasons many surgeons haven’t adopted this approach, and share their protocols for choosing patients, discussing the options with those patients, and proceeding with treatment.

## What the Data Show

Among the reasons many clinicians are still not treating presymptomatic patients is that the PANORAMA trial wasn’t focused primarily on the con-

cerns and goals of clinicians. “The goal of PANORAMA was to achieve a two-step diabetic retinopathy severity score improvement, with the ultimate objective of obtaining regulatory approval for the use of a given pharmaceutical agent,” Dr. Wykoff says. “It’s helpful to understand this. In that context, a clinician’s goals aren’t necessarily about achieving a two-step diabetic retinopathy severity improvement based on color fundus photograph readings. Among other things, that doesn’t necessarily correlate with visual function.”

Dr. Clark agrees that in terms of convincing clinicians to alter their paradigm, the design of the PANORAMA trial may be part of the problem. “First of all, the trial wasn’t really designed to answer the important clinical questions that could convince patients and physicians to change their behavior,” he says. “The primary outcome for PANORAMA was a two-step regression in diabetic retinopathy severity. That’s an important endpoint, and it was critical for FDA approval, but it’s not a clinical endpoint. Most clinicians don’t use serial color fundus photographs to rate diabetic retinopathy.

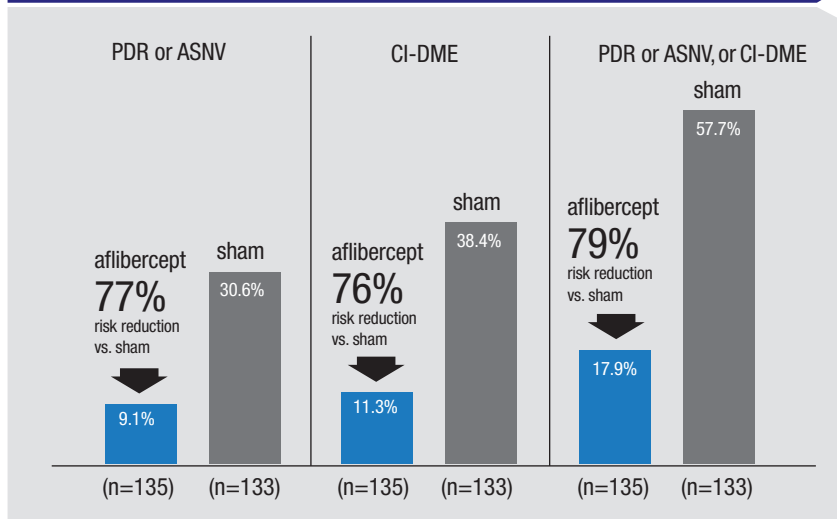
“On the other hand, an important secondary endpoint in PANORAMA was the percentage of patients that developed a vision-threatening complication,” he continues. “The complications studied in PANORAMA included the development of proliferative disease; the development of anterior segment neovascularization; and the development of center-involved diabetic macular edema. Those secondary endpoints are far more clinically relevant. Unfortunately, this was not the data that the presenters initially featured in their presentations, because it wasn’t the primary outcome of the trial.

“Now, as the discussion about PANORAMA evolves, we’re trying to change the focus to talking more about those vision-threatening complications,” he says. “The likelihood of avoiding a vision-threatening complication with either dosing strategy—as infrequently as one injection every four months—was 65 percent or higher. So even injecting the patient three times a year reduced the risk of developing one of these complications by a significant amount.

“The second issue with the clinical trial is that its design was a little confusing,” Dr. Clark continues. “The discussion during the first year of PANORAMA largely centered around the every-eight-week treatment group because that group had the highest rates of diabetic retinopathy severity regression. But in year two, the every-eight-week group was converted to treatment-as-needed. It turned out that these patients were then undertreated by the investigators, receiving fewer than two injections in the second year. As a result, the regression rates actually worsened in year two.



**PANORAMA Exploratory Endpoint: Risk Reduction at Week 100**



PANORAMA is the first Phase III anti-VEGF trial specifically designed to study patients with moderately severe to severe nonproliferative diabetic retinopathy without center-involved diabetic macular edema (ETDRS Diabetic Retinopathy Severity Scale score of 47 or 53). Compared to sham, fewer of the patients receiving aflibercept injections (2 mg every 16 weeks) progressed to PDR or anterior segment neovascularization (ASNV), or developed CI-DME through week 100. (The results of these exploratory endpoints require cautious interpretation, as a multiplicity adjustment has not been applied.) Data from: Wykoff CC. Intravitreal Aflibercept for Moderately Severe to Severe Non-Proliferative Diabetic Retinopathy (NPDR): 2-Year Outcomes of the Phase 3 PANORAMA Study. Presented at: Angiogenesis, Exudation and Degeneration Annual Meeting; February 8, 2020; Miami.

That muddied the waters a little bit.”

Both Drs. Wykoff and Clark agree that focusing on specific parts of the trial data is more clinically helpful. “The real money lies in paying attention to the 16-week data,” Dr. Clark explains. “Only this group had fixed dosing throughout the course of the two years. These patients were treated monthly for three months, then treated three times a year thereafter, and they had about a 65-percent reduction in vision-threatening complications.

“The standard of care for a patient with severe nonproliferative disease but no symptoms,” he continues, “is to see the patient for observation every four months, based on the guidelines of the American Academy of Ophthalmology and the American Diabetes Association—just like the every-16-week group in the PANORAMA study. The only difference here, in terms of the treatment burden for

these patients, is the addition of an intravitreal injection. And if they get one, their risk of developing a vision-threatening complication is reduced by two-thirds.”

Dr. Wykoff points out that the data from the second year of PANORAMA was particularly informative in regards to dosing frequency. “In the arms that transitioned to as-needed dosing, patients only got an average of 1.8 injections during the second year,” he points out. “That’s very few injections. In that context, 92 percent of the eyes maintained at least a one-step diabetic retinopathy improvement from baseline, among those who had achieved a two-step improvement at one year. In other words, once you improve your diabetic retinopathy severity with anti-VEGF dosing and achieve stability, the ongoing dosing frequency needed in most eyes, at least through one additional year, is probably very small.

Every 12 or 16 weeks is probably sufficient to maintain the improvement.”

**Should You Stay the Course?**

Despite the new data, many surgeons haven’t altered their treatment protocols. “We know that anti-VEGF injections are highly effective at slowing the disease process,” says Dr. Wykoff. “They slow the progression of diabetic retinopathy, improve diabetic retinopathy severity levels as measured by color fundus photographs, and decrease the rates of development of proliferative diabetic retinopathy and center-involved diabetic macular edema. This has been shown by data from the PANORAMA trial, as well as other studies such as RIDE, RISE, VISTA and VIVID.

“The problem is that intravitreal injections are invasive,” he continues. “Many patients with nonproliferative diabetic retinopathy without diabetic macular edema are asymptomatic. They have very good visual function. Actually, there is some evidence that they may not have totally normal visual function, even without diabetic macular edema, although we need more data to better understand this issue. But the way we currently measure visual function clinically with Snellen acuity, many of these patients have very good visual function. They often state that they’re completely asymptomatic. In that situation, it’s a high bar to start repeated intravitreal injections in most cases.

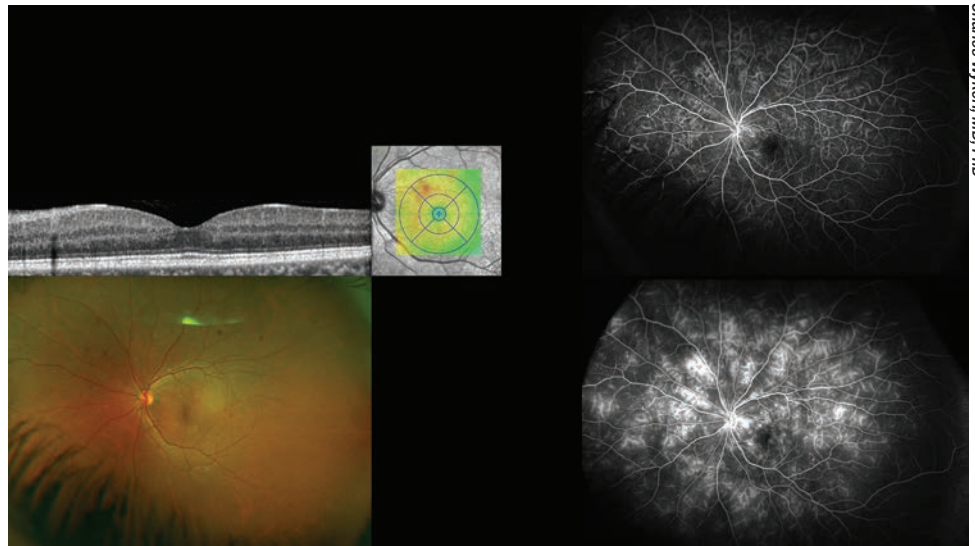
“There are certain situations in which patients may be more interested in pursuing treatment,” he continues, “such as when they’ve had complications and lost vision because of diabetic macular edema or diabetic retinopathy in the fellow eye. In that situation they may be more interested in earlier intervention to prevent disease progression. But many patients and physicians are still simply observing these high-risk nonproliferative

diabetic retinopathy eyes.

“There is data to support either option,” he notes. “The data can be used to support earlier intervention, but it can also be used to support watchful waiting. Some of these eyes, as we’ve learned from both PANORAMA and DRCR protocol V, can be stable over time. As a result, following these patients closely and looking for any sign of deterioration is a very common and reasonable clinical strategy. Maintaining stability in an eye with nonproliferative diabetic retinopathy without diabetic macular edema is a reasonable clinical objective.”

“I understand the resistance to this among patients and doctors when the patient doesn’t have a problem in the fellow eye or family members who’ve lost vision because of a complication from diabetes,” says Dr. Clark. “These patients have been managed appropriately for decades with close observation. If the patient hasn’t lost any vision, even at this level of severity when they might benefit from the treatment, why not maintain the status quo? Why introduce a treatment with potential complications and some additional cost, when these patients have been effectively managed in the past with observation and treatment for vision-threatening progression?”

“Basically, what we’re doing here is lowering the threshold for treatment,” he says. “Instead of treating the complications, the idea is to treat the retinopathy prior to the development of complications. However, if a patient at this severity level has no vision loss in either eye, there’s bound to be some resistance to doing this. So for now, at least, I think you need a tie-breaker to proceed with therapy, be it vision loss in the other eye or a family member.”



A 34-year-old asymptomatic female with Type 2 diabetes (HbA1c=12.2). Widefield fluorescein angiography revealed severe NPDR without DME, with extensive vascular leakage in her right eye. Visual acuity was 20/20; central retinal thickness was 244  $\mu$ m.

Charles Wykoff, MD, PhD

## Treatment Protocol

Dr. Wykoff explains his clinical protocol when managing these patients. “My personal bias is to lean toward earlier intervention,” he says. “I’d rather prevent progression of the disease and stabilize it at an earlier stage than wait for proliferative disease or center-involved diabetic macular edema and vision loss to initiate therapy. I try to achieve that goal using the least-frequent dosing possible.”

“The dosing frequency in PANORAMA was substantial: five monthly doses in the Q8 arm, and three monthly doses in the Q16 arm followed by every-16-week dosing through one year,” he continues. “In clinic, when I’m treating nonproliferative retinopathy without diabetic macular edema, I often start with a less-frequent dosing pattern, such as every eight, 12 or even 16 weeks from the outset, depending on the goals and my discussion with the patient. So in the clinic we often choose to dose less-frequently than was done in PANORAMA, depending on the objectives we’re trying to achieve.”

“Of course,” he adds, “this approach

is not for every patient, but it’s a discussion worth having with these patients and their caregivers.”

Would Dr. Clark consider treating patients on an eight-week schedule? “The data does suggest an additional benefit for those treated every eight weeks,” he notes. “Nevertheless, in clinical practice I’d approach this type of patient with the initial plan to pursue a dosing strategy consistent with the 16-week arm in PANORAMA. I’d have a short monthly loading period, followed by automatic extension out to four months. If the patient then developed a vision-threatening complication, I’d consider reducing the treatment interval to eight weeks. But initially I’d try to treat all of these patients every 16 weeks, because of the robust nature of the clinical trial data at two years.”

Both doctors say the patient’s situation and goals are a big part of making the treatment decision. “In most cases, patients with fovea-involving wet macular degeneration, PDR, or center-involved diabetic macular edema with vision loss are probably going to be offered treatment,” notes Dr. Wykoff. “But in earlier stages of DR

and DME, it's more of a discussion. There's a lot to think about. What are the risks of the treatment? What are the benefits? What are the patient's goals? What's the patient's ability to continue to receive ongoing close care? What's the status of the fellow eye? Patients need to be involved in these discussions and know what the data says about their situation.

"At the end of the day," he continues, "many patients will simply trust their physician and say, 'What do you think?'" But along the way, most patients want to try to make an informed decision, and with these datasets we can inform them better than ever. Before this we had the Early Treatment Diabetic Retinopathy Study from the 1980s, which helped us to prognosticate how eyes would do over time with different diabetic retinopathy severity levels. This newer data can guide us in terms of what the risk profile of these patients is like with and without anti-VEGF dosing."

Dr. Clark says that in his clinic he's opting to treat these patients—but with a few caveats. "It's not uncommon to identify a patient with severe nonproliferative disease who's undergoing treatment for diabetic macular edema in the fellow eye," he notes. "That's a pretty compelling group of patients to start with, because they already have a vision-threatening complication in one eye. In the fellow eye they have a threshold retinopathy, but without macular edema. Also, the additional treatment burden created by treating for regression in the fellow eye is minimal, because they're already coming in for treatment of the diabetic macular edema in the one eye. You're not going to increase the number of visits. Obviously there's an incremental increase in risk because of the additional injection, and some incremental additional cost. But the tradeoff, in terms of risk-reduction for the fellow eye, is dramatic. You have an 80-percent chance of avoiding dia-

betic macular edema or proliferative disease in that eye.

"I also think this is a meaningful conversation to have when these patients, in that narrow threshold of level 47 to level 53 disease severity, have family members who've lost vision because of a complication from diabetes," he adds. "I try to have a detailed discussion with these patients about the data, and they've indicated an interest in therapy."

### Measuring Treatment Success

One issue raised by this new protocol is that judging the success of your treatment before symptoms have occurred can be a challenge. "When managing diabetic macular edema and wet macular degeneration we have OCT," says Dr. Wykoff. "That technology can readily show us changes in fluid status. But eyes with severe NPDR without diabetic macular edema, by definition, don't have center-involved fluid. That means we're relying more on other, less-quantifiable parameters such as the clinical exam.

"I use a lot of fundus photography with eyes that have diabetic retinopathy," he notes. "In my clinic I routinely use widefield imaging to manage these patients. I also like to obtain widefield fluorescein angiograms, especially at baseline. I want to know the burden of ischemia and make sure I know of any proliferative disease before initiating anti-VEGF dosing. Then, when I'm treating patients with nonproliferative diabetic retinopathy, I like to repeat a widefield fluorescein angiogram once a year, or once every other year. In reality, I often can't repeat them as frequently as I would like.

"If you seldom take fundus photographs or don't have access to such imaging," he adds, "you'll need to rely on clinical documentation, noting whether you think it's mild, moderate or severe nonproliferative diabetic retinopathy."

### Integrating the Information

Dr. Wykoff says he doesn't think the purpose of this data should be simply to drive usage. "The value of these datasets is to inform patients and clinicians about what to expect with patients in this disease state with various management strategies," he explains. "They allow us to quantify the risk that the patient will end up in a specific clinical state if we do treat them or don't treat them. That allows us to make informed decisions and recommendations. I think, towards that end, these datasets have been incredibly valuable. And, we'll continue to learn more from them as we do more post-hoc, or hypothesis-generating analyses."

Dr. Wykoff adds that he does see a gradual shift toward earlier treatment. "I think more doctors are considering this and discussing it with these patients," he says. "It's very different from center-involved diabetic macular edema with vision loss, PDR or wet macular degeneration, where most patients are going to receive treatment, and it doesn't make sense for every patient. It may even be a minority of patients with nonproliferative diabetic retinopathy that ultimately get treated with anti-VEGF agents before they have diabetic macular edema or PDR. But I believe there's a movement to at least consider earlier intervention and discuss it with patients, along with considering close clinical observation. As our interventional options become more durable, and hopefully—eventually—less invasive, I believe we'll see a continued shift toward earlier intervention." **REVIEW**

*Dr. Wykoff is a consultant for Genentech and Regeneron and does research for both companies. Dr. Clark is a consultant, investigator and on the speaker's bureau for both Regeneron and Genentech, and an investigator for Bayer Pharmaceuticals.*

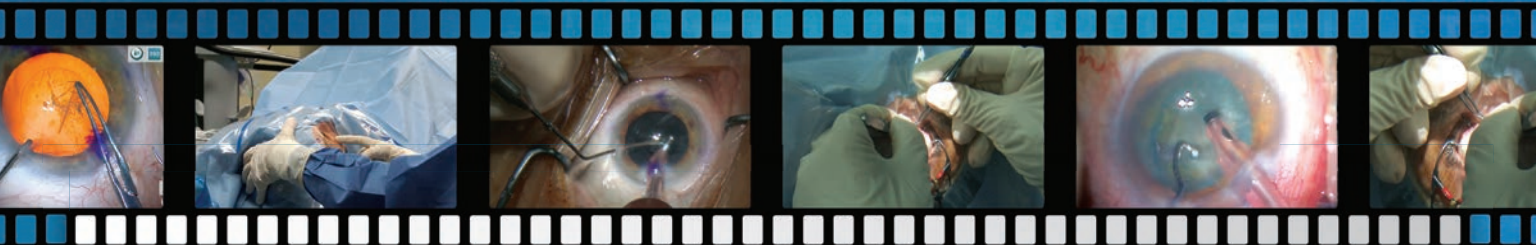




Monthly

# MACKOOL ONLINE CME

## CME SERIES | SURGICAL VIDEOS



To view CME video  
go to:

[www.MackoolOnlineCME.com](http://www.MackoolOnlineCME.com)

### Episode 56: "The Blind, Painful Eye: Retrolubar Alcohol Injection"

Surgical Video by:  
Richard J. Mackool, MD

#### Video Overview:

Here we depart from our usual presentation of intraocular microsurgical procedures and techniques.

A very elderly patient with early phthisis bulbi, and a blind and extremely painful eye receives a retrolubar alcohol injection to immediately relieve her intractable pain. The appropriate alcohol concentration and anticipated outcome is also discussed.

## MackoolOnlineCME.com MONTHLY Video Series



Richard J. Mackool, MD

We are excited to continue into our fifth year of Mackool Online CME. With the generous support of several ophthalmic companies, I am honored to have our viewers join me in the operating room as I demonstrate the technology and techniques that I have found to be most valuable, and that I hope are helpful to many of my colleagues. We continue to edit the videos only to either change camera perspective or to reduce down time - allowing you to observe every step of the procedure.

As before, one new surgical video will be released monthly, and physicians may earn CME credits or just observe the case. New viewers are able to obtain additional CME credit by reviewing previous videos that are located in our archives.

I thank the many surgeons who have told us that they have found our CME program to be interesting and instructive; I appreciate your comments, suggestions and questions. Thanks again for joining us on Mackool Online CME.



**CME Accredited Surgical Training Videos Now Available Online: [www.MackoolOnlineCME.com](http://www.MackoolOnlineCME.com)**

Richard Mackool, MD, a world renowned anterior segment ophthalmic microsurgeon, has assembled a web-based video collection of surgical cases that encompass both routine and challenging cases, demonstrating both familiar and potentially unfamiliar surgical techniques using a variety of instrumentation and settings.

This educational activity aims to present a series of Dr. Mackool's surgical videos, carefully selected to address the specific learning objectives of this activity, with the goal of making surgical training available as needed online for surgeons motivated to improve or expand their surgical repertoire.

#### Learning Objective:

*After completion of this educational activity, participants should be able to:*

- present the indication and technique of retrolubar injection of alcohol.

**Satisfactory Completion** - Learners must pass a post-test and complete an evaluation form to receive a certificate of completion. You must listen to/view the entire video as partial credit is not available. If you are seeking continuing education credit for a specialty not listed below, it is your responsibility to contact your licensing/certification board to determine course eligibility for your licensing/certification requirement.



JOINTLY ACCREDITED PROVIDER™  
INTERPROFESSIONAL CONTINUING EDUCATION

**Physicians** - In support of improving patient care, this activity has been planned and implemented by Amedco LLC and Review Education Group. Amedco LLC is jointly accredited by the Accreditation Council for Continuing Medical Education (ACCME), the Accreditation Council for Pharmacy Education (ACPE), and the American Nurses Credentialing Center (ANCC), to provide continuing education for the healthcare team

**Credit Designation Statement** - Amedco designates this enduring material activity for a maximum of .25 AMA PRA Category 1 Credits™. Physicians should claim only the credit commensurate with the extent of their participation in the activity.

Jointly provided by:




Supported by an unrestricted independent  
medical educational grant from:



Additionally Supported by:



In Kind Support:



Video and Web Production by:  
JR Snowden, Inc

# The Experts' Take on Astigmatic Keratotomy

Christine Leonard, Associate Editor

When it comes down to the knife or the laser, surgeon preference varies.

In the 1990s, limbal relaxing incisions by and large replaced astigmatic keratotomy on the cornea for astigmatism correction. “The cornea has circumferential fiber rings around the limbus that extend within 1.5 D of the blood vessels of the limbus, so when you cut within that zone right next to the limbus and along, rather than across, the annulus of fibers, the cornea isn’t weakened as much and you don’t end up with wacky overcorrections,” explains Steven G. Safran, MD, PA, a staff surgeon at Robert Wood Johnson University Hospital in Hamilton, New Jersey. “We made the switch to limbal relaxing incisions from corneal incisions because they’re safer.”

Often done in conjunction with cataract surgery—most cataract surgery candidates have at least 1.25 D of astigmatism<sup>1</sup>—incisional keratotomy methods such as manual LRIs enjoy a long history of published studies supporting their safety and efficacy for astigmatism correction,<sup>2-5</sup> in addition to well-developed nomograms, some of which have been in use for over 20 years. Performing manual incisions is relatively inexpensive, since there’s no need to purchase an expensive femtosecond laser. All you need to perform incisional keratotomy is a toric axis marker and a diamond knife, which can last forever with the proper care, experts say.

More recently, femtosecond lasers have been on the rise for managing astigmatism in conjunction with cataract surgery,<sup>6-7</sup> making it very simple and convenient for the ophthalmic surgeon to create LRIs with the laser at the time of laser-assisted cataract surgery. Proponents of laser-assisted cataract and LRI procedures say that the femtosecond laser can ensure and increase incisional precision and uniformity. Additionally, technologies like pachymetry, real-time OCT and topography can be paired with the laser for added safety and improved anatomical visualization.

In this article, we’ll hear from proponents of both methods, and discuss the current pros and cons of lasers and knives.

## Pro Laser

Preeya K. Gupta, MD, a corneal specialist at the Duke Eye Center, says that the femtosecond laser provides an easy way to integrate astigmatism correction into your clinical practice, especially if you’re already using the laser to do cataract surgery. “Adding astigmatism correction takes only seconds of additional time. We should all be correcting even low levels of astigmatism, because it leads to better visual outcomes,” says Dr. Gupta. “The

## Nomogram Modification

Laser nomograms are often modified versions of blade nomograms, since the most robust nomograms we have are for blade incisions, not for femto arcuates, says Preeya K. Gupta, MD, a corneal specialist at the Davis Ambulatory Surgical Center, Duke Eye Center. “Generally speaking, if you use a manual incision calculator to calculate your femto LRIs, you’re going to have an overcorrection because of the nature of the femto incision, which behaves differently. You have to modify it by decreasing by a certain percentage. Off-label, many doctors use blade nomograms to calculate femto arcuates by treating about 70 percent of WTR and 80 percent of ATR astigmatism.”

Dr. Eric Donnenfeld’s nomogram for manual limbal relaxing incisions is one of the most widely used nomograms and is among the pre-programmed nomograms in the new Catalys cOS 6.0 system, according to Shachar Tauber, MD, physician and director of telemedicine and ophthalmic research at Mercy Clinic Eye Specialists in Springfield, Missouri. In this case, two-thirds reduction is the recommended amount, though surgeons can adjust this on a case-by-case basis. “It’s suggested that you follow the results for a 30-day period and adjust,” Dr. Tauber says. “It’s better to undercorrect than overcorrect astigmatism. Be conservative and ratchet it up slowly.”

Dr. Gupta is developing a femtosecond laser nomogram specifically for lower levels of astigmatism. “We’re in the process of studying and validating it now,” she says. “It’s important to understand what effects are produced by certain incision lengths. From analyzing our outcomes, we can see that treating even very low levels of astigmatism with the femtosecond laser is visually beneficial for patients.”

The Donnenfeld Nomogram for LRIs is as follows: for 0.5 D astigmatism, one incision, 1½ clock hours (45 degrees each); 0.75 D, two incisions, 1 clock hour (30 degrees each); 1.5 D, two incisions, 2 clock hours (60 degrees each); 3 D, two incisions, 3 clock hours (90 degree each).

femtosecond laser provides a precise and automated way to do this.”

Dr. Gupta, who uses the LenSx laser from Alcon, prefers the laser to manual methods for a couple of reasons. “Before I started using the femtosecond laser, I did manual LRIs, but I didn’t do them on every patient,” she says. “I’d reserve them for patients who had 1 D or more of astigmatism. With the laser, on the other hand, I consider treating even low levels of astigmatism. I treat astigmatism for every laser cataract surgery patient.”

It’s partly a matter of convenience, she explains. “If I’m already sitting at the laser for cataract surgery, it’s not a lot of extra effort to treat astigmatism at the same time,” she says. “The patient is already docked to the laser, whereas if I were to switch to manual incisions, it’d require several extra steps: You need to make a plan, have other instruments and have the patient sit up for marking. Using the laser for both cataract surgery and astigmatism correction makes

sense from a practical standpoint.”

Shachar Tauber, MD, lead physician on the specialty council and director of telemedicine and ophthalmic research at Mercy Clinic Eye Specialists in Springfield, Missouri, who began his medical journey in the radial keratotomy and astigmatic keratotomy school of refractive surgery, says he was very grateful when excimer and femtosecond lasers arrived on the scene. “I’ve gotten completely away from manual keratotomy, even for transplants,” says Dr. Tauber, who uses the Catalys laser from Johnson & Johnson Vision. “I can have cyclotorsion set up for better accuracy with my marking, and I can pair my laser to the topographer. Incorporating topographic imaging allows for proper orientation of the steep axis and better planning of arcuates. With a laser, I feel confident that the quality, placement and accuracy of the incisions are excellent.”

Here are some reasons surgeons love their lasers:

- **Improved precision.** Dr. Gupta and Dr. Tauber both agree that, though surgeons are very skilled in creating manual incisions, achieving a level of precision comparable to that of a laser is difficult. “There’s more variability with manual incisions,” Dr. Tauber says. “With a laser I can input the exact number of degrees I want and set variables, like the optical zone diameter based on the pupil or the limbus, and be equal on both sides. The length and depth of the incision are also set up by the laser, so it doesn’t depend on my hand. If we look at the precision of a laser for astigmatic incisions—whether intrastromal or anterior penetrating—it’s quite precise, and the error is very small and very consistent. Arcuate incisions for the Catalys were clinically validated within  $0.83 \pm 0.66$  percent of intended

optical zone,  $0.22 \pm 0.2$  degrees of intended axis and  $0.22 \pm 0.29$  degrees of intended length.”<sup>8</sup>

“The curvature of the incision is also very precise with a laser,” Dr. Gupta adds. “You can standardize its placement on the optical zone a little more precisely than with manual methods.”

- **Intrastromal incisions.** “What attracted me initially to the laser was the ability to do intrastromal arcuate incisions,” says Dr. Tauber. “The laser leaves the top and bottom 20 percent [of the cornea] intact; this makes for a more pristine ocular surface. You can’t correct as much astigmatism with intrastromal incisions, and your incisions will need to be longer, but that’s the extent of its limitations. You can’t do intrastromal incisions manually.”

Intrastromal incisions began with nomograms created by Dr. Julian Stevens in London, explains Dr. Tauber. “That’s the nomogram we use,” he says. “We’re working with Dr. Doug Koch at the Baylor College of Medi-



cine to continue perfecting intrastromal incisions. In Europe, others have demonstrated the stability of intrastromal incisions as well as their faster healing rate. So far, there doesn't seem to be any progression [to corneal melt], which is sometimes seen with anterior penetrating incisions."

One other benefit of an intrastromal incision is peace of mind—though the possibility of infection is already rare with anterior penetrating incisions, there's almost no risk of infection with intrastromals. "In theory, there shouldn't be an infection when an incision doesn't break the surface," Dr. Tauber explains.

- **Cyclorotation detection.** The LensAR, LenSx (Alcon), Victus (Bausch + Lomb) and now the Catalys (Johnson & Johnson Vision) are some of the lasers that include a system for detecting and compensating for cyclorotation. "To me," says Dr. Tauber, "the dividing line between manual and femto comes down to two things: the laser's ability to do intrastromal incisions, which is better in my mind for the ocular surface, and the laser's cyclorotation detection and correction. For the first time in the history of astigmatic correction we're no longer using ink pen-style marking, which has a significant number of inaccuracies built into it for both astigmatic incisions and toric IOLs. With the advent of cyclorotation detection and correction, the femtosecond laser has become a solid tool.

"Traditionally, we marked the cornea with ink at the slit lamp or as the patient entered the operating room," Dr. Tauber continues. "However, a paper in 2011 showed that manual marking error can amount to more than nine degrees, with a range up to 10 degrees.<sup>9</sup> That's quite a margin of error. Femtosecond lasers reduce that error, so we're thrilled."

- **Real-time OCT.** Manual LRIs may be dislocated or penetrate the cornea too deeply. Using OCT in conjunction with the femtosecond laser

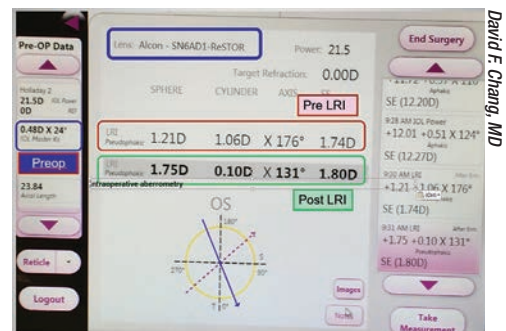
enhances precision and allows surgeons to see how deeply they're cutting. Dr. Gupta points out. With OCT, surgeons can obtain in seconds images of the anterior and posterior cornea, in addition to pachymetry, corneal diameter, anterior chamber depth and iris boundaries. "OCT allows us to plan and program the laser to treat at a specific depth, say 80 percent," she says. "When doing manual incisions, we're not able to precisely image the cornea, so there'll be some variability not only in depth of placement but also in the incision itself. Depending on the force of pressure, it's also possible to perforate the cornea."

"You have several safety margins when OCT gives you the anatomy," adds Dr. Tauber. "Real-time OCT will change if your patient moves, which allows you to either stop before you start or to abort an incision, whether it be for cataract removal, a paracentesis or an arcuate. If your patient moves enough, the OCT will show you that the incision may not be where you want it. This rarely happens, but it's a beautiful safety factor."

## Pro Manual

"A surgeon must interact with the eye—a laser can't do that," says Dr. Safaran, who finds lasers to be overkill at best and dangerous at worst. He says that while many studies show it's possible to use a femtosecond laser for keratotomy and cataract surgery, their findings point to higher complication rates and no clinically-meaningful improvements over conventional means.<sup>10-11</sup>

David F. Chang, MD, a clinical professor at the University of California, San Francisco, and in private practice in Los Altos, California, says his use of astigmatic keratotomy has declined substantially now that presbyopia-correcting IOLs all come in toric versions



Intraoperative wavefront aberrometry showing pre- and post-LRI refractions performed following placement of a multifocal IOL. The preop keratometric cylinder was 0.48 D x 24, but the pseudophakic refraction unexpectedly showed 1.06 D x 176. After placing two LRIs, this was reduced to 0.1 D. Postop, the patient had a spherical refractive outcome. Note: the spherical equivalent is misleading with pseudophakic intraoperative aberrometry because injecting enough OVD to make the eye firm pushes the IOL posterior to its eventual postop anatomic plane surgeons say.

and the light adjustable IOL (RxLAL; RxSight) is available. When he does perform astigmatism keratotomy, however, he prefers a blade. "One indication for astigmatic keratotomy is for eyes with low astigmatism (i.e., estimated 0.5 to 0.75 D) because we don't have lower-power toric IOLs," he says. "Astigmatic keratotomy is also a less expensive alternative for patients who can't afford a toric IOL."

Here are some reasons surgeons prefer to stick with a blade:

- **In-clinic convenience.** With manual incisions, doctors have the convenience of correcting astigmatism at the slit lamp during a regular postop exam, rather than taking the patient back to the operating room or laser suite. Additionally, some surgeons believe that correcting astigmatism in the postop phase at a follow-up visit may result in better outcomes because the eye is more stable.

Postop astigmatic correction can be very beneficial. For example, Dr. Chang's preferred way of managing complex astigmatism is the light-adjustable IOL from RxSight. "We can

EVERY MONDAY  
**E-NEWS YOU CAN USE**



Have you been receiving and reading custom e-blasts from *Review of Ophthalmology*?

If not, you're missing out on valuable information!

You're a busy practitioner and not surprisingly, your e-mail inbox is often full. Fortunately, when you scan through the sender list, determining which messages to delete and which to save or read, you can feel confident knowing that e-blasts from *Review of Ophthalmology*, a Jobson Medical Information LLC publication, contain the most current and comprehensive information available in the field to keep you on the cutting edge.

*Review of Ophthalmology's* online stable of products includes editorial newsletters and promotional information about new products, treatments and surgical techniques, as well as alerts on continuing education courses for ophthalmologists.



Our FREE weekly e-newsletter, *Review of Ophthalmology Online*, brings you the latest in ophthalmic research, as well as industry news. In an effort to keep eyecare professionals informed, this resource is waiting in your inbox **every Monday morning**.



*Retina Online*, our free monthly e-newsletter, is for retina specialists and general ophthalmologists interested in enhancing their knowledge on the topics of retina and related disease diagnosis and treatment, as well as the latest in surgical procedures.

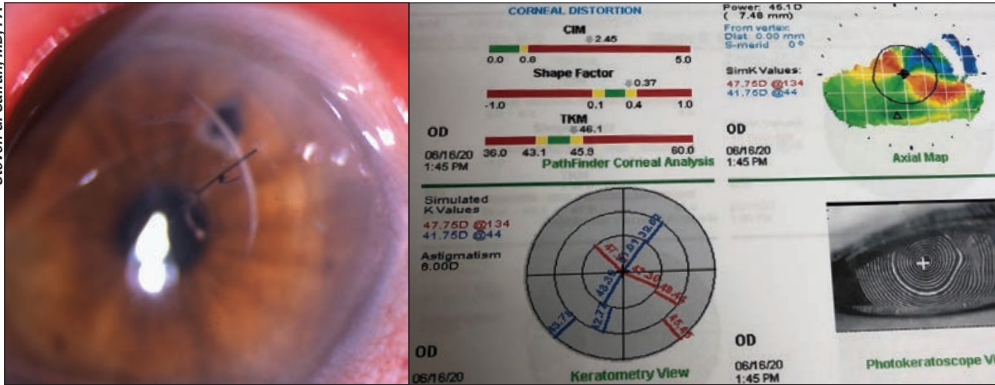
Your time is valuable — and so is your practice. These e-products are the most effective way for you to receive updates on breaking news and research — all just a click away.

**DON'T MISS OUT!**

Unfamiliar with our products? Visit [www.reviewofophthalmology.com](http://www.reviewofophthalmology.com) and check out our newsletter archives.

Go to [www.jobson.com/globalEmail/default.aspx](http://www.jobson.com/globalEmail/default.aspx) to sign up for the e-newsletters that interest you.

Steven G. Safran, MD, PA



A FLACS LRI causing 6 D of irregular/regular astigmatism. Patient refraction was +0.25 -4.25 X, with cloudy vision and vitreous in the anterior chamber. One of the original two sutures was removed by the referring surgeon. The patient is about five months post-cataract surgery on topical steroids two to four times a day; IOP is normal.

effectively create a ‘customized’ toric IOL several weeks after surgery,” he says. “It’s based on the postop refraction rather than our preop predictions of surgically induced astigmatism, posterior corneal astigmatism, and cylindrical power and axis.”

• **Intraoperative aberrometry.** Dr. Chang says that the best way to improve your LRI results is not by using a femtosecond laser, but by using intraoperative wavefront aberrometry. “Intraoperative wavefront aberrometry has significantly improved my AK results more than relying on preoperative nomogram planning,” he says. “This is because after you place one LRI, you can immediately re-measure the actual refractive astigmatism. Based on this, you could lengthen the first LRI, or add a second LRI opposite to the first. So the best way to improve your LRI results is not by using a femtosecond laser, but rather titrating what you do with pseudophakic intraoperative aberrometry.

“For diffractive multifocal and EDOF IOLs, I always perform intraoperative aberrometry after the IOL implantation,” he continues. “This lets me refine the axis for any toric IOL. If my preop calculations called for a spherical lens, pseudophakic intraoperative aberrometry often indicates some residual astigmatism. Because residual astigmatism reduces multifocal and EDOF performance, I will then add one or two LRIs to reduce the astigmatism to 0.5 D or less, based on titration with intra-

operative aberrometry measurements of the live refraction. Femto AK can’t provide me with the important benefit of adding or titrating LRIs based on the pseudophakic intraoperative aberrometry during surgery.”

• **Manual is sufficient.** One common argument in favor of laser over manual methods is that lasers are more precise. “I think this is misleading,” says Dr. Chang. “There are no long-term studies that have shown superiority of femto AK to either toric IOLs or manual AK. You must have at least six months follow-up to evaluate the regression of effect with incisional keratotomy. There are even conflicting results from studies looking at consistency of femto LRI depth. The greatest variable for astigmatic keratotomy outcomes isn’t the depth of the incision, but corneal hysteresis and patient age.”

Dr. Safran adds that while precision is good, laser-like precision just isn’t necessary. “Besides the fact that laser LRIs are inaccurate by nature, you’re only trying to treat half a diopter or a diopter of astigmatism with an LRI,” he explains. “You’re not trying to treat 3 D. My manual LRI nomograms are small, medium and large, based on the patient’s age and how the tissue responds as I cut it. Let’s say you have a patient with 1.5 D of astigmatism. If I knock it down by 0.75 D or by 1.5 D and correct it all, the patient will be happy. If I overcorrect to 2 D, the patient will be down the other way, but it’s still only by half a diopter. Any correc-

tion between 0.75 and 2 D will work. LRIs don’t need to be super precise.”

• **Lasers aren’t an improvement.** “For years, we had no real peer-reviewed data on femto corneal relaxing incisions until a 2016 paper on intrastromal astigmatic keratotomy,” says Dr. Safran. “But this study reported safety with only one month of follow-up data, and they achieved less than half a diopter of correction.<sup>12</sup> Another study of 51 eyes concluded that laser CRIs were effective, but the data show that over the three-month follow-up period, the mean effect of astigmatism correction was decreasing while the range of outcomes was increasing,” he says. “It was getting more unpredictable.<sup>13</sup>

“If you look at the laser studies, there’s very little effect—maybe a quarter of a diopter of correction, and that’s nothing—a homeopathic effect,” he continues. “But when laser goes wrong, it’s not fixable. We stopped cutting the cornea, because you end up with irreparable damage. Femtosecond laser corneal incisions don’t work until they do work, and when they do work, they create problems.”

Dr. Safran points to several studies showing troubling laser side effects in FLACS, which usually precedes laser LRIs, including acidic shifts in aqueous humor pH,<sup>14</sup> increased levels of prostaglandins,<sup>15,18,11</sup> miosis,<sup>16</sup> increased inflammatory mediators and fibroblast growth factor,<sup>17-18</sup> and higher rates of posterior capsular tears.<sup>11</sup>



“There’s no evidence that FLACS is better than phaco, but plenty of studies showing it may increase complications,” Dr. Safran says. “Cutting the cornea with a laser to correct astigmatism is a bit like warming your hands with a burning coal. Nothing happens until you get burnt. Studies show lasers cause more astigmatism and don’t heal as well as manual incisions.”

The European Society of Cataract and Refractive Surgery conducted a multicenter case-control study across nine European countries and Australia that compared the visual, refractive and adverse outcomes of 2,814 FLACS cases and 4,987 conventional phacoemulsification cases.<sup>8</sup> Seventy-two percent of FLACS and 74.3 percent of manual phaco eyes were within 0.5 D of target. One percent of FLACS and 0.4 percent of manual phaco eyes had worse postop CDVA of five letters or more at follow-up.

The study data suggest that laser use might be more proinflammatory than conventional phaco, and contribute to higher rates of corneal edema, uveitis requiring treatment and early PCO, reducing visual acuity. Though femto patients had less postop astigmatism and less surgically induced astigmatism in the study, femto didn’t yield better visual or refractive outcomes than conventional phaco. In fact, the femto group had worse postop visual acuity, more postop complications (3.2 percent versus 1.8 percent for phaco) and more patients with worse postop visual acuity than their preop visual acuity.

“Some say that lasers can help less-experienced surgeons achieve better outcomes, but that’s not the case,” Dr. Safran says. He points to a study of Wills Eye residents in which FLACS and manual phaco achieved similar complication rates and visual and refractive outcomes.<sup>9</sup> At one month and one year follow-up, visual acuity in the manual phaco group was better (0.11 logMAR [Snellen: 20/26] at one

month; 0.08 logMAR [20/24] at one year) than in the femto group (0.13 logMAR [20/27] at one month; 0.13 logMAR at one year), though these between-group differences weren’t statistically significant at either time point. Persistent postop inflammation occurred in significantly more cases in the femto group. The researchers add that rates of macular edema and elevated IOP were similar between the groups.

• **Cut where you want.** “LRIs are much more predictable, heal faster and are safer than laser corneal incisions because you’re cutting along the circumferential corneal annulus of fibers, which contains blood vessels and stem cells,” Dr. Safran says. “If the manual LRI doesn’t work the way I want it to, it doesn’t cause a problem, because it’ll heal. It won’t cause that ectasia pattern that occurs when you cut the cornea.”

Dr. Safran says he can place manual incisions exactly where he wants them in the limbus, but that’s not possible with a laser. “Because of the laser’s design, you can’t make cuts close enough to the limbus for true LRIs,” he explains. “The cuts don’t end up where they’re supposed to be, and are instead on the peripheral cornea.”<sup>20</sup>

Intrastromal incisions also suffer from inherent laser inaccuracies, says Dr. Safran. He points to a 2017 study of 77 eyes of 77 patients that used anterior segment OCT to visualize intrastromal corneal incisions and anterior penetrating arcuates to analyze structural changes and location of incisions.<sup>21</sup> The researchers found that the intrastromal incisions were frequently placed more anteriorly than planned and that incision midpoint depth varied among patients. They concluded that further improvements are needed to ensure precise incision location. **REVIEW**

*Dr. Gupta is a consultant for Alcon. Dr. Tauber is a consultant for J&J Vision. Dr. Safran has been a speaker*

*for J&J Vision and Optos. Dr. Chang is a consultant for Carl Zeiss, RxSight and J&J Vision.*

- Ferrer-Blasco T, Montés-Micó R, Peixoto-de-Matos SC, et al. Prevalence of corneal astigmatism before cataract surgery. *J Cataract Refract Surg* 2009;35:1:70-75.
- Budak K, Friedman NJ, Koch DD. Limbal relaxing incisions with cataract surgery. *J Cataract Refract Surg* 1998;24:4:503-8.
- Bayramlar H, Daglioglu MC, Borazan M. Limbal relaxing incisions for primary mixed astigmatism and mixed astigmatism after cataract surgery. *J Cataract Refract Surg* 2003;29:4:723-8.
- Monaco G, Scialdone A. Long-term outcomes of limbal relaxing incisions during cataract surgery: Aberrometric analysis. *Clin Ophthalmol* 2015;9:1581-7.
- Kim DH, Wee WR, Lee JH, et al. The short term effects of a single limbal relaxing incision combined with clear corneal incision. *Korean J Ophthalmol* 2010;24:2:78-82.
- Visco DM, Bedi R, Packer M, et al. Femtosecond laser-assisted arcuate keratotomy at the time of cataract surgery for the management of preexisting astigmatism. *J Cataract Refract Surg* 2019;45:12:1762-9.
- Venter J, Blumenfeld R, Schallhorn S, et al. Non-penetrating femtosecond laser intrastromal astigmatic keratotomy in patients with mixed astigmatism after previous refractive surgery. *J Refract Surg* 2013;29:3:180-6.
- Culbertson D. Why use a femtosecond laser for incisions? Presented at ESCRS, September 2012. Milan, Italy.
- Visser N, Berendschot T, Bauer N, et al. Accuracy of toric intraocular lens implantation in cataract and refractive surgery. *J Cataract Refract Surg* 2011;37:8:1394-1402.
- Ewe S, Abell R, Oakley CL, et al. A comparative cohort study of visual outcomes in femtosecond laser-assisted versus phacoemulsification cataract surgery. *Ophthalmol* 2016;123:1:178-82.
- Popovic M, Campos-Möller X, Schlenker MB, et al. Efficacy and safety of femtosecond laser-assisted cataract surgery compared with manual cataract surgery: A meta-analysis of 14,567 eyes. *Ophthalmol* 2016;123:10:2113-26.
- Day A, Lau N, Stevens J, et al. Nonpenetrating femtosecond laser intrastromal astigmatic keratotomy in eyes having cataract surgery. *J Cataract Refract Surg* 2016;42:102-9.
- Wang L, Zhang S, Zhang Z, et al. Femtosecond laser penetrating corneal relaxing incisions combined with cataract surgery. *J Cataract Refract Surg* 2016;42:995-1002.
- Rossi M, Di Censo F, Di Censo M, et al. Changes in aqueous humor pH after femtosecond laser-assisted cataract surgery. *J Refract Surg* 2015;31:7:462-5.
- Schultz T, Joachim SC, Kuehn M, et al. Changes in prostaglandin levels in patients undergoing femtosecond laser-assisted cataract surgery. *J Refract Surg* 2013;29:11:742-7.
- Jun JH, Hwang KY, Chang SD. Pupil-size alterations induced by photodisruption during femtosecond laser-assisted cataract surgery. *J Cataract Refract Surg* 2015;41:2:278-85.
- Chen H, Lin H, Zheng D, et al. Expressions of cytokines, chemokines and growth factors in patients undergoing cataract surgery with femtosecond laser pretreatment. *PLoS One* 2015 Sept 2;10:9:e0137227.
- Liu YC, Setiawan M, Ang M, et al. Changes in aqueous oxidative stress, prostaglandins, and cytokines: Comparisons of low-energy femtosecond laser-assisted cataract surgery versus conventional phacoemulsification. *J Cataract Refract Surg* 2019;45:2:196-203.
- Manning S, Barry P, Henry Y, et al. Femtosecond laser-assisted cataract surgery versus standard phacoemulsification cataract surgery: Study from the European Registry of Quality Outcomes for Cataract and Refractive Surgery. *J Cataract Refract Surg* 2016;42:12:1779-1790.
- Gavris M, Belicioiu R, Olteanu I, et al. The advantages of femtosecond laser-assisted cataract surgery. *Romanian J of Ophthalmol* 2015;59:1:38-42.
- Wang L, Jiang L, Hallahan K, et al. Evaluation of femtosecond laser intrastromal incision location using optical coherence tomography. *Ophthalmol* 2017;124:8:1120-5.

## Point-Counterpoint: SLT vs. Medical Therapy

## Don't Give Up on Meds

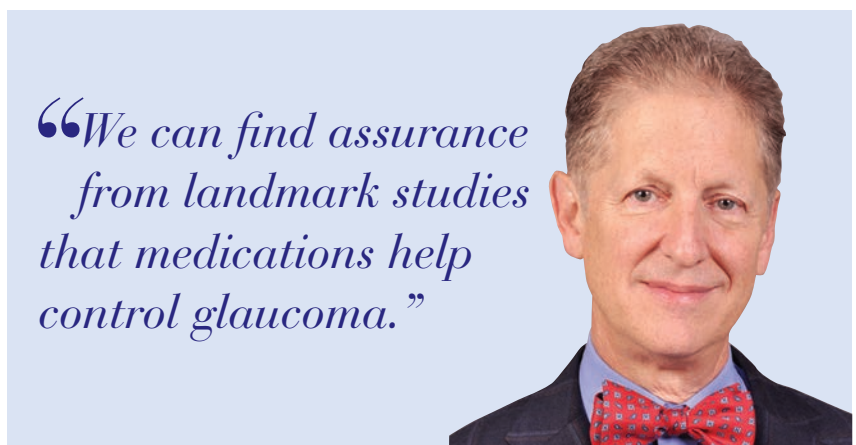Robert Fechtner, MD, Syracuse, New York

The proposal to begin treating newly diagnosed glaucoma patients with selective laser trabeculotomy instead of traditional medical therapy challenges decades of clinical reasoning and practice patterns. I'm sure Tony Realini, MD, my debating opponent, so well-steeped in the practice and research of first treating with SLT, offers a compelling argument for making this major change. In practice we aren't doing that. Are we just not ready? Paradigm shifts don't come easily. The reason may be not fully apparent until we examine evidence and custom. In this counterpoint, let me elucidate my remaining questions as we consider SLT first for all.

### Good Data, No Doubt

Let me first acknowledge that several prospective trials, such as the LiGHT and the WIGLS studies (led by Dr. Realini), present strong arguments that initial treatment with SLT works.<sup>1-6</sup> We would do well to pay attention to these studies, and also to recognize that this proposal extends to treatment of ocular hypertension, not just a new diagnosis of glaucoma.

The St. Lucia WIGLS trial involved patients who had previously been treated with medications and those who were treatment-naïve. To me, the intriguing result is how effective SLT was and how long the positive effect of SLT lasted in this Afro-Caribbean population. These findings are com-



PELLING, and we should consider this possible benefit of SLT on a broader global scale.

The LiGHT study looked at newly diagnosed patients, the ones we're discussing here. It's worth mentioning that this wasn't a study with a primary endpoint of outcomes, such as structural or function progression (although visual field results have been reported). Rather, the study had fewer familiar primary endpoints, such as demonstrating no difference between the groups in health-related quality of life and a very small difference in the frequency of visits at the target pressure, including 93 percent in the laser group and 91 percent in the medication group. The study couldn't show differences in IOP control since the design was “treat in pursuit of target.”

No surgery was needed to lower IOP in the laser group, compared to 11 surgeries needed for the medical therapy group. Laser patients could

be advanced to medications. Medication patients were excluded from laser. (More about the significance of this later.) The study also looked at cost-effectiveness under the United Kingdom National Health Service, but that can't be generalized to the United States health-care system.

What does LiGHT tell me? SLT first works. Medication first works. Repeat SLT works. Medications can be added whether SLT or medication was first. We know all this, don't we? All told, the benefits demonstrated for SLT were what I consider meaningful but secondary benefits. Have the quality-of-life and cost-effectiveness data changed our paradigm? Not yet. Why not? Please keep reading.

### Adherence, Burden

In glaucoma care, we keenly appreciate issues of adherence and  
*(Continued on page 50)*

## Point-Counterpoint: SLT vs Medical Therapy

# Time to Stop the Drops

Tony Realini, MD, MPH, Morgantown, West Virginia

If you were diagnosed with primary open-angle glaucoma today, would you prefer selective laser trabeculoplasty or medical therapy? If you're like most of the ophthalmologists I've spoken to during the past 10 years, you'd raise your hand for SLT. But suppose I asked how many of your patients with newly diagnosed POAG receive primary SLT—would you join most of our colleagues and lower your hand?

That's the conundrum I encounter frequently: Doctors who treat their patients differently than they would want to be treated themselves. And here's my confession: I used to be one of those doctors. I've given a lot of thought to my transition from meds-first to laser-first, and I've identified a handful of issues that I had to overcome along the way. In this point-counterpoint article, I'll take the laser-first position, and I'll explain why my practice has evolved this way. My goal is not to convince those who believe in medications as the first line of treatment for most patients; instead, I'm talking to the many of you out there who are ready to make the transition and need that last gentle nudge to make it happen.

### First: The Why

Why am I advocating for SLT to be the preferred first-line treatment for glaucoma? What's so great about it that we would even discuss a paradigm shift in treatment? If you're

*“Why pick treatments many patients won't use, knowing nonadherence will worsen their condition?”*



one of the many ophthalmologists who would hypothetically prefer first-line SLT if you were diagnosed with glaucoma, you've already answered this question for yourself, so ask yourself why you feel this way.

There are a number of good reasons. The most important consideration—efficacy—will be discussed more fully below, but suffice it to say that primary SLT is as equally effective as daily prostaglandin analog therapy, which the vast majority of your patients who aren't receiving primary SLT will end up taking. Safety is another key concern. Many patients will experience mild pain and inflammation for a few days after SLT, but the evidence for sight-threatening complications of SLT exists in the medical literature only at the level of case reports.

I've encountered far more common and more severe adverse events from topical therapy than from SLT.

Cost is also a factor. At a systems level, the SLT-first approach has been shown to be more cost-effective to the health-care system than a meds-first approach.<sup>1</sup> At a patient level, insurance may not cover drug costs but will cover procedure costs, and for uninsured patients, SLT is cheaper in the long run than buying medications every month (although the cost is all up front, rather than being amortized over the patient's lifetime).

These are good reasons to choose SLT over medications, but not the best ones. The best single reason is this: SLT keeps people off medications. Don't get me wrong—there's nothing inherently wrong with medications. But there's nothing inherently right about them, either. They burn, they sting, they make the eyes red, and these symptoms are magnified in the 50 percent or more of

*(Continued on page 52)*



**Don't Give Up on Meds***(Continued from page 48)*

burden of treatment—very patient-centric aspects of care. I continue to teach that 100 percent of patients are adherent to SLT as long as they show up for the laser appointment—a rate impossible to achieve with self-administration of daily drops. We have a lot of evidence suggesting that adherence to chronic medical therapy is poor, whether it involves glaucoma drops, insulin injections or anti-rejection treatments after solid-organ transplants. We assume SLT provides a better experience for patients than administering drops one or more times a day. We can also infer that taking adherence out of the hands of patients may improve outcomes.

But accepting “SLT first” for newly diagnosed patients is not a panacea. We just don't really see that many newly diagnosed patients. Most patients we will care for this year have had glaucoma or ocular hypertension for a number of years. New patients are relatively infrequently encountered compared to the volume of chronic cases we manage.

We don't know from the data that Dr. Realini has presented how well the laser works in eyes that have undergone chronic medical therapy or if the use of SLT after medication can eliminate the need for medication. We also know SLT isn't appropriate for some secondary glaucomas, such as neovascular glaucoma, inflammatory glaucoma or narrow-angle glaucoma.

The results of the LiGHT studies are impressive. However, we must remember an important principle: The results of a study are applicable to that study's population and don't always generalize well, despite the similarities some of our patients may share with some of the patients in a study. Broader, global studies will be welcome if they further support that

treating patients first with SLT gives a better outcome than once-daily prostaglandin therapy as a first step.

**Established Treatment**

The fact is that, for now, we can find assurance in evidence from landmark studies, including LiGHT, that medications help control glaucoma. Can we agree that this is not a bad thing? Medical therapy alone or medications and laser together slow progression from ocular hypertension to glaucoma (OHTS study) and progression in newly diagnosed glaucoma patients (EMGT study).<sup>7,8</sup> The EMGT study requires some perspective because the subjects received both medical therapy and laser treatment upon diagnosis. What's important here, though, is that we have structural and functional outcome data for the use of medical therapy alone and the combination of medical and laser trabeculoplasty, and that these data come from studies with many years of follow up. However, the LiGHT study suggests that SLT first followed by medication, compared to medications alone, produced a better visual field outcome several years down the line.

Another important point worth considering: We can offer SLT first, but it doesn't eliminate the eventual need for medications. In another very recent study, (selective laser trabeculoplasty versus topical medication), researchers found that at month 24, successful IOP reduction was 18.6 percent better in the medication group compared to the SLT group.<sup>9</sup> Even if we agree that using SLT first offers patient-centric benefits, we might expect half of those patients to require medication within two years, according to this study. Two additional years free of glaucoma medication is a worthwhile quality-of-life benefit. It's unknown if offers an improved outcome.

Granted, the researchers in this most recent study used a different approach to laser treatment than what was used in the LiGHT study. I believe this is one more point that demonstrates that we still have more to learn when it comes to SLT followed by medication or vice versa.

We don't have clarity yet on what to do when the beneficial effects of the laser wear off. Will a repeat SLT provide additional years of control? I believe it will, at least for some patients. Then we add medication.

**Access to SLT**

SLT first works only if patients have access to SLT. We assume when we say SLT first that patients can actually get access to laser treatment. That isn't always the case, given the misdistribution of health-care resources. Not every physician's office has a laser. For at least some patients, finding access to a laser treatment would pose a burden on them.

We also need to recognize that we're debating this issue in a wealthy, developed nation, not in less-advantaged countries, where patients have just as much need for an effective treatment of glaucoma. An environment where there are few ophthalmologists, no lasers and no intact medication distribution channels makes our question irrelevant. Inequities—which also exist among patients with little or no access to care in our country—raise troubling public-health questions. We must appreciate that many of the fortunate among us in this country have the luxury of considering both options.

We also have a scope of practice in the United States that would prevent some patients from immediately accessing initial SLT. New diagnoses of ocular hypertension and glaucoma are often made by optometrists. The use of the laser by optometrists is

*(Continued on page 54)*

# OPHTHALMIC

## *Product Guide*



Innovative products to  
enhance your practice

The **future**  
is in your  
hands. One  
tap, many  
possibilities.

Experience the digital edition on your handheld device.  
Use your smart device to scan the code below or visit:



[www.reviewofophthalmology.com/publications/archive](http://www.reviewofophthalmology.com/publications/archive)

Download a QR scanner app. Launch app and hold your mobile device over  
the code to view [www.reviewofophthalmology.com/publications/archive](http://www.reviewofophthalmology.com/publications/archive).

**REVIEW**<sup>®</sup>  
of Ophthalmology

**Time to Stop the Drops***(Continued from page 49)*

glaucoma patients who have concurrent ocular surface disease. For generally asymptomatic patients with mild to moderate glaucoma, topical therapy imposes a burden that's worse than the disease from their perspective.

It's no wonder adherence to medical therapy is notoriously poor and nonadherence compromises intraocular pressure control and leads to disease progression in so many patients. Why would we pick a treatment that many of our patients won't use, knowing their nonadherence could worsen their glaucoma? As my mentor Rob Fechtner, MD, arguing the other side of this issue on page 50, once told me, "There's never been a documented case of nonadherence to trabeculoplasty."

I have to underscore this point: SLT keeps people off medications. The American Academy of Ophthalmology and the European Glaucoma Society assert that the ultimate goal of glaucoma therapy is to preserve quality of life. The commitment of daily self-dosing, the costs and the side effects associated with medical therapy take a toll on quality of life. Many of you have already reached the conclusion that reducing or eliminating the medication burden is an important goal when caring for glaucoma patients. This is why you offer minimally invasive glaucoma surgery with elective cataract surgery. You know they'll be happier on fewer or no drops. So why are you still starting them on drops in the first place?

**Seeing the LiGHT**

Despite the benefits of SLT, one thing has been missing: high quality data. We can't expect to drive an evidence-based treatment paradigm change without evidence. The recent LiGHT study (Laser in Glaucoma

and ocular HyperTension) provides this crucial missing piece.<sup>1</sup>

The three-year (and ongoing), 718-patient LiGHT study was well-designed, adequately powered and well executed. Treatment-naïve patients with mild-to-moderate POAG or high-risk ocular hypertension were randomly assigned to SLT or medical therapy (starting with a prostaglandin analog) as first-line treatment. The results? IOP control was comparable in both groups, but more eyes in the medication group than in the SLT group had disease progression (36 versus 23), and all 11 eyes requiring trabeculectomy were in the medication group. At three years, 60 percent of SLT eyes remained medication-free after a single treatment, and 78 percent were medication-free with one or two SLT treatments. By comparison, 65 percent of eyes in the medication group were well-controlled on a single medication at three years, while 35 percent required additional adjunctive therapies. Interestingly, achievement of target IOP was 93 percent in the SLT group and 91 percent in the medication group. Thus, the higher progression rates and surgical rates in the medication group suggest some patients in the medication group may have taken their medications only at the time of study visits and had higher IOP between visits, leading to progression and the need for surgery.

**Time for a Change**

At this point, I hope you're convinced that primary SLT offers a better quality of life than medical therapy for many of our patients. When I decided 10 years ago that I wanted my patients to benefit from primary SLT, I encountered key barriers created by what I call the four "Ts": Time; Talk; Transience; and Timing. Here's how I overcame them to provide primary SLT to more than 90 percent of my

newly diagnosed patients.

- **The Time issue.** Time is precious, especially when we're face-to-face with our patients. Many ophthalmologists have told me that it just takes too much time to discuss SLT versus meds. It's far easier and faster to write a prescription for a prostaglandin analogue. This is true. However, those of you who perform MIGS have decided that the discussion time is worth investing to reduce or eliminate your patient's glaucoma medication burden at the time of cataract surgery. And those of you who implant premium IOLs have decided that the discussion time for these upgrades is worth investing to improve quality of life through spectacle independence. Treat your SLT discussion the same way—if you believe it's the right thing to do (like MIGS and/or premium IOLs), you'll find the time to discuss doing it.

- **The Talk issue.** How we talk to our patients about SLT determines their interest in the treatment. My informed consent discussion has evolved over time in concert with my attitudes toward SLT. Initially, I presented SLT as an alternative to the standard approach of medical therapy, which—in the early days—it was. Not surprisingly, fewer than 5 percent of my patients opted for SLT. Who wants to deviate from the standard of care? Over time, I came to believe that these treatment options were equal in quality and that I should present them accordingly. When I began telling patients that we have two good treatment options, described them both, and asked which they preferred, about a quarter of my patients opted for SLT.

As my own experience with SLT grew—both in the clinical and the research arenas—I came to believe (in all the ways described above) that SLT was better than medications for most patients (which is why most

*(Continued on page 54)*





I was only seeing light flashes early on, but light

**FLASHES**

when you've not seen anything for  
so many years—it was wonderful

—Keith H, retinal prosthesis recipient

**WE'RE SEEING  
AMAZING RESULTS.  
AND SO ARE THEY.**

At the Foundation Fighting Blindness our mission is everybody's vision. Our work shines a light on the darkness of inherited retinal diseases (IRDs).

We're the world's leading organization searching for treatments and cures. We need your help to fuel the discovery of innovations that will illuminate the future for so many. We have robust disease information, a national network of local chapters and support groups, local educational events, and our My Retina Tracker® Registry to help keep your patients connected with clinical and research advancements.

Help accelerate our mission  
by donating at [ECPs4Cures.org](https://ECPs4Cures.org).

**FOUNDATION  
FIGHTING  
BLINDNESS**

[FightingBlindness.org](https://FightingBlindness.org)

### Don't Give Up on Meds

(Continued from page 50)

limited to Alaska, Kentucky, Louisiana and Oklahoma. A substantial change in practice patterns would have to occur for optometrists to refer all newly diagnosed glaucoma patients to ophthalmologists for laser surgery. The social and economic barriers would likely be difficult to resolve.

Finally, while I see compelling evidence that the laser can be equally effective, at least initially, and for offering secondary benefits, we need to make sure we don't dismiss the utility of medications. Some patients won't respond to SLT, or the efficacy will diminish over time.

### How Long?

One final thought to close my side of this debate: Even if we reach a consensus on SLT-first treatment, we're introducing evidence-based changes that may take many years to adopt. I'm reminded of a classic paper that shows us that 17 years typically passes between the time when meaningful research calls for evidence-based changes in patient care and the time when those changes reach clinical practice.<sup>10</sup> So, what are we waiting for? Go ahead. Adopt first-line SLT for most patients newly diagnosed with glaucoma or ocular hypertension. But remember the many barriers, including several that aren't under our control at this point. **REVIEW**

*Dr. Fechtner is professor and chair of Ophthalmology and Visual Sciences at SUNY Upstate Medical University in Syracuse. He has published widely on medical therapy for glaucoma, but is thankful to have an SLT laser down the hall.*

*Dr. Fechtner consults with Aerie and Nicox.*

1. Gazzard G, Konstantakopoulou E, Garway-Heath D, et al. Selective laser trabeculoplasty versus eye drops for first-line treatment of ocular hypertension and glaucoma (LiGHT): A multicentre randomised controlled trial. *Lancet* 2019;293:0180:1505-1516.
2. Realini T, Shillingford-Ricketts H, Burt D, et al. West Indies Glaucoma Laser Study (WIGLS): 12-month efficacy of selective laser trabeculoplasty in Afro-Caribbeans with glaucoma. *Am J Ophthalmol* 2017;184:28-33.
3. Realini T, Shillingford-Ricketts H, Burt D, et al. West Indies Glaucoma Laser Study (WIGLS)-2: Predictors of selective laser trabeculoplasty efficacy in Afro-Caribbeans with glaucoma. *J Glaucoma* 2018;27:10:845-848.
4. Realini T, Shillingford-Ricketts H, Burt D, Balasubramani. West Indies Glaucoma Laser Study (WIGLS) 3. Anterior chamber inflammation following selective laser trabeculoplasty in Afro-Caribbeans with open-angle glaucoma. *J Glaucoma* 2019;28:7:622-625.
5. Realini T, Olawoye O, Kizor-Akaraie N, et al. The Rationale for selective laser trabeculoplasty in Africa. *Asia Pac J Ophthalmol (Phila)* 2018;7:6:387-393.
6. Polat J, Grantham L, Mitchell K, Realini T. Repeatability of selective laser trabeculoplasty. *Br J Ophthalmol* 2016;100:10:1437-41.
7. Kass MA, Heuer DK, Higginbotham EJ, et al. The ocular hypertension treatment study: A randomized trial determines that topical ocular hypotensive medication delays or prevents the onset of primary open-angle glaucoma. *Arch Ophthalmol* 2002;120:6:701-13.
8. Anders Heijl A, Leske MC, Bengtsson B, et al. Reduction of intraocular pressure and glaucoma progression: Results from the Early Manifest Glaucoma Trial. *Arch Ophthalmol*, 2002;120:10:1268-79.
9. Ghee Soon Ang GS, Fenwick E, Constantinou M. Selective laser trabeculoplasty versus topical medication as initial glaucoma treatment: The glaucoma initial treatment study randomized clinical trial. *Br J Ophthalmol* 2020;104:6:813-821.

### Time to Stop the Drops

(Continued from page 52)

of us ophthalmologists would want primary SLT for ourselves). Once I started sharing with patients that I would select SLT for myself if I had their eyes, patients rarely chose medical therapy. After all, who would want a different treatment than the one the doctor would want for himself? For those of you who may view this approach as too paternalistic for the new age, ask yourself this: If you had cancer, would you want your oncologist to offer you treatment options without ranking them best to worst and let you pick one, or would you want her to succinctly synthesize everything she knows about cancer and its treatment by telling you what she thinks is the best option for your cancer?

• **The Transience issue.** SLT wears off over time, typically within a few years for most patients. SLT can be safely repeated, however, and restores IOP to the same level achieved by the first SLT. There are no reports in the peer-reviewed literature of unique complications of repeat SLT after 20 years of its use. If the fact that SLT isn't permanent keeps you from using it, remember that prostaglandin analog therapy wears off too, every day, and has to be repeated every day as well. My patients understand that sitting still for five minutes every few years is preferable to sitting still for five minutes every day for self-administration of drops.

• **The Timing issue.** Once you start doing SLT, you'll find that popping in and out of the laser suite can disrupt the flow of a busy day. Here's my pearl: The first three appointments in every one of my clinic schedule templates are laser slots. I perform them all up front, at the start of the clinic session, so I can then remain focused on patient flow and stay on schedule.

### It's Time

In the glaucoma world, 2020 is the age of enLiGHTenment. The time is right for a paradigm change. Our patients are well-informed, and their expectations have never been higher. We have data to support an evolution in practice patterns. Let's make it happen. **REVIEW**

*Tony Realini, MD, MPH, is a professor of ophthalmology and glaucoma fellowship director at West Virginia University in Morgantown. He has no financial relationships with any SLT manufacturers.*

1. Gazzard G, Konstantakopoulou E, Garway-Heath D, et al. Selective laser trabeculoplasty versus eye drops for first-line treatment of ocular hypertension and glaucoma (LiGHT): A multicentre randomised controlled trial. *Lancet* 2019;393:1505-16.
2. Katz LJ, Steinmann WC, Kabir A, et al. Selective laser trabeculoplasty versus medical therapy as initial treatment of glaucoma: A prospective, randomized trial. *J Glaucoma* 2012;21:460-8.

# New Forceps for Tough IOL Implantations

**I**f you're looking for assistance with placing IOLs in eyes with little or no capsular support, Bausch + Lomb says its new 25-gauge Scleral Fixation Forceps, part of the company's Pinnacle 360 instrument line, can help. The new device aids in the placement of scleral-sutured posterior chamber lenses, the company says.

As with all B+L Pinnacle 360 instruments, the new forceps feature ergonomic 360-degree actuation and glare-free tips that undergo a patented fine-wire process to create microserrated edges that promote traction, B+L says. For information, visit [bauschretina.com](http://bauschretina.com).



B+L's new 25-ga. forceps.

## Catalys Upgrades Its Software

Johnson & Johnson Vision recently collaborated with Cassini Technologies on a software upgrade that helps make managing astigmatism easier for users of J&J's Catalys femtosecond laser. The companies say the new software simplifies astigmatism management workflow and increases operational efficiency.

The improvements include advanced visualization that provides full-volume, 3-D, high-resolution and streaming optical coherence tomography imaging, a built-in nomogram for arcuate incisions, and the

addition of iris registration for automatic cyclorotation compensation, the companies say.

For information, visit [jvision.com](http://jvision.com).

## Ngenuity Improves Your View

Alcon recently launched an upgrade for its heads-up 3-D viewing system, Ngenuity. The company says the system's 1.4 upgrade streamlines the setup for Datafusion, (which integrates the company's Constellation vitreoretinal surgery system with Ngenuity), and allows retinal surgeons to track surgical parameters in real-time. The company says the upgrade also supports operating-room spacing and setup to minimize the risk of spreading coronavirus.

This latest version of the Ngenuity System will also be available for the anterior segment in late July, the company says.

The new features for cataract surgeons will include a display of the Centurion Vision System's surgical parameters for real-time surgical feedback, as well as a view of the data from the ORA VerifEye+ intraoperative aberrometer and the aberrometer's reticle.

For more information on the Ngenuity, visit <https://professional.myl->

[con.com/vitreoretinal-surgery/visualization/ngenuity-3d-system/](http://con.com/vitreoretinal-surgery/visualization/ngenuity-3d-system/).


## An Infusion of Lens Comfort

Bausch + Lomb recently received U.S. Food and Drug Administration approval for its new daily disposable silicone hydrogel (SiHy daily) contact lens, the B+L Infuse.

The company says the new contact lens is composed of a next-generation lens material it calls kalifilcon A. Bausch says kalifilcon A is designed to help contact lens wearers who usually complain of contact lens dryness.

The company says that the lens makes use of B+L's latest proprietary contact lens technologies to offer "outstanding breathability for healthy lens wear while providing exceptional all-day comfort and high-definition optics."

The new Infuse contact lens is expected to be available in the second half of 2020, according to the company.



(Continued on page 62)



# Risk Factors for AMD After Cataract Surgery

**A recent study** sought to identify possible pre-, peri- and postoperative risk factors for wet AMD after cataract surgery. The cohort study pulled 2010 to 2017 data from two Swedish registers that included patients who had undergone treatment for wet AMD a year or more after cataract surgery. The researchers compared eyes with and without preoperative AMD that had undergone cataract surgery and were later treated for wet AMD to eyes not treated within the study period. Characteristics such as age, gender, use of a blue light-blocking IOL, preop VA, ocular comorbidities, posterior capsule rupture, date of cataract surgery and date of AMD treatment initiation were also analyzed.

The researchers found that the only independent factor associated with postoperative wet AMD treatment in both groups was female sex (67.3 percent versus 58.8 percent,  $p < 0.001$ , and 66.4 percent versus 60.6 percent,  $p = 0.001$ , respectively). In eyes without preoperative AMD, older age was an independent factor ( $78.4 \pm 6.5$  versus  $73.4 \pm 9.6$  years,  $p < 0.001$ ).

Blue-light-blocking IOL use seemed to decrease the likelihood of developing wet AMD after cataract surgery, but this wasn't statistically significant in eyes with preoperative AMD. The researchers noted any protective effect against developing

wet AMD after cataract surgery from a blue light-blocking IOL must be very small.

*Acta Ophthalmology* 2020 June 23.  
[Epub ahead of print]  
Westborg I, Albrecht S, Granstam E, et al.

## Time Between Exams Tied to Neovascularization Severity

A retrospective, observational study involving 55 patients diagnosed with unilateral Type 3 neovascularization, who later developed neovascularization in the fellow eye, was conducted at the Konyang University College of Medicine in Seoul, South Korea. The study sought to uncover any association between two factors: how much time passed between the previous visit and the visit at which the problem in the fellow eye was discovered (the "examination interval"); and the best-corrected visual acuity and degree of deterioration in that fellow eye when the neovascularization was discovered.

The data showed that there were significant associations between the length of the examination interval and both the BCVA and degree of deterioration in the fellow eye ( $p = 0.005$  and  $p = 0.001$ , respectively). Other findings included:

- The mean interval between the previous visit and the discovery of neovascularization in the fellow eye

was  $4.8 \pm 2.2$  months (range: 2 to 10 months).

- The time between the initial diagnosis of the first eye and the diagnosis of the fellow eye was  $22.7 \pm 17.5$  months.

- Patients were instructed to return to the hospital if they noticed visual deterioration, but only half of the patients recognized deterioration if it was less than three lines, suggesting the importance of monitoring by a health care professional.

The authors state that this result suggests the need for frequent fellow-eye examinations in patients with unilateral Type 3 neovascularization. (The authors note that a high incidence of bilateral involvement is characteristic of Type 3 neovascularization, and preserving the visual acuity in the fellow eye is closely associated with patient quality of life.)

The researchers postulate that a home monitoring system that's able to detect changes in visual function associated with choroidal neovascularization could provide a practical means to reduce this interval without burdening the patient with extra visits.

*Retina* 2020;40:7:1255-61.  
Kim JH, Kim JW, Kim CG, et al.

## MERLOT Turns Sour

Researchers tasked with assessing the efficacy and safety of epimacu-

lar brachytherapy for chronic, active, neovascular nAMD report that EMB is ineffective as an adjunctive treatment when combined with anti-VEGF therapy.

The device trial, called the Macular Epiretinal Brachytherapy vs Ranibizumab (Lucentis) Only Treatment (MERLOT), was conducted at 24 National Health Service hospitals across the United Kingdom. Individuals who had nAMD and received intravitreal ranibizumab were enrolled between 2009 and 2012, and were randomized 2:1 and stratified by lens status and angiographic lesion type to receive either EMB plus as-needed ranibizumab, or just as-needed ranibizumab monotherapy. Participants were followed up monthly for 24 months and then assessed at final visits at month 36. Analyses followed the intent-to-treat approach.

Interventions included pars plana

vitrectomy with 24 Gy EMB plus as-needed ranibizumab vs. as-needed ranibizumab monotherapy.

Copriary outcomes were the number of as-needed ranibizumab injections and the mean change in Early Treatment Diabetic Retinopathy Study best-corrected visual acuity, with a noninferiority margin of -5 ETDRS letters.

Secondary outcomes were the percentage of participants losing fewer than 15 ETDRS letters and gaining zero or more, or 15 or more ETDRS letters and the mean change in angiographic total lesion size, choroidal neovascularization size and foveal thickness on optical coherence tomography.

Of 363 participants, 329 (90.6 percent) completed 24 months of follow-up (222 participants in the EMB group and 107 in the ranibizumab group). Here are some of the findings:

- The mean BCVA change was -11.2 ETDRS letters in the EMB group and -1.4 letters in the ranibizumab group, with a difference of 9.8 ETDRS letters.

- In the EMB group, 65.6 percent of participants (160 of 244) lost fewer than 15 letters vs. 86.6 percent (103 of 119) in the ranibizumab group, with a statistically significant difference of 21 percent.

Investigators say that, despite the acceptable safety of EMB, it didn't reduce the number of ranibizumab injections and was actually associated with worse visual acuity than anti-VEGF treatment alone. They conclude that these results don't support EMB use as an adjunct treatment for chronic, active nAMD.

*JAMA Ophthalmol 2020; July 09.*

*[Epub ahead of print].*

Jackson TL, Soare C, Petrarca C, et al.

## REVIEW Classifieds

### Career Opportunities

#### OPHTHALMOLOGISTS

Danbury, CT

Ophthalmologists to share office with long standing Ophthalmologist in Danbury, CT. High quality equipment. \$2,250 per month or adjoining office without equipment- \$1,750 per month.

203-545-3539 or  
email [mehrimd@aol.com](mailto:mehrimd@aol.com)

**REVIEW**  
of Ophthalmology

**Do you have Products  
and Services for sale?**

CONTACT US TODAY  
FOR CLASSIFIED ADVERTISING  
Toll free: 888-498-1460  
E-mail: [sales@kerhgroup.com](mailto:sales@kerhgroup.com)

**REVIEW**  
of Ophthalmology

# Targeting Ophthalmologists?

**CLASSIFIED ADVERTISING  
WORKS**

Contact us today  
for classified advertising:  
Toll free: **888-498-1460**  
E-mail: [sales@kerhgroup.com](mailto:sales@kerhgroup.com)

**KERHGROUP**





# A Review of Advances in Myopia Management

Researchers and clinicians alike are working together to help stem the rising tide of myopia across the globe.

*Barry N. Wasserman, MD, Tara Franz, OD, and Nidhi Rana, MS, OD, FAAO  
Philadelphia*

**M**yopia is an increasingly prevalent refractive disorder which can ultimately lead to vision loss. An estimated 28.3 percent of the world's population is myopic and 4 percent of the world population has high myopia (greater than -5 D). This percentage is even higher among the East Asian population.<sup>1</sup> High myopia can lead to visual impairment and vision loss from glaucoma, cataracts, retinal detachment and choroidal neovascularization.<sup>2</sup> This public health burden is likely to increase over time, with one study projecting that the prevalence of myopia will increase to 49.8 percent by 2050 and high myopia to increase to 9.8 percent.<sup>1</sup>

Over the past decade, much research has been done on slowing the progression of myopia, and there are now several effective treatment options. This review will highlight the latest treatment options available.

## Myopia Progression

Myopia often progresses as a result of axial lengthening. Proposed pathophysiology involves some level of defocus which sets off a chemi-

cal cascade of neurotransmitters that signal the eye to elongate. Specifically, peripheral light rays focus behind the retina, creating relative hyperopic peripheral refractive error (hyperopic defocus).<sup>3-6</sup> As a result, some optical myopia treatments are designed to stimulate myopic defocus. Other treatments discussed—outdoor sunlight and atropine—are thought to work directly on the neurochemical cascade.<sup>7,8</sup>

## Spectacle Correction

Glasses, utilizing various designs, have been studied for inhibiting myopia progression. In the Control of Myopia Evaluation Trials, COMET and COMET 2, protocols were based on the theory that myopic progression could be controlled by relaxing accommodative effort. However, these studies showed that progressive addition lenses were not clinically effective at slowing progression.<sup>9,10</sup>

A recent study from Hong Kong showed some success with a different spectacle design. A lens called the Defocus Incorporated Multiple Segments (DIMS) spectacle lens is

designed to induce myopic defocus. This lens has a central 9-mm zone for distance viewing, with multiple segments of +3.5-D defocus surrounding the central zone. The design is based on the theory of creating peripheral defocus (i.e., myopic defocus) to inhibit myopic progression instead of relaxing the accommodative system. Although this study was done solely on Chinese children, the results from a two-year, randomized trial were promising: Axial myopia progression was reduced by  $0.55 \pm 0.09$  D.<sup>11</sup>

This study's generalizability is limited due to its homogenous patient sample, and further studies are needed to determine the lens' true ability to limit myopia progression across ethnic populations. Since parents tend to understand the benefits of glasses and myopic children already wear them, it's possible that a myopia-control spectacle lens may be met with less resistance than other forms of treatment.

## Outdoor Sunlight

Time spent outdoors has been shown to have a modest effect on

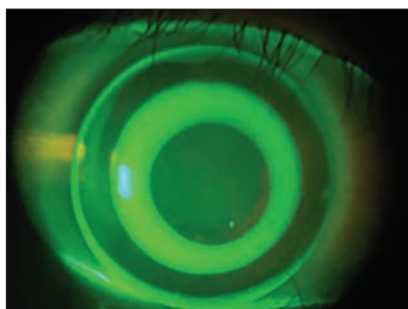


reducing myopia progression. One study in a Chinese population showed that an increase of 40 minutes/day of outdoor time during school was enough to have an effect: The cumulative incidence of myopia was 39.5 percent in the control group vs. only 30.4 percent in the intervention group after three years. In children who already had myopia, however, the change in refractive spherical equivalent was only 0.17 D between groups, with no difference in axial length.<sup>12</sup> A separate one-year study done in Taiwan showed a modest effect (a reduction of 0.12 D) with 11 hours per week of increased outdoor time. This study also demonstrated myopia control, even in a lower-light-intensity environment.<sup>13</sup>

Although incorporating outdoor sunlight is cost-effective and easy for parents to understand, the implementation has been challenging. In the studies, even though parents were instructed to increase outdoor time at home, the compliance was poor. In addition, the effect of myopia control was modest in the three-year study. These studies also have limited generalizability due to their patient population. More studies are required to determine the long-term reduction in myopia progression across different ethnic populations. It's for these reasons that increasing outdoor time for children would be most effective as an adjunct, rather than a primary, treatment option.

## Low-dose Atropine

Treatment with low-dose atropine has become a more popular treatment option following the results of the Atropine for the Treatment of Myopia studies, ATOM 1 and ATOM 2. In these studies, investigators used doses of atropine that were low enough to avoid photophobia and near vision blur, yet could also control myopic progression over time. Specifically,



Nicholas Gidosh, OD, FAAO

Figure 1. The fluorescein pattern seen with an orthokeratology lens demonstrating the reverse geometry design. The central part of the lens flattens the cornea which causes the fluorescein to pool in the mid-peripheral area where the cornea thickens.

ATOM 2 demonstrated that the 0.01% concentration was most effective for myopia control after five years, when taking into consideration the effect following treatment cessation and side-effect profile (SE progression of  $-1.38 \pm 0.98$  D; axial length progression of  $0.75 \pm 0.48$  mm).<sup>8</sup>

However, within the past year, the Low-Concentration Atropine for Myopia Progression (LAMP) study demonstrated that a higher concentration of atropine could have a more profound effect than lower concentrations. After two years, children treated with 0.05% atropine were found to have less myopic progression and less axial lengthening compared to 0.01% (spherical equivalent refraction progression of  $-0.55 \pm 0.86$  D vs.  $-1.12 \pm 0.85$  D and axial length progression of  $0.39 \pm 0.35$  mm vs.  $0.59 \pm 0.38$  mm).<sup>14</sup> However, the LAMP study is still ongoing and the effects of treatment cessation remain unknown.

A major benefit of atropine is that it's effective and easy to implement for parents of young children. Also, studies have shown that these relatively low doses have minimal side effects. However, long-term data in regards to toxicity to ocular structures is not yet available. Additionally, the price of the drug may be a barrier for some patients: A month's supply of a

low dose of atropine has to be compounded and can cost up to \$50 for a bottle if not covered by insurance (totaling \$600 per year). Increased availability in non-compounded forms, which would be possible with some changes from the pharmaceutical industry, or improved insurance coverage for these medications could decrease the therapy's cost-barrier for families.

## Contact Lenses

Researchers and clinicians have been exploring ways that contact lenses can help suppress an eye's drift toward nearsightedness.

- **Orthokeratology.** Until very recently, orthokeratology contact lenses were the only lenses regularly used for myopia control. These rigid lenses are worn overnight and removed in the morning. While the patient is sleeping, the lens flattens the central cornea by epithelial cell compression (See Figure 1). This corneal shape change temporarily reduces myopic refractive error, allowing the patient to see clearly during the day without the lenses. This can be an advantage for patients in sports, especially watersports. As the central cornea flattens, the mid-peripheral cornea simultaneously thickens, which creates peripheral myopic defocus. This myopic defocus is thought to inhibit axial lengthening, thereby inhibiting myopic progression overall.

A recent literature review found that orthokeratology lenses reduced axial elongation by 50 percent over a two-year period (a change of 0.30 mm in the treatment group vs. 0.60 mm in a control group).<sup>15</sup> In these studies, there wasn't sufficient data on a washout period. Therefore, the authors of the study couldn't determine if there was a rebound effect (as happened with some doses of atropine) after treatment cessation.

There are several concerns to ad-

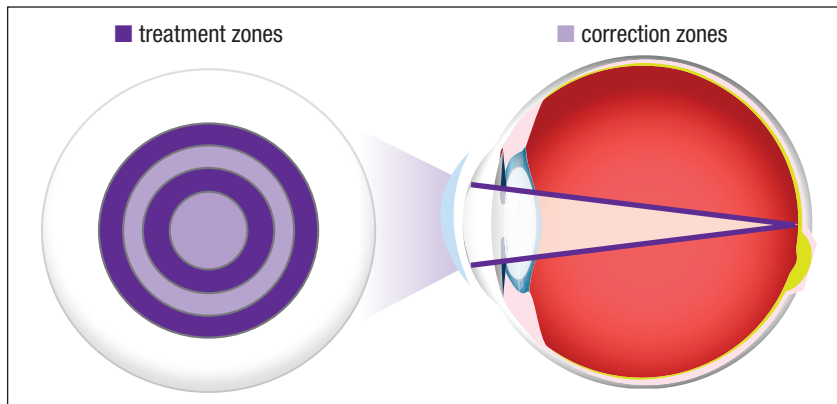


Figure 2. The design of the MiSight contact lens. Myopic correction zones are shown in light purple, whereas the defocus zones or treatment zones (using plus power) are shown in dark purple. Light rays passing through the central correction zone land on the fovea, allowing for clear distance vision, whereas rays going through the peripheral treatment zones land in front of the retina, creating myopic defocus.

dress with orthokeratology treatments. One drawback is that these lenses aren't covered by insurance. The initial orthokeratology fitting process and contact lenses generally range from \$1,000 to \$2,000, but can be as high as \$4,000. Additionally, this is a niche treatment, so the patient must search for an eye-care provider who is specially trained to fit these lenses.

There are other restrictions that can prove to be prohibitive for this form of treatment: The lenses must be worn for eight hours for full correction, and they will only correct up to 6 D of myopia, due to the limits of epithelial cell compression. Also, while adverse events are rare due to the high oxygen permeability of the lenses, microbial keratitis can occur with poor hygiene and poor compliance.<sup>15</sup> This may be a considerable barrier for children, in whom ulcerative keratitis could lead to permanent vision loss.

• **MiSight Lenses.** CooperVision is in the process of launching the first FDA-approved daily wear contact lens for myopia control, called MiSight. The dual-focus design of this contact lens creates myopic defocus to inhibit myopia progression (See Figure 2 for design details).

The company's three-year clinical trial showed a reduction in myopic progression of 0.73 D and axial length reduction of 0.32 mm at three years compared to the control group. In stark contrast to the orthokeratology lenses, which are hard and worn while sleeping, this lens is a daily disposable made from a material similar to the Proclear 1-Day contact lens. There were no serious adverse events (e.g., microbial keratitis) during the three-year study, and wear-time averaged 13 hours per day for the lens.<sup>16</sup> While this is the first randomized clinical trial done with this lens, there have been similar results for other dual-focus contact lens designs.<sup>17</sup>

The MiSight clinical trial is ongoing and will continue for seven years. At the end of the study, the authors hope to be able to assess the long-term myopia control and safety profile of the lens, as well as any rebound effect after treatment cessation. This study also included a more heterogeneous demographic to better understand myopia control across different ethnicities.

There are barriers to this treatment similar to orthokeratology. In order to fit the MiSight lens, the practitioner must be certified through a training

program (launched in the spring of 2020). Lenses are only available to practitioners who have completed the certification process. The lens-fitting process is similar to orthokeratology: There's a charge for the fit, the lenses and any follow-up care required. Unfortunately, the lenses are not covered by insurance and the cost is similar to orthokeratology lenses.

In conclusion, multiple treatment options are currently available to slow the progression of myopia in pediatric patients. Optical defocus spectacles and contact lenses, orthokeratology and low-dose atropine all show similar results in the reduction of myopic progression and a reduction of axial lengthening. The practitioner must decide on the most appropriate option(s) for each patient.

There was less myopic reduction with outdoor sunlight alone. Therefore, it may be appropriate to encourage additional outdoor sunlight exposure in patients who are still emmetropic, or as an adjunct therapy to one of the other options.

Low-dose atropine may be a preferable treatment in young patients, as parents may be hesitant to start contact lenses at an early age. However, adverse effects are rare with contact lenses in children, and the new daily disposable lens option may make it easier for children and parents to maintain proper hygiene. In the future, a spectacle lens option may be available, and it may be more widely embraced than contact lenses, if the dual-focus design is introduced in the United States.

All of these treatment options for myopia progression currently come with some financial burden for the family, so education and discussion with parents is crucial when selecting the appropriate treatment plan for the patient. **REVIEW**

*Dr. Wasserman is a clinical instructor  
(Continued on page 62)*

A PUBLICATION BY **REVIEW**  
of Ophthalmology

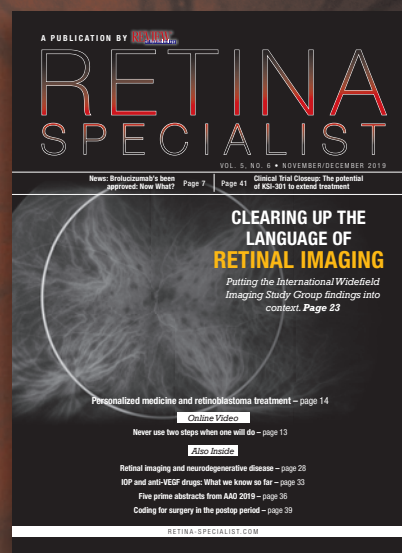
# RETINA SPECIALIST

Retina Specialist focuses on the latest advances in the diagnosis, medical management and surgical treatment of diseases of the retina, along with practical, real-world advice from leading clinicians and other experts on managing the successful retina practice.

## KEEP UP WITH CUTTING-EDGE SCIENCE IN RETINA.

Watch for issues in:

- JANUARY/FEBRUARY
- MARCH/APRIL
- MAY/JUNE
- JULY/AUGUST
- SEPTEMBER/OCTOBER
- NOVEMBER/DECEMBER



**FOR INQUIRIES CONTACT**  
**RETINASPECIALIST@JOBSON.COM**

### ADVERTISING OPPORTUNITIES

JIM HENNE • PUBLISHER • 610-492-1017 • JHENNE@JOBSON.COM  
MICHELE BARRETT • 215-519-1414 • MBARRETT@JOBSON.COM  
MICHAEL HOSTER • 610-492-1028 • MHOSTER@JOBSON.COM

[www.retina-specialist.com](http://www.retina-specialist.com)



@RetSpecMag



RetinaSpecialistMag



(Continued from page 60)

of pediatric ophthalmology and strabismus at Wills Eye Hospital and a clinical associate professor at Thomas Jefferson University Hospital in Philadelphia.

Drs. Franz and Rana practice in the Pediatric Ophthalmology department at Wills Eye Hospital.

None of the authors has a financial interest in any of the products mentioned in the article

Please direct correspondence to:

Dr. Tara Franz  
 Pediatric Ophthalmology  
 Wills Eye Hospital  
 Sidney Kimmel Medical College of Thomas Jefferson University  
 840 Walnut Street  
 Suite 1210  
 Philadelphia, Pennsylvania, 19107  
 Phone: (267) 733-9693  
 Fax: (215) 928-3983  
 Email: [tfranz@willseye.org](mailto:tfranz@willseye.org)

- Holden BA, Fricke TR, Wilson DA, Jong M, Naidoo KS, Sankaridurg P, Wong TY, Resnikoff S. Global prevalence of myopia and high myopia and temporal trends from 2000 through 2050. *Ophthalmology* 2016;123:5:1036-1042.
- Saw SM, Gazzard G, Shih-Yen EC, Chua WH. Myopia and associated pathological complications. *Ophthalmic Physiol Opt* 2005;25:5:381-91.
- Mutti DO, Hayes J, Mitchell GL, et al. Refractive error, axial length, and relative peripheral refractive error before and after the onset of myopia. *Invest Ophthalmol Vis Sci* 2007;48:6:2510-2519.
- Hung LF, Crawford ML, Smith EL. Spectacle lenses alter eye growth and refractive status of young monkeys. *Nat Med* 1995;1:761-5
- Smith EL III, et al. Peripheral vision can influence eye growth and refractive development in infant monkeys. *Invest Ophthalmol Vis Sci* 2005;46:11:3965-72.
- Mutti DO, Sholtz RI, Riedman NE, Zadnik K. Peripheral refraction and ocular shape in children. *Invest Ophthalmol Vis Sci* 2000;41:5:1022-30.
- Cohen Y, Peleg E, Belkin M, et al. Ambient illumination, retinal dopamine release and refractive development in chicks. *Exp Eye Res* 2012;103:33-40.
- Chia A, Lu Q, Tan D. Five-year clinical trial on atropine for the treatment of myopia 2. *Ophthalmology* 2015;123:2:391-399.
- Gwiazda J, Hyman L, Hussein M, et al. A randomized clinical trial of progressive addition lenses versus single vision lenses on the progression of myopia in children. *Invest Ophthalmol Vis Sci* 2003;44:4:1492-1500.
- Correction of Myopia Evaluation Trial Study 2 Group (part of the Pediatric Eye Disease Investigator Group). Progressive-addition lenses versus single-vision lenses for slowing progression of myopia in children with high accommodative lag and near esophoria. *Invest Ophthalmol Vis Sci* 2011;52:5:2749-2756.
- Lam CSY, Tang WC, T DYY, et al. Defocus incorporated multiple segments (DIMS) spectacle lenses slow myopia progression: A 2-year randomised clinical trial. *British Journal Ophthalmology* 2020;104:3:363-368.
- He M, Xiang F, Zeng Y, et al. Effect of time spent outdoors at school on the development of myopia among children in China. *JAMA* 2015;314:11:1142-1148.
- Wu PC, Chen CT, Lin KK, et al. Myopia prevention and outdoor light intensity in a school-based cluster randomized trial. *Ophthalmology* 2018;125:8:1239-1250.
- Yam JC, Li FF, Zhang X, et al. Two-year clinical trial of the Low-Concentration Atropine for Myopia Progression (LAMP) study. *Ophthalmology* 2020;126:1:113-124.
- VanderVeen DK, Kraker RT, Pineles SL, Hutchinson AK, Wilson LB, Galvin JA, Lambert S.R. Use of orthokeratology for the prevention of myopic progression in children: A report by the American Academy of Ophthalmology. *Ophthalmology* 2019;126:4:623-636.
- Chamberlain P, Peixoto-de-Matos S, Logan N, et al. A 3-year randomized clinical trial of MiSight lenses for myopia control. *Optom Vis Sci* 2019;96:8:556-567.
- Anistice N, Phillipa J. Effect of dual-focus soft contact lens wear on axial myopia progression in children. *Ophthalmology* 2011;118:6:1152-1161.

(Continued from page 55)



The XyCam RI doesn't require dilation or contrast dyes to provide dynamic views of the retinal circulation.

### New Blood in Retina

If you've been searching for a new way to visualize retinal blood flow, the new XyCam RI from Vasoptic Medical may be worth a look.

The company describes the device as a non-invasive retinal imager designed to capture and provide dynamic blood flow information for clinical use. It doesn't need contrast dyes or pupil dilation to get an image, and the company says it uses a less-intense light source than some other units in order to make the exam easier for the patient. Vasoptic adds that the XyCam RI enables ophthalmologists to rapidly assess the vascular status of the retina. For more information on the XyCam RI, visit [vasoptic.com](http://vasoptic.com).

### Supplement Your Patients' Eye Health

MacuHealth recently announced a new patented carotenoid formulation for use in its nutritional supplement formulation of lutein, zeaxanthin and meso-zeaxanthin. The new upgrade is called Micro-Micelle Technology.

The company says the enhancement, which is actually a formulation process, increases the bioavailability levels of nutrients in the eye. MacuHealth explains that, by providing the carotenoids in their free form (the original MacuHealth product) and then enhancing their stability and solubility via the addition of acetates, the carotenoids are effectively incorporated into micromicelles. The company says that the result is an increase in the capture of carotenoids by cells, an improvement in absorption and bioavailability and an ultimate increase in carotenoid concentration in the target tissue.

MacuHealth says that this effect was borne out by its recent study that found that patients receiving the new supplement showed "statistically significant improvements in carotenoid concentrations at the target tissue (by Macular Pigment Optical Volume) and skin carotenoid scores."

For information about the new supplement, visit [macuhealth.com](http://macuhealth.com).



## A painless nodule brings an 18-year-old man to Will Eye's Ocular Oncology Department.

*Marisa Schoen, MD, Tatyana Milman, MD, Sara E. Lally, MD, Carol L. Shields, MD*

### Presentation

An 18-year-old Caucasian male presented with a painless nodule in the superior medial canthus (See Figure 1). The patient denied vision changes, diplopia or rapid growth of the lesion. The patient first noticed the mass 11 months prior and initially saw his primary medical doctor, who referred the patient to an ophthalmologist. Four months later, on ophthalmic examination, he was diagnosed with allergic conjunctivitis. Allergy eye drops and warm compresses were prescribed twice daily for a month with no improvement. On follow-up, orbital imaging was recommended. Computed tomography revealed a well-circumscribed, extraconal mass within the superonasal left orbit, measuring 24 mm x 12 mm x 17 mm and without involvement of the extraocular muscles, but with mass effect on the medial rectus muscle and globe. The CT attenuation of approximately 60 Hounsfield units suggested a solid or complex cystic mass. Magnetic resonance imaging demonstrated intermediate T2 and T1 signal and fairly homogeneous contrast enhancement with no cystic spaces or fluid levels within the mass (See Figure 2). The patient was referred to the Wills Eye Hospital Ocular Oncology Department for further management.

### Medical History

There was no relevant past medical, ocular history or prior surgery. There was no trauma to either eye. Family history was noncontributory.

### Examination

Ocular examination demonstrated visual acuity of 20/30 (PH 20/20-1) in the right eye and 20/30 (PH 20/20) in the left eye. Pupils were equal, round and reactive bilaterally with no afferent pupillary defect. Intraocular pressures were 10 and 13 mmHg OD and OS, respectively. Color plates were full in both eyes. Extraocular motility was full OU. Visual fields were full to confrontation OU. External examination showed a non-tender, non-erythematous palpable mass measuring approximately 20 mm x 15 mm at the left medial orbital rim, with displacement of the globe inferotemporally and 2 mm ptosis of the left upper eyelid. Hertel exophthalmometry showed no proptosis. Anterior segment and funduscopic examination were normal OU.

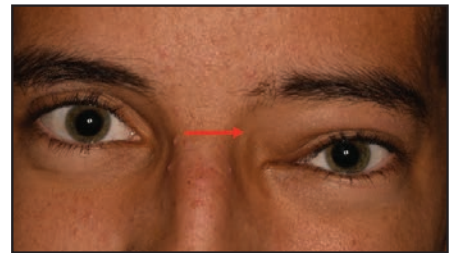


Figure 1. External photograph demonstrating superonasal fullness of the left orbit and slight ptosis.

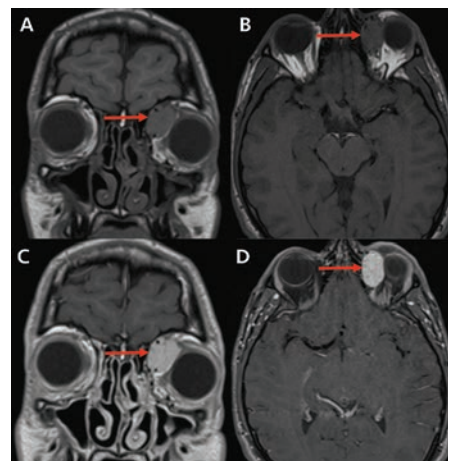


Figure 2. T1-weighted MRI in the coronal (A) and axial (B) planes without contrast showing a well-circumscribed extraconal lesion that demonstrates isointensity to the extraocular muscles and cerebral cortex, and shows fairly homogeneous enhancement with contrast (C, D).

***What is your diagnosis? What further workup would you pursue?  
The diagnosis appears on p. 64.***

## Workup, Diagnosis and Treatment

Given the radiographic appearance and painless, chronic, slow-growing nature of the lesion, the most likely diagnosis was felt to be orbital cavernous hemangioma versus dermoid cyst; however, other etiologies such as orbital lymphoma or rhabdomyosarcoma couldn't be ruled out.

The patient underwent left orbitotomy through an upper eyelid crease incision, with complete removal of the tumor followed by intraorbital injection of sub-Tenon's kenalog (See Figure 3). The tumor was noted to be adherent to surrounding structures.

Microscopic examination (Figure 4) showed a well-circumscribed mass composed of cells with spindle nuclei in a variably cellular arrangement, without nuclear overlapping, with intervening foci of keloidal coarse collagen. Prominent vascular channels—both small and capillary-sized and large, branching, hyalinized (hemangiopericytoma-type)—were present throughout the lesion. Scattered lymphocytes and occasional lymphoid aggregates were also noted. Immunohistochemical stains showed that the neoplastic cells express diffusely STAT-6 (nuclear stain-

ing), consistent with solitary fibrous tumor. There was no evidence of appreciable nuclear atypia, mitotic figures or necrosis. The Ki-67 proliferative index was 1-2 percent.

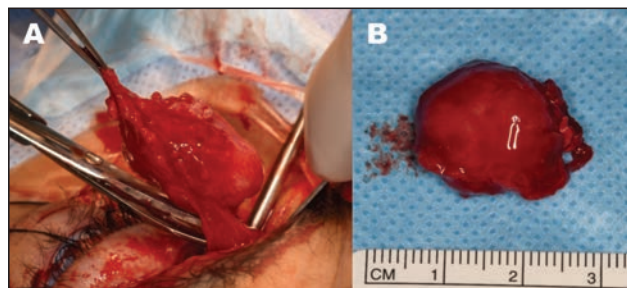


Figure 3. Anterior eyelid crease incision with orbitotomy (A) for the removal of a well-defined soft tissue mass (B).

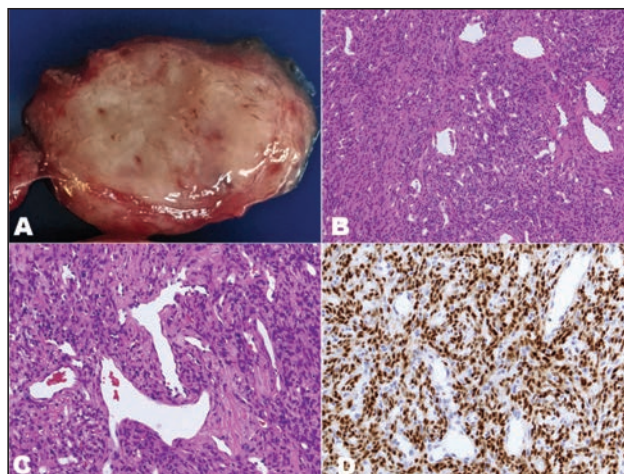


Figure 4. Solitary fibrous tumor, pathologic findings. Gross specimen, bisected (A) appears as a well-circumscribed, vaguely lobulated mass with a heterogeneous gray-tan, vascular, solid cut surface. On scanning magnification (B), the tumor is composed of haphazardly arranged cells in a "patternless pattern" within variably collagenous stroma and variably sized vascular channels. On higher magnification (C), the neoplastic cells have ovoid to spindle nuclei, lack mitotic activity, and are separated by variably dense collagen bands. Angulated, "staghorn-like" or "hemangiopericytoma-type" vascular channels are noted. Signal transducer and activator of transcription (STAT-6) immunohistochemical stain (D) is diffusely and strongly positive in the spindle cell nuclei of the tumor. [stains: hematoxylin-eosin (B, C) and STAT6 (D); original magnification x25 (B), x50 (C, D)]

## Discussion

A wide range of lesions can occur in the orbit, and the differential diagnosis in children varies from that in adults. Lesions can be classified by tumor type; they include cystic, vascular, neural (optic nerve, peripheral nerve, meningeal), inflammatory, osseous and fibrocystic, myogenic, metastatic, lacrimal gland, lymphoid, adipose and histiocytic tumors. The most common orbital tumors in children are cystic lesions, and the most common malignancy in children is rhabdomyosarcoma.<sup>1</sup> Understanding the relative incidence of different orbital tumors in

each age group can help elucidate the diagnosis when used in conjunction with the patient's clinical history and radiographic findings.

The most common orbital cystic lesion in children is the dermoid cyst. This lesion typically forms along orbital suture lines from epithelial cells that become trapped during embryogenesis. The most common site is near the superotemporal orbital rim near the zygomatic-frontal suture site.<sup>2,3</sup> CT imaging typically reveals an extraconal, well-defined mass with an enhancing wall and non-enhancing lumen. How-

ever, some cases may show denser areas which correspond to the accumulation of keratin and other epithelial debris within the lumen of the cyst. MRI shows a well-defined, round to ovoid structure with variable signal intensity based on the material in the lumen, and typically no enhancement with contrast.<sup>4</sup> Histopathology reveals the cyst lined by surface epithelium.<sup>2</sup> A small orbital dermoid cyst can be observed if asymptomatic; however, in most cases, the cyst gradually enlarges and can rupture or form a cutaneous fistula, necessitating treatment. Treat-



ment involves complete excision of the cyst, being careful to remove the lesion with the capsule intact. If the cyst ruptures, irrigation and removal of the cyst remnants should be performed to minimize risk of recurrence or chronic granulomatous inflammation.<sup>2-4</sup>

Vascular lesions include tumors such as capillary hemangioma and lymphangioma. Capillary hemangioma is the most common vascular tumor of childhood.<sup>1</sup> This lesion increases in size for the first one to two years, then stabilizes and gradually regresses.<sup>2,3</sup> They have variable appearance on CT and MRI, ranging from round or ovoid circumscribed masses to irregular or diffuse lesions that enhance with contrast.<sup>4</sup> Microscopic exam often shows lobules of vascular channels and proliferating endothelial cells separated by connective tissue septa.<sup>2</sup> Management is aimed at preventing and treating amblyopia and strabismus. If vision isn't threatened, the lesion can be monitored closely. Refraction and occlusive patching should be implemented in patients with amblyopia, and treatment to accelerate regression of the tumor may be considered.

Treatment options include corticosteroids, interferon, radiation, resection and propranolol.<sup>2-4</sup> Propranolol therapy can be used orally or topically and has been shown to be an effective and relatively safe option for treating orbital and eyelid capillary hemangiomas.<sup>5</sup> Oral or local injection of corticosteroids may also be used, however, but this is associated with risks such as central retinal artery obstruction, eyelid depigmentation, eyelid necrosis and adrenal gland suppression.<sup>2</sup> Patients with concomitant cutaneous vascular lesions warrant systemic workup for associated conditions such as Kasabach Merritt and PHACE (Posterior fossa brain malformations, Hemangiomas of the face, Arterial anomalies, Cardiac anomalies, and Eye abnormalities) syndromes.<sup>2</sup>

Unlike capillary hemangioma, which

usually presents in infancy, lymphangioma is a slow-growing lesion that often goes unnoticed until later childhood or teenage years when spontaneous or traumatic hemorrhage may occur and cause sudden, progressive proptosis and/or periorbital soft-tissue swelling.<sup>2,3</sup> These lesions typically appear as cystic masses with hemorrhage and varying degrees of enhancement on CT; on MRI, they appear isointense on T1-weighted and hyperintense on T2-weighted images.<sup>4</sup> Histopathology shows irregular dilated vascular channels with delicate connective tissue septa.<sup>2</sup> Asymptomatic lesions that aren't sight-threatening are typically observed, since surgical removal is challenging and associated with a high risk of morbidity and recurrence. Vision-threatening lesions (e.g., causing compressive optic neuropathy) and cosmetically unacceptable lesions may be treated with aspiration, sclerotherapy or surgical removal.<sup>2-4,6</sup> Exploratory orbitotomy and biopsy is warranted for lesions that can't be distinguished from rhabdomyosarcoma.

Rhabdomyosarcoma is the most common orbital malignancy of childhood. Patients typically present with proptosis, globe displacement, blepharoptosis, eyelid/conjunctival swelling and in some instances pain, and the mean age of onset is 7 years.<sup>1,4</sup>

Rhabdomyosarcoma appear hyperdense on CT, isointense on T1- and hyperintense on T2-weighted MRI scans, and they enhance with contrast. They usually present as solid lesions, but can demonstrate cavitory changes that make it difficult to differentiate them from vascular orbital tumors.<sup>4</sup> Erosion of surrounding bone may be evident on imaging, reflecting the aggressive nature of the neoplasm. Biopsy shows spindle cells with hyperchromatic nuclei and varying features that delineate the lesions into four types: alveolar; botryoid; embryonal; and pleomorphic. The embryonal type is most common, while the alveolar type is the

**Aerie Pharmaceuticals Corporate 17 & 18**

[www.rhopena.com](http://www.rhopena.com)

**Akorn Pharmaceuticals 2**

(800) 932-5676

[www.akorn.com](http://www.akorn.com)

**Allergan, Inc. Cover Tip**

[www.allergan.com](http://www.allergan.com)

**Allergan, Inc. A1-A4 (Regional Insert)**

(800) 347-4500

[www.allergan.com](http://www.allergan.com)

**Compulink 8**

(800) 456-4522

[www.compulinkadvantage.com](http://www.compulinkadvantage.com)

**EyePoint Pharmaceuticals 13 & 14**

(817) 677-6120

[www.dexycu.com](http://www.dexycu.com)

**Horizon Pharma USA 22, 23 & 24**

[www.TEDbreakthrough.com](http://www.TEDbreakthrough.com)

**Icare USA 27**

(888) 389-4022

[www.icare-usa.com](http://www.icare-usa.com)

**Novartis Pharmaceuticals 67 & 68**

[www.novartis.com](http://www.novartis.com)

**S4OPTIK 31 & 33**

(888) 224-6012

[www.s4optik.com](http://www.s4optik.com)

**Tearcare 7 & 35**

(877) 266-1144

[www.TearCare.com](http://www.TearCare.com)

*This advertiser index is published as a convenience and not as part of the advertising contract. Every care will be taken to index correctly. No allowance will be made for errors due to spelling, incorrect page number, or failure to insert.*

most malignant.<sup>4</sup> Prompt management with biopsy to confirm the diagnosis is key, followed by systemic evaluation for metastasis, and chemotherapy and radiation.

Solitary fibrous tumor (SFT) is a rare fibroblastic spindle cell neoplasm that can develop anywhere in the body, including the orbit. It's most commonly seen in middle-aged adults; however, several cases have been reported in children.<sup>1,7-11</sup> Patients typically present with painless, progressive proptosis or eyelid swelling, and imaging reveals well-circumscribed, variably vascular contrast-enhancing lesions that generally don't produce bony changes.<sup>2-4</sup> On CT, SFT appears isodense to the cerebral cortex and extraocular muscles. MRI shows lesions that are isointense on T1- and isointense to hyperintense on T2-weighted images.<sup>4</sup> While helpful in narrowing the diagnosis, these findings aren't specific for SFT, and it can be difficult to distinguish SFT from other solid orbital lesions such as cavernous hemangioma.

Complete excision is recommended, given the unpredictable nature of this lesion and the potential for malignant transformation.<sup>2-4,12</sup> The protein STAT6 is detectable by immunohistochemistry and has been shown to be a highly sensitive and specific diagnostic marker for SFT.<sup>13-16</sup> Patients should be followed at regular intervals with post-operative imaging, given the potential for asymptomatic recurrence.

Previously, SFTs were considered separate entities from other fibroblastic mesenchymal tumors such as hemangiopericytomas (HPC). Further histologic review, however, called this classification into question. In 2011, researchers reviewed 41 fibroblastic orbital tumors from the Ophthalmic Registry at the Armed Forces Institute of Pathology and demonstrated that SFTs shared similar morphologic and immunohistochemical features with hemangiopericytomas, giant cell

angiofibromas and fibrous histiocytomas.<sup>17</sup> Several years later, a gene fusion of NGFI-A binding protein 2 (NAB2) and signal transducer and activator of transcription 6 (STAT6) was identified as the pathogenic mutation underlying SFT. In normal cells, NAB2 functions as a transcriptional repressor in the early growth response (EGR) pathways, which play a critical role in cell growth and proliferation. In SFT cells, the repressor domain in NAB2 is replaced by the activator domain of STAT6, resulting in constitutive expression of the EGR pathway and uncontrolled cell proliferation and growth.<sup>18</sup>

Subsequent studies have demonstrated the utility of STAT6 as a reliable diagnostic marker for SFT, with sensitivity and specificity of 96 to 100 percent.<sup>16,19-20</sup> Additional studies reassessed the clinicopathologic behavior of SFT, given recent advancements in molecular testing. One study was a retrospective review of head and neck lesions previously diagnosed as SFT, HPC, giant cell angiofibroma or orbital fibrous histiocytoma. Using STAT6 as an immunohistochemical marker, researchers found that a greater proportion of head and neck SFT arose in the orbit than previously reported (specifically, 25 percent [22 of 88] of the cases included in the study), and was the second most common site after the sinonasal tract (30 percent). They also reported a higher rate of local recurrence (median time to recurrence: 19 months).<sup>21</sup> Another study focused on orbital SFT and found six of 21 cases (29 percent) with a local recurrence, with a median time to recurrence of 4.9 months. Of the six cases with local recurrence, four were asymptomatic and detected via surveillance imaging. All available tissue stained positively for both CD34 (n=21) and STAT6 (n=20).<sup>13</sup> These studies highlight the importance of long-term follow-up and surveillance imaging to monitor for local recurrence of SFT.

In summary, a variety of lesions can occur in the orbit in children, with the most common being the dermoid cyst. Orbital SFT is a rare fibroblastic mesenchymal tumor that's typically seen in middle-aged adults, but can occur in children and should be included in the differential diagnosis of orbital lesions in children, as demonstrated by our case. SFTs are typically benign but have the propensity for local recurrence and metastasis. Thus, close follow-up with surveillance imaging should be performed. **REVIEW**

- Shields JA, Shields CL, Scartozzi R. Survey of 1264 patients with orbital tumors and simulating lesions: The 2002 Montgomery Lecture, part 1. *Ophthalmology* 2004;111:5:997-1008.
- Shields JA, Shields CL. *Atlas of Orbital Tumors*. Philadelphia: Lippincott Williams & Wilkins, 1999.
- Nicholson DH, Green WR. *Pediatric Ocular Tumors*. New York: Masson Publishing USA, 1981.
- Shields JA, Shields CL. *Eyelid, Conjunctival, and Orbital Tumors: An Atlas and Textbook*. 3rd ed. Philadelphia: Wolters Kluwer, 2016.
- Vohra V, Gupta P, Malik PK, Pathak A. Propranolol therapy in a case of capillary hemangioma. *Oman J Ophthalmol* 2015;8:3:191-193.
- Schwarz RM, Ben Simon GJ, Cook T, Goldberg RA. Sclerosing therapy as first line treatment for low flow vascular lesions of the orbit. *Am J Ophthalmol* 2006;141:2:333-9.
- Vu, A.F., et al., Recurrent orbital solitary fibrous tumor in a 12-Year-Old. *Ocul Oncol Pathol* 2017;3:2:83-86.
- Alexandrakis G, Johnson TE. Recurrent orbital solitary fibrous tumor in a 14-year-old girl. *Am J Ophthalmol* 2000;130:3:373-376.
- Lucci LM, Anderson RL, Harrie RP, et al. Solitary fibrous tumor of the orbit in a child. *Ophthalmic Plast Reconstr Surg* 2001;17:5:369-373.
- Demirci H, Shields CL, Eagle RC Jr, Shields JA. Giant cell angiofibroma, a variant of solitary fibrous tumor, of the orbit in a 16-year-old girl. *Ophthalmic Plast Reconstr Surg* 2009;25:5:402.
- Blandamura S, Alaggio R, Bettini G, et al. Four cases of solitary fibrous tumour of the eye and orbit: One with sarcomatous transformation after radiotherapy and one in a 5-year-old child's eyelid. *J Clin Pathol* 2014;67:3:263-267.
- Sagiv O, Bell D, Guo Y, et al. Pathological features and clinical course in patients with recurrent or malignant orbital solitary fibrous tumor/hemangiopericytoma. *Ophthalmic Plast Reconstr Surg* 2019;35:2:148-154.
- Blessing NW, Bermudez-Magner JA, Fernandez MP, et al. Solitary fibrous tumor of the orbit: A case series with clinicopathologic correlation and evaluation of STAT6 as a diagnostic marker. *Ophthalmic Plast Reconstr Surg* 2020;36:2:164-71.
- Cheah AL, Billings SD, Goldblum JR, et al. STAT6 rabbit monoclonal antibody is a robust diagnostic tool for the distinction of solitary fibrous tumor from its mimics. *Pathology* 2014;46:5:389.
- Yoshida A, Tsuta K, Ohno M, et al. STAT6 immunohistochemistry is helpful in the diagnosis of solitary fibrous tumors. *Am J Surg Pathol* 2014;38:4:552-559.
- Doyle LA, Vivero M, Fletcher CD, et al. Nuclear expression of STAT6 distinguishes solitary fibrous tumor from histologic mimics. *Mod Pathol* 2014;27:3:390-395.
- Furusato E, Valenzuela IA, Fanburg-Smith JC, et al. Orbital solitary fibrous tumor: encompassing terminology for hemangiopericytoma, giant cell angiofibroma, and fibrous histiocytoma of the orbit: Reappraisal of 41 cases. *Hum Pathol* 2011;42:1:120-128.
- Robinson DR, Wu YM, Kalyana-Sundaram S, et al. Identification of recurrent NAB2-STAT6 gene fusions in solitary fibrous tumor by integrative sequencing. *Nat Genet* 2013;45:2:180-185.
- Cheah AL, Billings SD, Goldblum JR, et al. STAT6 rabbit monoclonal antibody is a robust diagnostic tool for the distinction of solitary fibrous tumour from its mimics. *Pathology* 2014;46:5:389.
- Yoshida A, Tsuta K, Ohno M, et al. STAT6 immunohistochemistry is helpful in the diagnosis of solitary fibrous tumors. *Am J Surg Pathol* 2014;38:4:552-559.
- Smith SC, Gooding WE, Elkins M, et al. Solitary fibrous tumors of the head and neck: A multi-institutional clinicopathologic study. *Am J Surg Pathol* 2017;41:12:1642-1656.

**XIIDRA® (lifitegrast ophthalmic solution), for topical ophthalmic use**  
**Initial U.S. Approval: 2016**

**BRIEF SUMMARY: Please see package insert for full prescribing information.**

**1 INDICATIONS AND USAGE**

Xiidra® (lifitegrast ophthalmic solution) 5% is indicated for the treatment of the signs and symptoms of dry eye disease (DED).

**4 CONTRAINDICATIONS**

Xiidra is contraindicated in patients with known hypersensitivity to lifitegrast or to any of the other ingredients in the formulation [see *Adverse Reactions (6.2)*].

**6 ADVERSE REACTIONS**

The following serious adverse reactions are described elsewhere in the labeling:

- Hypersensitivity [see *Contraindications (4)*]

**6.1 Clinical Trials Experience**

Because clinical trials are conducted under widely varying conditions, adverse reaction rates observed in clinical trials of a drug cannot be directly compared to rates in the clinical trials of another drug and may not reflect the rates observed in practice.

In five clinical studies of DED conducted with lifitegrast ophthalmic solution, 1401 patients received at least one dose of lifitegrast (1287 of which received lifitegrast 5%). The majority of patients (84%) had ≤ 3 months of treatment exposure. One hundred-seventy patients were exposed to lifitegrast for approximately 12 months. The majority of the treated patients were female (77%). The most common adverse reactions reported in 5%-25% of patients were instillation-site irritation, dysgeusia, and reduced visual acuity.

Other adverse reactions reported in 1%-5% of the patients were blurred vision, conjunctival hyperemia, eye irritation, headache, increased lacrimation, eye discharge, eye discomfort, eye pruritus, and sinusitis.

**6.2 Postmarketing Experience**

The following adverse reactions have been identified during post-approval use of Xiidra. Because these reactions are reported voluntarily from a population of uncertain size, it is not always possible to reliably estimate their frequency or establish a causal relationship to drug exposure.

Rare cases of hypersensitivity, including anaphylactic reaction, bronchospasm, respiratory distress, pharyngeal edema, swollen tongue, and urticaria have been reported. Eye swelling and rash have been reported [see *Contraindications (4)*].

**8 USE IN SPECIFIC POPULATIONS**

**8.1 Pregnancy**

Risk Summary

There are no available data on Xiidra use in pregnant women to inform any drug-associated risks. Intravenous (IV) administration of lifitegrast to pregnant rats, from pre-mating through gestation Day 17, did not produce

teratogenicity at clinically relevant systemic exposures. Intravenous administration of lifitegrast to pregnant rabbits during organogenesis produced an increased incidence of omphalocele at the lowest dose tested, 3 mg/kg/day (400-fold the human plasma exposure at the recommended human ophthalmic dose [RHOD], based on the area under the curve [AUC] level). Since human systemic exposure to lifitegrast following ocular administration of Xiidra at the RHOD is low, the applicability of animal findings to the risk of Xiidra use in humans during pregnancy is unclear [see *Clinical Pharmacology (12.3)* in the full prescribing information].

Data

Animal Data

Lifitegrast administered daily by IV injection to rats, from pre-mating through gestation Day 17, caused an increase in mean pre-implantation loss and an increased incidence of several minor skeletal anomalies at 30 mg/kg/day, representing five, 400-fold the human plasma exposure at the RHOD of Xiidra, based on AUC. No teratogenicity was observed in the rat at 10 mg/kg/day (460-fold the human plasma exposure at the RHOD, based on AUC). In the rabbit, an increased incidence of omphalocele was observed at the lowest dose tested, 3 mg/kg/day (400-fold the human plasma exposure at the RHOD, based on AUC), when administered by IV injection daily from gestation Days 7 through 19. A fetal no observed adverse effect level (NOAEL) was not identified in the rabbit.

**8.2 Lactation**

Risk Summary

There are no data on the presence of lifitegrast in human milk, the effects on the breastfed infant, or the effects on milk production. However, systemic exposure to lifitegrast from ocular administration is low [see *Clinical Pharmacology (12.3)* in the full prescribing information]. The developmental and health benefits of breastfeeding should be considered, along with the mother's clinical need for Xiidra and any potential adverse effects on the breastfed child from Xiidra.

**8.4 Pediatric Use**

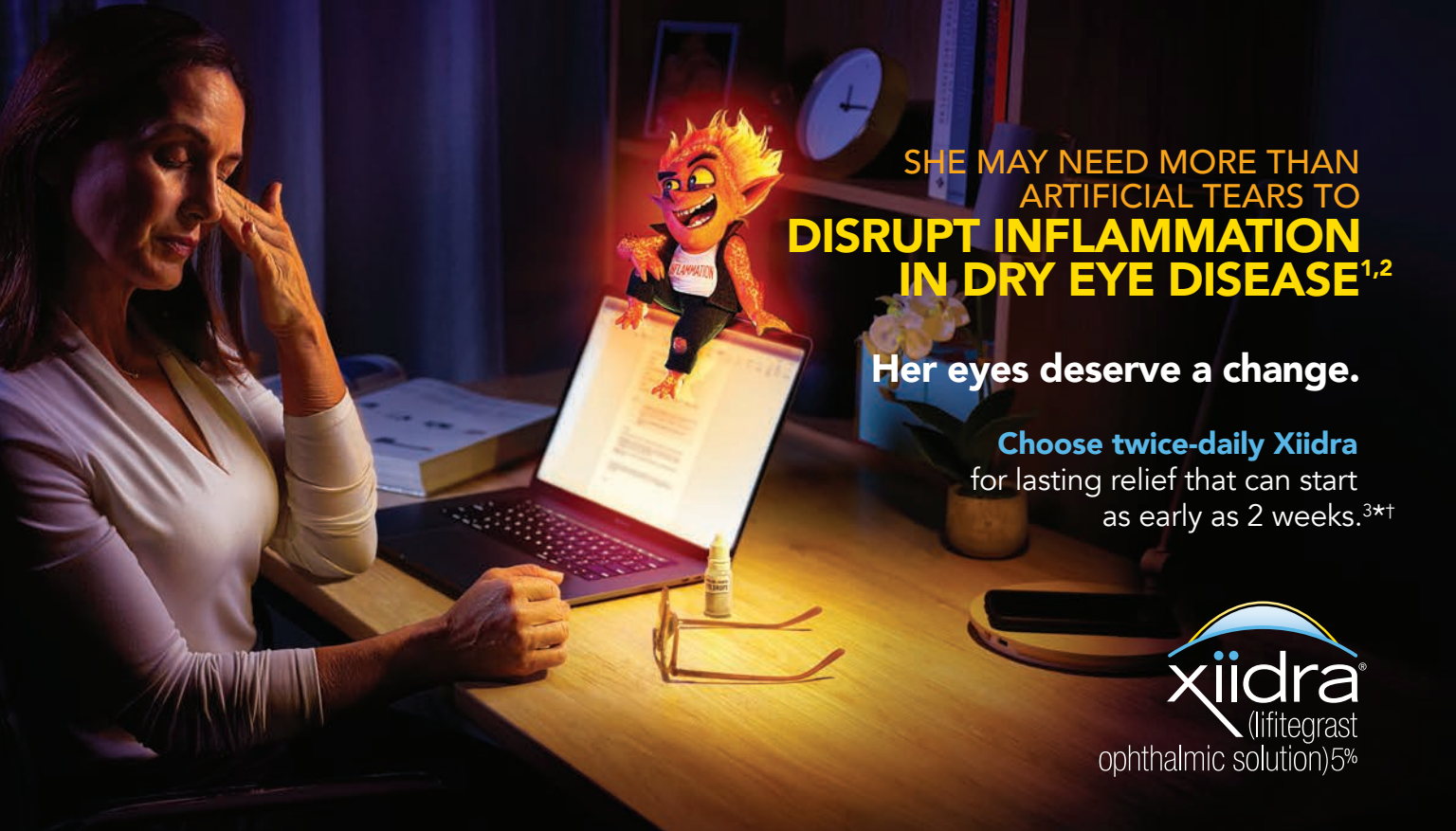Safety and efficacy in pediatric patients below the age of 17 years have not been established.

**8.5 Geriatric Use**

No overall differences in safety or effectiveness have been observed between elderly and younger adult patients.

Manufactured for:  
Novartis Pharmaceuticals Corporation  
One Health Plaza  
East Hanover, NJ 07936  
T2019-110





SHE MAY NEED MORE THAN  
ARTIFICIAL TEARS TO  
**DISRUPT INFLAMMATION  
IN DRY EYE DISEASE**<sup>1,2</sup>

**Her eyes deserve a change.**

**Choose twice-daily Xiidra**  
for lasting relief that can start  
as early as 2 weeks.<sup>3\*†</sup>

**xiidra**<sup>®</sup>  
(lifitegrast  
ophthalmic solution)5%

\*In some patients with continued daily use. One drop in each eye, twice daily (approximately 12 hours apart).

†Xiidra is an LFA-1 antagonist for the treatment of dry eye disease. Pivotal trial data: The safety and efficacy of Xiidra were assessed in four 12-week, randomized, multicenter, double-masked, vehicle-controlled studies (N=2133). Patients were dosed twice daily. Use of artificial tears was not allowed during the studies. The study endpoints included assessment of signs (based on Inferior fluorescein Corneal Staining Score [ICSS] on a scale of 0 to 4) and symptoms (based on patient-reported Eye Dryness Score [EDS] on a visual analogue scale of 0 to 100).<sup>3</sup>

A larger reduction in EDS favoring Xiidra was observed in all studies at day 42 and day 84. Xiidra reduced symptoms of eye dryness at 2 weeks (based on EDS) compared to vehicle in 2 out of 4 clinical trials. Effects on signs of dry eye disease ICSS (on a scale from 0-4; 0=no staining; 4=coalescent) was recorded at each study visit. At day 84, a larger reduction in inferior corneal staining favoring Xiidra was observed in 3 of the 4 studies.<sup>3</sup>

## Indication

Xiidra<sup>®</sup> (lifitegrast ophthalmic solution) 5% is indicated for the treatment of signs and symptoms of dry eye disease (DED).

## Important Safety Information

- Xiidra is contraindicated in patients with known hypersensitivity to lifitegrast or to any of the other ingredients.
- In clinical trials, the most common adverse reactions reported in 5-25% of patients were instillation site irritation, dysgeusia and reduced visual acuity. Other adverse reactions reported in 1% to 5% of the patients were blurred vision, conjunctival hyperemia, eye irritation, headache, increased lacrimation, eye discharge, eye discomfort, eye pruritus and sinusitis.
- To avoid the potential for eye injury or contamination of the solution, patients should not touch the tip of the single-use container to their eye or to any surface.
- Contact lenses should be removed prior to the administration of Xiidra and may be reinserted 15 minutes following administration.
- Safety and efficacy in pediatric patients below the age of 17 years have not been established.

**Please see Brief Summary of Prescribing Information on adjacent page.**

**References:** **1.** U.S. Food and Drug Administration. Code of Federal Regulations, Title 21, Volume 5 (21CFR349). <https://www.accessdata.fda.gov/scripts/cdrh/cfdocs/cfcr/CFRSearch.cfm?CFRPart=349&showFR=1>. Accessed April 17, 2020. **2.** Jones L, Downie LE, Korb D, et al. TFOS DEWS II Management and Therapy Report. *Ocul Surf*. 2017;15(3):575-628. **3.** Xiidra [prescribing information]. East Hanover, NJ: Novartis Pharmaceuticals Corp; November 2019.



Novartis Pharmaceuticals Corporation  
One Health Plaza  
East Hanover, New Jersey 07936-1080

© 2020 Novartis

5/20

XIA-1388813