

CORONAVIRUS: THE LATEST RESEARCH P. 4 • HOW TO MANAGE ACANTHAMOEBA P. 16
THE EVOLUTION OF 3-D VIEWING P. 26 • TUBES, TRABS AND CATARACT P. 62
RIGHT-SIZE YOUR CAPSULORHEXIS P. 66 • WILLS RESIDENT CASE P. 69

REVIEW[®] of Ophthalmology

April 2020

reviewofophthalmology.com

GOING FOR THE GOLD

*The tools, techniques and tips that can elevate your
outcomes to record levels.*

Nailing the Outcome with Biometry and Formulas P. 32
Point-Counterpoint: Scleral-Sutured IOLs vs. Yamane P. 42
Adjustable IOLs: Lights, Lasers and Lock-ins P. 50

ALSO INSIDE:

Daring to Treat Vitreous Floaters P. 57

Dextenza[®]

(dexamethasone ophthalmic insert) 0.4mg
for intracanalicular use

NOW USE UNIQUE
BILLING CODE J1096

BIG TIME INNOVATION¹

The first and only ophthalmic steroid insert approved for the treatment of inflammation and pain following ophthalmic surgery

DEXTENZA IS AN ADVANCEMENT IN STEROID TREATMENT

- Designed to deliver a tapered dose¹
- Contains fluorescein for visualization²
- No additional components or assembly required²
- Resorbable, so no need for removal²
- Insert can be removed via saline irrigation or manual expression, if necessary²
- Physicians rated DEXTENZA as easy to insert^{3,4*}

LEARN MORE AT DEXTENZA.COM

INDICATION

DEXTENZA is a corticosteroid indicated for the treatment of ocular inflammation and pain following ophthalmic surgery.

IMPORTANT SAFETY INFORMATION

CONTRAINDICATIONS

DEXTENZA is contraindicated in patients with active corneal, conjunctival or canalicular infections, including epithelial herpes simplex keratitis (dendritic keratitis), vaccinia, varicella; mycobacterial infections; fungal diseases of the eye, and dacryocystitis.

WARNINGS AND PRECAUTIONS

Prolonged use of corticosteroids may result in glaucoma with damage to the optic nerve, defects in visual acuity and fields of vision. Steroids should be used with caution in the presence of glaucoma. Intraocular pressure should be monitored during treatment.

Corticosteroids may suppress the host response and thus increase the hazard for secondary ocular infections. In acute purulent conditions, steroids may mask infection and enhance existing infection.

Use of ocular steroids may prolong the course and may exacerbate the severity of many viral infections of the eye (including herpes simplex).

Fungus invasion must be considered in any persistent corneal ulceration where a steroid has been used or is in use. Fungal culture should be taken when appropriate.

Use of steroids after cataract surgery may delay healing and increase the incidence of bleb formation.

ADVERSE REACTIONS

The most common ocular adverse reactions that occurred in patients treated with DEXTENZA were: anterior chamber inflammation including iritis and iridocyclitis (10%); intraocular pressure increased (6%); visual acuity reduced (2%); cystoid macular edema (1%); corneal edema (1%); eye pain (1%) and conjunctival hyperemia (1%).

The most common non-ocular adverse reaction that occurred in patients treated with DEXTENZA was headache (1%).

Please see brief summary of full Prescribing Information on adjacent page.

*73.6% of physicians in Study 1, 76.4% in Study 2, and 79.6% in Study 3 rated DEXTENZA as easy to insert.

References: **1.** Sawhney AS et al, inventors; Incept LLC, assignee. US patent 8,409,606 B2. April 2, 2013. **2.** DEXTENZA [package insert]. Bedford, MA: Ocular Therapeutix, Inc; 2019. **3.** Walters T et al. *J Clin Exp Ophthalmol.* 2016;7(4):1-11. **4.** Tyson SL et al. *J Cataract Refract Surg.* 2019;45(2):204-212.

© 2020 Ocular Therapeutix, Inc. All rights reserved.
DEXTENZA is a registered trademark of Ocular Therapeutix, Inc. PP-US-DX-0193

Ocular
Therapeutix[™]

IMPORTANT PRODUCT INFORMATION

ARGOS® Optical Biometer

Caution: Federal (USA) law restricts this device to the sale by or on the order of a physician.

Indications: ARGOS® is a non-invasive, non-contact biometer based on swept-source optical coherence tomography (SS-OCT). The device is intended to acquire ocular measurements as well as perform calculations to determine the appropriate intraocular lens (IOL) power and type for implantation during intraocular lens placement.

Intended Use: The Reference Image functionality is intended for use as a preoperative and postoperative image capture tool. It is intended for use by ophthalmologists, physicians, and other eye-care professionals and may only be used under the supervision of a physician.

Warnings and Precautions:

- Only properly trained personnel with experience may operate the device and control software and interpret the results.
- Factors that influence the measurement of patient's eyes are listed in the User Manual (Table 1): pseudophakic eye, wearing contact lenses, fixation problem, cornea opacity, non-intact cornea, refractive surgery, blood in the vitreous humor, retinal detachment, keratoconus, asteroid , ambient light in the room, and deformation of the corneal shape. Please consider the guidance provided in Table 1 when you encounter these factors.
- Optical Radiation - This device is equipped with a Class 1 laser light source.

ATTENTION: Refer to the ARGOS® User Manual for a complete description of proper use and maintenance, optical and technical specifications, as well as a complete list of warnings and precautions.

ARGOS®
with Image Guidance by ALCON®



Vision Planner

Alcon

© 2019 Alcon Inc. 12/19 US-ARB-1900018

Dextenza[®]

(dexamethasone ophthalmic insert) 0.4 mg
for intracanalicular use

BRIEF SUMMARY: Please see the DEXTENZA Package Insert for full prescribing information for DEXTENZA (06/2019)

1 INDICATIONS AND USAGE

DEXTENZA[®] (dexamethasone ophthalmic insert) is a corticosteroid indicated for the treatment of ocular inflammation and pain following ophthalmic surgery.

4 CONTRAINDICATIONS

DEXTENZA is contraindicated in patients with active corneal, conjunctival or canalicular infections, including epithelial herpes simplex keratitis (dendritic keratitis), vaccinia, varicella; mycobacterial infections; fungal diseases of the eye, and dacryocystitis.

5 WARNINGS AND PRECAUTIONS

5.1 Intraocular Pressure Increase

Prolonged use of corticosteroids may result in glaucoma with damage to the optic nerve, defects in visual acuity and fields of vision. Steroids should be used with caution in the presence of glaucoma. Intraocular pressure should be monitored during the course of the treatment.

5.2 Bacterial Infection

Corticosteroids may suppress the host response and thus increase the hazard for secondary ocular infections. In acute purulent conditions, steroids may mask infection and enhance existing infection [see Contraindications (4)].

5.3 Viral Infections

Use of ocular steroids may prolong the course and may exacerbate the severity of many viral infections of the eye (including herpes simplex) [see Contraindications (4)].

5.4 Fungal Infections

Fungus invasion must be considered in any persistent corneal ulceration where a steroid has been used or is in use. Fungal culture should be taken when appropriate [see Contraindications (4)].

5.5 Delayed Healing

The use of steroids after cataract surgery may delay healing and increase the incidence of bleb formation.

6 ADVERSE REACTIONS

The following serious adverse reactions are described elsewhere in the labeling:

- Intraocular Pressure Increase [see Warnings and Precautions (5.1)]
- Bacterial Infection [see Warnings and Precautions (5.2)]
- Viral Infection [see Warnings and Precautions (5.3)]
- Fungal Infection [see Warnings and Precautions (5.4)]
- Delayed Healing [see Warnings and Precautions (5.5)]

6.1 Clinical Trials Experience

Because clinical trials are conducted under widely varying conditions, adverse reaction rates observed in the clinical trials of a drug cannot be directly compared to rates in the clinical trials of another drug and may not reflect the rates observed in practice. Adverse reactions associated with ophthalmic steroids include elevated intraocular pressure, which may be associated with optic nerve damage, visual acuity and field defects, posterior subcapsular cataract formation; delayed wound healing; secondary ocular infection from pathogens including herpes simplex, and perforation of the globe where there is thinning of the cornea or sclera [see Warnings and Precautions (5)].

DEXTENZA was studied in four randomized, vehicle-controlled studies (n = 567). The mean age of the population was 68 years (range 35 to 87 years), 59% were female, and 83% were white. Forty-seven percent had brown iris color and 30% had blue iris color. The most common ocular adverse reactions that occurred in patients treated with DEXTENZA were: anterior chamber inflammation including iritis and iridocyclitis (10%); intraocular pressure increased (6%); visual acuity reduced (2%); cystoid macular edema (1%); corneal edema (1%); eye pain (1%) and conjunctival hyperemia (1%).

The most common non-ocular adverse reaction that occurred in patients treated with DEXTENZA was headache (1%).

8 USE IN SPECIFIC POPULATIONS

8.1 Pregnancy

Risk Summary

There are no adequate or well-controlled studies with DEXTENZA in pregnant women to inform a drug-associated risk for major birth defects and miscarriage. In animal reproduction studies, administration of topical ocular dexamethasone to pregnant mice and rabbits during organogenesis produced embryofetal lethality, cleft palate and multiple visceral malformations [see Animal Data].

Data

Animal Data

Topical ocular administration of 0.15% dexamethasone (0.75 mg/kg/day) on gestational days 10 to 13 produced embryofetal lethality and a high incidence of cleft palate in a mouse study. A daily dose of 0.75 mg/kg/day in the mouse is approximately 5 times the entire dose of dexamethasone in the DEXTENZA product, on a mg/m² basis. In a rabbit study, topical ocular administration of 0.1% dexamethasone throughout organogenesis (0.36 mg/day, on gestational day 6 followed by 0.24 mg/day on gestational days 7-18) produced intestinal anomalies, intestinal aplasia, gastroschisis and hypoplastic kidneys. A daily dose of 0.24 mg/day is approximately 6 times the entire dose of dexamethasone in the DEXTENZA product, on a mg/m² basis.

8.2 Lactation

Systemically administered corticosteroids appear in human milk and could suppress growth and interfere with endogenous corticosteroid production; however the systemic concentration of dexamethasone following administration of DEXTENZA is low [see Clinical Pharmacology (12.3)]. There is no information regarding the presence of DEXTENZA in human milk, the effects of the drug on the breastfed infant or the effects of the drug on milk production to inform risk of DEXTENZA to an infant during lactation. The developmental and health benefits of breastfeeding should be considered along with the mother's clinical need for DEXTENZA and any potential adverse effects on the breastfed child from DEXTENZA.

8.4 Pediatric Use

Safety and effectiveness in pediatric patients have not been established.

8.5 Geriatric Use

No overall differences in safety or effectiveness have been observed between elderly and younger patients.

17 PATIENT COUNSELING INFORMATION

Advise patients to consult their surgeon if pain, redness, or itching develops.

Ocular
Therapeutix™

MANUFACTURED FOR:

Ocular Therapeutix, Inc.
Bedford, MA 01730 USA
PP-US-DX-0072-V2

Dextenza®

(dexamethasone ophthalmic insert) 0.4 mg
for intracanalicular use

BRIEF SUMMARY: Please see the DEXTENZA Package Insert for full prescribing information for DEXTENZA (06/2019)

1 INDICATIONS AND USAGE

DEXTENZA® (dexamethasone ophthalmic insert) is a corticosteroid indicated for the treatment of ocular inflammation and pain following ophthalmic surgery.

4 CONTRAINDICATIONS

DEXTENZA is contraindicated in patients with active corneal, conjunctival or canalicular infections, including epithelial herpes simplex keratitis (dendritic keratitis), vaccinia, varicella; mycobacterial infections; fungal diseases of the eye, and dacryocystitis.

5 WARNINGS AND PRECAUTIONS

5.1 Intraocular Pressure Increase

Prolonged use of corticosteroids may result in glaucoma with damage to the optic nerve, defects in visual acuity and fields of vision. Steroids should be used with caution in the presence of glaucoma. Intraocular pressure should be monitored during the course of the treatment.

5.2 Bacterial Infection

Corticosteroids may suppress the host response and thus increase the hazard for secondary ocular infections. In acute purulent conditions, steroids may mask infection and enhance existing infection [see Contraindications (4)].

5.3 Viral Infections

Use of ocular steroids may prolong the course and may exacerbate the severity of many viral infections of the eye (including herpes simplex) [see Contraindications (4)].

5.4 Fungal Infections

Fungus invasion must be considered in any persistent corneal ulceration where a steroid has been used or is in use. Fungal culture should be taken when appropriate [see Contraindications (4)].

5.5 Delayed Healing

The use of steroids after cataract surgery may delay healing and increase the incidence of bleb formation.

6 ADVERSE REACTIONS

The following serious adverse reactions are described elsewhere in the labeling:

- Intraocular Pressure Increase [see Warnings and Precautions (5.1)]
- Bacterial Infection [see Warnings and Precautions (5.2)]
- Viral Infection [see Warnings and Precautions (5.3)]
- Fungal Infection [see Warnings and Precautions (5.4)]
- Delayed Healing [see Warnings and Precautions (5.5)]

6.1 Clinical Trials Experience

Because clinical trials are conducted under widely varying conditions, adverse reaction rates observed in the clinical trials of a drug cannot be directly compared to rates in the clinical trials of another drug and may not reflect the rates observed in practice. Adverse reactions associated with ophthalmic steroids include elevated intraocular pressure, which may be associated with optic nerve damage, visual acuity and field defects, posterior subcapsular cataract formation; delayed wound healing; secondary ocular infection from pathogens including herpes simplex, and perforation of the globe where there is thinning of the cornea or sclera [see Warnings and Precautions (5)].

DEXTENZA was studied in four randomized, vehicle-controlled studies (n = 567). The mean age of the population was 68 years (range 35 to 87 years), 59% were female, and 83% were white. Forty-seven percent had brown iris color and 30% had blue iris color. The most common ocular adverse reactions that occurred in patients treated with DEXTENZA were: anterior chamber inflammation including iritis and iridocyclitis (10%); intraocular pressure increased (6%); visual acuity reduced (2%); cystoid macular edema (1%); corneal edema (1%); eye pain (1%) and conjunctival hyperemia (1%).

The most common non-ocular adverse reaction that occurred in patients treated with DEXTENZA was headache (1%).

8 USE IN SPECIFIC POPULATIONS

8.1 Pregnancy

Risk Summary

There are no adequate or well-controlled studies with DEXTENZA in pregnant women to inform a drug-associated risk for major birth defects and miscarriage. In animal reproduction studies, administration of topical ocular dexamethasone to pregnant mice and rabbits during organogenesis produced embryofetal lethality, cleft palate and multiple visceral malformations [see Animal Data].

Data

Animal Data

Topical ocular administration of 0.15% dexamethasone (0.75 mg/kg/day) on gestational days 10 to 13 produced embryofetal lethality and a high incidence of cleft palate in a mouse study. A daily dose of 0.75 mg/kg/day in the mouse is approximately 5 times the entire dose of dexamethasone in the DEXTENZA product, on a mg/m² basis. In a rabbit study, topical ocular administration of 0.1% dexamethasone throughout organogenesis (0.36 mg/day, on gestational day 6 followed by 0.24 mg/day on gestational days 7-18) produced intestinal anomalies, intestinal aplasia, gastroschisis and hypoplastic kidneys. A daily dose of 0.24 mg/day is approximately 6 times the entire dose of dexamethasone in the DEXTENZA product, on a mg/m² basis.

8.2 Lactation

Systemically administered corticosteroids appear in human milk and could suppress growth and interfere with endogenous corticosteroid production; however the systemic concentration of dexamethasone following administration of DEXTENZA is low [see Clinical Pharmacology (12.3)]. There is no information regarding the presence of DEXTENZA in human milk, the effects of the drug on the breastfed infant or the effects of the drug on milk production to inform risk of DEXTENZA to an infant during lactation. The developmental and health benefits of breastfeeding should be considered along with the mother's clinical need for DEXTENZA and any potential adverse effects on the breastfed child from DEXTENZA.

8.4 Pediatric Use

Safety and effectiveness in pediatric patients have not been established.

8.5 Geriatric Use

No overall differences in safety or effectiveness have been observed between elderly and younger patients.

17 PATIENT COUNSELING INFORMATION

Advise patients to consult their surgeon if pain, redness, or itching develops.

Ocular
Therapeutix™

MANUFACTURED FOR:
Ocular Therapeutix, Inc.
Bedford, MA 01730 USA
PP-US-DX-0072-V2

OPHTHALMIC

Product Guide

Innovative products
to enhance your practice

The **future** is in your
hands. One tap, many
possibilities.

Experience the digital edition on your
handheld device. Use your smart device
to scan the code below or visit:



Download a QR scanner app. Launch app and hold your
mobile device over the code to view

www.reviewofophthalmology.com/publications/archive



REVIEW
of Ophthalmology

An Outbreak of Research into The Novel Coronavirus

New breakthroughs and information have arisen from all corners of the global medical community in the face of the novel coronavirus pandemic. Ophthalmic research has also played a part. The immunomodulatory research on cyclosporine and corneal transplants conducted by Mohammed Ziaei, MD, an ophthalmologist currently practicing in New Zealand, and his UK-based team in 2016, was recently cited by researchers in China studying potential interventions for coronavirus.¹ “Cyclosporine can block the replication of the coronavirus,” Dr. Ziaei says. “[The researchers] used my article as a reference for its efficacy in organ transplants as well as a mechanism of action.”

The review article, published in the *Journal of Medical Virology*, states that “nucleocapsid protein of SARS-CoV played an important role in the process of virus particle assembly and release, and it might also bind to human cyclophilin A. Cyclophilin A is a key member of immunophilins acting as a cellular receptor for cyclosporine A. Cyclophilin A has played an important role in viral infection, either facilitating or inhibiting their replication. In addition, the inhibition of cyclophilins by cyclosporine A could block the replication of coronavirus of all genera, including SARS-CoV, as well as avian

infectious bronchitis virus.”²

Plaquenil (hydroxychloroquine sulfate) and Resochin (chloroquine phosphate) have also made a reappearance in the news as potential drugs for combatting coronavirus. Bayer recently donated three million chloroquine tablets for government research.³ Originally used to prevent or treat malaria, Plaquenil is now used to treat inflammatory diseases, such as lupus and rheumatoid arthritis. Ophthalmologists conduct regular checks on these patients, since one rare side effect of the drug, when taken at high doses long-term, is retinal toxicity.

An interventional clinical trial in Shanghai, begun in February, investigated the efficacy and safety of hydroxychloroquine for the treatment of pneumonia caused by SARS-CoV-2.⁴ The study included 30 randomized participants, taking hydroxychloroquine 400 mg per day for five days, along with conventional treatments. Those with retinal disease were excluded from the study. The recommended dosing for Plaquenil is 6.5 mg/kg of body weight, with the maximum adult dosage at 400 mg daily. Results are pending.

Another recent study in China examined the antiviral activity and optimal dosing design for hydroxychloroquine for the coronavirus. The

researchers propose that the immunomodulatory effect of hydroxychloroquine may be useful in controlling the cytokine storm that occurs late-phase in critically ill coronavirus patients. They found that hydroxychloroquine was more potent than chloroquine for inhibiting SARS-CoV-2.⁵

New research is emerging rapidly. A March 16, 2020 study published in *Bioscience Trends* found chloroquine phosphate to have “apparent efficacy and acceptable safety against COVID-19-associated pneumonia” in multicenter clinical trials in China.⁶ A French study in a small number of patients found Plaquenil 200 mg three times daily for 10 days combined with azithromycin 500 mg for the first day, then 250 mg for four additional days to be effective in treating COVID-19.⁷

Hydroxychloroquine and chloroquine recently received FDA Emergency Use Authorization for treating coronavirus in teen and adult patients. This will allow the millions of doses of the drugs that have been donated by pharmaceutical companies to be added to the country’s stockpile. This may help patients who depend on Plaquenil to control chronic conditions to continue to have access to the drug, rather than have to suffer from others hoarding it in an effort to treat potential cases of COVID-19.

Coming Next Month ...

In the March issue, we featured “Making Complications Disappear,” the first in a two-part series on how surgeons manage tough situations in their cataract cases. The second installment will appear in our May issue.


1. Ziaei M, Ziaei F, Manzouri B. Systemic cyclosporine and corneal transplantation. *Int Ophthalmol* 2016;36:139-146.
2. Zhang L, Liu Y. Potential interventions for novel coronavirus in China: A systematic review. *J Med Virol* 2020;92:5:479-490. [ePub ahead of print]
3. @BayerUS. Tweet: 12:36 PM, March 19, 2020.
4. Lu H. Efficacy and safety of hydroxychloroquine for treatment of pneumonia caused by 2019-nCoV (HC-nCoV). NCT04261517.



Ken Beckman



Alan Crandall



Eric Donnenfeld




Alan Faulkner



John Hovanesian




Doug Katsev




James Loden



Cynthia Matossian



Cathleen McCabe



Lisa Nijm



Bob Osher



Steve Silverstein



Denise Visco



Keith Walter



George Waring

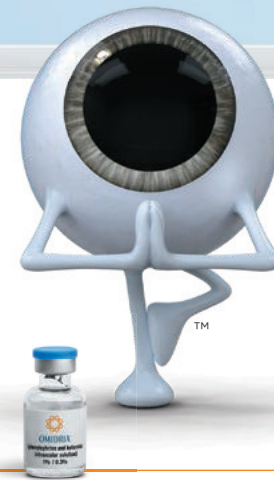

Your name here

These cataract surgeons use OMIDRIA® (phenylephrine and ketorolac intraocular solution) 1% / 0.3% for **less stress, pure success** in their O.R. day¹

What about you?

OMIDRIA helps your cataract surgery by inhibiting prostaglandin release to block inflammation and maintain iris tone, preventing miosis and reducing postoperative pain for your patients.^{2,3} Experience less stress in your O.R. day with OMIDRIA.¹



INDICATIONS AND USAGE

OMIDRIA® (phenylephrine and ketorolac intraocular solution) 1% / 0.3% is added to ophthalmic irrigating solution used during cataract surgery or intraocular lens replacement and is indicated for maintaining pupil size by preventing intraoperative miosis and reducing postoperative ocular pain.

IMPORTANT SAFETY INFORMATION

OMIDRIA must be added to irrigating solution prior to intraocular use.

OMIDRIA is contraindicated in patients with a known hypersensitivity to any of its ingredients.

Systemic exposure of phenylephrine may cause elevations in blood pressure.

Use OMIDRIA with caution in individuals who have previously exhibited sensitivities to acetylsalicylic acid, phenylacetic acid derivatives, and other nonsteroidal anti-inflammatory drugs (NSAIDs), or have a past medical history of asthma.

The most commonly reported adverse reactions at ≥2% are eye irritation, posterior capsule opacification, increased intraocular pressure, and anterior chamber inflammation.

Please see the Full Prescribing Information for OMIDRIA at www.omidria.com/prescribinginformation.

You are encouraged to report Suspected Adverse Reactions to the FDA. Visit www.fda.gov/medwatch, or call 1-800-FDA-1088.

References: 1. Omeros survey data on file. 2. OMIDRIA [package insert]. Seattle, WA: Omeros Corporation; 2017. 3. Al-Hashimi S, Donaldson K, Davidson R, et al; for ASCRS Refractive Cataract Surgery Subcommittee. Medical and surgical management of the small pupil during cataract surgery. *J Cataract Refract Surg.* 2018;44:1032-1041.

The healthcare professionals portrayed in this advertisement are consultants of Omeros Corporation.



OMEROS®, the OMEROS logo®, OMIDRIA®, and the OMIDRIA logo® are registered trademarks of Omeros Corporation.

© Omeros Corporation 2019, all rights reserved. 2019-022



OMIDRIA®
(phenylephrine and ketorolac
intraocular solution)
1% / 0.3%

Coronavirus: The Economic Impact

In mid March, as the country waited for a financial stimulus package from the government, *Review* conducted an e-survey to get a sense from ophthalmologists how restrictions on patients and the American Academy of Ophthalmology's recommendation to see only urgent or emergency cases were impacting their practices. Among the findings, of the 146 physicians who responded, 20 percent said they weren't heeding the AAO's recommendations in order to try to keep their practices afloat.

In addition, a number of physicians shared the steps they're taking to try to remain solvent when they can't see their normal patient load:

- "Call patients to give them peace of mind and let them know they're not abandoned. Possibly convert to telehealth exams. Your business will bounce back once this recovers. But you have to follow social distancing and quarantine to stay healthy and end this pandemic."
- "We're answering calls with call forwarding to the home of our front-desk person. Emergencies are being answered by telephone and for dire emergencies the doctor will come in."
- "Limit hours and—I hate to say it—furlough your staff, talk to the landlord about deferring part of the rent, and limit ordering nonessential supplies."
- "We are exploring telemedicine but there is limited application in ophthalmology. We've decreased partner pay to zero and hoping to restructure practice loans to interest only."
- "Honestly? Not much [you can do] other than just biting the bullet and paying some semblance of salary, in a meaningful amount, to keep the hourly employees from falling apart. We'll need them in a couple of months. I never stopped taking call, inpatient consults or trauma; there's still that for a trickle of work. We've added telehealth when possible."
- "Let staff apply for unemployment funds. Have some staff available for emergencies. Have accounts receivable and payable staff come in one day per week, monitor and reroute faxes to staff members on laptops at home and come in one day per week for eRXs. Keep good communication with staff. Delay payments or doctor salaries if possible. Consider accessing lines of credit or obtain SBA low interest loans."

The full survey report that was e-mailed is available in the Enews section of reviewofophthalmology.com.

5. Yao X, Ye F, Zhang M, et al. In vitro antiviral activity and projection of optimized dosing design of hydroxychloroquine for the treatment of severe acute respiratory syndrome coronavirus 2 (SARS-CoV-2). *Clin Infect Dis* 2020. [ePub ahead of print]

6. Gao J, Tian Z, Yang X. Breakthrough: Chloroquine phosphate has shown apparent efficacy in treatment of covid-19 associated pneumonia in clinical studies. *Biosci Trends* 2020;14:1:72-73.

7. Gautret P, Lagier JC, Parola P. Hydroxychloroquine and azithromycin as a treatment of COVID-19: Results of an open-label non-randomized clinical trial. *Int J Antimicrob Agents*; 20 Mar 2020 [Online ahead of print]

about several cases of inflammation associated with the administration of the drug.

Since its approval, more than 57,000 vials of Beovu have been distributed in U.S. clinics.¹ Pravin Dugel, MD, presented to the Macula Society on the inflammation cases flagged by the ASRS. Findings included fifty-seven clinician-reported intraocular inflammation events, including nine cases with significant vision loss and five cases of retinal occlusive vasculitis, as evaluated by the Safety Review Committee (ongoing).²

"A vast majority of the patients had had previous injections, but it's not clear to me how many of them were treatment-naïve for Beovu," says Sunir Garg, MD, partner with Mid Atlantic Retina and co-director of the Retina

(Continued on page 17)

Update on Beovu

Novartis' new anti-VEGF agent Beovu (brolucizumab), which received FDA approval in October 2019, is currently under a comprehensive product quality review after the American Society of Retina Specialists issued a warning to its members

EDITORIAL STAFF

Editor in Chief

Walter C. Bethke
(610) 492-1024
wbethke@jobson.com

Senior Editor

Christopher Kent
(212) 274-7031
ckent@jobson.com

Senior Editor

Sean McKinney
(610) 492-1025
semckinney@jobson.com

Associate Editor

Christine Leonard
(610) 492-1008
cleonard@jobson.com

Chief Medical Editor

Mark H. Blecher, MD

Art Director

Jared Araujo
(610) 492-1032
jaraujo@jobson.com

Senior Graphic Designer

Matt Egger
(610) 492-1029
megger@jobson.com

International coordinator, Japan

Mitz Kaminuma
Reviewophthalmo@aol.com

Business Offices

19 Campus Boulevard, Suite 101
Newtown Square, PA 19073
(610) 492-1000
Fax: (610) 492-1039

Subscription inquiries:

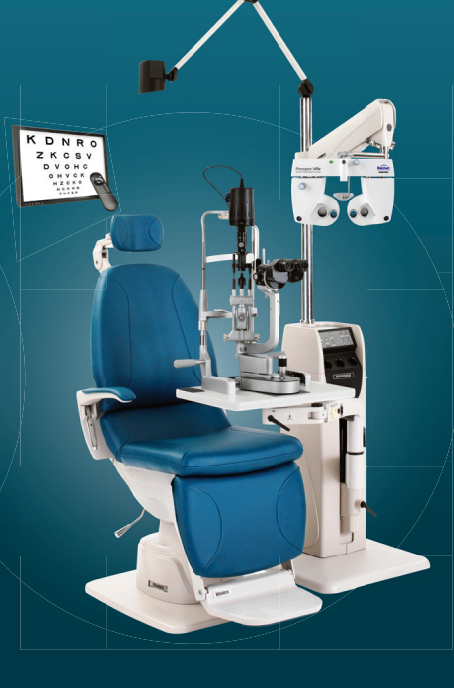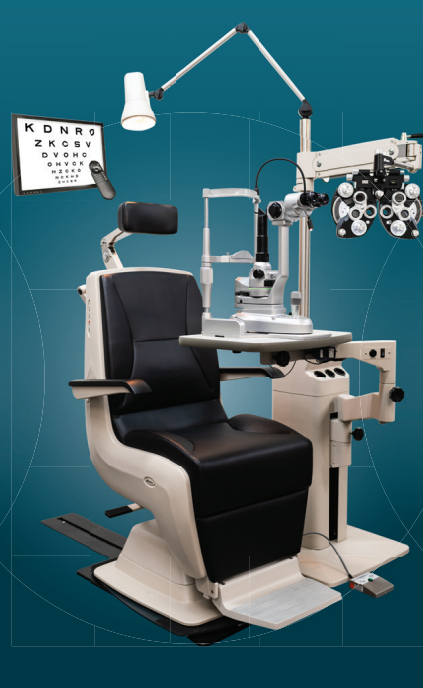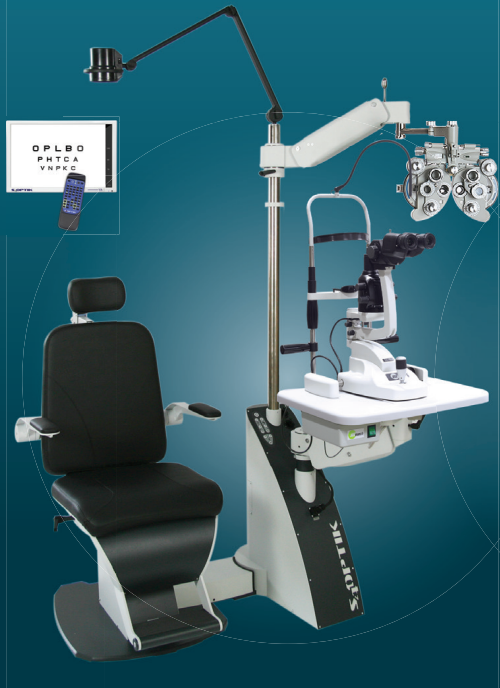United States — (877) 529-1746
Outside U.S. — (845) 267-3065

E-mail:

revophthalmology@cambeywest.com
Website: www.reviewofophthalmology.com



40 years of partnership
50,000+ lanes of experience
Experts at what we do.



Haag-Streit • Marco • Reichert • Reliance • S4Optik • Topcon • and more

QUALITY | SELECTION | PRICE | SUPPORT



35 SERVICE CENTERS

COAST TO COAST

800.LOMBART

VIEW LANE PACKAGES @ LOMBARTINSTRUMENT.COM/STORE/PACKAGES

WWW.LOMBARTINSTRUMENT.COM | INFO@LOMBARTINSTRUMENT.COM

CONTRIBUTORS

CHIEF MEDICAL EDITOR
Mark H. Blecher, MD

CONTACT LENSES
Penny Asbell, MD

CORNEA / ANTERIOR SEGMENT
Thomas John, MD

GLAUCOMA MANAGEMENT
Peter Netland, MD, PHD
Kuldev Singh, MD

MASTERS OF SURGERY
Taliva D. Martin, MD
Sara J. Haug, MD, PhD

MEDICARE Q & A
Paul M. Larson, MBA

PEDIATRIC PATIENT
Wendy Huang, MD

PLASTIC POINTERS
Ann P. Murchison, MD, MPH

REFRACTIVE SURGERY
Arturo S. Chayet, MD

RETINAL INSIDER
Carl Regillo, MD, FACS
Yoshihiro Yonekawa, MD

TECHNOLOGY UPDATE
Steven T. Charles, MD
Michael Colvard, MD

WILLS RESIDENT CASE SERIES
Rebecca Russ Soares, MD, MPH

ADVISORY BOARD

PENNY A. ASBELL, MD, MEMPHIS, TENN.
BRANDON AYRES, MD, PHILADELPHIA
SURENDRA BASTI, MD, CHICAGO
WILLIAM I. BOND, MD, PEKIN, ILL.
ALAN N. CARLSON, MD, DURHAM, N.C.
Y. RALPH CHU, MD, EDINA, MINN.
ADAM J. COHEN, MD, CHICAGO
UDAY DEVGAN, MD, FACS, LOS ANGELES
ERIC DONNENFELD, MD, ROCKVILLE CENTRE, N.Y.
DANIEL S. DURRIE, MD, KANSAS CITY, MO.
ROBERT EPSTEIN, MD, MCHEENRY, ILL.
ROBERT D. FECHTNER, MD, NEWARK, N.J.
WILLIAM J. FISHKIND, MD, TUCSON, ARIZ.
BRIAN FRANCIS, MD, Los Angeles
JAMES P. GILLS, MD, TARPON SPRINGS, FLA.
HARRY GRABOW, MD, SARASOTA, FLA.
DOUGLAS K. GRAYSON, MD, NEW YORK CITY
THOMAS S. HARBIN, MD, MBA, ATLANTA
DAVID R. HARDTEN, MD, MINNEAPOLIS
KENNETH J. HOFFER, MD, SANTA MONICA, CALIF.
JACK T. HOLLADAY, MD, MSEE, HOUSTON
JOHN D. HUNKELER, MD, KANSAS CITY, MO.
THOMAS JOHN, MD, TINLEY PARK, ILL.
ROBERT M. KERSHNER, MD, MS, PALM BEACH GARDENS, FLA.
GUY M. KEZIRIAN, MD, PARADISE VALLEY, ARIZ.
TERRY KIM, MD, DURHAM, N.C.
BRAD KLIGMAN, MD, GARDEN CITY, N.Y.
TOMMY KORN, MD, SAN DIEGO
DAVID A. LEE, MD, HOUSTON
FRANCIS S. MAH, MD, PITTSBURGH

NICK MAMALIS, MD, SALT LAKE CITY
EDWARD MANCHE, MD, PALO ALTO, CALIF.
MIKE S. MCFARLAND, MD, PINE BLUFF, ARK.
JEFFREY B. MORRIS, MD, MPH, ENCINITAS, CALIF.
KEVIN MILLER, MD, LOS ANGELES
MARLENE R. MOSTER, MD, PHILADELPHIA
ROBERT J. NOECKER, MD, FAIRFIELD, CONN.
ROBERT OSHER, MD, CINCINNATI
MARK PACKER, MD, WEST PALM BEACH, FLA.
CHRISTOPHER J. RAPUANO, MD, PHILADELPHIA
AUGUST READER III, MD, SAN FRANCISCO
TONY REALINI, MD, MORGANTOWN, W.V.
KENNETH J. ROSENTHAL, MD, GREAT NECK, N.Y.
ERIC ROTHCHILD, MD, DELRAY BEACH, FLA.
SHERI ROWEN, MD, BALTIMORE
JAMES J. SALZ, MD, LOS ANGELES
INGRID U. SCOTT, MD, MPH, HERSHEY, PA.
JOEL SCHUMAN, MD, PITTSBURGH
GAURAV SHAH, MD, ST. LOUIS
DAVID R. STAGER JR., MD, DALLAS
KARL STONECIPHER, MD, GREENSBORO, N.C.
JAMES C. TSAI, MD, NEW YORK CITY
VANCE THOMPSON, MD, SIOUX FALLS, S.D.
FARRELL C. TYSON, MD, CAPE CORAL, FLA.
R. BRUCE WALLACE III, MD, ALEXANDRIA, LA.
ROBERT G. WILEY, MD, CLEVELAND
FRANK WEINSTOCK, MD, CANTON, OHIO

REVIEW[®]
of Ophthalmology

BUSINESS OFFICES
19 CAMPUS BOULEVARD, SUITE 101
NEWTOWN SQUARE, PA 19073
SUBSCRIPTION INQUIRIES (877) 529-1746
(USA ONLY); OUTSIDE USA, CALL (847) 763-9630

BUSINESS STAFF
PUBLISHER
JAMES HENNE
(610) 492-1017 JHENNE@JOBSON.COM

REGIONAL SALES MANAGER
MICHELE BARRETT
(610) 492-1014 MBARRETT@JOBSON.COM

REGIONAL SALES MANAGER
MICHAEL HOSTER
(610) 492-1028 MHOSTER@JOBSON.COM

CLASSIFIED ADVERTISING
(888)-498-1460

PRODUCTION MANAGER
FARRAH APONTE
212-274-7057 FAPONTE@JOBSON.COM

PRODUCTION MANAGER
KAREN LALLONE
(610) 492-1010 KLALLONE@JOBSON.COM

SUBSCRIPTIONS
\$63 A YEAR, \$99 (U.S.) IN CANADA,
\$158 (U.S.) IN ALL OTHER COUNTRIES.
SUBSCRIPTIONS E-MAIL:
REVOPHTHALMOLOGY@CAMBEYWEST.COM

CIRCULATION
PO BOX 71, CONGERS, NY 10920-0071
(877) 529-1746
OUTSIDE USA: (845) 267-3065

SENIOR CIRCULATION MANAGER
HAMILTON MAHER
(212) 219-7870 hmaher@hihealth.com

CEO, INFORMATION GROUP SERVICES
MARC FERRARA

SENIOR VICE PRESIDENT, OPERATIONS
JEFF LEVITZ

VICE PRESIDENT, HUMAN RESOURCES
TAMMY GARCIA

VICE PRESIDENT, CREATIVE SERVICES & PRODUCTION
MONICA TETTAMANZI

CORPORATE PRODUCTION DIRECTOR
JOHN ANTHONY CAGGIANO

VICE PRESIDENT, CIRCULATION
JARED SONNERS



395 Hudson Street, 3rd Floor,
New York, NY 10014

REVIEW OF OPHTHALMOLOGY (ISSN 1081-0226; USPS No. 0012-345) is published monthly, 12 times per year by Jobson Medical Information, 395 Hudson Street, 3rd Floor, New York, NY 10014. Periodicals postage paid at New York, NY and additional mailing offices. Postmaster: Send address changes to Review of Ophthalmology, PO Box 71, Congers, NY 10929-0071. Subscription Prices: US One Year \$63.00, US Two Year \$112.00, Canada One Year \$99.00, Canada Two Year \$181.00, Int'l One Year \$158.00, Int'l Two Year \$274.00. For subscription information call (877) 529-1746 (USA only); outside USA, call (845)-267-3065. Or email us at revophthalmology@cambeywest.com. Canada Post: Publications Mail Agreement #40612608. Canada Returns to be sent to Bleuchip International, P.O. Box 25542, London, ON N6C 6B2.



TEPEZZA™

teprotumumab-trbw

For injection, for intravenous use

Brief Summary - Please see the TEPEZZA package insert for full prescribing information.

INDICATIONS AND USAGE

TEPEZZA is indicated for the treatment of Thyroid Eye Disease.

WARNINGS AND PRECAUTIONS

Infusion Reactions

TEPEZZA may cause infusion reactions. Infusion reactions have been reported in approximately 4% of patients treated with TEPEZZA. Signs and symptoms of infusion-related reactions include transient increases in blood pressure, feeling hot, tachycardia, dyspnea, headache and muscular pain. Infusion reactions may occur during any of the infusions or within 1.5 hours after an infusion. Reported infusion reactions are usually mild or moderate in severity and can usually be successfully managed with corticosteroids and antihistamines. In patients who experience an infusion reaction, consideration should be given to pre-medicating with an antihistamine, antipyretic, corticosteroid and/or administering all subsequent infusions at a slower infusion rate.

Exacerbation of Preexisting Inflammatory Bowel Disease

TEPEZZA may cause an exacerbation of preexisting inflammatory bowel disease (IBD). Monitor patients with IBD for flare of disease. If IBD exacerbation is suspected, consider discontinuation of TEPEZZA.

Hyperglycemia

Hyperglycemia or increased blood glucose may occur in patients treated with TEPEZZA. In clinical trials, 10% of patients (two-thirds of whom had preexisting diabetes or impaired glucose tolerance) experienced hyperglycemia. Hyperglycemic events should be controlled with medications for glycemic control, if necessary.

Monitor patients for elevated blood glucose and symptoms of hyperglycemia while on treatment with TEPEZZA. Patients with preexisting diabetes should be under appropriate glycemic control before receiving TEPEZZA.

ADVERSE REACTIONS

The following clinically significant adverse reactions are described elsewhere in the labeling:

- Infusion Reactions [see Warnings and Precautions]
- Exacerbation of Inflammatory Bowel Disease [see Warnings and Precautions]
- Hyperglycemia [see Warnings and Precautions]

Clinical Trials Experience

Because clinical trials are conducted under widely varying conditions, adverse reaction rates observed in the clinical trials of a drug cannot be directly compared to rates in the clinical trials of another drug and may not reflect the rates observed in practice.

The safety of TEPEZZA was evaluated in two randomized, double-masked, placebo-controlled clinical studies (Study 1 [NCT:01868997] and Study 2 [NCT:03298867]) consisting of 170 patients with Thyroid Eye Disease (84 received TEPEZZA and 86 received placebo). Patients were treated with TEPEZZA (10 mg/kg for first infusion and 20 mg/kg for the remaining 7 infusions) or placebo given as an intravenous infusion every 3 weeks for a total of 8 infusions. The majority of patients completed 8 infusions (89% of TEPEZZA patients and 93% of placebo patients).

The most common adverse reactions (≥5%) that occurred at greater incidence in the TEPEZZA group than in the control group during the treatment period of Studies 1 and 2 are summarized in Table 1.

Table 1. Adverse Reactions Occurring in 5% or More of Patients Treated with TEPEZZA and Greater Incidence than Placebo

Adverse Reactions	TEPEZZA N=84 N (%)	Placebo N=86 N (%)
Muscle spasms	21 (25%)	6 (7%)
Nausea	14 (17%)	8 (9%)
Alopecia	11 (13%)	7 (8%)
Diarrhea	10 (12%)	7 (8%)
Fatigue ^a	10 (12%)	6 (7%)
Hyperglycemia ^b	8 (10%)	1 (1%)
Hearing impairment ^c	8 (10%)	0
Dysgeusia	7 (8%)	0
Headache	7 (8%)	6 (7%)
Dry skin	7 (8%)	0

a - Fatigue includes asthenia

b - Hyperglycemia includes blood glucose increase

c - Hearing impairment (includes deafness, eustachian tube dysfunction, hyperacusis, hypoacusis and autophony)

Immunogenicity

As with all therapeutic proteins, there is potential for immunogenicity. The detection of antibody formation is highly dependent on the sensitivity and specificity of the assay.

In a placebo-controlled study with TEPEZZA, 1 of 42 patients treated with placebo had detectable levels of antidrug antibodies in serum. In the same study, none of the 41 patients treated with TEPEZZA had detectable levels of antidrug antibodies in serum.

USE IN SPECIFIC POPULATIONS

Pregnancy

Risk Summary

Based on findings in animals and its mechanism of action inhibiting insulin-like growth factor-1 receptor (IGF-1R), TEPEZZA may cause fetal harm when administered to a pregnant woman. Adequate and well-controlled studies with TEPEZZA have not been conducted in pregnant women. There is insufficient data with TEPEZZA use in pregnant women to inform any drug associated risks for adverse developmental outcomes. In utero teprotumumab exposure in cynomolgus monkeys dosed once weekly with teprotumumab throughout pregnancy resulted in external and skeletal abnormalities. Teprotumumab exposure may lead to an increase in fetal loss [see Data]. Therefore, TEPEZZA should not be used in pregnancy, and appropriate forms of contraception should be implemented prior to initiation, during treatment and for 6 months following the last dose of TEPEZZA.

If the patient becomes pregnant during treatment, TEPEZZA should be discontinued and the patient advised of the potential risk to the fetus.

The background rate of major birth defects and miscarriage is unknown for the indicated population. In the U.S. general population, the estimated background risks of major birth defects and miscarriage in clinically recognized pregnancies are 2-4% and 15-20%, respectively.

Data

Animal Data

In an abridged pilot embryofetal development study, seven pregnant cynomolgus monkeys were dosed intravenously at one dose level of teprotumumab, 75 mg/kg (2.8-fold the maximum recommended human dose [MRHD] based on AUC) once weekly from gestation day 20 through the end of gestation. The incidence of abortion was higher for the teprotumumab treated group compared to the control group. Teprotumumab caused decreased fetal growth during pregnancy, decreased fetal size and weight at caesarean section, decreased placental weight and size, and decreased amniotic fluid volume. Multiple external and skeletal abnormalities were observed in each exposed fetus, including: misshapen cranium, closely set eyes, micrognathia, pointing and narrowing of the nose, and ossification abnormalities of skull bones, sternbrae,

carpals, tarsals and teeth. The test dose, 75 mg/kg of teprotumumab, was the maternal no observed adverse effect level (NOAEL).

Based on mechanism of action inhibiting IGF-1R, postnatal exposure to teprotumumab may cause harm.

Lactation

Risk Summary

There is no information regarding the presence of TEPEZZA in human milk, the effects on the breastfed infant or the effects on milk production.

Females and Males of Reproductive Potential

Contraception

Females

Based on its mechanism of action inhibiting IGF-1R, TEPEZZA may cause fetal harm when administered to a pregnant woman (see Use in Specific Populations). Advise females of reproductive potential to use effective contraception prior to initiation, during treatment with TEPEZZA and for 6 months after the last dose of TEPEZZA.

Pediatric Use

Safety and effectiveness have not been established in pediatric patients.

Geriatric Use

Of the 171 patients in the two randomized trials, 15% were 65 years of age or older; the number of patients 65 years or older was similar between treatment groups. No overall differences in efficacy or safety were observed between patients 65 years or older and younger patients (less than 65 years of age).

OVERDOSAGE

No information is available for patients who have received an overdose.

PATIENT COUNSELING INFORMATION

Embryo-Fetal Toxicity

Advise females of reproductive potential that TEPEZZA can cause harm to a fetus and to inform their healthcare provider of a known or suspected pregnancy.

Educate and counsel females of reproductive potential about the need to use effective contraception prior to initiation, during treatment with TEPEZZA and for 6 months after the last dose of TEPEZZA.

Infusion-related reactions

Advise patients that TEPEZZA may cause infusion reactions that can occur at any time. Instruct patients to recognize the signs and symptoms of infusion reaction and to contact their healthcare provider immediately for signs or symptoms of potential infusion-related reactions.

Exacerbation of Inflammatory Bowel Disease

Advise patients on the risk of inflammatory bowel disease (IBD) and to seek medical advice immediately if they experience diarrhea, with or without blood or rectal bleeding, associated with abdominal pain or cramping/colic, urgency, tenesmus or incontinence.

Manufactured by:

Horizon Therapeutics Ireland DAC
Dublin, Ireland
U.S. License No. 2022

Distributed by:

Horizon Therapeutics USA, Inc.
Lake Forest, IL 60045

TEPEZZA and the HORIZON logo are trademarks owned by or licensed to Horizon.

© 2020 Horizon Therapeutics plc L-TEP-00018 01/20



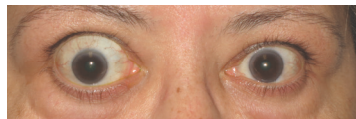NOW APPROVED

The first and only FDA-approved treatment for Thyroid Eye Disease (TED)

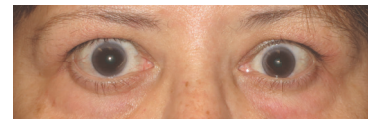TEPEZZA™ teprotumumab-trbw

TEPEZZA decreases proptosis, diplopia, and the signs and symptoms of TED without concomitant steroids¹⁻³

SEE THE DIFFERENCE⁴



BASELINE
Proptosis: 25 mm



POST-TREATMENT (WEEK 24)
Proptosis: 21 mm

Real TEPEZZA patient treated in a clinical trial. Results shown are with no surgical intervention. Individual results may vary. TEPEZZA met its primary endpoint vs placebo in 2 randomized, placebo-controlled trials ($P < 0.01$), defined as proptosis responder rate at Week 24 (percentage of patients with ≥ 2 -mm reduction in proptosis in the study eye from baseline).^{1-3,5}

Learn more at TEPEZZAhcp.com

INDICATION

TEPEZZA is indicated for the treatment of Thyroid Eye Disease.

IMPORTANT SAFETY INFORMATION

Warnings and Precautions

Infusion Reactions: TEPEZZA may cause infusion reactions. Infusion reactions have been reported in approximately 4% of patients treated with TEPEZZA. Reported infusion reactions have usually been mild or moderate in severity. Signs and symptoms may include transient increases in blood pressure, feeling hot, tachycardia, dyspnea, headache, and muscular pain. Infusion reactions may occur during an infusion or within 1.5 hours after an infusion. In patients who experience an infusion reaction, consideration should be given to premedicating with an antihistamine, antipyretic, or corticosteroid and/or administering all subsequent infusions at a slower infusion rate.

Preexisting Inflammatory Bowel Disease: TEPEZZA may cause an exacerbation of preexisting inflammatory bowel disease (IBD). Monitor patients with IBD for flare of disease. If IBD exacerbation is suspected, consider discontinuation of TEPEZZA.

Hyperglycemia: Increased blood glucose or hyperglycemia may occur in patients treated with TEPEZZA. In clinical trials, 10% of patients (two-thirds of whom had preexisting diabetes or impaired glucose tolerance) experienced hyperglycemia. Hyperglycemic events should be managed with medications for glycemic control, if necessary. Monitor patients for elevated blood glucose and symptoms of hyperglycemia while on treatment with TEPEZZA. Patients with preexisting diabetes should be under appropriate glycemic control before receiving TEPEZZA.

Adverse Reactions

The most common adverse reactions (incidence $\geq 5\%$ and greater than placebo) are muscle spasm, nausea, alopecia, diarrhea, fatigue, hyperglycemia, hearing impairment, dysgeusia, headache, and dry skin.

Please see Brief Summary of Prescribing Information for TEPEZZA on adjacent pages.

References: 1. TEPEZZA (teprotumumab-trbw) [prescribing information] Horizon. 2. Data on File. Horizon, April 2019. 3. Smith TJ, Kahaly GJ, Ezra DG, et al. Teprotumumab for thyroid-associated ophthalmopathy. *N Engl J Med*. 2017;376(18):1748-1761. 4. Data on File. Horizon, January 2020. 5. Data on File. Horizon, December 2019.

TEPEZZA and the HORIZON logo are trademarks owned by or licensed to Horizon.
© 2020 Horizon Therapeutics plc P-TEP-00026 01/20



REVIEW[®] of Ophthalmology

April 2020 • Volume XXVII No. 4 | reviewofophthalmology.com

Cover Focus

32 | **Biometry and Formulas— Nailing the Outcome**

Christopher Kent, Senior Editor

Our ability to measure the eye accurately and calculate the IOL power keeps evolving—but there's still room for improvement.

42 | **Point/Counterpoint: Yamane Technique vs. Scleral-Sutured Fixation**

*Gregory S. H. Ogawa, MD, and
Brandon Ayres, MD*

50 | **Adjustable IOLS: Lights, Lasers And Lock-ins**

Christine Leonard, Associate Editor

An update on new technology for making postop IOL adjustments.

Feature Article

57 | **Daring to Treat Vitreous Floaters**

Sean McKinney, Senior Editor

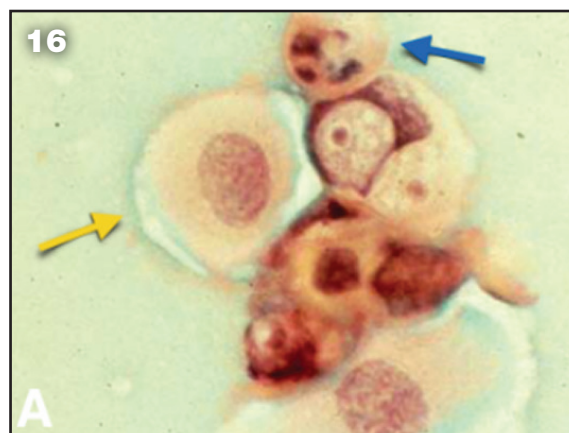
More experts are taking a second look at approaches to resolving these visual disturbances.

April 2020 | reviewofophthalmology.com | 11

Departments

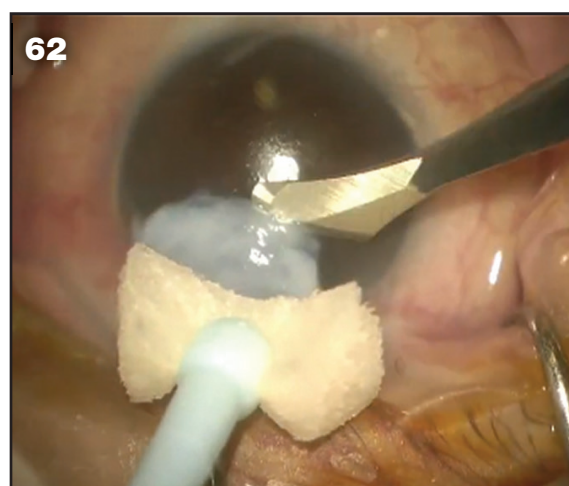
4 | [Review News](#)

16 | [Cornea/Anterior Segment](#)
***Acanthamoeba* : The Keratitis that Won't Quit!**
A discussion of the epidemiological risk factors and current diagnostic and therapeutic strategies for this formidable protozoan invader.



26 | [Technology Update](#)
3-D Heads-up Displays & The Anterior Segment Surgeon
Proponents say this technology is becoming more viable as a tool for surgeons working at the front of the eye.

62 | [Glaucoma Management](#)
Tubes, Trabs and Cataract Surgery
Glaucoma patients often present extra challenges during cataract surgery. An expert offers helpful strategies.

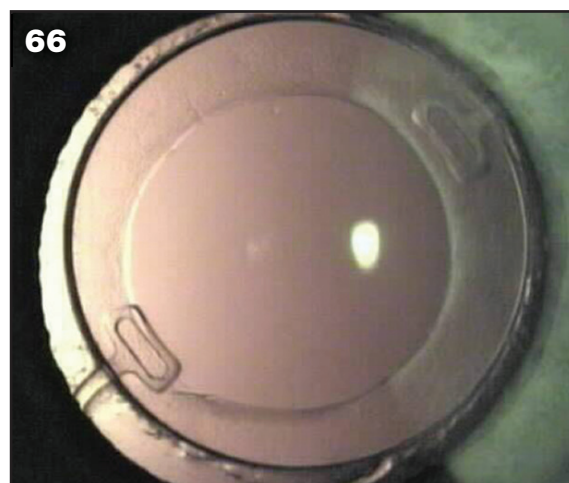


66 | [Refractive/Cataract Rundown](#)
How to Right-size Your Capsulorhexis
Learn the best strategies to use when you need to go small, large or somewhere in between.

69 | [Wills Eye Resident Case Series](#)

74 | [Classifieds](#)


74 | [Advertiser Index](#)



iStent
inject®

maximize
efficacy

minimize
concerns



In micro-invasive surgery, seek the micro-invasive option...

- 500,000+ Glaukos trabecular micro-bypass stents implanted and 100+ peer-reviewed publications
- Lowest reported post-op mean IOP of any trabecular bypass stent^{1*}
- Lowest reported rates of significant endothelial cell loss (ECL)^{1*†}
- Lowest reported rates of peripheral anterior synechiae (PAS)^{1*}

TransformMIGS.com | 800.GLAUKOS (452.8567)

* In any trabecular bypass MIGS pivotal trial.
† Significant ECL defined as $\geq 30\%$ ECL.

INDICATION FOR USE. The iStent inject® Trabecular Micro-Bypass System Model G2-M-IS is indicated for use in conjunction with cataract surgery for the reduction of intraocular pressure (IOP) in adult patients with mild to moderate primary open-angle glaucoma. **CONTRAINDICATIONS.** The iStent inject is contraindicated in eyes with angle-closure glaucoma, traumatic, malignant, uveitic, or neovascular glaucoma, discernible congenital anomalies of the anterior chamber (AC) angle, retrolubar tumor, thyroid eye disease, or Sturge-Weber Syndrome or any other type of condition that may cause elevated episcleral venous pressure. **WARNINGS.** Gonioscopy should be performed prior to surgery to exclude congenital anomalies of the angle, PAS, rubeosis, or conditions that would prohibit adequate visualization of the angle that could lead to improper placement of the stent and pose a hazard. **MRI INFORMATION.** The iStent inject is MR-Conditional, i.e., the device is safe for use in a specified MR environment under specified conditions; please see Directions for Use (DFU) label for details. **PRECAUTIONS.** The surgeon should monitor the patient postoperatively for proper maintenance of IOP. The safety and effectiveness of the iStent inject have not been established as an alternative to the primary treatment of glaucoma with medications, in children, in eyes with significant prior trauma, abnormal anterior segment, chronic inflammation, prior glaucoma surgery (except SLT performed > 90 days preoperative), glaucoma associated with vascular disorders, pseudoexfoliative, pigmentary or other secondary open-angle glaucomas, pseudophakic eyes, phakic eyes without concomitant cataract surgery or with complicated cataract surgery, eyes with medicated IOP > 24 mmHg or unmedicated IOP < 21 mmHg or > 36 mmHg, or for implantation of more or less than two stents. **ADVERSE EVENTS.** Common postoperative adverse events reported in the randomized pivotal trial included stent obstruction (6.2%), intraocular inflammation (5.7% for iStent inject vs. 4.2% for cataract surgery only), secondary surgical intervention (5.4% vs. 5.0%) and BCVA loss ≥ 2 lines ≥ 3 months (2.6% vs. 4.2%). **CAUTION:** Federal law restricts this device to sale by, or on the order of, a physician. Please see DFU for a complete list of contraindications, warnings, precautions, and adverse events.

REFERENCE: 1. Samuelson TW, Sarkisian SR, Lubeck DM, et al. Prospective, randomized, controlled pivotal trial of an *ab interno* implanted trabecular micro-bypass in primary open-angle glaucoma and cataract. *Ophthalmology*. Jun 2019;126(6):811-821.

© 2019 Glaukos Corporation. Glaukos and iStent inject are registered trademarks of Glaukos Corporation. PM-US-1099

GLAUKOS®
Transforming Glaucoma Therapy



SCIENCE IS JUST THE
BEGINNING OF OUR INNOVATION.
LET'S PARTNER IN DOING MORE
TO GIVE PEOPLE THE

VISION TO LIVE

Genentech
A Member of the Roche Group

© 2020 Genentech USA, Inc. 1 DNA Way, South San Francisco, CA 94080-4990
All rights reserved. M-US-00002492(v1.0) 1/20



Acanthamoeba: The Keratitis that Won't Quit!

We discuss the epidemiological risk factors and current diagnostic and therapeutic strategies for this formidable protozoan invader.

Kenneth R. Kenyon, MD, and William Binotti, MD, Boston

When it comes to *Acanthamoeba* keratitis, the best treatment is prevention. These insidious amoebae are found worldwide,¹ in virtually every environment, including soil, air, swimming pools, bottled water, domestic tap water and, most importantly for our purposes, contact lens solutions and paraphernalia.

Diagnosing this condition can be tricky—and treatment even more so—as the little buggers are highly resistant to conventional antimicrobial therapies, as well as freezing, desiccation and the typical chlorine levels used for drinking water disinfection.² Here, we'll discuss ocular *Acanthamoeba* infection, its epidemiology, clinical presentations and the latest methods of diagnosing and treating this insidious threat.

Themes and Variations

Though *Acanthamoeba* keratitis is relatively rare, accounting for perhaps 5 to 10 percent of all microbial keratitis, at referral centers like Tufts New England

Eye Center we encounter at least one new case per month (*Figure 1*). The first case of *Acanthamoeba* in the eye was reported 1973, in a South Texas rancher with a history of right eye trauma.² Subsequently, with increasing use of soft contact lenses and FDA approval of extended-wear contact lenses, *Acanthamoeba* keratitis cases began to mount; probably 85 to 90 percent of *Acanthamoeba* keratitis is contact lens-associated, with incidence estimates of about one corneal infection in 10,000 contact lens wearers per year,³⁻⁶ and increasing.

Acanthamoeba is a genus of free-living bacterivore amoebae. They're able to inhabit every conceivable form of water source and supply and also have the especially confounding ability to morph between two evolutive forms: an active trophozoite form and a dormant cyst (*Figure*

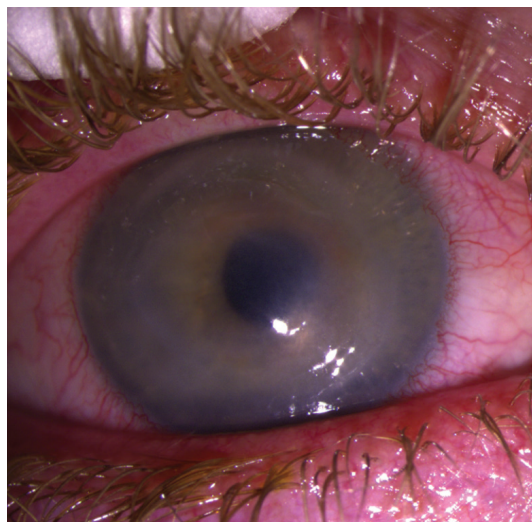


Figure 1. *Acanthamoeba* keratitis with a double ring infiltrate and central stromal infiltration.

2A). When faced with adverse environmental conditions, such as cold temperatures or antibiotic therapy, the *Acanthamoeba* trophozoite assumes its cystic form, a 15- to 30- μm sphere, which is largely impervious to stress and can maintain viability for years. The active and reproductive trophozoites, usually 25 to 50 μm in size⁷ are often overlooked in

(Continued from page 6)

Research Unit at Wills Eye Hospital in Philadelphia. “The mechanism of inflammation isn’t currently known either.”

In trials, the rate of inflammation was higher than what was seen with Lucentis and Eylea, says Rishi Singh, MD, a surgeon at the Cole Eye Institute, Cleveland Clinic, and assistant professor of ophthalmology at the Lerner College of Medicine in Cleveland, Ohio. “I think we were unaware that the inflammation was major or linked at all to the vascular occlusive events,” he says. “In previous phase III studies, we saw some small amount of inflammation present in early ranibizumab studies, so there was no concern. In light of some of the recent CEDAR and SEQUOIA studies, this was less significant.”

Novartis maintains that its data continue to support an overall favorable risk-benefit profile for the drug that remains consistent with or below the approved prescribing information. The prescribing leaflet states a 4 percent rate of intraocular inflammation and a 1 percent rate of retinal artery occlusion.

The rate, however, isn’t the issue, experts say. “The rate may very well be 4 percent, but it’s the severity of some of the cases that’s the issue,” says Dr. Garg. “If it were just mild iritis, then we could instruct the patient about what to look for and how to treat it, which is typically done with topical steroids over a short period time. The issue here is that, out of the 21 cases presented at the Macula Society, nine of them were thought to have profound or significant inflammation and seven of them lost at least five lines of vision. So it’s not the rate of inflammation, but the severity.

“The number of artery occlusions was also a little strange,” Dr. Garg continues. “One of the things we’ve struggled with for all of our drugs is whether or not the anti-VEGF drug

itself increases the risk of thromboembolic events, such as a stroke, heart attack or artery occlusion in the retina. The problem we’ve run into is that patients with macular degeneration are older people, and older people get strokes, heart attacks and artery occlusions in the retina anyway. So if you do a study, a few patients will get artery occlusions and there’s some question about whether the artery occlusion rate is higher with this drug than with other ones, or whether it was just luck of the draw and it shook out that way.

“Our group published a study looking at the incidence of artery occlusions after intravitreal anti-VEGF injections,” he says. “We found a higher incidence of artery occlusions in macular degeneration versus vein occlusion, but we had under 50,000 injections, and when you’re looking at something so rare, it’s a little hard to say with great confidence that the injections themselves contributed to it. We had retinal artery occlusion in one out of 1,389 injections. Statistically, it’s a low incidence, but in totality with all the other things we’re seeing, it’s caused some concern among the retina community.”³³

Dr. Garg himself hasn’t seen any cases like the adverse events reported in the post-marketing data for Beovu. He says his practice was slow to adopt Beovu and has done comparatively few Beovu injections since the commercial launch. In light of the ASRS announcement, he says, “I’m more hesitant to use Beovu until we have a better sense of what’s happening, why it’s happening, who’s at risk and what we can do to eliminate the chances of these occurrences.”

Dr. Singh says that since the announcement from the ASRS, “We discuss the most recent data on both uveitis and retinal vascular occlusive events with our patients. Even though the numbers are low, they appear to be higher than other market-available anti-VEGF cases. We give the patients

the option of continuing on Beovu or switching back to their previous agent. About 50 percent of patients remain on the same course and another 50 percent switch back. Overall, I’m impressed with the drying ability and durability of Beovu in our patients.”

Novartis has suggested that patients who’ve had previous intraocular inflammation may be at higher risk for developing inflammation after Beovu. For continued use of Beovu, Dr. Garg recommends that surgeons be hesitant to use it in patients with a history of intraocular inflammation, particularly if they’ve had such inflammation after an anti-VEGF injection. “I would also be very hesitant to inject both eyes with Beovu at the same time,” he adds. “If I were to use Beovu in both eyes, I would try to get Beovu from different lots, and I’d definitely stagger the injections by several weeks. In one of the cases with severe inflammation, the patient presented a month after the most recent Beovu shot, but it wasn’t clear to me when the visual loss began. The patient may have experienced visual loss after a week and just showed up after a month.”

Dr. Garg points out that there are likely still some unreported cases of Beovu-associated inflammation that may have seemed like flukes—perhaps a lid infection. “Since the presentation at the Macula Society, doctors have been sharing a few of their cases,” he says. “But we don’t know the exact percentages or the incidence of significant visual loss in some of these patients.”

Nevertheless, Dr. Garg remains hopeful that Novartis and the retina community will get to the bottom of this. “Beovu has great value to our patients,” he says. “The results from HAWK and HARRIER were really encouraging, and we know that there’s a small but reasonable percent of patients who still have activity with our current anti-VEGF drugs. Their lesions continue to leak fluid and ex-

(Continued on page 49)

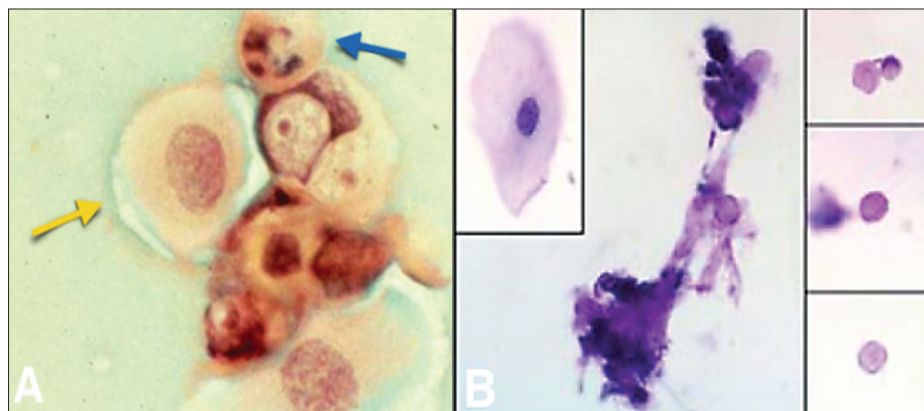


Figure 2. (A) Corneal smear showing *Acanthamoeba* cyst (blue arrow), trophozoite (yellow arrow), and epithelial cells (Papanicolau, x 400). (B) Corneal scraping from contact lens shows *Acanthamoeba* cysts (PAS stain).

microscopic smears and sections because of their resemblance to white blood cells.

An Ounce of Prevention

Given the nearly ubiquitous presence of *Acanthamoeba* in water—whether fresh water, sea water, tap water, bottled water, swimming pools or hot tubs, we always advise patients to remove contact lenses for showering and swimming, especially in fresh water.

There was an *Acanthamoeba* keratitis epidemic in the 1980s after the FDA approved the making of saline solution from salt tablets for contact lens hygiene. Instead of using sterile distilled water, lens wearers would cut corners and just throw in some tap water, with predictably disastrous results. Then as now, poor contact lens hygiene—using home-brewed saline, storing lenses in tap water, rinsing lens cases in tap water—remains a major contributor to corneal infection. And even if proper care methods are observed, the extended wear of contact lenses overnight and use of orthokeratology lenses are additional risk factors.³ Even among non-contact

lens wearers, ocular exposure to contaminated water supplies while swimming, hot tubbing or even aquarium cleaning can result in *Acanthamoeba* infection.

The Great Masquerader

While most microbial keratitis, even among contact lens wearers, remains bacterial, the seemingly straightforward corneal infection that doesn't respond to usual regimens of antibiotics must be suspected for the less common causative organisms, be they fungal, viral and/or protozoal. Hence, although the community standard of care remains treating with a fluoroquinolone antibiotic, usually in the absence of corneal smears and cultures, the recalcitrant cases persisting after perhaps five to seven days of treatment are suspect for the rarer infection sources and even polymicrobial infection. Coinfection with bacteria or herpes simplex virus can occur in 10 to 23 percent of keratitis cases.⁸

In such antibiotic-unresponsive scenarios, and given the confounding effect of antibiotic therapy on establishing a diagnosis, the cases which are referred to

specialized centers must not only be corneal cultured and occasionally biopsied but, importantly, all of the patient's medications and topical eyedrops—especially contact lenses, cases and solutions—should be cultured, given the high probability of revealing the hidden or masquerading organism (Figure 2B).⁷

The typical clinical presentations of *Acanthamoeba* keratitis exhibit one or more of three hallmark features.

In increasing severity, the first is an epithelial pseudodendrite, which can resemble lesions caused by HSV (Figure 3A) or subepithelial infiltrates (Figure 3B). The second is radial keratoneuritis, developing along inflamed corneal nerves in a web-like pattern (Figure 4A). The third and most advanced is the ring infiltrate, resembling a Life Saver candy—a white ring of intrastromal inflammatory cells with a clear center (Figure 4B).

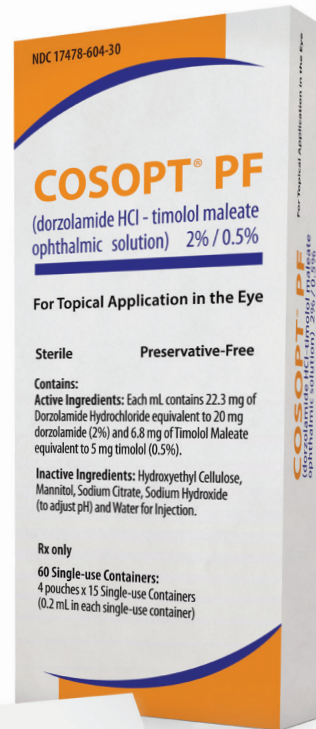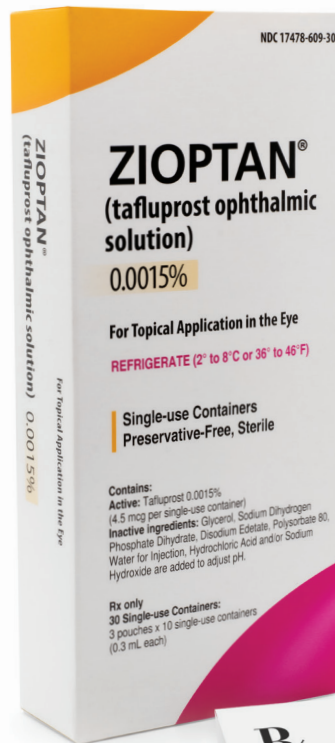As *Acanthamoebae* invade the corneal stroma, they elicit a massive inflammatory response of white blood cells which, in their effort to eradicate the infection, inflict their own collateral damage, resulting in a loss of corneal clarity and enzymatic digestion of corneal tissue (stromal lysis). Moreover, since the inflammatory process involves corneal sensory nerves, it seemingly elicits such excruciating ocular pain that patients often confine themselves to darkened rooms due to extreme photophobia.⁷

Given the resistance of the infection and the chronicity of the inflammatory response, therapy, once it's initiated, is continued until complete microbial eradication is achieved, a process that can

100% PRESERVATIVE FREE


ZIOPTAN[®]
(tafluprost ophthalmic
solution) 0.0015%

ZIOPTAN.com




Cosopt[®] PF
(dorzolamide HCl - timolol maleate
ophthalmic solution) 2% / 0.5%

COSOPTPF.com



 **AKORN**

Cosopt[®] and ZIOPTAN[®] are registered trademarks of Merck Sharp & Dohme Corp and are used under license.
Santen ZIOPTAN[®] is licensed by Santen Pharmaceutical Co., Ltd.
©2020 Akorn, Inc. 1925 West Field Court, Suite 200, Lake Forest, IL 60045
JA009 Rev 01/20

often take months. Even if the infection doesn't extend beyond the cornea to involve the sclera, the inflammatory consequences of limbal stem cell deficiency, cataract, iris atrophy and secondary glaucoma (consequent to PAS) further compromise the ocular surface and anterior segment.

Complex Diagnostics

For all referred infectious keratitis cases, especially those non-responsive to customary antibiotic therapies, it becomes mandatory to go back to square one and perform the full battery of corneal scrapings and cultures, including the customized approach for those suspect for *Acanthamoeba*.⁹

In particular, corneal scrapings must be not only stained with Gram, Giemsa and PAS, but also stained with calcofluor white, acridine orange and immunospecific antibodies, as well as routine PAS.^{3,10} Moreover, cultures require special growth conditions—specifically an *E. coli*-enriched medium, which must be observed for at least one week.

Apart from these traditional microbiological modalities for diagnosis, the confocal microscope offers *in vivo* imaging of the affected cornea at magnification of up to 800x, thereby directly resolving the presence of infectious organisms. This laser microscope is non-invasive and affords rapid diagnosis of *Acanthamoeba* and/or other infections at earlier stages, when treatment is more effective. We're able to see into the depths of the cornea at a very high magnification and obtain microstructural imaging at the cellular level; cysts are characteristically reflective and round, whereas trophozoites exhibit hyperreflective ovoid or irregular

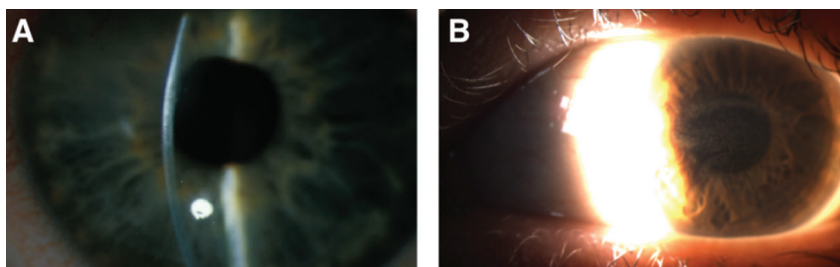


Figure 3. Early *Acanthamoeba* infection showing epithelial pseudodendrites (A) and non-specific subepithelial infiltrates (B).

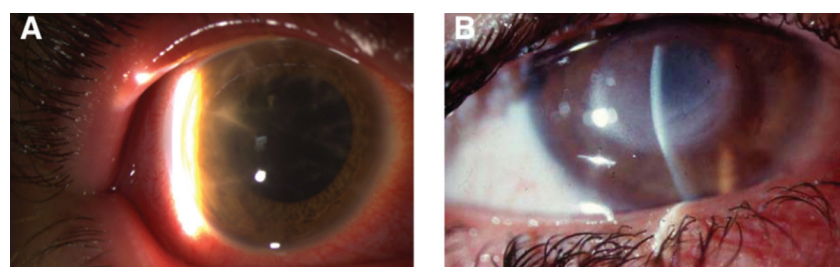


Figure 4. *Acanthamoeba* keratitis with radial keratoneuritis (A) and ring infiltrate (B).

profiles (Figure 6).^{11,12}

Although the microscope's small field of view and high magnification can be misleading and result in a false positive or negative diagnosis,¹³ in experienced hands, it's very helpful for differentiating between the trophozoite and cystic forms and, more importantly, for localizing the depth of their invasion. We can also use it as a monitoring device to track response to therapy, to guide the tapering of medications after symptom resolution and to detect co-infection by other microbes.

Tough Treatment

If *Acanthamoeba* keratitis is difficult to diagnose, it's even tougher to treat. Potentially requiring months to eradicate, *Acanthamoeba* infection is very challenging for both the patient and the clinician. For starters, *Acanthamoeba* doesn't respond to antivirals or most antibiotics. The various classes of amoebicidal

drugs (see Table, page 24), are difficult to obtain (most being non-FDA approved), challenging to formulate and toxic to use, and therefore difficult for patients to tolerate during the long course of treatment.

Of the agents that are useful for killing the trophozoites, there are three groups: 1) topical biguanides, including chlorhexidine 0.02% and polyhexamethylene biguanide (PHMB), which are, in fact, swimming pool cleaners; 2) topical diamidines, of which propamidine or Brolene 0.1% are most commonly used;^{3,14} and 3) various antifungal imidazoles, such as fluconazole, ketoconazole and voriconazole, in both topical and/or oral routes of administration (see Table).³ The diamidines interfere with the amoebae's DNA synthesis but, while they're OTC in Europe, they're not available in the United States. We typically use some cocktail combination of biguanide, diamidine and/or imidazole, depending on clinician



A fully preloaded IOL, designed to deliver without compromise

Comparison of Preloaded IOLs

Company	Rayner	Alcon	Johnson & Johnson
Lens platform	600C	Acrysof IQ	Tecnis1
Injector	RayOne	UltraSert	iTec
Nd:YAG rate	1.7% ¹	7.47% ⁷	3.75% ⁷
Miyata grade (Glistenings)	0 ² (None)	3 ⁸ (High)	0 ¹² (None)
ABBE value	56 ²	37 ⁹	55 ⁹
Refractive index	1.46 ³	1.55 ¹⁰	1.47 ¹²
Mean decentration	0.08 mm ⁴	0.78 mm ¹¹	0.27 mm ¹³
Nozzle diameter	1.65 mm ⁵	2.08 mm ⁵	1.86 mm ⁵
Injector steps	2 ⁶	3 ¹⁰	4 ¹²

Request an evaluation at
evaluations@rayner.com



¹Mathew RG et al. Ophthalmic Surg Lasers Imaging. 2010; 41(6): 651-55, ²Rayner. Data on file. White paper, ³Ferreira T et al. J of Refract Surg. 2019; 35(7): 418-25, ⁴Bhagal-Bhamra GK et al. J of Refract Surg. 2019; 35(1): 48-53, ⁵Nanavaty M et al. J of Refract Surg. 2017; 43(4): 558-63, ⁶www.rayner.com, ⁷Cullin F et al. Acta Ophthalmol. 2014; 92(2): 179-83, ⁸Werner L. J of Refract Surg. 2010; 36(8): 1398-1420, ⁹Zhao H et al. Br J Ophthalmol. 2007; 91(9): 1225-29, ¹⁰www.myalcon.com, ¹¹Humbert G et al. Fr J Ophthalmol. 2013; 36(4): 352-61, ¹²invisionpro.com, ¹³Baumeister M et al. J of Refract Surg. 2009; 35(6): 1006-12

MADE IN UK



Regulatory restrictions may apply in certain markets.
©2019 Rayner Surgical Inc. Unauthorized reproduction prohibited.
‘Rayner’, the RayOne logo and ‘Lock & Roll’ are proprietary marks of Rayner.
All other trade marks are the property of their respective owners. EC 2019-102US 11/19



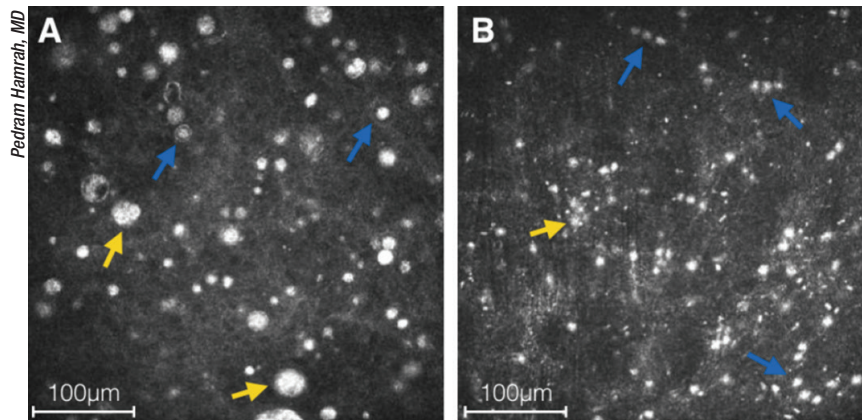


Figure 5. *In vivo* confocal microscopy of *Acanthamoeba* infection at the epithelial level (A) and the stromal depth (B) of the cornea; examples of clusters of cysts are marked by blue arrows, trophozoites by yellow arrows.

preference, drug availability and patient tolerance.

In contrast, *Acanthamoeba* cysts are essentially “bulletproof,” remaining impervious to amoebicidal drugs. The somewhat controversial treatment strategy of using topical steroids is beneficial for preventing the drug-susceptible trophozoites from conversion to drug-resistant cysts. However, the steroid balancing act is delicate, since the trophozoites also remain reproductive and steroids will suppress the immune and inflammatory responses, possibly facilitating additional stromal ulceration. Here again, the confocal microscope is extremely valuable for determining the state of the amoebic organisms’ concentration and viability, and for assessing their activity.

Play to Win

Acanthamoeba keratitis usually presents unilaterally with both the trophozoite and cystic forms present, and as soon as it’s diagnosed it must be treated very aggressively, according to the previously specified regimen. Even a mild, superficial infection can

progress rapidly, and the deeper into the cornea the amoebae invade, the more inaccessible they become to poorly penetrating topical drugs. Since trophozoites replicate quickly, it’s important to apply drugs hourly around-the-clock for at least the first 48 hours. Nighttime drug administration can then be reduced, while daytime drops remain hourly. Based on the therapeutic response, and as the infection subsides, the medication frequency can be slowly tapered to perhaps four times a day, which often must be maintained for several months.³

The goal of treatment is to kill all trophozoites and cysts, as evidenced by clinical and confocal microscopic improvement. As previously discussed, judicious use of topical steroids may be beneficial both to lure trophozoites out of encystment and to control the chronic inflammatory process. Meanwhile, be sure to constantly manage ocular surface drug toxicity and allergy, neurotrophic persistent epithelial defects, and intraocular pressure as the inflammation subsides.

Another therapeutic strategy of potential, but equivocal, benefit

is corneal cross-linking (CXL), utilizing much the same techniques that have been developed for keratoconus stabilization. Presumably the ultraviolet light exposure of CXL is effective for killing organisms located relatively superficially, but with less efficacy for deeper-penetrated amoebae.^{7,9} As results remain somewhat inconsistent, however, further investigation is required to refine the CXL technique for this use.

Surgical interventions may be required during active therapy, ranging from corneal debridement of non-viable tissue to aid drug penetration, to amniotic membrane disc or graft application to reduce inflammation and promote epithelial recovery, to therapeutic keratoplasty for anatomical restoration of extremely thinned or perforated corneas. The latter also reduces the intrastromal microorganism load and prevents extension infection to the limbus and sclera, whereupon it becomes nearly impossible to eradicate. Emergent glaucoma surgery and extraction of intumescent cataract may also be required.

Following eradication of active infection, anatomical and visual rehabilitation might require limbal autograft transplantation to restore the damaged limbal stem cell population; medical treatment of neurotrophic keratopathy with nerve growth factor (Oxervate, Dompé); definitive cataract, glaucoma and/or anterior segment reconstructive surgery; and, once all associated issues have been resolved, penetrating keratoplasty to replace the scarred cornea.

After all is said and done, the visual prognosis for most medically treated patients is on the order of 20/100. For eyes requiring penetrating keratoplasty, the risk factors of chronic inflammation,

DID YOU KNOW?

KEELER

has slit lamps!

For over 100 years, we have been creating innovative products. The Keeler slit lamp is one of them – designed with you and your patients in mind. The KSL delivers a visually pleasing, customizable device equipped with excellent, high-quality optics.

SLIT LAMP FEATURES



Sharp & clear
Keeler Optics



KSL-H series:
tower illumination



KSL-Z series:
lower illumination



Digital-ready
& full digital units



3x magnification
drum (10x, 16x, 25x)



5x magnification
drum (6x, 10x, 16x,
25x, 40x)



Unique 1mm
square for Uveitis
evaluation



Bright & white
LED illumination



We also carry
portable slit lamps!

VISIT OUR WEBSITE FOR MORE PRODUCT DETAILS

www.keelerusa.com / 800-523-5620

Keeler

Anti-amoebic Medications

Agent	Trade Name	Manufacturer	Topical Concentration
Cationic antiseptics			
Chlorhexidine			0.02%
Polyhexamethylene biguanide	Baquacil	Zeneca	0.02%
Aromatic diamidines			
Propamide isethionate	Brolene	Mays & Baker	0.1%
Azoles			
Clotrimazole	Lotrimin	Schering	1%
Fluconazole	Diflucan	Roerig	0.2%
Ketoconazole	Nizoral	Janssen	5% (or 200 mg oral)
Aminoglycosides			
Neomycin	Neosporin	generic	10 ml/3.5 g (ointment)

stromal neovascularization, limbal deficiency, glaucoma and prior keratoplasty all affect the prognosis, but overall keratoplasty survival is approximately 50 percent. Among successful grafts, there's a 50-percent chance of attaining 20/40 vision.¹⁵ As with other high-risk keratoplasties, management of immune rejection, ocular surface issues and intraocular pressure continues indefinitely.^{7,9}

Parting Pearls

Following are some tips for particular aspects of managing *Acanthamoeba*:

- **An ounce of prevention...** As primary vision providers, educate contact lens wearers about the perils of poor lens hygiene, extended and over-extended contact lens wear and ocular water exposure while wearing contacts.
- **Red-flag alert.** Just as any acute contact-lens-related keratitis should be considered to be *Pseudomonas* until proven otherwise, any CL-related keratitis unresponsive to one week of conventional and/or fortified topical antibiotic therapy should be considered to be *Acanthamoeba*, fungal and/or viral

and must undergo more rigorous diagnostic culture and imaging studies to verify an exact etiologic diagnosis. Above all, don't delay by playing polypharmacy roulette: Referral for an appropriate evaluation and management should be on a "run, don't walk" basis, since any delay vastly prolongs and worsens the prognosis.

- **Confirm etiology.** As the *Acanthamoeba* therapy train rolls on forever, specific confirmation of diagnosis by culture, imaging and/or biopsy is mandatory. Remember: *Acanthamoeba*, fungus and even viral infections can produce clinically similar keratitis, so there is seldom justification for continuing empirical "shotgun therapy." Once diagnostically confirmed, therapy has to be "all-in": aggressive, with multiple agents, intensive topical application and recognition of potential medication toxicity, given the months of therapy required for *Acanthamoeba* eradication.

• **"It ain't over 'til it's over."**

Finally, given the long-term course of medical therapy plus the associated aspects of ocular surface and other anterior segment sequelae, the commitment of both clinicians and patients becomes a "BFF" (best friend forever) relationship, recognizing that following eradication of the infection, the subsequent medical and surgical management requires equally committed and vigilant commitment.

In conclusion, *Acanthamoeba* keratitis, particularly among highly at-risk contact lens wearers, remains the most difficult of corneal infections to diagnose and treat. Maintaining a high level of suspicion for *Acanthamoeba* as the potential etiology for recalcitrant keratitis cases, referral for diagnostic studies and aggressive pharmacologic management are mandatory to save such eyes from devastating visual loss. Although medical therapy is intense, toxic and seemingly interminable, medical cures are nonetheless attainable. If the "collateral

(Continued on page 73)

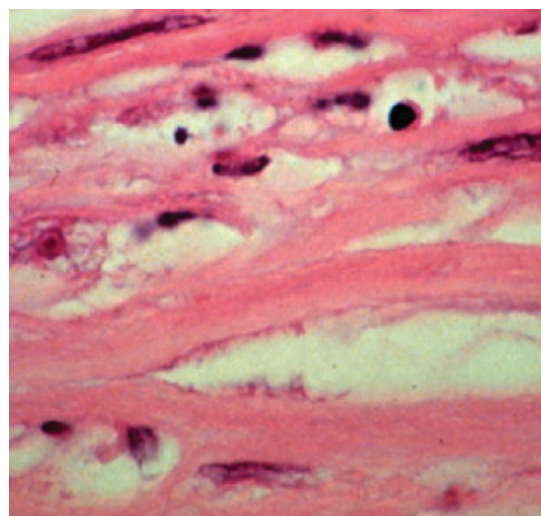


Figure 6. Light microscopic view of a corneal section demonstrating *Acanthamoeba* cysts.

WORKING TO EMPOWER A NEW ERA OF GLAUCOMA SURGICAL DEVICE INNOVATION

We're dedicated to advancing proactive glaucoma surgery by working toward more predictable and sustainable outcomes



PREDICTABILITY

- A minimally invasive device would help mitigate trauma and expedite recovery¹
- Subconjunctival drainage is a proven method to achieve target IOP²



SUSTAINABILITY

- Device design could help maximize outflow while minimizing hypotony^{3,4}
- Biocompatible material that resists degradation could help deliver more-sustainable benefits³



Hear from your peers and register for more information at
AdvancingGlaucomaSurgery.com

References: 1. Chan JE, Netland PA. EX-PRESS Glaucoma Filtration Device: efficacy, safety, and predictability. *Med Devices (Auckl)*. 2015;8:381-388. 2. Lee RMH, Bouremel Y, Eames I, Brocchini S, Kaw PT. The implications of an ab interno versus ab externo surgical approach on outflow resistance of a subconjunctival drainage device for intraocular pressure control. *Transl Vis Sci Technol*. 2019;8(3):58. 3. Amoozgar B, Wei X, Lee JH, et al. A novel flexible microfluidic meshwork to reduce fibrosis in glaucoma surgery. *PLoS One*. 2017;12(3):e0172556. 4. Agrawal P, Bradshaw SE. Systematic literature review of clinical and economic outcomes of micro-invasive glaucoma surgery (MIGS) in primary open-angle glaucoma. *Ophthalmol Ther*. 2018;7(1):49-73.

© 2019 Santen Inc. All rights reserved. PP-GLAU-US-0037



3-D Heads-up Displays & the Anterior Segment

Proponents say this technology is becoming more viable as a tool for surgeons working at the front of the eye.

Christopher Kent, Senior Editor

Large-screen, “heads-up” 3-D displays for ophthalmic surgery are not a new idea, but this technology initially had some limitations that led many anterior segment surgeons to avoid it. Because many of the drawbacks that were deal-breakers for anterior segment surgeons didn’t apply as much to retinal surgery, some retinal surgeons adopted the technology. Now, proponents say the technology has evolved, and most of those problems have been minimized or eliminated. As a consequence, some anterior segment surgeons are giving this technology a second look.

Here, surgeons discuss their experience using this type of display, explain how it’s changed, and offer some thoughts about why the digital basis of this tech might allow it to help surgeons in novel ways.

An Optical Upgrade

Steve Charles, MD, FACS, FICS, founder of the Charles Retina Institute in Memphis Tennessee, and one of the world’s leading vitreoretinal surgeons, says he’s used Alcon’s Ngenuity system for all of his cases since

it was introduced to the market. (Sony and Zeiss also make heads-up 3-D viewing systems; Sony’s is made in partnership with Haag-Streit.)

Dr. Charles notes that early versions of this technology had some significant image latency. “The onscreen visual was noticeably delayed relative to the surgeon’s movements,” he says. “Today the image quality is significantly better; the dynamic range has increased and the latency has been completely eliminated. As a result, interest among both retinal and anterior segment surgeons has increased.”

Rom Kandavel, MD, a partner at the Colvard-Kandavel Eye Center in Encino, California, and volunteer clinical professor at Jules Stein Eye Institute in Los Angeles, recently got his first chance to try using a 3-D heads-up display to perform anterior segment surgery. “At first this technology was presented as a way to improve the ergonomics of surgery,” he says. “That’s a legitimate point. But once I got to try it, I was most impressed by how much better the view is, in almost every way.”

Surgeons note several specific things about the optics that they say

are better than a traditional surgical microscope:

- **Significantly better depth-of-field.** “Not only do you get great clarity, but you get it at almost every focal distance,” says Dr. Kandavel. “You can be in focus at the posterior capsule, the anterior capsule and the endothelium all at the same time. The surgeon can accommodate through those levels, and they’re all in very good focus.”

He points out that the optics of a traditional microscope limit the depth-of-field. “The interpupillary distance and the working distance result in limited stereopsis,” he explains. “It’s a fraction of the stereopsis you get looking at a 55-inch OLED screen from a distance of four feet. With this new technology you can see minute differences in anterior and posterior locations. That’s really important for the everyday cataract surgeon, and it’s also important for residents; it lets them accurately gauge depth while grooving the nucleus, and it helps them detect the posterior capsule once they begin removing pieces.” Dr. Charles agrees, noting that the Ngenuity’s stereo pair of single-chip



SPEED, EASE, AND ACCURACY. IT'S ALL IN THE PLAN.

Introducing the ARGOS[®] Biomater with Image Guidance by Alcon[®]

An advanced comprehensive planning solution that delivers improved diagnostic precision and a more efficient clinical workflow. The ARGOS[®] Biomater combines speed, ease, and accuracy—seamlessly integrating best-in-class features that can provide better outcomes for your patients. Now that's great planning.

Alcon

© 2019 Alcon Inc. 12/19 US-ARB-1900018

ARGOS[®]
with Image Guidance by ALCON[®]



Vision Planner

IMPORTANT PRODUCT INFORMATION

ARGOS® Optical Biometer

Caution: Federal (USA) law restricts this device to the sale by or on the order of a physician.

Indications: ARGOS® is a non-invasive, non-contact biometer based on swept-source optical coherence tomography (SS-OCT). The device is intended to acquire ocular measurements as well as perform calculations to determine the appropriate intraocular lens (IOL) power and type for implantation during intraocular lens placement.

Intended Use: The Reference Image functionality is intended for use as a preoperative and postoperative image capture tool. It is intended for use by ophthalmologists, physicians, and other eye-care professionals and may only be used under the supervision of a physician.

Warnings and Precautions:

- Only properly trained personnel with experience may operate the device and control software and interpret the results.
- Factors that influence the measurement of patient's eyes are listed in the User Manual (Table 1): pseudophakic eye, wearing contact lenses, fixation problem, cornea opacity, non-intact cornea, refractive surgery, blood in the vitreous humor, retinal detachment, keratoconus, asteroid , ambient light in the room, and deformation of the corneal shape. Please consider the guidance provided in Table 1 when you encounter these factors.
- Optical Radiation - This device is equipped with a Class 1 laser light source.

ATTENTION: Refer to the ARGOS® User Manual for a complete description of proper use and maintenance, optical and technical specifications, as well as a complete list of warnings and precautions.

ARGOS® |  Vision Planner
with Image Guidance by ALCON

Alcon

© 2019 Alcon Inc. 12/19 US-ARB-1900018

REVIEW | Technology Update

cameras provide a depth-of-field 4.5 times greater than what a conventional optical operating microscope provides.

Mike Colvard, MD, FACS, director of the aforementioned Colvard-Kandavel Eye Center, and a clinical professor of ophthalmology at the University of California Los Angeles School of Medicine, recently had his first chance to observe this technology being used for anterior segment surgery. “The depth-of-field was astounding,” he reports. “You’re able to look at the cornea, the anterior chamber, the anterior surface of the lens and the posterior aspect of the lens, all at the same time.”

Dr. Kandavel believes retina specialists initially adopted this technology more readily than anterior segment surgeons because of that increased depth-of-field. “It’s particularly helpful for macular hole repair,” he notes. “The digital processing of the image also allows the highlighting of certain structures, which is helpful when peeling membranes, so it caught on in retina first. Nevertheless, the current version of this technology holds a lot of promise for anterior segment surgery.”

• **Very high magnification with no loss of clarity.** “With typical microscopes, when you start cranking up the magnification, you often lose some clarity and depth-of-field,” Dr. Colvard points out. “You don’t with this technology. When you increase the magnification, you keep the depth-of-field and the clarity.”

Dr. Charles agrees, noting that this is part of the purpose of the large display. “However, when using this system at high magnification, being at the correct viewing distance is crucial,” he points out. “The 55-inch OLED display should be positioned four feet from the surgeon. If you use a smaller display placed closer to the surgeon, the result is vergence-accommodation conflict. Also, the

surgeon should wear glasses that have a full distance correction +0.5 D, to optimize the perceived image.”

Dr. Kandavel notes that the improved resolution at high magnification is particularly useful when performing many MIGS procedures. “If you zoom in on the trabecular meshwork, the resolution and focus is excellent,” he says. “You need that visual clarity to work effectively in that space.”

• **Clarity out to the edge of the image.** “When viewing through a conventional operating microscope, the resolution decreases—and aberrations increase—the further you look from the viewing axis,” notes Dr. Charles. “In contrast, with this technology the cameras are matched to the point-spread function of the optical system. That makes the image resolution for the surgeon just as good at the periphery of the image as it is in the center.”

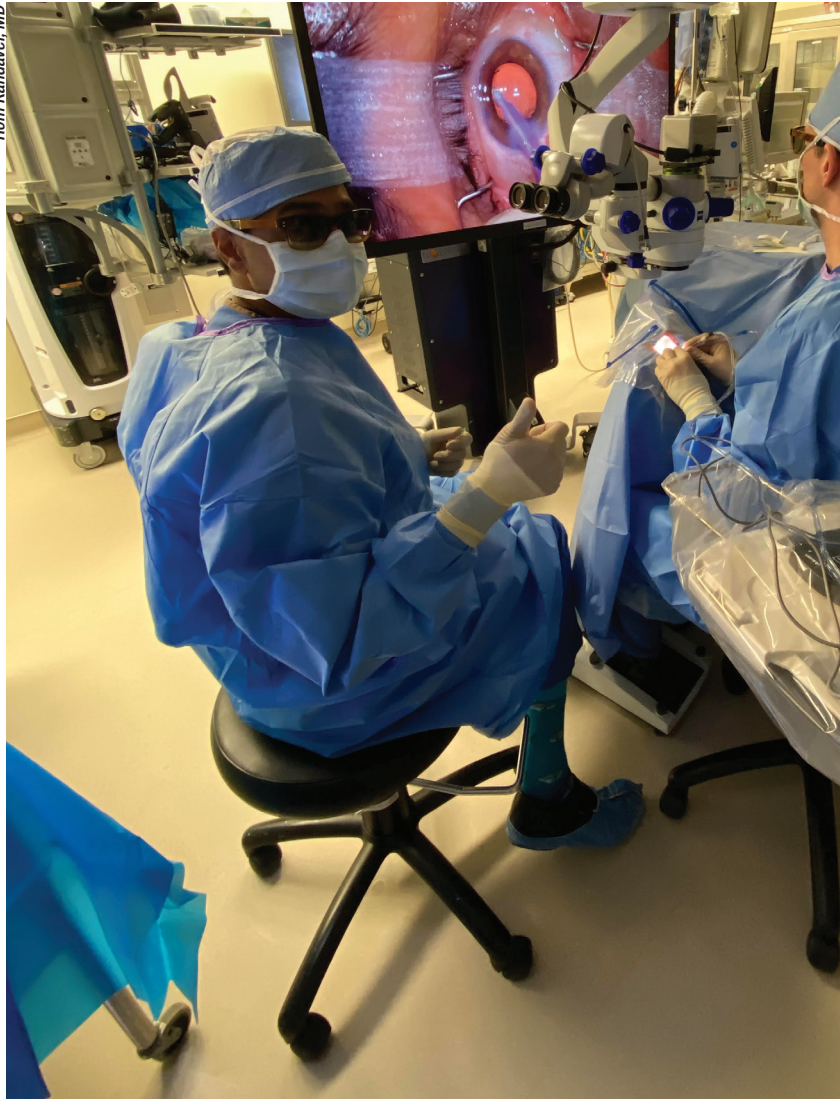• **Less phototoxicity.** “Because the image is digital, the microscope can be at much lower illumination while the screen displays the image at a higher level of brightness,” Dr. Kandavel points out. “That’s not too important for short cataract cases, but it certainly makes a difference in retina cases and longer anterior segment cases.”

• **Individual structures can be digitally enhanced.** Dr. Kandavel notes that this is another advantage that comes from working with a digital image. “The image can be digitally processed to enhance the contrast or brightness of any structure you choose,” he says.

Non-optical Advantages

The fact that the image appears on a large screen may bring other benefits to this technology as well:

• **Better ergonomics for the surgeon.** Dr. Kandavel says this is a serious advantage that shouldn’t



Proponents say that today's heads-up 3-D displays have resolved many early technical problems, such as reducing the time lag between the surgeon's motions and the onscreen image. However, using the technology for anterior segment surgery raises other practical concerns, such as whether to move the screen from one side of the bed to the other when operating on left vs. right eyes, or have the surgeon turn his or her head to look at a fixed-location screen.

be overlooked. "Multiple surgeons working in our surgery center have had surgery on their cervical spine because of the strain placed on their backs during surgery," he notes. "This system can help keep that from happening, especially over many years of performing surgery. You can essentially sit in whatever position you desire and still have a really good view. Physicians always put the patient first;

this is a technology that will help the physician."

He adds that this ergonomic change can be especially helpful when performing some MIGS procedures. "Right now when performing MIGS procedures we generally have to tilt the patient's head and put on a gonioscope in order to achieve the right angle to see the trabecular meshwork," he says. "When I use the Ngenuity

system, I put the gonioscope on and tilt the scope, but I don't have to tilt it as much, and it doesn't affect my head position because I'm just looking at a screen."

- **The surgeon can interact with the surroundings.** Dr. Kandavel says this consequence of the heads-up display caught him by surprise. "I underestimated how much more interactive it makes you with your operating room," he says. "With a microscope, your peripheral vision is almost completely taken up by the oculars. With the heads-up display, you can see your scrub tech, anesthesiologist, even the patient's body, all while you're looking at the screen. The whole room is within your visual grasp."

- **Additional information can be added to the screen.** "For example, you can do a split screen with the ORA aberrometer," says Dr. Kandavel. "Or, you can put all of your phaco parameters on the screen, so you can monitor your vacuum, aspiration and energy while performing the surgery. Then you don't have to turn your head to look at another screen."

- **It has a short learning curve.** "I was surprised how quickly people take to the technology, even young surgeons," says Dr. Colvard. "I watched third-year residents using this technology for the first time at the VA hospital; they had no trouble performing beautifully. So it's something that people can adapt to very quickly. They weren't struggling at all. Also, everybody in the room has the same view that the surgeon has—and in 3-D."

Drawbacks

Dr. Kandavel points out a few disadvantages that come with switching to this viewing system. Most of them have to do with managing a large screen in the operating room.

"A retina surgeon operates at the top of the bed, so the screen can be


put at the patient's feet," he says. "As a result, both the screen and the retina surgeon are in the same position for each case. In contrast, anterior segment surgeons operate left and right, so in order to keep the same view you have to move the screen from one side of the patient to the other—at least in theory. In terms of room turnover and efficiency, that could potentially slow you down.

"However, there are a couple of ways around that," he continues. "You could schedule all left-eye surgeries in a row, then all right eyes. In that scenario you'd only have to move the screen once, or perhaps a few times a day. It's also possible to operate with your hands in front of you while looking to your left or right; that way the screen can remain at the patient's feet, or at the top of the bed. I had some success doing that, but it can be challenging.

"There's an optimal viewing angle, meaning that you want to be right in front of the screen," he explains. "Some ovalization of the image and distortion occurs if you're at a very oblique angle to the screen. This sometimes becomes an issue with an attending resident, because the resident will have the optimal view. The assisting surgeon is accustomed to sitting to the right or left of the resident at the apex of the patient's head, but with this technology, you want to be located behind your resident so you have the same view the resident has. Otherwise, you're looking at the screen obliquely, and you may not have the same depth perception they have. That can make it harder to help the resident during surgery."

In regards to the time lag between the surgeon's movements and the visual on the screen that initially discouraged many surgeons from adopting this technology, Dr. Kandavel says the time lag has been greatly reduced. "It's perceptible, but just barely," he says. "In reality, we don't generally

move at fast enough speeds to make it an issue. Also, after a few cases, you neuroadapt to the slight delay and get used to it. I've done multiple cases in a row and had no problem at all."


"Other even more sophisticated advances should be possible ... because the system is working with a digital signal. Right now we're just scratching the surface."
 — Rom Kandavel, MD

There's also the issue of cost; this technology can cost a practice in the range of \$90,000. Surgeons may be reluctant to lay out money for a new viewing system when they feel that their microscopes are already doing a fine job. However, Dr. Kandavel argues that a surgeon can make the numbers work if he or she is in the market for a new microscope.

"Regarding the cost, it appears to be similar to upgrading to a newer microscope," he says. "In my mind, just getting a newer microscope is an incremental improvement, and it costs about the same as moving to this entirely different way of seeing the surgical field. With this system you're getting so much more. Instead of making a small step forward, you're making a giant leap." (Dr. Kandavel acknowledges that the cost will vary depending on which 3-D system you choose to purchase.)

What Lies Ahead

Dr. Kandavel sees the potential for

a number of useful future developments. "For instance, because it's a digital system, you can 'lock onto' structures such as the limbus or the iris," he says. "You wouldn't need a microscope pedal because the instrument would automatically remain focused on the area of your choice, regardless of patient movement. It would stay in the center of your field of vision at all times.

"Other even more sophisticated advances should be possible," he continues. "At some point the software may be able to identify the density of an individual cataract piece in the anterior chamber in real time, based on how the light is passing through it. Then, it could interface with the phaco unit and modulate your energy, vacuum and aspiration accordingly. It could reduce surge and phaco power, all automatically. Or, it could alert you when you're getting very close to the posterior capsule. And, if the posterior capsule was suddenly sucked up to the aspiration tip—God forbid—the software would immediately release it, faster than a human being could respond. All of this is possible because the system is working with a digital signal. Right now we're just scratching the surface."

Dr. Colvard agrees. "One of the old surgical adages is: You can only fix what you can see," he says. "The joke was, if the doctor can't see very well, chances are the patient won't see very well either.

"Being able to see clearly—with great depth-of-field—is a tremendous asset," he adds. "That's particularly true with a procedure like capsulorhexis, and especially for a young surgeon." **REVIEW**

Dr Charles is consultant for Alcon but receives no compensation relating to this product. Drs. Colvard and Kandavel report no financial ties to any company or device discussed in this article.



WORKING TOGETHER to relieve dry eyes

Clinically proven to reduce the signs and symptoms of dry eyes¹

47%
improvement
in symptoms

20%
improvement
in tear breakup time

67%
reduction
in number of
glands blocked

40%
improvement
in meibum quality

Critical **first steps** to treating dry eye symptoms include ocular lubricants, lid hygiene and dietary modifications such as oral fatty acid supplementation.²
-2017 DEWS II Report



RESTORES



CLEANSSES



NOURISHES

More than eye drops,
dry eye therapy™



theratears.com/professionals



References: 1. Ngo W, Srinivasan S, Houtman D, Jones L. The relief of dry eye signs and symptoms using a combination of lubricants, lid hygiene and ocular nutraceuticals. *J Optom.* 2017 Jan-Mar;10(1):26-33. 2. Jones L, Downie L, Korb D, et al. TFOS DEWS II Management and Therapy Report. *Ocul Surg.* Jul 2017;15:575-628.
© 2020 Akorn Consumer Health | A Division of Akorn, Inc. | M16-040-01

Biometry and Formulas: Nailing the Outcome

Christopher Kent, Senior Editor

Our ability to measure the eye accurately and calculate the IOL power keeps evolving—but there's still room for improvement.

Today's technology for measuring the eye and formulas for determining IOL power before cataract surgery are far beyond anything available to surgeons 20 years ago. Nevertheless, results for many cataract surgery patients still fall outside the range of desirable outcomes. Here, experts share their experience and advice for making the most of biometry and formulas to improve your patients' postop vision.

A Bevy of Biometers

Today, clinicians and researchers have numerous biometers available to them. Kenneth J. Hoffer, MD, FACS, a clinical professor of ophthalmology at the Jules Stein Eye Institute, University of California, Los Angeles, notes that he's worked with every optical biometer since the first IOLMaster became available in 1999. "That includes the original IOLMaster from Zeiss, now referred to as the IOLMaster 500; Haag-Streit's Lenstar; the Aladdin from Topcon EU; Nidek's AL-Scan; Zeimer's Galilei G6; Tomey's OA-2000; the Pentacam AXL from Oculus; Movu's Argos (now owned by Alcon); the IOLMaster 700 from Zeiss; and two that aren't available yet: Heidelberg's Artemis and Haag-Streit's Eyestar 900," he says.

"We're currently doing a comparative study of the Artemis, and we should have those results soon.

"All of these instruments do a good job, although there are a few differences between them," he continues. "The competition in the field is probably a good thing. Zeiss, for example, might never have created the IOLMaster 700, moving from partial-coherence interferometry to swept-source OCT, if all of those other instruments hadn't forced them to up their game. I do think offering swept-source OCT is an advantage; that's now part of the IOLMaster 700, the Argos and the OA-2000, and it will be part of the Eyestar 900 and the Artemis. But any of these optical biometers will give you an accurate axial length measurement."

Of course, getting an accurate measurement depends on more than just technology; the person taking the measurement has to know how to avoid potential pitfalls. Douglas D. Koch, MD, professor and chair of ophthalmology at Baylor's Cullen Eye Institute in Houston, says the two biggest mistakes surgeons make are not verifying the quality of their data and not getting a separate measurement to verify its consistency. "The most significant errors made by optical biometry today involve measuring corneal power—in other words,

the steep and flat meridians,” he notes. “Fortunately, the new biometers all give you a way to verify the quality of those corneal power readings. For example, you can look at the reflections of the LED mires on the cornea. Depending on how you set up the machine, they can even be printed out. Or, you can use the standard deviation of measurement as a guide. Warren Hill, MD, looked at data from the Lenstar; he concluded that a corneal power standard deviation greater than about 0.3 D is a red flag. Likewise, a meridional standard deviation of 3.5 degrees or more is also a red flag.”

Dr. Koch points out that the IOLMaster 700 lets you look at a macular OCT scan to confirm that the measurement was taken correctly. (See example, above.) “The macular OCT scan lets you know if the patient was fixating adequately,” he explains. “You should see the umbo or the foveal pit clearly in the center of the OCT. If you don’t see a foveal pit, that means that either an epiretinal membrane or some other pathology is present, or the patient was not fixating correctly. That finding should lead to further investigation.”

Taking a Second Reading

Dr. Koch says that validating the biometry with a second reading is very important—especially if you’re considering a toric IOL. “Biometry can be wrong,” he points out. “I recall one case in which I took a Lenstar reading on a patient; it was about 43.3 D. The IOLMaster 700 gave us no readings at all for this patient, with obvious mire distortion on the printout. I went back and looked at a measurement I’d gotten with the Galilei when the same patient initially presented three months earlier. That measurement was 44.4 D—more than a diopter of

OD right		Analyze	
Eye status			
LS: Phakic	VS: Vitreous body	LVC: Untreated	
Ref: ---	VAK: ---		
Biometric values			
AL: 24.87 mm	SD: 8 µm	WTW: 12.5 mm	lx: +0.5 mm ly: +0.1 mm
CCT: 534 µm	SD: 4 µm	P: 4.7 mm	CW-Chord: 0.1 mm @ 129°
ACD: 4.45 mm	SD: 14 µm		
LT: 3.80 mm	SD: 15 µm		
SE: 43.27 D	SD: 0.02 D	TSE: 43.43 D	SD: 0.01 D
K1: 42.83 D @ 179°	SD: 0.03 D	TK1: 43.09 D @ 173°	SD: 0.02 D
K2: 43.73 D @ 89°	SD: 0.02 D	TK2: 43.78 D @ 83°	SD: 0.03 D
AK: +0.90 D @ 89°		ΔTK: +0.69 D @ 83°	
B scan			

When using the IOLMaster 700, it's essential to review the swept-source OCT image (lower right corner, above) prior to interpreting the measurements. The image should center on and be perpendicular to the foveal depression.

disagreement, and with very different astigmatism measurements.

“Upon more careful examination, I found dry spots on the cornea that were present during the Lenstar and IOLMaster measurements,” he continues. “So, I treated the dry eye. When I repeated the Lenstar and IOLMaster measurements, they matched the Galilei measurement. The moral of the story is that validating your biometry with a second reading from another instrument can improve the quality and consistency of your measurements and avoid some poor outcomes.”

“If you don’t have a second device, you can at least measure the patient with the same device twice,” he adds. “Ideally, you should measure the patient on two different occasions, perhaps when the patient first presents, then on the preoperative visit. If you have to work with only one visit, get a measurement, have the patient sit back and blink, then get another.”

Surendra Basti, MD, a professor of ophthalmology and director of the cataract service at Northwestern University’s Feinberg School of Medicine, in Chicago, points out that it’s not practical to recommend that regular

surgeons take multiple measurements of most patients. “There will always be surgeons who have access to a lot of devices, but those surgeons are few,” he says. “We need to focus on what’s practical. All surgeons have a biometry device, and almost all surgeons have a topography device. If you use those—along with immersion biometry in special cases—you should be fine.”

Of course, optical biometry may not work for every patient. “If the cataract is very dense, optical biometry may not be able to provide an accurate measurement,” notes Warren E. Hill, MD, FACS, medical director of East Valley Ophthalmology

in Mesa, Arizona, who specializes in challenging intraocular lens power calculations and unusual anterior segment surgery. “In this case, immersion ultrasound is performed. If the patient is also a high-to-extreme axial myope with a posterior staphyloma, then an immersion vector A- and B-scan is required. This is a more sophisticated form of immersion biometry that measures the refractive axial length rather than the anatomic axial length.”

The Formula Factor

Perhaps the more daunting hurdle when aiming for an ideal outcome is plugging the biometric and refractive data into the most effective IOL power formula. When deciding which formula to use, a number of questions arise: Should you compare the results of multiple formulas? Should you use different formulas if the axial length is unusually long or short? And how should your choice be modified if your patient has had prior refractive surgery?

Dr. Koch says he still plugs the numbers into multiple formulas and compares the results. “I like to use the Holladay I, Holladay II, Barrett Uni-

Surendra Basti, MD

Reichert
TECHNOLOGIES

Left
IOPcc 14.9
CH 12.3
IOPg 16.7
WS 8.4



MEASURE BEYOND PRESSURE WITH CORNEAL HYSTERESIS & GET A BETTER PRESSURE MEASUREMENT WITH IOPcc.

Only **Ocular Response Analyzer® G3** measures **Corneal Hysteresis (CH)** and **Corneal Compensated IOP (IOPcc)** using patented technology to assess corneal biomechanical properties.

Corneal Hysteresis has shown to be an independent risk factor and more predictive of glaucoma development and progression than CCT or IOP.¹⁻³

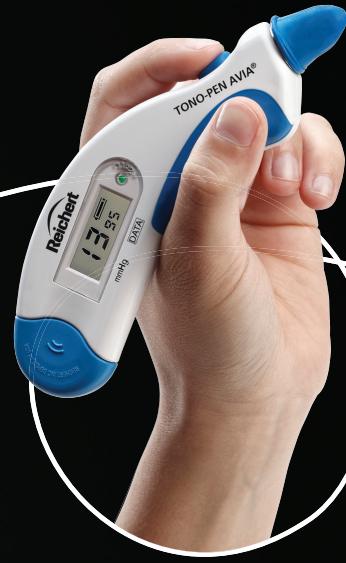Using biomechanics, IOPcc is less influenced by corneal properties than Goldmann applanation tonometry.⁴

NEW!



THE NEW SHAPE OF IOP WITH CATS™ TONOMETER PRISM.

Your Goldmann, **better** pressure. The patented **CATS™ Tonometer Prism*** has been shown in studies to significantly improve Goldmann IOP measurement accuracy.⁵



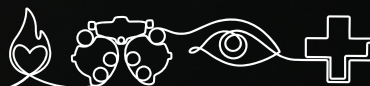MEASURE QUICKLY AND CONFIDENTLY WITH TONO-PEN AVIA® TONOMETER.

The most trusted handheld tonometer just got **better**. **Tono-Pen AVIA®** featuring **Quick-Tap®** Measurement Mode, now have more confidence with fewer measurements.

FROM BETTER TO BEYOND.

We share your passion for improving glaucoma care by innovating better tonometry solutions and measuring beyond pressure with Corneal Hysteresis.

PASSIONATEABOUTEYECARE.COM/GLAUCOMA



Passionate About Eye Care!



© 2020 AMETEK, Inc. & Reichert, Inc. (04-2020) · Ocular Response Analyzer, Tono-Pen AVIA, and Quick-Tap are registered trademarks of Reichert, Inc. · Designed & assembled in USA · **References:** 1. Medeiros FA, Meira-Freitas D, Lisboa R, Kuang TM, Zangwill LM, Weinreb RN. Corneal hysteresis as a risk factor for glaucoma progression: a prospective longitudinal study. *Ophthalmology*. 2013 Aug;120(8):1533-40. 2. De Moraes CV, Hill V, Tello C, Liebmann JM, Ritch R. Lower corneal hysteresis is associated with more rapid glaucomatous visual field progression. *J Glaucoma*. 2012 Apr-May;21(4):209-13. 3. Susanna CN, Diniz-Filho A, Daga FB, Susanna BN, Zhu F, Ogata NG, Medeiros FA. Am J Ophthalmol. A Prospective Longitudinal Study to Investigate Corneal Hysteresis as a Risk Factor for Predicting Development of Glaucoma. 2018 Mar;187:148-152. doi: 10.1016/j.ajo.2017.12.018. 4. Felipe A, Medeiros, MD and Robert N. Weinreb, MD. Evaluation of the Influence of Corneal Biomechanical Properties on Intraocular Pressure Measurements Using the Ocular Response Analyzer. *J Glaucoma* 2006;15:364-370. 5. Goldmann and error correcting tonometry prisms compared to intracameral pressure. McCafferty S, Levine J, Schwiegerling J, Enikov ET. *BMC Ophthalmol*. 2018 Jan 4;18(1):2. *CATS™ Tonometer Prism is distributed by Reichert Technologies · CATS is a trademark of CATS Tonometer, LLC · CATS logo is a registered trademark of CATS Tonometer, LLC.

versal II and the Hill RBF for my cataract patients,” he says. “Sometimes just seeing variability between the formulas’ results tells you that there may be something unusual about the biometry—a shallow anterior chamber, or a thick or thin lens, for example. If nothing else, you can tell the patient that you’ve run the calculations with four of the best formulas, and they’re not in total agreement. If that only helps in terms of educating the patient, that’s still a real benefit.”

“We know that traditional formulas tend to leave long eyes hyperopic,” says Dr. Koch. “That’s why Li Wang, MD, and I developed the Wang-Koch axial length modification to use with the Holladay I formula. You can also get good results in long eyes using the Barrett Universal II and the Hill RBF 2.0 formulas. Short eyes, under 22 mm, remain a challenge. We reported that the best formulas only gave us a little more than 70 percent of these eyes within a half diopter.¹ Interestingly, the best two formulas we found in that paper were the Holladay I and Holladay II. But short eyes remain a problem that we really haven’t solved. You just have to use your best formulas and make your best guess. And in this situation, make sure the patient understands that the calculations may be inaccurate and he or she may be left with a refractive error, despite your doing your best.”

Dr. Hill says his preference is to use both the Barrett Universal and Hill-RBF formulas for all eyes. “When these two calculation methods agree, chances are very good that the refractive outcome will be as anticipated,” he says. “They also have the advantage of not requiring an axial length adjustment for very long eyes, and they perform very well for short eyes.”

One Formula Fits All?

As formulas have improved, many surgeons are feeling less need to check

The Importance of the Ocular Surface

“For those of us who develop IOL power calculation methods, the Ks can be the most problematic aspect,” notes Warren E. Hill, MD, FACS, medical director of East Valley Ophthalmology in Mesa, Arizona. “A dry or unstable ocular surface is usually directly responsible for that. In fact, it’s difficult to overstate how much the status of the ocular surface can impact refractive outcomes.

“One easy way to identify an unstable ocular surface is to obtain a topographic axial curvature map, looking for multiple small, flat and steep islands,” he continues. “Of course, dry eye is usually one of our first thoughts when we find a poor ocular surface, but other factors, such as meibomian gland dysfunction, may also play a role. In our clinic, if we see any sign of MGD we ask the patient to do warm compresses and lid scrubs for two weeks prior to biometry, combined with high-quality artificial tears. If the patient has advanced MGD, especially if a premium IOL is being considered, we may also recommend that the patient undergo a LipiFlow treatment prior to biometry.

“After you improve the ocular surface,” he concludes, “irregular, asymmetric astigmatism may turn into a nice bow-tie pattern, and complex aberration profiles may shift toward something more normal.”

—CK

multiple formulas. Dr. Basti says he’s moving away from that practice. “Over the years we’ve become used to the idea of using different formulas for eyes with different axial lengths,” he notes. “My technicians still make a printout showing the results using four formulas: SRKT; Holladay I; Holladay II; and Barrett. However, I find myself relying almost entirely on the Barrett Universal II as my go-to formula. It does well, even in eyes with long or short axial lengths. It will almost certainly give you reliable results in almost every eye that you normally encounter.

“The one instance in which I think you would do well to look at multiple formulas,” he adds, “is in post-refractive-surgery eyes. Other than that, the idea of looking at multiple formulas is becoming less and less relevant.”

Dr. Hoffer is well-known for his IOL power formulas, from the original Hoffer formula that he published in 1974 to the Hoffer Q that became available in 1993. He notes that he was the first to suggest using different formulas for eyes with different axial lengths, in 1993. “Initially, most surgeons opted for finding the ‘best’ formula and using it on every eye,” he explains. “Our studies showed that

the Hoffer Q formula worked better in eyes shorter than 22 mm, while it was equal to the Holladay I and the SRK/T in the medium axial length range, 22 to 24.5 mm. The Holladay I formula produced the best results in eyes between 24.5 and 26 mm, and the SRK/T was better in eyes over 26 mm.

“Today, we have formulas using all kinds of approaches, including artificial intelligence,” he continues. “The formula that’s currently getting the best results is a new one created by Jack X. Kane, MD, in Melbourne, Australia. I met him five years ago when he was a resident. His formula can be used by plugging in your numbers at his website; he’s following the Holladay principle of not publishing the formula’s details, an approach also followed by Barrett and many of the AI formulas. He also has a formula for use with toric IOLs. Given the study results I’ve seen, both from Dr. Kane and independent sources, I’d recommend using his formula, regardless of the axial length.”

Dr. Koch acknowledges that many surgeons today are simply relying on a single formula. “Many surgeons are just using the Barrett Universal II, which is a fabulous formula,” he says. “That’s fine. How well that will serve

A PUBLICATION BY **REVIEW**
of Ophthalmology

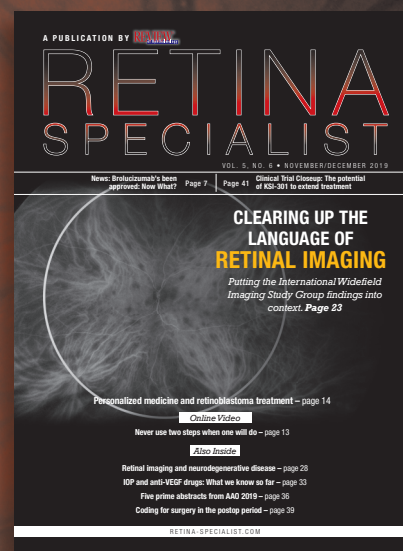
RETINA SPECIALIST

Retina Specialist focuses on the latest advances in the diagnosis, medical management and surgical treatment of diseases of the retina, along with practical, real-world advice from leading clinicians and other experts on managing the successful retina practice.

KEEP UP WITH CUTTING-EDGE SCIENCE IN RETINA.

Watch for issues in:

- JANUARY/FEBRUARY
- MARCH/APRIL
- MAY/JUNE
- JULY/AUGUST
- SEPTEMBER/OCTOBER
- NOVEMBER/DECEMBER



FOR INQUIRIES CONTACT
RETINASPECIALIST@JOBSON.COM

ADVERTISING OPPORTUNITIES

JIM HENNE • PUBLISHER • 610-492-1017 • JHENNE@JOBSON.COM
MICHELE BARRETT • 215-519-1414 • MBARRETT@JOBSON.COM
MICHAEL HOSTER • 610-492-1028 • MHOSTER@JOBSON.COM

www.retina-specialist.com

 @RetSpecMag

 RetinaSpecialistMag

you depends on the patient's expectations, and your expectations. I still think it's valuable to have more than one formula's result to look at."

Dr. Koch adds that there's another problem that may be hindering better outcomes, regardless of the formula being used. "We may not be inputting the most accurate information about the IOLs we're implanting, with regards to asphericity," he says. "That information will be necessary to refine those outcomes. Furthermore, there's a slight variability in IOL powers. They're supposed to be within 0.2 to 0.3 D of labeling, and I think the labeled powers tend to be very accurate, but it would be nice to have them refined even further."

Prior Refractive Surgery

Dr. Koch says that when dealing with a post-refractive-surgery eye, a number of factors add to the challenge. "We're still struggling with how to measure corneal power in this situation, and we don't fully understand how previous refractive surgery affects the lens position calculation," he explains. "In addition, the refraction is more nebulous in these eyes. They often have a somewhat multifocal cornea, so you may not be able to measure a clear endpoint. Twenty to 25 percent of these eyes end up outside the ± 0.5 D range, and part of that may reflect the mushiness of the refraction and refractive error."

Dr. Koch says that getting a good outcome in this situation is all about the formulas. "If you know the patient's prior refractive history, the Masket, the Barrett and the Haigis L formulas work well," he notes. "We've also had good success with the OCT formula that was developed for use with the RTVue, or the next generation of that device, the Avanti. Another interesting advance is being able to measure total corneal power. With the IOLMaster 700, for example, you can

measure total keratometry. But even using that data, we're still not breaking the 80-percent accuracy mark in our post-LASIK calculations—at least based on the written reports I've seen, as well as our own data."

*"Short eyes remain a problem that we really haven't solved."
— Douglas Koch, MD*

"When measuring eyes that have undergone prior refractive surgery, we rely heavily on standard biometry in the form of autokeratometry," says Dr. Hill. "In addition, we often measure these eyes with topography and several other methods. A number of different post-refractive-surgery calculation algorithms have been developed for different devices, such as the Atlas topographer, the Pentacam and the RTVue. You can see how these are used on the ASCRS IOL calculation website (iolcalc.ascrs.org/wbfrmCalculator.aspx); for eyes with prior refractive surgery, a specific calculation method can provide the IOL power. My personal preference for both prior LASIK and RK eyes is the Barrett True K method."

"If you have information about the eye before and after the refractive procedure, both the Barrett True K and the modified Masket formulas will do well," says Dr. Basti. "In patients for whom you have no prior refractive information, the three formulas that do the best are the Barrett True K No History, the Haigis L, and the OCT-based formula. The OCT formula is useful because in post-refractive eyes the challenge is to estimate the true corneal power, and OCT can give you a very accurate measurement of that."

When calculating the lens power for

post-refractive eyes, Dr. Basti recommends using the ASCRS online calculator. "The ASCRS calculator asks you whether you have information related to how much refractive error was corrected with the prior refractive procedure," he notes. "If you have that information, you put it in and one row of formulas lights up. Those formulas—the modified Masket and Barrett True K—will be most accurate in eyes that have had refractive surgery, if you have the preop information. If you don't have that information, which often happens, another row of formulas lights up. That row includes the Barrett True K No History, the Haigis L and the OCT-based formulas."

Dr. Koch says he's hopeful that ray tracing may lead to a breakthrough. "Ray tracing does a better job of incorporating the variable corneal power within the central 3- to 4-mm zone than the other technologies," he points out. "So far, it hasn't outdone our best formulas, like the Barrett True K formula, but I think that's because we're not giving those ray-tracing formulas the best corneal power information. Thomas Olsen, MD, has developed a ray-tracing formula that's shown some pretty good results. But I still don't see anybody cracking the 80-percent barrier. Something is still missing."

Strategies for Success

Surgeons offer these pearls for improving your outcomes:

- **Know your biometry device well.** "The better you know your biometer, the better your outcomes will be," says Dr. Basti. "Every biometry device has recommendations from the manufacturer explaining how to optimize its use. In fact, one of the biggest mistakes surgeons make is not looking at the quality metrics of each measurement they take.

"For example," he continues, "the IOLMaster recommends that the

(Continued on page 65)

When ocular itch gets in the way of their day...

ALLEVIATE WITH
ZERVIAE™

Available by prescription only.

ZERVIAE delivers the proven power of cetirizine—a leading oral allergy medication—now targeted to the eyes.^{1,2,a}

- Clinically meaningful and rapid reduction in ocular itch vs vehicle at 15 minutes and 8 hours ($P < 0.0001$ at all time points measured)^{1,3}
- Designed for comfortable delivery with Hydrella™, a glycerin and HPMC formulation^{1,4}
- Administered as a single drop, twice daily approximately 8 hours apart¹

STUDY DESIGN: The pivotal trials for ZERVIAE included two Phase 3, double-masked, randomized, vehicle-controlled, parallel-group studies involving 201 patients. Study 2 required more severe allergic conjunctivitis symptoms. Patients were screened for an allergen response using the conjunctival allergen challenge (CAC) model and randomized to receive either ZERVIAE or vehicle. Primary efficacy endpoints were ocular itching and conjunctival redness 15 minutes and 8 hours post treatment instillation.³

INDICATIONS AND USAGE

ZERVIAE™ (cetirizine ophthalmic solution) 0.24% is a histamine-1 (H1) receptor antagonist indicated for treatment of ocular itching associated with allergic conjunctivitis.

DOSAGE AND ADMINISTRATION

Instill one drop in each affected eye twice daily (approximately 8 hours apart).

IMPORTANT SAFETY INFORMATION

WARNINGS AND PRECAUTIONS

Contamination of Tip and Solution: As with any eye drop, care should be taken not to touch the eyelids or surrounding areas with the dropper tip of the bottle or tip of the single-use container in order to avoid injury to the eye and to prevent contaminating the tip and solution. Keep the multi-dose bottle closed when not in use. Discard the single-use container after using in each eye.

Contact Lens Wear: Patients should be advised not to wear a contact lens if their eye is red. ZERVIAE should not be instilled while wearing contact lenses. Remove contact lenses prior to instillation of ZERVIAE. The preservative in ZERVIAE, benzalkonium chloride, may be absorbed by soft contact lenses. Lenses may be reinserted 10 minutes following administration of ZERVIAE.

ADVERSE REACTIONS

The most commonly reported adverse reactions occurred in approximately 1-7% of patients treated with either ZERVIAE or vehicle. These reactions were ocular hyperemia, instillation site pain, and visual acuity reduced.

Please see brief summary of Full Prescribing Information on the adjacent page.

HPMC=hydroxypropyl methylcellulose.

^aBased on a U.S. News report on data from the 2019 Pharmacy Times Survey of Pharmacists' OTC Recommendations.

References: 1. ZERVIAE [package insert]. Fort Worth, Texas: Eyeavance Pharmaceuticals LLC; 2020. 2. *U.S. News & World Report*. Antihistamines for allergies. <https://health.usnews.com/health-products/top-rec-antihistamines-oral-8>. Accessed October 7, 2019. 3. Meier EJ, Torkildsen GL, Gomes PJ, et al. Phase III trials examining the efficacy of cetirizine ophthalmic solution 0.24% compared to vehicle for the treatment of allergic conjunctivitis in the conjunctival allergen challenge model. *Clin Ophthalmol*. 2018;12:2617-2628. 4. Malhotra RP, Meier E, Torkildsen G, et al. Safety of cetirizine ophthalmic solution 0.24% for the treatment of allergic conjunctivitis in adult and pediatric subjects. *Clin Ophthalmol*. 2019;13:403-413.



© 2020 Eyeavance Pharmaceuticals LLC. All rights reserved.
ZERVIAE™ and Hydrella™ are trademarks of Eyeavance Pharmaceuticals LLC.
ZER-02-20-AD-22

NEW



ZERVIAE™
cetirizine ophthalmic solution, 0.24%

FORMULATED WITH HYDRELLA™

Learn more at MyZerviate.com

ZERVIAE™ (cetirizine ophthalmic solution) 0.24%

Brief Summary

INDICATIONS AND USAGE

ZERVIAE (cetirizine ophthalmic solution) 0.24% is a histamine-1 (H1) receptor antagonist indicated for treatment of ocular itching associated with allergic conjunctivitis.

DOSAGE AND ADMINISTRATION

Recommended Dosing: Instill one drop of ZERVIAE in each affected eye twice daily (approximately 8 hours apart). The single-use containers are to be used immediately after opening and can be used to dose both eyes. Discard the single-use container and any remaining contents after administration. The single-use containers should be stored in the original foil pouch until ready to use.

CONTRAINDICATIONS

None.

WARNINGS AND PRECAUTIONS

Contamination of Tip and Solution: As with any eye drop, care should be taken not to touch the eyelids or surrounding areas with the dropper tip of the bottle or tip of the single-use container to avoid injury to the eye and to prevent contaminating the tip and solution. Keep the multi-dose bottle closed when not in use. Discard the single-use container after using in each eye.

Contact Lens Wear: Patients should be advised not to wear a contact lens if their eye is red.

ZERVIAE should not be instilled while wearing contact lenses. Remove contact lenses prior to instillation of ZERVIAE. The preservative in ZERVIAE, benzalkonium chloride, may be absorbed by soft contact lenses. Lenses may be reinserted 10 minutes following administration of ZERVIAE.

ADVERSE REACTIONS

Clinical Trials Experience: Because clinical trials are conducted under widely varying conditions, adverse reaction rates observed in the clinical trial of a drug cannot be directly compared to rates in the clinical trials of another drug and may not reflect the rates observed in practice.

In 7 clinical trials, patients with allergic conjunctivitis or those at risk of developing allergic conjunctivitis received one drop of either cetirizine (N=511) or vehicle (N=329) in one or both eyes. The most commonly reported adverse reactions occurred in approximately 1%–7% of patients treated with either ZERVIAE or vehicle. These reactions were ocular hyperemia, instillation site pain, and visual acuity reduced.

USE IN SPECIFIC POPULATIONS

Pregnancy

Risk Summary

There were no adequate or well-controlled studies with ZERVIAE in pregnant women. Cetirizine should be used in pregnancy only if the potential benefit justifies the potential risk to the fetus.

Data

Animal Data

Cetirizine was not teratogenic in mice, rats, or rabbits at oral doses up to 96, 225, and 135 mg/kg, respectively (approximately 1300, 4930, and 7400 times the maximum recommended human ophthalmic dose (MRHOD), on a mg/m² basis).

Lactation

Risk Summary

Cetirizine has been reported to be excreted in human breast milk following oral administration. Multiple doses of oral dose cetirizine (10 mg tablets once daily for 10 days) resulted in systemic levels (Mean C_{max} = 311 ng/mL) that were 100 times higher than the observed human exposure (Mean C_{max} = 3.1 ng/mL) following twice daily administration of cetirizine ophthalmic solution 0.24% to both eyes for 1 week. Comparable bioavailability has been found between the tablet and syrup dosage forms. However, it is not known whether the systemic absorption resulting from topical ocular administration of ZERVIAE could produce detectable quantities in human breast milk.

There is no adequate information regarding the effects of cetirizine on breastfed infants, or the effects on milk production to inform risk of ZERVIAE to an infant during lactation. The developmental and health benefits of breastfeeding should be considered along with the mother's clinical need for ZERVIAE and any potential adverse effects on the breastfed child from ZERVIAE.

Pediatric Use: The safety and effectiveness of ZERVIAE has been established in pediatric patients two years of age and older. Use of ZERVIAE in these pediatric patients is supported by evidence from adequate and well-controlled studies of ZERVIAE in pediatric and adult patients.

Geriatric Use: No overall differences in safety or effectiveness have been observed between elderly and younger patients.

NONCLINICAL TOXICOLOGY

Carcinogenesis, Mutagenesis, Impairment of Fertility

Carcinogenicity

In a 2-year carcinogenicity study in rats, orally administered cetirizine was not carcinogenic at dietary doses up to 20 mg/kg (approximately 550 times the MRHOD, on a mg/m² basis). In a 2-year carcinogenicity study in mice, cetirizine caused an increased incidence of benign liver tumors in males at a dietary dose of 16 mg/kg (approximately 220 times the MRHOD, on a mg/m² basis). No increase in the incidence of liver tumors was observed in mice at a dietary dose of 4 mg/kg (approximately 55 times the MRHOD, on a mg/m² basis). The clinical significance of these findings during long-term use of cetirizine is not known.

Mutagenesis

Cetirizine was not mutagenic in the Ames test or in an *in vivo* micronucleus test in rats. Cetirizine was not clastogenic in the human lymphocyte assay or the mouse lymphoma assay.

Impairment of Fertility

In a fertility and general reproductive performance study in mice, cetirizine did not impair fertility at an oral dose of 64 mg/kg (approximately 875 times the MRHOD, on a mg/m² basis).

PATIENT COUNSELING INFORMATION

Risk of Contamination: Advise patients not to touch dropper tip to eyelids or surrounding areas, as this may contaminate the dropper tip and ophthalmic solution. Advise patients to keep the bottle closed when not in use. Advise patients to discard single-use containers after each use.

Concomitant Use of Contact Lenses: Advise patients not to wear contact lenses if their eyes are red. Advise patients that ZERVIAE should not be used to treat contact lens-related irritation. Advise patients to remove contact lenses prior to instillation of ZERVIAE. The preservative in ZERVIAE solution, benzalkonium chloride, may be absorbed by soft contact lenses. Lenses may be reinserted 10 minutes following administration of ZERVIAE.

Administration: Advise patients that the solution from one single-use container is to be used immediately after opening. Advise patients that the single-use container can be used to dose both eyes. Discard the single-use container and remaining contents immediately after administration.

Storage of Single-use Containers:

Instruct patients to store single-use containers in the original foil pouch until ready to use.

Rx Only

Manufactured by: Renaissance Lakewood, LLC, Lakewood, NJ 08701

Distributed by: Eyeavance Pharmaceuticals LLC, Fort Worth, TX 76102



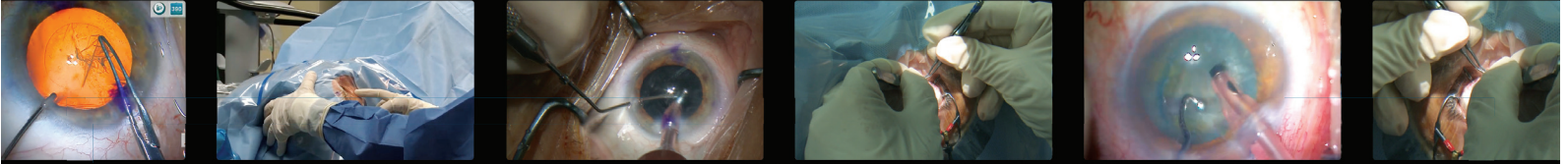
© 2020 Eyeavance Pharmaceuticals LLC. All rights reserved.
ZERVIAE™ is a trademark of Eyeavance Pharmaceuticals LLC.
ZER-01-20-MS-10



Monthly

MACKOOL ONLINE CME

CME SERIES | SURGICAL VIDEOS



To view CME video
go to:

www.MackoolOnlineCME.com

Episode 52: "Horizontal Phaco Chop Technique with "Penetrating" Limbal Relaxing Incisions"

Surgical Video by:
Richard J. Mackool, MD

Video Overview:

In this myopic patient with low ocular rigidity, I demonstrate both my phaco chop technique and simultaneous astigmatic correction using a pair of full thickness i.e. Penetrating, Limbal Relaxing Incisions.

MackoolOnlineCME.com MONTHLY Video Series



Richard J. Mackool, MD

We are excited to continue into our fifth year of Mackool Online CME. With the generous support of several ophthalmic companies, I am honored to have our viewers join me in the operating room as I demonstrate the technology and techniques that I have found to be most valuable, and that I hope are helpful to many of my colleagues. We continue to edit the videos only to either change camera perspective or to reduce down time - allowing you to observe every step of the procedure.

As before, one new surgical video will be released monthly, and physicians may earn CME credits or just observe the case. New viewers are able to obtain additional CME credit by reviewing previous videos that are located in our archives.

I thank the many surgeons who have told us that they have found our CME program to be interesting and instructive; I appreciate your comments, suggestions and questions. Thanks again for joining us on Mackool Online CME.



CME Accredited Surgical Training Videos Now Available Online: www.MackoolOnlineCME.com

Richard Mackool, MD, a world renowned anterior segment ophthalmic microsurgeon, has assembled a web-based video collection of surgical cases that encompass both routine and challenging cases, demonstrating both familiar and potentially unfamiliar surgical techniques using a variety of instrumentation and settings.

This educational activity aims to present a series of Dr. Mackool's surgical videos, carefully selected to address the specific learning objectives of this activity, with the goal of making surgical training available as needed online for surgeons motivated to improve or expand their surgical repertoire.

Learning Objective:

After completion of this educational activity, participants should be able to:

- Employ an efficient technique for nucleus segmentation and an incisional technique to reduce astigmatism.

Satisfactory Completion - Learners must pass a post-test and complete an evaluation form to receive a certificate of completion. You must listen to/view the entire video as partial credit is not available. If you are seeking continuing education credit for a specialty not listed below, it is your responsibility to contact your licensing/certification board to determine course eligibility for your licensing/certification requirement.



JOINTLY ACCREDITED PROVIDER™
INTERPROFESSIONAL CONTINUING EDUCATION

Physicians - In support of improving patient care, this activity has been planned and implemented by Amedco LLC and Review Education Group. Amedco LLC is jointly accredited by the Accreditation Council for Continuing Medical Education (ACCME), the Accreditation Council for Pharmacy Education (ACPE), and the American Nurses Credentialing Center (ANCC), to provide continuing education for the healthcare team

Credit Designation Statement - Amedco designates this enduring material activity for a maximum of .25 AMA PRA Category 1 Credits™. Physicians should claim only the credit commensurate with the extent of their participation in the activity.

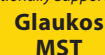Jointly provided by:



Supported by an unrestricted independent
medical educational grant from:



Additionally Supported by:



Crestpoint Management

In Kind Support:



Video and Web Production by:
JR Snowden, Inc

Point-Counterpoint: Scleral-Sutured Fixation vs. Yamane Technique

Sticking with Scleral-Sutured IOLs

Gregory S. H. Ogawa, MD, Albuquerque, New Mexico

After 26 years of scleral fixing IOLs, I continue to achieve excellent results by using a scleral-sutured technique. Yes, I keep on top of the innovations that our colleagues introduce, including the use of haptic scleral fixation championed by proponents of the Yamane technique. However, I still don't see a reason to change my approach, nor do the results of nearly 2,000 cases I have completed suggest that I should do so.

In this point-counterpoint, my point is that my tried-and-true method is still the best one to use when patients experience dislocation problems with their crystalline lenses or original IOLs.

Validating Data

To check the validity of my approach, I evaluated the results of 202 scleral-sutured 9-0 polypropylene posterior chamber IOL surgeries that I completed between 2004 and 2008, the data for which I presented at the 2017 AAO meeting. Indications for surgery included aphakia, dislocated/subluxated IOLs or natural lenses, corneal edema and uveitis/glaucoma/hyphema syndrome. The average time between surgery and data review was 10.8 years.

“I can't recall any of my patients needing reoperations related to the IOL fixation.”



This series—standardized by the use of data from a single surgeon—showed overall improvement in visual acuity, minor complications (six intraoperative and five postop), sustained IOL fixation and refractive predictability. These results were all with 9-0 polypropylene (Prolene; Ethicon) before transitioning to polytetrafluoroethylene (PTFE) monofilament suture (Gore-Tex; W.L. Gore). The data revealed no cases of IOL tilt, suture erosion or unusual IOP elevation. Additionally, I can't recall any of my suture-fixed IOL patients needing reoperations related to the IOL fixation, besides the few who had late polypropylene suture breakage. Nor have I seen erosions of sutures coming through

my patients' conjunctiva when the knot is buried inside the eye.

In contrast, professor Shin Yamane, MD, pioneer of the haptic-fixed technique named after him, has only been using his technique since 2014. A sober look at his technique, which, granted, has garnered much excitement, shows no 10-year data supporting its long-term efficacy.¹ Also, keep in mind that Dr. Yamane uses an IOL from Santen Pharmaceuticals (Osaka, Japan) that has an optic with a 7-mm diameter, which is 1 mm greater than foldable options available in the United States.

Using Yamane's smaller-diameter implants increases the potential for

(Continued on page 44)

Point-Counterpoint: Scleral-Sutured Fixation vs. Yamane Technique

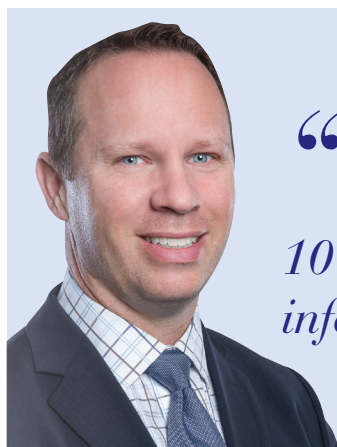Make Room for Yamane's Efficiency

Brandon Ayres, MD, Philadelphia

Colleagues ask me why I choose the Yamane technique for secondary IOLs in eyes that have minimal or no capsular support. The simple answer is that the haptics used to fixate the IOL are stronger than scleral sutures and that the Yamane technique's 3-mm incision is much better for the patient than the 7-mm incision required to complete the scleral-sutured technique. But there's more to it than that, as I've discovered while doing hundreds of these procedures. I'll explain the advantages the Yamane technique can provide most of your patients, as well as challenges you need to overcome and contraindications to consider. My argument is this: Shouldn't more surgeons at least start doing these procedures when appropriate?

Why Yamane?

For many years, surgeons in our practice performed scleral-sutured procedures, using Gore-Tex fixation and a variety of foldable IOLs. We've switched to haptic fixation, using the Yamane technique for most cases in part because of the problems we've experienced when working with nonabsorbable polytetrafluoroethylene (PTFE) monofilament suture (Gore-Tex; W.L. Gore), in-



“You can be in and out of the eye in 10 minutes, reducing infections and OR time.”

cluding opacification of the lens material and exposure of the Gore-Tex knot. (Remember that Gore-Tex is not approved for use in the eye.) The Yamane technique meets the same objective as scleral-sutured fixation, and it can be used by all surgeons.

You can also use the Yamane technique with almost any three-piece IOL you have in the OR or on standby. Most three-piece IOLs are made of either silicone or hydrophobic acrylic material. It may be wise to stick with the hydrophobic acrylic three-piece IOLs, because using this material is always safe. Even if the patient needs vitreoretinal or corneal surgery, the material will stand the test of time. Silicone three-piece IOLs can be problematic if patients

need silicone oil placed for retinal detachment repair. Hydrophilic acrylic IOLs with hydroxyapatite may opacify when exposed to the surgical air or gas used in retinal surgery, as well as lamellar keratoplasty (DSEK and DMEK).

Degradable Sutures

Lack of scleral suture stability has also been a concern for us. Polypropylene (Prolene), the suture material that functions as a frequent alternative to Gore-Tex, can degrade or break, leading to dislocation of secondary IOLs. I've already needed to refixate several secondary IOLs that

(Continued on page 45)

Scleral-Sutured Fixation at a Glance

After conjunctival peritomies are created at the main incision location and on the far side of the eye, a 7-mm wide scleral groove must be created in a frown configuration (matching the 7-mm-wide optic of the IOL). A tunneling blade is shown dissecting anteriorly into clear cornea as the next step (See Figure 1). A pointed-tip keratome and then an enlargement keratome are needed to open the main incision in a corneal valve configuration.

After a 24-ga. (0.8-mm-wide) angled MVR blade is used to create a pair of sclerotomies approximately 5 clock hours to the left of the middle of the main incision, and 1 clock hour to its right, a 7-cm piece of ePTFE (without needles) is placed through the eyelet on the lead haptic of the CZ70BD IOL (Alcon) (See Figure 2). The IOL is placed into the eye with angled tying forceps, while straight tying forceps take up the slack on the externalized suture arms that are both simultaneously held by the straight tying forceps (See Figure 3).

The trailing haptic is left just outside the eye at the main incision while a two-wrap throw is tied in the 7-cm suture. A 4-cm piece of ePTFE is placed through the eyelet on the trailing haptic and then oriented in the same configuration as was used for the first haptic. Either an angled mini IOL manipulator in the eyelet of the trailing haptic or forceps grasping the haptic is used to place the trailing haptic into the eye, through the pupil, then posterior to the iris. After externalizing the suture arms and securing them with a two-wrap throw, the knot in the ePTFE suture is

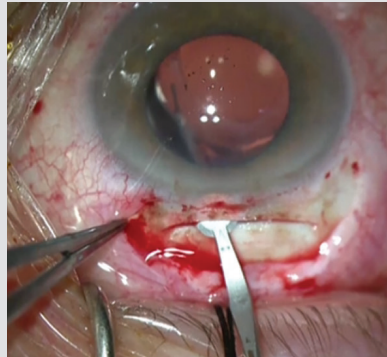


Figure 1. A spoon blade creating a scleral tunnel to a corneal valve incision through Descemet's membrane.

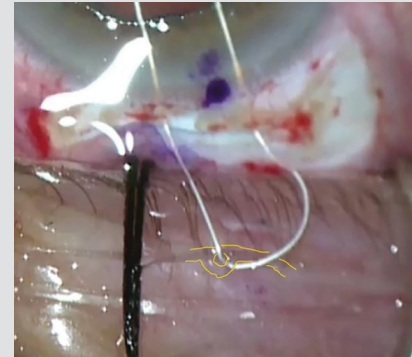


Figure 2. One suture arm comes over the haptic through the eyelet, the other between the eyelet and optic.

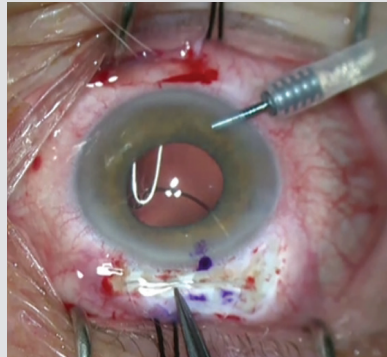


Figure 3. Placing the IOL into the eye while taking up slack on the suture through the lead haptic.

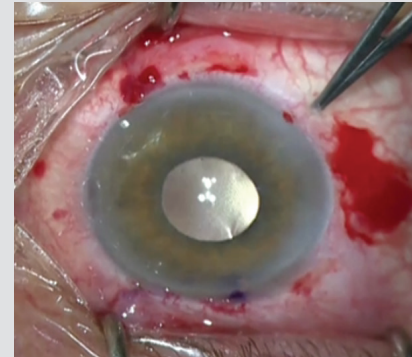


Figure 4. Purkinje images indicate excellent IOL position and centration at the end.

finalized, resulting in a 2-1-1-1-1 knot before the suture arms are trimmed.

Three interrupted 10-0 nylon sutures are usually sufficient to stabilize the main incision; then the ePTFE knots are buried into

the eye. Purkinje images confirm IOL position and centration at completion of the case (See Figure 4). Below is a link to a 10-minute video of the procedure, as just described:

[youtube.com/watch?v=feNASol6MGE](https://www.youtube.com/watch?v=feNASol6MGE)

Scleral-Sutured

(Continued from page 42)

symptoms from decentration. The Santen IOL also has a greater overall diameter than IOLs in the United States and offers more haptic material to use, potentially useful in larger eyes. For these reasons, one could argue that using Dr. Yamane's results to support the use of his technique in the United States may not be valid.

Right Setting

Besides reliable long-term results, practice environment also plays a role in my decision to keep performing scleral-sutured fixation of secondary IOLs. Here in New Mexico, where the number of doctors per capita is low, we have a population of only 2 million people, including 1 million in metropolitan Albuquerque, where I see patients and perform surgery. If a patient has a problem with a lens

or a need for a second surgery, that patient may have to drive up to six hours to get follow-up care. We also have a high concentration of Native Americans, who, by cultural norms, typically don't return to see us unless they have more serious issues. Imagine that a postop patient has part of a haptic beginning to push through the conjunctiva after use of the Yamane technique. Although the emerging

(Continued on page 46)

COMBO
COMBINE WITH OUR
UNIQUE STAND

Yamane

(Continued from page 43)

I had sutured into patients' scleras with polypropylene. A primary concern with Gore-Tex, meanwhile, is that using this stronger material for scleral fixation is significantly more challenging than what we experience when we use the haptic fixation of the Yamane technique. Fixating with Gore-Tex also creates the need for more scleral incisions.

Meanwhile, we've found that the haptics of secondary IOLs keep implants in place longer than sutures. With the Yamane technique, you can take advantage of the enduring longevity of fixation. Your patient benefits significantly from the Yamane's approximate 3-mm incision, which won't require a single suture. Also, we're making needle sclerotomies, not large ones, meaning patients on anticoagulants are less likely to experience vitreous hemorrhage. And we can get by with less anesthesia.

Efficiency is probably the biggest advantage, however. Even a very efficient surgeon may require 20 to 25 minutes to suture in an IOL. With haptic fixation, you can be in and out of the eye in 10 minutes, reducing your patient's exposure to potential infections and time in the OR.

Special Equipment

The Yamane technique does require special equipment. Make sure you have microforceps, low-temperature cautery and the correct needles and/or trocars. A thin-walled 30-ga. needle, or at least a 27-ga. needle, is essential. Your equipment supplier may be able to provide haptic-fixation kits that include an anterior segment pressure maintainer, low temperature cautery, a marking pen and a caliper.

With such a kit, your scrub nurse doesn't have to go picking out these items one at a time.

I will say this: If you're new to the Yamane technique, you'll face initial challenges. If a haptic gets kinked when you're trying to manipulate an implant in the eye, for example, that haptic will be rendered useless. When trying your first few cases, which can be difficult, use a three-piece IOL that has polyvinylidene fluoride (PVDF) haptics.

PVDF haptics don't kink easily and are much more resilient than other haptics. In the United States, the only available three-piece PVDF IOL is the Zeiss CT Lucia 602. Use it until you've developed the necessary dexterity to thread the haptics and manage the procedure. All other three-piece IOLs have PMMA haptics, which you can eventually adapt for this technique.

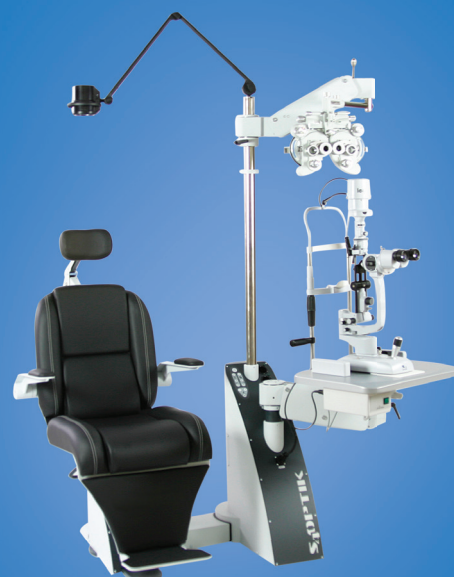The benefits of taking this approach? When I compare scleral-sutured fixation patients to haptic-fixated patients, I always find that the haptic-fixated patients are more comfortable after surgery. They also generally seem to recover faster and their implants achieve stability more quickly. We typically produce good results, which satisfies patients, because we're using better and more familiar materials. Although applying the haptics of an IOL for scleral fixation is admittedly an off-label use, we're not using an off-label suture, such as Gore-Tex. So it's one less off-label issue we need to discuss with the patient as a potential drawback.

Adapting the Technique

The three most important steps

(Continued on page 46)

**Effortless
instrument
positioning**



**Advanced
ergonomics**



S4OPTIK

www.s4optik.com | 888-224-6012

Sensible equipment. Well made, well priced.
For today's modern office.

Scleral-Sutured*(Continued from page 44)*

haptic may initially feel like a minor foreign body sensation, it eventually could open a tract for pathogens into the eye, resulting in a case of endophthalmitis.

We know that we won't have the opportunity to perform a second surgery or respond to complications easily in our setting. I'm also a surgeon to whom other surgeons send their patients for the last surgery those patients, hopefully, will need. This role compels me to respond accordingly. Currently, I wind up doing about 100 of these procedures each year, with no serious IOL-related complications.

Additional Risks

The longer you expect a patient to have a sclera-friction-supported IOL in place, the more likely the haptic will erode through the conjunctiva or loosen in the sclera. So I think sutured scleral fixation is especially important for younger patients, holding up for multiple decades of lens fixation. This is another reason to fixate with Gore-Tex, which should last a lifetime.

For patients in their 80s and 90s on anticoagulation—who would benefit from a smaller needle pass than is feasible with Gore-Tex—I often use Prolene sutures. Although Prolene

degrades over time, the impact of suture degradation is less significant in this age group.

Good to Go

Like most of us, I typically do a lens exchange when a patient's lens implant has gotten loose or dislocated and the patient doesn't have a lens capsule to support the secondary IOL. I use a reproducible approach to set up the procedure, make the incision and place the new implant (Alcon CZ70BD) right where I want it to be. The lens is flat and centered. Then I finish tying my sutures and everything is good to go. (See "Scleral-Sutured Fixation at a Glance" on page 44.)

On the other hand, I recently heard a Yamane-technique expert say in a lecture that he needs to make an extra needle pass (after the initial two needle passes) in 30 to 40 percent of his cases because the patient's lens is either tilted or not centered. He's quite comfortable doing this. I like to just do my procedure and have it come out the way it's supposed to come out on my first try. My rate of making just one additional incision to move a suture is roughly 1 percent.

In certain cases, such as when a patient with a dislocated IOL has a large glaucoma bleb affecting the cornea, or some other anatomic characteristic that prevents me from making an appropriately-sized scleral tunnel

incision, I may elect to harness the original lens implant through small incisions instead of replacing it.

By passing the Gore-Tex inside the haptic and through the lens capsule (if there's no significant Soemmering material), I can refixate this original implant, which can be an effective solution.

Never Say Never?

Would I ever use the Yamane technique? I could see myself performing the procedure for the patient who has an insufficient amount of scleral tissue for a tunnel, prompting me to go through a corneal incision. In such a case, I could take advantage of the Yamane's 3-mm incision instead of the 7-mm incision required for CZ70BD fixation. That said, I haven't encountered this situation yet and therefore I haven't needed to switch to the Yamane technique. In the meantime, I'll just keep doing what I've been doing. Why should I change now?

Dr. Ogawa is a partner at Eye Associates of New Mexico and an associate clinical professor of ophthalmology at the University of New Mexico School of Medicine. He has disclosed no relevant financial relationship.

1. Yamane S, Sato S, Maruyama-Inoue M, Kadonosono K. Flanged intrascleral intraocular lens fixation with double-needle technique. *Ophthalmology* 2017;124:8:1136-1142.

Yamane*(Continued from page 45)*

when adapting the Yamane technique are practice, practice and practice—in the wet lab before performing on patients. Make sure you can set up the incisions and make proper measurements. Otherwise, you could end up with a decentered implant. (See "Yamane Technique at a Glance" on page 48.)

Your comfort is an important factor. Many of us are used to scleral-suture-fixating IOLs. With the Yamane approach, understand that getting the haptic-fixated IOL spot on with your first try can be a challenge. I've watched beginning surgeons struggle for more than an hour to complete the procedure. So although I assure you that the surgery can be done in 10 minutes, I need to point out this is possible only after doing many cases.

When Yamane's Not Ideal

As effective as haptic-fixated surgery may be, I find that I'm able to use it in only 70 percent of my cases of complicated IOLs. Because I know my own nomogram, I can scleral fixate in the remaining cases with sutures. I know I'm accurate when suturing with four-point Gore-Tex in an off-label fashion like this.

I really think that centration and

tilt are actually very predictable and better when we use scleral-sutured fixation, which can be one advantage of this technique that sets it apart. I put the IOL in, suture it, then tie my sutures. I usually like the way the implant looks. I don't have to go back and move a suture or revise it.

Because of these factors, I'm mindful that scleral-sutured fixation might meet the expectations of premium IOL patients better than haptic fixation in some cases. When fixating a premium IOL, I want to at least minimize any need for postop distance glasses. I can help the patient more from a refractive-target standpoint if I use scleral-sutured fixation. This is generally borne out in our patient data, although the data vary among surgeons and procedures.

I'll also turn to scleral-sutured fixation if I'm managing a complication from another surgeon, and I need to be as precise as possible with my IOL calculation. We'll consider scleral-sutured fixation as long as the patient has no retinal pathology, which we can confirm because the patient undergoes a vitrectomy before fixation. Other essential prerequisites for scleral-sutured fixation include good corneal cell counts and otherwise healthy corneas.

There are a handful of other situations in which Yamane might not be the preferred approach:

- **Disorganized anterior segment.** The haptic-fixation technique would be more difficult to perform in the presence of extensive iris damage or aniridia. During the Yamane technique, you'll tend to rest the three-piece IOL first on the anterior chamber and iris while making your sclerotomies. Having no iris, or no substantial iris, would complicate the procedure. Scleral fixation may have an advan-

tage here.

- **Artificial iris procedure.** Not many surgeons do this, but if you're one of them, don't involve the Yamane technique, for the reasons mentioned above.

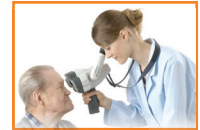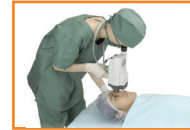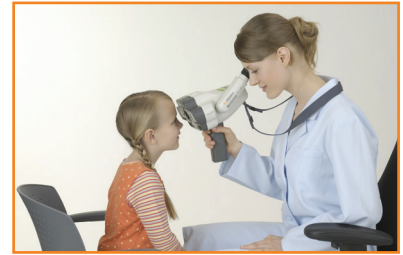- **Lack of conjunctival space.** You need some real estate on the conjunctiva to succeed with the Yamane technique. The best ergonomic approach is to sit in a temporal position at 6 and 12 o'clock to make the needle sclerotomies, thread the haptics and place the haptics in the anterior segment. Sitting in a superior position and making your sclerotomies at 3 and 9 o'clock also works well. However, if your patient has a trabeculectomy, tube shunt or tube, these areas will already be occupied by other hardware, making it very difficult to shift your incisions to where you need them to fit. Suture fixation may be a better approach.

Achilles Heel

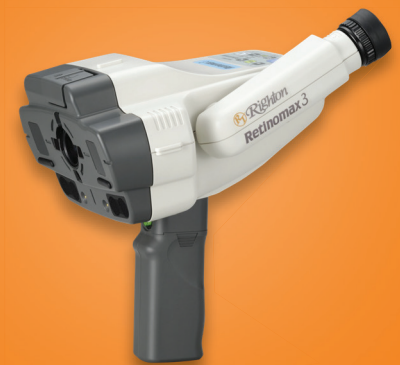Lens tilt and decentration admittedly are the Achilles heel of the Yamane technique, affecting about 30 percent of my Yamane cases (besides the approximate 30 percent of overall secondary IOL cases for which I elect to perform scleral-sutured fixation from the outset). If I find a lens is too nasal, or imperfect in any other way after fixating it with haptics, I cut the responsible haptic and fixate it again. I don't see the routine need to revise a surgery as a failure because I can fix the lens during the same procedure, without creating infection and without the patient realizing it. To succeed, you need to be comfortable revising the surgery before finishing it. I should also emphasize that the differences between the outcomes of scleral-fixated versus

(Continued on page 48)

Precise Measurements Anytime, Anywhere



THE SERIES 3 HAND-HELD AUTOREFRACTOR **RETINOMAX** Righton



- ✓ Fast
- ✓ Lightweight
- ✓ Ergonomically Balanced
- NEW Auto Quick Measurement
- NEW Auto Pupil Measurement
- ✓ Small Pupil 2.3mm Measurement Acquisition
- ✓ Flexible Positioning—Sitting, Standing, Supine

S4OPTIK

www.s4optik.com | 888-224-6012

Sensible equipment. Well made, well priced.
For today's modern office.

Yamane Technique at a Glance

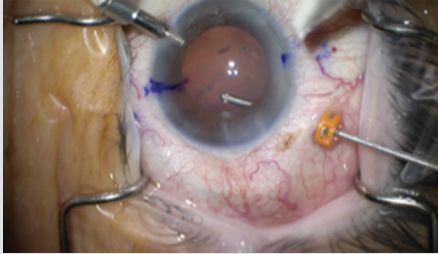


Figure 1. An anterior vitrectomy, being performed here, ensures that no vitreous is present in the anterior segment and that all retained lens material is removed. Triamcinolone helps visualize the vitreous strands, facilitating adequate removal. Centration marks are placed on the conjunctiva at 6 and 12 o'clock. Marks are placed 2.5 to 3.0 mm posterior to the limbus, and a 2-mm tunnel length is also marked on the conjunctiva.

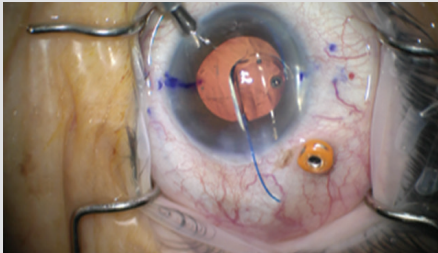


Figure 2. A three-piece intraocular lens is placed in the anterior chamber, allowing the trailing haptic to prolapse through the primary incision. In this case, the haptic is made out of polyvinylidene fluoride (PVDF).

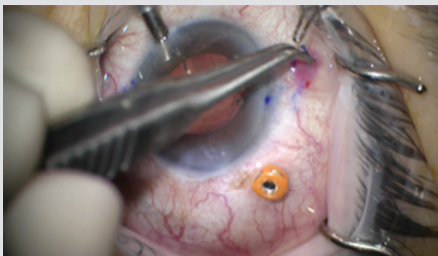

Figure 3. Here's a view of the trailing haptic after it's externalized by removal of the thin-walled needle. The haptic is carefully grasped with tying forceps and a terminal flange is created, using low-temperature, battery-operated cautery. Without touching the haptic, cautery is brought close enough to the terminal end of the haptic to cause it to melt and create a smooth flange.

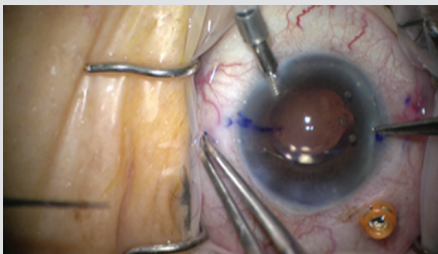


Figure 4. The terminal flanges are shown being carefully prolapsed through the conjunctiva and into the scleral channels.

A brief video of the procedure can be seen at: <https://www.youtube.com/watch?v=7ePEE0gw4Lc>

Yamane

(Continued from page 47)

haptic-fixated secondary IOLs are quite small.

Obvious Benefits

Surgeons are paying a lot of attention to the haptic fixation of the Yamane technique—and rightfully so. It's been great for our practice, and I've come to enjoy the technique because of the benefits it helps me

achieve for my patients and my surgery. I just don't want to oversimplify it and give the impression that the technique is easy and that you can do it with little training and practice.

Any scleral IOL fixation technique for a secondary IOL can be risky if it's not tackled with the right levels of knowledge, experience and preparation. However, any surgeon who has a sufficient degree of commitment and dedication to mastering a procedure can succeed with the Yamane

technique, which I'm advocating for here. **REVIEW**

Dr. Ayres is part of the Cornea Service at Wills Eye Hospital and Ophthalmic Partners of Pennsylvania. He's also Co-Director of the Cornea Fellowship at Wills and an instructor at Jefferson Medical College, Thomas Jefferson University in Philadelphia. He is a Consultant for Alcon, Carl Zeiss Meditec and Microsurgical Technology.

(Continued from page 17)

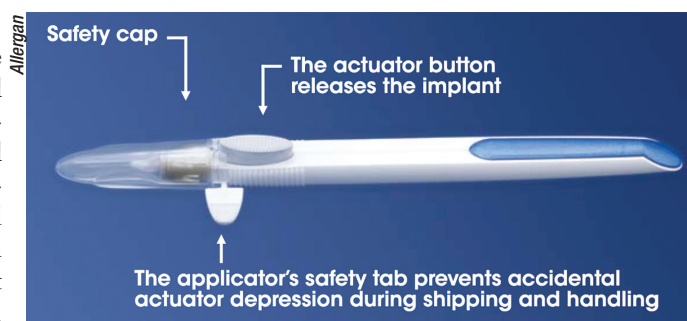
pand, and anecdotally, the patients that have switched from a previous drug to Beovu seem to have a good response. It's definitely going to take some time until we can resume using Beovu with great confidence, but by sharing our experiences, sharing cases and staying transparent, we can figure this out."

Dr. Garg and Dr. Singh have no relevant financial disclosures.

1. Novartis Press release
2. Screenshots of a presentation to the Macula Society by Pravin Dugel, MD, from Sunir Garg, MD.
3. Gao X, Borkar D, Obeid A, et al. Incidence of retinal artery occlusion following intravitreal anti-vascular endothelial growth factor injections. *Acta Ophthalmologica* 2019;e938-e939.

Sustained-Release Glaucoma Implant Approved

For the first time, American doctors treating glaucoma or ocular hypertension have access to a sustained-release implant that can offer many patients a way to lower their intraocular pressure without having to use drops—or at least with fewer drops. In early March the U.S. Food and Drug Administration approved Allergan's Durysta implant, which contains 10 µg of bimatoprost, a prostaglandin analog. The implant comes preloaded into a single-use applicator that allows it to be injected directly into the anterior chamber. (The applicator must be refrigerated



An instructional image provided by Allergan describes the operation of the Durysta sustained-release implant's delivery device.

prior to use.) The drug is then slowly released over a period of 12 weeks—although data from the two clinical trials that led to approval suggest that its beneficial effects may extend beyond that time limit.

The implant's efficacy was tested in two 20-month-long multicenter, randomized, controlled clinical trials involving 1,122 patients with open-angle glaucoma or ocular hypertension, with an eight-month-long follow-up period. (Subjects' mean baseline IOP was 24.5 mmHg.) The implant's efficacy was compared to that of twice-daily topical timolol 0.5% drops. In both trials, the implant reduced IOP about 30 percent from baseline (about 5 to 8 mmHg) over the 12-week period. (The FDA approval states that the implant shouldn't be readministered to an eye that has previously had one, which would seem to undercut its utility.)

In the two clinical trials, 27 percent of patients experienced conjunctival hyperemia; 5 to 10 percent experienced such issues as foreign body sensation, eye pain and photophobia. The drug has also been reported to cause iris pigment changes in 1 to 5 percent of patients; those changes are likely to be permanent.

Felipe A. Medeiros, MD, PhD, professor of ophthalmology, director of clinical research and vice chair for technology at Duke University in Durham, North Carolina, partici-

pated in the trials. "The procedure is straightforward and painless, and patients don't feel anything once it's in place," he notes. "As far as side effects, in the Phase III clinical trials, most of those occurred within two days. Ocular adverse events such as discomfort and hyperemia were mostly due to the betadine used for steril-

ization during the procedure. Patients with a history of angle closure or active uveitis wouldn't be good candidates; nor would those with a history of diseases that may affect corneal endothelial cells, such as Fuchs'.

"Patients are very enthusiastic about the idea of a sustained-release medication that provides long-term IOP control and potentially also improves the quality of IOP control—i.e., fewer peaks and fluctuations," he continues. "Many patients have issues with adhering to topical medication protocols. The evidence in the literature points to more than half of glaucoma patients not being adherent. In addition, many patients have coexisting conditions that make it difficult to administer drops; they have to rely on their partners or relatives to administer them. Durysta may also help in these situations."

Other possible benefits (or drawbacks) to this approach to treatment should become apparent as doctors use it. "In a preliminary post-hoc analysis from the Durysta Phase III clinical trials, we found that patients randomized to Durysta had slower rates of visual progression over time compared to those on timolol," Dr. Medeiros notes. "This may indicate a better control of IOP. We're now collecting raw visual-field data from all of the sites that participated in these trials to conduct more extensive analyses of the data." **REVIEW**

Adjustable IOLs: Lights, Lasers and Lock-ins

Christine Leonard, Associate Editor

An update on new technology for making postop IOL adjustments.

Refractive IOL implantation still poses many challenges today. Meeting patient goals and expectations, achieving consistent and accurate results with theoretical formulas and counseling patients about their options are just some of the hurdles refractive surgeons face.¹

Adjustable IOL technology, however, may be able to offer some solutions. RxSight's (formerly Calhoun Vision) Light Adjustable Lens (Rx-LAL), which received Food and Drug Administration approval in the fall of 2017, and the developing Perfect Lens femtosecond laser technology are two promising advances in this field. Both of these technologies are able to alter the refractive characteristics of an implanted IOL after surgery in order to achieve a customized, patient-specific refraction. Adjustable IOL technology may also enable the delegation of pre and postop counseling to ODs and increase bilateral same-day sequential cataract surgery volume.¹ Two-part modular IOLs offer another possible option. Here, we'll take a closer look at these adjustable IOL technologies and how they work.

Outlook

Surgeons say that adjustable IOLs' potential for customization after

they're implanted will bring peace of mind and represent a significant step forward. "Being able to adjust refractive error, treat astigmatism and add or 'erase' multifocality in an accurate manner is exciting," says Y. Ralph Chu, MD, founder of Chu Vision Institute in Minnesota and a member of the Perfect Lens scientific advisory board.

Adjustable IOL technology has the potential to improve many cataract outcomes, but one population that's particularly well-suited to postop adjustments is those who have had previous refractive surgery. "It's very hard to do lens power calculations on previous refractive surgery patients, particularly radial keratotomy," says Sydney Tyson, MD, MPH, of Wills Eye Hospital in Philadelphia. "The greatest patient benefit is probably knowing that you'll have the best result you can possibly have with a minimum amount of effort on both the surgeon's part and the patient's part," he says. "Right now, if patients pay a certain amount of money to get a certain result, it doesn't necessarily guarantee that outcome.

"Everyone is anatomically different, and there's a lot of variability in proper lens placement," Dr. Tyson continues. "If we can efficiently fine-tune a patient's vision postoperatively,

then we're not as dependent on theoretical formulas for lens power calculations. We don't really know where the lens is going to sit inside the capsular bag when we implant it—it could be a little anterior or a little posterior or even be tilted—and that'll change the patient's prescription, particularly with premium lenses, which magnify misses more than monofocal lenses.

“Classically, we would do adjustments by laser vision correction after the fact, or sometimes in extreme cases, a lens exchange,” Dr. Tyson explains. “But those are costly, and in the case of LASIK, you're working on the cornea to make adjustments. For lens exchanges, you have to go back into surgery, and it's another procedure with the risk of infection and the associated complications.”

Experts say there's still a significant percentage of patients with missed target refractions.² A 2018 multicenter data study of 282,811 cases reported to the European Registry of Quality Outcomes for Cataract and Refractive Surgery between January 2014 and December 2015 found that the biometry prediction error within 0.5 D was achieved in only 72.7 percent of the cases. A biometry prediction error within 1 D was achieved for 263,015 eyes (93 percent).³ The authors reported that risk factors such as poor preoperative CDVA, ocular comorbidity and previous eye surgery were related to poor refractive outcomes.

Similarly, a 2014 retrospective study of 1,275 cataract surgeries performed in 2010 at Massachusetts Eye and Ear Infirmary reported that 94 percent of cases (1,196 surgeries) achieved outcomes within 1 D of the target refraction.⁴ The authors note that the refractive outcomes at the academic teaching institution were higher than average international benchmarks.

From a market opportunity standpoint, adjustable IOL technology like Perfect Lens, which can adjust almost

any IOL, may become one of the biggest growth areas in ophthalmology, predicts Kevin M. Miller, MD, professor and Kolokotronis chair of ophthalmology at the David Geffen School of Medicine at UCLA, and member of the Stein Eye Institute. “I think there's a bigger potential for this technology than we saw with LASIK and PRK, because there are so many more people it would apply to. There are already millions of people in the United States with lens implants, and not all of them see perfectly. They can get glasses to correct their residual refractive errors, or they could have a noninvasive procedure to adjust their implants so they wouldn't have to wear glasses. If the cost wasn't too high—maybe the difference between a \$300 pair of glasses and a \$1,000 procedure—then many patients might opt for the procedure.”

IOLs Today

Current IOL technology still involves unwanted optical phenomena. Furthermore, surgeons must still estimate surgically-induced astigmatism, effective lens position and posterior corneal astigmatism. ASCRS points out that posterior corneal astigmatism is a significant knowledge gap in the field. According to the ESCRS 2018 Clinical Survey, only 65 percent of surgeons consider PCA in their toric power calculations.⁵ In the ASCRS 2018 Clinical Survey, 17 percent of respondents don't think it's clinically significant (versus 27 percent of non-U.S. respondents), 35 percent believe there's no good way of measuring it and 29 percent don't know how to calculate PCA or understand its significance.

As for intraoperative aberrometry, about 60 percent of respondents stated they have no plans to use it, and only 3 percent of respondents currently use it on all cataract patients.⁶

The Options: Modular IOLs

Modular IOLs include a base unit implanted in the capsular bag and an exchangeable optic. Changing out the optic to improve refractive accuracy requires an additional trip to the OR and a second incision. Modular IOL systems allow for adjustments of the optic throughout a patient's life. Toric optics can be rotated and realigned and multifocals can be exchanged for monofocals if patients fail to neuroadapt.⁷

Modular IOLs tend to be bulkier than traditional IOLs because they're a two-piece system, but surgeons can achieve a great deal of accuracy and predictability with modular IOLs because effective lens position isn't much of an issue, says Dr. Tyson. “We fill the bag completely with a silicone substance. When the lens is replaced, we know exactly where it is, as opposed to a traditional IOL, which could be in one spot or another, depending on where it finally ends up.”

Several modular IOLs are in development or currently available, like the Juvene (LensGen, Irvine, CA), a biomimetic device with the ability to change curvature to mimic the eye's natural lens, and the Harmoni Modular IOL (Alcon).

The Options: RxLAL

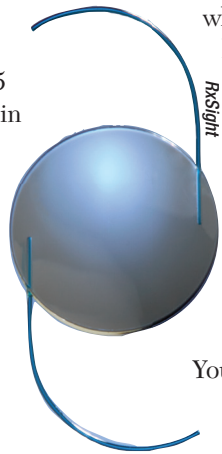
RxSight's RxLAL is currently the only FDA-approved light adjustable lens on the market. Its slit lamp-based light delivery device technology is built to adjust its own specialized IOL—a three-piece foldable silicone monofocal light-adjustable lens that's implanted through a 2.8-mm clear corneal incision with a proprietary injector.¹ The overall diameter is 13 mm with a 6-mm optic, squared posterior optic edges, round anterior edges, and blue poly(methyl methacrylate) modified-C haptics with posterior optic-haptic 10-degree angulation. The

IOL is available in powers from +10 to +30 D; in 1-D increments from +10 to +15 D and +25 to +30 D; and in 0.5-D increments from +16 to +24 D.² The IOL can be modified up to a total of 3 D of cylinder and 2 D of sphere.²

Vance Thompson, MD, of Vance Thompson Vision in Sioux Falls, South Dakota, one of the FDA-monitored sites for the RxLAL, says the light adjustable lens is ideal for those who aren't candidates for multifocality but want a premium lens, as well as for those who don't wish to risk glare and dysphotopsias and those who desire precision monovision or precise distance vision with reader glasses.

"Currently, we estimate the effective lens position and incisional healing in our calculations," Dr. Thompson says. "In addition to those two big variables, our inability to precisely measure posterior corneal astigmatism makes cataract surgery less accurate than we would like it to be. LASIK is often used for fine-tuning, but there are a lot of patients who'd rather have their optic fine-tuned than their cornea. Now, when we explain to patients why implants aren't as accurate as LASIK, we can offer them a new implant where final effective lens position and final astigmatism won't matter once healing has taken place, because for the first time ever, we can customize the power of the implant inside their eye to their desired vision for the remainder of their life."

The photoreactive silicone of the RxLAL has two unique features, explains Dr. Miller. "The first is the mobile molecules. You can think of the lens as 'half-baked'—it's not completely polymerized in the manufacturing process, so there's some silicone material that's not locked in. Most of the time,



The RxLAL is a three-piece, foldable silicone monofocal IOL.

when you bake silicone, you polymerize the entire thing and lock in the refraction, but for the RxLAL, about 10 percent of the lens isn't locked, and that 10 percent has a photosensitizer attached to it, so that when UV light hits it, it polymerizes. The second special feature is the heavy UV-blocking back layer. You don't want to shine intense UV light into the eye while treating this lens and cause retinal damage."

The light adjustments are done with a specific wavelength of UV light (365 nm).² Each light

treatment lasts approximately 20 to 30 seconds, depending on the type of treatment, while the final lock-in adjustment treatment is longer. "It's important that patients remain still and look straight ahead," Dr. Miller notes.

"The lens is implanted like any standard cataract lens," he continues. "It's silicone, so it's very springy inside the eye and opens up quickly. Once the lens finds a stable place in the eye a few weeks after surgery, the patient is placed in front of the light delivery device for adjustments and the final lock-in."

Doctors tend to feel comfortable with the RxLAL because it's implanted just like any other IOL, says Dr. Thompson. Similarly, the light adjustments function a bit like LASIK. "In laser vision correction, if we want to increase the power of the cornea, we treat the outside part of the cornea to bring more curvature to the center," he says. "With a light adjustable lens, to increase power, or lessen hyperopia or increase myopia, you illuminate the center of the lens by photopolymerizing the macromers in the center. When the unpolymerized macromers diffuse from the periphery to establish equilibrium, you get an increase in curvature in the center. If you want

to decrease power, or lessen myopia, you would treat the outside portion of the lens and photopolymerize those macromers so the unpolymerized macromers in the center will migrate toward the periphery, for a negative lens effect.

"You can also do this in a toric fashion," Dr. Thompson adds. "It's very specific math. Anything you can mathematically describe, you can do with light adjustability in a very accurate fashion. Once you achieve the desired power and the patient decides that's the vision they want, you irradiate the whole lens equally to consume all of the unpolymerized macromers and polymerize the lens. The lock-in is a power-neutral treatment and doesn't change anything."

Light Treatments

The RxLAL is FDA-approved for three or four light treatments over a one-to-two-week period 17 to 21 days after surgery.⁸ The RxLAL recipient is also required to limit his or her UV light exposure for the duration of the fine-tuning phase by wearing polarized UV-blocking glasses both indoors and outdoors to ensure the adjusted refraction isn't affected by ambient UV light.

"It's very important that patients wear their UV protective glasses, which come in both clear and sunglass options," says Dr. Thompson. "We start the adjustments at three weeks postop. Typically it's three adjustments, at least 48 hours apart, so you can pretty much do a full adjustment with a Monday, Wednesday, Friday schedule. Then there are two lock-ins in the following week, and it's finished."

Setting patient expectations is important for these adjustment visits—which some surgeons worry could be onerous—since these visits aren't brief. At each exam, patients will undergo refraction and measurements



“ I didn't realize
STARS
were little dots that twinkled ”

—Misty L, RPE65 gene therapy recipient

**WE'RE SEEING
AMAZING RESULTS.
AND SO ARE THEY.**

At the Foundation Fighting Blindness our mission is everybody's vision. Our work shines a light on the darkness of inherited retinal diseases (IRDs).

We're the world's leading organization searching for treatments and cures. We need your help to fuel the discovery of innovations that will illuminate the future for so many. We have robust disease information, a national network of local chapters and support groups, local educational events, and our My Retina Tracker® Registry to help keep your patients connected with clinical and research advancements.

Help accelerate our mission
by donating at ECPs4Cures.org.

**FOUNDATION FIGHTING
BLINDNESS**

FightingBlindness.org

before the adjustments and dilation for five visits. “You’re doing two- or three-hour visits, and you want to plan accordingly,” Dr. Thompson says. “At the same time, patients are getting the vision they want for the rest of their life with a procedure that doesn’t touch the cornea, and without the risks associated with LASIK or PRK. It’s amazing when you hit your true refractive endpoint.”

Benefits & Results

Surgeons familiar with the technology say that, in addition to the ability to fine-tune the postop refraction, the RxLAL offers some other benefits in terms of the mechanics of the procedure and the results.

- **Short learning curve.** Compared to PRK and LASIK, adjusting the RxLAL has a relatively small learning curve. “One of the things that intimidates doctors first getting involved in the premium lens journey is having a patient with leftover correction who isn’t fully satisfied and needs some fine-tuning on the cornea,” Dr. Thompson says. “[Laser refractive surgery] is a whole other discipline that a lot of doctors may not want to add, along with the expensive technology. With the RxLAL, it’s just your typical cataract surgery and typical postop care. Setting up a patient for the light-delivery device with a focusing lens on the cornea looks a lot like you’re getting ready to do a YAG laser. You center the beam, enter the correction into the computer and deliver it.”

- **Precision.** Yassine Daoud, MD, chair of ophthalmology at Howard County General Hospital and assistant professor of ophthalmology at Johns Hopkins University School of Medicine remarks that the RxLAL’s FDA clinical results were fairly comparable to the accuracy we see in LASIK and PRK. The Phase III FDA clinical study for the RxSight in subjects with pre-existing corneal astigmatism in-

cluded 600 patients, and 91.8 percent of patients achieved a result within 0.5 D of the target. “This is remarkable,” he says. “That’s 20 percent more within half a diopter [compared to the benchmark outcomes of 75 percent within 0.5 D].” All of the patients in the RxLAL study saw 20/40 or better postop uncorrected. This is comparable to surgeons’ results from LASIK in studies such as the FDA’s PROWL-I and -II.⁹

- **Long-term results.** While the RxLAL has been available in the United States only since 2017, it’s been available in Mexico and Europe since 2008. A study published this year in the *Journal of Cataract and Refractive Surgery* of a seven-year follow-up and clinical evaluation of the RxLAL after cataract removal found that the 61 patients (103 eyes) with the lens had stable refraction, good visual acuity and no IOL-associated pathologies. Additionally, the UV light exposure from adjustment and lock-in treatments wasn’t found to cause any additional endothelial damage.² Rabbit models irradiated at one, two, three and five times the expected maximum UV irradiation doses have shown no retinal toxicity after near-UV light exposure up to five times, which is the expected maximum light treatment dosage for adjustment and lock-in of the RxLAL.¹⁰

RxLAL Limitations

RxSight says it launched the RxLAL in about 30 sites across the United States. To date, the company says the light adjustable lens accounts for about half of the premium procedures performed at the sites. In addition to the usual issues with selling patients on premium lenses and their increased cost, surgeons note a couple other issues that might slow down widespread use of the lens.

- **All those postop visits.** One of the reasons posited as to why more

surgeons aren’t implanting the lens is that many of them worry that the number of follow-up treatments and time investment for patient and physician may be burdensome. “Our current IOL formulas achieve very reasonable outcomes,” Dr. Daoud says. “So why would a heavy-volume surgeon or any clinical specialist want to offer a procedure that may not be covered by insurance or would require a patient to wear sunglasses for a few weeks or return for four or six additional visits to fine-tune their prescription? In the meantime, we have ways of correcting significant residual refractive error with LASIK or PRK.”

- **Dilation requirements.** “You need to be able to dilate to 7 mm for the adjustment,” Dr. Thompson says. “And that’s to give you a little bit of insurance, if you will, because the beam we’re using to make the adjustment is 5.5 mm in diameter. So if the optic is perfectly centered on the pupil, 5.5 mm is all you need, but not everybody’s lens is centered perfectly in their pupil. We like them to be dilated to 7 mm so we can ensure that we’re going to be able to light-adjust the whole optic.”

“Sometimes, if there’s dilation fatigue, we use stronger drops or a pledget soaked in dilating drops,” says Dr. Thompson. “But if we got them to dilate to 7 mm in their consult, we’ll get them to dilate to 7 mm again; we just might have to work harder at it. I wouldn’t recommend using the RxLAL in a patient if you can’t dilate them pharmacologically to 7 mm. They wouldn’t be a good candidate.”

A possible solution would be to decrease the treatable area to 5 mm, suggests Dr. Miller. “If they made a 6-mm lens with a central 5-mm treatable area, we could treat more patients who have smaller pupils or dilation problems. There wouldn’t be as many molecules to move around, so you wouldn’t get quite the same amount of change in lens power and you might

lose a diopter or so, but there'd be many more small-pupil patients for whom you could implant the lens and offer treatment."

Future RxSight Developments

The current LAL technology is a one-time adjustment that's locked in, but a continuously adjustable option is possible. "It's called two-photon technology," Dr. Miller explains. "Right now, patients need to wear UV-blocking glasses so the atmospheric UV light doesn't affect the lens in their eye and adjust it in a random fashion. With two-photon technology, there would be two very specific wavelengths of light that hit the lens at the same time, which are, from my understanding, not available in sunlight, so patients wouldn't have to worry about refractive effects on their lens.

"In this scenario, you could implant someone with a LAL and bring them in for adjustment, adjust them, and then leave the rest of the molecules in the lens untouched and in reserve for a future treatment, if need be," he continues. "The current FDA approval is for the adjustments and permanent lock-in procedure, but future iterations of the RxLAL could include a continuously adjustable version."

The Options: Perfect Lens

Perfect Lens is a specialized femtosecond laser that can modify a standard hydrophobic acrylic lens that's already implanted inside the eye. Toricity, asphericity, spherical aberration and multifocality can be achieved in a brief office procedure, says the company. Additionally, the Perfect Lens technology can manufacture IOLs with customized prescriptions for patients *ex vivo*.

"Every year we do a survey from ASCRS and ESCRS, and what we've found is that the third most common reason for requiring an IOL exchange

is incorrect lens power," says Nick Mamalis, MD, ASCRS president and professor at the University of Utah School of Medicine. He's currently researching for Perfect Lens. "Even with improvements in measuring and calculating the implants, we still end up with refractive surprises. Perfect Lens will be a good way of correcting misses without having to exchange an IOL or put in a piggyback lens."

Use of femtosecond lasers to change refractive indices of materials has been studied for years.^{11,12} Along with ophthalmic inventor Stephen Q. Zhou, Perfect Lens executive vice president, COO and physicist Ruth Sahler and vice president and physicist Josef Bille discovered a process by which existing molecules within a polymeric material become hydrophilic inside an intraocular lens.¹³ When immersed in an aqueous medium and exposed to femtosecond laser radiation, polymeric material gains the ability to undergo a hydrophilicity-based refractive index change.¹⁴

The Perfect Lens technology has mainly been tested on hydrophobic acrylic, since it's the most widely-used material in lenses in the United States, but it could in theory work on hydrophilic acrylic, says Dr. Mamalis. At present Perfect Lens doesn't work on silicone, but Dr. Chu says it could be made to. "Right now, most of the work has been done on acrylics," he says.

Dr. Mamalis explains how the Perfect Lens laser technology works. "Perfect Lens is a type of femtosecond laser, but it has very low power and a very fine focus. The laser creates a focal change in the lens' hydrophilicity, so it doesn't change the surface of the lens, it changes its subsurface (50 microns below the surface)," he says. "Changing the hydrophilicity changes the refractive index of the lens itself in the focal area. We do this with a technique called phase wrapping. Instead of changing the entire curvature of the lens, we have concentric

rings of phase wrapping where a tiny change in the polymer itself creates a significant change in the power of the whole lens. So we're only treating a very small portion of the lens at a time, just underneath the surface."

Dr. Chu explains that treating the inside of the lens in different patterns modifies refractive error, astigmatism and multifocality. "It all depends on the pattern," he says. "One of the benefits is that this procedure doesn't affect the cornea. Your patient lies down and there's a cone that engages the eye. The laser is focused precisely into the lens. Performing a Perfect Lens procedure is very similar to LASIK in that it's kind of a one-shot procedure. There aren't any additional follow-up visits for fine-tuning adjustments."

An *in vivo* Perfect Lens treatment is a very brief procedure. "You dock the laser to the eye as if you were going to laser for cataract surgery, but achieving the amount of correction takes less than a minute or so," says Dr. Mamalis. "Maybe up to a minute and a half. It's not a long procedure. Theoretically it could be done in an outpatient surgical suite; you wouldn't have to go to the main operating room. The greatest patient benefit is the fact that you could correct their vision without having to resort to a secondary surgery. This would eliminate the need for IOL exchange, piggyback IOLs, or having to do a LASIK or PRK on the cornea to correct vision."

"I think the idea of a patient being able to 'try on multifocality' or 'try on reading vision' is pretty attractive," Dr. Chu says. "If a patient tries a multifocal lens, it's nice for him or her to know that there's a technology that could be used to modify the multifocality without having to go back inside the eye and to the OR."


Perfect Lens can lock-in a customized refraction for a patient, but that doesn't mean the patient must keep that vision for life. In theory, Perfect Lens technology might be able to

modify a lens up to 20 times, says Dr. Miller. “Light is applied to only a very thin sliver of the lens,” he says. “The treatment changes the structure of the acrylic molecules and thus the hydrophilicity of the material to either attract or repel more water in an infinitesimally small portion of the lens. At a later date, if a patient develops a refractive error, you could simply treat a different sliver of the lens—though you might have to keep track of which portion you’ve already treated, since you can’t treat the same sliver twice. To add or take away multifocality, you simply do the inverse of what you did previously, just like putting a +2 D lens in front of an eye with a -2 D lens. Since the average person lives 10 to 11 years after cataract surgery, you wouldn’t need to re-treat the lens too often. About two or three treatments would be good for life, if they’re needed at all.”

“On the bench and in the laboratory, we’ve been able to change the lens up to several diopters,” Dr. Mamalis says. “The adjustments made are within a tenth of a diopter of the intended correction.¹⁵ It’s very precise.” For the experimental study of femtosecond laser-created refractive lenses, the Perfect Lens study group used a standard hydrophobic model (EC-1Y), a femtosecond laser, an acoustic-optic modulator, beam-shaping optics, a scan system and an objective lens to create the refractive index change within the IOL. Building a refractive index shaping lens within an IOL using a femtosecond laser lets the IOLs refractive properties be altered.¹⁵ Studies on rabbit models, specifically pigmented rabbits, showed no signs of retinal toxicity or corneal or endothelial damage.¹⁶ Perfect Lens is approaching human trials soon.

Will Biometry Still Matter?

With new technology for modifying refraction postoperatively and poten-



With phase wrapping, a refractive index-shaping lens is treated inside an existing, implanted IOL. By targeting slivers of concentric rings, the laser (green) polymerizes the lens’ subsurface, changing the lens’ hydrophilicity and refractive index.

tially eliminating refractive surprises, some wonder what effect this will have on the perennial cycle of innovation in preop biometry, but surgeons say that biometry is still key to accurate IOL implantation. “We might be reaching the limits of what biometry can do,” notes Dr. Chu. “Biometry has improved so much recently.”

“Biometry won’t become obsolete because we still need to get into the general ballpark for IOL power,” Dr. Tyson says. “You have to know where to shoot so you can minimize the amount of adjustment afterward.”

“Postoperative lens adjustments will complement biometry,” adds Dr. Mamalis. “It’s not like you’re going to put a 20-D lens in everybody and just correct it. Get as close as you can with biometry, and if there’s a significant refractive error left after the eye’s healed from surgery, then this technology could adjust that.”

Dr. Miller predicts a slow end to biometry innovation if technologies like RxLAL and Perfect Lens come into wide use. “I don’t think the light adjustable lens is going to be the end, since it’s not continuously adjustable right now. For the Perfect Lens, if this can be turned into a continuous treatment throughout a patient’s life, it’ll depend on how much lens change can

be achieved. Super-accurate formulas would then become superfluous—just get it close enough and adjust from there once the patient has reached refractive stability. Biometry just won’t need to be super accurate.” **REVIEW**

Drs. Tyson and Daoud have no financial disclosures. Dr. Miller has no financial relationships but notes that he was an investigator for RxSight (when it was Calhoun Vision). Drs. Mamalis and Chu are on the Perfect Lens scientific advisory board. Dr. Thompson discloses relationships with RxSight, Alcon and Johnson & Johnson.

1. Chang D. Disruptive innovation and refractive IOLs: How the game will change with adjustable IOLs. *Asia-Pacific J Ophthalmol* 2019;8:6:432-435.
2. Schojai M, Schultz T, Schulze K, et al. Long-term follow-up and clinical evaluation of the light-adjustable intraocular lens implanted after cataract removal: 7-year results. *J Cataract Refract Surg* 2020;46:8-13.
3. Lundström M, Dickman M, Henry Y, et al. Risk factors for refractive error after cataract surgery: Analysis of 282,811 cataract extractions reported to the European Registry of Quality Outcomes for cataract and refractive surgery. *J Cataract Refract Surg* 2018;44:447-452.
4. Simon SS, Chee YE, Haddadin RI, et al. Achieving target refraction after cataract surgery. *Ophthalmol* 2014;121:440-444.
5. ESCRS Clinical Results Survey: 2018 Results. Accessed March 3 2020. <https://www.eurotimes.org/wp-content/uploads/2019/11/Clinical-Survey-Results-2018-12pp-Supplement-press.pdf>.
6. ASCRS Clinical Results Survey: 2018 Results. *EyeWorld Supplements*. Accessed March 3 2020. <file:///Users/cleonard/Downloads/ascrs-clinical-survey-2018.pdf>.
7. Werner L. The Harmoni Modular IOL System. *Cataract and Refractive Surgery Today* 2018. Accessed March 4 2020. <https://crstoday.com/articles/2018-may/the-harmoni-modular-iol-system/>.
8. FDA approves first implanted lens that can be adjusted after cataract surgery to improve vision without eyeglasses in some patients. FDA.gov Press Release. Accessed 2 March 2020. <https://www.fda.gov/news-events/press-announcements/fda-approves-first-implanted-lens-can-be-adjusted-after-ataract-surgery-improve-vision-without>.
9. Eydelman M, Hilmantel G, Tarver ME, et al. Symptoms and satisfaction of patients in the Patient-Reported Outcomes With Laser in situ leratomiileusis (PROWL) Studies. *JAMA Ophthalmol* 2017;135:1:13-22.
10. Werner L, Chang W, Haymore J, et al. Retinal safety of the irradiation delivered to light-adjustable intraocular lenses evaluated in a rabbit model. *J Cataract Refract Surg* 2010;36:8:1392-7.
11. Ohmachi Y, Igo T. Laser induced refractive-index change in As-S-Ge glasses. *Appl Phys Lett* 1972;20:12:506-508.
12. Ding L, Blackwell R, Kunzler JF, et al. Large refractive index change in silicone-based and non-silicone-based hydrogel polymers induced by femtosecond laser micro-machining. *Opt Express* 2006;14:24:11901-11909.
13. Sahler R, Zhou SQ, Bille JF. Hydrophilicity alteration system and method. US Patent 9186242B2 (2015).
14. Bille J, Engelhard J, Volpp H-R, et al. Chemical basis for alteration of an intraocular lens using a femtosecond laser. *Biomed Opt Express* 2017;8:3:1390-1404.
15. Sahler R, Bille JF, Enright S, et al. Creation of a refractive lens within an existing intraocular lens using a femtosecond laser. *J Cataract Refract Surg* 2016;42:8:1207-1215.
16. Werner L, Ludlow J, Nguyen J, et al. Biocompatibility of intraocular lens power adjustment using a femtosecond laser in rabbit model. *J Cataract Refract Surg* 2017;43:8:1100-1106.

Daring to Treat Floaters

Sean McKinney, Senior Editor

More experts are taking a second look at controversial approaches to resolving these visual disturbances.

Call it a case of mounting evidence eating away at popular wisdom. The use of YAG laser vitreolysis and vitrectomy to treat vitreous floaters has always seemed nearly off-limits to most right-thinking ophthalmologists. But more retinal specialists and some anterior segment surgeons are moving away from blanket views of pathologies, learning more about the nuances of these visual disturbances and intervening with improved techniques and technologies when treatment seems necessary.

In this report, they share their reasons and strategies—and precautions to take to ensure that you proceed with care.

Considering Vitrectomy

Retinal specialists say vitrectomy remains the conventional—if not widely used—treatment for vitreous floaters. Before deciding to operate, they continue to carefully consider risks for complications, such as cataract formation, glaucoma, endophthalmitis, retinal tears, retinal detachment, hypotony, choroidal effusion, suprachoroidal hemorrhage, vitreous hemorrhage, cystoid macular edema, optic neuropathy and phototoxicity.^{1,2,3} With these assessments in mind, Chicago retinal specialist Jennifer Lim, MD,

says she always takes a hard look at the need for treatment when responding to the many patients who come to her with complaints of vitreous floaters, including high myopes and those with a history of vitreous detachments.

“The patients I treat with vitrectomy have chronic floaters that haven’t abated, usually for at least four months,” says Dr. Lim, Marion H. Schenk chair in ophthalmology, director of the retina service and vice-chair for diversity and inclusion at the University of Illinois-Chicago College of Medicine. “I first want to make sure they’re not accommodating to their symptoms. I also want to find out if the floaters are affecting their adult activities of daily living, such as causing difficulty reading or driving. For extremely troubled patients who report symptoms that haven’t necessarily been in concert with my exam findings, I’ve asked them to undergo psychological assessments to confirm that they’re not affected by anxiety disorders or some form of psychological condition.”

Dr. Lim points out that some patients with chronic vitreous floaters or large Weiss rings can’t perform their jobs, especially when sharp vision is needed. Multiple floaters in the mid to posterior vitreous can cause difficulty in reading, driving, computer

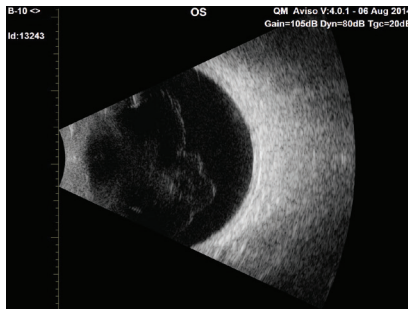


Figure 1. Ultrasound of central vitreous opacities and PVD.

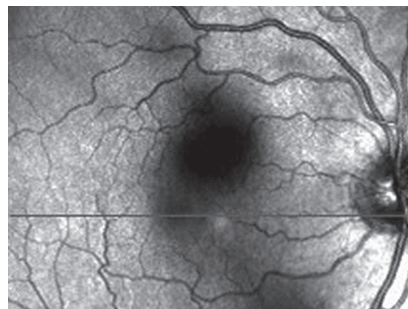
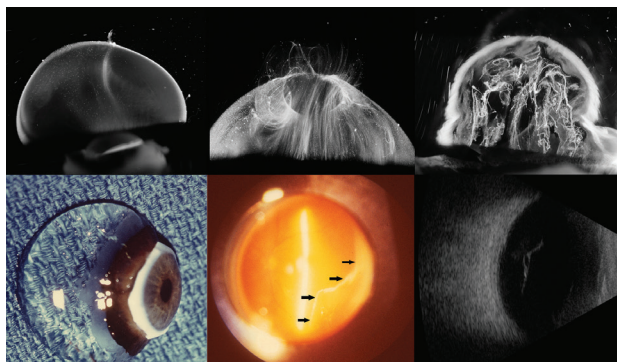


Figure 2. Scanning laser ophthalmoscopy image of vitreous opacities causing vision-degrading myodesopsia.

Figure 3. Top row: Vitreous images showing, left to right, aging changes from youth to middle age to old age.

Bottom row: From left to right, young vitreous, PVD and ultrasound of PVD with Weiss ring.

(Sebag J. Vitreous and Vision Degrading Myodesopsia. *Prog Ret Eye Res* 2020 Mar 6:100847. (in press))



usage and concentration, she notes.

“These are the patients I will operate on,” she notes. “As a retinal specialist, I’ve done a lot of vitrectomies. Admittedly, though, I haven’t done a lot of “floaterectomies.” But I’m now more amenable to doing them than I was three years ago. When indicated, the procedure is extremely gratifying and helpful to the patient. In fact, I just did one of these procedures yesterday.”

To qualify a patient for this surgery, Dr. Lim has learned to use objective data, borrowing from some of the techniques developed by Jerry Sebag, MD, FACS, senior research scientist, Doheny Eye Institute/UCLA and professor of clinical ophthalmology, at UCLA’s David Geffen School of Medicine. Dr. Sebag, also founding director of the VMR Institute for Vitreous Macula Retina in Huntington Beach, California, has advanced the use of pars plana vitrectomy to treat visually-significant vitreous opacities that create what he calls the “visual

phenomenon of floaters”—but only in clinically significant cases, which he describes as vision-degrading myodesopsia.⁴

He says he uses the National Eye Institute Visual Function Questionnaire, followed by a vitreous floaters functional questionnaire he has developed that’s “more specifically related to the impact of floaters on patients’ well-being and quality of life.”⁵ Dr. Sebag explains that he also measures contrast sensitivity function to identify patients who might benefit from a vitrectomy. He and other researchers have discovered that opacities in the vitreous body following PVD in older patients and in association with myopic vitreopathy in younger patients degrade the contrast sensitivity function by an average of 91 percent.^{6,7,8,9}

Dr. Sebag says he also relies on the “overlooked” value of ultrasonography, which he says can identify structures in the vitreous that help explain degradation of the contrast sensitivity function and the patient’s level

of unhappiness and poor quality-of-life.^{10,11,12}

“When findings are abnormal, I’m comfortable clearing patients for symptom-remediating surgery and recommending vitrectomy,” states Dr. Sebag.

The “flip side” of using these measures is that this approach can be used to confidently rule out treatment for patients, he notes. “Lots of people have floaters, but fewer have vision-degrading myodesopsia,” he says. “I can legitimately tell a patient, ‘Your case is not sufficiently severe for therapy because your contrast sensitivity function is not as bad as what we usually see in patients who do need therapy.’” (Dr. Sebag explains his approach in “Straight from the Cutter’s Mouth: A Retina Podcast,” Dec. 12, 2017, linked here by permission of the publisher: retinapodcast.com/episodes/2017/12/12/episode-78-vision-degrading-vitreopathy-with-dr-jerry-sebag)

Documenting Floaters

Like Dr. Sebag, Dr. Lim uses contrast sensitivity testing to determine if a patient may be a candidate for a vitrectomy. “It’s helpful that we can actually document the effects of vitreous floaters in these ways,” she says. “I seriously consider treating patients who are significantly bothered by cloudy floaters, especially when their posterior hyaloid face is thickened or partly opacified, causing them to experience a film over their vision that won’t go away.”

So far, she says she’s avoided complications in patients she’s treated. “During the past five years, in the fewer than 10 floaterectomies that I’ve performed, no patient has developed cataracts,” she says. “Keep in mind these patients tended to be on the younger side. And if they’re older, many have already had their cataracts removed.” Every case is an exercise in

caution, she notes, especially for high myopes, who are at increased risk of retinal tears and detachments.

“When you’re trying to induce a PVD intraoperatively, you risk inducing tears at the vitreous base, along with a retinal detachment,” she says. “But fortunately I haven’t had any cases of postop endophthalmitis, or any tears or retinal detachments inter-operatively.”

Dr. Lim believes that YAG laser vitreolysis, the only alternative to vitrectomy and observation, may be worth exploring because of the recent promise it’s shown.^{13,14} “If we had a YAG laser in our office, I might consider trying it on an ideal patient, such as one who has had cataract extraction and who has a Weiss ring,” she says. “I wouldn’t use the laser for small floaters. I’m still dubious about the laser to some extent, though, because it creates lots of tiny floaters.”

Clarifying Floaters

One of the challenges of floaters is understanding their diverse levels of significance, according to Chirag Shah, MD, MPH, a partner at Ophthalmic Consultants of Boston. “Floaters can appear as rings, wisps, sheets, squiggles or other patterns in the central or peripheral vision, varying widely in terms of how they affect patients and how clinicians respond to them,” he says.

When evaluating vitreous floaters, Dr. Shah rules out retinal tears, hemorrhage, inflammation and other pathologies that could be at the root of the problem. He also makes sure the floaters match the symptoms his patient reports. “A discrepancy between what I see and what the patient expresses might indicate that the patient is overreacting to his floaters and, thus, might not be a good candidate for treatment,” he says.

If a patient reports significant floaters that correlate with symptoms—

and the patient is sufficiently bothered by the floaters—Dr. Shah follows the patient closely. “I tell the patient that, over time, the brain can often adapt and ignore those floaters. This approach is, by far, the safest option for floaters.”

He notes that most of his patients neuroadapt and cope with the floaters, prompting him to monitor them in the long term. “I try to reassure these patients,” he adds. “It’s very uncommon that I recommend further treatment for floaters, such as a YAG laser treatment or vitrectomy.”

Beyond Reassurance

Dr. Shah takes a different course when he determines that patients are coping with very bothersome symptoms. “Again, the appearance of their floaters has to match their symptoms,” he says. “We discuss the options of observation, YAG laser vitreolysis and vitrectomy. If they have discrete floaters that continue to disrupt their lives, such as a Weiss ring, I’ll refer them for YAG vitreolysis.”

Sheets of floaters, diffuse floaters and excessive numbers of tiny floaters also pose a challenge that may require a vitrectomy. Dr. Shah turns to vitrectomy only two or three times a year for vitreous floaters. “I emphasize the downsides to the patient, such as a guaranteed risk of cataract formation and a small but real risk of a retinal tear and retinal detachment, as well as risks of infection, bleeding and anesthesia,” he says. “I send them home with literature and tell them to do their homework so that they know what they are getting into. If you can avoid doing a vitrectomy and satisfy a patient with YAG vitreolysis, that is by far the safer way to go.”

Dr. Shah recently joined one of his partners, Jeffrey Heier, MD, to oversee a six-month randomized controlled trial of 52 patients who either underwent YAG laser vitreolysis or

weren’t treated.¹⁴ “There was no risk of infection, and only a very low risk of elevated intraocular pressure in patients treated with YAG vitreolysis,” he says. “There was also a low risk of worsening floaters by fragmenting them into smaller pieces with the laser, instead of vaporizing them. It’s important to emphasize that the risks were less than the risks of vitrectomy.”

The risks of YAG vitreolysis include glaucoma, retinal tear, retinal detachment, cataract from striking the lens with the laser and retinal damage from striking the retina, says Dr. Shah. To minimize risks of lens or retinal damage, he recommends ensuring a safe distance between the focal point of the laser and the retina and crystalline lens. In his study, he required the Weiss ring floater to be 5 mm posterior to the posterior capsule of the crystalline lens and 3 mm anterior of the retina, as measured by B-scan.

Bullish on Vitreolysis

I. Paul Singh, MD, a glaucoma and anterior segment specialist in Racine, Wisconsin, has offered laser vitreolysis to dozens of unhappy patients. He accepts referrals from Dr. Shah in Boston, as well as from referring physicians all over the world.

“If a patient isn’t a good candidate for a vitrectomy, then vitreolysis can be a good option,” says Dr. Singh, president of the Eye Centers of Racine and Kenosha. He performs about 10 YAG laser vitreolysis procedures per week, in addition to his 25 cataract surgeries and regular visits with glaucoma patients. “In the case of a Weiss ring, for example, laser floater treatment can be fantastic,” he continues, noting that this treatment typically involves an average of only 1.2 sessions. “We’ve found more than 90 percent of patients who undergo this treatment are very happy. Surgeons can easily identify good candidates and correlate signs and symptoms. If, for example, a

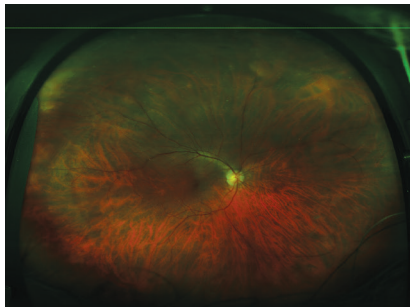


Figure 4. Fundus photo showing floaters prior to YAG laser vitreolysis.

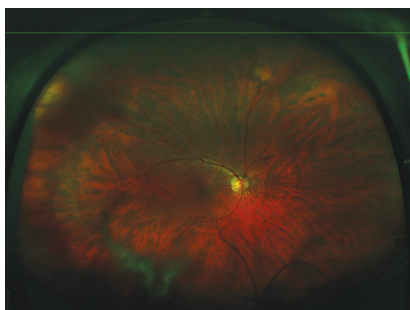


Figure 5. Six months after YAG laser vitreolysis, the patient's myopic vitreopathy progresses, with worsening floaters. A fluffy caterpillar-like floater in the inferior vitreous cavity, or a so-called "floater duet," is shown.

patient has a solitary lesion, an opacity, such as Weiss ring, or a mass, the laser can help, especially for patients who are phakic or pseudophakic and who don't want to undergo a vitrectomy."

Dr. Singh says YAG laser vitreolysis poses "very low relative risks," noting that, in one series of 1,264 cases, he recorded an adverse event rate of 0.8 percent, which included seven IOP spikes, two phakic lenses that were struck by the laser and one retinal hemorrhage.

"Four patients had a history of uveitis that didn't worsen and 27 had diabetic retinopathy and didn't develop macular edema," he notes. "Four patients developed vitreomacular traction that resolved immediately."

Enough Evidence?

Despite these positive results, many leading retinal specialists say claims

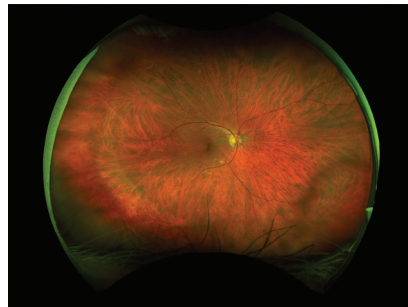


Figure 6. The patient elects to undergo pars plana vitrectomy, after which he reports 100-percent improvement in his floaters.

that YAG laser treatments can resolve floaters remain to be substantiated and that, currently, only vitrectomy has any proven value.^{15,16} Dr. Singh says he's well-acquainted with this perception. "The problem is that, until recently, we didn't have great technology to more efficiently and safely take care of significant vitreous floaters," he notes. "The conventional YAG lasers that we used in the past were designed for posterior capsulotomy and iridotomy treatments. They provided a limited view of the posterior vitreous, making it difficult to identify floaters and membranes to target. The risk of damage to surrounding ocular tissue is also greater if you're not able to visualize the posterior vitreous."

He notes that conventional YAG lasers have had non-coaxial illumination towers, which provided illumination from a source that was different than the optical system. "The light was oblique and, as a result, we couldn't see behind the capsule very well. Identifying many of the clinically significant and symptomatic floaters wasn't possible."

Another limiting factor of conventional lasers was that energy delivery wasn't optimized, he adds. "The laser used now has a truncated energy beam," he points out. "So, less energy is needed to create optical breakdown. In general, the previous studies done on YAG vitreolysis were done with energy settings that were entirely too

low," he continues. "We're talking about 1 mJ or 2 mJ. You can actually go up to 4 mJ, 5 mJ, 6 mJ or even 7 mJ, depending on where a floater is located. Also, the previous laser treatments were done with 20, 30, 40, 50, 60 or 100 shots. Often, you actually need to use 400 or 500 shots, depending on the floater itself. So people who have some skepticism about the YAG laser for treatment of vitreous floaters seem to be clinging to concerns from many years ago. Recently, we've presented a lot of compelling data on safety and efficacy at the AAO and ASCRS meetings."

Cutting-edge Vitrectomy

Dr. Sebag, the West Coast clinician and researcher who introduced contrast sensitivity function testing and ultrasonography to the preop assessment of potential vitrectomy patients, doesn't refer his patients for YAG laser vitreolysis treatment. But he does use vitrectomy more aggressively than most. When deciding to operate, he says he takes careful steps to minimize risk and complications. The surgery is performed at an ambulatory surgery center under retrobulbar anesthesia. The concept of "less is more" is the guiding principle of the intervention.

"I use a 25-ga. instrument, since I don't see any advantage to 27-ga. instruments in this setting," he says. "The procedure is sutureless. Two aspects of the vitrectomy are especially important. First, I don't induce a surgical PVD in an individual who doesn't already have one, in order to prevent an increased risk of iatrogenic retinal tears, but also to avoid increasing intravitreal pO₂ levels too much. Studies show that following PVD, pO₂ levels rise, and that's what contributes to lens opacification and cataract formation.¹¹

Second, I leave 3 or 4 mm of gel vitreous intact behind the lens. This is because vitreous contains antioxidants that mitigate the effects of reactive

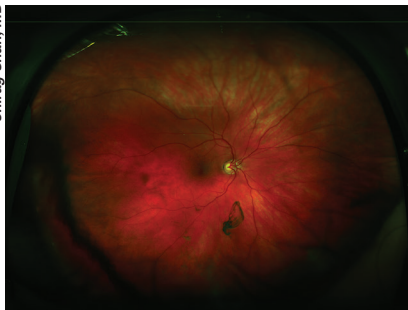

Figure 7. A Weiss ring before it's treated with YAG laser vitreolysis.

oxygen species that induce the cross-linking and protein aggregation in the crystalline lens that lead to cataract formation.”¹¹

Studies have shown that the incidence of post-vitreotomy cataract surgery is markedly lower following a limited vitrectomy as opposed to extensive vitrectomy with PVD induction—as low as 16.9 percent with an average follow-up of 32 months, Dr. Sebag notes.^{6,12}

“To minimize risks, I’ve employed a limited vitrectomy,” continues Dr. Sebag. “Some would call it a core vitrectomy. Basically, I remove the central vitreous that contains the opacities. In some individuals, the posterior vitreous contains opacities. And I do go down close to the fundus, which is also very important to characterize preoperatively with ultrasound and OCT, showing me what’s going on in the preretinal posterior vitreous that may require attention.

I have about three or four dozen patients in their 20 and 30s, myopes who have myopic vitreopathy in the posterior vitreous, which is the cause for their vision-degrading myodesopsia. They’ve all done very well without forming cataracts now, six to seven years after their procedures.”

Minimizing Iatrogenic Breaks

When evaluating the data from some 200 of these cases, Dr. Sebag says about 22 percent underwent la-

ser or cryoretinopexy three months preoperatively. “When I recognize lattice with erosions or holes or other lesions that I think would put the patient at too much risk for a vitrectomy, we’ll offer them preop prophylactic treatments,” he notes. “I think that has resulted in our low, 1.5-percent incidence of postop retinal tears and detachments.”

That said, Dr. Sebag offers this precaution: “Prophylactic laser isn’t necessary on every patient. Just a careful peripheral fundus exam with scleral depression is enough to identify cases that need prophylaxis.

“I don’t use the YAG laser to treat vitreous opacities, as there are no studies to date that prove efficacy,” he adds, “although the most recent study suggests that a prospective randomized trial using objective quantitative outcome measures is warranted.”^{9,17,18}

New Possibilities


Ophthalmologists expect to keep pushing the envelope on vitreous floaters. Concern over quality of life and the increasing reach of therapeutic approaches will drive change.

“One recent experience I had with a patient demonstrates at least one example of new ways to respond to floaters,” says Dr. Shah in Boston. (See Figures 3, 4 and 5 on page 60.) “The patient had floaters that I tried to treat with YAG laser vitreolysis in our clinical trial. His myopic vitreopathy progressed, and he developed worse floaters.”

Next, Dr. Shah says he offered to perform a vitrectomy on the patient, which helped clear his floaters and left him completely satisfied. “I don’t think we lose much, if anything, by trying this type of step-wise approach, from observation to YAG vitreolysis to vitrectomy,” he concludes. “Managing floaters is different than it used to be.” **REVIEW**

Dr. Lim is involved in grants/research for Genentech, Regeneron, Graybug, Stealth, Chengdu Kanghong and Alderya. She’s a consultant for Novartis, Ophthea, Aura Biosciences and Santen, and she receives honoraria for meetings from Alcon and Allergan. Dr. Sebag is a former consultant to ThromboGenics, Johnson & Johnson and Roche. Dr. Shah provides speaking and research services to Ellex. Dr. Singh is a consultant for Ellex, Allergan, Alcon, B+L, Aerie, Ivantis, Sun, Shire, New World Medical, SenSimed and Zeiss.

- Stein JD, Zacks DN, Grossman D, et al. Adverse events after pars plana vitrectomy among medicare beneficiaries. *Arch Ophthalmol* 2009;127:12:1656-63.
- Day S, Grossman DS, Mruthunjaya P, et al. One-year outcomes after retinal detachment surgery among medicare beneficiaries. *Am J Ophthalmol* 2010;150:3:338-45.
- Chang S. LXII Edward Jackson lecture: Open angle glaucoma after vitrectomy. *Am J Ophthalmol* 2006;141:6:1033-1043.
- Sebag J. Vitreous and Vision Degrading Myodesopsia. *Progr Ret Eye Res* 2020; March [Epub ahead of print]
- Sebag J. Floaters and the quality of life. (Guest Editorial) *Am J Ophthalmol* 2011; 152:3-4.
- Sebag J, Yee KMP, Nguyen JH, Nguyen-Cuu J: Long-term safety and efficacy of vitrectomy for vision degrading myodesopsia from vitreous floaters. *Ophthalmology Retina* 2018;2:881-7.
- Garcia G, Khoshnevis M, Yee KM, Nguyen-Cuu J, Nguyen JH, Sebag J. Degradation of contrast sensitivity following posterior vitreous detachment. *Am J Ophthalmol* 2016; 172:7-12.
- Garcia G, Khoshnevis M, Nguyen-Cuu J, Yee KMP, Nguyen JH, Sadun AA, Sebag J. The effects of aging vitreous on contrast sensitivity function. *Graefes Arch Clin Exp Ophthalmol* 2018; 256:919-25.
- Milston R, Madigan M, Sebag J. Vitreous floaters: Etiology, diagnostics, and management. *Surv Ophthalmol* 2016;61:2:211-27.
- Mamou J, Wa C, Yee K, Silverman R, Ketterling J, Sadun A, Sebag J. Ultrasound-based quantification of vitreous floaters correlates with contrast sensitivity and quality of life. *Invest Ophthalmol Vis Sci* 2015;56:1611-7.
- Ankamah E, Sebag J, Ng E, Nolan JM. Vitreous antioxidants, degeneration, and vitreo-retinopathy: Exploring the links. *Antioxidants* 2019;9:1.
- Yee KM, Tan HS, Lesnick-Oberstein SY, Filas B, Nguyen J, Nguyen-Cuu J, Sebag J. Incidence of cataract surgery after vitrectomy for vitreous opacities. *Ophthalmology Retina* 2017;1:154-7.
- Lim JI. YAG laser vitreolysis-Is it as clear as it seems? Comment on YAG Laser vitreolysis vs sham YAG vitreolysis for symptomatic vitreous floaters: A randomized clinical trial. [*JAMA Ophthalmol* 2017] *JAMA Ophthalmol* 2017;135:9:924-925
- Shah CP, Heier JS. Long-term follow-up of efficacy and safety of YAG vitreolysis for symptomatic Weiss ring floaters. *Ophthalmic Surg Lasers Imaging Retina*. 2020 1;51:2:85-88.
- Kokavec J, Wu Z, Sherwin JC, et al. Nd:YAG laser vitreolysis versus pars plana vitrectomy for vitreous floaters. *Cochrane Database Syst Rev* 2017:1:6.
- Milston R, Madigan MC, Sebag J. Vitreous floaters: Etiology, diagnostics, and management. *Surv Ophthalmol*;61:2:211-27.
- Sebag J. Methodological and efficacy issues in a randomized clinical trial investigating vitreous floater treatment. *JAMA Ophthalmol* 2018;136:4:448.
- Nguyen JH, Nguyen-Cuu J, Yu F, Yee KM, Mamou J, Silverman RH, Ketterling J, Sebag J. Assessment of vitreous structure and visual function after Nd:YAG laser vitreolysis. *Ophthalmology* 2019;126:11:1517-26.



Tubes, Trabs and Cataract Surgery

Glaucoma patients often present extra challenges during cataract surgery. An expert offers helpful strategies.

Constance Okeke, MD, MSCE, Norfolk, Virginia

Performing cataract surgery on glaucoma patients often involves challenges beyond those we'd encounter with a healthy patient. That's especially true if the patient has a pre-existing trabeculectomy or tube shunt. To achieve a successful outcome with these patients we need to devote more time and thought to the surgery, and utilize more of our intraoperative skills.

The potential problems associated with performing cataract surgery on a glaucoma patient are typically the result of anatomical factors. For example, previous inflammatory episodes may have left the pupil reluctant to dilate, possibly with posterior and/or anterior synechiae. An overhanging bleb sometimes obscures our view, requiring us to change our incision sites and possibly necessitating the removal of excess bleb tissue. If a tube is present, its position can be problematic; it may be affecting the cornea or cataract, and it may interfere with our view during the procedure. (In some cases, we may be able to work around the tube; in some cases we may need to shorten it.) (See examples, facing page.)

These eyes also have more postoperative issues than a healthy eye would. Postoperative inflammation is not uncommon, and that can lead to bleb failure. It can also cause postop pressure spikes, resulting in the need for more glaucoma medications. One study found that patients who had prior functional blebs undergoing even uncomplicated cataract surgery could see intraocular pressure rise by 3 mmHg.¹

The message is clear: Operating on a patient with glaucoma isn't your typical cataract surgery. Here, I'd like to offer some suggestions for steps you can take that will help to ensure an optimal outcome when working with one of these patients.

Before the Surgery

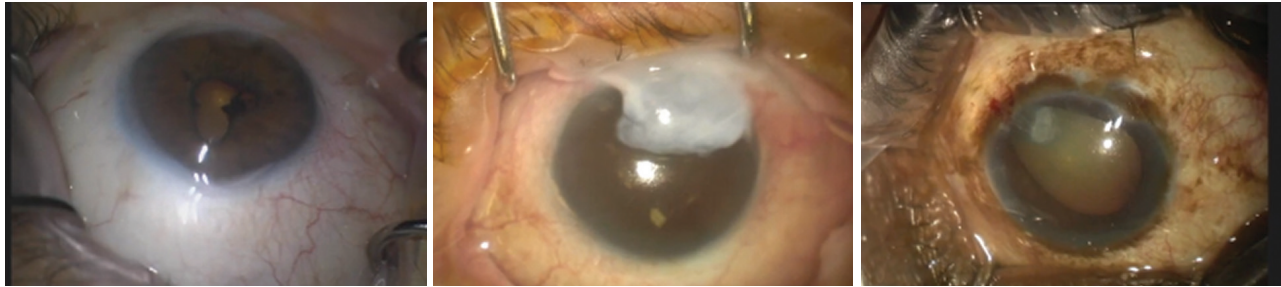When you realize you're examining a cataract patient who has either a tube shunt or a trabeculectomy bleb, you should consider several issues:

- **What's the stage of the disease?** Many choices you need to make will be based around whether the disease is controlled or uncontrolled. For example, if the patient is on one or

more medications and the angle anatomy is clearly open, especially nasally, one could consider combining the cataract extraction with a minimally invasive glaucoma surgery to gain additional IOP lowering and potentially reduce the need for medications. The stage of the disease (mild, moderate or severe) can help dictate which MIGS procedure one should choose.

- **Check the angle with gonioscopy.** This may reveal a specific problem that's contributing to uncontrolled IOP. For example, if you see appositional angle closure with peripheral anterior synechiae, this can alert you to the need to combine the cataract surgery with goniosynechiolysis. (You'll find a video that describes this technique at the following link: aao.org/annual-meeting-video/role-of-goniosynechiolysis-trabecular-bypass-proce.)

- **Look carefully at the condition of the cornea and the pupil.** If the corneal endothelium has significant guttata, as in Fuchs' Dystrophy, one can make additional efforts to protect the cornea intraoperatively with



Challenges you may encounter when performing cataract surgery on a glaucoma patient are frequently anatomical. They include poor pupil dilation as a result of previous inflammatory bouts (above, left); an overhanging bleb that obscures the surgeon's view (center); and issues relating to the position of a tube shunt (right).

extra use of a dispersive viscoelastic; you should also counsel the patient preoperatively on the potentially longer time for corneal healing and visual recovery. Additionally, if the pupil shows signs of irregularity and poor dilation, you should plan for the possibility of needing extra steps to achieve pupil expansion intraoperatively.

- **Consider adding a MIGS procedure to the cataract surgery.** Although this might not make sense for every patient with a tube or bleb, many patients would benefit from additional IOP lowering, as noted above, and studies have confirmed that this can happen when a MIGS procedure is performed after a tube shunt or trabeculectomy.^{2,3} A MIGS procedure can also help to stabilize eye pressure and limit the possible pressure spikes that can occur following this type of surgery in these patients. In addition, many patients would be grateful for being able to use fewer drops every day, a common benefit of MIGS.

When deciding whether to add a MIGS procedure, three factors are key:

- *Is the pressure currently controlled?* If not, adding a MIGS procedure makes very good sense.

- *If the pressure is under control with medications, how many medications is the patient using?* If the number of drops is minimal, there may be less need for adding a MIGS

procedure. On the other hand, if the patient is taking multiple drops every day, that's a good reason to consider the benefit of adding a MIGS procedure.

- *Does the eye have at least 180 degrees of viable angle tissue available for the MIGS procedure?* Without this condition, many MIGS procedures would be off the table.

In terms of which MIGS to consider, I've used various procedures, including goniotomy procedures such as Trabectome, Kahook Dual Blade and gonioscopy-assisted transluminal trabeculotomy, stents (including iStent and Hydrus), canaloplasty such as ABiC with iTrack, and conjunctival stents like the Xen. I've seen good eye pressure reduction with all of them. I've also had success combining canaloplasty and goniotomy procedures, as in the Omni procedure. In short, you have many options to consider that can potentially help your patient.

- **Make sure the patient has realistic expectations.** Patients with a pre-existing tube or trab may assume that their cataract surgery outcome will be the same as their friends' outcomes, when in fact their situation is considerably more complex. (The worst scenario is a patient who's 20/20 but is still unhappy because he thought the visual difficulties caused by the glaucoma were going to be eliminated by the cataract surgery.)

To avoid an unhappy patient

postop, I recommend:

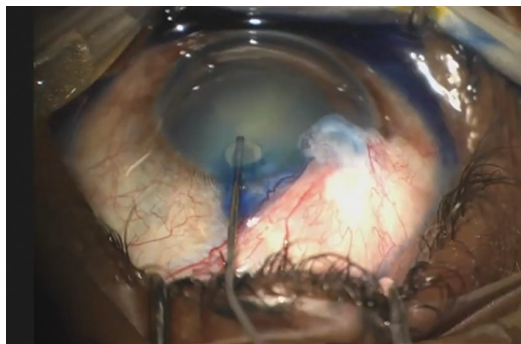
- *Always show the patient his or her visual field preoperatively.* This helps to drive home the reality that the patient has problems that cataract surgery can't correct.

- *Discuss the possibility that the patient may need fewer glaucoma medications, especially if you're adding a MIGS procedure.* This benefit may help offset any dismay the patient feels after learning that the surgery won't cure the glaucoma.

- *Explain that the prior glaucoma surgery could fail.* While this may be unlikely, it's better to warn the patient that it's within the realm of possibility. Also, be sure to explain that additional steps may be required intraoperatively and postoperatively in the unlikely event that this should occur.

- **Choose an appropriate intraocular lens.** Factors that should influence your choice include the stage of the disease (especially in terms of the visual field); the condition of the ocular surface; and whether the patient has astigmatism. Many surgeons choose aspheric IOLs for these patients because of contrast sensitivity issues. However, these patients can be candidates for astigmatic correction via a toric IOL or a limbal relaxing incision, especially if they're interested in reduced spectacle dependence and their glaucoma surgery has been stable for some time.

Because these patients have less-



When a bleb is present, it may be necessary to be flexible about your incision sites. With instruments going in and out, proximity could result in damage to the bleb.

than-perfect visual fields, they're generally not good candidates for extended-depth-of-focus or multifocal lenses; the glaucomatous damage may be encroaching on central fixation. Monovision should be considered cautiously in patients who have significant field loss in one or both eyes.

Intraop and Postop

During and after the surgery, these strategies will help ensure a good outcome:

- **Use topical drops and intracameral medication for anesthesia.** This will avoid the risk of a hemorrhage that's associated with a retrobulbar block.

- **Be flexible about your incision sites, to avoid the bleb.** You'll be moving instruments in and out of those incisions, so they need to be well away from the bleb to ensure it isn't inadvertently damaged.

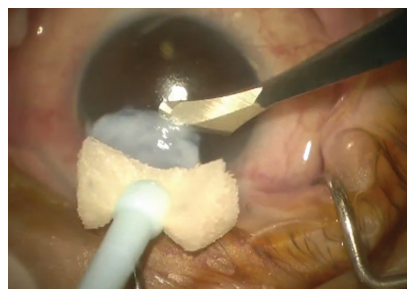- **If an overhanging bleb is interfering with visualization, excise it.** Leon Herndon, MD, taught me a simple technique that involves using a 57-degree blade to excise the bleb and approximate it to the limbus. (See picture, right.) Excising the bleb in this manner creates a clean break that allows better visualization both for the cataract surgeon and for the patient postoperatively.

- **If a bleb is marginally functioning, consider needling it with or without 5-FU intraoperatively or postoperatively.** This approach has been described in the literature, and can be helpful in some patients with marginally-functioning blebs who are being considered for cataract surgery.

- **If an existing tube shunt is problematic, consider shortening it.** If the tube is long, close to the cornea or pressing against the cataract, you'll need to shorten it. I sometimes use a Sinsky hook through a paracentesis to stabilize the tube and then use intraocular scissors to cut the tube shorter. I then use Utrata forceps to remove the tube piece from the eye.

If you perform this maneuver, be sure to use copious amounts of Viscoat to protect the endothelium. Reapply midway through the procedure if you have any concerns.

- **Check the patient frequently after surgery.** Be on the lookout for IOP spikes and any sign of a hyphema. Aggressive inflammation control is advisable; that may require the use of low-concentration steroids like loteprednol, as well as increased use of NSAIDs. (I like to use the once-a-day NSAIDs two or three times a day to help reduce the need for steroids.)



If an overhanging bleb is problematic, it can be excised using a 57-degree blade to approximate it to the limbus.

I also watch for bleb failure and use gonioscopy to monitor for peripheral anterior synechiae formation in the angle with any MIGS procedure.

Staying the Course

Performing cataract surgery on a prior tube or trabeculectomy patient presents challenges beyond those associated with a healthy patient. To address those challenges effectively, devote extra time, thought and preparation to your preop evaluation; make sure you address patient expectations before surgery so that any issues that arise won't lead the patient to believe you did something wrong; and consider adding a MIGS procedure to the cataract surgery. MIGS procedures can help lower IOP, limit the risk of IOP spikes, reduce the patient's medication burden and relieve medication-related ocular surface disease.

These strategies should help you achieve the best possible outcomes when working with a patient who has a pre-existing trab or tube, and reduce the likelihood of an unhappy patient postoperatively. [REVIEW](#)

Dr. Okeke is an assistant professor of ophthalmology at Eastern Virginia Medical School in Norfolk, and a glaucoma specialist and cataract surgeon at Virginia Eye Consultants. She produces educational glaucoma videos on her iGlaucoma YouTube channel. She is a consultant for Aerie, Alcon Laboratories, Allergan, Bausch + Lomb, Ellex, Glaukos, MST, Novartis, Reichert, Santen, Sight Sciences and Sun Ophthalmics.

1. Swamyathan K, Capistrano AP, Cantor LB, WuDunn D. Effect of temporal corneal phacoemulsification on intraocular pressure in eyes with prior trabeculectomy with an antimetabolite. *Ophthalmology* 2004;111:4:674-8.
2. Bussell I, Kaplowitz K, Schuman J, Loewen N. Outcomes of ab-interno trabeculectomy with the Trabectome after failed Trabeculectomy. *British J Ophth* 2015; 99:2:258-262.
3. Mosaed S, Chak G, Haider A, Lin K, Minckler D. Results of Trabectome surgery following failed glaucoma tube shunt implantation: Cohort study. *Medicine (Baltimore)* 2015; 94:30:e1045.

Dealing With a Postoperative Refractive Surprise

Douglas D. Koch, MD, professor and chair of ophthalmology at Baylor's Cullen Eye Institute in Houston, explains that if the patient ends up with an imperfect result despite his best efforts, he has some general criteria for how to proceed. "If the error is more than +1 D or -2 D, I'd probably exchange the lens rather than resort to laser refractive surgery," he says. "If the laser correction is between -2 and +1 D, the treatment won't alter the corneal asphericity to any great extent, so that would probably be the way to go.

"The only time I might not exchange the lens when the refractive surprise exceeds those boundaries is when I don't understand the outcome," he continues. "It makes no sense to replace the lens if you're not sure what's going on. If the patient ends up 1.5 D hyperopic, and you repeat the calculations and all of the formulas say the patient should have ended up with -0.5 D of myopia, then you have a mystery. Was the IOL mislabeled? Is the effective lens position off for some reason? If the reason for the outcome is unknown, replacing the lens may or may not change the result. In that situation I'm more inclined to recommend corneal refractive surgery, because at least I'm addressing a known refractive error."

—CK

(Continued from page 38)

measuring beam go from the cornea to the fovea. The instrument gives you a swept-source-OCT image that shows the trajectory of the beam; it can confirm that the patient was looking at the correct spot and the measurement was taken accurately. In contrast, older versions of the IOLMaster such as the IOLMaster 500 let you see the light reflections on the cornea. If those reflections are crisp, that indicates that the measurement was reliable."

"The best way to do biometry is to follow the validation guidelines that have been developed for each biometer," notes Dr. Hill. "Validation criteria are available for both the Haag-Streit Lenstar and the Zeiss IOLMaster. [Dr. Hill assembled those criteria for both companies.] Surgeons need to avoid simply 'button pushing' and accepting everything at face value, because a measurement is only as good as our ability to know what it means. I've seen numerous cases in which a refractive surprise was traced back to some problematic aspect of the preoperative measurements that could have been identified if validation criteria had been applied. As carpenters like to say, measure twice and cut once."

• If the axial length measurement is different between the eyes, check the measurement with immersion

biometry. "Axial length is the biggest determinant of lens power, so even a small error can lead to a significant error in the lens power you pick," says Dr. Basti. "A difference in axial length between the two eyes of more than 0.3 mm is a red flag. The eyes might simply be different, but there could be something else going on. In that situation it's prudent to take another measurement using immersion biometry."

• If implanting a toric lens, also use topography. "You can't just use the astigmatism measurement taken by the biometer," notes Dr. Basti. "With high astigmatism, a current optical biometry device will likely give you accurate an spherical power, but if you want to measure the astigmatism for a toric lens, it's prudent to also use a topographer—especially a device such as the Pentacam, Galilei or Cassini devices—that can help factor in the posterior corneal astigmatism."

Looking Ahead

Not surprisingly, the existing popular formulas continue to be improved and refined. "Later this year, version 3.0 of the Hill-RBF artificial intelligence IOL power calculation method will be released, first as an on-line calculator and later within the EyeSuite software of the Haag-Streit Lenstar,"

says Dr. Hill. "This update is the culmination of one and a half years of work in cooperation with 44 study sites in 22 countries, with some of the world's most accomplished cataract surgeons contributing data. Version 3.0 will now take into account the influence of the white-to-white measurement, lens thickness, central corneal thickness and gender."

Dr. Hoffer is also preparing to release his latest update. "Later this year we'll be releasing the Hoffer QS formula," he says. "Refinements in this new formula are producing results on a par with the Barrett Universal II."

Of course, no matter how good your biometry and formulas are, some patients will inevitably miss the intended mark. For those patients, new technologies that offer the possibility of changing IOL powers postop may save the day. "The FDA-approved RxSight light-adjustable lens is a neat technology," notes Dr. Koch. "The problem is that it's expensive. It's not for the average patient. I'm cautiously optimistic about the upcoming technologies that use femtosecond lasers to modify almost any IOL that's already inside the eye; they'll allow us to implant affordable IOLs in our patients and tweak them postoperatively, if the patient desires. However, those options are in much earlier phases of development." (For more on these technologies, see the feature on p. 50.) **REVIEW**

Dr. Koch is a consultant for Carl Zeiss Meditec, Alcon, Johnson & Johnson Vision and Perfect Lens. Dr. Hill is a consultant for Zeiss, Haag-Streit, Alcon, Omega Ophthalmics, Optos and Veracity Surgical. Dr. Hoffer earns name trademark royalties from companies that include his formulas in their devices, for ensuring they're programmed accurately. Dr. Basti has no financial ties to any device mentioned.

1. Gökçe SE, Zeiter JH, Weikert MP, Koch DD, Hill W, Wang L. Intraocular lens power calculations in short eyes using 7 formulas. J Cataract Refract Surg 2017;43:7:892-897.



How to Right-size Your Capsulorhexis

Learn the best strategies to use when you need to go small, large or somewhere in between.

Sean McKinney, Senior Editor

Most cataract surgeons say consistency is their top goal when creating a capsulorhexis. Then, with furrowed brow, they may explain the inevitable need to adopt variations to ensure reproducible and stable long-term results in this era of premium refractive IOLs.

Sound familiar? Here, surgeons offer insights you can use to establish a baseline approach and respond on short notice when circumstances in the OR dictate a need to do so.

Taking Control

Mark Kontos, MD, a senior partner at Empire Eye Physicians, which has offices in eastern Washington and northern Idaho, says he uses a cystotome to maximize the chances of making a perfectly centered capsulorhexis.

“I like to use the cystotome because it gives me more control,” he says. “When I’m creating the capsulorhexis, I don’t rush. I look at the visual axis of the patient to get an idea of the size I’m trying to achieve. I maintain control of the edge and maintain good visibility. I can keep

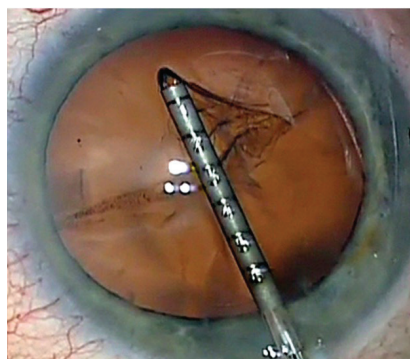


Figure 1. Microincision capsulorhexis for-cepts are used to create a capsulorhexis.

the capsulorhexis exactly the size I want it to be, usually a standard of 4.8 to 5 mm.”

For patients willing to pay extra as part of their refractive package, Dr. Kontos offers to do their capsulorhexis with the Catalys femtosecond laser. “The laser is best at ensuring absolute uniformity, helping me create a well-centered capsulorhexis,” he says. “It puts me at the leading edge. I set parameters, and an OCT unit built into the laser measures the capsulorhexis. By default, based on the way the laser does the procedure, I’m centered over the capsular bag.”

In some cases, when a patient has

a high angle kappa, for example, he adjusts the laser to slightly decenter the capsulorhexis. “The thing that’s nice about the laser is that you can do a capsulorhexis in less than a second,” says Dr. Kontos. “So, you don’t have to worry about a lot of variability. When you have complete control of the whole process, it allows you to do just about anything you want in terms of sizing and location.”

Avoiding Risks

Uday Devgan, MD, FACS, FRCS, a partner at Specialty Surgical Center, Beverly Hills, California, cautions against making a capsulorhexis that’s too small—in most cases. “For an optic size of 6 mm in diameter, we want a capsulorhexis that’s 5 to 5.5 mm in diameter so that it overlaps for a full 360 degrees,” says Dr. Devgan, also chief of ophthalmology at Olive View UCLA Medical Center. “Making a smaller capsulorhexis will only make the nucleus removal more challenging and will result in a smaller effective optic size when the anterior capsular rim opacifies with time.”

Dr. Kontos adds that a capsulorhex-



Figure 2. A 360-degree anterior capsule overlap reduces the incidence of posterior capsule opacification.

is made too small is destined for unwanted contraction. “In capsular contraction syndrome, the capsule might start at 4 mm and contract down to 3 mm or 2 mm over time,” he says. “This can result in fibrosis, putting a lot of strain on the zonules and causing dehiscence. The lens could end up shifting and becoming dislocated after you finish the surgery. This can potentially impair vision and create the need for an anterior YAG laser procedure for you to resolve postop symptoms.”

Large capsulorhexis size isn’t an absolute protection against risk, however. Dr. Devgan notes that you need to know when a small capsulorhexis is actually indicated. “You want a smaller capsulorhexis when another surgery—such as DMEK, a glaucoma tube shunt procedure or a pars plana vitrectomy—is performed concomitantly,” he says. “We want to prevent the optic from escaping from the capsular bag during these combined procedures.”

Although you typically want to make the capsulorhexis overlap the lens optic by about 0.5 mm all the way around the optic, Richard Hoffman, MD, who practices in Eugene, Oregon, says you may discover a need to slightly increase or decrease the overlap in some cases. “The risk of making your capsulorhexis too large is that you’ll have a greater chance

of seeing your rhexis move out to the equator and then losing it,” says Dr. Hoffman. “The risk of making it too small—which is easy to do—can become more clear when you do the hydrodissection steps. You may find that the fluid has a difficult time getting around a dense lens, and you can actually blow out the posterior capsule.”

When doing a routine capsulorhexis, Dr. Hoffman says he makes sure he puts enough viscoelastic into the patient’s eye to keep the lens from prolapsing forward. “I also use a microincision capsulorhexis forceps to help create the capsulorhexis,” he adds. “It has millimeter marks on the cannula so that when I put it in the eye, I can hold it over the anterior capsule and visualize what a 5-mm size would be.

“When I do the capsulorhexis, I usually start in the center and perforate the lens,” he says. “I’ll cut out about 2 to 3 mm with the blade of the forceps. Then I’ll just grab that flap and rotate it around. Most surgeons do their capsulorhexis through the coaxial wound, which is about 2.2 to 2.5 mm. That works fine in normal eyes.” In a high-risk eye, he adds, he starts with a smaller opening and spirals out to the size that he wants.

Avoiding Intraocular Issues

Dr. Kontos warns that a capsulorhexis can get so over-sized that it risks creating an intraocular issue. “A large capsulorhexis can get into the zonules,” he says. “It’s hard to tell at times how much the zonules have moved to the center of the capsule. You can’t always see them. Sometimes, when you’re making a large capsulorhexis and you get into where the zonules are attached, inside the capsular structure, it’s very easy for the capsulorhexis to radialize and no longer function as a continuous, circular capsulorhexis.”

Another potential issue: If the cap-

sular edge doesn’t overlap the edge of the lens, this means the rhexis is too large, he points out.

“It can lead to instability of the lens inside the bag,” he says. “Sometimes, as the capsule contracts, if a portion of the lens is not overlapped by the circumference of the capsule, then that part of the lens can pop out of the capsule, and the capsule can contract behind it. That can lead to malposition of the lens inside the bag, and sometimes those forces can move the lens in any given direction. That, in turn, could lead to a refractive shift or astigmatism.”

If these or other issues arise while you’re still in the patient’s eye, Dr. Kontos urges you to take a calm problem-solving approach as you continue your procedure. “For example, if you feel like the capsulorhexis is extending beyond where you want it to be, add viscoelastic and direct the capsule in the direction that you want—and the size that you want it to be,” he says.

“If you realize you’ve made your capsulorhexis too small, or you think you’re making it too small, just continue what you’re doing and complete the capsulorhexis,” Dr. Kontos adds. “Then you can go back and make a bigger capsulorhexis around the one that’s too small, instead of trying to make the original capsulorhexis big-

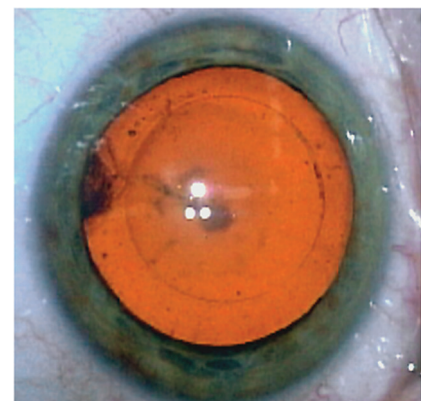


Figure 3. For this patient, a 6-mm optical zone mark has been placed on this cornea to yield a 5.13-mm capsulorhexis.

REVIEW | Refractive/Cataract Rundown

Richard Hoffman, MD

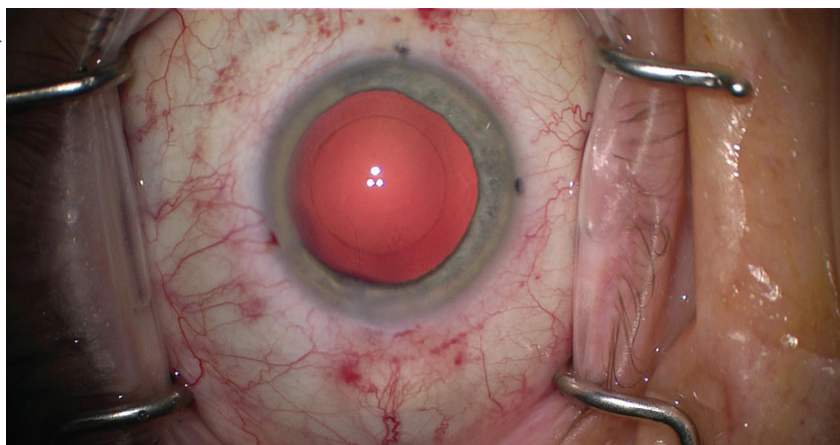


Figure 4. A Catalyst OCT-guided femtosecond laser is used to create a capsulorhexis.

ger at the end of your first attempt, potentially creating an irregularly shaped capsulorhexis.”

Pseudoexfoliation Challenge

Pseudoexfoliation syndrome poses a familiar and unique challenge when making a capsulorhexis. “I recommend making a sufficiently large capsulorhexis of at least 5 mm in diameter for these patients, since they tend to get capsular phimosis,” says Dr. Devgan. Bringing the cataract partially out of the capsular bag can help minimize stress on the zonules while you disassemble the nucleus, he adds.

Dr. Hoffman says he’s comfortable creating a capsulorhexis of 7 mm for his pseudoexfoliation-syndrome patients, especially when a dense, rock-hard cataract is involved. “I think it’s safer to do the case through a capsulorhexis of this size,” he notes. For posterior polar cataracts, when the patient’s capsule is at high risk of rupturing, Dr. Hoffman says he tries to make the capsulorhexis about 5 mm. “That way, if the posterior capsule ruptures, you have the option of putting a three-piece lens in the ciliary sulcus and the optic cap, capturing the optic through the anterior capsulorhexis to stabilize the lens,” he points out.

Impact on IOL Calculations

Surgeons recommend that you carefully consider the impact of your capsulorhexis on your IOL calculations.

“Remember these calculations are based on a best estimate of where the lens sits inside the bag, the effective lens position” says Dr. Kontos. “A number of factors affect this. The impact of the capsulorhexis won’t be the same if it’s a different size every time.”

Evidence suggests that the effective lens position is altered by these variations, he continues. “If you’re going to use an A-constant to personalize your lens calculations, then you have to insist on a capsulorhexis that’s uniform every time. If not, you really can’t have a reliable A-constant that’s personalized for what you’re trying to accomplish.”

Dr. Devgan notes that a lens cal-

culatation depends on three simple factors. “You have the keratometry, the axial length of the eye and the exact location in the eye where the IOL will sit,” he says. “Where will it sit? Will it be it 3 mm back? Or 3.2 mm, 3.5 mm or 4 mm back? Shifting the lens even a fraction of a millimeter will change the refractive outcome a lot. All of the formulas have different ways of trying to figure out the effective lens position.

“If you have a rhexis that’s not going to hold the lens securely, then there’s no way of really determining where the lens will sit in the eye,” he concludes. “So I’m going to make a consistent rhexis in every case. My rhexis going to overlap the optic. It’s going to hold it securely in place. Then I’ll have a lot more accuracy in determining the effective lens position, and therefore a more accurate calculation.”

Your Signature

Dr. Devgan encourages his colleagues to look at each capsulorhexis as a part of their legacy.

“The capsulorhexis is an important part of your signature that you leave in every eye,” he says. “Even decades after your surgery, a fellow doctor will be able to examine that eye and see the results of your handiwork. A centered and precise capsulorhexis will securely hold the IOL optic in position for the most accurate refractive outcome over time.” **REVIEW**

Mark Kontos, MD

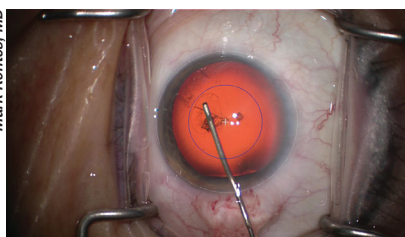


Figure 5. The Zeiss Callisto automatically measures and creates a target zone for capsulorhexis.

Dr. Kontos is a consultant for Zeiss, Sun, Allergan and Johnson & Johnson Vision. Dr. Devgan is the owner of Catataractcoach.com, a free online education site. He’s served as a consultant and speaker for Alcon and Bausch + Lomb, and he’s a principal for LensGen and IOLCalc.com. Dr. Hoffman is a consultant for MicroSurgical Technology.

Blurred vision and floaters bring a 79-year-old woman to the Wills Eye Hospital Oncology Service.

Anand D. Gopal, MD, Arman Mashayekhi, MD, Tatyana Milman, MD, Michael Abendroth, MD, and Carol L. Shields, MD

Presentation

A 79-year-old Caucasian woman developed blurred vision and floaters in her left eye, which progressed over the course of several months. Past ocular history was unremarkable. At the time of initial evaluation by a local retina specialist, she denied having headache, eye pain or photophobia. Examination was notable for dense vitreous cellular reaction in the left eye. The patient received an injection of sub-Tenon's triamcinolone and was started on topical difluprednate three times daily for presumed inflammatory vitritis with no improvement in her visual acuity. She presented to the Wills Eye Hospital Ocular Oncology Service one month later for a second opinion.

Medical History

The patient's past medical history was notable for polymyalgia rheumatica and rheumatoid arthritis (treated with prednisone), atrial fibrillation, hypothyroidism, chronic obstructive pulmonary disease, gastrointestinal reflux disease, hypertension and diverticulitis. She had a complex oncologic history that included colon cancer treated with partial colectomy and chemotherapy 15 years prior and cutaneous malignant melanoma of her back that was locally excised six years earlier. Additionally, she was diagnosed with patch/plaque-stage mycosis fungoides (MF) at age 56 years, which progressed to tumor stage, requiring initiation of systemic therapy and local radiation, though there was never nodal or visceral involvement. Family history was remarkable for multiple cancers among siblings, including gastric, central nervous system, bone and prostate. The patient disclosed a history of prior tobacco use totaling 80 pack-years.

Medications at the time included amlodipine, apixaban, sotalol, diclofenac, fluticasone/salmeterol, levalbuterol, furosemide, levothyroxine, pantoprazole, famotidine, prednisone, bexarotene and alprazolam.

Examination

On presentation to Wills, visual acuity was 20/60 in the right eye and CF at 8' in the left eye. Pupils were equal, round and reactive in each eye. There was no afferent pupillary defect. Extraocular motility was full bilaterally. Intraocular pressure was 12 mmHg OU. Anterior segment evaluation revealed moderate nuclear sclerosis OU. There was 4+ cell noted in the anterior vitreous in the left eye (*Figure 1A*). On ophthalmoscopic examination bilateral macular drusen were noted (*Figure 1B*). Fundus examination was otherwise unremarkable in the right eye. Ophthalmoscopic examination of the left eye demonstrated diffuse vitreous opacities with 2+ vitreous haze and without clinically evident retinal, subretinal or choroidal infiltration. A choroidal nevus was documented in the left macula.

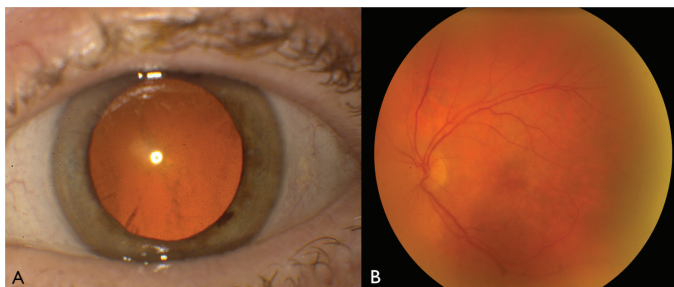


Figure 1. (A) Slit lamp photograph of the left eye in retroillumination revealed cell in the anterior vitreous. (B) Fundus examination of the left eye demonstrated diffuse vitreous cell and haze without clinically evident retinal, subretinal or choroidal infiltrate.

What is your diagnosis? What further workup would you pursue? The diagnosis appears on p. 70.

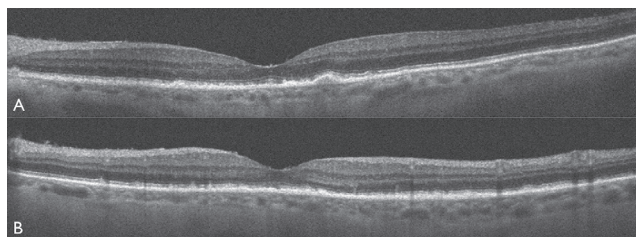


Figure 2. Optical coherence tomography of the right (A) and left (B) eyes revealed small sub-retinal pigment epithelial detachments.

Workup, Diagnosis and Treatment

The differential diagnosis for insidious-onset vitritis in an elderly patient is broad and should include infectious and inflammatory etiologies as well as neoplastic conditions that may masquerade as vitritis. Infection, particularly in light of this patient's relative immunocompromise secondary to chronic oral corticosteroid use and mycosis fungoides, should be excluded. Infectious etiologies to consider include bacterial or fungal endophthalmitis, HIV, tuberculosis, Lyme disease, toxoplasmosis, HZV/VZV, Bartonella and syphilis. Inflammatory conditions causing posterior or intermediate uveitis may present similarly, and include sarcoidosis and multiple sclerosis. Finally, neoplastic conditions such as vitreoretinal lymphoma should be considered, particularly in an older patient with prior oncologic history.

Serologic evaluation of the following were negative or non-reactive: HIV 1/2 antigen/antibody; Lyme IgG/IgM; Quantiferon Gold; Toxoplasma IgG/IgM; Bartonella henselae; and quintana IgG/IgM. FTA-ABS testing was equivocal; though given the patient's low risk profile, it was interpreted as non-reactive. Erythrocyte sedimentation rate was 57 (reference range 0-29 mm/hour). Complete blood count, comprehensive metabolic panel, ACE level, LDH, and muramidase level were all within normal limits. Optical coherence tomography revealed small sub-retinal pigment epithelial deposits in both eyes consistent with drusen (Figures 2A and B). B-scan ultrasonography demonstrated dense vitritis in the left eye, consistent with clinical examination (Figure 3). Skin evaluation disclosed pruritic, erythematous scaly patches and plaques on the patient's lower legs, consistent with active mycosis fungoides (Figure 4).

Given the patient's age and important oncologic history, primary attention was directed toward evaluation for intraocular dissemination of systemic malignancy. The patient underwent therapeutic and diagnostic pars plana vitrectomy with vitreous biopsy. Cytopathologic examination of a vitreous specimen from the left eye revealed variably sized atypical lymphocytes with markedly folded, irregular nuclear contours, scant to abundant cytoplasm and frequent mitotic figures and apoptotic bodies (Figures 5A and B). Immuno-

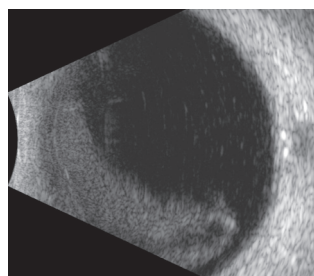


Figure 3. B-scan ultrasonography of the left eye showing dense vitreous opacity inferiorly and posterior vitreous detachment.

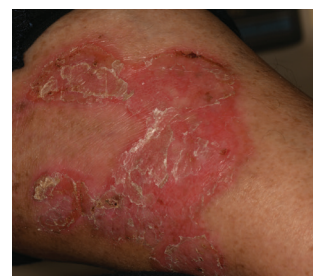

Figure 4. Examination of the patient's skin disclosed erythematous scaly patches and plaques on the lower extremity, consistent with her known history of mycosis fungoides.

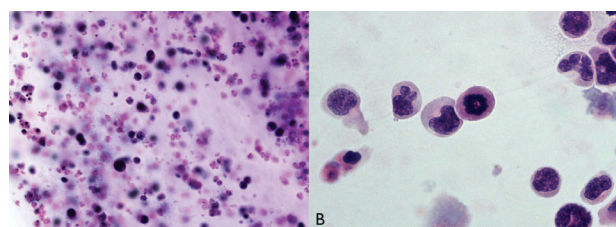


Figure 5. (A) Cytologic evaluation of the vitreous aspirate demonstrated a cellular specimen with a mixed population of cells in a background of necrosis. (B) Higher magnification photomicrograph highlights the cellular constituents of the aspirate, predominantly composed of small to medium sized lymphocytes and dendritic macrophages with occasional multinucleation. Several lymphocytes had markedly atypical nuclei with prominent nuclear folds and grooves, lending the nucleus a "cerebriform" or "flower cell"-like appearance. Also present were atypical mitotic figures and apoptotic bodies. [stain: hematoxylin-eosin; original magnification x100 (A), x250 (B)]

histochemical staining revealed CD3 positivity and absence of CD20 expression. There was aberrant co-expression of CD4 and CD8 and loss of CD7 expression. There was no evidence of CD30+ transformed large cells (Figures 6A-F). Examination of skin-punch biopsy performed 12 years earlier revealed nearly identical morphologic and immunophenotypic features, confirming a diagnosis of vitreoretinal T-cell lymphoma arising from an MF variant of cutaneous T-cell lymphoma (CTCL) (Figure 7).

The patient underwent brain MRI, which demonstrated areas of T2 hyperintensity in multiple brain regions, suggestive of central nervous system lymphoma. Whole body PET-CT confirmed CNS uptake, but didn't show visceral involvement. Peripheral blood flow cytometry was negative for circulating neoplastic T cells. Repeat ophthalmoscopic examination one month after vitrectomy revealed new vitreous cell in the right eye, in addition to persistent vitritis in the residual vitreous skirt of the left eye. She was referred to Medical Oncology and initiated on six cycles of high-dose

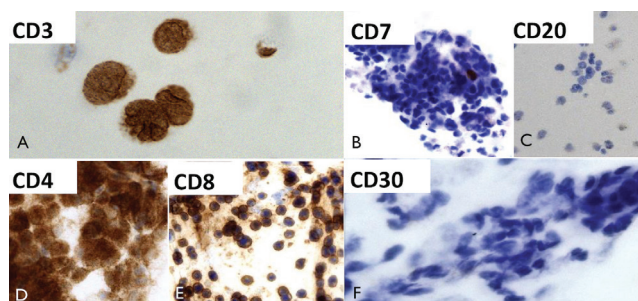


Figure 6. Immunohistochemical studies demonstrated expression of the T-cell marker CD3 (A) by the atypical lymphocytes. There was aberrant loss of CD7 expression (B). Immunostain for CD20 was negative, consistent with absence of B-cells (C). There was aberrant co-expression of CD4 (D) and CD8 (E). CD30 immunostain (F), obtained to exclude large cell transformation, was negative. Based on these morphologic and immunohistochemical findings, a pathologic diagnosis of vitreoretinal T-cell lymphoma, cytormorphologically and immunophenotypically compatible with intraocular involvement by cutaneous T-cell lymphoma/mycosis fungoides, was made. [stains: CD3 (A), CD7 (B), CD20 (C), CD4 (D), CD8 (E), CD30 (F); original magnification x250 (A), x100 (B-F)]

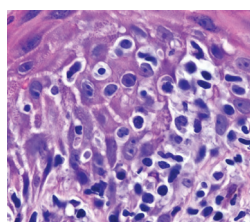


Figure 7. Prior skin biopsy demonstrated intraepidermal proliferation of atypical lymphocytes morphologically and immunophenotypically identical to that seen on vitreous biopsy (immunohistochemical stains not shown) [stain: hematoxylin-eosin; original magnification x100].

Discussion

Intraocular lymphoma can initially manifest in the eye itself, arise in the setting of prior primary CNS lymphoma, or less commonly can be a manifestation of disseminated systemic lymphoma.¹ Dissemination of systemic lymphoma most frequently involves the uvea; vitreoretinal involvement is uncommon.¹ Most intraocular lymphomas are of B-cell origin and intraocular involvement by T-cell lymphoma is exceedingly rare.^{2,3} A recent review of 29 cases of T-cell lymphoma with involvement of the eye found the mycosis fungoides-subtype of cutaneous T-cell lymphoma to be most frequent (27.6 percent).⁴

The cutaneous T-cell lymphomas comprise a heterogeneous group of lymphoproliferative disorders characterized by predominant localization of neoplastic T cells to the skin, though visceral sites may become involved with disease progression. Mycosis fungoides, which accounts for 44 percent of cutaneous T-cell lymphomas, typically follows an indolent course with five-year survival rates approaching 90 percent.⁵ Mycosis fungoides presents classically with pruritic erythematous cutaneous patches that, over time, can progress to infiltrative plaques and nodular tumors. Patients are

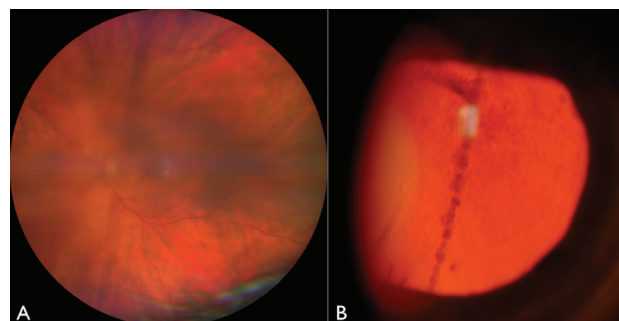


Figure 8. (A) Ophthalmoscopic examination six months after vitreous biopsy and shortly after completion of high-dose systemic methotrexate reveals persistent vitreous cells in the left eye. (B) A vitreous string of pearls was noted nasally in the left eye on slit lamp examination.

systemic methotrexate for presumed CNS involvement by disseminated cutaneous T-cell lymphoma. Four months later, after completion of systemic methotrexate therapy, the patient was noted to have increased vitritis in the left eye (Figures 8A and B). There was no evidence of lymphoma in the right eye. She received serial injections of intravitreal methotrexate (400 ug/0.1 ml) to the left eye with clearance of vitreous cells after three injections. Repeat brain MRI at eight months post-CNS diagnosis demonstrated a new, 3-cm lesion in the right basal ganglia. The patient elected to pursue hospice care and passed away from her disease approximately 10 months after initial ophthalmic presentation.

typically older age (median age at diagnosis: 55 to 60), more frequently male and Caucasian.⁵ Clinical staging of mycosis fungoides is based on the following: extent of cutaneous disease; presence of lymph node and visceral involvement; and identification of circulating neoplastic cells in the blood. Treatment is stage-dependent, ranging from topical corticosteroid therapy and phototherapy for early stage mycosis fungoides (cutaneous patches or plaques only, stage IA to IIA) to the use of systemic therapy with immunomodulatory agents, such as interferon and oral retinoids; and chemotherapeutics, including methotrexate, for cases of refractory early-stage and more advanced disease (skin tumors greater than or equal to 1 cm, stage IIB to IVB).⁶

Ophthalmic manifestations of cutaneous T-cell lymphoma are rare. A comprehensive study of 2,155 patients with cutaneous T-cell lymphoma revealed ophthalmic abnormalities in fewer than 2 percent of them.⁷ These included cicatricial eyelid ectropion (0.8 percent), retinal infiltration (0.09 percent) and optic nerve involvement (0.05 percent).⁷ In a review of 29 cases of biopsy-confirmed disseminated T-cell lymphoma of the intraocular structures, the median age

Resident Case Series

at intraocular diagnosis was 57 years. Intraocular manifestations were noted at a mean of 76 months following skin diagnosis.⁴ Eye findings on presentation included vitritis (66 percent) and non-granulomatous anterior uveitis (45 percent). Differentiating between T-cell and B-cell vitreoretinal lymphoma isn't possible based on clinical eye examination alone; it requires biopsy with histopathology and immunohistochemistry.

Vitreoretinal T-cell lymphoma has the potential to masquerade as intraocular infection or inflammation. Hence, diagnosis requires a high degree of clinical suspicion. Findings on optical coherence tomography can include fine hyperreflective sub-retinal pigment epithelial deposits, corresponding to hyperautofluorescence on fundus autofluorescence imaging.⁸ While clinical examination and imaging studies can guide diagnosis, the gold standard remains cytopathologic examination of an intraocular sample, which can be obtained via vitreous aspiration or pars plana vitrectomy. Advantages of vitrectomy over needle biopsy include therapeutic potential to improve vision and maximization of the diagnostic yield.^{8,9} Nevertheless, non-diagnostic vitreous specimens aren't uncommon and may necessitate additional sampling. Further, presence of reactive inflammatory cells, necrosis and cellular debris may complicate cytopathologic evaluation.⁸ In a retrospective case series of 33 eyes with suspected intraocular lymphoma that underwent vitrectomy, the positive predictive value of cytopathology was 100 percent and negative predictive value was just under 61 percent.¹⁰ These findings indicate that a negative vitreous specimen doesn't exclude intraocular lymphoma and repeat sampling may be necessary.

Morphologically, neoplastic T cells appear as medium to large lymphoid cells with irregular nuclear contours and scant cytoplasm.⁸ Immunohistochemical studies reveal CD3 positivity

and absence of CD20 staining. Molecular testing and flow cytometry can be used adjunctively to improve diagnostic accuracy. In cases of suspected disseminated lymphoma from known systemic (or extraocular) primary, morphologic, immunophenotypic and, when available, molecular genetic comparison of intraocular specimen to primary tumor, as in this case, may aid in confirming the final diagnosis. Subsequent MRI of the brain with or without cerebrospinal fluid sampling is recommended to assess for CNS involvement in confirmed cases of intraocular lymphoma.¹

Given the rarity of disseminated vitreoretinal T-cell lymphoma, there are no guidelines for therapy. Most approaches are based on data from patients with primary vitreoretinal B-cell lymphoma. Radiation therapy, intravitreal chemotherapy and systemic chemotherapy, alone or in combination, have been described.¹¹ Among patients with vitreoretinal B-cell lymphoma without concurrent CNS manifestations, development of CNS disease has been shown to occur at a similar frequency when comparing those receiving systemic treatment and those receiving intraocular treatment alone.¹¹ Intravitreal injection of methotrexate is a common and effective treatment choice.¹¹

In a series of 44 eyes with biopsy-proven vitreoretinal lymphoma (either B- or T-cell type), injection of intravitreal methotrexate achieved intraocular clearance of malignant cells following a mean of six injections; however patients are advised to undergo a full year of injections for a complete course.¹² Toxicities were few, and included corneal epitheliopathy, cataract progression and neovascular glaucoma.¹² More recently, use of intravitreal melphalan has been described as having the potential to achieve intraocular control with fewer injections.¹³ Despite the efficacy of intravitreal therapy, patients often succumb to the burden of CNS

or systemic disease. Overall, prognosis is poor for patients with intraocular T-cell lymphoma with a mean survival of 21.7 months after intraocular diagnosis.²

In summary, a 79-year-old woman with a longstanding history of cutaneous T-cell lymphoma on systemic oral therapy presented with several months of progressive blurred vision and floaters in the left eye. Pars plana vitrectomy with vitreous biopsy demonstrated malignant T cells morphologically and immunophenotypically similar to those seen on skin biopsy 12 years earlier, confirming a diagnosis of vitreoretinal T-cell lymphoma arising from cutaneous T-cell lymphoma. Subsequent imaging demonstrated CNS disease, and the patient was initiated on systemic chemotherapy with high-dose methotrexate. Although resolution of intraocular lymphoma was achieved with serial injections of intravitreal methotrexate, the patient succumbed to progressive CNS disease. **REVIEW**

1. Davis JL. Intraocular lymphoma: A clinical perspective. Eye (London, England) 2013;27:2:153-162.
2. Chaput F, Amer R, Baglivo E, et al. Intraocular T-cell lymphoma: Clinical presentation, diagnosis, treatment, and outcome. Ocular Immunology and Inflammation. 2017;25:5:639-648.
3. Levasseur SD, Wittenberg LA, White VA. Vitreoretinal lymphoma: A 20-year review of incidence, clinical and cytologic features, treatment, and outcomes. JAMA Ophthalmology 2013;131:1:50-55.
4. Levy-Clarke GA, Greenman D, Sieving PC, et al. Ophthalmic manifestations, cytology, immunohistochemistry, and molecular analysis of intraocular metastatic T-cell lymphoma: Report of a case and review of the literature. Survey of Ophthalmology 2008;53:3:285-295.
5. Jawed SI, Myskowski PL, Horwitz S, Moskowitz A, Querfeld C. Primary cutaneous T-cell lymphoma (mycosis fungoides and Sezary syndrome): Part I. Diagnosis: Clinical and histopathologic features and new molecular and biologic markers. J Am Acad Dermatol 2014;70:2:205 e201-216; quiz 221-202.
6. Jawed SI, Myskowski PL, Horwitz S, Moskowitz A, Querfeld C. Primary cutaneous T-cell lymphoma (mycosis fungoides and Sezary syndrome): Part II. Prognosis, management, and future directions. J Am Acad Dermatol. 2014;70:2:223 e221-217; quiz 240-222.
7. Cook BE, Jr., Bartley GB, Pittelkow MR. Ophthalmic abnormalities in patients with cutaneous T-cell lymphoma. Transactions of the American Ophthalmological Society 1998;96:309-324; discussion 324-307.
8. Tang LJ, Gu CL, Zhang P. Intraocular lymphoma. International Journal of Ophthalmology 2017;10:8:1301-1307.
9. Mudhar HS, Sheard R. Diagnostic cellular yield is superior with full pars plana vitrectomy compared with core vitreous biopsy. Eye (London, England) 2013;27:1:50-55.
10. Davis JL, Miller DM, Ruiz P. Diagnostic testing of vitrectomy specimens. Am J Ophthalmol 2005;140:5:822-829.
11. Riemens A, Bromberg J, Touitou V, et al. Treatment strategies in primary vitreoretinal lymphoma: A 17-center European collaborative study. JAMA Ophthalmology 2015;133:2:191-197.
12. Frenkel S, Hendler K, Siegal T, Shalom E, Pe'er J. Intravitreal methotrexate for treating vitreoretinal lymphoma: 10 years of experience. The British Journal of ophthalmology 2008;92:3:383-388.
13. Shields CL, Sioufi K, Mashayekhi A, Shields JA. Intravitreal melphalan for treatment of primary vitreoretinal lymphoma: A new indication for an old drug. JAMA Ophthalmology 2017;135:7:815.

(Continued from page 24)

damage” of ocular surface, cornea, cataract and glaucoma don’t prove insuperable, then anatomical and visual recovery are feasible. Truly, desperate times call for desperate measures. **REVIEW**

Dr. Kenyon is a clinical professor of ophthalmology at Tufts University School of Medicine/New England Eye Center and is a faculty member at Harvard Medical School and the Schepens Eye Research Institute. Dr. Binotti is a clinical research fellow at Tufts/New England Eye Center, currently investigating anterior segment imaging modalities.

1. Marciano-Cabral F, Cabral G. Acanthamoeba species as agents of disease in humans. *Clin Microbiol Rev* 2003;16:273-307.
2. Alizadeh H, Silvary RE, Meyer DR, et al. In vitro amoebicidal activity of propamidine and pentamidine isethionate against Acanthamoeba species and toxicity to corneal tissues. *Cornea* 1997;16:94-100.
3. Keenan JD, McLeod SD. Parasitic keratitis. In: Yanoff M and Duker JS, eds. *Ophthalmology*, 5th ed. Edinburgh, UK: Elsevier 2019:230-23.
4. Acanthamoeba keratitis multiple states, 2005–2007. *MMWR Morb Mortal Wkly Rep* 2007;56:21:532–534.
5. Thebpatiphat N, Hammersmith KM, Rocha FN, et al. Acanthamoeba keratitis: A parasite on the rise. *Cornea* 2007;26:6:701–706.
6. Dart JK, Radford CF, Minassian D, et al. Risk factors for microbial keratitis with contemporary contact lenses: A case-control study. *Ophthalmol* 2008;115:10:1647–1654.
7. Maycock NJR, Jayaswal R. Update on Acanthamoeba keratitis: Diagnosis, treatment and outcomes. *Cornea* 2016;35:7:13-720.
8. Dart JKG, Saw VPJ, Kilvington S. Acanthamoeba keratitis: Diagnosis and treatment update 2009. *Am J Ophthalmol* 2009;148:487-499.
9. Austin A, Lietman T, Rose-Nussbaumer J. Update on the management of infectious keratitis. *Ophthalmol* 2017; 124:1678-1689.
10. Rivière D, Szczebara FM, Berjeaud JM, et al. Development of a real-time PCR assay for quantification of Acanthamoeba trophozoites and cysts. *J Microbiological Methods* 2006;64:1:78–83.
11. Huang P, Tepelus T, Vickers LA, et al. Quantitative analysis of depth, distribution, and density of cysts in Acanthamoeba keratitis using confocal microscopy. *Cornea* 2017;36:927–932.
12. Goh JWY, Harrison R, Hau S, et al. Comparison of in vivo confocal microscopy, PCR and culture of corneal scrapes in the diagnosis of Acanthamoeba keratitis. *Cornea* 2018;37:480–485.
13. Parmar DN, Awwad ST, Petroll WM, et al. Tandem scanning confocal corneal microscopy in the diagnosis of Acanthamoeba keratitis. *Ophthalmol* 2006;113:538-547.
14. Alizadeh H, Silvary RE, Meyer DR, et al. In vitro amoebicidal activity of propamidine and pentamidine isethionate against Acanthamoeba species and toxicity to corneal tissues. *Cornea* 1997;16:1:94-100.
15. Ficker LA, Kirkness C, Wright P. Prognosis for keratoplasty in Acanthamoeba keratitis. *Ophthalmology* 1993;100:105–110.

Left your *Review* of Ophthalmology magazine at the office? No problem!



Read *Review* on the go from any mobile device!

Simply go to www.reviewofophthalmology.com and click on the digimag link to get your current issue.

REVIEW Classifieds

Career Opportunities

OPHTHALMOLOGISTS Danbury, CT

Ophthalmologists to share office with long standing Ophthalmologist in Danbury, CT. High quality equipment. \$2,250 per month or adjoining office without equipment- \$1,750 per month.

203-545-3539 or
email mehrimd@aol.com

REVIEW of Ophthalmology

**Do you have Products
and Services for sale?**

CONTACT US TODAY
FOR CLASSIFIED ADVERTISING
Toll free: 888-498-1460
E-mail: sales@kerhgroup.com

REVIEW of Ophthalmology

Targeting Ophthalmologists?

**CLASSIFIED ADVERTISING
WORKS**

Contact us today
for classified advertising:
Toll free: **888-498-1460**
E-mail: sales@kerhgroup.com

KERHGROUP



REVIEW Advertising Index

Akorn Pharmaceuticals 19 & 31
(800) 932-5676
www.theratears.com

Alcon Laboratories 27 & 28
(800) 451-3937

EyePoint Pharmaceuticals 5
(817) 677-6120
www.eyevance.com

Eyevance 39 & 40
(817) 677-6120
www.eyevance.com

Genentech 14 & 15
www.gene.com

Glaukos 13
(800) 452-8567
www.glaukos.com

Horizon Pharma USA 9 & 10
www.tepezzahcp.com

Keeler Instruments 23
(800) 523-5620

Lombart Instruments 7
info@lombartinstrument.com
www.lombartinstrument.com

Novartis Pharmaceuticals 75 & 76
www.xiidra-ecp.com

Ocular Therapeutics, Inc. 2 & 3
(877) 628-8998
www.ocutx.com

Omeros 5
www.omidria.com

Rayner 21
(866) 961-1811
USMarketing@rayner.com
www.usa.rayner.com

Reichert Technologies 34 & 35
(888) 849-8955
www.reichert.com

S4OPTIK 45 & 47
(888) 224-6012

Santen Inc. USA 25
(415) 268-9100
www.santeninc.com

This advertiser index is published as a convenience and not as part of the advertising contract. Every care will be taken to index correctly. No allowance will be made for errors due to spelling, incorrect page number, or failure to insert.

XIIDRA® (lifitegrast ophthalmic solution), for topical ophthalmic use
Initial U.S. Approval: 2016

BRIEF SUMMARY: Please see package insert for full prescribing information.

1 INDICATIONS AND USAGE

Xiidra® (lifitegrast ophthalmic solution) 5% is indicated for the treatment of the signs and symptoms of dry eye disease (DED).

4 CONTRAINDICATIONS

Xiidra is contraindicated in patients with known hypersensitivity to lifitegrast or to any of the other ingredients in the formulation [see *Adverse Reactions (6.2)*].

6 ADVERSE REACTIONS

The following serious adverse reactions are described elsewhere in the labeling:

- Hypersensitivity [see *Contraindications (4)*]

6.1 Clinical Trials Experience

Because clinical trials are conducted under widely varying conditions, adverse reaction rates observed in clinical trials of a drug cannot be directly compared to rates in the clinical trials of another drug and may not reflect the rates observed in practice.

In five clinical studies of DED conducted with lifitegrast ophthalmic solution, 1401 patients received at least one dose of lifitegrast (1287 of which received lifitegrast 5%). The majority of patients (84%) had ≤ 3 months of treatment exposure. One hundred-seventy patients were exposed to lifitegrast for approximately 12 months. The majority of the treated patients were female (77%). The most common adverse reactions reported in 5%-25% of patients were instillation-site irritation, dysgeusia, and reduced visual acuity.

Other adverse reactions reported in 1%-5% of the patients were blurred vision, conjunctival hyperemia, eye irritation, headache, increased lacrimation, eye discharge, eye discomfort, eye pruritus, and sinusitis.

6.2 Postmarketing Experience

The following adverse reactions have been identified during post-approval use of Xiidra. Because these reactions are reported voluntarily from a population of uncertain size, it is not always possible to reliably estimate their frequency or establish a causal relationship to drug exposure.

Rare cases of hypersensitivity, including anaphylactic reaction, bronchospasm, respiratory distress, pharyngeal edema, swollen tongue, and urticaria have been reported. Eye swelling and rash have been reported [see *Contraindications (4)*].

8 USE IN SPECIFIC POPULATIONS

8.1 Pregnancy

Risk Summary

There are no available data on Xiidra use in pregnant women to inform any drug-associated risks. Intravenous (IV) administration of lifitegrast to pregnant rats, from pre-mating through gestation Day 17, did not produce

teratogenicity at clinically relevant systemic exposures. Intravenous administration of lifitegrast to pregnant rabbits during organogenesis produced an increased incidence of omphalocele at the lowest dose tested, 3 mg/kg/day (400-fold the human plasma exposure at the recommended human ophthalmic dose [RHOD], based on the area under the curve [AUC] level). Since human systemic exposure to lifitegrast following ocular administration of Xiidra at the RHOD is low, the applicability of animal findings to the risk of Xiidra use in humans during pregnancy is unclear [see *Clinical Pharmacology (12.3)* in the full prescribing information].

Data

Animal Data

Lifitegrast administered daily by IV injection to rats, from pre-mating through gestation Day 17, caused an increase in mean pre-implantation loss and an increased incidence of several minor skeletal anomalies at 30 mg/kg/day, representing five, 400-fold the human plasma exposure at the RHOD of Xiidra, based on AUC. No teratogenicity was observed in the rat at 10 mg/kg/day (460-fold the human plasma exposure at the RHOD, based on AUC). In the rabbit, an increased incidence of omphalocele was observed at the lowest dose tested, 3 mg/kg/day (400-fold the human plasma exposure at the RHOD, based on AUC), when administered by IV injection daily from gestation Days 7 through 19. A fetal no observed adverse effect level (NOAEL) was not identified in the rabbit.

8.2 Lactation

Risk Summary

There are no data on the presence of lifitegrast in human milk, the effects on the breastfed infant, or the effects on milk production. However, systemic exposure to lifitegrast from ocular administration is low [see *Clinical Pharmacology (12.3)* in the full prescribing information]. The developmental and health benefits of breastfeeding should be considered, along with the mother's clinical need for Xiidra and any potential adverse effects on the breastfed child from Xiidra.

8.4 Pediatric Use

Safety and efficacy in pediatric patients below the age of 17 years have not been established.

8.5 Geriatric Use

No overall differences in safety or effectiveness have been observed between elderly and younger adult patients.

Manufactured for:
Novartis Pharmaceuticals Corporation
One Health Plaza
East Hanover, NJ 07936
T2019-110



THERE'S NO SWITCHING THIS

Xiidra is the only lymphocyte function-associated antigen-1 (LFA-1) antagonist treatment for Dry Eye Disease^{1,2}

Xiidra, the first in a class of LFA-1 antagonists for Dry Eye Disease, is a prescription eye drop FDA-approved to treat both signs and symptoms of the disease.^{1,3}

There's no FDA-approved therapeutic equivalent.^{2,4}
Check out patient resources, insurance coverage, and more at [Xiidra-ECP.com](https://www.xiidra-ecp.com)

References:

1. Xiidra [prescribing information]. East Hanover, NJ: Novartis Pharmaceuticals Corporation; November 2019.
2. TFOS DEWS II Research Subcommittee. Report of the Research Subcommittee of the Tear Film & Ocular Surface Society Dry Eye Workshop II (2017). *Ocul Surf.* 2017;15(3):269-649.
3. FDA approves new medication for dry eye disease. FDA News Release. July 2016. <https://www.fda.gov/news-events/press-announcements/fda-approves-new-medication-dry-eye-disease>. Accessed March 17, 2020.
4. Food and Drug Administration. Electronic Orange Book. <https://www.fda.gov/media/71474/download>. Accessed March 17, 2020.

Indication

Xiidra® (lifitegrast ophthalmic solution) 5% is indicated for the treatment of signs and symptoms of dry eye disease (DED).

Important Safety Information

Xiidra is contraindicated in patients with known hypersensitivity to lifitegrast or to any of the other ingredients.

In clinical trials, the most common adverse reactions reported in 5-25% of patients were instillation site irritation, dysgeusia and reduced visual acuity. Other adverse reactions reported in 1% to 5% of the patients were blurred vision, conjunctival hyperemia, eye irritation, headache, increased lacrimation, eye discharge, eye discomfort, eye pruritus and sinusitis.

To avoid the potential for eye injury or contamination of the solution, patients should not touch the tip of the single-use container to their eye or to any surface.

Contact lenses should be removed prior to the administration of Xiidra and may be reinserted 15 minutes following administration.

Safety and efficacy in pediatric patients below the age of 17 years have not been established.

For additional safety information, see accompanying Brief Summary of Safety Information on the adjacent page and Full Prescribing Information on [Xiidra-ECP.com](https://www.xiidra-ecp.com).



Novartis Pharmaceuticals Corporation
East Hanover, New Jersey 07936-1080

© 2020 Novartis

3/20

XIA-1387617