

THE MEDICARE APPEALS PROCESS P. 16 • RESEARCH BRIEFS P. 60
OCTA AND GLAUCOMA P. 62 • THE LATEST TECHNOLOGY AND DRUGS P. 70
WILLS EYE RESIDENT CASE SERIES P. 77

REVIEW[®] of Ophthalmology

MAY 2019

reviewofophthalmology.com

CHARTING YOUR OWN COURSE

Experts share tips on how to go solo, but note that there are many challenges to overcome as well. P. 20

ALSO INSIDE:

- EHR: Room for Improvement? **P. 32**
- The Questionable Cataract: Who Decides? **P. 40**
- How to Manage Uveitic Glaucoma **P. 48**
- Strong Moves for Weak Zonules **P. 54**

Personalized vision* with
TECNIS® can help you meet
their expectations with:

- Improved near visual acuities without compromising distance vision¹
- Low incidence of visual symptoms¹
- High patient satisfaction¹

To learn more, see us at
ASCRS 2019 booth 1921†
or visit TecnisIOL.com

*Personalized vision refers to combining a TECNIS Symfony® IOL in 1 eye and a TECNIS® Multifocal +3.25 D IOL in the other eye. Or alternatively, a TECNIS® Multifocal +3.25 D IOL in 1 eye and a TECNIS® Multifocal +2.75 D IOL in the other eye.

†Not affiliated with the official program of ASCRS 2019.



Not actual patient.

INDICATIONS AND IMPORTANT SAFETY INFORMATION FOR TECNIS SYMFONY® AND TECNIS SYMFONY® TORIC EXTENDED RANGE OF VISION IOLs

Rx Only

INDICATIONS FOR USE: The TECNIS Symfony® Extended Range of Vision IOL, Model ZXR00, is indicated for primary implantation for the visual correction of aphakia, in adult patients with less than 1 diopter of pre-existing corneal astigmatism, in whom a cataractous lens has been removed. The lens mitigates the effects of presbyopia by providing an extended depth of focus. Compared to an aspheric monofocal IOL, the lens provides improved intermediate and near visual acuity, while maintaining comparable distance visual acuity. The Model ZXR00 IOL is intended for capsular bag placement only. The TECNIS Symfony® Toric Extended Range of Vision IOLs, Models ZXT150, ZXT225, ZXT300, and ZXT375, are indicated for primary implantation for the visual correction of aphakia and for reduction of residual refractive astigmatism in adult patients with greater than or equal to 1 diopter of preoperative corneal astigmatism, in whom a cataractous lens has been removed. The lens mitigates the effects of presbyopia by providing an extended depth of focus. Compared to an aspheric monofocal IOL, the lens provides improved intermediate and near visual acuity, while maintaining comparable distance visual acuity. The Model Series ZXT IOLs are intended for capsular bag placement only. **WARNINGS:** Patients with any of the conditions described in the Directions for Use may not be suitable candidates for an intraocular lens because the lens may exacerbate an existing condition, may interfere with diagnosis or treatment of a condition, or may pose an unreasonable risk to the patient's eyesight. Lenses should not be placed in the ciliary sulcus. May cause a reduction in contrast sensitivity under certain conditions, compared to an aspheric monofocal IOL; fully inform the patient of this risk before implanting the lens. Special consideration should be made in patients with macular disease, amblyopia, corneal irregularities, or other ocular disease. Inform patients to exercise special caution when driving at night or in poor visibility conditions. Some visual effects may be expected due to the lens design, including: a perception of halos, glare, or starbursts around lights under nighttime conditions. These will be bothersome or very bothersome in some people, particularly in low-illumination conditions, and on rare occasions, may be significant enough that the patient may request removal of the IOL. Rotation of the TECNIS Symfony® Toric IOLs away from their intended axis can reduce their astigmatic correction, and misalignment >30° may increase postoperative refractive cylinder. If necessary, lens repositioning should occur as early as possible prior to lens encapsulation. **PRECAUTIONS:** Interpret results with caution when refracting using autorefractors or wavefront aberrometers that utilize infrared light, or when performing a duochrome test. Confirmation of refraction with maximum plus manifest refraction technique is recommended. The ability to perform some eye treatments (e.g. retinal photocoagulation) may be affected by the optical design. Target emmetropia for optimum visual performance. Care should be taken to achieve IOL centration, as lens decentration may result in a patient experiencing visual disturbances under certain lighting conditions. For the TECNIS Symfony® Toric IOL, variability in any preoperative surgical parameters (e.g. keratometric cylinder, incision location, surgeon's estimated surgically induced astigmatism and biometry) can influence patient outcomes. Carefully remove all viscoelastic and do not over-inflate the capsular bag at the end of the case to prevent lens rotation. **SERIOUS ADVERSE EVENTS:** The most frequently reported serious adverse events that occurred during the clinical trial of the TECNIS Symfony® lens were cystoid macular edema (2 eyes, 0.7%) and surgical reintervention (treatment injections for cystoid macular edema and endophthalmitis, 2 eyes, 0.7%). No lens-related adverse events occurred during the trial.

INDICATIONS AND IMPORTANT SAFETY INFORMATION FOR THE TECNIS® MULTIFOCAL FAMILY OF 1-PIECE IOLs

Rx Only

INDICATIONS: The TECNIS® Multifocal 1-Piece intraocular lenses are indicated for primary implantation for the visual correction of aphakia in adult patients with and without presbyopia in whom a cataractous lens has been removed by phacoemulsification and who desire near, intermediate, and distance vision with increased spectacle independence. The intraocular lenses are intended to be placed in the capsular bag. **WARNINGS:** Physicians considering lens implantation should weigh the potential risk/benefit ratio for any conditions described in the Directions for Use that could increase complications or impact patient outcomes. Multifocal IOL implants may be inadvisable in patients where central visual field reduction may not be tolerated, such as macular degeneration, retinal pigment epithelium changes, and glaucoma. The lens should not be placed in the ciliary sulcus. Inform patients about the possibility that a decrease in contrast sensitivity and an increase in visual disturbances may affect their ability to drive a car under certain environmental conditions, such as driving at night or in poor visibility conditions. **PRECAUTIONS:** Prior to surgery, inform prospective patients of the possible risks and benefits associated with the use of this device and provide a copy of the patient information brochure to the patient. The long term effects of intraocular lens implantation have not been determined. Secondary glaucoma has been reported occasionally in patients with controlled glaucoma who received lens implants. Do not reuse, resterilize or autoclave. **ADVERSE EVENTS:** The rates of surgical re-interventions, most of which were non-lens related, were statistically higher than the FDA grid rate for both the ZMB00 (+4.00 D) and ZLB00 (+3.25 D) lens models. For the ZMB00, the surgical re-intervention rates were 3.2% for first eyes and 3.3% for second eyes. The re-intervention rate was 3.3% for both the first and second eyes in the ZLB00 group. **ATTENTION:** Reference the Directions for Use for a complete listing of Indications and Important Safety Information.

REFERENCE: 1. JJV Data on File 2018. Validity of investigator initiated studies by Machat and Dell (DOF2018CT4021).

TECNIS® and TECNIS Symfony® are trademarks of Johnson & Johnson Surgical Vision, Inc.

©Johnson & Johnson Surgical Vision, Inc. 2019 | TecnisIOL.com | PP2019MLT4052 | February 2019

See the Passion in
Each Patient.

Johnson & Johnson VISION

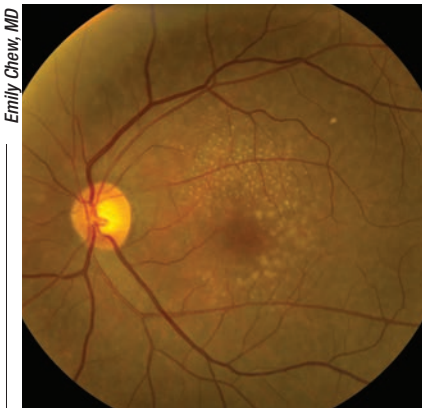Calcium Intake and Age-Related Macular Degeneration

In a recently published study, a secondary analysis of patients enrolled in the Age-Related Eye Disease Study was conducted to determine whether an association exists between dietary and supplementary calcium intake and age-related macular degeneration.

Emily Chew, MD, director of the division of epidemiology and clinical applications at the National Eye Institute at the National Institutes of Health, conducted the retrospective analysis. She says studies have suggested calcium might play a role in macular degeneration, so she wanted to see if it had any effect on the disease. “We were not only interested in dietary intake of calcium, but also supplementary intake since it’s common, particularly for women with osteoporosis, to be taking calcium supplements,” says Dr. Chew.

The pathology of AMD is poorly understood, and experts are still trying to determine its risk factors. “Unfortunately, we don’t know the pathway through which macular degeneration occurs,” says Dr. Chew. “We can only understand it by looking at risk factors, genetics, studying long-term follow-up and seeing what drugs and dietary influences might be affecting it.” She says it’s not surprising that calcium may affect macular degeneration, however. “It’s been recognized and demonstrated by scientists that the heart of drusen, which are the hallmark for [determining] macular degeneration, is actually calcium,” she says.

Retrospectively, the study investigated possible associations between



dietary and supplementary calcium intake and the risk of developing AMD, as well as the disease’s progression to intermediate and late stages. A total of 4,751 participants who had no macular degeneration, as well as those with mild, moderate and severe disease, were followed for a mean of 10 years. The study found a significant association between higher levels of dietary and supplementary calcium intake and a lower incidence of progression to late AMD. Dr. Chew notes that additional findings showed that patients weren’t harmed by the increased calcium intake, similar to findings from the Blue Mountains Eye Study.

Dr. Chew notes that, since the study was retrospective, they don’t know whether any biases exist or if the individuals involved are typical of the general public. Additionally, she adds that most of the subjects were white, so the data may not apply to all groups of people.

Previous studies that looked into

the association between calcium intake and AMD have produced mixed results. Findings from the Blue Mountains Eye Study show that calcium may be an important factor in limiting AMD development/progression.¹ Conversely, findings from the Nutrition Examination Survey suggest that increased calcium intake is harmful in terms of macular degeneration.² However, Dr. Chew says the latter was only based on cross-sectional data. “[In our analysis], we looked longitudinally, using a baseline to see how calcium is associated with worsening of AMD over time,” she says. “We think the longitudinal data was more powerful.”

Similar to findings in the Blue Mountains Eye study, other results include an inconsistent association between calcium consumption and the different stages of AMD. Dr. Chew says that there are signs showing changes occurring at different stages of the disease. “We think there’s more than one pathway in which macular degeneration occurs,” she says. “We know that certain genetic associations are important for getting the disease, but for it to progress, other factors may come into play.”

With this in mind, the researchers say additional study is required. “We have new ideas suggesting calcium might be important but we can’t say whether increased intake prevents macular degeneration without a randomized trial that studies it,”

(Continued on page 8)

Basics of Medical Devices for the New Entrepreneur

The ARVO and ASCRS meetings are upon us, and these conferences represent opportunities for physician-entrepreneurs to build momentum in their development of their new devices, get input from colleagues and meet with potential partners and investors. In this column, we'll provide a brief overview of regulatory considerations and pearls related to the development of new devices in ophthalmology for the first-time physician-entrepreneur.

In ophthalmology, medical devices include such things as hand-held surgical instruments, sutures, diagnostic imagers, intraocular lenses, contact lenses, lasers, and software for image analysis, smart phones and tablets. The government agency charged with evaluating these devices for approval and overseeing their manufacturing, performance and safety is the Center for Devices and Radiological Health, a branch of the FDA.

Before a company can begin selling a medical device, it needs to prepare what's known as a premarket submission. The nature of this regulatory filing is largely based on the classification of the device. Devices generally fall into one of three classes based on technology complexity, intended use (i.e., diagnostic or intervention) and, to an extent, their risk profile. Most of the classifications in ophthalmology were defined in the late 1980s, but new ones are still generated today, and sometimes a classification will change as a technology and its uses are better understood. Classification determines the extent of regulatory control required by the FDA for the device to be marketed, and the type of preclinical and clinical testing required.

Classifications & Premarket Submissions

About 90 percent of Class I devices are exempt from premarket submission (i.e., FDA approval is not required). Instead, they're required to follow what the FDA terms "General Controls":

- Establishment Registration;
- Medical Device Listing;
- Quality Systems Regulation;
- Labeling requirements; and
- Medical Device Reporting.

Class II devices (and some Class I devices that are nonexempt) are cleared for market-

ing through the Premarket Notification process, or 510(k). When a 510(k) is granted, the device's sponsor is then allowed to say the product is cleared to be marketed. The 510(k) process grants clearance, not approval (this is a common mistake in how sponsors talk about the process and one that the FDA takes very seriously.) In a 510(k), there must be a comparison of the investigational device to one or more similar, legally marketed devices (called predicate devices). For a device to be cleared for marketing by the FDA, the 510(k) submission must demonstrate that the investigational device is 'substantially equivalent' to the predicate device. Once submitted, the FDA has 90 days to review the 510(k). In ophthalmology, a large portion of the devices commonly seen today that are cleared through the 510(k) process, such as optical coherence tomographers, artificial-intelligence-based programs and some lasers, require clinical trials.



Selecting the predicate device for comparison is half the battle. Substantial equivalence is determined if the investigational device, in comparison to a predicate:

- has the same intended use and has the same technological characteristics; or
- has the same intended use but has different technological characteristics and the information has been submitted to the FDA;
- doesn't raise new questions of safety and efficacy; and
- demonstrates that the device is at least as safe and effective as the legally marketed device.

In many cases the predicate is obvious, such as comparing a new daily wear contact lens to a lens that's already being marketed. In other cases one needs to be more creative to identify a predicate and justify its use in the comparison. For example, some of the software platforms may actually pick a predicate from an area outside of ophthal-

mology, such as radiology. Image management and manipulation are common in other therapeutic areas as well.

Class III devices require a Pre-Market Approval (PMA) to demonstrate safety and efficacy, and are typically interventions, such as a retinal prosthesis or an IOL. (It's a little-known fact that extended wear contact lenses are actually Class III devices, too—the agency treats daily wear and extended wear differently based on the underlying risks.)

For Class III devices, the FDA has 180 days to review the PMA and make a determination for approval. PMA approval is based on a determination by the agency that the PMA contains sufficient valid scientific evidence to ensure that the device is safe and effective for its intended use(s). When a PMA is granted, these devices are considered approved by the FDA.

The De Novo pathway is used for a new device that hasn't previously been classified, and there's a chance that it could be considered Class II based on the criteria discussed earlier. The process was modified in 2012 to not require a 510(k) submission in advance. Upon submission of the request, the FDA will conduct a review of substantial equivalence, as well as determine whether a new product code is warranted, which would allow the device to be marketed. Some very important recent advances in ophthalmology have come via the De Novo pathway, such as the first AI screening program for diabetics from IDx, and a new dry-eye treatment from Oculve (now owned by Allergan). A key element of this program allows the new products to serve as predicates, which may make it easier to bring new technology to patients in the future.

For software, there's another risk-profile assessment that applies to how the data will be used, and if there will be an impact on potential diagnosis or treatment decisions. We'll cover the development and approval path of software- and AI-based devices in a separate column.

The other pathway is the Humanitarian Device Exemption. The HDE pathway is intended to support development of a new product designated as a Humanitarian Use Device (intended to diagnosis or treat a disease

(Continued on page 6)

DID YOU KNOW?

KEELER

has slit lamps!

For over 100 years, we have been creating innovative products. The Keeler slit lamp is one of them – designed with you and your patients in mind. The KSL delivers a visually pleasing, customizable device equipped with excellent, high-quality optics.

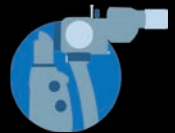SLIT LAMP FEATURES



Sharp & clear
Keeler Optics



KSL-H series:
tower illumination



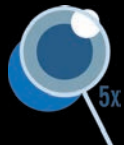KSL-Z series:
lower illumination



Digital-ready
& full digital units



3x magnification
drum (10x, 16x, 25x)



5x magnification
drum (6x, 10x, 16x,
25x, 40x)



Unique 1mm
square for Uveitis
evaluation



Bright & white
LED illumination



We also carry
portable slit lamps!

VISIT OUR WEBSITE FOR MORE PRODUCT DETAILS

www.keelerusa.com / 800-523-5620

Keeler

Editor in Chief

Walter C. Bethke
(610) 492-1024
wbethke@jobson.com

Senior Editor

Christopher Kent
(814) 861-5559
ckent@jobson.com

Associate Editor

Alexandra Skinner
(610) 492-1025
askinner@jobson.com

Chief Medical Editor

Mark H. Blecher, MD

Art Director

Jared Araujo
(610) 492-1032
jaraujo@jobson.com

Senior Graphic Designer

Matt Egger
(610) 492-1029
megger@jobson.com

Graphic Designer

Ashley Schmouder
(610) 492-101048
aschmouder@jobson.com

International coordinator, Japan

Mitz Kaminuma
Reviewophtho@aol.com

Business Offices

11 Campus Boulevard, Suite 100
Newtown Square, PA 19073
(610) 492-1000
Fax: (610) 492-1039

Subscription inquiries:

United States — (877) 529-1746
Outside U.S. — (845) 267-3065
E-mail:
revophthalmology@cambeywest.com
Website: www.reviewofophthalmology.com



(Continued from page 4)

that exists in no more than 8,000 patients) for rare diseases. Also, there should be no comparable device marketed in the United States. The threshold for safety is the same as for a Class III PMDA device, but benefits only need to outweigh the risks, thus making the efficacy threshold lower.

When marketed, devices must be labeled as an HUD, and not sold for profit (some exceptions exist). The Argus II Retina Prosthesis System, and INTACS for keratoconus were two devices that were approved with the HDE pathway.

While these are the main pathways for devices to enter the commercial arena in the United States, there are other programs that can help along the way. The FDA has designations such as Breakthrough and Early Feasibility, which can work in concert with the pathways mentioned above. We'll discuss these programs and their potential benefits in the future.

Getting Early Feedback from the FDA

The first step toward securing approval for your product occurs at what's known as the Pre-submission Meeting.

At this meeting, you can get initial feedback from the FDA on your device's classification, the premarket submission most appropriate for it, and the preclinical and clinical requirements you'll have to fulfill. The meeting is held roughly 75 to 90 days after submitting a meeting request. This request will include the "briefing package," which is all of the background data required for the FDA to answer your questions.

Scheduling a meeting early in your development process is best, in order to help with your business and funding plans. The guidance documents you'll receive from the FDA in advance of the meeting will provide suggested questions and content to make sure the meeting is as productive as possible. The product's sponsor should provide as much detail about the proposed product as possible, so that the FDA can get a clear picture of how the company intends the product to work.

Each briefing package will be different, based on the questions and insight the sponsor is hoping to gain from the meeting, but it should start with a robust description of the device.

Preparing for Clinical Trials

Every device is classified into one of two categories as preparations are made for a clinical trial: Nonsignificant risk (NSR) or significant risk (SR).

Nonsignificant risk devices generally don't pose a significant risk to human subjects. Examples include most daily-wear contact lenses and lens solutions, imaging devices and non-contact tonometry devices. A nonsignificant risk device study requires only institutional review board approval prior to its initiation. The IRB would make the determination of NSR in its approval letter for the study. Notice of IRB approval allows the device to be shipped to the investigational site.

If the device presents a potential for serious risk to the health, safety or welfare of a subject, it's deemed to be a significant risk device. Significant risk devices may include implants, devices that support or sustain human life and devices that are substantially important in diagnosing, curing, mitigating or treating disease, or preventing impairment to human health. For these devices, the sponsor must submit an Investigational Device Exemption (IDE) application to the FDA, and it will need both FDA and IRB approval prior to initiation of a clinical study.

While the IRB determines the level of risk, the FDA can also weigh in on the subject and has guidance documents that cover situations that are on the border between NSR and SR.

Prior to any submission, the risk assessment of the device, which justifies why the sponsor chose a particular risk classification for the device, should be completed by the sponsor and included among its submissions to the FDA and IRB.

Here are a few hypothetical examples of sample products and some preliminary considerations:

- **Surgical instrument.** A metal instrument (forceps, scleral depressor, retractor, etc.) for manipulating tissue during surgery. Class I. Subject to General Controls, no formal clearance or approval required from the FDA.

- **Novel IOL design.** All IOLs are classified as Class III, requiring a PMA. Supplements are submitted for modifications to existing approved lenses. The nature of the modifications dictate the extent of clinical testing required.

(Continued on page 8)

Dextenza[®]

(dexamethasone ophthalmic insert) 0.4mg
for intracanalicular use

NOW APPROVED. COMING SOON.

BIG TIME INNOVATION¹

THE FIRST AND ONLY
OPHTHALMIC STEROID INSERT

DEXTENZA is an advancement in steroid treatment

- Resorbable, so no need for removal²
- Insert can be removed via saline irrigation or manual expression, if necessary²
- Physicians rated DEXTENZA as easy to insert^{3*}
- Designed to deliver a tapered dose¹
- Contains fluorescein for visualization²
- No additional components or assembly required²

VISIT BOOTH 1737 AT ASCRS

INDICATION

DEXTENZA is a corticosteroid indicated for the treatment of ocular pain following ophthalmic surgery.

IMPORTANT SAFETY INFORMATION

CONTRAINDICATIONS

DEXTENZA is contraindicated in patients with active corneal, conjunctival or canalicular infections, including epithelial herpes simplex keratitis (dendritic keratitis), vaccinia, varicella; mycobacterial infections; fungal diseases of the eye, and dacryocystitis.

WARNINGS AND PRECAUTIONS

Prolonged use of corticosteroids may result in glaucoma with damage to the optic nerve, defects in visual acuity and fields of vision. Steroids should be used with caution in the presence of glaucoma. Intraocular pressure should be monitored during treatment.

Corticosteroids may suppress the host response and thus increase the hazard for secondary ocular infections. In acute purulent conditions, steroids may mask infection and enhance existing infection.

Use of ocular steroids may prolong the course and may exacerbate the severity of many viral infections of the eye (including herpes simplex).

Fungus invasion must be considered in any persistent corneal ulceration where a steroid has been used or is in use. Fungal culture should be taken when appropriate.

Use of steroids after cataract surgery may delay healing and increase the incidence of bleb formation

ADVERSE REACTIONS

The most common ocular adverse reactions that occurred in patients treated with DEXTENZA were: anterior chamber inflammation including iritis and iridocyclitis (9%); intraocular pressure increased (5%); visual acuity reduced (2%); eye pain (1%); cystoid macular edema (1%); corneal edema (1%); and conjunctival hyperemia (1%).

The most common non-ocular adverse reaction that occurred in patients treated with DEXTENZA was headache (1%).

Please see brief summary of full Prescribing Information on adjacent page.

*73.6% of physicians in Study 1 and 76.4% in Study 2 rated DEXTENZA as easy to insert.

References: 1. Sawhney AS et al, inventors; Incept LLC, assignee. US patent 8,409,606 B2. April 2, 2013. 2. DEXTENZA [package insert]. Bedford, MA: Ocular Therapeutix, Inc; 2018. 3. Walters T et al. *J Clin Exp Ophthalmol.* 2016;7(4):1-11.

© 2019 Ocular Therapeutix, Inc. All rights reserved.
DEXTENZA is a registered trademark of Ocular Therapeutix, Inc. PP-US-DX-0071 02/2019

Ocular
Therapeutix[™]

Dextenza®

(dexamethasone ophthalmic insert) 0.4 mg
for intracanalicular use

BRIEF SUMMARY: Please see the DEXTENZA Package Insert for full prescribing information for DEXTENZA (11/2018)

1 INDICATIONS AND USAGE

DEXTENZA® (dexamethasone ophthalmic insert) is a corticosteroid indicated for the treatment of ocular pain following ophthalmic surgery (1).

4 CONTRAINDICATIONS

DEXTENZA is contraindicated in patients with active corneal, conjunctival or canalicular infections, including epithelial herpes simplex keratitis (dendritic keratitis), vaccinia, varicella; mycobacterial infections; fungal diseases of the eye, and dacryocystitis.

5 WARNINGS AND PRECAUTIONS

5.1 Intraocular Pressure Increase

Prolonged use of corticosteroids may result in glaucoma with damage to the optic nerve, defects in visual acuity and fields of vision. Steroids should be used with caution in the presence of glaucoma. Intraocular pressure should be monitored during the course of the treatment.

5.2 Bacterial Infection

Corticosteroids may suppress the host response and thus increase the hazard for secondary ocular infections. In acute purulent conditions, steroids may mask infection and enhance existing infection [see Contraindications (4)].

5.3 Viral Infections

Use of ocular steroids may prolong the course and may exacerbate the severity of many viral infections of the eye (including herpes simplex) [see Contraindications (4)].

5.4 Fungal Infections

Fungal invasion must be considered in any persistent corneal ulceration where a steroid has been used or is in use. Fungal culture should be taken when appropriate [see Contraindications (4)].

5.5 Delayed Healing

The use of steroids after cataract surgery may delay healing and increase the incidence of bleb formation.

6 ADVERSE REACTIONS

The following serious adverse reactions are described elsewhere in the labeling:

- Intraocular Pressure Increase [see Warnings and Precautions (5.1)]
- Bacterial Infection [see Warnings and Precautions (5.2)]
- Viral Infection [see Warnings and Precautions (5.3)]
- Fungal Infection [see Warnings and Precautions (5.4)]
- Delayed Healing [see Warnings and Precautions (5.5)]

6.1 Clinical Trials Experience

Because clinical trials are conducted under widely varying conditions, adverse reaction rates observed in the clinical trials of a drug cannot be directly compared to rates in the clinical trials of another drug and may not reflect the rates observed in practice. Adverse reactions associated with ophthalmic steroids include elevated intraocular pressure, which may be associated with optic nerve damage, visual acuity and field defects, posterior subcapsular cataract formation; delayed wound healing; secondary ocular infection from pathogens including herpes simplex, and perforation of the globe where there is thinning of the cornea or sclera [see Warnings and Precautions (5)].

DEXTENZA was studied in three randomized, vehicle-controlled studies (n = 351). The mean age of the population was 68 years (range 43 to 87 years), 62% were female, and 85% were white. Forty-six percent had brown iris color and 31% had blue iris color. The most common ocular adverse reactions that occurred in patients treated with DEXTENZA were: anterior chamber inflammation including iritis and iridocyclitis (9%); intraocular pressure increased (5%); visual acuity reduced (2%); eye pain (1%); cystoid macular edema (1%); corneal edema (1%); and conjunctival hyperemia (1%).

The most common non-ocular adverse reaction that occurred in patients treated with DEXTENZA was headache (1%).

8 USE IN SPECIFIC POPULATIONS

8.1 Pregnancy

Risk Summary

There are no adequate or well-controlled studies with DEXTENZA in pregnant women to inform a drug-associated risk for major birth defects and miscarriage. In animal reproduction studies, administration of topical ocular dexamethasone to pregnant mice and rabbits during organogenesis produced embryofetal lethality, cleft palate and multiple visceral malformations [see Animal Data].

Data

Animal Data

Topical ocular administration of 0.15% dexamethasone (0.75 mg/kg/day) on gestational days 10 to 13 produced embryofetal lethality and a high incidence of cleft palate in a mouse study. A daily dose of 0.75 mg/kg/day in the mouse is approximately 5 times the entire dose of dexamethasone in the DEXTENZA product, on a mg/m² basis. In a rabbit study, topical ocular administration of 0.1% dexamethasone throughout organogenesis (0.36 mg /day, on gestational day 6 followed by 0.24 mg/day on gestational days 7-18) produced intestinal anomalies, intestinal aplasia, gastroschisis and hypoplastic kidneys. A daily dose of 0.24 mg/day is approximately 6 times the entire dose of dexamethasone in the DEXTENZA product, on a mg/m² basis.

8.2 Lactation

Systemically administered corticosteroids appear in human milk and could suppress growth and interfere with endogenous corticosteroid production; however the systemic concentration of dexamethasone following administration of DEXTENZA is low [see Clinical Pharmacology (12.3)]. There is no information regarding the presence of DEXTENZA in human milk, the effects of the drug on the breastfed infant or the effects of the drug on milk production to inform risk of DEXTENZA to an infant during lactation. The developmental and health benefits of breastfeeding should be considered along with the mother's clinical need for DEXTENZA and any potential adverse effects on the breastfed child from DEXTENZA.

8.4 Pediatric Use

Safety and effectiveness in pediatric patients have not been established.

8.5 Geriatric Use

No overall differences in safety or effectiveness have been observed between elderly and younger patients.

17 PATIENT COUNSELING INFORMATION

Advise patients to consult their surgeon if pain, redness, or itching develops.

Ocular
Therapeutix™

MANUFACTURED FOR:
Ocular Therapeutix, Inc.
Bedford, MA 01730 USA
PP-US-DX-0072

REVIEW | News

(Continued from p. 3)

says Dr. Chew. “Now, we’re looking extensively at diets, involvement of different nutrients and genetic interactions. We’re planning to release that data very soon.”

Overall, Dr. Chew says that the biggest accomplishment of the study is that it can allay any fears that taking calcium will worsen AMD, and that doctors can assure their patients that taking calcium is okay for their macular degeneration. **REVIEW**

1. Gopinath B, Flood VM, Louie JC, et al. Consumption of dairy products and the 15-year incidence of age-related macular degeneration. *Br J Nutr* 2014;111:9:1673-1679.
2. Kakigi CL, Singh K, Wang SY, Enanoria WT, Lin SC. Self-reported calcium supplementation and age-related macular degeneration. *JAMA Ophthalmol* 2015;133:7:746-754.

REVIEW | OPDI

(Continued from page 6)

• **Drug-eluting implant.** Generally speaking, drug/device combinations with the primary purpose being the delivery of the drug, are submitted and processed as a drug through CDER at the FDA (with appropriate input and review from the Device Division), and thus need to meet the clinical and preclinical requirements of a drug as well. Generally, a separate device approval isn’t required for a drug/device combination.

• **Contact lens rewetting drop.** Class II device, submitted via 510k process. This is one of the only examples in which an eye-drop solution is treated as a device in the United States. There is a detailed FDA Guidance Document on contact lens products, with standard ISO preclinical testing and clinical requirements. Note that clinical testing on the range of lenses the product is intended to be used with is required for a new rewetting drop.

• **iPad vision test.** If the software itself won’t provide a diagnosis, there’s still a consideration of how the results will impact a physician’s decision making. Quality control and software validations are based on the level of risk and need to be considered early in the process.

Mr. Chapin is senior vice president of corporate development at Ora, which offers device and drug consulting, as well as conducting clinical research and development. Mr. Bouchard is vice president for medical devices at Ora. The authors welcome your comments or questions regarding product development. Please send correspondence to mchapin@oraclinical.com or rbouchard@oraclinical.com, or visit www.oraclinical.com

For reference:

- www.fda.gov/MedicalDevices/DeviceRegulationandGuidance/HowtoMarketYourDevice/default.htm
- <https://www.fda.gov/downloads/training/cdrhlearn/ucm421766.pdf>
- www.fda.gov/MedicalDevices/DeviceRegulationandGuidance/HowtoMarketYourDevice/PremarketSubmissions/PremarketApprovalPMA/ucm047991.htm
- <https://www.fda.gov/medicaldevices/device-regulation-and-guidance/overview/generalandspecialcontrols/ucm055910.htm>

The POWER of the PULSE

Advanced Doctor Treatment for Anterior Blepharitis*

ASCRS Show Special - \$1,495 for the AB Max™ Starter Kit

The advanced technology of the PATENT PENDING AB Max™ delivers PULSE action for more efficient and rapid debridement. AB Max™ offers:

- Treatment of the same conditions as a standard Algerbrush** PLUS Anterior Blepharitis
- Removal of even the most tenacious scurf and debris
- Advanced Anterior Blepharoexfoliation



MAXimize Your Algerbrush Investment

The AB Max™ works seamlessly with your Algerbrush, transforming it into a multi-purpose device.

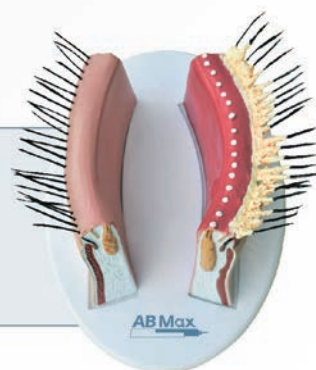
With AB Max™ you receive:

- BETTER treatment outcomes with HIGHER PROFITS
- Affordable Anterior Blepharoexfoliation
- 5X faster return on your investment
- Add \$100,000 to your bottom line WITHOUT a major investment



www.AB-Max.com • 800-721-8006

Visit us at ASCRS
booth # 513 and
ask about receiving
a FREE anatomical
eyelid model



*Anterior blepharitis means blepharitis on the outer eyelid margin, including the eyelashes.

**Algerbrush is a trademark of The Alger Companies. Myco Industries, Inc. is not affiliated with The Alger Companies. Patents pending Myco Industries, Inc. For use by medical professionals only.

CONTRIBUTORS

CHIEF MEDICAL EDITOR

Mark H. Blecher, MD

CONTACT LENSES

Penny Asbell, MD

CORNEA / ANTERIOR SEGMENT

Thomas John, MD

GLAUCOMA MANAGEMENT

Peter Netland, MD, PHD
Kuldev Singh, MD

MASTERS OF SURGERY

Taliva D. Martin, MD
Sara J. Haug, MD, PhD

MEDICARE Q & A

Paul M. Larson, MBA

PEDIATRIC PATIENT

Wendy Huang, MD

PLASTIC POINTERS

Ann P. Murchison, MD, MPH

REFRACTIVE SURGERY

Arturo S. Chayet, MD

RETINAL INSIDER

Carl Regillo, MD, FACS
Yoshihiro Yonekawa, MD

TECHNOLOGY UPDATE

Steven T. Charles, MD
Michael Colvard, MD

WILLS RESIDENT CASE SERIES

Jason Flamendorf, MD

ADVISORY BOARD

PENNY A. ASBELL, MD, MEMPHIS, TENN.

WILLIAM I. BOND, MD, PEKIN, ILL.

ALAN N. CARLSON, MD, DURHAM, N.C.

Y. RALPH CHU, MD, EDINA, MINN.

ADAM J. COHEN, MD, DOWNERS GROVE, ILL.

UDAY DEVGAN, MD, FACS, LOS ANGELES

ERIC DONNENFELD, MD, ROCKVILLE CENTRE, N.Y.

DANIEL S. DURRIE, MD, KANSAS CITY, MO.

ROBERT EPSTEIN, MD, MCHENRY, ILL.

ROBERT D. FECHTNER, MD, NEWARK, N.J.

WILLIAM J. FISHKIND, MD, TUCSON, ARIZ.

JAMES P. GILLS, MD, TARPON SPRINGS, FLA.

HARRY GRABOW, MD, SARASOTA, FLA.

DOUGLAS K. GRAYSON, MD, NEW YORK CITY

THOMAS S. HARBIN, MD, MBA, ATLANTA

DAVID R. HARDTEN, MD, MINNEAPOLIS

KENNETH J. HOFFER, MD, SANTA MONICA, CALIF.

JACK T. HOLLADAY, MD, MSEE, HOUSTON

JOHN D. HUNKELER, MD, KANSAS CITY, MO.

THOMAS JOHN, MD, TINLEY PARK, ILL.

ROBERT M. KERSHNER, MD, MS, PALM BEACH GARDENS, FLA.

GUY M. KEZIRIAN, MD, PARADISE VALLEY, ARIZ.

TERRY KIM, MD, DURHAM, N.C.

TOMMY KORN, MD, SAN DIEGO

DAVID A. LEE, MD, HOUSTON

FRANCIS S. MAH, MD, PITTSBURGH

NICK MAMALIS, MD, SALT LAKE CITY

WILLIAM G. MARTIN, MD, OREGON, OHIO

MIKE S. MCFARLAND, MD, PINE BLUFF, ARK.

JEFFREY B. MORRIS, MD, MPH, ENCINITAS, CALIF.

MARLENE R. MOSTER, MD, PHILADELPHIA

ROBERT J. NOECKER, MD, FAIRFIELD, CONN.

ROBERT OSHER, MD, CINCINNATI

MARK PACKER, MD, WEST PALM BEACH, FLA.

STEPHEN PASCUCCI, MD, BONITA SPRINGS, FLA.

PAUL PENDER, MD, BEDFORD, N.H.

CHRISTOPHER J. RAPUANO, MD, PHILADELPHIA

AUGUST READER III, MD, SAN FRANCISCO

TONY REALINI, MD, MORGANTOWN, W.V.

KENNETH J. ROSENTHAL, MD, GREAT NECK, N.Y.

ERIC ROTHCHILD, MD, DELRAY BEACH, FLA.

SHERI ROWEN, MD, BALTIMORE

JAMES J. SALZ, MD, LOS ANGELES

INGRID U. SCOTT, MD, MPH, HERSHEY, PA.

JOEL SCHUMAN, MD, PITTSBURGH

GAURAV SHAH, MD, ST. LOUIS

DAVID R. STAGER JR., MD, DALLAS

KARL STONECIPHER, MD, GREENSBORO, N.C.

JAMES C. TSAI, MD, NEW YORK CITY

VANCE THOMPSON, MD, SIOUX FALLS, S.D.

FARRELL C. TYSON, MD, CAPE CORAL, FLA.

R. BRUCE WALLACE III, MD, ALEXANDRIA, LA.

ROBERT G. WILEY, MD, CLEVELAND

FRANK WEINSTOCK, MD, CANTON, OHIO

BUSINESS OFFICES

11 CAMPUS BOULEVARD, SUITE 100
NEWTOWN SQUARE, PA 19073
SUBSCRIPTION INQUIRIES (877) 529-1746
(USA ONLY); OUTSIDE USA, CALL (847) 763-9630

BUSINESS STAFF

PUBLISHER

JAMES HENNE

(610) 492-1017 JHENNE@JOBSON.COM

REGIONAL SALES MANAGER

MICHELE BARRETT

(610) 492-1014 MBARRETT@JOBSON.COM

REGIONAL SALES MANAGER

MICHAEL HOSTER

(610) 492-1028 MHOSTER@JOBSON.COM

CLASSIFIED ADVERTISING

(888)-498-1460

VICE PRESIDENT OF OPERATIONS

CASEY FOSTER

(610) 492-1007 CFOSTER@JOBSON.COM

PRODUCTION MANAGER

SCOTT TOBIN

(610) 492-1011 STOBIN@JOBSON.COM

SUBSCRIPTIONS

\$63 A YEAR, \$99 (U.S.) IN CANADA,
\$158 (U.S.) IN ALL OTHER COUNTRIES.

SUBSCRIPTIONS E-MAIL:

REVOPHTHALMOLOGY@CAMBEYWEST.COM

CIRCULATION

PO BOX 71, CONGERS, NY 10920-0071
(877) 529-1746

OUTSIDE USA: (845) 267-3065

SENIOR CIRCULATION MANAGER

HAMILTON MAHER

(212) 219-7870 hmaher@jhihealth.com

CEO, INFORMATION GROUP SERVICES

MARC FERRARA

SENIOR VICE PRESIDENT, OPERATIONS

JEFF LEVITZ

VICE PRESIDENT, HUMAN RESOURCES

TAMMY GARCIA

VICE PRESIDENT, CREATIVE SERVICES & PRODUCTION

MONICA TETTAMANZI

CORPORATE PRODUCTION DIRECTOR

JOHN ANTHONY CAGGIANO

VICE PRESIDENT, CIRCULATION

EVELDA BAREA



440 Ninth Avenue, 14th Floor
New York, N.Y. 10001

REVIEW OF OPHTHALMOLOGY (ISSN 1081-0226; USPS No. 0012-345) is published monthly, 12 times per year by Jobson Medical Information, 440 Ninth Avenue, 14th Floor, New York, N.Y. 10001. Periodicals postage paid at New York, NY and additional mailing offices. Postmaster: Send address changes to Review of Ophthalmology, PO Box 71, Congers, NY 10929-0071. Subscription Prices: US One Year \$63.00, US Two Year \$112.00, Canada One Year \$99.00, Canada Two Year \$181.00, Int'l One Year \$158.00, Int'l Two Year \$274.00. For subscription information call (877) 529-1746 (USA only); outside USA, call (845)-267-3065. Or email us at revophthalmology@cambeywest.com. Canada Post: Publications Mail Agreement #40612608. Canada Returns to be sent to Bleuchip International, P.O. Box 25542, London, ON N6C 6B2.

SUBMICRON STRONG

Engineered with SM Technology™ for efficient penetration at a low BAK level (0.003%)^{1,2}

~2× GREATER PENETRATION to the aqueous humor^{2*}

*Compared to LOTEMAX® GEL (loteprednol etabonate ophthalmic gel) 0.5%. Clinical significance of these preclinical data has not been established.

LOTEMAX® SM
(loteprednol etabonate ophthalmic gel) 0.38%

SMALL & MIGHTY
SUBMICRON PARTICLES

PROVEN STRENGTH

- 30% of LOTEMAX® SM patients had complete ACC resolution vs vehicle (15%) at Day 8 (N=371, $P < 0.0001$)^{1,3†}
- 74% of LOTEMAX® SM patients were completely pain-free vs vehicle (49%) at Day 8 (N=371, $P < 0.0001$)^{1,3†}

†Pooled analysis of Phase 3 clinical studies. **Study 1:** 29% LOTEMAX® SM (N=171) vs 9% vehicle (N=172). **Study 2:** 31% LOTEMAX® SM (N=200) vs 20% vehicle (N=199); $P < 0.05$ for all.

‡Pooled analysis of Phase 3 clinical studies. **Study 1:** 73% LOTEMAX® SM (N=171) vs 48% vehicle (N=172). **Study 2:** 76% LOTEMAX® SM (N=200) vs 50% vehicle (N=199); $P < 0.05$ for all.

Indication

LOTEMAX® SM (loteprednol etabonate ophthalmic gel) 0.38% is a corticosteroid indicated for the treatment of post-operative inflammation and pain following ocular surgery.

Important Safety Information

- LOTEMAX® SM, as with other ophthalmic corticosteroids, is contraindicated in most viral diseases of the cornea and conjunctiva including epithelial herpes simplex keratitis (dendritic keratitis), vaccinia, and varicella, and also in mycobacterial infection of the eye and fungal diseases of ocular structures.
- Prolonged use of corticosteroids may result in glaucoma with damage to the optic nerve, defects in visual acuity and fields of vision. If LOTEMAX® SM is used for 10 days or longer, IOP should be monitored.
- Use of corticosteroids may result in posterior subcapsular cataract formation.

Important Safety Information (cont.)

- The use of steroids after cataract surgery may delay healing and increase the incidence of bleb formation. In those with diseases causing thinning of the cornea or sclera, perforations have been known to occur with the use of topical steroids. The initial prescription and renewal of the medication order should be made by a physician only after examination of the patient with the aid of magnification such as slit lamp biomicroscopy and, where appropriate, fluorescein staining.
- Prolonged use of corticosteroids may suppress the host response and thus increase the hazard of secondary ocular infections. In acute purulent conditions, steroids may mask infection or enhance existing infections.
- Employment of a corticosteroid medication in the treatment of patients with a history of herpes simplex requires great caution. Use of ocular steroids may prolong the course and may exacerbate the severity of many viral infections of the eye (including herpes simplex).
- Fungal infections of the cornea are particularly prone to develop coincidentally with long-term local steroid application. Fungus invasion must be considered in any persistent corneal ulceration where a steroid has been used or is in use. Fungal cultures should be taken when appropriate.
- Contact lenses should not be worn when the eyes are inflamed.
- There were no treatment-emergent adverse drug reactions that occurred in more than 1% of subjects in the three times daily group compared to vehicle.

You are encouraged to report negative side effects of prescription drugs to the FDA. Visit www.fda.gov/medwatch or call 1-800-FDA-1088.

Please see brief summary of Prescribing Information on adjacent page.

References: 1. LOTEMAX SM [prescribing information]. Bridgewater, NJ: Bausch & Lomb, Incorporated. 2. Cavet ME, Glogowski S, DiSalvo C, Richardson ME. Ocular pharmacokinetics of submicron loteprednol etabonate ophthalmic gel, 0.38% following topical administration in rabbits. Poster presented at 2015 ARVO Annual Meeting; May 4, 2015; Denver, Colorado. 3. Data on file. Bausch & Lomb, Inc.

BAUSCH+LOMB

©/TM are trademarks of Bausch & Lomb Incorporated or its affiliates.
© 2019 Bausch & Lomb Incorporated. All rights reserved. Printed in USA. LSM.0118.USA.19

Visit www.LOTEMAXSM.com

LOTEMAX® SM
(loteprednol etabonate ophthalmic gel) 0.38%

BRIEF SUMMARY OF PRESCRIBING INFORMATION

This Brief Summary does not include all the information needed to use LOTEMAX[®] SM safely and effectively. See full prescribing information for LOTEMAX[®] SM.

LOTEMAX[®] SM (loteprednol etabonate ophthalmic gel) 0.38%

For topical ophthalmic use

Initial U.S. Approval: 1998

INDICATIONS AND USAGE

LOTEMAX[®] SM is a corticosteroid indicated for the treatment of post-operative inflammation and pain following ocular surgery.

DOSAGE AND ADMINISTRATION

Invert closed bottle and shake once to fill tip before instilling drops. Apply one drop of LOTEMAX[®] SM into the conjunctival sac of the affected eye three times daily beginning the day after surgery and continuing throughout the first 2 weeks of the post-operative period.

CONTRAINDICATIONS

LOTEMAX[®] SM, as with other ophthalmic corticosteroids, is contraindicated in most viral diseases of the cornea and conjunctiva including epithelial herpes simplex keratitis (dendritic keratitis), vaccinia, and varicella, in mycobacterial infection of the eye and fungal diseases of ocular structures.

WARNINGS AND PRECAUTIONS

Intraocular Pressure (IOP) Increase: Prolonged use of corticosteroids may result in glaucoma with damage to the optic nerve, defects in visual acuity and fields of vision. Steroids should be used with caution in the presence of glaucoma. If this product is used for 10 days or longer, intraocular pressure should be monitored.

Cataracts: Use of corticosteroids may result in posterior subcapsular cataract formation.

Delayed Healing: The use of steroids after cataract surgery may delay healing and increase the incidence of bleb formation. In those diseases causing thinning of the cornea or sclera, perforations have been known to occur with the use of topical steroids. The initial prescription and renewal of the medication order should be made by a physician only after examination of the patient with the aid of magnification such as slit lamp biomicroscopy and, where appropriate, fluorescein staining.

Bacterial Infections: Prolonged use of corticosteroids may suppress the host response and thus increase the hazard of secondary ocular infections. In acute purulent conditions of the eye, steroids may mask infection or enhance existing infection.

Viral infections: Employment of a corticosteroid medication in the treatment of patients with a history of herpes simplex requires great caution. Use of ocular steroids may prolong the course and may exacerbate the severity of many viral infections of the eye (including herpes simplex).

Fungal Infections: Fungal infections of the cornea are particularly prone to develop coincidentally with long-term local steroid application. Fungus invasion must be considered in any persistent corneal ulceration where a steroid has been used or is in use. Fungal cultures should be taken when appropriate.

Contact Lens Wear: Contact lenses should not be worn when the eyes are inflamed.

ADVERSE REACTIONS

Because clinical trials are conducted under widely varying conditions, adverse reaction rates observed in the clinical trials of a drug cannot be directly compared to rates in the clinical trials of another drug and may not reflect the rates observed in practice. Adverse reactions associated with ophthalmic steroids include elevated intraocular pressure, which may be associated with infrequent optic nerve damage, visual acuity and field defects, posterior subcapsular cataract formation, delayed wound healing and secondary ocular infection from pathogens including herpes simplex, and perforation of the globe where there is thinning of the cornea or sclera. There were no treatment-emergent adverse drug reactions that occurred in more than 1% of subjects in the three times daily group compared to vehicle.

USE IN SPECIAL POPULATIONS

Pregnancy: Risk Summary: There are no adequate and well controlled studies with loteprednol etabonate in pregnant women. Loteprednol etabonate produced teratogenicity at clinically relevant doses in the rabbit and rat when administered orally during pregnancy. Loteprednol etabonate

produced malformations when administered orally to pregnant rabbits at doses 4.2 times the recommended human ophthalmic dose (RHOD) and to pregnant rats at doses 106 times the RHOD. In pregnant rats receiving oral doses of loteprednol etabonate during the period equivalent to the last trimester of pregnancy through lactation in humans, survival of offspring was reduced at doses 10.6 times the RHOD. Maternal toxicity was observed in rats at doses 1066 times the RHOD, and a maternal no observed adverse effect level (NOAEL) was established at 106 times the RHOD. The background risk of major birth defects and miscarriage for the indicated population is unknown. However, the background risk in the U.S. general population of major birth defects is 2 to 4%, and of miscarriage is 15 to 20%, of clinically recognized pregnancies. Data: *Animal Data.* Embryofetal studies were conducted in pregnant rabbits administered loteprednol etabonate by oral gavage on gestation days 6 to 18, to target the period of organogenesis. Loteprednol etabonate produced fetal malformations at 0.1 mg/kg (4.2 times the recommended human ophthalmic dose (RHOD) based on body surface area, assuming 100% absorption). Spina bifida (including meningocele) was observed at 0.1 mg/kg, and exencephaly and craniofacial malformations were observed at 0.4 mg/kg (17 times the RHOD). At 3 mg/kg (128 times the RHOD), loteprednol etabonate was associated with increased incidences of abnormal left common carotid artery, limb flexures, umbilical hernia, scoliosis, and delayed ossification. Abortion and embryofetal lethality (resorption) occurred at 6 mg/kg (256 times the RHOD). A NOAEL for developmental toxicity was not established in this study. The NOAEL for maternal toxicity in rabbits was 3 mg/kg/day. Embryofetal studies were conducted in pregnant rats administered loteprednol etabonate by oral gavage on gestation days 6 to 15, to target the period of organogenesis. Loteprednol etabonate produced fetal malformations, including absent innominate artery at 5 mg/kg (106 times the RHOD); and cleft palate, agnathia, cardiovascular defects, umbilical hernia, decreased fetal body weight and decreased skeletal ossification at 50 mg/kg (1066 times the RHOD). Embryofetal lethality (resorption) was observed at 100 mg/kg (2133 times the RHOD). The NOAEL for developmental toxicity in rats was 0.5 mg/kg (10.6 times the RHOD). Loteprednol etabonate was maternally toxic (reduced body weight gain) at 50 mg/kg/day. The NOAEL for maternal toxicity was 5 mg/kg. A peri/postnatal study was conducted in rats administered loteprednol etabonate by oral gavage from gestation day 15 (start of fetal period) to postnatal day 21 (the end of lactation period). At 0.5 mg/kg (10.6 times the clinical dose), reduced survival was observed in live-born offspring. Doses \geq 5 mg/kg (106 times the RHOD) caused umbilical hernia/incomplete gastrointestinal tract. Doses \geq 50 mg/kg (1066 times the RHOD) produced maternal toxicity (reduced body weight gain, death), decreased number of live-born offspring, decreased birth weight, and delays in postnatal development. A developmental NOAEL was not established in this study. The NOAEL for maternal toxicity was 5 mg/kg. **Lactation:** There are no data on the presence of loteprednol etabonate in human milk, the effects on the breastfed infant, or the effects on milk production. The developmental and health benefits of breastfeeding should be considered, along with the mother's clinical need for LOTEMAX[®] SM and any potential adverse effects on the breastfed infant from LOTEMAX[®] SM. **Pediatric Use:** Safety and effectiveness of LOTEMAX[®] SM in pediatric patients have not been established. **Geriatric Use:** No overall differences in safety and effectiveness have been observed between elderly and younger patients.

NONCLINICAL TOXICOLOGY

Carcinogenesis, Mutagenesis, Impairment of Fertility: Long-term animal studies have not been conducted to evaluate the carcinogenic potential of loteprednol etabonate. Loteprednol etabonate was not genotoxic *in vitro* in the Ames test, the mouse lymphoma tk assay, or in the chromosomal aberration test in human lymphocytes, or *in vivo* in the mouse micronucleus assay. Treatment of male and female rats with 25 mg/kg/day of loteprednol etabonate (533 times the RHOD based on body surface area, assuming 100% absorption) prior to and during mating caused preimplantation loss and decreased the number of live fetuses/live births. The NOAEL for fertility in rats was 5 mg/kg/day (106 times the RHOD).

LOTEMAX is a trademark of Bausch & Lomb Incorporated or its affiliates.

© 2019 Bausch & Lomb Incorporated

Bausch + Lomb, a division of Valeant Pharmaceuticals North America LLC
Bridgewater, NJ 08807 USA

LSM.0091.USA.19

Based on 9669600-9669700

Revised: 02/2019

REVIEW[®] of Ophthalmology

May 2019 • Volume XXV No. 5 | reviewofophthalmology.com

Cover Story

20 | **Saving Private Practice: Is Solo Still Viable?**

Christopher Kent, Senior Editor

Being on your own comes with many advantages and challenges—especially today.

Features

32 | **EHR: Room for Improvement?**

Alexandra Skinner, Associate Editor

Doctors discuss EHR issues that need attention, and suggest ways to improve current systems.

40 | **The Questionable Cataract: Who Decides?**

Walter Bethke, Editor in Chief

Surgeons share tips to help you navigate the sometimes murky waters of preop evaluations.

48 | **How to Manage Uveitic Glaucoma**

Lama Al-Aswad, MD, MPH

Tips and techniques for dealing with this unique subset of glaucoma patients.

54 | **Strong Moves for Weak Zonules**

Michelle Stephenson, Contributing Editor

Experts share their best tips for managing these difficult cases.

Departments

3 | [Review News](#)

16 | [Medicare Q & A](#)

The Medicare Appeals Process

Appealing a claim can be daunting. Here's how to navigate the process, should you need to make an appeal.

60 | [Research Review](#)

Statins' Value vs. Diabetic Retinopathy

62 | [Glaucoma Management](#)

Managing Glaucoma with OCT Angiography

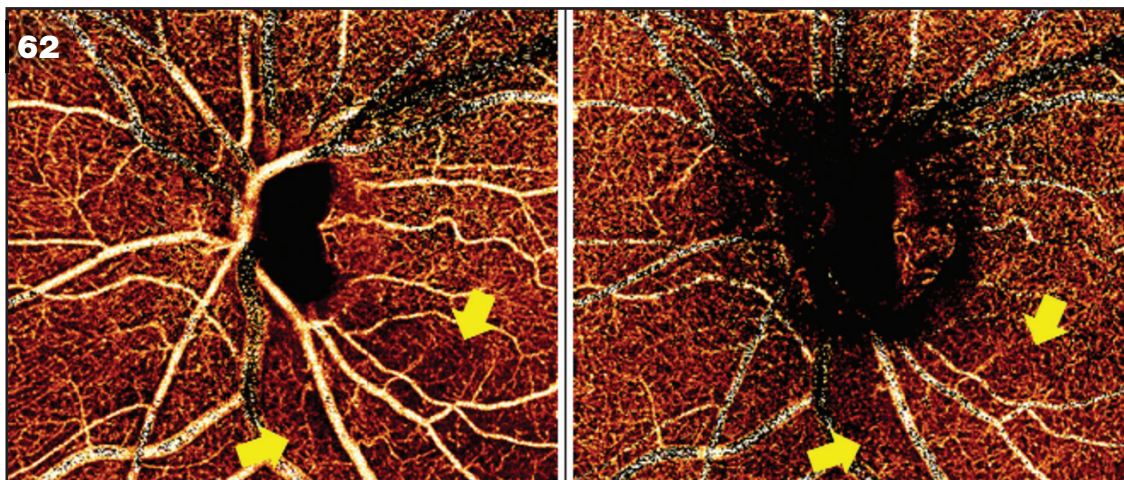
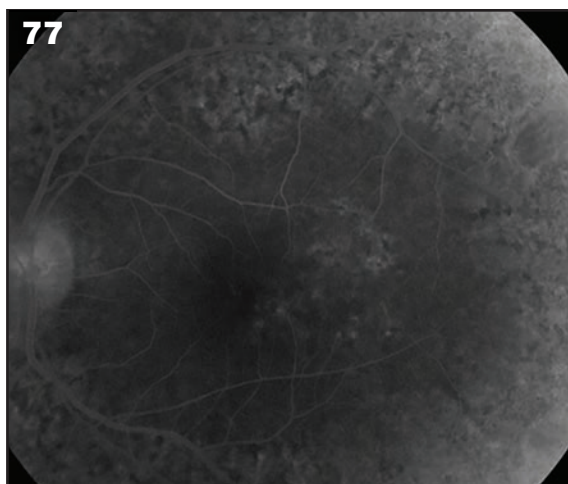
This technology is showing promise as a clinical tool for diagnosing and monitoring glaucoma patients.

70 | [Product News](#)

76 | [Classifieds](#)

76 | [Ad Index](#)

77 | [Wills Eye Resident Case Series](#)



iStent
inject®

TRANSFORMING MIGS IN MORE WAYS THAN ONE.

Optimized Outflow: Two multi-directional stents designed to restore natural outflow

Clinically Proven: Significant IOP reduction across a wide range of clinical studies^{1,2}

Procedural Elegance: Predictability and precision to meet the needs of your practice

Proven Safety: Safety profile similar to cataract surgery alone¹



ASCRS BOOTH 3145

All with the exceptional customer support you've come to expect from Glaukos.

TransformMIGS.com | 800.GLAUKOS (452.8567)

INDICATION FOR USE. The iStent *inject*® Trabecular Micro-Bypass System Model G2-M-IS is indicated for use in conjunction with cataract surgery for the reduction of intraocular pressure (IOP) in adult patients with mild to moderate primary open-angle glaucoma. **CONTRAINDICATIONS.** The iStent *inject* is contraindicated in eyes with angle-closure glaucoma, traumatic, malignant, uveitic, or neovascular glaucoma, discernible congenital anomalies of the anterior chamber (AC) angle, retrolubar tumor, thyroid eye disease, or Sturge-Weber Syndrome or any other type of condition that may cause elevated episcleral venous pressure. **WARNINGS.** Gonioscopy should be performed prior to surgery to exclude congenital anomalies of the angle, PAS, rubeosis, or conditions that would prohibit adequate visualization of the angle that could lead to improper placement of the stent and pose a hazard. **MRI INFORMATION.** The iStent *inject* is MR-Conditional, i.e., the device is safe for use in a specified MR environment under specified conditions; please see Directions for Use (DFU) label for details. **PRECAUTIONS.** The surgeon should monitor the patient postoperatively for proper maintenance of IOP. The safety and effectiveness of the iStent *inject* have not been established as an alternative to the primary treatment of glaucoma with medications, in children, in eyes with significant prior trauma, abnormal anterior segment, chronic inflammation, prior glaucoma surgery (except SLT performed > 90 days preoperative), glaucoma associated with vascular disorders, pseudoexfoliative, pigmentary or other secondary open-angle glaucomas, pseudophakic eyes, phakic eyes without concomitant cataract surgery or with complicated cataract surgery, eyes with medicated IOP > 24 mmHg or unmedicated IOP < 21 mmHg or > 36 mmHg, or for implantation of more or less than two stents. **ADVERSE EVENTS.** Common postoperative adverse events reported in the randomized pivotal trial included stent obstruction (6.2%), intraocular inflammation (5.7% for iStent *inject* vs. 4.2% for cataract surgery only), secondary surgical intervention (5.4% vs. 5.0%) and BCVA loss \geq 2 lines \geq 3 months (2.6% vs. 4.2%). **CAUTION:** Federal law restricts this device to sale by, or on the order of, a physician. Please see DFU for a complete list of contraindications, warnings, precautions, and adverse events.

REFERENCES: 1. iStent *inject*® Trabecular Micro-Bypass System: Directions for Use, Part #45-0176. 2. Hengerer FH. Personal experience with second-generation trabecular micro-bypass stents in combination with cataract surgery in patients with glaucoma: 3-year follow-up. ASCRS 2018 Presentation.

© 2018 Glaukos Corporation. Glaukos and iStent *inject* are registered trademarks of Glaukos Corporation. PM-US-0026

GLAUKOS®
Transforming Glaucoma Therapy



The Medicare Appeals Process

Appealing a claim can be daunting. Here's how to navigate the process, should you need to make an appeal.

Q One of my Medicare claims was denied and now I need to appeal. How does the Medicare Appeals process work?

A Not every claim you file with Medicare will go through smoothly the first time, but in many cases it's obvious to your billing staff what went awry. In that situation, fixing the issue and resubmitting or reopening the claim may result in correct processing and proper payment without a formal appeal. Sometimes, however, a paid or submitted claim is reviewed by a payer and formally denied. Denials after a review by your Medicare contractor can happen for a number of reasons:

- **Diagnosis not on payer list for coverage.** If a doctor has chart documentation that says a patient has a certain disease, and that disease isn't on the payer list for coverage, then the service you delivered (e.g. surgery, diagnostic test or exam) is considered non-covered.
- **Medical necessity considerations—even with a proper diagnosis.** Most often, these occur when the payer's pub-

lished guidance isn't followed, or proper documentation isn't used (even if there isn't published guidance).

Check the chart when the payer says you have an incorrect diagnosis; some services are published as only covered for certain specific diagnoses. If your patient has noncovered diagnosis "X," and the payer allows only "A, B or C" for payment, then this isn't an appeal you're likely to win—although you can write to the Medicare Contractor requesting this be a covered diagnosis in the future.

Formal denials for medical necessity or lack of documentation require more work. Medicare has an official process with various levels of appeal.

Q I found out I have to appeal something formally. What's the first level of the appeal process?

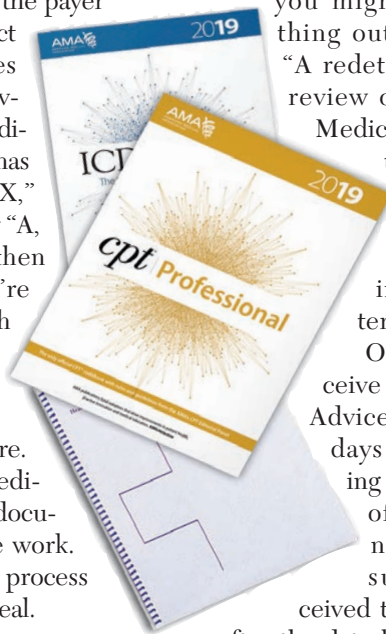
A The first level of appeal is known as Redetermination. You can access the CMS-20027 form on

your local Medicare Administrative Contractor's website or get it directly from CMS. (You can do it without the form but it isn't advised since


you might leave something out.) CMS notes, "A redetermination is a review of the claim by Medicare Administrative Contractor (MAC) personnel not involved in the initial claim determination."

Once you receive the Remittance Advice, you have 120 days to file according to the RA's date of receipt. CMS notes that it's assumed you received the RA five days

after the date listed on the notice. Your MAC will also inform you, "If you wish to avoid recoupment from occurring you need to file your request for redetermination within 30 days from the date of this letter as described above." Note that the date on the letter is not the date you are assumed to have received it—an



Less stress, pure success ...in your O.R. day¹



OMIDRIA® (phenylephrine and ketorolac intraocular solution) 1% / 0.3% is added to ophthalmic irrigating solution used during cataract surgery or intraocular lens replacement and is indicated for maintaining pupil size by preventing intraoperative miosis and reducing postoperative ocular pain.

The data are compelling and consistent—OMIDRIA makes cataract surgery better for you and your patients

Published and presented clinical studies and manuscripts in press and/or in preparation report that in post-launch (i.e., not included in current labeling), prospective and retrospective, double-masked and open-label, cohort and case-controlled, single- and multi-center analyses, the use of OMIDRIA, compared to the surgeons' standard of care, statistically significantly:

- Prevents Intraoperative Floppy Iris Syndrome (IFIS)²
- Reduces complication rates (epinephrine comparator)³
- Decreases use of pupil-expanding devices (epinephrine comparator)³⁻⁸
- Reduces surgical times (epinephrine comparator)^{3,5,7,8}
- Prevents miosis during femtosecond laser-assisted surgery (epinephrine comparator)^{6,9}
- Improves uncorrected visual acuity on day after surgery (epinephrine comparator)³
- Delivers NSAID to the anterior chamber and related structures better than routine preoperative topical drug administration, resulting in effectively complete postoperative inhibition of COX-1 and COX-2^{10,11}
- Reduces the incidence of rebound iritis, postoperative pain/ photophobia, and cystoid macular edema (CME) in patients without preoperative vitreomacular traction (VMT), when used with a postoperative topical NSAID (compared to postoperative topical NSAID + corticosteroid without OMIDRIA)¹²

OMIDRIA inhibits prostaglandin release, reducing intraoperative inflammation, to prevent miosis and reduce postoperative pain¹³

OMIDRIA is separately reimbursed under Medicare Part B and by many Medicare Advantage and commercial payers.*

Contact your OMIDRIA representative today or visit omidria.com to learn more.

*Based on currently available information and subject to change without notice. Individual plan coverage, policies, and procedures may vary and should be confirmed. Omeros does not guarantee coverage or payment.

IMPORTANT SAFETY INFORMATION

OMIDRIA must be added to irrigating solution prior to intraocular use.

OMIDRIA is contraindicated in patients with a known hypersensitivity to any of its ingredients.

Systemic exposure of phenylephrine may cause elevations in blood pressure.

Use OMIDRIA with caution in individuals who have previously exhibited sensitivities to acetylsalicylic acid, phenylacetic acid derivatives, and other nonsteroidal anti-inflammatory drugs (NSAIDs), or have a past medical history of asthma.

The most commonly reported adverse reactions at ≥2% are eye irritation, posterior capsule opacification, increased intraocular pressure, and anterior chamber inflammation.

Please see the Full Prescribing Information for OMIDRIA at www.omidria.com/prescribinginformation.

You are encouraged to report Suspected Adverse Reactions to the FDA.

Visit www.fda.gov/medwatch, or call 1-800-FDA-1088.

References: 1. Omeros survey data on file. 2. Silverstein SM, Rana V, Stephens R, Segars L, Pankratz J, Shivani R, et al. Effect of phenylephrine 1.0%-ketorolac 0.3% injection on tamulosin-associated intraoperative floppy-iris syndrome. *J Cataract Refract Surg*. 2018;44(9):1103-1108. 3. Rosenberg ED, Nattis AS, Alevi D, et al. Visual outcomes, efficacy, and surgical complications associated with intracameral phenylephrine 1.0%/ketorolac 0.3% administered during cataract surgery. *Clin Ophthalmol*. 2018;12:21-28. 4. Bucci FA, Jr, Michalek B, Fluet AT. Comparison of the frequency of use of a pupil expansion device with and without an intracameral phenylephrine and ketorolac injection 1%/0.3% at the time of routine cataract surgery. *Clin Ophthalmol*. 2017;11:1039-1043. 5. Visco D. Effect of phenylephrine/ketorolac on iris fixation ring use and surgical times in patients at risk of intraoperative miosis. *Clin Ophthalmol*. 2018;12:301-305. 6. Walter K, Delwadia N. Miosis prevention in femtosecond cataract surgery using a continuous infusion of phenylephrine and ketorolac. Presented at: 2018 American Society of Cataract and Refractive Surgery (ASCRS) and American Society of Ophthalmic Administrators (ASOA) Annual Meeting; April 13-17, 2018; Washington, DC. 7. Matossian C. Clinical outcomes of phenylephrine/ketorolac vs. epinephrine in cataract surgery in a real-world setting. Presented at: American Society of Cataract and Refractive Surgery (ASCRS) and American Society of Ophthalmic Administrators (ASOA) Annual Meeting; April 13-17, 2018; Washington, DC. 8. Al-Hashimi S, Donaldson K, Davidson R, et al. Medical and surgical management of the small pupil during cataract surgery. *J Cataract Refract Surg*. 2018;44:1032-1041. 9. Gayton JL. E-poster presented at: 15th International Congress on Vision Science and Eye; 2017 Aug 10-11; London, UK. 10. Katsev DA, Katsev CC, Pinnow J, Lockhart CM. Intracameral ketorolac concentration at the beginning and end of cataract surgery following preoperative topical ketorolac administration. *Clin Ophthalmol*. 2017;11:1897-1901. 11. Waterbury LD. Alternative drug delivery for patients undergoing cataract surgery as demonstrated in a canine model. *J Ocul Pharmacol Ther*. 2018;34:154-160. 12. Visco D, et al. Study to evaluate patient outcomes following cataract surgery when using OMIDRIA with postoperative topical NSAID administration versus a standard regimen of postoperative topical NSAIDs and steroids. Presented at: 28th Annual Meeting of the American College of Eye Surgeons (ACES), the American Board of Eye Surgery (ABES), and the Society for Excellence in Eyecare (SEE), Caribbean Eye Meeting; February 1-5, 2019; Cancun, Mexico. 13. OMIDRIA [package insert]. Seattle, WA: Omeros Corporation; 2017.

OMIDRIA® and the OMIDRIA logo® are registered trademarks of Omeros Corporation.
© Omeros Corporation 2019, all rights reserved. 2019-006



OMIDRIA®

(phenylephrine and ketorolac
intraocular solution)
1% / 0.3%

important distinction.

Recoupment means that if you don't pay the demand in full, the owed money will be subtracted from other payments you'll get. Importantly, interest begins accruing on any balance, even if you elect to stop recoupment, and it'll continue to accrue until you finally win (in which case it would go away in full), or lose (in which case you would owe it all plus the interest). The interest rate in effect is 10.75 percent (simple, not compound).

CMS adds that you should include "any and all documentation that supports the argument against the previous decision." Leave out anything that doesn't help your argument. This information (chart, op note, test result, anything you write, etc.) is sent with the form to the MAC that made the original determination. The sending address can be found on the MAC website, in the Redetermination process section. Keep a complete copy of what you send. There isn't a minimum dollar amount regarding the amount in controversy that's needed to file. You can mail or send your packet electronically, but regardless of how it's sent, be sure to get a return receipt so you know it was delivered.

Q I lost a first-level appeal. What can I do next if I want to pursue it further?

A Your MAC will have notified you via a Redetermination Notice as to whether or not the decision was in your favor. If the decision was unfavorable, you can forgo the appeal process and have it recouped gradually, pay it in full, or go to a second-level appeal known as Reconsideration. Again, CMS assumes you've received the notice five days after the date listed. Be sure to see if the denial is for the same reason, and if not, address it carefully. There's a different form for second-level appeals—CMS-20033. Your

2019 Medicare Appeals Process

Process: Level of Appeal	Days for Provider to File Appeal	Time Limit for Reviewer to Respond	Minimum Amount in Controversy (AIC)
Redetermination	120 days	60 days	\$0
Reconsideration	180 days	60 days	\$0
Administrative Law Judge	60 days	90 days	\$160
Department Appeals Board	60 days	90 days	\$0
Federal District Court	60 days	N/A	\$1,630

MAC can provide instructions and forms, or you can download the documents from CMS.

You have 180 days to file a Reconsideration based on the date listed on the notice received, but recoupment will begin no earlier than 60 days from the date on the letter, unless you notify them. This appeal doesn't go to your MAC; instead it goes to a Qualified Independent Contractor (QIC). Again, there's no minimum amount in controversy required to file an appeal, but this is likely your last chance to send any new information that could help your case. CMS notes, "Any documentation not submitted at the reconsideration level may be excluded from consideration at subsequent levels of appeal ..." They add, "The reconsideration decision will contain detailed information on further appeals rights, where applicable."

Q I lost part of the second-level appeal. What's next?

A If your Reconsideration goes unfavorably, in full or part, you can proceed to a third level of appeal—an Administrative Law Judge (ALJ) hearing—but recoupment begins immediately. A third form is needed, the OHMA-100, and you have 60 days from the receipt of the

QIC notice to file. There must be at least \$160 in controversy and it's unlikely that additional information can be submitted.

There are fourth and fifth levels of appeal, but they are rarely required. At the fifth level, you must file within 60 days and have at least \$1,630 in controversy. The appeal is filed with the Federal District Court, and it's a good idea to have a lawyer represent you.

Q Can you summarize how to be successful when formally appealing?

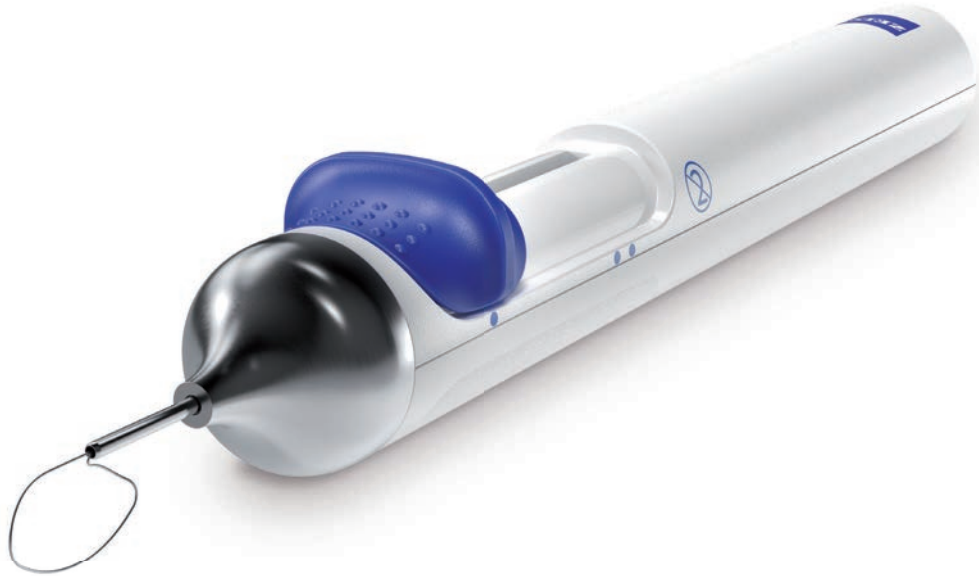A Successful appeals require paying close attention to payer guidance, if it exists, and meeting medical necessity requirements. Reasons for any denials are important to address, as subsequent rounds of appeal might not be denied or questioned for the same reason(s).

The required timelines to return your information and (separately) avoid recoupment require monitoring, as these change based on the level of appeal. **REVIEW**

Mr. Larson is a senior consultant at the Corcoran Consulting Group. Contact him at plarson@corcoranccg.com.

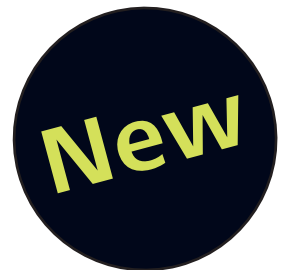Experiencing zero-energy lens fragmentation.

ZEISS miLOOP



Keep the zonules intact


The new miLOOP® from ZEISS is a micro-interventional device, developed to deliver zero-energy¹ lens fragmentation and achieve full-thickness lens fragmentation. The dissecting action of ZEISS miLOOP is designed to reduce force on the delicate capsular bag and zonules.



Lens cracking

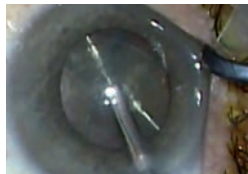

Lens cracking

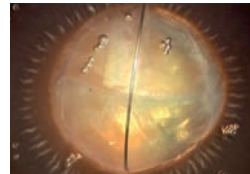


Broken zonules

Lens fragmentation with ZEISS miLOOP



Lens fragmentation



Preserved zonules

More product information:
www.zeiss.com/miloop



¹ without the need to apply energy from phacoemulsification

Saving Private Practice: Is Solo Still Viable?

Christopher Kent, Senior Editor

Being on your own comes with many advantages and challenges—especially today.

It's no secret that practicing medicine "ain't what it used to be." Escalating costs, reduced reimbursements, having to implement electronic medical records, managing relationships with insurance companies, keeping up with billing and coding rules, and staying on top of government regulations are just some of the challenges facing anyone in medicine today. Many ophthalmologists are dealing with these nonmedical matters by circling their wagons and joining with other doctors and/or institutions. The question is: Can a doctor in solo private practice survive in this environment?

"I've been consulting for ophthalmologists for 40 years, and every year I've heard the tribal beat that small private practice is moribund and will soon be unavailable as a professional option," says John Pinto, president of J. Pinto & Associates, an ophthalmic practice management consulting firm. "Of course, private, independent practices continue to do just fine. This way of practicing has survived massive drops in fees, the encroachment of health systems on a local and regional basis, the 1990s encroachment of Wall Street, and the Great Recession. And it's doing just fine in the midst of the latest industry shift—putting practices together in a private equity context.

"Today, there are about 7,000 private ophthalmology practices in this country," he adds. "That number may decline over time, but for those doctors who want to be private practitioners, the opportunities are still there. In fact, we've recently gotten an increasing number of calls from doctors in academic or institutional settings who want to go out and hang a shingle. So the interest in solo practice is still very real."

The Challenges

It's not hard to see why surgeons like being in private practice. "The appeal of being in private practice is the same as always—being in control," says Mr. Pinto. Specifically, doctors in private practice cite advantages that include: getting to structure their practice the way they want it to be; being able to make decisions without having to get approval from others; being able to decide how much responsibility they'll take on in the office, potentially eliminating the need to hire technicians (a huge cost saving); and being able to decide how many hours a week they want to work.

On the other hand, the challenges faced by private, independent practices today—especially boutique-scale practices—are considerable. Those

INVELTYS

The **first and only** corticosteroid
FDA approved for **BID treatment**
of post-operative inflammation and pain
following ocular surgery



BID STRONG

Powered by **AMPPLIFY™ Drug Delivery Technology**

Indication

INVELTYS (loteprednol etabonate ophthalmic suspension) 1% is indicated for the treatment of post-operative inflammation and pain following ocular surgery.

Important Safety Information

INVELTYS is contraindicated in most viral diseases of the cornea and conjunctiva including epithelial herpes simplex keratitis (dendritic keratitis), vaccinia, and varicella, and also in mycobacterial infection of the eye and fungal diseases of ocular structures.

Prolonged use of corticosteroids may result in glaucoma with damage to the optic nerve, defects in visual acuity and fields of vision. If this product is used for 10 days or longer, IOP should be monitored.

Use of corticosteroids may result in posterior subcapsular cataract formation.

Use of steroids after cataract surgery may delay healing and increase the incidence of bleb formation. In those diseases causing thinning of the cornea or sclera, perforations have been known to occur with the use of topical steroids. The initial prescription and renewal of the medication order should be made by a physician only after examination of the patient with the aid of magnification such as slit lamp biomicroscopy and, where appropriate, fluorescein staining.

Prolonged use of corticosteroids may suppress the host response and thus increase the hazard of secondary ocular infections. In acute purulent conditions, steroids may mask infection or enhance existing infection.

Use of a corticosteroid medication in the treatment of patients with a history of herpes simplex requires great caution. Use of ocular steroids may prolong the course and may exacerbate the severity of many viral infections of the eye (including herpes simplex).

Fungal infections of the cornea are particularly prone to develop coincidentally with long-term local steroid application. Fungus invasion must be considered in any persistent corneal ulceration where a steroid has been used or is in use.

In clinical trials, the most common adverse drug reactions were eye pain (1%) and posterior capsular opacification (1%). These reactions may have been the consequence of the surgical procedure.

Please see Brief Summary of Prescribing Information for INVELTYS on the next page.

INVELTYS™

(loteprednol etabonate
ophthalmic suspension) 1%

INVELTYS™ (loteprednol etabonate ophthalmic suspension) 1%, for topical ophthalmic use

BRIEF SUMMARY OF FULL PRESCRIBING INFORMATION

INDICATIONS AND USAGE

INVELTYS is a corticosteroid indicated for the treatment of post-operative inflammation and pain following ocular surgery.

CONTRAINDICATIONS

INVELTYS is contraindicated in most viral diseases of the cornea and conjunctiva including epithelial herpes simplex keratitis (dendritic keratitis), vaccinia, and varicella, and also in mycobacterial infection of the eye and fungal diseases of ocular structures.

WARNINGS AND PRECAUTIONS

Intraocular Pressure (IOP) Increase—Prolonged use of corticosteroids may result in glaucoma with damage to the optic nerve, as well as defects in visual acuity and fields of vision. Steroids should be used with caution in the presence of glaucoma. If this product is used for 10 days or longer, intraocular pressure should be monitored.

Cataracts—Use of corticosteroids may result in posterior subcapsular cataract formation.

Delayed Healing—Use of steroids after cataract surgery may delay healing and increase the incidence of bleb formation. In those diseases causing thinning of the cornea or sclera, perforations have been known to occur with the use of topical steroids. The initial prescription and renewal of the medication order should be made by a physician only after examination of the patient with the aid of magnification such as slit lamp biomicroscopy and, where appropriate, fluorescein staining.

Bacterial Infections—Prolonged use of corticosteroids may suppress the host response and thus increase the hazard of secondary ocular infections. In acute purulent conditions of the eye, steroids may mask infection or enhance existing infection.

Viral Infections—Use of corticosteroid medication in the treatment of patients with a history of herpes simplex requires great caution. Use of ocular steroids may prolong the course and may exacerbate the severity of many viral infections of the eye (including herpes simplex).

Fungal Infections—Fungal infections of the cornea are particularly prone to develop coincidentally with long-term local steroid application. Fungus invasion must be considered in any persistent corneal ulceration where a steroid has been used or is in use. Fungal cultures should be taken when appropriate.

Contact Lens Wear—The preservative in INVELTYS may be absorbed by soft contact lenses. Contact lenses should be removed prior to instillation of INVELTYS and may be reinserted 15 minutes following administration.

ADVERSE REACTIONS

Adverse reactions associated with ophthalmic steroids include elevated intraocular pressure, which may be associated with infrequent optic nerve damage, visual acuity and field defects, posterior subcapsular cataract formation, delayed wound healing and secondary ocular infection from pathogens including herpes simplex, and perforation of the globe where there is thinning of the cornea or sclera.

Clinical Trial Experience—Because clinical trials are conducted under widely varying conditions, adverse reaction rates observed in the clinical trials of a drug cannot be directly compared to rates in the clinical trials of another drug and may not reflect the rates observed in practice. The most common adverse drug reactions in the clinical trials with INVELTYS were eye pain and posterior capsular opacification, both reported in 1% of patients. These reactions may have been the consequence of the surgical procedure.

USE IN SPECIFIC POPULATIONS

Pregnancy—Risk Summary: INVELTYS is not absorbed systemically following topical ophthalmic administration and maternal use is not expected to result in fetal exposure to the drug.

Lactation—Risk Summary: INVELTYS is not absorbed systemically by the mother following topical ophthalmic administration, and breastfeeding is not expected to result in exposure of the child to INVELTYS.

Pediatric Use—Safety and effectiveness in pediatric patients have not been established.

Geriatric Use—No overall differences in safety and effectiveness have been observed between elderly and younger patients.

NONCLINICAL TOXICOLOGY

Carcinogenesis, Mutagenesis, Impairment of Fertility—Long-term animal studies have not been conducted to evaluate the carcinogenic potential of loteprednol etabonate. Loteprednol etabonate was not genotoxic *in vitro* in the Ames test, the mouse lymphoma thymidine kinase (tk) assay, or in a chromosome aberration test in human lymphocytes, or *in vivo* in the single dose mouse micronucleus assay.

For a copy of the Full Prescribing Information, please visit www.INVELTYS.com.

Manufactured for:
Kala Pharmaceuticals, Inc. Waltham, MA 02453
Marks designated by TM and © are owned by
Kala Pharmaceuticals, Inc.
Patented. See www.kalarx.com/patents
© 2018 Kala Pharmaceuticals, Inc. All rights reserved.
US-INV-1800055 December 2018

First-hand Experience: Getting Started

Michael Stock, MD, recently opened a solo practice in St. Louis. Before that, he'd started out by joining another solo provider. "That didn't work out," he explains. "We had very different philosophies about how to treat patients and manage a practice. So I decided to branch out on my own, and I started my own practice in May of 2018."

Dr. Stock says the first practice situation was a useful learning experience. "I wasn't sure from the outset whether or not it would work out, so I spent every minute learning as much as I could about running a business," he says. "Then, when it became clear that it was time to go our separate ways, I realized I could try the same thing again and possibly end up with the same problem, or I could try going out on my own."

"Today, the reality is that ophthalmologists are in demand," he continues. "The number of new doctors coming into practice is smaller than the number of doctors who are retiring. So I realized that even though I have a family and kids, I could try solo practice for a year. If I ended up falling flat on my face, I would have lost a year, but I could get hired by another practice in a second. So, I found a spot and set up my own practice."

Richard L. Lindstrom, MD, managing partner at Minnesota Eye Consultants and an attending surgeon at the Phillips Eye Institute and Minnesota Eye Laser and Surgery Center in Minneapolis, has

been in solo practice as well. "I was in an academic group practice for 10 years," he explains. "Then, when I left the university, I went into solo practice as an anterior segment surgeon doing cornea and cataract, refractive and glaucoma. I started with six employees and my own office, which was small—1,500 square feet—with four or five lanes. I had two certified ophthalmic medical technologists to work up patients, a fellow, one nurse, one person at the front desk, one business office and an administrative assistant. My practice was adjacent to the Phillips Eye Institute, so I was able to use all of their lasers and advanced diagnostic equipment."

"There were definitely some attractive things about being in solo private practice, and I stayed in solo practice for about two years before I was joined by my first associate," he continues. "Now, 30 years later, we have 30 doctors in our practice—18 ophthalmologists and 12 optometrists. We also have three physician's assistants and just over 300 employees manning five offices with adjacent ASCs, four of which we own."

"My story is different from some solo doctors', because I always intended to build a larger group practice," he adds. "But I've experienced all the models, in terms of practice size, and I can testify that being in solo practice can work and be enjoyable."

—CK

challenges include:

- **Financial challenges.** "The cost of hiring qualified lay staff has been going up faster than inflation," notes Mr. Pinto. "The cost of bringing in professional colleagues as partner-track associates is also going up, because we're not training enough new ophthalmologists. Then there's the cost of technology, both in terms of advanced testing and treatment equipment—a pretty heavy lift for a small practice—and the challenges inherent in adopting EHR."

"Nowadays, to build a nice office and equip it well will cost you \$600,000 to a million dollars," says Richard L. Lindstrom, MD, managing partner at Minnesota Eye Consultants and an attending surgeon at the Phillips Eye Institute and Minnesota Eye Laser and Surgery Center in Minneapolis. "When I went into solo practice 30 years ago, I had to borrow \$60,000, but I had 10 years at the university un-

der my belt, a well-established practice and no debt. Today, many doctors are starting out with significant debt; they've had to borrow money to get through college and medical school."

He notes that it's also harder to borrow that money from a bank than it used to be. "Doctors are not as secure a risk as we once were," he says. "That means that an individual may need some family money or support to get started. I'm sure that's part of the reason the majority of residents coming into practice today are joining at least a small group, and not just hanging out a shingle. I'd estimate that only 5 percent of today's young doctors can manage the start-up expenses."

- **Managing insurance claims.** In terms of challenges, Kerry McKillop, COE and practice administrator at the Kirk Eye Center, a solo practice in Loveland, Colorado, says that billing continues to become more time-consuming. "We have a great billing

manager who's been with us for about 19 years," she notes. "She stays up-to-date on what every insurance company needs, and that's quite a chore. In fact, she used to be able to handle all of the billing and payment issues by herself; now our office manager spends a good deal of time entering payments as well. Luckily, we have a computer system that helps us manage some of the details, such as letting us know about a patient's eligibility before the patient comes in. That tells us what information we need to collect from the patient, so we don't spend time collecting that after the fact."

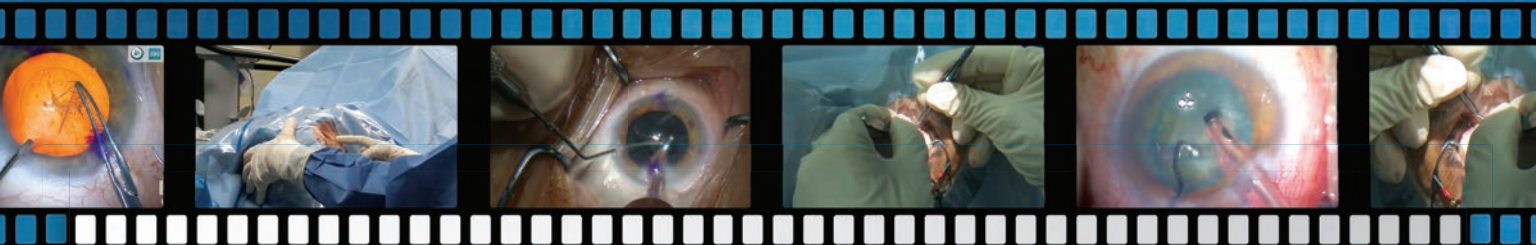
- **Government regulations.** Ms. McKillop notes that increasing government regulations also make things tougher. "We have to keep up with all the MIPS things, of course, and they change yearly," she says. "That forces us to make changes periodically, which gets tiresome. On the other hand, they're not impossible to manage, and



Monthly

MACKOOL ONLINE CME

CME SERIES | SURGICAL VIDEOS



To view CME video
go to:

www.MackoolOnlineCME.com

Episode 41: "A Controlling Floppy Iris and Zonular Laxity with Capsule Retractors"

Surgical Video by:
Richard J. Mackool, MD

Video Overview:

An 80 year old Flomax patient with severe zonular laxity can present a number of challenges during cataract surgery. Here I demonstrate how the proper use of capsule retractors makes the case safer for the patient and easier for the surgeon.

MackoolOnlineCME.com MONTHLY Video Series



Richard J. Mackool, MD

We are excited to continue into our fourth year of Mackool Online CME. With the generous support of several ophthalmic companies, I am honored to have our viewers join me in the operating room as I demonstrate the technology and techniques that I have found to be most valuable, and that I hope are helpful to many of my colleagues. We continue to edit the videos only to either change camera perspective or to reduce down time - allowing you to observe every step of the procedure.

As before, one new surgical video will be released monthly, and physicians may earn CME credits or just observe the case. New viewers are able to obtain additional CME credit by reviewing previous videos that are located in our archives.

I thank the many surgeons who have told us that they have found our CME program to be interesting and instructive; I appreciate your comments, suggestions and questions. Thanks again for joining us on Mackool Online CME.



CME Accredited Surgical Training Videos Now Available Online: www.MackoolOnlineCME.com

Richard Mackool, MD, a world renowned anterior segment ophthalmic microsurgeon, has assembled a web-based video collection of surgical cases that encompass both routine and challenging cases, demonstrating both familiar and potentially unfamiliar surgical techniques using a variety of instrumentation and settings.

This educational activity aims to present a series of Dr. Mackool's surgical videos, carefully selected to address the specific learning objectives of this activity, with the goal of making surgical training available as needed online for surgeons motivated to improve or expand their surgical repertoire.

Learning Objective:

After completion of this educational activity, participants should be able to:

- demonstrate the use of capsule retractors to simultaneously prevent severe pupil constriction and provide support for the capsule/lens complex during phacoemulsification.

Satisfactory Completion - Learners must pass a post-test and complete an evaluation form to receive a certificate of completion. You must listen to/view the entire video as partial credit is not available. If you are seeking continuing education credit for a specialty not listed below, it is your responsibility to contact your licensing/certification board to determine course eligibility for your licensing/certification requirement.



JOINTLY ACCREDITED PROVIDER™
INTERPROFESSIONAL CONTINUING EDUCATION

Physicians - In support of improving patient care, this activity has been planned and implemented by Amedco LLC and Postgraduate Healthcare Education. Amedco LLC is jointly accredited by the Accreditation Council for Continuing Medical Education (ACCME), the Accreditation Council for Pharmacy Education (ACPE), and the American Nurses Credentialing Center (ANCC), to provide continuing education for the healthcare team

Credit Designation Statement - Amedco designates this enduring material activity for a maximum of .25 AMA PRA Category 1 Credits™. Physicians should claim only the credit commensurate with the extent of their participation in the activity.

Endorsed by:
Review of Ophthalmology®
Video and Web Production by:
JR Snowdon, Inc

Jointly provided by:
AMEDCO
REG
(Review Education Group)

Supported by an unrestricted independent
medical educational grant from:
Alcon

Additionally Supported by:
Glaukos
MST
Crestpoint Management
Carl Zeiss Meditec

In Kind Support:
Sony Healthcare
Solutions



One advantage of owning a small private practice is being able to provide a more personal patient experience, which can be a real selling point for patients. This can include strategies such as providing cookies when wait times unexpectedly grow long, or passing out green carnations for St. Patrick's Day. (Pictured above: The waiting area for Kirk Eye Center in Loveland, Colorado, a privately owned one-doctor practice.)

as a small practice we have some advantages. We're not required to do all the things that big practices are."

• **Going without MD backup.** Ms. McKillop points out that despite having greater flexibility to create the kind of practice you want, being in solo practice puts more pressure on the doctor and limits flexibility in other ways. "In a large practice, if you don't want to come in one day, it's not a big deal to reschedule your patients with another doctor," she notes. "We're a little more restricted in that sense; if Dr. Kirk doesn't show up, I have 45 patients to reschedule. He's the only MD here, and we're booked a month out."

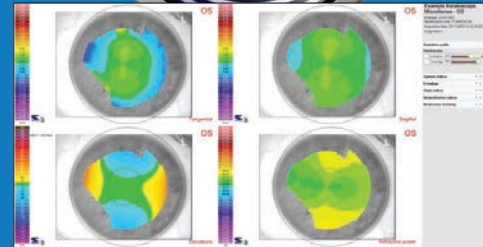
"Some appointments are more problematic to reschedule than others, of course," she continues. "Comprehensive eye exams can be rescheduled and it's not a big deal. We have two optometrists here; they can take over many of the things that Dr. Kirk would do if he decides to be out for a day or two. But there are many medical things they can't do. If you have a glaucoma patient who's in big trouble, that appointment won't be easy to postpone, and patients who need injections are usually on a schedule

that we need to stick to. So anybody starting out in solo practice will have to be dedicated to working long hours. You have to be devoted if you want to make this work."

Despite this impressive list of challenges, Mr. Pinto notes that they can be overcome, as many practices have proven. However, he adds that the challenges facing solo ophthalmologists aren't likely to diminish any time soon. "The macroeconomic and social environment we're heading into for the next 20 or 25 years is one of profound challenge," he says. "We have debts in this country and other developed countries that are unsustainable. We have levels of growth that have pushed the natural world to its limits. We have political strife and energy prices that are set to rise substantially, and our country's ability to pay for health care is reaching its limits."

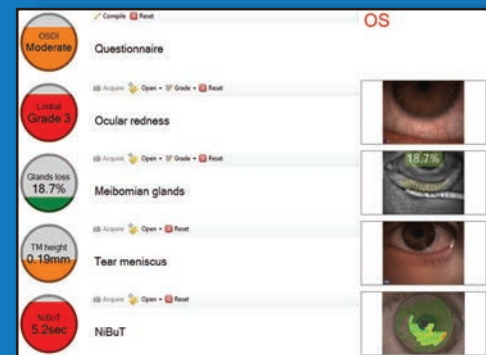
"All of these factors are not going to leave ophthalmology untouched, even though the demand for ophthalmologic care is increasing rapidly," he says. "So plenty of challenges lie ahead. Whether group practices will have an easier time dealing with them than solo practices remains to be seen."

S4OPTIK ANTARES



Corneal Topography & More!

Introducing the NEW Dry Eye Report



Comprehensive Diagnostic Imaging For Dry Eyes

More Information: info@s4optik.com

S4OPTIK

250 Cooper Ave., Suite 100 Tonawanda NY 14150

www.s4optik.com | 888-224-6012

Sensible equipment. Well made, well priced
For today's modern office.

Is It Really That Hard?

Michael Stock, MD, recently opened a solo practice in St. Louis. He says he's heard many warnings about the difficulty of being in solo practice today, but his experience has not supported that perspective. "Some people make it sound like it's extraordinarily difficult to go out on your own—that it's something that can't be done today," he says. "But is it really that difficult? No. Cre-

dentiaing is a pain in the butt, but you just do it once. Billing and insurance companies are a burden, but if you have even one person to help you with that, it's quite manageable. I know how to do the coding, and I keep up to date so I know I'm doing it correctly. If a claim is rejected, we treat it as a learning experience. We figure out why it was rejected and adjust. The rejection rate we had the first month was astronomically different from our current rejection rate.

"What about MIPS?" he continues. "If you have the right EHR software, it's built into the system. You just click on some buttons. Besides, if you're just starting a practice, you won't even be part of MIPS until you start generating some Medicare revenue."

Dr. Stock says that although he's heard horror stories about doctors having difficulty getting onto insurance panels, that has not been his experience. "I can't say how hard it might be in different parts of the country, but I've gotten on every panel I've applied for," he says. "A few needed a bit of harassment. One gave me the runaround for months. But eventually, with persistent calling, I got through to the right person. If you bug the right person enough, it's less painful for them to let you onto the panel than give you a reason to continue bugging them.

"Southern California or New York



Access to the latest advanced equipment can be a challenge for solo practitioners, especially when starting out. Alternatives to purchasing the equipment include joint purchases with nearby practices, buying refurbished equipment (from reliable sources) and partnering with local institutions that will allow doctors access to their advanced equipment, such as the Phillips Eye Institute in Minneapolis (above).

City might be different," he admits. "However, I know of many solo eye doctors in southern California. The reason they went into solo practice was that the area was so saturated that no practices wanted to hire them. They've done fine. I've seen many solo doctors get onto insurance plans, even in densely populated areas.

"If you're really concerned about taking on these challenges yourself, you can hire a consultant to help you," he adds. "But after doing this myself, I can tell you that managing these tasks is significantly easier than any of the medical training we go through."

Dr. Stock says he believes the real problem isn't that these tasks are difficult to do, but that doctors may not be up for dealing with another learning curve. "I suspect that once doctors finish their training, they want to just be doctors," he says. "They're not looking for more learning curves—but that's not a good place to be if you want to run your own practice.

"I think many more doctors would go out on their own in a second if it didn't seem like such a high barrier," he adds, "but the prospect of another learning curve keeps them from going off on their own."

The Benefits of Teaming Up

Jennifer Loh, MD, who started her

own private practice with a focus on cataract and refractive surgery three years ago in Miami, is in a hybrid version of private practice that allows her to maintain control of her practice while working in concert with a number of other private practices (and a few small group practices) to share some of the burdens associated with insurance and govern-

ment regulations.

"We're a group of individual practices that have joined together to operate as one large mega-group," she explains. "We all bill under the same tax ID. There's a central business office, where all the billing, claims, denials and so forth are managed. However, in terms of day-to-day operation, each practice is run and managed by an individual doctor. The doctor sets his or her own schedule, is responsible for recruiting patients and managing the employees, and the practice is its own profit and loss center.

"Basically, the benefit of being part of this group is that we have some economy of scale in certain key areas," she continues. "Most important, we have the benefit of being considered a large group for insurance purposes. Especially in an urban area like south Florida, it's almost impossible to get onto insurance panels as a solo doctor. Most insurance companies won't even speak to you unless you're part of a big group. I have a colleague who's on his own; he started his own practice about six months ago. He's only been able to get on two insurance plans, after trying and trying and trying.

"Of course," she adds, "if you've already been in practice for 20 or 30 years, this isn't an issue because you're already on the insurance panels. But if you're a solo practice starting new,

pretty much the only way to get in is to join a group practice—at least in this part of the country.”

Dr. Loh notes that the group also alleviates some of the paperwork burden by managing some processes centrally. “The group has a centralized billing department that handles all claims and denials,” she explains. “We also have a human resources manager who oversees issues with individual employees. We’re able to use technology like ADP to manage our payroll, and we have a good EHR system and a group IT expert. As a solo doctor, I wouldn’t be able to afford that level of personnel expertise. But because of the way this arrangement works, I’m still able to control my own schedule and life, and the way I practice.”

Dr. Loh says one limitation of this particular arrangement is that the practices in the group don’t share equipment. “For one thing, we’re all at different locations, pretty far apart,” she says. “The other factor is that when the group was initially formed, most of the practices already existed and owned their own equipment. I’m one of only two practices that came into existence after the group was formed. So, I’m responsible for buying all my own capital equipment. But at least we share some of the overhead relating to human resource expenses.”

Strategies for Starting Out

Surgeons offer these tips for those thinking about going solo:

- **Choose an auspicious location for your practice.** Being in the right location can make an enormous difference in terms of getting on insurance panels—which is much harder to do in an area crowded with doctors offering the same services as you. The right location can also minimize competition and make you easily available to patients who need your services.

Being in a small town can help. “It’s tough to compete inside a major

metropolitan center where big consolidations are occurring,” notes Dr. Lindstrom. “I’m a fan of what I call ‘exurbia’—the areas about 60 to 100 miles from the center of a metropolitan area. In some of those smaller communities you have a better opportunity to be successful as a solo ophthalmologist. When you encounter complex or specialty-care patients you can send them to specialists in the nearby metropolitan area. I think this creates a pretty ideal situation for a solo practitioner.”

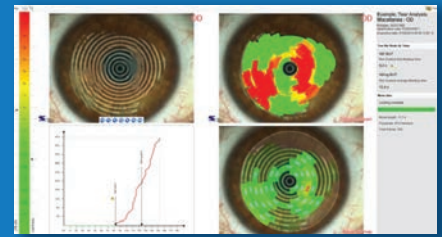
Ms. McKillop notes that being in the small town of Loveland, Colorado, has limited the competition they face. “The one competing ophthalmologist in town joined a larger group to our north,” she says. “The bigger practice has many MDs and several satellite locations. They’d undoubtedly like to dominate this market, but we’ve got our own niche, and we’re doing fine.”

She adds that the practice’s physical location in town also works to their advantage. “We’re located on Highway 34, which is the main artery in and out of town,” she says. “Forty thousand cars drive past our big sign out front every day. That helps remind everyone that we’re here.”

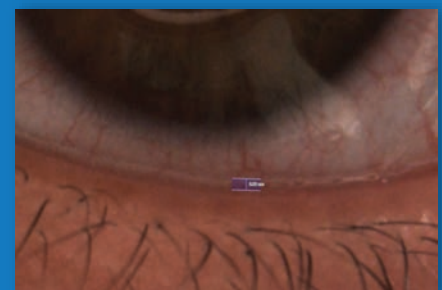- **Think about how to set yourself apart from other practices in the area.** “It’s important that your practice stand out in some way,” says Ms. McKillop. “It’s not always easy to figure out how to do that, but as a small practice, offering personal service is a good place to start.”

- **Consider narrowing your focus.** Dr. Lindstrom notes that many of the larger, high-volume solo practices focus on one practice specialty, usually cataract surgery; they refer most of the other sophisticated subspecialty care out. “Often they do cataract surgery and refractive-cornea along with glaucoma,” he says. “They refer out retina and the like. That means they don’t need all of the sophisticated equipment that a glaucoma, cornea or retina

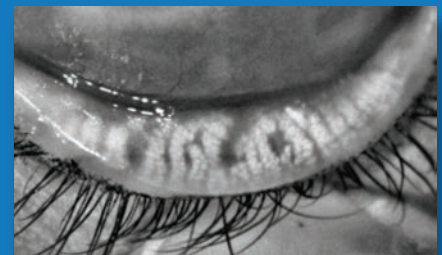S4OPTIK ANTARES DRY EYE TESTING



Non-Invasive Tear Film Break-up Analysis



Tear Meniscus Height



Meibomian Gland Imaging & Analysis

Ocular Surface Disease Index (OSDI)

Ask your patients the following 12 questions, and check the number in the box that best represents each answer.

Have you experienced any of the following during the last week?	All of the time	Most of the time	Half of the time	Some of the time	None of the time
1. Eyes that are sensitive to light?	0-4	0-3	0-2	0-1	0-0
2. Eyes that feel gritty?	0-4	0-3	0-2	0-1	0-0
3. Painful or sore eyes?	0-4	0-3	0-2	0-1	0-0
4. Blurred vision?	0-4	0-3	0-2	0-1	0-0
5. Poor vision?	0-4	0-3	0-2	0-1	0-0
Subtotal score for answers 1 to 5: 3					

Have problems with your eyes caused you to perform any of the following during the last week?	All of the time	Most of the time	Half of the time	Some of the time	None of the time	N/A
6. Reading?	0-4	0-3	0-2	0-1	0-0	0-N/A
7. Driving at night?	0-4	0-3	0-2	0-1	0-0	0-N/A
8. Working with a computer or bank machine (ATM)?	0-4	0-3	0-2	0-1	0-0	0-N/A
9. Watching TV?	0-4	0-3	0-2	0-1	0-0	0-N/A
Subtotal score for answers 6 to 9: 4						

Ocular Surface Disease Index Questionnaire

More Information: info@s4optik.com

S4OPTIK

250 Cooper Ave., Suite 100 Tonawanda NY 14150

www.s4optik.com | 888-224-6012

Sensible equipment. Well made, well priced
For today's modern office.

Resources for Solo Practitioners

Michael Stock, MD, who recently opened a solo practice in St. Louis, says he's found some very useful resources for ophthalmologists interested in private practice. "There's an online forum called Solo Eye Docs Group," he says. "It's a collective of about 150 doctors who run their own practices. Many started their own practices from scratch; some bought solo practices and took them over; some were solo but have now hired other doctors and brought them in. The group's website is solobuildingblogs.com/solo-eye-docs-group/. The site gives members a platform for asking a wide range of questions like, 'How do you get credentialed?' 'What's the best light switch to buy for this lane equipment?' 'What do you do when an employee keeps showing up late?' 'How do you deal with this coding or billing issue?' Basically, you can reach out to people who are in the same situation as you. It's been a nice resource."

Dr. Stock notes that the group is only open to those in solo practice. "To join, you have to have a lease, or be about to execute on one, and basically prove that you really are a solo doctor," he says. "There's a membership fee of sorts; it's a donation to the Surgical Scope Fund, or OphthPAC. It's \$500 a year, and we generate a fair amount of cash for the fund."

Dr. Stock says another resource that helped him learn to run a practice was completing the Kellogg School of Management Physician-CEO program, presented in association with SurgiVision

Consultants, at Northwestern University's business school. "Over the course of a year I attended four intensive training modules," he says. "In these modules, we learned business skills that are essential to being an effective physician leader. In contrast with the Solo Eye Docs group, where I'm communicating with colleagues in situations like my own, Physician-CEO exposed me to colleagues at all stages of their careers and in diverse organizations. Many were highly successful physicians running large, prestigious practices. Getting to hear their experiences and bounce ideas off of these colleagues has been invaluable."

John Pinto, president of consulting firm J. Pinto & Associates, adds that new support systems are appearing that should help young doctors interested in going into private practice. "We've had conversations with an interesting new company that I can't name, that will help young doctors going into solo practice by providing capital and expertise," he says. "It's a doctor-based enterprise that will help provide a leg up for young doctors who are temperamentally suited to be in solo practice, but don't have the risk tolerance or the business backing that was more common a generation or two ago. I see it as a kind of counter-current to the private equity trend. It's another sign that doctors are more in control of their professional and business destiny—and will remain more in control in the years ahead—than many suspect."

—CK

specialist needs."

• ***Offer a service that's needed by the population in your area.***

William B. Trattler, MD, director of cornea at the Center for Excellence in Eye Care in Miami, and a volunteer faculty member at the Herbert Wertheim College of Medicine at Florida International University, points out that your chances of success in solo practice increase if you're focused on a specialty that's in demand. "If your practice specializes in glaucoma or neuro-ophthalmology in South Florida, your services are needed because there are low numbers of these specialists here," he says. "On the other hand, if you're a general ophthalmologist, finding patients may be a bit harder. So your subspecialty may impact how likely it is that you'll succeed as a solo doctor."

• ***Don't worry too much about affording expensive equipment.***

Dr. Loh says that, in her experience, this isn't a major hurdle. "Like any business, you can take out a loan," she notes. "And you can buy used equipment. I've purchased lots of refurbished equipment from a reputable dealer, and it works really well. Besides, if you're going into private practice, you can start small. You may not have the biggest office, with every gadget in the world at first, but you can slowly grow."

Dr. Lindstrom adds that in some settings there are other ways to gain access to advanced equipment. "Here in Minneapolis we have something called the Phillips Eye Institute," he says. "It's an open-panel institute that individual ophthalmologists can join. The institute has a diagnostic center with all the advanced diagnostic instruments and lasers, and a great OR environment. That gives ophthalmologists access to the best equipment

without having to purchase it."

• ***Consider sharing an ASC with other solo practices.*** "In my opinion, being on the facility side is very important, but it's a rare solo practitioner who can afford his own ambulatory surgical center," says Dr. Lindstrom. "Typically, a group of five or six solo ophthalmologists get together and build an ASC that has one or two ORs. Ideally, everyone owns 10 or 20 percent of the ASC. Then, one doctor uses the OR each day. I think that's a pattern that makes sense."

• ***Build your practice from the top down.*** "Make sure you have an exceedingly strong managing partner and an exceedingly strong administrator, working together to operate the company in challenging circumstances," advises Mr. Pinto.

Dr. Lindstrom agrees. "Hire a high-quality advisor/consultant, a good attorney and a good CPA," he suggests.

O3+Maqui™

Omega-3 with Maqui Berry

COMBATS
DRY EYE SYMPTOMS
AND PROMOTES HEALTHY TEARS^Δ



MaquiBright®

Clinical trials show Maqui Berry increases tear production and improves dry eye symptoms.



Omega-3 Fatty Acids

O3+Maqui contains 2420mg of highly refined omega-3 fish oil in a re-esterified triglyceride form.



Patented Unigel™ Technology

The only patented technology that combines a liquid & powder tablet in one convenient softgel.

LEARN MORE & ORDER

Visit O3Maqui.com or call (866) 752-6006

FocusLaboratories.com



^ΔThis statement has not been evaluated by the Food and Drug Administration. This product is not intended to diagnose, treat, cure or prevent any disease.

“Sophisticated help with the business side is becoming more important.”

Ms. McKillop notes that having a good billing department is essential. “If you can’t bill for your services and collect for them in a timely manner, you won’t have a chance of succeeding as a solo practitioner,” she says.

- **Be aware that advice from academic doctors about practicing may be based on limited experience.** “I got a lot of good advice from community doctors that my attending doctors thought was questionable, but they work in two different worlds,” Dr. Stock points out. “Academic doctors are wonderful people with impressive knowledge and skills, but most of them have limited knowledge about running a business. So if you need advice, try to get it from doctors who are in the same situation you’re in.”

Once You’re Up and Running ...

These strategies can help ensure that your solo practice thrives:

- **Make the most of being able to offer personalized attention.** “Personalized service is something we can offer that the big practices can’t,” notes Ms. McKillop. “We often hear from our patients that they didn’t like going to the bigger practice in town because it was too impersonal. Here, there’s always someone smiling at the front desk, and patients know the names of the technicians that are working them up. If patients end up having to wait longer than normal, we get them some cookies. A big practice can’t do that.”

“The bottom line is that we make sure that our patients are taken care of and receive personal attention,” she says. “That’s one of our biggest assets.”

- **Offer cash-pay procedures.** Dr. Trattler points out that offering self-pay procedures can help provide a bulwark against declining reimbursements. “One solo practitioner I know is an oculoplastics specialist who also does cataracts,” he says. “He offers

self-pay oculoplastics procedures such as Botox and cosmetic lid surgery. These help to offset the low rates he gets with the insurance companies.”

“Patients appreciate that personalized, private-practice type of care.”

— Jennifer Loh, MD

- **Make sure your facilities are always being used.** “Most solo practitioners can benefit from having one or more optometric employees,” notes Dr. Lindstrom. “When you’re in the OR or on vacation, the optometrists can be seeing patients in the office. It’s really hard to make solo practice work economically if the office is empty, or the ASC sits empty.”

- **Arrange your affairs to ensure that you’ll have access to capital when you need it.** “You’ll be practicing in a business environment with greater volatility,” says Mr. Pinto. “Don’t draw every last penny out of the practice as your salary. You have to be setting aside reserves for dealing with unforeseen challenges.”

- **Stay on top of your practice’s business details.** “As the owner of your practice, you have to stay informed about everything that’s happening on the business side of things,” Mr. Pinto says. “If areas are unfamiliar to you, do your homework.”

- **Be willing to put in as much time as is necessary to keep the practice thriving.** “As ophthalmologist John Corboy has observed, if you’re not smarter than the other guys, you have to work harder than they do,” says Mr. Pinto. “Since all ophthalmologists are pretty smart, in the years ahead you’ll have to work harder at

all levels—focusing more intensely in the clinic and working longer hours when necessary.”

- **Remain flexible so you can respond to changes.** “Tennis players about to receive a serve hop from foot to foot,” notes Mr. Pinto. “They’re preparing to be able to spring off in any direction, and that’s what you have to do as an ophthalmologist. You have to be ready to lunge to the left or right or run forward to stay with the profession, wherever it’s heading.”

Outlook: Positive

Mr. Pinto notes that the demand for eye-care services is increasing at four to five times the rate at which the population is growing, while the number of ophthalmologists is remaining flat. “Ophthalmologists really are in the drivers seat, in terms of choosing the professional context they’d prefer to operate in,” he says. “I think ophthalmologists will continue to be able to write their own ticket for many generations to come.”

Dr. Lindstrom says that while he sees a future for solo practice, it’s probably not the ideal model going forward unless you’re fiercely independent. “I think the ideal model will shift more towards a group practice, such as four to six MDs who own their own ASC,” he says. “I suspect the number of solo practitioners will shrink over time, but they’ll continue to be a significant part of the field. They’ll need to be nimble and make wise choices, but I think they’ll do just fine.”

“I think most doctors would actually prefer to be in private practice,” adds Dr. Loh. “Most private practice doctors are happy; they like having their own practice. Furthermore, I think there’s a need and a desire for it. Patients appreciate that personalized, private-practice type of care. So if being in private practice is truly your dream, I think it’s still possible, and I think it’s well worth it.” **REVIEW**

WHEN RELIABILITY COUNTS
**THE RIGHT
PACK
MATTERS**

Visit BVI
at ASCRS
BOOTH
1206

Minimize your
pack-building time

Expedite your
OR experience

Treat more patients

CustomEyes® your pack



EHR Systems: Room For Improvement?

Alexandra Skinner, Associate Editor

Doctors discuss EHR issues that need attention, and suggest ways to improve current systems.

Electronic medical records offer many benefits, such as improved documentation and efficient storage and recall of past data. However, as with most things, physicians say there's some room for improvement in their records systems. In this article, doctors are given a platform to not only discuss their EHR gripes but also address the "wish-list" items they'd like to see included or improved upon in future EHR systems.

EHR Issues

The advent of EHRs changed the way physicians document patient interactions and, in the process, also changed those interactions. Though EHR innovations have had a positive influence on some aspects of care, Jamie Wells, MD, FAAP, a board-certified physician and director of medicine at the American Council on Science and Health, a "pro-science consumer advocacy organization," says this isn't necessarily so in all cases. "EHR disrupts medical practice, and it hasn't been a positive disruptor," she says. Claiming that the dawn of EHR was the catalyst that caused the coding and billing industry to quickly grow, Dr. Wells says this has consequently shifted attention from what she feels should be the highest priority in the

medical field: the doctor-patient relationship. "You're creating a new industry that adds third party diversion from the doctor-patient relationship, which just erodes it," she contends.

• **Preserving the doctor-patient relationship.** Doctors say it's crucial to maintain rapport with the patient, even if having the EHR system in the exam lane makes it more challenging.

Andrew Iwach, MD, executive director of the Glaucoma Center of San Francisco and board chair for the Glaucoma Research Foundation, says that when it comes to quality of care, the primary concern is the patient-doctor interaction. "My job is, number one, patient quality of care and happiness, and number two, keeping doctors happy," he says. "We're looking at the patient experience and how the value of our practice is perceived beyond the technical skills that we have. Patients appreciate me looking them in the eye versus looking at a terminal." Dr. Wells agrees that understanding the patient dialogue can be as valuable, if not more valuable, than structured data. "Being a phenomenal physician vs. being a so-so one, involves utilizing not just your expertise, knowledge and experience but also skills of observation," she says. "Your sense of vision, smell, and hearing in combination with your assessment of body language, and

NEW The first and only FDA-approved, single-dose, sustained-release, intracameral steroid for the treatment of postoperative inflammation¹⁻³

For Post-Cataract Surgery Inflammation **Target Within**¹⁻³

With a single injection at the end of cataract surgery, anti-inflammatory efficacy begins as early as day 1 and continues through day 30^{1*}

- The percentage of patients who received DEXYCU (517 mcg) who had anterior chamber cell clearing on day 8 was 60% (n=94/156) vs 20% (n=16/80) in the placebo group¹
- The cumulative percentage of subjects receiving rescue medication of ocular steroid or nonsteroidal anti-inflammatory drug (NSAID) at day 30 was significantly lower in the DEXYCU (517 mcg) treatment group (20%; n=31/156) compared to placebo (54%; n=43/80)¹

*DEXYCU was studied in a randomized, double-masked, placebo-controlled trial. Patients received either DEXYCU or a vehicle administered by a physician at the end of the surgical procedure. The primary endpoint was the proportion of patients with anterior chamber cell clearing (cell score=0) on postoperative day 8.

NOW AVAILABLE



DEXYCU[™]
(dexamethasone intraocular suspension) 9%

INDICATION AND USAGE

DEXYCU[™] (dexamethasone intraocular suspension) 9% is indicated for the treatment of postoperative inflammation.

IMPORTANT SAFETY INFORMATION

CONTRAINDICATIONS

None.

WARNINGS AND PRECAUTIONS

Increase in Intraocular Pressure

- Prolonged use of corticosteroids, including DEXYCU, may result in glaucoma with damage to the optic nerve, defects in visual acuity and fields of vision
- Steroids should be used with caution in the presence of glaucoma

Delayed Healing

- The use of steroids after cataract surgery may delay healing and increase the incidence of bleb formation
- In those diseases causing thinning of the cornea or sclera, perforations have been known to occur with the use of corticosteroids

Exacerbation of Infection

- The use of DEXYCU, as with other ophthalmic corticosteroids, is not recommended in the presence of most active viral diseases of the cornea and conjunctiva including epithelial herpes simplex keratitis (dendritic keratitis), vaccinia, and varicella, and also in mycobacterial infection of the eye and fungal disease of ocular structures

- Use of a corticosteroid in the treatment of patients with a history of herpes simplex requires caution and may prolong the course and may exacerbate the severity of many viral infections
- Fungal infections of the cornea are particularly prone to coincidentally develop with long-term local steroid application and must be considered in any persistent corneal ulceration where a steroid has been used or is in use. Fungal culture should be taken when appropriate
- Prolonged use of corticosteroids may suppress the host response and thus increase the hazard of secondary ocular infections. In acute purulent conditions, steroids may mask infection or enhance existing infection

Cataract Progression

- The use of corticosteroids in phakic individuals may promote the development of posterior subcapsular cataracts

ADVERSE REACTIONS

- The most commonly reported adverse reactions occurred in 5-15% of subjects and included increases in intraocular pressure, corneal edema and iritis

Please see brief summary of full Prescribing Information on adjacent page.

References: 1. DEXYCU[™] (dexamethasone intraocular suspension) 9% full U.S. Prescribing Information. EyePoint Pharmaceuticals, Inc. December 2018. 2. Donnenfeld E, Holland E. Dexamethasone intracameral drug-delivery suspension for inflammation associated with cataract surgery: a randomized, placebo-controlled, phase III trial. *Ophthalmology*. 2018;125(6):799-806. 3. Data on file. EyePoint Pharmaceuticals, Inc.



DEXYCU and the EyePoint logo are trademarks of EyePoint Pharmaceuticals, Inc.
©2019 EyePoint Pharmaceuticals, Inc. All rights reserved.
480 Pleasant Street, Suite B300, Watertown, MA 02472

01/2019
US-DEX-1900045

**DEXYCU (dexamethasone intraocular suspension) 9%,
for intraocular administration
Initial U.S. Approval: 1958**

BRIEF SUMMARY: Please see package insert for full prescribing information.

1 INDICATIONS AND USAGE

DEXYCU (dexamethasone intraocular suspension) 9% is indicated for the treatment of postoperative inflammation.

4 CONTRAINDICATIONS

None.

5 WARNINGS AND PRECAUTIONS

5.1 Increase in Intraocular Pressure

Prolonged use of corticosteroids including DEXYCU may result in glaucoma with damage to the optic nerve, defects in visual acuity and fields of vision. Steroids should be used with caution in the presence of glaucoma.

5.2 Delayed Healing

The use of steroids after cataract surgery may delay healing and increase the incidence of bleb formation. In those diseases causing thinning of the cornea or sclera, perforations have been known to occur with the use of corticosteroids.

5.3 Exacerbation of Infection

The use of DEXYCU, as with other ophthalmic corticosteroids, is not recommended in the presence of most active viral diseases of the cornea and conjunctiva including epithelial herpes simplex keratitis (dendritic keratitis), vaccinia, and varicella, and also in mycobacterial infection of the eye and fungal disease of ocular structures.

Employment of a corticosteroid medication in the treatment of patients with a history of herpes simplex requires caution. Use of ocular steroids may prolong the course and may exacerbate the severity of many viral infections of the eye (including herpes simplex). Fungal infections of the cornea are particularly prone to develop coincidentally with long-term local steroid application. Fungus invasion must be considered in any persistent corneal ulceration where a steroid has been used or is in use. Fungal culture should be taken when appropriate.

Prolonged use of corticosteroids may suppress the host response and thus increase the hazard of secondary ocular infections. In acute purulent conditions, steroids may mask infection or enhance existing infection.

5.4 Cataract Progression

The use of corticosteroids in phakic individuals may promote the development of posterior subcapsular cataracts.

6 ADVERSE REACTIONS

The following adverse reactions are described elsewhere in the labeling:

- Increase in Intraocular Pressure [see *Warning and Precautions (5.1)*]
- Delayed Healing [see *Warnings and Precautions (5.2)*]
- Infection Exacerbation [see *Warnings and Precautions (5.3)*]
- Cataract Progression [see *Warnings and Precautions (5.4)*]

6.1 Clinical Trials Experience

Because clinical studies are conducted under widely varying conditions, adverse reaction rates observed in the clinical studies of a drug cannot be directly compared to rates in the clinical studies of another drug and may not reflect the rates observed in practice.

The following adverse events rates are derived from three clinical trials in which 339 patients received the 517 microgram dose of DEXYCU. The most commonly reported adverse reactions occurred in 5-15% of subjects and included increases in intraocular pressure, corneal edema and iritis. Other ocular adverse reactions occurring in 1-5% of subjects included, corneal endothelial cell loss, blepharitis, eye pain, cystoid macular edema, dry eye, ocular inflammation, posterior capsule opacification, blurred vision, reduced visual acuity, vitreous floaters, foreign body sensation, photophobia, and vitreous detachment.

8 USE IN SPECIFIC POPULATIONS

8.1 Pregnancy

Risk Summary

There are no adequate and well-controlled studies of DEXYCU (dexamethasone intraocular suspension) in pregnant women. Topical ocular administration of dexamethasone in mice and rabbits during the period of organogenesis produced cleft palate and embryofetal death in mice and malformations of abdominal wall/intestines and kidneys in rabbits at doses 7 and 5 times higher than the injected recommended human ophthalmic dose (RHOD) of DEXYCU (517 micrograms dexamethasone), respectively [see *Data in the full prescribing information*].

In the US general population the estimated background risk of major birth defects and miscarriage in clinically recognized pregnancies is 2 to 4% and 15 to 20%, respectively.

8.2 Lactation

Risk Summary

Systemically administered corticosteroids are present in human milk and can suppress growth, interfere with endogenous corticosteroid production, or cause other unwanted effects. There is no information regarding the presence of injected DEXYCU in human milk, the effects on breastfed infants, or the effects on milk production to inform risk of DEXYCU to an infant during lactation. The developmental and health benefits of breastfeeding should be considered, along with the mother's clinical need for DEXYCU and any potential adverse effects on the breastfed child from DEXYCU.

8.4 Pediatric Use

Safety and effectiveness of DEXYCU in pediatric patients have not been established.

8.5 Geriatric Use

No overall differences in safety or effectiveness have been observed between older and younger patients.

Manufactured for: EyePoint Pharmaceuticals US, Inc. Watertown, MA 02472

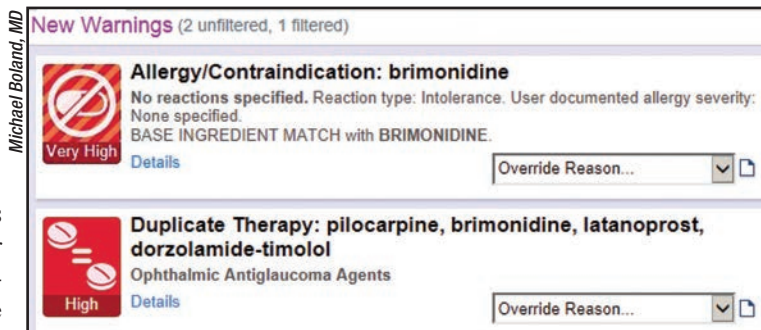
the patient's facial affect can optimize diagnosis.”

Though EHR has brought new levels of efficiency and documentation to medical practice, some doctors say the need to enter data during patient interactions can put some distance between the ophthalmologist and the patient. Dr. Wells explains, “A busy practitioner has a limited amount

of time, and everything that co-ops an office visit erodes the capacity to have an informed discussion or a healing conversation,” she says. “It's crucial to watch [patients] as they answer so you can understand their state of mind, and if your head is in a computer screen, you can entirely miss the nuances of a conversation.”

Michael F. Chiang, MD, the Knowles professor of ophthalmology and medical informatics, as well as clinical epidemiology, at Oregon Health and Science University, and associate director of the OHSU Casey Eye Institute, says, “Most EHRs require the physician to direct attention toward a desktop computer—which may detract from patient-doctor communication.” However, the integration of EHR doesn't always take attention away from the patient. Dr. Chiang says that the degree to which an EHR detracts from this interaction can depend on the specific doctor.

Michele Lim, MD, professor of ophthalmology, vice chair and medical director at the University of California-Davis Eye Center, agrees, adding that the range of doctor aptitude is pretty wide on this count. “It depends on how the doctor integrates the EHR or computer when they're seeing a patient,” she says. “There are two ends of the spectrum: On the good side, a lot of doctors have learned to preface the visit by communicating that they're



Some doctors are suffering from “alarm fatigue.” Here, EHR is displaying two warnings. Wilmer's Michael Boland, MD, says the top one is relevant (an allergy to a medication being prescribed) but the bottom one is less so (alerting Dr. Boland that the patient is on duplicate therapy for glaucoma).

going to take a moment to type their thoughts and background information into the computer. Then, they turn back toward the patient and talk to him or her while making eye contact, which is very acceptable.

“The other end of the spectrum would be a doctor who's busy or in a rush,” she adds. “There are so many things to document and, usually, the computer is positioned so that your back is to the patient, which can make him or her feel like you aren't paying attention.”

Dr. Iwach agrees that a lot of it is intuitive, based on the doctor's feel for the interaction. “Technology is wonderful,” he says, “but it has to be implemented at the right time.” He says that understanding whether the patient is being helped is what counts, and he urges doctors to ask themselves if the way they're using the EHR system is really helping patients.

• **System issues.** When it comes to EHR, there are many different systems and setups available. However, physicians say that the issues that consistently crop up usually involve “box checking” and “alarm fatigue.”

Though many physicians got into medicine for similar reasons, Dr. Wells says, nobody goes into medicine intending to check boxes. “The majority of people go into medicine

for human interaction and to help people,” she says.

Dr. Chiang says that box checking may contribute to a weakening of the patient's ability to convey important details about her complaint; the traditional patient dialogue is often being replaced by check-boxes and pre-populated text phrases, he says. Dr. Wells says that just checking

a box doesn't compel a patient to share her story. “There are many of these yes/no boxes and just checking them may not stimulate the memory of a patient interaction that would allow you to recall a certain piece of relevant information,” she says.

Some doctors are also suffering from “alarm fatigue.” Michael Boland MD, PhD, associate professor at Wilmer Eye and Health Sciences Informatics, director of information technology and residency program director at Johns Hopkins' Wilmer Eye Institute, says alarm fatigue occurs when the EHR's system alerts begin piling up as the physician checks boxes during the exam and history. “If you don't pay careful attention to [reminders and pop-ups], you end up with way too many alerts for medications that don't really make sense or apply,” he says.

Dr. Lim has thoughts on what could be behind some of the alarm-fatigue irritation. She says that some doctors are aggravated by EHR regulations, requirements and objectives set forth by the Meaningful Use program—the federal incentive for EHR adoption—which can contribute to the entering of unnecessary information. “[There's a] feeling that EHR designers are designing toward fulfilling these regulations more than they're trying to meet the needs of actual clinicians,” she says. Dr. Wells acknowledges that while pop-up

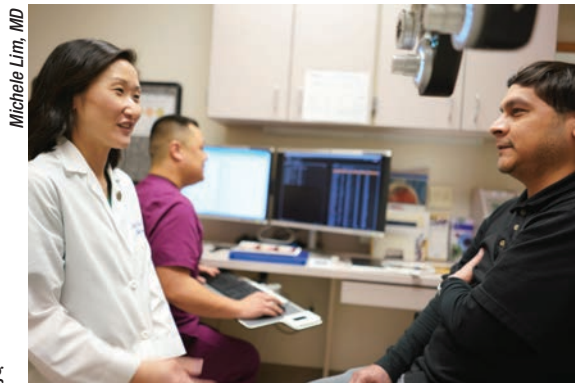reminders are well-intended, they can be frustrating and create unnecessary steps that shift the physician's focus to non-clinical tasks.

Dr. Boland says you can minimize alarm fatigue by taking the time to correctly implement an EHR system and ensure it's customized to work as smoothly as possible. "In general, the more time you're spending entering data, the less time you're spending interacting with patients," he says. To minimize alarms and reminders and make it easier to

document what's necessary without having to take as much time away from the doctor-patient relationship, Dr. Boland suggests purposefully specifying the desired workflows and designing how the EHR will implement them before configuring the system. "We have a small group at Johns Hopkins Medicine whose job is to review and approve all such decision-support tools before they can be implemented in EHR," he says. "The design and build is done by our internal EHR team, but the vendor can help if the team runs into trouble with a particular project.

"If you don't get the system designed to satisfy your particular requirements, you're probably not going to be happy with it later," Dr. Boland adds. He says that having someone internal who's able to sit down and discuss design steps to improve a practice's current workflow is crucial. "This job is best done by someone with both clinical and EHR/IT experience," he says. "Such people aren't common, so it may require sending someone from the practice to be trained on EHR configuration so they can translate between the clinical and IT worlds." In Dr. Boland's case, he filled this role.

Having an EHR team that works to customize parts of the EHR system, such as which drug interactions will pop an alarm, can decrease alarm fatigue Dr. Boland says. "We, as an



Michele Lim, MD

Davis Eye Center's Michele Lim, MD, finds it helpful to use a scribe, which she says can help optimize the doctor-patient interaction.

institution, have been pretty meticulous about trying to minimize [alarm fatigue]," he says. "You want to make sure you're only showing very-high-importance alerts; otherwise people just ignore them."

Dr. Boland feels that some doctors are better off with EHRs and some are worse off, but that it's related to the amount of time taken to adapt the system to their desired workflow. "If you don't take the time to understand what will work best in your practice, [EHR] may not be equipped with the right set of processes for you, and you either end up trying to recreate a paper-based workflow using an electronic system—which isn't a good use of it—or you try to take an out-of-the-box electronic system and wedge it into your practice," he says.

• **Data errors.** Dr. Iwach says there are other issues associated with EHR beyond the changing doctor-patient interaction. He says the process of collecting data includes a lot of cut-and-paste that could contribute to errors.

"EHRs allow you to use a lot of templates, copy-forwards and shortcuts," Dr. Lim says. "People aren't editing the information they copy forward, so outdated data that isn't valid anymore makes it into your current notes, which is where errors come from." Dr. Chiang adds that reviewing everything within a short patient encounter is of-

ten difficult, due to EHRs containing so much—often redundant—data. "Findings can be imported, so it may be difficult to know exactly what occurred in the office visit," he says.

Users say this process can cause some confusion. "Once something is written incorrectly in your record, it can follow you forever," Dr. Wells says.

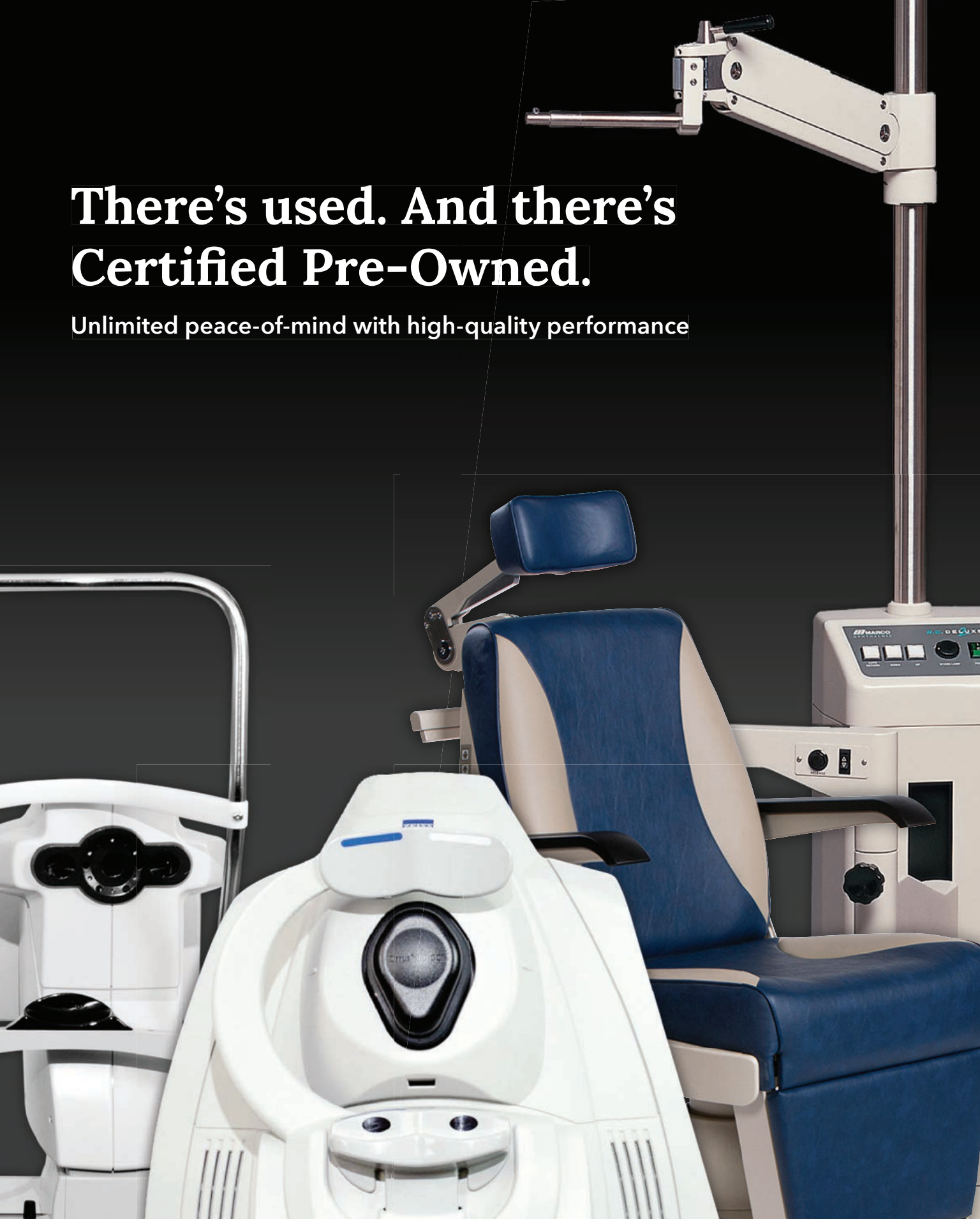In terms of treatment options, Dr. Chiang says critical findings can be missed in long EHR notes containing standard pre-populated text (e.g., "copy-forward" and "all-normal" functions in the EHR system). "You end up with a bunch of notes you can't trust, and you have to be very careful," Dr. Lim adds. She says that errors can go unnoticed—or worse, a doctor could read a note containing a mistake and come to the wrong conclusion.

Dr. Wells says that a ripple effect can take place because physicians sometimes make decisions based on what's in a record. As a member of the claims committee for the Ophthalmic Mutual Insurance Company, Dr. Iwach says one problem with medical errors is that when there's litigation, professionals turn to the medical record because it's regarded as the legal record of what happened. "You add a whole additional level of complexity to EMR if you have a record that's compromised, not because of any ill intent but as a result of the demand, inconvenience and busy clinical setting," says Dr. Iwach.

To avoid errors based on the EHR data, Drs. Chiang and Lim say that education is integral. Dr. Chiang acknowledges that medical errors occurred prior to EMRs. "[Paper] charts containing old records were often unavailable, missing or illegible at the time of medical decision-making, so they didn't provide easy communication among different providers," he says. However, he adds that whether records are paper or digital, it still falls

There's used. And there's Certified Pre-Owned.

Unlimited peace-of-mind with high-quality performance



lombartinstrument.com/pre-owned

LOMBART

to the physician to provide the best care for the patient.

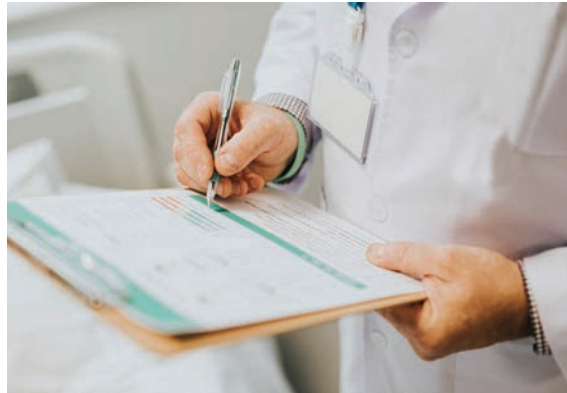Dr. Lim provides a few examples of how education has helped avoid medical errors. “In my department, we talk about [avoiding medical errors] a lot, and from the time we first started using EHR to now, people are more careful in how they enter data,” she says. “You only have to be a victim of bad data once—perhaps reading someone else’s botched note—to ensure you’re careful entering your own data.”

Dr. Lim adds that using a scribe can help avoid errors, though not every practice can afford to employ one. “A few years ago we began adopting scribes and that helps get the information down a bit more pristinely,” she says. Dr. Lim says using a scribe lets the doctor-patient conversation unfold naturally, without the disruption of entering data into a computer. However Dr. Chiang urges doctors to implement scribes properly and to ensure appropriate training. He says documentation should still be reviewed by physicians, emphasizing that it shouldn’t be outsourced to scribes.

An EHR Wish-List

Doctors acknowledge that EHR systems are becoming a fact of life, and the current systems have a lot of potential, especially in ophthalmology, which is very data-driven. With many different needs on doctor’s minds, here are a few of the top requests.

- **An improved interface.** In most cases, EHR interfaces attempt to mimic a paper chart, but Dr. Wells says that the ease of paper was lost in the transition to technology. To review one patient, she may have a dozen or so tabs to navigate, making her wish that there were only a few tabs, each designated for a particular use. “One for progress, one for medical testing information



Trying to recreate a paper-based system using EHR isn’t a good use of the technology, surgeons say.

and one for imaging information,” she says. “That way, you wouldn’t have to sift through 30 different tabs.”

Dr. Boland agrees, emphasizing the need for computer-driven data synthesis. He says EHR should be better at showing the doctor what he needs to see, when he needs to see it. “Systems should be more context-dependent,” he says. “If I’m seeing a patient with glaucoma, I automatically want to see IOPs and visual field results, so ideally, [the system] would take advantage of the computer’s abilities in order to show me the information graphically, or in a more digestible way.”

In general, Dr. Lim would like enhanced customization in the form of a more graphical representation. She wants the user to be able to organize information like visual fields and pressure measurements more easily; having the ability to pull together information quickly would be a big advantage. She says she essentially does that with her scribe, but in an audible way instead of visually. When referring to the advantage of being able to ask her scribe to dictate patient-specific data, like past IOL or OCT values, Dr. Lim says, “We need an Alexa for EMR!” referring to the virtual-assistance device developed by Amazon that’s capable of voice interaction and other functions that could potentially prove helpful for ophthalmologists.

- **Artificial intelligence.**

AI could potentially be incorporated into EHR systems in many different ways, from simply helping the doctor retain patient information to actually aiding in the diagnostic process.

Dr. Boland would like to see AI-assisted documentation to help restore the doctor-patient interaction. “People would like a better way to enter data into an EMR,” he says. “[Perhaps] through natural language processing where you just talk to the patient in the exam lane and

some sort of AI assistant documents the conversation for you.” Dr. Wells says that companies are starting to test this idea using AI and voice recognition.

AI may have the ability to go even further by potentially providing decision-making assistance and guidance toward possible treatment options. Dr. Lim says there’s a lot of talk surrounding this topic. She wonders if, in the future, a physician might be able to “take pieces of disparate data, like a patient’s test results, and incorporate AI to help guide him or her toward a treatment.”

- **Improved interoperability.**

When it comes to sharing data between different EHR systems, doctors agree significant improvement is needed. Dr. Boland calls for improved data sharing. “In ophthalmology, we need standards that let us share ophthalmology-specific data with each other,” he says. “Otherwise, we’re going to be stuck with these generic systems that were designed for primary care, which doesn’t really help us in a meaningful way.”

- **Ophthalmic imaging integration.**

It’s a big undertaking, but many doctors feel that better integration of imaging results would benefit their practice. Currently, companies employ picture archiving and communication systems. Dr. Lim says there may be workarounds to incorporate imaging, but it’s still not truly integrated. “Most

ophthalmologists have to use separate systems to capture all of their imaging results and look at them; but now you're dealing with two different systems that you have to somehow link together," she says. Dr. Boland agrees that it'd be better if images were integrated more tightly with EHR. In particular, he'd like more vendor-neutral analysis of OCT images. "For retina folks specifically, it's currently a big struggle because, depending on what machine they're using, to get images of the retina they have to launch all of the vendor-specific software to do the review," he says. "Using two or three different systems just to view the images can become cumbersome."

• **A break from EHR?** Sometimes, physicians will switch EHR systems in hopes of finding one that better suits their practice. Dr. Iwach says instead of switching EHR systems, maybe it should be more socially acceptable to take a break from EHR. "I'm not saying not to use technology, but per-

haps a modified use of technology," he says. "How about 'efficient' medical records, instead of 'electronic'? Maybe we utilize some paper for taking notes but then use computers, servers and scanners in conjunction to enable more efficient data collection while still promoting the doctor-patient relationship."

Even though he hasn't yet implemented EHR in his practice—and therefore incurs a penalty—Dr. Iwach has a background in software and computer databases that has kept him from implementing what he feels are systems that wouldn't quite fit within his practice. With published papers on the subject going back to his residency in the 1980s, he feels it's his background and interest in tech that has made him more of a "cautious consumer" of software. "All I suggest is that we don't forget there are alternatives," he says. "It may not be an option for all settings, but don't take [waiting to implement EHR] off the

list of options. I'm passionate about the topic and I want people to be able to think, 'maybe there's another way.' It's good to have a message out there that gives people permission to question technology and its timing."

Most doctors agree that EHRs, while not perfect, have their benefits, and they hope that, with time, the systems will have more features that doctors find useful. Dr. Boland says this may be a ship that can't be turned around. "I think EHRs are likely here to stay, so we need to acknowledge that and focus on taking the time to consider how [EHR] can be used to make workflow better," he says. "Take control of your EHR so that it doesn't take control of you." **REVIEW**

Drs. Wells, Lim and Boland report no relevant financial disclosures. Dr. Iwach is a consultant for Bausch & Lomb and Dr. Chiang is a consultant for Novartis and an equity owner of Intelereitina.



Visit us at
ASCRS
Booth
3428

YOU HAVE TRIED THE REST, NOW TRY THE BEST!

The Eye Doctor Plus Moist Heat Dry Eye Mask is made in England with the finest of material.

It is the best because:

1. The patented material is antimicrobial.
2. Has a removable cover for easy washing.
3. Comes with a storage pouch and Lid Wipes.
4. Can be used for Heat or Cold.
5. Can be heated in either a microwave or oven for moist heat.
6. The mask shape will fit any size face.
7. Mask can be used over and over. Guaranteed for one year.



1-833-4DRYEYE
Info@thedryeyedoctor.net
www.thedryeyedoctor.net



The Questionable Cataract: Who Decides?

Walter Bethke, Editor in Chief

Surgeons share tips to help you navigate the sometimes murky waters of preop evaluations.

Surgeons say that the success of modern cataract surgery, both with premium lenses and high-quality monofocal IOLs, can push some patients to visit their ophthalmologist to try to get cataract surgery—medically justified or not—in an effort to “get what my neighbor got.” Some of these patients are even savvy enough to work the system by claiming visual difficulties.

To avoid committing insurance fraud and exposing these individuals to unnecessary risks, surgeons say there are certain measures you can take. They’re quick to add, however, that just because a patient’s attempt at insurance- or Medicare-paid surgery is rebuffed doesn’t mean he won’t want to spring for it himself in the form of refractive lens-based proce-

sure, and they offer further advice on making sure the right patient gets the right procedure—or none at all.

“I Think I Have a Cataract”

Boulder, Colorado, ophthalmologist Mark Packer says that though malingering in most of medicine is usually done to qualify for some sort of disability payment, it can take on a new form in ophthalmology.

“There aren’t a lot of examples in other fields where someone is malingering in order to get an operation, other than Munchausen’s syndrome,” he says. “But in ophthalmology, I’ve definitely seen this. I guess it arose even before the Medicare ruling in 2005 regarding presbyopic IOLs. Before that, patients were aware that their friends went to see the ophthalmologist for cataract surgery, and that they used to wear bifocals but now they don’t. This would lead them to my office, saying something to the effect, ‘I don’t have cataracts but I want that.’ But then they find out it will cost \$10,000 because they don’t have cataracts. ‘But my neighbor didn’t pay anything—the insurance paid for it!’ You reply that that’s because the neighbor had cataracts. ‘So,’ he thinks, ‘what does it take to have a cataract? Maybe I can find one.’”





POWERED
FOR PENETRATION^{1,2}

DESIGNED WITH
COMFORT IN MIND^{1,2}



DELIVER THE PROLENSA[®] EFFECT¹⁻³

Achieve POWERFUL CORNEAL PENETRATION with the
#1 prescribed branded ocular NSAID, PROLENSA[®].

The only branded formulation of bromfenac approved for once-daily use.¹

*IQVIA NPA Monthly, November 2018

INDICATIONS AND USAGE

PROLENSA[®] (bromfenac ophthalmic solution) 0.07% is a nonsteroidal anti-inflammatory drug (NSAID) indicated for the treatment of postoperative inflammation and reduction of ocular pain in patients who have undergone cataract surgery.

IMPORTANT SAFETY INFORMATION ABOUT PROLENSA[®]

- PROLENSA[®] contains sodium sulfite, a sulfite that may cause allergic type reactions including anaphylactic symptoms and life-threatening or less severe asthmatic episodes in certain susceptible people. The overall prevalence of sulfite sensitivity in the general population is unknown and probably low. Sulfite sensitivity is seen more frequently in asthmatic than in non-asthmatic people.
- All topical nonsteroidal anti-inflammatory drugs (NSAIDs), including bromfenac, may slow or delay healing. Concomitant use of topical NSAIDs and topical steroids may increase the potential for healing problems.
- There is the potential for cross-sensitivity to acetylsalicylic acid, phenylacetic acid derivatives, and other NSAIDs, including bromfenac. Use with caution in patients who have previously exhibited sensitivities to these drugs.
- There have been reports that ocularly applied NSAIDs may cause increased bleeding of ocular tissues (including hyphemas) in conjunction with ocular surgery. Use with caution in patients with known bleeding tendencies or who are receiving other medications which may prolong bleeding time.

- Use of topical NSAIDs may result in keratitis. Patients with evidence of corneal epithelial breakdown should immediately discontinue use of topical NSAIDs, including bromfenac, and should be closely monitored for corneal health. Patients with complicated ocular surgeries, corneal denervation, corneal epithelial defects, diabetes mellitus, ocular surface diseases (e.g., dry eye syndrome), rheumatoid arthritis, or repeat ocular surgeries within a short period of time may be at increased risk for corneal adverse events which may become sight threatening. Topical NSAIDs should be used with caution in these patients. Post-marketing experience with topical NSAIDs suggests that use more than 24 hours prior to surgery or use beyond 14 days post-surgery may increase patient risk for the occurrence and severity of corneal adverse events.
- PROLENSA[®] should not be instilled while wearing contact lenses. The preservative in PROLENSA[®], benzalkonium chloride, may be absorbed by soft contact lenses. Lenses may be reinserted after 10 minutes following administration of PROLENSA[®].
- The most commonly reported adverse reactions in 3%-8% of patients were anterior chamber inflammation, foreign body sensation, eye pain, photophobia, and blurred vision.

Please see brief summary of full Prescribing Information for PROLENSA[®] on adjacent page.

References: 1. PROLENSA Prescribing Information. 2. Baklayan GA, Patterson HM, Song CK, Gow JA, McNamara TR. 24-hour evaluation of the ocular distribution of (14)C-labeled bromfenac following topical instillation into the eyes of New Zealand white rabbits. *J Ocul Pharmacol Ther.* 2008;24(4):392-398. 3. Data on file, Bausch & Lomb Incorporated.

BAUSCH + LOMB

PROLENSA is a trademark of Bausch & Lomb Incorporated or its affiliates.
© 2019 Bausch & Lomb Incorporated. All rights reserved. Printed in USA. PRA.0017.USA.19

PROLENSA[®]
(bromfenac ophthalmic
solution) 0.07%

BRIEF SUMMARY OF PRESCRIBING INFORMATION

This Brief Summary does not include all the information needed to prescribe Prolensa safely and effectively. See full prescribing information for Prolensa.

PROLENSA (bromfenac ophthalmic solution) 0.07%

Rx only

Initial Rx Approval: 1997

INDICATIONS AND USAGE

PROLENSA® (bromfenac ophthalmic solution) 0.07% is indicated for the treatment of postoperative inflammation and reduction of pain in patients who have undergone cataract surgery.

DOSAGE AND ADMINISTRATION

Recommended Dosing

One drop of PROLENSA ophthalmic solution should be applied to the affected eye once daily beginning 1 day prior to cataract surgery, continued on the day of surgery, and through the first 14 days of the postoperative period.

Use with Other Topical Ophthalmic Medications

PROLENSA ophthalmic solution may be administered in conjunction with other topical ophthalmic medications such as alpha-agonists, beta-blockers, carbonic anhydrase inhibitors, cycloplegics, and mydriatics. Drops should be administered at least 5 minutes apart.

CONTRAINDICATIONS

None

WARNINGS AND PRECAUTIONS

Sulfite Allergic Reactions

Contains sodium sulfite, a sulfite that may cause allergic-type reactions including anaphylactic symptoms and life-threatening or less severe asthmatic episodes in certain susceptible people. The overall prevalence of sulfite sensitivity in the general population is unknown and probably low. Sulfite sensitivity is seen more frequently in asthmatic than in non-asthmatic people.

Slow or Delayed Healing

All topical nonsteroidal anti-inflammatory drugs (NSAIDs), including bromfenac, may slow or delay healing. Topical corticosteroids are also known to slow or delay healing. Concomitant use of topical NSAIDs and topical steroids may increase the potential for healing problems.

Potential for Cross-Sensitivity

There is the potential for cross-sensitivity to acetylsalicylic acid, phenylacetic acid derivatives, and other NSAIDs, including bromfenac. Therefore, caution should be used when treating individuals who have previously exhibited sensitivities to these drugs.

Increased Bleeding Time

With some NSAIDs, including bromfenac, there exists the potential for increased bleeding time due to interference with platelet aggregation. There have been reports that ocularly applied NSAIDs may cause increased bleeding of ocular tissues (including hyphemas) in conjunction with ocular surgery.

It is recommended that PROLENSA ophthalmic solution be used with caution in patients with known bleeding tendencies or who are receiving other medications which may prolong bleeding time.

Keratitis and Corneal Reactions

Use of topical NSAIDs may result in keratitis. In some susceptible patients, continued use of topical NSAIDs may result in epithelial breakdown, corneal thinning, corneal erosion, corneal ulceration, or corneal perforation. These events may be sight threatening. Patients with evidence of corneal epithelial breakdown should immediately discontinue use of topical NSAIDs, including bromfenac, and should be closely monitored for corneal health.

Post-marketing experience with topical NSAIDs suggests that patients with complicated ocular surgeries, corneal denervation, corneal epithelial defects, diabetes mellitus, ocular surface diseases (e.g., dry eye syndrome), rheumatoid arthritis, or repeat ocular surgeries within a short period of time may be at increased risk for corneal adverse events which may become sight threatening. Topical NSAIDs should be used with caution in these patients.

Post-marketing experience with topical NSAIDs also suggests that use more than 24 hours prior to surgery or use beyond 14 days post-surgery may increase patient risk for the occurrence and severity of corneal adverse events.

Contact Lens Wear

PROLENSA should not be instilled while wearing contact lenses. Remove contact lenses prior to instillation of PROLENSA. The preservative in PROLENSA, benzalkonium chloride may be absorbed by soft contact lenses. Lenses may be reinserted after 10 minutes following administration of PROLENSA.

ADVERSE REACTIONS

Clinical Trial Experience

Because clinical trials are conducted under widely varying conditions, adverse reaction rates observed in the clinical trials of a drug cannot be directly compared to

rates in the clinical trials of another drug and may not reflect the rates observed in clinical practice.

The most commonly reported adverse reactions following use of PROLENSA ophthalmic solution following cataract surgery include: anterior chamber inflammation, foreign body sensation, eye pain, photophobia and vision blurred. These reactions were reported in 3 to 8% of patients.

USE IN SPECIFIC POPULATIONS

Pregnancy

Treatment of rats at oral doses up to 0.9 mg/kg/day (systemic exposure 90 times the systemic exposure predicted from the recommended human ophthalmic dose [RHOD] assuming the human systemic concentration is at the limit of quantification) and rabbits at oral doses up to 7.5 mg/kg/day (150 times the predicted human systemic exposure) produced no treatment-related malformations in reproduction studies. However, embryo-fetal lethality and maternal toxicity were produced in rats and rabbits at 0.9 mg/kg/day and 7.5 mg/kg/day, respectively. In rats, bromfenac treatment caused delayed parturition at 0.3 mg/kg/day (30 times the predicted human exposure), and caused dystocia, increased neonatal mortality, and reduced postnatal growth at 0.9 mg/kg/day.

There are no adequate and well-controlled studies in pregnant women. Because animal reproduction studies are not always predictive of human response, this drug should be used during pregnancy only if the potential benefit justifies the potential risk to the fetus.

Because of the known effects of prostaglandin biosynthesis-inhibiting drugs on the fetal cardiovascular system (closure of ductus arteriosus), the use of PROLENSA ophthalmic solution during late pregnancy should be avoided.

Nursing Mothers

Caution should be exercised when PROLENSA is administered to a nursing woman.

Pediatric Use

Safety and efficacy in pediatric patients below the age of 18 have not been established.

Geriatric Use

There is no evidence that the efficacy or safety profiles for PROLENSA differ in patients 70 years of age and older compared to younger adult patients.

NONCLINICAL TOXICOLOGY

Carcinogenesis, Mutagenesis and Impairment of Fertility

Long-term carcinogenicity studies in rats and mice given oral doses of bromfenac up to 0.6 mg/kg/day (systemic exposure 30 times the systemic exposure predicted from the recommended human ophthalmic dose [RHOD] assuming the human systemic concentration is at the limit of quantification) and 5 mg/kg/day (340 times the predicted human systemic exposure), respectively, revealed no significant increases in tumor incidence.

Bromfenac did not show mutagenic potential in various mutagenicity studies, including the reverse mutation, chromosomal aberration, and micronucleus tests. Bromfenac did not impair fertility when administered orally to male and female rats at doses up to 0.9 mg/kg/day and 0.3 mg/kg/day, respectively (systemic exposure 90 and 30 times the predicted human exposure, respectively).

PATIENT COUNSELING INFORMATION

Slowed or Delayed Healing

Advise patients of the possibility that slow or delayed healing may occur while using NSAIDs.

Sterility of Dropper Tip

Advise patients to replace bottle cap after using and to not touch dropper tip to any surface, as this may contaminate the contents. Advise patients that a single bottle of PROLENSA be used to treat only one eye.

Concomitant Use of Contact Lenses

Advise patients to remove contact lenses prior to instillation of PROLENSA. The preservative in PROLENSA, benzalkonium chloride, may be absorbed by soft contact lenses. Lenses may be reinserted after 10 minutes following administration of PROLENSA.

Concomitant Topical Ocular Therapy

If more than one topical ophthalmic medication is being used, the medicines should be administered at least 5 minutes apart.

Rx Only

Manufactured by:

Bausch + Lomb, a division of Valeant Pharmaceuticals
North America LLC, Bridgewater, NJ 08807 USA

Product under license from:

Senju Pharmaceutical Co., Ltd., Osaka, Japan 541-0046
Prolensa is a trademark of Bausch & Lomb Incorporated or its affiliates.
© Bausch & Lomb Incorporated

Revised: 06/2016

Based on: 9306701/9306801

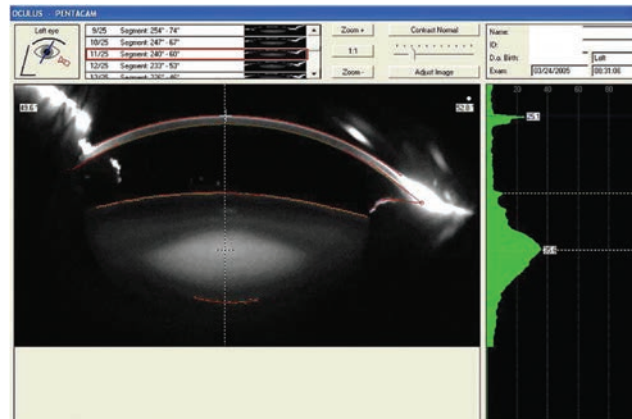
PRA.0119.USA.16

It turns out, however, that if a patient really wants to say he has poor vision, this can be difficult to disprove just by using visual acuity charts. “They can see the size of the letters,” Dr. Packer says. “They might know what 20/40 looks like or, if you’re using an older chart, it might say ‘20/40’ right on the chart. While today we have randomized, digital charts that no one can memorize, if someone’s motivated to lie to get the surgery paid for by Medicare or insurance, it can still be hard to prove that someone is malingering, just by using visual acuity.”

At this point, if you simply don’t believe what a patient is saying for some reason, it would be easy enough to smack the patient down as dissembling and refuse to do the surgery. However, surgeons say the effect of this is to alienate a member of your community, as well as all of that person’s family members and friends. “It’s helpful to have some other workarounds that maybe patients aren’t as familiar with, but which can provide evidence that they’re not really a candidate for medically-reimbursed cataract surgery,” Dr. Packer says. “I’ve got a few of those up my sleeve.”

Since physicians say visual acuity can be “squishy” and easy to manipulate, one of the first ways to weed out a less-than-truthful patient is with the VF-14 visual function questionnaire. “It has such questions as, ‘Do you drive?’ and ‘If you drive, is it difficult?’” says Dr. Packer. “A patient doesn’t know what the score on that is supposed to be,

The VF-14 questionnaire can help weed out malingerers.



Scheimpflug imaging can provide an objective grading of a cataract that can help in borderline cases, surgeons say.

or what a realistic score would be for someone with the degree of visual disability that he’s claiming to have—but I do. So, if the vision is 20/50, for instance, in general that correlates with a VF-14 in the range of 60 to 75. If it’s better than that, such as an 88, then there’s no reason to have cataract surgery, because that’s the average score for individuals who’ve had the surgery. In that case, there’d be no room for improvement.”

Contrast sensitivity is another test about which patients have little understanding, so they can’t easily manipulate its results. “They don’t know how it’s graded,

what a result is supposed to look like or anything else about it,” avers Dr. Packer. “They don’t know how hard to try on it or how poorly they’re supposed to do on it, yet they can’t say ‘I don’t see anything,’ because that’s not plausible. It’s a subjective test, however, so a very sophisticated patient might be able to fake it, but most aren’t that sophisticated and won’t know how; they’ll get a score that’s either too good or too bad. Then, they’re caught. This is the general method for spotting a malingerer: Give him a test where a certain response would be physiologically impossible.”

Surgeons say that the advent of certain instruments, such as the Pentacam, allows them to objectively evaluate a cataract’s density, which can help in cases such as this. “We do tests like the iTrace or HD Analyzer to look at the quality of the optical system,” says Jeffersonville, Indiana, surgeon Asim Piracha. “We use these to see if we can objectively confirm their complaints and say, ‘Yes, your vision is poor.’ If, however, these tests show a perfect optical system, I wouldn’t recommend surgery, because I don’t think the surgery would help them. We then get into why they’re not seeing well. Is it amblyopia? A retinal issue? An optic nerve problem? Often, we do a Pentacam exam and end up doing more testing than we’d normally do; we perform topography and an OCT of the optic nerve and retina to make sure it’s not something I’m missing on exam. If there aren’t any findings, however, they can complain but I can’t do cataract surgery because I’m not seeing any findings on exam

Overview:

The Visual Function Index (VF-14) is a brief questionnaire designed to measure functional impairment on patients due to cataract. It consists of 18 questions covering 14 aspects of visual function affected by cataracts. The VF-14 shows high internal consistency and is a reliable, valid instrument providing information not conveyed by visual acuity or general health status measures.

General Functioning

- (1) Do you have any difficulty, even with glasses, reading small print, such as labels on medicine bottles, a telephone book, food labels?
- (2) Do you have any difficulty, even with glasses, reading a newspaper or a book?
- (3) Do you have any difficulty, even with glasses, reading a large-print book or large-print newspaper or numbers on a telephone?
- (4) Do you have any difficulty, even with glasses, recognizing people when they are close to you?
- (5) Do you have any difficulty, even with glasses, seeing steps, stairs or curbs?
- (6) Do you have any difficulty, even with glasses, reading traffic signs, street signs, or store signs?
- (7) Do you have any difficulty, even with glasses, doing fine handwork like sewing, knitting, crocheting, carpentry?
- (8) Do you have any difficulty, even with glasses, playing games such as bingo, dominos, card games, mahjong?
- (9) Do you have any difficulty, even with glasses, writing checks or filling out forms?
- (10) Do you have any difficulty, even with glasses, taking part in sports like bowling, handball, tennis, golf?
- (11) Do you have any difficulty, even with glasses, cooking?
- (12) Do you have any difficulty, even with glasses, watching television?

Response	Points
not applicable	



I didn't realize
STARS
were little dots that twinkled

—Misty L, *RPE65* gene therapy recipient

WE'RE SEEING AMAZING RESULTS. **AND SO ARE THEY.**

Foundation Fighting Blindness is shining a light in the darkness of Inherited Retinal Degenerations. We are the world's leading organization searching for treatments and cures, and with many treatments already found, today's innovations are illuminating a future of possibilities.

Patients with Inherited Retinal Degenerations are urged to partner with us to accelerate the discovery of treatment and cures.

We have robust disease information, a national network of local chapters and support groups, local educational events, and our My Retina Tracker patient registry helps to keep your patients connected with clinical and research advancements.



Visit ECPs4Cures.org
to make a donation
to help find more cures.

FightBlindness.org

FOUNDATION **FIGHTING
BLINDNESS**

that would justify it.”

Determining that a patient is feigning worse vision is only half the battle, however. The final challenge is informing him that you’re not going to perform surgery in such a way that you don’t incite anger or resentment. “When you return to the exam room with the patient, and have such things as his questionnaire, contrast sensitivity and the objective measurement of the cataract’s densitometry,” says Dr. Packer, “you can say, ‘Look, even though your visual acuity is in line with Medicare or your insurance carrier’s definition of a cataract, based on this additional testing you’re functioning pretty well. I don’t believe that cataract surgery’s benefits will outweigh the risks for you. Please come back and see me in a year.’” He says framing it in this way gives you an argument to fall back on, rather than just pointing your finger at him and saying that he’s faking it.

Dr. Piracha says he’s seen patients seeking cataract surgery not because of malingering, but because of the effects of past corneal refractive surgery. “Some older patients come in and think, ‘I can’t see well, it must be a cataract,’” he says. “When I perform iTrace on these patients such as, for example, the post-RK patient who’s now hyperopic—+4 D and seeing maybe 20/30 best-corrected—and it shows the cornea isn’t right but the lens is pretty good, I tell them that cataract surgery probably won’t improve their quality of vision, it’ll just help reduce the hyperopia. Also, with the post-RK eye, cataract surgery’s not as predictable. I get patients referred in also, such as post-LASIK and post-RK, and they say they want cataract surgery. This testing helps me tell them that I don’t see a value in cataract surgery for them, since it’s not going to address their irregular astigmatism. If you perform cataract surgery on these patients, they can be difficult to deal with postop, because they expected cataract surgery to fix them but they still won’t see well.”

For surgeons who don’t have an iTrace, Dr. Piracha says the time-honored RGP over-refraction will tell you if the irregular vision is from the cornea or not. “If it’s an RK patient, or a patient with ectasia, and you do the RGP over-refraction and they go from 20/40 to 20/20,” Dr. Piracha says, “you know the problem is the cornea. If we do it, however, and they’re still 20/40, then we know the problem isn’t the cornea, because the RGP covers up the irregular astigmatism.”

When the Talk Turns Elective

Surgeons say that a few of these patients who are exaggerating their poor vision will actually be open to having an elective lens procedure when they’re eventually told that an insurance-paid cataract surgery isn’t advisable. Though this development may cause the surgeon to heave a sigh of relief—the patient isn’t going away mad and possibly em-

Patented MediBeads® are why Bruder is the #1 Doctor Recommended Moist Heat Eye Compress

No Silica Gel Beads | No Gels | No Grains



Bruder is the only moist heat compress in the world that contains patented MediBeads.

- Provides uniform moist heat – No hot spots.
- Washable and reusable – Will not break down in water.
- Anti-bacterial – Like no other mask on the market.
- Flexible two-pod design – Comfortably fits all facial types.

Accept No Substitutes. Recommend the **Bruder Moist Heat Eye Compress** to your patients and give them the exceptional performance, comfort, safety and durability of MediBeads.

VISIT OUR PROFESSIONAL PORTAL
to purchase online at order.bruder.com

Visit Bruder Booth #2352
During ASCRS in San Diego

Bruder
Better. By Design.

Legal Lookouts

Denver, Colorado, attorney C. Gregory Tiemeier has represented ophthalmologists in a number of malpractice cases, from lasers to lenses. Here are his tips for covering yourself, whichever way the surgical discussion goes.

- *Get it in writing.* Mr. Tiemeier says if you go ahead with an insurance-covered procedure in which you have some objective proof of a cataract—it doesn't need to be 3+—but the main complaints are subjective, make sure to have a record of it. "If you're going to perform the procedure and want to cover yourself, make sure the patient signs something to the effect of, 'I have problems with reading, low-light vision, driving at night, driving during the day, etc.,'" he says. "Though brightness acuity testing can be a gamble, the critical question is how it's affecting the patient subjectively, though some objective findings need to be there. If you don't want to perform the surgery, such as a case where you've done BAT and you think the patient is faking it, make a note to the effect that the patient's subjective complaints and the BAT aren't consistent with the degree of cataract that's observed objectively."

- *RLE is less common.* "If you're going to perform an elective clear lens extraction on someone and he doesn't have a cataract, be aware that you're increasing your risk slightly in terms of legal exposure," Mr. Tiemeier says. "When compared to more 'mainstream' procedures like PRK and LASIK, this is less common. This is important to note because there are conservative doctors out there who won't remove a lens unless it has a cataract. Postoperatively,

the patient could go to one of these doctors and the doctor will say, "I can't believe they did a clear lens extraction on you."

- *Focus on the informed consent.* Mr. Tiemeier says that any time a patient is paying out of pocket for a procedure, the patient's expectations go up dramatically. "You need to adjust your informed consent process accordingly," he warns. "I know most doctors tend to view informed consent as a kind of 'necessary evil,' but I remind them that if the patient is unhappy for some reason and you get sued, it's going to take more time to deal with that lawsuit than the five minutes it would have taken to sit down with the patient and explain that this surgery is different from LASIK or PRK; you're going inside the eye, so the risks go up, especially the risk of endophthalmitis. You also have to have something in the document that says, 'You may need to wear glasses after the surgery.'" Though Mr. Tiemeier hasn't been involved with any CLE lawsuits, he has had suits involving multifocal IOLs. Based on that experience, he says surgeons should also advise patients in the informed consent for multifocal lenses that it might take up to six months to adjust to the multifocality effects.

- *Check your malpractice coverage.* This could be a hidden trap. "Though I'm not aware of any insurance companies that exclude clear lens extraction," Mr. Tiemeier says, "it would probably be a good idea to make sure that it's not excluded from your malpractice coverage before you do it."

— WB

barrased—experts remind that just because the patient is ready and willing to pay for the procedure doesn't automatically mean that it should happen.

"We have to consider a few major things," says Arturo Chayet, MD, of Tijuana, Mexico's, Codet Vision Institute. "The first is the refractive error. In other words, myopes vs. hyperopes. There's very strong data from the past 20 years that's made it well-known that if a patient has an axial length of over 25 mm, and undergoes uneventful cataract surgery or refractive lens exchange, he's in the highest incidence group for retinal detachment.

"And, there's the knowledge that high myopes are also at a higher risk for spontaneous bag dislocation 10 years after IOL implantation," Dr. Chayet continues. "So these two issues, in my opinion, are definite exclusion criteria for RLE in high myopes."

If a patient isn't a candidate, Los Angeles ophthalmologist Sam Masket says the best thing is to be upfront and honest about it. "I always say that if it's good for the patient, it's good for the doctor—and the industry," Dr. Masket says. "The patient's interests must always be front and center."

Dr. Chayet says that the patient's age also plays a large role—especially which side of age 60 they're on. "I've found that there's a big difference between someone younger than 60, and someone older," he says. "The crystalline lens becomes very dysfunctional after age 60. In my practice, most of the patients who request RLE start doing so at about age 52, right around the time they began wearing progressive lenses or using bifocals." Dr. Chayet isn't saying everyone should universally accept "dysfunctional lens syndrome" as a diagnostic term, but he is saying he thinks presbyopia is a pre-

cursor to cataracts. "I personally don't do RLE on someone who's younger than 60 and has 20/30 or better distance vision," Dr. Chayet says. "I've found that the expectations of those patients are very high, and their satisfaction rate after RLE isn't that good. Most of the very unsatisfied patients I've seen after RLE are these patients. Surgeons who perform RLE on them are pushing the envelope.

"Now, if the patient is older than 60, his distance vision is 20/40 or worse and the axial length is shorter than 25 mm, then I think the RLE conversation becomes more appropriate," Dr. Chayet continues. "At that point, you have to explain to the patient what to expect and the side effects of our current IOLs, even if you go with monovision with monofocal IOLs. If the patient accepts the possibility of these side effects, then I feel comfortable doing the procedure."

Lid Hygiene is important to Overall Eye Health

Dr. Chayet says categorizing patients based on their vision also helps ensure a positive outcome. “If the distance vision is good, I wouldn’t recommend doing any RLE,” he says. “On the other hand, if the patient is +4 D with 20/200 uncorrected distance vision with an anterior chamber depth of 2 mm or less, I think that patient might benefit from surgery. That’s because not only will he be able to see well, but the surgery will increase the depth of the anterior chamber, and will increase the angle, which will reduce the risk of glaucoma in the future. These types of patients, however, are the least frequently encountered ones seeking RLE these days.” He says the only refractive procedure he’d perform on a high myope would be a phakic intra-ocular lens in the form of the Visian ICL. “Even if I know cataract is a risk for them,” he says, “I’d rather implant an ICL [than perform RLE.]”

There are also the patients who aren’t malingering, but have visual issues that don’t reach the level of an insurance-covered cataract. Dr. Piracha offers as an example the patient who has a best-corrected vision of 20/25 or 20/30, and inquires about a refractive option. “This happens a good bit,” he says. “We rule out all the causes for decreased night vision, all the issues associated with glare and halo, and examine the ocular surface and topography to make sure nothing else is going on, and if they say they’d like to have refractive surgery, we’ll discuss it with them. If they don’t meet the definition of cataract per insurance—which here in Indiana is 20/50 or worse with either best-corrected vision testing or testing with glare—we tell them, ‘You have a mild cataract that doesn’t meet the official criteria yet, so you have two choices: Do an elective surgery now in order to get better vision without glasses, as well as improve your visual quality, or wait until you meet the criteria for insurance coverage, in which case we can see you back here in a year for another evaluation.’ I inform them that if they decide to wait, insurance will cover part of the procedure, but not the refractive-cataract surgery part—i.e., if they have astigmatism or want to see both near and far, then they’ll still need to pay for the laser AK, or a toric or multifocal lens.” He then follows this with a discussion of the risks outlined by Dr. Chayet, especially with regard to high myopes.

In the end, if a patient is trying to get surgery paid for but doesn’t really have a cataract, Dr. Packer says it often comes down to your estimate of his character, “as much as you can do that in the three minutes that you’re with him in the exam room,” he says. “Ask yourself, ‘Is this someone who’s primary motivation is refractive but he’s trying to frame it as a medical procedure?’ That’s the main distinction.” **REVIEW**

Dr. Piracha has spoken for iTrace in the past. The other surgeons have no financial interest in the products they discuss.

PRESCRIPTION STRENGTH
WITHOUT A PRESCRIPTION



INTRODUCING

Bruder® **Hygienic** **EYELID SOLUTION™**

PRESCRIPTION STRENGTH

CONTAINS
0.02% PURE
HYPOCHLOROUS ACID SOLUTION

A Convenient and Effective Alternative
to Costly Prescription-only Solutions

Safe for Daily Long-Term Use

VISIT **BRUDER BOOTH #2352**
DURING **ASCRS - SAN DIEGO** TO LEARN MORE

HELP YOUR PATIENTS ENHANCE THEIR OCULAR
HEALTH THROUGH AN IMPROVED HOME LID
CLEANSING ROUTINE BY RECOMMENDING
BRUDER EYE CARE PRODUCTS.

Bruder

Better. By Design.

bruder.com | 888-827-8337

How to Manage Uveitic Glaucoma

Lama Al-Aswad, MD, MPH
New York

Tips and techniques for dealing with this unique subset of glaucoma patients.

One of the many pitfalls to deal with when a patient has two co-existing diseases is the confounding possibility that the treatment for one will interfere with—or even worsen—the other. Such is the case with uveitic glaucoma patients. In these cases, one of the mainstays of uveitis treatment—steroids—can exacerbate the glaucoma while, at the same time, the inflammation can make successful glaucoma surgery more difficult to achieve. In this article, I'll share my approach to managing these challenging cases.

Etiology

Uveitic glaucoma occurs in about 20 percent of patients with uveitis. There are multiple reasons why it may occur: inflammatory cells obstructing the trabecular meshwork; peripheral anterior synechiae; pupillary block; trabeculitis; and as a response to the steroids being used to treat the uveitis. There can also be instances of inflammation of the trabecular meshwork that results in elevated intraocular pressure.

Workup and Management

If a patient presents with a history of uveitis and elevated IOP, there are several key aspects of diagnosis and

management to keep in mind.

- **Look at the medication regimen.** This is one of the first things the clinician will want to do. Is he currently using steroids? If so, how often? Altering the steroid regimen is one of the simplest, most straightforward actions you can take in these cases. In addition to measuring the patient's visual acuity and IOP, be sure to perform gonioscopy to check for anterior synechiae, and make sure there are no posterior synechiae that might cause pupillary block.

You may want to change the steroid regimen. Some patients arrive in your office from the uveitis specialist and they have quiet eyes due to a strong steroid regimen. In these cases, it might be beneficial to decrease the frequency of the steroids to see if they're steroid responders. In some cases, however, you may not be able to do this. If you do find—or suspect—posterior synechiae, there's a higher chance, unfortunately, that manipulating the frequency of the steroids might not do anything for the patient, since the trabecular meshwork is closed by the synechiae.

- **Consider an iridotomy.** If you think pupillary block is the cause, a laser iridotomy can open a passage between the posterior and anterior chambers.

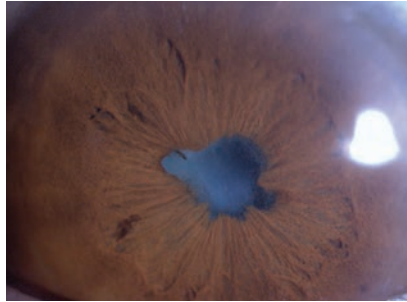• **Use your imaging and diagnostic tools.** You may find that the patient has elevated IOP from steroid use but no evidence of glaucoma, or that the steroids have increased the pressure and there's also evidence of nerve damage. Use your diagnostic tools, such as visual field exams and optical coherence tomography of the optic nerve, to get a baseline for the patient so you can follow him over time. I will sometimes also perform anterior segment OCT in certain individuals in order to document whether there's synechiae or not. This last step isn't always necessary, but it can be informative in some patients.

Sometimes, nerve fiber layer measurements appear normal in a patient with glaucoma; that's why longitudinal information is very important. The nerve fiber layer should correlate with your clinical diagnosis first. Then, follow the patient over time to get a better idea of his status. It's important that your imaging and functional testing agree with your exam. For instance, if I see a cup that appears large and potentially glaucomatous, but the OCT doesn't confirm that, I'm suspicious, but I'll need longitudinal data to help with the diagnosis and management.

• **Communicate with the patient's uveitis specialist/rheumatologist.** It's important to work hand-in-hand with this person, because you may need to take some uveitis patients off of steroids or, depending on the severity of the uveitis and its cause, switch to other immunosuppressive modalities to control the inflammation.

When I'm working with the uveitis specialist, I follow his recommendations. I do my best to control the inflammation while controlling the pressure, and won't tolerate any cells in the anterior chamber, if possible.

• **Manage the inflammation.** Initially, if the eye is very inflamed, the patient is prescribed Pred Forte or Durezol for use every one to two hours while awake, in addition to Cyclogyl or homatropine, depending on the sever-



Working with a uveitis specialist is key, as you may need to alter the uveitis therapy.

ity. For the latter two drugs, I prefer alternating between twice a day and once a day, which doesn't keep the pupil dilated or constricted in the presence of a lot of inflammation. I like to have the pupil moving on and off in order to decrease the chance of synechiae.

Depending on the severity of the inflammation, I eventually begin tapering the steroid. Long ago, I learned that a slow taper is important; the faster you taper, the higher the chance of developing rebound inflammation that can be hard to control.

If the eye is very quiet, or is close to being quiet, but the IOP is trending upward, I'll alternate the steroid with a non-steroidal anti-inflammatory drop to help with the inflammation. This allows me to decrease the steroid regimen; instead of using it three times a day, the patient can use it only twice, or even once. I then can also slowly taper it. If the eye is then quiet for a while, I take away the steroid and keep the patient on the NSAID for a longer period. This approach has also worked in patients who were steroid responders but whose inflammation wasn't severe. (If it's bad, though, this approach won't work.)

If the inflammation is severe and the patient is a steroid responder, it's important to assess the pressure. If it's a little on the high side, and I have time to work with a uveitis specialist to help switch the patient to another modality for controlling the inflammation, like

methotrexate or CellCept, I will. The issue is that these immunomodulators usually have a loading time of a few months before they're fully functional in the patient. I'll work with the uveitis specialist to slowly take the patient off of the steroids as the immunosuppressive therapy is introduced.

Sometimes I don't have time for this approach, because the pressure is very high and there's a risk of damage to the optic nerve. In such cases, I take the patient to the operating room to insert a glaucoma implant, hitting the eye hard with preop prednisone drops and p.o. prednisone if needed, intraoperative IV prednisone and more drops postoperatively to decrease the inflammation with the option to use p.o. prednisone.

In some of these cases, the patient can develop complications such as psychosis from the oral steroids, and I'll need to work with the immunologist or uveitis specialist to start immunotherapy and get the patient off of the oral corticosteroids.

If the etiology of the inflammation is viral (i.e., herpetic), you're likely to use a steroid and begin treatment—or maintain treatment—with acyclovir, in a way similar to conventional herpes therapy. If the herpetic patient's pressure remains high regardless of treatment and the inflammation is chronic, then you'll most likely need a glaucoma implant to control the intraocular pressure.

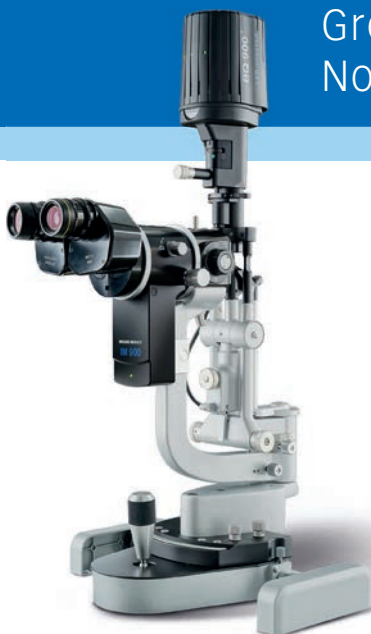• **Manage the glaucoma.** Naturally, if the pressure is high in these patients, you should start treating with glaucoma drugs immediately. Most physicians will use a carbonic anhydrase inhibitor, beta blocker or alpha agonist. On rare occasions, we'll use a prostaglandin as a temporary solution for a high pressure, but we usually avoid prostaglandins in these patients because they can induce a low-grade inflammation. (I haven't used Rhopressa in uveitic patients yet but, if I needed something else,



SEE WHERE A HAAG-STREIT SLIT LAMP CAN TAKE YOU.



Ground-breaking optics powered by LED illumination.
Now with a 10-Year Limited Warranty.



The slit lamp is the engine that keeps your practice in motion. And the hands-down industry leader for over 60 years, Haag-Streit, outshines the competition with an LED illumination system that results in our sharpest, brightest optics ever. With a level of diagnostic detail this advanced, the road ahead becomes clearer than ever.

Haag-Streit slit lamps now come with a 10-Year Limited Warranty, which provides you with the peace of mind you need for the piece of equipment your practice depends on most.

Visit us at **ASCRS Booth #1845** or learn more at HSdriven.com.

800.787.5426
haag-streit-usa.com

© 2019 Haag-Streit USA. All Rights Reserved.

DRIVEN TO EXCELLENCE



I'd probably try it.)

In terms of dosages, most of the time I use a CAI or alpha agonist twice a day, though I will occasionally prescribe them three times daily. In some cases I'll use Diamox pills (250 mg, b.i.d.). I'll rarely prescribe Diamox 500 mg, because some patients find it hard to tolerate, depending on their body weight and overall physical condition. If the patients fail medical management, or can't tolerate it, we'll move on to surgery.

Surgery

In some cases, modifying the drug regimen won't be enough, and the patient will require surgery.

In cases that need surgery for their glaucoma, I prefer to have the eye as quiet as possible. In some cases, however, I don't have the luxury of time and have to perform immediate surgery. Depending on the severity of the disease, I start the patient on p.o. steroid preoperatively, administer IV steroids during the procedure and then prescribe a Medrol dose pack p.o. for a week postoperatively. If the preop inflammation is severe, and I had to operate in the setting of this severe inflammation, I'll keep the patient on the p.o. prednisone for longer than a week, and taper it slowly. In some less-severe cases, though, I'll forgo the preoperative steroid regimen and just administer the intraoperative IV steroids and the p.o. postoperative steroids. The duration of the steroid regimen is based on the degree of inflammation.

The other consideration is which surgery to choose for these patients. If there's inflammation in the eye, a trabeculectomy will most likely fail, so your first line of surgical treatment will be a tube implant.¹ One study showed that a trabeculectomy can work in some cases, but only if you have zero tolerance for cell and flare in the anterior chamber in the uveitic

patient. This is difficult to achieve, however, especially if you've just operated; for the trabeculectomy to work, the eye has to be very stable and without inflammation for a long time.

Since glaucoma implants are usually the procedure of choice in these patients, I prefer using an Ahmed valve because of the risk of hypotony early on when there's inflammation present. There's also a risk of later hypotony as well. I've operated on a few patients in whom I first did a glaucoma tube and then a trabeculectomy years later after the inflammation resolved, and there was no evidence of recurrence for a few years.

Some surgeons will do what is known as an "orphan" trabeculectomy in addition to a non-valved Baerveldt glaucoma implant. It's called "orphan" because the surgeon performs the trabeculectomy with the knowledge that it will most likely fail after a few weeks, but by that point the tube will have started working. I don't like this approach, though; I feel that there is distinct "real estate" in the eye and, for the glaucoma patient, every millimeter is important, since you might need to use it later for a future glaucoma procedure. Using up this real estate in order to perform a procedure that I expect will fail doesn't seem like a good use of it.

In some cases of mild uveitis and glaucoma I've had success using the Trabectome instead of a tube. Other, newer minimally-invasive glaucoma surgeries might be effective in uveitic glaucoma too, but I've only had experience with the Trabectome in such patients.

I've also worked with a uveitis specialist in implanting the Retisert sustained-release steroid implant. This is implanted during pars plana vitrectomy, cataract extraction and glaucoma implantation. The Retisert can work for two to three years in patients who aren't compliant with drops. One of the limitations, though is the price.

According to the [drugs.com](https://www.drugs.com/pricing) pricing guide, a single Retisert costs \$19,871.² Other sustained-release anti-inflammatory options are Ozurdex (Allergan) and Yutiq (EyePoint).

A lot of these patients will also need cataract surgery because they've been on chronic steroids for a while. In many of these cases, I'll do the glaucoma surgery and the cataract procedure simultaneously. If there isn't evidence of cataract, though, I might do the glaucoma procedure alone and come back later if a cataract develops. The one consideration is that you may have to adjust your wound based on the position of the tube.

The cataract procedure itself is a little more complex, since there may be synechiae you have to break or membranes you have to cut. You might need to employ a pupil-expansion ring or iris hooks. (Glaucoma specialists are used to these complex cases.) My inflammation control regimen after cataract surgery in these patients is similar to that for glaucoma surgery: oral prednisone both pre- and postop, Pred Forte or Durezol every one or two hours postop, and cyclopentolate.

Managing the uveitic glaucoma patient can be challenging, and requires a team approach. The uveitis specialist has tools to help control the inflammation, which can help you better manage the glaucoma. Working together, you can help guarantee better results for the patient. **REVIEW**

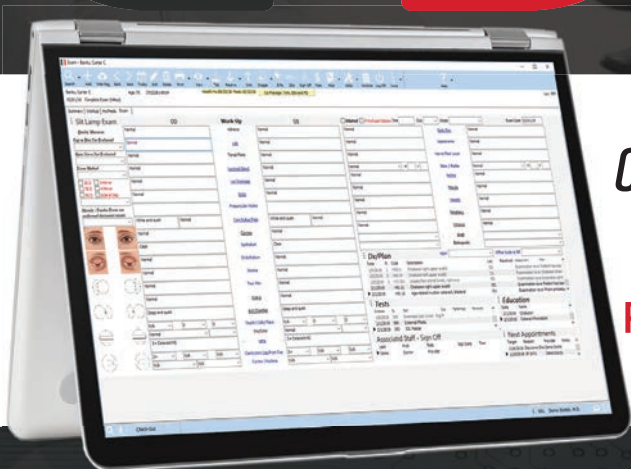Dr. Al-Aswad is an associate professor of ophthalmology at Columbia University Medical Center's Edward S. Harkness Eye Institute. She also serves as the Institute's glaucoma fellowship director and the director of the tele-ophthalmology initiative. She has no financial interest in any products mentioned.

1. Da Mata A, Burk SE, Netland PA, Baltatzis S, Christen W, Foster CS. Management of uveitic glaucoma with Ahmed glaucoma valve implantation. *Ophthalmology* 1999;106:11:2168-72.

2. Drugs.com Retisert pricing. <https://www.drugs.com/pricing-guide/retisert>. Accessed 2 April 2019.

SMART IS BETTER

AI-DRIVEN EHR & PM FOR
OPTIMAL EFFICIENCY



OPHTHALMOLOGY'S ALL-IN-1 SOLUTION

ENTERPRISE | EHR | PM | ASC | RCM | OPTICAL
PATIENT ENGAGEMENT | WORKFLOW OPTIMIZATION

Powered by artificial intelligence, Advantage SMART Practice[®] uses real-time data to drive efficiencies across your practice.

Our all-in-one system completely automates administrative tasks to maximize your time with patients and deliver better financial results for your business.

EHR & PM LEADER FOR 34 YEARS

SEE IT LIVE.

ASCRS ANNUAL MEETING. BOOTH #3013

WWW.COMPULINKADVANTAGE.COM/ONETAB | 800.456.4522



Strong Moves for Weak Zonules

Michelle Stephenson, Contributing Editor

Experts share their best tips for managing these difficult cases.

When patients with weak zonules present for cataract surgery, surgeons will need to get creative when implanting the IOL.

According to Richard Hoffman, MD, who is in practice in Eugene, Oregon, diagnosing zonular laxity is fairly straightforward. “Preoperatively, if patients have phacodonesis, a history of trauma or pseudoexfoliation, then you need to be prepared for weak zonules,” he explains. “And, if they don’t have phacodonesis, one very easy way of diagnosing zonular laxity at the beginning of the procedure is to push down on the lens to start the capsulorhexis. If you see a whole bunch of striae or folds, that usually implies that you’ve got mild to moderate zonular weakness. At that point, you have to decide whether you want to place capsule hooks or place a capsular tension ring.”

After the Diagnosis

“The first thing to consider is the severity of the weakness,” says Uday Devgan, MD, who is in practice in Los Angeles. “Am I able to just insert the lens into the capsular bag or maybe even have a sulcus lens with optic capture? Or am I going to need to suture in some sort of support for the lens or the capsule? That’s the difference

between doing a routine surgery and possibly placing a capsular tension ring, which will take 10 minutes or less, versus doing a more complicated procedure in which I’ll have to suture in some type of support for the capsule or suture the lens in place, which will take 20 to 30 minutes.”

Dr. Hoffman agrees. “Everything depends on how loose the zonules are,” he says. “If the lens is frankly subluxed and moving around in the eye, I will usually just coordinate that with the retinal surgeon and have him do a pars plana vitrectomy and lensectomy. Then, I’ll scleral-fixate a posterior chamber lens. The latest technique I’m using is the Yamane intrascleral haptic fixation technique. However, it’s rare to have a patient whose whole lens is jiggling around. Some people try to rescue the lens with the capsular bag, do a rhexis, support it with hooks, and then sew in capsular prosthetic devices. It’s just a lot of work, and I find it’s a lot easier just to remove a very loose crystalline lens and scleral-fixate a posterior chamber lens in extreme cases.”

In most cases, patients just have a small amount of zonular laxity or weakness. “Most of the time, we can get by with just being very gentle during the procedure. If there’s a lot of capsular laxity but the lens isn’t frankly moving, then I’ll use capsule hooks, sometimes

new!

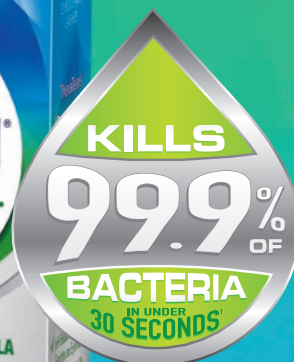Gentle on
Eyelids.

Tough on
Bacteria.



RECOMMEND
THE ONLY FDA-ACCEPTED
ANTIMICROBIAL
EYELID CLEANSER

- ✓ Advanced Hypochlorous Acid (0.01%) formula for superior cleansing
- ✓ Cleanses away bacteria and irritants
- ✓ pH balanced formula is gentle on eyelids
- ✓ Effective daily eyelid and eyelash hygiene
- ✓ No rinse - soap free



Coming soon without a prescription at Walgreens, CVS Pharmacy®, Amazon, Rite Aid, and other retailers nationwide

Visit theratears.com to learn more



Reference: 1. Results from an in vitro laboratory study. TheraTears® SteriLid® Antimicrobial Eyelid Cleanser and Facial Wash showed efficacy in reduction of colony forming units for eight common eyelid organisms. Data was captured at 30 and 60 seconds.

M18-069-00

in combination with a capsular tension ring. However, lately, I've been moving towards just using the capsule hooks and then putting the capsular tension ring in after I've removed most of the cataract," Dr. Hoffman explains.

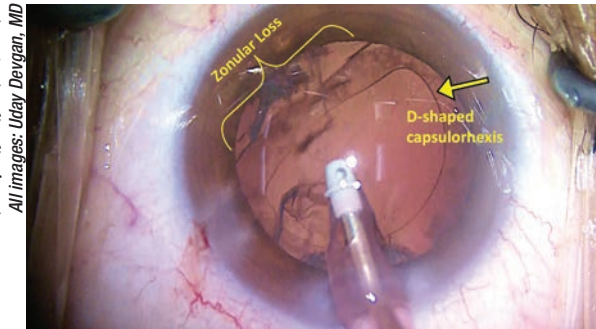
What's the Cause?

After determining the severity of the weakness, surgeons will need to ascertain whether the weakness is due to a progressive disease or whether it's due to trauma, so they'll know whether the zonules will continue to deteriorate.

"There's a difference between being hit in the eye with a car air bag or a left hook, versus a progressive disease, such as pseudoexfoliation or Marfan syndrome," Dr. Devgan says. "With trauma, what you see today is what you will see over time. With progressive disease, the zonules will be worse in the future, and you'll need to plan for that."

He adds that, in patients with weak zonules due to trauma, surgeons can typically support the weak area with a capsular tension ring during surgery. "However, if the weakness is due to a progressive disease, you may do a capsular tension ring, and if there is really severe zonular loss, you may have to plan on sewing in a lens after removing the cataract," he says. "Another option would be to put in an anterior chamber lens or plan some other alternative placement of the lens."

According to Alan Crandall, MD, from the Moran Eye Center at the University of Utah, if the laxity was caused by trauma and is less than four to five clock hours, a capsular tension ring by itself will usually stabilize the lens. "But then, there are the progressive phenomena, such as pseudoexfoliation," he notes. "These patients' pupils don't dilate well. You'll also need to figure out how much zonulopathy currently exists.



A capsular tension ring is valuable in cases of weakening due to trauma.

"One of the biggest clues is wrinkling in the anterior capsule as you start the rhexis," Dr. Crandall continues. "If a patient has pseudoexfoliation, we don't want to stress the zonules during surgery, so we make sure that we have a good hydrodissection, a 5.5-mm rhexis, and use pre-chop or some form of zonular-friendly debulking and cataract removal system. The miLoop (Carl Zeiss Meditec), for example, is good to use because the energy comes all the way up. The best technique depends on the hardness of the cataract. In pseudoexfoliation, with any zonular instability, I'm always going to put in a capsular tension ring. Additionally, you may need to use a capsular tension segment, such as a Cionni modified segment (FCI Ophthalmics), to suture."

If the patient has zonular weakness due to trauma, Dr. Crandall recommends tearing toward the defect when performing the rhexis. "You want to use the good zonules for counter-traction. If they don't have any stability, as in loose pseudoexfoliation, surgeons should start the rhexis and then put in an iris hook, a capsule hook or Griesshaber hooks (Alcon) in order to use them as counter-traction to continue the rhexis," he says. "Once the cataract procedure has been performed, you will need to decide whether to place a Cionni segment, a capsular tension segment or two capsular tension segments."

Suturing/Gluing

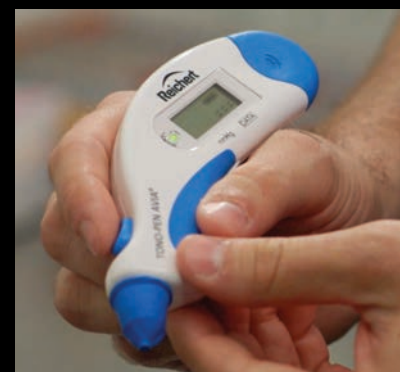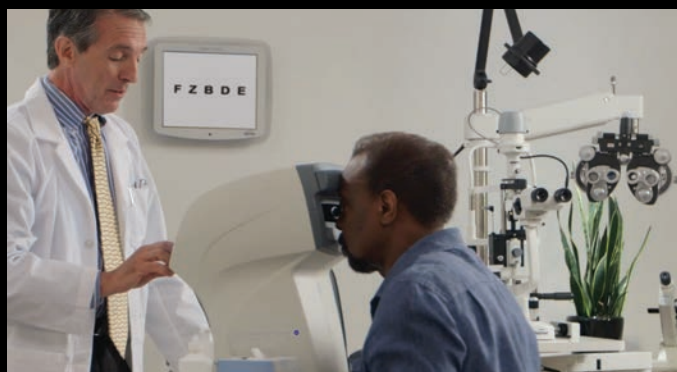
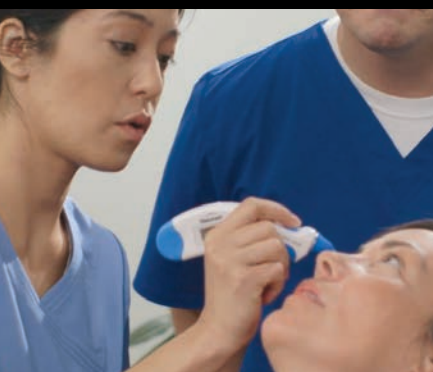If the lens needs to be secured in the eye, there are a few options, and surgeons will need to determine which is best for their patient. "If there's absolutely no capsular support, and the capsule is just shot, then we will sew the lens or attach it to the sclera," Dr. Devgan explains. "It can be sewn to the sclera using various suture techniques, or it can be glued to the sclera. Additionally, there's the Yamane technique that fixes the haptics of the lens to the sclera. These options are all scleral-based. If there is some support, then maybe sewing it to the iris would be helpful, as well."

A new technique was recently described that uses 8-0 polypropylene sutures for four-point scleral fixation.¹ Surgeons first mark four sclerotomy sites 2.5 mm from the limbus, and two scleral grooves are created in between. Two sets of polypropylene sutures are then passed through the IOL haptics, and the posterior chamber IOL is inserted behind the iris. The sutures are then pulled *ab interno* and tightened for optimal IOL centration. The sutures and the exposed knots are embedded in the scleral groove and are sealed with fibrin glue. This technique was performed uneventfully in nine cases, and the posterior chamber IOL remained stable for 10 months with no signs of subluxation, dislocation, tilt or suture-related complications, such as erosion or infection.

Additionally, the Yamane technique for transconjunctival intrascleral fixation of an IOL was recently prospectively studied in 100 eyes of 97 consecutive patients with aphakia, dislocated IOL or a subluxated crystalline lens, who underwent posterior chamber sutureless implantation of an IOL.² This technique consists of making two angled incisions parallel to the limbus using 30-gauge thin-wall



Passionate about glaucoma care?



FROM CORNEAL HYSTERESIS TO IOP, SO ARE WE.

Only **Ocular Response Analyzer® G3** measures **Corneal Hysteresis** and **Corneal Compensated IOP (IOPcc)** using patented technology to assess the unique corneal biomechanical properties of your patient. Corneal Hysteresis has shown to be an independent risk factor and more predictive of glaucoma development and progression than CCT or IOP¹⁻³. Using biomechanics, IOPcc is less influenced by corneal properties than Goldmann applanation tonometry⁴.

Only **Tono-Pen AVIA®** continues to advance handheld tonometry with the all-new **Quick-Tap™** measurement mode. The same ready-to-use, calibration-free, and accurate operation, now with more confidence in fewer measurements. Trusted by clinicians for over 30 years. We share your passion for improving glaucoma care.

VISIT US AT ASCRS #907 OR REICHERT.COM/GLAUCOMACARE



AMETEK® © 2019 AMETEK, Inc. & Reichert, Inc. (04-2019) - Ocular Response Analyzer and Tono-Pen are registered trademarks of Reichert, Inc. - Designed & assembled in USA

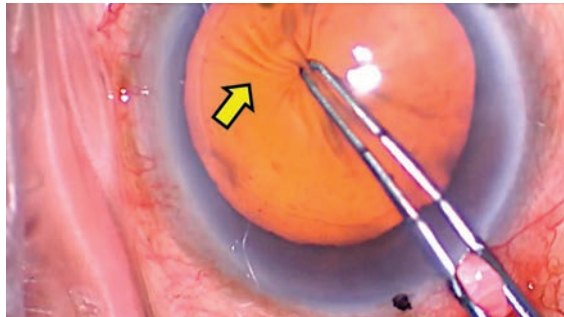
References: 1. Medeiros FA, Meira-Freitas D, Lisboa R, Kuang TM, Zangwill LM, Weinreb RN. Corneal hysteresis as a risk factor for glaucoma progression: a prospective longitudinal study. *Ophthalmology*. 2013 Aug;120(8):1533-40. 2. De Moraes CV, Hill V, Tello C, Liebmann JM, Ritch R. Lower corneal hysteresis is associated with more rapid glaucomatous visual field progression. *J Glaucoma*. 2012 Apr-May;21(4):209-13. 3. Susanna CN, Dimiz-Filho A, Daga FB, Susanna BN, Zhu F, Ogata NG, Medeiros FA. Am J Ophthalmol. A Prospective Longitudinal Study to Investigate Corneal Hysteresis as a Risk Factor for Predicting Development of Glaucoma. 2018 Mar;187:148-152. doi: 10.1016/j.ajo.2017.12.018. 4. Felipe A, Medeiros, MD and Robert N. Weinreb, MD. Evaluation of the Influence of Corneal Biomechanical Properties on Intraocular Pressure Measurements Using the Ocular Response Analyzer. *J Glaucoma* 2006;15:364-370. CPT is registered trademark of the American Medical Association.

needles. The haptics of the IOL were externalized with the needles and were cauterized to make a flange of the haptics. The flange was then pushed back and fixed into the scleral tunnels. The IOLs were fixed with exact centration and axial stability.

Preoperatively, the mean best-corrected visual acuity was 0.25 logMAR units (somewhat worse than 20/32), which significantly improved postoperatively to 0.11 (around 20/25) at six months, 0.09 (a little better than 20/25) at 12 months, 0.12 at 24 months and 0.04 (nearly 20/20) at 36 months. Mean corneal endothelial cell density decreased from 2,341 cells/mm² preoperatively to 2,313 cells/mm², 2,240 cells/mm², 2,189 cells/mm² and 2,244 cells/mm² postoperatively at six, 12, 24 and 36 months, respectively. Mean IOL tilt was 3.4 ± 2.5 degrees.

Postoperative complications included iris capture by the IOL in eight eyes (8 percent), vitreous hemorrhage in five eyes (5 percent) and cystoid macular edema in one eye (1 percent). No patients experienced postoperative retinal detachment, endophthalmitis or intraocular lens dislocation.

Another option is to glue the IOL in place. A recent study found scleral-glued surgery to be a good option for fixating an IOL in eyes with pseudoexfoliation and poor zonular integrity or absent zonular support.³ The study included 28 eyes, and the indications for scleral-glued IOL fixation included late endocapsular IOL dislocation (75 percent), exchange for iris-fixated IOL due to complications (14 percent), subluxed crystalline lens (7 percent) and aphakia after complicated cataract surgery (4 percent). More than half of eyes (54 percent) had pre-existing glaucoma at the time of scleral-glued surgery. Eight eyes (29 percent) experienced postoperative



A wrinkled anterior capsule (arrow) is a sign of weak zonules.

ocular hypertension that required escalated medical management. The investigators recommend paying special attention to intraocular pressure control following surgery, because it can be less predictable in eyes with pseudoexfoliation, with or without pre-existing glaucoma. At the final follow-up, corrected distance visual acuity was equivalent to or better than it was preoperatively in 89 percent of eyes.

Decentered IOLs

Some patients, especially pseudoexfoliation patients, experience weak zonules after cataract surgery, which can cause their lens to decenter. “This is common, and I think we’re going to see more cases like this,” Dr. Hoffman says. “When I lectured about this 10 years ago, I recommended that people place capsular tension rings in pseudoexfoliation patients, even when there doesn’t appear to be any zonular weakness, because a certain percentage of these patients end up having subluxed lenses that are in the capsular bag seven or eight years down the road. The zonules have just degraded with time.”

In these cases, Dr. Hoffman says he usually fixates the haptics to the sclera using a lasso technique. “This is a lot easier if the haptic is in the meridian of the subluxation, and it’s even easier if the patient has a capsular tension ring, because you don’t have to

worry about where the haptics are,” he says. “You just fixate the capsular tension ring to the sclera using either 9-0 Prolene or CV8 Gore-Tex, which usually works. These patients tend to be elderly, and it’s probably going to take 15 to 20 years or more for 9-0 Prolene to degrade. In a younger patient, Gore-Tex makes a lot of sense.”

Dr. Devgan adds that the treatment depends on the type of lens and how decentered it is. “If it’s a three-piece lens that you can reach from the anterior segment, then you can just keep that lens in the eye and sew it in place,” he says. “Usually, sewing it to the back of the iris or to the sclera is sufficient. If it’s a single-piece lens, it’s a little tougher to suture in place, but it still can be done. If the lens is very far dislocated into the eye, you may just have to take it out via a pars plana approach. Depending on your comfort level, you may want to ask for the assistance of your vitreoretinal colleagues. Remember that when your patient is sitting at the slit lamp, the lens in the eye is perpendicular to the floor. However, when you lie the patient on the operating room table, if the lens isn’t well-supported, the lens can fall way back into the vitreous, which makes the situation much tougher,” he says. **REVIEW**

Dr. Devgan owns and runs cataractcoach.com. Dr. Crandall is a consultant for Iantech, which was recently purchased by Carl Zeiss Meditec. Dr. Hoffman has no financial interests related to the products/companies mentioned in this article.

1. John T, Tighe S, Hashem O, Sheha H. New use of 8-0 polypropylene suture for four-point scleral fixation of secondary intraocular lenses. *J Cataract Refract Surg*. 2018;44:12:1421.
2. Yamane S, Sato S, Maruyama-Inoue M, Kadonosono K. Flanged intrascleral intraocular lens fixation with double-needle technique. *Ophthalmology*. 2017;124:8:1136-1142.
3. Ragam A, Ritterband DC, Waisbren ED, Mathew-Padiyedathu J, Kang J, Seedor JA. Clinical outcomes and intraocular pressure control after scleral-glued intraocular lens insertion in eyes with pseudoexfoliation. *J Glaucoma*. 2018;27:2:164-169.



NuLids[®] – transformational dry eye therapy



Transforms your patients' lives

Finally... A doctor directed at-home treatment for dry eye disease that is safe, effective and easy to use.

A multi-center study¹ showed:

- 50% decrease in dry eye symptoms
- 65% improvement in TBUT
- 80% increase in meibomian glands yielding liquid secretions.

¹ Schanzlin, Olkowski, Coble, Gross. NuLids II Study, April 2018



Transforms your practice

The NuLids System helps reduce patient out-of-pocket expenses while creating an additional revenue stream for the practice – all without impacting overhead costs or disrupting other in-office treatments.

A multi-center study¹ showed 95% were satisfied or very satisfied with the treatment.

For more information visit www.NuSightMedical.com or call us at 833-468-5437



NuLids[®]

Doctor directed, at-home dry eye relief



Statins' Value vs. Diabetic Retinopathy

In a recent retrospective, population-based cohort study, researchers investigated the association between statin use and prevention of vision-threatening diabetic retinopathy in patients with type 2 diabetes and dyslipidemia.

Studies have suggested that statins may reduce the risk of developing diabetic retinopathy, so the researchers wanted to see if there was, indeed, an effect from the drugs.

The study collected data between January 1, 1998, and December 31, 2013, from 37,894 Taiwanese patients (half in the statin group and half in the nonstatin group) with type 2 diabetes. There was a mean follow-up of 7.6 years for the statin group and 7.3 years for the nonstatin group.

Ultimately, 2,004 patients in the statin group (10.6 percent) and 2,269 patients in the nonstatin group (12 percent) developed diabetic retinopathy. Researchers say there was a statistically significantly lower rate of diabetic retinopathy (NPDR, PDR, vitreous hemorrhage, tractional retinal detachment and macular edema) in the statin group. Not only did those taking statins have a decreased risk of developing DR, but also a lower need for treatments. Even when treatment was needed, a smaller number of interventions was required than in patients not taking statins.

Researchers say that the effectiveness of statins as the primary means of

preventing retinopathy in patients with diabetes remains uncertain. However, findings suggest that the therapy could slow the progression of vision-threatening DR.

JAMA Ophthalmology 2019;137:4:363-371.
Kang EY, Chen TH, Garg, S, et al.

Drug Prices in Australia vs. the United States

Researchers from multiple centers say that prices for certain drugs decreased at a greater rate in Australia than in the States.

The retrospective price-comparison study looked at the prices paid by government organizations in the United States (Medicare) and Australia (Pharmaceuticals and Benefits Scheme) for the drugs adalimumab (Humira; AbbVie), ranibizumab (Lucentis; Genentech) and aflibercept (Eylea; Regeneron). They collected data on the initial, final and change in medication price annually from 2013 to 2017 in inflation-adjusted, 2017 U.S. dollars. They took steps to ensure “an accurate comparison of prices between changes in inflation and currency exchange rates.” The study reported the following:

- The mean prices (U.S.-dollar prices unadjusted for inflation) in 2013 and 2017 in the U.S. were \$1,114 (\$1,053) and \$1,818 (\$1,818), respectively, for adalimumab; \$2,102 (\$1,988)

and \$1,904 (\$1,904), respectively, for ranibizumab; and \$2,074 (\$1,961) and \$1,956 (\$1,956), respectively, for aflibercept.

- The mean (Australian dollar prices unadjusted for inflation) 2013 and 2017 prices in Australia were \$1,854 (A \$1,797) and \$1,206 (A \$1,574), respectively, for adalimumab; \$2,157 (A \$2,090) and \$972 (A \$1,268), respectively, for ranibizumab; and \$2,030 (\$1,967) and \$996 (\$1,300), respectively, for aflibercept.

- The estimated annual change in price for adalimumab was +12.8 percent in the U.S. compared with -11.1 percent in Australia, a difference of 23.9 percent per year ($p < 0.001$). The annual change for ranibizumab was -2.6 percent in the U.S. compared with -18.5 percent in Australia, a difference of 15.9 percent per year ($p = 0.003$). The annual change for aflibercept was -1.5 percent in the U.S. compared with -16.9 percent in Australia, a difference of 15.4 percent ($p = 0.001$).

The researchers say the data shows that prices for the three drugs dropped significantly during the past five years in Australia compared with the United States, though the study couldn't determine why such differences exist or what actions might affect future pricing in the countries.

JAMA Ophthalmol 2019;137:4:358-362.

Parikh R, Feng PW, Tainsh L.



**KENNETH A. BECKMAN,
MD, FACS**

Director of Corneal Surgery at
Comprehensive Eyecare of Central Ohio
Clinical Assistant Professor
of Ophthalmology
at The Ohio State University
Columbus, Ohio

Dr Beckman was compensated by Alcon
for his participation in this advertorial.

SYSTANE® Complete Designed to Deliver Better Coverage*

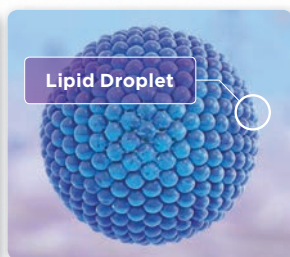
Dry eye is one of the most frequent causes of patient visits to eye care practitioners, affecting an estimated 30 million people in the US.¹ As many as 1 in 3 ophthalmic patients report experiencing at least one symptom of dry eye.² Dry eye symptoms adversely affect vision-related quality of life and productivity.³⁻⁶

Dry eye is recognized as a condition with a multifactorial etiology that results in loss of homeostasis of the tear film.⁷⁻⁸ Determining the major etiology behind the dry eye is an essential step in its management. Published recommendations such as those from the 2017 Tear Film and Ocular Surface

instillation.¹⁷ In contrast, osmolarity changes induced by hypotonic tear substitutes are reversed in 1-2 minutes.^{17,18}

SYSTANE® Complete has a unique delivery system that helps provide better coverage versus SYSTANE® Balance.¹¹⁻¹² SYSTANE® Complete's patented formulation is comprised of nanosized droplets that have a greater surface area allowing for more lubricant particles per drop.^{13,16} This advanced lipid nanodroplet technology allows rapid delivery of the lubricant across the ocular surface resulting in better coverage* to provide fast hydration and locking in moisture for long-lasting relief.^{15,16,19}

“SYSTANE® Complete is a very versatile drop that can work in different types of dry eye and can be used as first-line or as an adjuvant treatment”



Smaller droplet size

Greater total surface area

Better coverage

Total surface area = 6 cm²



1 cm cube

Total surface area = 60 cm²



all 1 mm cubes

Total surface area = 60,000,000 cm²



all 1 nm cubes

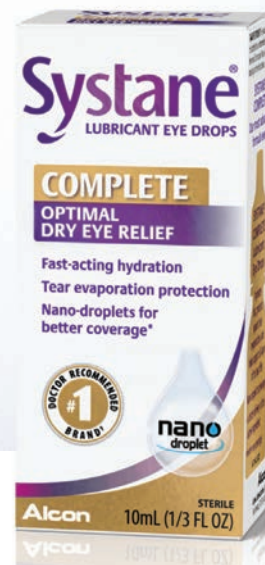Illustration depicting the increased surface area of nano-sized materials.²⁰

Society Dry Eye Workshop (DEWS) II and the Cornea, External Disease, and Refractive Society (CEDARS) describe a systematic approach that includes a detailed patient history, clinical assessments and diagnostic measures.⁸⁻⁹ This diagnostic process can be further complicated by an overlap in the etiology of dry eye that can be present in many cases.⁸⁻¹⁰ If only one of the underlying mechanisms of dry eye is addressed, patients may be unable to derive meaningful relief. A simple way to help relieve patient symptoms is to recommend an artificial tear designed for every major type of dry eye, such as SYSTANE® Complete.^{7,11-15}

Dry eye management is focused on restoring tear film homeostasis. SYSTANE® Complete contains HP-guar, a non-ionic polymer that becomes a gel upon instillation and is known to enhance the effect of the active demulcents.¹⁶ In a prospective, open-label trial, administration of an HP-guar containing lubricant four times daily for 3 weeks resulted in a significant reduction in tear osmolarity 15 minutes after

Additionally, SYSTANE® Complete is designed to minimize blur upon instillation due to its nanodroplet formulation.^{10,13} Patients often try different products seeking the formulation that works best for them. My patients describe SYSTANE® Complete as easy to use and providing them long-lasting relief,^{15,16,19} thereby satisfying their needs.


SYSTANE® Complete simplifies the choice for patients and practitioners because it is designed to provide symptom relief for every major type of dry eye, supports all layers of the tear film and protects against evaporation – it's one simple choice for optimal relief from dry eye symptoms.^{7,11,13-16,19,21}



*Compared to SYSTANE® Balance Lubricant Eye Drops.

References 1. TFOS. What is DEWS II. Available at http://www.tearfilm.org/dettreports-tfos_dews_ii_report/32_30/eng/. Accessed May 16, 2018. 2. Martinez JD, Galor A, Ramos-Betancourt N, et al. Frequency and risk factors associated with dry eye in patients attending a tertiary care ophthalmology center in Mexico City. *Clin Ophthalmol*. 2016;10:1335-1342. 3. Mertzani P, Abetz L, Rajagopalan K, et al. The relative burden of dry eye in patients' lives: comparisons to a U.S. normative sample. *Invest Ophthalmol Vis Sci*. 2005;46:46-50. 4. Mijanovic B, Dana R, Sullivan DA, Schaumberg DA. Impact of dry eye syndrome on vision-related quality of life. *Am J Ophthalmol*. 2007;143:409-415. 5. Barabino S, Labetoulle M, Rolando M, Messmer EM. Understanding symptoms and quality of life in patients with dry eye syndrome. *Ocular Surf*. 2016;14:365-376. 6. American Academy of Ophthalmology. Cornea/External Disease Panel. Preferred practice pattern guidelines. Dry eye syndrome. San Francisco, CA: American Academy of Ophthalmology; 2013. 7. Craig JP, Nichols KK, Akpek EK, et al. TFOS DEWS II Definition and Classification Report. *Ocul Surf*. 2017;15:276-283. 8. Milner MS, Beckman KA, Luchs JJ, et al. Dysfunctional Tear Syndrome: Dry Eye Disease and Associated Tear Film Disorders - New Strategies for Diagnosis and Treatment. *Curr Opin Ophthalmol*. 2017; Jan;27 Suppl 1:3-47. 9. Wolffsohn JS, Arita R, Chalmers R, et al. TFOS DEWS II Diagnostic Methodology Report. *Ocul Surf*. 2017; 15:575-628. 10. Korb D, Blackie C, Meadows D, Christensen M, Tudor M. Evaluation of extended tear stability by two emulsion based artificial tears. Poster presented at the 6th International Conference of the Tear Film and Ocular Surface: Basic Science and Clinical Relevance, September 22-25, 2010, Florence, IT. 12. Davitt WF, Bloomenstein M, Christensen M, Martin AE. Efficacy in patients with dry eye after treatment with a new lubricant eye drop formulation. *J Ocul Pharmacol Ther*. 2010;26:347-353. 13. Ketelson H, Rangarajan R. Pre-clinical evaluation of a novel phospholipid nanoemulsion based lubricant eye drops. *Invest Ophthalmol Vis Sci*. 2017;58:3929. 14. Lane S, Paugh J, et al. An Evaluation of the in vivo Retention Time of a Novel Artificial Tear as Compared to a Placebo Control. *Invest Ophthalmol Vis Sci*. 2009;50:4679. 15. Benelli U. SYSTANE® lubricant eye drops in the management of ocular dryness. *Clin Ophthalmol*. 2011;5:783-790. 16. Data on file. Alcon; 2017. 17. Ng A, Keech A, Jones L. Tear osmolarity changes after use of hydroxypropyl-guar-based lubricating eye drops. *Clin Ophthalmol*. 2018;12:695-700. 18. Baudouin C, Aragone P, Messmer EM, et al. Role of hyperosmolarity in the pathogenesis and management of dry eye disease: proceedings of the OCEAN group meeting. *Ocul Surf*. 2013;11:246-258. 19. Data on file. Alcon. 20. United States National Nanotechnology Initiative. <https://www.nano.gov/nanotech-101/special>. Accessed April 5, 2018. 21. Ogundele A, Ketelson H, et al. Preclinical evaluation of a novel hydroxypropyl-guar phospholipid nanoemulsion lubricant eye drop for dry eye disease. Poster presented at: The 36th World Ophthalmology Congress (WOC), June 16-19, 2018; Barcelona, Spain.





Managing Glaucoma With OCT Angiography

This technology is showing promise as a clinical tool for diagnosing and monitoring glaucoma patients.

David Huang, MD, PhD, Liang Liu, MD, Yali Jia, PhD, Portland, Oregon

When it comes to managing glaucoma, we have plenty of technologies to help us. Nevertheless, new options are always welcome—especially if they increase our ability to detect and monitor the disease, while making clinic visits a little less burdensome for patients.

I believe optical coherence tomographic angiography is exactly that kind of technology. OCTA makes it easy to monitor blood flow within the retina, giving us a new way to evaluate the health of the ganglion cells that can be devastated by the disease.

Blood Flow and Glaucoma

The idea of evaluating glaucomatous damage by measuring blood flow is hardly new. Ophthalmologists who have been in the field for many years point out that the correlation between blood flow and glaucomatous damage was clear decades ago. Using fluorescein angiography, they showed that glaucomatous damage was accompanied by reduced fluorescence, as well as delayed vascular filling. However, fluorescein angiography is invasive and only semi-quantitative,

making it impractical for the routine clinical monitoring of glaucoma. Several other imaging technologies, such as Doppler ultrasound, Doppler OCT, laser Doppler flowmetry, and laser speckle flowgraphy have also been used to show that retinal and optic nerve blood flow are reduced in glaucoma patients. However, these instruments have high measurement variability and are more suitable for detecting differences between groups of research subjects than performing diagnostic evaluation in individual patients.

OCTA is different from these previous instruments in two important ways. First, OCTA is noninvasive. Second, OCTA can measure vessel density with high repeatability and reproducibility. Since each OCTA scan takes just a few seconds, it can easily be done at every glaucoma patient visit. And because the measurements are precise, it can be used to make a diagnosis and monitor disease progression.

How Does OCTA Work?

The way OCTA detects blood ves-

sels down to the capillary level is straightforward. The OCTA software compares sequential cross-sectional OCT image frames at the same position, looking for signal fluctuations that indicate blood flow. Our group has been heavily involved in developing and testing this technology. Among other things, we've developed an algorithm called split-spectrum amplitude-decorrelation angiography—SSADA for short—that's so efficient that you just need two frames to accurately identify capillaries.¹ This efficient algorithm, along with improvements in the speed of Fourier-domain OCT, made clinical OCTA feasible.

Since OCTA senses motion, it's susceptible to artifacts produced by bulk eye motion such as microsaccades, ocular pulsation and ocular drift. Therefore high-speed, active eye tracking, image registration postprocessing and bulk motion subtraction algorithms are all needed to produce high-quality OCTA images. These technical requirements have stimulated rapid advances in commercial OCT technology on both hardware and software fronts.

enVista[®]



The design is distinctive. The outcomes are clear.

Aberration-free optic | Glistening-free performance | Predictable outcomes

Let's be clear about enVista.
enVistaOL.com • 800.338.2020

INDICATIONS: Indicated for primary implantation for the visual correction of aphakia in adult patients in whom the cataractous lens has been removed. The lens is intended for placement in the capsular bag.
WARNINGS: Careful preoperative evaluation and sound clinical judgment should be used by the surgeon to decide the risk / benefit ratio before implanting a lens in a patient. **PRECAUTIONS:** Do not resterilize this intraocular lens by any method. Do not store lenses at temperatures over 43°C (110°F). Careful preoperative evaluation and sound clinical judgment should be used by the surgeon to decide the benefit/risk ratio before implanting a lens in a patient with conditions as outlined in the enVista IOL Directions for Use. **ADVERSE EVENTS:** As with any surgical procedure, there is risk involved. Potential complications accompanying cataract or implant surgery may include, but are not limited to the following: corneal endothelial damage, infection (endophthalmitis), retinal detachment, vitritis, cystoid macular edema, corneal edema, pupillary block, cyclitic membrane, iris prolapse, hypopyon transient or persistent glaucoma, and secondary surgical intervention. **CAUTION:** Federal law restricts this device to sale by or on the order of a physician. **ATTENTION:** Reference the Directions for Use labeling for a complete listing of indications and important safety information.

®/TM are trademarks of Bausch & Lomb Incorporated or its affiliates.

© 2017 Bausch & Lomb Incorporated.

EVA.0035.USA.17

LONG TERM VISION | FOR YOUR PATIENTS | FOR YOUR PRACTICE

BAUSCH + LOMB

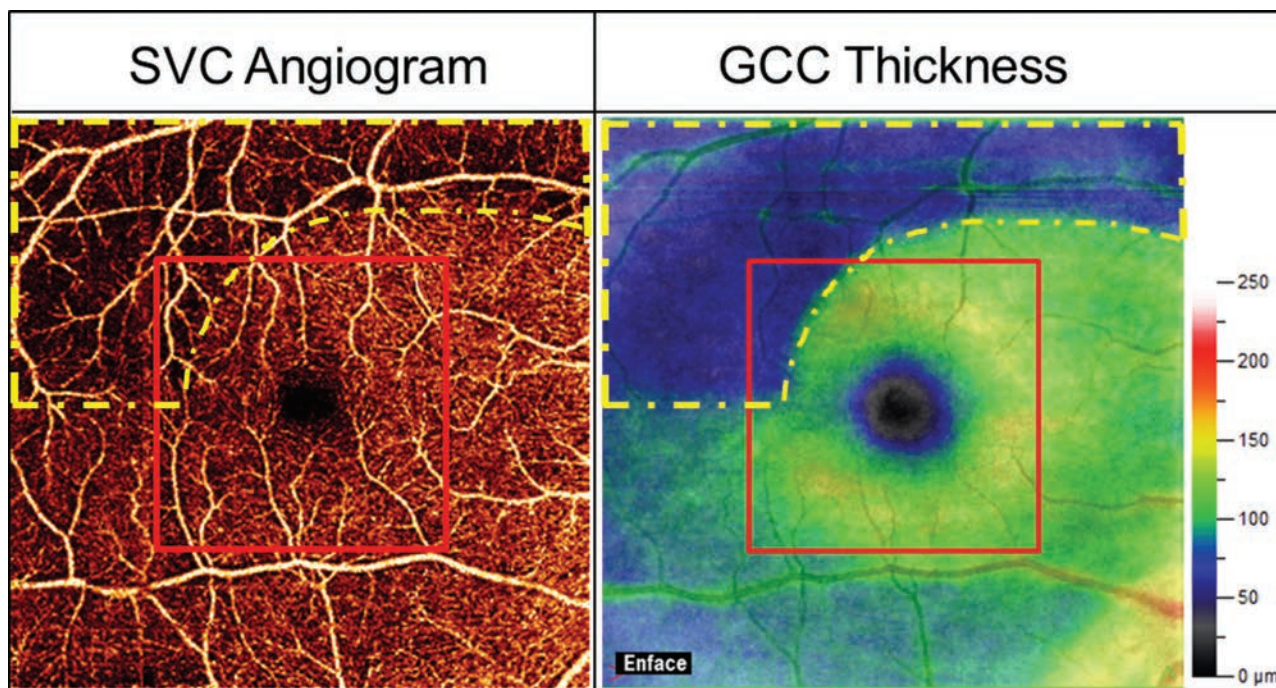


Figure 1. 6 x 6-mm superficial vascular complex (SVC) OCT angiogram (left) and 6 x 6-mm ganglion cell complex thickness map (right) of a typical glaucomatous eye. The glaucoma damage (yellow dashed outline) was mostly outside the central 3 x 3-mm area (the red outline). Thus the larger scan area is needed for early detection of the pattern of damage common in glaucoma.

Where to Look for Glaucoma

We first used OCTA to study altered blood flow in glaucoma patients in 2014.² In that study, we scanned the optic nerve head. We found that glaucoma patients have reduced capillary density and flow index at the level of superficial disc tissue and at the plane of the lamina cribrosa. The flow deficit at the lamina cribrosa was intriguing because this is potentially the site where elevated intraocular pressure could affect optic nerve perfusion. However, for routine diagnostic purposes, the optic nerve head is not an ideal image target due to shadowing of neural tissue from numerous large blood vessels and highly variable geometry of the disc rim and vessels.

So, when we turned our attention to designing the ideal diagnostic scans for glaucoma, we decided to focus on the peripapillary retina³ and macula.⁴ In both of these regions, we found that the retinal vessel

density provided excellent diagnostic accuracy. Furthermore, vessel density correlated well with visual field parameters—better than with structural OCT parameters such as the overall retinal nerve fiber layer thickness.

It's worth noting that OCTA scans must cover sufficient area to provide accurate diagnostic information. For the peripapillary region, we've found that a 4.5 x 4.5-mm scan provides the best diagnostic accuracy. For the macular region, a 6 x 6-mm scan is needed (See Figure 1). There have been studies that used small macular OCTA scans of 3 or 4 mm areas that found poor diagnostic accuracy. That's to be expected, because glaucoma affects the peripheral portions of the macula first.

Flow Rate or Vessel Density?

When we began to investigate functional imaging for glaucoma, we first focused on measuring volumetric flow rate with Doppler

OCT,⁵ then on measuring flow index with OCTA.² However, we found the reproducibility of these flow measurements to be poor. The fundamental reason may be that the velocity and volumetric rate of blood flow are affected by variations in the patient's physiologic state. For example, we've demonstrated that these measurements are affected by the oxygen concentration in inhaled gas mixture and by visual stimulation. There may also be many other factors that affect blood flow.

In contrast, we've found that the reproducibility of vessel density measurements by OCTA is excellent. Vessel density is measured on *en face* OCTA images of the appropriate anatomic slabs. A "projection" operation is used to select the maximum flow value within the slab's depth range, so that the three-dimensional OCTA data is reduced to a two-dimensional *en face* angiogram. The vessel density can be defined by the percent area occupied by vascular

OCULUS Pentacam® AXL

The All-in-One Unit!



Visit the OCULUS booth #2245
at ASCRS in San Diego

Please note: The availability of the products and features may differ in your country. Specifications and design are subject to change. Please contact your local distributor for details.

Optical biometry and built-in IOL formulas for any eye status

Use Total Corneal Refractive Power (TCRP) keratometry to account for individual total corneal astigmatism of every patient and select suitable aspheric, toric and multifocal IOL candidates more confidently. Perform swift IOL calculations using the built-in IOL Calculator, avoid manual transcription errors and optimize your personal constants.

Included: Barrett IOL formulas and customized formulas for post-corneal refractive patients

www.pentacam.com

    Follow us!

 OCULUS®

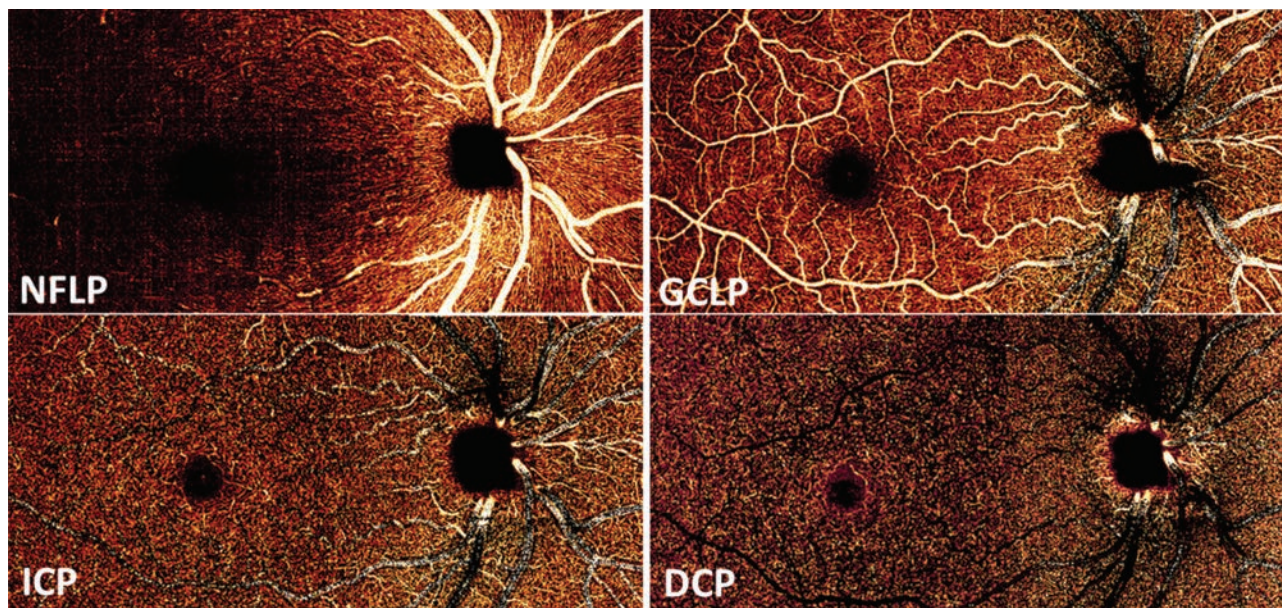


Figure 2. *En face* projection-resolved OCT angiograms of four retinal vascular plexuses in the right eye of a normal human participant. NFLP = nerve fiber layer plexus; GCLP = ganglion cell layer plexus; ICP = intermediate capillary plexus; DCP = deep capillary plexus. The NFLP and GCLP can be combined into the superficial vascular complex (SVC), which contain both large vessels and capillaries. The ICP and DCP can be combined into the deep vascular complex (DVC), which is primarily composed of capillary networks.

pixels (pixels with higher flow signal relative to the nonvascular background) in the *en face* angiogram. Large vessels can be excluded if one wishes to measure capillary density; the latter may be useful in assessing perfusion in smaller sectors, so that variations in the course of large vessels don't unduly bias the measurement.

For glaucoma assessment, we believe that percent area vessel density and capillary density are the ideal metrics for diagnosis and monitoring.

Which Plexuses are Affected?

In the earlier OCTA studies, we looked at the retinal circulation as a single slab, because blood flow in the superficial plexuses cast time-varying shadows onto deeper layers that are also detected as flow by the OCTA algorithms. Thus, flow signal in the various retinal plexuses could not be cleanly separated. This limitation was overcome when we developed a projection-resolved OCTA algorithm

that could distinguish *in-situ* flow from projected flow. With projection-resolved OCTA, it's possible to resolve up to four vascular plexuses in the retina⁶ (See Figure 2).

In the peripapillary region, glaucoma primarily affects the nerve fiber layer plexus, which perfuses the NFL. In the macula, glaucoma affects both the NFLP and the ganglion cell layer plexus, which perfuses the ganglion cell layer. Together, the NFLP and GCLP constitute the superficial vascular complex. Thus, focusing on the peripapillary NFLP and macular SVC enhances the visualization of focal glaucomatous defects and improves diagnostic accuracy. For example, we've shown that the macular SVC vessel density has better diagnostic accuracy than the all-plexus retinal vessel density.⁴

Why Use OCT Angiography?

According to the American Academy of Ophthalmology's IRIS Registry, OCT has already overtaken visual

fields as the more frequently used method for glaucoma evaluation. Structural OCT measurements of the peripapillary NFL and macular ganglion cell complex are now part of standard glaucoma management. Since OCTA measurement of peripapillary NFLP vessel density is highly correlated with NFL thickness, and macular SVC vessel density is highly correlated with GCC thickness, why do we need to invest in OCTA machines? Why not just stick with the more familiar OCT technology we already have?

The answer is that OCTA has additional value, both in the very early and late stages of glaucoma.

Two clinical studies have shown that OCTA can detect early pre-perimetric glaucoma better than structural OCT.^{7,8} Why would this be the case? I believe it's because OCTA detects both dysfunctional (sick) and lost (dead) ganglion cells, while structural OCT only detects lost ganglion cells. I speculate that in very early glaucoma, sick, dysfunctional

HEAD FOR THE SUN, THE SEA, AND THE SAVINGS.

Be sure you don't miss out on exclusive Reliance and Haag-Streit deals at ASCRS booth 1845.

Now's the time and ASCRS is the place to enjoy special deals on a wide range of industry-leading Reliance Medical and Haag-Streit products. For a preview, visit <http://promo.haag-streit-usa.com/>. But don't wait – offers are only good through June 30, 2019.

FX920 Chair + 7900 IC Stand

Price: \$21,315 with BI 900 Slit Lamp

Price: \$25,785 with BI 900 + Imaging

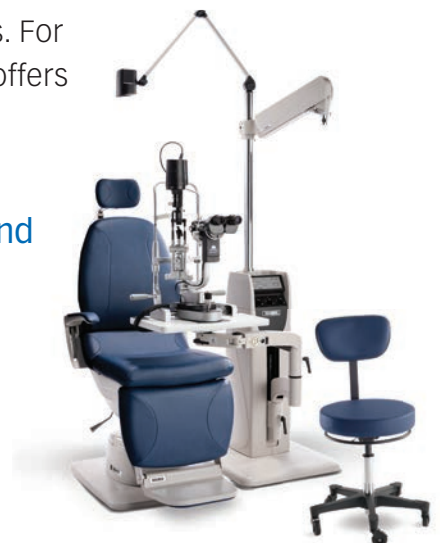
Includes a 5346 Stool and tonometer.

FX920 Chair + 7900 NC Stand

Price: \$20,935 with BI 900 Slit Lamp

Price: \$25,335 with BI 900 + Imaging

Includes a 5346 Stool and tonometer.



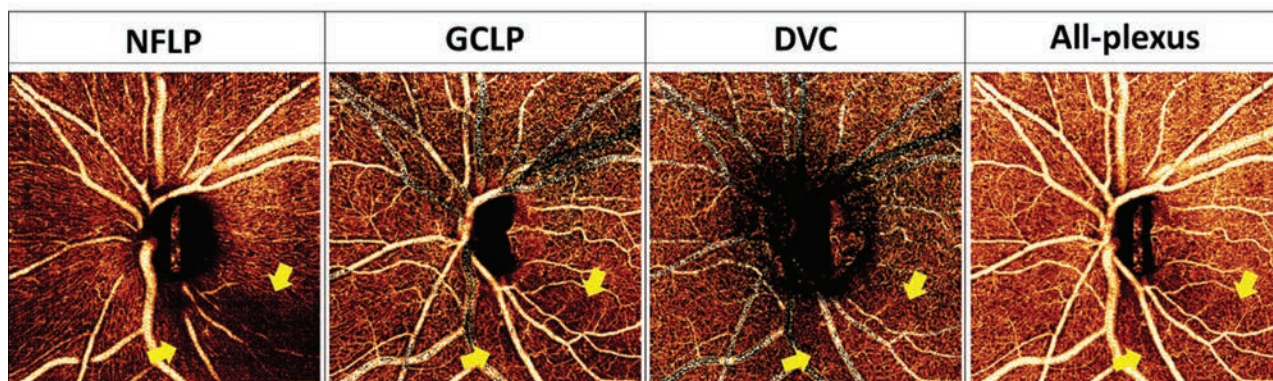




Figure 3. A glaucomatous eye imaged by the AngioVue OCT angiography system (Optovue) using the 4.5 x 4.5-mm AngioDisc scan pattern. The focal capillary dropout (arrows) can be visualized more clearly in the nerve fiber layer plexus slab than on the ganglion cell layer plexus and all-plexus retinal angiograms, while the deep vascular complex appears unaffected.

ganglion cells have lower metabolism that leads to reduced capillary density. This reduced density is detectable by OCTA, prior to the apoptosis these ganglion cells undergo and the subsequent thinning of NFL and GCC that can be detected by structural OCT. Thus, by adding OCTA to our diagnostic toolkit, we can detect glaucoma earlier and intervene in a timelier fashion.

Other studies have shown that OCTA parameters correlate better with visual field parameters than structural OCT parameters such as NFL thickness.^{3,9} This is partly due to the lessening of the “floor effect” with OCTA measurements. The floor effect describes the fact that while NFL thickness is correlated with visual field mean deviation in early glaucoma, it reaches a floor value in moderate glaucoma, and then doesn’t decrease any further in advanced glaucoma. This limits the utility of NFL thickness for monitoring glaucoma progression in the moderate and advanced stages.¹⁰ While vessel density also eventually reaches a floor, it appears to do so only in advanced glaucoma. Thus OCTA has the potential to improve the monitoring of glaucoma in the moderate to advanced stages. (A large longitudinal study is needed to demonstrate this potential.)

Simulating Visual Fields

Given that OCTA parameters correlate well with visual field data over a wider range of disease severities, it has the potential for simulating actual visual field results. This would be a boon to the many patients who cannot reliably perform visual field tests. And the fact is—your patients hate taking visual field tests.


*These metrics are now
 becoming available
 on commercial OCT
 machines as well.*


We’ve developed a method of sectorwise visual field simulation using peripapillary NFLP OCTA results (See Figure 4, p. 75). The results show good correlation in the early and moderate stages of the disease. The simulated visual field sectors could also be summed into a mean deviation parameter: NFLP_MD. NFLP_MD is highly correlated with VF_MD, but has better diagnostic accuracy and reproducibility. Thus, the simulated visual field might perform better than an actual visual field for monitoring

glaucoma progression—in addition to being more painless and convenient. (We caution that this method of visual field simulation is not FDA-cleared or commercially available, and a large longitudinal study is needed to validate its utility.)

The variability of visual field testing is not just inconvenient, it could result in unnecessary surgery, or delayed treatment and loss of vision. Statistical analyses¹¹ have shown that for a glaucomatous eye with MD worsening at a rate of -1 dB/year, testing every six months over four years is required for the trend to become statistically significant (90 percent power, $p < 0.05$), at which time the mean deviation would already be 4 dB worse. This represents a 60-percent loss of retinal sensitivity before a clinician has firm evidence to support intensifying treatment! A more reproducible, objective method for monitoring glaucoma progression could detect significant progression sooner, thus allowing more timely intervention to save vision.

OCTA Availability

The results we’ve published were achieved using capillary and vessel-density algorithms developed in

(Continued on page 75)

COMING 2019

Open your eyes to
what's on the
horizon in dry eye.

Sign up for updates at [TearCare.com](https://www.tearcare.com)

TearCare is indicated for the application of localized heat when the current medical community recommends the application of a warm compress to the eyelids. Such applications would include Meibomian Gland Dysfunction (MGD), Dry Eye, or Blepharitis.

©2018 Sight Sciences. All rights reserved. 06221.A



15

EyePoint Launches New Treatment Option

EyePoint Pharmaceuticals has released Yutiq, a new treatment option for chronic non-infectious posterior uveitis.

are avoided, as the implant contains 0.18 mg of the steroid, which it consistently releases for 36 months.



Yutiq is the first FDA-approved fluocinolone acetonide micro-insert that delivers continuous fluocinolone acetonide for up to three years. It can be administered in a physician's office through a single-dose preloaded applicator. The company says that peaks and valleys associated with typical treatment options

Additionally, for those eligible to receive financial assistance, the company has launched EyePoint Assist, a program that bolsters patient access to Yutiq. For more information, call (646) 368-8014.

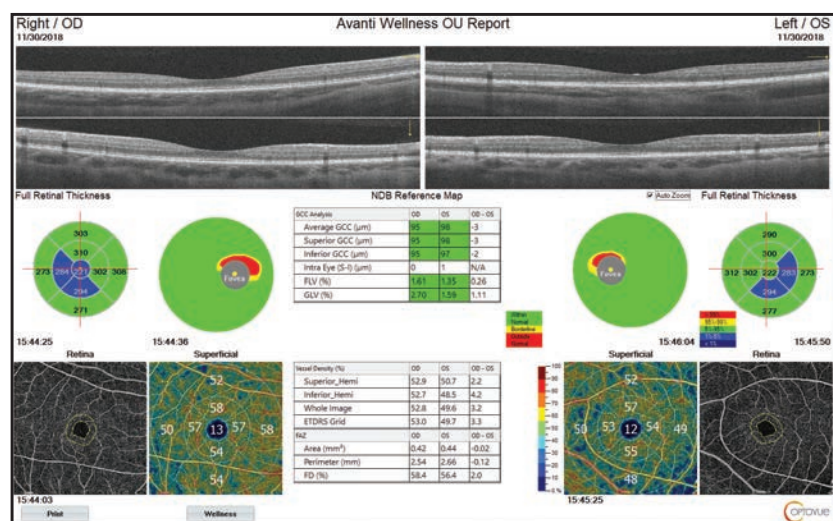
Humphrey Field Analyzer 3

Zeiss has announced its next-

generation visual field test, HFA3. The new system uses technological advancements to accelerate clinic flow while still delivering the same testing strategies and test patterns as prior generations of HFA, the company says. They add that HFA3's new features increase confidence in test results, save time and make test administration simpler. Zeiss says HFA3 provides faster initialization, works on a wider spectrum of patients than earlier models and keeps test results equal and interchangeable with data from prior generations of HFA. Visit zeiss.com/meditec/us/home.

AngioWellness Scan

Doctors can now assess and diagnose new pathologies using the AngioWellness scan, a new patient-monitoring tool in Optovue's AngioVue OCTA unit, says the company. Optovue says that the scan was designed to help eye-care professionals offer a more comprehensive assessment of diabetic patients and glaucoma suspects. The scan combines structural information about retinal and ganglion cell layer thickness with objective metrics on retinal vasculature into one report, to identify those who may need monitoring or treatment. Visit optovue.com for more information.



The AngioWellness Scan can assess and diagnose new pathologies, says Optovue.

DISCOVER LOTEMAX[®] SM: SUBMICRON STRONG

LOTEMAX[®] SM
(loteprednol etabonate
ophthalmic gel) 0.38%

Join your peers for a webinar presentation introducing the exciting new advancements of LOTEMAX[®] SM, the newest loteprednol etabonate formulation from Bausch + Lomb

REGISTER FOR ONE OF THE FOLLOWING WEBINAR SESSIONS:



MARGUERITE MCDONALD, MD

Tuesday, April 9th • 6:00 PM ET | 3:00 PM PT



MITCHELL JACKSON, MD

Wednesday, April 24th • 8:00 PM ET | 5:00 PM PT



AUDREY TALLEY ROSTOV, MD

Thursday, April 25th • 9:00 PM ET | 6:00 PM PT



RAJESH RAJPAL, MD

Wednesday, May 15th • 6:00 PM ET | 3:00 PM PT

Dates and speakers are subject to change or substitution.

THIS LIVE WEBINAR PRESENTATION WILL COVER:

- **OVERCOMING CHALLENGES** of ocular drug delivery
- **LOTEMAX[®] SM FORMULATION** features designed with the patient in mind
- **NEW SM TECHNOLOGY[™]** in LOTEMAX[®] SM
- **THE PROVEN EFFICACY AND SAFETY** of LOTEMAX[®] SM

This promotional webinar is sponsored by Bausch + Lomb. No CME/CE or food will be provided for this program. Only physicians and healthcare professionals involved in providing patient care or product recommendations may attend this educational program.

REGISTER NOW AT www.reviewofophthalmology.com/LotemaxSMWebinar2019

INDICATION

LOTEMAX[®] SM (loteprednol etabonate ophthalmic gel) 0.38% is a corticosteroid indicated for the treatment of post-operative inflammation and pain following ocular surgery.

IMPORTANT SAFETY INFORMATION

- LOTEMAX[®] SM, as with other ophthalmic corticosteroids, is contraindicated in most viral diseases of the cornea and conjunctiva including epithelial herpes simplex keratitis (dendritic keratitis), vaccinia, and varicella, and also in mycobacterial infection of the eye and fungal diseases of ocular structures.
- Prolonged use of corticosteroids may result in glaucoma with damage to the optic nerve, defects in visual acuity and fields of vision. If LOTEMAX[®] SM is used for 10 days or longer, IOP should be monitored.
- Use of corticosteroids may result in posterior subcapsular cataract formation.
- The use of steroids after cataract surgery may delay healing and increase the incidence of bleb formation. In those with diseases causing thinning of the cornea or sclera, perforations have been known to occur with the use of topical steroids. The initial prescription and renewal of the medication order should be made by a physician only after examination of the patient with the aid of magnification such as slit lamp biomicroscopy and, where appropriate, fluorescein staining.

IMPORTANT SAFETY INFORMATION (CON'T)

- Prolonged use of corticosteroids may suppress the host response and thus increase the hazard of secondary ocular infections. In acute purulent conditions, steroids may mask infection or enhance existing infections.
- Employment of a corticosteroid medication in the treatment of patients with a history of herpes simplex requires great caution. Use of ocular steroids may prolong the course and may exacerbate the severity of many viral infections of the eye (including herpes simplex).
- Fungal infections of the cornea are particularly prone to develop coincidentally with long-term local steroid application. Fungus invasion must be considered in any persistent corneal ulceration where a steroid has been used or is in use. Fungal cultures should be taken when appropriate.
- Contact lenses should not be worn when the eyes are inflamed.
- There were no treatment-emergent adverse drug reactions that occurred in more than 1% of subjects in the three times daily group compared to vehicle.

You are encouraged to report negative side effects of prescription drugs to the FDA. Visit www.fda.gov/medwatch or call 1-800-FDA-1088.

Please see Brief Summary of full Prescribing Information on adjacent page.

BAUSCH + LOMB

©/TM are trademarks of Bausch & Lomb Incorporated or its affiliates.
© 2019 Bausch & Lomb Incorporated. All rights reserved. Printed in USA. LSM.0056.USA.19

LOTEMAX[®] SM
(loteprednol etabonate
ophthalmic gel) 0.38%

BRIEF SUMMARY OF PRESCRIBING INFORMATION

This Brief Summary does not include all the information needed to use LOTEMAX[®] SM safely and effectively. See full prescribing information for LOTEMAX[®] SM.

LOTEMAX[®] SM (loteprednol etabonate ophthalmic gel) 0.38%

For topical ophthalmic use

Initial U.S. Approval: 1998

INDICATIONS AND USAGE

LOTEMAX[®] SM is a corticosteroid indicated for the treatment of post-operative inflammation and pain following ocular surgery.

DOSAGE AND ADMINISTRATION

Invert closed bottle and shake once to fill tip before instilling drops. Apply one drop of LOTEMAX[®] SM into the conjunctival sac of the affected eye three times daily beginning the day after surgery and continuing throughout the first 2 weeks of the post-operative period.

CONTRAINDICATIONS

LOTEMAX[®] SM, as with other ophthalmic corticosteroids, is contraindicated in most viral diseases of the cornea and conjunctiva including epithelial herpes simplex keratitis (dendritic keratitis), vaccinia, and varicella, in mycobacterial infection of the eye and fungal diseases of ocular structures.

WARNINGS AND PRECAUTIONS

Intraocular Pressure (IOP) Increase: Prolonged use of corticosteroids may result in glaucoma with damage to the optic nerve, defects in visual acuity and fields of vision. Steroids should be used with caution in the presence of glaucoma. If this product is used for 10 days or longer, intraocular pressure should be monitored.

Cataracts: Use of corticosteroids may result in posterior subcapsular cataract formation.

Delayed Healing: The use of steroids after cataract surgery may delay healing and increase the incidence of bleb formation. In those diseases causing thinning of the cornea or sclera, perforations have been known to occur with the use of topical steroids. The initial prescription and renewal of the medication order should be made by a physician only after examination of the patient with the aid of magnification such as slit lamp biomicroscopy and, where appropriate, fluorescein staining.

Bacterial Infections: Prolonged use of corticosteroids may suppress the host response and thus increase the hazard of secondary ocular infections. In acute purulent conditions of the eye, steroids may mask infection or enhance existing infection.

Viral infections: Employment of a corticosteroid medication in the treatment of patients with a history of herpes simplex requires great caution. Use of ocular steroids may prolong the course and may exacerbate the severity of many viral infections of the eye (including herpes simplex).

Fungal Infections: Fungal infections of the cornea are particularly prone to develop coincidentally with long-term local steroid application. Fungus invasion must be considered in any persistent corneal ulceration where a steroid has been used or is in use. Fungal cultures should be taken when appropriate.

Contact Lens Wear: Contact lenses should not be worn when the eyes are inflamed.

ADVERSE REACTIONS

Because clinical trials are conducted under widely varying conditions, adverse reaction rates observed in the clinical trials of a drug cannot be directly compared to rates in the clinical trials of another drug and may not reflect the rates observed in practice. Adverse reactions associated with ophthalmic steroids include elevated intraocular pressure, which may be associated with infrequent optic nerve damage, visual acuity and field defects, posterior subcapsular cataract formation, delayed wound healing and secondary ocular infection from pathogens including herpes simplex, and perforation of the globe where there is thinning of the cornea or sclera. There were no treatment-emergent adverse drug reactions that occurred in more than 1% of subjects in the three times daily group compared to vehicle.

USE IN SPECIAL POPULATIONS

Pregnancy: Risk Summary: There are no adequate and well controlled studies with loteprednol etabonate in pregnant women. Loteprednol etabonate produced teratogenicity at clinically relevant doses in the rabbit and rat when administered orally during pregnancy. Loteprednol etabonate

produced malformations when administered orally to pregnant rabbits at doses 4.2 times the recommended human ophthalmic dose (RHOD) and to pregnant rats at doses 106 times the RHOD. In pregnant rats receiving oral doses of loteprednol etabonate during the period equivalent to the last trimester of pregnancy through lactation in humans, survival of offspring was reduced at doses 10.6 times the RHOD. Maternal toxicity was observed in rats at doses 1066 times the RHOD, and a maternal no observed adverse effect level (NOAEL) was established at 106 times the RHOD. The background risk of major birth defects and miscarriage for the indicated population is unknown. However, the background risk in the U.S. general population of major birth defects is 2 to 4%, and of miscarriage is 15 to 20%, of clinically recognized pregnancies. Data: *Animal Data.* Embryofetal studies were conducted in pregnant rabbits administered loteprednol etabonate by oral gavage on gestation days 6 to 18, to target the period of organogenesis. Loteprednol etabonate produced fetal malformations at 0.1 mg/kg (4.2 times the recommended human ophthalmic dose (RHOD) based on body surface area, assuming 100% absorption). Spina bifida (including meningocele) was observed at 0.1 mg/kg, and exencephaly and craniofacial malformations were observed at 0.4 mg/kg (17 times the RHOD). At 3 mg/kg (128 times the RHOD), loteprednol etabonate was associated with increased incidences of abnormal left common carotid artery, limb flexures, umbilical hernia, scoliosis, and delayed ossification. Abortion and embryofetal lethality (resorption) occurred at 6 mg/kg (256 times the RHOD). A NOAEL for developmental toxicity was not established in this study. The NOAEL for maternal toxicity in rabbits was 3 mg/kg/day. Embryofetal studies were conducted in pregnant rats administered loteprednol etabonate by oral gavage on gestation days 6 to 15, to target the period of organogenesis. Loteprednol etabonate produced fetal malformations, including absent innominate artery at 5 mg/kg (106 times the RHOD); and cleft palate, agnathia, cardiovascular defects, umbilical hernia, decreased fetal body weight and decreased skeletal ossification at 50 mg/kg (1066 times the RHOD). Embryofetal lethality (resorption) was observed at 100 mg/kg (2133 times the RHOD). The NOAEL for developmental toxicity in rats was 0.5 mg/kg (10.6 times the RHOD). Loteprednol etabonate was maternally toxic (reduced body weight gain) at 50 mg/kg/day. The NOAEL for maternal toxicity was 5 mg/kg. A peri-/postnatal study was conducted in rats administered loteprednol etabonate by oral gavage from gestation day 15 (start of fetal period) to postnatal day 21 (the end of lactation period). At 0.5 mg/kg (10.6 times the clinical dose), reduced survival was observed in live-born offspring. Doses \geq 5 mg/kg (106 times the RHOD) caused umbilical hernia/incomplete gastrointestinal tract. Doses \geq 50 mg/kg (1066 times the RHOD) produced maternal toxicity (reduced body weight gain, death), decreased number of live-born offspring, decreased birth weight, and delays in postnatal development. A developmental NOAEL was not established in this study. The NOAEL for maternal toxicity was 5 mg/kg.

Lactation: There are no data on the presence of loteprednol etabonate in human milk, the effects on the breastfed infant, or the effects on milk production. The developmental and health benefits of breastfeeding should be considered, along with the mother's clinical need for LOTEMAX[®] SM and any potential adverse effects on the breastfed infant from LOTEMAX[®] SM.

Pediatric Use: Safety and effectiveness of LOTEMAX[®] SM in pediatric patients have not been established.

Geriatric Use: No overall differences in safety and effectiveness have been observed between elderly and younger patients.

NONCLINICAL TOXICOLOGY

Carcinogenesis, Mutagenesis, Impairment of Fertility: Long-term animal studies have not been conducted to evaluate the carcinogenic potential of loteprednol etabonate. Loteprednol etabonate was not genotoxic *in vitro* in the Ames test, the mouse lymphoma tk assay, or in the chromosomal aberration test in human lymphocytes, or *in vivo* in the mouse micronucleus assay. Treatment of male and female rats with 25 mg/kg/day of loteprednol etabonate (533 times the RHOD based on body surface area, assuming 100% absorption) prior to and during mating caused preimplantation loss and decreased the number of live fetuses/live births. The NOAEL for fertility in rats was 5 mg/kg/day (106 times the RHOD).

LOTEMAX is a trademark of Bausch & Lomb Incorporated or its affiliates.

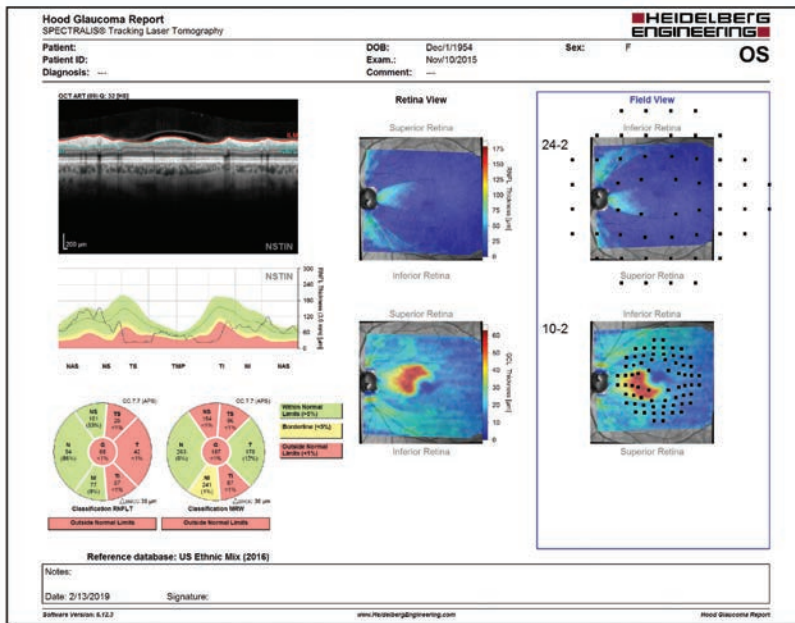
© 2019 Bausch & Lomb Incorporated

Bausch + Lomb, a division of Valeant Pharmaceuticals North America LLC
Bridgewater, NJ 08807 USA

LSM.0091.USA.19

Based on 9669600-9669700

Revised: 02/2019



but with the incorporation of a dual Hartmann-Shack aberrometer and a digital phoropter, the measurement can be taken in just one step. In three minutes, the company says that autorefractometry and subjective refinement can be done using Eye Refract. Go to visionixusa.com/ecp-products/refraction-instruments/eye-refract-automatic-refraction-system for more information.

New Antiviral Option Arrives

Doctors now have an additional option when managing herpes keratitis, as Fera Pharmaceuticals has announced that the FDA has approved its new drug Avaclyr. The product is an ophthalmic ointment containing acyclovir 3%.

The company describes Avaclyr as a herpes simplex virus nucleoside analog DNA polymerase inhibitor, indicated for the treatment of acute herpetic keratitis (dendritic ulcers) in patients with herpes simplex (HSV-1 and HSV-2) virus. The most common adverse reactions, which occurred in 2 to 10 percent of subjects, were eye pain (stinging), punctate keratitis and follicular conjunctivitis.

Fera says it's in the process of finalizing selection of a commercialization partner to provide doctors and patients access to Avaclyr. Call (516) 277-1449.

GMPE Software Update

Heidelberg Engineering has announced that the Hood Glaucoma Report will be available as a new feature in the Spectralis OCT Glaucoma Module Premium Edition (GMPE). The software can aid in diagnosis and management of glaucoma, the company says, by highlighting essential diagnostic information in an intuitive layout, allowing for quick and comprehensive assessment.

The report lets doctors visualize high resolution OCT B-scans alongside functional and structural measurements so that information can be related to 10-2 and 24-2 visual field points. OCT B-scans and the unique anatomy of each eye are emphasized in the report. Taking advantage of the Anatomic Positioning System in GMPE, which tailors scan placement and orientation to each patient's individual anatomy, Heidelberg says the report serves as an intuitive diagnostic aid. Visit heidelbergengineering.com.


New Daily Disposables

SynergEyes has launched Simplif-

Eyes 1Day, a daily disposable contact lens. The company says the lenses include a new technology called Dual Tangible Polymers, from Tangible Science. SimplifEyes 1Day uses a tangible polymer coating on lens surfaces, along with another tangible polymer in the solution, which it says discourages debris build-up while providing comfort and enhanced wettable surfaces. Through a partnership with MyContactLens Online Ordering System the lens-ordering process can potentially be simplified with direct delivery to the patient's home. Call (619) 855-4522 for more information.

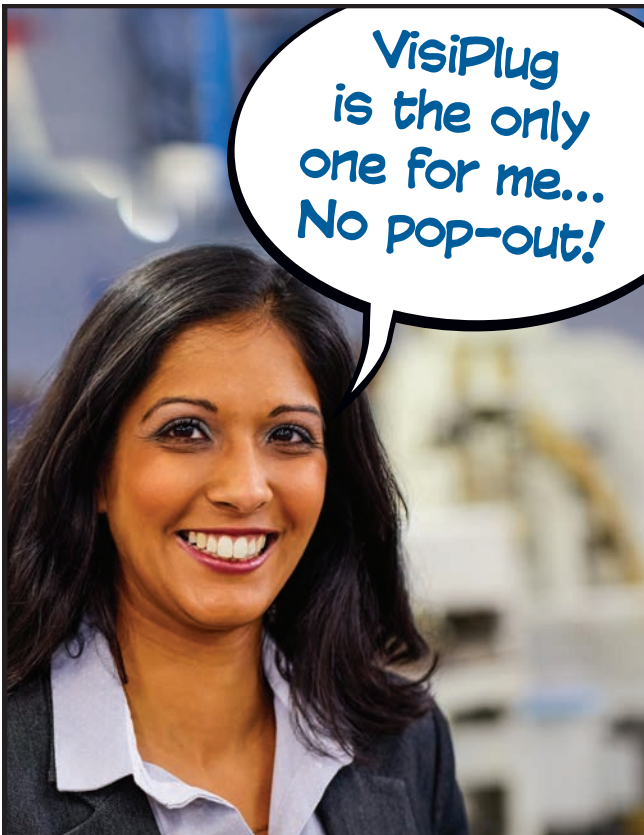Refraction System

Luneau Technology has recently announced the availability of the Visionix Eye Refract, a refraction system designed with space, speed and consistency in mind, says the company. The system provides an automated wavefront refraction measurement, which is usually a two-step process,



Moist-Heat Mask

Bruder recently announced the release of Eyeleve, a moist-heat mask that can provide a solution to patient discomfort caused by all-day contact lens use. The mask increases comfortable contact lens wear-time by up to three hours daily, the company says, and with anti-microbial threads woven into its fabric, the mask



VisiPlug is the only one for me... No pop-out!

Lacrimedics' VisiPlug is not like "other" punctum plugs. We have no reported "pop-outs" since VisiPlug's introduction in 2003... and it's distributed in over forty countries!

FDA approved for the treatment of the Dry Eye components of varying Ocular Surface Diseases (OSD), after surgery to prevent complications due to Dry Eye Disease, and to enhance the efficacy of topical medications.

VisiPlug® – a visibly better plug to treat dry eye!

Come see us at ASCRS-2019 in Booth 837

 **Lacrimedics**
(800) 367-8327
E-mail: info@lacrimedics.com
www.lacrimedics.com

1Dramatization. Not a real patient.
©2017 Lacrimedics, Inc.

REVIEW | **Product News**

decreases the level of certain bacteria and helps to address eyelid hygiene while reducing the risk of corneal infection. Delivering consistent and therapeutic moist heat, Eyeleve stimulates glands and increases oil production in an effort to stabilize the ocular surface, the company says, and this may alleviate symptoms of meibomian gland dysfunction and dry eye related to contact lens use. For more information, visit www.eyeleve.com.



VisoPocket Folding Magnifier

Eschenbach's new folding magnifier, VisoPocket, can help improve daily visual activities, says the company. Its ultrathin lens can provide 2.5X magnification, and while its lightweight design makes it discreet, the magnifier still features a large lens that provides a wide field of view, Eschenbach says.



A cutout tab on the corner of the magnifier's built-in leather case provides easy access when it comes to viewing a menu, map, bills or prescriptions, the company adds. Since VisoPocket is compact, it can be carried in a pocket or purse, and it's available in three colors, including black, brown and Bordeaux. Call (800) 487-5389 for more information. **REVIEW**

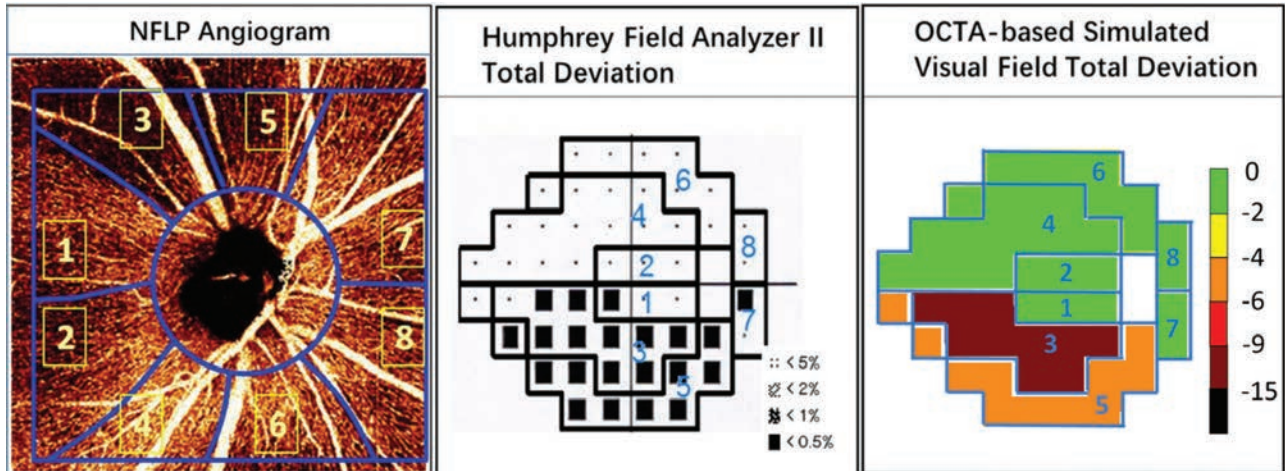


Figure 4. In an eye with moderate glaucoma, the *en face* OCT angiogram of the nerve fiber layer plexus and the visual field map were divided into eight corresponding sectors according to a modified Garway-Heath scheme. The nerve fiber layer plexus angiogram showed a superotemporal area of capillary dropout. In the OCTA-based simulated visual field total deviation map, sectors 3 and 5 had moderate to advanced defects matching those found in the actual visual field.

(Continued from page 68)

our laboratory and reading center. However, these metrics are now becoming available on commercial OCT machines as well, so it's possible to get peripapillary disc scans and macular scans using commercially available OCT angiography systems. That means that this isn't limited to the laboratory; glaucoma specialists can now use these scans to monitor their glaucoma patients.

For example, the AngioVue, which runs on the Avanti OCT system from Optovue, has a good set of metrics for quantifying the peripapillary NFLP and the macular SVC. On the AngioVue peripapillary scan, the NFLP is called the radial peripapillary capillary, or RPC. We recommend using the 4.5 x 4.5-mm high-definition OCTA scan for the disc region, and the RPC density, to evaluate glaucoma. For the AngioVue macular scans, you should use the larger, 6 x 6-mm HD scan pattern and look at what they call the superficial retinal vessel density. The current AngioVue superficial retinal slab corresponds exactly to the SVC.

Zeiss's Cirrus HD-OCT platform has the AngioPlex OCT angiography

software. You can use the AngioPlex 6-mm macular scan to evaluate glaucoma. That system can analyze superficial retinal vessel density, which they call perfusion density. To the best of my knowledge, that system currently doesn't have specific software to analyze the peripapillary NFLP around the disc, but I believe it's possible to export the images and process them for this purpose. Heidelberg has an OCT angiography module for Spectralis that was introduced at the American Academy of Ophthalmology meeting in 2018, and Topcon has developed swept-source OCT angiography software called OCTARA (pending FDA clearance) that works with its Triton OCT platform.

Thus, the OCTA options for the glaucoma specialist will expand in the near future. As the possibility of detecting and monitoring glaucoma with this technology becomes apparent, all of these systems will undoubtedly offer software updates, allowing clinicians to perform these types of analyses. **REVIEW**

Dr. Huang is the Peterson Professor of Ophthalmology and a professor of biomedical engineering at Oregon

Health and Science University in Portland. Dr. Jia is the Weeks Professor of Ophthalmology and an associate professor of biomedical engineering at OHSU. They report financial interests in Optovue. Dr. Liu is a research associate at OHSU.

1. Jia Y, Tan O, Tokayer J, et al. Split-spectrum amplitude-decorrelation angiography with optical coherence tomography. *Opt Express* 2012;20:4:4710-4725.
2. Jia Y, Wei E, Wang X, et al. Optical coherence tomography angiography of optic disc perfusion in glaucoma. *Ophthalmology* 2014;121:7:1322-1332.
3. Liu L, Jia Y, Takusagawa HL, et al. Optical coherence tomography angiography of the peripapillary retina in glaucoma. *JAMA ophthalmology* 2015;133:9:1045-1052.
4. Takusagawa HL, Liu L, Ma KN, et al. Projection-resolved optical coherence tomography angiography of macular retinal circulation in glaucoma. *Ophthalmology* 2017;124:11:1589-1599.
5. Wang Y, Bower BA, Izatt JA, Tan O, Huang D. In vivo total retinal blood flow measurement by Fourier domain Doppler optical coherence tomography. *J Biomed Opt* 2007;12:4:041215.
6. Campbell JP, Zhang M, Hwang TS, et al. Detailed vascular anatomy of the human retina by projection-resolved optical coherence tomography angiography. *Sci Rep* 2017;7:42201.
7. Akil H, Huang AS, Francis BA, Sadda SR, Chopra V. Retinal vessel density from optical coherence tomography angiography to differentiate early glaucoma, pre-perimetric glaucoma and normal eyes. *PLoS One* 2017;12:2:e0170476.
8. Yarmohammadi A, Zangwill LM, Manalastas PIC, et al. Peripapillary and macular vessel density in patients with primary open-angle glaucoma and unilateral visual field loss. *Ophthalmology* 2018;125:4:578-587.
9. Yarmohammadi A, Zangwill LM, Diniz-Filho A, et al. Relationship between optical coherence tomography angiography vessel density and severity of visual field loss in glaucoma. *Ophthalmology* 2016;123:12:2498-2508.
10. Zhang X, Dastiridou A, Francis BA, et al. Comparison of glaucoma progression detection by optical coherence tomography and visual field. *Am J Ophthalmol*. 2017;184:63-74.
11. Wu Z, Saunders LJ, Daga FB, Diniz-Filho A, Medeiros FA. Frequency of testing to detect visual field progression derived using a longitudinal cohort of glaucoma patients. *Ophthalmology* 2017;124:6:786-792.

Career Opportunities

OPHTHALMOLOGISTS

Danbury, CT

Ophthalmologists to share office with long standing Ophthalmologist in Danbury, CT. High quality equipment. \$2,250 per month or adjoining office without equipment- \$1,750 per month.

203-545-3539 or
email mehrimd@aol.com



Do you have Products and Services for sale?

CONTACT US TODAY
FOR CLASSIFIED ADVERTISING
Toll free: 888-498-1460
E-mail: sales@kerhgroup.com



Targeting Ophthalmologists?

CLASSIFIED ADVERTISING WORKS

Contact us today
for classified advertising:
Toll free: **888-498-1460**
E-mail: sales@kerhgroup.com



REVIEW Advertising Index

Alcon Laboratories 61
Phone (800) 451-3937
Fax (817) 551-4352

Akorn Consumer Health 55
Phone (800) 579-8327
Fax www.akornconsumerhealth.com

Bausch + Lomb 11, 12, 41, 42, 63, 71, 72
Phone (800) 323-0000
Fax (813) 975-7762

Beaver-Visitec International, Inc. 31
Phone (866) 906-8080
Fax (866) 906-4304
www.beaver-visitec.com

Bruder Ophthalmic Products 45, 47
Phone (888) 827-8337
Fax eyes@bruderophthalmic.com

Carl Zeiss Meditec Inc. 19
Phone (877) 486-7473
Fax (925) 557-4101

Compulink 53
Phone (800) 456-4522
www.compulinkadvantage.com

Dry Eye Doctor 39
Phone (833) 4DRYEYE
Fax info@thedryeyedoctor.net
www.thedryeyedoctor.net

EyePoint Pharmaceutical 33, 34
Phone (617) 926-5000
Fax (617) 926-5050
[eyepointpharma.com](http://www.eyepointpharma.com)

EyeVance Pharmaceuticals 81
Phone (817) 677-6120
Fax [eyevance.com](http://www.eyevance.com)

Focus Laboratories, Inc. 29
Phone (866) 752-6006
Fax (501) 753-6021
www.focuslaboratories.com

Glaukos 15
Phone (800) 452-8567
Fax www.glaukos.com

Haag-Streit 51
Phone (800) 627-6286
Fax (603) 742-7217

Icare USA 49
Phone (888) 389-4022
Fax www.icare-usa.com

Johnson & Johnson Surgical Vision, Inc. 2
Fax <https://surgical.jnjvision.com>

Kala Pharmaceuticals 21, 22
Phone (781) 996-5252
Fax (781) 642-0399
Fax info@kalarx.com
www.kalarx.com

Keeler Instruments 5
Phone (800) 523-5620
Fax (610) 353-7814

Lacrimedics, Inc 74
Phone (800) 367-8327
Fax (253) 964-2699
Fax info@lacrimedics.com
www.lacrimedics.com

Lombart Instruments 37
Phone (800) 446-8092
Fax (757) 855-1232

Myco Industries, Inc./AB Max™ 9
Phone (800) 721-8006
Fax info@mycoindustries.com
www.AB-Max.com

NuSight Medical Operations 59
Phone (833) 468-5437
Fax www.NuSightMedical.com

Ocular Therapeutix, Inc. 7, 8
Phone (877) 628-8998
Fax www.ocutx.com

Oculus, Inc. 65
Phone (888) 284-8004
Fax (425) 867-1881

Omeros 17
Phone (206) 676-5000
Fax (206) 676-5005

Reichert Technologies 57
Phone (888) 849-8955
Fax (716) 686-4545
www.reichert.com

Reliance Medical 67
Phone (800) 735-0357
Fax (513) 398-0256

S4OPTIK 25, 27
Phone (888) 224-6012

Shire Ophthalmics 83, 84
Fax www.shire.com

Sight Sciences 69
Phone (877) 266-1144
Fax info@sightsciences.com
www.sightsciences.com

This advertiser index is published as a convenience and not as part of the advertising contract. Every care will be taken to index correctly. No allowance will be made for errors due to spelling, incorrect page number, or failure to insert.

A 47-year-old male presents to the Wills Eye Hospital emergency room with poor night vision, flashes and floaters.

Travis Peck, MD, James P. Dunn, MD

Presentation

A 47-year-old African-American male presented to the Wills Eye emergency room for acute, severe, boring right eye pain that had been present for three days. On further questioning, the patient reported poor night vision and occasional flashes and floaters. These symptoms had been slowly progressing for months to years. Review of systems was negative for fevers, cough, sinusitis, neurologic dysfunction, arthralgias, and genital ulcers or pain.

Medical History

Past ocular history included central serous chorioretinopathy secondary to systemic steroid therapy. Past medical history included: HIV infection with an undetectable viral load and a recent CD4+ count of 450/mL; syphilis that was treated three times previously with intramuscular penicillin with a rapid plasma reagin (RPR) titer of 1:4 three months prior; sarcoidosis; hepatitis B and C infection; and hypertension. Family history was non-contributory. Social history was significant for one-pack-per-day cigarette use and unprotected same-sex intercourse; he denied any drug use. Current medications included ritonavir, rilpivirine, darunavir, dolutegravir and emtricitabine.

Examination

Ocular examination demonstrated visual acuity of 20/20 OD and 20/30 OS. Pupils were normal, and intraocular pressures were 15 mmHg OD and 16 mmHg OS. Confrontation visual fields were circumferentially constricted in both eyes. Extraocular motility was full bilaterally. Anterior segment examination revealed focal temporal injection in the right eye that didn't blanch with phenylephrine and trace nuclear sclerosis cataracts OU.

Dilated fundus examination demonstrated petalloid macular edema in the left eye. The peripheral retina of both eyes showed symmetric, circumferential scalloped areas of depigmentation with scattered areas of pigment clumping (*Figures 1 and 2*).

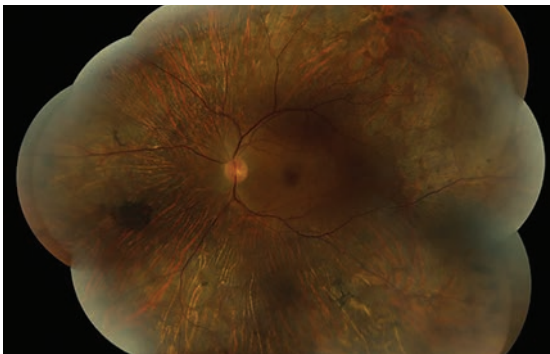

Figure 1. Montage fundus photograph of the left eye showing circumferential retinal atrophy extending to the vascular arcades. An area of retinal atrophy temporal to the fovea can also be seen.

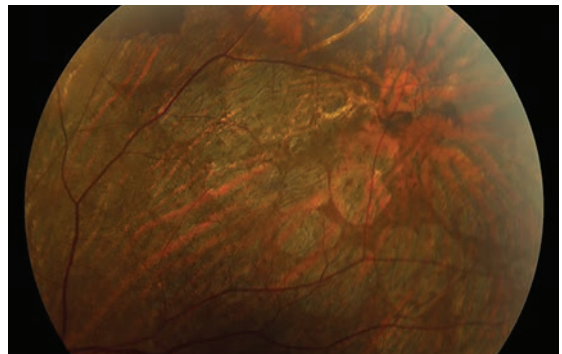


Figure 2. Enlarged color photo of the peripheral retinal gyrate-like atrophy with pigment deposition.

What is your diagnosis? What further workup would you pursue? The diagnosis appears on p. 79



SAVE THESE DATES



3RD YEAR RESIDENT PROGRAMS & WET LAB

Dear CSE 3rd-Year Resident Program Director and Coordinator,

We would like to invite you to review the upcoming 3rd-Year Ophthalmology Resident Programs and Wet Lab for 2019 in Fort Worth, Texas. The programs offer a unique educational opportunity for third-year residents by providing the chance to meet and exchange ideas with some of the most respected thought leaders in ophthalmology. The programs are designed to provide your residents with a state-of-the-art didactic and wet lab experience. The programs also serve as an opportunity for your residents to network with residents from other programs.

After reviewing the material, it is our hope that you will select and encourage your residents to attend one of these educational activities, which are CME accredited to ensure fair balance.

Best regards,
Kendall Donaldson, MD, Yousuf Khalifa, MD, Anjali Tannan, MD, & Mitch Weikert, MD, MS



Third-Year Resident Wet Lab Programs 2019:

August 2-3 Fort Worth, TX Course Director: Mitch Weikert, MD, MS	August 16-17 Fort Worth, TX Course Director: Yousuf Khalifa, MD	August 23-24 Fort Worth, TX Course Director: Anjali Tannan, MD	September 20-21 Fort Worth, TX Course Director: Kendall Donaldson, MD
--	---	--	---

Register Now: www.revophth.com/ResEdu2019

For more information: Visit the registration site above or
Email: dholmes@postgradhealthed.com • Call: Denette Holmes 866-627-0714

Courses are restricted to US-based 3rd-year residents enrolled in a US-based ophthalmology resident program and within their third year at the time of the course. There is no registration fee for these activities. Air, ground transportation in Fort Worth, hotel accommodations and modest meals will be provided through an educational scholarship for qualified participants.

Satisfactory Completion - Learners must complete an evaluation form to receive a certificate of completion. Your chosen sessions must be attended in their entirety. Partial credit of individual sessions is not available. If you are seeking continuing education credit for a specialty not listed below, it is your responsibility to contact your licensing/certification board to determine course eligibility for your licensing/certification requirement.



JOINTLY ACCREDITED PROVIDER™
INTERPROFESSIONAL CONTINUING EDUCATION

Physicians - In support of improving patient care, this activity has been planned and implemented by Amedco LLC and Postgraduate Healthcare Education. Amedco LLC is jointly accredited by the Accreditation Council for Continuing Medical Education (ACCME), the Accreditation Council for Pharmacy Education (ACPE), and the American Nurses Credentialing Center (ANCC), to provide continuing education for the healthcare team

Credit Designation Statement - Amedco designates this live activity for *AMA PRA Category 1 Credits™*. Physicians should claim only the credit commensurate with the extent of their participation in the activity.

Endorsed by:

Review of Ophthalmology®

Jointly provided by:

REG
(Review Education Group)



Supported by an independent medical education grant from:

Alcon

Workup, Diagnosis and Treatment

Ancillary imaging, including fluorescein angiography (Figure 3) and OCT (Figure 4), was obtained. The former showed late leakage in the superior macula of the left eye. OCT demonstrated cystoid macular edema in both eyes. Goldmann visual fields showed mild, scalloped, concentric peripheral visual field loss, most prominent superiorly.

The work-up of this patient with a history of HIV, syphilis and sarcoidosis, presenting with bilateral insidious peripheral vision loss and nyctopia due to wide-spread peripheral, pigmentary RPE atrophy, began by excluding infectious etiologies. Given the patient's history of syphilis, an RPR and Venereal Disease Research Laboratory (VDRL) titer were drawn. (Fluorescent treponemal antibody-absorption [FTA-ABS] remains reactive from an initial infection, so it's not useful in monitoring for recurrence.) The RPR titer was 1:4, decreased from 1:16 previously. A computed tomography scan of the chest showed hilar lymphadenopathy and interstitial lung disease consistent with known sarcoidosis.

The patient's medication list was reviewed, and only ritonavir was associated with a retinopathy. Ritonavir toxicity is reported to have a

characteristic pattern of perifoveal whitening and late bull's-eye macular atrophy. No association with macular edema or peripheral atrophy has been made with this medication. Further review of his previous highly active antiretroviral therapy revealed that he had been treated with didanosine, the use of which has been associated with a gyrate-like peripheral retinopathy. Given the low suspicion

for other diagnoses and the similarity of previous case reports of didanosine toxicity to this case, a presumed diagnosis of didanosine toxicity was made. However, didanosine has never been reported to cause macular edema, as was seen in this patient.

The patient was started on topical dorzolamide to treat the macular edema, to limit interactions with his other medications and to avoid steroids, given his history of CSCR. In addition to the dorzolamide for

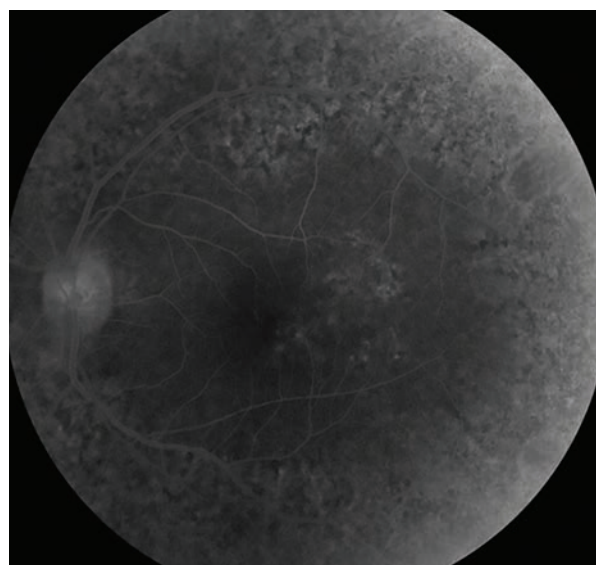


Figure 3. Fluorescein angiography of the left eye at one minute and thirty seconds demonstrates leakage in the temporal macula as well as peripheral window defects.

macular edema, he also received one week of oral ibuprofen that successfully treated his scleritis, which was the cause of his presentation to the Wills ER, but incidental to the retinal findings.

He was followed closely for three years without any progression of the peripheral retinal findings. The macular edema fluctuated in severity, despite continuing topical dorzolamide.

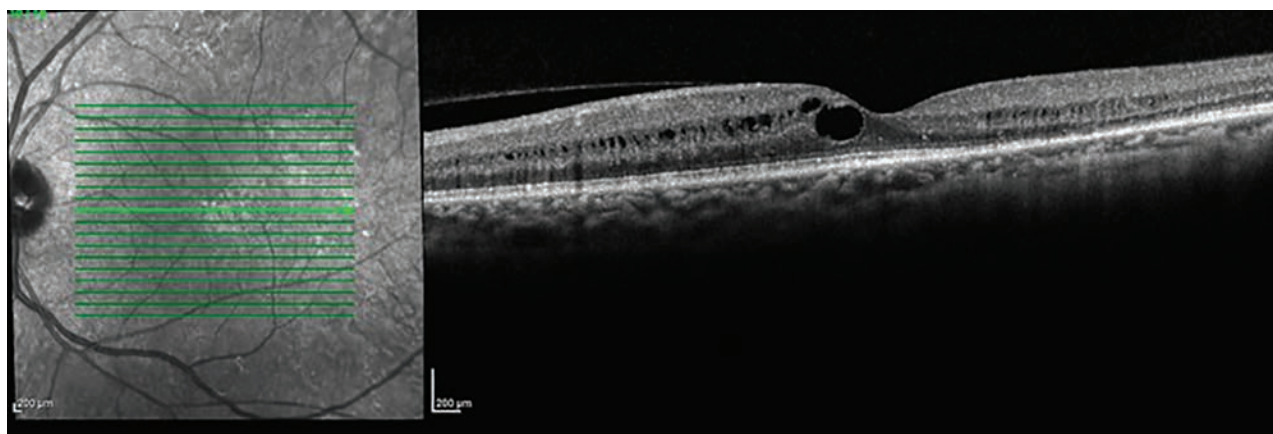


Figure 4. Optical coherence tomography of the left eye shows cystoid macular edema, as well as outer retinal atrophy temporally.

Discussion

Didanosine is a nucleoside reverse transcriptase inhibitor (NRTI) most well-known for its role as a component of HAART used in the management of HIV. It's an adenosine analogue that terminates viral transcription when it's incorporated into a growing nucleic acid chain. Introduced in 1991, the drug was the second HIV medication approved by the Food and Drug Administration, preceded only by zidovudine.¹ It became the first generic HIV medication in 2001. The most well-known adverse effect of didanosine is acute pancreatitis, which has resulted in a black-box warning. Other gastrointestinal symptoms can also occur, such as nausea, vomiting, diarrhea and abdominal pain. Peripheral neuropathy is reported in a quarter of patients, and case reports of optic neuritis have been described.¹

There are 22 case reports of didanosine-related ophthalmic toxicity, all of which include a peripheral retinal atrophy with pigmentary deposition.² The pigmentary changes often take on a gyrate-like pattern, as described in this case, and never involve the macula. For this reason, symptoms are limited to nyctalopia and photopsias, with central visual acuity remaining largely unaffected.² It's believed that the process primarily affects rods, due to their high mitochondrial activity, as didanosine inhibits mitochondrial function *in vitro*.¹

Signs and symptoms in these patients are typically stable or slowly worsen. There are no cases where the retinal findings or symptoms resolved. The most important step in management is to diagnose didanosine as the offending medication and discontinue its use, although case reports have documented progression of retinal atrophy despite cessation of therapy.³

This raises the question of whether the retinopathy is due to didanosine

alone or is associated with the entire class of NRTIs. There are no documented cases of this pattern of retinal toxicity in patients on HAART not taking didanosine, but it's possible that the use of other medications that affect mitochondrial function may increase the risk of didanosine toxicity.³ In our patient, didanosine had already been discontinued at the time of diagnosis, but he didn't know when it was stopped. Fortunately, the toxicity didn't progress in our patient.

The cystoid macular edema in this case remains something of a diagnostic mystery. The patient was taking ritonavir, which is known to cause a maculopathy. However, this has a characteristic pattern described as perifoveal whitening, telangiectasias, intraretinal crystals and RPE disruption with late retinal atrophy. Progression leads to a bull's eye maculopathy due to retinal atrophy, but no reports document macular edema.⁴ Macular edema is not associated with any other HAART medications, including didanosine.⁵ As the patient had no other conditions associated with cystoid macular edema, it seems possible that this could be a novel presentation of didanosine toxicity.

This case illustrates the importance of a broad differential diagnosis in HIV-positive patients. The most important first step is to rule out an infectious process. Pathogens affecting the retina include syphilis, toxoplasmosis, cytomegalovirus, herpes simplex and the varicella-zoster virus. The *Herpes viridae* have characteristic presentations that aren't consistent with the retinopathy or insidious time-course seen in this case. Toxoplasmosis can cause a bilateral necrotizing chorioretinitis in HIV patients, but the mid-peripheral atrophic appearance of the fundus in this patient didn't appear compatible with toxoplasmosis scars. Syphilis was

the most likely possible infectious process, especially given the patient's history of syphilis treated multiple times with only intramuscular penicillin. Ocular manifestations of syphilis include anterior or intermediate uveitis, optic neuritis and posterior subretinal placoid lesions. Pertinent to this case, syphilis leading to a non-necrotizing bilateral process resulting in large areas of retinal atrophy followed by RPE hyperplasia has been described. Inflammatory findings are typically present, including retinal vasculitis or vitritis. Decreasing RPR titers, the gyrate-like appearance and lack of progression weren't consistent with syphilis or other infectious processes.

In conclusion, this is a case of bilateral pigmentary retinopathy in an HIV-positive patient with a history of syphilis and sarcoidosis. After infectious, inflammatory and neoplastic processes were ruled out, a diagnosis of didanosine toxicity was presumed. An important point is that patients, especially those with HIV and autoimmune diseases, may have numerous simultaneous ocular processes. While Occam's razor states that a single underlying diagnosis may explain numerous seemingly unrelated findings, this may not be the case in HIV patients. This case presented a management dilemma in balancing medication side effects with the necessity of steroid therapy and HAART. Co-management with infectious disease and other specialties is critical in proper management of these medically complex patients. **REVIEW**

1. Kakuda TN. Pharmacology of nucleoside and nucleotide reverse transcriptase inhibitor-induced mitochondrial toxicity. *Clin Ther* 2000;22:685-708.
2. Haug SJ, Wong RW, Day S, et al. Didanosine retinal toxicity. *Retina* 2016;36 Suppl 1:S159-S167.
3. Gabrielian A, MacCumber MM, Kukuzyev A, et al. Didanosine-associated retinal toxicity in adults infected with human immunodeficiency virus. *JAMA Ophthalmol* 2013;131:255-259.
4. Pinto R, Vila-Franca M, Oliveira Afonso C, et al. Ritonavir and bull's eye maculopathy: Case report. *GMS Ophthalmol Cases* 2013;3:Doc01.
5. Whitcup SM, Butler KM, Caruso R, et al. Retinal toxicity in human immunodeficiency virus-infected children treated with 2',3'-dideoxyinosine. *Am J Ophthalmol* 1992;113:1-7.

Flarex[®]

(fluorometholone
acetate
ophthalmic
suspension) 0.1%

**NOW JOINING THE
EYEVANCE[™] FAMILY**
of ophthalmic treatment options



© 2019 EyeVance Pharmaceuticals LLC. All rights reserved.
FLAREX[®] is a registered trademark of EyeVance Pharmaceuticals LLC.
FLA-004 01/2019

Save the Date



JULY 25
2019

CHICAGO

OCT 10
2019

SAN
FRANCISCO

FACILITATING MEANINGFUL INTERACTIONS AND THE
EXCHANGE OF INFORMATION BETWEEN INDUSTRY
AND CLINICAL LEADERS SINCE 2009.

Register Today!

The Ophthalmology Innovation Summit at ASRS* and AAO unites industry, entrepreneurial and clinical leaders to collaborate on the development and commercialization of innovative drugs and devices to address unmet clinical needs.

FOR MORE INFORMATION, VISIT WWW.OIS.NET

*OIS@ASRS is not affiliated with ASRS.



BRIEF SUMMARY:

Consult the Full Prescribing Information for complete product information.

INDICATIONS AND USAGE

Xiidra® (lifitegrast ophthalmic solution) 5% is indicated for the treatment of the signs and symptoms of dry eye disease (DED).

DOSAGE AND ADMINISTRATION

Instill one drop of Xiidra twice daily (approximately 12 hours apart) into each eye using a single-use container. Discard the single-use container immediately after using in each eye. Contact lenses should be removed prior to the administration of Xiidra and may be reinserted 15 minutes following administration.

CONTRAINDICATIONS

Xiidra is contraindicated in patients with known hypersensitivity to lifitegrast or to any of the other ingredients in the formulation.

ADVERSE REACTIONS

Clinical Trials Experience

Because clinical studies are conducted under widely varying conditions, adverse reaction rates observed in clinical studies of a drug cannot be directly compared to rates in the clinical trials of another drug and may not reflect the rates observed in practice. In five clinical studies of dry eye disease conducted with lifitegrast ophthalmic solution, 1401 patients received at least 1 dose of lifitegrast (1287 of which received lifitegrast 5%). The majority of patients (84%) had ≤ 3 months of treatment exposure. 170 patients were exposed to lifitegrast for approximately 12 months. The majority of the treated patients were female (77%). The most common adverse reactions reported in 5-25 % of patients were instillation site irritation, dysgeusia and reduced visual acuity. Other adverse reactions reported in 1% to 5% of the patients were blurred vision, conjunctival hyperemia, eye irritation, headache, increased lacrimation, eye discharge, eye discomfort, eye pruritus and sinusitis.

Postmarketing Experience

The following adverse reactions have been identified during postapproval use of Xiidra. Because these reactions are reported voluntarily from a population of uncertain size, it is not always possible to reliably estimate their frequency or establish a causal relationship to drug exposure.

Rare cases of hypersensitivity, including anaphylactic reaction, bronchospasm, respiratory distress, pharyngeal edema, swollen tongue, and urticaria have been reported. Eye swelling and rash have been reported.

USE IN SPECIFIC POPULATIONS

Pregnancy

There are no available data on Xiidra use in pregnant women to inform any drug associated risks. Intravenous (IV) administration of lifitegrast to pregnant rats, from pre-mating through gestation day 17, did not produce teratogenicity at clinically relevant systemic exposures. Intravenous administration of lifitegrast to pregnant rabbits during organogenesis produced an increased incidence of omphalocele at the lowest dose

tested, 3 mg/kg/day (400-fold the human plasma exposure at the recommended human ophthalmic dose [RHOD], based on the area under the curve [AUC] level). Since human systemic exposure to lifitegrast following ocular administration of Xiidra at the RHOD is low, the applicability of animal findings to the risk of Xiidra use in humans during pregnancy is unclear.

Animal Data

Lifitegrast administered daily by intravenous (IV) injection to rats, from pre-mating through gestation day 17, caused an increase in mean preimplantation loss and an increased incidence of several minor skeletal anomalies at 30 mg /kg / day, representing 5,400-fold the human plasma exposure at the RHOD of Xiidra, based on AUC. No teratogenicity was observed in the rat at 10 mg /kg /day (460-fold the human plasma exposure at the RHOD, based on AUC). In the rabbit, an increased incidence of omphalocele was observed at the lowest dose tested, 3 mg /kg /day (400-fold the human plasma exposure at the RHOD, based on AUC), when administered by IV injection daily from gestation days 7 through 19. A fetal No Observed Adverse Effect Level (NOAEL) was not identified in the rabbit.

Lactation

There are no data on the presence of lifitegrast in human milk, the effects on the breastfed infant, or the effects on milk production. However, systemic exposure to lifitegrast from ocular administration is low. The developmental and health benefits of breastfeeding should be considered, along with the mother's clinical need for Xiidra and any potential adverse effects on the breastfed child from Xiidra.

Pediatric Use

Safety and efficacy in pediatric patients below the age of 17 years have not been established.

Geriatric Use

No overall differences in safety or effectiveness have been observed between elderly and younger adult patients.

NONCLINICAL TOXICOLOGY

Carcinogenesis, Mutagenesis, Impairment of Fertility

Carcinogenesis: Animal studies have not been conducted to determine the carcinogenic potential of lifitegrast.

Mutagenesis: Lifitegrast was not mutagenic in the *in vitro* Ames assay. Lifitegrast was not clastogenic in the *in vivo* mouse micronucleus assay. In an *in vitro* chromosomal aberration assay using mammalian cells (Chinese hamster ovary cells), lifitegrast was positive at the highest concentration tested, without metabolic activation.

Impairment of fertility: Lifitegrast administered at intravenous (IV) doses of up to 30 mg/kg/day (5400-fold the human plasma exposure at the recommended human ophthalmic dose (RHOD) of lifitegrast ophthalmic solution, 5%) had no effect on fertility and reproductive performance in male and female treated rats.



Manufactured for: Shire US Inc., 300 Shire Way, Lexington, MA 02421. For more information, go to www.Xiidra.com or call 1-800-828-2088. Marks designated ® and ™ are owned by Shire or an affiliated company. ©2018 Shire US Inc. SHIRE and the Shire Logo are trademarks or registered trademarks of Shire Pharmaceutical Holdings Ireland Limited or its affiliates. Patented: please see <https://www.shire.com/legal-notice/product-patents> Last Modified: 01/2018 S33769



Xiidra may provide

LASTING RELIEF

starting as early as 2 weeks¹

One drop in each eye, twice daily, about 12 hours apart.
Discard the single-use container immediately after use.¹

Choose Xiidra first for patients with signs and symptoms of Dry Eye Disease

Xiidra reduced symptoms of eye dryness at 2 weeks in 2 out of 4 studies, and in all 4 studies at 6 and 12 weeks. Xiidra also improved signs of inferior corneal staining at 12 weeks in 3 out of 4 studies.¹

The safety and efficacy of Xiidra compared to vehicle were studied in 2133 patients in 4 well-controlled, 12-week trials.¹

Check it out at Xiidra-ECP.com

Indication

Xiidra® (lifitegrast ophthalmic solution) 5% is indicated for the treatment of signs and symptoms of dry eye disease (DED).

Important Safety Information

Xiidra is contraindicated in patients with known hypersensitivity to lifitegrast or to any of the other ingredients.

In clinical trials, the most common adverse reactions reported in 5-25% of patients were instillation site irritation, dysgeusia and reduced visual acuity. Other adverse reactions reported in 1% to 5% of the patients were blurred vision, conjunctival hyperemia, eye irritation, headache, increased lacrimation, eye discharge, eye discomfort, eye pruritus and sinusitis.

To avoid the potential for eye injury or contamination of the solution, patients should not touch the tip of the single-use container to their eye or to any surface.

Contact lenses should be removed prior to the administration of Xiidra and may be reinserted 15 minutes following administration.

Safety and efficacy in pediatric patients below the age of 17 years have not been established.

For additional safety information, see accompanying Brief Summary of Safety Information on the adjacent page and Full Prescribing Information on Xiidra-ECP.com.

Reference:

1. Xiidra [Prescribing Information]. Lexington, MA: Shire US.

©2018 Shire US Inc., Lexington, MA 02421. 1-800-828-2088. All rights reserved. SHIRE and the Shire Logo are trademarks or registered trademarks of Shire Pharmaceutical Holdings Ireland Limited or its affiliates. Marks designated ® and ™ are owned by Shire or an affiliated company. S42270 10/18

