

EVOLUTION OF PORTABLE VISUAL FIELD TESTS P. 16 • MANAGING THE ANOPHTHALMIC PATIENT P. 26
ANGLE CLOSURE: GONIOSCOPY OR OCT? P. 60 • BE PREPARED FOR PEDIATRIC RETINA PATIENTS P. 66
RESEARCHERS DELVE INTO ORBITAL CANCERS P. 70 • WILLS EYE RESIDENT CASE P. 71

REVIEW[®] of Ophthalmology

April 2019

reviewofophthalmology.com

ALL PATIENTS WELCOME!

A large, stylized illustration of a red and white striped circus tent. The tent has two peaks and a central entrance. A small figure of a person in a blue uniform stands in the entrance, gesturing towards the tent. The background is a light blue and white striped pattern with a border of small stars.

Techniques and technology that let you help more cataract patients.

- How to Deal with Premium-IOL Problems **P. 30**
- Peel Back the Veil on ERM Management **P. 40**
- MSICS and miLoop for Non-phaco Candidates **P. 54**

ALSO INSIDE:

- The Continuing Role of Lasers in PDR **P. 44**
- The Artificial Iris in Practice **P. 48**

TECNIS
Symfony[®]
Extended Range of Vision IOLs



TECNIS[®]
Multifocal IOLs
+3.25 D

Do your cataract patients require improved near vision?

Personalized vision* with **TECNIS**[®] can help you meet their expectations with:

- Improved near visual acuities without compromising distance vision¹
- Low incidence of visual symptoms¹
- High patient satisfaction¹

Visit **TecnisIOL.com** to learn more.

*Personalized vision refers to combining a TECNIS Symfony[®] IOL in 1 eye and a TECNIS[®] Multifocal +3.25 D IOL in the other eye. Or alternatively, a TECNIS[®] Multifocal +3.25 D IOL in 1 eye and a TECNIS[®] Multifocal +2.75 D IOL in the other eye.



Not actual patient.

INDICATIONS AND IMPORTANT SAFETY INFORMATION FOR TECNIS SYMFONY[®] AND TECNIS SYMFONY[®] TORIC EXTENDED RANGE OF VISION IOLs

Rx Only

INDICATIONS FOR USE: The TECNIS Symfony[®] Extended Range of Vision IOL, Model ZXR00, is indicated for primary implantation for the visual correction of aphakia, in adult patients with less than 1 diopter of pre-existing corneal astigmatism, in whom a cataractous lens has been removed. The lens mitigates the effects of presbyopia by providing an extended depth of focus. Compared to an aspheric monofocal IOL, the lens provides improved intermediate and near visual acuity, while maintaining comparable distance visual acuity. The Model ZXR00 IOL is intended for capsular bag placement only. The TECNIS Symfony[®] Toric Extended Range of Vision IOLs, Models ZXT150, ZXT225, ZXT300, and ZXT375, are indicated for primary implantation for the visual correction of aphakia and for reduction of residual refractive astigmatism in adult patients with greater than or equal to 1 diopter of preoperative corneal astigmatism, in whom a cataractous lens has been removed. The lens mitigates the effects of presbyopia by providing an extended depth of focus. Compared to an aspheric monofocal IOL, the lens provides improved intermediate and near visual acuity, while maintaining comparable distance visual acuity. The Model Series ZXT IOLs are intended for capsular bag placement only. **WARNINGS:** Patients with any of the conditions described in the Directions for Use may not be suitable candidates for an intraocular lens because the lens may exacerbate an existing condition, may interfere with diagnosis or treatment of a condition, or may pose an unreasonable risk to the patient's eyesight. Lenses should not be placed in the ciliary sulcus. May cause a reduction in contrast sensitivity under certain conditions, compared to an aspheric monofocal IOL; fully inform the patient of this risk before implanting the lens. Special consideration should be made in patients with macular disease, amblyopia, corneal irregularities, or other ocular disease. Inform patients to exercise special caution when driving at night or in poor visibility conditions. Some visual effects may be expected due to the lens design, including: a perception of halos, glare, or starbursts around lights under nighttime conditions. These will be bothersome or very bothersome in some people, particularly in low-illumination conditions, and on rare occasions, may be significant enough that the patient may request removal of the IOL. Rotation of the TECNIS Symfony[®] Toric IOLs away from their intended axis can reduce their astigmatic correction, and misalignment >30° may increase postoperative refractive cylinder. If necessary, lens repositioning should occur as early as possible prior to lens encapsulation. **PRECAUTIONS:** Interpret results with caution when refracting using autorefractors or wavefront aberrometers that utilize infrared light, or when performing a duochrome test. Confirmation of refraction with maximum plus manifest refraction technique is recommended. The ability to perform some eye treatments (e.g. retinal photocoagulation) may be affected by the optical design. Target emmetropia for optimum visual performance. Care should be taken to achieve IOL centration, as lens decentration may result in a patient experiencing visual disturbances under certain lighting conditions. For the TECNIS Symfony[®] Toric IOL, variability in any preoperative surgical parameters (e.g. keratometric cylinder, incision location, surgeon's estimated surgically induced astigmatism and biometry) can influence patient outcomes. Carefully remove all viscoelastic and do not over-inflate the capsular bag at the end of the case to prevent lens rotation. **SERIOUS ADVERSE EVENTS:** The most frequently reported serious adverse events that occurred during the clinical trial of the TECNIS Symfony[®] lens were cystoid macular edema (2 eyes, 0.7%) and surgical reintervention (treatment injections for cystoid macular edema and endophthalmitis, 2 eyes, 0.7%). No lens-related adverse events occurred during the trial.

INDICATIONS AND IMPORTANT SAFETY INFORMATION FOR THE TECNIS[®] MULTIFOCAL FAMILY OF 1-PIECE IOLs

Rx Only

INDICATIONS: The TECNIS[®] Multifocal 1-Piece intraocular lenses are indicated for primary implantation for the visual correction of aphakia in adult patients with and without presbyopia in whom a cataractous lens has been removed by phacoemulsification and who desire near, intermediate, and distance vision with increased spectacle independence. The intraocular lenses are intended to be placed in the capsular bag. **WARNINGS:** Physicians considering lens implantation should weigh the potential risk/benefit ratio for any conditions described in the Directions for Use that could increase complications or impact patient outcomes. Multifocal IOL implants may be inadvisable in patients where central visual field reduction may not be tolerated, such as macular degeneration, retinal pigment epithelium changes, and glaucoma. The lens should not be placed in the ciliary sulcus. Inform patients about the possibility that a decrease in contrast sensitivity and an increase in visual disturbances may affect their ability to drive a car under certain environmental conditions, such as driving at night or in poor visibility conditions. **PRECAUTIONS:** Prior to surgery, inform prospective patients of the possible risks and benefits associated with the use of this device and provide a copy of the patient information brochure to the patient. The long term effects of intraocular lens implantation have not been determined. Secondary glaucoma has been reported occasionally in patients with controlled glaucoma who received lens implants. Do not reuse, resterilize or autoclave. **ADVERSE EVENTS:** The rates of surgical re-interventions, most of which were non-lens related, were statistically higher than the FDA grid rate for both the ZMB00 (+4.00 D) and ZLB00 (+3.25 D) lens models. For the ZMB00, the surgical re-intervention rates were 3.2% for first eyes and 3.3% for second eyes. The re-intervention rate was 3.3% for both the first and second eyes in the ZLB00 group. **ATTENTION:** Reference the Directions for Use for a complete listing of Indications and Important Safety Information.

REFERENCE: 1. JJV Data on File 2018. Validity of investigator initiated studies by Machat and Dell (DOF2018CT4021).

TECNIS[®] and TECNIS Symfony[®] are trademarks of Johnson & Johnson Surgical Vision, Inc.

©Johnson & Johnson Surgical Vision, Inc. 2019 | TecnisIOL.com | PP2018MLT4303 | February 2019

See the Passion in
Each Patient.

Johnson & Johnson VISION

Correlations Found Between Glaucoma and Pregnancies

It's well-established that the incidence and prevalence of glaucoma is affected by gender, but the reasons for this remain unclear. Noting that some previous studies have found a correlation between having given birth and glaucoma, researchers in South Korea set out to pursue this further.

A study published in the January 2019 issue of *The Journal of Glaucoma* used a population-based, cross-sectional analysis of data from the Korean National Health and Nutrition Examination Survey, conducted in 2010 and 2011, to investigate any association between pregnancy, delivery and the prevalence of open-angle glaucoma in 1,798 postmenopausal South Korean women. Demographic information, comorbidities and health-related behaviors were included in the analysis. Excluded from the database were subjects with evidence of retinal detachment or age-related macular degeneration; pseudophakic and aphakic subjects; anyone who did not undergo an ophthalmic evaluation; and anyone with a history of intraocular surgery. (The authors note that one limitation of their study was the small number of women in the survey who had no pregnancies, making it impossible to draw any conclusions regarding subjects in that situation.)

Several correlations between number of pregnancies and glaucoma were found:

- There was a significant difference between the open-angle glau-

coma group and the no-glaucoma group in both the number of deliveries the women had undergone and the subject's age at the time of the first delivery.



- When the analysis was adjusted to account for age, hypertension and intraocular pressure, the lowest increased risk for open-angle glaucoma was associated with two deliveries; women with one delivery had a greater risk of open-angle glaucoma than those with two deliveries ($p=0.023$). Those with three or more deliveries also had a greater risk of open-angle glaucoma than those with two deliveries ($p=0.027$).

- Giving birth for the first time

between the age of 16 to 20 years or 21 to 23 years was associated with a two-fold increased risk of open-angle glaucoma, compared to a reference group of subjects aged 24 to 26 ($p<0.05$).

The authors conclude that these findings suggest that changes taking place in the body during pregnancy may affect the development of glaucoma.

Without further data, any explanation for these effects is theoretical, but the authors hypothesize a number of possible explanations for their findings. These include: high estrogen levels during pregnancy; transient events during labor, including systemic hypotension and decreased ocular perfusion because of massive bleeding, inducing glaucoma-like changes in the optic nerve; increased oxytocin levels during labor inducing capillary constriction and decreasing aqueous outflow; stress during labor causing the release of epinephrine and norepinephrine, increasing IOP; and valsalva maneuvers during labor producing intermittent increases in IOP.

While all of these changes are short-lived, raising the question of whether they could have such a

Farewell ... and Welcome

This issue marks a changing of the guard in our Retinal Insider department. After 20 years of expertly co-editing the column alongside Carl Regillo, MD, Emmett Cunningham, MD, PhD, is stepping down. *Review* and its readers thank Dr. Cunningham for his fine work. In his place comes Yoshihiro Yonekawa, MD, an expert clinician and surgeon currently at Massachusetts Eye and Ear Infirmary, but soon to be at Wills Eye Hospital. We'd like to take this opportunity to welcome Dr. Yonekawa to the magazine.

Editor in Chief

Walter C. Bethke
(610) 492-1024
wbethke@jobson.com

Senior Editor

Christopher Kent
(814) 861-5559
ckent@jobson.com

Associate Editor

Alexandra Skinner
(610) 492-1025
askinner@jobson.com

Chief Medical Editor

Mark H. Blecher, MD

Art Director

Jared Araujo
(610) 492-1032
jaraujo@jobson.com

Senior Graphic Designer

Matt Egger
(610) 492-1029
megger@jobson.com

Graphic Designer

Ashley Schmouder
(610) 492-101048
aschmouder@jobson.com

International coordinator, Japan

Mitz Kaminuma
Reviewophtho@aol.com

Business Offices

11 Campus Boulevard, Suite 100
Newtown Square, PA 19073
(610) 492-1000
Fax: (610) 492-1039

Subscription inquiries:

United States — (877) 529-1746
Outside U.S. — (845) 267-3065
E-mail:
revophthalmology@cambeywest.com
Website: www.reviewofophthalmology.com



significant impact, the authors note that the risk of glaucoma increases with more pregnancies/births. The primary exception to that is that the risk didn't increase between the first and second births; the authors hypothesize that this might reflect the optic nerve's ability to recover from small insults below a certain threshold. Only when the challenging conditions recur three or more times would the physiologic insult cause the likelihood of later glaucoma to increase further.

"This population-based study showed an association between pregnancy and risk of open-angle glaucoma," notes Peter A. Netland, MD, PhD, Vernah Scott Moyston Professor and Chair at the University of Virginia in Charlottesville. "The physiologic changes that take place during pregnancy are complex and numerous. The possibility of a hormone effect on the risk of glaucoma is interesting and merits further investigation."

New Drugs Approved by FDA

Two companies, Aerie Pharmaceuticals and Bausch + Lomb, received Food and Drug Administration approvals in recent months.

Aerie's glaucoma drug Rocklatan (netarsudil and latanoprost ophthalmic solution) 0.02%/0.005% has been approved by the U.S. Food and Drug Administration for the treatment of open-angle glaucoma and ocular hypertension. It's the first q.d. fixed-dose combination of a prostaglandin analog and a Rho kinase inhibitor.

The approval was supported by

two Phase III trials, MERCURY 1 (NCT 02558400) and MERCURY 2 (NCT 02674854). The company reports that Rocklatan achieved the primary 90-day efficacy endpoint, as well as positive 12-month safety and efficacy results, showing statistically significant intraocular pressure reduction vs. either latanoprost or netarsudil alone at each time point.

For its part, Bausch + Lomb announced the FDA approval of a treatment for postoperative inflammation and pain following ocular surgery: corticosteroid Lotemax SM. B+L says that Lotemax SM uses sub-micron technology to deliver fast drug dissolution in tears and improve drug exposure into the aqueous, and that it provides two times greater penetration to the aqueous humor compared to Lotemax Gel (loteprednol etabonate ophthalmic gel) 0.5%.

The drug has the lowest preservative percentage in a loteprednol etabonate formulation, and has a pH close to that of human tears, B+L adds.

In one randomized study, at post-stop day eight, the new drug cleared anterior chamber cells in 29 percent of patients vs. 9 percent of patients who were administered only vehicle, and 73 percent of the Lotemax SM patients reported being clear of pain vs. 48 percent of vehicle patients.

Court Moves Against Drug Compounder

The federal court in the Northern District of Texas has ordered JMA Partners, doing business as Guardian Pharmacy Services in Dallas, to stop producing compounded drug prod-

(Continued on page 8)

DID YOU KNOW?

KEELER

has slit lamps!

For over 100 years, we have been creating innovative products. The Keeler slit lamp is one of them – designed with you and your patients in mind. The KSL delivers a visually pleasing, customizable device equipped with excellent, high-quality optics.

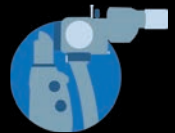SLIT LAMP FEATURES



Sharp & clear
Keeler Optics



KSL-H series:
tower illumination




KSL-Z series:
lower illumination



Digital-ready
& full digital units



3x magnification
drum (10x, 16x, 25x)



5x magnification
drum (6x, 10x, 16x,
25x, 40x)



Unique 1mm
square for Uveitis
evaluation



Bright & white
LED illumination



We also carry
portable slit lamps!

VISIT OUR WEBSITE FOR MORE PRODUCT DETAILS

www.keelerusa.com / 800-523-5620

Keeler

CONTRIBUTORS

CHIEF MEDICAL EDITOR

Mark H. Blecher, MD

CONTACT LENSES

Penny Asbell, MD

CORNEA / ANTERIOR SEGMENT

Thomas John, MD

GLAUCOMA MANAGEMENT

Peter Netland, MD, PHD
Kuldev Singh, MD

MASTERS OF SURGERY

Taliva D. Martin, MD
Sara J. Haug, MD, PhD

MEDICARE Q & A

Paul M. Larson, MBA

PEDIATRIC PATIENT

Wendy Huang, MD

PLASTIC POINTERS

Ann P. Murchison, MD, MPH

REFRACTIVE SURGERY

Arturo S. Chayet, MD

RETINAL INSIDER

Carl Regillo, MD, FACS
Emmett T. Cunningham Jr., MD, PHD, MPH

TECHNOLOGY UPDATE

Steven T. Charles, MD
Michael Colvard, MD

WILLS RESIDENT CASE SERIES

Jason Flamendorf, MD

ADVISORY BOARD

PENNY A. ASBELL, MD, MEMPHIS, TENN.

WILLIAM I. BOND, MD, PEKIN, ILL.

ALAN N. CARLSON, MD, DURHAM, N.C.

Y. RALPH CHU, MD, EDINA, MINN.

ADAM J. COHEN, MD, DOWNERS GROVE, ILL.

UDAY DEVGAN, MD, FACS, LOS ANGELES

ERIC DONNENFELD, MD, ROCKVILLE CENTRE, N.Y.

DANIEL S. DURRIE, MD, KANSAS CITY, MO.

ROBERT EPSTEIN, MD, MCHENRY, ILL.

ROBERT D. FECHTNER, MD, NEWARK, N.J.

WILLIAM J. FISHKIND, MD, TUCSON, ARIZ.

JAMES P. GILLS, MD, TARPON SPRINGS, FLA.

HARRY GRABOW, MD, SARASOTA, FLA.

DOUGLAS K. GRAYSON, MD, NEW YORK CITY

THOMAS S. HARBIN, MD, MBA, ATLANTA

DAVID R. HARDTEN, MD, MINNEAPOLIS

KENNETH J. HOFFER, MD, SANTA MONICA, CALIF.

JACK T. HOLLADAY, MD, MSEE, HOUSTON

JOHN D. HUNKELER, MD, KANSAS CITY, MO.

THOMAS JOHN, MD, TINLEY PARK, ILL.

ROBERT M. KERSHNER, MD, MS, PALM BEACH GARDENS, FLA.

GUY M. KEZIRIAN, MD, PARADISE VALLEY, ARIZ.

TERRY KIM, MD, DURHAM, N.C.

TOMMY KORN, MD, SAN DIEGO

DAVID A. LEE, MD, HOUSTON

FRANCIS S. MAH, MD, PITTSBURGH

NICK MAMALIS, MD, SALT LAKE CITY

WILLIAM G. MARTIN, MD, OREGON, OHIO

MIKE S. MCFARLAND, MD, PINE BLUFF, ARK.

JEFFREY B. MORRIS, MD, MPH, ENCINITAS, CALIF.

MARLENE R. MOSTER, MD, PHILADELPHIA

ROBERT J. NOECKER, MD, FAIRFIELD, CONN.

ROBERT OSHER, MD, CINCINNATI

MARK PACKER, MD, WEST PALM BEACH, FLA.

STEPHEN PASCUCCI, MD, BONITA SPRINGS, FLA.

PAUL PENDER, MD, BEDFORD, N.H.

CHRISTOPHER J. RAPUANO, MD, PHILADELPHIA

AUGUST READER III, MD, SAN FRANCISCO

TONY REALINI, MD, MORGANTOWN, W.V.

KENNETH J. ROSENTHAL, MD, GREAT NECK, N.Y.

ERIC ROTHCHILD, MD, DELRAY BEACH, FLA.

SHERI ROWEN, MD, BALTIMORE

JAMES J. SALZ, MD, LOS ANGELES

INGRID U. SCOTT, MD, MPH, HERSHEY, PA.

JOEL SCHUMAN, MD, PITTSBURGH

GAURAV SHAH, MD, ST. LOUIS

DAVID R. STAGER JR., MD, DALLAS

KARL STONECIPHER, MD, GREENSBORO, N.C.

JAMES C. TSAI, MD, NEW YORK CITY

VANCE THOMPSON, MD, SIOUX FALLS, S.D.

FARRELL C. TYSON, MD, CAPE CORAL, FLA.

R. BRUCE WALLACE III, MD, ALEXANDRIA, LA.

ROBERT G. WILEY, MD, CLEVELAND

FRANK WEINSTOCK, MD, CANTON, OHIO

BUSINESS OFFICES

11 CAMPUS BOULEVARD, SUITE 100
NEWTOWN SQUARE, PA 19073
SUBSCRIPTION INQUIRIES (877) 529-1746
(USA ONLY); OUTSIDE USA, CALL (847) 763-9630

BUSINESS STAFF

PUBLISHER

JAMES HENNE

(610) 492-1017 JHENNE@JOBSON.COM

REGIONAL SALES MANAGER

MICHELE BARRETT

(610) 492-1014 MBARRETT@JOBSON.COM

REGIONAL SALES MANAGER

MICHAEL HOSTER

(610) 492-1028 MHOSTER@JOBSON.COM

CLASSIFIED ADVERTISING

(888)-498-1460

VICE PRESIDENT OF OPERATIONS

CASEY FOSTER

(610) 492-1007 CFOSTER@JOBSON.COM

PRODUCTION MANAGER

SCOTT TOBIN

(610) 492-1011 STOBIN@JOBSON.COM

SUBSCRIPTIONS

\$63 A YEAR, \$99 (U.S.) IN CANADA,
\$158 (U.S.) IN ALL OTHER COUNTRIES.

SUBSCRIPTIONS E-MAIL:

REVOPHTHALMOLOGY@CAMBEYWEST.COM

CIRCULATION

PO BOX 71, CONGERS, NY 10920-0071
(877) 529-1746

OUTSIDE USA: (845) 267-3065

SENIOR CIRCULATION MANAGER

HAMILTON MAHER

(212) 219-7870 hmaher@jhihealth.com

CEO, INFORMATION GROUP SERVICES

MARC FERRARA

SENIOR VICE PRESIDENT, OPERATIONS

JEFF LEVITZ

VICE PRESIDENT, HUMAN RESOURCES

TAMMY GARCIA

VICE PRESIDENT, CREATIVE SERVICES & PRODUCTION

MONICA TETTAMANZI

CORPORATE PRODUCTION DIRECTOR

JOHN ANTHONY CAGGIANO

VICE PRESIDENT, CIRCULATION

EVELDA BAREA



440 Ninth Avenue, 14th Floor
New York, N.Y. 10001

REVIEW OF OPHTHALMOLOGY (ISSN 1081-0226; USPS No. 0012-345) is published monthly, 12 times per year by Jobson Medical Information, 440 Ninth Avenue, 14th Floor, New York, N.Y. 10001. Periodicals postage paid at New York, NY and additional mailing offices. Postmaster: Send address changes to Review of Ophthalmology, PO Box 71, Congers, NY 10929-0071. Subscription Prices: US One Year \$63.00, US Two Year \$112.00, Canada One Year \$99.00, Canada Two Year \$181.00, Int'l One Year \$158.00, Int'l Two Year \$274.00. For subscription information call (877) 529-1746 (USA only); outside USA, call (845)-267-3065. Or email us at revophthalmology@cambeywest.com. Canada Post: Publications Mail Agreement #40612608. Canada Returns to be sent to Bleuchip International, P.O. Box 25542, London, ON N6C 6B2.

Dextenza[®]

(dexamethasone ophthalmic insert) 0.4mg
for intracanalicular use

NOW APPROVED. COMING SOON.

BIG TIME INNOVATION¹

THE FIRST AND ONLY
OPHTHALMIC STEROID INSERT

DEXTENZA is an advancement in steroid treatment

- Resorbable, so no need for removal²
- Insert can be removed via saline irrigation or manual expression, if necessary²
- Physicians rated DEXTENZA as easy to insert^{3*}
- Designed to deliver a tapered dose¹
- Contains fluorescein for visualization²
- No additional components or assembly required²

VISIT BOOTH 1737 AT ASCRS

INDICATION

DEXTENZA is a corticosteroid indicated for the treatment of ocular pain following ophthalmic surgery.

IMPORTANT SAFETY INFORMATION

CONTRAINDICATIONS

DEXTENZA is contraindicated in patients with active corneal, conjunctival or canalicular infections, including epithelial herpes simplex keratitis (dendritic keratitis), vaccinia, varicella; mycobacterial infections; fungal diseases of the eye, and dacryocystitis.

WARNINGS AND PRECAUTIONS

Prolonged use of corticosteroids may result in glaucoma with damage to the optic nerve, defects in visual acuity and fields of vision. Steroids should be used with caution in the presence of glaucoma. Intraocular pressure should be monitored during treatment.

Corticosteroids may suppress the host response and thus increase the hazard for secondary ocular infections. In acute purulent conditions, steroids may mask infection and enhance existing infection.

Use of ocular steroids may prolong the course and may exacerbate the severity of many viral infections of the eye (including herpes simplex).

Fungus invasion must be considered in any persistent corneal ulceration where a steroid has been used or is in use. Fungal culture should be taken when appropriate.

Use of steroids after cataract surgery may delay healing and increase the incidence of bleb formation

ADVERSE REACTIONS

The most common ocular adverse reactions that occurred in patients treated with DEXTENZA were: anterior chamber inflammation including iritis and iridocyclitis (9%); intraocular pressure increased (5%); visual acuity reduced (2%); eye pain (1%); cystoid macular edema (1%); corneal edema (1%); and conjunctival hyperemia (1%).

The most common non-ocular adverse reaction that occurred in patients treated with DEXTENZA was headache (1%).

Please see brief summary of full Prescribing Information on adjacent page.

*73.6% of physicians in Study 1 and 76.4% in Study 2 rated DEXTENZA as easy to insert.

References: 1. Sawhney AS et al, inventors; Incept LLC, assignee. US patent 8,409,606 B2. April 2, 2013. 2. DEXTENZA [package insert]. Bedford, MA: Ocular Therapeutix, Inc; 2018. 3. Walters T et al. *J Clin Exp Ophthalmol.* 2016;7(4):1-11.

Dextenza®

(dexamethasone ophthalmic insert) 0.4 mg
for intracanalicular use

BRIEF SUMMARY: Please see the DEXTENZA Package Insert for full prescribing information for DEXTENZA (11/2018)

1 INDICATIONS AND USAGE

DEXTENZA® (dexamethasone ophthalmic insert) is a corticosteroid indicated for the treatment of ocular pain following ophthalmic surgery (1).

4 CONTRAINDICATIONS

DEXTENZA is contraindicated in patients with active corneal, conjunctival or canalicular infections, including epithelial herpes simplex keratitis (dendritic keratitis), vaccinia, varicella; mycobacterial infections; fungal diseases of the eye, and dacryocystitis.

5 WARNINGS AND PRECAUTIONS

5.1 Intraocular Pressure Increase

Prolonged use of corticosteroids may result in glaucoma with damage to the optic nerve, defects in visual acuity and fields of vision. Steroids should be used with caution in the presence of glaucoma. Intraocular pressure should be monitored during the course of the treatment.

5.2 Bacterial Infection

Corticosteroids may suppress the host response and thus increase the hazard for secondary ocular infections. In acute purulent conditions, steroids may mask infection and enhance existing infection [see Contraindications (4)].

5.3 Viral Infections

Use of ocular steroids may prolong the course and may exacerbate the severity of many viral infections of the eye (including herpes simplex) [see Contraindications (4)].

5.4 Fungal Infections

Fungus invasion must be considered in any persistent corneal ulceration where a steroid has been used or is in use. Fungal culture should be taken when appropriate [see Contraindications (4)].

5.5 Delayed Healing

The use of steroids after cataract surgery may delay healing and increase the incidence of bleb formation.

6 ADVERSE REACTIONS

The following serious adverse reactions are described elsewhere in the labeling:

- Intraocular Pressure Increase [see Warnings and Precautions (5.1)]
- Bacterial Infection [see Warnings and Precautions (5.2)]
- Viral Infection [see Warnings and Precautions (5.3)]
- Fungal Infection [see Warnings and Precautions (5.4)]
- Delayed Healing [see Warnings and Precautions (5.5)]

6.1 Clinical Trials Experience

Because clinical trials are conducted under widely varying conditions, adverse reaction rates observed in the clinical trials of a drug cannot be directly compared to rates in the clinical trials of another drug and may not reflect the rates observed in practice. Adverse reactions associated with ophthalmic steroids include elevated intraocular pressure, which may be associated with optic nerve damage, visual acuity and field defects, posterior subcapsular cataract formation; delayed wound healing; secondary ocular infection from pathogens including herpes simplex, and perforation of the globe where there is thinning of the cornea or sclera [see Warnings and Precautions (5)].

DEXTENZA was studied in three randomized, vehicle-controlled studies (n = 351). The mean age of the population was 68 years (range 43 to 87 years), 62% were female, and 85% were white. Forty-six percent had brown iris color and 31% had blue iris color. The most common ocular adverse reactions that occurred in patients treated with DEXTENZA were: anterior chamber inflammation including iritis and iridocyclitis (9%); intraocular pressure increased (5%); visual acuity reduced (2%); eye pain (1%); cystoid macular edema (1%); corneal edema (1%); and conjunctival hyperemia (1%).

The most common non-ocular adverse reaction that occurred in patients treated with DEXTENZA was headache (1%).

8 USE IN SPECIFIC POPULATIONS

8.1 Pregnancy

Risk Summary

There are no adequate or well-controlled studies with DEXTENZA in pregnant women to inform a drug-associated risk for major birth defects and miscarriage. In animal reproduction studies, administration of topical ocular dexamethasone to pregnant mice and rabbits during organogenesis produced embryofetal lethality, cleft palate and multiple visceral malformations [see Animal Data].

Data

Animal Data

Topical ocular administration of 0.15% dexamethasone (0.75 mg/kg/day) on gestational days 10 to 13 produced embryofetal lethality and a high incidence of cleft palate in a mouse study. A daily dose of 0.75 mg/kg/day in the mouse is approximately 5 times the entire dose of dexamethasone in the DEXTENZA product, on a mg/m² basis. In a rabbit study, topical ocular administration of 0.1% dexamethasone throughout organogenesis (0.36 mg/day, on gestational day 6 followed by 0.24 mg/day on gestational days 7-18) produced intestinal anomalies, intestinal aplasia, gastroschisis and hypoplastic kidneys. A daily dose of 0.24 mg/day is approximately 6 times the entire dose of dexamethasone in the DEXTENZA product, on a mg/m² basis.

8.2 Lactation

Systemically administered corticosteroids appear in human milk and could suppress growth and interfere with endogenous corticosteroid production; however the systemic concentration of dexamethasone following administration of DEXTENZA is low [see Clinical Pharmacology (12.3)]. There is no information regarding the presence of DEXTENZA in human milk, the effects of the drug on the breastfed infant or the effects of the drug on milk production to inform risk of DEXTENZA to an infant during lactation. The developmental and health benefits of breastfeeding should be considered along with the mother's clinical need for DEXTENZA and any potential adverse effects on the breastfed child from DEXTENZA.

8.4 Pediatric Use

Safety and effectiveness in pediatric patients have not been established.

8.5 Geriatric Use

No overall differences in safety or effectiveness have been observed between elderly and younger patients.

17 PATIENT COUNSELING INFORMATION

Advise patients to consult their surgeon if pain, redness, or itching develops.

Ocular
Therapeutix™

MANUFACTURED FOR:

Ocular Therapeutix, Inc.
Bedford, MA 01730 USA
PP-US-DX-0072

(Continued from p. 6)

ucts that are intended to be sterile until the company shows it has complied with the Federal Food, Drug, and Cosmetic Act and other requirements.

According to an announcement of the decision by the FDA, the agency inspected Guardian in 2016 and, as a result, issued the pharmacy a warning letter for unsanitary conditions, among other FD&C Act violations. Then, in 2017, the FDA received adverse event reports regarding at least 43 patients who received ocular injections of a drug compounded by Guardian containing triamcinolone and moxifloxacin during cataract surgery. The patients reportedly suffered symptoms that included decreased vision, poor night vision, loss of color vision and reductions in best-corrected vision. Upon investigation, the FDA says it found a high percentage of an excipient, poloxamer 407, and the presence of potential process-degradation products in the compounded drug.

The current consent decree requires Guardian to stop sterile operations until it takes corrective action such as hiring a qualified independent expert to inspect its operation, establishes a comprehensive quality control program and receives authorization from the FDA to resume operating.

Companies Hope Success is in the Genes

In a mini feeding frenzy of sorts, spurred by the potential of gene therapy, Roche agreed to purchase Luxturna-maker Spark Therapeutics in February for approximately \$4.3 billion, and in March Biogen announced that it's buying gene-therapy maker Nightstar for about \$877 million.

According to an official statement by Roche, in addition to the already approved Luxturna, a one-time gene therapy for biallelic RPE65 mutation-associated retinal dystrophy, Spark Therapeutics' lead clinical asset is SPK-8011, a novel gene therapy for the treatment of haemophilia A, which is expected to start a Phase III clinical trial in 2019.

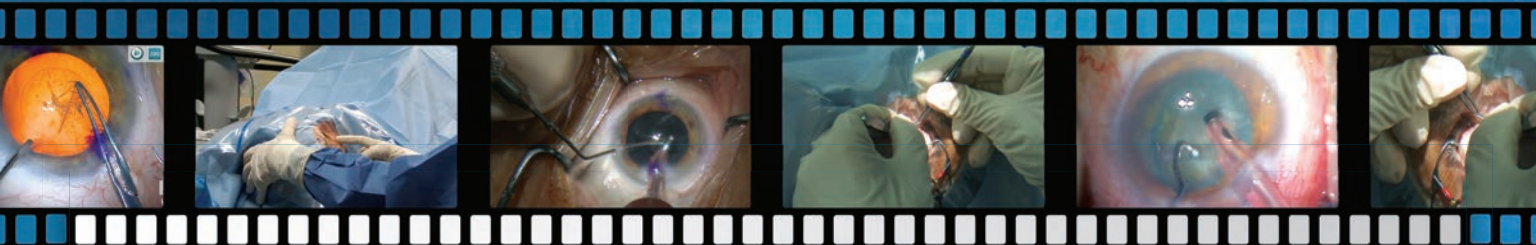
Nightstar's lead candidate is the adeno-associated viral vector-based therapy NSR-REP1, a gene therapy for the treatment of choroideremia, a rare, X-linked genetic retinal disorder that currently has no treatment. NSR-REP1 is currently in a Phase III trial. The company has other potential treatments in the works as well, including gene therapies targeting X-linked retinitis pigmentosa and Stargardt's disease. **REVIEW**



Monthly

MACKOOL ONLINE CME

CME SERIES | SURGICAL VIDEOS



To view CME video
go to:

www.MackoolOnlineCME.com

Episode 40: "A Systematic Approach to a Difficult Eye"

Surgical Video by:
Richard J. Mackool, MD

Video Overview:

When the goal is to implant a toric IOL in an eye with recurring bouts of uveitis, poster synechiae, an extremely shallow chamber and a previous iridectomy, a step-by-step approach is required. Here I demonstrate my approach including a pars plana vitrectomy to first deepen the anterior chamber.

MackoolOnlineCME.com MONTHLY Video Series



Richard J. Mackool, MD

We are excited to continue into our fourth year of Mackool Online CME. With the generous support of several ophthalmic companies, I am honored to have our viewers join me in the operating room as I demonstrate the technology and techniques that I have found to be most valuable, and that I hope are helpful to many of my colleagues. We continue to edit the videos only to either change camera perspective or to reduce down time - allowing you to observe every step of the procedure.

As before, one new surgical video will be released monthly, and physicians may earn CME credits or just observe the case. New viewers are able to obtain additional CME credit by reviewing previous videos that are located in our archives.

I thank the many surgeons who have told us that they have found our CME program to be interesting and instructive; I appreciate your comments, suggestions and questions. Thanks again for joining us on Mackool Online CME.



CME Accredited Surgical Training Videos Now Available Online: www.MackoolOnlineCME.com

Richard Mackool, MD, a world renowned anterior segment ophthalmic microsurgeon, has assembled a web-based video collection of surgical cases that encompass both routine and challenging cases, demonstrating both familiar and potentially unfamiliar surgical techniques using a variety of instrumentation and settings.

This educational activity aims to present a series of Dr. Mackool's surgical videos, carefully selected to address the specific learning objectives of this activity, with the goal of making surgical training available as needed online for surgeons motivated to improve or expand their surgical repertoire.

Learning Objective:

After completion of this educational activity, participants should be able to:

- incorporate techniques for deepening the anterior chamber and enlarging a miotic pupil in a post-uveitis eye with posterior synechiae, circumferential pupillary membrane and shallow chamber into their practice

Satisfactory Completion - Learners must pass a post-test and complete an evaluation form to receive a certificate of completion. You must listen to/view the entire video as partial credit is not available. If you are seeking continuing education credit for a specialty not listed below, it is your responsibility to contact your licensing/certification board to determine course eligibility for your licensing/certification requirement.



JOINTLY ACCREDITED PROVIDER™
INTERPROFESSIONAL CONTINUING EDUCATION

Physicians - In support of improving patient care, this activity has been planned and implemented by Amedco LLC and Postgraduate Healthcare Education. Amedco LLC is jointly accredited by the Accreditation Council for Continuing Medical Education (ACCME), the Accreditation Council for Pharmacy Education (ACPE), and the American Nurses Credentialing Center (ANCC), to provide continuing education for the healthcare team

Credit Designation Statement - Amedco designates this enduring material activity for a maximum of .25 AMA PRA Category 1 Credits™. Physicians should claim only the credit commensurate with the extent of their participation in the activity.

Endorsed by:
Review of Ophthalmology®
Video and Web Production by:
JR Snowdon, Inc

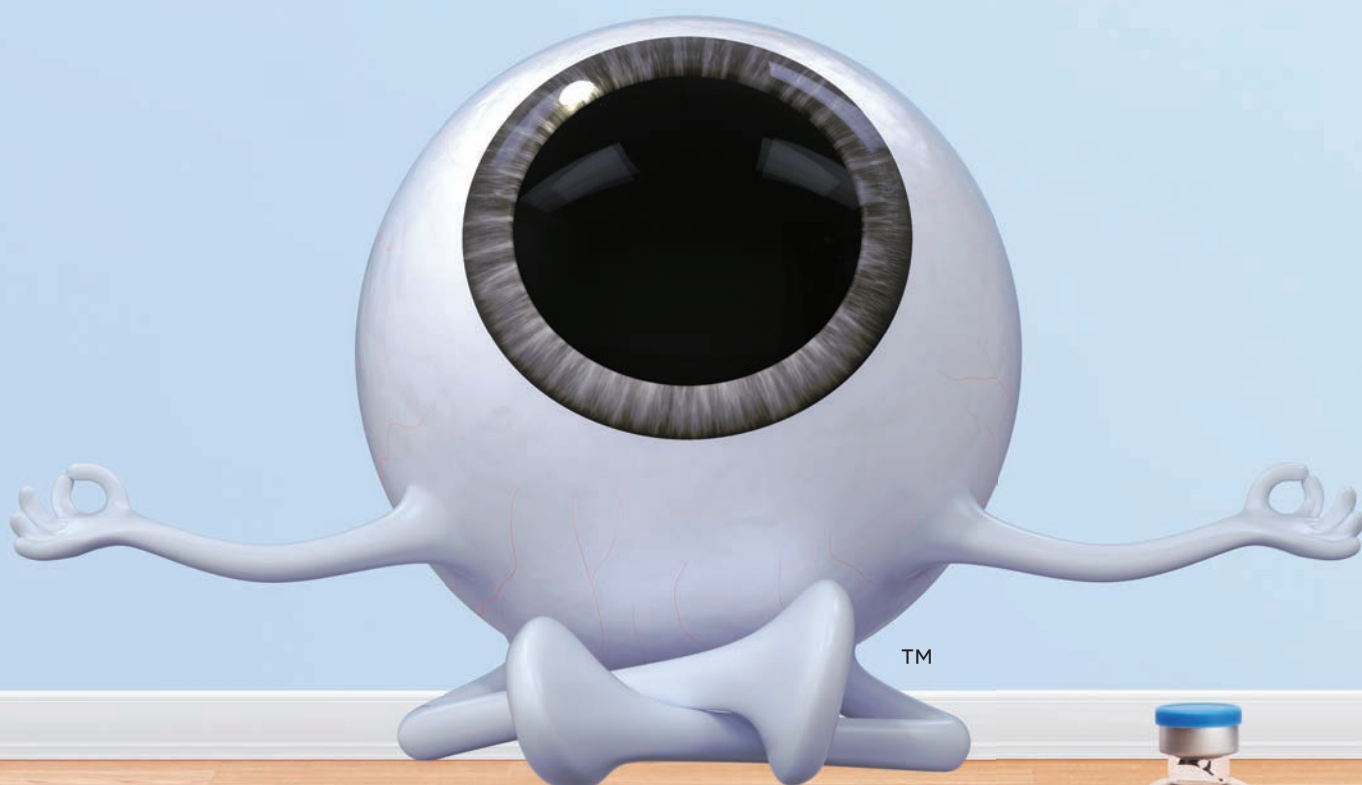
Jointly provided by:
AMEDCO & PHE

Supported by an unrestricted independent
medical educational grant from:
Alcon

Additionally Supported by:
**Glaukos
MST
Crestpoint Management
Carl Zeiss Meditec**

In Kind Support:
**Sony Healthcare
Solutions**

Less stress, pure success ...in your O.R. day¹



References: 1. Omeros survey data on file. 2. Silverstein SM, Rana V, Stephens R, Segars L, Pankratz J, Shivani R, et al. Effect of phenylephrine 1.0%-ketorolac 0.3% injection on tamsulosin-associated intraoperative floppy-iris syndrome. *J Cataract Refract Surg.* 2018;44(9):1103-1108. 3. Rosenberg ED, Nattis AS, Alevi D, et al. Visual outcomes, efficacy, and surgical complications associated with intracameral phenylephrine 1.0%/ketorolac 0.3% administered during cataract surgery. *Clin Ophthalmol.* 2018;12:21-28. 4. Buccì FA Jr, Michalek B, Fluet AT. Comparison of the frequency of use of a pupil expansion device with and without an intracameral phenylephrine and ketorolac injection 1%/0.3% at the time of routine cataract surgery. *Clin Ophthalmol.* 2017;11:1039-1043. 5. Visco D. Effect of phenylephrine/ketorolac on iris fixation ring use and surgical times in patients at risk of intraoperative miosis. *Clin Ophthalmol.* 2018;12:301-305. 6. Walter K, Delwadia N. Miosis prevention in femtosecond cataract surgery using a continuous infusion of phenylephrine and ketorolac. Presented at: 2018 American Society of Cataract and Refractive Surgery (ASCRS) and American Society of Ophthalmic Administrators (ASOA) Annual Meeting; April 13-17, 2018; Washington, DC. 7. Matossian C. Clinical outcomes of phenylephrine/ketorolac vs. epinephrine in cataract surgery in a real-world setting. Presented at: American Society of Cataract and Refractive Surgery (ASCRS) and American Society of Ophthalmic Administrators (ASOA) Annual Meeting; April 13-17, 2018; Washington, DC. 8. Al-Hashimi S, Donaldson K, Davidson R, et al. Medical and surgical management of the small pupil during cataract surgery. *J Cataract Refract Surg.* 2018;44:1032-1041. 9. Gayton JL. E-poster presented at: 15th International Congress on Vision Science and Eye; 2017 Aug 10-11; London, UK. 10. Katsev DA, Katsev CC, Pinnow J, Lockhart CM. Intracameral ketorolac concentration at the beginning and end of cataract surgery following preoperative topical ketorolac administration. *Clin Ophthalmol.* 2017;11:1897-1901. 11. Waterbury LD. Alternative drug delivery for patients undergoing cataract surgery as demonstrated in a canine model. *J Ocul Pharmacol Ther.* 2018;34:154-160. 12. Visco D, et al. Study to evaluate patient outcomes following cataract surgery when using OMIDRIA with postoperative topical NSAID administration versus a standard regimen of postoperative topical NSAIDs and steroids. Presented at: 28th Annual Meeting of the American College of Eye Surgeons (ACES), the American Board of Eye Surgery (ABES), and the Society for Excellence in Eyecare (SEE), Caribbean Eye Meeting; February 1-5, 2019; Cancùn, Mexico. 13. OMIDRIA [package insert]. Seattle, WA: Omeros Corporation; 2017.

OMIDRIA® (phenylephrine and ketorolac intraocular solution) 1% / 0.3% is added to ophthalmic irrigating solution used during cataract surgery or intraocular lens replacement and is indicated for maintaining pupil size by preventing intraoperative miosis and reducing postoperative ocular pain.

The data are compelling and consistent—OMIDRIA makes cataract surgery better for you and your patients

Published and presented clinical studies and manuscripts in press and/or in preparation report that in post-launch (i.e., not included in current labeling), prospective and retrospective, double-masked and open-label, cohort and case-controlled, single- and multi-center analyses, the use of OMIDRIA, compared to the surgeons' standard of care, statistically significantly:

- Prevents Intraoperative Floppy Iris Syndrome (IFIS)²
- Reduces complication rates (epinephrine comparator)³
- Decreases use of pupil-expanding devices (epinephrine comparator)³⁻⁸
- Reduces surgical times (epinephrine comparator)^{3,5,7,8}
- Prevents miosis during femtosecond laser-assisted surgery (epinephrine comparator)^{6,9}
- Improves uncorrected visual acuity on day after surgery (epinephrine comparator)³
- Delivers NSAID to the anterior chamber and related structures better than routine preoperative topical drug administration, resulting in effectively complete postoperative inhibition of COX-1 and COX-2^{10,11}
- Reduces the incidence of rebound iritis, postoperative pain/photophobia, and cystoid macular edema (CME) in patients without preoperative vitreomacular traction (VMT), when used with a postoperative topical NSAID (compared to postoperative topical NSAID + corticosteroid without OMIDRIA)¹²

OMIDRIA inhibits prostaglandin release, reducing intraoperative inflammation, to prevent miosis and reduce postoperative pain¹³

OMIDRIA is separately reimbursed under Medicare Part B and by many Medicare Advantage and commercial payers.*

Contact your OMIDRIA representative today or visit omidria.com to learn more.

*Based on currently available information and subject to change without notice. Individual plan coverage, policies, and procedures may vary and should be confirmed. Omeros does not guarantee coverage or payment.

IMPORTANT SAFETY INFORMATION

OMIDRIA must be added to irrigating solution prior to intraocular use.

OMIDRIA is contraindicated in patients with a known hypersensitivity to any of its ingredients.

Systemic exposure of phenylephrine may cause elevations in blood pressure.

Use OMIDRIA with caution in individuals who have previously exhibited sensitivities to acetylsalicylic acid, phenylacetic acid derivatives, and other nonsteroidal anti-inflammatory drugs (NSAIDs), or have a past medical history of asthma.

The most commonly reported adverse reactions at $\geq 2\%$ are eye irritation, posterior capsule opacification, increased intraocular pressure, and anterior chamber inflammation.

Please see the Full Prescribing Information for OMIDRIA at www.omidria.com/prescribinginformation.

You are encouraged to report Suspected Adverse Reactions to the FDA. Visit www.fda.gov/medwatch, or call 1-800-FDA-1088.

OMIDRIA® and the OMIDRIA logo® are registered trademarks of Omeros Corporation.
© Omeros Corporation 2019, all rights reserved. 2019-007

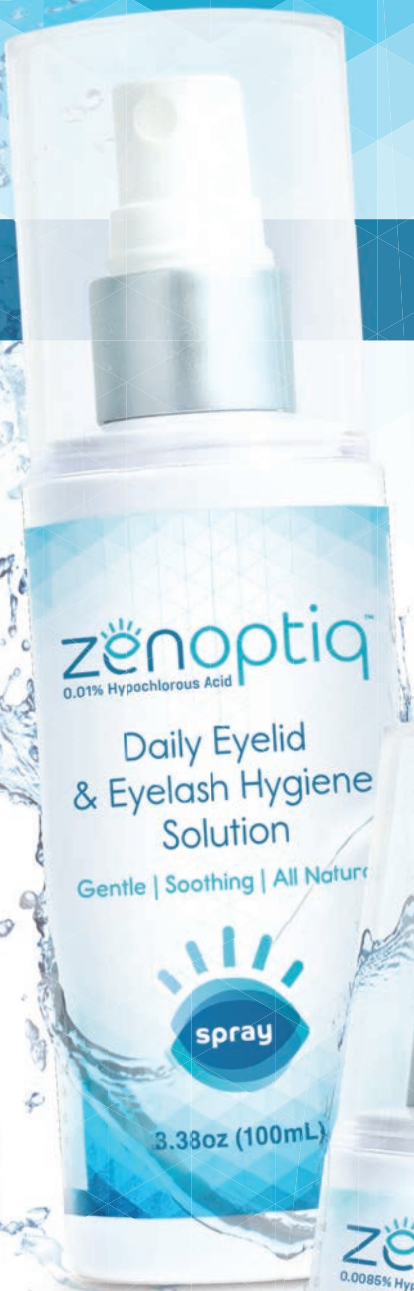

OMIDRIA®

(phenylephrine and ketorolac
intraocular solution)
1% / 0.3%

Hypochlorous Acid Solution
NOW Available *Without* a Prescription

zenoptiq™
Hypochlorous Acid Solution



Daily Eyelid & Eyelash Cleanser

- Naturally removes foreign matter
- Nontoxic, nonirritating
- Has been shown in studies to reduce bacteria/microbes
- Formulated to relieve symptoms of MGD, Blepharitis and Dry Eye
- Available in 0.01 % HOCL spray and 0.085% HOCL gel

LEARN MORE AT
zenoptiq.com



(866) 752-6006 – FocusLaboratories.com

Trademarks: Zenoptiq™ (Paragon BioTeck, Inc.) | Copyright © 2018 Paragon BioTeck, Inc. All Rights Reserved.

FLM191-0119-01

REVIEW[®] of Ophthalmology

April 2019 • Volume XXV No. 4 | reviewofophthalmology.com

Cover Focus

30 | **Premium IOLs: Dealing with Postop Problems**

Christopher Kent, Senior Editor

Problems can still arise with advanced IOLs. Here's help.

40 | **Peel Back the Veil on ERM Management**

Michelle Stephenson, Contributing Editor

Experts weigh in on diagnosis, as well as the timing of the ERM procedure.

54 | **MSICS and miLoop for Non-phaco Candidates**

Alexandra Skinner, Associate Editor

What to do when the gold standard, phaco, isn't an option.

Features

44 | **The Continuing Role of Lasers in PDR**

Kristine Brennan, Contributing Editor

Though anti-VEGF is effective, experts say it still may be best to start with PRP in some patients.

48 | **The Artificial Iris in Practice**

Christopher Kent, Senior Editor

The first approved iris prosthesis is helping many patients—although it has limitations.

Departments

3 | [Review News](#)

16 | [Technology Update](#)

The Evolution of Portable Visual Field Tests

Innovation is making it easier to test visual function at home using portable and/or virtual reality tech.



26 | [Plastic Pointers](#)

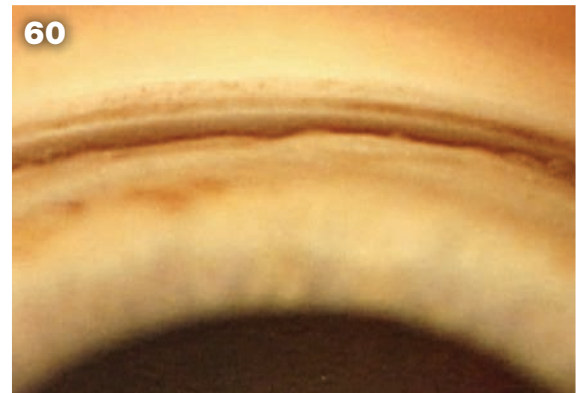
Managing the Anophthalmic Socket

How to treat the anophthalmic patient when he presents with problems related to his implant.

60 | [Glaucoma Management](#)

Diagnosing Angle Closure: Gonioscopy vs. OCT

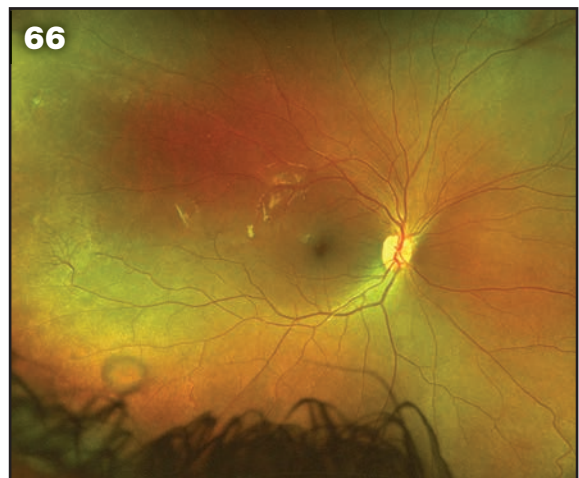
Both approaches offer advantages, but gonioscopy remains the gold standard.



66 | [Retinal Insider](#)

Be Prepared for Pediatric Patients

Pediatric retina patients' ocular anatomy can pose unique challenges.



69 | [Classifieds](#)

69 | [Ad Index](#)

70 | [Research Review](#)

Researchers Delve into Orbital Lymphoma

71 | [Wills Eye Resident Case Series](#)

iStent
inject®

TRANSFORMING MIGS IN MORE WAYS THAN ONE.

Optimized Outflow: Two multi-directional stents designed to restore natural outflow

Clinically Proven: Significant IOP reduction across a wide range of clinical studies^{1,2}

Procedural Elegance: Predictability and precision to meet the needs of your practice

Proven Safety: Safety profile similar to cataract surgery alone¹



ASCRS BOOTH 3145

All with the exceptional customer support you've come to expect from Glaukos.

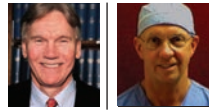TransformMIGS.com | 800.GLAUKOS (452.8567)

INDICATION FOR USE. The iStent *inject*® Trabecular Micro-Bypass System Model G2-M-IS is indicated for use in conjunction with cataract surgery for the reduction of intraocular pressure (IOP) in adult patients with mild to moderate primary open-angle glaucoma. **CONTRAINDICATIONS.** The iStent *inject* is contraindicated in eyes with angle-closure glaucoma, traumatic, malignant, uveitic, or neovascular glaucoma, discernible congenital anomalies of the anterior chamber (AC) angle, retrolubar tumor, thyroid eye disease, or Sturge-Weber Syndrome or any other type of condition that may cause elevated episcleral venous pressure. **WARNINGS.** Gonioscopy should be performed prior to surgery to exclude congenital anomalies of the angle, PAS, rubeosis, or conditions that would prohibit adequate visualization of the angle that could lead to improper placement of the stent and pose a hazard. **MRI INFORMATION.** The iStent *inject* is MR-Conditional, i.e., the device is safe for use in a specified MR environment under specified conditions; please see Directions for Use (DFU) label for details. **PRECAUTIONS.** The surgeon should monitor the patient postoperatively for proper maintenance of IOP. The safety and effectiveness of the iStent *inject* have not been established as an alternative to the primary treatment of glaucoma with medications, in children, in eyes with significant prior trauma, abnormal anterior segment, chronic inflammation, prior glaucoma surgery (except SLT performed > 90 days preoperative), glaucoma associated with vascular disorders, pseudoexfoliative, pigmentary or other secondary open-angle glaucomas, pseudophakic eyes, phakic eyes without concomitant cataract surgery or with complicated cataract surgery, eyes with medicated IOP > 24 mmHg or unmedicated IOP < 21 mmHg or > 36 mmHg, or for implantation of more or less than two stents. **ADVERSE EVENTS.** Common postoperative adverse events reported in the randomized pivotal trial included stent obstruction (6.2%), intraocular inflammation (5.7% for iStent *inject* vs. 4.2% for cataract surgery only), secondary surgical intervention (5.4% vs. 5.0%) and BCVA loss \geq 2 lines \geq 3 months (2.6% vs. 4.2%). **CAUTION:** Federal law restricts this device to sale by, or on the order of, a physician. Please see DFU for a complete list of contraindications, warnings, precautions, and adverse events.

REFERENCES: 1. iStent *inject*® Trabecular Micro-Bypass System: Directions for Use, Part #45-0176. 2. Hengerer FH. Personal experience with second-generation trabecular micro-bypass stents in combination with cataract surgery in patients with glaucoma: 3-year follow-up. ASCRS 2018 Presentation.

© 2018 Glaukos Corporation. Glaukos and iStent *inject* are registered trademarks of Glaukos Corporation. PM-US-0026

GLAUKOS®
Transforming Glaucoma Therapy



The Evolution of Portable Visual Field Testing

Innovative technology is making it easier to check visual function at home using portable and virtual methods.

Robert Chang, MD, Palo Alto, Calif.

The idea of testing visual fields outside the office isn't new. However, novel technology is making it easier to check visual function more reliably at home. Ideally, this would facilitate monitoring of presumed stable or controlled glaucoma patients or suspects, to reduce the overall number of office visits per year. Innovative solutions have shifted from internet and desktop-based testing to more portable and virtual methods that help to reduce fixation losses, improve engagement and possibly help reshape the paradigm of repeatable visual field testing—especially in low-resource settings. Here's a look at the current state of “at-home” visual field testing.

The Benefits

While visual fields remain the gold standard for monitoring visual function, the perimetry machine is a large, carefully calibrated bowl that's mostly used in an

office setting and is typically administered by a perimetrist to help patients maintain focus. Unfortunately, this gold-standard medical test, which is highly subjective, can't be repeated as often as physicians would like. There are problems with patient attention, fatigue, comprehension, boredom, etc., and typically, patients only perform one or two fields per year in the office (or even fewer if lost to follow-up). Thus it would be nice to have a way for patients to test themselves at their own

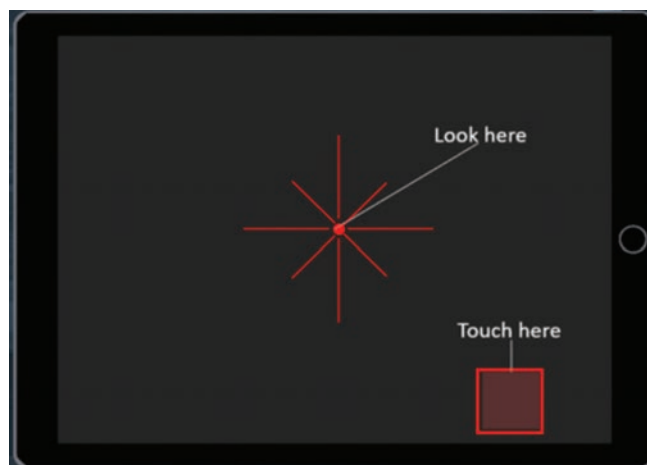
convenience to fill in the gaps.

The additional data would be useful in two main situations:

- for reassurance that a glaucoma suspect is still normal; and
- to assess whether a glaucoma patient is progressing.

Of course, office examination would likely still be needed for confirmatory testing and treatment recommendations, but a faster, easier self-administered test outside the office could be used as a screening method to help determine when patients need to return to the specialist.

GLANCE Optical



Melbourne Rapid Fields is an iPad app that uses a moving fixation target to test up to 30 degrees of field.

Many glaucoma patients routinely see the doctor on a schedule, every three, six or 12 months, depending on the level of risk or stage of disease. At-home testing affords the possibility of remote monitoring and enabling tele-glaucoma care.

A Potential Disadvantage?

Visual fields alone, whether done in-office or

INVELTYS

The **first and only** corticosteroid
FDA approved for **BID treatment**
of post-operative inflammation and pain
following ocular surgery



BID STRONG

Powered by **AMPPLIFY™ Drug Delivery Technology**

Indication

INVELTYS (loteprednol etabonate ophthalmic suspension) 1% is indicated for the treatment of post-operative inflammation and pain following ocular surgery.

Important Safety Information

INVELTYS is contraindicated in most viral diseases of the cornea and conjunctiva including epithelial herpes simplex keratitis (dendritic keratitis), vaccinia, and varicella, and also in mycobacterial infection of the eye and fungal diseases of ocular structures.

Prolonged use of corticosteroids may result in glaucoma with damage to the optic nerve, defects in visual acuity and fields of vision. If this product is used for 10 days or longer, IOP should be monitored.

Use of corticosteroids may result in posterior subcapsular cataract formation.

Use of steroids after cataract surgery may delay healing and increase the incidence of bleb formation. In those diseases causing thinning of the cornea or sclera, perforations have been known to occur with the use of topical steroids. The initial prescription and renewal of the medication order should be made by a physician only after examination of the patient with the aid of magnification such as slit lamp biomicroscopy and, where appropriate, fluorescein staining.

Prolonged use of corticosteroids may suppress the host response and thus increase the hazard of secondary ocular infections. In acute purulent conditions, steroids may mask infection or enhance existing infection.

Use of a corticosteroid medication in the treatment of patients with a history of herpes simplex requires great caution. Use of ocular steroids may prolong the course and may exacerbate the severity of many viral infections of the eye (including herpes simplex).

Fungal infections of the cornea are particularly prone to develop coincidentally with long-term local steroid application. Fungus invasion must be considered in any persistent corneal ulceration where a steroid has been used or is in use.

In clinical trials, the most common adverse drug reactions were eye pain (1%) and posterior capsular opacification (1%). These reactions may have been the consequence of the surgical procedure.

Please see Brief Summary of Prescribing Information for INVELTYS on the next page.

INVELTYS™

(loteprednol etabonate
ophthalmic suspension) 1%

**INVELTYS™ (loteprednol etabonate ophthalmic suspension) 1%,
for topical ophthalmic use**

BRIEF SUMMARY OF FULL PRESCRIBING INFORMATION

INDICATIONS AND USAGE

INVELTYS is a corticosteroid indicated for the treatment of post-operative inflammation and pain following ocular surgery.

CONTRAINDICATIONS

INVELTYS is contraindicated in most viral diseases of the cornea and conjunctiva including epithelial herpes simplex keratitis (dendritic keratitis), vaccinia, and varicella, and also in mycobacterial infection of the eye and fungal diseases of ocular structures.

WARNINGS AND PRECAUTIONS

Intraocular Pressure (IOP) Increase—Prolonged use of corticosteroids may result in glaucoma with damage to the optic nerve, as well as defects in visual acuity and fields of vision. Steroids should be used with caution in the presence of glaucoma. If this product is used for 10 days or longer, intraocular pressure should be monitored.

Cataracts—Use of corticosteroids may result in posterior subcapsular cataract formation.

Delayed Healing—Use of steroids after cataract surgery may delay healing and increase the incidence of bleb formation. In those diseases causing thinning of the cornea or sclera, perforations have been known to occur with the use of topical steroids. The initial prescription and renewal of the medication order should be made by a physician only after examination of the patient with the aid of magnification such as slit lamp biomicroscopy and, where appropriate, fluorescein staining.

Bacterial Infections—Prolonged use of corticosteroids may suppress the host response and thus increase the hazard of secondary ocular infections. In acute purulent conditions of the eye, steroids may mask infection or enhance existing infection.

Viral Infections—Use of corticosteroid medication in the treatment of patients with a history of herpes simplex requires great caution. Use of ocular steroids may prolong the course and may exacerbate the severity of many viral infections of the eye (including herpes simplex).

Fungal Infections—Fungal infections of the cornea are particularly prone to develop coincidentally with long-term local steroid application. Fungus invasion must be considered in any persistent corneal ulceration where a steroid has been used or is in use. Fungal cultures should be taken when appropriate.

Contact Lens Wear—The preservative in INVELTYS may be absorbed by soft contact lenses. Contact lenses should be removed prior to instillation of INVELTYS and may be reinserted 15 minutes following administration.

ADVERSE REACTIONS

Adverse reactions associated with ophthalmic steroids include elevated intraocular pressure, which may be associated with infrequent optic nerve damage, visual acuity and field defects, posterior subcapsular cataract formation, delayed wound healing and secondary ocular infection from pathogens including herpes simplex, and perforation of the globe where there is thinning of the cornea or sclera.

Clinical Trial Experience—Because clinical trials are conducted under widely varying conditions, adverse reaction rates observed in the clinical trials of a drug cannot be directly compared to rates in the clinical trials of another drug and may not reflect the rates observed in practice. The most common adverse drug reactions in the clinical trials with INVELTYS were eye pain and posterior capsular opacification, both reported in 1% of patients. These reactions may have been the consequence of the surgical procedure.

USE IN SPECIFIC POPULATIONS

Pregnancy—Risk Summary: INVELTYS is not absorbed systemically following topical ophthalmic administration and maternal use is not expected to result in fetal exposure to the drug.

Lactation—Risk Summary: INVELTYS is not absorbed systemically by the mother following topical ophthalmic administration, and breastfeeding is not expected to result in exposure of the child to INVELTYS.

Pediatric Use—Safety and effectiveness in pediatric patients have not been established.

Geriatric Use—No overall differences in safety and effectiveness have been observed between elderly and younger patients.

NONCLINICAL TOXICOLOGY

Carcinogenesis, Mutagenesis, Impairment of Fertility—Long-term animal studies have not been conducted to evaluate the carcinogenic potential of loteprednol etabonate. Loteprednol etabonate was not genotoxic *in vitro* in the Ames test, the mouse lymphoma thymidine kinase (tk) assay, or in a chromosome aberration test in human lymphocytes, or *in vivo* in the single dose mouse micronucleus assay.

For a copy of the Full Prescribing Information, please visit www.INVELTYS.com.

Manufactured for:
Kala Pharmaceuticals, Inc. Waltham, MA 02453
Marks designated by TM and © are owned by
Kala Pharmaceuticals, Inc.
Patented. See www.kalarx.com/patents
© 2018 Kala Pharmaceuticals, Inc. All rights reserved.
US-INV-1800055 December 2018

at home, normally don't provide enough clinical data to manage glaucoma patients, despite serving as a clinical endpoint. Specialists also review glaucoma risk factors, optic nerve appearance, intraocular pressure, structural macular and nerve fiber layer imaging, and a complete eye exam. If portable visual field data were relied upon to make the diagnosis of progression, the diagnosis might come too late, as glaucoma is irreversible and identification of progression prior to field loss is optimal. With that in mind, it's imperative to continue to examine a glaucoma patient at regularly scheduled office visit intervals. Furthermore, sometimes too much additional data results in noise, creates additional work interpreting test results, and may even be more costly, if there's overtesting.



A limitation of using portable devices to perform VF testing is the inability to control fixation and the distance from the eye to the screen. Virtual reality headsets may solve those issues through adjustable fixation using gaze tracking.

Artificial Intelligence

Researchers are exploring how to apply artificial intelligence algorithms to all sorts of ophthalmic test results, with most of the recent excitement centering on deep learning. Multiple publications have analyzed automation of visual field interpretation for the detection of glaucoma.¹⁻⁴

While physicians currently plot VF glaucoma progression analysis using a visual function index for event-based and trend-based progression analysis relative to a normative data-

base, one can imagine that with more data, the algorithms could optimize comparison of patients with similar severity, or their own baseline, with better predictive analytics. Additionally, when some risk factors change, self-directed, out-of-the-office testing allows for additional, concentrated repeat testing at that time point to make a more informed decision about the timing or risk/benefit ratio of a given therapeutic intervention.

Finally, even if a lower-resolution, simple, portable test isn't as accurate as a high-resolution, in-office gold standard, there's still value in col-

lecting a high volume of lower-resolution data. Aggregating more data over a longer period of time may actually be more predictive than the smaller amount of higher-quality data that's acquired only during annual or semi-annual office visits.

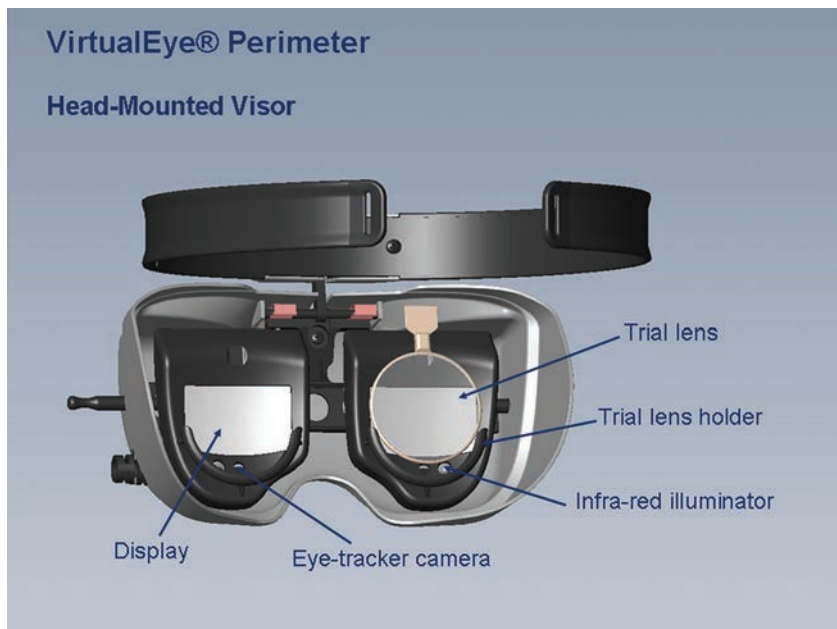
Portable Tests

Portable visual fields continue to evolve with the advent of tablets, smartphones and virtual reality headsets. Some of the most notable tests, both past and present, include the following:

- **Moorfields Motion Displacement Test.** One of the early portable visual field tests was the Moorfields Motion Displacement Test. Developed on a laptop PC, the MDT was designed for speed and patient ease of use. In the test, patients saw 32 white lines on a gray background while fixating in the center. When any of the lines moved or "wiggled," the patient

would click a button. The two-minute test could be completed without glasses and even when a cataract was present. While the MDT is no longer available, it represented the early push to move away from an office-based perimeter and onto existing computer screens, a test that could be administered both online and offline. (Other similar computerized perimetric strategies include rarebit perimetry, Peristat and campimetry.)

- **Melbourne Rapid Fields Test.** Dr. George Kong created Visual Field Easy (<https://itunes.apple.com/us/app/visualfields-easy/id495389227>), a



BioFormatix

sive environment can improve user engagement. VR headsets can take advantage of smartphones and easily test individual eyes without one needing to be patched.

There are multiple inexpensive, lightweight, mobile VR applications and software platforms that are either available or in development, such as Vivid Vision (<https://www.seevividly.com>), BioFormatix's VirtualEye Perimeter (<http://bioformatix.com/perimetry.html>), MicroMedical Devices' PalmScan VF2000 (<https://micromedinc.com/our-devices/palmscan-vf2000-visual-field-perimeter/>) and Elisar's eCloud Perimeter (<https://www.elisar.com/>). These applications can be used with a variety of input "clickers."

One early VR study by Athens' Stylianos Tsapakis and co-workers found a high correlation between the reliability of VF testing using a VR testing system they developed and the Humphrey test.⁸ The central 24 degrees of visual field were tested in 20 eyes of 10 patients using VR glasses, a smartphone with a 6-inch display and software that implemented a fast-threshold 3-dB step staircase algorithm. The results were compared to those using the Humphrey perimeter test on the same group of patients, which resulted in a correlation coefficient of $r=0.808$ ($p<0.0001$).⁸

The next level of improvement over virtual reality visual field testing would be to eliminate the subjective aspect of clicking to indicate when a visual stimulus is seen. Could there be a way to detect a patient's response to a given stimulus via the brain, without any input? This is the goal of nGoggle, a portable brain-computer interface (like an electroencephalograph) that detects visual function through recorded electrical responses directly from the visual cortex.

(Continued on page 53)

With virtual reality, no matter where the patient looks, the stimulus can be shown relative to fixation at that moment. Gyroscopes can account for head movement, and the immersive environment can improve user engagement.

free iPad app, now known as the Melbourne Rapid Fields test. The MRF takes advantage of a moving fixation target in order to effectively increase the tablet surface area to test up to 30 degrees of field. Several published studies have validated the device as a screening tool similar to a tangent perimeter.⁵⁻⁷

MRF denoted a further shift toward portability of VF tests, thanks to the advent of iPads making software more portable. It's easy to use, inexpensive and can be used anywhere, which is a big advantage in remote locations. Over time, threshold testing strategy, stimulus size and screen contrast have been standardized across tablets.

A recent study by Australia's Selwyn Prea, BOptom, Mphil, and colleagues included 60 patients; it was conducted to compare the repeatability of the MRF vs. the Humphrey Field Analyzer SITA-standard and fast programs. The investigators found that MRF had good test-retest repeatability and that it correlated

strongly with HFA across four visits over six months.⁶

In terms of speed, MRF was similar to SITA-fast and was significantly faster than SITA-standard (MRF 4.6 ± 0.1 minutes vs. SITA-fast 4.3 ± 0.2 minutes vs. SITA-standard 6.2 ± 0.1 minutes, $p<0.001$).⁶ MRF proved to be very repeatable, with intraclass correlation coefficients (with a value of 1 being a perfect correlation) for baseline and the six-month visit being 0.98, compared to 0.95 and 0.93 for SITA-fast and SITA-standard, respectively.⁶

• **Virtual Reality Peripheral Vision Testing.** One of the major limitations of using portable devices to perform VF testing is the inability to control fixation and the distance from the eye to the screen. Virtual reality headsets solve those issues through adjustable fixation using gaze tracking. With VR, no matter where the patient looks, the stimulus can be shown relative to fixation at that moment. Gyroscopes can account for head movement, and the immer-



The Role for Vyzulta® in the Management of Open-angle Glaucoma and Ocular Hypertension

Constance Okeke, MD, MSCE

Glaucoma is a heterogeneous group of diseases that damage the optic nerve affecting an estimated 70 million people worldwide, including 2 million in the US.¹ As there are no treatment modalities available for a damaged optic nerve and no means by which to regenerate tissue or restore vision that has been lost, we continue to rely on protecting the optic nerve from the stress of elevated intraocular pressure (IOP).^{1,2} As the single treatable risk factor for glaucoma progression,²⁻⁷ elevated IOP remains the target of all current medical, surgical, or laser treatments.

IOP is necessary to give the eye its shape; excessive pressure, however, represents an imbalance in aqueous production and its outflow and poses a risk to the optic nerve. Aqueous humor originates in the ciliary body and exits the anterior chamber via two main pathways—the unconventional or uveoscleral pathway, and the conventional or trabecular pathway.⁸

The trabecular pathway—comprised of the trabecular meshwork (TM), Schlemm's canal, and adjacent tissue—is the route through which a majority of fluid is thought to leave the eye. It is IOP-responsive, ie, able to increase or decrease outflow in order to maintain healthy intraocular aqueous fluid levels and pressure.¹ Notably, the trabecular pathway has been shown to be a primary site of outflow obstruction in eyes affected by primary open-angle glaucoma (POAG).^{1,8}

Prostaglandin Analogs

Prostaglandin analogs (PGAs)—the most widely prescribed IOP-lowering agents—act mainly by increasing aqueous outflow through the uveoscleral pathway.^{9,10} A key benefit of the PGA class is that drops can be administered once daily, which is particularly valuable in the treatment of chronic conditions with low rates of medication adherence, such as glaucoma.¹¹ The PGAs are generally considered the most effective class of IOP-lowering agents,¹²⁻¹⁷ able to reduce IOP by 25% to 33% from baseline with single-agent therapy.¹⁸ They are also typically well tolerated; ocular side effects when they occur are commonly mild and tolerated.¹⁸ For many of us in clinical practice, the relationship between IOP-lowering medication tolerability and adherence is clearly evident.

Latanoprostene Bunod

What is novel about Vyzulta® (latanoprostene bunod ophthalmic solution) 0.024%, a nitric oxide (NO)-releasing prostaglandin F2 analog for the reduction of IOP in patients with OAG or ocular hypertension, is its dual mechanism of action.^{19,20} Latanoprostene bunod is metabolized into two moieties—latanoprost acid, which acts on the uveoscleral pathway, as is typical of a PGA, and butanediol mononitrate, which releases gaseous NO (Figure 1).²⁰ Both moieties are responsible for the molecule's pharmacological activities.²⁰ NO is a

INDICATION

VYZULTA® (latanoprostene bunod ophthalmic solution), 0.024% is a prostaglandin F2 analog indicated for the reduction of intraocular pressure in patients with open-angle glaucoma or ocular hypertension.

IMPORTANT SAFETY INFORMATION

- Increased pigmentation of the iris and periorbital tissue (eyelid) can occur. Iris pigmentation is likely to be permanent
- Gradual changes to eyelashes, including increased length, increased thickness, and number of eyelashes, may occur. These changes are usually reversible upon treatment discontinuation
- Use with caution in patients with a history of intraocular inflammation (iritis/uveitis). VYZULTA should generally not be used in patients with active intraocular inflammation
- Macular edema, including cystoid macular edema, has been reported during treatment with prostaglandin analogs. Use with caution in aphakic patients, in pseudophakic patients with a torn posterior lens capsule, or in patients with known risk factors for macular edema
- There have been reports of bacterial keratitis associated with the use of multiple-dose containers of topical ophthalmic products that were inadvertently contaminated by patients
- Contact lenses should be removed prior to the administration of VYZULTA and may be reinserted 15 minutes after administration
- Most common ocular adverse reactions with incidence $\geq 2\%$ are conjunctival hyperemia (6%), eye irritation (4%), eye pain (3%), and instillation site pain (2%)

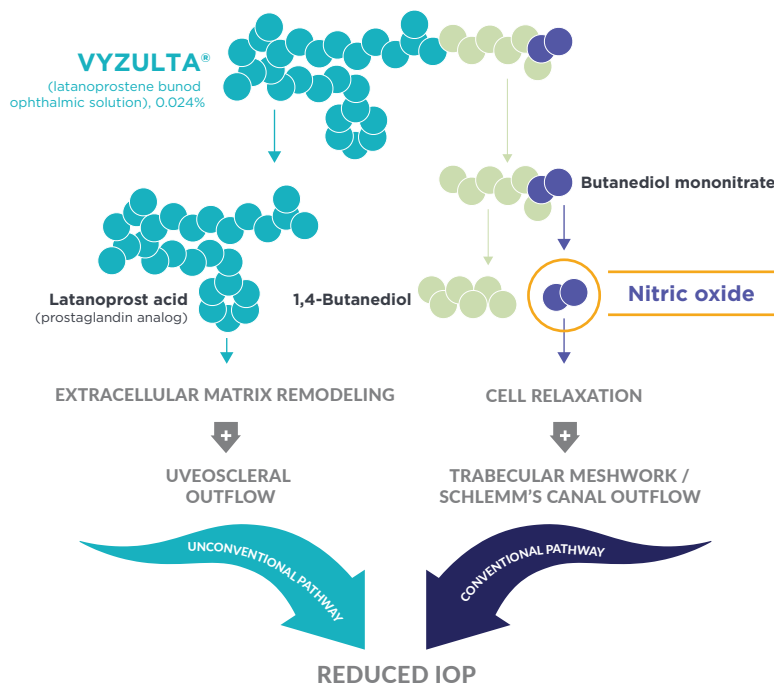


FIGURE 1

One molecule, two pathways: Vyzulta® (latanoprostene bunod ophthalmic solution 0.024%) is a nitric oxide-releasing prostaglandin F2 analog that increases both trabecular and uveoscleral outflow.

particularly exciting aspect of Vyzulta,[®] as it acts to relax the fibers of the TM along the trabecular pathway, opening a second aqueous humor escape route for lowering IOP (Figure 1).²⁰

The release of NO by Vyzulta is important, as evidence suggests that abnormal NO formation or signaling may play a role in IOP dysregulation in glaucoma.²⁰ NO is synthesized by nitric oxide synthase (NOS) in endothelial cells at various sites in the body, inducing vasodilation, gastric emptying, and other generally dilatory or relaxation-inducing functions.^{21,22} In normal eyes, endogenous NO production in Schlemm's canal plays a role in regulating IOP.²⁰ NO is a gas and cannot be directly measured due to a half-life of mere seconds;^{21,22} however, reduced aqueous humor concentrations of NO markers (eg, cGMP, NADPH, and total nitrite levels) in glaucomatous eyes supports the hypothesis that impaired NO production contributes to imbalanced aqueous dynamics and increased IOP.²¹⁻²³

NO performs its actions via the complex cGMP/protein kinase G signaling cascade, resulting in multiple downstream events including rho kinase inhibition and, ultimately, TM relaxation.^{20,24} Further research should investigate what long-term impact NO-releasing molecules such as latanoprostene bunod have on the TM in glaucomatous eyes.

Clinical Trials

In clinical studies of up to 12 months' duration in patients with OAG or ocular hypertension, the IOP-lowering effect of Vyzulta once-daily was up to 9.1 mm Hg from baseline.^{16,17,19} The two pivotal phase 3 clinical trials—APOLLO and LUNAR—evaluated the noninferiority of Vyzulta vs. timolol 0.5% in patients with OAG or ocular hypertension. In LUNAR (N = 420), IOP reduction with Vyzulta dosed once daily

at night was noninferior to that with timolol 0.5% dosed twice daily. In APOLLO (N = 420), IOP reduction with Vyzulta dosed once daily at night was superior to timolol 0.5% dosed twice daily (Table 1).^{16,17}

In VOYAGER, a phase 2, 29-day dose-ranging comparison study of subjects with OAG or ocular hypertension, Vyzulta led to a 9.0 mm Hg (34.6%) mean diurnal IOP decrease from baseline vs. 7.77 mm Hg (29.8%) decrease with latanoprost 0.005% ($P = 0.005$).²⁵ A post-hoc analysis revealed that 42% of patients treated with Vyzulta achieved at least 2 mm Hg greater IOP reduction vs. mean diurnal IOP reduction with latanoprost 0.005% (7.8 mm Hg).²⁶ In a study evaluating increasing concentrations of latanoprost in patients with OAG or ocular hypertension, no greater IOP-lowering effect was shown with concentrations higher than the clinical dose of 0.005%.²⁷ The additional IOP lowering of Vyzulta observed in the VOYAGER study is believed to be attributable to the activity of NO.²⁵

Sustained IOP reduction was observed among patients treated with Vyzulta for 52 weeks in the JUPITER study.²⁸

It was also noteworthy that Vyzulta clinical trials showed meaningful IOP reduction among patients with high and low baseline IOP. The phase 3 open-label JUPITER trial conducted in Japan followed OAG patients (including those with normal-tension glaucoma) being treated with Vyzulta for at least 12 months (N = 130).²⁸ Mean baseline IOP was 19.6 mm Hg in study eyes, and 75% of patients had IOP between 15 and 21 mm Hg.²⁸ Mean IOP reductions from baseline among Vyzulta-treated eyes were 22% at week 4 (to 15.3 mm Hg), and 26.3% at week 52.²⁸ These findings suggest that Vyzulta may

TABLE I Change from baseline in mean IOP in APOLLO and LUNAR study

	Week 2			Week 6			Month 3		
	8 am	12 pm	4 pm	8 am	12 pm	4 pm	8 am	12 pm	4 pm
APOLLO									
LBN mean CFB (mm Hg)	-9.0	-8.5	-7.7	-9.1	-7.9	-9.0	-8.7	-7.9	
Timolol mean CFB (mm Hg)	-7.8	-7.2	-6.6	-8.0	-7.4	-6.7	-7.9	-7.4	-6.6
Treatment difference	-1.21	-1.37	-1.11	-1.03	-1.24	-1.26	-1.02	-1.27	-1.33
P value	<0.001	<0.001	<0.001	<0.002	<0.001	<0.001	<0.002	<0.001	<0.001
LUNAR									
LBN mean CFB (mm Hg)	-8.3	-8.1	-7.5	-8.8	-8.5	-7.8	-8.8	-8.6	-7.9
Timolol mean CFB (mm Hg)	-7.9	-7.3	-6.9	-7.9	-7.7	-6.8	-7.9	-7.4	-6.6
Treatment difference	-0.44	-0.76	-0.69	-0.92	-0.84	-0.98	-0.88	-1.29	-1.34
P value	0.216	0.022	0.025	0.005	0.007	0.003	0.006	<0.001	<0.001

be effective in patients with lower baseline IOP, which is typically harder to treat. Durable IOP reduction over 1 year on Vyzulta® is also encouraging.

Importantly, in addition to robust efficacy, Vyzulta has an acceptable safety profile.^{16,17,28} In the LUNAR and APOLLO studies, the most common ocular adverse events observed were conjunctival hyperemia (6%), eye irritation (4%), eye pain (3%), and instillation site pain (2%); the rate of study discontinuation due to an ocular adverse event was 0.6%.¹⁹ In the JUPITER trial over 52 weeks, 1 patient of 130 (0.8%) dropped out of the study due to an ocular adverse event, which was related to a cataract and considered unrelated to treatment.²⁸

Vyzulta in Clinical Practice

In my view, Vyzulta warrants utmost consideration for IOP-lowering treatment in the following four clinical scenarios or patient types. First, Vyzulta could be a good first-line agent for a wide range of patients with OAG or ocular hypertension across a range of starting IOPs. For example, a treatment-naïve patient who presents with IOP with 30 mm Hg or higher could be treated with Vyzulta first line and monitored for effect.

Second, established patients who are not responding to current treatment with another IOP-lowering agent, such as timolol or latanoprost, may benefit from Vyzulta in an effort to achieve a lower IOP over the short and long term. As discussed above, in clinical trials, once-daily Vyzulta was superior to twice-daily timolol at month 3^{16,17} and superior to latanoprost.²⁵ Vyzulta has the potential to reduce IOP while maintaining the benefits of monotherapy. It's important to remember that any increment of IOP lowering is clinically meaningful. Research has shown that for every 1 mm Hg IOP reduction, risk for disease progression is reduced by 10% to 19%.^{2,3,29}

Third, patients with normal-tension glaucoma or those with low baseline IOP are good candidates for treatment with Vyzulta, as documented in a long-term clinical trial.²⁸ In patients with low baseline IOP, Vyzulta might be implemented as first-line monotherapy, as switchover monotherapy, if not achieving target IOP, or as an adjunct to medical or surgical therapy.

Fourth, glaucoma patients in adult early stage comprise a group with the potential to benefit from treatment with Vyzulta because Vyzulta is the first NO-releasing PGA with action at the TM.¹⁸ Sustained IOP reduction was observed among patients treated with Vyzulta for 52 weeks in the JUPITER study.²⁸ That said, I consider Vyzulta whenever IOP-lowering is needed—even if it is just a few points—irrespective of disease stage.

Talking about Novel Treatments

I find that patients are quite receptive to hearing about a novel medication that could possibly help them; and many appreciate that my practice is up to date on the most current therapeutic offerings. When counseling patients, I explain that Vyzulta has a dual mechanism of action. I mention the results of the VOYAGER study in which Vyzulta was more effective at lowering IOP than latanoprost;²⁵ so it might help to lower IOP in them. And I let them know that it is indicated for treatment of glaucoma, dosed once a day, and has an acceptable safety profile.^{16,17,19,28}

Vyzulta is remarkable not only because it was shown to be effective in clinical trials, is dosed once daily, and is novel in its mechanism of action, but also because it may impact outflow through the TM.²⁴ More will be learned as basic and clinical research continues on the topic; in the meantime, it is important to get an effective, novel medication like Vyzulta into the hands of our patients.



VYZULTA

(latanoprostene
bunod ophthalmic
solution), 0.024%



Constance Okeke, MD, MSCE, is a board certified ophthalmologist who has practiced ophthalmology since 2001. She has a specialty in glaucoma and cataract surgery and currently sees patients in private practice at Virginia Eye Consultants in Norfolk, VA. She is a Fellow of the American Academy of Ophthalmology and a member of the American Glaucoma Society and the Association for Research Vision and Ophthalmology. Dr. Okeke is a paid consultant to Bausch + Lomb.

REFERENCES

1. Goel M, Picciani RG, Lee RK, et al. Aqueous humor dynamics: a review. *Open Ophthalmol J*. 2010;4:52-9.
2. Garway-Heath DF, Crabb DP, Bunce C, et al. Latanoprost for open-angle glaucoma (UKGTS): a randomised, multicentre, placebo-controlled trial. *Lancet*. 2015;385(9975):1295-304.
3. Leske MC, Heijl A, Hussein M, et al; Early Manifest Glaucoma Trial Group. Factors for glaucoma progression and the effect of treatment: the early manifest glaucoma trial. *Arch Ophthalmol*. 2003;121(1):48-56.
4. Kass MA, Heuer DK, Higginbotham EJ, et al. The Ocular Hypertension Treatment Study: a randomized trial determines that topical ocular hypotensive medication delays or prevents the onset of primary open-angle glaucoma. *Arch Ophthalmol*. 2002;120(6):701-13.
5. Heijl A, Leske C, Bengtsson B, et al. Reduction of intraocular pressure and glaucoma progression: Results from the Early Manifest Glaucoma Trial. *Arch Ophthalmol*. 2002;120(10):1268-79.
6. The AGIS Investigators. The Advanced Glaucoma Intervention Study (AGIS): 7. The relationship between control of intraocular pressure and visual field deterioration. *Am J Ophthalmol*. 2000;130(4):429-40.
7. Collaborative Normal-Tension Glaucoma Study Group. Comparison of glaucomatous progression between untreated patients with normal-tension glaucoma and patients with therapeutically reduced intraocular pressures. *Am J Ophthalmol*. 1998;126(4):487-97.
8. Braunger BM, Fuchshofer R, Tamm ER. The aqueous humor outflow pathways in glaucoma: A unifying concept of disease mechanisms and causative treatment. *Eur J Pharm Biopharm*. 2015;95(Pt B):173-81.
9. Schachtschabel U, Lindsey JD, Weinreb RN. The mechanism of action of prostaglandins in uveoscleral outflow. *Curr Opin Ophthalmol*. 2000;11:112-5.
10. Symphony National. *Total Glaucoma Market*. July 2016-June 2017.
11. Okeke CO, Quigley HA, Jampel HD, et al. Adherence with topical glaucoma medication monitored electronically the Travatan Dosing Aid study. *Ophthalmology*. 2009;116:191-9.
12. Alm A, Stjernschantz J. Effects on intraocular pressure and side effects of 0.005% latanoprost applied once daily, evening or morning. A comparison with timolol. Scandinavian Latanoprost Study Group. *Ophthalmology*. 1995;102(12):1743-52.
13. Camras CB. Comparison of latanoprost and timolol in patients with ocular hypertension and glaucoma: a six-month masked, multicenter trial in the United States. The United States Latanoprost Study Group. *Ophthalmology*. 1996;103(1):138-47.
14. Higginbotham EJ, Schuman JS, Goldberg I, et al; Bimatoprost Study Groups 1 and 2. One-year, randomized study comparing bimatoprost and timolol in glaucoma and ocular hypertension. *Arch Ophthalmol*. 2002;120(10):1286-93.
15. Netland PA, Landry T, Sullivan EK, et al; Travoprost Study Group. Travoprost compared with latanoprost and timolol in patients with open-angle glaucoma or ocular hypertension. *Am J Ophthalmol*. 2001;132(4):472-84.
16. Weinreb RN, Scassellati Sforzolini B, Vittitow J, et al. Latanoprostene bunod 0.024% versus timolol maleate 0.5% in subjects with open-angle glaucoma or ocular hypertension: The APOLLO study. *Ophthalmology*. 2016;123(5):965-73.
17. Medeiros FA, Martin KR, Peace J, et al. Comparison of latanoprostene bunod 0.024% and timolol maleate 0.5% in open-angle glaucoma or ocular hypertension: the LUNAR study. *Am J Ophthalmol*. 2016;168:250-9.
18. Prum BE Jr, Rosenberg LF, Gedde SJ, et al. Primary Open-Angle Glaucoma Preferred Practice Pattern® Guidelines. *Ophthalmology*. 2016;123(1):41-111.
19. VYZULTA Prescribing Information. June 2018. Bausch + Lomb, Inc. Bridgewater, NJ.
20. Cavet ME, DeCory HH. The role of nitric oxide in the intraocular pressure lowering efficacy of latanoprostene bunod: review of nonclinical studies. *J Ocul Pharmacol Ther*. 2018;34:52-60.
21. Galassi F, Renieri G, Sodi A, et al. Nitric oxide proxies and ocular perfusion pressure in primary open angle glaucoma. *Br J Ophthalmol*. 2004;88:757-60.
22. Nathanson JA, McKee M. Alterations of ocular nitric oxide synthase in human glaucoma. *Invest Ophthalmol Vis Sci*. 1995;36:1774-84.
23. Doganay S, Evereklioglu C, Turkoz Y, et al. Decreased nitric oxide production in primary open-angle glaucoma. *Eur J Ophthalmol*. 2002;12:44-8.
24. Fogagnolo P, Rossetti L. Medical treatment of glaucoma: present and future. *Expert Opinion on Investigational Drugs*. 2011;20:947-59.
25. Weinreb RN, Ong T, Scassellati Sforzolini B, et al; VOYAGER study group. A randomised, controlled comparison of latanoprostene bunod and latanoprost 0.005% in the treatment of ocular hypertension and open angle glaucoma: the VOYAGER study. *Br J Ophthalmol*. 2015;99(6):738-45.
26. Data on File. Bausch & Lomb Incorporated.
27. Eveleth D, Starita C, Tressler C. A 4-week, dose-ranging study comparing the efficacy, safety and tolerability of latanoprost 75, 100 and 125 mg/mL to latanoprost 50 mg/mL (Xalatan) in the treatment of primary open-angle glaucoma and ocular hypertension. *BMC Ophthalmol*. 2012;12:9.
28. Kawase K, Vittitow JL, Weinreb RN, Araie M; JUPITER Study Group. Long-term safety and efficacy of latanoprostene bunod 0.024% in Japanese subjects with open-angle glaucoma or ocular hypertension: The JUPITER Study. *Adv Ther*. 2016;33(9):1612-27.
29. Heijl, A. Glaucoma treatment: by the highest level of evidence. *The Lancet*. 2015;385(9975):1264-66.

VYZULTA and the V design are registered trademarks of Bausch & Lomb Incorporated or its affiliates. ©2019 Bausch & Lomb Incorporated. All rights reserved. VYZ.0066.USA.19

BRIEF SUMMARY OF PRESCRIBING INFORMATION

This Brief Summary does not include all the information needed to use VYZULTA safely and effectively. See full Prescribing Information for VYZULTA.

VYZULTA™ (latanoprostene bunod ophthalmic solution), 0.024%, for topical ophthalmic use.

Initial U.S. Approval: 2017

1 INDICATIONS AND USAGE

VYZULTA™ (latanoprostene bunod ophthalmic solution) 0.024% is indicated for the reduction of intraocular pressure (IOP) in patients with open-angle glaucoma or ocular hypertension.

4 CONTRAINDICATIONS

None

5 WARNINGS AND PRECAUTIONS

5.1 Pigmentation

VYZULTA™ (latanoprostene bunod ophthalmic solution), 0.024% may cause changes to pigmented tissues. The most frequently reported changes with prostaglandin analogs have been increased pigmentation of the iris and periorbital tissue (eyelid).

Pigmentation is expected to increase as long as latanoprostene bunod ophthalmic solution is administered. The pigmentation change is due to increased melanin content in the melanocytes rather than to an increase in the number of melanocytes. After discontinuation of VYZULTA, pigmentation of the iris is likely to be permanent, while pigmentation of the periorbital tissue and eyelash changes are likely to be reversible in most patients. Patients who receive prostaglandin analogs, including VYZULTA, should be informed of the possibility of increased pigmentation, including permanent changes. The long-term effects of increased pigmentation are not known.

Iris color change may not be noticeable for several months to years. Typically, the brown pigmentation around the pupil spreads concentrically towards the periphery of the iris and the entire iris or parts of the iris become more brownish. Neither nevi nor freckles of the iris appear to be affected by treatment. While treatment with VYZULTA™ (latanoprostene bunod ophthalmic solution), 0.024% can be continued in patients who develop noticeably increased iris pigmentation, these patients should be examined regularly [see Patient Counseling Information (17) in full Prescribing Information].

5.2 Eyelash Changes

VYZULTA may gradually change eyelashes and vellus hair in the treated eye. These changes include increased length, thickness, and the number of lashes or hairs. Eyelash changes are usually reversible upon discontinuation of treatment.

5.3 Intraocular Inflammation

VYZULTA should be used with caution in patients with a history of intraocular inflammation (iritis/uveitis) and should generally not be used in patients with active intraocular inflammation as it may exacerbate this condition.

5.4 Macular Edema

Macular edema, including cystoid macular edema, has been reported during treatment with prostaglandin analogs. VYZULTA should be used with caution in aphakic patients, in pseudophakic patients with a torn posterior lens capsule, or in patients with known risk factors for macular edema.

5.5 Bacterial Keratitis

There have been reports of bacterial keratitis associated with the use of multiple-dose containers of topical ophthalmic products. These containers had been inadvertently contaminated by patients who, in most cases, had a concurrent corneal disease or a disruption of the ocular epithelial surface.

5.6 Use with Contact Lens

Contact lenses should be removed prior to the administration of VYZULTA because this product contains benzalkonium chloride. Lenses may be reinserted 15 minutes after administration.

6 ADVERSE REACTIONS

The following adverse reactions are described in the Warnings and Precautions section: pigmentation (5.1), eyelash changes (5.2), intraocular inflammation (5.3), macular edema (5.4), bacterial keratitis (5.5), use with contact lens (5.6).

6.1 Clinical Trials Experience

Because clinical trials are conducted under widely varying conditions, adverse reaction rates observed in the clinical trials of a drug cannot be directly compared to rates in the clinical trials of another drug and may not reflect the rates observed in practice.

VYZULTA was evaluated in 811 patients in 2 controlled clinical trials of up to 12 months duration. The most common ocular adverse reactions observed in patients treated with latanoprostene bunod were: conjunctival hyperemia (6%), eye irritation (4%), eye pain (3%), and instillation site pain (2%). Approximately 0.6% of patients discontinued therapy due to ocular adverse reactions including ocular hyperemia, conjunctival irritation, eye irritation, eye pain, conjunctival edema, vision blurred, punctate keratitis and foreign body sensation.

8 USE IN SPECIFIC POPULATIONS

8.1 Pregnancy

Risk Summary

There are no available human data for the use of VYZULTA during pregnancy to inform any drug associated risks.

Latanoprostene bunod has caused miscarriages, abortion, and fetal harm in rabbits. Latanoprostene bunod was shown to be abortifacient and teratogenic when administered intravenously (IV) to pregnant rabbits at exposures ≥ 0.28 times the clinical dose.

Doses ≥ 20 $\mu\text{g}/\text{kg}/\text{day}$ (23 times the clinical dose) produced 100% embryofetal lethality. Structural abnormalities observed in rabbit fetuses included anomalies of the great vessels and aortic arch vessels, domed head, sternal and vertebral skeletal anomalies, limb hyperextension and malrotation, abdominal distention and edema. Latanoprostene bunod was not teratogenic in the rat when administered IV at 150 mcg/kg/day (87 times the clinical dose) [see Data].

The background risk of major birth defects and miscarriage for the indicated population is unknown. However, the background risk in the U.S. general population of major birth defects is 2 to 4%, and of miscarriage is 15 to 20%, of clinically recognized pregnancies.

Data

Animal Data

Embryofetal studies were conducted in pregnant rabbits administered latanoprostene bunod daily by intravenous injection on gestation days 7 through 19, to target the period of organogenesis. The doses administered ranged from 0.24 to 80 mcg/kg/day. Abortion occurred at doses ≥ 0.24 mcg/kg/day latanoprostene bunod (0.28 times the clinical dose, on a body surface area basis, assuming 100% absorption). Embryofetal lethality (resorption) was increased in latanoprostene bunod treatment groups, as evidenced by increases in early resorptions at doses ≥ 0.24 mcg/kg/day and late resorptions at doses ≥ 6 mcg/kg/day (approximately 7 times the clinical dose). No fetuses survived in any rabbit pregnancy at doses of 20 mcg/kg/day (23 times the clinical dose) or greater. Latanoprostene bunod produced structural abnormalities at doses ≥ 0.24 mcg/kg/day (0.28 times the clinical dose). Malformations included anomalies of sternum, coarctation of the aorta with pulmonary trunk dilation, retroesophageal subclavian artery with absent brachiocephalic artery, domed head, forepaw hyperextension and hindlimb malrotation, abdominal distention/edema, and missing/fused caudal vertebrae.

An embryofetal study was conducted in pregnant rats administered latanoprostene bunod daily by intravenous injection on gestation days 7 through 17, to target the period of organogenesis. The doses administered ranged from 150 to 1500 mcg/kg/day. Maternal toxicity was produced at 1500 mcg/kg/day (870 times the clinical dose, on a body surface area basis, assuming 100% absorption), as evidenced by reduced maternal weight gain. Embryofetal lethality (resorption and fetal death) and structural anomalies were produced at doses ≥ 300 mcg/kg/day (174 times the clinical dose). Malformations included anomalies of the sternum, domed head, forepaw hyperextension and hindlimb malrotation, vertebral anomalies and delayed ossification of distal limb bones. A no observed adverse effect level (NOAEL) was established at 150 mcg/kg/day (87 times the clinical dose) in this study.

8.2 Lactation

Risk Summary

There are no data on the presence of VYZULTA in human milk, the effects on the breastfed infant, or the effects on milk production. The developmental and health benefits of breastfeeding should be considered, along with the mother's clinical need for VYZULTA, and any potential adverse effects on the breastfed infant from VYZULTA.

8.4 Pediatric Use

Use in pediatric patients aged 16 years and younger is not recommended because of potential safety concerns related to increased pigmentation following long-term chronic use.

8.5 Geriatric Use

No overall clinical differences in safety or effectiveness have been observed between elderly and other adult patients.

13 NONCLINICAL TOXICOLOGY

13.1 Carcinogenesis, Mutagenesis, Impairment of Fertility

Latanoprostene bunod was not mutagenic in bacteria and did not induce micronuclei formation in the *in vivo* rat bone marrow micronucleus assay. Chromosomal aberrations were observed *in vitro* with human lymphocytes in the absence of metabolic activation.

Latanoprostene bunod has not been tested for carcinogenic activity in long-term animal studies. Latanoprost acid is a main metabolite of latanoprostene bunod. Exposure of rats and mice to latanoprost acid, resulting from oral dosing with latanoprost in lifetime rodent bioassays, was not carcinogenic.

Fertility studies have not been conducted with latanoprostene bunod. The potential to impact fertility can be partially characterized by exposure to latanoprost acid, a common metabolite of both latanoprostene bunod and latanoprost. Latanoprost acid has not been found to have any effect on male or female fertility in animal studies.

13.2 Animal Toxicology and/or Pharmacology

A 9-month toxicology study administered topical ocular doses of latanoprostene bunod to one eye of cynomolgus monkeys: control (vehicle only), one drop of 0.024% bid, one drop of 0.04% bid and two drops of 0.04% per dose, bid. The systemic exposures are equivalent to 4.2-fold, 7.9-fold, and 13.5-fold the clinical dose, respectively, on a body surface area basis (assuming 100% absorption). Microscopic evaluation of the lungs after 9 months observed pleural/subpleural chronic fibrosis/inflammation in the 0.04% dose male groups, with increasing incidence and severity compared to controls. Lung toxicity was not observed at the 0.024% dose.

Distributed by:

Bausch + Lomb, a division of

Valeant Pharmaceuticals North America LLC

Bridgewater, NJ 08807 USA

U.S. Patent Numbers: 6,211,233; 7,273,946; 7,629,345; 7,910,767; 8,058,467.

VYZULTA is a trademark of Bausch & Lomb Incorporated or its affiliates.

© Bausch & Lomb Incorporated

Based on 9464800 11/2017 VYZ.0055.USA.16 Issued: 11/2017



Managing the Anophthalmic Socket

How to treat the anophthalmic patient when he presents with problems related to his implant.

Anna P. Murchison, MD, MPH, Philadelphia, and Carlo R. Bernardino, MD, FACS, Salinas, Calif.

Anophthalmia, from the Greek, meaning “absence of eye,” is uncommon as a congenital condition. Congenital anophthalmia, sometimes used interchangeably with microphthalmia, can be due to chromosomal, environmental or monogenic factors. More commonly, anophthalmia is acquired, most often due to a blinding trauma or a blind painful eye. In this article, we’ll help you understand how to evaluate and manage anophthalmic sockets to allow patients to achieve the best functional and cosmetic outcomes possible.

The Surgical History

Whether the anophthalmia was congenital or acquired, when a patient undergoes implant surgery, it’s with the following goals in mind: treat the underlying condition; replace the orbital volume; maximize motility; and provide the most comfortable and aesthetically symmetric appearance possible. Today, most implants are solid (polymethyl methacrylate or silicone), porous (hydroxyapatite and high-density polyethylene) or autogenous

dermis-fat grafts. The implants come in a range of shapes and degree of integration with the overlying prosthetic. Recent surveys note porous materials as the most commonly used for implants.^{1,2}

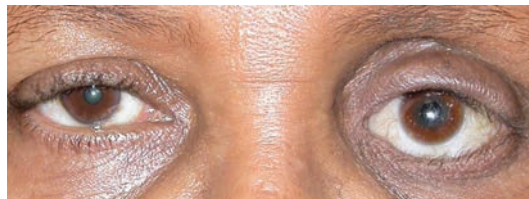

Figure 1. Anophthalmia, left. The left eye socket has a deep superior sulcus with lower lid retraction and lash position abnormalities, compared to the unaffected right eye.

All anophthalmic sockets undergo changes, including orbital fat atrophy and changes in the orbital circulation.³ These changes and the placement of an orbital implant can lead to a variety of complications and management difficulties.

For these reasons, it is important that the general ophthalmologist be able to adequately evaluate and treat simple problems of the anophthalmic socket.

Patient Evaluation

When a patient with anophthalmia and an implant presents, there are a few basic questions the general ophthalmologist should ask after a general ophthalmic and surgical history:

- Does the patient have pain with the prosthetic in?
- Does the prosthesis fall out?
- Is there discharge or bleeding from the socket?
- How old is the current prosthetic and when was the last time it was polished?
- Does the patient have polycarbonate glasses to protect the seeing eye?
- Is the patient happy with the cosmesis and movement of the prosthetic?

When evaluating the anophthalmic socket it’s important to note the general appearance and symmetry compared to the contralateral side. With the prosthetic in place the patient should be evaluated for enophthalmos or prosthetic malposition. The lower eyelid should be evaluated for laxity. Lash position and lid margin position should be noted, as entropion can indi-

WHEN RELIABILITY COUNTS
**THE RIGHT
PACK
MATTERS**

Visit BVI
at ASCRS
BOOTH
1206

Minimize your
pack-building time

Expedite your
OR experience

Treat more patients

CustomEyes® your pack



cate socket contracture. The superior sulcus should be checked for deepening and symmetry with the opposite side (Figure 1). The upper eyelid position should be examined for ptosis, and levator function should be evaluated.

Evaluate the movement of the prosthetic compared to the seeing eye. Poor movement can be due to fornix abnormalities, enophthalmos or poor prosthetic depth. Address any socket or prosthetic abnormality, and if the patient is still unhappy with the motility, there are surgical prosthetic-implant coupling methods that may improve motility for the patient (Figures 2A to 2C).

Remove the prosthetic and evaluate it. If the prosthetic is thick it may be placing pressure on the lower lid and could be camouflaging low orbital volume. Also, note whether the prosthetic is smooth and clean. Evaluate the socket for inflammation, excessive mucous, giant papillary conjunctivitis under the upper eyelid and pyogenic granulomas. Take note of the forniceal depth, and whether the superior fornix is excessively deep or the fornices aren't well defined. Examine the tissue over the implant for thinning, fistula or defects. Lastly, on palpation of the socket, note the presence or absence of an implant and its position.

Of course the patient should wear protective glasses and have careful exams of the seeing eye, with the frequency of exams determined by the patient's age, history and the health of the eye.

Treatments

Following are the more common complaints of the anophthalmic patient, and how to manage them.

- **Discharge.** This is a common complaint, and there can be a range of underlying causes for it. A common etiology is giant papillary

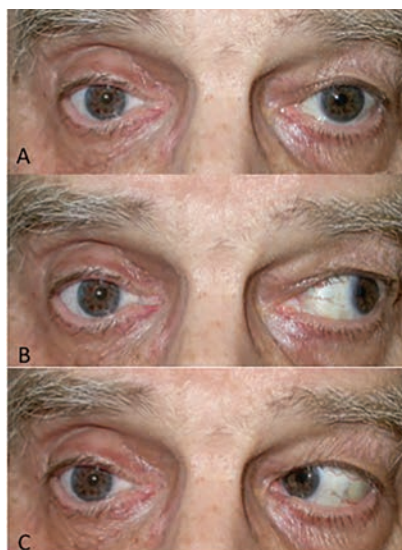


Figure 2. Anophthalmia, right. In addition to the asymmetry in primary gaze with a deep sulcus of the right upper lid, the patient has very poor motility of the prosthesis. The underlying motility should also be evaluated with the prosthesis removed and the prosthetic should be examined.

conjunctivitis. This inflammatory reaction is diagnosed by visualizing papillae of 1 mm or greater on the superior tarsal conjunctiva. The conjunctiva becomes edematous and excessive discharge can be seen. Since the pathogenesis is thought to be a combination of immunologic response to the prosthetic/deposits and mechanical trauma from the prosthetic itself, though the process isn't fully understood, one might think the optimal treatment is removal of the prosthetic, as in contact lens-related GPC. However, since socket contraction can occur without the prosthetic or a conformer in place,

this is usually the last management option. Instead, the primary treatment is prosthetic polishing and topical cromolyn sodium or topical steroids.

Other conditions that may cause discharge are poor prosthetic fit, implant extrusion, pyogenic granuloma in the socket, excessively deep fornices, conjunctival infection or nasolacrimal duct obstruction.

- **Enophthalmos.** This is caused by either the prosthetic's position or a deep superior sulcus, and can be present initially or develop over time due to implant size, implant shifting and/or change or atrophy of the orbital tissues. It can be addressed by surgically augmenting the orbital volume. A variety of surgical techniques can be applied, including subperiosteal implants or secondary orbital implants. (A comprehensive discussion of implants and surgical techniques is beyond the scope of this general review.)

After surgery, if any superior sulcus deformity remains, there are surgical and filler options to improve the appearance. However, for the patient interested in a non-surgical fix, placing a +2 D sphere or higher over the affected side will magnify the eye socket and make the enophthalmos less noticeable. Caution should be used in increasing the thickness of the prosthetic to compensate for this volume loss, as over time the lower lid will become more lax and the prosthetic will sink inferiorly.

- **Lower eyelid laxity.** Lower lid laxity, with or without lid margin malposition, can be partially due to the weight of the prosthetic and can lead to other changes, including ptosis of the upper lid. This is addressed by having the prosthetic remade, followed by surgery with horizontal lid shortening. If there's any forniceal shortening or other findings, they would also need to be addressed.

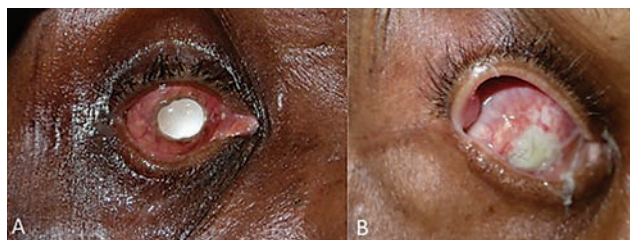


Figure 3. Anophthalmia with implant exposures. Figure A shows exposure of a smooth, acrylic implant. Figure B shows an exposed, porous implant leading to mucoid discharge.

The History of Anophthalmos Management

The first enucleations were possibly performed by the Chinese as early as 2,600 BC. However, the first report by Johannes Lange⁷ was not until 1555, and the first description of the procedure appeared in 1583, by George Bartisch.⁸ In the 1800's the procedure made dramatic advances, including extraocular muscle disinsertion, as well as the introduction of controlled anesthesia, leading to great improvements and increased use of the procedure.⁹ Evisceration seems to have first been performed unintentionally by James Beer in 1817 after an expulsive choroidal hemorrhage; in 1874 J.F. Noyes completed the first planned evisceration. There were several modifications of the procedure, later discarded, until Alfred Graefe and P.H. Mules' more modern version in 1884.²

The first ocular prosthetics, of painted metal, were described in 1579, and glass prosthetics from Vienna were also starting to be made. Since then, many other materials and shapes have been tried, such as ivory, rubber, wool and cartilage. In recent history, the advent of inert plastics has given us the implants we use today. —AM and CB

• **Socket contracture.** This can accompany lid malposition and has myriad causes. There's no single surgical technique to address socket contracture and management should be individualized and address lid position abnormalities at the same time.

• **Orbital implant exposure or extrusion.** Thankfully, this is an uncommon patient presentation, with average incidences of 5.6 percent (exposure) and 1.3 percent (extrusion) with porous implants (*Figures 3A and 3B*).⁴ When this occurs, the time since surgery and size of the defect can impact the management. Surgery is often required, and involves a simple closure or a patch graft.

• **Upper eyelid ptosis.** This is common in the anophthalmic socket. This can be a true ptosis or a pseudoptosis due to poor support from the prosthetic or poor orbital volume and implant location. As is well known, any orbital surgery, such as volume augmentation, should precede eyelid correction. Once any socket problems have been corrected, the ptosis can be addressed.

If the ptosis is mild the ocularist can build up the prosthetic superiorly to support the upper eyelid. However, since this increases the weight of the prosthetic it can begin a cycle of problems in the future by inducing lower eyelid laxity, which then leads to a deeper superior sulcus and the need for a larger prosthetic in a perpetuating cycle. If the ptosis is to be addressed surgically, the ophthalmologist should keep in mind that levator strength may be underestimated.⁵

Other Considerations

Orbital pain in the anophthalmic socket can be difficult to diagnose, since the etiology can range from prosthetic irritation or migration/extrusion of the implant to neurologic causes. One should also rule out lacrimal insufficiency, inflammation (scleritis, sympathetic ophthalmia and GPC),

trochlear irritation and possible recurrent tumors.⁶ Amputation neuromas, an exuberant overgrowth of neurons and connective tissue at the transected nerve, are uncommon but can result in pain, particularly with eye movement. Periorbital pathologies, such as sinus diseases or central nervous system tumors can also cause referred socket pain and should be considered. If the etiology isn't found on examination or improved with medical therapy, imaging may be warranted.

Psychogenic factors, such as drug-seeking behavior, can also lead to pain, but these are diagnoses of exclusion. Chronic pain syndromes, which can overlap with psychogenic factors, can also complicate the evaluation and are diagnosed in conjunction with other specialists after ruling out orbital/prosthetic etiologies. In these cases, patients nearly always need referral to an ocularist for assessment and prosthetic modification and/or polishing. If the etiology isn't clear and persists after prosthetic polishing and lubrication, the patient may need a CT scan to aid in diagnosis.

It's worth mentioning that pediatric anophthalmia can be even more difficult to manage, especially because the orbit of a child is not fully developed until after age 5. As the soft tissue and orbit can require expansion, these often challenging cases may require multiple surgeries and sometimes sub-

specialty management to avoid orbital and facial asymmetry.

The anophthalmic socket has a unique set of problems and requires a different clinical and surgical approach than a socket with a globe. The management of these patients should be carried out with close communication between the ophthalmologist and ocularist to achieve optimal comfort and cosmesis for patients. **REVIEW**

Dr. Murchison is the director of the Wills Eye Emergency Department and a member of the Oculoplastic and Orbital Surgery Service at Wills Eye Hospital. Dr. Bernardino is an oculoplastic surgeon at Vantage Eye Center in Salinas. The authors report no financial interest in any product discussed.

1. Su GW, Yen MT. Current trends in managing the anophthalmic socket after primary enucleation and evisceration. *Ophthalmic Plast Reconstr Surg* 2004;20:4:274-280.

2. Viswanathan P, Sagoo MS, Olver JM. UK national survey of enucleation, evisceration and orbital implant trends. *Br J Ophthalmol* 2007;91:5:616-9.

3. Smith TJ et al. Primary and secondary implants in the anophthalmic orbit: Preoperative and postoperative computed tomographic appearance. *Ophthalmology* 1991;98:1:106-10.

4. Wladis EJ, et al. Orbital implants in enucleation surgery: A report by the AAO. *Ophthalmology* 2018;125:2:311-317.

5. Nunnery WR, Cepela M. Levator function in the evaluation and management of blepharoptosis. *Ophthalmol Clin North Am* 1991;4:1-16.

6. Jordan DR, Klapper SR. Enucleation, evisceration, secondary orbital implantation. In: Black E, Nesi F, Gladstone G, Levine M, Calvano C, eds. *Smith and Nesi's Ophthalmic Plastic and Reconstructive Surgery*, 3rd Ed. New York: Springer, 2012.

7. Beard CH. Enucleation. In: *Ophthalmic Surgery*. Philadelphia: P. Blakiston's Son & Co., 1910:457-477.

8. Luce CM. A short history of enucleation. *Int Ophthalmol Clin* 1970;10:681-7.

9. Fox SA. Enucleation and Allied Procedure. In *Ophthalmic Plastic Surgery*, 4th Ed. New York: Grune & Stratton Inc. 1970:475-501.

Premium IOLs: Dealing With Postop Problems

Christopher Kent, Senior Editor

Advanced-technology IOLs have far fewer postop issues than in the past, but problems can still arise. Here's help.

As intraocular lenses have become more technologically advanced, the issues surrounding patient selection, lens implantation and patient management have become more complex. At the same time, the technology used to select the best lens for a given patient has improved dramatically, and doctors' understanding of how to choose appropriate candidates and manage them before and after surgery has become far more sophisticated than it was when premium lenses first appeared.

R. Bruce Wallace III, MD, FACS, founder and medical director of Wallace Eye Associates in Alexandria, Louisiana, and clinical professor of ophthalmology at Louisiana State University and Tulane Schools of Medicine in New Orleans, notes that success with these lenses has become easier. "The lenses are better now," he says. "We still have a few postoperative issues, but not nearly the number we had in the past."

Nevertheless, problems can still occur. "When it comes to advanced technology IOLs, several possible postoperative concerns can lead to a dissatisfied patient," notes Elizabeth Yeu, MD, a partner at Virginia Eye Consultants in Norfolk, and an assistant professor at the Eastern Virginia Medical School. "Potential issues in-

clude objective or subjective problems related to the ocular surface, including dry eye; residual refractive error; IOL-related concerns, such as problems with night vision or quality-of-vision issues; blurred vision as a result of posterior capsular opacification; or simply unmet expectations. Essentially, our patients are our customers, and good customer service underlies everything. Leaving clinical issues unresolved will lead to dissatisfaction."

Here, surgeons offer insights regarding how to manage problems that may arise, along with a few pearls for preoperative patient management that can help to minimize these postoperative issues.

Refractive Surprises

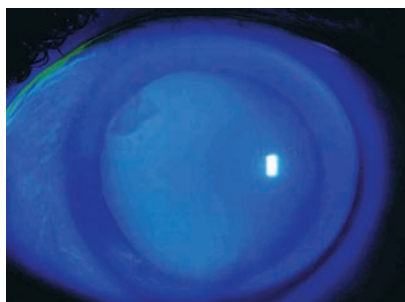
Although an imperfect lens power calculation is always a possibility when a postoperative refractive surprise occurs, such issues are becoming less common. (For more on how to avoid miscalculating the lens power, see "IOL Power Formulas: 10 Questions Answered" in the January 2018 issue of *Review*.) Other issues such as corneal problems and toric lens rotation also need to be considered.

"Postoperative ocular surface issues can lead to visual difficulties, discom-

fort and an unhappy patient, and the number one cause of ocular surface issues is dry-eye disease,” notes Dr. Yeu. “Preoperative dry eye can lead to a refractive surprise, with undercorrected or overcorrected astigmatism or an altered spherical equivalent outcome—but postoperative exacerbation of dry-eye symptoms can also be problematic.

“Dry eye isn’t as straightforward as we used to believe,” she continues. “If you look at a study like the one conducted by Pria Gupta, MD and Chris Starr, MD,¹ about three-quarters of patients coming in for cataract surgery have at least mild to moderate dry eye, but only a small number of them have actually been diagnosed with dry-eye disease. It’s a diagnosis that’s easy to miss in many patients. Many of our older patients may not feel dry, per se, or they may not have the classic symptom of irritation. They may only have a fluctuating vision issue, if the disease is mild preoperatively. But postoperatively, a subclinical or asymptomatic case of dry eye may become clinically symptomatic. The reasons are not completely straightforward, but use of medications relating to the cataract surgery is a common etiology.”

Adding to the complexity of the problem, a refractive surprise can also be the result of other subtle corneal problems that were missed before the surgery—or that have occurred following surgery because of the postoperative drops. These can include subtle epithelial basement membrane dystrophy, nodular degeneration or a pterygium that wasn’t addressed preoperatively. “Some patients coming in for cataract surgery have very minimal epithelial basement membrane dystrophy that may only involve the superior 10 percent of the peripheral cornea,” says Dr. Yeu. “If you lift up the lid, it’s actually relatively common to find this. But postoperatively, whether because the patient caused corneal trauma with the tip of the eye



Elizabeth Yeu, MD

A refractive surprise can result from subtle corneal problems missed before the surgery—or that occurred after the surgery because of the use of postoperative drops. Above: A Salzmann’s nodule at 10 o’clock.

dropper or because of the toxicities of the medications, it goes from subclinical EBMD to a very clinically relevant EBMD. It may not be that the clinician missed the problem—the EBMD may simply become a much bigger issue as the surface decompensates postoperatively.

“Because this is a possibility, whenever you have an unhappy patient related to a refractive ‘miss’ leading to a sub-par visual outcome, you have to look for a few things,” she continues. “A carefully performed refraction is going to be very important, but that has to be accompanied by a very careful ocular surface examination, both before and after staining. Prior to any drop instillation, you should repeat whatever diagnostic images were obtained preoperatively, to compare them and see if there’s an interval difference that could be the source of the surprise outcome. If the problem appears to be caused by a poor ocular surface, aggressive treatment to normalize the surface will be necessary as an initial step, prior to moving forward with any other intervention. Lastly, a macular OCT should be a part of the evaluation for patients with sub-optimal postoperative vision and for refractive misses.”

Residual Refractive Error

Arddalan Eddie Aminlari, MD, who

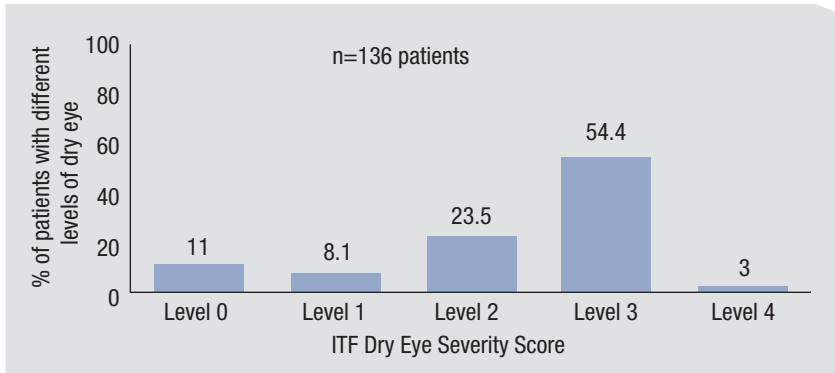
practices at The Morris Eye Group in Encinitas, California, says it’s remarkable how good refractive outcomes have become, with both monofocal and presbyopia-correcting lenses. “However, every once in a while someone will fall outside the normal range, with long or short axial lengths, or steep or flat corneas,” he notes. “It can be a little more difficult to achieve a perfect outcome with these patients, so postoperatively, refractive surprises sometimes still need to be addressed.

“There are several ways to address them,” he says. “Even very low residual astigmatism can effect near, intermediate and distance vision, and it’s important to address this in patients who receive a premium lens, which requires an excellent optical system. If the patient has a small amount of mixed astigmatism, but has a spherical equivalent of plano, I might address this with manual limbal relaxing incisions. Performing LASIK or PRK is a reasonable option for patients who have a higher level of compound or mixed astigmatism.

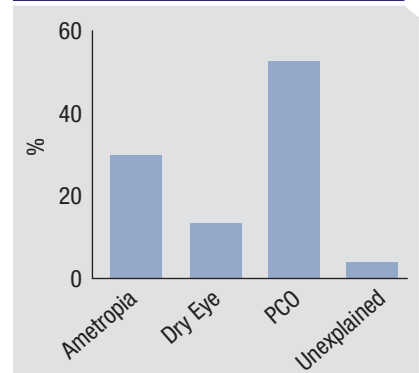
“Patients with higher levels of residual spherical errors might require a lens exchange, or in rare cases a piggyback IOL,” he continues. “However, it would have to be a big refractive miss for me to do a lens exchange. Again, with the new equipment and formulas we’re using today, needing a lens exchange is uncommon, even in patients with previous refractive surgery.”

Dr. Yeu agrees. “If the refractive error is small, say, on the order of 1.25 D or less, and it’s just mixed astigmatism because the spherical equivalent is relatively close to emetropia, performing astigmatic keratotomy or one or more limbal relaxing incisions could be the answer,” she says. “However, if it’s a larger refractive error, or the spherical equivalent is significantly off, then you’ll have to think about whether the patient is a candidate for a laser application like LASIK or PRK, or whether the patient would be better served by

Prevalence of Dry Eye in Cataract Patients



Dissatisfaction with MF IOLs



Addressing dry eye in premium lens patients, both preoperatively and postoperatively, is crucial, surgeons say. Studies suggest that three-quarters of patients coming in for cataract surgery have at least mild to moderate dry eye, but only a small number of them have actually been diagnosed.¹ Above, left: One study found that 25.9 percent of cataract patients had previously received a diagnosis of dry-eye disease, but 80.9 percent had an ITF dry eye level of 2 (indicating moderate dry eye) or higher, based on the presence of signs and symptoms.³ Right: At the same time, a significant number of multifocal lens patients attribute dissatisfaction with their lenses to symptoms of dry eye.⁴

doing an IOL exchange. Ultimately, especially if it's a quality-of-vision concern, the patient may need an IOL exchange. However, resorting to a lens exchange isn't that common anymore, because our current advanced technology lenses produce a better overall quality of vision, with fewer of the night-vision dysphotopsia concerns that patients may complain about."

Of course, when the implanted lens is toric and the patient's astigmatism isn't effectively resolved, postop rotation is an obvious potential culprit. Dr. Aminlari says that he's found two strategies that help to prevent postop toric lens rotation. "At the time of surgery, I leave the intraocular pressure a little lower than I would normally leave it," he says. "I can check by palpation to make sure the eye isn't overinflated, as there's a tendency for the lens to rotate in this situation. It's also important to remove all viscoelastic, including underneath the lens, because retained viscoelastic can also cause a lens to rotate after surgery. These strategies come into play with toric multifocals and extended-depth-of-focus torics as well."

Dr. Aminlari adds that he uses the LENSAR femtosecond system, which has a feature that helps him should

postoperative rotation occur. "The LENSAR system incorporates Intelli-Axis, which creates a capsular mark allowing the placement of the lens with a much higher degree of certainty," he explains. "Postoperatively, if you find a residual astigmatic error on refraction, it's easy to identify the location of the toric markers in relation to the capsular mark."

"In that situation, if I do see rotation, I don't wait very long to go in and rotate the lens," he adds. "I usually go in within the first few weeks."

Managing Dysphotopsias

When implanting a presbyopia-correcting IOL, dysphotopsias such as glare and haloes are a common postoperative complaint. Dr. Yeu points out that most patients who are likely to be bothered by postoperative dysphotopsias can be identified before surgery. "When I talk to the patient preoperatively, I look to see if the patient has a high level of concern or a lot of fear tied to night-vision-related issues," she says. "Of course, this might be an concern for someone who does commercial driving at night or works the graveyard shift. If that individual is determined to try a presbyopia-cor-

recting lens, I'll choose the lowest add possible, and I'd consider a mid- to low-add multifocal or an extended-depth-of-focus IOL.

"If we're proceeding with one of these patients I'll start by treating the nondominant eye," she continues. "Then, if the patient has a significant problem during the postoperative period, we can stop and decide how to move forward. One option is to balance the nondominant eye with a monofocal for distance in the dominant eye. That gives the patient a kind of customized vision, where they're able to maintain 'social reading.' That means that although they won't be able to sit and read a book or work on the computer for more than 10 or 15 minutes without spectacles to support their near vision, they can at least look at their phone or read a restaurant menu without having to search for reading glasses. Meanwhile, this arrangement will mitigate their night vision problems. This approach has allowed me to avoid doing an IOL exchange in a number of patients."

Dr. Yeu says this same strategy can work when a patient seems like a good candidate for bilateral implantation of a presbyopia-correcting IOL, but ends up unhappy with the dyspho-

topias. “If a patient like this comes back four to six months later and the situation hasn’t gotten better, but the patient doesn’t want to lose the freedom of independence from spectacles, I’ll offer them the same option,” she says. “Doing an IOL exchange in the dominant eye, swapping out the presbyopia-correcting lens with a monofocal for distance, often saves us from having to do a bilateral IOL exchange. Patients are often happy with that compromise.”

Postoperative Pain

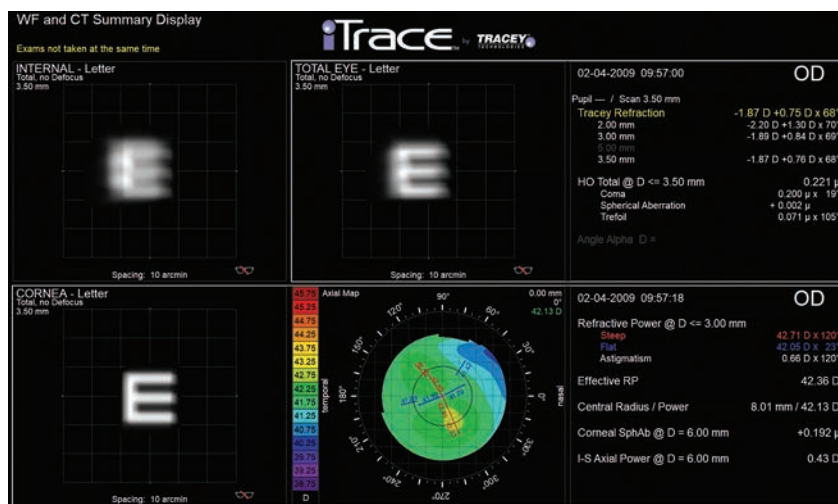
Dr. Yeu notes that patient dissatisfaction is frequently associated with postoperative pain. “It’s important for us to do everything we can around the time of surgery to prevent pain,” she says. “That’s why it’s important to consider using preoperative and perioperative NSAIDs. Intraoperatively, of course, we try to disturb as little of the corneal epithelium as possible, beyond what’s necessary to perform intraocular surgery.

“Sometimes postoperative pain is tied to dry eye or ocular surface disease that’s gone from being relatively asymptomatic to being uncomfortable,” she adds. “Then you have to go down the pathway of doing the ocular surface examination and deciding how to manage whatever you find.”

Dr. Aminlari notes that most of the pain he’s seen postoperatively has been in connection with dry eye. “I’ve never seen serious postoperative pain, presumably because the medications we use control the inflammation in the eye and help to prevent that,” he says. “However, dry eye sometimes causes a burning sensation and blurred vision intermittently, which is another reason to look for postoperative dry eye and address it promptly.”

Managing a Decentered IOL

“In the uncommon instance that I



An IOL that’s significantly tilted can cause a refractive problem and lead to a shift in refractive astigmatism—especially when it’s a multifocal or extended-depth-of-focus IOL.

encounter a visually significant decentered presbyopia-correcting IOL, it definitely needs to be addressed,” says Dr. Yeu. “If the patient has already had a YAG capsulotomy, that makes for a much more challenging scenario, and trying to center the IOL may not be a great option. But if the capsule is intact, you can consider reopening the bag and then trying to center the IOL.

“You have to figure out whether the IOL is decentered because there’s something wrong with the zonules, leading to uneven distribution of forces on the bag, or whether the IOL just needs to be repositioned inside the bag,” she continues. “Sometime you’re in the operating room and you try to center the IOL and you realize that it keeps creeping in one direction. The first thing you should be thinking of as the surgeon is that there’s some level of zonular laxity in that one quadrant. In such a patient, placing a capsular tension ring to provide equatorial balance of support throughout will allow you to center the IOL much more readily.”

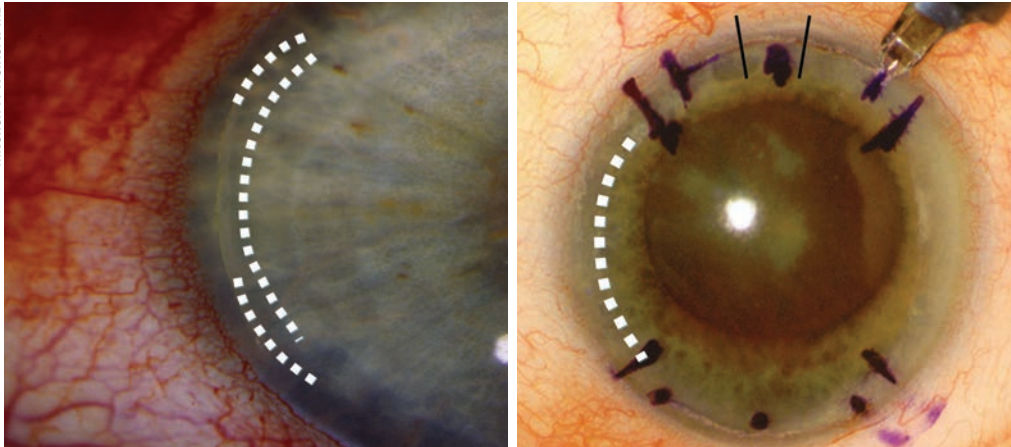
Dr. Wallace suggests checking the haptics with the lens still inside the eye. “If a lens doesn’t seem to center properly, there may be a haptic that’s not working properly,” he notes. “It’s

hard to tell, if you can’t see the haptic behind the iris. Sometimes it’s important to examine the lens while it’s still in the eye; rotate it into the anterior chamber and look at the haptics to see if there’s any abnormality there.”

Managing a Tilted IOL

Dr. Yeu notes that an IOL that’s significantly tilted can definitely cause a refractive problem—especially when it’s a multifocal or extended-depth-of-focus IOL—and lead to refractive astigmatism shifts. “Work by Mitch Weikert and Doug Koch has demonstrated that it’s not uncommon for IOLs to tilt evenly across the horizontal axis, inducing mild against-the-rule astigmatism.² More significant IOL tilting can occur with decentration of the IOL, capsular contraction, inadvertently malpositioned haptics (for example, one in the capsular bag and one in the sulcus), or poor coverage of the optic edge by the anterior capsule. For that reason, it’s important for us to be as accurate as possible when making the capsulorhexis or capsulotomy, which is why I use either a femtosecond laser or the Zepto capsulotomy system when I’m using an advanced-technology IOL. Those technologies

Mitchell P. Weikert, MD



Above, left: Residual mixed astigmatism, undercorrected. In this situation surgical options include adding a limbal relaxing incision or opening femtosecond laser LRIs. If staying within the same meridian as an existing LRI, you can lengthen the existing LRI or place an additional LRI central to the existing one. Above, right: Residual mixed astigmatism, overcorrected. If there's a gaping LRI, you can suture it and then place a therapeutic bandage soft contact lens. If you're dealing with a "flipped axis" toric IOL, you can add an LRI in the opposite axis. However, quality of vision may be compromised.

allow me to create a standardized, perfectly round, well-centered capsulotomy every time. That allows for very circumferential and equal coverage of the optic edge."

Dr. Aminlari notes that when patients present with lens tilt—which he says is very uncommon—they often need a lens exchange. "Some surgeons might want to attempt scleral fixation of the lens," he says. "It's possible that the zonules holding the capsular bag in place are broken, and if so, there's nothing we can do to fix them. In those situations, probably the safest approach is to remove the lens from the eye and come up with a better solution, such as putting a new lens into the ciliary sulcus."

The Piggyback Option

Dr. Yeu says she rarely considers implanting a piggyback lens because the lens options are limited. "We used to have access to the STAAR silicone three-piece IOL," she points out. "That was great because it was an anteriorly round-edged, three-piece lens made of silicone, a little bit larger than a standard IOL; it could easily go into

the sulcus. It came in low and minus powers, so you could use it in those patients who had a myopic or small hyperopic error.

"Now our options are a bit more limited," she continues. "The Bausch + Lomb silicone IOL is a three-piece with a square edge, but it only goes to zero diopters, so it can't be used in patients with a myopic error. Then there's the AR40, which is a round-edged hydrophobic acrylic three-piece IOL; that lens is available into the minus powers. However, there are concerns that if you use the same material for both IOLs you might end up causing interlenticular opacification. I haven't seen that happen as long as one of the IOLs is in the sulcus and the other IOL is in the bag. However, because none of our lens options are ideal, I don't use the secondary piggyback option very often."

Dr. Wallace says he has occasionally resorted to implanting a piggyback lens to resolve a postoperative problem. "Some of these patients are not good candidates for LASIK," he points out. "These are not 20-year-old myopes. They have issues like dry eye that might be made worse

by LASIK. Other ocular problems such as a thin cornea could also make a patient less-than-ideal as a candidate for LASIK. You have to do a thorough evaluation of the eye, beyond just the refractive error, to figure out whether the patient would benefit from LASIK.

"One of the good things about a piggyback lens compared to LASIK," adds Dr. Wallace, "is that if it doesn't work properly—if there's a degradation of visual

acuity—changing the lens is better than doing a second LASIK procedure which would sacrifice more corneal tissue. That means you have an option if you later have another surprise with that eye."

Postop Treatment: Timing Counts

Because the eye can take weeks or months to calm down following surgery—and because some postoperative problems will resolve on their own, given time—surgeons agree that holding off trying to address postoperative complaints (with the exception of a toric IOL malrotation) is important.

"If I suspect the patient just needs time to adjust to the lenses, I often won't do much in terms of intervention until some time has passed," says Dr. Aminlari. "Instead, I pay attention to the patient's complaints, try to be as supportive as I can, and become their advocate. This is similar to patients who've just started wearing progressive-lens spectacles. They may complain in the beginning, but eventually they get used to them. Over time, patients start to neuroadapt to the multifocal or extended-depth-of-

DISCOVER LOTEMAX[®] SM: SUBMICRON STRONG

LOTEMAX[®] SM
(loteprednol etabonate
ophthalmic gel) 0.38%

Join your peers for a webinar presentation introducing the exciting new advancements of LOTEMAX[®] SM, the newest loteprednol etabonate formulation from Bausch + Lomb

REGISTER FOR ONE OF THE FOLLOWING WEBINAR SESSIONS:



MARGUERITE MCDONALD, MD

Tuesday, April 9th • 6:00 PM ET | 3:00 PM PT



MITCHELL JACKSON, MD

Wednesday, April 24th • 8:00 PM ET | 5:00 PM PT



AUDREY TALLEY ROSTOV, MD

Thursday, April 25th • 9:00 PM ET | 6:00 PM PT



RAJESH RAJPAL, MD

Wednesday, May 15th • 6:00 PM ET | 3:00 PM PT

Dates and speakers are subject to change or substitution.

THIS LIVE WEBINAR PRESENTATION WILL COVER:

- **OVERCOMING CHALLENGES** of ocular drug delivery
- **LOTEMAX[®] SM FORMULATION** features designed with the patient in mind
- **NEW SM TECHNOLOGY[™]** in LOTEMAX[®] SM
- **THE PROVEN EFFICACY AND SAFETY** of LOTEMAX[®] SM

This promotional webinar is sponsored by Bausch + Lomb. No CME/CE or food will be provided for this program. Only physicians and healthcare professionals involved in providing patient care or product recommendations may attend this educational program.

REGISTER NOW AT www.reviewofophthalmology.com/LotemaxSMWebinar2019

INDICATION

LOTEMAX[®] SM (loteprednol etabonate ophthalmic gel) 0.38% is a corticosteroid indicated for the treatment of post-operative inflammation and pain following ocular surgery.

IMPORTANT SAFETY INFORMATION

- LOTEMAX[®] SM, as with other ophthalmic corticosteroids, is contraindicated in most viral diseases of the cornea and conjunctiva including epithelial herpes simplex keratitis (dendritic keratitis), vaccinia, and varicella, and also in mycobacterial infection of the eye and fungal diseases of ocular structures.
- Prolonged use of corticosteroids may result in glaucoma with damage to the optic nerve, defects in visual acuity and fields of vision. If LOTEMAX[®] SM is used for 10 days or longer, IOP should be monitored.
- Use of corticosteroids may result in posterior subcapsular cataract formation.
- The use of steroids after cataract surgery may delay healing and increase the incidence of bleb formation. In those with diseases causing thinning of the cornea or sclera, perforations have been known to occur with the use of topical steroids. The initial prescription and renewal of the medication order should be made by a physician only after examination of the patient with the aid of magnification such as slit lamp biomicroscopy and, where appropriate, fluorescein staining.

IMPORTANT SAFETY INFORMATION (CON'T)

- Prolonged use of corticosteroids may suppress the host response and thus increase the hazard of secondary ocular infections. In acute purulent conditions, steroids may mask infection or enhance existing infections.
- Employment of a corticosteroid medication in the treatment of patients with a history of herpes simplex requires great caution. Use of ocular steroids may prolong the course and may exacerbate the severity of many viral infections of the eye (including herpes simplex).
- Fungal infections of the cornea are particularly prone to develop coincidentally with long-term local steroid application. Fungus invasion must be considered in any persistent corneal ulceration where a steroid has been used or is in use. Fungal cultures should be taken when appropriate.
- Contact lenses should not be worn when the eyes are inflamed.
- There were no treatment-emergent adverse drug reactions that occurred in more than 1% of subjects in the three times daily group compared to vehicle.

You are encouraged to report negative side effects of prescription drugs to the FDA. Visit www.fda.gov/medwatch or call 1-800-FDA-1088.

Please see Brief Summary of full Prescribing Information on adjacent page.

BAUSCH + LOMB

©/TM are trademarks of Bausch & Lomb Incorporated or its affiliates.
© 2019 Bausch & Lomb Incorporated. All rights reserved. Printed in USA. LSM.0056.USA.19

LOTEMAX[®] SM
(loteprednol etabonate
ophthalmic gel) 0.38%

BRIEF SUMMARY OF PRESCRIBING INFORMATION

This Brief Summary does not include all the information needed to use LOTEMAX® SM safely and effectively. See full prescribing information for LOTEMAX® SM.

LOTEMAX® SM (loteprednol etabonate ophthalmic gel) 0.38%

For topical ophthalmic use

Initial U.S. Approval: 1998

INDICATIONS AND USAGE

LOTEMAX® SM is a corticosteroid indicated for the treatment of post-operative inflammation and pain following ocular surgery.

DOSAGE AND ADMINISTRATION

Invert closed bottle and shake once to fill tip before instilling drops. Apply one drop of LOTEMAX® SM into the conjunctival sac of the affected eye three times daily beginning the day after surgery and continuing throughout the first 2 weeks of the post-operative period.

CONTRAINDICATIONS

LOTEMAX® SM, as with other ophthalmic corticosteroids, is contraindicated in most viral diseases of the cornea and conjunctiva including epithelial herpes simplex keratitis (dendritic keratitis), vaccinia, and varicella, in mycobacterial infection of the eye and fungal diseases of ocular structures.

WARNINGS AND PRECAUTIONS

Intraocular Pressure (IOP) Increase: Prolonged use of corticosteroids may result in glaucoma with damage to the optic nerve, defects in visual acuity and fields of vision. Steroids should be used with caution in the presence of glaucoma. If this product is used for 10 days or longer, intraocular pressure should be monitored.

Cataracts: Use of corticosteroids may result in posterior subcapsular cataract formation.

Delayed Healing: The use of steroids after cataract surgery may delay healing and increase the incidence of bleb formation. In those diseases causing thinning of the cornea or sclera, perforations have been known to occur with the use of topical steroids. The initial prescription and renewal of the medication order should be made by a physician only after examination of the patient with the aid of magnification such as slit lamp biomicroscopy and, where appropriate, fluorescein staining.

Bacterial Infections: Prolonged use of corticosteroids may suppress the host response and thus increase the hazard of secondary ocular infections. In acute purulent conditions of the eye, steroids may mask infection or enhance existing infection.

Viral infections: Employment of a corticosteroid medication in the treatment of patients with a history of herpes simplex requires great caution. Use of ocular steroids may prolong the course and may exacerbate the severity of many viral infections of the eye (including herpes simplex).

Fungal Infections: Fungal infections of the cornea are particularly prone to develop coincidentally with long-term local steroid application. Fungus invasion must be considered in any persistent corneal ulceration where a steroid has been used or is in use. Fungal cultures should be taken when appropriate.

Contact Lens Wear: Contact lenses should not be worn when the eyes are inflamed.

ADVERSE REACTIONS

Because clinical trials are conducted under widely varying conditions, adverse reaction rates observed in the clinical trials of a drug cannot be directly compared to rates in the clinical trials of another drug and may not reflect the rates observed in practice. Adverse reactions associated with ophthalmic steroids include elevated intraocular pressure, which may be associated with infrequent optic nerve damage, visual acuity and field defects, posterior subcapsular cataract formation, delayed wound healing and secondary ocular infection from pathogens including herpes simplex, and perforation of the globe where there is thinning of the cornea or sclera. There were no treatment-emergent adverse drug reactions that occurred in more than 1% of subjects in the three times daily group compared to vehicle.

USE IN SPECIAL POPULATIONS

Pregnancy: Risk Summary: There are no adequate and well controlled studies with loteprednol etabonate in pregnant women. Loteprednol etabonate produced teratogenicity at clinically relevant doses in the rabbit and rat when administered orally during pregnancy. Loteprednol etabonate

produced malformations when administered orally to pregnant rabbits at doses 4.2 times the recommended human ophthalmic dose (RHOD) and to pregnant rats at doses 106 times the RHOD. In pregnant rats receiving oral doses of loteprednol etabonate during the period equivalent to the last trimester of pregnancy through lactation in humans, survival of offspring was reduced at doses 10.6 times the RHOD. Maternal toxicity was observed in rats at doses 1066 times the RHOD, and a maternal no observed adverse effect level (NOAEL) was established at 106 times the RHOD. The background risk of major birth defects and miscarriage for the indicated population is unknown. However, the background risk in the U.S. general population of major birth defects is 2 to 4%, and of miscarriage is 15 to 20%, of clinically recognized pregnancies. Data: *Animal Data.* Embryofetal studies were conducted in pregnant rabbits administered loteprednol etabonate by oral gavage on gestation days 6 to 18, to target the period of organogenesis. Loteprednol etabonate produced fetal malformations at 0.1 mg/kg (4.2 times the recommended human ophthalmic dose (RHOD) based on body surface area, assuming 100% absorption). Spina bifida (including meningocele) was observed at 0.1 mg/kg, and exencephaly and craniofacial malformations were observed at 0.4 mg/kg (17 times the RHOD). At 3 mg/kg (128 times the RHOD), loteprednol etabonate was associated with increased incidences of abnormal left common carotid artery, limb flexures, umbilical hernia, scoliosis, and delayed ossification. Abortion and embryofetal lethality (resorption) occurred at 6 mg/kg (256 times the RHOD). A NOAEL for developmental toxicity was not established in this study. The NOAEL for maternal toxicity in rabbits was 3 mg/kg/day. Embryofetal studies were conducted in pregnant rats administered loteprednol etabonate by oral gavage on gestation days 6 to 15, to target the period of organogenesis. Loteprednol etabonate produced fetal malformations, including absent innominate artery at 5 mg/kg (106 times the RHOD); and cleft palate, agnathia, cardiovascular defects, umbilical hernia, decreased fetal body weight and decreased skeletal ossification at 50 mg/kg (1066 times the RHOD). Embryofetal lethality (resorption) was observed at 100 mg/kg (2133 times the RHOD). The NOAEL for developmental toxicity in rats was 0.5 mg/kg (10.6 times the RHOD). Loteprednol etabonate was maternally toxic (reduced body weight gain) at 50 mg/kg/day. The NOAEL for maternal toxicity was 5 mg/kg. A peri-/postnatal study was conducted in rats administered loteprednol etabonate by oral gavage from gestation day 15 (start of fetal period) to postnatal day 21 (the end of lactation period). At 0.5 mg/kg (10.6 times the clinical dose), reduced survival was observed in live-born offspring. Doses \geq 5 mg/kg (106 times the RHOD) caused umbilical hernia/incomplete gastrointestinal tract. Doses \geq 50 mg/kg (1066 times the RHOD) produced maternal toxicity (reduced body weight gain, death), decreased number of live-born offspring, decreased birth weight, and delays in postnatal development. A developmental NOAEL was not established in this study. The NOAEL for maternal toxicity was 5 mg/kg.

Lactation: There are no data on the presence of loteprednol etabonate in human milk, the effects on the breastfed infant, or the effects on milk production. The developmental and health benefits of breastfeeding should be considered, along with the mother's clinical need for LOTEMAX® SM and any potential adverse effects on the breastfed infant from LOTEMAX® SM.

Pediatric Use: Safety and effectiveness of LOTEMAX® SM in pediatric patients have not been established.

Geriatric Use: No overall differences in safety and effectiveness have been observed between elderly and younger patients.

NONCLINICAL TOXICOLOGY

Carcinogenesis, Mutagenesis, Impairment of Fertility: Long-term animal studies have not been conducted to evaluate the carcinogenic potential of loteprednol etabonate. Loteprednol etabonate was not genotoxic *in vitro* in the Ames test, the mouse lymphoma tk assay, or in the chromosomal aberration test in human lymphocytes, or *in vivo* in the mouse micronucleus assay. Treatment of male and female rats with 25 mg/kg/day of loteprednol etabonate (533 times the RHOD based on body surface area, assuming 100% absorption) prior to and during mating caused preimplantation loss and decreased the number of live fetuses/live births. The NOAEL for fertility in rats was 5 mg/kg/day (106 times the RHOD).

LOTEMAX is a trademark of Bausch & Lomb Incorporated or its affiliates.

© 2019 Bausch & Lomb Incorporated

Bausch + Lomb, a division of Valeant Pharmaceuticals North America LLC
Bridgewater, NJ 08807 USA

LSM.0091.USA.19

Based on 9669600-9669700

Revised: 02/2019


focus lenses, and in the long run they benefit from them.

“In terms of treating residual astigmatism, it’s important to wait until you’re getting measurements that are consistent,” he continues. “I typically do a refraction at four weeks; at that time we check to make sure there’s no residual astigmatism. If there is, and the patient has visual complaints, I’ll often start aggressive dry-eye therapy and have the patient return one to two months later. If the astigmatism is consistent, then I’ll perform topography and check the refraction myself. At that time I’ll make the decision about whether to do an LRI, LASIK or a lens exchange.

“If it’s because of toric lens rotation, the sooner you correct it, the better,” says Dr. Yeu. “Some technologies, such as the iTrace from Tracey Technologies, can measure the internal aberrations and determine what the best position of the toric IOL should be. There’s also a free application at astigmatismfix.com that can help you correct the problem. If you use that, it’s very important to know exactly what the position of the toric lens is at present; then that information has to be coupled with a very careful, accurate manifest refraction, either done by you or by an expert refractionist. Accurate data will be essential for determining exactly how much the lens implant should be rotated in order to minimize the patient’s postoperative refractive error.”

As long as the problem isn’t tied to a toric lens rotating inside the eye, Dr. Yeu says it’s important to wait to address the problem until the patient is finished with the postoperative drops. “If the patient is on generics, I will either switch over to a less-frequent dosing regimen, or initiate preservative-free medications,” she says. “Some patients just have a really tough time with preservatives. It’s not common, but I’ve seen patients whose ocular surface looks like it’s taken a beating

when I see them at the early postoperative follow-up. In that situation, I give them a small sub-Tenon’s aliquot of a steroid, take them off of all other medications and do everything possible to optimize the corneal surface. The steroid will help them for the next two to four weeks. Meanwhile, I’ll have them lubricate aggressively with a preservative-free artificial tear. Once the eye looks better, I may use punctal plugs and have the patient take omega-3 supplements.”


*“If you ignore
complaints, even
if you don’t think
they’re well-founded,
you’ll end up with an
unhappy patient.”*
—R. Bruce Wallace, MD

Dr. Aminlari agrees. “Often, I find that the problem is more of a postoperative dry eye issue,” he says. “That’s why I want to give patients time to get off of their postoperative medications and use some aggressive artificial tears before I make any of those decisions.”

Robert T. Crotty, OD, clinical director at Wallace Eye Associates, says that his experience has confirmed the idea that it’s crucial to wait several months before trying to compensate for an imperfect result. “Recently, Dr. Wallace put toric multifocals in both eyes of a patient,” he says. “The first eye was great; everything went as planned and the patient was very happy. Then we did the second eye and ended up with a little residual astigmatism, and in a different direction than we would have expected. The lens was correctly aligned; there wasn’t any rotation

problem. But the patient couldn’t get clear vision, and we couldn’t refract him.

“We were puzzled, because there was no obvious explanation,” he continues. “All of his retinal findings were normal. He had a little posterior capsular opacity, but it was very early; we didn’t want to do a YAG laser, hoping it might work, because it would make it much harder to exchange the lens if we needed to do that. We treated aggressively with lubrication, to no avail. Even though it hadn’t been 12 weeks since the surgery, we finally decided to explant the lens. However, the patient then came in so that we could redo all the measurements, and he announced that his vision was suddenly fine. We remeasured to see for ourselves, and sure enough, all the problems had gone away.

“The lesson we learned was to stick to our protocol,” Dr. Crotty concludes. “Things really do change over time. That’s why we don’t like to do anything with a patient until about 12 weeks after surgery. This patient is now perfectly happy and doing well, and we didn’t have to do a thing. But it took a little handholding and patience on the part of both doctor and patient to get through two months of poor vision.”

Postoperative Pearls

These strategies can help manage premium patients who present with postoperative concerns:

- **Don’t ignore postoperative complaints, even if you feel they’re unjustified.** “This has to be understood by the entire team, not just the doctor,” Dr. Wallace points out. “That includes the technicians and everyone taking care of the patient. Patients want to feel that you care. If you ignore complaints, even if you don’t think they’re well-founded, you’ll end up with an unhappy patient. At the least, have the patient return for remeasuring and don’t charge for the visit. This

Preoperative Pearls for Preventing Postop Problems

Everyone agrees that the best cure for postoperative problems with premium lenses is preventing them in the first place. Surgeons suggest employing these preoperative strategies to minimize the likelihood of postop trouble:

- **Examine the cornea carefully and address any problems before considering implanting a premium lens.** “When we’re doing preoperative measurements, one of the things we’re looking for is higher-order aberrations, including from the cornea,” says Robert T. Crotty, OD, clinical director at Wallace Eye Associates. “We look for Fuchs’ dystrophy, anterior basement membrane dystrophy and other irregularities. Occasionally, we’ve had patients with nodular degeneration; in that situation we have a corneal specialist do a superficial keratectomy and let that heal for a few months. If the cornea looks better at that point, that patient may be a candidate for a multifocal—or more likely an extended-depth-of-focus lens. Corneal irregularities need to be looked at very carefully before you talk about premium lenses.”

- **Try giving these patients a preoperative personality type questionnaire.** “We show the patient a bar graph where one end is ‘perfectionist’ and the other end is ‘very easy-going,’” explains Dr. Crotty. “We ask the patient to put an X on the line showing where he or she falls on that spectrum. If I see the X by perfectionist, I want to talk more to that patient. There’s nothing wrong with being a perfectionist, but we want the patient to know that it may be difficult to tolerate haloes when driving at night if you

expect your vision to be perfect. No lens out there is perfect, and they need to know that up front.”

- **Make sure patient expectations are realistic.** “Most patients have certain expectations that are not reasonable,” notes Arrdalan Eddie Aminlari, MD, who practices at The Morris Eye Group in Encinitas, California. “That’s why it’s so important to talk to the patient about what to expect postoperatively. I find that I spend more time having that discussion with premium lens patients than I do explaining glaucoma to my glaucoma patients. In fact, they have more concerns than my glaucoma patients.”

Experts also emphasize the importance of covering the possible need for reading glasses postop and the risk of night vision problems. They add that this includes working with doctors in your referral network, to ensure that they don’t set unrealistic expectations that you will then need to dial down. You can also ask referring doctors to give you a heads-up if an incoming patient may have characteristics (such as a Type-A personality) that might prove to be problematic.

- **Make sure the ocular surface is pristine before taking biometry measurements.** “You won’t get accurate biometry if the patient has dry eye,” says R. Bruce Wallace III, MD, FACS, founder and medical director of Wallace Eye Associates in Alexandria, Louisiana. “You have to address the dry eye in order to get the right numbers for the IOL calculation.”

(continued on facing page)

is basic stuff, but it helps to keep the patient happy.”

Dr. Aminlari agrees, noting that it’s important to make sure patients know you’re on their side. “Most postoperative complaints are fixable, so listening to our patients and being an advocate for them is the most important aspect of postoperative care, in my opinion,” he says. “Certainly don’t write off patient complaints. We may do a perfect surgery, but the postoperative period may not be perfect for the patient.”

- **Separate problems that you can address from those that are likely to resolve with time.** Dr. Aminlari points out that making this distinction gets easier with experience. “That’s why it’s important to talk to patients and understand where they’re coming from,” he says. “Then, do a very thorough check to make sure that you’re ruling out the more significant

potential problems such as macular edema or significant dry eye. Those things can be treated, potentially improving patients’ vision, but the majority of patients will have complaints related to high expectations. It’s important to reassure the patient, and make them understand that neuroadaptation to these lenses can take up to six months.”

- **Don’t correct astigmatism based on topography alone, or before the ocular surface is pristine.** “We should not be correcting a residual refractive error based on what we see topographically, especially if there’s a discrepancy between the magnitude and meridian of residual astigmatism on topography versus what you find using your IOLMaster or Lenstar,” says Dr. Yeu. “The topography data may also be altered by a Salzmann’s nodular degeneration or

pterygium, so we have to clean up the ocular surface before we attempt to fix the astigmatic error.”

- **Check for postoperative dry eye.** Dr. Aminlari says dry eye is a significant factor in his patient population (partly because he’s located in California, where it’s usually dry and sunny). “Many patients need to be treated preoperatively for dry eye, but I also see it postoperatively,” he says. “Many of the medications we give these patients postoperatively have preservatives and can cause dry eye. So aggressive treatment of dry eye, both pre- and post-cataract surgery, will be helpful in clearing the surface of the eye to allow optimal vision. You have to remember that the first refractive surface of the eye is the tear film, so to get the best visual function, you have to optimize it.”

- **Make sure your staff is edu-**

Preoperative Pearls (continued)

- **Give every premium patient a macular OCT.** “There’s enough hidden maculopathy out there that any given patient might not be a good candidate for a multifocal implant, but without that OCT you won’t know until you’ve operated,” says Dr. Wallace. “Then you find out that the corrected vision isn’t as good as it should be. A macular OCT will reveal any problem before you proceed.”

- **Give patients plenty of preoperative warning about dysphotopsias.** “Virtually all of the multifocals and extended-depth-of-focus lenses, to some degree, cause dysphotopsia,” says Dr. Aminlari. “Often, in twilight, patients will complain of glare and haloes. With the Symphony lens, for example, they describe a ‘spiderwebbing’ of images. In my experience, patients educated on the potential for this have fewer complaints postoperatively. I hear patients say, ‘It’s not nearly as bad as you made it sound like it could be.’ And of course I reassure patients that this phenomenon will tend to improve over time.”

- **Consider implanting an extended-depth-of-focus lens instead of a multifocal.** Dr. Crotty says that extended-depth-of-focus lenses like the Symphony have some benefits relative to other multifocals. “Some younger patients who work on a computer all day need more arm’s-length vision with these lenses,” he says. “Even truck drivers may get a little bit better night vision, because the haloes and glare issues are noticeably less with extended-depth-of-focus lenses than with a standard multifocal. Those

problems are not entirely gone—so you don’t want to tell the patient that they won’t have any of these issues—but they are less common than with other multifocals.”

Dr. Crotty explains that surgeons in his practice shoot for plano to -0.25 D in the dominant eye, and then maybe -0.5 D in the non-dominant eye, to try to improve near vision with extended-depth-of-focus lenses. “Those patients have to understand that they’ll have a little more trouble reading small print or medicine bottles, and when trying to read in dim light,” he says. “If they understand that on the front end, they’ll do better with that type of lens.”

- **Think twice before putting a multifocal in a patient who has glaucoma.** “I know that some physicians are comfortable putting a multifocal in a patient with mild glaucoma, but glaucoma is a progressive disease,” Dr. Aminlari points out. “In 10 years it could be significantly worse, so someone getting a multifocal now may be in trouble if they develop progressive glaucoma later on. Also, in the subset of patients with pseudoexfoliation, there’s a higher risk of lens instability and potential decentration over time.”

- **If implanting a multifocal or toric lens in a high myope, consider using a capsular tension ring.** “High myopes with high axial length have a little more capsular instability,” Dr. Aminlari points out. “For that reason, if we’re putting a multifocal or toric lens in those patients, we use a capsular tension ring to provide more stability for the lens.”

—CK

cated about the lenses you’re using. “When we start offering an advanced-technology lens, we bring in the company representative to speak to our staff,” says Dr. Aminlari. “The rep tells us about some of the experiences other physicians have had with the lens. Having the staff know about these issues enables them to reassure patients who have complaints after surgery. They can also report to me what the patient is saying.

“This is especially helpful because sometimes patients are more open with a technician than they are with the physician,” he notes. “The patient may not want the doctor to think of him as a complainer, so he may not tell the doctor things that he will tell the technician. That’s another reason it’s good to have my technician be very up-to-date with the technology I’m using.”

Things are Getting Better

Implanting premium lenses can seem daunting to surgeons who aren’t already doing so, in no small part because of the potential for ending up with unhappy patients who have paid extra money out-of-pocket. However, Dr. Wallace hopes that most surgeons aren’t put off, because postoperative issues following premium lens implantation have become less and less frequent.

“I think a lot of surgeons are afraid to use multifocals because patient expectations are so much higher when you have to pay extra money for what you’re getting,” he says. “That’s true, but it’s a problem that can be addressed.

“Unfortunately, surgeons hear horror stories about certain patients and that makes them nervous about offer-

ing these lenses,” he adds. “No one wants to go back to surgery and take a lens out. But it’s important to realize that the problems that might require a premium lens explantation are pretty uncommon these days.” **REVIEW**

Drs. Aminlari, Wallace and Crotty have no relevant financial ties to any product discussed. Dr. Yeu is a consultant for Carl Zeiss Meditec and Bausch + Lomb.

1. Gupta PK, Drinkwater OJ, VanDusen KW, Brissette AR, Starr CE. Prevalence of ocular surface dysfunction in patients presenting for cataract surgery evaluation. *J Cataract Refract Surg* 2018;44:9:1090-1096.
2. Wang L, Guimaraes de Souza R, Weikert MP, Koch DD. Evaluation of crystalline lens and intraocular lens tilt using a swept-source optical coherence tomography biometer. *J Cataract Refract Surg* 2019;45:1:35-40.
3. Trattler W, Donnenfeld E, Majmudar P, et al. Incidence of concomitant cataract and dry eye: A prospective health assessment of cataract patients’ ocular surface. *IOVS* 2010;51:5411.
4. Woodward MA, Randleman JB, Stulting RD. Dissatisfaction after multifocal intraocular lens implantation. *J Cataract Refract Surg* 2009;35:6:992-7.

Peel Back the Veil on ERM Management

Michelle Stephenson, Contributing Editor

Experts weigh in on diagnosis, as well as the timing of the ERM procedure.

Primary epiretinal membrane is common, with a prevalence of 4 to 18.5 percent, and it commonly occurs together with cataracts.¹ In patients with both conditions, surgeons say, setting realistic expectations and deciding which procedure to perform first can improve outcomes and patient satisfaction.

Role of OCT

According to Vance Thompson, MD, who is in practice in Sioux Falls, SD, it's important to perform optical coherence tomography on every routine cataract surgery patient. "This is mainly because we're trying to avoid any disappointing visual surprise. We also do a full dilated retinal evaluation and examine the macula very closely. Sometimes, we have a patient who has an epiretinal membrane that can be seen on OCT, but is not seen on physical exam. Or, you may see something subretinal that you don't see on your exam," he says.

Nick Mamalis, MD, professor of ophthalmology at the University of Utah's John Moran Eye Center, agrees. "Sometimes, especially with moderately dense cataracts, we just don't get a great view, and a very subtle epiretinal membrane can some-

times be missed preoperatively," he says. "You don't want to dilate a patient two weeks postoperatively and see an epiretinal membrane. You really want to know that ahead of time, and I think a good macular OCT is the best way to do that."

Single or Combined Procedure?

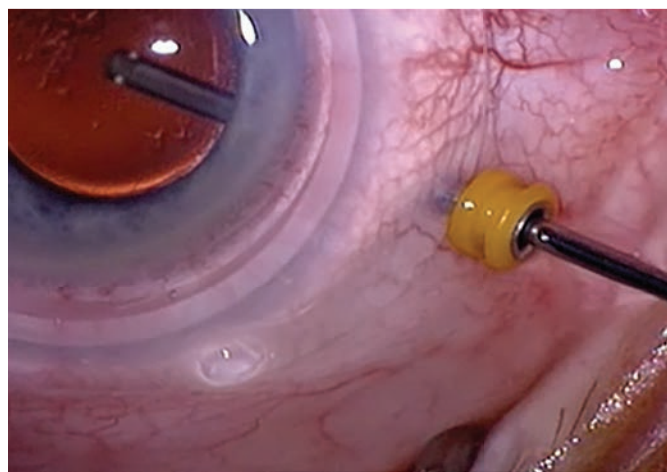
When a cataract patient presents with an epiretinal membrane, surgeons will need to decide whether to perform a combined surgery or perform the cataract surgery first and address the epiretinal membrane at a later time. "Even if I think it's best to perform cataract surgery first, I will usually work with a retinal specialist, especially if it's a pretty significant epiretinal membrane," says Thomas Oetting, MD, clinical professor of ophthalmology and visual sciences at the University of Iowa. "The retina specialist will talk to the patient about the process and the potential for addressing the epiretinal membrane after cataract surgery. Every now and then, the retina specialist will surprise me by saying that he or she wants the patient to undergo a combined procedure."

If the decision is made to do the cataract surgery as the first, stand-alone procedure, the surgeon will

need to take the presence of an epiretinal membrane into consideration. “I always ask myself what I can do for this patient, either if they need a vitrectomy in the future or if they already have decreased contrast sensitivity,” says Dr. Oetting. “So, there are issues regarding IOL choice and the patients’ propensity to experience cystoid macular edema, because these patients are at high risk of developing the condition after surgery. We can try to prevent cystoid macular

edema using prophylaxis. I always make a big deal about showing patients the OCT so that they know what it looks like before cataract surgery. No matter how much you talk about it, patients are always slightly suspicious that the cataract surgery caused the epiretinal membrane. This is one of the main reasons to get an OCT on all routine cataract surgery patients.”

Dr. Mamalis says the decision between standalone and combined procedures depends on how significant the epiretinal membrane is. “If it’s a dense epiretinal membrane and there’s a lot of distortion of the retina, or if there’s any sign of traction on the retina, then the decision would be different than if you were looking at a small epiretinal membrane with minimal distortion, no obvious traction and no obvious edema,” he says. “In the setting of a small epiretinal membrane, I think it’s all right to do the cataract surgery first. Then, if the epiretinal membrane worsens, a procedure can be done later. If there’s a relatively dense epiretinal membrane and it’s causing traction and a lot of distortion, you can perform a combined procedure with a retina colleague.”



H. Michael Lambert, MD

The Moran Eye Center’s Nick Mamalis, MD, says that if a patient has a minor cataract but significant ERM, the retina specialist should perform the membrane peel and vitrectomy before the cataract surgery is done.

Often, with combined procedures, retina specialists like to put their ports in first when the eye is completely pressurized. “In these cases, we’ll have them put in their ports for the vitrectomy, and then put in the irrigation line and keep the pressure fairly low,” Dr. Mamalis explains. “Then, I’ll go ahead and just do my regular phacoemulsification. The only difference is that I put a single 10-0 nylon radial suture in the cataract wound. Even if it’s a 2.4-mm wound, I’ll still put a suture in there so that there’s no chance of the wound opening during the vitrectomy. The retina specialist will then proceed with the vitrectomy and the membrane peel.”

If a patient has an insignificant cataract and a very significant epiretinal membrane, Dr. Mamalis has the retina specialist perform the membrane peel with the vitrectomy first. “Retina specialists are very good at counseling patients and telling them that one of the side effects of a vitrectomy is that the cataract will get worse,” he says. “That can happen relatively quickly, and, in these cases, retina specialists will send the patient back to me for the cataract surgery when it gets bad enough to

warrant surgery.”

Dr. Thompson says that he never performs a combined procedure, and he leaves it up to the retina specialist to decide which procedure should be performed first. “Most retina specialists say it’s tough to predict how visually significant a mild or sometimes even moderate epiretinal membrane can be and to truly make a balanced decision. Many times, they suggest taking out a visually significant cataract first, so that we can quantify how much

the epiretinal membrane is affecting the patient’s vision. However, an epiretinal membrane is not an emergency. Time doesn’t typically affect the success of surgery. It can be helpful to have a patient make an educated decision based on his or her vision post-cataract surgery. You just don’t want a visual surprise. Patient expectations are so high with cataract surgery. If you don’t tell them ahead of time that they have an epiretinal membrane and that their vision may not be as good as they were hoping, then they think the surgery caused it. And that’s the last thing we want,” he says.

Recently, a study was conducted to assess cataract surgery outcomes in patients with epiretinal membranes.¹ The study was a retrospective clinical database study that included 812 eyes with primary epiretinal membrane and 159,184 reference eyes. Compared to the reference eyes, eyes with epiretinal membrane had higher rates of cystoid macular edema and less postoperative improvement in visual acuity.

In this study, epiretinal membrane eyes assessed four to 12 weeks postoperatively gained 0.27 logMAR (approximately three Snellen lines), with

200 of 448 (44.6 percent) improving by 0.30 logMAR or more (≥ 3 Snellen lines) and 32 of 448 (7.1 percent) worsening by 0.30 logMAR or more. Reference eyes gained a mean of 0.44 logMAR (approximately four Snellen lines), with 48,583 of 77,408 (62.8 percent) improving by 0.30 logMAR or more and 2,125 of 77,408 (2.7 percent) worsening by 0.30 logMAR or more. Although all eyes with preoperative VA of 20/40 or less improved, only reference eyes with a preoperative VA better than 20/40 showed improvement. Cystoid macular edema developed in 57 of 663 ERM eyes (8.6 percent) and 1,731 of 125,435 reference eyes (1.38 percent). Epiretinal membrane surgery was performed in 43 of 663 epiretinal membrane eyes (6.5 percent).

Additionally, an Australian study found that combined cataract and epiretinal membrane vitrectomy is just as effective as consecutive operations for improving visual acuity, while reducing the risk of exposing a patient to two separate surgical procedures.²

This retrospective study included 209 eyes: 62 had cataract surgery prior to epiretinal membrane peel, 105 had combined epiretinal membrane peel and cataract surgery, and 28 had cataract surgery after epiretinal membrane peel. Patients who had cataract surgery before epiretinal membrane, versus combined surgery, had improvements in visual acuity at three months (-0.10 vs -0.08) and 12 months post-follow-up (-0.18 vs -0.22), with no significant difference between the groups. There was also no difference between the groups with regard to the proportion of eyes that had perioperative or postoperative complications.

IOI Choice

According to Dr. Oetting, an epiretinal membrane is a contra-

indication to multifocal IOLs, but not to toric IOLs. “Because you’re most likely going to do a vitrectomy, I would not implant a silicone lens,” he says. “Besides those exceptions, I think the IOL discussion is relatively simple. The cataract surgery itself is relatively straightforward. There’s really not that much different about it. I sometimes will put in a slightly larger lens, like an Alcon MA50, because it’s easier to do a vitrectomy with a bigger lens. However, I usually just use a single-piece acrylic lens.”

Postoperative Considerations

Postoperatively, it’s important to avoid cystoid macular edema. Dr. Oetting recommends using the prednisone a little longer. “Instead of doing my usual taper of q.i.d. for a week, then t.i.d. for a week, then b.i.d., then q.d. with prednisone acetate, I might go 6, 4, 3, 2, 1,” he says. “I usually give patients a week to heal postoperatively before starting an NSAID. I typically use Acular (ketorolac tromethamine, Allergan) and Pred Forte (prednisolone acetate ophthalmic suspension, Allergan), as they are inexpensive. We usually place intracameral moxifloxacin, so we do not routinely use a topical antibiotic. I use the NSAID for about a month, and then I assess the patient. If any cystoid macular edema is present, then I will continue it for longer.”

Dr. Oetting sees patients a year after cataract surgery to assess the epiretinal membrane. “We want to see how the epiretinal membrane is doing and assess whether it has gotten to the point where a retina surgeon might want to do a membrane peel,” he says. “If there is some functional decline that appears to be related to the epiretinal membrane following the cataract surgery, I think it warrants having a retina specialist look at the patient.”

Outcomes and Expectations

Dr. Oetting notes that patients with an epiretinal membrane who undergo cataract surgery generally have a good outcome, but says it’s important for patients to have realistic expectations. “Often, there’s some decline in vision that’s related to the retina and some decline in vision that’s related to the cataract, and you’re only addressing the cataract part,” he says. “Cystoid macular edema is a real issue, so you have to warn patients about that, and you have to treat for that. That can be a limiting factor for a while, but it typically lasts only for the first two or three months. Patients can usually separate the symptoms of the epiretinal membrane from the symptoms of the cataract. I explain these differences before surgery, so they can recognize that the distortion and the metamorphopsia that comes from the epiretinal membrane is not going to get much better with the cataract surgery, but the glare and the generalized blur will improve with cataract surgery. This helps patients to not be disappointed with their outcome.”

Dr. Thompson agrees. “Whenever you mention a retinal issue, patients get very concerned, because they’ve heard of things like macular degeneration. It is worth taking time to help alleviate their fears and set realistic expectations,” he says. “It’s important to make sure that they’re psychologically handling the explanation well, and that their expectations are set for surgery to maximize the chance for their success.” **REVIEW**

Dr. Thompson, Dr. Mamalis and Dr. Oetting report no financial interest in the specific products discussed.

1. Hardin JS, Gauldin DW, Soliman MK, Chu CJ, Yang YC, Sallam AB. Cataract surgery outcomes in eyes with primary epiretinal membrane. *JAMA Ophthalmol.* 2018;136:2:148-154.

2. Ng FJ, Allen P, Vote BJ. Combined epiretinal membrane and cataract surgery: Visual outcomes. *Australian Medical Student Journal.* April 15, 2018. <http://www.amsj.org/archives/6366>

COMING 2019

Open your eyes to
what's on the
horizon in dry eye.

Sign up for updates at [TearCare.com](https://www.tearcare.com)

TearCare is indicated for the application of localized heat when the current medical community recommends the application of a warm compress to the eyelids. Such applications would include Meibomian Gland Dysfunction (MGD), Dry Eye, or Blepharitis.

©2018 Sight Sciences. All rights reserved. 06221.A



15

The Continuing Role Of Lasers in PDR

Kristine Brennan, Contributing Editor

Though anti-VEGF is effective, experts say it still may be best to start with PRP in some patients.

Anti-VEGF injections have revolutionized the treatment of neovascular AMD and diabetic eye disease. Prior to their FDA approval—and in the case of bevacizumab, off-label use—pan-retinal photocoagulation was the standard of care for diabetic retinopathy. Laser treatment, however, has drawbacks, including loss of peripheral vision and night vision over a course of repeated treatments. Furthermore, although successful laser treatment helps prevent significant vision loss, it may not yield improved visual acuity to the same degree that anti-VEGF therapy can.¹ Here, retina specialists explain why retinal laser treatments are still vital for managing PDR, even as the hunt for less burdensome, more effective therapies continues.

Choosing One or Both

“I think it’s best handled as a conversation between physician and patient,” says Michael W. Stewart, MD, professor and chair of ophthalmology at the Mayo Clinic Florida in Jacksonville, in reference to the task of helping PDR patients choose whether to try anti-VEGF, laser or a combination of both modalities. “You can start by saying, ‘Here are

two choices, and here are the pluses and minuses of both. Given your health and stability, what would you prefer to do?’ By and large, Protocol S from the DRCR.net [Diabetic Retinopathy Clinical Research Network] demonstrated that visual acuity is about the same with both,” he says.

DRCR.net Protocol S compared visual-acuity outcomes in high-risk PDR patients who received ranibizumab injections and laser treatment.² Patients were randomly assigned to PRP or to six intravitreal ranibizumab injections, administered every four weeks, and then PRN at follow-up. The study showed noninferiority of visual outcomes with ranibizumab therapy in comparison to PRP. “The visual fields are generally better and fuller in patients who receive anti-VEGF therapy, so those patients have better peripheral vision. But overall, VA-wise, outcomes are about the same,” says Dr. Stewart.

The patients who got ranibizumab in Protocol S, however, showed less progression of their PDR than did those who underwent PRP, and more regression of central macular thickness. They also didn’t require vitrectomy as often as the patients treated with laser.

A prospective, interventional case series was conducted in 17 patients (20 eyes) with high-risk PDR, who were treated with intravitreal bevacizumab (2.5 mg) followed by PRP when the peripheral vitreous became clear, or two weeks after injection.³ Although this was a small study (20 eyes of 17 patients) with a mean follow-up of 7.5 months, the Snellen visual-acuity testing and fluorescein angiography suggested that combined intravitreal bevacizumab and PRP was an effective treatment option.

At 52 weeks, the Clinical Efficacy of Intravitreal Aflibercept Versus Panretinal Photocoagulation for Best Corrected Visual Acuity in Patients with Proliferative Diabetic Retinopathy (CLARITY) study demonstrated that patients treated with intravitreal aflibercept had better outcomes than patients who received PRP at one year.⁴

What Does it All Mean?

What do such findings suggest for the future of ophthalmic laser treatments for PDR? “I think it’s patient-dependent, but I personally think the fallback is always laser,” says Dr. Stewart. “The physician and the patient would need to reach an agreement in any individual case. So I think they can agree in certain cases that anti-VEGF would be a better choice, after taking into account concerns such as treatment burden, cost and the possibility of noncompliance.”

Jason Hsu, MD, co-director of retina research at Wills Eye Hospital, associate professor of clinical ophthalmology at Thomas Jefferson University Hospital and in practice at Mid Atlantic Retina in the Philadelphia area, is in agreement about the continuing importance of lasers—in no small part because noncompliance is a risk regardless

of which therapy ophthalmologists and patients choose. “PRP is still an essential therapy for patients with PDR,” he says. “It’s impossible to guess who is going to be adherent with regular visits. By five years, only 66 percent of patients in Protocol S followed up, and that was a clinical trial, where there is generally much closer attention paid to these patients.”

“I think [the physician and patient] can agree in certain cases that anti-VEGF would be a better choice, after taking into account concerns such as treatment burden, cost and the possibility of non-compliance.”

— Michael W. Stewart, MD

Dr. Hsu and colleagues have published two studies: one looking at factors that increase the risk of loss to follow-up in PDR patients⁵ and the other comparing outcomes of PDR in patients lost to follow-up who had PRP and anti-VEGF therapy.⁶

“Given the outcome results we saw in our second study, I would be devastated if even one patient of mine who had anti-VEGF monotherapy was lost to follow-up and went blind, when that could have been prevented with PRP,” he says. Dr. Hsu emphasizes that anti-VEGF therapy is important, too,

however. “I want to be clear that I’m not against anti-VEGF; in fact, I often combine the two treatments,” he stresses. “In cases where patients present with vitreous hemorrhage, I will often start with anti-VEGF until the hemorrhage has cleared enough to permit laser treatment. Also, patients with center-involving diabetic macular edema need anti-VEGF therapy. In both of those scenarios, I’ll try to add PRP as soon as it’s feasible to do so; and I make it very clear to the patient that the injection is only a temporizing measure. In cases of PDR with high-risk characteristics and no vitreous hemorrhage or macular edema, I will go immediately to PRP. But I think every practice also needs to implement a tracking system for these patients, with calls and letters if they miss appointments,” he says.

“We know that PRP has a more permanent effect on regression of neovascular disease, which has been well documented in long-term follow-up studies,” Dr. Hsu continues. “However, the long-term effects of anti-VEGF therapy on controlling neovascularization are somewhat unclear. The DRCR network five-year Protocol S results indicated that most patients still needed, on average, three injections even in year five, suggesting that anti-VEGF monotherapy will require ongoing treatment in the long run to maintain its efficacy,” he says.

The lack of a predictable endpoint for anti-VEGF monotherapy for PDR lends credence to the continuing role of laser treatment, where feasible. “I worry that if a patient with PDR is lost to follow-up for an extended period of time, he may suffer irreversible vision loss if no PRP has been done,” notes Dr. Hsu. “Even the most reliable-appearing patient has unforeseen events, such as loss of a job, loss of health insurance or an extended illness, since

All images: Jason Hsu, MD

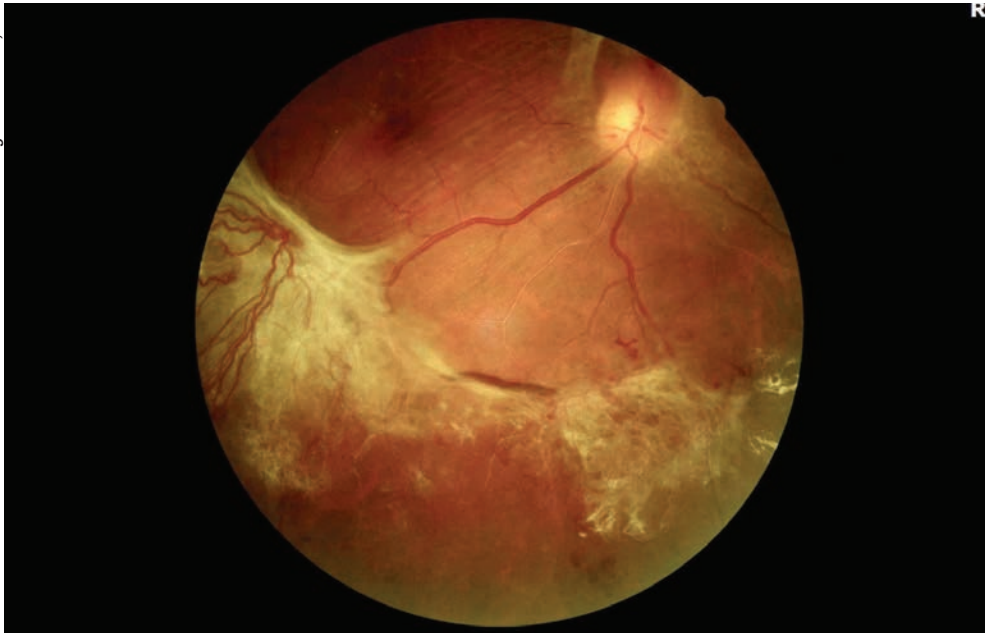

Figure 1. Fundus photo of a 51-year-old diabetic with no prior treatment who presented with proliferative diabetic retinopathy. Severe fibrovascular proliferation can be seen along the inferotemporal arcade of the right eye, causing some retinal striae in the macula.

these are by definition sicker patients. As a result, my general goal is to get PRP in as soon as possible in all PDR patients with high-risk characteristics.”

Dr. Hsu says that his study findings convinced him that reliance on anti-VEGF therapy alone puts patients at long-term risk. “What alarmed me most was that when

that laser offers better control of disease in cases of noncompliance. “In case the patient doesn’t come back, you don’t get a runaway proliferative retinopathy that then leads to permanent vision loss,” he says. “To me that’s an important consideration. One thing that people are now citing as a big factor in favor of laser treatment is that if you take a patient down a road of repeat intravitreal anti-VEGF injections, and then for some reason that patient misses a follow-up appointment—perhaps because they’ve just decided not to come back, or their insurance has changed and they can no longer come back, or because they get sick and they’re unable to return—then once the VEGF drive is turned back on again,

we looked at patients who received either anti-VEGF or PRP, we found that more than a quarter did not return for a year or more—if ever—immediately after the treatment,” he says. “While our study⁵ identified several risk factors for loss to follow-up, including younger age, African-American or Hispanic race, and lower income based on regional average adjusted gross income from ZIP code of residence, the reality is that these factors do not allow us to predict who is going to return for follow-ups accurately.”

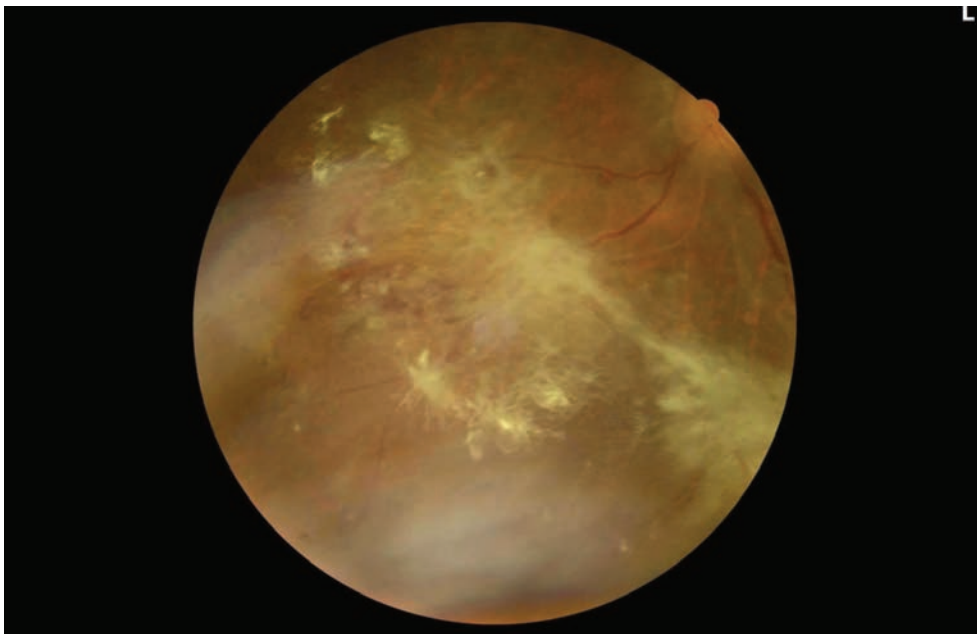


Figure 2. One year later, the active neovascular component has regressed after panretinal photocoagulation, leaving preretinal fibrosis. Visual acuity is 20/40.

there are some patients who'll develop severe proliferative disease and permanent vision loss as a result," he says. "But if laser therapy were already in place, that wouldn't be the case. Some people think that such a reactivation of the VEGF drive is a rebound, and that it may be even more exuberant than it was initially."

Dr. Hsu found that anti-VEGF-only patients he followed fared worse than those who'd been treated with laser.⁶ "Our second study showed that PDR patients who had only received anti-VEGF injections prior to being lost to follow-up had worse outcomes," he says. "Despite visual acuity being fairly similar just before being lost to follow-up, the anti-VEGF group had poorer visual acuity upon return and at the final visit, even after a period of retreatment. This may have been driven by worsening of the PDR, as we saw a significantly higher rate of traction retinal detachment in the anti-VEGF group upon return and at the final visit, with a third of the eyes developing this complication, versus only about 2 percent in the PRP group. In addition, surgery to repair the TRD was performed in 20 percent of eyes in the anti-VEGF group; while no eyes in the PRP group required TRD repair, suggesting the severity was much greater in the anti-VEGF group."

The Search Continues

Dr. Stewart says that other laser modalities have been tried in combination with anti-VEGF injections, but they haven't compared favorably to PRP. "People have pursued peripheral photocoagulation as an adjunct to anti-VEGF therapy for the treatment of macular edema, as a way of down-regulating VEGF," he says. "Thus far, it's been disappointingly unsuccessful. Theoretically, it makes great sense, but practically it's just never worked." He says that micropulse laser therapy

doesn't have robust evidence to back it up at this time, either. "Micropulse is a great treatment," he says, "but it's only been used on small numbers of people, and there aren't any really good randomized controlled trials. The data doesn't really support the treatment. In fact, it probably has no great advantage over standard laser in terms of visual outcomes."

"What alarmed me most was that when we looked at patients who received either anti-VEGF or PRP, we found that more than a quarter did not return for a year or more—if ever—immediately after the treatment."

— Jason Hsu, MD

With regard to pharmaceutical therapies for PDR, the hunt is still on, says Dr. Stewart. Durability would be an important characteristic of future treatments, since compliance is subject to the fallibility of human nature and the vicissitudes of life. "Real life is always more complicated than a prospective research trial," he says, "and in proliferative disease, what we're worried about is the compliance issue. There's the very real risk of runaway proliferative disease.

"It's possible that better future treatments would be able to be put into the eye at less-frequent intervals, but we really don't know how to best define a 'longer-acting' treatment," Dr. Stewart adds. "Would it be six

months? Six years? The longer we're able to have a sustained anti-VEGF effect, then the less potential disadvantage it would have over laser photocoagulation in the long run, but we just don't have such an agent available yet."

The quest for a better therapy may go beyond longer-acting anti-VEGF drugs, according to Dr. Stewart. "Somewhere along the way, we're going to have the ability to reverse diabetic retinopathy," he says. "The anti-VEGF agents will do that to some degree, in that they'll reverse what we see as hemorrhages and exudates and things like that, but they don't really change the underlying perfusion status as much as we'd like. Somewhere along the way, we're going to get a drug that's going to help us reverse nonperfusion, and that's what's going to result in a true reversal of retinopathy. We don't know what form that will take, and we don't know what the biological target would be. But it will be a very attractive treatment option when we have it." **REVIEW**

Dr. Stewart receives institutional research support from Allergan and Regeneron; consults for Alkahest; and is on the advisory board for Bayer. Dr. Hsu receives grant support from Genentech/Roche.

1. Stewart MW. Treatment of diabetic retinopathy: Recent advances and unresolved challenges. *World J Diabetes* 2016;7:16:333-41.
2. Writing Committee for the DRCR Network, Gross JG, Glassman AR, Jampol LM, et al. Panretinal photocoagulation vs intravitreal ranibizumab for proliferative diabetic retinopathy: A randomized clinical trial. *JAMA*. 2015;314:2137-2146.
3. Yang C-S, Hung K-C, Huang Y-M. Intravitreal bevacizumab (Avastin) and panretinal photocoagulation in the treatment of high-risk proliferative diabetic retinopathy. *J Ocul Pharmacol Ther* 2013;29:6:550-555.
4. Sivaprasad S, Prevost TA, Vasconcelos JC, et al. Clinical efficacy of intravitreal aflibercept versus panretinal photocoagulation for best corrected visual acuity in patients with proliferative diabetic retinopathy at 52 weeks (CLARITY): A multicentre, single-blinded, randomised, controlled, phase 2b, non-inferiority trial. *Lancet* 2017; 389:10085:2193-2203.
5. Obeid A, Gao X, Ali FS, Talcott KE, Aderman CM, Hyman L, Ho AC, Hsu J. Loss to follow-up in patients with proliferative diabetic retinopathy after panretinal photocoagulation or intravitreal anti-VEGF injections. *Ophthalmol* 2018;125:1386.
6. Obeid A, Su D, Patel SN, Uhr JH, Borkar D, Gao X, Fineman MS, Regillo CD, Maguire JI, Garg SJ, Hsu J. Outcomes of eyes lost to follow-up with proliferative diabetic retinopathy that received panretinal photocoagulation versus intravitreal anti-vascular endothelial growth factor. *Ophthalmol* 2019;126:3:407-13.

The Artificial Iris In Practice

Christopher Kent, Senior Editor

The first approved iris prosthesis is helping many patients—although it has limitations.

Although customized intraocular replacements for a damaged iris have been available for some time outside the United States, it's only recently that the CustomFlex ArtificialIris, created by HumanOptics in Germany, became the first stand-alone prosthetic iris to receive approval from the U.S. Food and Drug Administration. To date, there's still no billing code allowing financial reimbursement for implanting the device, but surgeons are nevertheless pleased to have something to offer patients who need an iris prosthesis.

Here, surgeons who have implanted the device share some of their experience and advice.

Characteristics of the Device

The CustomFlex ArtificialIris is a flexible, biocompatible silicone device indicated for use in adults or children with congenital aniridia and/or iris defects. It has a black, opaque back surface that completely absorbs light, only allowing light to pass through the fixed, central 3.35-mm aperture. Compared to vision with a damaged or missing iris, this improves contrast sensitivity, reduces glare and light sensitivity and eliminates transillumination defects. The Customflex can also improve an individual's cosmetic

appearance by eliminating visible iris defects. The prosthesis is custom-designed to mimic the appearance of the patient's other (undamaged) iris, based on photographs approved by the patient and surgeon. The pupil opening has an undulated edge resembling that of a natural iris.

When implanting the device, the outside diameter is cut to the appropriate size for the patient's eye using a trephine. The CustomFlex can be inserted into the ciliary sulcus using a sclerocorneal approach, or via "open sky" during penetrating keratoplasty. (The company notes that the device can also be implanted in the capsular bag.) It comes in two formats: with or without fiber. The former design allows suturing of the device, if needed; the latter design does not.

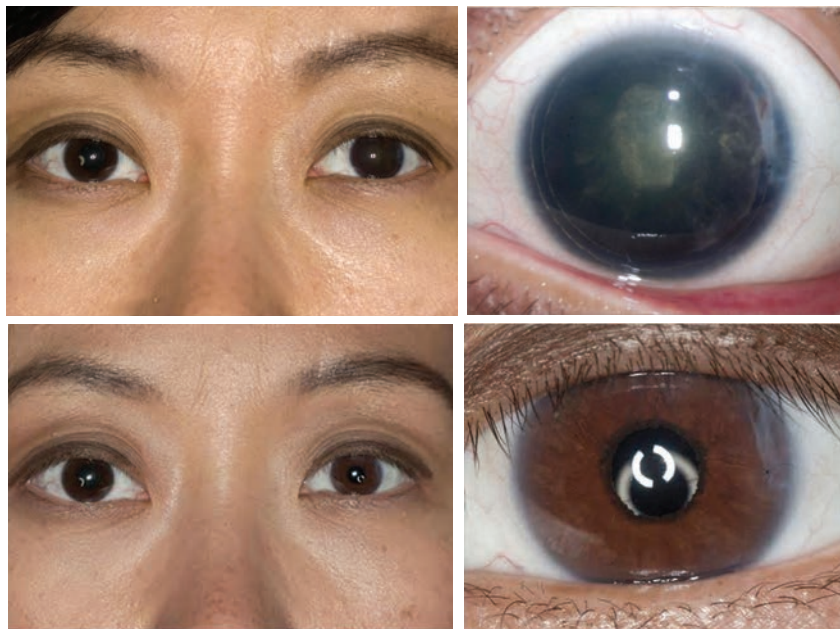
The FDA approval followed a non-randomized clinical trial involving 389 patients. More than 70 percent of subjects receiving the implant reported a significant decrease in light sensitivity and glare, and significant improvements in health-related quality of life. Furthermore, 94 percent reported satisfaction with the outcome. Complication rates were low; they included dislocation, strands of device fiber in the eye, increased IOP, iritis and the need for additional surgery to reposition, remove or replace the device.

The Patient Experience

“These can be some of the most gratifying cases an ophthalmologist may encounter,” says Michael E. Snyder, MD, who practices at the Cincinnati Eye Institute and is volunteer assistant professor at the University of Cincinnati School of Medicine. “Patients who get the custom, flexible artificial iris often refer to the experience as being ‘life-changing.’ As one might expect, many folks with iris damage or deformities have suffered with light sensitivity, glare, halos, arcs and monocular shadow images. In the overwhelming majority of patients, most or all of the patient’s photic symptoms are relieved after device placement. How people feel about the restoration of a more normal appearance to their eyes can also be quite dramatic.

“As ophthalmologists, we often don’t appreciate the degree to which patients feel like their vision is washed out because of the iris defects,” he continues. “This is especially true in pseudophakes. As it turns out, any light that enters the eye around the periphery of the IOL margin is defocused. This affects vision much like the experience of being in a movie theater when someone opens the door to the theater, letting light in from the outdoors. Even though the projector is still focused on the screen with the same number of lumens of light, the viewing experience is diminished by the defocused excess light.”

Kevin M. Miller, MD, Kolokotronis Chair in Ophthalmology at the David Geffen School of Medicine, UCLA, was an investigator during the FDA clinical trial of the artificial iris. Many of the patients he now treats that receive an artificial iris have suffered serious ocular damage, and he notes that it’s not always easy to determine how these patients feel about receiving an artificial iris, because they have so many other ocular problems. “Patients with iris defects typically have



Kevin M. Miller, MD

An example of an excellent outcome. Top images: This patient suffered a blunt injury to her left eye following phakic intraocular lens implantation; the iris and the implantable contact lens were expelled, leaving her aniridic with a cataract. She then underwent cataract extraction with intraocular lens implantation and passive fixation of a dark brown custom artificial iris in the ciliary sulcus. Bottom images: Three months later the color match is excellent and the iris is perfectly centered.

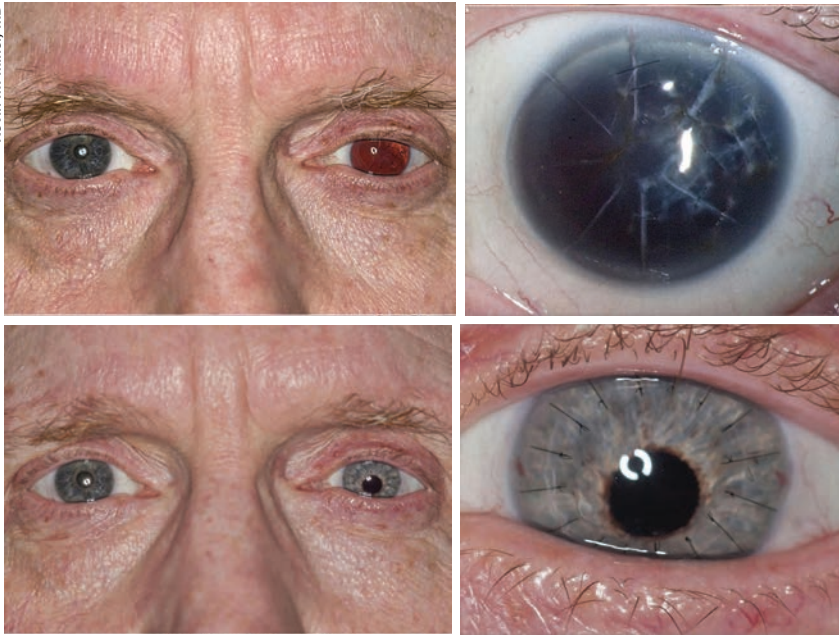
suffered trauma, leaving them with a boatload of other issues,” he says. “By and large, these are sick eyes. Their cornea is often decompensating; many have glaucoma as a side effect of the trauma; they may have double vision, a retinal detachment or silicone oil in the eye. An iris defect is just one of their problems. For example, I had a patient whose eye was gutted when a bungee cord snapped and the hook on the end ripped through his eye and lids. Another patient had his globe ruptured by flying glass from a broken bottle. In my experience, 95 percent of the cases needing an iris are like that.”

What about patients whose eyes haven’t suffered trauma? “It’s a rare patient in my practice who is born with some or all of the iris missing, although we do see a few,” says Dr. Miller. “But even those patients have additional comorbidities. A congenital aniridic, born without an iris, may have a limbal stem cell deficiency; the

cornea may be hazy; abnormal corneal blood vessels may have grown in; and severe dry eye, epitheliopathy, nystagmus or early cataracts may also be present. Aniridic capsules are thin and easy to tear, and these patients often have glaucoma. So even the nontraumatized eyes have lots of comorbidity.

“Because of that, when we do surgery on these eyes, we try to fix as many of these problems as we can,” he explains. “We might be doing a corneal transplant, lens exchange, cataract removal or a host of other things. The recovery may be long and difficult, not because of the artificial iris, but because of all the other problems. Once a corneal transplant is healed, the patient may have double vision, so we have to fix that. Once we fix the double vision the patient might have a blepharoptosis and we might have to fix that. Some of these problems go on for years and years. As a result, the patient’s feelings about the artificial iris are hard to capture because they

Kevin M. Miller, MD



An example of an imperfect outcome. Top images: This patient suffered a ruptured globe injury that resulted in expulsion of his iris and lens. The injury left him aphakic with a badly scarred cornea and no iris. Bottom images: The patient's appearance three months after penetrating keratoplasty and scleral suture fixation of a posterior chamber intraocular lens and custom-painted blue artificial iris. The iris is inferiorly decentered and the color match to the iris in the right eye is less than ideal.

go through so much.”

Despite these caveats, Dr. Miller notes that patients are rarely, if ever, unhappy with the artificial iris itself. “Does anybody every regret having had the artificial iris put in? Definitely not,” he says. “The artificial iris solves the light and glare sensitivity problem, and it improves the cosmetic appearance of most patients’ eyes.”

The Challenge of Iris Matching

Although the premise of matching the appearance of the artificial iris to the other eye’s iris makes perfect sense, getting a perfect match is more difficult than it may sound.

“While the devices are custom-made to match an index photo taken of the fellow eye, there can be subtle variations in color and luminosity of the device in different lighting conditions,” Dr. Snyder explains. “The appearance can vary a bit more than native iris tissue. A realistic expecta-

tion is that the custom iris will typically look either the same as, or very similar to, the fellow eye at what I call ‘cocktail party distance’ in normal room lighting.”

Dr. Snyder also points out that the actual diameter of the artificial pupil (3.55 mm) is different from the size observed from outside the eye. “What we ophthalmologists usually think of as pupil size is actually the size of the entrance pupil, or the appearance of the pupil as seen through the cornea’s magnification,” he explains. “Accordingly, the apparent pupil size in an eye with an indwelling CustomFlex ArtificialIris is roughly 4 mm.”

“I’d say that after the eye has settled down, most patients are pleased with the cosmetic appearance of the eye,” says Dr. Miller. “However, it’s usually not perfect. In fact, it’s far from perfect for many patients, for two reasons. First, they may have cosmetic issues because of the other problems we’re addressing, such as scarring from a

corneal transplant, a misaligned eye or a ptosis. If you have a nice artificial brown iris, but your eye is chronically inflamed because of all the surgeries you’ve been through, you may not feel too good about your eye, regardless of how good the artificial iris looks.

“Second, there are many factors that can lead to an imperfect match with the other eye, despite everyone’s best efforts,” he continues. “Although the artificial irises are hand-painted, the process by which the company paints the iris isn’t perfect. We send photographs of the fellow eye to Germany, where artists paint the prosthetic iris based on the photograph they receive. But you can imagine all of the steps along the way that could result in imperfect color matching, including the lighting when the photo is taken, the color saturation in the image and the spectral sensitivity of the film or digital camera. Then we have to print the image on paper to send it, and the printing process introduces color errors. Last but not least, the brightness is altered a little when you place an artificial iris inside an eye. The cornea focuses a lot of light onto the iris, so it looks much lighter inside the eye than when you hold it in your hand. Of course, we do our best to compensate for all of this, but matching the color and brightness is very challenging.”

How Hard Is It to Implant?

Dr. Miller says the difficulty of implanting the artificial iris varies widely depending on the patient’s situation. “In some cases it’s very easy to implant,” he says. “Sometimes you can just inject it using an AMO Silver Series injector and unfold it. But sometimes it’s very difficult because of the other issues the eye presents.

“The company that’s distributing the artificial iris, VEO Ophthalmics, won’t let you implant these unless you meet a number of criteria,” he notes. “For one thing, you have to show that you

LOMBART

SERVICE SOLUTIONS

A CONFIDENT DIAGNOSIS STARTS WITH YOUR EQUIPMENT

We have dedicated, factory-trained technicians across the country available to service your instruments. Additionally, our Clinical Support team can remotely access your advanced technology products to troubleshoot quickly.

INSTRUMENT REPAIRS

Our certified ophthalmic Service Technicians conduct on- and off-site repairs nationwide, helping you minimize downtime and treat your patients. Our extensive parts inventory enable us to get you up and running quickly, oftentimes in only one visit. We're here for you – if we sell it, we service it.

PREVENTATIVE MAINTENANCE

Improve performance and extend the life of your instruments by having us check functionality, clean, calibrate, and complete a general service of your equipment at regular intervals. We complete multi-point inspection checklists to fine-tune your lane from top to bottom.

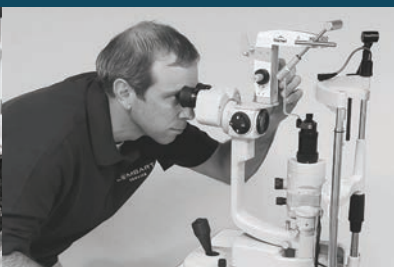PHOROPTER CLEANING

A phoropter cleaning is not simply wiping down the external lenses. We break the instrument down and clean/lubricate every piece, repair/replace all worn parts, align all cylinder lenses, cross cylinder lens axes, and readout scales, then perform a complete functional performance check against OEM specifications.

RELOCATION SERVICES

Office moves can be hectic and complicated. It's not worth the risk of damaging your expensive instruments – we can help. Our trained service technicians safely pack, move, reinstall, and recalibrate your instruments. We also provide temporary storage solutions in some cases – just ask!

ASK US ABOUT COMPREHENSIVE PROTECTION PLANS
FOR YOUR ENTIRE OFFICE. [800.LOMBART](tel:800.LOMBART)



have considerable experience doing complex ophthalmic maneuvers inside the eye. You have to have experience with lens exchange and related procedures. That makes sense, because these eyes are often very complex, messed-up eyes, and it takes a surgeon with a broad skill set to be able to deal with all of the other issues that may accompany implanting an iris. The company doesn't want to have surgeons with limited experience attempting to implant these devices and making the eye worse than it was to start with."

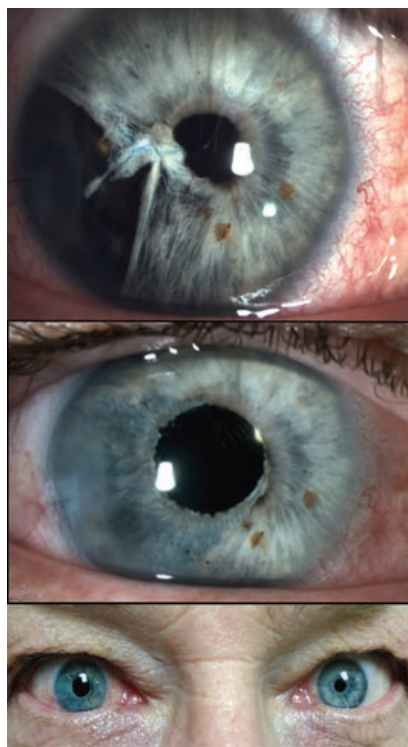
Dr. Snyder says there definitely is a learning curve to implantation. "As with surgery in any complex eye, some cases are harder than others," he notes. "VEO Ophthalmics, the distributor of the CustomFlex, has developed a rather robust training program; several investigators from the initial study serve as mentors to new implanters. Surgeons who are experienced and facile in complex cases such as scleral-sutured PCIOLs, or cases involving vitreous management in the anterior segment or management of zonulopathy, will find their skill sets will serve them well as they acquire experience working with iris prosthesis patients."

The manufacturer notes that the CustomFlex should not be implanted in patients who are pregnant, or have an active ocular infection or uncontrolled inflammation; any untreated medical issues that are potentially vision-threatening; rubeosis of the iris; proliferative diabetic retinopathy; Stargardt's retinopathy; or any disorder that might cause the eye to be abnormal in size, shape or function.

Strategies for Success

Surgeons offer these suggestions to increase the likelihood of ending up with a good outcome and a happy patient:

- **Don't overpromise the result.** Patients need to be forewarned that the outcome could be less than per-



Michael E. Snyder, MD

Even when the color match is excellent and the artificial iris is well-centered, the changing size of the natural iris in the other eye can cause the eyes to be an imperfect match in bright or dim lighting conditions.

fect, both in terms of appearance and in terms of resolving visual difficulties. "As with any procedure, setting patient expectations is important," says Dr. Snyder. "It's worth mentioning that the fellow eye's pupil size will be changing with ambient light while the custom iris aperture stays constant. As a result, in bright sunlight the fellow eye may have a smaller pupil than the pseudopupil of the custom iris, while in a very dim room, the fellow-eye pupil may appear larger."

Iris color may also be a giveaway in some cases. "The match [between the eyes] should be close, but the colors will be off a little bit," notes Dr. Miller. "As a result, in about half of these eyes you can't tell that the patient has an artificial iris, but in others, you can tell.

"Also," he continues, "it's hard to perfectly position the iris inside the eye when suturing it in place. As a

result, the pupil is often a little bit off-center. When suturing it in an open-globe configuration, which is what we do most of the time, it's very hard to center the device. You don't really know how the iris is going to sit relative to the center of the cornea until the eye is closed up and pressurized. By that point, if it's not perfectly centered, there's too much trauma associated with reopening the eye to start over again, so we generally don't.

"How obvious any decentration is depends partly on the color of the iris," Dr. Miller adds. "If it's a light blue or green iris, it can be very obvious when it's not perfectly centered. If it's a dark brown iris, nobody can tell."

Dr. Snyder notes that patients need to understand that the prosthesis won't address other visual issues. "Eyes that benefit from an iris prostheses also tend to have other comorbid pathologies," he points out. "Visual limitations are more commonly set by these other factors."

Dr. Miller agrees. "We have to put this in the context of all of the other problems these patients present with," he says. "If the patient has a macula-off retinal detachment and a dense cataract and a cornea scar, we're going to do our best to fix all of this. However, the patient will still have issues postoperatively because of all of these other problems, and there will probably be additional surgeries in the patient's future. We have to make sure the patient understands this. Don't oversell the final result."

- **Don't be shy about deciding to learn the procedure.** "If you occasionally treat patients with traumatized or missing irides, this should be part of your armamentarium," says Dr. Miller. "There is a learning curve, but you have to take the first step at some point. Most of the procedures we do have a prescribed certification protocol that you have to go through, and expanding your skill set is an important part of being a surgeon."

“However,” he adds, “if you only encounter a traumatized or missing iris once a year, it probably makes more sense to refer that patient to another surgeon. You need to do a lot of these surgeries to become good at it, and you won’t become good at it doing one patient every year.”

• **Be prepared to implant the iris for free.** “If you’re going to get into this, you’re going to be doing it for free for a while,” Dr. Miller points out. “There’s no billing code for this right now, so patients pay for the iris, but the surgeon does the surgery for free.”

• **If a cataract patient needs an artificial iris, don’t do the cataract surgery first and then refer the patient for the other procedure.** “I’ve had patients referred to me this way, with the best of intentions,” says Dr. Miller. “It may be a simple case, like congenital aniridia with a cataract. The other doctor says, ‘I’ll take out your cataract and it will make you better.’ Actually, it makes them a lot worse. Their glare sensitivity usually gets much worse after the cataract comes out, because now light hits the edge of the IOL implant and the capsule that’s opacified around the implant.

“These patients should have the iris implanted at the same time the cataract surgery is done,” he explains. “Besides leaving the patient with worse vision, separating the surgeries results in a much greater cost to the patient. If we do both surgeries at once, we can bill for the cataract surgery and put in the artificial iris for free. If the only reason for the trip to the OR is to implant the iris, the patient may be looking at a huge bill for both the iris and the trip to the OR. That OR cost would have been covered by insurance if both surgeries had been done at the same time.”

At Last, an Option

As mentioned earlier, the CustomFlex is now being distributed through VEO Ophthalmics. It takes four to eight weeks for the custom iris to be delivered after receipt of the order and the approved photographs.

“I’m glad we finally have an approved artificial iris,” says Dr. Miller. “Only a few patients will need the iris, fortunately, but it’s nice to finally have something we can offer when patients have a messed-up eye. Artificial pupil contact lenses are hard and uncomfortable to wear, and they don’t really solve all of the problems that come with a disrupted or missing iris. The only other alternatives are tinted glasses and patching the eye. Now we have an option that didn’t exist before.”

For more information about obtaining the device, visit veo-ophthalmics.com. [REVIEW](#)

Dr. Snyder is a consultant for HumanOptics. Dr. Miller has no relevant financial interests.

(Continued from page 20)

In a study involving the nGoggle, researchers (some of whom have a financial interest in nGoggle Inc.) sought to objectively assess visual function loss in 62 eyes of 33 glaucoma patients. Each subject underwent VF testing using the nGoggle and a standard automated perimetry test over the course of three months. The nGoggle was able to distinguish between healthy eyes and those with glaucomatous neuropathy.⁹ Researchers measured values such as receiver operating characteristic curves summarizing diagnostic accuracy, intraclass correlation coefficients and coefficients of variation for assessing repeatability. The ROC curve area for the nGoggle mfSSVEP was 0.924 (95% CI: 0.863-0.964), which was larger than SAP MD (AUC=0.813; 95% CI: 0.716-0.896), SAP MS (AUC=0.797; 95% CI: 0.687-0.880; $p=0.030$) and SAP PSD (AUC=0.768; 95% CI: 0.657-0.858; $p=0.012$).⁹

As the nascent field of portable visual field testing continues to develop, we’re reminded of how much technological advancements play a role in enabling new diagnostics, that don’t need to be restricted to the medical office. These new enhancements may make visual field exams more interesting, faster and more reliable. Moving forward, generating more functional visual data will be useful for quantifying rates of progression more accurately to match with optimally timed interventions. Automated algorithms will continue to improve as we enter the era of big data, driven by Internet-connected portable devices. [REVIEW](#)

Robert Chang, MD, is an ophthalmologist at Byers Eye Institute at Stanford Eye Institute.

1. Kucur S, Holló G, Sznitman R. A deep learning approach to automatic detection of early glaucoma from visual fields. *PLoS One* 2018;13:11:e0206081. doi: 10.1371/journal.pone.0206081. eCollection 2018.
2. Ting DSW, Pasquale LR, Peng L, Campbell JP, Lee AY, Raman R, Tan GSW, Schmetterer L, Keane PA, Wong TY. Artificial intelligence and deep learning in ophthalmology. *Br J Ophthalmol* 2019;103:167-175.
3. Li F, Wang Z, Qu G, Song D, Yuan Y, Xu Y, Gao K, Luo G, Xiao Z, Lam DSC, Zhong H, Qiao Y, Zhang X. Automatic differentiation of glaucoma visual field from non-glaucoma visual field using deepconvolutional neural network. *BMC Med Imaging* 2018;18:1:35.
4. Asaoka R, Murata H, Iwase A, Araie M. Detecting preperimetric glaucoma with standard automated perimetry using a deep learning classifier. *Ophthalmology* 2016;123:1974-80.
5. Johnson CA, Thapa S, George Kong YX, Robin AL. Performance of an iPad application to detect moderate and advanced visual field loss in Nepal. *Am J Ophthalmol* 2017;182:147-154.
6. Prea SM, Kong YXG, Mehta A, He M, Crowston JG, Gupta V, Martin KR, Vingrys AJ. Six-month longitudinal comparison of a portable tablet perimeter with the Humphrey Field Analyzer. *Am J Ophthalmol* 2018;190:9-16.
7. Vingrys AJ, Healey JK, Liew S, Saharinen V, Tran M, Wu W, Kong GY. Validation of a tablet as a tangent perimeter. *Transl Vis Sci Technol* 2016;5:4:3. eCollection 2016 Jul.
8. Tsapakis S, Papaconstantinou D, Diagourtas A, Droutsas K, Andreanos K, Moschos MM, Brouzas D. Visual field examination method using virtual reality glasses compared with the Humphrey perimeter. *Clin Ophthalmol* 2017;11:1431-1443
9. Nakanishi M, Wang YT, Jung TP, Zao JK, Chien YY, Diniz-Filho A, Daga FB, Lin YP, Wang Y, Medeiros FA. Detecting glaucoma with a portable brain-computer interface for objective assessment of visual function loss. *JAMA Ophthalmol* 2017;135:6:550-557.

MSICS and miLoop for Non-phaco Candidates

Alexandra Skinner, Associate Editor

What to do when the gold standard, phaco, isn't an option.

Phacoemulsification has become the status quo for surgeons performing cataract removal in the United States. However, even this gold-standard technique has its drawbacks. Some patients cannot safely undergo a phaco procedure due to underlying endothelial issues or mature cataracts. Also, for many locations in the developing world, phaco is not an economical option. While phaco may be the current surgical approach of choice, techniques like sutureless manual small incision cataract surgery and devices like the miLoop can play a role in cataract removal for non-phaco candidates in the United States and in the developing world. Here, experts share their tips and techniques for cataract surgery in patients who can't, or shouldn't, undergo phaco.

The Non-phaco Candidate

Several factors can make a patient a better candidate for a procedure other than phaco. These include having a weak corneal endothelium or dense cataract, or living in the developing world with limited access to health-care resources.

Since phacoemulsification delivers ultrasonic energy as it breaks up the

cataract, the procedure can cause stress to the endothelium. Nick Marmalis, MD, a professor of ophthalmology at John Moran Eye Center, University of Utah notes, "If you have someone with an endothelial dystrophy, you want to remove the lens nucleus with as little energy as possible."

On a similar note, even if a patient has no existing corneal issues, if he has a very hard cataract, he'll have to undergo extended phacoemulsification to break it up, which can still pose problems. Hunter T. Newsom, MD, medical director of Newsom Eye and lifetime visiting professor at the University of Iowa says, "When you have a cataract that's extremely hard and dense, you have to use a large amount of phaco, and that's going to cause a more significant amount of energy to be put inside the eye, which is going to damage the corneal endothelium."

Patients in the developing world frequently present with advanced cataracts. "Oftentimes in the developing world you have patients with a relatively hard, dense, leathery nucleus, which requires a lot of ultrasound energy to remove," says Dr. Marmalis. On a recent trip to South Sudan, Alan Crandall MD, the John A. Moran Presidential Pro-

fessor, senior vice chair and director of glaucoma and cataract at the Moran Eye Center, says, “All we saw were dense, white, sometimes black cataracts.” Also, in some parts of the world, it’s not possible to set up a fully equipped phaco surgery suite, and other options need to be explored.

Manual Small Incision Cataract Surgery

As a viable alternative to phaco, MSICS uses little to no ultrasound energy and is very economical.

MSICS involves the use of a scleral tunnel incision. While the incision itself is only about 5 to 6 mm long, it’s created in such a way that it becomes larger as it nears the anterior chamber. This aids in the removal of the natural lens, which is accomplished using a syringe or a glide. The syringe creates suction, while the glide uses pressure to gently force the lens out. One of the other benefits, proponents say, is that sutures aren’t required with this technique, due to the small incision.

Here’s a closer look at MSICS’ advantages, disadvantages, potential pitfalls and results.

• **MSICS’ advantages.** While not as technologically advanced as modern cataract removal, some surgeons say that MSICS—sometimes called extracapsular cataract extraction—has several advantages. — MSICS can effectively remove cataracts without energy, therefore minimizing endothelial damage. “Extracaps applies a lot less trauma to the corneal endothelial cells,” says Dr. Newsom. — MSICS allows the cataract to be removed whole, which also helps



Figure 1. In the Dominican Republic, patients wait in long lines to be evaluated. Dr. Newsom says that doing surgery quickly and efficiently is important where there are a large number of cataract patients, and eliminating the need for sutures allows for rapid surgery.

protect the endothelium, since the surgeon doesn’t need to use energy to break it up. Dr. Mamalis says that the incision is actually wider as you’re coming out of the anterior chamber. “The advantage here is that you don’t have to disassemble a hard lens nucleus,” he says. — MSICS can be economical. “The instrumentation for extracaps includes things that can be used multiple times,” says Dr. Newsom. This reusability helps keep the technique inexpensive. This is one of the main reasons that MSICS is such a viable option for those in the developing world. Comparatively, Dr. Mamalis says there are challenges associated with using phaco in the developing world. “Since it’s relatively expensive, there are difficulties in just getting the phacoemulsification machine, he says. “There’s a significant expense involved with the necessary tubing, packs and tips.” Dr. New-

som expands on this idea, citing added costs associated with the disposable instruments and accessories. “Single-use is the way that all modern phaco machines are trending,” he says. “It’s very rare that you have things that are reusable, and this serves to drive costs up, not down.” — MSICS allows you to use a sutureless incision, which Dr. Mamalis says adds to its feasibility in the developing world. “Sutures add an expense and take increased surgical time to place,” he says. “When you’re in a setting where there are a large number of cataract patients and you have to do surgery as quickly and efficiently as possible, eliminating the need for sutures allows for rapid surgery.”

Dr. Crandall emphasizes that MSICS still has a place in the United States. “In Utah, we treat refugees and people in the Navajo Nation, and at least once or twice we see a dense, white cataract or a morgagnian cataract. Those are unlikely to be phacoable, so we’ll go ahead and perform an extracaps,” he says.

• **MSICS disadvantages.** While MSICS is inexpensive and effective, there are disadvantages to the technique. A cornerstone of MSICS is that the cataract can be removed whole. However, this can sometimes prove to be more complicated than it sounds. “Even though it’s called small-incision, you still make a fairly large incision through the sclera and the cornea,” Dr. Mamalis says.

Dr. Newsom notes other possible incision issues: “If you’re going into the sclera, you’re going to have to do a peritomy or go through the conjunctiva in some way,” he says.

Hunter I. Newsom, MD

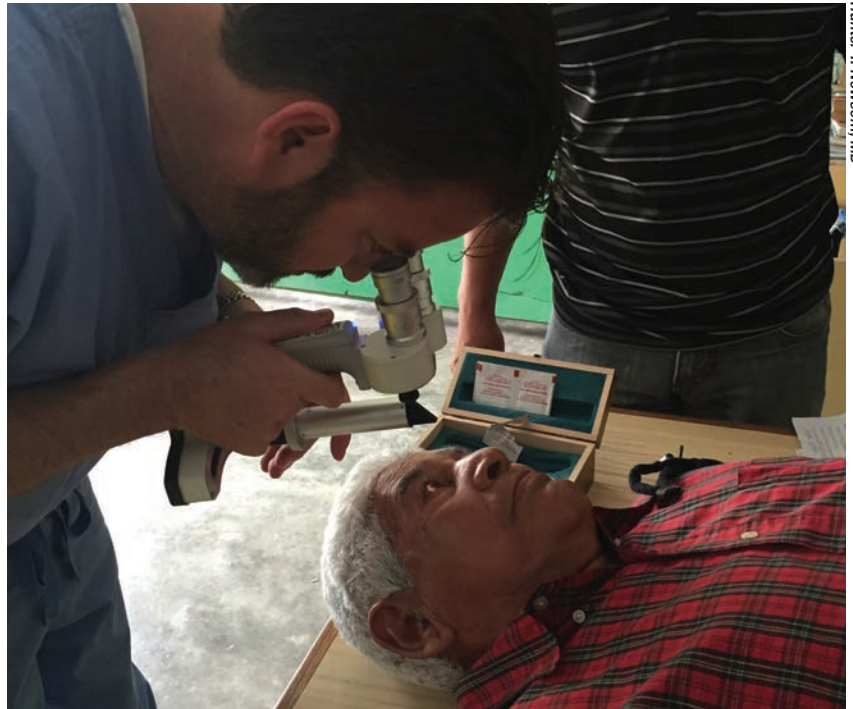“You’re going to be cutting blood vessels at the limbus and pulling the conjunctiva, and that introduces blood and [the need for] cautery. The eye is going to look a lot redder and more injected.” For the entry wound, Dr. Mamalis prefers a scleral frown incision. “You want to make sure that, as you’re making the scleral incision, you’re at the correct depth and that the inside opening is large enough to allow you to remove the relatively large lens nucleus,” he says.

The capsulotomy size can also be a challenge. “Whether you’re doing a can-opener type opening or a continuous capsulorhexis, it can be difficult to get the large cataract out of the bag and into the anterior chamber,” says Dr. Newsom. As a result, Dr. Mamalis says, the surgeon needs to make a capsulorhexis that’s large enough to get the nucleus out of the bag whole. Dr. Newsom suggests using Trypan blue to help accurately perform the capsulorhexis.

Another consideration is that since extracapsular surgery preceded the advent of phacoemulsification, it’s not usually taught to surgeons anymore, especially in the United States. “Newer surgeons don’t do a lot of extracapsular surgeries,” says Dr. Mamalis. “To be honest, a lot of our residents aren’t trained on many extracapsular cases, so it’s unfamiliar territory to them.” Dr. Crandall adds, “It’s hard to teach people this technique. The problem is that the rate of seeing patients with non-phacoable cataracts in the U.S. is small.”

• **Pitfalls.** A few MSICS trouble spots to watch out for include complications with the procedure itself and the rate of postop astigmatism.

Dr. Newsom discusses some potential complications to be aware of. “You have all kinds of chamber-depth issues,” he says. “You’ve got everything coming up and it tends to bang on the cornea. With extracap, everything is shallower, and the iris can get



Hunter T. Newsom, MD

Figure 2. Minor surgery is conducted on a patient in the Dominican Republic by Hunter Newsom, MD, and his team.

damaged or try to come out of the wound, which can potentially create a hemorrhage.” He adds that there’s more corneal edema and inflammation, and that healing is slower for extracapsular surgery compared to phaco.

In terms of astigmatism, there’s only so much that can be done in certain countries. “In the developing world, you know there’s going to be a huge amount of astigmatism, but the cataract is gone and they can see again [which is the most important aspect of the surgery],” says Dr. Newsom. Dr. Crandall agrees, saying, “The priority is to restore vision. We’re talking about people who are seeing light perception; all they can see is light or dark. First and foremost, we’re interested in getting patients back on the chart and walking around. It’s not that we don’t care about astigmatism, but when you have 500 people who have light-perception cataracts, and you have five days to perform procedures, [you

just can’t measure it].”

In reference to his past work in the Dominican Republic, Dr. Newsom says IOL selection was a challenge. “Determining what type of lens power to put in the eye and measuring astigmatism is difficult,” he says. “We didn’t have the precision of our usual keratometry measurements.” When comparing the developing world to the United States, he likens the IOL selection-process to getting a pair of shoes; he says that, in the United States you can choose from many different numbered sizes, but in the developing world, he says, you may only have sizes small, medium and large, “You have what you have, and there’s not a big selection to choose from,” he says.

• **MSICS results.** In a study that compared the efficacy and visual results of two different MSICS methods, called “modified Blumenthal and Ruit,” it was found that MSICS produces good visual outcomes and only minor complications.¹ Af-

new!

thera
tears.

EXTRA

HARNESS EXTRA POWER FROM A NATURAL WONDER

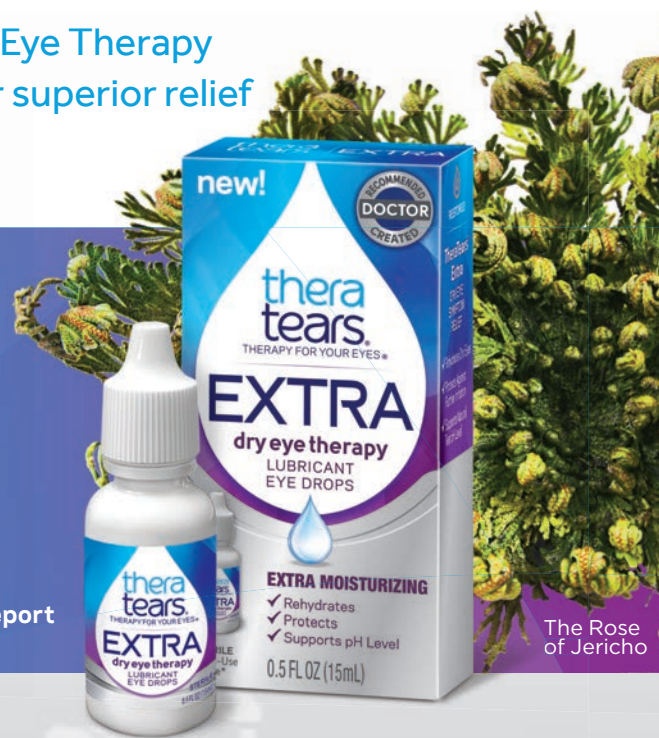NEW TheraTears® Extra Dry Eye Therapy
is enhanced with trehalose for superior relief

Trehalose is a natural disaccharide found in plants with moisture retention properties that help organisms survive in absence of water. In ophthalmic products, trehalose enhances active ingredients to help¹:

- Protect corneal cells from desiccation
- Restore osmotic balance to the ocular surface
- Maintain the homeostasis of corneal cells

-2017 DEWS II Report

Learn about our complete line of
dry eye therapy products at theratears.com



The Rose
of Jericho

Reference: 1. Jones L, Downie L, Korb D, et al. TFOS Dews II Management and Therapy Report. The Ocular Surface Jul 2017; 575-628.

© 2018 Akorn Consumer Health | A Division of Akorn, Inc. | M17-047

ter three months, corrected visual acuity in the Blumenthal group was 0.73 (just under 20/25) and 0.69 (a little better than 20/32) in the Ruit group.¹ The average postoperative astigmatism was 0.87 ± 0.62 D and 0.86 ± 0.62 D for the Blumenthal and Ruit groups, respectively, while mean surgically induced astigmatism was 0.55 ± 0.45 D and 0.50 ± 0.44 D, respectively.¹ Otherwise, noted complications included minimal hypophemias and corneal edema.¹

The miLoop

Surgeons say the miLoop device, from Zeiss, can help streamline some of the steps of MSICS.

The miLoop is a relatively inexpensive and disposable instrument made of nitinol, a strong material; it can be injected through a small, clear corneal incision. Once injected, the filament loop extends under the anterior capsule and goes around the nucleus to the equator and then the posterior surface. As the loop is withdrawn, it cuts through the nucleus, bisecting it. The device can then be used to rotate the nucleus and further break it into quarters or even smaller pieces. Doctors say no phaco is needed, just a manual irrigation/aspiration handpiece.

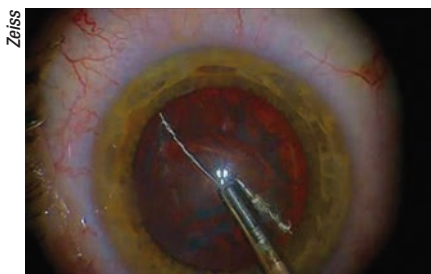

Figure 3. miLoop ensnares the lens.

• **Advantages.** As an alternative to phaco, some surgeons say miLoop is a viable tool for managing non-phaco candidates in the United States and for medical missions in the developing world.

In surgery, surgeons say certain patient presentations might benefit from the use of the miLoop. “MiLoop is useful for people who have a very dense, hard, leathery nucleus that’s difficult to disassemble and would require a lot of phaco energy,” Dr. Mamalis says.

Doctors agree that these patients could have issues associated with extended phaco time, so in an effort to see how gently the device could tackle the nucleus, Dr. Crandall aided in the creation of the Miyake/Apple technique. Using the technique, they confirmed that the device was very zonular- and capsular-bag friendly. “The beauty of the miLoop is that it can be used [to break up] really hard cataracts,” Dr. Crandall says, “since the energy is kept away from the bag and the zonules. It’s a great skill to know.”

Dr. Mamalis feels that an advantage of the miLoop is that the surgeon doesn’t have to make a scleral tunnel. “You can disassemble a hard nucleus into small pieces that you can remove through a clear corneal incision,” he says. When considering the usefulness of the device in the developing world, he adds that it’s helpful to be able to use a small, clear corneal incision. “Anything you can do to make the incision smaller, especially in a developing-world setting, is helpful,” he says.

Dr. Crandall adds that there are two advantages to using the miLoop in international settings. “One is that you have the ability to use a small incision, since you can break the nucleus in half, which can be critical,” he says. “Two, you can use foldable lenses.” He also states that since the miLoop incision is smaller than a conventional, 10-mm extracapsular incision, there may be less induced astigmatism to worry about postop, though the difference would be small.

When it comes to patients in the

United States who may not be able to undergo phaco, Dr. Newsom says that the miLoop allows him to make on-the-spot decisions as to whether phaco will be too strenuous for a given eye, and therefore shouldn’t be used to perform cataract surgery. “MiLoop is a very interesting option that I think everyone should have access to in the operating room,” he says. “I want [miLoop] there, ready to be opened, so that as I’m doing my initial assessment I can determine whether I need it based on the case, intraoperatively. MiLoop has eliminated any reason for a potential extracapsular.”

Dr. Mamalis says that the miLoop can also be used as a training tool. “MiLoop could allow doctors who don’t have experience making a scleral-corneal incision to disassemble a nucleus into multiple, smaller pieces,” he says.

• **Disadvantages.** Since it’s the only device of its kind, Dr. Mamalis says there’s a learning curve. “The device works wonderfully but, like any other technology, it has to be used properly and it’s important that people are trained to use it,” he says.

Dr. Mamalis says visualization can be an issue, and there’s also a need to have an intact capsule. “Sometimes what’s difficult with the miLoop is that if you have a really dense nucleus, once the loop goes behind it, you sometimes can’t visualize it well,” he says. “Also, if you’ve got some tears in the anterior capsule or you’ve got an anterior capsular extension, you may want to reconsider the use of the miLoop.”

• **Technique tips.** To get a better handle on the miLoop, Dr. Mamalis suggests employing the Miyake/Apple technique to view it in action, using a cadaver eye. “You take a donated, human cadaver eye and section it coronally, at the equator, and glue the anterior segment of the eye to a glass slide,” he says. “That al-

lows for simultaneous videoing both anteriorly and posteriorly, which is very helpful when you're evaluating devices like the miLoop." This has enabled Dr. Mamalis to video the device as it's sectioning the nucleus, and see what's happening to the capsular bag and the zonules. He notes that there are also many videos available online that can show you how to use the loop.

Using enough viscoelastic is also important. "Adequately use viscoelastic to ensure that the loop is going underneath the anterior capsule properly and then coming around the equator," explains Dr. Mamalis. "Make sure that you're going all the way around the nucleus without snagging or getting caught on anything in order to break the nucleus into multiple pieces and disassemble it."

• **miLoop results.** In a randomized, controlled study, where several of the researchers were employees or consultants for the maker of miLoop, Iantech, the safety and efficacy of surgery with the miLoop was assessed in moderate to severe cataracts. The study found that miLoop fragmented every dense nucleus within the capsular bag.² The miLoop filament completely transected the nucleus without any centrifugally directed instrument forces that would stress or stretch the capsular bag, the researchers said. In advanced cataracts and cases involving weak zonules, there were no instances of zonular dialysis or anterior/posterior capsule tears.²

Looking Ahead

Though cataract surgeons in the United States almost exclusively use phaco, Dr. Mamalis says reliable phaco is still difficult to access in the developing world, and alternatives will always be welcome. "[For phaco to be feasible] you need to be in a situation where maintenance

can be performed on the machine so that it's working consistently," he says. Dr. Newsom adds that certain complications of phaco might be too much for surgeons in less-well-equipped countries, as well. "There are limited options readily available to fix a problem," he says. "If you have healing issues in the cornea because of increased phaco energy, you probably don't have access to corneal transplants. There's also limited access to specialists who can potentially treat a patient that might have endothelial damage as a result of extended phaco time."

Dr. Crandall expands on this idea, saying, "If you're in a developing country and you have one of these big, expensive machines and a light bulb burns out, what are you going to do? They don't have the back-ups that we do." For this reason, doctors say that even donated phaco machines can be problematic.

That said, MSICS looks to continue as the main form of cataract removal in the developing world, with miLoop poised to find its niche. Dr. Mamalis says that patients with a relatively dense nucleus would benefit from both of these techniques, too. He adds that there's a large overlap in MSICS candidates and miLoop candidates, and if properly done, you can get very good results using either. "[MSICS and miLoop are] very friendly to the cornea," Dr. Mamalis says. "They will allow you to remove a relatively dense nucleus without requiring the high ultrasound energy that's necessary when performing phaco." **REVIEW**

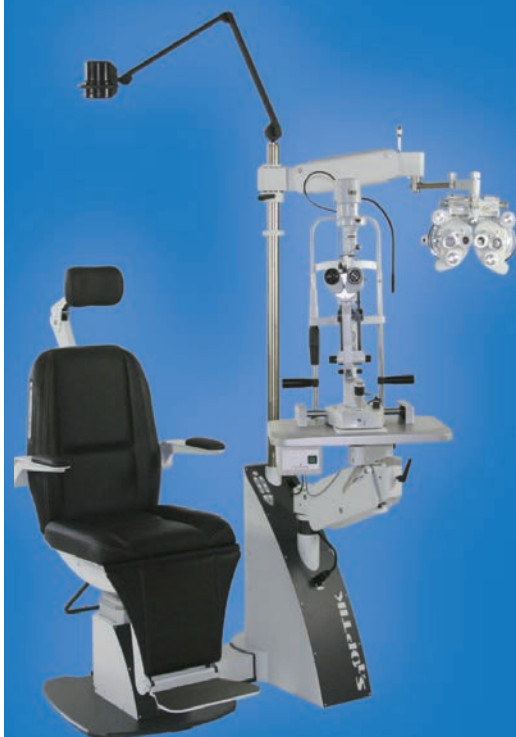Drs. Newsom, Mamalis and Crandall report no financial disclosures in the products discussed.

1. Kongsap P. Visual outcome of manual small-incision cataract surgery: Comparison of modified Blumenthal and Ruit techniques. *International Journal of Ophthalmology* 2011;4:1:62-5.
2. Ianchulev T, Chang DF, Koo E, et al. Microinterventional endocapsular nucleus disassembly: Novel technique and results of first-in-human randomised controlled study. *British Journal of Ophthalmology* 2019;103:176-180.

S4OPTIK

EXAM LANE SOLUTIONS

UNIQUE COMBO CHAIR & STAND




A complete solution
to optimize space
and functionality at an
affordable price

MANUFACTURED IN NORTH AMERICA

S4OPTIK

250 Cooper Ave., Suite 100 Tonawanda NY 14150
www.s4optik.com | 888-224-6012

Sensible equipment. Well made, well priced
For today's modern office.



Diagnosing Angle Closure: Gonioscopy vs. OCT

Both approaches offer advantages in terms of convenience and accuracy, but gonioscopy still remains the gold standard.

Sunita Radhakrishnan, MD, San Francisco

Although primary open-angle glaucoma is more common than primary angle-closure glaucoma, the latter has higher visual morbidity, including blindness. Precursor stages of primary angle-closure glaucoma are characterized by iridotrabecular contact of at least 180 degrees of the angle, which can be detected with gonioscopy.

Unfortunately, angle-closure disease is often missed. Most patients with this condition don't have symptomatic attacks of angle closure that might prompt them to seek eye care. Even when a patient presents for an eye exam, gonioscopy may not always be performed. The van Herick test, which estimates the peripheral anterior chamber depth relative to the peripheral corneal thickness, is commonly used to decide which patient should undergo gonioscopy. The most significant problem with this approach is that it doesn't have a high enough sensitivity and specificity to catch all patients with angle closure. In one study, the van Herick test, performed by technicians, residents and attendings, was compared to gonioscopy performed by attendings as the

gold standard; the sensitivity of the van Herick test to detect angle closure was only 58 to 79 percent.¹

Gonioscopy Pros and Cons

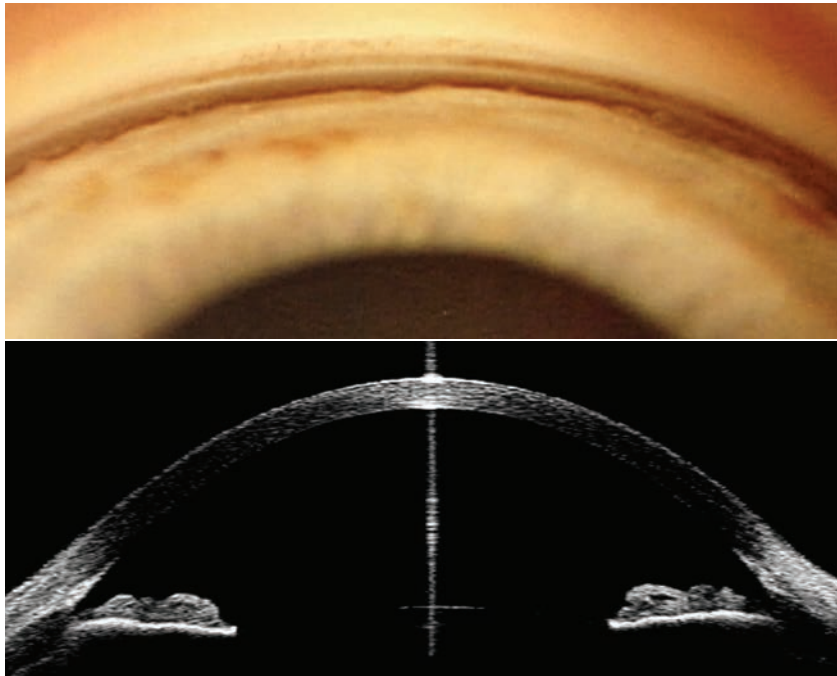
Gonioscopy is the gold standard for diagnosing angle closure. As a glaucoma specialist, I specifically check the angle with gonioscopy on a regular basis. It does require an anesthetic, but it usually takes less than a minute. In addition to providing a quick 360-degree assessment of the angle width—with and without indentation—peripheral anterior synechiae can be detected, the degree of trabecular meshwork pigmentation can be observed, and abnormalities such as neovascularization of the angle and angle recession can be diagnosed.

However, gonioscopy has some limitations. It's a subjective technique that requires contact with the eye and slit lamp illumination, both of which can artificially widen the angle. It's also not performed as often as recommended. One reason for this may be that in clinics where technicians perform the initial slit lamp assessment and then dilate the

patient, making the patient wait for gonioscopy by the ophthalmologist might be considered disruptive to the schedule. Furthermore, it's possible to misdiagnose the angle status, even when you perform gonioscopy—especially if you don't do it very often. For example, a pigmented Schwalbe's line might be mistaken for the trabecular meshwork, creating the erroneous impression of an open angle when the angle is actually closed. Similarly, if the trabecular meshwork is very pale, it can be difficult to determine the condition of the angle structures. There are some workarounds to help with this, such as the corneal wedge technique that can help you identify Schwalbe's line, but the fact is, sometimes even with gonioscopy it can be difficult to tell what's going on in the angle. (Of course, the more you do it, and the more familiar you are with these issues, the more likely you are to make an accurate assessment.)

Weighing the Alternatives

These considerations—and the reality that many cases of closed



Both gonioscopy and anterior-segment optical coherence tomography have pros and cons when it comes to assessing the condition of the angle.

angles are not being caught—open the door to other ways of assessing the angle that might bypass some of gonioscopy's limitations. These include:

- **The scanning peripheral depth analyzer.** This instrument (not available in the United States) uses visible light to automatically scan from the optical axis to the limbus, estimating the distance between the cornea and the iris and quantifying it into different grades. It's an easy-to-use, non-contact method to indirectly estimate the angle width, but the technology doesn't have high enough specificity to be a good alternative to gonioscopy.^{2,3}

- **The Pentacam.** The Pentacam uses a rotating Scheimpflug camera and provides cross-sectional images of the anterior chamber, but it's not able to visualize the angle recess itself. Instead, it makes some extrapolations based on the corneal surface and iris surface to draw conclusions about the angle recess.

- **Ultrasound biomicroscopy.** UBM uses high-frequency ultrasound and gives excellent cross-sectional views of the angle structures, including the ciliary body. However, it's cumbersome to use on a routine basis and requires a highly skilled operator to perform the scans. Those considerations make it unsuitable for use as a screening tool for angle closure.

Anterior segment OCT is another cross-sectional imaging modality that can visualize the anterior chamber and angle structures. However, unlike UBM, OCT is an optical technology; it can't penetrate the iris pigment epithelium, so the ciliary body can't be viewed. The Visante OCT (Carl Zeiss Meditec) uses a wavelength of 1310 μm , which is ideal for visualizing angle structures; but, unfortunately, the Visante is no longer being manufactured. Retina-focused OCT instruments that are widely available, such as Carl Zeiss Meditec's Cirrus, Heidelberg's Spectralis and Optovue's

S4OPTIK

ELITE SLIT LAMP



The **H5 ELITE** slit lamp features an innovative LED illumination system providing brilliant light spectrum, while increasing patient comfort.

An **extensive power range**, with five magnification settings from 6x to 40x. Standard on all ELITE slit lamps.



IMAGING

The **S4OPTIK H5 ELITE** slit lamp comes digital ready. Combine with the S4OPTIK all-in-one digital camera to acquire exceptional still and video images.

S4OPTIK

250 Cooper Ave., Suite 100 Tonawanda NY 14150
Sensible equipment. Well made, well priced
For today's modern office.

Gonioscopy vs. OCT: Pros and Cons

Gonioscopy	OCT
Subjective	Objective
Rapid 360-degree assessment	Time-consuming; not practical for scanning 360 degrees with current FDA-approved devices
Requires contact; some patients cannot tolerate contact procedures	Non-contact; comfortable for patient
360-degree assessment	Cross-sectional view; not practical for scanning 360 degrees
Requires illumination	Can be performed in the dark
Can detect other causes of elevated IOP such as pigment dispersion or angle recession	Cannot assess angle features other than angle width
Indentation possible, revealing PAS, plateau configuration	Indentation not possible
Limited information about the anterior chamber	Snapshot of entire anterior chamber in one scan
Scleral spur can be misidentified if trabecular meshwork is pale or Schwalbe's line is pigmented	Scleral spur can't be identified in up to 30 percent of angle images
Angle width measurement is subjective	Angle width measurement is objective, but variability can be high

Avanti, can also be used to image the anterior segment, but these use light wavelengths between 800 and 900 μm that don't penetrate the angle as well. As a result, the images are less detailed in the angle region than those produced by the Visante OCT. Nevertheless, it's usually possible to tell whether the iris and cornea are touching.

Probably the primary reasons these instruments are seldom used for angle analysis is because of workflow in the clinic. They're normally used after the patient has been dilated, and they usually require an additional external lens for imaging the front of the eye. Nevertheless, I have seen some doctors use retinal OCT to assess the angle.

The AS-OCT Advantage

Although gonioscopy is the gold standard for angle assessment, a noncontact technology that could

image the angle in the dark without illumination would, in theory, allow us to screen patients much more easily. In fact, when anterior segment OCT was first developed, it was seen as a very promising way to screen for angle closure.

This approach has some clear potential advantages over gonioscopy. Those include:

- **It's easy to use.** OCT doesn't require an ophthalmologist with expertise in performing gonioscopy to diagnose iridotrabecular contact.
- **It's comfortable for the patient.** In contrast, gonioscopy requires touching the eye, which patients generally prefer to avoid.
- **It may produce fewer artifacts.** As mentioned earlier, to perform gonioscopy you need slit lamp illumination and you have to touch the eye, both of which can artificially widen the angle. With OCT there's no need to touch the eye, and because it can be done in the dark it reveals the

physiological state of the angle, giving us a better sense of the true condition of the angle.

• **It can quantify angle width and changes occurring with pupil dilation.** Another useful test related to angle closure is seeing how the angle opens (or closes) as the pupil reacts to greater or lesser illumination. Both gonioscopy and OCT can be used to evaluate this, but OCT allows us to quantify the amount of change.

• **OCT detects more angle closure than gonioscopy.** Ironically, one reason that OCT has low specificity when used to assess the angle in studies is that it actually detects more angle closure than gonioscopy, which is treated as the gold standard for comparison.

Being able to detect more angle closure than gonioscopy can certainly be seen as a good thing. However, angle closure on OCT doesn't always mean that the patient should immediately be treated. In fact, even patients with gonioscopic angle closure don't always require treatment. In the case of primary angle closure suspects who are usually asymptomatic and have no abnormality other than angle closure, the American Academy of Ophthalmology's *Preferred Practice Patterns* leaves decisions about treatment up to the doctor, saying that treatment with iridotomy in this situation "may be considered." Therefore, using OCT alone isn't sufficient to decide how a patient should be treated. However, it can help to identify individuals who should be checked more carefully for a problem in the future.

• **It may detect the likelihood of future angle closure better than gonioscopy.** Interestingly, one study looked at patients who were classified as having open angles by gonioscopy, but classified as having closed angles with OCT.⁴ The study found that after four years, 17 percent of the

patients in this category that returned for follow-up had developed closed angles in two or more quadrants (as classified by gonioscopy), and 10 percent developed angle closure in three or more quadrants.

Although this finding was based on only the 62 percent of the original patient sample that returned for follow-up at year four, this is significant. On gonioscopy, these people appeared to have open angles. Yet some went on to develop closed angles, and OCT picked up on that before closure was visible on gonioscopy. If a patient appears to have open angles, most ophthalmologists won't be checking periodically to see if the angle is closing. That leaves these individuals open to future trouble—trouble that might be prevented by an OCT scan.

Ironically, this potential advantage to scanning with anterior segment OCT wouldn't be particularly useful to me, because as a glaucoma specialist, I perform gonioscopy on all of my patients on a regular basis—even if the angle has appeared to be open in the past. If all seems well, I check them every three or four years; if they're borderline, I check them every year. However, if OCT is able to catch some patients at risk for future trouble, patients that gonioscopy isn't able to identify, this could be useful for a doctor who doesn't perform gonioscopy very often. It might provide a warning that this patient needs to be checked periodically, despite the appearance of an open angle. (That could mean referring the patient to a glaucoma specialist who's more comfortable with regular gonioscopy screening.)



OCT Disadvantages

Despite its advantages, at a practical level in the clinic, using OCT as an alternative for examining the condition of the angle can be

problematic, for a number of reasons:

- **Anterior segment OCT isn't widely available.** That means the equipment most appropriate for evaluating the angle isn't available in many practices.

- **Most OCT scans (used for evaluating the optic nerve and retina) are performed after the patient has been dilated.** Even if you decide to use OCT technology that's not optimized for viewing anterior segment structures, this use may not be convenient in terms of patient flow.


Even when relying primarily on gonioscopy to assess the angle, AS-OCT serves several very useful purposes.


- **OCT only measures a tiny fraction of the angle.** Primary angle closure is defined in the Academy's *Preferred Practice Patterns* as being characterized by iridotrabecular contact for at least 180 degrees. (Iridotrabecular contact is defined as the posterior trabecular meshwork not being visible using static gonioscopy.) This is relevant when comparing OCT and gonioscopy, because OCT typically only scans a slice from four quadrants. Essentially, you're seeing the condition of the angle in four degrees out of 360.

Since the definition of angle closure is iridotrabecular contact over at least 180 degrees, we conclude that if two of four OCT scans show a closed angle, that indicates at least 180 degrees of closure. (Trying to base the conclusion on a larger number of scans can be problematic. Among other issues, scanning the superior

and inferior quadrants is challenging because the eyelid gets in the way.) In contrast, gonioscopy provides information about the entire angle.

Of note, there is a new swept-source, 1310- μm OCT instrument not approved in the United States that does allow 360-degree measurement of the angle. So far, there's no data to suggest that this technology is superior to gonioscopy, but in theory it might be a viable alternative for detecting angle closure. (However, even where this technology is available, it doesn't appear to be replacing gonioscopy.)

- **Quantifying the angle requires subjective input about the location of the scleral spur.** The scleral spur can be difficult to identify with OCT in up to 30 percent of images. This is a problem if you're trying to quantify the opening of the angle using OCT; the person doing the measurement has to decide where the scleral spur is, resulting in variability in the outcome depending on that decision. In addition, when assessing change over time, one can't be sure that the same region is being scanned, and measurement variability can be introduced due to differences in the iris structure at different locations. For these reasons, I don't routinely use OCT for quantitative analysis of the angle.

Population-based Screening

One important concern is that we'd like to have an instrument that can easily act as a screening tool in the general population to find individuals with angle closure. Aside from needing a technology that's simple to use, a major consideration here is having high specificity in order to avoid too many false positives. Generally, a specificity of 95 to 98 percent has been recommended for screening, along with a sensitivity of at least 85 percent.^{5,6} If a technology has high sensitivity and low specificity,

Sensitivity and Specificity of OCT in Different Studies

	Sensitivity (percent)	Specificity (percent)
Nolan et al, 2007 ⁷	98	55.4
Lavanya et al, 2008 ²	88.4	62.9
Nongpiur et al, 2013 ⁸	98	78
Zhang et al, 2014 ³	73	87
Dabasia et al, 2015 ⁹	87	87
Kochupurakal, 2016 ¹⁰	91	12

it will flag most patients as having a closed angle, including many who don't actually have it, burdening the health-care system.

This is an area in which OCT doesn't do well. Studies of OCT used for detection of angle closure have shown widely varying results in comparison to gonioscopy, with specificity ranging from 12 to 87 percent—although it's important to note that the definition of angle closure isn't uniform across the studies. In addition, finding angle closure on OCT doesn't always imply the need for immediate treatment. Given these facts, I don't believe OCT can be justified as a screening tool for angle closure out in the community.

OCT's usefulness as a screening tool does increase, however, if the screening is being done in the office (i.e., opportunistic screening) rather than out in the world, especially in settings where gonioscopy may not be feasible. In the clinic, a higher false-positive rate may be acceptable. In that environment, high sensitivity—a limited number of false negatives—is more important. However, in this setting the cost and availability of OCT is a limitation. If there's adequate expertise, gonioscopy is a faster, cheaper, way to assess the angle and make treatment decisions in a patient who is already in the clinic.

OCT as an Adjunct

In my experience, the approach that's most effective for angle assessment is to use gonioscopy as

the primary tool with anterior segment OCT reserved as an adjunct technology. Even when relying primarily on gonioscopy to assess the angle, AS-OCT serves several very useful purposes:

• **OCT can help to determine the cause of the angle closure.**

OCT is useful for identifying the mechanism(s) behind the angle closure. The various mechanisms of primary angle closure often coexist; they include pupillary block, high lens vault, thick peripheral iris, and an anteriorly positioned ciliary body (although the last can't be seen with OCT—only with ultrasound biomicroscopy). OCT can also reveal causes of secondary angle closure, such as supraciliary fluid that's pushing the iris-lens diaphragm forward. It's important to know this because the appropriate treatment varies depending upon the cause of the problem.

• **OCT is excellent for patient education.**

In my practice, people often come in for a second opinion about whether they should receive a laser iridotomy. In most cases they're totally asymptomatic; a general ophthalmologist or an optometrist has noted their closed angle and suggested the iridotomy. Patients find that idea scary when they haven't heard of it before, so they come to a glaucoma specialist to find out if this is correct.

Of course, I could show them a drawing or generic photo of a normal angle versus a closed angle to help

them understand the problem, but I've found that showing the patient a picture of his or her own angle compared to an open angle is most effective. Then I can explain how angle closure attacks can happen and how an iridotomy might help.


• **OCT can be helpful in situations where gonioscopy isn't feasible.**

Occasionally a patient will present with a hazy cornea, making angle visualization difficult or impossible; OCT can still provide a view of the angle. Also, some patients are unable to tolerate a contact lens placed on the eye. OCT can allow angle evaluation without touching the eye.

In the final analysis, OCT is a great adjunct, but there's no substitute for performing gonioscopy. [REVIEW](#)

Dr. Radhakrishnan is a glaucoma specialist at the Glaucoma Center of San Francisco and research director at the Glaucoma Research and Education Group, also in San Francisco. She reports no relevant financial disclosures.

1. Johnson TV, Ramulu PY, Quigley HA, Singman EL. Low sensitivity of the Van Herick method for detecting gonioscopic angle closure independent of observer expertise. *Am J Ophthalmol* 2018;195:63-71.
2. Lavanya R, Foster PJ, Sakata LM, et al. Screening for narrow angles in the Singapore population: Evaluation of new noncontact screening methods. *Ophthalmology* 2008;115:10:1720-7, 1727.e1-2.
3. Zhang Y, Li SZ, Li L, Thomas R, Wang NL. The Handan Eye Study: Comparison of screening methods for primary angle closure suspects in a rural Chinese population. *Ophthalmic Epidemiol* 2014;21:4:268-75.
4. Baskaran M, Iyer JV, Narayanaswamy AK, et al. Anterior segment imaging predicts incident gonioscopic angle closure. *Ophthalmology* 2015;122:12:2380-4.
5. Stamper RL. Glaucoma Screening. *J Glaucoma* 1998;7:3:149-50.
6. Thomas R, Parikh R, Paul P, Mullyil J. Population-based screening versus case detection. *Indian J Ophthalmol* 2002;50:3:233-7.
7. Nolan WP, See JL, Chew PT, et al. Detection of primary angle closure using anterior segment optical coherence tomography in Asian eyes. *Ophthalmology* 2007;114:1:33-9.
8. Nongpiur ME, Haaland BA, Friedman DS, et al. Classification algorithms based on anterior segment optical coherence tomography measurements for detection of angle closure. *Ophthalmology* 2013;120:1:48-54.
9. Dabasia PL, Edgar DF, Murdoch IE, Lawrenson JG. Noncontact screening methods for the detection of narrow anterior chamber angles. *Invest Ophthalmol Vis Sci* 2015;56:6:3929-35.
10. Kochupurakal RT. Role of optical coherence tomography in assessing anterior chamber angles. *J Clin Diagn Res.* 2016;10:4:NC18-NC20.



SANTEN – TURNING THE PRESSURE OF GLAUCOMA INTO PROGRESS

With an aging population, we recognize the increasing pressure of managing glaucoma for patients who are living longer and want to maintain independence. At SANTEN, we're committed to developing novel therapeutic solutions that will advance your approach to glaucoma management and help you preserve your patients' vision.

Learn more about our pipeline and our mission to preserve eyesight at www.SantenUSA.com



Be Prepared for Pediatric Patients

Pediatric retina patients' ocular anatomy can pose unique challenges.

Yoshihiro Yonekawa, MD, Boston

When working with pediatric patients, it can be easy to fall into the trap of simply considering them small adults. From the ophthalmic examination to operating on complex pediatric pathology, some differences become apparent quickly, while some are subtle and require knowledge beforehand in order to tackle these unique cases. In this article, I'll review some of the challenges of diagnosing and treating children with retinal conditions, and explain how to optimize outcomes as much as possible.

A Different Exam

The differential diagnosis for children with retinal pathology is different than it is for adults. The most common diagnoses we encounter in adult clinics are age-related macular degeneration, diabetic retinopathy, vein occlusions, macular hole, epiretinal membrane and retinal detachment. In pediatric retina, however, we take care of premature neonates with retinopathy of prematurity in the neonatal intensive care unit, older kids with traumatic retinal detachment, genetic conditions such as sickle cell retinopathy, Stickler

syndrome, familial exudative vitreo-retinopathy (FEVR), X-linked retinoschisis and incontinentia pigmenti, and sequelae of developmental anatomic anomalies like persistent fetal vasculature, optic disc pits and colobomas.

When diagnosing these conditions, in say, 3-year-olds running circles around the exam chair, the approach we take is quite different than a typical adult fundusoscopic exam. Neonates are typically easy to overpower, especially if they are swaddled. You will need additional hands to stabilize a child that's approaching several months of age. Toys with bright lights and which make noises can also help children focus, and you can move these toys in the direction you would like them to look.

For patients between 1 and 3, things get interesting, and your approach often depends on the child's personality and developmental stage. First, you have to win the child's trust, and you can't go wrong with a high-five to initiate your interaction. I like to set the ophthalmoscope light low, and allow the child to sit on the parent's lap. I quickly look at the red reflex first, as that alone can provide tons of information. If I suspect an area of pathology,

I aim to look there first, since we don't know when the child will decide that this isn't fun anymore. Some children find it entertaining when I look for animals or cartoon characters inside their eyes. It usually helps to have the parents working with you also, as they may have the child's favorite toys or tablet videos that they can use as distractions. When in doubt, and when faced with possibly blinding or life-threatening conditions, we must remember to have a low threshold to proceed with an examination under anesthesia.

Imaging technologies can also augment our ophthalmoscopic exam. This includes modalities such as widefield scanning laser ophthalmoscopy imaging and ultrasonography. SLO imaging, such as with the Optos camera, is quick, comfortable and great for imaging the peripheral retina, where many pediatric retinopathies may reside. A peripheral retinal exam is difficult even for adults to tolerate, and B-scan ultrasonography can supplement the peripheral ophthalmoscopic exam in a comfortable way in children.

Our understanding of the genetic basis of diseases continues to expand. Identifying the genetic cause for he-

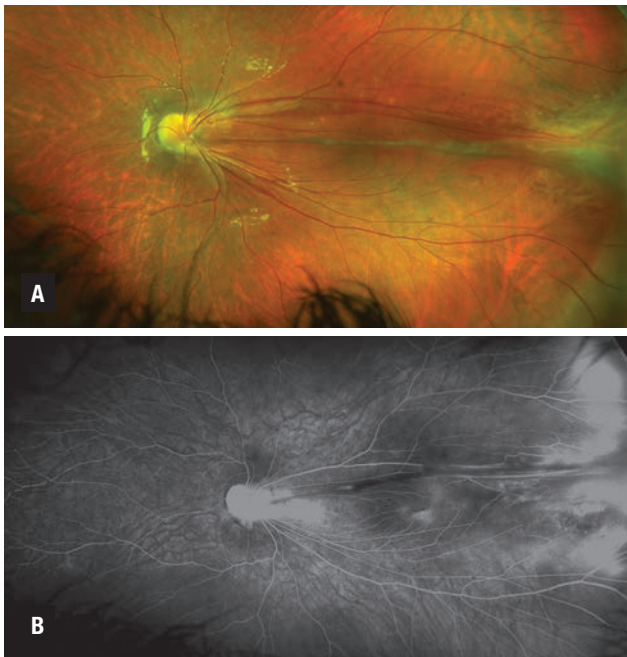


Figure 1. Widefield fluorescein angiography. (A) Widefield imaging captures the peripheral pathology in this child with familial exudative vitreoretinopathy. There is temporal dragging of the retinal vasculature and a peripheral traction retinal detachment without overlying hyaloidal organization. (B) Widefield fluorescein angiography demonstrates hyperfluorescence consistent with leakage from the vasculature.

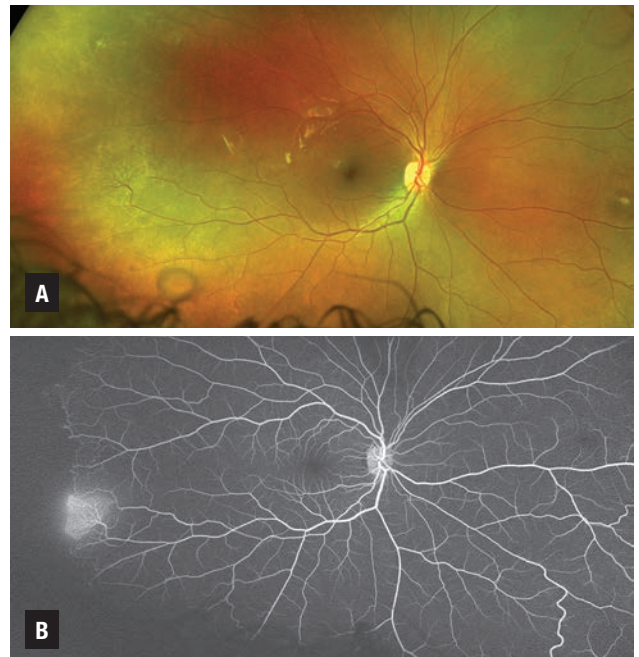


Figure 2: Oral fluorescein angiography. (A) For children who cannot tolerate intravenous injection of fluorescein, the dye can be ingested to obtain late-phase angiograms. This is a child with sickle cell retinopathy. (B) Oral fluorescein angiography shows peripheral nonperfusion and neovascularization temporally.

reditary retinal diseases facilitates diagnosis, prognostication and how we follow and treat patients. However, genetic testing can be expensive, challenging in terms of insurance, and it can take weeks to months to obtain results. A cost-effective, quick and meaningful way to uncover a potential genetic condition is to examine family members. Not only will this approach provide a better understanding of your patient's condition, but you may identify early pathology in family members that may be treatable.¹

Another diagnostic gem for many pediatric retinal conditions is widefield fluorescein angiography (*Figure 1*).^{2,3} Many of the diagnoses listed at the top of the article are primary or secondary retinal vasculopathies, and detailed imaging of the peripheral retinal vasculature is key in making the correct diagnosis and subsequent treatment plan. It's essential, for example, to identify

and distinguish Coats' disease vs. retinoblastoma vs. capillary hemangiomas.

However, many children won't tolerate an intravenous injection of fluorescein. One useful trick, then, is to have children drink the dye, and then take the images approximately 20 minutes later. Oral FA is a great way to acquire late-phase angiograms (*Figure 2*).⁴ Note that you can't obtain early and mid frames, so the diagnostic capacities are relatively limited compared to intravenous FA. For children too young for imaging in clinic, widefield FA can be performed under anesthesia. Also note that fluorescein is dosed by weight in children.⁵

Surgical Considerations

In pediatric retina surgery, remember two important concepts: 1) a young child's ocular anatomy is different from an adult's; and 2) the child's vitreous is

very formed and adherent to the retinal surface. Here's how these factors can affect surgery, and how to account for them.

- **Anatomic differences.** The proportions of the ocular structures in young children are different from an adult's—for instance, the lens is relatively large and the pars plana is small (*Figure 3*). The extent of the difference depends on the patient's age. For instance, if we created a typical sclerotomy 3.5 to 4 mm posterior to the limbus in a neonate as we do for adults during vitrectomy, we would slice through retina and the result would be disastrous. Typically, for children younger than 1, we enter 1 mm posterior to the limbus; for kids between 1 and 2 years of age, we enter 1 to 2 mm posterior; and for children who are between 2 and 3 years old, we enter 2 to 3 mm posterior to the limbus. We enter 3 mm posterior for most other

children. These are rough guidelines, and we always examine the eye carefully beforehand to make sure the pars plana is available for entry. This is because the pediatric patient's ocular anatomy can be altered by the underlying pathology. A prime example is persistent fetal vasculature. There can be segments of retina that developed, or became pulled, very anteriorly by the ciliary processes. If we go through the pars plana in those areas, we could nick the retina and cause an inoperable rhegmatogenous retinal detachment.

While pediatric eyes are smaller, their crystalline lenses are proportionately larger. We always have to be cognizant of the lens as we work in the tight intraocular space (unless we are removing the lens for very anterior retinal detachments). To decrease the risk of lenticular trauma, in the beginning of the surgery we aim our instruments more posteriorly, but away from any anteriorized retina. It's also a good practice to slow down and be deliberate when inserting and removing instruments, especially curved ones.

• **Visualization.** One of the practical issues with young children is that their eyes are smaller, so we have to hold our instruments closer together. As we note above, the sclerotomies are created closer to the limbus, so that again decreases the distance between our right and left hands. Because we hold our instruments closer together, it's easier to hit the viewing lens. If we hit the viewing lens,

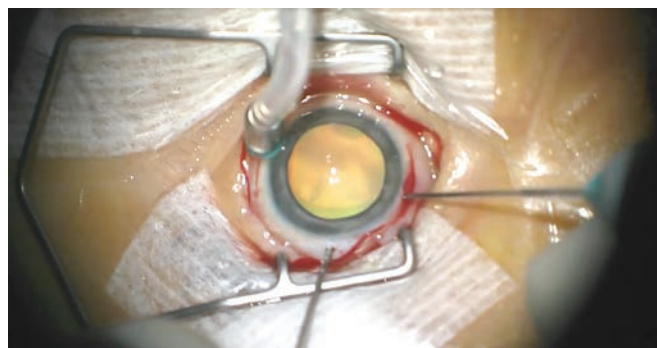


Figure 3. Thoughtful trocar placement for young children. This 2-month-old with familial exudative vitreoretinopathy is undergoing vitrectomy. Note that the sclerotomies are made directly in the sclera without cannulas, because the surgical space is limited. In this patient, the sclerotomies are created 1 mm posterior to the limbus, unlike the usual 3.5 to 4 mm in older patients. The temporal sclerotomy is also displaced superiorly, to avoid an anterior tractional retinal detachment in the superotemporal quadrant.

we lose our view—and if we lose our view, we can't operate. To help with this situation, there are certain non-contact viewing systems that allow the lens to sit higher off of the cornea. There are also specific pediatric retinal surgery lenses that are smaller in diameter than their adult counterparts.

• **Scleral buckles are your best friends.** For most vitreoretinal surgeons, vitrectomy is now the go-to method for repairing primary rhegmatogenous retinal detachment in adults. Vitrectomy usually works in

on the tamponade to work properly.

It's for these reasons that we prefer scleral buckling to fix RRDs in children (Figure 4). Scleral buckles don't rely on the vitreous being separated, and you don't have to rely on positioning. In fact, almost all primary RRDs in children would do great with a nicely placed scleral buckle. Primary buckling is a fading art, but remains a mainstay of pediatric RD surgery.⁵

• **No margin for error.** The child's formed vitreous poses challenges for tractional retinal detachments also.

In adults with diabetic TRDs or PVR retinal detachments, the general approach is to release the membranes, but if the membranes are too intrinsic to the retina and can't be peeled, you can perform a retinectomy (especially for PVR) to cut the stiff retina and flatten the retina with brute force. You can't take that approach in children, though. For a child with a TRD from conditions like ROP, Norrie disease or FEVR, the goal is to

(Continued on page 73)

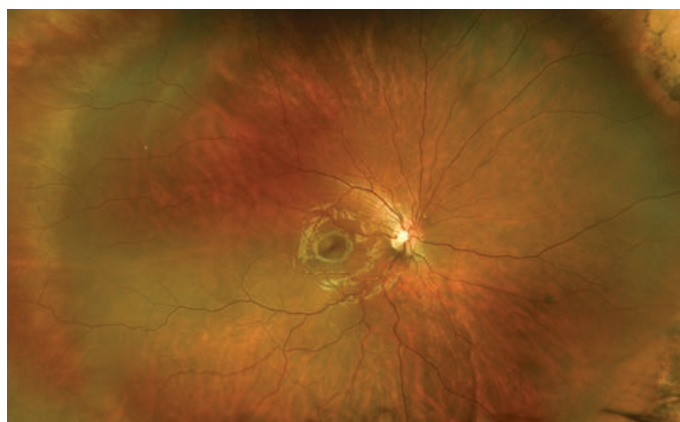


Figure 4. The formed and adherent vitreous, as well as the inability to position reliably, make scleral buckle the ideal surgical modality to treat rhegmatogenous retinal detachment in children. This child had an open globe repair and subsequently developed a retinal detachment, which was repaired with a primary encircling buckle.

Career Opportunities

OPHTHALMOLOGISTS
Danbury, CT

Ophthalmologists to share office with long standing Ophthalmologist in Danbury, CT. High quality equipment. \$2,250 per month or adjoining office without equipment- \$1,750 per month.

203-545-3539 or
email mehrimd@aol.com



Do you have Products and Services for sale?

CONTACT US TODAY
FOR CLASSIFIED ADVERTISING
Toll free: 888-498-1460
E-mail: sales@kerhgroup.com



Targeting
Ophthalmologists?

CLASSIFIED ADVERTISING
WORKS



Contact us today
for classified advertising:
Toll free: 888-498-1460
E-mail: sales@kerhgroup.com



REVIEW Advertising Index

For advertising opportunities contact:

- Michele Barrett (215) 519-1414 or mbarrett@jobson.com
- James Henne (610) 492-1017 or jhenne@jobson.com
- Michael Hoster (610) 492-1028 or mhoster@jobson.com

Akorn Consumer Health 57
Phone (800) 579-8327
www.akornconsumerhealth.com

Bausch + Lomb 21-25, 35, 36
Phone (800) 323-0000
Fax (813) 975-7762

Beaver-Visitec International, Inc. 27
Phone (866) 906-8080
Fax (866) 906-4304
www.beaver-visitec.com

Focus Laboratories, Inc. 12
Phone (866) 752-6006
Fax (501) 753-6021
www.focuslaboratories.com

Glaukos 15
Phone (800) 452-8567
www.glaukos.com

Johnson & Johnson Surgical Vision, Inc. 2
<https://surgical.jnjvision.com>

Kala Pharmaceuticals 17, 18
Phone (781) 996-5252
Fax (781) 642-0399
info@kalarx.com www.kalarx.com

Keeler Instruments 5
Phone (800) 523-5620
Fax (610) 353-7814

Lombart Instruments 51
Phone (800) 446-8092
Fax (757) 855-1232

Ocular Therapeutix, Inc. 7, 8
Phone (877) 628-8998
www.ocutx.com

Omeros 10-11
Phone (206) 676-5000
Fax (206) 676-5005

S4OPTIK 59, 61
Phone (888) 224-6012

Santen Inc. USA 65
Phone (415) 268-9100
Fax (510) 655-5682
www.santeninc.com

Shire Ophthalmics 75, 76
www.shire.com

Sight Sciences 43
Phone (877) 266-1144
info@sightsciences.com
www.sightsciences.com

This advertiser index is published as a convenience and not as part of the advertising contract. Every care will be taken to index correctly. No allowance will be made for errors due to spelling, incorrect page number, or failure to insert.

Researchers Delve into Orbital Lymphoma

A group of investigators from seven different centers around the world came together to investigate and characterize the clinical features of subtype-specific orbital lymphoma.

The retrospective, interventional case series collected patient data from January 1, 1980 through December 31, 2017, comprising 797 patients with a histologically verified orbital lymphoma. The primary endpoints were overall survival, disease-specific survival and progression-free survival. The median age was 64 years, and 51 percent of patients (n=407) were male.

The researchers report that most of the lymphomas were of B-cell origin (98 percent, n=779). Extranodal marginal zone B-cell lymphoma (EMZL) was the most frequent subtype (57 percent, n=452), followed by diffuse large B-cell lymphoma (DLBCL) (15 percent, n=118), follicular lymphoma (FL) (11 percent, n=91), and mantle cell lymphoma (MCL) (8 percent, n=66). Localized, Ann Arbor stage IE EMZL and FL were frequently treated with external beam radiation therapy. DLBCL, MCL and disseminated EMZL and FL were primarily treated with chemotherapy. EMZL and FL patients had a markedly better prognosis (10-year disease-specific survival of 92 percent and 71 percent, respectively) than DLBCL and MCL patients (10-year disease-specific sur-

vival of 41 percent and 32 percent, respectively).

Am J Ophthalmol 2019;199:44-57.
Olsen TG, Holm F, Mikkelsen LH, Rasmussen PK, Coopland SE, et al.

Identifying Babies at Low Risk For Developing ROP

Most premature infants don't end up developing retinopathy of prematurity. However, due to difficulties in determining those at risk, sensitive screening procedures for premature infants persist after NICU discharge—even in infants without ROP. In a recent study, which took place in North American neonatal intensive-care units, doctors sought to understand the factors associated with premature infants being at low risk, and to identify those who wouldn't benefit from continued ROP monitoring post hospital discharge.

Currently, screening for ROP begins at 32 weeks postmenstrual age and continues every one to two weeks until the retinal vessels have matured, which is around 40 weeks. Only 5 percent of at-risk infants are eventually treated, however. The evaluations are seen as uncomfortable for the infant and can pose a burden to ophthalmologists, since physicians with ROP experience are limited.

In the study, 1,257 infants with

birth weights less than 1,251 g, who were born at 22 to 35 weeks' gestation, were monitored during all in-hospital examinations to determine birth characteristics associated with the absence of ROP, and identify those who would be considered low risk for subsequent ROP treatment. The infants underwent 4,113 ROP examinations between 31 and 47 weeks' postmenstrual age; 1,153 exams found no ROP, and 456 infants showed no ROP prior to study center discharge. There was no ROP in 59 percent of infants of 27 to 33 weeks gestation age compared to 15 percent of infants younger than 27 weeks at the time of hospital discharge. Larger birth weight and higher gestational age were significantly associated with absence of ROP in a multivariate analysis of infants born between 27 and 33 weeks gestation.

The study concluded by identifying characteristics that are associated with low likelihood of developing ROP. These factors include infants at 27 weeks' gestational age or greater who have a birth weight of at least 750 g. The researchers add that if ROP hasn't been detected by the time the infant is discharged, continued surveillance would have limited value.

JAMA Ophthalmology
2019;137:160-166
Wade K, Ying G, Baumritter A, et al.



A 75-year-old man presents to Wills for evaluation of ptosis and a headache.

Kyle McKey, MD, Tatyana Milman, MD, Carol L. Shields, MD

Presentation

A 75-year-old Caucasian male presented with one week of painful, progressive, constant right blepharoptosis associated with a right-sided headache. The patient denied changes in vision, diplopia, fever, jaw claudication, scalp tenderness or proximal muscle weakness.

Medical History

Past ocular history was unremarkable. Past medical history included atrial fibrillation, type II diabetes mellitus and hypertension. He also previously had prostate adenocarcinoma managed by radical prostatectomy in 2005, followed by radiotherapy for recurrence in 2006 and enzalutamide (anti-androgen) therapy. In 2012, the patient developed metastases to the spine for which he received palliative external beam radiotherapy. Family history and social history were non-contributory.

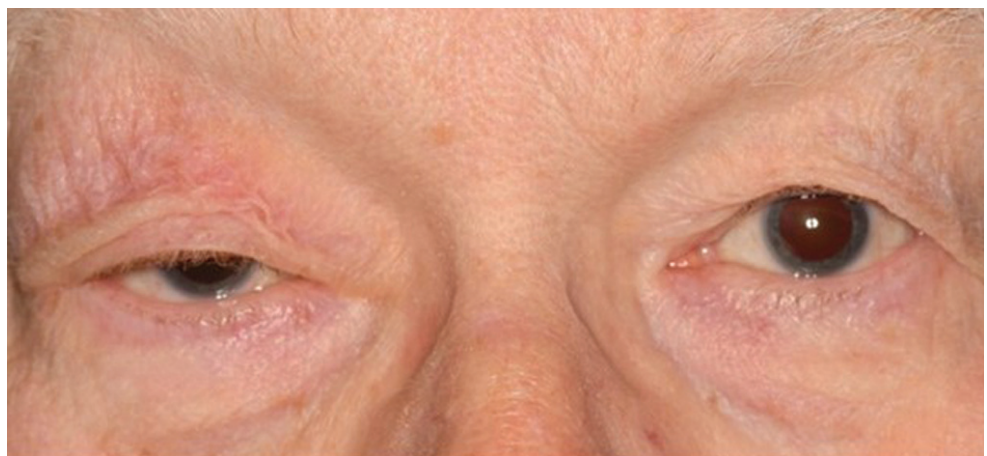Current medications included metoprolol, digoxin, glimepiride, atorvastatin, omeprazole, leuprolide and enzalutamide.

Examination

On examination, best corrected visual acuity was 20/40 OD and 20/25 OS. Pupils were normal, and confrontation visual fields were full in both eyes. Extraocular motility demonstrated a 20-percent limitation of upgaze of the right eye, but was otherwise normal. External examination was remarkable for 3 mm of non-fatigable right upper eyelid ptosis (*Figure 1*). There was no proptosis by Hertel exophthalmometry and no hypesthesia. Color plates were 7/8 OD and 8/8 OS.

Anterior segment examination showed an age-related nuclear sclerotic cataract OU, but was otherwise unremarkable. Dilated fundus examination demonstrated a blonde fundus with macular drusen in each eye. The cup-to-disc ratio was 0.4 OU without disc edema or pallor.

Figure 1. External photograph showing blepharoptosis of the upper eyelid.



What is your diagnosis? What further workup would you pursue? The diagnosis appears on p. 72.

Workup, Diagnosis and Treatment

Ancillary imaging studies included CT scan of the orbits without contrast, which showed a 2.3 x 2.2 x 0.7 cm soft tissue subperiosteal mass within the superior posterior aspect of the right orbit, with associated periosteal reaction and cortical thinning (*Figure 2*). MRI of the brain and orbits with and without contrast showed the same size heterogenous mass in the right orbit, involving the orbital roof and superior rectus muscle. Orbitotomy of the affected right orbit was performed, and the tumor was removed piecemeal with long rongeurs. The tumor was found to extend to the orbital apex, and the periosteal reaction was extensive.

Grossly, the mass consisted of fragments of firm, gray and dark brown tissue measuring 12 x 11 x 5 mm in aggregate. Microscopic evaluation demonstrated fragments of lamellar bone with reactive changes, surrounded

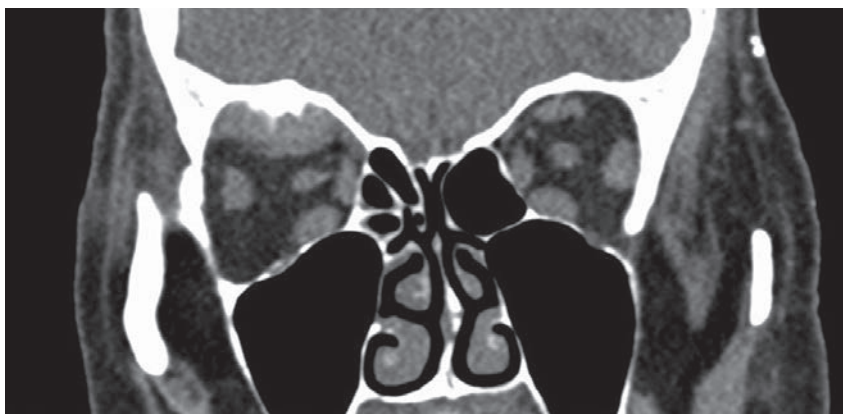

Figure 2. Coronal section of a CT scan of the orbits showing homogenous enlargement in the area of the superior rectus and levator superioris with adjacent bony reaction of the orbital roof.

by nests, islands and bands of infiltrating malignant cells with frequent mitotic figures, apoptotic bodies and geographic necrosis (*Figure 3*). Immunohistochemical stains showed that the neoplastic cells expressed NKX3.1 and androgen receptors.

The combined clinical, morphologic and immunohistochemical findings were compatible with metastasis of the patient's known prostate adenocarcinoma to the orbit, prompting referral to an oncologist for systemic management.

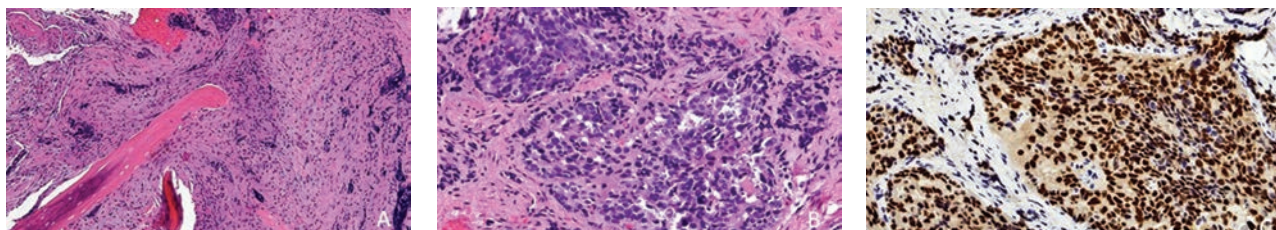


Figure 3. A: Spicules of bone associated with dense fibrosis (hematoxylin-eosin; original magnification x 50). B: Higher magnification demonstrates nests of atypical cells with a vaguely cribriform arrangement in a densely fibrotic stroma (hematoxylin-eosin; original magnification x 100). C: The neoplastic nuclei express prostate adenocarcinoma marker NKX 3.1 (original magnification x 100).

Discussion

Metastatic orbital lesions account for approximately 1 to 13 percent of all orbital tumors reported in the literature.¹ In a review of 1,264 patients with orbital tumors from the Wills Eye Hospital Oncology Service, metastatic tumors to the orbit were the seventh most common type of orbital lesion, comprising 7 percent of all orbital tumors. In adults over the age of 60, metastases comprised 10 percent of the total number of tumors.² The reported incidence of metastatic tumors to the orbit has increased in recent years; this may be due to an increase in the median survival of patients with cancer, as well as improvement in our ability to detect metastasis with refinement of ancillary studies and fine-needle aspiration biopsy techniques.³ The most common types of

cancer to metastasize to the orbit include breast, lung and prostate carcinomas.¹⁻³

Prostate carcinoma is the most common malignancy in males in the United States, with an estimated 220,800 new cases in 2015. In the past decade, there have been several advances in our ability to treat metastatic prostate carcinoma. Despite such advances, metastatic prostate carcinoma remains an often-lethal disease accounting for approximately 27,000 cancer-related deaths in the United States annually.⁴

Prostate carcinoma has a well-recognized pattern of metastatic disease, most frequently involving the axial skeleton and local lymph nodes. Skeletal metastases are pre-

dominantly osteoblastic (95 percent of cases) and preferentially involve the spine, pelvis and femur. These lesions are found in up to 84 percent of patients with advanced disease. Metastasis to the orbit is rare, occurring in less than 1 percent of patients with prostate carcinoma.⁵

In general, the presenting symptoms of orbital metastasis include proptosis, pain, diplopia, decreased vision and ptosis.^{3,6} Pain is more common in prostate carcinoma because it tends to spread to the orbital bone and periosteum where there are sensory nerves rather than orbital soft tissue. Bony lesions are usually osteoblastic and may simulate a meningioma, especially if the sphenoid bone is affected. The rapid development of osteoblastic orbital lesions in an elderly male is highly suggestive of metastatic prostate carcinoma.³

Nearly all prostate cancers are carcinoma, specifically adenocarcinoma, and can range from well-differentiated to very poorly differentiated. Recognition of metastatic prostate carcinoma is important, since it can be managed safely and effectively with hormonal therapy. Prostate carcinoma is a radiosensitive malignancy, so treatment for orbital disease usually consists of radiotherapy combined with hormonal therapies.³

In summary, we describe a patient with metastatic prostate adenocarcinoma to the orbit, who presented with painful blepharoptosis and limitation of extraocular motility. This case highlights the importance of medical history in guiding diagnostic workup and management. **REVIEW**

1. Shields JA, Shields CL, Scartozzi R. Survey of 1,264 patients with orbital tumors and simulating lesions. *Ophthalmology* 2004;111:997-1008.
2. Demirci H, Shields CL, Shields JA, et al. Orbital tumors in the older adult population. *Ophthalmology* 2002;109:243-248.
3. Ahmed SM, Esmaili B. Metastatic tumors of the orbit and ocular adnexa. *Current Opinion in Ophthalmol* 2007;18:405-13.
4. Park JC, Eisenberger MA. Advances in the treatment of metastatic prostate cancer. *Mayo Clin Proc* 2015;90:1719-33.
5. Long MA, Husband JES. Features of unusual metastases from prostate cancer. *Br J Radiol* 1999;72:933-41.
6. Shields JA, Shields CL, Brotman HK, et al. Cancer metastatic to the orbit. *Ophthalmic Plast Reconstr Surg* 2001;17:346-354.

(Continued from page 68)

release all the traction without making any retinal breaks, and certainly no retinectomies. This is because in an adult you can almost always flatten the retina by resorting to cutting it and being aggressive with the peeling. In children, however, it's almost impossible to flatten the retina completely due to the adherent vitreous and intense membranes, so a small iatrogenic retinal break in a TRD in a young child can lead to an inoperable eye.

Since the stakes are high in these pediatric TRD surgeries, the old saying, "perfect is the enemy of good" couldn't be any more true. The goal is to release the traction without making breaks, and then rely on the retinal pigment epithelium to gradually pump the subretinal fluid out and reattach the retina over time. If you must drain subretinal fluid or hemorrhage, it's a good idea to drain externally through a sclerotomy, as opposed to the internal retinotomies that we're used to making in adults.

• **Think of the entire patient, not just the eyes.** Some children and adults are at very high risk for anesthesia-related morbidity and mortality. Perhaps the highest risk as a general group would be ROP infants, who are likely to have multiple severe co-morbidities.² These children also tend to have bilateral, progressive pathology. Over the course of several days, an infant with ROP can progress from 20/20 potential as a stage 4A retinal detachment to hand-motion vision as a stage 4B detachment. So how do we address bilateral, progressive disease in sick patients? Do we schedule two separate surgeries and potentially double the anesthesia risk, while watching the second eye progress?

Bilateral ophthalmic surgery is usually not performed in the United States. The main theoretical risk is bilateral endophthalmitis, which indeed would be devastating. However, the risk for endophthalmitis after vitrectomy has been reported to be 0.03 percent to

0.08 percent, and assuming that we treat each eye as being independent of the other by redraping, rescrubbing, regowning, etc., the risk for bilateral endophthalmitis is equivalent to 1 patient in 1,500,000 to 10,000,000 bilateral surgeries.⁶ On the other hand, the risk for anesthesia-related mortality in children is as high as 1 in 10,000, 10 to 100 times higher for all-cause mortality; it's even higher in neonates, and higher still in premature neonates.⁶ So the risk of mortality with a second anesthesia session is many times higher than the risk of developing bilateral endophthalmitis.

In these instances, we recommend considering simultaneous bilateral surgery to decrease the risk of mortality and progression of blinding disease. We have previously published guidelines for this practice.⁶ We love focusing on patients' eyes, but we also need to take a step back when our patients are ill and assess the entire patient to optimize outcomes—for both the vision and the life of the patient.

Ultimately, we have to approach pediatric patients and their unique eyes thoughtfully. Pediatric retina surgery is a gratifying field, because you're potentially saving vision for the next 100 years of the young patient's life. There's nothing like telling a mother that her baby is going to be able to see. **REVIEW**

Dr. Yonekawa is a retina surgeon at Massachusetts Eye and Ear and directs the pediatric retina surgery program at Boston Children's Hospital. He will be joining Mid Atlantic Retina and Wills Eye Hospital in Philadelphia later this year.

1. Kashani AH, Leamed D, Nudleman E, et al. High prevalence of peripheral retinal vascular anomalies in family members of patients with FEVR. *Ophthalmology* 2014;121:1:262-268.
2. Yonekawa Y, Thomas BJ, Thanos A, et al. The cutting edge of retinopathy of prematurity care: Expanding the boundaries of diagnosis and treatment. *Retina* 2017;37:12:2208-2225.
3. Kang KB, Wessel MM, Tong J, et al. Ultra-widefield imaging for the management of pediatric retinal diseases. *J Pediatr Ophthalmol Strabismus* 2013;50:5:282-288.
4. Nayak BK, Ghose S. A method for fundus evaluation in children with oral fluorescein. *Br J Ophthalmol* 1987;71:12:908-909.
5. Yonekawa Y, Fine HF. Practical pearls in pediatric vitreoretinal surgery. *Ophthalmic Surg Lasers Imaging Retina* 2018;49:8:561.
6. Yonekawa Y, Wu WC, Kusaka S, et al. Immediate sequential bilateral pediatric vitreoretinal surgery: An international multicenter study. *Ophthalmology* 2016;123:8:1802-1808.



SAVE THESE DATES



3RD YEAR RESIDENT PROGRAMS & WET LAB

Dear CSE 3rd-Year Resident Program Director and Coordinator,

We would like to invite you to review the upcoming 3rd-Year Ophthalmology Resident Programs and Wet Lab for 2019 in Fort Worth, Texas. The programs offer a unique educational opportunity for third-year residents by providing the chance to meet and exchange ideas with some of the most respected thought leaders in ophthalmology. The programs are designed to provide your residents with a state-of-the-art didactic and wet lab experience. The programs also serve as an opportunity for your residents to network with residents from other programs.

After reviewing the material, it is our hope that you will select and encourage your residents to attend one of these educational activities, which are CME accredited to ensure fair balance.

Best regards,
Review Education Group



Third-Year Resident Wet Lab Programs 2019:

August 2-3 Fort Worth, TX	August 16-17 Fort Worth, TX	August 23-24 Fort Worth, TX	September 20-21 Fort Worth, TX
------------------------------	--------------------------------	--------------------------------	-----------------------------------

www.revophth.com/ResEdu2019

For more information: Visit the registration site above or
Email: dholmes@postgradhealthed.com • Call: Denette Holmes 866-627-0714

Courses are restricted to US-based 3rd-year residents enrolled in a US-based ophthalmology resident program and within their third year at the time of the course. There is no registration fee for these activities. Air, ground transportation in Fort Worth, hotel accommodations and modest meals will be provided through an educational scholarship for qualified participants.

Satisfactory Completion - Learners must complete an evaluation form to receive a certificate of completion. Your chosen sessions must be attended in their entirety. Partial credit of individual sessions is not available. If you are seeking continuing education credit for a specialty not listed below, it is your responsibility to contact your licensing/certification board to determine course eligibility for your licensing/certification requirement.



JOINTLY ACCREDITED PROVIDER™
INTERPROFESSIONAL CONTINUING EDUCATION

Physicians - In support of improving patient care, this activity has been planned and implemented by Amedco LLC and Postgraduate Healthcare Education. Amedco LLC is jointly accredited by the Accreditation Council for Continuing Medical Education (ACCME), the Accreditation Council for Pharmacy Education (ACPE), and the American Nurses Credentialing Center (ANCC), to provide continuing education for the healthcare team

Credit Designation Statement - Amedco designates this live activity for *AMA PRA Category 1 Credits™*. Physicians should claim only the credit commensurate with the extent of their participation in the activity.

Endorsed by:

Jointly provided by:

Supported by an independent medical education grant from:

Review of Ophthalmology®

REG
(Review Education Group)



Alcon



BRIEF SUMMARY:

Consult the Full Prescribing Information for complete product information.

INDICATIONS AND USAGE

Xiidra® (lifitegrast ophthalmic solution) 5% is indicated for the treatment of the signs and symptoms of dry eye disease (DED).

DOSAGE AND ADMINISTRATION

Instill one drop of Xiidra twice daily (approximately 12 hours apart) into each eye using a single-use container. Discard the single-use container immediately after using in each eye. Contact lenses should be removed prior to the administration of Xiidra and may be reinserted 15 minutes following administration.

CONTRAINDICATIONS

Xiidra is contraindicated in patients with known hypersensitivity to lifitegrast or to any of the other ingredients in the formulation.

ADVERSE REACTIONS

Clinical Trials Experience

Because clinical studies are conducted under widely varying conditions, adverse reaction rates observed in clinical studies of a drug cannot be directly compared to rates in the clinical trials of another drug and may not reflect the rates observed in practice. In five clinical studies of dry eye disease conducted with lifitegrast ophthalmic solution, 1401 patients received at least 1 dose of lifitegrast (1287 of which received lifitegrast 5%). The majority of patients (84%) had ≤ 3 months of treatment exposure. 170 patients were exposed to lifitegrast for approximately 12 months. The majority of the treated patients were female (77%). The most common adverse reactions reported in 5-25 % of patients were instillation site irritation, dysgeusia and reduced visual acuity. Other adverse reactions reported in 1% to 5% of the patients were blurred vision, conjunctival hyperemia, eye irritation, headache, increased lacrimation, eye discharge, eye discomfort, eye pruritus and sinusitis.

Postmarketing Experience

The following adverse reactions have been identified during postapproval use of Xiidra. Because these reactions are reported voluntarily from a population of uncertain size, it is not always possible to reliably estimate their frequency or establish a causal relationship to drug exposure.

Rare cases of hypersensitivity, including anaphylactic reaction, bronchospasm, respiratory distress, pharyngeal edema, swollen tongue, and urticaria have been reported. Eye swelling and rash have been reported.

USE IN SPECIFIC POPULATIONS

Pregnancy

There are no available data on Xiidra use in pregnant women to inform any drug associated risks. Intravenous (IV) administration of lifitegrast to pregnant rats, from pre-mating through gestation day 17, did not produce teratogenicity at clinically relevant systemic exposures. Intravenous administration of lifitegrast to pregnant rabbits during organogenesis produced an increased incidence of omphalocele at the lowest dose

tested, 3 mg/kg/day (400-fold the human plasma exposure at the recommended human ophthalmic dose [RHOD], based on the area under the curve [AUC] level). Since human systemic exposure to lifitegrast following ocular administration of Xiidra at the RHOD is low, the applicability of animal findings to the risk of Xiidra use in humans during pregnancy is unclear.

Animal Data

Lifitegrast administered daily by intravenous (IV) injection to rats, from pre-mating through gestation day 17, caused an increase in mean preimplantation loss and an increased incidence of several minor skeletal anomalies at 30 mg /kg / day, representing 5,400-fold the human plasma exposure at the RHOD of Xiidra, based on AUC. No teratogenicity was observed in the rat at 10 mg /kg /day (460-fold the human plasma exposure at the RHOD, based on AUC). In the rabbit, an increased incidence of omphalocele was observed at the lowest dose tested, 3 mg /kg /day (400-fold the human plasma exposure at the RHOD, based on AUC), when administered by IV injection daily from gestation days 7 through 19. A fetal No Observed Adverse Effect Level (NOAEL) was not identified in the rabbit.

Lactation

There are no data on the presence of lifitegrast in human milk, the effects on the breastfed infant, or the effects on milk production. However, systemic exposure to lifitegrast from ocular administration is low. The developmental and health benefits of breastfeeding should be considered, along with the mother's clinical need for Xiidra and any potential adverse effects on the breastfed child from Xiidra.

Pediatric Use

Safety and efficacy in pediatric patients below the age of 17 years have not been established.

Geriatric Use

No overall differences in safety or effectiveness have been observed between elderly and younger adult patients.

NONCLINICAL TOXICOLOGY

Carcinogenesis, Mutagenesis, Impairment of Fertility

Carcinogenesis: Animal studies have not been conducted to determine the carcinogenic potential of lifitegrast.

Mutagenesis: Lifitegrast was not mutagenic in the *in vitro* Ames assay. Lifitegrast was not clastogenic in the *in vivo* mouse micronucleus assay. In an *in vitro* chromosomal aberration assay using mammalian cells (Chinese hamster ovary cells), lifitegrast was positive at the highest concentration tested, without metabolic activation.

Impairment of fertility: Lifitegrast administered at intravenous (IV) doses of up to 30 mg/kg/day (5400-fold the human plasma exposure at the recommended human ophthalmic dose (RHOD) of lifitegrast ophthalmic solution, 5%) had no effect on fertility and reproductive performance in male and female treated rats.



Manufactured for: Shire US Inc., 300 Shire Way, Lexington, MA 02421. For more information, go to www.Xiidra.com or call 1-800-828-2088. Marks designated ® and ™ are owned by Shire or an affiliated company. ©2018 Shire US Inc. SHIRE and the Shire Logo are trademarks or registered trademarks of Shire Pharmaceutical Holdings Ireland Limited or its affiliates. Patented: please see <https://www.shire.com/legal-notice/product-patents> Last Modified: 01/2018 S33769



Xiidra may provide

LASTING RELIEF

starting as early as 2 weeks¹

.....
**One drop in each eye, twice daily, about 12 hours apart.
Discard the single-use container immediately after use.¹**
.....

Choose Xiidra first for patients with signs and symptoms of Dry Eye Disease

Xiidra reduced symptoms of eye dryness at 2 weeks in 2 out of 4 studies, and in all 4 studies at 6 and 12 weeks. Xiidra also improved signs of inferior corneal staining at 12 weeks in 3 out of 4 studies.¹

The safety and efficacy of Xiidra compared to vehicle were studied in 2133 patients in 4 well-controlled, 12-week trials.¹

.....
Check it out at Xiidra-ECP.com
.....

Indication

Xiidra® (lifitegrast ophthalmic solution) 5% is indicated for the treatment of signs and symptoms of dry eye disease (DED).

Important Safety Information

Xiidra is contraindicated in patients with known hypersensitivity to lifitegrast or to any of the other ingredients.

In clinical trials, the most common adverse reactions reported in 5-25% of patients were instillation site irritation, dysgeusia and reduced visual acuity. Other adverse reactions reported in 1% to 5% of the patients were blurred vision, conjunctival hyperemia, eye irritation, headache, increased lacrimation, eye discharge, eye discomfort, eye pruritus and sinusitis.

To avoid the potential for eye injury or contamination of the solution, patients should not touch the tip of the single-use container to their eye or to any surface.

Contact lenses should be removed prior to the administration of Xiidra and may be reinserted 15 minutes following administration.

Safety and efficacy in pediatric patients below the age of 17 years have not been established.

For additional safety information, see accompanying Brief Summary of Safety Information on the adjacent page and Full Prescribing Information on Xiidra-ECP.com.

Reference:

1. Xiidra [Prescribing Information]. Lexington, MA: Shire US.

©2018 Shire US Inc., Lexington, MA 02421. 1-800-828-2088. All rights reserved. SHIRE and the Shire Logo are trademarks or registered trademarks of Shire Pharmaceutical Holdings Ireland Limited or its affiliates. Marks designated ® and ™ are owned by Shire or an affiliated company. S42270 10/18

