

TIPS FOR THE STAAR TORIC ICL P. 16 • TECH FOR TREATING STEREOACUITY PROBLEMS P. 18  
DIAGNOSIS AND MANAGEMENT OF LID LAXITY P. 46 • A HEAD-MOUNTED O.R. DISPLAY P. 51  
EXFOLIATION SYNDROME: A SYSTEMIC RISK? P. 54 • WILLS EYE RESIDENT CASE REPORT P. 63

# REVIEW<sup>®</sup> of Ophthalmology

February 2019

reviewofophthalmology.com

REFRACTIVE SURGERY FOCUS

## Refractive Surgery: Time for a Change?

*Will new technologies coexist with current methods or overthrow them?*

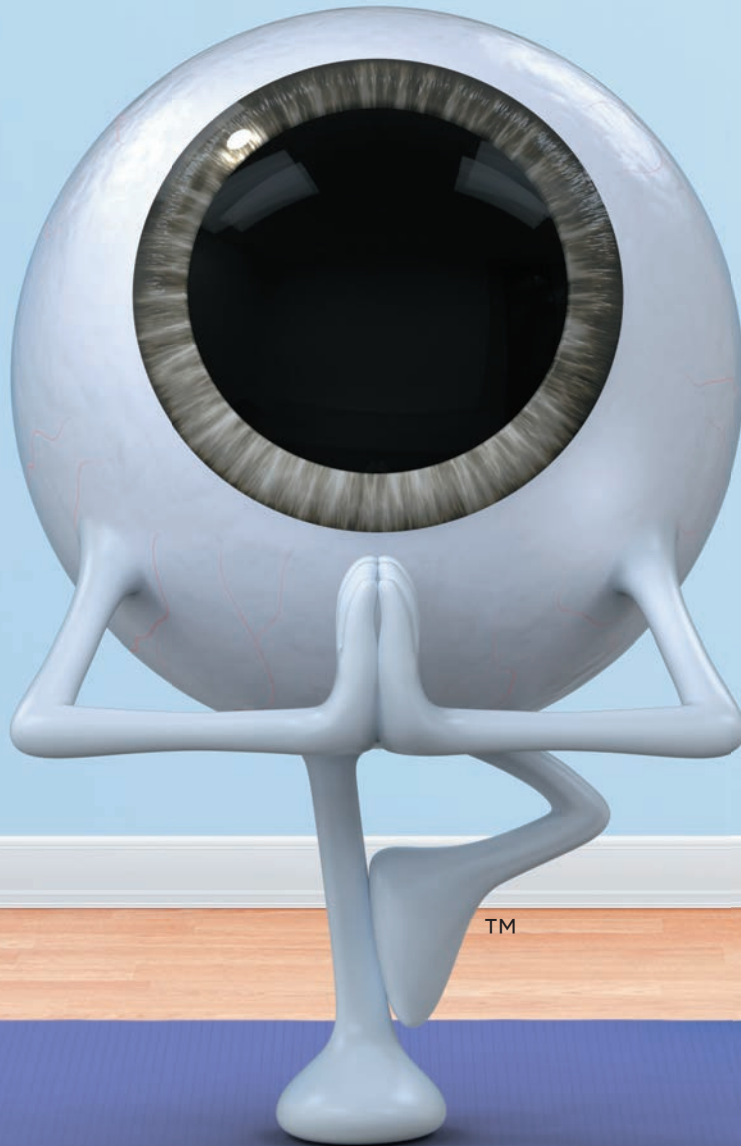
- Topo-guided LASIK in Practice **P. 24**
- Point-Counterpoint: SMILE vs. LASIK **P. 32**

### ALSO INSIDE:

- Will Dry Eye Ever Be Cured? **P. 38**
- DMEK Success: Maintaining the Graft **P. 42**



# Less stress. Pure success.



TM

**References:** 1. Silverstein SM, Rana V, Stephens R, Segars L, Pankratz J, Shivani R, et al. Effect of phenylephrine 1.0%-ketorolac 0.3% injection on tamsulosin-associated intraoperative floppy-iris syndrome. *J Cataract Refract Surg.* 2018;44(9):1103-1108. 2. Rosenberg ED, Nattis AS, Alevi D, et al. Visual outcomes, efficacy, and surgical complications associated with intracameral phenylephrine 1.0%/ketorolac 0.3% administered during cataract surgery. *Clin Ophthalmol.* 2018;12:21-28. 3. Bucci FA Jr, Michalek B, Fluet AT. Comparison of the frequency of use of a pupil expansion device with and without an intracameral phenylephrine and ketorolac injection 1%/0.3% at the time of routine cataract surgery. *Clin Ophthalmol.* 2017;11:1039-1043. 4. Visco D. Effect of phenylephrine/ketorolac on iris fixation ring use and surgical times in patients at risk of intraoperative miosis. *Clin Ophthalmol.* 2018;12:301-305. 5. Walter K, Delwadia N. Miosis prevention in femtosecond cataract surgery using a continuous infusion of phenylephrine and ketorolac. Presented at: 2018 American Society of Cataract and Refractive Surgery (ASCRS) and American Society of Ophthalmic Administrators (ASOA) Annual Meeting; April 13-17, 2018; Washington, DC. 6. Matossian C. Clinical outcomes of phenylephrine/ketorolac vs. epinephrine in cataract surgery in a real-world setting. Presented at: American Society of Cataract and Refractive Surgery (ASCRS) and American Society of Ophthalmic Administrators (ASOA) Annual Meeting; April 13-17, 2018; Washington, DC. 7. Al-Hashimi S, Donaldson K, Davidson R, et al. Medical and surgical management of the small pupil during cataract surgery. *J Cataract Refract Surg.* 2018;44:1032-1041. 8. Gayton JL. E-poster presented at: 15th International Congress on Vision Science and Eye; 2017 Aug 10-11; London, UK. 9. Katsev DA, Katsev CC, Pinnow J, Lockhart CM. Intracameral ketorolac concentration at the beginning and end of cataract surgery following preoperative topical ketorolac administration. *Clin Ophthalmol.* 2017;11:1897-1901. 10. Waterbury LD. Alternative drug delivery for patients undergoing cataract surgery as demonstrated in a canine model. *J Ocul Pharmacol Ther.* 2018;34:154-160.

OMIDRIA® (phenylephrine and ketorolac intraocular solution) 1% / 0.3% is added to ophthalmic irrigating solution used during cataract surgery or intraocular lens replacement and is indicated for maintaining pupil size by preventing intraoperative miosis and reducing postoperative ocular pain.

## The data are compelling and consistent—OMIDRIA makes cataract surgery better for you and your patients

Published and presented clinical studies report that in post-launch (i.e., not included in current labeling), prospective and retrospective, double-masked and open-label, cohort and case-controlled, single- and multi-center analyses, the use of OMIDRIA, compared to the surgeons' standard of care, statistically significantly:

- Prevents Intraoperative Floppy Iris Syndrome (IFIS)<sup>1</sup>
- Reduces complication rates (epinephrine comparator)<sup>2</sup>
- Decreases use of pupil-expanding devices (epinephrine comparator)<sup>2-7</sup>
- Reduces surgical times (epinephrine comparator)<sup>2,4,6,7</sup>
- Prevents miosis during femtosecond laser-assisted surgery (epinephrine comparator)<sup>5,8</sup>
- Improves uncorrected visual acuity on day after surgery (epinephrine comparator)<sup>2</sup>
- Delivers NSAID to the anterior chamber and related structures better than routine preoperative topical drug administration, resulting in effectively complete postoperative inhibition of COX-1 and COX-2<sup>9,10</sup>

**Separately reimbursed under Medicare Part B**

**Contact your OMIDRIA representative today or visit [omidria.com](http://omidria.com) to learn more**

### IMPORTANT SAFETY INFORMATION

OMIDRIA must be added to irrigating solution prior to intraocular use.

OMIDRIA is contraindicated in patients with a known hypersensitivity to any of its ingredients.

Systemic exposure of phenylephrine may cause elevations in blood pressure.

Use OMIDRIA with caution in individuals who have previously exhibited sensitivities to acetylsalicylic acid, phenylacetic acid derivatives, and other nonsteroidal anti-inflammatory drugs (NSAIDs), or have a past medical history of asthma.

The most commonly reported adverse reactions at  $\geq 2\%$  are eye irritation, posterior capsule opacification, increased intraocular pressure, and anterior chamber inflammation.

Please see the Full Prescribing Information for OMIDRIA at [www.omidria.com/prescribinginformation](http://www.omidria.com/prescribinginformation).

You are encouraged to report Suspected Adverse Reactions to the FDA. Visit [www.fda.gov/medwatch](http://www.fda.gov/medwatch), or call 1-800-FDA-1088.



**OMIDRIA®**

(phenylephrine and ketorolac  
intraocular solution)  
1% / 0.3%

# Decreasing Patient Wait Times Using New Technology

**Radio frequency identification** is commonly used to deter shoplifting, but those at University of Michigan Kellogg Eye Center are employing RFID to achieve real-time localization of patients and health-care providers. The practice says that the technology is streamlining operations by using data visualization to decrease patient wait time and therefore improve the quality of the visit.

“We know that people’s time is valuable and people are always more satisfied with their care if they don’t have to wait as long,” says Paula Anne Newman-Casey, MD, an assistant professor of ophthalmology at Michigan Medicine, who conducted the study. By analyzing raw data, she aimed to accomplish two things. “I was looking to deploy a system to calculate how much time patients spend waiting to be seen in order to see if we could implement policy changes to work on reducing that time. Also, I was looking to see where we could add standardized education to patient visits.” She explained that by analyzing RFID data, the clinic would be able to test new policies and quantitate any impacts on wait times and overall length of clinic visits.

Doctors, ophthalmic technicians, medical assistants and more than 2,000 patients agreed to don ID tags embedded with a small chip that transmits a signal to a remote scanner. With the information generated, the facility can attempt to increase the number of patients seen and improve clinic efficiencies, notes Dr. Newman-Casey. She says that there is interest in using the

data to improve scheduling and optimize templates. The end result, the center says, is a “smart clinic,” where more patients can be seen without compromising wait times.

Dr. Newman-Casey is also designing a web application that delivers personalized glaucoma coaching. The goal is to train medical assistants to provide support to patients through the application, which, she says, “generates specific education and counseling sessions for the patient based on their actual test results, diagnosis, doctor’s recommendations and barriers to optimal self-care. Instead of having a generic discussion about the disease, the information that the counselor provides is highly personalized.” Dr. Newman-Casey believes personalized education can encourage people to take medications as prescribed, and offering additional self-management support will help people take better care of themselves.

## Visual Field Loss and Disability

Researchers from the Duke University Department of Ophthalmology in Durham, North Carolina, and the Department of Ophthalmology at the State University of Campinas in Brazil say that even a small amount of visual field loss can result in disability.

In their study, published in the January issue of the *American Journal of Ophthalmology*, the researchers analyzed 263 glaucoma patients using visual function questionnaires and used a method called latent class analysis to quantify the amount of visual field damage associated with disability. They divided patients into mutually exclusive classes based on their responses on the questionnaires, and investigated any differences in standard automated perimetry mean deviation and integrated binocular mean sensitivity values between the classes.

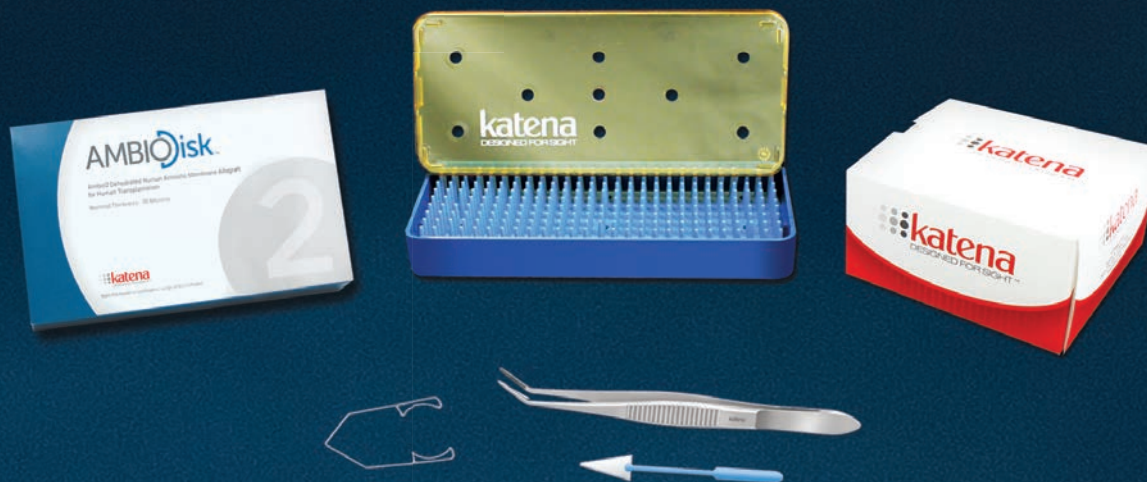The researchers say that a model with two classes, disabled and non-disabled, turned out to fit the data best. The disabled group had 48 patients (18 percent) and the nondisabled group had 215 (82 percent). The average mean deviation in the better eye in the disabled group was -5.98 dB, versus -2.51 dB in the nondisabled group ( $p < 0.001$ ). For the worse eye, the values were -13.36 dB in the disabled group and -6.05 dB in the nondisabled group. They found that patients with severe glaucoma in the better eye had five times higher odds of being classified as disabled.

“We identified that, on average, a loss of approximately 6 dB in the better eye was associated with disability in glaucoma,” the researchers noted. “For the worse eye, the average loss in the disabled group was approximately 13 dB. This is an important finding, as it shows that even relatively early defects can be associated with disability if they occur in the better eye.” **REVIEW**

# HIT THE DRY EYE MARK WITH AMBIOisk.



Launch your adoption of amniotic membrane  
with the **Jump Start Kit**. *Call Katena for details!*



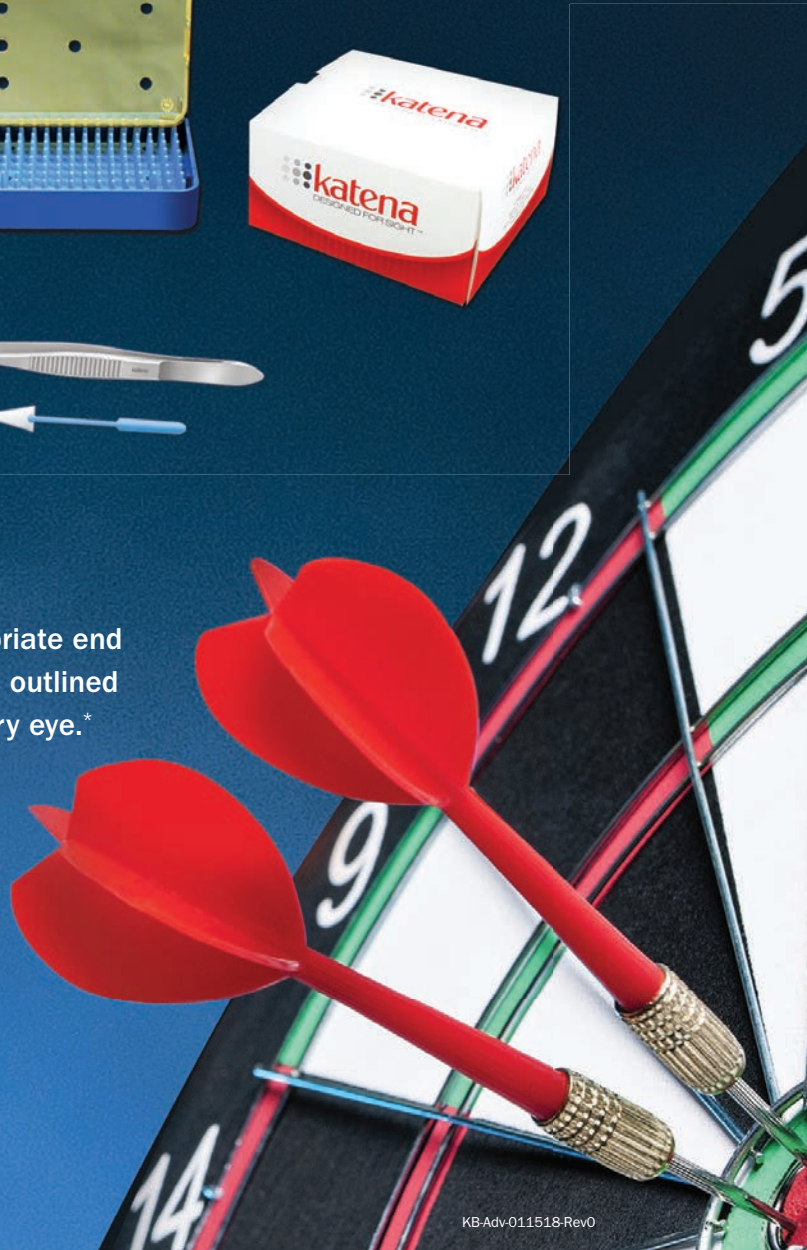Amniotic membrane is considered an appropriate end stage treatment option to address conditions outlined in the DEWS II step 4 guidelines for severe dry eye.\*



800.225.1195 • info@katena.com • www.katena.com

\* Physicians may choose to use amniotic membrane at their discretion.  
REFERENCE: Craig JP et al., TFOS DEWS II Report Executive Summary,  
The Ocular Surface (2017), <http://dx.doi.org/10.1016/j.jtos.2017.08.003>

KB-Adv-011518-Rev0



## Basics of Venture Funds for the New Entrepreneur

In early January of each year, the biotech and pharmaceutical industry descend on San Francisco for the JP Morgan Healthcare Conference. There, start-up companies pitch their new projects, since the entire investment community is gathered in one place. If you aspire to be one of these start-ups, and you have an idea for a product or company, it helps to understand how venture funds work to ensure that your fundraising “road show” targets the right funds and positions itself appropriately.

In past articles, we’ve discussed preparing your business plan, as well as securing financing and partners. Here, in an article geared toward the first-time physician-entrepreneur, we’ll provide the basic information you need in order to understand venture funds. These comments are very general, and it’s important to remember that each investor has his own strategies and comfort zone.

### Fund Structure

There are multiple types of investment funds and vehicles, ranging from single angel investors or groups that raise their own capital for funding deals on a case-by-case basis, to more traditional venture funds, to corporate-structured investment vehicles. The structure and strategy of the investor will impact whether your opportunity matches its size, timeline and risk profile. This column focuses mainly on the perspective of the traditional limited-partnership venture fund.

In the LP venture fund, capital is raised from its investors, the limited partners. Typically, these LPs are large institutions, family offices, high-net-worth individuals and large pension funds. The fund proceeds are shared with the managing group, known as the General Partner. The GP usually invests in the fund.

It’s important to understand how the partners who are selecting investments and managing the fund are incentivized, as it relates to the risk, timing and strategy of your investment. The GP benefits from fund investments in two ways: receiving its own return from the capital it invested within the limited partnership and by receiving a carried interest, which is a percentage of the proceeds that the fund generates after it first pays the LP investors back their investment. This structure mandates that the fund provides exits from its investments so that it can return cash to LPs, and the GP prefers to do

this as quickly as possible so that the returns reach a certain threshold, at which point the GP starts to receive cash, as well.

These exits may take the form of selling shares, acquisitions or a public offering. Licensing with long-term royalties alone doesn’t directly drive early returns to the LPs or GP. Therefore, laying out the timeline for value inflections, or points when a license or exit is possible, is critical in your pitch. Learn as much as you can from the fund on its strategy/focus, prior investments, when returns are expected, and which funding partners they typically co-invest with (recognizing that there may be some communication between funds).

### Size of Investments

For some funds, ophthalmology alone may be seen as too narrow of a niche. This is mentioned to point out that a fund may be open to looking for an ophthalmic investment that isn’t a single asset. Sometimes this can be addressed if a product has multiple indications, in or out of ophthalmology, that should be highlighted. These products are considered platform technologies and provide a greater likelihood of return than single-asset products. Having “multiple shots on goal” doesn’t always appeal to investors, however, and some may consider the pursuit of other potential uses in parallel to be more of a distraction than a benefit.

Larger funds need to deploy larger amounts of capital, and a larger fund may not be as motivated to go through diligence for a small (several million dollar) investment unless it can put sufficient capital to work. For example, some funds may look to deploy \$5 million, \$10 million or more in individual investments, and for funds with this capacity, generally speaking, a \$1- to 2-million investment may not fit their investment profile. However, in some cases, a fund may look at a smaller, seed or early investment as a way to get involved and provide them with access to invest in follow-on rounds.

It’s always important to thoroughly understand your funding needs and consider whether it makes sense to take a larger investment in order to expand a clinical trial for higher statistical powering, extended dosing or follow-up period, or to accelerate a follow-on project in parallel. When you talk with an investor, learn what size investments

he or she usually makes.

### The Fund’s Life Cycle

Where the fund is in its life cycle will also impact the investment approach. A fund typically has a lifespan, such as seven to 10 years. There is an investment period during which time the fund can deploy capital, and then there’s usually capital kept in reserve for follow-on investments. For example, a fund with a 10-year life may identify targets within the first one to three years and plan for subsequent follow-on investments. The fund is looking to have monetization events occur after that and hopes to exit all of its investments before the end of its life. The amount of capital available to invest and the timing of the investment period are important pieces of information to ask about when meeting with VC firms.

Why does this matter to you as an entrepreneur? A management team or partnership typically creates multiple funds, each with its own lifespan and focus. Typically, once established and investing (especially once initial exits are realized), the fund’s management team may already be focused on its subsequent fund (e.g., Fund 3 may be in harvest mode, Fund 4 in follow-on investments, and Fund 5 in initial investments). Often, an investment may fit the general target profile for a fund, but they may be fully invested and in the middle of creating their next fund. If you’re talking with a fund during the later stages of its life, but you have a three-to-five-year time period to exit, that may not fit into its life cycle.

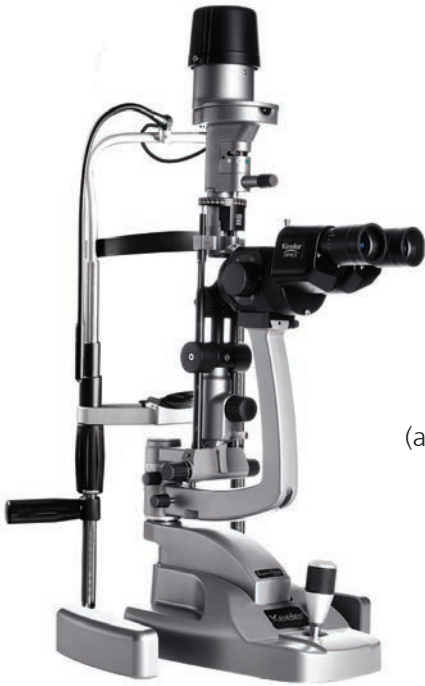### Risk Profile of the Fund

Some funds are focused on later-stage, low-risk opportunities. These funds may seek lower risk for their LPs and are comfortable with less return. If you are a pre-clinical stage company, you generally won’t fit their model of seeking commercial-stage projects that don’t have development risk. For other venture funds, having Phase II data may be considered “later stage,” particularly if they usually focus on pre-IND-stage opportunities. The lesson here is to make sure to be aligned on messaging and use of the words “late stage.” Late-stage to some funds means you have market approval and are launched, or near approval with a clear path to launch, or are looking to monetize royalties.

# The Keeler<sup>3</sup> Trade In Program

## Buy 3 // Trade 3 // Get 1 Free

The Power of 3. Purchase any 3 Keeler Slit Lamps and trade in 3 of your old Slit Lamps and we'll send you a 4th Keeler Slit Lamp absolutely free of charge.



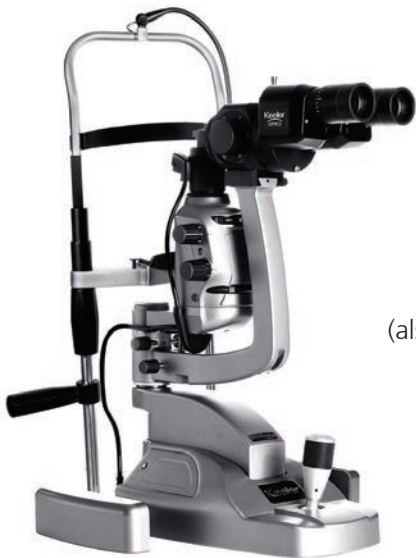**KSL-H**

(also in Digital Ready)



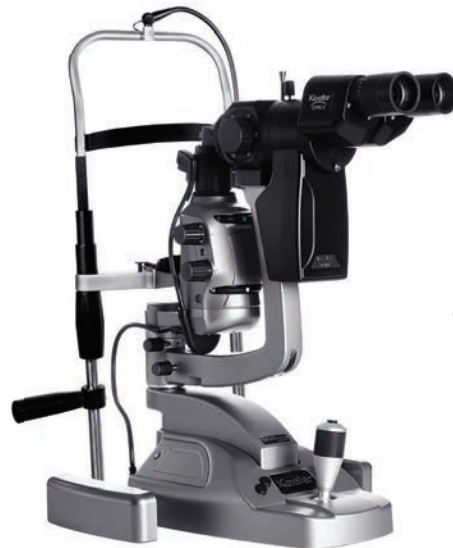**KSL-H-D**

(full Digital)



**KSL-Z**

(also in Digital Ready)



**KSL-H-D**

(full Digital)

**Keeler**  
OPTICS

Keeler Instruments, Inc. • 3222 Phoenixville Pike, bldg. 50 • Malvern, PA 19355  
Tel: (800) 523-5620 • Fax: (610) 353-7814 • email: keeler@keelerusa.com

**Offer valid until March 31, 2019.**

Contact Keeler or one of our authorized dealers for more information.

**Editor in Chief**

**Walter C. Bethke**  
(610) 492-1024  
wbethke@jobson.com

**Senior Editor**

**Christopher Kent**  
(814) 861-5559  
ckent@jobson.com

**Senior Associate Editor**

**Kristine Brennan**  
(610) 492-1008  
kbrennan@jobson.com

**Associate Editor**

**Alexandra Skinner**  
(610) 492-1025  
ckent@jobson.com

**Chief Medical Editor**

**Mark H. Blecher, MD**

**Art Director**

**Jared Araujo**  
(610) 492-1032  
jaraujo@jobson.com

**Senior Graphic Designer**

**Matt Egger**  
(610) 492-1029  
megger@jobson.com

**Graphic Designer**

**Ashley Schmouder**  
(610) 492-101048  
aschmouder@jobson.com

**International coordinator, Japan**

**Mitz Kaminuma**  
Reviewophtho@aol.com

**Business Offices**

11 Campus Boulevard, Suite 100  
Newtown Square, PA 19073  
(610) 492-1000  
Fax: (610) 492-1039

**Subscription inquiries:**

United States — (877) 529-1746  
Outside U.S. — (845) 267-3065

**E-mail:**

revophthology@cambeywest.com

**Website:** www.reviewofophthology.com



Some funds may be looking specifically for minimal human proof-of-concept (POC) being established before they consider an investment. There may be ways to structure investments and the timetable for them to deploy capital such that early seed-type investments are made to help obtain the POC (preclinical or clinical) with further investment(s) to follow.

**The Fund's Team**

Different funds have different “personalities” and different types of people who manage them. The backgrounds and skill sets of fund managers vary greatly. The type of information that you emphasize in your pitch (e.g., related to general market information) may be presented in more detail if you're speaking to a general health-care fund or family office that may not know as much about ophthalmology's unmet needs and potential markets versus a fund that focuses more on this field.

Look for expertise that supplements and complements your team. Investment in the ophthalmic space has grown tremendously over the past decade, driven by multiple industry dynamics. This has brought a range of different types of investors, new funds looking to enter the space and strategic investors (e.g., regional companies looking to bring new products in). Some investors have specific ophthalmology expertise and experience, and have been successful for many years. There are also now a few dedicated funds, investment networks and strategic investors focused specifically on ocular product development.

Note that fund managers are focused on managing the LP capital, and often don't have the intention of getting into the routine operational details and project management related to their investments. As some funds seek out more later-stage, mature opportunities, some new entrepreneurs may actually be seeking, or could leverage, investors with a more “service-oriented approach” to make use of specific experience that a fund's team may have in a particular industry—such as ophthalmology—including development, clinical studies, portfolio management and strategy, corporate finance and licensing/exit deals. Some investors may be more open to a deeper level of dialogue and may be willing to help refine target profiles, plans and strategy, if necessary, where others may see this need as an indication that the plan isn't fully baked. Many funds expect to see a detailed plan for development, clinical study strategy, timelines and budgets up front, while others may be open to incubating concepts and working through things. This highlights the importance of understanding the characteristics of the fund and the investment professionals you're talking with—their backgrounds, the differences in philosophies between investors, and how the investors interact with their portfolio companies. Doing so allows you to tailor your pitch to them.

New entrepreneurs should realize that the top of the funnel is very large for funds that are seeing new deals every day. Make sure your initial outreach is focused with appropriate messaging for that fund, and tailor the pitch to your audience. (*See our prior column, “Due Diligence and Key Elements of the Pitch” Aug 2018*). Before your first meeting, evaluate what companies they've invested in to get a feel for the investment stages, type of portfolio, type of team and sizes of investments. These are all reasonable questions to ask during your first conversation, as well, but it helps to be as prepared as possible.

As a new entrepreneur raising capital, you certainly want to cast a wide net, leverage network opportunities and make connections wherever you can. Sometimes it just takes having that internal champion that your plan resonates with, even if an opportunity is outside the typical focus of a specific fund. Certainly, don't limit who you reach out to and connect with. Hopefully, some of these points will help you choose the initial tier of venture funds to target and allow you to tailor your approach to them.

*Mr. Chapin is senior vice president of corporate development at the consulting, clinical research and development firm Ora. Dr. Weiss is an assistant professor of ophthalmology at Rush University Medical Center, chairman of ophthalmology at MacNeal Hospital, founder of Chicago Eye Consultants, and managing member of Infocus Capital Partners. Infocus is the manager of Infocus Fund I, an ophthalmology-specialized fund that invests across drugs, devices, diagnostics and drug delivery. Dr. Rothman is a clinical assistant professor of ophthalmology at the Hofstra Northwell School of Medicine, a partner at Glaucoma Consultants of Long Island, and a managing member of Infocus. The authors welcome your comments or questions regarding product development and investments. Please send correspondence to mchapin@oraclinical.com or visit [oraclinical.com](http://oraclinical.com) and [infocuscapitalpartners.com](http://infocuscapitalpartners.com).*



Hypochlorous Acid Solution  
**NOW Available *Without* a Prescription**

**zenoptiq™**  
Hypochlorous Acid Solution

**zenoptiq™**  
0.01% Hypochlorous Acid

Daily Eyelid  
& Eyelash Hygiene  
Solution

Gentle | Soothing | All Natural



3.38oz (100mL)

**zenoptiq™**  
0.0085% Hypochlorous Acid

Daily Eyelid  
& Eyelash Hygiene  
Solution

Gentle | Soothing | All Natural



2.0oz (60.0mL)

## Daily Eyelid & Eyelash Cleanser

- Naturally removes foreign matter
- Nontoxic, nonirritating
- Has been shown in studies to reduce bacteria/microbes
- Formulated to relieve symptoms of MGD, Blepharitis and Dry Eye
- Available in 0.01 % HOCL spray and 0.0085% HOCL gel

LEARN MORE AT  
**zenoptiq.com**



(866) 752-6006 – FocusLaboratories.com

Trademarks: Zenoptiq™ (Paragon BioTeck, Inc.) | Copyright © 2018 Paragon BioTeck, Inc. All Rights Reserved.

FLM191-0119-01

# CONTRIBUTORS

**CHIEF MEDICAL EDITOR**

Mark H. Blecher, MD

**CONTACT LENSES**

Penny Asbell, MD

**CORNEA / ANTERIOR SEGMENT**

Thomas John, MD

**GLAUCOMA MANAGEMENT**

Peter Netland, MD, PHD  
Kuldev Singh, MD

**MASTERS OF SURGERY**

Taliva D. Martin, MD  
Sara J. Haug, MD, PhD

**MEDICARE Q & A**

Paul M. Larson, MBA

**PEDIATRIC PATIENT**

Wendy Huang, MD

**PLASTIC POINTERS**

Ann P. Murchison, MD, MPH

**REFRACTIVE SURGERY**

Arturo S. Chayet, MD

**RETINAL INSIDER**

Carl Regillo, MD, FACS  
Emmett T. Cunningham Jr., MD, PHD, MPH

**TECHNOLOGY UPDATE**

Steven T. Charles, MD  
Michael Colvard, MD

**WILLS RESIDENT CASE SERIES**

Thomas Jenkins, MD.

# ADVISORY BOARD

**PENNY A. ASBELL, MD**, MEMPHIS, TENN.

**WILLIAM I. BOND, MD**, PEKIN, ILL.

**ALAN N. CARLSON, MD**, DURHAM, N.C.

**Y. RALPH CHU, MD**, EDINA, MINN.

**ADAM J. COHEN, MD**, DOWNERS GROVE, ILL.

**UDAY DEVGAN, MD, FACS**, LOS ANGELES

**ERIC DONNENFELD, MD**, ROCKVILLE CENTRE, N.Y.

**DANIEL S. DURRIE, MD**, KANSAS CITY, MO.

**ROBERT EPSTEIN, MD**, MCHENRY, ILL.

**ROBERT D. FECHTNER, MD**, NEWARK, N.J.

**WILLIAM J. FISHKIND, MD**, TUCSON, ARIZ.

**JAMES P. GILLS, MD**, TARPON SPRINGS, FLA.

**HARRY GRABOW, MD**, SARASOTA, FLA.

**DOUGLAS K. GRAYSON, MD**, NEW YORK CITY

**THOMAS S. HARBIN, MD, MBA**, ATLANTA

**DAVID R. HARDTEN, MD**, MINNEAPOLIS

**KENNETH J. HOFFER, MD**, SANTA MONICA, CALIF.

**JACK T. HOLLADAY, MD, MSEE**, HOUSTON

**JOHN D. HUNKELER, MD**, KANSAS CITY, MO.

**THOMAS JOHN, MD**, TINLEY PARK, ILL.

**ROBERT M. KERSHNER, MD, MS**, PALM BEACH GARDENS, FLA.

**GUY M. KEZIRIAN, MD**, PARADISE VALLEY, ARIZ.

**TERRY KIM, MD**, DURHAM, N.C.

**TOMMY KORN, MD**, SAN DIEGO

**DAVID A. LEE, MD**, HOUSTON

**FRANCIS S. MAH, MD**, PITTSBURGH

**NICK MAMALIS, MD**, SALT LAKE CITY

**WILLIAM G. MARTIN, MD**, OREGON, OHIO

**MIKE S. MCFARLAND, MD**, PINE BLUFF, ARK.

**JEFFREY B. MORRIS, MD, MPH**, ENCINITAS, CALIF.

**MARLENE R. MOSTER, MD**, PHILADELPHIA

**ROBERT J. NOECKER, MD**, FAIRFIELD, CONN.

**ROBERT OSHER, MD**, CINCINNATI

**MARK PACKER, MD**, WEST PALM BEACH, FLA.

**STEPHEN PASCUCCI, MD**, BONITA SPRINGS, FLA.

**PAUL PENDER, MD**, BEDFORD, N.H.

**CHRISTOPHER J. RAPUANO, MD**, PHILADELPHIA

**AUGUST READER III, MD**, SAN FRANCISCO

**TONY REALINI, MD**, MORGANTOWN, W.V.

**KENNETH J. ROSENTHAL, MD**, GREAT NECK, N.Y.

**ERIC ROTHCHILD, MD**, DELRAY BEACH, FLA.

**SHERI ROWEN, MD**, BALTIMORE

**JAMES J. SALZ, MD**, LOS ANGELES

**INGRID U. SCOTT, MD, MPH**, HERSHEY, PA.

**JOEL SCHUMAN, MD**, PITTSBURGH

**GAURAV SHAH, MD**, ST. LOUIS

**DAVID R. STAGER JR., MD**, DALLAS

**KARL STONECIPHER, MD**, GREENSBORO, N.C.

**JAMES C. TSAI, MD**, NEW YORK CITY

**VANCE THOMPSON, MD**, SIOUX FALLS, S.D.

**FARRELL C. TYSON, MD**, CAPE CORAL, FLA.

**R. BRUCE WALLACE III, MD**, ALEXANDRIA, LA.

**ROBERT G. WILEY, MD**, CLEVELAND

**FRANK WEINSTOCK, MD**, CANTON, OHIO

**BUSINESS OFFICES**

11 CAMPUS BOULEVARD, SUITE 100  
NEWTOWN SQUARE, PA 19073  
SUBSCRIPTION INQUIRIES (877) 529-1746  
(USA ONLY); OUTSIDE USA, CALL (847) 763-9630

**BUSINESS STAFF**

PUBLISHER

**JAMES HENNE**

(610) 492-1017 JHENNE@JOBSON.COM

REGIONAL SALES MANAGER

**MICHELE BARRETT**

(610) 492-1014 MBARRETT@JOBSON.COM

REGIONAL SALES MANAGER

**MICHAEL HOSTER**

(610) 492-1028 MHOSTER@JOBSON.COM

**CLASSIFIED ADVERTISING**

(888)-498-1460

VICE PRESIDENT OF OPERATIONS

**CASEY FOSTER**

(610) 492-1007 CFOSTER@JOBSON.COM

PRODUCTION MANAGER

**SCOTT TOBIN**

(610) 492-1011 STOBIN@JOBSON.COM

**SUBSCRIPTIONS**

\$63 A YEAR, \$99 (U.S.) IN CANADA,  
\$158 (U.S.) IN ALL OTHER COUNTRIES.

SUBSCRIPTIONS E-MAIL:

REVOPHTHALMOLOGY@CAMBEYWEST.COM

**CIRCULATION**

PO BOX 71, CONGERS, NY 10920-0071  
(877) 529-1746

OUTSIDE USA: (845) 267-3065

SENIOR CIRCULATION MANAGER

**HAMILTON MAHER**

(212) 219-7870 hmaher@jhihealth.com

CEO, INFORMATION GROUP SERVICES

**MARC FERRARA**

SENIOR VICE PRESIDENT, OPERATIONS

**JEFF LEVITZ**

VICE PRESIDENT, HUMAN RESOURCES

**TAMMY GARCIA**

VICE PRESIDENT, CREATIVE SERVICES & PRODUCTION

**MONICA TETTAMANZI**

CORPORATE PRODUCTION DIRECTOR

**JOHN ANTHONY CAGGIANO**

VICE PRESIDENT, CIRCULATION

**EVELDA BAREA**



440 Ninth Avenue, 14th Floor  
New York, N.Y. 10001

REVIEW OF OPHTHALMOLOGY (ISSN 1081-0226; USPS No. 0012-345) is published monthly, 12 times per year by Jobson Medical Information, 440 Ninth Avenue, 14th Floor, New York, N.Y. 10001. Periodicals postage paid at New York, NY and additional mailing offices. Postmaster: Send address changes to Review of Ophthalmology, PO Box 71, Congers, NY 10929-0071. Subscription Prices: US One Year \$63.00, US Two Year \$112.00, Canada One Year \$99.00, Canada Two Year \$181.00, Int'l One Year \$158.00, Int'l Two Year \$274.00. For subscription information call (877) 529-1746 (USA only); outside USA, call (845)-267-3065. Or email us at revophthalmology@cambeywest.com. Canada Post: Publications Mail Agreement #40612608. Canada Returns to be sent to Bleuchip International, P.O. Box 25542, London, ON N6C 6B2.

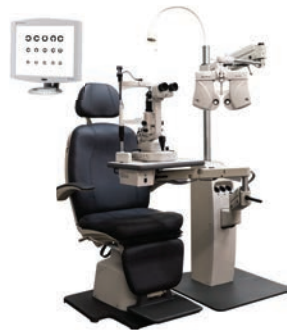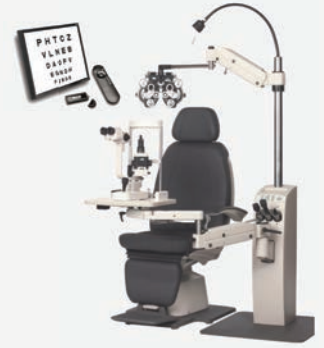## VALUE LANE PACKAGE

- ✓ LOMBART CS-5 Stand & Exam Chair
- ✓ Topcon SL-2G Slit Lamp
- ✓ Topcon VT-10 Refractor
- ✓ LOMBART CVSe Acuity System

~~\$23,794~~

**\$13,995**

Savings of up to \$9,799



## DIGITAL REFRACTION PACKAGE

- ✓ Lombart CS-5 Instrument Stand & Exam Chair
- ✓ Topcon SL-2G Slit Lamp
- ✓ Premium Digital Refractor (Topcon CV5000S or Reichert VRx)
- ✓ Corresponding Acuity System

~~\$47,169~~

**\$29,485**

Savings of up to \$17,684

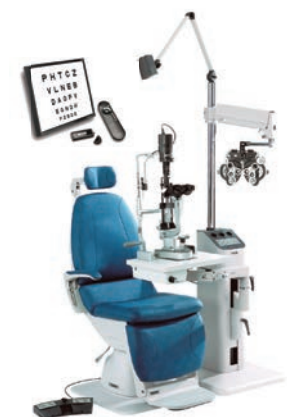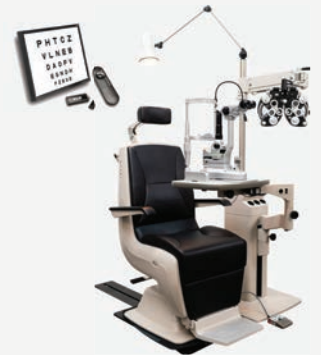## MARCO MYLANE PACKAGE

- ✓ Marco Deluxe Stand
- ✓ Marco Encore Automatic Chair
- ✓ Marco M2 Ultra Slit Lamp
- ✓ Marco RT-700 Illuminated Refractor
- ✓ LOMBART CVSe Acuity System

~~\$26,957~~

**\$19,995**

Savings of up to \$6,962



## PREMIUM LANE PACKAGE

- ✓ Reliance 7900 Stand with Console
- ✓ Reliance FX 920 Examination Chair
- ✓ Haag-Streit BI900 LED Slit Lamp
- ✓ Reichert Ultramatic RX Master Phoropter®
- ✓ Haag-Streit Tonometer
- ✓ Reliance Stool
- ✓ LOMBART CVSe Acuity System

~~\$40,460~~

**\$27,695**

Savings of up to \$12,765

Imaging Upgrade Available  
for Only \$4,400!

**ASK US ABOUT QUICK DELIVERY!**

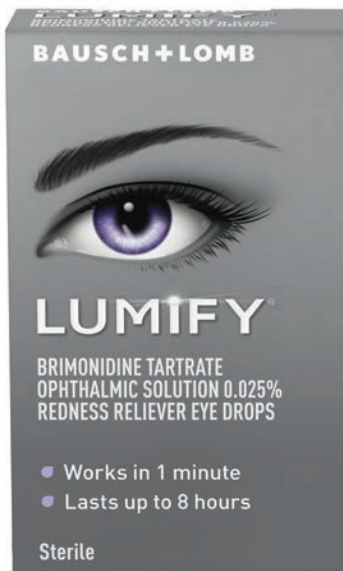(1) FREE Preventative Maintenance in First Two Years

**CALL US TODAY AT 1-800-LOMBART**

# LUMIFY®

BRIMONIDINE TARTRATE OPHTHALMIC SOLUTION 0.025%  
REDNESS RELIEVER EYE DROPS

## A REDNESS RELIEVER LIKE NO OTHER:



- The first and only OTC eye drop with low dose brimonidine tartrate (0.025%)
- Strong safety and efficacy profile with no tachyphylaxis and virtually no rebound redness in clinical trials
- Starts working in 1 minute - lasts for up to 8 hours

LUMIFY redness reliever eye drops are available at national retailers in 2.5mL and 7.5mL sizes.

**FDA**  
APPROVED



Images representative of clinical trial results, individual results may vary.

**Introduce your patients to LUMIFY® redness reliever eye drops!**

Learn more at [LUMIFYDROPS.com/professional](https://www.lumifydrops.com/professional)

# REVIEW<sup>®</sup> of Ophthalmology

February 2019 • Volume XXVI No. 2 | [reviewofophthalmology.com](http://reviewofophthalmology.com)

## Cover Focus

---

### 24 | **Topo-Guided LASIK in Refractive Practice**

*Christopher Kent, Senior Editor*

A little extra preop effort may yield unprecedented outcomes.

### 32 | **Point-Counterpoint: SMILE v. LASIK**

*Jesper Hjortdal, MD, PhD*

*Steven Wilson, MD*

SMILE and LASIK aficionados debate the pros and cons of each.

## Features

---

### 38 | **Will We Ever Cure Dry Eye?**

*Michelle Stephenson, Contributing Editor*

A look at potential new therapies for this complex condition.

### 42 | **DMEK Success: Maintaining the Graft**

*Kristine Brennan, Senior Associate Editor*

How to avoid trauma to donor tissue and head off postop complications.



# Departments

---

4 | [Review News](#)

16 | [Refractive/Cataract Rundown](#)

**Tips for Using the New Toric ICL**

Ways to make the most of a promising new phakic lens when treating astigmatism.

18 | [Technology Update](#)

**Binocular Vision: Keeping it Together**

New technologies for the treatment of stereoacuity problems—and more.

46 | [Plastic Pointers](#)

**Lid Laxity: Diagnosis and Management**

Why recognizing it early matters, and how to address it surgically.

51 | [Retinal Insider](#)

**First Look: A Head-mounted O.R. Display**

Surgeons who've used this novel prototype explain how it works.

54 | [Glaucoma Management](#)

**Does Exfoliation Syndrome Pose a Systemic Risk?**

The latest evidence on possible whole-body health effects.

59 | [Product News](#)

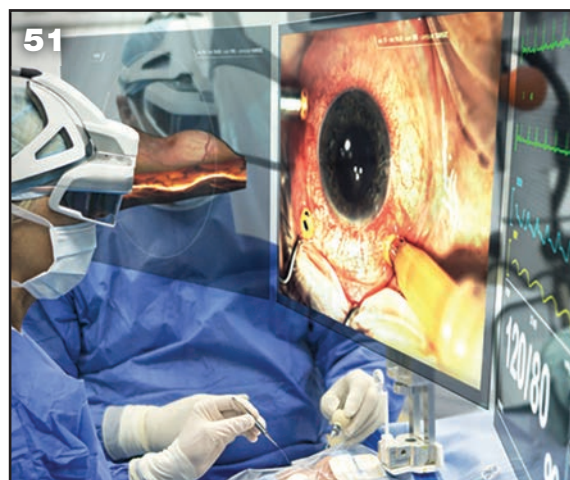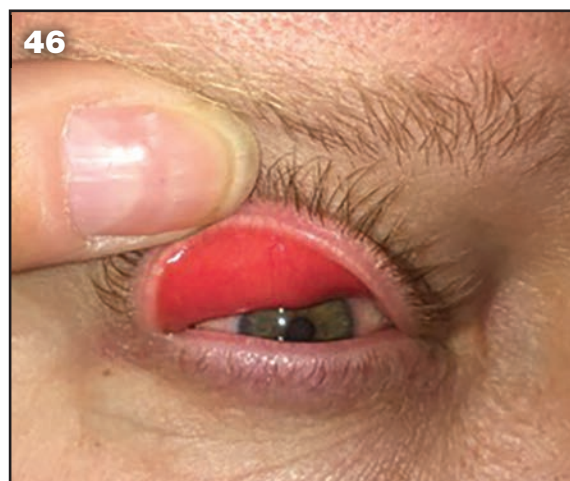60 | [Research Review](#)

**Adding Anastomoses to Anti-VEGF in CRVO**

62 | [Classifieds](#)

63 | [Wills Eye Resident Case Series](#)

66 | [Ad Index](#)





# See the Passion in Each Patient.

Keep life in sight.

Learn more about **TECNIS® IOLs** at **TecnisIOL.com**



Not actual patients.

## INDICATIONS AND IMPORTANT SAFETY INFORMATION

Rx Only

**ATTENTION:** Reference the Directions for Use for a complete listing of Indications and Important Safety Information. **INDICATIONS:** The TECNIS® 1-Piece Lens is indicated for the visual correction of aphakia in adult patients in whom a cataractous lens has been removed by extracapsular cataract extraction. These devices are intended to be placed in the capsular bag. **WARNINGS:** Physicians considering lens implantation should weigh the potential risk/benefit ratio for any conditions described in the TECNIS® 1-Piece IOL Directions for Use that could increase complications or impact patient outcomes. The TECNIS® 1-Piece IOL should not be placed in the ciliary sulcus. **PRECAUTIONS:** Do not reuse, resterilize, or autoclave. **ADVERSE EVENTS:** In 3.3% of patients, reported adverse events of cataract surgery with the 1-Piece IOL included macular edema. Other reported reactions occurring in less than 1% of patients were secondary surgical intervention (pars plana vitrectomy with membrane peel) and lens exchange (due to torn lens haptic).

\*Compared against AcrySof® IQ (SN60WF), HOYA AF-1™ FY-60AD and enVista® IOLs (MX60).

**Reference: 1.** Data on file. Chromatic aberration of the TECNIS® Symphony IOL. Johnson & Johnson Surgical Vision, Inc. Santa Ana, CA.

TECNIS is a trademark of Johnson & Johnson Surgical Vision, Inc. All other trademarks are the intellectual property of their respective owners. ©Johnson & Johnson Surgical Vision, Inc. 2018 | TecnisIOL.com | PP2018CT5383



### Leading Innovation

Transformative technology. Reliable outcomes.

### High-Quality Vision

Unmatched image contrast.<sup>1\*</sup> Outstanding visual acuity.

### Exceptional Satisfaction

Broadest IOL portfolio. Enhancing each lifestyle.

Bring Vision to Life.

*Johnson & Johnson* VISION



# Tips for Using the New Toric Visian

Phakic IOL users finally have a new option for treating their refractive-surgery patients who have astigmatism.

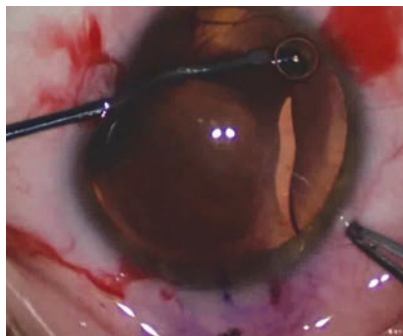*Walter Bethke, Editor in Chief*

**A**s observers of the refractive-surgery realm will tell you, it's taken a while for the United States to get a toric phakic intraocular lens. At long last, however, the Food and Drug Administration approved Staar's Visian Toric ICL for the correction of up to 4 D of cylinder, giving refractive surgeons a new, potentially versatile option for correcting their patients' refractive errors. If you're one of the many who were waiting for this development, and you're ready to begin implanting these lenses, here are some helpful tips from surgeons who've already done it.

## Preop Measurements

Surgeons say that, just as with the non-toric Visian, sizing of the lens is important, due to where it sits in the eye.

"Fundamentally, one thing that's worth understanding is that it's different than a toric IOL that you'd implant during cataract surgery," explains John Vukich, MD, director of the Refractive Surgery Service at Dean Clinic in Madison, Wisconsin, and associate clinical professor of ophthalmology at



Magid Moshirfar, MD

The toric ICL is designed so no more than 22.5 degrees of rotation is required to align the toric axis properly.

the University of Wisconsin-Madison. "With a toric IOL, you're looking at corneal astigmatism as the primary driver of the amount of correction that you use. Here, this is a refractive procedure; you're not changing the fundamental relationship between the cornea and the natural lens; instead, you're treating the entire refractive error. Therefore, corneal topography remains important; the surgeon should look for irregularity and signs of atypical corneal contour. That said, you treat the patient's refraction and not the corneal topography; it's a different way of thinking about the refractive error. The consequence of that is that it tends to

be a little bit easier to get the precise correction you're looking for with a toric ICL."

The toric Visian comes in four sizes (overall diameter), and the size the surgeon selects is based on white-to-white or sulcus-to-sulcus measurements. The lens is designed to be placed entirely within the posterior chamber directly behind the iris and in front of the anterior capsule of the crystalline lens. "In terms of the right size, we want to implant this so there's approximately 250 to 750  $\mu\text{m}$  of vault centrally between the crystalline lens and the posterior surface of the ICL once it's in the eye," explains Dr. Vukich.

Dr. Vukich uses the white-to-white measurement. "This is the FDA-approved way that the lens nomograms are set up," he says. "I measure the white-to-white distance myself. I don't use an IOLMaster or other biometric measurements because they're often not interpretive in terms of where the limbus actually is. Often, these prospective toric ICL patients are chronic contact lens wearers and therefore there's some ambiguity as to where, exactly, the limbus is located. As such, a surgeon's judgment is actually bet-



ter than allowing a machine to place a perimeter around the cornea and declare, 'This is the limbus.' My results have been excellent, and I haven't had to explant or exchange an ICL because of over-vault in several years—and I implant them regularly. I'm not saying there's a zero chance of vault issues, but if you're comfortable, careful and consistent with the measurements, you'll get good results."

Majid Moshirfar, MD, medical director of Hoopes Vision Refractive Research Center and professor of ophthalmology at the John A. Moran Eye Center at the University of Utah, uses ultrasound for lens sizing. "I usually use high-resolution ultrasound to carefully measure the sulcus-to-sulcus dimension," says Dr. Moshirfar. "Then, once the sulcus is measured, we also look at the lenticular rise and the aqueous depth—not the anterior chamber depth. We measure the latter from the endothelium to the anterior capsule. Then, using those measurements, I'm mainly using the Parkhurst nomograms to choose the proper ICL size that I'll use for the case."

Dr. Moshirfar acknowledges though that not all surgeons have access to those ultrasound technologies, though. "If you want to use the white-to-white measurement, I would take it from the Galilei and the Pentacam and average them. You can use the modified FDA nomogram based on the average white-to-white measurement from those two devices. However, I think ultrasound allows you to make a better judgment on lens sizing because you can see how thick the iris is and what the angle of the anterior chamber is going to be." For most cases, he says the lens sizes are 12.6 or 13.2 mm. "Very seldom will I use the 12.1- or 13.7-mm sizes."

Surgeons say you can help enhance your outcomes preoperatively in the way you order your lens. "My advice is this: If you can order the lens ahead of time, you'll have a greater likelihood of

getting a lens closer to what you like," he says. "What I mean is, many times you can order a lens that's weighted exactly at the 180-degree meridian and you don't need to change it at all. But, if you order it at the last minute, you may have to rotate it 10 to 15 degrees, and then the implantation can become more difficult. Try to get a lens that's within five degrees of the axis that you want."

Dr. Moshirfar says that if you have experience with the non-toric ICL, selecting the right patients when you're starting out with the toric ICL can make a difference as you gain confidence with the lens. "I recommend starting with patients who have more myopia than astigmatism," he says. "Start with someone who's -8 D with 2 or 3 D of astigmatism. Do this, and there won't be a major learning curve for someone who's been using the ICL for years.

"For those who have never implanted an ICL, however," Dr. Moshirfar adds, "I'd encourage them to instead begin with the non-toric ICL for high myopes."

## Implantation Tips

One of the interesting design features of the toric Visian is that the lens ships with the astigmatic correction already ground into the proper axis (hence Dr. Moshirfar's comment about ordering the right lens ahead of time). It's designed so that no more than 22.5 degrees of rotation is necessary. This has the potential to make the implantation easier than a lens that needs to be rotated into position by a high number of degrees.

"The critical axis is the horizontal," Dr. Vukich says. "You want to know where the 180-degree axis is, so you need to mark that, accounting for cyclotorsion. You don't have to mark the astigmatic axis on the eye. Instead, you're just rotating to the zero-to-180 degree meridian because the astigmat-

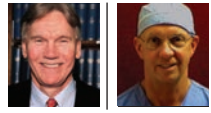ic axis is already part of the ICL. You're either rotating it clockwise or counterclockwise a few degrees in one direction or the other. Inherently, it's easier to mark at the zero-and-180 meridian, since it's within the palpebral fissures and can be done at the slit lamp.

"I use the YAG laser marking method," Dr. Vukich continues. "At the slit lamp, under topical anesthesia, with the YAG set to 5 mJ and the anterior focus, I make a slight divot in the epithelium at the zero-and-180 degree axis. I then touch the divot with a marking pen. The mark is durable—it won't fade or bleed out into a diffuse, large mark that's ambiguous. The mark will heal the next morning."

Dr. Moshirfar says the need for a lot of intraoperative rotation can make the case more challenging because rotating the lens can be difficult. "It's a rectangular-shaped lens," he says. "This is unlike other toric IOLs, such as cataract lenses, with which we've gotten used to the toric concept. Sometimes it just doesn't want to budge. It's forgiving for 3 to 5 degrees of rotation, but if you want to rotate it 15 degrees, it keeps wanting to go back to the original 180-degree meridian you started at; you might as well rotate it 30 degrees." It's for this reason he advocates ordering the lens ahead of time, so the axis will be very close to the patient's astigmatic axis when properly implanted.

Dr. Moshirfar says the rest of the case proceeds a little differently than with the non-toric ICL. "First, make sure you're 100-percent happy with the position of the lens," he advises. "In another words, do any rotation that you need to do first. Then, you can remove all the viscoelastic and bring the pupil down. The last thing you want to do is remove the viscoelastic, bring the pupil down and then do further axis alignment. This is in contrast to working with the non-toric ICL, where sometimes we'd remove some of the

*(continued on page 41)*



# Binocular Vision: Keeping It Together

New devices use the latest technology to evaluate and treat problems related to stereo visual acuity—and more.

*Christopher Kent, Senior Editor*

**O**phthalmologists spend much of their time helping patients maintain (or regain) excellent visual acuity. But good binocular vision requires more than just two eyes that see well; the input to both eyes must be successfully combined by our eyes and brain to create our experience of a three-dimensional environment. Sometimes the muscles controlling the eyes have difficulty accomplishing that, leading to double vision. Other times, even when we're successfully experiencing binocular vision, we pay a price for doing so because maintaining it requires an extraordinary amount of effort.

Here, doctors profile two new systems that can help to diagnose and manage problems tied to maintaining binocular vision.

## The Downside of Digital

The digital revolution we're living through has spawned a host of new devices that invite us to stare at screens. It was probably inevitable that this would lead to vision problems, because when the eye muscles and brain have to maintain a near fo-

cus for a long time, we can experience everything from headaches to dry eyes to shoulder and neck pain. Any of these can be misdiagnosed.

EyeBrain Medical, a company located in Costa Mesa, California, has created the Neurolens measurement device and contoured prism glasses to help solve this problem. According to the company, the average American adult spends more than nine hours a day using digital devices—with 70 percent of Americans using two or more devices at the same time. So it shouldn't be surprising that a huge percent of U.S. adults complain of headaches, neck/shoulder pain and eyestrain when using these devices.

How does stressing of the eyes and brain lead to these symptoms? According to EyeBrain, in addition to combining images in the face of ocular motor imbalances—a challenge in itself—the brain maintains a feedback loop with the extraocular muscles to keep the eyes aligned. The proprioceptive signals involved in that feedback loop are transmitted through the ophthalmic branch of the trigeminal nerve. When the visual system has to strain to compensate for

misalignment and/or disagreement between central and peripheral images, double vision may result; but even if double vision doesn't occur, the trigeminal nerve can still become overstimulated, leading to trigeminal dysphoria and triggering symptoms. The company claims that this is reflected in complaints reported during more than 17,000 eye exams. That data shows:

- 53 percent of eye-care patients complain of “tired eyes”;
- 50 percent experience neck pain or stiffness;
- 42 percent have discomfort at the computer;
- 42 percent are light sensitive;
- 37 percent have dry-eye symptoms;
- 36 percent complain of headaches; and
- 18 percent experience dizziness.

Fifty-six percent of patients present with at least three of these symptoms.

## Addressing the Problem

To help patients deal with this, two things are necessary: First, a device must be able to measure the extent

of the problem in a given individual. That's the purpose of the NeuroLens measurement device. Second, a visual aid—in this case, the NeuroLens glasses—must be customized to minimize or eliminate that person's specific problem.

Vance Thompson, MD, founder of Vance Thompson Vision in Sioux Falls, South Dakota, and a professor of ophthalmology at the University of South Dakota Sanford School of Medicine, became interested in this in the early 2000s. He explains how the NeuroLens device and glasses came about. "We always think about clarity of vision, but not the discomfort caused by poor eye alignment," he notes. "Ten years ago I had two patients, one post-LASIK and one post-cataract surgery, who felt so dry they were ready to scratch their eyeballs out. However, they had no signs of dry eye and no dry-eye therapy helped. Then, an optometrist colleague, Dr. Jeff Krall from Mitchell, South Dakota, who understood the disparity between central and peripheral vision, put a contoured prism in their glasses and their pain went away. The patients came back saying that their symptoms were gone when they wore the glasses.

"Dr. Krall then told me about A.E. Turville," he continues. "Dr. Turville described this phenomenon in the 1950s and developed the Turville Ophthalmometer for measuring the imbalance between central and peripheral binocular vision. Although his premise was right on the money, his device was clunky. So, we set out to develop a modern, automated device that could accomplish the same thing, measuring the discrepancy at both distance and near. That was the genesis of the NeuroLens system. We also noted that the need for prism is greater up close than at distance, so we patented an idea of Dr. Krall's: contoured prisms that have more power when the patient is reading at



Numerous seemingly unrelated physical symptoms may be related to eye alignment strain. The NeuroLens measuring device evaluates the patient's eye alignment at distance and near and prescribes specially designed lenses to compensate for both.

near. The prism gradually decreases as the patient shifts from working at close range to viewing at distance. Those glasses are now sold as NeuroLenses."

## How the System Works

According to the company, NeuroLenses are the only prescription lenses that use a contoured prism. Measurement of the degree of misalignment at both distance and near is accomplished with the NeuroLens eye-tracking device. Patients focus on a single point while a dynamic display of rotating planets and stars allow the device to evaluate peripheral and central vision, providing a comprehensive assessment of the patient's eye alignment and synchronization, accurate to one-hundredth of a diopter of prism. The results become the basis for the NeuroLens prescription.

The company says the process of treating the patient involves five steps. First, a Lifestyle Index questionnaire is administered to determine whether a patient is a potential candidate for the glasses. Second, if the patient is a candidate, he undergoes a three-minute NeuroLens measurement test to measure any misalignment prob-

lem at distance and near. Third, the doctor reviews the results with the patient, explaining trigeminal dysphoria and how it can lead to the symptoms the patient noted on the questionnaire. Fourth, appropriate lenses are ordered online through the company's ordering portal. Finally, after wearing the glasses for a few weeks, the patient is surveyed to make sure he or she has gotten relief. According to a survey conducted by the company 45 days after treatment, of 360 patients who received the NeuroLens glasses, 90 percent experienced symptom relief.<sup>1</sup>

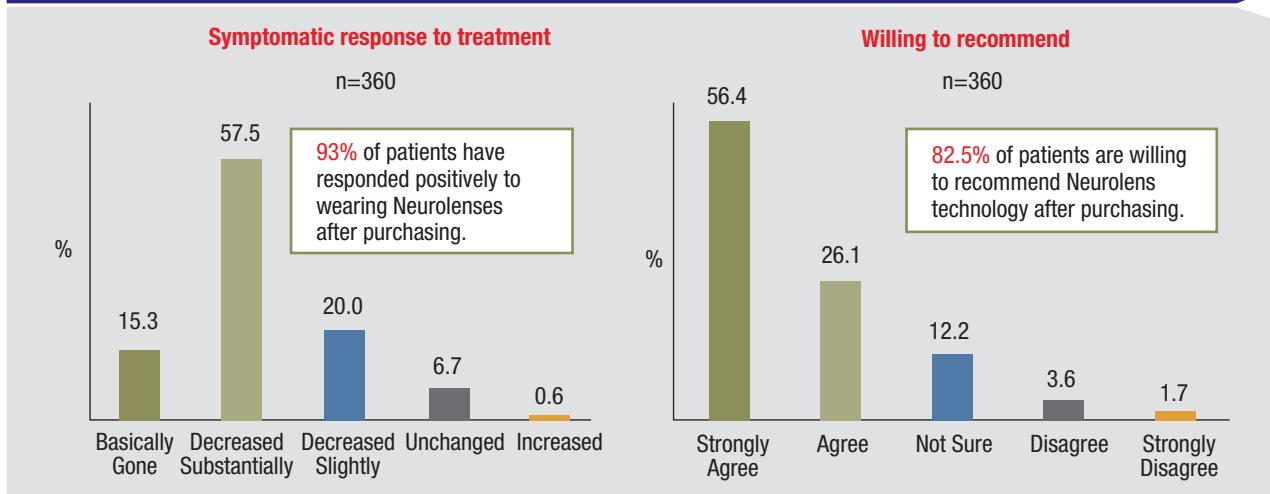
"Today, I consider this potential problem during every LASIK and cataract evaluation," says Dr. Thompson. "If the patient has dry eye, eyestrain symptoms or headaches that are out of line with the exam findings, this often explains it. For example, a surgeon came to me for cataract surgery; he noted that he couldn't do surgery for more than 10 minutes without getting headaches. We measured him and put him in contoured prism glasses, and he went right back to doing 10-hour cases.

"The headaches caused by this problem are hard to treat because the doctors treating these patients don't realize that a binocular visual issue is part of the problem," he adds. "This was well demonstrated when we took 160 of our local neurologist's toughest headache patients—people whose headaches truly made them miserable. We measured all of them for this vision problem and found that many of them did, in fact, have it. Those patients had a 90-percent favorable response to the contoured prism glasses."

## Using It in Practice

David C. Moline, OD, FAAO, a fellow of the American Academy of Optometry who's been in practice for more than 35 years, bought the first

## Patient Reactions to NeuroLens Treatment



commercially available NeuroLens measurement device just over a year ago, and has purchased another since then. (His practice is known for being an early adopter of new technologies.) “We’ve had a very good experience with the device and the NeuroLens glasses,” he says. “What’s fascinating is that this company has identified a subset of the population who have significant symptomatology relating to the overuse of digital devices, and this technology really does help them.”

Dr. Moline explains that all of his patients are given the questionnaire. “It asks whether the patient has headaches; stiff shoulders; difficulty working at the computer; tired eyes; and/or dry eyes,” he says. “We score patients from one to five. Anybody who has three or more of the symptoms is then tested with the measurement device to see what his eye misalignment is. The test takes three or four minutes to conduct, and it produces a printout with the amount of misalignment and a recommendation for the prescription. We’ve been able to incorporate this into our pretesting routine, so when our technicians look at the survey and see that a patient has three or more symptoms, they automatically run the test before the doctor sees the patient. It gives us a good idea of the

potential cause of their symptoms.

“I’d say that about 60 percent of our patients qualify to do the test,” he continues. “Of that group, about 20 percent are good candidates for the special lenses. So about 10 to 12 percent of our patients suffer these symptoms without understanding that misalignment is part of the problem. Those patients are helped significantly by these lenses.”

Dr. Moline says that patient responses range from instant relief to a gradual realization that the symptoms are gone after a month of adjusting to the contoured prism. “In some cases, you put these lenses on the patient and get an immediate, positive reaction,” he says. “Of course, that’s not always the case. Some patients put the lenses on and struggle for two to four weeks. They may experience dizziness or other symptoms as they get used to the contoured prism. Managing patients like this isn’t always easy; they sometimes need a lot of hand-holding. The company recently released a video of a skeptical patient who didn’t believe the glasses would help; in addition, she had a lot of difficulty adjusting to them. But after adjusting to them she forgot to wear them one day and her symptoms returned. Now she’s a believer.”

Dr. Moline says he tried them himself, even though he doesn’t have any of the symptoms listed in the questionnaire. “It took me a while to get accustomed to them,” he notes. “The lenses are progressives—which the company refers to as ‘contoured’—but when I tried switching back to my standard progressives with no prism, I discovered I wasn’t seeing as sharply or feeling as comfortable. I put the NeuroLenses on and my vision cleared up immediately. So even though I didn’t have any of the symptoms people complain about, the lenses still improved my vision.”

### Practical Benefits

Dr. Moline notes that the glasses are not inexpensive, but they do solve the problem for most patients and the glasses come with a money-back guarantee. “That’s how confident the company is that the lenses will help,” he says. “In fact, patients seldom ask for their money back. During the company’s three-year beta-testing period, about 10,000 glasses were sold. Of those 10,000 people, 85 percent said they’d recommend them to family and friends because of the reduction of symptoms. Furthermore, before I got involved with the product I spoke

new!

thera  
tears.

EXTRA

# HARNESS EXTRA POWER FROM A NATURAL WONDER

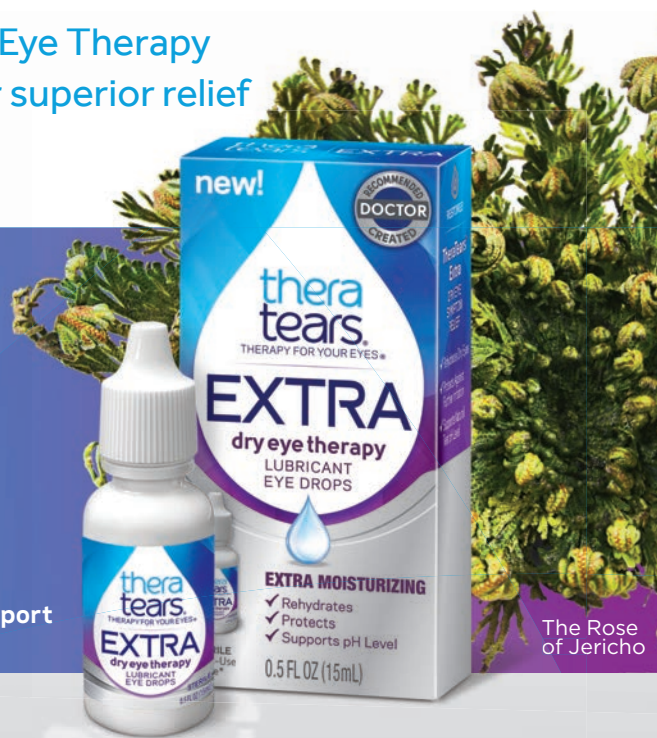NEW TheraTears® Extra Dry Eye Therapy  
is enhanced with trehalose for superior relief

Trehalose is a natural disaccharide found in plants with moisture retention properties that help organisms survive in absence of water. In ophthalmic products, trehalose enhances active ingredients to help<sup>1</sup>:

- Protect corneal cells from desiccation
- Restore osmotic balance to the ocular surface
- Maintain the homeostasis of corneal cells

-2017 DEWS II Report

Learn about our complete line of  
dry eye therapy products at [theratears.com](http://theratears.com)



The Rose  
of Jericho

Reference: 1. Jones L, Downie L, Korb D, et al. TFOS Dews II Management and Therapy Report. The Ocular Surface Jul 2017; 575-628.

© 2018 Akorn Consumer Health | A Division of Akorn, Inc. | M17-047

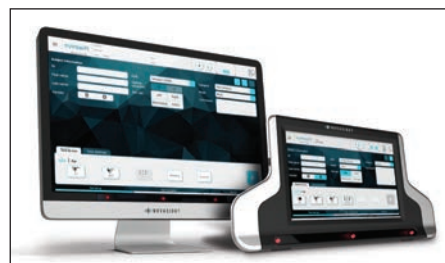to a doctor who was part of the beta testing who had sold 1,000 pairs of lenses. He said they'd given two refunds. So I tell my patients, if you buy the lenses and your symptoms get a lot better, you'll be happy. If you buy them and it doesn't seem to help, there's a 100-percent money-back policy." (Dr. Moline adds that he doesn't charge patients for conducting the test.)

Dr. Moline notes that all of this leads to another positive aspect of offering this technology: It's not covered by insurance. "This is a significant potential source of income," he points out. "The out-of-pocket for the patient can be as high as \$850 for the NeuroLens glasses, but again, that comes with a money-back guarantee, and if patients get relief, they're happy they spent the money. Meanwhile, you only need to treat a handful of patients per month to cover the cost of payments on a five-year lease of the device. So it's a source of revenue that's new and different, and in our experience very valuable." (The company declined to specify the cost to the doctor to purchase or lease the measurement device.)

Dr. Moline says the small company behind the system is constantly working to improve the technology. "Once in a while the measuring device has difficulty getting the readings, although for us that's only been the case in maybe one percent of the patients we test," he says. "They're also trying to improve how this concept is presented to the patient, so the patient understands what's going on. A month ago, for example, we received new marketing materials to help us explain to both staff and patients exactly what the system is doing."

### A Lot of Potential

Dr. Moline notes that being able to measure and treat this problem is something that was not previously



The EyeSwift system uses eyetracking to evaluate the vision of a child (or adult) while the subject watches an entertaining video. (See illustration, facing page.)

available to doctors. "The NeuroLens measurement gives us information that's different from what we've had for the past 30 years," he says. "It uses peripheral vision fusion cues that give a more real-life, accurate measurement than older measuring devices. Of course, we've had prism compensation for misalignment for years, but we never had a progressive lens that provides different compensation for distance and up-close in the same lens. That's new, and it's one of the biggest things about this product."

"As I mentioned, about 10 to 12 percent of patients benefit from this, and for a few of them, it changes their lives," he concludes. "They've suffered from these symptoms for a long time, with no one knowing why or how to fix it. It's exciting to have the chance to help them." For more information about the NeuroLens system, visit [neurolenses.com/eye-care/](http://neurolenses.com/eye-care/).

### Vision Assessment in Children

NovaSight, a small startup company in Israel, has created a novel vision-assessment system called Eyeswift, ideal for screening children for vision impairments ranging from poor visual acuity to strabismus. The company states that the Eyeswift system is designed to address children's unique needs and attention spans; it can detect multiple vision impairments in less than a minute.

The Eyeswift system comprises a pair of occludable LCD glasses that can be worn over prescription spec-

tacles, and a computer (either tablet or desktop). The wirelessly controlled glasses, which can fully occlude either eye digitally on command, and a 90 Hz eye-tracking system, monitor and record eye movements while the child watches an animated video. The system is designed to test visual acuity; visual resolution; stereo acuity; Worth's four dot test; eye motility; reading skill level; color vision; and contrast sensitivity. In addition, it can detect the presence of manifest or latent strabismus and vergence amplitude, important for detecting convergence insufficiency. After analysis, it provides a detailed report about the child's vision.

Tamara Wygnanski-Jaffe, MD, head of the pediatric ophthalmology and strabismus unit at the Goldschleger Eye Institute at the Sheba Medical Center at Tel Hashomer, Israel, has been using the system since August 2017. "The first version I used was a prototype," she explains. "The current version has software and hardware that are much easier to use; the test is shorter and easier to perform, and it's easier and more fun for the young children who take the test."

### Assessing Strabismus

"Although it's designed to assess many different visual parameters, I've worked primarily with the strabismus part of the system, both in clinical trials and in the clinic, detecting and measuring tropia and phoria," Dr. Wygnanski-Jaffe says. "That's its most

unique function. To do the strabismus test, the subject sits about 50 cm from the screen wearing the occluding glasses. The child fixates on a target, which quickly becomes a very entertaining animated movie, complete with audio. Then the device monitors the subject's eye usage to determine whether he or she has strabismus, and whether it's a tropia or a phoria."

Dr. Wagnanski-Jaffe explains that the first part of the test determines whether you have strabismus by occluding one eye and tracking the movement of the other eye to find out whether you have no deviation; a right- or left-eye deviation; or an alternating deviation. "The second part of the test determines what type of deviation you have and how big it is," she says. "In fact, that's one of the advantages of the Eyeswift system; it can also quantify the amount of strabismus.

"To accomplish this, it does what we would do in orthoptics: the alternate-cover test," she explains. "Here, it's done automatically by the computer; each eye is occluded for three seconds, five times, for a total of 30 seconds. Then the software calculates the gaze position of the eye and shifts the target to where the deviation will be larger, and it repeats this process for each eye until there's no eye movement. This allows the software to calculate the direction of the strabismus, its amplitude and the exact deviation. The strabismus test takes about 49 seconds, although in some cases it may take up to a minute."

Asked about some of the other tests the Eyeswift can do, Dr. Wagnanski-Jaffe says that it checks reading skill level by asking the subject to read an age-appropriate paragraph while monitoring the eye movements. "The system monitors how many fixations and regressions you have, your reading speed, and how long you spent reading each word," she explains. "This is a good test to do along with



the strabismus test, because kids with strabismus or amblyopia sometimes don't read as well as normal children. With both test results you might, for example, show the parents that the child has strabismus, and that's why he reads slowly. Or, the child has no strabismus but he's a poor reader, so you can suggest that the parents work with an educator to help improve his reading skills."

Dr. Wagnanski-Jaffe notes that the system can also test spatial resolution for young children, similar to what's called preferential looking, such as Teller acuity. "Small, pre-verbal kids can be shown a butterfly composed of stripes, to see if they follow the butterfly," she explains. "And when testing visual acuity, there's a feature where you just touch the computer tablet when you see the letter E or the number. You don't even have to be verbal to take that test. All of the tests are quick and repeatable, so this system can be used for both screening and diagnosis, and also for monitoring, if you see the patient at different times. You can have all of the data put up on a graph to see the condition improving or worsening over time. That can also be helpful for showing you the effect of surgery or glasses."

### Fast and Easy

Dr. Wagnanski-Jaffe says the biggest advantage of the Eyeswift system

is that it's very easy for the patient. "It's interesting, it's quick and it's repeatable," she notes. "Lots of kids like doing it, and it can also be used on adults. Another advantage is that it's very easy to operate—much easier than operating your smartphone! The software does everything automatically. A technician with very little experience and minimal training can run the tests. Then you can have someone else assess the results, or send them to a reading center, so you don't need a specialized team at your location."

Dr. Wagnanski-Jaffe points out that this is far easier and less expensive than the old methods for diagnosing strabismus. "For example, the cover test has been considered the gold-standard strabismus test," she says. "To do that test you need an orthoptist, optometrist or pediatric ophthalmologist. That test is great, but it's manual and time-consuming, and the equipment isn't universally available. It's very dependent on the examiner's skills, experience and level of attention, because if you want to see very small movements, you have to be very observant to detect them. There's also the expense of having someone qualified to conduct that test, and the problem of inter-examiner variability. These are not issues with the Eyeswift."

Dr. Wagnanski-Jaffe notes that other products have been developed by other companies in recent years with the same goal in mind. "Some of them had really good correlations with the gold-standard alternate cover test," she notes. "However, the equipment often doesn't fit young children, because you have to restrain the head and fit it into a machine where the subject can't move freely. Also, many of those devices require a fairly lengthy period of calibration that can strain the subject's head and neck. Some won't work if the subject wears glasses, and some of them can't dif-

*(continued on p. 66)*

# Topo-guided LASIK in Refractive Practice

*Christopher Kent, Senior Editor*

If you're willing to do the work, surgeons say your outcomes may be unprecedented.

**A**lthough the United States Food and Drug Administration has so far only approved limited uses for topography-guided LASIK—a technology that makes it possible to minimize or eliminate aberrations on the corneal surface—U.S. surgeons do have access to the technology. Available platforms include Alcon's Contoura Vision, which uses the Wavelight Topolyzer VARIO diagnostic device, proprietary treatment-planning software and either the Allegretto Wave Eye-Q or Wavelight EX500 Excimer Laser systems; NIDEK's EC-5000 Advanced Vision Excimer laser system (NAVEX), comprising the Quest M2/EC-5000CX, OPD-Scan III and Final Fit custom ablation software; and Johnson & Johnson Vision's iDESIGN Refractive Studio, which measures wavefront analysis and corneal topography and then combines them to generate a custom LASIK procedure for each patient.

The potential advantages of eliminating corneal aberrations are easy to understand, but the technology itself can be complex. Furthermore, today's non-topography-guided laser-ablation technology has become very sophisticated, leading many surgeons to wonder whether offering topography-guided ablation is worth the learning

curve required to master it—not to mention the time and effort required to use it on each patient. Here, surgeons with extensive experience using this approach share their opinions regarding its pros and cons.

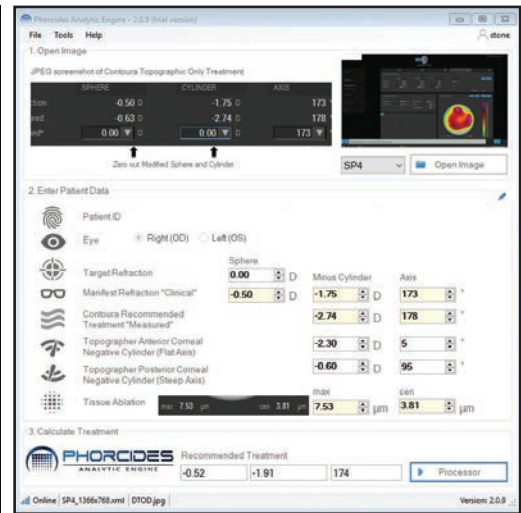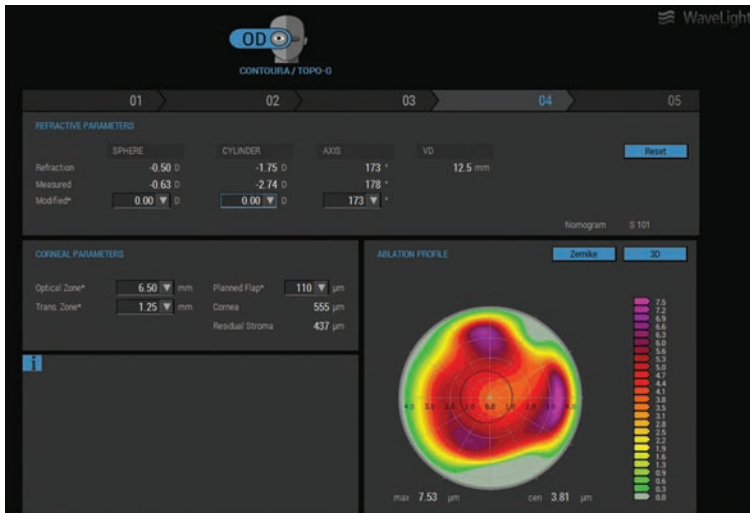## **Topo-guided LASIK: The Upside**

Surgeons who've used topography-guided technology agree that it can produce remarkable outcomes. However, they disagree about how many patients stand to benefit from this, as well as the value of this technology when its use is limited by the FDA.

A. John Kanellopoulos, MD, clinical professor of ophthalmology at NYU Medical School and medical director of the Laservision.gr Institute in Athens, Greece, has had extensive experience with topography-guided LASIK. "We've routinely used this technology in our clinical practice for more than 10 years now, to treat both myopia and hyperopia," he says. "We've also published extensively on this topic, discussing our work with what we call topography-modified refraction, or TMR. We use this approach nearly 100 percent of the time, as long as the topographies we obtain are consistent and accurate.

"Our results using this approach are the best we've ever seen," he contin-





One challenge surgeons using topography-guided ablation often face is conflicting astigmatism measurements—amount and/or axis—from topography and the manifest refraction. Above left: A patient whose amount of astigmatism on topography differs substantially from the manifest refraction. Above right: Phorides software uses vector analysis and mathematics to suggest treatments in these challenging cases. Beta surgeons are currently using this software in a controlled fashion to determine the best option for these patients.

ues. “Almost 75 percent of these patients are achieving 20/16 visual acuities, and 20 percent of them achieve 20/10. These are numbers we’ve never seen with any laser refractive procedure in the past, and many other clinicians have now reproduced these data. I think that most people who become familiar with this platform will see the tremendous potential that it offers, even in virgin eyes. And of course it’s an effective alternative for treating eyes that have had previous laser vision correction, or even radial keratotomy, although these uses are still off-label in the United States.”

Karl Stonecipher, MD, medical director for TLC Laser Eye Centers in Greensboro, North Carolina, and clinical associate professor of ophthalmology at the University of North Carolina, says his practice tries to use topography-guided LASIK on as many patients as possible. “This technology has increased our word-of-mouth referrals,” he says. “These patients see exceptionally well, and they notice the difference. In a recent study we published, we found a significant increase in 20/15-or-better vision favoring topography-guided LASIK over

wavefront optimized.<sup>1</sup> This technology gives us the best opportunity to make patients see better than they did previously with glasses or contact lenses.

“However,” he adds, “we’re limited by the current range of approval, so when treating patients who don’t fall within the topography-guided approved specs we do wavefront-optimized LASIK. We may also elect to do wavefront-optimized treatment in patients with thinner corneas, because that allows us to spare tissue and preserve corneal integrity.”

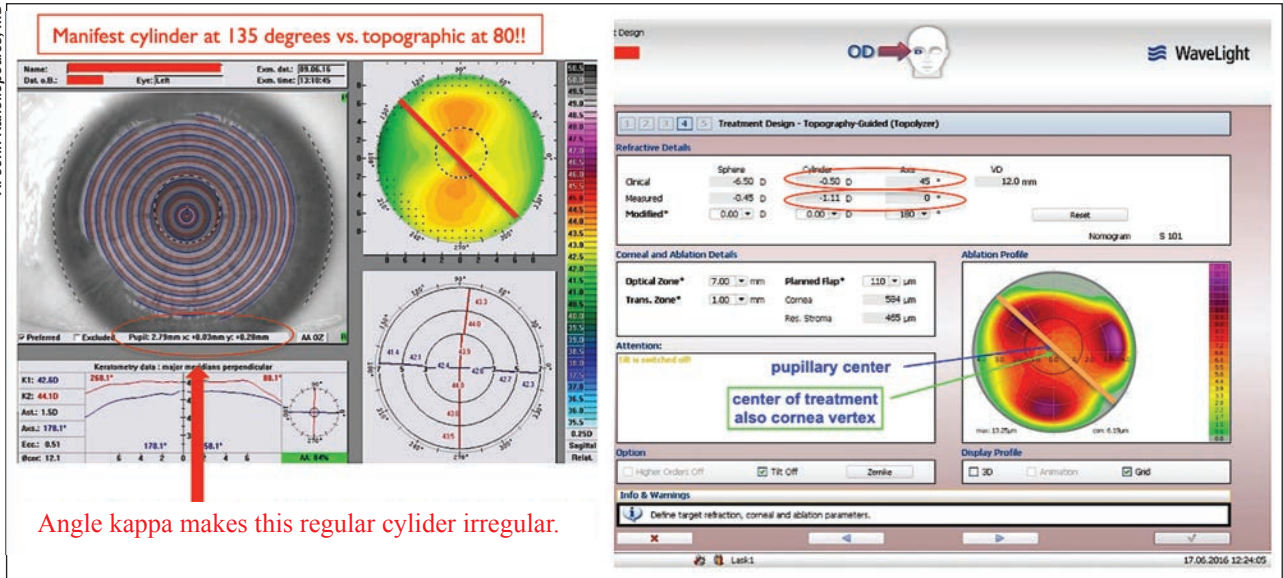
Dr. Kanellopoulos points out that how often you choose to use topography-guided LASIK on your patients depends partly on how high your bar is set for visual outcomes. “Most laser platforms today offer wavefront-optimized LASIK,” he says. “That technology produces excellent results, and most patients achieve 20/20. If your aim is simply to get your patients to 20/20, topography-guided LASIK may not impress you, as it requires more preoperative work and planning. This technology becomes pivotal, in my opinion, if you’re trying to pursue the best possible correction of the patient with the fewest possible future retreat-

ments. As a side effect, you also gain a better understanding of the patient’s optical and visual function.”

Dr. Kanellopoulos says that his experience supports the idea that any patient with repeatable topography readings can benefit from topography-guided LASIK. “If the patient has consistent topographies—meaning the epithelium is relatively untouched and the corneal topography maps are consistent—he stands to benefit considerably from this approach,” Dr. Kanellopoulos says. “The reason for this is that most patients actually have more astigmatism than you measure in the refraction. The slightest amount of angle kappa, i.e., more than 100 µm on the x and/or y axis, means that the eye is not seeing through the center of the astigmatic ‘bow tie,’ but slightly off-center. This causes refractive coma, so the correction the patient chooses is compensating for both the refractive error and the functional corneal coma. Topography-guided treatment can minimize or eliminate this coma.

“I think every potential patient who seeks laser vision correction is a good candidate for topography-guided LASIK or topography-guided PRK,”

A. John Kanellopoulos, MD



Angle kappa can cause a discrepancy between the cylinder measured by topography and clinical refraction. In the case above, there is significant angle kappa in the y-axis. The topography software measures -1.11 D of cylinder (measured line) at 180 degrees. In contrast, the clinical refraction finds -0.5 D of cylinder at 45 degrees. Adjusting the topography-guided ablation software to zero refractive correction shows that the software is attempting to normalize the cornea in regard to the cornea apex, in a trefoil pattern reminiscent of vertical coma. A possible explanation for the discrepancy in cylinder is that the patient himself “refracts” this corneal coma as cylinder, thus reducing and shifting the axis of the topographic cylinder found in the clinical refraction. The topography-modified refraction here will change the cylinder from -0.5 to -1 D and the axis from 45 to 0 degrees. The sphere will then be reduced from -6.5 D to -6.25 D to maintain the same spherical equivalent.

he concludes. “I believe trying this on a few patients will let any clinician see the superiority of this approach. In our experience, the only patients that don’t benefit from a topography-guided approach are patients who don’t have consistent topographies, meaning they don’t have four or five topographies that are very similar. In that situation, any data you choose to base the treatment upon may not be valid.”

### A More Conservative Approach

William I. Bond, MD, FACS, medical director at Bond Eye Associates in Peoria, Illinois, and an assistant clinical professor at the University of Illinois Medical School, was a principal investigator in the original trial that resulted in LASIK being approved in the United States, as well as an investigator in the original topography-guided LASIK trials. He says that, given the current approval status, he doesn’t use topography-guided LASIK too often.

“I’d hoped it would be available for treating irregular corneas,” he says. “Since wavefront-optimized technology is so robust for most corneas, and it’s a little time-consuming to evaluate the topography, I don’t use it very often. Using this technology requires having a technician who is very well-versed in getting the topographic data. There are some techniques and tricks for accomplishing this, and the manufacturers can help you with that. But most patients have very regular corneas that are easily treated without it. We probably only use it for 3 to 5 percent of our cases.

“However, if you can get good topographic images, you can do a very good job for people,” he says. “Although I don’t have the data to prove it, it’s been my clinical experience that we get a much higher rate of 20/15 and 20/10 outcomes when we do use the technology. And of course, it will be wonderful for treating patients with irregular corneas. Those are patients

we’ve been waiting for years to help. This technology can make a person very happy who would otherwise be borderline-happy.”

Dan Z. Reinstein, MD, adjunct professor of ophthalmology at Columbia University Medical Center in New York City and medical director at the London Vision Clinic in the United Kingdom, says he uses topography-guided treatments primarily only for therapeutic refractive surgery—i.e., to correct topographic irregular astigmatism (currently off-label in the United States). He says he wholeheartedly believes that every surgeon should have access to a topography-guided system, as well as a phototherapeutic keratectomy option, to use for therapeutic re-treatments.

“In an editorial in the *Journal of Refractive Surgery*,<sup>2</sup> I argued that laser manufacturers should be mandated to include—and the FDA should facilitate the inclusion of—topography-guided software as a standard option,

The OCULUS Pentacam® offers you  
a higher degree of safety!



Effective  
Preoperative  
Planning



Time Saving  
without  
Compromise



Easy  
Measurement  
Process



### Your Direct Route to Reliable Results

The Pentacam® is equipped with intuitive and user-friendly software features that help the physicians select the best refractive surgery option for the patient to ensure patient safety and optimal results. With a post-surgical scan, the precise corneal measurements allow you to detect rare post-op irregularities early. Surgical success is documented completely from start to finish.



Visit our booth #26 during the Telling It Like It Is meeting!

## Topography and Spherical Refraction

“A common mistake that surgeons new to this technology make is thinking that topography-guided treatment will give them the perfect outcome when combined with the clinical refraction,” notes A. John Kanellopoulos, MD, clinical professor of ophthalmology at NYU Medical School and medical director of the Laservision.gr Institute in Athens, Greece. “If there’s a significant amount of topographic correction, the refractive outcome will change. It won’t be what you’d expect if you had treated using wavefront-optimized technology. This is certainly true when correcting astigmatism; when we change the amount of astigmatism, an appropriate adjustment needs to be made to the spherical equivalent. If we decrease the astigmatism by a diopter, we’ll need to adjust the spherical correction to take this into account.”

Dr. Kanellopoulos points out that the clinician can see the amount of change that will be created by the topography-guided treatment by looking at the ablation plan with the amount of sphere and cylinder set to zero. “This will clearly show what the laser is going to do for that specific cornea in order to normalize it,” he says. “This will allow the clinician to adjust the spherical correction accordingly. If a clinician finds this type of adjustment daunting, it’s probably best to treat using a more familiar technology such as a wavefront-optimized procedure. If that patient has a problem in the future, you can refer the patient to an expert in topography-guided treatments to address it.”

—CK

rather than as an expensive add-on,” Dr. Reinstein says. “This would allow the few patients who suffer from visual disturbances to be treated. Topography-guided treatment, together with trans-epithelial PTK, provides the surgeon with the toolbox to improve overall patient outcomes, but most importantly, it enables the surgeon to help the rare but real patients who sustain visual complications.”

However, Dr. Reinstein says he doesn’t believe that topography-guided software should be marketed as being essential for the treatment of virgin eyes. “In my experience, about 95 percent of virgin eyes will derive little or no benefit from this technology because there’s very little irregularity in a normal cornea,” he says. “It could have a measurable benefit in some cases, but in other cases it could be detrimental. Most patients that do have ocular aberrations have neurally adapted to them, so they don’t experience loss of contrast or night-vision problems as a result of the nascent corneal aberrations. In addition, a major study done in 2001 showed that in

virgin, unoperated eyes, the first surface of the cornea and internal optics partially compensate for each other’s aberrations to produce an improved retinal image.<sup>3</sup> Treating corneal coma, for example, could actually unmask lenticular coma. It’s not always beneficial to remove corneal aberrations.”

### Obtaining Good-Quality Data

As with any refractive surgery, basing your treatment plan on accurate measurements—and astute analysis of the data—is crucial. These strategies will help when you’re gearing up for topography-guided surgery:

- **Don’t start doing treatments until you’ve done your homework.** “The best advice I can give to a surgeon who’s new to topography-guided treatments is that you absolutely must do a comprehensive corneal evaluation of the patient before planning your treatment, including epithelial thickness mapping,” says Dr. Reinstein. “Furthermore, be sure to consult with experienced colleagues and your laser-applications team on as many cases as

it takes to be comfortable planning the treatment yourself.

“Optimizing the refractive outcome can be challenging, for several reasons,” he continues. “For one thing, a manifest refraction only uses lower-order aberrations—i.e., sphere and cylinder—so higher-order aberrations such as coma and secondary astigmatism can be mistakenly interpreted as increased refractive cylinder. Much work is currently being done to understand how to optimally combine the manifest refraction and the corneal astigmatism/aberrations. Another source of refractive inaccuracy is the asymmetric epithelial remodeling that occurs following a custom ablation as the epithelium remodels to fit the new stromal surface. Taking the time to learn from surgeons who have experience with this technology, and then doing a thorough, comprehensive exam, can prevent refractive surprises.”

- **Give patients a full suite of testing before using topography-guided LASIK.** “To determine who would benefit from a topography-guided procedure you should perform topography, tomography, wavefront (corneal and whole-eye), and epithelial thickness mapping,” recommends Dr. Reinstein. “Because of the possible interaction of corneal and lenticular aberrations, it’s important to evaluate all of the aberrations of the eye’s optical system. In addition, the epithelial thickness map is crucial for understanding the stromal surface; that’s the only way to identify patients for whom a topography-guided treatment would be less effective.”

Dr. Stonecipher says that his technicians do all of the standard testing for laser vision correction when evaluating patients for topography-guided LASIK. “That includes screening for ocular surface disease,” he notes. “In addition, we do VARIO analysis using the WaveLight Topolyzer system, and we incorporate the Phorclides in-

tegration software created by Mark Lobanoff, MD. Phorcides is our current preferred software for choosing a treatment in these patients. It uses mathematical algorithms to fine-tune our treatment plan, and it appears to eliminate a lot of the ‘art’ of using this technology.”

Dr. Kanellopoulos says that when collecting the data, a careful refraction—and a careful analysis of that refraction—is a good start. “We use subjective measurements before and after cycloplegia, and a wavefront analyzer that takes additional refractive measurements,” he explains. “We also take axial length measurements with interferometry in order to correlate the length of the eye and corneal curvature with the manifest refraction. Careful topographic measurement of the eyes with an instrument such as Alcon’s WaveLight platform using the VARIO placido disc Topolyzer, will reveal the exact amount of corneal astigmatism and let the clinician know how consistent and reproducible the topographies are.”

• **Make sure you’ve obtained a high-quality topography scan.** “The topography scan is the most important part of the treatment, as this data defines the ablation made to the cornea,” notes Dr. Reinstein. To ensure that the data is good:

— *Be sure the cornea is healthy before obtaining topographic data.* “Contact lens warpage and ocular surface disease must be eliminated prior to analyzing the patients with the VARIO device,” says Dr. Stonecipher. “Fortunately, diagnosis and treatment of ocular surface disease is becoming more mainstream. Just make sure that the patient understands the reasons for eliminating their contact lens use prior to surgery.”

— *Check that the scans were properly focused and well centered, i.e., that the patient was looking at the target.* “Centration is crucial,” Dr. Reinstein notes.

— *Confirm that the mires are smooth and regular.* “If they’re irregular, use lubricating drops and repeat the exam,” says Dr. Reinstein.

— *Perform multiple scans to satisfy yourself that any irregularity you’re treating is repeatable.* “The ablation algorithm cannot differentiate between a true irregularity and an artifact in the data,” Dr. Reinstein points out.

“Be sure the ablation is being done where it should be .... Steep areas on placido topography are generally assumed to represent an elevation, but they can sometimes actually be a depression.”

— *Dan Z. Reinstein, MD*

— *Select the scan that has the largest area of continuous data.* “Pay particular attention to the superior region,” says Dr. Reinstein. “Data acquisition in that area is often limited by the eyelid.”

## Adjusting the Ablation Profile

Dr. Reinstein notes that once the topography scan you’ve chosen has been imported into the laser and an ablation profile has been generated, you may need to make adjustments to different aspects of the profile. In that situation:

• **Confirm that the ablation profile makes sense with respect to the diagnostic scans.** “In other words, be sure that the ablation is being done where it should be,” says Dr. Reinstein. “For example, pay careful atten-

tion to steep areas on placido topography. These are generally assumed to represent an elevation, but they can sometimes actually be a depression. It’s possible for the algorithm to misinterpret these, so this data must be cross-checked with elevation-based tomography.”

• **Check the centration.** “This is the most important part of the ablation profile calculation,” says Dr. Reinstein. “The placido topography scan, and most tomography scans, are centered on the corneal vertex, and the ablation profile has been generated centered on the corneal vertex. So, the ablation should be performed on the corneal vertex. Some systems have the corneal vertex location integrated into the ablation profile, but if not, the surgeon should manually center the ablation on the coaxially sighted corneal light reflex. It should not be centered on the entrance pupil unless the topography and tomography data are also centered on the entrance pupil.”

• **Optimize the optical zone.** “Because one of the goals of a topography-guided treatment is to optimize the optical zone, you’ll usually want to treat a large optical zone,” Dr. Reinstein says. “However, if you’re treating a patient [off-label] who’s had previous refractive surgery, a smaller optical zone may need to be used due to tissue constraints. In that situation, the best way to determine 3-D flap anatomy and residual stromal tissue reserves is with very high frequency (VHF) digital ultrasound scanning. As a second alternative, taking point measurements here and there is possible with most corneal-designed OCT devices.”

• **If necessary, adjust the refraction.** “The manifest refraction can be entered to simultaneously treat an expected residual prescription, although sometimes this is limited by tissue constraints,” explains Dr. Reinstein. “Most systems include an algorithm to take into account the refractive effect

of the planned change in topography. Nevertheless, you may still experience refractive surprises. This is largely due to fact that the epithelial thickness profile is not currently taken into account.”

• **Consider the depth of the ablation.** “Outside of the United States, many therapeutic patients have had multiple procedures,” notes Dr. Reinstein. “As a result, there may be limited tissue available. Some systems allow the ablation profile to be shifted down, so that the total ablation depth is smaller, but some irregularities in the profile may still remain.”

• **Consider an off-label PTK.** “Some systems allow a PTK ablation to be performed as part of the same procedure [off-label], so that these can be done as a single ablation,” says Dr. Reinstein. “For example, a trans-epithelial PTK ablation can be performed to target irregularities masked by the epithelium, while the topography-guided ablation targets those detectable on topography.”

Dr. Kanellopoulos adds one other consideration: It’s important to compare the topographic and refraction-based astigmatic data. “The corneal and refractive astigmatic data may not be identical,” he explains. “In that situation, if you’re using topography-guided LASIK, you can decide whether to blend the corneal and clinical refraction data, modifying the treatment amount and axis of astigmatism based on the topographic data. (See example, p. 26.) On rare occasions you may find that you also need to account for posterior corneal astigmatism, but this is seldom an issue.”

### A Caveat ...

Dr. Reinstein notes one other point that he’s learned over the years, relating to the currently off-label use of this technology to treat abnormal and post-refractive-surgery eyes (something many American surgeons are ea-

ger to try). “Don’t use this technology to try to correct irregularly irregular astigmatism, such as localized, focal irregularity on the stromal surface,” he says. “If you’re using topography-guided treatments to address an eye with astigmatism, it works best for regularly irregular astigmatism. That would include enlarging a small optical zone or recentering a decentered optical zone. These patients experience a significant improvement in visual quality from a topography-guided retreatment.”<sup>4,5</sup>

“The reason for this distinction is that the epithelium acts to compensate for irregularities on the stromal surface,” he explains. “This is driven by the curvature gradient of the stromal surface, so when the irregularities are localized, the amount of masking is greater.”<sup>6-8</sup> In these cases the majority of the stromal irregularity is hidden from front-surface topography. As a result, performing a topography-guided treatment will be minimally effective, and may actually make the patient worse.<sup>9</sup> For this reason, getting an epithelial thickness map is crucial for understanding the stromal surface. It’s the only way of identifying patients in whom a topography-guided treatment would be less effective.”

### A Challenge Worth Accepting

Dr. Kanellopoulos points out that there are plenty of opportunities to get help mastering topography-guided ablation. “Maximizing vision with this technology can be complicated,” he says. “I’ve had the honor of chairing and working alongside several other world-recognized topography-guided surgery ‘aficionados’ to offer courses on this subject just prior to all of the major meetings in the past three years. In these courses we spend a full eight hours going through sample cases step-by-step, helping clinicians become familiar with all of the parameters involved in using this technology and allowing them to design treat-

ments on their own. In addition to those courses, I would invite anybody who is interested in this to visit the pertinent website [topo/guided.com](http://topo/guided.com).”

Dr. Bond says he hopes surgeons won’t be afraid to use this technology. “It’s a little more time-consuming to do the evaluations, but once that’s done it’s pretty rewarding,” he says. “You’ll get some word-of-mouth and you’ll be known as the guy who can do this type of treatment. Patients always expect to be happy and do well, and that’s not a problem when treating the easy patients. However, getting good vision for some patients is a different world. That’s where this technology can really help.” **REVIEW**

*Dr. Kanellopoulos is a consultant for WaveLight, Alcon, iOptics and Avedro. Dr. Bond is a consultant to Alcon Laboratories and WaveLight. Dr. Stonecipher is a consultant for Alcon. Dr. Reinstein is a consultant to Carl Zeiss Meditec and has a financial interest in ArcScan, producer of the Insight 100, a VHF digital ultrasound scanner.*

1. Stonecipher K, Parrish J, Stonecipher M. Comparing wavefront-optimized, wavefront-guided and topography-guided laser vision correction: clinical outcomes using an objective decision tree. *Curr Opin Ophthalmol* 2018;29:4:277–285.
2. Reinstein DZ. Therapeutic refractive surgery: State of technology and a call to action. *J Refract Surg*. 2018;34:294-295.
3. Artal P, Guirao A, Berrio E, Williams DR. Compensation of corneal aberrations by the internal optics in the human eye. *J Vis*. 2001;1:1-8.
4. Reinstein DZ, Archer TJ, Carp GI, Stuart AJ, Rowe EL, Nesbit A, Moore T. Incidence and outcomes of optical zone enlargement and recenteration after previous myopic LASIK by topography-guided custom ablation. *J Refract Surg*. 2018;34:121-130.
5. Reinstein DZ, Archer TJ, Gobbe M. Combined corneal topography and corneal wavefront data in the treatment of corneal irregularity and refractive error in LASIK or PRK using the Carl Zeiss Meditec MEL80 and CRS Master. *J Refract Surg*. 2009;25:503-515.
6. Reinstein DZ, Archer TJ, Dickeson ZI, Gobbe M. Trans-epithelial phototherapeutic keratectomy protocol for treating irregular astigmatism based on population epithelial thickness measurements by Artemis very high-frequency digital ultrasound. *J Refract Surg*. 2014;30:380-387.
7. Reinstein DZ, Archer TJ, Gobbe M. Rate of change of curvature of the corneal stromal surface drives epithelial compensatory changes and remodeling. *J Refract Surg*. 2014;30:800-802.
8. Vinciguerra P, Azzolini C, Vinciguerra R. Corneal curvature gradient determines corneal healing process and epithelial behavior. *J Refract Surg*. 2015;31:281-282.
9. Reinstein DZ, Archer TJ, Gobbe M. Improved effectiveness of trans-epithelial phototherapeutic keratectomy versus topography-guided ablation degraded by epithelial compensation on irregular stromal surfaces [plus video]. *J Refract Surg*. 2013;29:526-533.

COMING 2019

Open your eyes to  
what's on the  
horizon in dry eye.

Sign up for updates at [TearCare.com](https://www.tearcare.com)

TearCare is indicated for the application of localized heat when the current medical community recommends the application of a warm compress to the eyelids. Such applications would include Meibomian Gland Dysfunction (MGD), Dry Eye, or Blepharitis.

©2018 Sight Sciences. All rights reserved. 06221.A



15

Point-Counterpoint: SMILE vs. LASIK

# A SMILE is My Greatest Asset

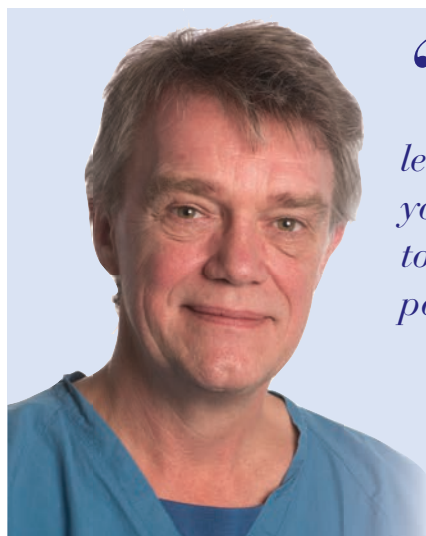
*Jesper Hjortdal, MD, PhD  
Aarhus, Denmark*

In life, when you find something that works, you stick with it. Maybe it's a restaurant that never fails to deliver a good meal, or an automobile brand that's never let you down. For me, it's the SMILE procedure. For several years now, SMILE has been the predominant refractive procedure in my practice, comprising 98 percent of our surgeries. We've chosen it simply because of its great outcomes and good safety profile, even when compared to LASIK. Here, I'll tell you what we like so much about it.

## SMILE: The Benefits

From the surgery itself through the postop period, small-incision lenticule extraction has many things to recommend it:

- **Fewer variables.** Air quality. Temperature. Humidity. Tears. BSS irrigation. All of these variables come into play when you're performing LASIK, and they can negatively affect your refractive outcome.<sup>1</sup> With the SMILE procedure, however, they don't matter nearly as much. This simplifies the procedure for the surgeon so he can focus on the things that do matter. With SMILE, you simply dock the laser with the suction ring, activate the suction and let the femtosecond laser perform the photodisruption in the



*“Since SMILE involves directly cutting a lenticule within the cornea, you have the opportunity to achieve better optics postoperatively.”*

cornea independent of these factors.

- **Potential optical benefits.** Since SMILE involves directly cutting a lenticule within the cornea, you have the opportunity to achieve better optics postoperatively. In excimer-laser surgery, however, there's some eccentricity to the ablation when the laser hits peripheral positions, and this eccentricity can affect the refractive outcome. SMILE directly cuts the tissue because you've drawn the cornea into the patient interface; therefore, in theory, you have a more reproducible lenticule removal.

In terms of postop vision, in the FDA trial of SMILE, none of the 328

patients saw 20/40 or better uncorrected preop. At the six-month visit, however, 98 percent (327 eyes) and 88 percent (287 eyes) saw 20/40 or better and saw 20/20 or better, respectively. Results at the 12-month follow-up were similar. The manifest refraction spherical equivalent was within  $\pm 1$  D of target in 98 percent of eyes. No fewer than 79 percent of eyes were within  $\pm 0.25$  D, and 92 percent were within  $\pm 0.5$  D of target from one week to 12-months postop.<sup>2</sup>

- **Preservation of corneal nerves.** With SMILE, the incision is smaller than LASIK's; creating a LASIK flap

*(Continued on page 34)*



## Point-Counterpoint: SMILE vs. LASIK

# LASIK: The Clear Choice

*Steven Wilson, MD  
Cleveland*

Often, when a difficult problem is finally solved, it turns out that the solution isn't only effective—it's elegant as well, unburdened by unnecessary complexity. For the problem of refractive errors, LASIK remains the most elegant solution, in addition to being very safe and effective. This is why SMILE's overly complicated approach to treating refractive errors falls short in comparison. Here, I'll explain why I choose LASIK for my refractive patients.

### SMILE's Shortcomings

Before I delve into the reasons why SMILE isn't as good as LASIK, I want to say that I'm a big fan of the Zeiss VisuMax laser, and it's my favorite flap-making laser for LASIK procedures.

That said, I'm not a fan of SMILE. I've come to this opinion by monitoring the ophthalmic literature since the procedure was first released. Also, we have the VisuMax in our facility, and one of my partners has been performing SMILE for a couple of years, so I've observed the procedure's results. Here are the issues with SMILE that I've noticed.

- **It's more difficult to do.** The first, and one of the more important, things I've noticed through this observation is that LASIK is a much sim-



pler procedure than SMILE. Because of SMILE's complexity, you're much more likely to end up with a problem during surgery. There were even some papers published about how to handle retained lenticules that were either not fully cut by the laser or were torn during the extraction process, trapping a lenticule fragment within the interface. This fragment then has to be removed or the patient will have severe irregular astigmatism. This increased difficulty is one of my major concerns as SMILE seeks acceptance among a wider audience of ophthalmologists.

- **SMILE cuts introduce vari-**

**ability.** Another one of the major differences between the two procedures is that, when you make a cut with the femtosecond, no two cuts are the same. I've used the IntraLase, the Alcon LenSx and the VisuMax, and they all have this issue; when you cut across the cornea to make the LASIK flap, they can skip a spot here or there in a random way or produce other small imperfections. So, when you lift the flap, you notice slight irregularity in the bed. LASIK, however, is very forgiving of this, because as long as you return the flap to its original position, those irregularities are

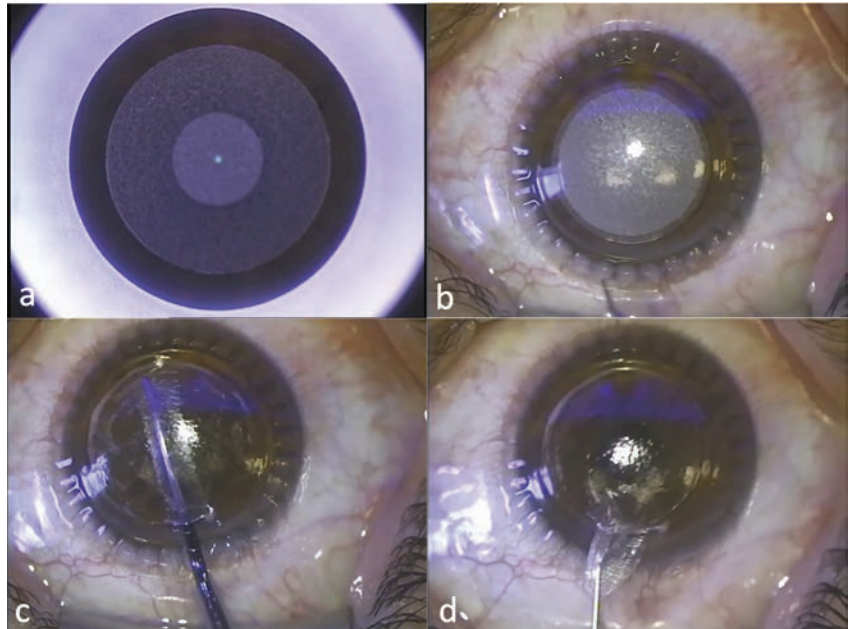
*(Continued on page 34)*

**A SMILE is My Greatest Asset**

*(Continued from page 32)*

involves a large incision that extends almost around the entire cornea. This large incision has the potential to influence, for a while at least, the sensitivity of the cornea—especially the nerves in the anterior cornea. In SMILE, however, the patient has better corneal sensitivity postop and less of a reduction in reflex tearing.

Though we haven't compared SMILE directly to LASIK, we did perform a study comparing it with femtosecond refractive lenticule extraction—FLEX—which involves creating a full flap similar to a LASIK flap while creating a lenticule. We performed SMILE in one eye and FLEX in the fellow eye. When we subsequently measured sensitivity and measured corneal nerve endings using confocal microscopy, after six months we found that SMILE has an advantage in terms



Steps of SMILE. A: The posterior refractive side of the lenticule has been cut and the cap-cut is almost half done. B: Immediately after completion of the lenticule cut by the femtosecond laser. C: Manual dissection of the anterior and posterior side of the lenticule. D: The intrastromal lenticule is being removed with forceps.

*(Continued on page 36)*

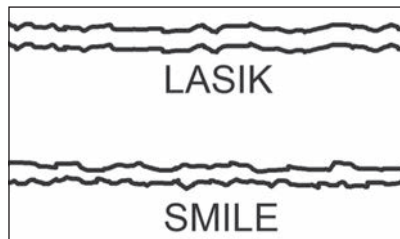
**LASIK: The Clear Choice**

*(Continued from page 33)*

masked and not reflected in the optical surface. Therefore, they don't affect the patient's vision.

When you make the two femtosecond cuts necessary to create the lenticule in SMILE, however, you now have two femtosecond-cut surfaces that no longer match up. Then, when you extract that piece of cornea and the two mismatched surfaces are pressed together, they don't match. That's what produces the irregularities that result in patients having a delayed visual recovery with SMILE compared to LASIK (LASIK patients see clearly almost immediately, compared to a several-day delay with SMILE reported in several studies).

• **More manipulation, more irregularities.** It's not just the laser cuts that introduce vision-affecting irregularities, it's the extra mechanical ma-



The reason SMILE patients take longer than LASIK patients to recover vision, Dr. Wilson says, is because the interfaces in SMILE don't line up when the lenticule is removed, resulting in irregularities.

nipulation, as well: Once the lenticule is cut by the two laser passes, you still don't have a free lenticule. Instead, you now have to use a second instrument in the interface, a spatula, both anterior and posterior to the lenticule, to physically break the remaining adhesions between the lenticule and surrounding cornea. By doing that, you induce even more irregularity.

• **The femtosecond is less precise than the excimer.** Piggybacking on

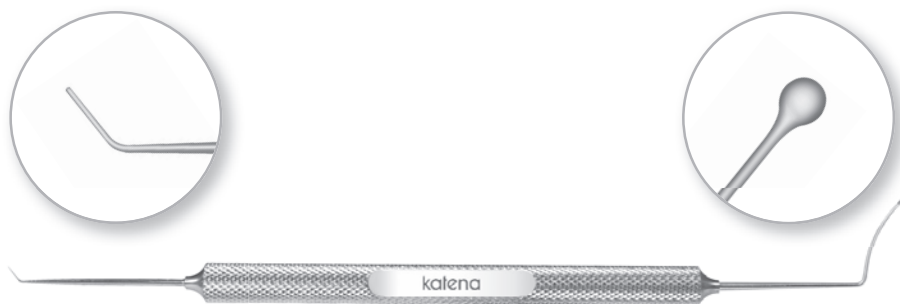the previous points, Zeiss will probably say that it has a new spot distribution coming out that will help with the problem of the surface irregularities—and it might—but the irregularities will still be a problem, even with a new spot distribution. Why? Because the femtosecond just doesn't have the inherent accuracy and precision of an excimer laser: The original IBM researchers who studied the early excimer lasers actually used one to carve the IBM logo onto a human hair—no femtosecond laser will ever match that precision. As a result, SMILE will always have a slower visual recovery, and much less of a “wow” factor, than LASIK.

• **Enhancement questions.** The flip side to the elegant solution referenced earlier is the problem with multiple solutions; this usually means none of them is ideal. This is the current situation with SMILE enhance-

*(Continued on page 36)*

# SMILE Instruments

Small Incision Lenticule Extraction is quickly gaining popularity with surgeons around the world. The procedure provides unprecedented accuracy in vision correction without the creation of a flap, thereby reducing flap-related and dry eye complications.



**K3-2542** SMILE Spatula

This double-ended instrument was designed specifically for SMILE procedures. One end features a 3mm long spatula, set at a 45° angle, with a blunt conical tip. It is used to identify the wound site and to begin the dissection of the laser created intrastromal tunnel. The opposite end features a beveled disc-shaped distal tip with a flat posterior surface. This end is used to complete the dissection of the tunnel as well as both the anterior and posterior surfaces of the lenticule.



**K5-5062** Mendez SMILE Forceps

Once the lenticule has been completely dissected, the tips of this forceps are used to reach, grasp and remove the tissue. According to Dr. Mendez, "Its atraumatic profile, round front and sides allows for easy access even in 2mm incisions. The large grasping surfaces firmly hold the lenticule without the risk of tearing it. The forceps open side-to-side as to prevent stretching and stress to the cap".

Designed by Antonio Mendez, M.D. of Tijuana, Mexico

Mendez SMILE Procedure



## A SMILE is My Greatest Asset

(Continued from page 34)

of better preservation of nerves and less of a reduction in corneal sensitivity. We didn't find a change in the composition or quantity of the tears.<sup>3</sup>

- **Retained corneal strength.** Also, in theory, since you create a corneal cap in SMILE—not a flap as in LASIK—this should result in a stronger corneal stroma postop. Over the long term, having a small incision rather than a flap reduces the risk of flap slippage if the patient suffers even a small ocular trauma, because flaps can be dislocated even years postop. In a contralateral-eye study in which I participated (N: 10 eyes of five patients), we found that flap-based lenticule extraction produced a 49 percent greater reduc-

tion (range: 2 to 87 percent) in effective stromal collagen fiber stiffness within the flap region than SMILE procedures in the patients' fellow eyes. There were also lower stresses and deformations in the residual stromal bed in the SMILE cases, and stromal bed displacements and stresses were more affected by a loading increase in eyes with flaps than in the flapless ones.<sup>4</sup> SMILE also helps avoid—but doesn't eliminate—one of the most dreaded complications associated with LASIK: ectasia.

## Responding to Criticisms

Over the past year or so, some surgeons have leveled criticisms at the SMILE procedure. However, these issues aren't as significant as they're

made out to be:

- **SMILE is too difficult.** Some surgeons say that working with the SMILE lenticule is much more technically difficult than performing the steps involved with LASIK. Though working with the lenticule is more involved than cutting and lifting a flap, LASIK still has a learning curve of its own. Also, after you've performed some SMILE procedures and gotten comfortable with it, you'll appreciate benefits such as better corneal sensation, stronger corneal structure and excellent predictability, even at high levels of correction.

- **Enhancements are a problem.** Enhancements haven't really been an issue for us due to the procedure's high accuracy, at least in our hands. We haven't had to do one in the past year.

## LASIK: The Clear Choice

(Continued from page 34)

ments.

LASIK is very easy to enhance. If you perform the enhancement within the first postop year, you can lift the flap without much difficulty and apply additional excimer laser to fine-tune an under- or overcorrection, or treat a little induced astigmatism. With SMILE, though, no one has agreed on the best way to perform a retreatment if the primary procedure gets an undesirable result. You either have to do a surface ablation or try to convert the SMILE to a LASIK, and the company's actually designed an algorithm to do that. At our facility, we found the SMILE enhancement rate to be higher than LASIK's, because it's just not as precise. There's also the impression a patient gets if he needs an enhancement: Preop, the patient was no doubt told the purported advantages of SMILE over PRK and LASIK, only to find out that, six months later, he needs PRK or LASIK to correct his SMILE procedure that came up short.



Unmatched precision: The excimer laser was once used to carve the IBM company logo onto a human hair. The femtosecond is incapable of such feats, Dr. Wilson says.

This isn't an enjoyable conversation to have.

- **SMILE takes more time to do.** With all the tissue manipulation involved with SMILE, it ends up taking twice as long as LASIK. This is the last thing a busy surgeon wants to hear. Adding that extra surgery time is a very big deal for the refractive surgeon, because you only have so many surgery slots during a day. If you're occupying two spots instead of one, you

cut down on your productivity, and productivity is a big part of having a successful refractive practice.

- **SMILE misses out on surgical advances.** About 10 years ago, every other paper presented at the AAO and ASCRS was about the importance of wavefront-driven ablations in LASIK and their ability to reduce visual aberrations. More recently, companies like Alcon have introduced topography-driven ablations and highlighted

If an enhancement is required though, it's not an insurmountable obstacle. If we ever need to enhance a SMILE, our procedure of choice is a PRK procedure on top of the cap with adjunctive use of mitomycin-C. Zeiss has also developed a SMILE enhancement procedure known as CIRCLE, in which you convert the SMILE cap into a flap and then use the excimer laser to ablate the stromal tissue.

In a retrospective study of surface ablation enhancement after SMILE, surgeons performed PRK on 43 eyes out of 1,963 SMILE cases (2.2 percent). Spherical equivalent was  $-6.35 \pm 1.31$  D before SMILE and  $-0.86 \pm 0.43$  D before the PRK. Surface ablation was performed after a mean of  $9.82 \pm 5.27$  months, and resulted in a spherical equivalent of  $0.03 \pm 0.57$  D at

three months ( $p < 0.0001$ ). The number of patients within  $\pm 0.5$  and  $\pm 1$  D of their target refraction respectively increased from 23 percent to 80 percent and from 73 percent to 93 percent. In these 43 enhancement eyes, mean uncorrected distance acuity improved from  $0.23 \pm 0.20$  logMAR (a little worse than 20/32) to  $0.08 \pm 0.15$  logMAR (about 20/20) ( $p < 0.0001$ ). The average best-corrected acuity remained unchanged overall ( $p = 0.99$ ), with 65 percent of patients gaining at least a line. Six eyes (15 percent) lost a line of BCVA, but the final BCVA was 20/20 in four of these cases and 20/25 in the other two.<sup>5</sup>

Ultimately, for us, SMILE is the effective, safe procedure we've relied on for the vast majority of cases for several years and, at this point, it's hard to ar-

gue with 3,000 happy patients. **REVIEW**

*Dr. Hjortdal is a consultant and clinical professor of ophthalmology at Aarhus University Hospital in Denmark and medical director of the Danish Cornea Bank. Aarhus University Hospital has specified research support agreements with Carl Zeiss Meditec.*

1. Walter KA, Stevenson AW. Effect of environmental factors on myopic LASIK enhancement rates. *J Cataract Refract Surg* 2004;30:4:798-803.
2. Summary of safety and effectiveness from the SMILE FDA trial. [https://www.accessdata.fda.gov/cdrh\\_docs/pdf15/P150040B.pdf](https://www.accessdata.fda.gov/cdrh_docs/pdf15/P150040B.pdf). Accessed 5 January 2019.
3. Vestergaard AH, Grønbech KT, Grauslund J, Ivarsen AR, Hjortdal JØ. Subbasal nerve morphology, corneal sensation, and tear film evaluation after refractive femtosecond laser lenticule extraction. *Graefes Arch Clin Exp Ophthalmol*. 2013;251:11:2591-600.
4. Seven I, Vahdati A, Pedersen IB, et al. Contralateral eye comparison of SMILE and flap-based corneal refractive surgery: Computational analysis of biomechanical impact. *J Refract Surg* 2017;33:7:444-453.
5. Siedlecki J, Luft N, Kook D. Enhancement after myopic small incision lenticule extraction (SMILE) using surface ablation. *J Refract Surg* 2017;33:8:513-518.

some of the better results that can be achieved with that technology. Unfortunately, you can't use either of these approaches with SMILE. So are we suddenly saying that all of that development wasn't important? On the contrary: Eighty percent of my LASIK patients have wavefront-driven ablations done with the excimer laser.

• **There's still ectasia with SMILE.** One of the advantages touted for SMILE is biomechanical superiority compared to LASIK, with proponents specifically saying it leaves the anterior cornea basically untouched. This, they say, makes it less likely for patients who have abnormal corneal topography or thin corneas to develop ectasia after SMILE vs. LASIK for the same level of myopia correction. However, there are now several papers from surgeons who've used SMILE in place of LASIK for these questionable cases that subsequently developed ectasia.<sup>1</sup> Though, theoretically, there may be some biomechanical advantage to SMILE, someone performing the procedure has to be very careful about assuming he's going

to have an advantage in treating those cases with inferior steepening or low corneal thickness, because it could be a trap. Surgeons now recommend using the same screening criteria for SMILE as LASIK when it comes to ectasia risk.

The other biomechanical argument is that there's no risk of postop flap dislocation with SMILE. Theoretically, this is the case. However, I've only encountered one dislocated flap in the 23 years I've been doing LASIK. The large-scale data from the military supports this, as the service now allows soldiers and sailors to undergo LASIK due to the real incidence of late flap dislocations being so low.<sup>2,3</sup> In theory, a flap could be truncated by a severe enough blow, such as a car's airbag deploying, but typically that sort of force would be so powerful that it would risk damage to the cornea even if the patient had had SMILE, or no surgery at all.

• **Dry-eye considerations.** Though it may be true that there's less dry eye with SMILE than LASIK, I think that given the thin flaps used with today's

LASIK procedure, we don't have as much of a dry-eye problem as we did in the past. This is especially true if we pretreat patients prior to LASIK with medications like Restasis and other measures—which you'd want to do anyway with SMILE. In my practice, where I do a lot of LASIK and PRK, dry eye isn't that much of an issue when appropriate precautions are taken.

So, considering all of the reasons listed above, as well as the great outcomes my patients enjoy after LASIK, I'm confident in choosing it over the newcomer, SMILE. **REVIEW**

*Dr. Wilson is a professor of ophthalmology, director of corneal research, as well as the staff of the refractive surgery and cornea sections of the Cleveland Clinic's Cole Eye Institute.*

1. Moshirfar M, Albarracín JC, Desautels JD, Birdsong OC, Linn SH, Hoopes PC Sr. Ectasia following small-incision lenticule extraction (SMILE): A review of the literature. *Clin Ophthalmol* 2017;15:11:1683-1688.
2. Tanzer DJ, Brunstetter T, Zeber R. Laser in situ keratomileusis in United States naval aviators. *J Cataract Refract Surg* 2013 Jul;39:7:1047-58.
3. Warfighter Refractive Eye Surgery Program Overview. <https://www.crdamc.amedd.army.mil/surgery/lasik.aspx>. Accessed 10 January 2019.

# Will We Ever Cure Dry Eye?

*Michelle Stephenson, Contributing Editor*

Many new therapies are being researched as treatment options for this complex condition.

According to the Tear Film and Ocular Surface Society's Dry Eye Workshop II, "dry eye is a multifactorial disease of the ocular surface characterized by a loss of homeostasis of the tear film, and accompanied by ocular symptoms, in which tear film instability and hyperosmolarity, ocular surface inflammation and damage, and neurosensory abnormalities play etiological roles."<sup>1</sup>

Many therapeutic strategies currently on the market have been used to manage dry-eye disease. In recent years, though, new regenerative therapies have provided a new perspective for managing this complex condition.<sup>2</sup>

"We've learned a huge amount about the disease during the past 10 to 15 years," says Michael A. Lemp, MD, clinical professor of ophthalmology at Georgetown University. "However, it's still very confusing for a lot of doctors. Because there's been so much research done in different areas, ophthalmologists are really not clear on how to apply it."

The first step toward a potential cure is understanding the disease process. "Many people believe that inflammation is the principal mechanism at work in dry-eye disease," Dr. Lemp says. "I'm not one of those people, but there are a number of

papers indicating that dry eye is an inflammatory disease. While it is an inflammatory disease in a lot of people, inflammation isn't present in a lot of others. So, when it's there, and it is there in most moderate to severe cases, it is an attractive target to deal with. The whole inflammatory process in the body is complicated, which makes it a great area for research because there are many entry points. This means that there are many opportunities to interfere with those entry points and decrease inflammation. In short, anti-inflammatories are very useful for patients with moderate to severe disease."

According to Dr. Lemp, researchers are finding out more about the epigenesis of the disease. "We don't know what the initiating factor is, and it's probably not the same in all people, he says. "In other words, the development of dry eye as a disease probably started out in different ways in different people. Each person has some type of proclivity for developing it. If a patient has a systemic disease that has an inflammatory component, the inflammatory state can include the lacrimal glands. They're affected by inflammatory cells, which damage tissue and tear production. These are some of the patients who have the most severe

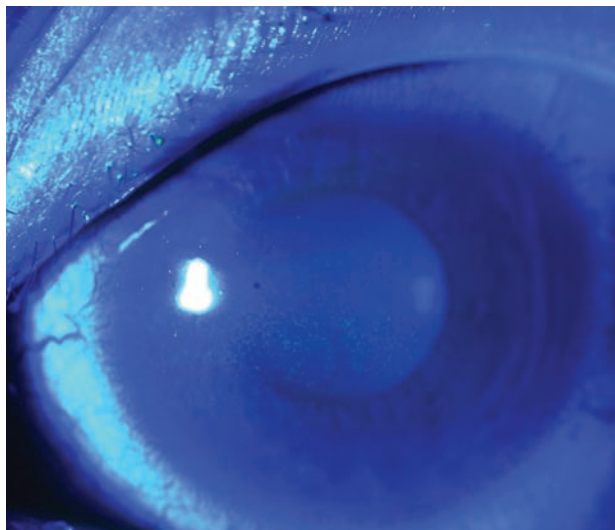
form of the disease, which is probably less than 10 percent of the dry-eye population.”

## Understanding Dry Eye

According to Dr. Lemp, most patients develop dry eye over time. “There are two basic subtypes of the disease. One is aqueous tear-deficient dry eye, and the other is evaporative dry eye, where the tears evaporate abnormally rapidly. The latter can be a result of meibomian gland dysfunction or other ocular surface or lid problems,” he explains.

Dr. Lemp adds that patients who have moderate to severe dry eye almost inevitably have both types. “For example, if a patient has meibomian gland dysfunction, in which he or she is not producing enough of the right kind of oil, and water is evaporating from the tear film, the patient will get a concentrated tear film,” he says. “That drives up tear osmolarity and signals the lacrimal glands to start producing more tears. So, it’s thought that the glands react as a compensatory mechanism. Then, what initially starts off as a compensatory process may actually worsen the disease if it continues. Many doctors continue to treat meibomian gland dysfunction as a separate disease, when it’s actually the most common subtype of dry eye. It’s been reported that 65 to 70 percent of dry-eye patients have evaporative dry eye. It should be noted, however, that early onset of meibomian gland dysfunction may not present itself as classical dry-eye disease.”

Patients with evaporative dry eye have extremely concentrated tears, which can negatively affect the ocular surface. “Tear osmolarity is one way of demonstrating that concentration,” Dr. Lemp notes. However, as measured in a laboratory test, it requires a



Fluorescein staining with the cobalt blue light demonstrating superficial punctate keratopathy related to dry eyes.

significant sample of tears, which most dry-eye patients don’t have. In 2008 or 2009, TearLab brought in-office tear osmolarity technology to the market. And, it turned out to be quite accurate. We conducted a 300-patient test, and it performed better than seven other tests that we evaluated. Tear osmolarity was the best identifier of dry eye. However, there was a lot of variability in dry-eye patients.”

Ophthalmologists were concerned that the test was not repeatable, but it was only not repeatable in dry-eye patients. It was then found that tear-film instability, reflected in the nonrepeatable results, is actually a marker for dry eye. “After dry-eye patients are treated effectively with an anti-inflammatory or other drug, the tear osmolarity variability disappears,” Dr. Lemp explains.

Tear-film instability is typically measured by tear-film breakup time, which is highly subjective. “You’ve got to look for the first spot that breaks up in the tear film after a blink, and you might miss it. That’s why it’s difficult to get reproducible results. Fortunately, OCT products that are currently on the market can show pictures of the tear film breaking up. You can pro-

gram these machines to do that, and you can get an accurate picture of how long it takes from a blink to the first breakup of the tear film. This technology has just become available in the past two years,” Dr. Lemp continues.

Additionally, a very small group of people suffer from a very severe form of ocular pain that is similar to dry-eye disease. “No matter what surface medications you treat them with, they remain in almost unbearable pain. We now know that it is a central nervous system problem in which some of the impulses that are going in from the

eye are becoming misdirected on a different pathway that has been built up in the central nervous system. It’s detached from what’s actually happening on the ocular surface, and treatment should be directed to the central nervous system,” Dr. Lemp says.

According to Stephen Pflugfelder, MD, director of the Ocular Surface Center at Baylor College of Medicine in Houston, if ophthalmologists hope to eventually cure dry eye, they need to be better at diagnosing and classifying the condition based on the underlying problem. “Unfortunately, I don’t think we do a good job of this right now,” he says. “This involves determining which glands are not functioning well and then maybe using targeted therapies, either medications, surgical therapies, or cell-based therapies, to try to treat that. This could involve the meibomian glands, the conjunctival goblet cells or the lacrimal glands.”

## Conventional Treatments

Treatment of dry eye has traditionally been focused on treating the symptoms, and is mostly based on lubrication and the control of inflamma-

Christopher Rapuano, MD

tion. However, Dr. Lemp explains that anti-inflammatories haven't been wholly successful. Some people respond well to them, while others don't. "Cyclosporine [Restasis, Allergan] was the first one that came on the market, and researchers looked at whether treatment with cyclosporine could increase tear production," he recounts. "They found a statistically significant improvement in 15 percent of the

people in the study, as opposed to 5 percent of the people who received placebo. A 15 percent improvement rate is not terribly impressive, but it was statistically significant, and that's why the Food and Drug Administration approved it," he says.

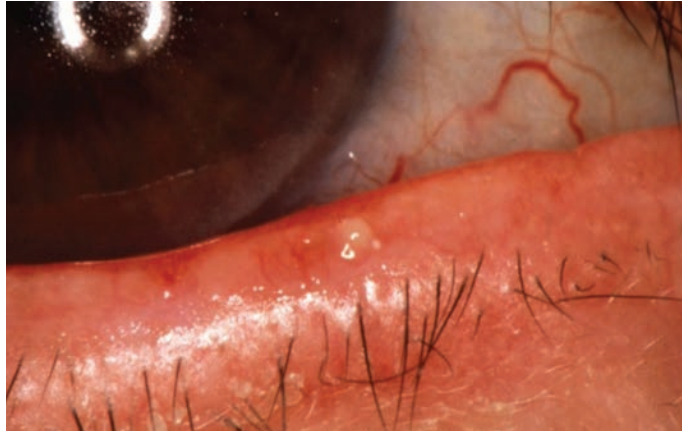
Dr. Lemp adds that ophthalmologists and patients are thankful for these anti-inflammatories, but that they're not as effective as some had hoped.

Dr. Pflugfelder agrees. "Cyclosporine has the unique property of actually increasing the number of mucus-producing goblet cells," he says. "So, in some ways, it addresses the underlying problem. However, that's only beneficial in people who have a goblet-cell deficiency to begin with. In the future, having better diagnostic tests to differentiate between a lipid deficiency and a mucus deficiency or specific deficiencies in tear components would be very valuable."

"This has led people to look at other treatment possibilities," Dr. Lemp adds. Allergan, for example, has developed TrueTear, which stimulates tear production by stimulating the nasal mucosa, a type of reflex tearing."

## New Treatment Strategies

The latest research is focused on the development of new biological



Researchers say most dry eye consists of a combination of aqueous deficiency and meibomian gland dysfunction (above).

strategies, with the goals of preventing disease progression, regenerating affected tissues and maintaining corneal transparency.<sup>2</sup> New treatments include growth factors and cytokines, as well as using different cell sources—specifically mesenchymal stem cells.

An important advance in the management of severe cases that don't respond to conventional therapy is the use of drops of different blood products. The most common choices are the use of autologous or allogeneic serum drops, platelet-derived plasma products and umbilical cord blood serum.<sup>2</sup>

"Autologous serum tears are gaining popularity. They use the patient's own antibodies and growth factors to combat dry eye," says Christopher J. Rapuano, MD, chief of the Wills Eye Cornea Service in Philadelphia. "However, the downsides are that the patient has to get his or her blood drawn, it's expensive and it's often not covered by insurance. There are a few companies that are researching immune components. Some companies are looking at amniotic membrane components, and some are looking at other components. As we learn more about the immune system related to dry eye, better immune treatments will be developed. Cyclosporine is an immune modulator, but it's broad-

spectrum. In the future, I think we're going to be able to target it better."

Autologous serum was first successfully used in patients with dry eye in 1984, and it gained widespread acceptance as an adjuvant therapy in different ocular-surface disorders in 1999. It helps to lubricate the eye, and also performs anti-inflammatory, antimicrobial and epitheliotrophic functions through certain biomolecules that are similar in

composition to natural tears.<sup>2</sup> Patients can use autologous serum as often as hourly.

Allogeneic serum from healthy blood donors can be used if a patient's own serum is unavailable. Additionally, platelet-rich plasma products have successfully treated cases of severe dry eye that didn't respond to conventional therapy.<sup>2</sup> Umbilical cord blood serum (recommended for use at a 20-percent concentration instilled four to six times per day<sup>2</sup>) also contains a high concentration of tear components. In one study, umbilical cord serum eye drops decreased symptoms and increased goblet-cell density in severe dry-eye syndrome more effectively than autologous serum drops.<sup>2</sup>

## Stem-cell Therapy

During the past decade, there's been an increasing interest in using stem-cell therapy to treat a number of different pathologies, including ocular diseases.

Mesenchymal stem cells have been proposed as cell therapy for many diseases with an inflammatory and immunomediated component. Mesenchymal stem-cell therapy in experimental dry-eye syndrome models was found to improve tear volume and tear-film stability, increasing epithelial



recovery and the number of goblet cells and decreasing the number of meibomian gland injuries in the conjunctiva.<sup>2</sup>

“I think stem cells could be helpful for regenerating the meibomian or lacrimal glands,” Dr. Pflugfelder says. “Let’s say you could inject stem cells into the lacrimal gland, and they would make it secrete again. Animal studies have shown that lacrimal-gland stem cells or mesenchymal stem cells may work. Another option would be to use the stem cells that are already present and stimulate them to start regenerating the tissue.”

Another potential treatment that’s in the early stage of research is lubricin, which is a protein in the tear film that facilitates the lubrication between the lid and the surface of the eye as you blink. It’s the same protein that’s present in joints to provide lubrication. “Lubricin is thought to be decreased in dry eye, and there is now a manufactured protein (ECF843 by Novartis) that is identical to it, which is being used in orthopedics and is in early stages of development for dry-eye disease,” Dr. Lemp explains.

Low-dose corticosteroid drops are also being investigated for the treatment of dry eye. “None of those treatments are being touted as a cure for dry eye, however,” Dr. Rapuano says. He adds that, as researchers learn more about the mechanisms of dry eye, physicians will have better targeted therapies. “As we treat conditions such as conjunctivochalasis better and look for other disorders, including superior limbic keratoconjunctivitis and floppy eyelids, we’ll improve our treatment of problems that fall under this huge umbrella of ‘dry eye.’ Certainly, we would love to have an anti-inflammatory medication that works better than cyclosporine and lifitegrast with very few side effects, and we’d love a nice strong steroid without the steroid side effects. Currently, those don’t exist,” Dr. Rapuano says.

Dr. Pflugfelder says he is hopeful for a cure. “I hope there will be a cure for dry eye, but I’m not sure it’s going to happen immediately,” he says. “It’s probably going to take a while, because cell-based therapies, such as stem-cell treatments, are complex. But, I do think it will eventually happen.” **REVIEW**

*Dr. Lemp has served as a consultant to TearLab and Santen. Dr. Pflugfelder is a consultant to and receives research funding from Allergan. Dr. Rapuano is a consultant to and/or lecturer for Allergan, Bio-Tissue, Kala, Shire, Sun Ophthalmics and TearLab.*

1. Winebrake JP, Drinkwater OJ, Brissette AR, Starr CE. The TFOS Dry Eye Workshop II: Key Updates. American Academy of Ophthalmology. 2017.  
2. Villatoro AJ, Fernandez V, Claros S, et al. Regenerative therapies in dry eye disease: From growth factors to cell therapy. International Journal of Molecular Sciences 2017;18:11:2,264.

(continued from page 17)

viscoelastic, bring the pupil down, and then remove the rest of the viscoelastic. Because if the ICL moves as you’re removing residual viscoelastic, the pupil is constricted and you won’t be able to see the marks as easily as you’d want to see them.”

Right now, proper implantation involves making a peripheral iridotomy. In the future, however, it’s likely the lens will be modified to ship with a hole in it. “I’m hoping that once we get the new version of the ICL with the hole in it, we won’t have to do the peripheral iridotomy ourselves anymore,” he says. “That will be a lot more rewarding. Right now, when you do the laser PI prior to surgery or the surgical PI at the time of the implantation, in some patients you can get some light scattering and aberrations.”

## Postop

In terms of results and adverse events, here’s what the surgeons and the clinical trial have found:

In the trial, 97.4 percent of 194 eyes had a manifest refraction within 1 D of target at 12 months (76.8 percent were within  $\pm 0.5$  D). For the manifest cylinder, 92.3 percent were within  $\pm 1$  D of the target at a year (69.1 percent were within  $\pm 0.5$  D). Between one day and one week postop, 97.5 percent of patients’ lenses rotated 5 degrees or less, and 2.5 percent rotated 6 to 10 degrees. During the final observation period of six to 12 months, 94.3 percent had rotated 5 degrees or less; 3.6 percent had rotated between 6 and 10 degrees.

In the realm of adverse events, Dr. Vukich says the single most common one is temporary intraocular pressure elevation related to incomplete visco removal or, less commonly, an incomplete peripheral iridotomy or an iridotomy that’s too peripheral. “So, you can see angle-closure glaucoma,” Dr. Vukich says. “But that’s in far less than 1 percent of patients, and is easily avoidable by having an intact, patent peripheral iridotomy.”

Dr. Moshirfar says that, at least for the nine eyes he’s done so far, it appears that for many patients, the lens can actually achieve greater amounts of cylinder correction. “It’s interesting to see that, even if the toric power is 3 or 4 D, many of these patients get more efficacy than the designated power, meaning that if you put in a 3.5-D lens, you might actually get 4.25 D of effect.”

Dr. Moshirfar adds that, in some cases, some fine-tuning may be required. “This will be with PRK or LASIK,” he explains. “I tell patients with high amounts of cylinder—like 5 or 6 D—that the toric ICL may not get all of it and after three months we may have to do a touch-up.” **REVIEW**

*Dr. Vukich is a consultant to Staar. Dr. Moshirfar has no financial interest in any products mentioned.*

# DMEK Success: Maintaining the Graft

*Kristine Brennan, Senior Associate Editor*

Corneal transplant experts discuss avoiding trauma to the donor and heading off postop complications.

Descemet's membrane endothelial keratoplasty holds the promise of faster, better visual recovery for the right patients. "It's great," says Francis W. Price Jr., MD, of Price Vision Group in Indianapolis. "We're seeing a gradual increase in the percentage of people who are doing DMEK. It's just been slow to catch on because it's harder to do." Here, three experts share their rules for preserving the graft, avoiding complications, and determining when to try something else.

## Handle with Reverence

"The biggest consideration in DMEK surgery is minimizing manipulation of the graft so you can have adherence and survival of the graft," says Mark A. Terry, MD, director of Corneal Services at Legacy Devers Eye Institute in Portland, Oregon. Neda Shamie, MD, cataract, LASIK and corneal surgeon at Maloney-Shamie Vision Institute and an assistant clinical professor at USC Roski Eye Institute in Los Angeles, says, "I jokingly say I have reverence for the corneal endothelial cells; I really hold them in high regard and I do my very, very best to minimize any manual or mechanical damage to the graft."

Many surgeons use eye-bank-pre-

pared tissue, but unless it's patient-ready and preloaded, you'll still need to place it in an appropriate injector. "It's critical to use the correct delivery system. We used to use plastic injectors which were used for IOL implants," says Dr. Shamie, who currently uses glass injectors. "But plastic is very damaging to the endothelial cells. Because these grafts scroll in such a way that the endothelial cells are on the outside of the scroll, the plastic rubbing against those cells can be quite damaging."

The age of donor DMEK tissue also matters, according to Dr. Price. "For surgeons who aren't doing DMEK frequently, using tissue that's 60 to 70 years old makes things easier," he says, adding that most DMEK surgeons use donors aged 50 or older. "Younger tissue curls up tightly, making it harder to get into the right position to put air underneath it and push it up against the back of the patient's cornea."

To aid in atraumatic insertion and manipulation, Dr. Price's DMEK tissue is loaded into the injector in a trifold. "Our tissue is folded Descemet's out, endothelium in—which is the opposite of how the tissue wants to curl itself. In difficult cases, such as in patients who've had vitrectomies, where you can't shallow the anterior chamber, that can work out a lot

better,” he says. “Just pull the tissue in and before letting go, inject air under it so there is no need to shallow the AC.” Dr. Price also says that gentian-violet “S” or “F” stamping is helpful for avoiding upside-down DMEK grafts, although he cautions that the stamping risks some damage to endothelial cells. He prefers to use intraoperative OCT to verify tissue orientation, and it works with thick, hazy corneas.

“I tell visiting surgeons who come to Portland to learn DMEK to choose for their first cases a donor aged 60 or older,” says Dr.

Terry. “As you get better at controlling chamber depth and understanding the fluidics of unscrolling the tissue, you can then lower that to 50 years old. As you continue to improve, you can use increasingly younger donor tissue.”

Dr. Terry says that properly orienting the graft starts inside of the injector. “As you inject it, rotate the injector so that the tissue will be right side up at the very beginning,” he explains. “After the tissue’s inside of the eye, then the critical factor is controlling the anterior chamber depth. If your chamber is too deep when you try to unscroll the tissue, you will fail to open the tissue in spite of a lot of manipulation. If the chamber is totally flat, with no fluid in the anterior chamber, and you tap and try to unscroll the tissue, it won’t unscroll then either, and you’ll just damage the endothelial layer. What you want in DMEK surgery is an anterior chamber that you control completely. Anterior chamber depth can’t be serendipitous: The surgeon needs to actively add or remove fluid so that the chamber is very shallow, but not flat.”

“It’s important to keep in mind that the graft is so fragile that if there’s a lot

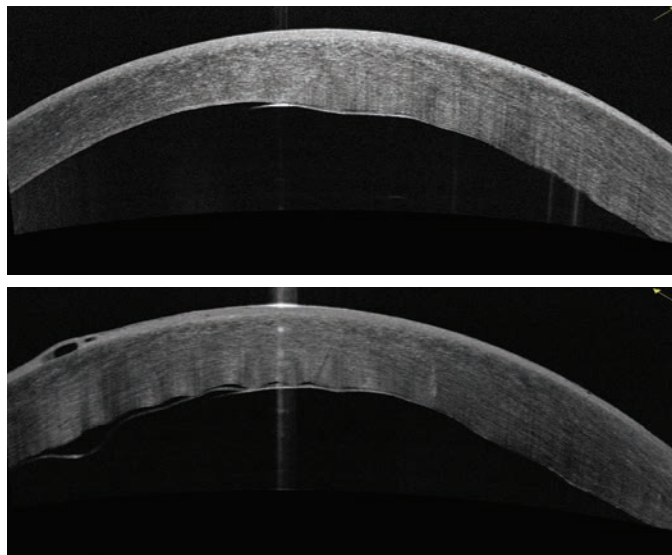


Figure 1: OCT image showing a cornea with central graft separation, six days post DMEK. Vision at the time of this study was 20/400.

All Images: Mark A. Terry, MD

touches the plastic of the IOL, you’re killing it,” he emphasizes. “This is why you want a small pupil. The key to safe DMEK surgery is to unscroll the tissue without allowing the endothelium to touch any hard object: an IOL, forceps, hook, spatula or anything else.”

If the graft incurs some damage, surgeons say it can be a tough call as to whether to proceed. “A little damage is okay: You just want to avoid major damage. That’s where experience comes into play,” says Dr. Price.

“I’ve never had to abort a case, but I do know of surgeons who’ve decided to abort, or if they have a backup tissue, or a case that’s scheduled later, they move on and then cancel the later procedure,” Dr. Shamie says. “It’s rare, though. What I recommend is to proceed: Go ahead with that graft if at all possible. If the cornea does not clear in one to three months, then consider repeating the surgery.”

“If there’s a tear, as long as you have a sufficient amount of graft tissue, you can remove the area that’s been torn and strip it away or just tear it off,” she continues. “Even if you transplant a half-moon-shaped or Pac-Man-shaped graft, as long as the cells on the remaining graft aren’t terribly traumatized, those cells will migrate and cover the area where there are no endothelial cells. You want to decenter your graft in those cases so that the optical zone is covered.”

## Block Pupillary Block

Pupillary block after DMEK is potentially serious, but less common than postop graft separation.<sup>1</sup> “If it happens, it’s for one of three reasons,” says Dr. Terry. “The first reason is that your

of pressure in the eye during injection, the graft could be ejected from the eye through a tiny 1-mm incision,” Dr. Shamie says. She adds that pupil miosis is critical to preventing trauma inside the eye. “If the pupil is dilated and there’s a plastic IOL sitting right where the graft is injected into the eye, that can be damaging. It’s really important to bring the pupil down as much as possible, since the iris tends to be less traumatic to the endothelial cells.”

Dr. Price points out that in addition to pupil miosis and controlled chamber depth, how gently you perform your fluidic maneuvering of the graft is also important. “You don’t want to do a really hard, long irrigation with balanced salt solution like you would in phaco, because the very thin and pliable DMEK tissue will squirt out of the incision,” he says, adding, “It’s really a lot of fun if done correctly. The donor tissue is like a jellyfish: It goes wherever the flow goes, so you don’t want too strong of a current, just short, gentle bursts of BSS.”

The importance of minimizing touches on the graft cannot be overstated, says Dr. Terry. “Every time the endothelial layer of the donor tissue

inferior peripheral iridectomy was not a complete, full-thickness iridectomy. You cannot just depend upon transillumination through the PI: You must make sure that you've excised pigment."

Even if you've done a full iridectomy, a gas bubble can cover it postoperatively, constituting the second cause of pupillary block, according to Dr. Terry. "At the end of surgery we always check that the inferior peripheral iridectomy will be open when the patient is sitting up," he says. "At the end of every case we put an 85- or 90-percent gas bubble in (a 20-percent concentration of SF6), and then we rotate the eye with forceps downward or we have the patient look down. We can see at that point on the table that the iridectomy will be uncovered in the sitting or upright position. Postoperatively, every hour on the hour until they go to bed, we have patients get up and walk around the room for two or three minutes. It helps them feel better and to avoid DVTs, and it also helps get the gas bubble to clear the peripheral iridectomy to prevent pupillary block."

Although surgeons can easily remove air if a block occurs right after surgery, Dr. Terry warns that a rarer form of pupillary block is still a risk even days after DMEK. "There is also the possibility of pupillary block occurring three or four days post surgery," he explains. "If a patient goes into a movie theater, for example, and their pupil dilates in the dark, the gas bubble, which is now smaller, can go behind the pupil. Then when the patient walks out of the theater and into normal light, the pupil constricts, trapping the gas bubble behind the iris. This is a reverse pupillary block, which causes severe pain and pressure. I tell my patients, 'If you have severe pain, I don't care if it's three days or a week after surgery: Call

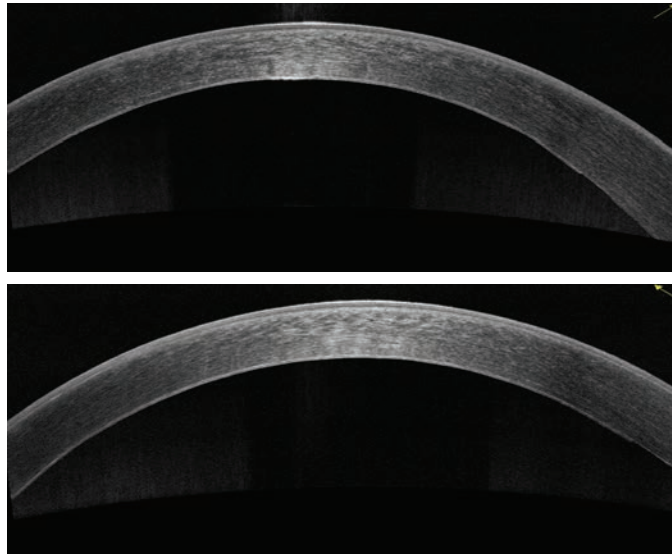


Figure 2: OCT of cornea four days after a rebubble at the slit lamp that was done 10 days post DMEK. The patient achieved 20/20 UCVA.

us. Within an hour, we'll take a look at you and see what's going on.' It's a rare occurrence, but patients need to know about it, and you need to be available to them after surgery."

### Rebubble or Reconsider?

Partial graft detachments are the most common post-DMEK complication;<sup>1,2</sup> experienced surgeons can make predictions about a graft's behavior to aid in decision-making. "I give a graft the benefit of the doubt when I know the surgery went reasonably well and it was as atraumatic as possible," Dr. Shamie says. "If the graft is not pumping or it's not attached 100 percent, I tend to feel that it may just need a little extra help. But if it was a graft in which the surgery was truly traumatic, and there was a lot of manipulation of the graft, and I've rebubbled once and it's not clearing or attaching at all, that's a case where I may not put the patient through waiting three months before giving up on the graft. Rather than letting the patient sit around for three months with blurry vision, I'd probably do a repeat transplant sooner."

The need for intervention in graft

separation depends on degree and location, according to DMEK surgeons. "If there's any edge lift, if it's a small amount, you can just watch it," says Dr. Price. "But if the edema extends into the pupillary area, or shows signs of increasing, then just go ahead and re-inject more air," he says, adding that his practice's data indicates that doing two or more rebubbings appears to decrease endothelial cell counts.<sup>3</sup> He cautions, however, that DMEK eyes getting repeat re-

bubbings may have greater cell loss for reasons other than re-injecting air multiple times. "I think that probably makes the data look worse," he notes.

"Graft detachment is probably the most common risk of DMEK surgery," says Dr. Shamie. "The key is to decide when to rebubble: If the graft separation is partial, with less than 20-percent separation, you can safely monitor it for spontaneous reattachment of that area."

If you know your graft was right side up and healthy at the time of surgery, Dr. Terry concurs that watchful waiting is appropriate for partial detachments. "We only reattach a graft with an air-bubble injection if the graft is one-third or more detached or if the central graft isn't attached," he says. "That's our criteria, based on OCT scan." He cites a paper by Christopher Sales, MD, and colleagues<sup>4</sup> describing a method of reattaching the graft at the slit lamp. "It only takes about three minutes and doesn't disturb your clinic flow," he says.

How many rebubbles is too many? "I've never had to rebubble more than once," Dr. Shamie notes. "If you are rebubbling, you should probably try

to keep it to less than 20 to 30 percent of the time in cases of DMEK: If you're rebubbling more frequently, you should probably consider making modifications to your technique in order to lessen trauma to the graft. Similarly, if you find that the majority of your cases require rebubbling more than once, there should probably be reconsideration for modifications. By the time a second rebubble is done, if the graft is not attaching and the cornea is significantly cloudy, then I would consider giving it at least a month before thinking about replacing the graft," she says. "I wouldn't give up on a graft, for example, where 50 percent of it is pumping and the overlying stroma is perfectly clear. That's a graft I would potentially wait on for three months before giving up on it. It's definitely case-by-case: It's hard to generalize. The more DMEK experience you gain, the more you know how to anticipate how a given graft will behave, how much time you can consider giving it the benefit of the doubt, and when you should give up on it," she says.

## Reject Rejection

The risk of rejection is low in DMEK, but it does happen.<sup>1</sup> "Most often when we see rejection, it's because people stop taking their drops," says Dr. Price. "Otherwise, the rejection rate is quite low. Like any other transplant, if you catch it early, in most cases you can reverse it. We'll typically give more frequent topical prednisone acetate or one of the other steroids. If there's a significant rejection episode, we'll give them a one-time dose of IV Solu-Medrol (Pfizer; New York).

Dr. Terry says that it's important to be alert for other underlying causes of apparent rejection. "It's very rare that I see a rejection from DMEK surgery. If it occurs, I look at other possible causes of inflammation," he says. "The key to rejection in DMEK is that it's usually a silent rejection, so you need

to follow these patients closely in the first year. If I see a patient with an increase of white blood cells in the anterior chamber six months after surgery, then I know that the inflammation is not from the surgery itself: It's either an infectious cause, like a virus such as CMV or HSV, or a true rejection of the tissue that we've transplanted. If you see inflammation outside of the early postoperative period—three, four, or six months later—then you should be suspicious not only of rejection, but of possible infectious etiology of the inflammation" he says.

Although DMEK's role in the corneal-transplant armamentarium is expanding, Dr. Terry urges surgeons not to focus on DMEK to the exclusion of other techniques, since patients may end up needing something else. "The biggest point to be made is that corneal transplant surgeons today should never say, 'I'm a DMEK surgeon,' or 'I'm a DSAEK surgeon,' or 'I'm a PK surgeon.' If you're a corneal-transplant surgeon, you've got to do it all. We are now in a new era of modern transplant surgery, and you have to be confident using techniques for the entire field." **REVIEW**

*Dr. Price is a consultant for Haag-Streit, a manufacturer of intraoperative OCT systems. Dr. Shamie is a consultant for CorneaGen of Orange County and Lions VisionGift in Oregon. Dr. Terry reports no financial interests in DMEK surgical devices, but receives royalties from Bausch + Lomb for the design of a surgical instrument used in DSAEK.*

1. Deng SX, Lee WB, Hammersmith KM, et al. Descemet membrane endothelial keratoplasty: Safety and outcomes: A report by the American Academy of Ophthalmology. *Ophthalmology* 2018;125:2:295-310.

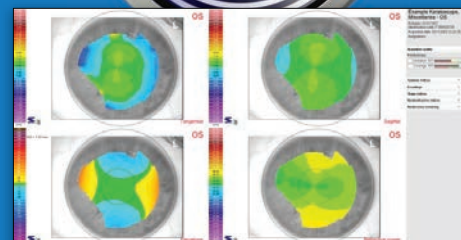
2. Oellerich S, Baydoun L, Peraza-Nieves J, et al. Multicenter study of 6-month clinical outcomes after Descemet membrane endothelial keratoplasty. *Cornea* 2016;36:12:1467-76.

3. Feng MT, Price MO, Miller JM, Price Jr FW. Air reinjection and endothelial cell density in Descemet membrane endothelial keratoplasty: Five-year follow-up. *J Cataract Refract Surg*. 2014;40:7:1116-1121.

4. Sales CS, Straiko MD, Terry MA. Novel technique for rebubbling DMEK grafts at the slit lamp using intravenous extension tubing. *Cornea* 2016;35:4:582-5.

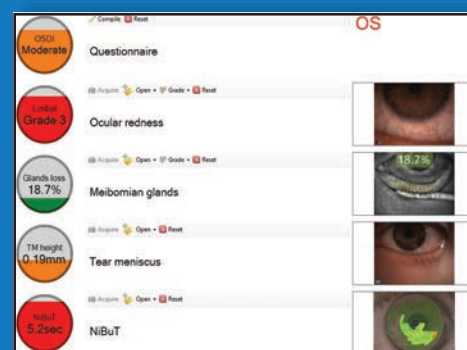
# S4OPTIK

## ANTARES



**Corneal Topography & More!**

## Introducing the NEW Dry Eye Report



## Comprehensive Diagnostic Imaging For Dry Eyes

More Information: [info@s4optik.com](mailto:info@s4optik.com)

# S4OPTIK

250 Cooper Ave., Suite 100 Tonawanda NY 14150

[www.s4optik.com](http://www.s4optik.com) | 888-224-6012

Sensible equipment. Well made, well priced

For today's modern office.



# Lid Laxity: Diagnosis And Management

Lax eyelid syndrome is linked to obstructive sleep apnea, so prompt diagnosis is crucial, says this physician.

*Blair K. Armstrong, MD, Philadelphia*

**Floppy eyelid syndrome** was first described by William Culbertson, MD, and H. Bruce Ostler, MD, in 1981. They described a series of 11 overweight men with chronic irritative symptoms and rubbery, easily-everted upper eyelids and papillary conjunctivitis. Since the initial description, similar findings have been observed in female, non-obese and pediatric populations, leading many authors to suggest the term *lax eyelid syndrome* to encompass this broader spectrum of affected patients. Nomenclature aside, LES presents a diagnostic and treatment challenge to the ophthalmologist and oculoplastic surgeon alike.

## Pathogenesis

The abnormality in LES is localized to the tarsus, which is a connective tissue plate that's larger and more defined in the upper eyelid, 8 to 10 mm tall centrally. In patients with LES, the tarsus becomes malleable and is easily everted with mild external force. Why this happens is not completely understood. Drs. Culbertson and Ostler noted

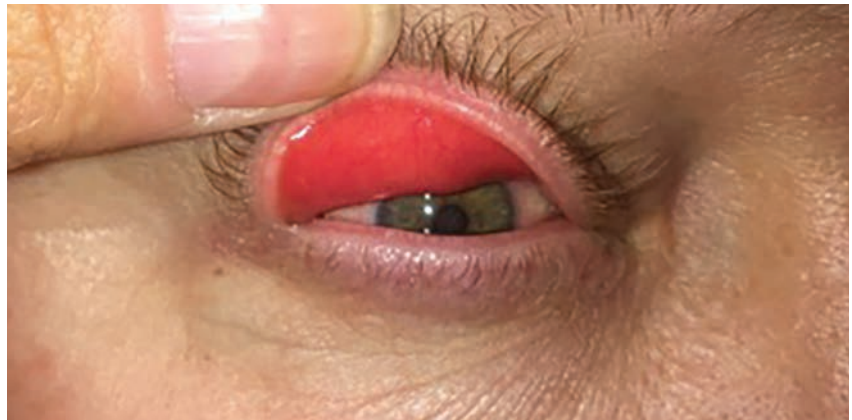

Figure 1: Eversion of an upper eyelid with gentle digital pressure. Note the injected palpebral conjunctiva. Slit lamp examination shows papillary conjunctivitis.

unilateral disease in patients who favored one side during sleep and bilateral disease in patients sleeping face down, implicating nocturnal eversion.<sup>1</sup> This mechanical theory, however, doesn't fully explain any associated corneal or epibulbar irritation. Many studies demonstrate concomitant tear-film abnormalities including *Demodex* mites, meibomian gland atrophy and blepharitis that may exacerbate reduced globe-eyelid apposition, leading to a symptomatic patient. At the histologic level, early studies showed nonspe-

cific inflammation of the tarsus,<sup>1</sup> while more recent studies reveal reduced elastic fibers and upregulation of elastin-degrading enzymes, particularly MMP-7 and MMP-9.

LES is linked to a variety of ocular and systemic conditions including obesity, keratoconus, eyelash ptosis and, most notably, obstructive sleep apnea.<sup>3</sup> OSA is a common and likely underdiagnosed entity characterized by nocturnal airway collapse for more than 10 seconds. This chronic hypoventilation leads to hyperten-

# S4OPTIK

## ANTARES

### DRY EYE TESTING

sion, heart disease and motor vehicle accidents, and has also been implicated in ischemic ocular disease including low-tension glaucoma and ischemic optic neuropathy. Because LES and OSA often occur concurrently, the ophthalmologist may be the first to identify a systemic condition associated with high morbidity.

### Diagnosis

Although classic FES describes a subgroup of obese, male patients, the expanded definition of LES encompasses a variety of patients with eyelid laxity and associated corneal, conjunctival or tear-film pathology.<sup>9</sup> Thus, this diagnosis should be considered even in patients who don't meet the classic demographic. Patients present with symptoms of pain, swelling, irritation, foreign-body sensation, tearing and ocular discharge. The most common ocular sign is a papillary conjunctivitis, occurring in up to 98 percent of LES patients. Other ocular findings include keratopathy, filamentary keratitis, infectious keratitis, recurrent corneal erosion, tear insufficiency and eyelash ptosis.<sup>8</sup>

The hallmark of the condition is eyelid laxity. This can be evaluated subjectively by easy or spontaneous eyelid eversion with gentle digital pressure (*Figure 1*). It can also be assessed with the "snap-back" test: distraction of the eyelid >8 mm away from the globe, or done more formally with a "laxometer" device.<sup>9,10</sup> When eyelid laxity exists in the presence of anterior segment findings, especially papillary conjunctivitis, the diagnosis can be assumed.

Because of the high morbidity and mortality of OSA, patients should be asked about snoring, excessive daytime sleepiness and obesity. Ophthalmologists should maintain suspicion for OSA and refer patients to their primary care physician or

pulmonologist. OSA can be diagnosed with polysomnography and treated with weight loss, continuous positive airway pressure and, occasionally, with pharyngeal surgery. Following is a discussion of treatment approaches.

### Non-surgical Measures

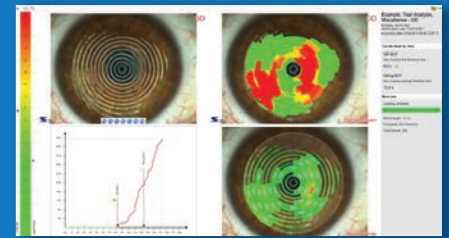
The diagnosis of LES can be challenging, and often these patients have been chronically treated with a variety of topical medications. Multiple topical medications should be stopped to eliminate confounding medicamentosa. They can then be added back one at a time. Topical measures consist of artificial tear drops, gels and ointments, and topical steroids. The eye can be shielded or taped shut at night. Moisture chambers, eyelid scrubs or punctal plugs may also be used.<sup>1,12</sup>

### Surgical Options

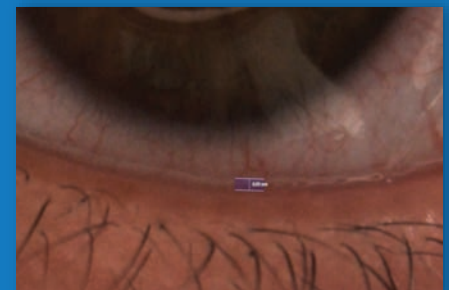When conservative measures fail, surgery is indicated. The goal of surgery is to reduce horizontal eyelid laxity, improve globe apposition and limit spontaneous eyelid eversion, thereby eliminating nocturnal exposure. Various surgical techniques have been described, including full-thickness wedge excision (FTWE), lateral tarsal strip (LTS), lateral canthal plication, and lateral tarsorrhaphy. FTWE and LTS will be discussed here.

- **Full-thickness wedge excision.**

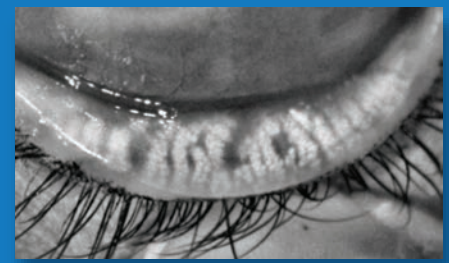The FTWE procedure is usually performed by excising a pentagon-shaped wedge of full-thickness eyelid at the lateral one-third of the lid. The wound edges are then approximated in a manner similar to repair of a full-thickness eyelid defect: Sequential suturing of the gray line, lash line, tarsal plate, preseptal orbicularis and skin. The amount of tissue resected varies based on the severity of



Non-Invasive Tear Film Break-up Analysis



Tear Meniscus Height



Meibomian Gland Imaging & Analysis

**Ocular Surface Disease Index (OSDI)**

Ask your patient the following 12 questions, and check the number in the box that best represents each answer.

Have you experienced any of the following during the last week?	All of the time	Most of the time	Half of the time	Some of the time	None of the time
1. Eyes that are sensitive to light?	0-4	0-3	0-2	0-1	0-0
2. Eyes that feel gritty?	0-4	0-3	0-2	0-1	0-0
3. Pained or sore eyes?	0-4	0-3	0-2	0-1	0-0
4. Blurred vision?	0-4	0-3	0-2	0-1	0-0
5. Poor vision?	0-4	0-3	0-2	0-1	0-0
Subtotal score for answers 1 to 5: <b>0</b>					

Have problems with your eyes caused you to perform any of the following during the last week?	All of the time	Most of the time	Half of the time	Some of the time	None of the time	N/A
6. Reading?	0-4	0-3	0-2	0-1	0-0	0-NSA
7. Driving at night?	0-4	0-3	0-2	0-1	0-0	0-NSA
8. Working with a computer or hand machine (ATM)?	0-4	0-3	0-2	0-1	0-0	0-NSA
9. Watching TV?	0-4	0-3	0-2	0-1	0-0	0-NSA
Subtotal score for answers 6 to 9: <b>4</b>						

### Ocular Surface Disease Index Questionnaire

More Information: [info@s4optik.com](mailto:info@s4optik.com)



250 Cooper Ave., Suite 100 Tonawanda NY 14150

[www.s4optik.com](http://www.s4optik.com) | 888-224-6012

Sensible equipment. Well made, well priced

For today's modern office.

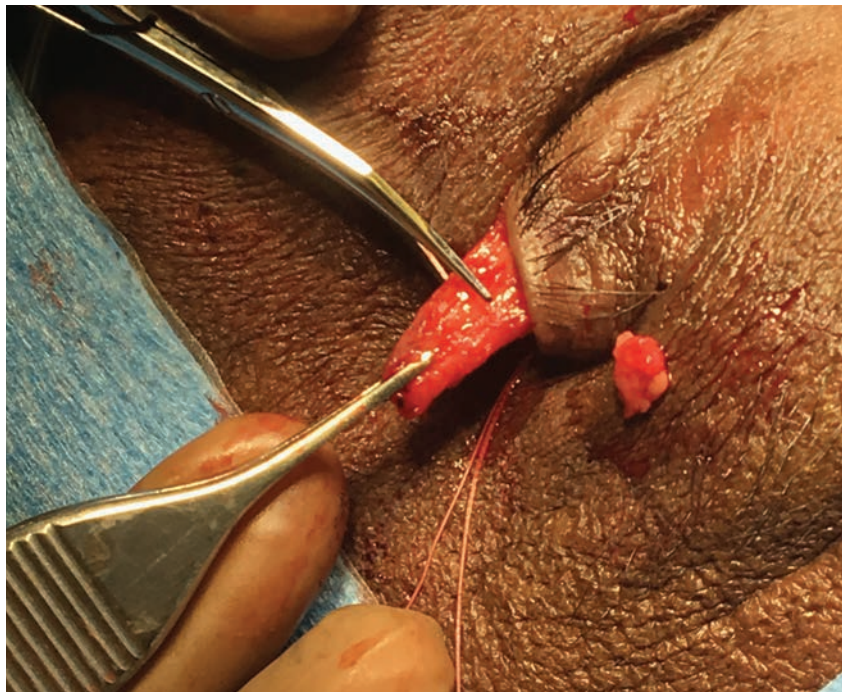


Figure 2: Intraoperative photograph of a patient undergoing an upper eyelid lateral tarsal strip procedure. The tarsal strip has been developed and the eyelid is placed on lateral stretch to determine the amount of the strip to be excised to restore anatomic tone to the eyelid. The strip will then be fixated to the periosteum of the orbital rim in the region of Whitnall's tubercle.

the disease and can be determined perioperatively by laterally stretching the eyelid to a more appropriate upper-lid tension. It's not unusual to excise up to 20 mm of tarsus in these patients. Caution must be taken to avoid injury to the ductules of the lacrimal gland which are located 5 mm superior to the lateral-most edge of tarsus in the upper eyelid. There are various modifications to the skin closure that can reduce cutaneous redundancy, including the classic Burow's triangle and myocutaneous flaps.

• **Lateral tarsal strip.** While LTS is a commonly performed procedure in the lower eyelid, it can also be used to address upper eyelid horizontal laxity and offers the benefit of preserving the tarsus.<sup>13</sup> Upper eyelid LTS is performed through cantholysis of the superior limb of the lateral canthal tendon followed by

identification of the orbital rim. A strip can be fashioned in a technique similar to lower eyelid LTS: division of the anterior and posterior lamellae and resection of the mucocutaneous junction. The lateral canthal tendon is resected; a varying amount of the lateral tarsus is also resected depending on the severity of the disease. The strip is then fixated to the periosteum of the lateral orbital rim in the region of Whitnall's tubercle using a 4-0 or 5-0 permanent suture placed in a horizontal mattress fashion. The lateral canthus is then reformed and the anterior lamellar incision closed. This incision can be fashioned such that the surgical scar is hidden in the natural eyelid crease. The beneficial effect of LTS is in tarsal shortening, but also likely in the creation of a broader pivot point at the lateral orbital rim, thereby reducing spontaneous eversion.<sup>13</sup>

## Conclusion

The spectrum of LES should be considered for patients with non-specific complaints and anterior segment findings who demonstrate upper and lower eyelid laxity. The most common ocular finding is papillary conjunctivitis. OSA should be suspected in these patients and can be diagnosed in conjunction with the primary care physician or pulmonologist. In this way, the ophthalmologist can play a pivotal role in diagnosis of this major public health concern. **REVIEW**

*Dr. Armstrong is a clinical assistant professor of ophthalmology at the Sidney Kimmel Medical College at Thomas Jefferson University, and a member of the Wills Eye Hospital Orbital and Oculoplastic Surgery Service. She practices at Armstrong, George, Cohen, Will Ophthalmology in Hatboro, Pennsylvania.*

- Culbertson W, Ostler H. The floppy eyelid syndrome. *American Journal of Ophthalmology* 1981;92:4:568-75.
- Eiferman R, Gossman MD, O'Neill K, et al. Floppy eyelid syndrome in a child. *Ophthalmic Plastic & Reconstructive Surgery* 1991;7:1:74.
- Woog J. Obstructive sleep apnea and the floppy eyelid syndrome. *Am J Ophthalmol* 1990;15:110:3:314-5.
- Burkat C, Lemke BN. Acquired lax eyelid syndrome. *Ophthalmic Plastic & Reconstructive Surgery* 2005;21:1:52-58.
- Tanenbaum M. A rational approach to the patient with floppy/lax eyelids. *Br J Ophthalmol* 1994;78:9:663-4.
- Van den Bosch WA, Lemij HG. The lax eyelid syndrome. *British Journal of Ophthalmology* 1994;78:9:666-70.
- Schlötzer-Schrehardt U, Stojkovic M, Hofmann-Rummelt C, et al. The pathogenesis of floppy eyelid syndrome involvement of matrix metalloproteinases in elastic fiber degradation. *Ophthalmology* 2005;112:4:694-704.
- Pham TT, Perry JD. Floppy eyelid syndrome. *Current Opinion in Ophthalmology* 2007;18:5:430-3.
- Fowler A, Dutton JJ. Floppy eyelid syndrome as a subset of lax eyelid conditions: Relationships and clinical relevance (an ASOPRS thesis). *Ophthalmic Plastic & Reconstructive Surgery* 2010;26:3:195-204.
- Sward M. Lax eyelid syndrome (LES), obstructive sleep apnea (OSA), and ocular surface inflammation. *The Ocular Surface* 2018;16:3:331-36.
- Karger RA, White WA, Park WC, et al. Prevalence of floppy eyelid syndrome in obstructive sleep apnea-hypopnea syndrome. *Ophthalmology* 2006;113:9:1669-74.
- Moore MB, Harrington J, McCulley JP. Floppy eyelid syndrome: Management including surgery. *Ophthalmology* 1986;93:2:184-8
- Ezra DG, Beaconsfield M, Sira M, et al. Long-term outcomes of surgical approaches to the treatment of floppy eyelid syndrome. *Ophthalmology* 2010;117:4:839-46.
- Vrcek I, Chou E, Blaydon S, et al. Wingtip flap for reconstruction of full-thickness upper and lower eyelid defects. *Ophthalmic Plastic and Reconstructive Surgery* 2017;33:2:144-146.





# THE RICK BAY FOUNDATION

*for Excellence in Eyecare Education*

[www.rickbayfoundation.org](http://www.rickbayfoundation.org)

*Support the Education of Future Healthcare & Eyecare Professionals*



## **About Rick**

Rick Bay served as the publisher of *The Review* Group for more than 20 years.



To those who worked for him, he was a leader whose essence was based in a fierce and boundless loyalty.


To those in the industry and the professions he served, he will be remembered for his unique array of skills and for his dedication to exceeding the expectations of his customers, making many of them fast friends.

Scholarships are awarded to advance the education of students in both **Optometry** and **Ophthalmology**, and are chosen by their school based on qualities that embody Rick's commitment to the profession, including integrity, compassion, partnership and dedication to the greater good.

**Interested in being a partner with us?**

Visit [www.rickbayfoundation.org](http://www.rickbayfoundation.org)

*(Contributions are tax-deductible in accordance with section 170 of the Internal Revenue Code.)*



**THE RICK BAY FOUNDATION®**  
*for Excellence in Eyecare Education*

*(The Rick Bay Foundation for Excellence in Eyecare Education is a nonprofit, tax-exempt organization under section 501(c)(3) of the Internal Revenue Code.)*

EVERY MONDAY  
**E-NEWS YOU CAN USE**



Have you been receiving and reading custom e-blasts from *Review of Ophthalmology*?

**If not, you're missing out on valuable information!**

You're a busy practitioner and not surprisingly, your e-mail inbox is often full. Fortunately, when you scan through the sender list, determining which messages to delete and which to save or read, you can feel confident knowing that e-blasts from *Review of Ophthalmology*, a Jobson Medical Information LLC publication, contain the most current and comprehensive information available in the field to keep you on the cutting edge.

*Review of Ophthalmology's* online stable of products includes editorial newsletters and promotional information about new products, treatments and surgical techniques, as well as alerts on continuing education courses for ophthalmologists.



Our **FREE** weekly e-newsletter, *Review of Ophthalmology Online*, brings you the latest in ophthalmic research, as well as industry news. In an effort to keep eyecare professionals informed, this resource is waiting in your inbox **every Monday morning**.



*Retina Online*, our free monthly e-newsletter, is for retina specialists and general ophthalmologists interested in enhancing their knowledge on the topics of retina and related disease diagnosis and treatment, as well as the latest in surgical procedures.

Your time is valuable — and so is your practice. These e-products are the most effective way for you to receive updates on breaking news and research — all just a click away.

**DON'T MISS OUT!**

Unfamiliar with our products? Visit [www.reviewofophthalmology.com](http://www.reviewofophthalmology.com) and check out our newsletter archives.

Go to [www.jobson.com/globalEmail/default.aspx](http://www.jobson.com/globalEmail/default.aspx) to sign up for the e-newsletters that interest you.



# First Look: A Head-Mounted OR Display

Surgeons with experience using a novel, prototype technology explain how it works.

*Anat Loewestein, MD, Ron Schneider and Adiel Barak, MD  
Tel Aviv, Israel*

**T**hough it's a reliable workhorse that ophthalmic surgeons have counted on for decades, the operating microscope does have some limitations in terms of the information that can be viewed in the oculars, as well as restriction of the surgeon's movement and potential for repetitive stress injury. We're currently working on a prototype for a head-wearable surgical display that would provide a view of the operation, as well as ancillary data, all projected onto the surgeon's retina so it appears to be on several large screens. We're hoping this modality will improve surgical precision and efficiency. Here's a look at how the device works.

## Functions and Features

The system is called Clarity, and it's being developed by Beyeonics Surgical, an Israeli medical device company. Its viewing approach is actually based on technologies used in the cockpits of fighter planes.

In short, the platform serves as a digital extension of the surgeon, providing an augmented-reality view of the surgery. The components of the

system and their features include the following:

- **Dual 3-D, ultra HD-resolution cameras suspended on a remote arm and a transparent head-wearable display.** The headset allows information to flow towards the surgeon with the simultaneous visualization of multiple fields of view (*Figure 1*). Using head motions, the surgeon shifts between different virtual screens projected onto his retina, and controls functions such as focus, HUD transparency, the X/Y-axes view of the image and light levels. Being able to switch the image in the display between transparent and opaque enables the surgeon to have situational awareness in the operating room, so his vision isn't completely occluded.

- **Data from different sources in one display.** The surgeon can customize the information and the user interface he sees. The technology provides a zero-lag display with no apparent image latency when he moves an instrument. Many different types of personalized, virtual information may eventually be displayed alongside the surgical image, and the company envisions Clarity eventually

integrating virtual screens from external hardware such as intraoperative OCT, wide-angle lenses (BIOM), angiography, phaco settings, picture archiving and communication (PACS), and a patient's vital signs.

- **Processor.** The system also contains a processing core that will allow the integration of information from multiple digital sources in real time (*Figure 2*), which will help with surgical decision-making.

## Prototype Study

Using the early prototype version of Clarity, 40 operations were successfully performed in Israel and the United States. The procedures included vitrectomy for macular hole, retinal detachments, epiretinal membrane peeling and silicone oil removal. The surgeons used Clarity for visualization and the Alcon Constellation vitrectomy system for the surgical procedure itself.

Using the system's head tracker, each surgeon navigated with his head between his own customized screens, and was able to achieve sharp visualization of the posterior chamber.

The surgeons noted that the image quality was good, and comparable to that of a surgical microscope. The maximum magnification of the system was greater than that of a microscope.

In addition, the light levels used during the surgery were more than 50 percent less than those of the traditional microscope, which may reduce the risk of retinal phototoxicity. In some cases, surgeons activated different digital color filters on the display in order to enhance the visualization of the internal limiting membrane and scar tissue.

The head-wearable display didn't impose any fatigue or stress on the head, and the surgeons reported that they found the use of head motions to operate the system to be intuitive.

### Future Work

Though the system has useful features, there's still room for improvement in some areas:

- **The need for a wireless headset.** The current head-wearable display involves a wired connection to the processor and camera, which limits a surgeon's mobility in the operating room environment.

- **An easier way to integrate applications into the digital display.** Applications such as topography images, vital signs and alignment displays for toric intraocular lenses will need to

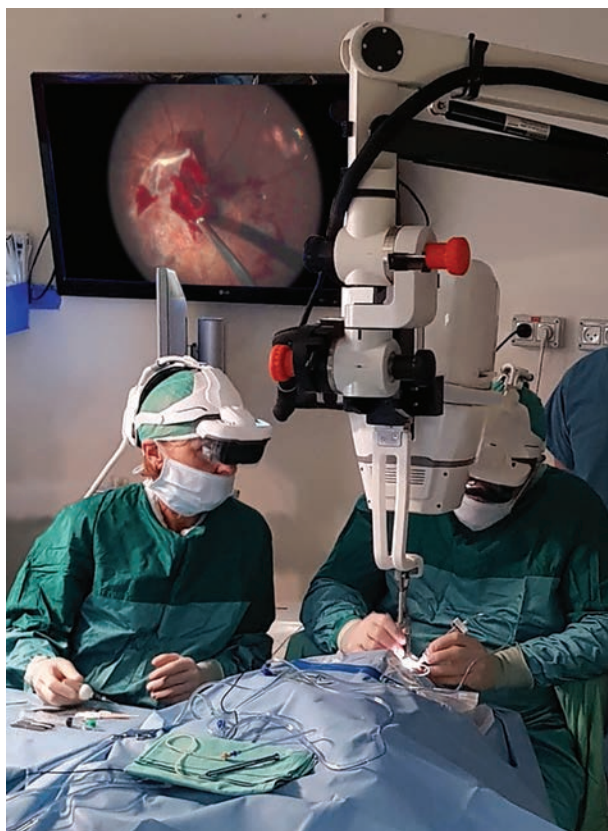

Figure 1. Diabetic retinopathy case. The dual 3-D ultra resolution cameras are suspended on a remote arm. The surgeon and the assistant wear transparent head-mounted displays that allow information to flow toward them in high resolution.

be inserted into the system in an easy, straightforward manner, which is not yet the case with the device. For vitreoretinal surgeons, a very useful ap-

plication will be intraoperative OCT. Offering this is a challenge, however, because when surgeons currently use iOCT systems in conjunction with a surgical microscope, there's always the need for a technician to also be in the room to assist with the iOCT's operation. It's not easy to adjust on the fly or intuitive to operate for one person. In response, Beyeonics is currently working on an iOCT system that would be compatible with Clarity. To be successful, such a system will have to be very accurate and easy to operate. When these types of digital displays are available on the headset, the surgeon will be able to make the best use of the technology.

The Clarity head-mounted display system is still in development, and Beyeonics hopes to get approval for the product in the United States in the next several months, with updated features that

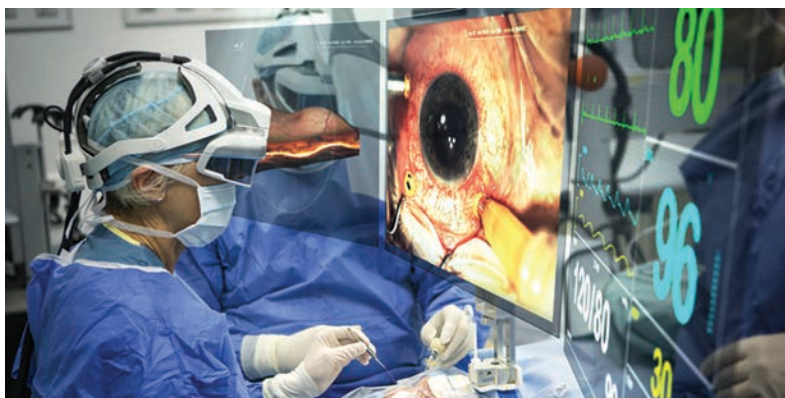

Figure 2. Using head motions, the surgeon can shift between different virtual screens projected onto his retina (simulated above), and control functions such as image focus and transparency. Integration of information from multiple digital sources in real time is also possible.

*Dr. Loewenstein is director of the Ophthalmology department at Tel-Aviv Sourasky Medical Center, where Dr. Barak is head of the Retinal and Vitreous Humor Unit.*

*Drs. Loewenstein and Barak are consultants to Beyeonics Surgical. Mr. Schneider is chief executive officer of Beyeonics Surgical.*

SAVE THE DATE



# 2019 Ophthalmology Update

**FEBRUARY 16-17, 2019 • CARLSBAD, CALIFORNIA**

An interdisciplinary faculty of ophthalmic subspecialists will review the continuing progress in Cataract and Refractive Surgery, Glaucoma, Retina, Neuro-Ophthalmology, Pediatric Ophthalmology, Ocular Surface Disease, Cornea and Oculoplastics.

## LOCATION

Cape Rey Carlsbad, A Hilton Hotel

1 Ponto Road, Carlsbad, CA

P: (760) 602-0800

Limited rooms reserved at \$232.50/night.

Please visit registration site for reservation information.

## PROGRAM CHAIRS

Don O. Kikkawa, MD, FACS

Robert N. Weinreb, MD

## DISTINGUISHED INVITED SPEAKERS

Jacque Duncan, MD

Sanjay Kedhar, MD

Andrea Kossler, MD

Elmer Tu, MD

## PROGRAM TIMES

Saturday, February 16<sup>th</sup>

8:00am – 5:00pm

Reception to follow

Sunday, February 17<sup>th</sup>

8:00am – 12:15pm

## UCSD FACULTY

Natalie Afshari, MD, FACS

Andrew Stephen Camp, MD

Daniel L. Chao, MD, PhD

Michael H. Goldbaum, MD

Weldon W. Haw, MD

Christopher W. Heichel, MD, FACS

Do Jiun, MD, PhD

Bobby S. Korn, MD, PhD, FACS

Jeffrey E. Lee, MD

Catherine Liu, MD, PhD

Eric D. Nudleman, MD, PhD

Shira L. Robbins, MD, FAAO, FAAP

Peter J. Savino, MD

Derek S. Welsbie, MD, PhD

## FOR MORE INFORMATION

Visit: [www.reviewofophthalmology.com/Update2019](http://www.reviewofophthalmology.com/Update2019)

E-mail: [reviewmeetings@jhihealth.com](mailto:reviewmeetings@jhihealth.com)

Phone: 855-851-9964



JOINTLY ACCREDITED PROVIDER™  
INTERPROFESSIONAL CONTINUING EDUCATION

In support of improving patient care, this activity has been planned and implemented by Amedco LLC and Postgraduate Healthcare Education LLC. Amedco LLC is jointly accredited by the Accreditation Council for Continuing Medical Education (ACCME), the Accreditation Council for Pharmacy Education (ACPE), and the American Nurses Credentialing Center (ANCC), to provide continuing education for the healthcare team.

Credit Designation Statement – This activity has been approved for *AMA PRA Category 1 Credit™*.



# Exfoliation Syndrome And Systemic Risk

It's clear that exfoliation affects parts of the body outside the eye; the question is whether that poses a danger to the patient.

*Louis R. Pasquale, MD, FARVO, New York City*

**O**ne issue that often arises when managing a glaucoma patient with exfoliation syndrome is whether the patient should be tested for systemic conditions that might be related to the presence of exfoliation. We know that exfoliation material—an extracellular accumulation of macromolecules with a core of elastin fibers—can form inside the eye, obstructing the outflow system in the trabecular meshwork and leading to elevated IOP and optic nerve damage. In fact, exfoliation syndrome is the leading cause of secondary open-angle glaucoma around the world. However, we also know that in these patients the exfoliation material appears in tissues in other parts of the body. When an individual has exfoliation syndrome, very minute quantities of exfoliation material can be found in organ systems such as the skin, pulmonary tissue, heart and gallbladder. The question is, are those other deposits of clinical importance?

In fact, there's a long list of possible clinical associations between exfoliation syndrome and other conditions that are discussed in the literature. Those possible associations

include myocardial infarction, cerebrovascular disease, renal vascular disease, abdominal aortic aneurysm, elevated homocysteine levels, sensorineural hearing loss, and recently, inguinal hernia and pelvic organ prolapse. Some doctors also believe there may be an association between exfoliation syndrome and Alzheimer's disease.

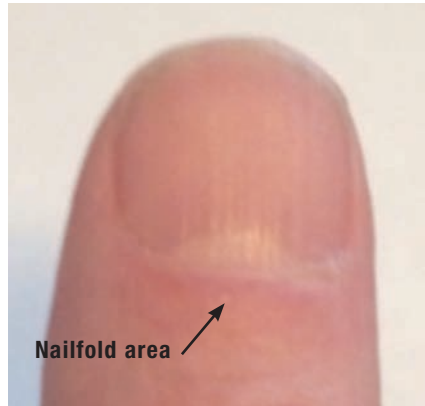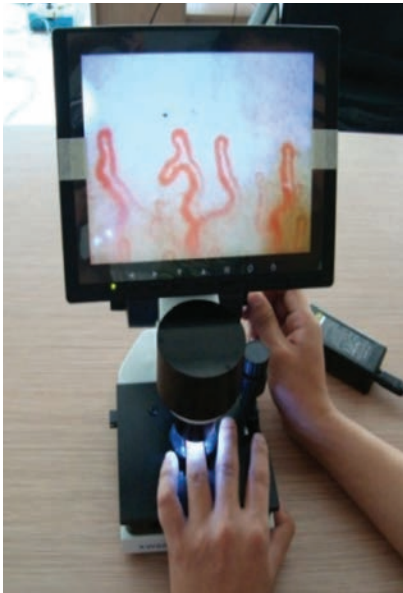
So: Does the presence of exfoliation syndrome warrant us recommending that our patients get a workup for other systemic conditions that might be associated with exfoliation syndrome?

## Evidence of Systemic Impact

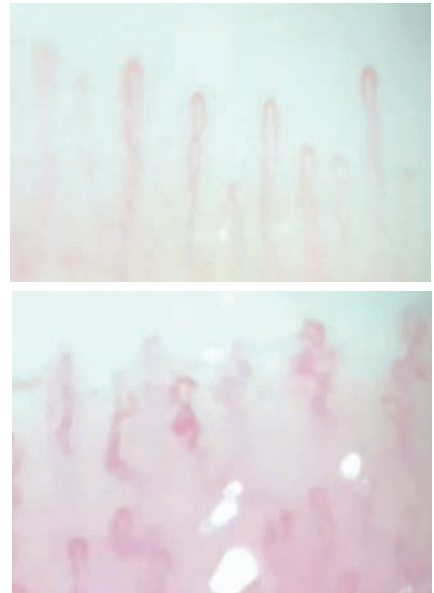
There's no question that the presence of exfoliation can alter physical structures in the body. For example, my colleagues and I have conducted nailfold capillary microscopy in patients with different kinds of glaucoma. This is a useful part of the body to study because the capillary structure can be observed noninvasively. We put some cedar oil on the fourth and fifth digits of the nondominant hand, making the skin translucent; then, our microscope

provides 300X magnification and allows noninvasive visualization of the nailfold capillaries. (*See images, facing page.*) These capillaries are elongated, hairpin-loop vessels resembling tiny skyscrapers; under the microscope you can see the blood coursing through them.

One of the things we discovered was that in exfoliation syndrome, the nailfold capillary morphology is quite different from that seen in healthy patients. The vessels are markedly tortuous, for reasons we don't completely understand, as we recently published.<sup>1</sup> What's interesting is that iris tissue also has these terminal hairpin-loop capillaries, which you can see if you study them under high magnification with fluorescence microscopy. Furthermore, the vessels in the iris are also affected by exfoliation syndrome; their walls become abnormal, encased with exfoliation material. It's possible that this encasement of the vessels also happened in the nailfold, contributing to the vessel tortuosity, although we don't have the evidence to prove it. In any case, this alteration of the nailfold capillaries in the presence



The presence of exfoliation is known to alter physical structures outside of the eye. Here, microscopy reveals the impact of exfoliation on nailfold capillaries. Above right: healthy capillaries. Below: Tortuous nailfold capillaries associated with exfoliation.



of exfoliation syndrome is another indication that the syndrome can have an impact outside the eye.

Other interesting findings have also turned up relating to different diseases. For example, my colleagues and I studied Alzheimer's disease at Boston University; we performed nailfold capillary microscopy on those patients. It turned out that they also had significant nailfold capillary tortuosity compared to controls.<sup>2</sup> This is intriguing, because in Alzheimer's disease cerebral blood vessels are encased in amyloid plaques; in exfoliation syndrome iris vessels are encased in exfoliation material. Perhaps in both cases this is contributing to the tortuosity of the blood vessels.

However, as stated above, this leads to the question: Are these non-ophthalmic manifestations of clinical importance? Do these manifestations indicate, for example, that some percentage of exfoliation syndrome patients are going to get Alzheimer's disease?

## Examining the Data

Despite the long list of possible

clinical associations with exfoliation syndrome discussed in the literature, the evidence supporting those associations is far from conclusive. For example:

- **Alzheimer's disease.** Consider the similarities (or lack thereof) between exfoliation syndrome in the eye and Alzheimer's disease:

- Amyloid is important in Alzheimer's disease, but immunohistochemical studies don't find amyloid in the blood vessels of exfoliation patients.<sup>3</sup>

- Certain peptides can be detected in the blood and cerebrospinal fluid of Alzheimer's disease patients; they're not found in the aqueous humor of exfoliation syndrome patients.<sup>4</sup>

- What we know about the genetics of the two diseases doesn't jibe; for example, there's a fairly robust association between common variants of LOXL1 and exfoliation syndrome, but these genetic variants are not associated with Alzheimer's disease.<sup>5</sup>

- A population-based study done in China found no association between cognitive function and exfoliation syndrome.<sup>6</sup>

So although Alzheimer's disease

and exfoliation syndrome share some common pathophysiologic motifs, they're not pathogenetically linked—at least based upon the data we have so far.

- **Cardiovascular disease.** A recent meta-analysis of 16 studies looked at associations between various cardiovascular manifestations and exfoliation; all of the studies found a positive association.<sup>7</sup> However, there are reasonable concerns about whether these results were confounded by aging, so it's possible that this is just a comingling of systemic disease with exfoliation syndrome—not a true association. To determine a connection more definitively, we need prospective studies that can determine whether patients who are disease-free at baseline but end up getting cardiovascular disease are more likely to get exfoliation syndrome.

- **Systolic blood pressure.** One well-powered study conducted in India found that systolic blood pressure was indeed higher in patients with exfoliation syndrome, but it was not high enough to meet a definition of systemic hypertension.<sup>8</sup>

- **Hearing loss.** Although a

### Exfoliation Syndrome and All-cause Mortality

Study	Study Duration	Comparison Group	Outcome
Ringvold et al. 1997	10 years	Non-XFS patients	No difference in all-cause mortality
Ritland et al. 2004	10 years	POAG patients	No difference in all-cause mortality
Tarkkanan et al. 2014	7 years	Non-XFS patients	XFS patients live longer
Svensson & Ekstron 2015	30 years	Non-XFS patients	No difference in all-cause mortality
Slettedal et al. 2015	30 years	Non-XFS patients	No difference in all-cause mortality

number of studies have found some link between exfoliation syndrome and hearing loss, one recent study found no such association.<sup>9</sup>

• **Homocysteine levels.** Homocysteine levels are slightly higher in serum, aqueous humor and tears of exfoliation syndrome patients compared to healthy controls. However, the largest study comparing homocysteine levels between patients with exfoliation syndrome and controls, done in India by Ashok Vardhan, DO, and colleagues, found no connection.<sup>8</sup>

This study, incidentally, was much larger than all of the other small studies relating to this put together. In fact, articles in the internal medicine literature are beginning to question whether the perceived association between homocysteine levels and cardiovascular disease is real.

• **Pelvic organ prolapse.** The Utah Population Database did find that exfoliation syndrome was more prevalent in women with pelvic organ prolapse, so it's possible that such an association is valid.<sup>10</sup>

Perhaps most importantly, studies looking at the mortality of individuals with exfoliation syndrome don't support the idea that they die earlier than healthy controls. (*See table, above.*) After all, if exfoliation syndrome is truly associated with conditions such as Alzheimer's disease, cardiovascular disease or stroke, one would expect that it would also be associated with premature death.

As it turns out, that's not what the current literature shows. In fact, one of those studies actually concluded that exfoliation patients live longer than individuals without exfoliation.

Of course, the cited mortality studies have limitations. For example, all of them were done in Scandinavian countries, and they only evaluated exfoliation syndrome status at baseline; they didn't update the status on an interim basis on follow-up. Nevertheless, if individuals who have exfoliation syndrome are more likely to die young, the evidence of that hasn't shown up in the literature so far.

### No Reason for Concern—Yet

The bottom line is that although exfoliation materials are associated with elastic and collagen fibers throughout the body, no robust systemic association between exfoliation syndrome and other health issues has been confirmed by prospective studies. Yes, the literature has raised enough red flags to justify some concern, but a careful examination suggests that no real association has been demonstrated. It's certainly possible that clear associations between exfoliation syndrome and systemic health issues may be found in the future; it's just that more studies need to be done.

In the meantime, not every doctor managing exfoliative glaucoma worries about this—although I've

heard doctors who have exfoliation syndrome themselves express concern about whether they should be checked for other health problems. For now, the evidence supporting such a connection is weak, and the most persuasive evidence that there isn't any association between exfoliation syndrome and systemic disease may be that patients with exfoliation syndrome don't appear to die prematurely.

So, when asked whether I believe that patients with exfoliation syndrome should have a systemic work-up of some kind, my answer is no—at least based on the evidence we have today. **REVIEW**

*Dr. Pasquale is site chair of the Department of Ophthalmology at Mount Sinai Hospital in New York, and professor and system vice chair for translational ophthalmology research in the Department of Ophthalmology at the Icahn School of Medicine at Mount Sinai. Dr. Pasquale is a consultant to Bausch + Lomb, Eyenovia and Verily; he has received NIH funding to study exfoliation syndrome.*

- Cousins CC, Kang JH, Bovee C, et al. Nailfold capillary morphology in exfoliation syndrome. *Eye (Lond)* 2017;31:5:698-707.
- Cousins CC, Alosco ML, Cousins HC, et al. Nailfold capillary morphology in Alzheimer's disease dementia. *J Alzheimers Dis* 2018;66:2:601-611.
- Ritch R, Schlötzer-Schrehardt U. Exfoliation syndrome. *Surv Ophthalmol* 2001;45:4:265-315.
- Janciauskiene S, Westin K, Grip O, Krakau T. Detection of Alzheimer peptides and chemokines in the aqueous humor. *Eur J Ophthalmol* 2011;21:1:104-11.
- Abramsson A, Landgren S, Zetterberg M, et al. No association of LOX1 gene polymorphisms with Alzheimer's disease. *Neuromolecular Med* 2011;13:2:160-6.
- Xu L, You QS, Wang YX, Jonas JB. Cognitive function and pseudoexfoliation syndrome. *The Beijing Eye Study* 2011. *Br J Ophthalmol* 2013;97:9:1215.
- Aviv U, Ben Ner D, Sharif N, Gur Z, Achiron A. Pseudoexfoliation: An ocular finding with possible systemic implications. *Isr Med Assoc J* 2017;19:1:49-54.
- Vardhan SA, HariPriya A, Ratukondla B, et al. Association of pseudoexfoliation with systemic vascular diseases in a South Indian population. *JAMA Ophthalmol* 2017;135:4:348-354.
- Tryggvason G, Jonasson F, Cotch MF, et al. Hearing in older adults with exfoliation syndrome/exfoliation glaucoma or primary open-angle glaucoma. *Acta Ophthalmol* 2016;94:2:140-6.
- Wirostko BM, Curtin K, Ritch R, et al. Risk for exfoliation syndrome in women with pelvic organ prolapse: A Utah Project on Exfoliation Syndrome (UPEXS) study. *JAMA Ophthalmol* 2016;134:11:1255-1262.

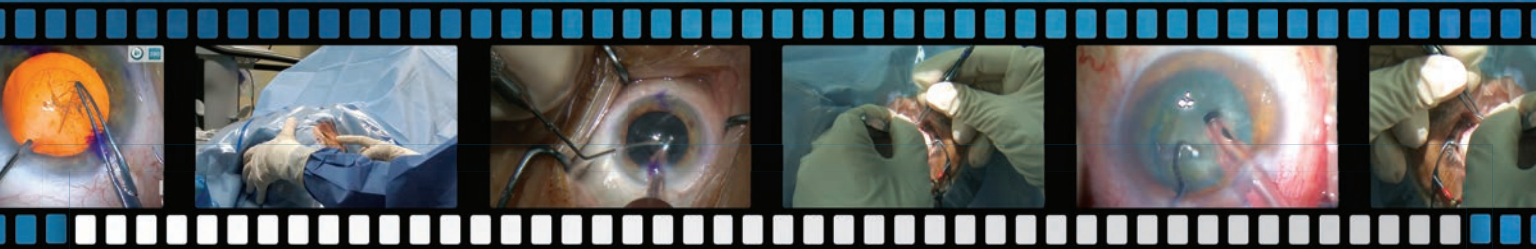




Monthly

# MACKOOL ONLINE CME

## CME SERIES | SURGICAL VIDEOS



To view CME video  
go to:

[www.MackoolOnlineCME.com](http://www.MackoolOnlineCME.com)

### Episode 38:

#### “Endothelial Protection for a Patient with Advanced Endothelial Dystrophy”

Surgical Video by:  
Richard J. Mackool, MD

#### Video Overview:

Endothelial protection is always important, though in a patient with severe corneal dystrophy and a shallow anterior chamber, it is even more critical. In this case, I discuss several pearls for safe removal of the nucleus in a patient with a severely compromised endothelium.

## MackoolOnlineCME.com MONTHLY Video Series



Richard J. Mackool, MD

We are excited to continue into our fourth year of Mackool Online CME. With the generous support of several ophthalmic companies, I am honored to have our viewers join me in the operating room as I demonstrate the technology and techniques that I have found to be most valuable, and that I hope are helpful to many of my colleagues. We continue to edit the videos only to either change camera perspective or to reduce down time - allowing you to observe every step of the procedure.

As before, one new surgical video will be released monthly, and physicians may earn CME credits or just observe the case. New viewers are able to obtain additional CME credit by reviewing previous videos that are located in our archives.

I thank the many surgeons who have told us that they have found our CME program to be interesting and instructive; I appreciate your comments, suggestions and questions. Thanks again for joining us on Mackool Online CME.



**CME Accredited Surgical Training Videos Now Available Online: [www.MackoolOnlineCME.com](http://www.MackoolOnlineCME.com)**

Richard Mackool, MD, a world renowned anterior segment ophthalmic microsurgeon, has assembled a web-based video collection of surgical cases that encompass both routine and challenging cases, demonstrating both familiar and potentially unfamiliar surgical techniques using a variety of instrumentation and settings.

This educational activity aims to present a series of Dr. Mackool's surgical videos, carefully selected to address the specific learning objectives of this activity, with the goal of making surgical training available as needed online for surgeons motivated to improve or expand their surgical repertoire.

#### Learning Objective:

*After completion of this educational activity, participants should be able to:*

- present techniques that reduce endothelial trauma during phacoemulsification

**Satisfactory Completion** - Learners must pass a post-test and complete an evaluation form to receive a certificate of completion. You must listen to/view the entire video as partial credit is not available. If you are seeking continuing education credit for a specialty not listed below, it is your responsibility to contact your licensing/certification board to determine course eligibility for your licensing/certification requirement.



JOINTLY ACCREDITED PROVIDER™  
INTERPROFESSIONAL CONTINUING EDUCATION

**Physicians** - In support of improving patient care, this activity has been planned and implemented by Amedco LLC and Postgraduate Healthcare Education. Amedco LLC is jointly accredited by the Accreditation Council for Continuing Medical Education (ACCME), the Accreditation Council for Pharmacy Education (ACPE), and the American Nurses Credentialing Center (ANCC), to provide continuing education for the healthcare team

**Credit Designation Statement** - Amedco designates this enduring material activity for a maximum of .25 AMA PRA Category 1 Credits™. Physicians should claim only the credit commensurate with the extent of their participation in the activity.

Endorsed by:  
**Review of Ophthalmology®**  
Video and Web Production by:  
**JR Snowdon, Inc**

Jointly provided by:  
**AMEDCO & PHE**

Supported by an unrestricted independent  
medical educational grant from:  
**Alcon**

Additionally Supported by:  
**Glaukos  
MST  
Crestpoint Management  
Carl Zeiss Meditec**

In Kind Support:  
**Sony Healthcare  
Solutions**

25<sup>TH</sup> ANNUAL

# OPHTHALMIC

## *Product Guide*



Innovative products to  
enhance your practice

The **future**  
is in your  
hands. One  
tap, many  
possibilities.

Experience the digital edition on your handheld device.  
Use your smart device to scan the code below or visit:



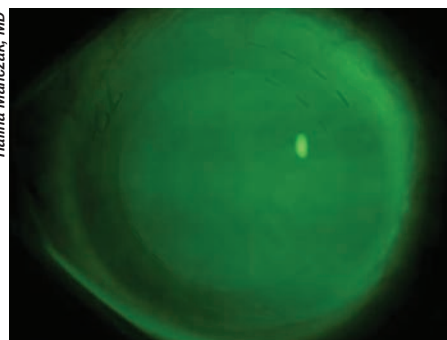
[www.reviewofophthalmology.com/publications/archive](http://www.reviewofophthalmology.com/publications/archive)

Download a QR scanner app. Launch app and hold your mobile device over  
the code to view [www.reviewofophthalmology.com/publications/archive](http://www.reviewofophthalmology.com/publications/archive).

**REVIEW**<sup>®</sup>  
of Ophthalmology

# Digiform Therapeutic Dry-eye Treatment

**A new therapeutic** option for dry eye and ocular-surface conditions is now available with the recent release of DigiForm Scleral Lenses in Optimum Extra and Optimum Extreme. The product is the result of a partnership between TruForm Optics and Contamac. The materials used in the lenses maintain the lowest wetting angles in the industry, the company says, allowing patients suffering from dry-eye conditions, corneal distortion or surface irregularities to benefit. The company adds that the lens design has a forgiving lens-to-sclera relationship and provides

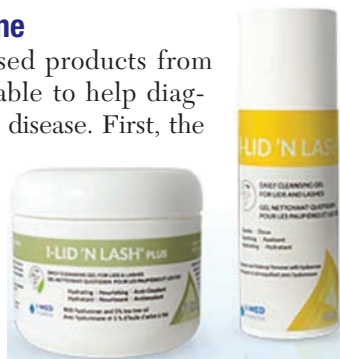

Halina Manczak, MD

an aqueous-hydrated environment and saline bath. They also offer an option for a lens coating, Tangible HydrA-PEG, that the company says can improve wettability, lubricity, deposit resistance and tear-film quality. For information, call (800) 792-1075.

## New I-MED Product Line

A slew of newly released products from I-MED Pharma is available to help diagnose and manage dry-eye disease. First, the I-Lid 'N Lash product line cleans and removes ocular debris and makeup to maintain lid and lash health, in addition to fighting meibomian gland dysfunction. It's



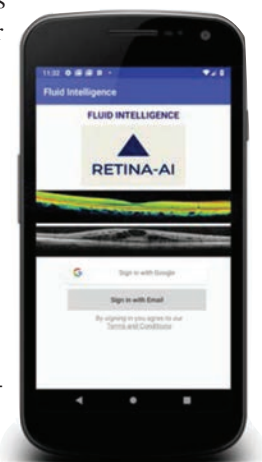
water-based and contains hydrating ingredients that soothe inflamed skin while removing makeup.

Second, I-Relief, which is a hot-and-cold therapy eye mask, can improve ocular health with consistent use over time, the company says, by increasing blood circulation and lipid oil production and reducing tear evaporation. Thermabeads within the mask help to maintain temperature and hydration while the soft cloth fabric and contouring effect aid in the comfortable fit.

Lastly, the SMTube is a quantitative way to measure tear function, which the company says is an important step in diagnosing dry-eye syndrome. The SMTube is a rapid, reliable, noninvasive product that works by absorbing tears, I-MED says. Visit [imedpharma.com](http://imedpharma.com).

## AI in Eye Care

Retina-AI says that improving patient care may have just gotten easier with the release of its new Android app, Fluid-Intelligence. The world's first app that harnesses the power of artificial intelligence for eye-care professionals can screen for common retinal diseases, the company says. When the app is used to take a photo of an OCT scan, the image is analyzed in the cloud, where a machine-learning algorithm works to detect macular edema and subretinal fluid. AI then determines the diagnosis and generates a real-time report. In a study that compared the assessment of OCT scans by retina specialists with that made by the app, initial results found a sensitivity of 90 percent and a specificity of 82.5 percent. For information, visit [retina-ai.com](http://retina-ai.com). **REVIEW**



# Adding Anastomoses to Anti-VEGF for CRVO

**A** randomized clinical trial, which took place at the Lions Eye Institute in Perth, Western Australia, was conducted to compare the efficacy of treating central retinal vein occlusion using only intravitreal ranibizumab, versus combining the anti-VEGF treatment with a laser-induced chorioretinal anastomosis (L-CRA).

Researchers note that ranibizumab, which is the current treatment for CRVO, aims to treat either macular edema or anterior segment neovascularization and doesn't address causal pathology. Since using a laser to effectively bypass the obstructed venous outflow that exists in CRVO has already been studied, the research was designed to discover whether adding the use of L-CRA to the current anti-VEGF treatment technique would improve outcomes and therefore lessen the therapy burden on both patients and physicians.

Over the course of the two-year study, 58 patients with macular edema caused by CRVO participated. Twenty-nine of them received both intravitreal ranibizumab and L-CRA treatment, while another 29 patients received intravitreal ranibizumab plus a sham L-CRA treatment. The primary criterion for interpreting efficacy was the number of injections that took place during the follow-up period of months seven to 24. They also analyzed changes in BCVA and central

subfield thickness.

The study found that the addition of L-CRA laser treatment to intravitreal ranibizumab significantly reduced the number of injections that were required during the follow-up period. As a result, researchers say that this approach has the potential to decrease the therapy burden on both patients and physicians. For patients, since the study findings suggest fewer ranibizumab injections are needed with the addition of L-CRA treatment, this approach has the potential to reduce the financial burden associated with recurrent injections. Similarly, physicians can have a reduced therapy burden due to a decreased number of patient follow-up visits.

*JAMA Ophthalmology* 2018;136:1391-1398.

McAllister I, Smithies L, Chen F, et al.

## Treat-and-extend Trial in nAMD: The CANTREAT Study

Researchers compared the efficacy of ranibizumab using a treat-and-extend regimen to monthly dosing in treatment-naïve subjects with neovascular age-related macular degeneration, as part of a prospective, randomized, open-label, multicenter, noninferiority post-authorization study.

Participants included treatment-naïve subjects with choroidal neovascularization secondary to AMD.

Subjects with nAMD were randomized 1:1 to receive intravitreal ranibizumab at a dose of 0.5 mg in a T&E or monthly dosing regimen.

The non-inferiority of T&E compared with the monthly dosing regimen was shown using a margin of five letters in best-corrected visual acuity improvement.

The main outcome measure was mean change in BCVA Early Treatment Diabetic Retinopathy Study letters from baseline to month 12. Baseline and 12-month visual acuity data were available for 526 individuals (T&E: n=268; monthly: n=258). Below are some of the results:

- At baseline, mean age was 78.8 ±7.8 years: 60.3 percent were females and 94.3 percent were Caucasian. No significant between-group baseline differences were observed.

- The primary outcome of non-inferiority regarding visual acuity was met with mean BCVA improvement of 8.4 ±11.9 letters in the T&E group and 6 ±11.9 letters in the monthly group ( $p=0.017$ ), with a between-group mean difference of 2.38 (CI, 0.32 to 4.45).

- Per protocol, a secondary analysis was performed to test for superiority of number of injections received up to month 12. This analysis demonstrated significantly fewer injections with T&E (9.4) vs. monthly (11.8) dosing, with a mean difference of -2.46 (CI,

-2.68 to -2.23).

Researchers determined that 12-month results of the two-year study revealed that, with regard to visual outcomes, the T&E regimen was noninferior to a monthly dosing regimen. They added that visual outcomes similar to those of the monthly dosing group were achieved in the T&E group with significantly fewer injections.

*Ophthalmology* 2019; Jan 21.  
[Epub ahead of print]  
Kertes PJ, Galic IJ, Greve M, et al.

## Nerve Fiber Layer Thinning with PDR Treatment

In a recent randomized, prospective study conducted by the Diabetic Retinopathy Clinical Research Network, clinicians documented the nerve fiber layer thinning associated with intravenous ranibizumab or panretinal photocoagulation treatments for proliferative diabetic retinopathy. The researchers note that while anti-VEGF treatment and PRP have been shown through various studies to decrease RNFL thickness, they sought to understand the thinning mechanism in both treatment groups. Also, since RNFL thickness measurements can be used to monitor glaucoma progression, they also sought to determine whether changes in RNFL thickness through intravitreal ranibizumab or PRP interventions might affect their ability to monitor glaucoma in these eyes.

Out of 120 patients and 146 eyes being treated, 74 were assigned to be treated with intravitreal ranibizumab, while 66 were treated using PRP. Various tests were performed and compared, including baseline and annual follow-up spectral domain optical coherence tomography RNFL imaging, OCT macular imaging and automated static perimetry.

After two years, the study found that RNFL thickness decreased  $10.9 \pm 11.7 \mu\text{m}$  in ranibizumab users and

decreased  $4.3 \pm 11.6 \mu\text{m}$  for PRP patients. The correlation between change in RNFL thickness and 60-4 Humphrey visual field mean deviation was  $-0.27$  ( $p=0.07$ ) for ranibizumab and  $+0.33$  ( $p=0.035$ ) for PRP. Finally, a correlation was noted between change in RNFL thickness and central subfield thickness  $+0.63$  ( $p<0.001$ ) and  $+0.34$  ( $p=0.005$ ) respectively.

These results indicate that patients being treated with intravitreal ranibizumab had greater thinning of the RNFL after two years. A strong correlation between decreased RNFL thickness and central OCT subfield in eyes treated with ranibizumab was evident. This in conjunction with no visual-acuity or visual-field loss showed that decreased edema of the inner retina was the mechanism lowering RNFL thickness in ranibizumab users. Due to fluid changes in the inner retina that may cause RNFL thinning, it was suggested to not use OCT-derived thickness measurements as a method of glaucoma diagnosis or monitoring in PDR patients being treated with ranibizumab.

*Retina* 2019;39:69-78.  
Jampol L, Odia I, Glassman A, et al.

## FLACS vs. Phaco Study

Researchers from the United Kingdom recently performed a randomized, controlled trial comparing femtosecond laser-assisted cataract surgery with conventional phaco surgery (CPS), and it ended in nearly a dead heat. The study was supported by a grant from Alcon Labs, but the researchers say the company had no role in the design or the conduct of the research.

The surgeons randomized 400 cataract patients to FLACS or CPS, and measured the visual acuity, refraction, central corneal thickness (CCT), central foveal thickness (CFT), endothelial cell loss, and rates of intraoperative and postoperative events. They

also measured quality-of-life impact with questionnaires.

Here are the main results:

- the mean uncorrected distance visual acuity as measured by the logarithm of the minimum angle of resolution [logMAR] was similar:  $0.15 \pm 0.21$  (between 20/25 and 20/32) after CPS and  $0.15 \pm 0.19$  logMAR after FLACS ( $p=1.0$ );
- pinhole-corrected visual acuity was  $0.04 \pm 0.12$  (a little worse than 20/20) after CPS and  $0.04 \pm 0.12$  after FLACS ( $p=1.0$ );
- the increase in CCT showed no significant difference, with  $13 \pm 19 \mu\text{m}$  for phaco and  $15 \pm 25 \mu\text{m}$  for FLACS ( $p=0.5$ );
- endothelial cell loss was similar, sitting at  $9.7 \pm 13.7$  percent for conventional phaco and  $10.2 \pm 13.7$  percent for FLACS ( $p=0.76$ );
- manifest refraction spherical equivalent error was similar, measuring  $-0.14 \pm 0.60$  D after CPS and  $-0.12 \pm 0.60$  D after FLACS ( $p=0.74$ ); and
- the mean change in CFT showed no overall difference; it was  $9 \pm 35 \mu\text{m}$  after CPS and  $6 \pm 35 \mu\text{m}$  post-FLACS ( $p=0.55$ ).

There was a statistically significant reduction in posterior capsule rupture with FLACS (no ruptures vs. 3 percent having ruptures following CPS,  $p=0.03$ ). The surgeons say that even though one more rupture in the femto group, or one fewer in the phaco group, would have rendered this non-statistically significant, it's an important finding due to the associated risks of further complications during the postop phase. Interestingly, the amount of phacoemulsification energy wasn't statistically significantly different between the groups. The researchers theorize this may be due to their preference for segmentation of the cataract rather than fragmentation into cubes.

*J Cataract Refract Surg* 2019; 45:1:11-20.

Roberts HW, Wagh VK, Sullivan DL, Hidzheva P, Detesan DI, Heemraz BS, Sparrow JM, O'Brart DPS.

Career Opportunities

**OPHTHALMOLOGISTS**  
Danbury, CT

Ophthalmologists to share office with long standing Ophthalmologist in Danbury, CT. High quality equipment. \$2,250 per month or adjoining office without equipment- \$1,750 per month.

203-545-3539 or  
email [mehrimd@aol.com](mailto:mehrimd@aol.com)



**Do you have Products and Services for sale?**

CONTACT US TODAY  
FOR CLASSIFIED ADVERTISING  
Toll free: 888-498-1460  
E-mail: [sales@kerhgroup.com](mailto:sales@kerhgroup.com)



# Targeting Ophthalmologists?

**CLASSIFIED ADVERTISING WORKS**



Contact us today  
for classified advertising:  
Toll free: **888-498-1460**  
E-mail: [sales@kerhgroup.com](mailto:sales@kerhgroup.com)



# Targeting Ophthalmologists?

**CLASSIFIED ADVERTISING WORKS**

- JOB OPENINGS
- CME PROGRAMS
- PRODUCTS & SERVICES
- AND MORE...

Contact us today for classified advertising:  
Toll free: **888-498-1460**  
E-mail: [sales@kerhgroup.com](mailto:sales@kerhgroup.com)





A 10-year-old boy presents to the Wills emergency room with double vision.

*Cherie A. Fathy, MD, Jason Flamendorf, MD, and Robert B. Penne, MD*

## Presentation

A 10-year-old Caucasian male presented to the Wills emergency room with a chief complaint of double vision. Five days prior to the onset of visual symptoms, his mother noticed nasal redness in both of his eyes. Three days prior to presentation, the patient developed constant binocular horizontal diplopia that was worst in left gaze. He also reported pain with extraocular movements and a headache.

## Medical History

The patient had no significant past medical or surgical history, and he wasn't taking any medications. Family history was notable for multiple family members with hyperthyroidism and hypothyroidism, including a grandfather with Graves' disease. Social history was non-contributory. The review of systems was significant for weight gain over the past year.

## Examination

Ocular examination revealed a visual acuity of 20/20 OU. Pupils and confrontation visual fields were normal OU. Intraocular pressures were 17 mmHg OD and 18 mmHg OS. Extraocular motility of the right eye was notable for 20-percent adduction, 40-percent abduction, 30-percent elevation, and 100-percent depression. The left eye had 40-percent adduction, 90-percent abduction, 30-percent elevation and 100-percent depression (*Figure 1*). Ishihara color plates were 11/11 OU. External examination demonstrated 3 mm of proptosis of the right globe measured by Hertel exophthalmometry, with both globes exhibiting resistance to retropulsion. Right upper eyelid ptosis was present, and hypesthesia in the V1 and V2 dermatomes was absent. Anterior segment examination revealed nasal chemosis and injection OU but was otherwise unremarkable. Dilated fundus examination was normal OU.

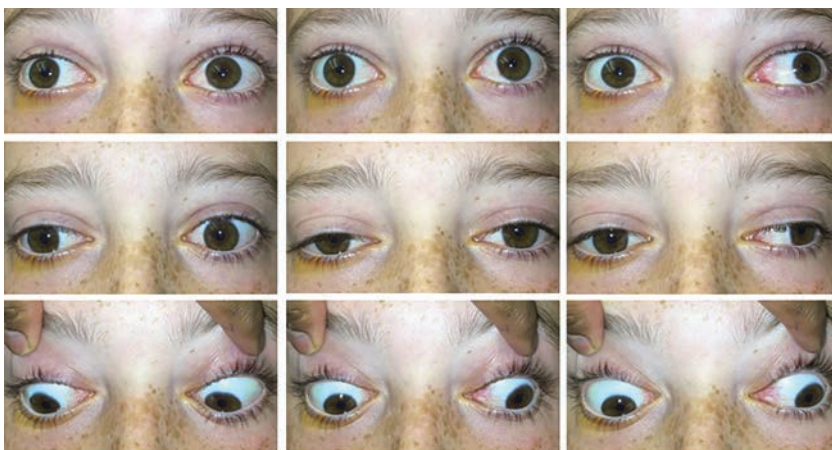

Figure 1. Extraocular motility demonstrating limitations in adduction, abduction and elevation in both eyes.

**What is your diagnosis? What further workup would you pursue? The diagnosis appears on p. 64.**

## Workup, Diagnosis and Treatment

Magnetic resonance imaging of the brain and orbits with and without contrast was obtained emergently and demonstrated “diffusely enlarged and edematous extraocular muscles with sparing of the tendinous insertions” (*Figure 2*). Additional laboratory and imaging studies were obtained, including a complete blood count with differential, erythrocyte sedimentation rate, c-reactive protein test, Lyme antibodies, thyroid testing, serum angiotensin converting enzyme, blood urea nitrogen test, creatinine, IgG4 antibodies, antineutrophil cytoplasmic antibodies, antinuclear antibodies, lactate dehydrogenase, uric acid, Quantiferon-gold, and a chest X-ray. While in the emergency room, the patient received empiric treatment with 6 mg of IV dexamethasone but didn’t have any significant improvement in his symptoms or exam. In addition, he had a thyroid-stimulating hormone elevated to 16.11 (normal 0.3-5.0 mU/mL) but a normal level of free T4. ESR was also elevated, but the CBC, CRP and chest X-ray were normal. All other testing was pending. Given the absence of optic nerve involvement, he was started on 40 mg of prednisone daily and discharged with a plan to follow up in the Wills Eye ophthalmology service.

At follow-up three days later, the patient reported resolution of the double vision. Ocular examination revealed decreasing proptosis of the right globe and significantly improved extraocular motility; the motility deficit was more parietic than restrictive. A secondary review of the

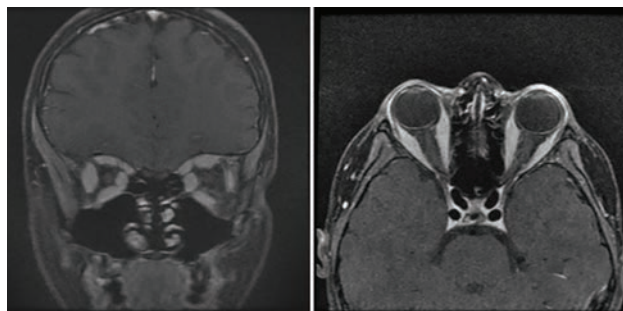


Figure 2. T1-weighted, post-contrast MRI of the orbits showing diffuse extraocular muscle enlargement without tendon sparing.

MRI called into question the presence of tendon sparing. All of the remaining testing was normal, including a thyroid-stimulating immunoglobulin. This compilation of findings and the rapid response to steroids made idiopathic orbital inflammation the most likely diagnosis.

A repeat TSH measured two weeks later was 8.750; free T4 and T3 were normal. The patient was referred to a pediatric endocrinologist who didn’t find any evidence of thyroid disease and explained that elevations in TSH can occur in peripubescent children. The patient’s extraocular motility deficits, ptosis and proptosis completely resolved two weeks after starting steroids, which were slowly tapered (*Figure 3*). At his follow-up appointment three months after initial presentation, he was off all steroids without any signs or symptoms of recurrence.

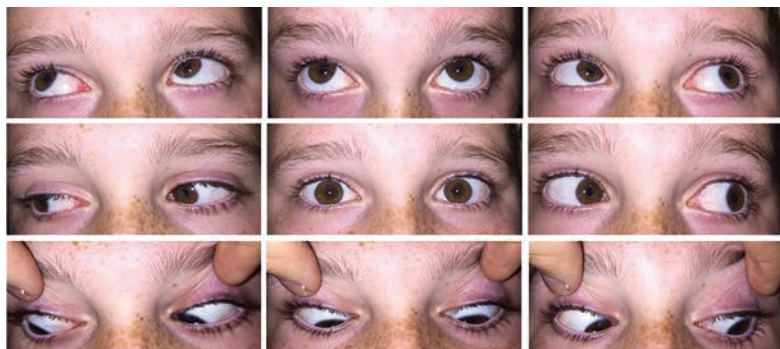

Figure 3. Extraocular motility with dramatic improvement shortly after starting oral steroids.

## Discussion

The differential diagnosis of extraocular muscle enlargement in the pediatric population is broad and includes inflammatory (thyroid eye disease, idiopathic orbital inflammation), infectious and neoplastic etiologies.

The initial findings in our case suggested thyroid eye disease as an etiology. Pediatric thyroid disease is a rare condition with an incidence of 0.1 to three cases per 100,000 children, and thyroid-associated ophthalmopathy

(TAO) has an incidence of 0.8 to 6.5 cases per 100,000 children with thyroid disease.<sup>1,2,3</sup> The mean age at diagnosis is 12.4 to 15 years, with two-thirds being postpubescent adolescents.<sup>1,3</sup> TAO is generally milder in children, and the most common manifestations are lid retraction, proptosis and soft tissue involvement.<sup>1,2,3</sup> Restrictive strabismus and optic neuropathy are uncommon in the pediatric population, but when they do occur, are more likely complications



in postpubescent children.<sup>1,2</sup> This may be related to an increase in smoking prevalence in older children, which is a known risk factor for TAO.<sup>1</sup> Although the patient in our case had an extensive family history of thyroid disease and an elevated TSH, the patient's age and paretic motility deficits were inconsistent with TAO, and the TSH was explained by peripubescent hormonal changes.

As the clinical course unfolded, idiopathic orbital inflammation (IOI) became the most likely diagnosis in the presence of an unrevealing work-up and rapid response to steroids. IOI was first described in 1905 and was initially referred to as "orbital pseudotumor" because of its appearance as a benign, non-infectious, space-occupying lesion in the orbit, or enlargement of an orbital structure.<sup>4</sup> A diagnosis of exclusion, its etiology is still unknown, although autoimmune disorders, upper respiratory infections, viral illnesses and aberrant wound healing have all been proposed as possible mechanisms for pathogenesis.<sup>4</sup> IOI can be divided into two anatomic subgroups: nonmyositic (e.g., dacryoadenitis, orbital fat inflammation) and myositic.

A consensus study based on surveys completed by members of the Orbital Society defined a set of criteria for the diagnosis of IOI.<sup>5</sup> Orbital pain, and pain with eye movements in the case of myositic IOI, are important criteria, as well as an acute or subacute onset (days or weeks), usually with a slow progression. Since IOI is diagnosed in the absence of an underlying etiology, a history of orbital-related systemic disease shouldn't be present, nor should thyroid disease in the setting of myositic IOI. While CT or MRI are important for localizing the anatomic compartment involved, serologies such as inflammatory markers and autoantibodies play a limited role as they may be falsely negative in patients with disease limited to the orbit or with mild systemic disease.

Nonmyositic IOI requires a pathologic diagnosis, with histopathology usually showing a nonspecific, polymorphous infiltrate of small, well-differentiated lymphocytes (primarily T cells), plasma cells, and neutrophil and eosinophil granulocytes.<sup>6</sup> Myositic IOI, on the other hand, can be diagnosed by an avid response to corticosteroids within 48 hours of initial administration.

A review of 30 cases of pediatric IOI found that the mean age of onset was 11 years, with a female predominance. Headache was the most common constitutional symptom, and signs on exam were similar to adults, including periorbital edema, ptosis and proptosis. In contrast to pediatric TAO, more than one-third of children with IOI had decreased extraocular movements. The most common radiographic findings included dacryoadenitis, orbital mass and myositis.<sup>7</sup> Another case series of 29 pediatric patients with IOI found that only 10.3 percent had bilateral involvement at the onset of disease, but 44.8 percent eventually developed bilateral disease. Patients with bilateral disease were more likely to have a motility disturbance (76.9 percent) compared to those with unilateral disease (56.3 percent). In addition, 92.3 percent of patients with bilateral disease developed recurrences, with an average of 4.7 episodes.<sup>8</sup> Females were also more likely to develop recurrent disease.<sup>7</sup>

Treatment of pediatric IOI, like the adult form of the disease, is dependent on disease severity, clinical and radiologic findings and initial versus recurrent disease. One case series reported that 80 percent of patients were treated with oral steroids with a starting dose of 1mg/kg/day.<sup>7</sup> Appropriately responding cases showed improvement in two to three days.<sup>7</sup> For those cases that did not respond, patients received IV steroids, rituximab, IVIG and/or radiation, with 83

percent achieving complete resolution at last follow-up. Local treatment in the form of a perimuscular injection of betamethasone suspension in 12 adults with orbital myositis led to complete resolution within one to two weeks and only one recurrence 14 months after the initial injection.<sup>9</sup>

Orbital myositis may not need to be routinely biopsied.<sup>5,7</sup> Indications for biopsy include the absence of pain, subacute onset, a restrictive pattern of extraocular motility deficits, and either a failure to respond to corticosteroids or a disease recurrence while tapering. Furthermore, atypical imaging findings that may be indications for biopsy include irregular edges, nodularity, focal intramuscular mass on imaging, orbital fat infiltration, lacrimal gland enlargement or swelling, orbital nerve enlargement, and/or sinus disease.<sup>5</sup>

In conclusion, IOI is an orbital inflammatory disease of unknown etiology that occurs in the absence of known systemic disease with orbital manifestations. Although often unilateral, bilateral disease is more common in the pediatric population, as demonstrated in our case. IOI usually responds to corticosteroids but may require biopsy followed by other types of immunosuppression in refractory or recurrent cases. **REVIEW**

1. Gogakos AI, Boboridis K, Krassas GE. Pediatric aspects in Graves' orbitopathy 2010;7:234-244.

2. Holt H, Hunter DG, Smith J, et al. Pediatric Graves' ophthalmopathy: The pre- and postpubertal experience. J AAPOS 2008;12:4:357-360.

3. Durairaj VD, Bartley GB, Garrity JA. Clinical features and treatment of Graves ophthalmopathy in pediatric patients. Ophthal Plast Reconstr Surg 2006;22:7-12.

4. Birch-Hirschfeld A. Zur diagnostic and pathologic der orbital tumoren. Ber Dtsch Ophthalmol Ges 1905;32:127-35.

5. Mombaerts I, Bilyk JR, Rose GE, et al. Consensus on diagnostic criteria of idiopathic orbital inflammation using a modified delphi approach. JAMA Ophthalmol 2017;135:769-776.

6. Mombaerts I, Goldschmeding R, Schlingemann RO, et al. What is orbital pseudotumor? Surv Ophthalmol 1996;41:66-78.

7. Spindle J, Tang SX, Davies B, et al. Pediatric idiopathic orbital inflammation: Clinical features of 30 Cases. Ophthal Plast Reconstr Surg 2016;32:270-4.

8. Mottow LS, Jakobiec FA. Idiopathic inflammatory orbital pseudotumor in childhood. I. Clinical characteristics. Arch Ophthalmol 1978;96:1410-7.

9. El Nasser A, Mohammad A. Local steroid injection for management of different types of acute idiopathic orbital inflammation: An 8-year study. Ophthal Plast Reconstr Surg 2013;29:286-9.

<b>Akorn Consumer Health</b>	<b>21</b>
Phone	(800) 579-8327
	<a href="http://www.akornconsumerhealth.com">www.akornconsumerhealth.com</a>
<b>Bausch + Lomb</b>	<b>12</b>
Phone	(800) 323-0000
Fax	(813) 975-7762
<b>Focus Laboratories, Inc.</b>	<b>9</b>
Phone	(866) 752-6006
Fax	(501) 753-6021
	<a href="http://www.focuslaboratories.com">www.focuslaboratories.com</a>
<b>Johnson &amp; Johnson Surgical Vision, Inc.</b>	<b>15</b>
	<a href="https://surgical.jnjvision.com">https://surgical.jnjvision.com</a>
<b>Katena</b>	<b>5, 35</b>
Phone	(800) 225-1195
	<a href="http://www.katena.com">www.katena.com</a>
<b>Keeler Instruments</b>	<b>7</b>
Phone	(800) 523-5620
Fax	(610) 353-7814
<b>Lombart Instruments</b>	<b>11</b>
Phone	(800) 446-8092
Fax	(757) 855-1232
<b>Oculus, Inc.</b>	<b>27</b>
Phone	(888) 284-8004
Fax	(425) 867-1881
<b>Omeros</b>	<b>2-3</b>
Phone	(206) 676-5000
Fax	(206) 676-5005
<b>S4OPTIK</b>	<b>45, 47</b>
Phone	(888) 224-6012
<b>Shire Ophthalmics</b>	<b>67, 68</b>
	<a href="http://www.shire.com">www.shire.com</a>
<b>Sight Sciences</b>	<b>31</b>
Phone	(877) 266-1144
	<a href="mailto:info@sightsciences.com">info@sightsciences.com</a>
	<a href="http://www.sightsciences.com">www.sightsciences.com</a>

*This advertiser index is published as a convenience and not as part of the advertising contract. Every care will be taken to index correctly. No allowance will be made for errors due to spelling, incorrect page number, or failure to insert.*

(continued from p. 23)

ferentiate between phoria and tropia, so you don't know if it's a manifest strabismus or a latent strabismus, which affects how you treat it. This system avoids all of these problems."

Dr. Wygnanski-Jaffe notes that the Eyeswift system was originally designed using adult subjects. "Partly for that reason, the Eyeswift is suitable for adults, and it's even easier to use with adults than with kids," she says. "Then, when the designers shifted to the pediatric population, it forced them to make the system work faster and more easily, and made them improve the animated movies. Now it can be used even on children less than three years old."

Asked about the system's limitations, Dr. Wygnanski-Jaffe notes that it uses eye-tracking technology, so it depends on the presence of good ocular motility. "If the patient has a palsy, or the eyes don't move at all, this system can't be used," she says. "However, that's also true with the standard cover test. Second, you need to have at least 20/200 vision in each eye because you need to fixate on a target. You can make the animation larger or smaller according to the subject's visual acuity, but the subject has to be able to fixate. Also, the cornea must be clear. The eye tracker uses infrared illumination reflected between the cornea and the pupil to determine the gaze position of the eye; if the cornea isn't clear, you won't get that reflection."

## Looking to the Future

Dr. Wygnanski-Jaffe notes that some useful tests have not been incorporated into the Eyeswift system yet. "The software doesn't include a test for distance deviation or the nine positions of gaze, but that will be included in the future," she says. "Also, this system was not designed to measure torsion, which is relatively rare. Upcoming versions will add these and other tests."

The Eyeswift system is currently CE-approved. Dr. Wygnanski-Jaffe says it should become available in Europe early this year, and is awaiting FDA approval in the United States. This price in the United States is expected to be in the ballpark of \$6,000. **REVIEW**

*Dr. Thompson is a founder of EyeBrain Medical and holds stock in the company. Dr. Moline sells the Neuro-lens to patients but has no other financial ties to Eye-Brain Medical or the product. Dr. Wygnanski-Jaffe has no financial ties to NovaSight or the Eyeswift system.*

1. Data on file, EyeBrain Medical.



## BRIEF SUMMARY:

Consult the Full Prescribing Information for complete product information.

## INDICATIONS AND USAGE

Xiidra® (lifitegrast ophthalmic solution) 5% is indicated for the treatment of the signs and symptoms of dry eye disease (DED).

## DOSAGE AND ADMINISTRATION

Instill one drop of Xiidra twice daily (approximately 12 hours apart) into each eye using a single-use container. Discard the single-use container immediately after using in each eye. Contact lenses should be removed prior to the administration of Xiidra and may be reinserted 15 minutes following administration.

## CONTRAINDICATIONS

Xiidra is contraindicated in patients with known hypersensitivity to lifitegrast or to any of the other ingredients in the formulation.

## ADVERSE REACTIONS

### Clinical Trials Experience

Because clinical studies are conducted under widely varying conditions, adverse reaction rates observed in clinical studies of a drug cannot be directly compared to rates in the clinical trials of another drug and may not reflect the rates observed in practice. In five clinical studies of dry eye disease conducted with lifitegrast ophthalmic solution, 1401 patients received at least 1 dose of lifitegrast (1287 of which received lifitegrast 5%). The majority of patients (84%) had  $\leq 3$  months of treatment exposure. 170 patients were exposed to lifitegrast for approximately 12 months. The majority of the treated patients were female (77%). The most common adverse reactions reported in 5-25 % of patients were instillation site irritation, dysgeusia and reduced visual acuity. Other adverse reactions reported in 1% to 5% of the patients were blurred vision, conjunctival hyperemia, eye irritation, headache, increased lacrimation, eye discharge, eye discomfort, eye pruritus and sinusitis.

### Postmarketing Experience

The following adverse reactions have been identified during postapproval use of Xiidra. Because these reactions are reported voluntarily from a population of uncertain size, it is not always possible to reliably estimate their frequency or establish a causal relationship to drug exposure.

Rare cases of hypersensitivity, including anaphylactic reaction, bronchospasm, respiratory distress, pharyngeal edema, swollen tongue, and urticaria have been reported. Eye swelling and rash have been reported.

## USE IN SPECIFIC POPULATIONS

### Pregnancy

There are no available data on Xiidra use in pregnant women to inform any drug associated risks. Intravenous (IV) administration of lifitegrast to pregnant rats, from pre-mating through gestation day 17, did not produce teratogenicity at clinically relevant systemic exposures. Intravenous administration of lifitegrast to pregnant rabbits during organogenesis produced an increased incidence of omphalocele at the lowest dose

tested, 3 mg/kg/day (400-fold the human plasma exposure at the recommended human ophthalmic dose [RHOD], based on the area under the curve [AUC] level). Since human systemic exposure to lifitegrast following ocular administration of Xiidra at the RHOD is low, the applicability of animal findings to the risk of Xiidra use in humans during pregnancy is unclear.

### Animal Data

Lifitegrast administered daily by intravenous (IV) injection to rats, from pre-mating through gestation day 17, caused an increase in mean preimplantation loss and an increased incidence of several minor skeletal anomalies at 30 mg /kg / day, representing 5,400-fold the human plasma exposure at the RHOD of Xiidra, based on AUC. No teratogenicity was observed in the rat at 10 mg /kg /day (460-fold the human plasma exposure at the RHOD, based on AUC). In the rabbit, an increased incidence of omphalocele was observed at the lowest dose tested, 3 mg /kg /day (400-fold the human plasma exposure at the RHOD, based on AUC), when administered by IV injection daily from gestation days 7 through 19. A fetal No Observed Adverse Effect Level (NOAEL) was not identified in the rabbit.

### Lactation

There are no data on the presence of lifitegrast in human milk, the effects on the breastfed infant, or the effects on milk production. However, systemic exposure to lifitegrast from ocular administration is low. The developmental and health benefits of breastfeeding should be considered, along with the mother's clinical need for Xiidra and any potential adverse effects on the breastfed child from Xiidra.

### Pediatric Use

Safety and efficacy in pediatric patients below the age of 17 years have not been established.

### Geriatric Use

No overall differences in safety or effectiveness have been observed between elderly and younger adult patients.

## NONCLINICAL TOXICOLOGY

### Carcinogenesis, Mutagenesis, Impairment of Fertility

**Carcinogenesis:** Animal studies have not been conducted to determine the carcinogenic potential of lifitegrast.

**Mutagenesis:** Lifitegrast was not mutagenic in the *in vitro* Ames assay. Lifitegrast was not clastogenic in the *in vivo* mouse micronucleus assay. In an *in vitro* chromosomal aberration assay using mammalian cells (Chinese hamster ovary cells), lifitegrast was positive at the highest concentration tested, without metabolic activation.

**Impairment of fertility:** Lifitegrast administered at intravenous (IV) doses of up to 30 mg/kg/day (5400-fold the human plasma exposure at the recommended human ophthalmic dose (RHOD) of lifitegrast ophthalmic solution, 5%) had no effect on fertility and reproductive performance in male and female treated rats.



Manufactured for: Shire US Inc., 300 Shire Way, Lexington, MA 02421.

For more information, go to [www.Xiidra.com](http://www.Xiidra.com) or call 1-800-828-2088.

Marks designated ® and ™ are owned by Shire or an affiliated company.

©2018 Shire US Inc. SHIRE and the Shire Logo are trademarks or registered trademarks of Shire Pharmaceutical Holdings Ireland Limited or its affiliates.

Patented: please see <https://www.shire.com/legal-notice/product-patents>

Last Modified: 01/2018 S33769



Xiidra may provide

# LASTING RELIEF

starting as early as 2 weeks<sup>1</sup>

One drop in each eye, twice daily, about 12 hours apart.  
Discard the single-use container immediately after use.<sup>1</sup>

## Choose Xiidra first for patients with signs and symptoms of Dry Eye Disease

Xiidra reduced symptoms of eye dryness at 2 weeks in 2 out of 4 studies, and in all 4 studies at 6 and 12 weeks. Xiidra also improved signs of inferior corneal staining at 12 weeks in 3 out of 4 studies.<sup>1</sup>

The safety and efficacy of Xiidra compared to vehicle were studied in 2133 patients in 4 well-controlled, 12-week trials.<sup>1</sup>

Check it out at [Xiidra-ECP.com](http://Xiidra-ECP.com)

### Indication

Xiidra® (lifitegrast ophthalmic solution) 5% is indicated for the treatment of signs and symptoms of dry eye disease (DED).

### Important Safety Information

Xiidra is contraindicated in patients with known hypersensitivity to lifitegrast or to any of the other ingredients.

In clinical trials, the most common adverse reactions reported in 5-25% of patients were instillation site irritation, dysgeusia and reduced visual acuity. Other adverse reactions reported in 1% to 5% of the patients were blurred vision, conjunctival hyperemia, eye irritation, headache, increased lacrimation, eye discharge, eye discomfort, eye pruritus and sinusitis.

To avoid the potential for eye injury or contamination of the solution, patients should not touch the tip of the single-use container to their eye or to any surface.

Contact lenses should be removed prior to the administration of Xiidra and may be reinserted 15 minutes following administration.

Safety and efficacy in pediatric patients below the age of 17 years have not been established.

For additional safety information, see accompanying Brief Summary of Safety Information on the adjacent page and Full Prescribing Information on [Xiidra-ECP.com](http://Xiidra-ECP.com).

#### Reference:

1. Xiidra [Prescribing Information]. Lexington, MA: Shire US.

©2018 Shire US Inc., Lexington, MA 02421. 1-800-828-2088. All rights reserved. SHIRE and the Shire Logo are trademarks or registered trademarks of Shire Pharmaceutical Holdings Ireland Limited or its affiliates. Marks designated ® and ™ are owned by Shire or an affiliated company. S42270 10/18

