

STEM CELL NEWS AND A WAVE OF FDA APPROVALS P. 3 • SULCUS IOL CONTROVERSY P. 12  
FIRST LOOKS AT iSTENT INJECT AND HYDRUS P. 14 • LASER PIs IN ASYMPTOMATIC PAC SUSPECTS P. 44  
NEW IMAGING OPENS A WINDOW ON CHOROIDAL MELANOMA P. 54 • WILLS RESIDENT CASE REPORT P. 63

# REVIEW<sup>®</sup> of Ophthalmology

SEPTEMBER 2018

reviewofophthalmology.com

ANNUAL  
DRY-EYE ISSUE

## COVERING THE SPECTRUM OF DRY-EYE CARE

- Hone Your Dry-Eye Diagnosis Skills **P. 20**
- Dry Eye: Managing Causes and Severities **P. 28**
- Devices for Treating the Meibomian Glands **P. 36**
- Dry-Eye Management Before Surgery **P. 40**



iStent  
inject®

## TRANSFORMING MIGS IN MORE WAYS THAN ONE.

**Optimized Outflow:** Two multi-directional stents designed to restore natural outflow

**Clinically Proven:** Significant IOP reduction across a wide range of clinical studies<sup>1,2</sup>

**Procedural Elegance:** Predictability and precision to meet the needs of your practice

**Proven Safety:** Safety profile similar to cataract surgery alone<sup>1</sup>



AAO BOOTH 1345

All with the exceptional customer support you've come to expect from Glaukos.

TransformMIGS.com | 800.GLAUKOS (452.8567)

**INDICATION FOR USE.** The iStent inject® Trabecular Micro-Bypass System Model G2-M-IS is indicated for use in conjunction with cataract surgery for the reduction of intraocular pressure (IOP) in adult patients with mild to moderate primary open-angle glaucoma. **CONTRAINDICATIONS.** The iStent inject is contraindicated in eyes with angle-closure glaucoma, traumatic, malignant, uveitic, or neovascular glaucoma, discernible congenital anomalies of the anterior chamber (AC) angle, retrolubar tumor, thyroid eye disease, or Sturge-Weber Syndrome or any other type of condition that may cause elevated episcleral venous pressure. **WARNINGS.** Gonioscopy should be performed prior to surgery to exclude congenital anomalies of the angle, PAS, rubeosis, or conditions that would prohibit adequate visualization of the angle that could lead to improper placement of the stent and pose a hazard. **MRI INFORMATION.** The iStent inject is MR-Conditional, i.e., the device is safe for use in a specified MR environment under specified conditions; please see Directions for Use (DFU) label for details. **PRECAUTIONS.** The surgeon should monitor the patient postoperatively for proper maintenance of IOP. The safety and effectiveness of the iStent inject have not been established as an alternative to the primary treatment of glaucoma with medications, in children, in eyes with significant prior trauma, abnormal anterior segment, chronic inflammation, prior glaucoma surgery (except SLT performed > 90 days preoperative), glaucoma associated with vascular disorders, pseudoexfoliative, pigmentary or other secondary open-angle glaucomas, pseudophakic eyes, phakic eyes without concomitant cataract surgery or with complicated cataract surgery, eyes with medicated IOP > 24 mmHg or unmedicated IOP < 21 mmHg or > 36 mmHg, or for implantation of more or less than two stents. **ADVERSE EVENTS.** Common postoperative adverse events reported in the randomized pivotal trial included stent obstruction (6.2%), intraocular inflammation (5.7% for iStent inject vs. 4.2% for cataract surgery only), secondary surgical intervention (5.4% vs. 5.0%) and BCVA loss  $\geq$  2 lines  $\geq$  3 months (2.6% vs. 4.2%). **CAUTION:** Federal law restricts this device to sale by, or on the order of, a physician. Please see DFU for a complete list of contraindications, warnings, precautions, and adverse events.

**REFERENCES:** 1. iStent inject® Trabecular Micro-Bypass System: Directions for Use, Part #45-0176. 2. Hengerer FH. Personal experience with second-generation trabecular micro-bypass stents in combination with cataract surgery in patients with glaucoma: 3-year follow-up. ASCRS 2018 Presentation.

© 2018 Glaukos Corporation. Glaukos and iStent inject are registered trademarks of Glaukos Corporation. PM-US-0026

GLAUKOS®  
Transforming Glaucoma Therapy

# Stem Cells Regrow Rod Cells For the First Time in Mammals

**Researchers at the Icahn School of Medicine at Mt. Sinai in New York City** recently used stem cells to induce the retina to regrow rod cells in an animal model of congenital blindness. The report was published in the August 15 online issue of the journal *Nature*.

The paper notes that cold-blooded vertebrates like the zebrafish can use Müller glial cells to regenerate any type of retinal neuron. In mammals, however, the MGCs stay quiet and don't allow regeneration in retinal degenerative diseases. "We're trying to reactivate this regenerative capability in the mammalian retina to regenerate photoreceptors," says lead investigator Bo Chen, PhD, associate professor of ophthalmology and director of the Ocular Stem Cell Program at Icahn.

Dr. Chen says the process involved two steps: "First, we used adeno-associated virus as a tool to deliver a gene to the MGCs by way of intravitreal injection," he explains. "This gene transfer induced the MGCs to re-enter the cell cycle, to divide and produce daughter cells. Then, two weeks later, we used another gene transfer to transfer transcription factors and help guide the MGCs to become photoreceptors." These newly created rods integrated into the existing retinal structure, and the researchers say there's no difference between them and naturally occurring rod cells. Four to six weeks after the gene transfer, the mice regained vision, though the researchers weren't able to measure the exact degree of visual improvement.

"Our goal is to one day have our

work benefit humans," Dr. Chen avers. "We're currently working with clinicians to see if we can get human retinal samples from patients who have undergone enucleation. We could then culture the retinal samples and work with them."

## FDA Approval Watch

August brought several new nods from the FDA:

- *Ivantis Hydrus*. Surgeons have a new tool for their anti-glaucoma arsenal in the form of this canal-based microstent. We take a closer look at the Hydrus and the new iStent inject, in this month's Technology Update.

- *Sun Pharma's Cequa 0.09%*. This cyclosporine A solution is a new option for dry-eye patients. Sun says that Cequa provides the highest FDA-approved concentration of CsA and is the first approved CsA product to use a nanomicellar technology to help overcome solubility challenges.

- *Eylea (afibercept) labeling*. The FDA approved a label change for Eylea in patients with wet AMD. The approval was based on second-year data from the Phase III VIEW 1 and 2 trials in which patients were treated with a modified 12-week dosing schedule. These data are now on the label.

- *MeiraGTx AAV-CNGA3*. The FDA granted orphan drug designation for AAV-CNGA3 gene therapy for the treatment of achromatopsia caused by mutations in the CNGA3 gene. AAV-CNGA3 is an investigational gene therapy delivered to the cone receptors via subretinal injection.

- *Dompé's Oxervate*. Oxervate received orphan-drug designation for the treatment of neurotrophic keratitis, becoming the first topical biologic in ophthalmology and the first drug approved specifically for NK.

- *Kala's Inveltys*. Inveltys (loteprednol etabonate ophthalmic suspension) 1% was approved for postop inflammation and pain following ocular surgery. It's the first b.i.d. ocular steroid approved for this indication. **REVIEW**

## Corrections

In July's Glaucoma Management, on p. 55 the statement "Some states, like Nevada and Georgia, dictate that all patients must be referred to an ophthalmologist for all further care once they are found to have glaucoma," is incorrect. In both of these states, optometrists with the proper credentials can manage glaucoma, and only have to refer glaucoma patients to an ophthalmologist under certain conditions.

In the August feature, "The nAMD Pipeline: Full But Not Fast," in the discussion of Genentech's Port Delivery System with ranibizumab, it was stated that the reservoir is refilled with Lucentis, which is incorrect. The system actually uses a special formulation of ranibizumab that's different from the FDA-approved doses of Lucentis.

*Review* regrets the errors.

# CONTRIBUTORS

**CHIEF MEDICAL EDITOR**

Mark H. Blecher, MD

**CONTACT LENSES**

Penny Asbell, MD

**CORNEA / ANTERIOR SEGMENT**

Thomas John, MD

**GLAUCOMA MANAGEMENT**

Peter Netland, MD, PHD  
Kuldev Singh, MD

**MEDICARE Q & A**

Paul M. Larson, MBA

**PEDIATRIC PATIENT**

Wendy Huang, MD

**PLASTIC POINTERS**

Ann P. Murchison, MD, MPH

**REFRACTIVE/CATARACT RUNDOWN**

Arturo S. Chayet, MD

**RETINAL INSIDER**

Carl Regillo, MD, FACS  
Emmett T. Cunningham Jr., MD, PHD, MPH

**TECHNOLOGY UPDATE**

Steven T. Charles, MD  
Michael Colvard, MD

**WILLS RESIDENT CASE SERIES**

Jason Flamendorf, MD

# ADVISORY BOARD

**PENNY A. ASBELL, MD**, NEW YORK CITY

**WILLIAM I. BOND, MD**, PEKIN, ILL.

**ALAN N. CARLSON, MD**, DURHAM, N.C.

**Y. RALPH CHU, MD**, EDINA, MINN.

**ADAM J. COHEN, MD**, DOWNERS GROVE, ILL.

**UDAY DEVGAN, MD, FACS**, LOS ANGELES

**ERIC DONNENFELD, MD**, ROCKVILLE CENTRE, N.Y.

**DANIEL S. DURRIE, MD**, KANSAS CITY, MO.

**ROBERT EPSTEIN, MD**, MCHENRY, ILL.

**ROBERT D. FECHTNER, MD**, NEWARK, N.J.

**WILLIAM J. FISHKIND, MD**, TUCSON, ARIZ.

**JAMES P. GILLS, MD**, TARPON SPRINGS, FLA.

**HARRY GRABOW, MD**, SARASOTA, FLA.

**DOUGLAS K. GRAYSON, MD**, NEW YORK CITY

**THOMAS S. HARBIN, MD, MBA**, ATLANTA

**DAVID R. HARDTEN, MD**, MINNEAPOLIS

**KENNETH J. HOFFER, MD**, SANTA MONICA, CALIF.

**JACK T. HOLLADAY, MD, MSEE**, HOUSTON

**JOHN D. HUNKELER, MD**, KANSAS CITY, MO.

**THOMAS JOHN, MD**, TINLEY PARK, ILL.

**ROBERT M. KERSHNER, MD, MS, FACS**, BOSTON

**GUY M. KEZIRIAN, MD**, PARADISE VALLEY, ARIZ.

**TERRY KIM, MD**, DURHAM, N.C.

**TOMMY KORN, MD**, SAN DIEGO

**DAVID A. LEE, MD**, HOUSTON

**FRANCIS S. MAH, MD**, PITTSBURGH

**NICK MAMALIS, MD**, SALT LAKE CITY

**WILLIAM G. MARTIN, MD**, OREGON, OHIO

**MIKE S. MCFARLAND, MD**, PINE BLUFF, ARK.

**JEFFREY B. MORRIS, MD, MPH**, ENCINITAS, CALIF.

**MARLENE R. MOSTER, MD**, PHILADELPHIA

**ROBERT J. NOECKER, MD**, FAIRFIELD, CONN.

**ROBERT OSHER, MD**, CINCINNATI

**MARK PACKER, MD**, BOULDER, CO.

**STEPHEN PASCUCCI, MD**, BONITA SPRINGS, FLA.

**PAUL PENDER, MD**, BEDFORD, N.H.

**CHRISTOPHER J. RAPUANO, MD**, PHILADELPHIA

**AUGUST READER III, MD**, SAN FRANCISCO

**TONY REALINI, MD**, MORGANTOWN, W.V.

**KENNETH J. ROSENTHAL, MD**, GREAT NECK, N.Y.

**ERIC ROTHCHILD, MD**, DELRAY BEACH, FLA.

**SHERI ROWEN, MD**, BALTIMORE

**JAMES J. SALZ, MD**, LOS ANGELES

**INGRID U. SCOTT, MD, MPH**, HERSHEY, PA.

**JOEL SCHUMAN, MD**, PITTSBURGH

**GAURAV SHAH, MD**, ST. LOUIS

**DAVID R. STAGER JR., MD**, DALLAS

**KARL STONECIPHER, MD**, GREENSBORO, N.C.

**JAMES C. TSAI, MD**, NEW YORK CITY

**VANCE THOMPSON, MD**, SIOUX FALLS, S.D.

**FARRELL C. TYSON, MD**, CAPE CORAL, FLA.

**R. BRUCE WALLACE III, MD**, ALEXANDRIA, LA.

**ROBERT G. WILEY, MD**, CLEVELAND

**FRANK WEINSTOCK, MD**, CANTON, OHIO

**BUSINESS OFFICES**

11 CAMPUS BOULEVARD, SUITE 100  
NEWTOWN SQUARE, PA 19073  
SUBSCRIPTION INQUIRIES (877) 529-1746  
(USA ONLY); OUTSIDE USA, CALL (847) 763-9630

**BUSINESS STAFF**

PUBLISHER  
**JAMES HENNE**  
(610) 492-1017 JHENNE@JOBSON.COM

REGIONAL SALES MANAGER  
**MICHELE BARRETT**  
(610) 492-1014 MBARRETT@JOBSON.COM

REGIONAL SALES MANAGER  
**MICHAEL HOSTER**  
(610) 492-1028 MHOSTER@JOBSON.COM

**CLASSIFIED ADVERTISING**  
(888)-498-1460

VICE PRESIDENT OF OPERATIONS  
**CASEY FOSTER**  
(610) 492-1007 CFOSTER@JOBSON.COM

PRODUCTION MANAGER  
**SCOTT TOBIN**  
(610) 492-1011 STOBIN@JOBSON.COM

**SUBSCRIPTIONS**  
\$63 A YEAR, \$99 (U.S.) IN CANADA,  
\$158 (U.S.) IN ALL OTHER COUNTRIES.  
SUBSCRIPTIONS E-MAIL:  
REVOPHTHALMOLOGY@CAMBEYWEST.COM

**CIRCULATION**

PO BOX 71, CONGERS, NY 10920-0071  
(877) 529-1746  
OUTSIDE USA: (845) 267-3065

SENIOR CIRCULATION MANAGER  
**HAMILTON MAHER**  
(212) 219-7870 hmaher@jhihealth.com

CEO, INFORMATION GROUP SERVICES  
**MARC FERRARA**

SENIOR VICE PRESIDENT, OPERATIONS  
**JEFF LEVITZ**

VICE PRESIDENT, HUMAN RESOURCES  
**TAMMY GARCIA**

VICE PRESIDENT, CREATIVE SERVICES & PRODUCTION  
**MONICA TETTAMANZI**

CORPORATE PRODUCTION DIRECTOR  
**JOHN ANTHONY CAGGIANO**

VICE PRESIDENT, CIRCULATION  
**EMELDA BAREA**



440 Ninth Avenue, 14th Floor  
New York, N.Y. 10001

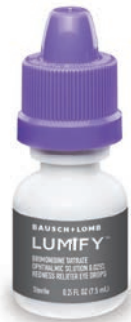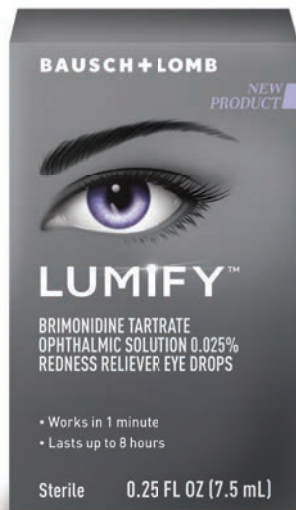REVIEW OF OPHTHALMOLOGY (ISSN 1081-0226; USPS No. 0012-345) is published monthly, 12 times per year by Jobson Medical Information, 440 Ninth Avenue, 14th Floor, New York, N.Y. 10001. Periodicals postage paid at New York, NY and additional mailing offices. Postmaster: Send address changes to Review of Ophthalmology, PO Box 71, Congers, NY 10929-0071. Subscription Prices: US One Year \$63.00, US Two Year \$112.00, Canada One Year \$99.00, Canada Two Year \$181.00, Int'l One Year \$158.00, Int'l Two Year \$274.00. For subscription information call (877) 529-1746 (USA only); outside USA, call (845)-267-3065. Or email us at revophthalmology@cambeywest.com. Canada Post: Publications Mail Agreement #40612608. Canada Returns to be sent to Bleuchip International, P.O. Box 25542, London, ON N6C 6B2.

**NEW!**

# LUMIFY™

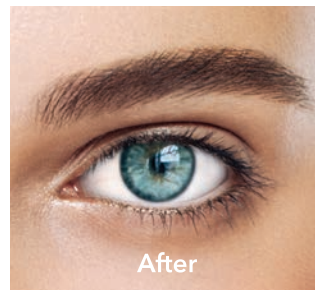
**BRIMONIDINE TARTRATE OPHTHALMIC SOLUTION 0.025%  
REDNESS RELIEVER EYE DROPS**

## A NEW REDNESS RELIEVER LIKE NO OTHER:



- The first and only OTC eye drop with low dose brimonidine tartrate (0.025%)
- Strong safety and efficacy profile with no tachyphylaxis and virtually no rebound redness in clinical trials
- Starts working in 1 minute - lasts for up to 8 hours

LUMIFY redness reliever eye drops are available at national retailers in **2.5 mL** and **7.5 mL** sizes.



Images representative of clinical trial results, individual results may vary.

**Introduce your patients to a new kind of redness reliever.**

Learn more at [lumifydrops.com/professional](http://lumifydrops.com/professional)  
To sell LUMIFY in your office, call 1-800-828-9030.

LUMIFY is a trademark of Bausch & Lomb Incorporated or its affiliates. © 2018 Bausch & Lomb Incorporated. PN08878 LUM.0193.USA.18

FROM THE EYE CARE EXPERTS AT **BAUSCH+LOMB**

# YOUR PATIENTS' SATISFACTION STARTS WITH A VARITRONICS CALL SYSTEM



**Increase patient flow and overall practice efficiency.**

**Increase profits.**

**Varitronics can show you how!**

**See more patients in the same amount of time without increasing staff.**

Varitronics, the leader in Non-Verbal Interoffice Communications for over four decades, offers the most feature-rich systems on the market today. Our custom designed Call Systems will streamline the way you work so that you can decrease your patient's waiting time while increasing your staff's efficiency.

**Call Systems are available for both new and existing construction.**



Wall panel and pager

Call, email, or visit our web site today to see how easy it is to benefit from the efficiency of Varitronics' Call System.



CS 2000 Wireless System

**VARITRONICS**

**See us at AAO Booth #2145**

**800.345.1244 • email:varimed@varitronics.com • www.varitronics.com**

**REVIEW**<sup>®</sup>  
of Ophthalmology

— EDITORIAL STAFF —

**Editor in Chief**

**Walter C. Bethke**

(610) 492-1024

wbethke@jobson.com

**Senior Editor**

**Christopher Kent**

(814) 861-5559

ckent@jobson.com

**Senior Associate Editor**

**Kristine Brennan**

(610) 492-1008

kbrennan@jobson.com

**Associate Editor**

**Liam Jordan**

(610) 492-1025

ljordan@jobson.com

**Chief Medical Editor**

**Mark H. Blecher, MD**

**Art Director**

**Jared Araujo**

(610) 492-1032

jaraujo@jobson.com

**Senior Graphic Designer**

**Matt Egger**

(610) 492-1029

megger@jobson.com

**International coordinator, Japan**

**Mitz Kaminuma**

Reviewophthalmo@aol.com

**Business Offices**

11 Campus Boulevard, Suite 100

Newtown Square, PA 19073

(610) 492-1000

Fax: (610) 492-1039

**Subscription inquiries:**

United States — (877) 529-1746

Outside U.S. — (845) 267-3065

**E-mail:**

revophthalmology@cambeywest.com

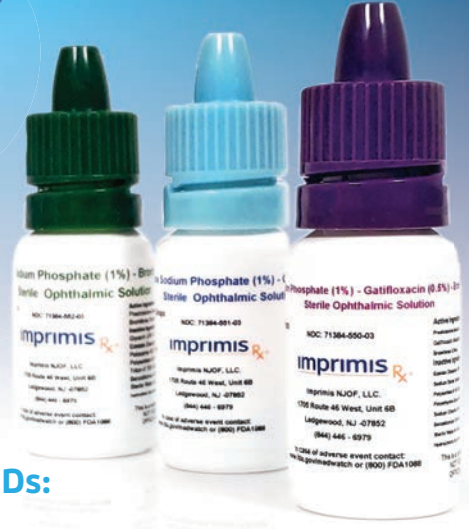Website: www.reviewofophthalmology.com



Introducing a New

**Solution**

For Your Practice



Expanding the **LESS DR<sup>PS</sup>**

portfolio of combination **steroid, antibiotic, and NSAIDs:**

Now offering both solutions and suspensions: **The Choice is Yours**

### SOLUTIONS

#### **PRED-GATI-BROM™ (3.5 ML)**

Prednisolone **phosphate**, gatifloxacin, bromfenac (1/0.5/0.075%)

#### **PRED-GATI-BROM (7 ML)**

Prednisolone **phosphate**, gatifloxacin, bromfenac (1/0.5/0.075%)

#### **PRED-BROM™ (3.5 ML)**

Prednisolone **phosphate**, bromfenac (1/0.075%)

#### **PRED-GATI™ (3.5 ML)**

Prednisolone **phosphate**, gatifloxacin (1/0.5%)

### SUSPENSIONS

#### **PRED-GATI-BROM™ (3.5 ML)**

Prednisolone **acetate**, gatifloxacin, bromfenac (1/0.5/0.075%)

#### **PRED-GATI-BROM (7 ML)**

Prednisolone **acetate**, gatifloxacin, bromfenac (1/0.5/0.075%)

#### **PRED-BROM™ (3.5 ML)**

Prednisolone **acetate**, bromfenac (1/0.075%)

#### **PRED-GATI™ (3.5 ML)**

Prednisolone **acetate**, gatifloxacin(1/0.5%)

**Proprietary Quality Sterile Compounded Formulations\***

**Visit us at AAO Booth #4254**

**Order Today: [order.imprimisrx.com/Lessdrops](http://order.imprimisrx.com/Lessdrops)**

\*For professional use only. Imprimis Pharmaceuticals specializes in customizing medications to meet unique patient and practitioner needs. No compounded medication is reviewed by the FDA for safety or efficacy. Imprimis Pharmaceuticals does not compound copies of commercially available products. References available upon request.

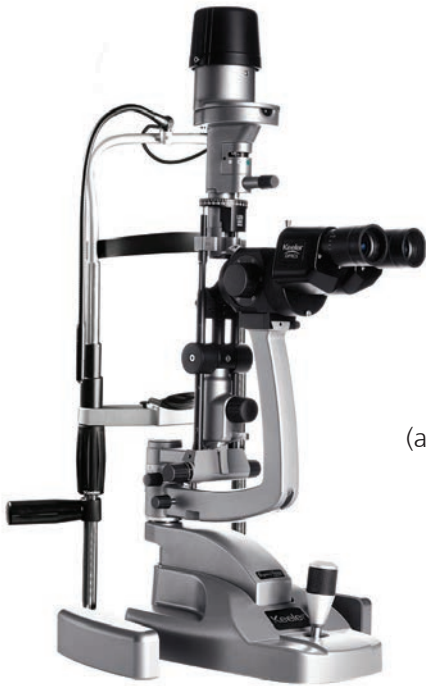LessDrops, Pred-Gati-Brom, Pred-Brom, Pred-Gati, and ImprimisRx are trademarks of Imprimis Pharmaceuticals, Inc. ©2018 Imprimis Pharmaceuticals, Inc. All Rights Reserved. IMPO0298 7/18

**imprimis<sup>®</sup>Rx**  
844.446.6979

# The Keeler<sup>3</sup> Trade In Program

## Buy 3 // Trade 3 // Get 1 Free

The Power of 3. Purchase any 3 Keeler Slit Lamps and trade in 3 of your old Slit Lamps and we'll send you a 4th Keeler Slit Lamp absolutely free of charge.



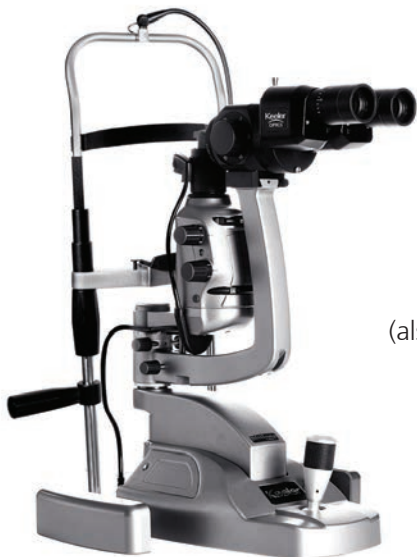**KSL-H**

(also in Digital Ready)



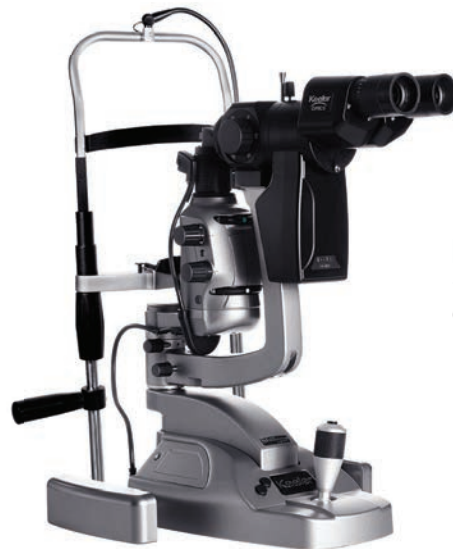**KSL-H-D**

(full Digital)



**KSL-Z**

(also in Digital Ready)



**KSL-H-D**

(full Digital)

**Keeler**  
OPTICS

Keeler Instruments, Inc. • 3222 Phoenixville Pike, bldg. 50 • Malvern, PA 19355  
Tel: (800) 523-5620 • Fax: (610) 353-7814 • email: keeler@keelerusa.com

**Offer valid until December 31, 2018.**

Contact Keeler or one of our authorized dealers for more information.



# REVIEW<sup>®</sup> of Ophthalmology

September 2018 • Volume XXV No. 9 | [reviewofophthalmology.com](http://reviewofophthalmology.com)

## Cover Focus

---

### 20 | **Dry Eye: Hone Your Diagnostic Skills**

*Liam Jordan, Associate Editor and  
Walter Bethke, Editor in Chief*

Profit from the experience of these corneal experts.

### 28 | **Managing Causes and Severities In Dry Eye**

*Christopher Kent, Senior Editor*

As awareness of the impact of dry eye grows, surgeons are learning to tailor their treatments.

### 36 | **Devices for Treating the Meibomian Glands**

*Christopher Kent, Senior Editor*

A number of recently developed instruments can help to relieve meibomian gland congestion.

### 40 | **Dry-eye Management Before Surgery**

*Michelle Stephenson, Contributing Editor*

How treating the ocular surface can improve your cataract and refractive surgery outcomes.



# Departments

---

3 | [Review News](#)

12 | [Letters to the Editor](#)  
**Taking Issue with Sulcus IOL Choices**

14 | [Technology Update](#)  
**iStent Inject & Hydrus: New Ways To Increase Outflow**  
Surgeons share their experience with the two latest FDA-approved MIGS devices.

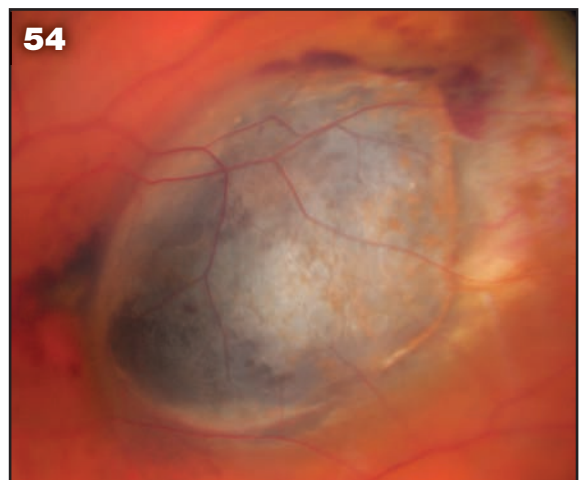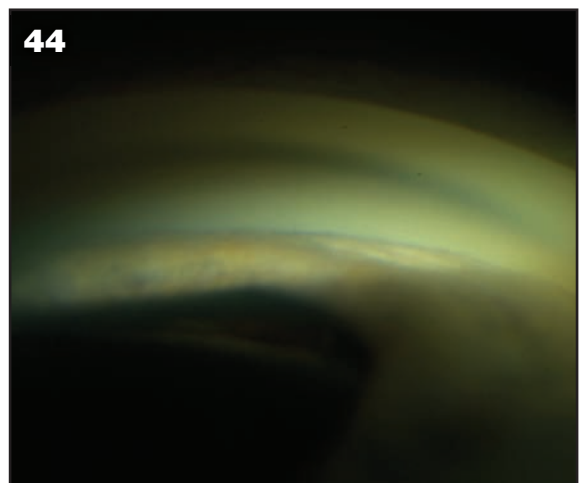

44 | [Glaucoma Management](#)  
**The Asymptomatic PAC Suspect: LPI or No?**  
Most don't hesitate to perform a laser PI in healthy narrow-angle patients. It may be time to reconsider.

54 | [Retinal Insider](#)  
**Imaging Advances for Choroidal Melanoma**  
Recent additions to the imaging toolbox are helping with diagnosis and management of these cancers.

62 | [Classifieds](#)

63 | [Wills Eye Resident Case Series](#)

66 | [Advertiser Index](#)



Johnson & Johnson VISION



Reserve a private session with a Brilliance Bar expert, and get answers to your most pressing surgical questions.

Leave armed with brilliant solutions to questions such as:

- How can you make your premium IOL patients' outcomes better?
- What phaco style is right for your technique?
- Should you incorporate laser surgery in your practice?
- How can you best optimize the ocular surface before surgery?

SATURDAY, OCTOBER 27				SUNDAY, OCTOBER 28			
10AM – 11AM	Zaina Al-Mohtaseb, MD Robert Maloney, MD	Preeya Gupta, MD	Ehsan Sadri, MD	10AM – 11AM	Christopher Blanton, MD	William Culbertson, MD	Blake Williamson, MD
11AM – 12PM	Elizabeth Davis, MD	Cynthia Matossian, MD	William Trattler, MD	11AM – 12PM	Sandy Feldman, MD Marc Odrich, MD	Dave Hardten, MD	Colman Kraff, MD
12PM – 1PM	Rex Hamilton, MD	Paul Kang, MD	Devesh Varma, MD	12PM – 1PM	Mark Kontos, MD	Ernesto Otero, MD	Michael Shapiro, MD
1PM – 2PM	Daniel Chang, MD	Steven Dewey, MD	Sam Garg, MD	1PM – 2PM	Kendall Donaldson, MD	Francis Mah, MD	Laura Periman, MD
2PM – 3PM	Mark Blecher, MD	Nicole Fram, MD	Pulin Shah, MD	2PM – 3PM	Eva Liang, MD	Tal Raviv, MD	Gustavo Tamayo, MD

Reserve your private session with an expert at our AAO Brilliance Bar

[NALMAGUE@ITS.JNJ.COM](mailto:NALMAGUE@ITS.JNJ.COM)



MORE  
brilliant  
TOGETHER  
#3708

While you're at AAO,  
visit our Speakers' Forum  
to hear expert booth talks

SAT & SUN | 10AM – 3PM | BOOTH #3708

# Taking Issue with Sulcus IOL Choices

## To the Editor:

In the July 2018 *Review* article “The IOL In the Sulcus: When, Why & How,” a suggestion was made that placing a single-piece acrylic IOL with haptics in the sulcus in an optic capture configuration (lens optic captured posteriorly through an intact capsulorhexis with haptics positioned in the sulcus) may be an acceptable option. As surgeons that frequently deal with complications of cataract surgery on referral we all have seen serious complications arise from single-piece acrylic IOL haptics that have been placed in the sulcus. These issues include iris chafing, pigment dispersion, chronic inflammation, cystoid macular edema, glaucoma and, ultimately, loss of vision. We all agree that efforts should be made to avoid placing the haptics of a single-piece acrylic intraocular lens in the sulcus, and that to do so intentionally places patients at unnecessary risk that could be avoided with use of an appropriate three-piece lens (or a lens designed for sulcus placement). The haptics of single-piece hydrophobic acrylic lenses should be positioned behind the anterior capsule rim to prevent a high risk of complications.

In the article, the optic capture configuration suggested by Dr. Grayson, with the lens optic prolapsed behind the intact anterior capsule rim and the haptics in the sulcus, may help to stabilize the lens against dislocation, but the lens haptics remain in the sulcus

where they may contact the iris pigment epithelium and cause problems. In models of optic capture performed by one of this letter’s authors (Dr. Ouano), prolapsing the optic posteriorly behind the anterior capsule pushes the lens haptics to a more anterior position where they might inflict even more damage. When posterior capsule support is lacking, if the haptics don’t remain in the sulcus the entire single-piece lens may dislocate into the vitreous. We ask surgeons to consider having an appropriate backup lens option available in cases where there may be risk of damage to the posterior capsule and loss of the option of in-the-bag placement for a scheduled single-piece acrylic lens. Optic capture of such lenses with the haptics in the sulcus isn’t an acceptable option.

*Signed,*

*Steven Safran, MD, Dean Ouano, MD, Sadeer Hannush, MD, Mark Gorovoy, MD, Jason Jones, MD, Michael Snyder, MD, Thomas Oetting, MD, and Greg Ogawa, MD*

#### References:

- Chang DF, Masket S, Miller KM, et al; ASCRS Cataract Clinical Committee. Complications of sulcus placement of single-piece acrylic intraocular lenses: Recommendations for backup IOL implantation following posterior capsule rupture. *J Cataract Refract Surg* 2009;35:8:1445-58.
- Uy HS, Chan PS. Pigment release and secondary glaucoma after implantation of single-piece acrylic intraocular lenses in the ciliary sulcus. *Am J Ophthalmol* 2006;142:2:330-2.
- LeBoyer RM, Werner L, Snyder ME, et al. Acute haptic-induced ciliary sulcus irritation associated with single-piece AcrySof intraocular lenses. *J Cataract Refract Surg* 2005;31:7:1421-7.
- Hong Y, Sun YX, Qi H, Zhou JC, Hao YS. Pigment dispersion glaucoma induced by the chafing effect of intraocular lens haptics in Asian eyes. *Curr Eye Res* 2013;38:3:358-62.
- Mohebbi M, Bashiri SA, Mohammadi SF, et al. Outcome of single-piece intraocular lens sulcus implantation following posterior capsular rupture during phacoemulsification. *J Ophthalmic Vis Res* 2017;12:3:275-280.
- Micheli T, Cheung LM, Sharma S, et al. Acute haptic-induced pigmentary glaucoma with an AcrySof intraocular lens. *J Cataract Refract Surg* 2002;28:10:1869-72.
- Vasavada AR, Raj SM, Karve S, et al. Retrospective ultrasound biomicroscopic analysis of single-piece sulcus-fixed acrylic intraocular lenses. *J Cataract Refract Surg* 2010;36:5:771-7.

Dr. Grayson responds:

I agree completely that sulcus placement of a one-piece acrylic IOL without anterior capsulotomy capture should never be performed, for all the reasons discussed in the article and then reiterated in the letter. I also agree that sulcus placement with one-piece IOL capture in a capsulotomy that’s irregular, decentered or larger than 5 mm should never be performed. Also, one-piece sulcus placement with IOL capture in short axial length eyes with decreased chamber depth and limited clearance between the posterior iris and the anterior capsule shelf shouldn’t be performed.

Sulcus placement of a one-piece acrylic with anterior capsulotomy capture can be performed in eyes with a longer axial length and a clinically evident deep anterior capsular shelf with respect to the posterior iris surface. There must also be a well-centered capsulotomy less than 5 mm, optimally created by a femtosecond laser. Most important, there should be a clinical consideration about the approach that would afford the patient the best visual rehabilitation outcome. I absolutely

*(Continued on page 60)*



**LET'S TAKE THE LONG VIEW TOGETHER.**

## **The trail is clear.**

Weaving along Hawaii's Na Pali Coast is the breathtaking Kalalau Trail. The trail is demanding...but in the end, its beauty is worth every step. Kalalau was early inspiration for us, today representing our innovative spirit and deep commitment to advancing the treatment of eye diseases. This is the journey we're all on at Kala and the one we can take together.

## **The technology in sight.**

Our proprietary and barrier-breaking **AMPPLIFY™** Drug Delivery Technology is designed to help us keep improving what's possible for eye care.

## **The vista awaits us.**

Visit [kalarx.com](http://kalarx.com) and let's get our journey underway.

**kala**   
PHARMACEUTICALS

© 2018 Kala Pharmaceuticals  
All rights reserved. AMPPLIFY™ is a trademark  
of Kala Pharmaceuticals. Printed in the USA.  
US-INV-1800002 August 2018



# iStent Inject & Hydrus: New Ways to Increase Outflow

Surgeons share their experience with the two latest FDA-approved MIGS devices.

*Christopher Kent, Senior Editor*

**T**his summer, the U.S. Food and Drug Administration has approved two new minimally invasive glaucoma surgery devices designed to help lower intraocular pressure by improving aqueous outflow through the trabecular meshwork: the iStent inject (Glaukos), approved in June, and the Hydrus (Ivantis), approved in August. Here, two surgeons familiar with both devices share their experience and advice regarding these new options for addressing mild to moderate glaucoma.

## Optimizing the TM Pathway

“To date there have been five prospective, randomized trials comparing cataract surgery alone to cataract surgery performed along with one of the procedures that are considered to be MIGS,” notes Thomas W. Samuelson, MD, a founding partner at Minnesota Eye Consultants in Minneapolis and an adjunct professor of ophthalmology at the University of Minnesota. (Dr. Samuelson was an investigator in the iStent inject trial.) “They include the original iStent trial and the subsequent iStent inject trial; the CyPass

COMPASS trial; and two prospective, randomized trials using the Hydrus—one in Europe and one in the U.S. One of the important takeaways from all of those trials has been that cataract surgery alone is a meaningful intervention for patients with mild to moderate glaucoma. That’s important, because that’s the foundation on which MIGS rests, in my opinion.

“While the exact mechanism is not clear, we think that removing the cataract is helping physiologic outflow,” he continues. “While speculative, I believe it is mechanical. Removing the lens allows the iris, angle and ciliary zone complex to assume a more posterior position, and that improves outflow. So, we start with that favorable occurrence and we try to add to it without disrupting that improvement in normal physiology.

“I think that’s where procedures like iStent and Hydrus and some of the other canal-based procedures really shine; they’re also improving physiologic outflow,” he continues. “My philosophy is that if I can augment the pressure-lowering caused by the cataract surgery, in a fashion that’s synergistic with whatever the cataract

has done, that’s an added bonus. With canal-based procedures you’re retaining the outflow pathway that you were born with, the one that’s most physiological. In contrast, combining cataract surgery with a procedure that diverts fluid away from the physiologic pathway—such as a procedure that diverts aqueous across the sclera into a bleb—seems counterintuitive to me, at least for patients with mild to moderate glaucoma undergoing concurrent phacoemulsification.”

What does the data have to say? The recent iStent inject study was conducted at 41 sites with 380 subjects receiving phaco plus iStent inject and 118 receiving phaco alone. Efficacy endpoints at 24 months were a  $\leq 20$ -percent reduction in diurnal IOP (primary endpoint) and the mean reduction in diurnal IOP (secondary endpoint). At 24 months, 75.3 percent of the iStent inject cohort achieved a 20-percent or greater reduction in unmedicated IOP, compared to 61.9 percent of the phaco-only cohort. At 24 months, the iStent inject cohort had a mean unmedicated IOP reduction of 6.9 mmHg, compared to a 5.4-mmHg reduction in the phaco-only

cohort. During the 24-month follow-up period, the overall rate of adverse events for the iStent inject group was similar to cataract surgery only.

The Hydrus trial (HORIZON) was a prospective, multi-center randomized trial in which 369 individuals received a Hydrus shunt in addition to phaco, while 187 received phaco only. The primary endpoint at 24 months was a 20-percent reduction in diurnal IOP; the secondary endpoint was the change in mean diurnal IOP. At 24 months, 77.2 percent of the Hydrus group had at least a 20-percent drop in DIOP; 57.8 percent of the phaco-only group achieved that. The mean change in DIOP was -7.6 mmHg at 24 months for the Hydrus group and -5.3 mmHg for the phaco-only group.<sup>1</sup>

### Updating the iStent

Alan Crandall, MD, a clinical professor and senior vice chair of ophthalmology, and director of glaucoma and cataract, in the Department of Ophthalmology at the Moran Eye Center, University of Utah, participated in the analysis of the data from the iStent inject trial, and he's been using the iStent inject for several months. "Everyone thought the original iStent would be very easy for non-glaucoma surgeons to use," he notes. "However, the number of people using it who are not glaucoma specialists has dropped, because it's not as easy as they thought. It's a little tricky to get into the canal, and you always have the issue of deciding where to put the stent.

"The new iStent model is different, both because it gives you two stents and because it's easier to put in," he continues. "The advantage of putting two in is that you're more likely to get access to at least one outflow channel, and the trial data supports this. In fact, outside the United States everybody uses two or three iStents to get a consistently lower IOP. Although the iStent inject study design was somewhat different from the original iStent trial, the data showed a more consistent and long-lasting result than was achieved with the original device—at least for the two or three years of follow-up that's been measured so far. The IOP lowering is at least one or two points greater than what we get with a single iStent."

Dr. Samuelson agrees that the iStent inject trial confirmed the efficacy of the new device. "In the iStent inject trial, the cataract-alone group had favorable IOP reductions; but the cataract plus the iStent inject lowered pressure better and reduced the need for medications better than the control arm," he says. "Furthermore, it did so in a very safe fashion; there were no significant differences in the safety measures between the groups."

Dr. Samuelson notes that safety is one of the hallmarks of the iStent approach. "I think once you become facile



# NuLids™ transformational dry eye therapy

Transforms your patients' lives



Finally... A doctor-directed at-home treatment for dry eye disease that is safe, effective and easy to use.

A multi-center study<sup>1</sup> showed:

- 50% decrease in dry eye symptoms
- 65% improvement in TBUT
- 80% increase in meibomian glands yielding liquid secretions.

For more information visit  
[www.NuSightMedical.com/rophi9](http://www.NuSightMedical.com/rophi9)  
or call us at 833-368-5437


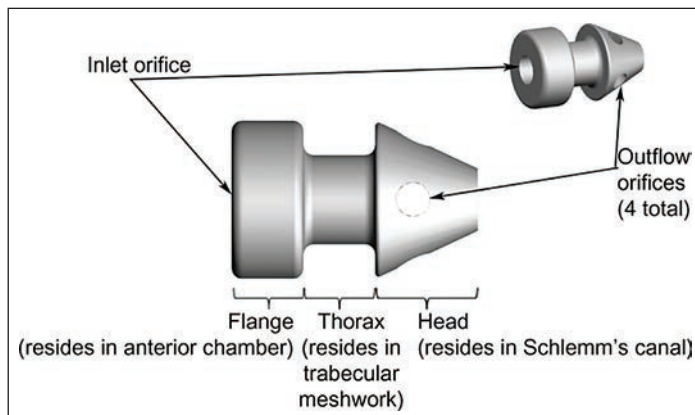


<sup>1</sup> Schanzlin, Olkowski, Coble, Gross. NuLids II Study, April 2018



**NuLids™**

Doctor prescribed, at-home dry eye relief



The iStent inject allows the surgeon to inject two stents into Schlemm's canal instead of one, increasing the likelihood of ending up adjacent to a collector channel. Surgeons also report that it's easier to use than the original iStent.

with these MIGS canal devices, especially the iStent, you can look patients in the eye and tell them that the greatest risk is the risk of disappointment, the possibility that this might not get them all the way to your pressure-lowering goal," he says. "That [level of safety] isn't true for all MIGS procedures, but I think it's true for the iStent. Its greatest attribute is how safe it is. Other procedures may prove to be more efficacious, but I'm not aware of any that are safer."

Dr. Crandall says the company is thinking about creating a next-generation iStent device that will contain three stents. "Having just gotten the iStent inject through regulatory, I'm sure they'll stick with the iStent inject for now," he notes. "Still, the idea of adding more stents is an obvious option to consider. It's possible that it would produce even greater pressure-lowering."

### Location, Location, Location

"One of the nice things about both of the new canal devices we're expecting in 2018—the iStent inject and the Hydrus—is that they take some of the guesswork out of placing the stents," Dr. Samuelson explains. "Using the original iStent meant placing a single stent, so the surgeon had to choose the most favorable place to put it, a process that has become known as 'intelligent placement.' Many surgeons

have found this challenging, which is completely understandable. In contrast, the iStent inject employs a two-stent strategy. If you put both stents in the inferonasal quadrant, where the number of collector channels is greatest, you're very likely to end up in close proximity to a collector channel. Likewise with Hydrus. It's 8 mm long, so you can put it into the inferonasal quadrant and cover the whole quadrant.

"In essence, the issue of where to put the stent in the angle goes away to some extent if you're using the iStent inject or the Hydrus," he says. "That's a nice advantage over the original iStent concept. So if you've been sitting on the sidelines because you found the original iStent procedure a bit tricky or couldn't figure out the best location for the stent, you should find the new options easier to use."

Dr. Samuelson notes that the insertion of the stent into the canal is also easier with the iStent inject. "My learning curve for the original iStent occurred as an investigator in the FDA trial," he says. "Doing my first 20 cases or so, I didn't have nearly as much confidence that I was getting the stent into the canal every time [as I did later]. In contrast, the new version is easier to implant; it uses a different insertion technique. Instead of circumferential placement requiring a lateral motion and checking the depth of the stent, this is a straight-in

insertion. I suspect that surgeons will like the new design and find it easier to use than the original iStent."

Dr. Crandall, however, notes one drawback to the new way of implanting the stent used in the iStent inject. "Although the new device is easier to use, the fact that you're injecting the stent rather than inserting it means that it can easily go into the wrong spot," he points out. "If the original stent was not in the canal, it was pretty obvious; then you could make another attempt to get it in. But the new device can be inadvertently injected just above or below the canal, and you won't necessarily realize that it's not in the canal. If it's a lightly pigmented eye you could end up too high, close to Schwalbe's line. In that situation you might suspect that something's wrong, because you should see blood coming out if you get the stent into the canal. But even in the canal you won't always see blood, so you might conclude that everything is OK and proceed to place the second stent. If you hit too low you could end up in the ciliary body or right below the canal, and the stent would still go right in.

"The bottom line is that there is still a skill set involved," he concludes. "To their credit, the Glaukos people know that and they emphasize the need for lots of practice, to make sure surgeons can identify the canal, which is sometimes not easy to do."



One obvious question is how much better the outcomes might be with two stents implanted rather than one. Dr. Samuelson explains that this question is harder to answer than one might expect. “The reason that’s hard to determine is that since the original iStent trial, the FDA has changed its study design recommendations,” he says. “Now the study design and study power is based on generating two-year data and a three-to-one randomization. In addition, unlike the original iStent trial, more recent MIGS trials include a terminal washout of glaucoma medications to eliminate the confounding effect of those medications on IOP. Those changes make it a little hard to compare the original iStent study to the subsequent MIGS studies, head-to-head.

“Nevertheless, I suspect the improvement in efficacy compared to the original design is not going to be overwhelming,” he says. “The big improvement will be in terms of ease of implantation. I don’t mean to imply that two stents wouldn’t be better than one; I think the data have demonstrated that they are.<sup>2</sup> It’s just a little bit difficult to prove that by comparing the results of the original iStent trial to the results of the iStent inject trial, because of the difference in study design.”

## Comparing the Options

Since the premise of the iStent inject is achieving improved outflow via better access to the collector channels, surgeons may wonder about the relative merits of the iStent inject compared to the Hydrus, which should provide even greater access to the channels, at least in theory. “The Hydrus has a lot of promise,” says Dr. Samuelson. “The data from the HORIZON trial, which is the pivotal U.S. trial for Hydrus, was extremely favorable—probably the best MIGS data that we’ve seen to date, in terms of the important combination of sustained efficacy and safety. There’s also a randomized, multicenter, international study soon to be published, the COMPARE trial [sponsored by Ivantis], in which Hydrus compared favorably to two iStents. The advantage of Hydrus is the tri-modal mechanism. First, it provides a direct inlet into the canal because the tail end of the Hydrus resides in the anterior chamber. Second, the main body of the Hydrus, the remaining 7 mm or so, sits within the canal, maintaining its patency. Third, it also tensions the canal tissue, improving physiological outflow.”

Dr. Crandall notes that a recent trial that compared the Hydrus to the iStent used the original iStent, not the iStent inject. “The paper with the data hasn’t been published yet,” he says. “If the Hydrus did better than the single iStent [in that study], that shouldn’t be a surprise; the Hydrus accesses at least 90 degrees of the canal, so its

# NuLids™ transformational dry eye therapy

## Transforms your practice

The NuLids System helps reduce patient out-of-pocket expenses while creating an additional revenue stream for the practice – all without impacting overhead costs or disrupting other in-office treatments.

A multi-center study<sup>1</sup> showed 95% were satisfied or very satisfied with the treatment.

For more information visit  
[www.NuSightMedical.com/rophi9](http://www.NuSightMedical.com/rophi9)  
or call us at 833-368-5437

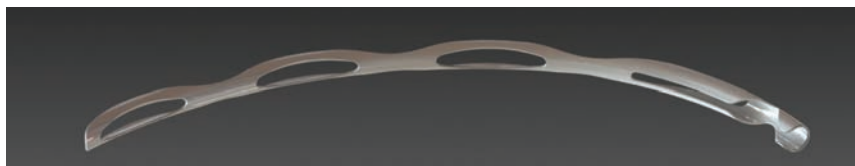<sup>1</sup> Schanzlin, Olkowski, Coble, Gross. NuLids II Study, April 2018




**NuLids™**

*Doctor prescribed, at-home dry eye relief*





The Hydrus Microstent features a tri-modal mechanism: The tail end, sitting in the anterior chamber, provides a direct inlet into Schlemm’s canal; the body of the stent maintains the patency of the canal; and the device tensions the canal tissue, improving outflow through it.



odds of accessing one or more outflow channels is much greater. But there’s no study comparing the Hydrus to the iStent inject.”

“Despite the promise of Hydrus, There will no doubt be proponents of both canal devices,” says Dr. Samuelson. “Some surgeons might prefer the iStent inject because it’s a ‘stealth’ device and the least-tissue-disruptive canal intervention. On the other hand, many surgeons will like the Hydrus design, and the fact that you can directly verify that it’s exactly where you want it to be in the canal because you can see it through the translucent inner wall.

“The only head-to-head data available favors Hydrus (the COMPARE trial), yet some will argue that with the Hydrus you’re manipulating 8 mm of the canal in a very important region,” he continues. “As a result, there could be some fibrosis over time that might not occur with a very stealthy implantation like the iStent inject, which is very tissue-friendly and maintains the normal architecture of the canal as much as possible. The data clearly show that cataract surgery alone improves physiologic function, so one might argue that it makes sense to disrupt the tissue as little as possible while augmenting outflow. For some, that concept might favor an iStent approach. You put in two minimally tissue-disruptive, extremely focal stents, leaving 98 percent of the canal normal, but improved from the phaco effect. Time will tell, but I’m confident that there’s room for more than one canal device, just as we have multiple IOL

platforms and phaco machines.

“Ultimately, the device that surgeons favor may depend on what long-term data shows in a large population of patients,” he adds. “More comparative data will be forthcoming, and both devices should really improve the MIGS portfolio.”

### The Road Ahead

Dr. Crandall says he expects the iStent inject to overshadow the original iStent in the marketplace very quickly. “I don’t think there’s any question about that,” he says. “The inject gives you two shots at hitting an outflow channel, and although it still requires gonioscopy skill and a good understanding of the anatomy to get it into the correct spot, it’s easier to use. In my experience, the Hydrus is a bit easier to insert than the original iStent, but I find the iStent inject to be even easier than the Hydrus. I think the iStent inject will replace the original iStent very quickly.”

Regarding whether these devices might someday be used separately from cataract surgery (i.e., off-label), Dr. Samuelson says he can imagine that happening. “I think the iStent may be a little more dependent on the phaco component of the procedure than another MIGS device such as the CyPass or Hydrus,” he says. “Nevertheless, I see them all as having a role in standalone surgery.”

What about the possibility of a device containing three or more iStent implants? “I would think that implanting more stents might allow you to tap

into more collector channels, and in general, the more the better,” he says. “However, there could be a limit at some point to how many are useful, especially in that segment of the population that has more distal disease.”

Dr. Crandall says he believes the new iStent device will eventually be used in the United States independently of cataract surgery as well as in concert with it. “Everywhere else in the world surgeons use the iStent by itself, as they do with most other MIGS devices,” he points out. “In the United States, to get through the regulatory pathway, use of the device had to be combined with cataract surgery to ensure that the outcomes would be impressive enough to have a good chance of approval by the FDA. That was true for Hydrus, too. The iStent will remain in that regulatory category for a while, I expect, but eventually surgeons in the U.S. will start using it by itself. That will also move us in the direction of trials comparing the different MIGS devices head-to-head, which will give us a lot of useful data.” **REVIEW**

*Drs. Crandall and Samuelson both consult for Ivantis and Glaukos.*

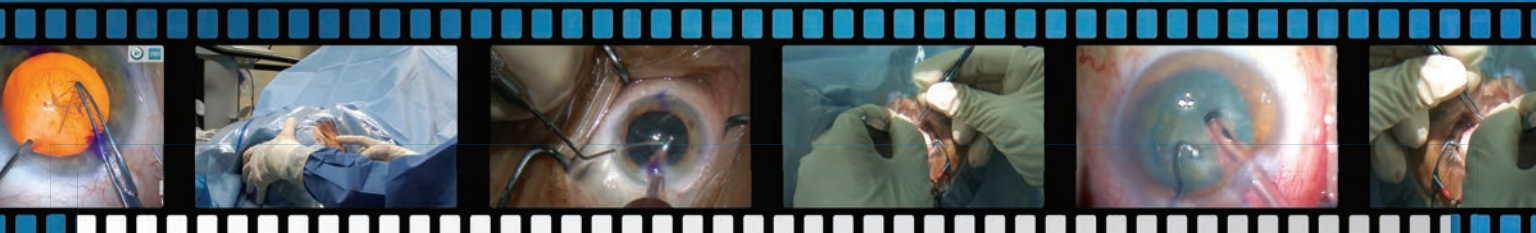
1. Samuelson TW, Chang DF, Marquis R, et al. A Schlemm canal microstent for intraocular pressure reduction in primary open-angle glaucoma and cataract: The HORIZON study. *Ophthalmology* 2018 Jun 23. pii: S0161-6420(17)33810-1. doi: 10.1016/j.ophtha.2018.05.012. [Epub ahead of print]
2. Belovay GW, Naqi A, Chan BJ, Rateb M, Ahmed II. Using multiple trabecular micro-bypass stents in cataract patients to treat open-angle glaucoma. *J Cataract Refract Surg* 2012;38:11:1911-7.



Monthly

# MACKOOL ONLINE CME

## CME SERIES | SURGICAL VIDEOS



To view CME video  
go to:

[www.MackoolOnlineCME.com](http://www.MackoolOnlineCME.com)

### Episode 33: "MIGS: Placement of a Trabecular Meshwork Stent to Lower IOP"

Surgical Video by:  
Richard J. Mackool, MD

#### Video Overview:

We change it up a bit this month by showing two implantations of a stent into the trabecular meshwork in eyes with glaucoma. The first case shows a straightforward insertion, and the second demonstrates successful insertion after failure of the initial attempt. The cataract and IOL insertion of each case were routine, so we present only the MIGS portion of each case.

## MackoolOnlineCME.com MONTHLY Video Series



Richard J. Mackool, MD

Welcome to the third year of Mackool Online CME! With the generous support of several ophthalmic companies, I am honored to have our viewers join me in the operating room as I demonstrate the technology and techniques that I have found to be most valuable, and that I hope are helpful to many of my colleagues. We continue to edit the videos only to either change camera perspective or to reduce down time - allowing you to observe every step of the procedure.

As before, one new surgical video will be released monthly, and physicians may earn CME credits or just observe the case. New viewers are able to obtain additional CME credit by reviewing previous videos that are located in our archives.

I thank the many surgeons who have told us that they have found our CME program to be interesting and instructive; I appreciate your comments, suggestions and questions. Thanks again for joining us on Mackool Online CME.



**CME Accredited Surgical Training Videos Now Available Online: [www.MackoolOnlineCME.com](http://www.MackoolOnlineCME.com)**

Richard Mackool, MD, a world renowned anterior segment ophthalmic microsurgeon, has assembled a web-based video collection of surgical cases that encompass both routine and challenging cases, demonstrating both familiar and potentially unfamiliar surgical techniques using a variety of instrumentation and settings.

This educational activity aims to present a series of Dr. Mackool's surgical videos, carefully selected to address the specific learning objectives of this activity, with the goal of making surgical training available as needed online for surgeons motivated to improve or expand their surgical repertoire.

#### Learning Objective:

*After completion of this educational activity, participants should be able to:*

- Discuss the technique and demonstrate the insertion of a stent into the trabecular meshwork

**Satisfactory Completion** - Learners must pass a post-test and complete an evaluation form to receive a certificate of completion. Your chosen sessions must be attended in their entirety. Partial credit of individual sessions is not available. If you are seeking continuing education credit for a specialty not listed below, it is your responsibility to contact your licensing/certification board to determine course eligibility for your licensing/certification requirement.



JOINTLY ACCREDITED PROVIDER™  
INTERPROFESSIONAL CONTINUING EDUCATION

**Physicians** - In support of improving patient care, this activity has been planned and implemented by Amedco LLC and Postgraduate Healthcare Education. Amedco LLC is jointly accredited by the Accreditation Council for Continuing Medical Education (ACCME), the Accreditation Council for Pharmacy Education (ACPE), and the American Nurses Credentialing Center (ANCC), to provide continuing education for the healthcare team

**Credit Designation Statement** - Amedco designates this live activity for a maximum of .25 AMA PRA Category 1 Credits™. Physicians should claim only the credit commensurate with the extent of their participation in the activity.

Endorsed by:

**Review of Ophthalmology®**

Video and Web Production by:  
**JR Snowdon, Inc**

Jointly provided by:

**AMEDCO & PHE**

Supported by an unrestricted independent  
medical educational grant from:

**Alcon**

Additionally Supported by:

**Glaukos  
MST  
Crestpoint Management  
Carl Zeiss Meditec**

In Kind Support:

**Sony Healthcare  
Solutions**

# Dry Eye: Hone Your Diagnostic Skills

Liam Jordan, Associate Editor, and Walter Bethke, Editor in Chief

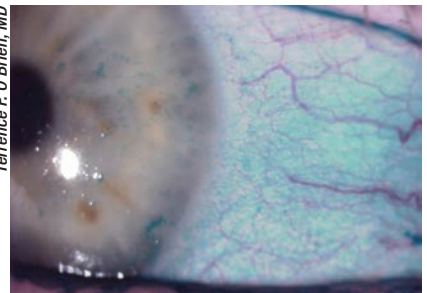
Profit from the experience of these corneal experts.

Physicians say that diagnosing a dry-eye patient, especially one who's seen several doctors already without getting any relief, is akin to trying to have a conversation in the middle of noisy, crowded room. To make any sense of things, you've got to be able to cut through the noise of the patient's varied, and sometimes conflicting, signs and symptoms and focus on certain key elements. In this article, cornea experts describe how you can get to the root of the problem when faced with a suspected dry-eye patient.

## Stop, Look and Listen

Experts say you can learn a lot about a patient both by asking the right questions and by paying careful attention to his eyes as you speak with him.

"The clinical exam starts when they come in the door," says Bennie Jeng, MD, Chair of the Department of Ophthalmology and Visual Sciences at the University of Maryland School of Medicine. "I watch them as we chat; I want to see their blink rate and the position of their lids. Many patients come in and say, 'I've been diagnosed with dry eye,' but as I watch them I notice they instead show signs of lower-lid ptosis, have incomplete blinks, or are older and pre-Parkinson's and don't blink. Their problem isn't really dry



Moderately severe dry eye with diffuse staining of conjunctival and corneal epithelium with lissamine green.

eye, it's exposure. You can give this type of patient artificial tears every hour and it's not going to solve their exposure problem."

Deepinder Dhaliwal, MD, director of refractive surgery and the Cornea Service at the University of Pittsburgh Medical Center, and a professor of ophthalmology at the University of Pittsburgh, also watches patients' blinking and behavior. "I look at how much they're touching their eyes," she says. "A lot of people with chronic irritation will try to pick mucus out of their eyes, or just keep touching them, and cause mucus fishing syndrome." In mucus fishing syndrome, touching the conjunctiva to remove mucus irritates the conjunctiva, which then produces more mucus. The patient then touches it again to remove the new mucus, perpetuating the cycle.

SYSTANE® COMPLETE:

# OUR MOST ADVANCED SOLUTION. ONE SIMPLE CHOICE.<sup>1-2</sup>

Our most innovative drop works to restore the tear film. It provides optimal relief by addressing **every major type of dry eye**.<sup>1-7</sup>

- Evaporative Dry Eye**
- Aqueous-deficient Dry Eye**
- Mixed Dry Eye**



**The Relief is Real™**



With **advanced, lipid nano-droplet technology**, the lubricant is rapidly delivered across the ocular surface—resulting in **better coverage\*** to provide **fast hydration and locking in moisture for long-lasting relief**.<sup>1-2,5,6,8</sup>

**TALK TO A REPRESENTATIVE TO LEARN MORE**

\*Compared to SYSTANE® BALANCE.

1. Ketelson H, Rangarajan R. Pre-clinical evaluation of a novel phospholipid nanoemulsion based lubricant eye drops. Poster presented at: The Annual Meeting of the Association for Research in Vision and Ophthalmology (ARVO); May 7-11, 2017; Baltimore, Maryland, USA. 2. Data on file, Alcon; 2017. 3. Fernandez KB, Epstein SP, Raynor GS, et al. Modulation of HLA-DR in dry eye patients following 30 days of treatment with a lubricant eyedrop solution. *Clin Ophthalmol*. 2015;9:1137-1145. 4. Davitt WF, Bloomenstein M, Christensen M, Martin AE. Efficacy in patients with dry eye after treatment with a new lubricant eye drop formulation. *J Ocul Pharmacol Ther*. 2010;26(4):347-353. 5. Korb D, Blackie C, Meadows D, Christensen M, Tudor M. Evaluation of extended tear stability by two emulsion based artificial tears. Poster presented at: 6th International Conference of the Tear Film and Ocular Surface: Basic Science and Clinical Relevance; September 22-25, 2010; Florence, Italy. 6. Lane S, Paugh J, Webb JR, Christensen MT. An evaluation of the in vivo retention time of a novel artificial tear as compared to a placebo control. Poster presented at: The Annual Meeting of the Association for Research in Vision and Ophthalmology (ARVO); May 3-7, 2009; Fort Lauderdale, FL. 7. Craig JP, Nichols KK, Akpek EK, et al. TFOS DEWS II definition and classification report. *Ocul Surf*. 2017;15:276-283. 8. Torkildsen G. The effects of lubricant eye drops on visual function as measured by the Inter-blink interval Visual Acuity Decay test. *Clin Ophthalmol*. 2009;3:501-506.

## Point-of-Care Tests

If you're looking to add some data points to your dry-eye exam, you might give these tests a look:

- **Advanced Tear Diagnostics TearScan.** This system tests a tear sample for the level of the protein lactoferrin, which appears to be associated with dry eye. In the 510(k) approval study, the sensitivity of the test was 83 percent (severe dry-eye cohort), and the specificity was 99 percent (normal cohort).
- **Bausch + Lomb Sjö Test.** The company says this blood test may help physicians detect Sjögren's syndrome in patients with dry-eye complaints. It tests for four traditional biomarkers and three novel ones, B + L says.
- **Johnson & Johnson Vision/TearScience LipiView II/LipiScan.** The LipiView II system images the meibomian glands, visualizes and measures the thickness of the lipid layer and helps detect partial blinks. LipiScan is a smaller unit that just provides the gland imaging.
- **Oculus Keratograph 5M.** This is a combination corneal topographer, keratometer and color camera. Oculus says it can help image the meibomian glands and tear breakup time, measure the tear meniscus height and let you evaluate the lipid layer.
- **Quidel InflammaDry.** This is a rapid, qualitative test for the presence of the inflammatory biomarker metalloproteinase-9 in tears. The company says this can help give you some idea of the role of inflammation in the dry-eye complaint.
- **TearLab Osmolarity Test.** Tests for the level of osmolarity in the tears of a suspected dry-eye patient. Readings above a certain level, either from one eye or in terms of the difference between the eyes, are deemed abnormal and might indicate an issue with the ocular surface's health.

Dr. Dhaliwal also says if you don't take control of the exam from the beginning, you risk being drawn into a 45-minute, meandering discussion. Don't let the patient come in and immediately dictate that the diagnosis is dry eye, even if he's seen other doctors already. "I've found that the most effective thing I can do is ask, 'What are the top three things that bother you about your eyes?'" she says. "If you instead start with an open-ended question such as, 'Tell me more about your dry eyes,' the patient will launch into a litany of complaints and such, which takes a lot of time and often doesn't work well with clinic flow and scheduling. After asking the top-three question, patients' responses can be fascinating. You'd think the typical dry-eye patient would say that his eyes burn or hurt—but no. Sometimes they'll talk about their 'decreased vision.' This isn't just fluctuating vision, which I'd expect with dry eye, but actual decreased vision, which they blame on their dry eye. In one patient, this decreased vision wasn't dry eye—it was a cataract. I've had another patient

say the number-one problem was itching that he said was from his 'dry eye.' But itching isn't dry eye, it's allergy. So, unless you ask the question and the patient answers in his own words, you don't know what you're dealing with.

"The other benefit of them stating these top three issues is that you then have very clear goals," Dr. Dhaliwal continues. "If they say their eyes burn, then your goal is to decrease that. If it's fluctuating vision, then we know we have to deal with that."

Dr. Jeng says the timing of the patient's symptoms is also a clue. "If it's truly dry eye, it tends to get worse as the day goes on," he says. "If, instead, they say the problem starts first thing in the morning, then there are one or two issues at work: One, it's not dry eye; and, two, it's probably due to exposure during the night, because if their eyes are closed during the night, they shouldn't be drying out."

Physicians say it's also important to find out what medications the patient is taking, since many systemic medications, such as anti-depressants and anti-histamines, can impact the ocular

surface. Something as simple as getting the patient off of an oral allergy drug and treating the problem locally can make a difference.

## Exam Tips

Experts say the exam is especially important in possible dry-eye patients, because of the relationship, or lack thereof, between signs and symptoms in the disease.

"There is a disconnect between signs and symptoms," explains Terrence P. O'Brien, MD, professor and Charlotte Breyer Rodgers Distinguished Chair in Ophthalmology at the Bascom Palmer Eye Institute of the Palm Beaches in Florida. "Most dry-eye patients complain of irritation, such as dryness, foreign body sensation and burning, but fluctuation in vision—especially with the excess screen time seen in younger patients—can be one of the early symptoms that's overlooked. Paradoxically, however, some patients with moderate to severe disease may have very few symptoms, while others will have disabling symptoms."

Dr. Jeng describes his approach to the physical examination: "I look at the lid position, blink rate and the completeness of blinks," he says. "I check for lagophthalmos by having them lie back and pretend to go to sleep, but tell them not to squeeze their eyes and instead just relax. I look to see if there's any exposure as they close their eyes. As part of this, I'll ask if anyone sees them while they're asleep, and often, they'll say their spouse sees them. I'll follow-up by asking the spouse (if present) if the patient sleeps with their eyes partially open, or I'll ask the patient if anyone's ever told them they sleep like this. If they tell me that they've always slept with their eyes partially open, and they say their symptoms are bad right from the get-go in the morning, that's a clue that it's an exposure issue."

To help cut through the confusion of patients' complaints, during the exam

# FEMTOBILITY™ TOUR '18

## FLACS

- Clear Corneal Incisions
- Arcuate Incisions
- Anterior Capsulotomy
- Lens Fragmentation

## INTERMISSION

### Cornea

- 2D and 3D  $\alpha$ -LASIK
- Intracorneal Rings
- Intrastromal Pocket
- Lamellar Keratoplasty
- Penetrating Keratoplasty



Play the Femto Z8 Laser's greatest hits at your practice.

No other Femtosecond Laser plays the hits like a rock star Ziemer Z8. And now, during our Femtobility Tour '18, you can try one first hand. We'll train you and your staff, and you'll have plenty of time to see for yourself.

Our compact, mobile and ROI-friendly Femtos are ready to make house calls. So, schedule one at [ziemerusa.com/roadtrip](http://ziemerusa.com/roadtrip) or contact Wayne Hopkins at [wayne.hopkins@ziemergroup.com](mailto:wayne.hopkins@ziemergroup.com) for details.

Dr. Dhaliwal will instill a drop of artificial tears without telling the patient the nature of the drop, and ask if it relieves the pain/discomfort/burning, etc., for even five seconds. “If it’s a true dry-eye patient, it will help for at least five seconds,” she says. “If they say no, then I’ll instill a drop of proparacaine—without telling them what it is—and ask how their pain is. If that doesn’t relieve it, then I know I can’t help them either; helping the ocular surface won’t help this deep, neuropathic pain.”

In her exam, Dr. Dhaliwal pulls down the patient’s lower lids and has him look up, then pulls up the upper lids and has him look down. He then looks left and right. “Look to see how floppy their lids are,” she advises. “Look for areas of hyperemia or superior limbic keratoconjunctivitis.”

During the exam, physicians will assess the meibomian glands in order to gauge their effect on the patient’s complaints. After various testing (*see below*), Dr. Dhaliwal will use a Q-tip to push on the glands and evaluate the secretions. She also examines the base of the lashes to check for Demodex and/or to categorize any blepharitis.

## Helpful Tests and Stains

Most physicians rely on their exam and the patient’s symptoms when diagnosing dry eye, but note there are some tests that provide useful insights.

Though it can take a relatively long time and isn’t too popular with patients, some physicians will administer a Schirmer’s I test (without anesthesia). “If the result is low—between a zero and a 2—one knows that there truly is aqueous deficiency,” says Dr. O’Brien. Dr. Dhaliwal, in an effort to gauge patients’ tearing but avoid some of the issues with Schirmer’s testing, prefers to use a phenol red thread, or zone quick, test in patients with a very low tear lake. “You put in the phenol red thread and assess the amount of tear production over 15 seconds,” she explains.

“It’s easier than Schirmer’s and patients don’t complain too much about it.”

Some clinicians use a few newer, point-of-care tests to garner more data. “I’ve found tear osmolarity testing helpful, but I don’t use it in every patient,” says Christopher Rapuano, MD, chief of Wills Eye Hospital’s Cornea Service. “I use it in the patients in whom I’m suspicious of a dry-eye issue or in whom there’s something unusual that doesn’t quite fit.” He says a high osmolarity can be a vote to continue with treatment, but a low result might incite him to look for something else, such as conjunctivochalasis.

Dr. O’Brien will also sometimes administer the InflammADry test for the inflammatory marker metalloproteinase-9. “This is a biomarker of inflammation,” he explains. “It’s not perfect—it’s semi-quantitative, not 100-percent quantitative—but it can help us confirm the presence of ocular inflammation and can be helpful when monitoring the effect of chronic immunomodulatory therapy. With positive results, the patient can be informed, ‘Your tears show inflammation,’ in order to reinforce the necessity for chronic use of various anti-inflammatory medications.”

Dr. Rapuano has the original LipiView device. “LipiView I images the tear lipid layer, which we have found helpful in determining partial blinkers, but not that helpful in determining MGD,” he says. “We don’t have LipiView II, which does do meibomian gland imaging. I do think there’s good rationale for imaging the glands for treatment and diagnosis, and for showing patients that they have gland dropout.”

Whatever ancillary tests are used, the physicians note that tear-film breakup time and staining are cornerstones of the diagnosis. Dr. Jeng says it’s important to remember that, although staining is important, not all staining equals dry eyes. “One of the common things we see is diffuse corneal stain-

ing in patients who’ve been told that they have dry eye and, as a result, have tried many different treatments,” he says. “However, this turns out to be toxicity from too many drops. It doesn’t mean they didn’t start out with dry eye, just that now they’re overmedicated. Treating these patients is a challenge because the treatment is to take away medicines, while we’re trained to give them to patients.”

Dr. Jeng identifies some other staining patterns and what they might indicate: “Superior corneal staining is not dry eye,” he emphasizes. “Swirling staining indicates limbal stem cell deficiency issues. Inferior conjunctival staining only—without cornea staining—can be a sign of mucus fishing syndrome.

“Dry-eye staining is usually in the inferior third or half of the cornea,” Dr. Jeng continues, “along with staining of the inferior limbus and inferior and lateral conjunctiva.”

Another step in determining that aqueous deficiency is present involves examining the tear lake. “Make sure that it’s the appropriate size/volume,” Dr. Jeng says. “If they don’t have an adequate tear lake, it could be aqueous deficiency.” If practices are so-equipped, they can also use anterior segment OCT to measure tear parameters. “This is a quantitative way of looking at the tear meniscus dimensions to assess tear volume, and provides very useful information in select patients,” says Dr. O’Brien.


In the end, Dr. Dhaliwal says that listening to the patient’s main complaints, regardless of what previous physicians have told them, and doing your own exam will cut through the noise. “With some patients,” she says, “you have to untangle the mess—but do it efficiently.” **REVIEW**

*Dr. Rapuano consults for TearLab. Drs. Dhaliwal, Jeng and O’Brien have no relevant financial interests to dry-eye diagnostic devices or tests.*



# SMART IS BETTER

TRANSFORM YOUR PRACTICE WITH  
ARTIFICIAL INTELLIGENCE



OPHTHALMOLOGY'S  
EHR & PM Leader for  
33 YEARS

Our Advantage SMART Practice™ suite of All-in-One Solutions use real-time data from your clinic to optimize efficiency, improve outcomes, and increase revenue.

EHR | PM | RCM | ASC | OPTICAL  
ANALYTICS | PATIENT ENGAGEMENT  
TELEHEALTH | ENTERPRISE PROVEN  
2015 ONC CERTIFIED

SEE IT LIVE. AAO 2018 ANNUAL MEETING. BOOTH 2232

[WWW.COMPULINKADVANTAGE.COM/ONETAB](http://WWW.COMPULINKADVANTAGE.COM/ONETAB) | 800.456.4522



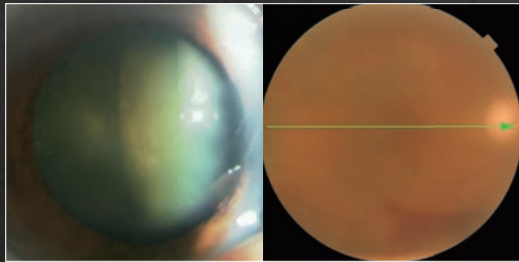
It's time for Triton.



YOUR VISION. OUR FOCUS.

It's time to see through opacities.

**FDA CLEARED**



SS-OCT

Contact your local Topcon Representative today  
or visit [newsgram.topconmedical.com/triton](http://newsgram.topconmedical.com/triton).



DRI OCT Triton™ Series  
A Multimodal Swept Source OCT

# Dry Eye: Managing Causes and Severities

Christopher Kent, Senior Editor

As awareness of the impact of dry eye grows, surgeons are learning to tailor their treatments. Here's help.

Treating dry eye—once widely considered a “nuisance diagnosis”—has now become the focus of countless clinical studies, products and articles. And as interest in managing dry eye has increased, the need to understand the details of a given patient's problem and refine your treatment to appropriately address those details has also grown.

Here, surgeons well-versed in the details of dry-eye treatment share their experience and advice regarding managing the different dry-eye diseases and severity levels that you're likely to encounter in your patients.

## The Problem with “Severity”

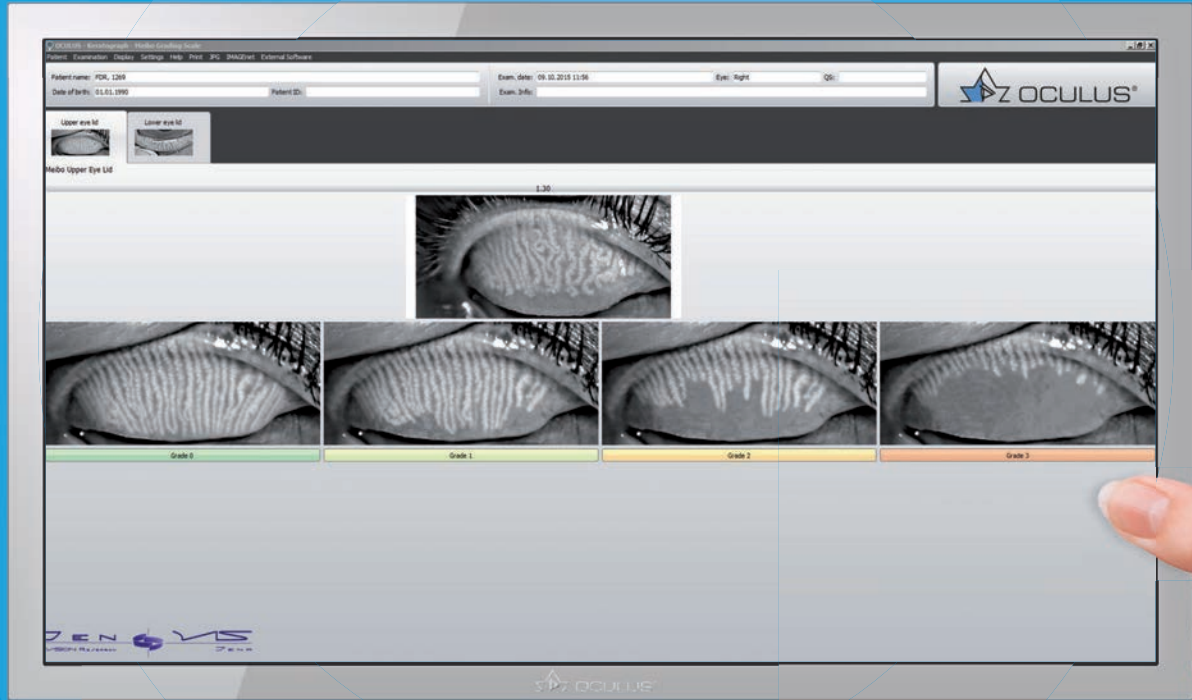
“Discussing severity in the field of dry eye is confusing,” notes Esen K. Akpek, MD, the Bendann Family Professor of Ophthalmology and Rheumatology at Johns Hopkins University School of Medicine, and director of the Ocular Surface Disease and Dry Eye Clinic at the Wilmer Eye Institute. “The reason for this is that what might be severe for the patient doesn't necessarily look severe to the physician—and what looks severe to the physician might be trivial for the patient. The confusion is compounded by the fact that the field is relatively new and evolving. There are

no agreed-upon, tried-and-true core outcome measures, like the ones you would use when designing a clinical study. We don't know which specific sign or symptom matters in the long run.

“That's not the case in many other areas of ophthalmology,” she continues. “For example, in glaucoma, the core outcome measures are changes in optic nerve cup-to-disc ratio and the visual field. In the field of dry eye, some of the measures that have been used matter to physicians; some matter to patients; and some matter to entities that approve drugs, such as the FDA. The problem is that none of them matter to all of these groups at the same time, and none is known to have a bearing on the long-term outcomes of dry eye.”

Dr. Akpek notes that it used to be widely believed that signs and symptoms of dry eye are discordant. “Based on new research, that may not be true,” she says. “We just published a paper in the journal *Ophthalmology* showing that the symptoms reported by the patient totally correlate with the signs—if you measure them after the patient has been reading for 30 minutes, which stresses the eyes' surface.<sup>1</sup> We found this to be true even in normals, but the worsening was especially noticeable in dry-eye pa-

# OCULUS Keratograph® 5M

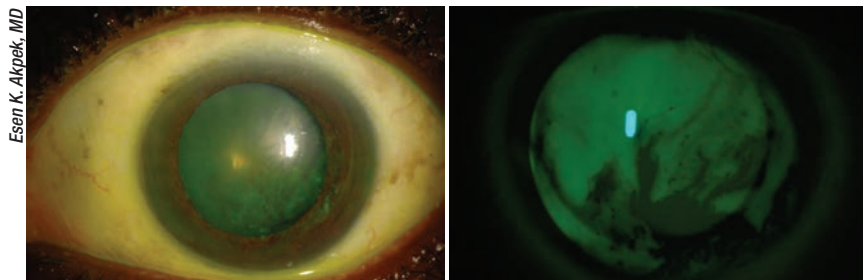


## Let's Focus on Dry Eye!



The Keratograph® 5M assists you in finding the cause of dry eye quickly and reliably. Create a comprehensive analysis of the meibomian glands!

- JENVIS Grading Scales: Easy classification of MGD based on individual meibography
- Meibo-Scan: Analysis of the meibomian glands of the upper and lower eyelids
- Comparative display of meibomian glands from up to four examinations



Esen K. Akpek, MD

Left: Slit-lamp picture of a patient being evaluated for cataract surgery demonstrating poor tear film overlying the cornea. Right: The same cornea under a cobalt blue light, showing a thin and irregular tear film.

tients, probably because they don't have enough tear-film reserve. At that point the dry-eye signs did correlate with the initial baseline symptoms.

"This is similar to angina," she continues. "If you have angina, you get pain upon exertion because of not-so-healthy coronary vessels. If you evaluate the patient at rest, you can't see the problem or measure it, even with an EKG. Similarly, if you measure eyes when they haven't been stressed, the signs of dry eye might not be obvious, especially in mild to moderate disease.

"After doing this study we concluded that what dry-eye patients complain about is absolutely real," she says. "The problem is, when we take a one-time severity measurement in the clinic, it may or may not correlate with what the patient says, depending on whether or not the eyes were recently stressed. For this reason I think we should always base our treatment on what the patient says, even if we don't see the signs. By the time we see the signs of ocular surface disease and staining at the slit lamp, the disease is usually pretty advanced. And if the Schirmer score is bad, that's even worse—that patient has chronic, severe dry eye.

"I used to care mostly about the signs," she concludes. "Now I listen to the patient."

### Determine the Cause First

If there's one key lesson that's

emerging from the growing interest in dry eye, it's that dry eye signs and symptoms can be caused by a number of different problems that previously might have remained undiagnosed. To address the signs and symptoms of dry eye, regardless of their severity, you first need to identify the nature of the exact problem the patient is dealing with.

"You wouldn't necessarily treat a Sjögren's patient with aqueous deficiency the same way you'd treat a rosacea patient with bad blepharitis and evaporative dry eye, or the way you'd treat someone with goblet cell deficiency caused by Stevens-Johnson syndrome, or the way you'd treat someone with Parkinson's who has an incomplete blink," says Kenneth A. Beckman, MD, FACS, director of corneal services at Comprehensive EyeCare of Central Ohio, and a clinical assistant professor of ophthalmology at Ohio State University. (Dr. Beckman was part of the team that developed the CEDARS dry-eye treatment protocol.) "They all have different underlying mechanisms.

"That's why it's important to first find the underlying pathway, keeping in mind that the patient may have multiple conditions," he says. "For example, a patient could have both blepharitis and aqueous deficiency, and you'd need to treat both. After you've determined the etiology, then treat according to the severity level. Don't just use a shotgun approach

and say, 'This person is severe, so he should get this treatment.' Maybe the patient just needs lid-tightening."

### Treating Aqueous Deficiency

Dr. Beckman says that when treating aqueous deficiency he'd start with lubricants. "Lubricants are generally the first step regardless of the underlying cause," he notes. "Then I'd move to anti-inflammatories, such as a steroid or cyclosporine or lifitegrast. If the patient still isn't getting relief, there are more esoteric options that are not necessarily commercially available that you can get compounded, like serum tears or amniotic membrane extract. You can also try punctal plugs. We have lots of options when treating aqueous deficiency." Another option is the recently approved Cequa (cyclosporine ophthalmic solution) 0.09%, from Sun Pharma. Sun says the drug provides the highest approved concentration of cyclosporine A, and can overcome solubility issues by way of nanomicellar technology.

Bruce Koffler, MD, medical director of Koffler Vision Group in Lexington, Kentucky, says he typically bases his treatment choices on the Tear Film & Ocular Surface Society (TFOS) Dry Eye Workshop II report (DEWS II). "The report gave us a nice schematic of severity levels and how we normally treat them," he notes. "If a patient has early disease and falls into category one, I'm a big artificial tear user. I'll try a variety of different tears, whether it be hypo-osmotic or hyperosmotic tears, or tears with different viscosities. Right now we're using preservative-free artificial tears that have new lipid or mineral oil components. Some of the new 'balanced' tear products are also putting omega-3 supplements into the tears."

Dr. Koffler says if symptoms are mild, he's inclined to start with artificial tears in a regular bottle, rather than preservative-free drops in a tu-

## Severe Patient: Start Simple?

One key question regarding treating different severity levels is whether to start with simple, basic treatments or immediately move to more serious ones when faced with a severe patient who hasn't already been treated.

Kenneth A. Beckman, MD, FACS, director of corneal services at Comprehensive EyeCare of Central Ohio, says he prefers to start with the basic treatments and add more options as needed. "I like to proceed stepwise, rather than give the patient a lot of things at once," he says. "I always start with lubricants and perhaps one intervention. Then I'll bring the patient back in six weeks or so to see how he's doing. If he's improving, I may stay the course. If he hasn't improved enough, I may add another option at that point."

Esen K. Akpek, MD, director of the Ocular Surface Disease and Dry Eye Clinic at the Wilmer Eye Institute, says that when faced with a patient who has severe dry eye, she doesn't start with the most basic treatments. "I'm used to seeing people with very

severe dry eye, such as Sjögren's or graft-versus-host disease," she explains. "These patients quickly lose vision from corneal complications, so I don't have much patience. I treat dry eye as an inflammatory disease, just like uveitis. If it's bad enough that I already see the signs, I hit it with everything I have. I put the inflammation down and work to improve the surface. Then I withdraw bit by bit as the patient improves.

"On the other hand," she continues, "if the patient is young and has mild dry eye—meaning the patient is mildly symptomatic—and there's no underlying systemic inflammatory disease, then I might start with the basics. We can try warm compresses, work to improve the meibum, use artificial tears, limit digital screen time and so forth. But if I see ocular surface signs, then the problem is already severe, and I start the patient on a lot of different things all at the same time."

—CK

berette. "Those patients are not going to use the drops that often, and there are a number of good artificial tears in bottles that are easy to obtain and easy to use," he notes. "Once the patient starts to get more symptoms and is using the tears more often, I might move to thicker artificial tears. I might also look for certain components that would help that patient. For example, I might look for artificial tears that have gelling components in them, so they'll provide a longer-lasting effect. And I might start thinking about switching the patient to preservative-free drops in tubettes, because if the patient is taking them more often, the preservatives might begin to cause ocular surface disease problems." Dr. Koffler says if the dry-eye problem isn't resolved he'll move on to the next treatment category and begin to introduce other treatments.

When patients need more advanced treatment, Dr. Koffler says he often turns to autologous serum tears. "Autologous tears are extremely comfortable for the patient, and they contain multiple active growth factors for healing the epithelial surface," he says. "Because they're kept refrigerated, the coolness is also quite comforting."

Dr. Koffler points out that it's recently become much easier to obtain autologous serum tears. "Our local eye bank, and several other eye banks as well, have been happy to do the autologous tear work for a very reasonable charge," he says. "They have a laminar-flow hood in their facilities, and they can do this under sterile conditions. The blood draw is taken care of as an outpatient, and the charge is typically based on the cost of the goods and the eye bank's overhead. As a result, almost all of my patients can afford this. However, if they can't, our eye bank has obtained a funding grant from the local Lion's Club ensuring that everyone who needs autologous serum tears has access to them."

Another option is amniotic membrane, which Dr. Koffler notes has recently become more readily available, with competition also causing the price to come down. "Today we can get nice round pieces of amniotic membrane to put right on the cornea and cover with a contact lens," he says. "I sometimes use this for really severe dry eye, when the cornea has filaments and surface breakdown. It can help to get the healing started. It's not for long-term therapy, because the mem-

brane may only last three to five days, but it can be repeated."

Dr. Beckman adds that some of his patients have tried the recently approved TrueTear Intranasal Tear Neurostimulator (Allergan). "This is an instrument that's inserted into the nostrils to stimulate the nerves, leading to tear production," he explains. "According to the company, it's been shown to increase aqueous, lipid and mucin production, so it is not just reflex tears. This can bypass the traditional neuro loop and therefore may help in patients with neurotrophic corneas, and it's also useful for patients who cannot or do not want to use drops. My patients have definitely seen an increase in tear production."

## Treating the Meibomian Glands

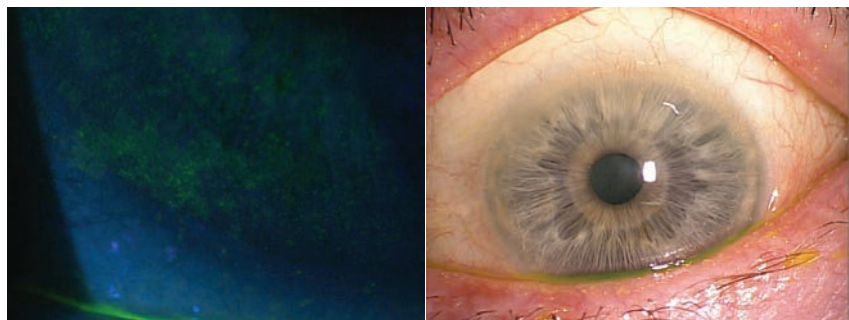
Dr. Akpek says that meibomian gland disease is very underdiagnosed in the field of ocular surface disease. "It reminds me of the old days when we didn't know much about dental plaques, how we get dental cavities, and the importance of flossing and brushing," she says. "By a certain age, everybody wore dentures; that was normal back then. Meibomian

glands are the same. Dust and dirt get in there and you start making poor-quality oil because of changes in hormones and other factors related to aging, menopause, and so forth. Then the glands get clogged up, and over a period of time they get damaged by distention, inflammation, fibrosis and tissue remodeling. They may even die off, and if they do they won't regenerate. This is very common, but it's always been under-recognized. Now I'm beginning to hear researchers say that meibomian gland dysfunction is the most common underlying etiology of dry eye and ocular surface disease."

Dr. Akpek says her experience has convinced her that meibomian gland dysfunction is the main reason dry eye is more common in older individuals. "True aqueous deficiency is actually rare, and I think it's almost always associated with an underlying autoimmune disease, something that causes lacrimal gland inflammation," she says. "On the other hand, meibomian gland disease is age-related and very common. Over the long term it also leads to aqueous tear deficiency because of the ocular surface inflammation that's caused by meibum deficiency."

"If the problem is meibomian gland dysfunction, or lid margin disease, we're going to emphasize warm compresses and lid hygiene," Dr. Beckman says. "We may use antibiotic drops or ointments, omega-3 supplements—which actually could be helpful with any type of dry eye—and cyclosporine or lifitegrast drops. Sometimes we treat these patients with oral antibiotics like doxycycline, and sometimes we get compounded antibiotic drops or ointments such as metronidazole or clindamycin. Some of these treatments are very effective."

In addition, more and more surgeons are using in-office or home-based devices that help to clear blocked meibomian glands. For an in-depth discussion of currently available devices in this category, see "Devices



Bruce Koffler, MD

Left: A slit lamp photograph of dry-eye-related superficial punctate keratopathy, as demonstrated with a Wratten filter. Right: An example of meibomian gland disease with telangiectasia, keratin plugs and a frothy tear film.

for Treating Meibomian Gland Dysfunction" on page 36.

### Treating Other Related Causes

Surgeons offer these suggestions when the problem isn't simple aqueous deficiency or meibomian gland dysfunction:

- **Goblet cell disease.** "If the problem is goblet cell disease, we'll address it with lubricants," says Dr. Beckman. "Cyclosporine and lifitegrast also work really well for this, and these patients may also benefit from compounded vitamin A ointment."

- **Autoimmune inflammatory disease.** "If I believe the patient has an autoimmune inflammatory disease such as Sjögren's or lupus, then I'll start to introduce T-cell inhibitor products that will be anti-inflammatory," says Dr. Koffler. "We may even introduce some mild steroids, either for daily use or as a nighttime ointment, to quiet the inflammation."

Dr. Akpek says she reserves the True-Tear device for patients with severe dry eye, such as Sjögren's-related or graft-versus-host disease-related dry eye. "It seems to improve the ocular surface staining," she notes.

- **Exposure.** "If the dry eye is being caused by exposure, you have to figure out exactly what the problem is," notes Dr. Beckman. "If it's an acute problem like a Bell's palsy, where the patient can't close her eye, that usually

gets better over time. The patient may just need to tape her eyes closed at night and use a lot of lubricants. If it looks like this closure problem is more permanent, the patient may need a tarsorrhaphy or lid tightening, or a gold weight in the upper lid. In this situation, the solution is basically a mechanical repair. It's like a rock in your shoe. You can put all the medicine you want on your foot, but if you don't get the rock out of your shoe, you're still going to have a problem."

### Getting Off to a Good Start

Surgeons offer these strategies to ensure the treatment you provide produces a positive result:

- **Check for dry eye at every exam.** "Many ophthalmologists only look for signs of dry eye when the patient complains," says Dr. Akpek. "Tear film and ocular surface evaluation should be part of the slit lamp exam, and it should be documented. I'm not suggesting that everything needs to be measured in every patient, but checking the inferior tear meniscus and the tear-film breakup time at the slit lamp, even without staining the ocular surface, is free and only takes 60 seconds. Everyone who comes in for an eye exam should have the basic things examined, regardless of the reason for the exam."

Some offices give all patients a questionnaire to elicit any symptoms of dry



eye, but in many practices the staff or the doctor just ask patients directly. "Many offices will use a standard survey like the Standardized Patient Evaluation of Eye Dryness (SPEED) questionnaire, or the Ocular Surface Disease Index questionnaire," notes Dr. Beckman. "In my office our staff asks a series of questions to identify patients who are at risk or have symptoms. If the responses indicate that dry eye may be present, the staff will start the dry-eye workup."

Dr. Akpek points out that any complaint about difficulty with vision should bring up some suspicion of dry eye, even if there are no significant ocular surface signs. "Dry eye has a lot of visual implications—it's not just discomfort, burning and redness; it can really affect vision," she says. "So every time a patient complains of anything relating to quality of vision, dry eye should be assessed."

• **Make sure patients know how to use whatever products they're already using.** "For example, some of our patients still use Lacrisert, the hydroxymethyl cellulose pellets that are inserted into the lower cul-de-sac to melt and provide dry-eye relief over a 24-hour period," says Dr. Koffler. "Lacrisert has been around for several years and it's still available; many patients swear by it. However, knowing how best to use it makes a big difference in whether it really works."

"It's not the easiest thing to put in, and some people get blurring," he continues. "In my experience, if we help the patient by offering suggestions such as putting it in at night, or wetting it initially to start the melting process, we can get a 70-percent compliance rate with this treatment. But if you don't offer some suggestions and explain how to properly put it in, and, you're not going to get a 70-percent success rate. So make sure your patients understand how to make the most of the treatments they're using."

• **Individualize your treatment.**

Even when dry eye is noted, many surgeons use a blanket treatment approach. "A common mistake many ophthalmologists make is not taking the time to look into dry-eye signs and symptoms, because these are not interesting cases," says Dr. Koffler. "It's easy to come in and quickly prescribe a treatment or two without analyzing all the implications and possible causes of the problem. Not addressing the issue carefully can be a disservice to the patient, and may affect the outcome of other procedures."

• **Test every patient with severe dry eye for Sjögren's.** "Sjögren's syndrome is very common and underdiagnosed," notes Dr. Akpek. "It has severe implications for the future of the patient, so it should never be missed. Any patient who has bad dry eye, particularly significant staining of the conjunctiva with lissamine green, should always be tested for Sjögren's."

• **Consider creating a "dry-eye cheat sheet."** Because the list of causes that can lead to dry-eye-related signs and symptoms is fairly long, Dr. Koffler suggests creating a "cheat sheet" listing all the possibilities, to help ensure you don't overlook a possible explanation for the patient's symptoms and your findings. "It's easy to forget some of the possible explanations," he notes. "The problem could be a medication the patient is taking, a blink problem, previous surgeries such as LASIK (which the patient may forget to mention), a meibomian gland issue, an autoimmune disease, an environmental problem, and so on. Having a cheat sheet could help prevent you from overlooking a likely source of the problem that needs to be addressed."

### Managing the Treatment

These strategies can help keep your treatment on the right track:

• **Don't overlook the impact of the patient's existing medications.**

# S4OPTIK

## OPHTHALMIC CHAIR 2000

### Precision Engineering



**Effortless cradle tilt recline** with perfect counterbalance; allow convenient patient positioning with one-handed release & control mechanism.

# S4OPTIK

250 Cooper Ave., Suite 100 Tonawanda NY 14150

[www.s4optik.com](http://www.s4optik.com) | 888-224-6012

Sensible equipment. Well made, well priced.

For today's modern office.

## The Patient Communication Factor

As with any treatment, aligning the patient's expectations with reality is important.

- **Make sure the patient understands that dry eye is a chronic condition.** "You don't want a gap between what the patient expects and what you're able to deliver," says Young Choi, MD, medical director at InVision Ophthalmology in Homewood, Alabama. "Patients are often looking for a magic bullet. They assume that if they have the right medication, all of their symptoms will go away and they won't ever have dry-eye problems again. That's a setup for trouble because the patient may never be satisfied, no matter how good the care you're providing is."

"I think doctors don't always appreciate how important it is to communicate to the patient that dry eye is chronic," he continues. "Patients need to understand that we can do a lot to lessen the symptoms, but the problem is never going to completely go away."

- **Don't tell the patient that he has dry-eye disease if the problem is meibomian gland disease, a blink problem or another issue.** "Don't jump to the diagnosis of dry eye," says Bruce Koffler, MD, medical director of Koffler Vision Group in

Lexington, Kentucky. "One of the things I've learned over the years is that we overuse this diagnosis. We do this at times because we get frustrated. A patient with grittiness, burning and redness is like a patient seeing an orthopedic surgeon for low back pain; there are so many things that can cause these symptoms that when we don't have a quick, simple answer we just label it 'dry eye.'

"If we do that, I think we're doing the patient a disservice," he continues. "A diagnosis of dry eye implies aqueous deficiency with classic staining or increased debris in the tear film. In fact, the patient may have rosacea, or a staph infection, or nighttime exposure because of a blinking problem. If the patient is told he has dry eye, he'll Google that and get all kinds of misinformation about what's happening to him and what needs to be done."

"Of course, some patients may have multiple issues, including true dry eye," he adds. "But if the patient has meibomian gland disease, let's call it that. If the patient has a blink disorder, let's call it that. Make sure we diagnose the problem correctly, and then let's not lump all of these issues under 'dry-eye disease.'"

—CK

"Doctors often forget to consider the possible effects of medications a dry-eye patient is already taking—especially when patients come in with a very long medication list," notes Dr. Koffler. "However, it's really important to know if a medication the patient is taking can cause dry eye. The problem could simply be that they're taking an allergy medicine with antihistamine, an anticholinergic for their stomach, or an antidepressant that's having an anticholinergic effect."

"In addition," he says, "some patients who are already taking drops for their ocular discomfort could be having issues with those products, which may not even be addressing their real problem. I had a patient today who was having trouble with her drops; it turned out she had rosacea, meibomian gland disease and a secondary staph infection along the lid margin."

There's also the issue of whether the individual has been using the most appropriate drops up to now. Dr. Koffler points out that a general ophthalmologist seeing a patient about a dry eye for the first time should always ask about this. "Is it the tear that would be most helpful for this patient?" he

asks. "Should you move the patient to a more balanced tear? Is the patient using a tear that contains preservatives every 15 minutes? If so, you'd better switch the patient to a preservative-free product. Of course, if the patient has already tried a variety of artificial tears, then you need to move on."

Dr. Beckman points out that ocular medications can actually be contributing to the problem. "For example, it's common to treat glaucoma with eye drops that can significantly contribute to dry eye," he notes. "If your glaucoma patient has a dry-eye problem, consider other glaucoma treatment options such as SLT, and using preservative-free drops that might be a little more surface-friendly."

- **Consider using Restasis or Xiidra early on.** "When Restasis first came out, doctors waited to prescribe it until the problem was pretty severe," says Dr. Beckman. "They thought it was the kind of medication you only use on really advanced cases. In my experience, that's not true. I think Restasis and Xiidra work better early on, before there's too much damage, so I don't hesitate to start a patient on them early in the disease."

- **Treat for signs, not just symptoms.** "Some patients will have severe dry eye with minimal symptoms," notes Dr. Beckman. "A patient who had a history of herpes in the eye may have a neurotrophic cornea and not feel the poor condition of the cornea, but you may find a lot of staining and scarring. So you have to factor in both the signs and the symptoms."

- **Don't be too quick to move past artificial tears.** "Even within the category of artificial tears, you have a tremendous range of choices to pick from, so you can probably stay in that treatment category for a little while," Dr. Koffler points out.

- **Remember that the patient may need multiple treatments.** Dr. Beckman notes that many patients and doctors don't appreciate that dry-eye treatment often requires resorting to multiple options. "If a patient has an infection, you might give him an antibiotic and the infection is cured," he says. "Dry-eye disease is more like glaucoma; sometimes you need multiple treatments to get the pressure down. Putting the patient on cyclosporine might make the patient 50 percent better, but to really get relief

you may need to add something else, whether it's punctal plugs or liftegrast. Many patients and doctors don't seem to understand that. Certainly the insurance companies don't, because it's very difficult to get them to cover a second drop. But the drops have different mechanisms, and they're pretty symbiotic."

### Monitoring Progress

Once the patient is being treated, it's important to stay on the case.

• **Remember that treatment may improve signs before symptoms.**

Dr. Beckman notes that improvement in signs and symptoms doesn't always happen simultaneously. "Sometimes I see an improvement in my findings, but the patient doesn't note any improvement in her symptoms," he says. "Patients may assume the medication didn't work, when in actuality it is working; it just takes time for them to feel it. In my experience, almost all patients improve with treatment."

• **Don't be too quick to switch treatments.** "Usually, if someone comes to me and says he failed on one of these medications, it's because he wasn't on it long enough," says Dr. Beckman. "Sometimes a doctor may not notice that the signs have improved—only that the symptoms didn't improve. Patients may come in with corneal staining resolved and osmolarity and tear-film breakup time improved, but they still have severe symptoms, so the doctor decides to switch to a different treatment. That's really not the best way to proceed. The patient just needs a little more time on the treatment, or the doctor needs to add something else."

• **On the other hand, be ready to back away from something that's not working.** "We can't afford to get frustrated with a patient if the patient can't tolerate the side effects of something we prescribe," notes Dr. Koffler. "We tend to think that dry-eye prod-

ucts can't really do any harm, but some of them are actually very irritating. Some can cause redness and burning, and some cause a bad metallic taste. If you're sensitive to a preservative in one of them, you'll certainly get allergy and redness and irritation. So don't be surprised if a patient has difficulty with a particular treatment, and don't blame the patient."

### Riding the Wave

Dr. Koffler notes that given the rapidly evolving nature of the field, it's important to keep up with the current literature and the latest diagnostic and treatment-related developments. "New products continue to be developed," he says. "There's a very active research effort in dry eye, partly because any successful medication or device that makes it to market could become very profitable."

Meanwhile, Dr. Beckman points out that dry eye and related conditions are still not being treated as much as they should be. "For the longest time dry eye was treated as a nuisance diagnosis," he says. "There weren't many treatments, or diagnostics to pick it up, so it was ignored. But today we see the impact it has on surgery outcomes and vision in general, so people are paying more attention. If you're going to put someone in a multifocal lens, for example, you want to make sure the corneal surface is clear. Nevertheless, I believe dry eye is still underdiagnosed." **REVIEW**

*Dr. Beckman consults for Allergan, Novartis, Shire, Sun, TearLab, RPS, Bausch + Lomb and is medical director for EyeXpress. Dr. Akpek has received institutional research support from Allergan and Bausch + Lomb and is currently a consultant with Shire. Dr.s Koffler and Choi have no relevant financial interests.*

1. Karakus S, Agrawal D, Hindman HB, Henrich C, Ramulu PY, Akpek EK. Effects of prolonged reading on dry eye. *Ophthalmology* 2018 Apr 25. pii: S0161-6420(17)33714-4. doi: 10.1016/j.ophtha.2018.03.039. [Epub ahead of print]

# S4OPTIK FULL POWERED

## EXAMINATION CHAIR

2500-CH



### Powerful, precise, automated.

Choose the S4OPTIK 2500-CH Examination Chair for convenient, motorized reclining.

- KleenTech Lift System®
- Weight bearing armrests
- Robust footrest
- Precision engineered

# S4OPTIK

250 Cooper Ave., Suite 100 Tonawanda NY 14150

[www.s4optik.com](http://www.s4optik.com) | 888-224-6012

Sensible equipment. Well made, well priced.

For today's modern office.

# Devices for Treating The Meibomian Glands

*Christopher Kent, Senior Editor*

A number of recently developed instruments can help to relieve meibomian gland congestion.

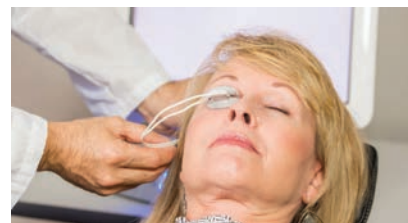Problems that arise with the meibomian glands commonly involve physical blockage that prevents the meibum from coming out to aid the stability of the tear film. As a result, multiple devices have appeared in the marketplace designed to use heat and pressure to alleviate the blockages (as well as to remove residue along the lid margins).

Esen K. Akpek, MD, the Bendann Family Professor of Ophthalmology and Rheumatology at Johns Hopkins University School of Medicine, and director of the Ocular Surface Disease and Dry Eye Clinic at the Wilmer Eye Institute, says that unclogging the glands is sort of like removing dental plaque. “It needs to be done once in a while,” she says. “Just doing warm compresses at home is not adequate to address the problem.”

Here are brief profiles of several of the most popular devices for improving meibomian gland functionality.

- **LipiFlow** (Johnson & Johnson Vision; Santa Ana, California). The LipiFlow Thermal Pulsation System consists of a console and a single-use sterile device that uses sensor-regulated heat and peristaltic motion to evacuate obstructed meibum. One section of the device goes behind the eyelids, providing the warmth; an out-

er section gently massages the lids against the inner section. The device is designed to protect the cornea and globe from the heat and pressure.



Dr. Akpek uses LipiFlow on a regular basis. “LipiFlow is expensive, but it’s also effective, especially for mild to moderate posterior blepharitis,” she says. “It’s a cleanup modality for resetting the glands. Its advantages are that it treats both the upper and lower lids and it’s painless. However, it does not treat anterior blepharitis, and in my experience, it does not work well for severe disease.”

Kenneth A. Beckman, MD, FACS, director of corneal services at Comprehensive EyeCare of Central Ohio, and a clinical assistant professor of ophthalmology at Ohio State University, says he uses LipiFlow regularly. “I find that most of my patients have significant improvement,” he says. “I like to debride the lid margins gently with a spatula before applying the LipiFlow applicators. I often perform



# A REPUTATION 120 YEARS IN THE MAKING.

by Ernest Cavin,  
CEO/President Reliance Medical Products/Haag-Streit USA

Behind every chair, stool, cabinet or stand from Reliance Medical Products is a story. A story of a company that began first selling whitewash sprayers to farmers; and since has morphed into a leading name in high-quality exam and procedure chairs, surgical stools, instrument delivery systems, treatment cabinets and room lighting systems for ophthalmic and ENT medical practices. It's a story of ingenuity, resolve and resilience.

As we reach our 120th year I'd like to take this opportunity to highlight what's made us so successful over the years.

## Our People

I'm often asked what the reason is behind the success of Reliance Medical Products. I always have one spontaneous reply: our employees! Companies are like families, and we're fortunate to have some of the brightest minds in the medical industry who help us bring our collective vision to life. We believe in a culture of constant learning and training, and whether someone is starting on day one or has been with us for 50 years, everyone at Reliance is driven to invest in the time and work that keeps us growing.

We have always been proud to say Reliance products are "Made in America." That is not just a statement about our production process; it is also about the spirit of the people who work here. American craftsmanship and passion are what make Reliance stay durable and reliable, and for over 120 years our people have worked against the odds to make what seemed impossible, possible.

## Our Products

The strength and durability of our people come through in every product from Reliance and Haag-Streit. We are able to help practices, exam rooms, surgical centers and more function and look better with instruments that last longer. It's a testament to our mission of understanding and delivering products that meet the needs of healthcare providers.

Reliance products have changed over the years and in 1988, the company became a subsidiary of Haag-Streit Holding, U.S., Inc., but our commitment to quality, durability and forward thinking has remained constant.

## Our Partners

Medical professionals, key opinion leaders and, of course, our network of Reliance/Haag-Streit dealers are what help keep us a leading name in our market.

We would never have been able to picture this successful journey without our dealers. Our network of national and regional dealers around the country has helped us create a



strong brand name within our industry – some of the business relationships go back more than 35 years. This go-getter attitude, our faith in each other and our commitment towards Reliance are the factors that have brought us where we are today.

## Our Mindset

Our first 120 years were defined by durability and our ability to withstand anything the medical world brought our way. Our next 120 years will be about seeing the challenges ahead by working closely with our partners to help us proactively create products that meet the needs of the lanes of the future. We will be able to do that by continuing to invest in the things that have made us successful so far: our people, our products, and our relationships with our partners.

— Ernest Cavin,  
CEO/President Reliance Medical Products/Haag-Streit USA

meibography at the exam to identify gland shortening, dilation or dropout, and I typically show the patients their images, so they can visualize and understand their problem. This definitely helps motivate patients to comply with treatment.” For more information, visit [tearscience.com/lipiflow/](http://tearscience.com/lipiflow/).

- **eyeXpress** (Holbar Medical Products; Tyler, Texas.) The eyeXpress is a therapeutic goggle system designed to provide uniform, regulated heat to the entire surface of the upper and lower lids. Dr. Beckman uses the eyeXpress as an adjunct to the LipiFlow. (Dr. Beckman is medical director for Holbar Medical Products.) “The eyeXpress is a heat mask that goes on the front of the eye and gets to a temperature of about 110 degrees,” he explains. “It doesn’t pulsate like LipiFlow, but it really heats up the surface nicely. I leave it on for about 15 minutes; then I personally express the lids. I usually get a lot of meibum out. It works well, and it’s less expensive than LipiFlow.

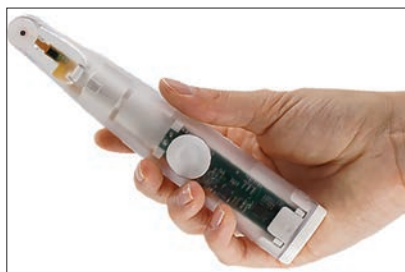

“A major advantage of the eyeXpress is that it’s not user dependent,” he continues. “You can put it on the eyes and leave. Some of the other devices need a technician and/or have to be held up to the face by the patient.

“I find that many patients need several sessions over several months,” he adds. “Often, if a patient is treated with LipiFlow, I include two eyeXpress sessions over the course of the year as part of the treatment package. It’s good for the patients and incurs minimal expense to me.” For more

information, visit [eyexpress.net](http://eyexpress.net).

- **NuLids**. (NuSight Medical; Rancho Santa Fe, California) According to the manufacturer, NuLids is the first dry eye management system designed for home use. The NuLids handpiece is compact, cordless and portable. The once-a-day treatment—which takes about a minute to complete—involves using a disposable tip made of a soft silicone material to remove biofilm and scurf that may be occluding the meibomian glands’ openings. The manufacturer claims that a recent study found no evidence of any corneal scratching or abrasion even if the tip inadvertently came into contact with the cornea.

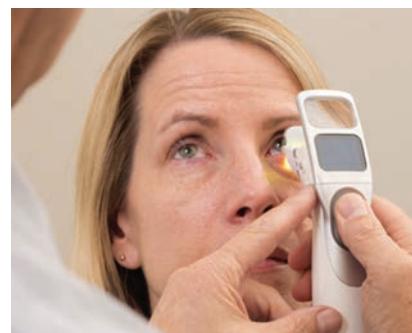

Helen K. Wu, MD, director of the Refractive Surgery Service at the New England Eye Center, and assistant professor of ophthalmology at Tufts University School of Medicine in Boston, has been trying the device with patients for several months. “Patients use the NuLids device daily to massage and clean the lids,” she explains. “It has a quad timer, signaling 15 seconds per lid for a total of one minute of care. The patient can place any cleanser on the disposable silicone tip, but a more viscous preparation works best. A gel preparation for dry eyes, such as GenTeal gel, also works well. The treatment is surprisingly gentle, with no pulling of lashes or ocular irritation. The lids of patients with anterior blepharitis immediately look better, and patients experience a ‘refreshed,’ ‘relaxed’ or ‘clean’ sensation.

“We’re currently selling the device

to patients,” she says. “They get a 30-day supply of silicone tips, which can be reordered through the company’s website. Initial feedback has been positive.” For more information visit [nusightmedical.com](http://nusightmedical.com).

- **iLux** (Tearfilm Innovations; Carlsbad, California). The iLux is a handheld device that treats meibomian gland dysfunction with light-based heat and compression, under direct visualization by the physician via a magnifying lens. The sterile, single-use, iLux Smart Tip has an inner pad that slips behind the eyelid being treated and an outer pad that’s pressed against the outer surface of the eyelid during heating and compression; the tip contains temperature sensors that maintain safe, therapeutic heat levels (between 104 and 108 F) during treatment. One-button control of heating and compression allows you to choose the location and duration of treatment. (iLux can treat both upper and lower eyelids.)



Sheri Rowen, MD, who practices at NVision Eye Centers in Newport Beach, California, and is a clinical assistant professor of ophthalmology at the University of Maryland, has used the iLux for several months. She says her experience has been very positive. “It’s quick and efficient,” she notes. “Treatments typically take less than 10 minutes, and because it’s portable I can use it in any room. I choose where to treat each lid based on meibography images and the expressibility of

the glands I observe at the slit lamp.

“Heating time and compression are under my control, and the magnifying lens lets me view the blocked meibomian gland orifices and expressed meibum during treatment,” she continues. “That’s helpful because I can see the result of the treatment and tell the patient what I’m seeing. I like to use it in combination with the BlephEx device, which removes the bacterial load and biofilm, and the results have been quite positive. The treatment can be repeated in a few months if needed.”

Dr. Rowen adds that it’s painless. “Patients enjoy it,” she says. “They describe a gentle warming sensation. The fact that the device and Smart Tips are reasonably priced makes the procedure affordable for patients, and they really appreciate a comfortable method of addressing their dry-eye problem. Patient acceptance has been very high.” For more information visit [tearfilm.com/ilux-device/](http://tearfilm.com/ilux-device/).

• **IPL (Intense Pulsed Light).** Intense pulsed light, or IPL, was originally developed for use in dermatology. Brief, powerful bursts of light at specific wavelengths (in this case, between 500 and 800 nm) cause changes in blood vessels near the surface of the skin, raise skin temperature and eliminate problematic flora on the skin and eyes, all of which may have a beneficial effect on meibomian gland dysfunction. (Many devices capable of producing this effect are on the market, but a popular one is the Quadra Q4 produced by DermaMed Solutions [Lenni, Pennsylvania].)

Dr. Akpek says she uses IPL on a regular basis. “I find that it’s very effective in severe dry-eye cases with significant disease,” she says. “It’s effective for both anterior and posterior blepharitis, particularly for treating Demodex mites, which are more common than most physicians think. However, IPL can be painful, it mostly

treats the lower lid, and it cannot be used on darkly pigmented individuals.” For more information, visit [dermamedsolutions.com/spa\\_equipment/intense\\_pulsed\\_light/overview/](http://dermamedsolutions.com/spa_equipment/intense_pulsed_light/overview/).

• **BlephEx** (RySurg; Palm Beach, Florida) BlephEx is a painless in-office procedure performed by the physician in which a handpiece spins a single-use, disposable, medical-grade micro-sponge along the edge of the eyelids and lashes, removing scurf and debris and exfoliating the eyelids. The procedure typically lasts six to eight minutes and is well tolerated. It’s typically repeated at four- to six-month intervals.




Dr. Akpek notes that like IPL, BlephEx works best in more severe dry-eye cases. “BlephEx is a handheld device that removes inflammatory biofilm,” she explains. “It’s good for anterior or posterior blepharitis. I almost always use this to exfoliate the lid margin skin and better expose the gland orifices before performing other procedures.” For more information, visit [rysurg.com](http://rysurg.com).

• **Thermoflo** (MIBO Medical Group, Dallas) The Thermoflo consists of a control unit and handpiece that delivers heat at 108 degrees F through a silver eye pad used with ultrasound gel applied to the tarsal conjunctiva. The control unit features an LCD touch-panel display that lets you adjust treatment time and settings.

Bruce Koffler, MD, medical director of Koffler Vision Group in Lexington, Kentucky, uses the Thermoflo. He says he places the heat paddle on each eye for 15 minutes. “After that we leave a heat mask on the pa-

tient’s eyes until I’m able to come to the room,” he says. “When I get in the room, I have a double-pronged paddle made of very smooth metal that goes in front and in back of the lid. I go right across the lid and apply gentle pressure to express some of the oils.



“I initially need to perform the procedure every six to eight weeks, while the patient continues doing daily lid hygiene with scrubbing and heat,” he notes. “Eventually I’ll do it three or four times a year and then move to semiannual treatments.

“The Thermoflo was affordable for our practice, and that’s allowed me to keep the out-of-pocket cost affordable for the patient,” he says. “We feel it’s a great compromise that gives us treatment availability at a reasonable price.” He adds that the Thermoflo unit has no disposable parts. “That’s a good thing,” he says. “We’re very happy with the Thermoflo.” For more information, visit [mibomedicalgroup.com/mibothermoflo.html](http://mibomedicalgroup.com/mibothermoflo.html).

## A Key Part of Treatment?

“Using these devices to reset the glands, I believe, is very important for the meibomian glands’ longevity,” notes Dr. Akpek. “They should be used on the glands before they atrophy. There’s no downside other than their expense. I’d use them on everybody if we could do them for free.

“In any case,” she adds, “if you’re dealing with very severe meibum-deficient dry eye, a combination of these treatments will probably work best for your patient.” **REVIEW**

# Dry-eye Management Before Surgery

Michelle Stephenson, Contributing Editor

How treating the ocular surface can improve your cataract and refractive surgery outcomes.

Because ocular surface conditions such as dry eye can affect patients' outcomes after cataract or refractive surgery, it's important to establish a healthy ocular surface preoperatively. Notably, the recent PHACO study found that the incidence of dry eye in patients scheduled to undergo cataract surgery was higher than anticipated.<sup>1</sup>

This prospective, multicenter, observational study included 136 patients who were at least 55 years old and were scheduled to undergo cataract surgery. Patients' mean age was 70.7 years. Most were Caucasian (73.5 percent), and half were women. Almost 60 percent had never complained of foreign body sensation. Most patients (62.9 percent) had a tear breakup time of five seconds or less, and 77 percent had positive corneal staining. Half of the eyes had positive central corneal staining, and 18 percent had a Schirmer's score with anesthesia of 5 mm or less. These findings were definitely not what was anticipated in the standard cataract patient population that presents routinely to the office.

According to Robert Lasky, MD, who is in practice in New York City, preparing the ocular surface for cataract or refractive surgery requires a customized approach for each patient. "If you neglect the ocular surface in

patients undergoing cataract or refractive surgery, outcomes will be compromised, and you will have fewer happy patients," he says. "However, the drying effects of cataract surgery are not nearly as devastating or detrimental to the ocular surface as refractive surgery. So, I'd probably be a lot more aggressive in the refractive surgery patient than in the cataract patient. Unfortunately, there is no cookbook answer. I look at the eye and the anatomy and listen to patients' complaints, and then I determine what I can do to ensure the best possible outcome."

According to John Sheppard, MD, who is in practice in Norfolk, Virginia, the main difference between cataract and refractive patients is age. "Many refractive patients are disgruntled or unsuccessful with contact lens usage, so they have much more environmental, iatrogenic dry eye than elderly cataract surgery patients. Lifestyle changes, as well as managing contact lenses or eliminating them preoperatively, are an important component of the treatment plan," he says.

Edward Manche, MD, who is in practice at Stanford University, agrees. "Cataract patients are often significantly older than refractive patients, often by several decades," he says. "From that standpoint, treatment may be a bit different, but you still approach them



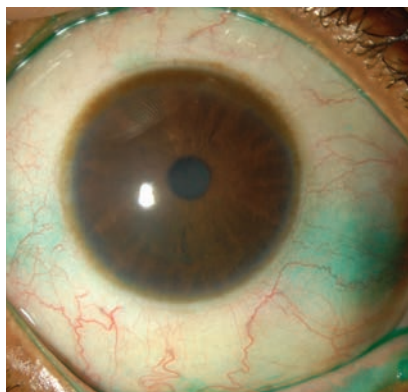with the same philosophy. However, older patients often have issues that a younger person might not have.”

## Preoperative Management

According to Karl Stonecipher, MD, who is in practice in Greensboro, North Carolina, the ocular surface disease index is still a great screening tool for dry eye. “We put it out in our waiting area, and it’s part of our intake form,” he says. “If a patient scores in the normal range, we move on. If he or she scores mild, moderate or severe, it behooves us, whether it’s a cataract or refractive patient, to move to the next level. I’ve empowered my staff to do two simple things: tear breakup time and corneal staining. They’re trained to read and put into my EMR a staining pattern with fluorescein, a tear breakup time or a lissamine green stain.”

Dr. Stonecipher says that diagnosis is key, because he doesn’t want to measure patients until their dry eye has been treated. “I typically see patterns of dryness,” he notes. “Younger patients tend to have evaporative dry eye because they still have pretty healthy tear-film levels. At the same time, we’re definitely seeing meibomian gland disease present at a much earlier age. Perimenopausal women between the ages of 40 and 60 with dysfunctional lens syndrome are more likely to have aqueous deficiency. My older patients are all over the board. They can have an evaporative component, an aqueous component or a mixed-mechanism dry eye, and most of them do.”

According to Dr. Stonecipher, if a refractive surgery patient is severely dry, you may want to consider only operating on him or her during the summer, when there are higher humidity levels. Alternatively, patients can try cyclosporine or lifitegrast for four to six weeks to see if they improve. “I often use Restasis (cyclosporine ophthalmic emulsion, 0.05%; Allergan) or Xiidra (lifitegrast ophthalmic solution, 5%;



Christopher Rapuano, MD

Training staff to read staining patterns can help the surgeon quickly identify ocular surface problems preop, experts say.

Shire) for a month prior to testing and treatment to improve the ocular surface,” he says.

For younger refractive surgery patients, Dr. Stonecipher also is investigating the use of Epic Treatment (Espansione, Italy), which is a combination of intense pulsed light and low-level light therapy. It simultaneously treats the lower and upper eyelids with direct and indirect applications. The company claims it improves dry-eye symptoms after a few hours, as a result of the synergy of the two technologies helping meibomian glands resume production of the necessary lipids. “Although the mechanism of action is still debated, IPL primarily opens, heats and stretches the glands,” says Dr. Stonecipher. “The nice thing about the Epic System is that it’s a no-gel IPL, so you don’t have to put gel around the eyes. You can do one quick treatment of IPL and then follow that with low-level light therapy, which is a photobiomodulation,” he says.

Dr. Stonecipher also expresses patients’ meibomian glands. “I have also just started to use TempSure (Hologic), which uses radiofrequency to heat the glands, [which is a treatment] for the more resistant patients who are not responding to the Epic system,” he explains.

Patients who continue to be resistant

then undergo LipiFlow (TearScience) treatments. “We have a tier system because it’s all out-of-pocket. The cost is a little less for Epic versus TempSure versus LipiFlow. I think all of these systems have their pluses and minuses, but insurance doesn’t pay for any of this, which is an issue. LipiFlow costs, on average, \$1,000 to \$1,500 per treatment of both eyes, while the others are between \$350 and \$550 per bilateral treatment,” he notes.

IPL combined with meibomian gland expression has been found to safely and effectively treat meibomian gland dysfunction, according to a study that was published this summer.<sup>2</sup> The prospective, randomized, double-masked, controlled study involved 44 patients. One eye was randomly selected for IPL treatment, and the fellow eye was a control. Study eyes received three IPL treatments four weeks apart. IPL was applied directly on the eyelids, while the eye was protected with a Jaeger lid plate. Control eyes received sham IPL treatments, and both eyes received meibomian gland expression. Meibomian-gland-yielding-secretion score, tear breakup time, standard patient evaluation of eye dryness (SPEED) and cornea fluorescein staining (CFS) scores all improved in the study eyes, while only SPEED and CFS scores improved in the control eyes. Changes in meibomian-gland-yielding-secretion score and tear breakup time were higher in the study eyes compared to the control eyes. Changes in SPEED and CFS scores were similar.

According to Dr. Sheppard, surgeons need to consider the ocular surface unit as a whole and look for more than just dry eye. Other things to consider are lid or lash abnormalities. “That’s very important. If there’s a lid abnormality, I’m not really interested in doing cataract surgery quite yet. If the seventh cranial nerve doesn’t function, then obviously there’s poor protection of the eye, and intelligent intervention

is required. The fifth cranial nerve, of course, is the sensory nerve, and eyes with poor sensation heal very slowly, blink infrequently and develop a host of related problems. Obviously, if the tear production is low or the oil glands don't produce well or are deficient—which we can now image—the ocular surface will be dysfunctional as well. Many of these conditions contribute to punctate keratopathy, which is desiccation of corneal epithelial cells that can render a patient uncomfortable, blur the vision and, more importantly, create bad measurements prior to cataract surgery. Bad measurements result in bad outcomes and unhappy patients," he says.

Dr. Sheppard also assesses the patient for blepharitis and allergy. "Those tend to be either confused with dry eye or ignored in the presence of dry eye as a contributory condition," he adds.

He notes that 75 percent of his patients presenting for cataract surgery have dry eye or a combination of ocular surface conditions that manifest as dry eye. "We create an intervention, and then we look to see that the critical central corneal epithelium is optically acceptable, clear and regular. We do that by confirming topographies, biometries, and even aberrometries of the visual system, looking for repeatability between methodologies. We'll obtain three different measurements of the cornea in our cataract evaluation. If the astigmatic powers and cylinder axis are reproducible by different devices, we're generally fairly satisfied that the patient indeed has accurate measurements and that he or she will produce an accurate calculation for intraocular lenses. So, we're looking for consistency and repeatability of measurements before proceeding with cataract surgery," he explains.

### Postoperative Management

Some patients continue to experience or develop dry-eye symptoms

after surgery. Dr. Stonecipher says that he sees five or six patients a month who have undiagnosed dry-eye disease post premium IOL or refractive surgery and who are extremely unhappy with their surgical outcome. "Most of the patients who come to see me for refractive surgery are young patients who have meibomian gland disease because they're staring at their computers and phones all day," he says. "I'm seeing increasing numbers of patients with severe evaporative dry eye, which is leading to their contact lens wear being compromised. Of my LASIK volume each month, approximately 20 to 30 percent of my patients fall into that category. That's a significant number, and if I operate on those patients and make their problem worse, even if it's temporary, it's my problem and not their problem anymore. However, if you tune them up before surgery, you will have fewer unhappy patients."

Dr. Sheppard adds that it's important to remember that any surgical procedure worsens existing ocular surface disease or can create new ocular surface disease. "When patients have no idea that there were abnormalities present prior to cataract surgery and then suddenly they arise, a very difficult discussion ensues," he says. "Therefore, warn patients about their pre-existing ocular surface conditions. Postoperatively, we definitely trigger more ocular surface disease and dry eyes because of the incisions, the lights and the microscope, the speculum holding the eye wide open, and all the medicines that patients are using."

According to Dr. Manche, many cases of dry eye resolve on their own after refractive surgery. "Dry eye generally tends to get better on its own over time following keratorefractive surgery," he says. "However, I try to think in terms of patient satisfaction as well as the speed of recovery, so I think it's important to treat these patients. Depending on the severity of the dry eye and the external disease, you may have patients

with chronic problems. It's really important to treat patients, both preoperatively and postoperatively, to help minimize patient dissatisfaction and speed recovery. I'm pretty aggressive about treating patients both pre- and postoperatively."

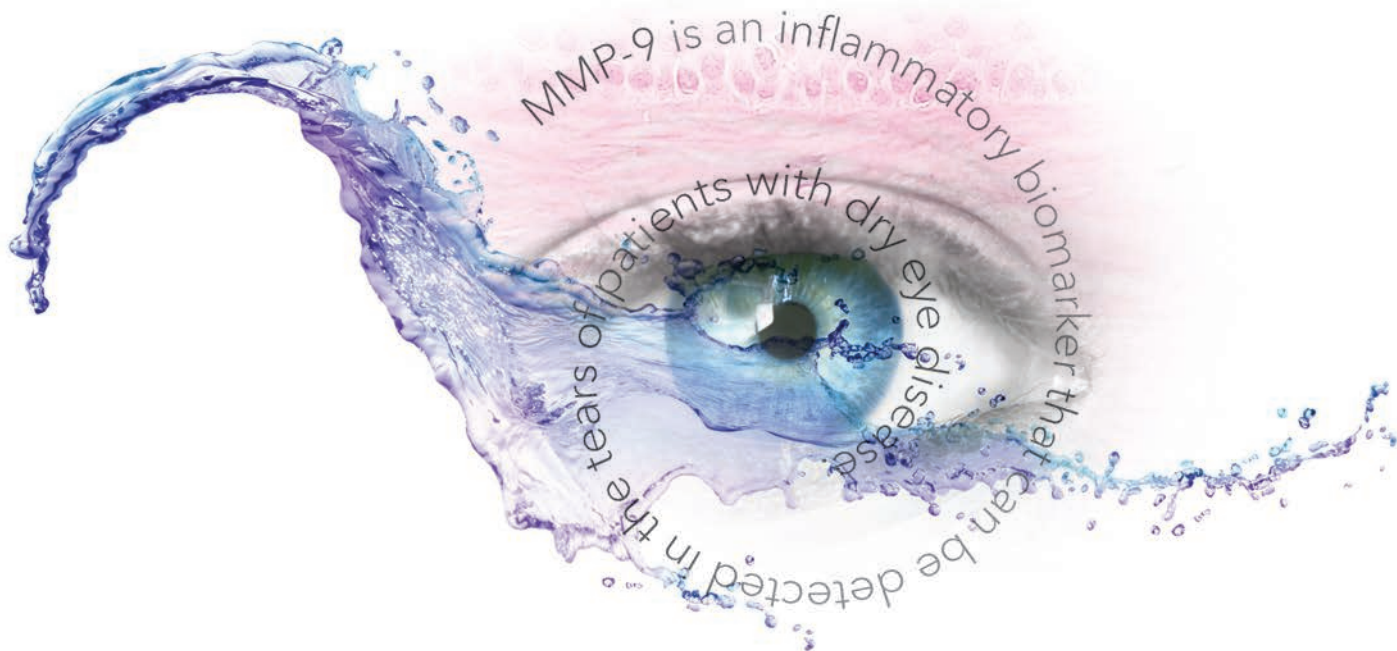
These surgeons agree that managing patient expectations is the key to a successful surgical outcome. According to Dr. Laskany, patients need to be well-informed about what they're getting into. "The unhappiest LASIK patients are those you've told that LASIK is just like a haircut, that they will see great, and nothing will happen," he says. "Then, they have surgery, they experience dry eye and they panic. They never had this annoying feeling before, and no one told them about this. Then, they fixate on it and life becomes miserable. If we tell patients that the procedure can make them a little drier, they're not as unhappy as the ones who seem blindsided and shocked by this new finding they never even knew could happen."

### The Future

Dr. Sheppard notes that we live in an interesting time for treating dry eye. "It's a truly exciting field that we're experiencing," he says. "Twenty years ago, dry eye was neglected and, if considered at all, treated only with tear supplements. Now, we understand that a variety of factors contribute to ocular surface disease and dryness, and we can treat our patients with genuinely targeted intent," he says. **REVIEW**

*Drs. Laskany, Sheppard and Manche have no financial interest in the products they mentioned. Dr. Stonecipher has consulted for Allergan, Espansione and Shire.*

1. Trattler WB, Majumdar PA, Donnenfeld ED, et al. The prospective health assessment of cataract patients' ocular surface (PHACO): The effect of dry eye. *Clin Ophthalmol* 2017;11:1423-1430.
2. Rong B, Tang Y, Tu P, et al. Intense pulsed light applied directly on eyelids combined with meibomian gland expression to treat meibomian gland dysfunction. *Photomed Laser Surg* 2018;36:6:326-332.



Is dry eye a complication of ocular surgery?

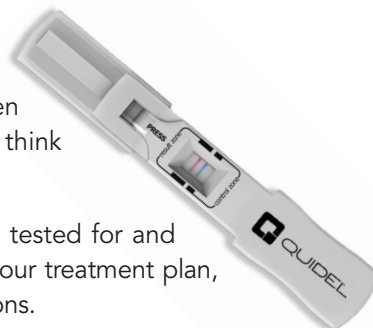It's not complicated.

Your cataract or refractive surgery patient didn't present with dry eye or other symptoms of ocular surface disease, then perioperatively complains of moderate to severe dry eye. They think there have been complications.


If elevated MMP-9, a key inflammatory biomarker for dry eye, is tested for and detected prior to surgery you have an opportunity to customize your treatment plan, which may improve post-surgical outcomes and reduce complications.

InflammaDry is the only rapid, CLIA-waived, in-office, point-of-care test that detects MMP-9. InflammaDry provides results in minutes, is easily performed in 4 simple steps, is minimally invasive and requires no special equipment.

To find out how testing for MMP-9 with InflammaDry can take the complication out of your anti-inflammatory treatment therapies before there are complications, visit us at **AAO Booth #3073** or contact your Quidel Account Manager at **800.874.1517**.



InflammaDry®



# The Asymptomatic PAC Suspect: LPI or No LPI?

Most MDs don't hesitate to perform a laser peripheral iridotomy in healthy patients with narrow angles. It may be time to reconsider.

*H. George Tanaka, MD, San Francisco*

**H**ere's a common scenario in many ophthalmologists' offices: A patient is referred for evaluation of narrow angles. The patient is middle-aged and totally asymptomatic; her vision and pressures are fine. Her visual fields and optic nerve OCTs all look OK. You look at the back of her eyes without dilating her pupils and the optic nerves appear totally healthy. Gonioscopy confirms the presence of narrow angles, but there are no peripheral anterior synechiae. She doesn't have glaucoma. The only thing the patient has is appositional closure—a narrow angle.

Ninety-nine out of 100 times, this person will receive a laser peripheral iridotomy. The reason for this is that an LPI is generally seen as a proactive way to minimize the likelihood of a future acute angle-closure attack. (Eliminating pupillary block may also delay the progression from primary angle closure suspect to primary angle closure or glaucoma.) The problem is, an LPI isn't consequence-free, and there's little direct evidence-based data to support doing LPI in this situation.

Here, I'd like to review the existing

data and discuss the reasoning behind this choice of action, in hopes of encouraging you to think twice before automatically performing an LPI, simply because a healthy patient has a narrow angle.

## The Rationale for Treatment

As doctors, we often prefer to err on the side of caution with our patients. The practical steps we take in a given scenario, of course, are usually based on the accepted wisdom about that situation. For example, when I was a resident 20 years ago, we believed that any intraocular pressures over 21 mmHg needed to be brought down. So, every patient that came into the clinic with a pressure of 22 or 23 mmHg would get a prescription for Xalatan, even if those individuals had a normal visual field and their optic nerves looked fine.

The truth was, we really had no proof that this was beneficial until the Ocular Hypertension Treatment Study came out. OHTS was a large, multicenter, randomized, prospective trial designed to reveal whether medical treatment lowered the risk of

glaucoma development. It turned out that it does—but it only cuts the risk of glaucoma from 9.5 to 4.4 percent. The take-home conclusion of OHTS was that most patients who have elevated IOP and nothing else don't need to be treated (although treatment does make sense for a subset of patients with high-risk characteristics such as thin corneas). Because of that study, today we typically just follow most of those patients instead of treating them.

Unfortunately, when it comes to patients with narrow angles, we don't have a study equivalent to OHTS. We don't actually know how many future angle-closure attacks we're preventing by performing LPIs. That's why we can't say to a patient with narrow angles, "Mrs. Smith, your risk of going blind is X percent (or your risk of getting glaucoma is Y percent), but the odds will improve by this much if I perform this procedure." We don't have the numbers to support that, so we just treat everybody.

The fact that we can now create an iridotomy with a laser is a big part of the reason for the current approach. Back in the days before

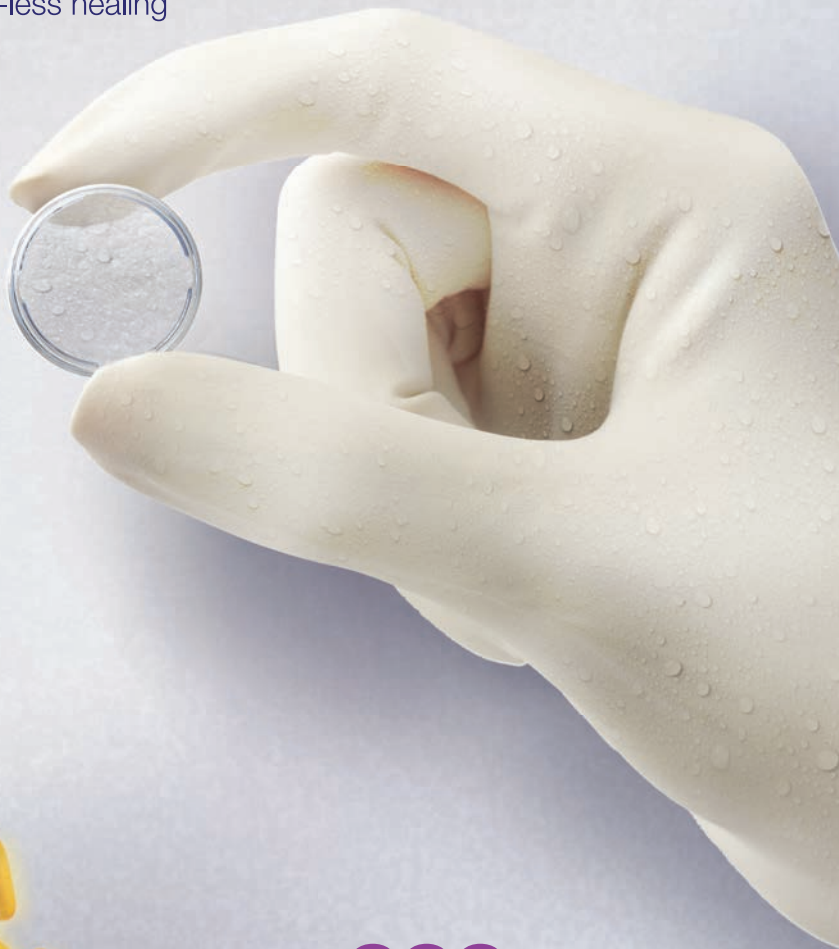# Treating Dry Eye can be Complicated

## Choose PROKERA® First

the only FDA cleared amniotic membrane that  
reduces inflammation and gives patients scar-less healing

**1** treatment  
= at least 3 months of relief <sup>1</sup>

**relief starts in 3-5 Days**



**???**

treatments

**relief could take 3+ months**

**PROVIDE FASTER RELIEF TO  
YOUR PATIENTS WITH PROKERA**

<sup>1</sup> John et al. "Corneal Nerve Regeneration after Self-Retained Cryopreserved Amniotic Membrane in Dry Eye Disease" 2017. Journal of Ophthalmology, 2017.

### Angle-Closure Disease Staging and Treatment

Disease Stage	Associated Signs	Recommended Treatment
PACS (primary angle closure suspect)	Appositional contact but no PAS; normal IOP and optic nerve. Trabecular meshwork at risk.	LPI? Or observation?
PAC (primary angle closure)	High IOP and/or PAS (i.e., trabecular meshwork dysfunction) but no optic nerve damage.	Phaco if IOP is above 30 mmHg (as per the EAGLE study)
PACG (primary angle-closure glaucoma)	High IOP and/or PAS with optic nerve damage.	Phaco, with or without trabeculectomy or GDD

lasers an iridectomy required taking the patient to the OR, opening the eye and snipping a piece of iris. That's obviously pretty invasive and risky. Since the risk/benefit ratio wasn't ideal, we used provocative testing to try to figure out which patients were likely to go into acute angle closure. We'd make people drink a gallon of water or sit them in a dark room, or more commonly, perform pharmacologic testing. These tests were helpful for identifying patients at the highest risk of angle-closure attacks, but they weren't perfect. (Based on these tests, gonioscopic criteria for high-risk patients were developed. Today, anterior chamber OCT can also be used to identify severely narrowed angles, which are generally presumed to be at high risk for an attack.)

Then the laser came along. Now we could create a hole in the iris without having to enter the eye, and the risk/benefit ratio was suddenly very different. So we stopped doing provocative tests. Now we just take a narrow-angle patient over to the YAG laser and do a quick treatment. The relative safety and ease of laser iridotomy has made it seem like a no-brainer. However, just as we overtreated ocular hypertension in the past, we're probably doing too many laser iridotomies in these patients.

#### The Levels of Angle Closure

Patients with narrow angles fall

somewhere along a continuum, based on a simple staging system. There are three distinct stages in the angle closure disease process: primary angle closure suspect; primary angle closure; and primary angle closure glaucoma. An individual's place on the continuum is determined by several factors, including how much appositional contact there is between the iris and the trabecular meshwork; whether the angle has peripheral anterior synechiae or PAS; whether the IOP is elevated; and the condition of the optic nerve. (*See table, above.*)

- If an individual has appositional contact but no PAS, and a normal IOP and optic nerve, he's considered a primary angle closure suspect or PACS. This is the most common scenario we're likely to encounter in the clinic.

- If someone has a high IOP and/or PAS (i.e., trabecular meshwork dysfunction) but no optic nerve damage, that's considered primary angle closure.

- If someone has all of the above and optic nerve damage, that's considered angle-closure glaucoma.

As it turns out, we have good clinical evidence to guide us when managing primary angle closure and angle-closure glaucoma, but not when managing PACS. The treatments at each stage are very different. We know that cataract surgery is beneficial for angle-closure glaucoma, so we treat these patients with cataract surgery combined with filtering surgery—either a trabeculectomy or tube, if

the amount of optic nerve damage is severe and the patient requires a low target IOP. (MIGS, a.k.a. minimally invasive glaucoma surgery, may have a role to play in addressing milder stages of PACG, but we don't know for sure; that's still under investigation.) For primary angle closure, the second stage, we have a large, prospective, international multicenter trial called the EAGLE study. (EAGLE stands for Effectiveness in Angle closure Glaucoma of Lens Extraction.)<sup>1</sup>

In the EAGLE trial, primary angle-closure patients age 50 and older, with pressures above 30 mmHg but no cataracts, were randomized to clear lens extraction or LPI (the latter being the standard of care). Surprisingly, the patients that underwent clear lens extraction, even when they were 20/20, did better than patients who received laser. They had lower pressures, more open angles, and they didn't need as many medications as the laser group. In the phaco group, 21 percent needed additional treatment; in the LPI group, 62 percent needed additional treatment. In addition, the cost-effectiveness of treatment and the patients' quality of life were slightly better in the phaco group.

Based on the EAGLE results, if I have a patient with primary angle closure, I'll recommend cataract surgery if the pressure is high, even if the patient doesn't have a cataract. (My criteria for "high pressure" in this scenario is above 30 mmHg, because that was the inclusion criteria in the study. It's not clear whether we could

# MGD can cause the lipid layer to break down.

RESTORE

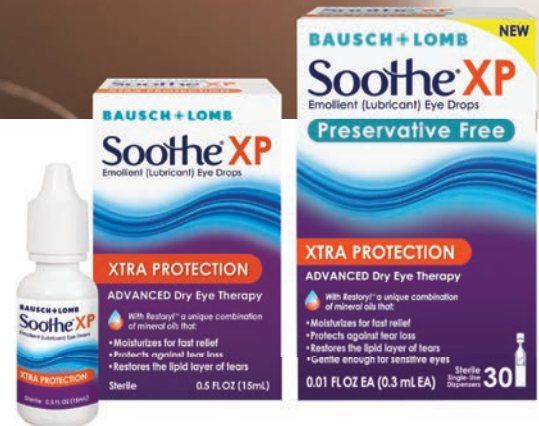SEAL

PROTECT

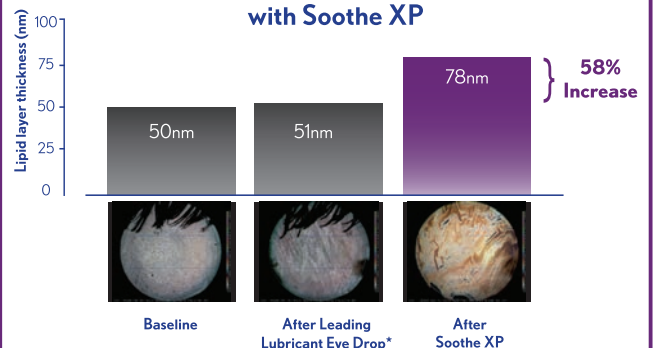
Now Available:  
Preservative Free!

## Soothe<sup>®</sup> XP helps replenish this layer.

- Up to 86% of patients reporting dry eye symptoms have Meibomian Gland Dysfunction (MGD).<sup>1</sup>
- MGD can cause the lipid layer to break down, which may lead to a compromised tear film.<sup>2</sup>
- Soothe XP contains Restoryl<sup>®</sup> mineral oils that may benefit MGD patients by helping to restore the lipid layer, seal in moisture, and protect against tear loss.



### Improved lipid layer thickness after treatment with Soothe XP



<sup>1</sup> Lemp MA et al. Distribution of Aqueous-Deficient and Evaporative Dry Eye in a Clinic-Based Patient Cohort: A Retrospective Study. *Cornea*. 2012; 31:472-478.

<sup>2</sup> Horwath-Winter J. Prevalence of MGD in a clinical dry eye population. *Acta Ophthalmol* 2011; 89 (s246)-2334.

®/TM are trademarks of Bausch & Lomb Incorporated or its affiliates.  
© 2018 Bausch & Lomb Incorporated. PN08785 SXP0028.USA.18

\*Non-lipid containing eye drop (Systane Ultra)

Lipid layer thickness (LLT) prior to and 15 minutes following a single drop of emollient or non-emollient eye drop in dry eyes with meibomian gland dysfunction. Data are the mean (±SD) LLT based on stroboscopic video color microscope (SVC™) measurements in study eyes (qualifying eyes in subjects with only one qualifying eye, or the eye with the lowest LLT at baseline in subjects with two qualifying eyes). p<0.001 paired t-test for the change from baseline. p<0.001, n=35, following a single drop.

**BAUSCH + LOMB**  
See better. Live better.

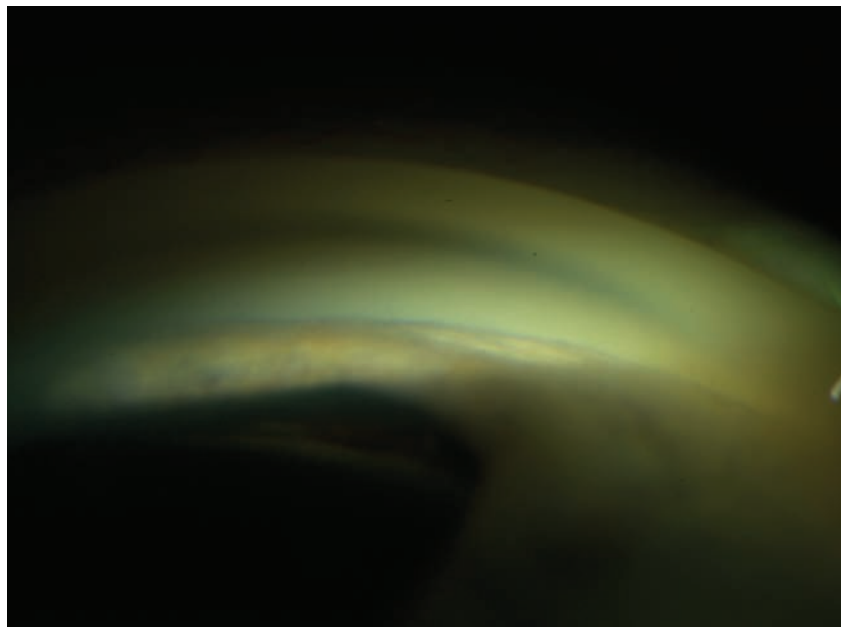
extrapolate that to a pressure lower than 30 mmHg.)

The bottom line is that we have good clinical evidence to guide our treatment decisions in those two scenarios. Unfortunately, we don't have any good evidence for how to manage a PACS patient. There is no "Primary Angle-Closure Suspect Treatment Study," which means there's no clinical evidence that any surgical treatment for patients with PACS—including LPIs—is beneficial.

Some relevant data does exist, but it's difficult to apply it directly to the situations we encounter in the clinic. For example, one study called the Zhongshan Angle Closure Prevention Trial (ZAP for short) was conducted in China.<sup>2</sup> ZAP was a well-designed, prospective, randomized trial involving 775 PACS patients. The researchers performed LPI in one eye while leaving the other eye alone to serve as a control. As expected, the laser treatment opened the angle, but even after laser treatment the angles continued to narrow at the 18-month follow-up period in the study. Interestingly, out of 775 patients, none of the individuals at risk suffered acute angle closure. That's important, because if you want to prevent something bad from happening, you first need to know the risk that the event will occur.

Longer follow-up data from the ZAP study has been submitted for publication, but right now we don't know how many untreated PACS patients developed acute angle closure, elevated IOP or synechial formation. ZAP is the first prospective, randomized trial to examine whether LPI in PACS is beneficial, but it was conducted in Chinese patients and may not be generalizable to an American population.

Another study conducted in India estimated that about one in five patients progresses from PACS to primary angle closure at five years, and



Gonioscopic view of a narrow angle. None of the anatomical angle landmarks, such as the trabecular meshwork or scleral spur, are visible. There is a significant amount of forward convexity of the iris. Compression gonioscopy would distinguish between appositional (reversible) and synechial (irreversible) closure.

about one in four of those patients goes on to develop glaucoma.<sup>3</sup> Again, these numbers may not apply to an American population.

### The Pros and Cons of an LPI

Let's consider the pros and cons of performing an LPI in PACS patients. Arguments in favor of performing an LPI include:

- **Acute angle closure is a potentially blinding ocular emergency.** It's one of the few emergencies in ophthalmology. Pupillary block is thought to be a major component of such an attack, and doing an iridotomy does eliminate pupillary block. Furthermore, angle-closure glaucoma is an aggressive disease, and probably the leading cause of glaucoma blindness in the world. Open-angle glaucoma is much more common than angle-closure glaucoma in America, but there are so many angle-closure patients in China and India that overall, more people on the

planet go blind from angle-closure glaucoma than open-angle glaucoma. So at least in those countries, it's a very relevant problem. By doing an LPI, you're treating a preventable cause of glaucoma blindness.

- **LPI in PACS probably prevents progression to PAC.** As mentioned previously, PACS, PAC and PACG represent sequential stages along a continuum of angle-closure disease. This disease process is progressive and driven by pupillary block, phacomorphic factors and other mechanisms. Eliminating pupillary block should delay or prevent the conversion of PACS to PAC.

- **An LPI is fairly benign.** Performing a laser peripheral iridotomy usually only takes a couple of minutes in the office or clinic, and the risks of infection or bleeding are minimal.

On the other hand, arguments against performing an LPI in PACS patients include:

- **An LPI isn't totally benign.** The patient can develop iritis or an





# SURGICAL.



## PREPARATION.

### The Bruder Moist Heat Eye Compress Goes Beyond the Treatment of Dry Eye Disease

A thorough investigation of ocular surface health and addressing problems proactively are the first steps toward a successful surgery.

Help optimize the ocular surface prior to surgery and improve your surgical outcomes with the easy-to-use Bruder Moist Heat Eye Compress. This innovative therapeutic eye compress helps enhance patient outcomes by improving a compromised tear film layer.

Improve your surgical outcomes by offering the patented Bruder Moist Heat Eye Compress to your patients.

#1

**#1 DOCTOR RECOMMENDED MOIST HEAT COMPRESS**

Perfect for your Patients. Perfect for your Practice.

Learn more or request a sample at [www.bruder.com/prep](http://www.bruder.com/prep)

**Bruder** Better.  
By Design.

[www.bruder.com](http://www.bruder.com) | 888.827.8337

©2018 Bruder Healthcare Company, Alpharetta, GA 30004

**The Risk of Primary Angle Closure Suspects Developing Acute Primary Angle Closure\***

Region	Enrollment criteria	Age	Mean follow-up period	Number of cases	Number that developed APAC
Guangzhou, China <sup>6</sup>	(1) anterior chamber depth $\leq 2$ mm; (2) peripheral anterior chamber depth $\leq 1/4$ CT; or (3) iris light band ratio $\leq 1/4$	$\geq 40$ years	4.8 years (one to six years)	485	6 (1.2 percent)
Chicago, USA <sup>7</sup>	(1) anterior chamber depth $< 2$ mm; (2) anterior chamber angle that the initial examining ophthalmologist believed was narrow enough to be capable of closure	Mean age: 62.1 years (range: 36.9 to 84.3 years)	2.7 years (one to six years)	129	8 (6.2 percent)
Vellore, India <sup>3</sup>	(1) Nonvisibility of the filtering trabecular meshwork for 180 degrees or more; (2) IOP less than 22 mmHg; and (3) no peripheral anterior synechiae in the angle.	Mean age: 54.8 years (range: 36 to 65 years)	Five years, or the time to having met the endpoints	48	0

\*Based on Zhang, Liu, Wang et al, 2017<sup>11</sup>

IOP spike. (In fairness, both of those things are treatable.)

Probably the worst thing that can happen, in my experience, is that in rare cases patients get extra spots of light in their vision—dysphotopsias. These are permanent, and they can be highly annoying to the patient. There’s really no way to fix them, except to surgically close the iridotomy or take out the crystalline lens.

Although this complication may sound minor, I’ve actually had patients leave my practice because the LPI I performed caused this to happen. (Of course, switching doctors doesn’t necessarily help: One patient left my practice and saw another glaucoma specialist in my area. The second doctor did the laser in the other eye and the same thing happened!)

• **An LPI can accelerate cataract development.** Doing an iridotomy will increase the rate of cataract progression because you’re altering the flow of aqueous in the eye.<sup>4,5</sup> Aqueous bathes the lens in nutrients and when you alter its path, you’re going to accelerate cataract development. Of course, here in America this isn’t necessarily a major issue because most people have access to high-quality cataract surgery. On the other hand, if

you’re talking about doing iridotomy on tens of thousands of Chinese or Indian people, you’re going to create a lot of cataracts in a relatively resource-poor environment. Those individuals may not easily be able to get cataract surgery.

• **An LPI may lead to the development of posterior synechiae.** An iridotomy allows aqueous to flow from the posterior to anterior chamber without passing through the pupil. This may lead to greater contact between the iris and lens near the pupil margin, thereby predisposing the eye to the formation of posterior synechiae, which could make future cataract surgery more difficult.

• **An LPI only treats pupillary block, which is just one mechanism of angle closure.** There are multiple mechanisms involved in angle closure. Pupillary block is probably the most common mechanism in Western nations, but in the Chinese and Indian populations there may be other contributing factors such as the size or vault of the lens, or the position or insertion of the ciliary body. Iridotomy does not address these components, which may explain the continued angle narrowing of treated eyes in the ZAP study. LPI is

only treating part of the problem, and by accelerating cataract formation, it may be increasing the phacomorphic component.

**What’s the Risk of an Attack?**

Obviously, a key part of justifying an LPI in an asymptomatic patient is the idea that we’re lowering the risk of a potential future acute angle closure attack. But the value of our intervention depends in large part on how serious that risk is.

Three longitudinal studies from around the world may help to shed some light on this question. (See table, above.) One study conducted in Guangzhou, China, found that six out of 485 PACS patients—or 1.2 percent—later had an acute angle-closure attack.<sup>6</sup> A study done in Chicago found that eight out of 129—6.2 percent—later had an acute attack.<sup>7</sup> (That’s pretty high, but this study was conducted in 1993. Some of these patients may not have met the exact criteria for PACS, and we don’t know whether or not the patients had symptoms.) A study conducted in Vellore, India, found that no one in a group of 48 PACS patients went on to have an acute angle closure attack.<sup>3</sup>

Given the data from these three studies, it's pretty clear that the risk of acute angle closure is low, although we don't know exactly how low.

What about patients who get dilated? Pupil dilation makes the angle more crowded, so you'd think that these patients would be much more prone to having an angle-closure attack. However, the data suggests that even in this situation the risk is pretty low. A study conducted in Singapore found that three out of 471 angle-closure suspects (0.64 percent) had an acute attack when dilated.<sup>8</sup> A study in Rotterdam found that two out of 149 patients with "narrow angles" (1.3 percent) had an acute attack when dilated.<sup>9</sup> (No specific definition of "narrow angles" was provided in the study.) The Baltimore Eye Survey found that none of 38 patients with "occludable angles" had an attack when dilated.<sup>10</sup> So even when PACS patients are dilated, the risk is pretty low.

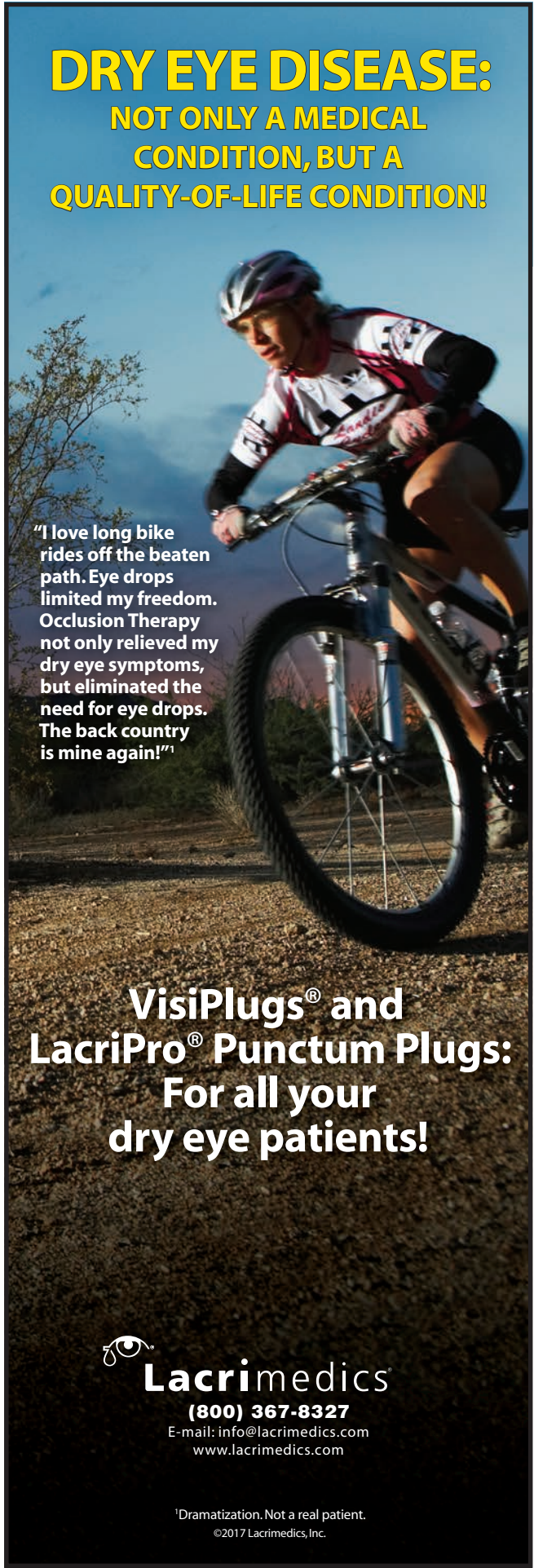
For argument's sake, let's assume the risk of acute angle closure attack in a totally asymptomatic patient with PACS is 1 percent. (I think that's high, but let's assume it's correct.) In terms of the number needed to treat, you'd have to do 100 iridotomies to prevent one acute angle-closure attack. As I noted earlier, an LPI is not a totally benign procedure. So the question becomes: Is it worth subjecting the 99 patients who wouldn't have had an acute angle closure attack to earlier cataract, possible iritis, IOP spikes and dysphotopsias to prevent an acute attack in the 100th patient? That's really the way to look at it.

## My Decision Tree

Eventually I suspect we'll pin down some biometric parameters that will predict who is at higher risk of getting into trouble. It could be that lens vault or iris thickness will turn out to correlate with acute angle closure attacks. Perhaps it won't be a static parameter but a dynamic feature we observe with constriction or dilation of the pupil, such as the change in iris volume, that will predict who gets into trouble. (Harry Quigley, MD, has looked at choroidal expansion and shown that this can cause the lens/iris diaphragm to move forward, possibly triggering an acute angle closure attack.) Currently, we don't have any 21st-century, high-tech provocative test to predict which PACS patients are at risk of developing angle closure. That's because we don't even know which biometric parameters are important. This lack of knowledge is why we're erring on the side of overtreatment, and why current accepted clinical practice involves performing LPIs on every patient with a narrow angle.

So how do I manage patients who qualify as primary angle closure suspects? My approach is to treat the patient, not the angle. Given the lack of evidence-based

## DRY EYE DISEASE: NOT ONLY A MEDICAL CONDITION, BUT A QUALITY-OF-LIFE CONDITION!



"I love long bike rides off the beaten path. Eye drops limited my freedom. Occlusion Therapy not only relieved my dry eye symptoms, but eliminated the need for eye drops. The back country is mine again!"<sup>1</sup>

**VisiPlugs<sup>®</sup> and  
LacriPro<sup>®</sup> Punctum Plugs:  
For all your  
dry eye patients!**



**Lacrimedics<sup>®</sup>**

**(800) 367-8327**

E-mail: [info@lacrimedics.com](mailto:info@lacrimedics.com)  
[www.lacrimedics.com](http://www.lacrimedics.com)

<sup>1</sup>Dramatization. Not a real patient.  
©2017 Lacrimedics, Inc.

data to recommend iridotomy, I make the decision on a case-by-case basis. For the vast majority of patients, I choose a course of observation, examining the patient every six to 12 months. History-taking is focused on symptoms that are suggestive of intermittent angle closure. IOP measurement and compression gonioscopy are used to rule out progression from PACS to PAC. Visual fields, OCT and digital disc photography may detect early optic nerve damage and the development of PACG. The development of elevated IOP, PAS or optic nerve damage in a PACS patient indicates the patient is no longer a PAC suspect; at that point intervention is warranted.

However, some circumstances will cause me to proceed with an LPI in an otherwise asymptomatic PACS patient. These include:



- **The patient has a history of retinal disease.** I'll perform LPI in a totally asymptomatic PACS patient if the patient is seeing a retinal specialist on a regular basis. Patients with a history of macular degeneration or peripheral retinal tears will likely require dilated exams for the rest of their lives.

- **The patient may not return in a timely manner.** With some patients, there's a question as to whether they're going to return for follow-up visits. They disappear. Those patients can show up five years later with a red, painful eye and a pressure of 60 mmHg.

- **The patient will not have timely access to medical care.** If a patient is going backpacking in the Sierras for several weeks or volunteers in Africa for several months at a time, he or she may not have prompt access to emergency ophthalmic care if acute angle closure occurs.

- **The patient has a family history of acute angle closure, angle closure glaucoma, or blindness resulting from angle closure.**

- **The patient develops symptoms suggestive of angle closure.** In my experience, an acute angle-closure attack doesn't come out of the blue; there are almost always warning signs. People who come in with acute angle closure have usually had symptoms such as eye pain or headaches in the preceding months, indicating that their intraocular pressure has been going up. Some of these patients have complained to me about migraine headaches, usually on one side (the side with the narrower angle). They're taking pain or migraine medication. Often LPI results in a complete disappearance of their migraines. However, the complaints are often more vague and ill-defined than the characteristic headache and eye pain we usually associate with elevated IOP.

  
*The numbers suggest that we may be causing some ocular morbidity in a large number of patients in our attempt to prevent dire consequences in a very small number of patients.*  


So, when I encounter a symptomatic patient with PACS, I usually proceed with LPI. In my experience, however, most patients with narrow angles will tell you they haven't had any symptoms. Those are the patients I observe.

### Time to Rethink?

It's easy to understand why we tend

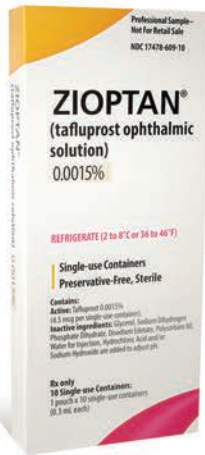to laser most patients who come in with narrow angles, but no other signs or symptoms. The last thing we want is for any patient to lose vision from an acute angle closure attack that might have been prevented. Nevertheless, the numbers suggest that we may be causing some ocular morbidity in a large number of patients in our attempt to prevent dire consequences in a very small number of patients. It's worth considering a more tailored approach. [REVIEW](#)

*Dr. Tanaka is a clinical instructor at California Pacific Medical Center in San Francisco, and in private practice in San Francisco and Oakland. He is a consultant for Ellex and Allergan, and a speaker for Glaukos and Aerie Pharmaceuticals, but he has no financial interests in the subject matter of this article. You can reach him at ghtanakamd@gmail.com.*

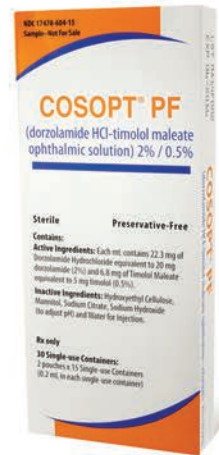1. Azuara-Blanco A, Burr J, Ramsay C, et al. Effectiveness of early lens extraction for the treatment of primary angle-closure glaucoma (EAGLE): a randomized controlled trial. *Lancet* 2016;388:1389-97.
2. Jiang Y, Chang DS, Zhu H. Longitudinal changes of angle configuration in primary angle-closure suspects. *Ophthalmol* 2014;121:9:1699-1705.
3. Thomas R, George R, Parikh R, et al. Five year risk of progression of primary angle closure suspects to primary angle closure: A population based study. *Br J Ophthalmol* 2003;87:450.
4. Lim LS, Husain R, Gazzard G, Seah HK, Aung T. Cataract progression after prophylactic laser peripheral iridotomy: Potential implications for the prevention of glaucoma blindness. *Ophthalmology* 2005;112:8:1355-9.
5. Vijaya L, Asokan R, Panday M, George R. Is prophylactic laser peripheral iridotomy for primary angle closure suspects a risk factor for cataract progression? The Chennai Eye Disease Incidence Study. *Br J Ophthalmol* 2017;101:5:665-670.
6. Ye T, Yu Q, Peng S, et al. [Six year follow-up of suspects of primary angle-closure glaucoma]. *Zhonghua Yan Ke Za Zhi* 1998;34:167.
7. Wilensky JT, Kaufman PL, Frohlichstein D, et al. Follow-up of angle-closure glaucoma suspects. *Am J Ophthalmol* 1993;115:338.
8. Lavanya R, Baskaran M, Kumar RS, Wong HT, Chew PT, Foster PJ, Friedman DS, Aung T. Risk of acute angle closure and changes in intraocular pressure after pupillary dilation in Asian subjects with narrow angles. *Ophthalmology* 2012;119:3:474-80.
9. Wolfs RC, Grobbee DE, Hofman A, deJong PT. Risk of acute angle-closure glaucoma after diagnostic mydriasis in nonselected subjects: The Rotterdam Study. *Invest Ophthalmol Vis Sci* 1997;38:12:2683-7.
10. Patel KH, Javitt JC, Tielsch JM, Street DA, Katz J, Quigley HA, Sommer A. Incidence of acute angle-closure glaucoma after pharmacologic mydriasis. *Am J Ophthalmol* 1995;120:6:709-17.
11. Zhang X, Liu Y, Wang W, et al. Why does acute primary angle closure happen? Potential risk factors for acute primary angle closure. *Surv Ophthalmol* 2017;62:5:635-647.



# 100% PRESERVATIVE FREE



If you're attending  
AAO 2018, visit us at  
**AKORN BOOTH  
#3700**




  
**ZIOPTAN<sup>®</sup>**  
(tafluprost ophthalmic  
solution) 0.0015%

[www.ZIOPTAN.com](http://www.ZIOPTAN.com)

  
**Cosopt<sup>®</sup> PF**  
(dorzolamide HCl - timolol maleate  
ophthalmic solution) 2% / 0.5%

[www.CosoptPF.com](http://www.CosoptPF.com)

COSOPT is a registered trademark of Merck Sharp & Dohme Corp and is used under license. ZIOPTAN is a registered trademark of Merck Sharp & Dohme Corp and is used under license.

 ZIOPTAN is licensed by Santen Pharmaceutical Co., Ltd.

 **AKORN**

©2018 Akorn, Inc. All rights reserved. E089 Rev 07/18



# Imaging Advances for Choroidal Melanoma

How recent additions to ophthalmologists' imaging toolbox are helping with diagnosis and management of these cancers.

Mary E. Aronow, MD, Boston

**T**he diagnosis of choroidal melanoma is clinical and supported by ancillary imaging findings. Recent advances in multimodal imaging allow for more accurate tumor characterization and a sophisticated approach to monitoring tumor response to therapy. Fundus photography, ultrasonography, fundus autofluorescence, angiography and optical coherence tomography play a central role in the practical management of choroidal melanoma. In particular, the development of ultra-widefield imaging systems and the expanded uses of OCT have impacted patient care significantly. Here, I'll review the state of the art when it comes to imaging choroidal melanoma.

## Fundus Photography

Since the development of the fundus camera in the early 1900s, progress in the field of digital imaging has revolutionized the ability to capture clinical observations. The early fundus camera introduced by Zeiss and Nordensen in 1926 provided a 20-degree field of view.<sup>1</sup> Standard modern mydriatic fundus cameras now capture 30 to 50 degrees of the fundus and allow for

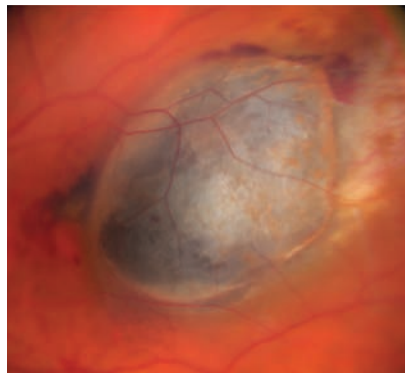


Figure 1. Choroidal melanoma in the macula captured with standard color fundus photography documents typical features: a dome-shaped pigmented choroidal mass with overlying orange pigment, the absence of drusen and the presence of subretinal fluid.

excellent documentation of features pertinent to choroidal melanoma, such as the degree of pigmentation, the presence or absence of drusen, lipofuscin (or "orange pigment"), overlying changes in the retinal pigment epithelium, and subretinal fluid (Figure 1). The standard field can be increased by fusing images to create a montage. In the Diabetic Retinopathy Study, "7-standard" overlapping 30-degree fields were viewed collectively to pro-

vide 75 degrees of the fundus.<sup>2</sup> Standard color fundus photography provides advantages, including accurate depiction of color and high image resolution; however, standard fields aren't ideal when choroidal melanoma is extensive or located in the anterior fundus.

More recently developed non-mydriatic, ultra-widefield imaging systems capture up to 200 degrees of the fundus in a single image. For peripherally located tumors, these systems allow for more complete documentation of tumor margins and associated features such as exudative retinal detachment, particularly when multiple clock hours of the fundus are involved (Figure 2). The ability to accurately photograph tumors located anterior to the equator at regular time intervals following primary therapy is important for assessing response to therapy and monitoring for recurrence at tumor margins.<sup>3</sup> While advantageous in this regard, ultra-widefield imaging has limitations. In comparison to standard color fundus photography, ultra-widefield systems have less accurate color representation. Additionally, the spherical shape of the globe results in distortion of



# IMAGES THAT EMPOWER.



**Welcome** to a platform where every image is remarkably accurate. Reliably repeatable. Proven to enable confident clinical decision-making. And ready for the advanced image analytics necessary for success in a changing healthcare environment. It's a platform like none other. And now, one that's accessible for any practice.

**Experience powerful images that empower you to do more for your patients and your practice. Experience Heidelberg Image Quality™.**

**To learn more, please call 800-931-2230 or visit [HeidelbergEngineering.com](https://www.HeidelbergEngineering.com)**

the peripheral image, producing artifactual changes in the shape and apparent size of tumors located more anteriorly. This can be overcome by using a multimodal approach, such as combining clinical impressions from ophthalmoscopy and tumor dimensions from ultrasonography to more accurately characterize overall tumor size.

### Fundus Autofluorescence

FAF can be performed using both standard and ultra-widefield imaging systems. This modality can be particularly helpful in confirming the presence of overlying lipofuscin, a frequent clinical feature of choroidal melanoma. With FAF, hyper-autofluorescence results when lipofuscin is exposed to intense blue light with a wavelength of 488 nm.<sup>4</sup> Lipofuscin accumulates in the retinal pigment epithelium and in macrophages, but its appearance is variable depending upon the pigmentation of the underlying lesion. For highly melanocytic tumors, lipofuscin will characteristically be bright orange. For more lightly pigmented or amelanotic choroidal melanoma, lipofuscin may appear “ruddy” brown. Other benign tumors, such as circumscribed choroidal hemangioma, can also have overlying lipofuscin, but its presence may be nearly undetectable by ophthalmoscopy. FAF is useful for identifying lipofuscin, and although not pathognomonic for choroidal melanoma, its presence is supportive of the diagnosis.<sup>5</sup>

### Angiography

Fluorescein angiography is available in both standard format and in ultra-widefield imaging platforms that offer 100- to 200-degree fields of view. Ultra-widefield systems may provide superior capture ability for more peripherally located choroidal melanoma (Figure 3). FA is also useful for assess-

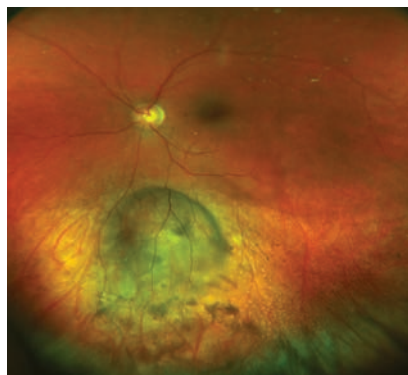


Figure 2. Ultra-widefield color fundus photography completely captures a choroidal melanoma in which the anterior margin is overlying the equator. Following treatment with I-125 plaque brachytherapy, the tumor demonstrates regression with a ring of surrounding chorioretinal atrophy.

ing and monitoring treatment-related side effects in the retina, such as capillary changes and areas of radiation-induced non-perfusion. Indocyanine green angiography, also available in standard and ultra-widefield formats, provides superior characterization of the choroidal vasculature and is particularly helpful for documenting features of choroidal melanoma (Figure 4), such as intrinsic vascularity (the “double-circulation sign”).

### Optical Coherence Tomography

Since its introduction, OCT has become widespread in ophthalmic practice.<sup>6</sup> Spectral-domain OCT has

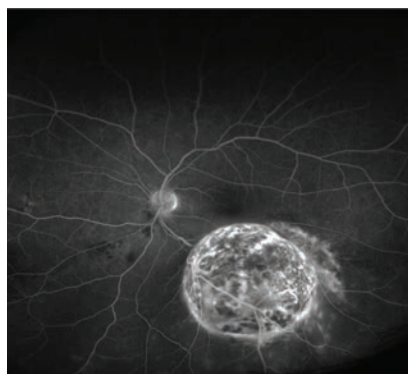


Figure 3. Ultra-widefield fluorescein angiography of choroidal melanoma. Intrinsic vasculature is present within the tumor.

essentially replaced conventional time-domain systems due to its superior speed, sensitivity and resolution. In particular, enhanced-depth-imaging OCT has become a valuable tool for characterizing the choroid.<sup>7</sup> This technique takes advantage of the increased depth of field in the inverted image that results from placing the SD-OCT device closer to the eye.

While ultrasonography remains the gold standard for measuring tumor dimensions, EDI-OCT can be particularly helpful for evaluating small choroidal melanoma. Ultrasonography provides millimeter-level resolution, but for tumors less than 1 mm in thickness, EDI-OCT can provide micron-level information related to tumor thickness and surface topography (Figure 5). In such cases, EDI-OCT has the potential to visualize a tumor completely and to differentiate it from the normal surrounding choroid.<sup>8</sup> In one series of 23 lesions composed of amelanotic choroidal nevus, melanocytic choroidal nevus, choroidal melanoma, circumscribed choroidal hemangioma and choroidal metastasis, tumor thickness could be measured by EDI-OCT, but not by ultrasonography in 10 cases (in each case, lesions were less than 1 mm thick).<sup>8</sup> EDI-OCT image quality is affected by tumor pigmentation, however. Amelanotic tumors may be somewhat easier to characterize, as they demonstrate less shadowing artifact and have a more homogenous, medium reflectivity.<sup>7</sup> Highly pigmented lesions are more likely to demonstrate posterior shadowing, which compromises visualization beyond the anterior tumor surface.<sup>9</sup>

EDI-OCT has also been used in an attempt to distinguish between small choroidal melanoma and suspicious choroidal nevi. In one series of 37 eyes with small choroidal melanoma, choroidal shadowing and choriocapillaris thinning was found all cases.<sup>10</sup> Compared with choroidal nevi of similar size, statistically significant EDI-OCT





SAVE THESE DATES



# 2ND YEAR OPHTHALMOLOGY RESIDENT WET LAB PROGRAMS

## 2018-2019 Residency Year

December 1-2, 2018  
Meeting is Full  
Fort Worth, TX


February 9-10, 2019  
(Saturday-Sunday)  
Fort Worth, TX

February 16-17, 2019  
(Saturday-Sunday)  
Fort Worth, TX

REGISTER FOR WAITLIST

RESERVE SEAT NOW

RESERVE SEAT NOW



Dear Resident Program Director and Coordinator,

We would like to invite you to review the upcoming 2nd-Year Ophthalmology Resident Wet Lab Programs for the 2018-2019 Residency Year in Fort Worth. These programs offer a unique educational opportunity for second-year residents. To better familiarize beginning ophthalmologists with cataract surgery, these programs will consist of both didactic lectures and a state-of-the-art, hands-on wet lab experience. Technology and technique will be explained and demonstrated and surgeons will leave better prepared to optimize outcomes and manage complications when they arise.

The programs also serve as an opportunity for your residents to network with residents from other programs.

After reviewing the material, it is our hope that you will select and encourage your 2nd Year residents to attend one of these educational activities, which are CME accredited to ensure fair balance.

Sincerely,

Postgraduate Healthcare Education

[www.reviewsce.com/CSE2ndYr2018-19](http://www.reviewsce.com/CSE2ndYr2018-19)

For more information: Visit the registration site above or

Email: [dholmes@postgradhealthed.com](mailto:dholmes@postgradhealthed.com) • Call: Denette Holmes 866-627-0714

Courses are restricted to 2nd-year residents enrolled in an ophthalmology residency program at the time of the course. There is no registration fee for this activity. Air, ground transportation in Fort Worth, hotel accommodations, and modest meals will be provided through an educational scholarship for qualified participants.

Satisfactory Completion - Learners must complete an evaluation form to receive a certificate of completion. Your chosen sessions must be attended in their entirety. Partial credit of individual sessions is not available. If you are seeking continuing education credit for a specialty not listed below, it is your responsibility to contact your licensing/certification board to determine course eligibility for your licensing/certification requirement.

Physicians - In support of improving patient care, this activity has been planned and implemented by Amedco LLC and Postgraduate Healthcare Education. Amedco LLC is jointly accredited by the Accreditation Council for Continuing Medical Education (ACCME), the Accreditation Council for Pharmacy Education (ACPE), and the American Nurses Credentialing Center (ANCC), to provide continuing education for the healthcare team

Credit Designation Statement - This activity has been approved for *AMA PRA Category 1 Credits™*.



JOINTLY ACCREDITED PROVIDER  
INTERPROFESSIONAL CONTINUING EDUCATION

Endorsed by:

Jointly provided by:

Supported by an independent medical  
education grant from:

Review of Ophthalmology®

PHE

AMEDCO

Alcon

features of small choroidal melanoma included: intraretinal edema; loss of photoreceptors; loss of the external limiting membrane; loss of the inner segment-outer segment junction; irregularity of the inner plexiform layer; and irregularity of the ganglion cell layer. Elongated photoreceptors were observed overlying small choroidal melanoma in 49 percent of eyes, but this finding wasn't observed in choroidal nevi.<sup>10</sup>

Swept-source OCT has recently been used to characterize choroidal lesions and may provide some advantages for pigmented tumors.<sup>11</sup> SS-OCT uses a wavelength-tunable laser and a dual-balanced photodetector that provides superior imaging speed. Its adaptability to longer wavelengths allows for imaging of the choroid and greater penetration of melanin.<sup>12</sup> In one series of 30 eyes with choroidal nevi, SS-OCT enabled visualization of intralesional details such as vessels, cavities and granularity. For melanocytic nevi, SS-OCT was superior for depicting intralesional characteristics (vessels, granularity, abnormal choriocapillaris) compared to EDI-OCT.<sup>11</sup> In another series of 85 choroidal lesions evaluated by SS-OCT, the majority of melanocytic choroidal lesions could be successfully characterized. In this series, multivariable analysis revealed several factors significantly associated with optimal image quality, including: lesion location closer to the fovea; lighter pigmentation; and smaller diameter.<sup>13</sup>

The newest form of OCT, optical coherence tomography angiography, is a non-invasive (i.e., dye-free) technique for imaging the retinal and choroidal vasculature. OCTA collects information regarding retinal and choroidal blood flow by comparing consecutive B-scans. OCTA may also help to distinguish choroidal melanoma from benign nevi by identifying unique vascular pat-

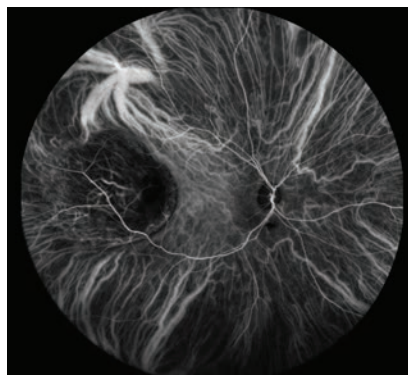


Figure 4. Ultra-widefield indocyanine green angiography of choroidal melanoma demonstrating intrinsic vasculature.

terns. In a series of 11 patients (six with choroidal melanoma and five with choroidal nevi), OCTA demonstrated a hyporeflective mass with no significant deformity of the choroidal vasculature and an intact retinal pigment epithelium-Bruch's membrane complex in all cases of choroidal nevi. In contrast, OCTA demonstrated an obscured RPE-Bruch's membrane complex and outer retinal layer in cases of choroidal melanoma.<sup>14</sup> The average choriocapillaris flow rate associated with choroidal melanoma was only 55.7 percent, compared to the normal choriocapillaris's flow rate of 62.8 percent ( $p=0.01$ ). Additionally, axial and peripheral feeder blood vessels were noted to be more dilated and tortuous for eyes with cho-

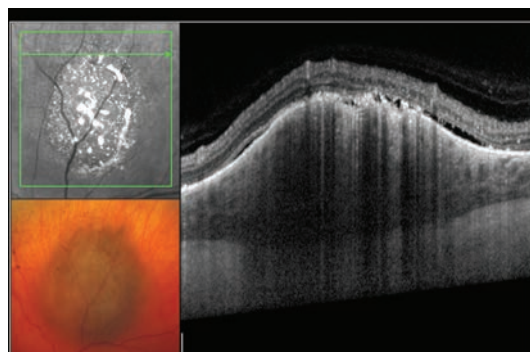


Figure 5. EDI-OCT of a suspicious pigmented choroidal lesion with overlying orange pigment and subretinal fluid. The lesion demonstrated significant and quantifiable growth over the course of six months and was ultimately treated with I-125 plaque brachytherapy.

roidal melanoma compared with benign nevi.<sup>14</sup>

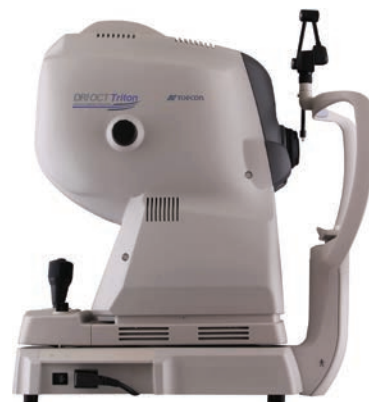OCTA can also be useful for both qualitatively and quantitatively assessing iatrogenic changes within the retina and choroid following treatment for choroidal melanoma. Images can be segmented to determine the degree of capillary dropout and nonperfusion in the superficial and deep layers of the retina, and in the choriocapillaris (Figure 6). A recent cross-sectional study compared OCTA findings in 10 eyes with choroidal melanoma imaged prior to therapy and 15 irradiated eyes with clinically apparent radiation retinopathy and/or optic neuropathy. In eyes with radiation-induced side effects, peripapillary retinal capillary density (PPCD) was lower in the treated eye and correlated with the radiation dose to the optic nerve as well as with the visual acuity outcome. In contrast, no significant difference was observed in PPCD in eyes with melanoma prior to irradiation compared with normal fellow eyes.<sup>15</sup>

### Future Directions

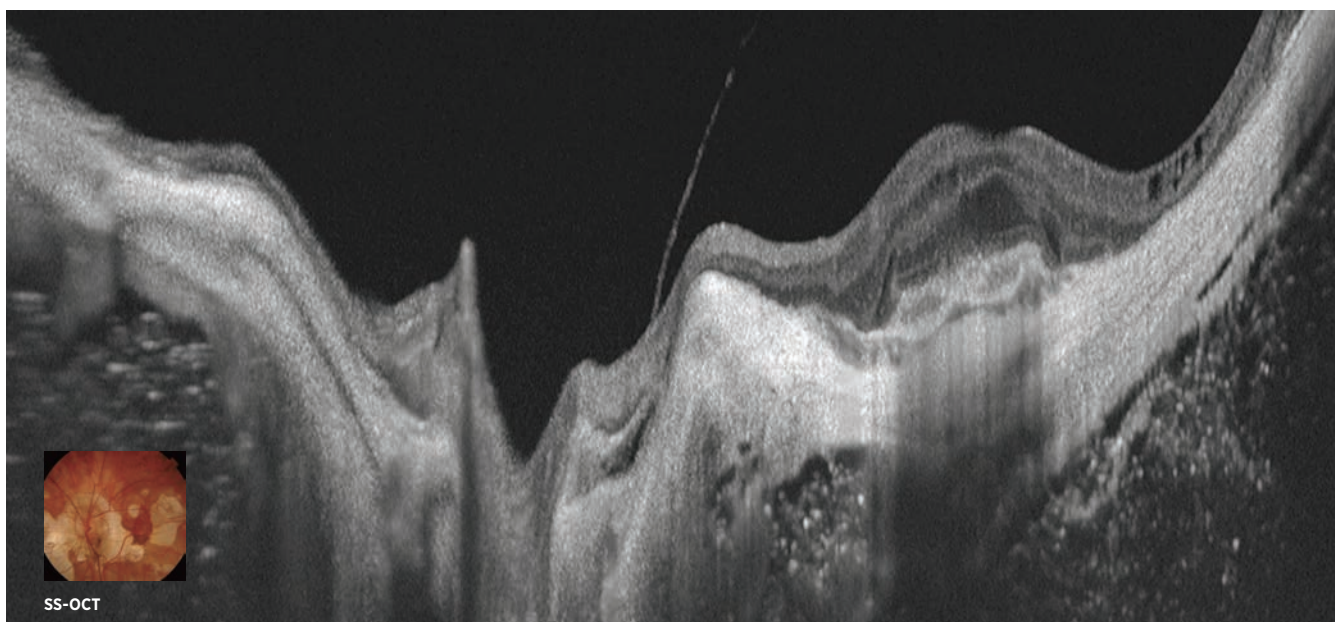
The widespread use of multimodal imaging for choroidal melanoma allows for superior characterization of tumors in a field that's continually evolving. No one imaging technique alone serves as a gold standard for management. It's the combination of imaging modalities that allows for superior tumor assessment and a more thorough understanding of the clinical features of choroidal melanoma. For diagnostically challenging cases, newer imaging strategies may provide a non-invasive means to differentiate choroidal melanoma from benign and simulating lesions. Multimodal imaging also allows greater opportunity to study treatment-related side effects. This is especially relevant, as radiation-dose protocols con-

# JOIN US AT AAO FOR A SYMPOSIUM INNOVATIONS IN SWEPT SOURCE OCT

This symposium will review the latest clinical and technical advances in SS-OCT including the potential of artificial intelligence in ophthalmology.



DRI OCT Triton™ Series  
A Multimodal Swept Source OCT



## SUNDAY, OCTOBER 28

Registration, Cocktails  
and Hors d'oeuvres  
**5:00 PM to 6:00 PM**

Presentation  
**6:00 PM to 7:30 PM**

Venue  
**Marriott Marquis**  
2121 S. Prairie Avenue  
Chicago, IL  
Room: Great Lakes A & B

### COMPLIMENTARY REGISTRATION

Online  
**reviewofophthalmology.com/  
OCTReception1028**

Call  
**877-451-6513**

Email  
**ReviewMeetings@jhihealth.com**

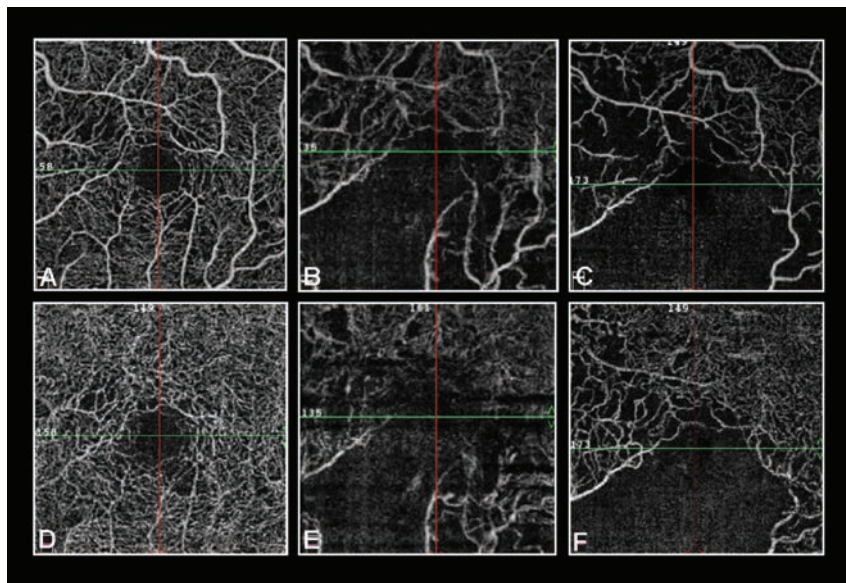
This event is not affiliated with the official program of AAO 2018. Your attendance at this meeting may be reported by the sponsor in accordance with the sunshine act. For further information visit, [cms.gov/Regulations-and-Guidance/Legislation/National-Physician-Payment-Transparency-Program/Downloads/Physician-fact-sheet.pdf](https://www.cms.gov/Regulations-and-Guidance/Legislation/National-Physician-Payment-Transparency-Program/Downloads/Physician-fact-sheet.pdf). Please refer to your state laws for any attendance restrictions. Attendance at this event is limited to eye care professionals. Due to individual state legislation, physicians licensed in Minnesota, Vermont and Massachusetts may not attend this symposium.

BROUGHT TO YOU BY



SPONSORED BY





Nahna K Kim, MD

Figure 6. OCTA showing a progressive decrease in macular capillary density 6 (A, D), 18 (B, E), and 24 (C, F) months following treatment with proton beam irradiation in the superficial retinal layers (top row) and deep retinal layers (bottom row).

tinue to be refined,<sup>16</sup> newer therapies will arise,<sup>17</sup> and the role of anti-vascular endothelial growth factor in preventing radiation retinopathy is currently being investigated.<sup>18</sup> Newer technologies will address issues such as the more accurate depiction of colors, particularly for ultra-widefield systems; the development of smaller and more portable devices; and cost-effectiveness. **REVIEW**

*Dr. Aronow is an assistant professor of ophthalmology at the Ocular Melanoma Center and Retina Service at Massachusetts Eye and Ear/Harvard Medical School. She can be reached at mary\_aronow@meei.harvard.edu. She has no financial interest in any of the products discussed in the article.*

1. Ciardella A, Brown D. Wide field imaging. In: Agarwal A, ed. Fundus Fluorescein and Indocyanine Green Angiography: A Textbook and Atlas. New York: Slack, 2007:79-83.
2. The Diabetic Retinopathy Study Research Group. Diabetic retinopathy study. Report Number 6: Design, methods, and baseline results. Report Number 7: A modification of the Airle House classification of diabetic retinopathy. Invest Ophthalmol Vis Sci 1981;21:1-226.
3. Mirchia K, Turell ME, Singh AD. Imaging modalities for uveal melanoma. European Ophthalmic Review 2012;6:1:56-63.
4. Schmitz Valckenberg S, Holz FG, Bird AC, et al. Fundus autofluorescence imaging: Review and perspective. Retina 2008;28:385-409.
5. Shields JA, Rodrigues MM, Sarin LK, et al. Lipofuscin pigment

- over benign and malignant choroidal tumors. Trans Sect Ophthalmol Am Acad Ophthalmol Otolaryngol 1976;81:5:871-81.
6. Huang D, Swanson EA, Lin CP, et al. Optical coherence tomography. Science 1991;254:1178-81.
7. Spaide RF, Koizumi H, Pozzoni MC. Enhanced depth imaging spectral-domain optical coherence tomography. Am J Ophthalmol 2008;146:4:496-500.
8. Torres VL, Brugnoli N, Kaiser PK, et al. Optical coherence tomography enhanced depth imaging of choroidal tumors. Am J Ophthalmol 2011;151:586-93.
9. Shah SU, Kaliki S, Shields CL, et al. Enhanced depth imaging optical coherence tomography of choroidal nevus in 104 cases. Ophthalmology 2012;119:1066-72.
10. Shields CL, Kaliki S, Rojanaporn D, et al. Enhanced depth imaging optical coherence tomography of small choroidal melanoma: Comparison with choroidal nevus. Arch Ophthalmol 2012;130:850-6.
11. Francis JH, Pang CE, Abramson DH, et al. Swept-source optical coherence tomography features of choroidal nevi. Am J Ophthalmol 2015;159:1:169-76.
12. Mrejen S, Spaide RF. Optical coherence tomography: Imaging of the choroid and beyond. Surv Ophthalmol 2013;58:387-429.
13. Ung C, Lains I, Silverman RF, et al. Evaluation of choroidal lesions with swept-source optical coherence tomography. Br J Ophthalmol 2018 Mar 31 [Epub ahead of print].
14. Ghassemi F, Mirshahi R, Fadakari K, Sabour S. Optical coherence tomography angiography in choroidal melanoma and nevus. Clin Ophthalmol 2018;12:207-14.
15. Skalet AH, Liu L, Binder C, et al. Quantitative OCT angiography evaluation of peripapillary retinal circulation after plaque brachytherapy. Ophthalmol Retina 2018;2:3:244-50.
16. Patel AV, Lane AM, Morrison MA, et al. Visual outcomes after proton beam irradiation for choroidal melanomas involving the fovea. Ophthalmology 2016;123:2:369-77.
17. Kines RC, Varsavsky I, Choudhary S, et al. An infrared dye-conjugated virus-like particle for the treatment of primary uveal melanoma. Mol Cancer Ther 2018;17:2:565-74.
18. Kim IK, Lane AM, Jain P, et al. Ranibizumab for the prevention of radiation complications in patients treated with proton beam irradiation for choroidal melanoma. Trans Am Ophthalmol Soc 2016;114:T2.

(Continued on page 12)

don't advocate routinely placing one-piece acrylics in the sulcus as a back-up when in-the-bag placement isn't possible.

I've successfully implanted two Symphony IOLs in the sulcus with IOL capture. Both were myopes with deep chambers and adequate distance between the posterior iris and the anterior capsule. Both were second-eye surgeries. One was a Symphony toric. From the clinical perspective, using a three-piece Tecnis in this second eye surgery wouldn't give the patient the best multifocal result, since the optical design of the Symphony is very different from the Tecnis. Blending different add power Tecnis IOLs in the same patient can work well, though, and is common since the optical design of the lenses are similar. In the toric Symphony patient, placing a spherical Tecnis three-piece ZMB00 would result in a different multifocal visual experience in addition to a lack of clarity from residual astigmatism. Corneal astigmatic cuts had been already placed by a femtolaser, but only for the residual astigmatism not fully corrected by the toric IOL. These cuts could be augmented, but would leave visually significant uncorrected astigmatism. If monofocal three-piece IOLs were used, the visual systems could be potentially disrupted by having one Symphony eye and one monofocal eye, especially when neuro-adapting to any night-vision issues.

I realize that two patients isn't a large enough series to advocate a change in practice. My discussion was simply to point out that given certain clinical circumstances and surgical situations, one-piece acrylic IOLs can be placed in the sulcus with anterior capsule capture. With more than one year of follow-up, both patients have done well, with excellent vision and none of the complications described.

*Signed,  
Douglas Grayson, MD*



SAVE THE DATE



OCTOBER 12-13, 2018

# CSE GLAUCOMA FELLOWS

Fort Worth, Texas

Dear Fellowship Program Director and Coordinator,

We would like to invite you to review the upcoming 2018 Glaucoma Fellowship Program and Wet Lab in Fort Worth at the Renaissance Worthington hotel. The program offers a unique educational opportunity for fellows by providing the chance to meet and exchange ideas with some of the most respected thought leaders in glaucoma. The Glaucoma Fellows Program and Wet Lab is designed to provide your fellows with a state-of-the-art didactic and wet lab experience. The program also serves as an opportunity for your fellows to network with fellows from other programs.

After reviewing the material, it is our hope that you will select and encourage your fellows to attend this educational activity which is CME accredited to ensure fair balance.

Sincerely,  
Postgraduate Healthcare Education

**Course Director:**

**Kuldev Singh, MD**  
*Stanford, CA*

**Wet Lab Directors:**

**Douglas J. Rhee, MD**  
*Cleveland, OH*

**Ronald Fellman, MD**  
*Dallas, TX*

**Faculty:**

Lee Alward, MD	Steven Gedde, MD	Marlene Moster, MD	Arthur Sit, MD
Donald Budenz, MD	Dale Heuer, MD	Kelly Muir, MD	George Spaeth, MD
Joseph Caprioli, MD	Michele Lim, MD	Pradeep Ramulu, MD	Josh Stein, MD
Brian Flowers, MD	Eydie Miller-Ellis	Joel Schuman, MD	

**For More Information & to Register:**  
**[www.revophth.com/2018cseglaucoma](http://www.revophth.com/2018cseglaucoma)**

Email: [dholmes@postgradhealthed.com](mailto:dholmes@postgradhealthed.com) or call Denette Holmes 866-627-0714

Participants in this course must be enrolled in a glaucoma fellowship program at the time of the course. There is no registration fee for these activities. Air, ground transportation in Dallas Fort Worth Airport, hotel accommodations and modest meals will be provided through an educational scholarship for qualified participants.

**Satisfactory Completion** - Learners must pass a post-test and complete an evaluation form to receive a certificate of completion. Your chosen sessions must be attended in their entirety. Partial credit of individual sessions is not available. If you are seeking continuing education credit for a specialty not listed below, it is your responsibility to contact your licensing/certification board to determine course eligibility for your licensing/certification requirement.



JOINTLY ACCREDITED PROVIDER  
INTERPROFESSIONAL CONTINUING EDUCATION

**Physicians** - In support of improving patient care, this activity has been planned and implemented by Amedco LLC and Postgraduate Healthcare Education. Amedco LLC is jointly accredited by the Accreditation Council for Continuing Medical Education (ACCME), the Accreditation Council for Pharmacy Education (ACPE), and the American Nurses Credentialing Center (ANCC), to provide continuing education for the healthcare team

**Credit Designation Statement** - Amedco designates this live activity for *AMA PRA Category 1 Credits™*. Physicians should claim only the credit commensurate with the extent of their participation in the activity.

Jointly provided by

Endorsed by  
**Review of Ophthalmology®**



Supported by an unrestricted independent  
medical educational grant from

**Alcon**

**Practice For Sale**



Practice Sales • Appraisals • Consulting  
[www.PracticeConsultants.com](http://www.PracticeConsultants.com)

**PRACTICES FOR SALE  
NATIONWIDE**

Visit us on the Web or call us to learn more about our company and the practices we have available.

[info@PracticeConsultants.com](mailto:info@PracticeConsultants.com)

**800-576-6935**

[www.PracticeConsultants.com](http://www.PracticeConsultants.com)

**Career Opportunities**

**OPHTHALMOLOGISTS**

Danbury, CT

Ophthalmologists to share office with long standing Ophthalmologist in Danbury, CT. High quality equipment. \$2,250 per month or adjoining office without equipment- \$1,750 per month.

**203-545-3539 or  
email [mehrimd@aol.com](mailto:mehrimd@aol.com)**

**Products and Services**



Before

After

**DIAMOND KNIFE REPAIR/RESIZE**

- Repair any make or style diamond blade
- Changing to a smaller incision? We can resize or reshape any style diamond blade
- Free annual cleaning and inspection of Pelion/Metico diamond blades
- Over 30 years experience in diamond knives

**We also repair any make surgical instrument, including phaco, I/A handpieces and tips**



[www.pelionsurgical.com](http://www.pelionsurgical.com)  
888-883-3991



# Targeting Ophthalmologists?

**CLASSIFIED ADVERTISING  
WORKS**



Contact us today  
for classified advertising:  
Toll free: **888-498-1460**  
E-mail: [sales@kerhgroup.com](mailto:sales@kerhgroup.com)



## FIND MORE PRACTICES FOR SALE ON



CONTACT US TODAY to list your practice:

**888-498-1460**

[opticlassifieds@kerhgroup.com](mailto:opticlassifieds@kerhgroup.com)

[www.opticlassifieds.com](http://www.opticlassifieds.com)

A 74-year-old man presents to Wills Eye Hospital for evaluation of a recurrent ocular surface lesion.

*Austin R. Meeker, MD, Christopher J. Rapuano, MD, and Carol L. Shields, MD*

## Presentation

A 74-year-old Caucasian man presented for a second opinion regarding a recurrent ocular surface lesion of the left eye. Four years prior to presentation he was treated for a “squamous papilloma” of the conjunctiva with excision and subconjunctival interferon (IFN). The lesion subsequently recurred three times. The patient underwent re-excision with postoperative topical mitomycin C after the first recurrence, then a second re-excision and treatment with topical 5-fluorouracil. When he developed a third recurrence, proton beam radiation was recommended at which time he sought a second opinion at the Wills Eye Hospital Oncology Service.

## Medical History

Past ocular history included cataract surgery in both eyes, ocular hypertension and dry age-related macular degeneration. Past medical history included hyperlipidemia. Family history disclosed a sister with primary open-angle glaucoma. Social history was non-contributory. Current medications were travoprost, AREDS2 vitamins and simvastatin.

## Examination

On examination, visual acuity with correction was 20/30 OD and 20/60 (pinhole 20/50) OS. Pupils were normal, and intraocular pressures were 17 mmHg OD and 18 mmHg OS. Extraocular movements and confrontation visual fields were full in both eyes.

Anterior segment examination of the left eye revealed a 4 mm x 4 mm fibrovascular frond at the superonasal limbus extending onto the cornea (*Figure 1*). Additionally, there was a posterior chamber intraocular lens in both eyes. Dilated fundus examination demonstrated a few macular drusen but was otherwise unremarkable.

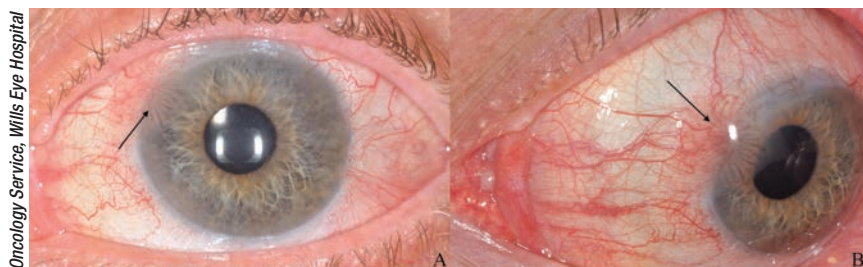


Figure 1. External photographs of the left eye in primary gaze (A) and abduction (B) upon presentation to Wills Eye Hospital. A 4 x 4 mm fibrovascular frond extends from the conjunctiva onto the corneal surface at the superonasal limbus (arrows).

***What is your diagnosis? What further workup would you pursue? The diagnosis appears on p. 64.***

## Workup, Diagnosis and Treatment

Given the typical appearance of the lesion, ocular surface squamous neoplasia (OSSN) was the leading diagnosis. Treatment involved careful excision and intraoperative subconjunctival IFN according to the method described by Drs. Jerry and Carol Shields of the Wills Eye Ocular Oncology Service.<sup>1</sup> The limbal conjunctiva was excised from 9 to 3 o'clock with 4-mm margins and alcohol-assisted removal of the corneal epithelium beginning 2 mm anterior to the extent of tumor, scraping toward the main lesion without direct manipulation of the tumor. A sample of Tenon's fascia from 10 to 2 o'clock and an orbital biopsy at 10 o'clock were sent for staging. Cryotherapy was performed at all surgical margins. Subconjunctival injection of 10 million units of IFN was performed 360 degrees around the surgical margin.

Histopathology of the surgical specimens demonstrated papillary squamous cell carcinoma *in situ* at the limbus, with both Tenon's fascia and the orbital biopsy negative for tumor (Figure 2). Postoperatively, treatment continued with monthly subconjunctival injections of IFN and topical IFN four times daily for four months.

At postoperative month six, the patient began to complain of blurred vision with inter-

mittent monocular diplopia in his left eye. His vision at this time was 20/70 (PH 20/60) OS, and anterior segment evaluation revealed irregular corneal epithelium superiorly. Over several months, his vision deteriorated to 20/400 (PH 20/80), and the irregular corneal epithelium covered the superior 60 percent of his corneal surface (Figure 3A). When conservative treatment for presumed limbal stem cell deficiency (LSCD) with artificial tears and eyelid hygiene didn't improve his symptoms or corneal appearance, selective epithelial debridement was performed.

Histopathology of the epithelial scraping revealed sheets of epithelial cells with focal collections of goblet cells; the increased cellularity of squamous cells with scant cytoplasm was suspicious for intraepithelial neoplasia. Given the history of multiple recurrences with concerning findings on histopathology, daily topical IFN

was restarted. The ocular surface re-epithelialized with healthy-appearing epithelium, and vision improved to 20/100 (PH 20/70) (Figure 3B). One year later, however, the corneal epithelial irregularity recurred (Figure 3C). At this time, daily topical interferon was restarted for a six-month course.

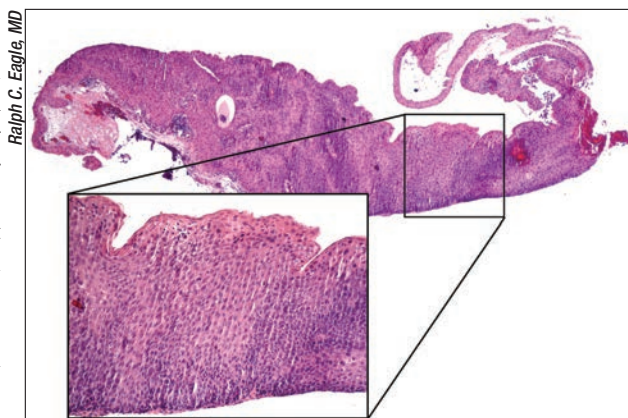


Figure 2. Histopathology of excised limbus. Lower power magnification demonstrates the papillary configuration of squamous cells. Higher-power photomicrograph (inset) shows full-thickness epithelial replacement with dysplastic squamous cells with scant cytoplasm. The basement membrane is intact with no subepithelial spread, consistent with squamous cell carcinoma *in situ*.

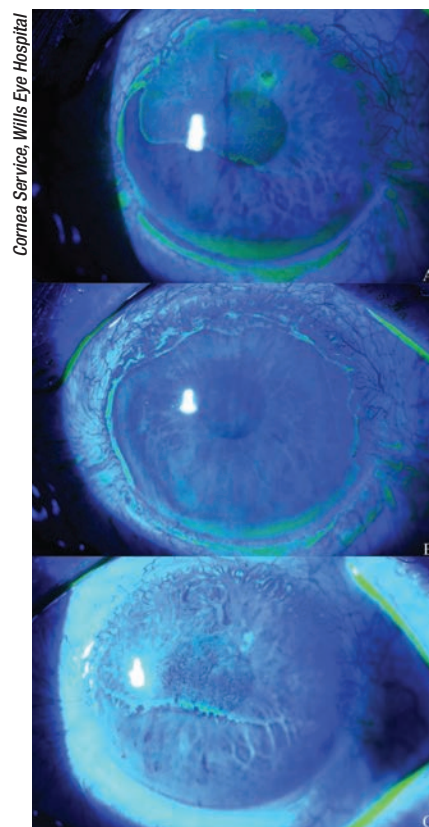


Figure 3. External photo of the left eye nine months after limbus excision with corneal scraping, subconjunctival interferon injection and cryotherapy to the surgical margins (A). Fluorescein staining highlights irregular corneal epithelium covering about 60 percent of the surface. Photo of the left eye one week after selective epithelial debridement (B). At post year one (C), fluorescein staining demonstrated recurrence of the corneal epithelial irregularity.

## Discussion

Ocular surface squamous neoplasia is a spectrum of disease encompassing squamous dysplasia, intraepithe-

lial neoplasia, carcinoma *in situ* and squamous cell carcinoma of the conjunctiva and cornea. It is typically uni-

lateral and rarely metastatic, with risk factors including age (typically age 70 and above), male gender, Caucasian



race, lightly pigmented iris, infection with HIV and HPV, and exposure to UV-B radiation.<sup>2</sup> Although diagnosis is primarily made by clinical presentation and examination findings, histopathology is useful for confirmation and staging. Historically, OSSN has been treated surgically with excision and adjuvant cryotherapy and/or local chemotherapy. Recurrence may occur if neoplastic cells remain after excision.<sup>3</sup>

The patient in the present case had three recurrences prior to his presentation at Wills Eye Hospital. Two strategies for preventing recurrences were employed at this time: “no touch” surgery and adjuvant IFN therapy. With 4-mm wide conjunctival margins and alcohol-assisted removal of the corneal involvement 2 mm anterior to the extent of tumor, scraping toward the main lesion, the excision was broad without direct manipulation of tumor cells.<sup>1</sup> Furthermore, IFN, both in its subconjunctival injection and topical drop forms, has demonstrated efficacy as an adjunct to surgery and as sole treatment for OSSN. In one study, five patients with histologically diagnosed OSSN responded with complete tumor control to topical IFN alone.<sup>4</sup> Similar results were observed in a case series of 81 eyes with OSSN in which IFN with or without surgical excision and cryotherapy led to complete tumor control in 95 percent of cases, with a recurrence rate of 5 percent.<sup>5</sup> Of note, in the 5 percent of recurrent cases, complete regression was achieved with further IFN and cryotherapy. Furthermore, there were minimal side effects in this cohort, with less than 5 percent of patients developing ocular surface irritation, a mild follicular reaction or hyperemia when IFN was administered topically. Finally, no patients developed LSCD, in contrast to topical chemotherapeutics such as MMC and 5-FU, which have been known to cause epitheliopathy and loss

of limbal stem cells.<sup>2</sup>

Despite the low risk of ocular surface toxicity from IFN, this patient had numerous risk factors for developing LSCD, including multiple surgical excisions at the limbus, cryotherapy and prior chemotherapeutic application, in addition to the ocular surface neoplasia itself. In milder cases of LSCD – which some suggest may represent limbal stem cell dysfunction rather than true deficiency – conservative management with artificial tears, eyelid hygiene and medical therapy such as topical cyclosporine, topical corticosteroids or oral doxycycline can lead to restoration of a healthy corneal epithelium.<sup>6</sup>

In cases refractory to supportive care and medical management, surgery is often necessary. When less than half of the limbus is damaged, selective epithelial debridement can allow dividing epithelium from healthy limbal cells to regenerate over the debrided area faster than the process of conjunctivalization, leading to improvement in the ocular surface in the visual axis.<sup>7</sup> In our patient, this intervention led to initial improvement in visual symptoms, visual acuity and the ocular surface examination. The histopathology of the epithelial scraping was concerning for possible recurrence of intraepithelial neoplasia; however, it's unclear whether this represented true recurrence, since epithelial scrapings don't have histologic features specific enough to diagnose OSSN. Furthermore, the area of epithelial irregularity involved only the cornea, while prior recurrences in this patient had occurred at the limbus and conjunctiva. Nevertheless, given this individual's concerning history and the favorable risk-benefit profile of IFN, the decision was made to restart IFN.

A history of OSSN can complicate decisions regarding management of LSCD. In patients not responsive to medical therapy for LSCD, limbal

stem cell transplantation (LSCT), including simple limbal epithelial transplantation (SLET), may be employed. Many surgeons, however, will delay LSCT for LSCD unresponsive to medical therapy in the setting of OSSN until a patient has been recurrence-free for months or years. There have been several reports of early intervention for LSCD, including one case describing simultaneous OSSN excision at the limbus and SLET to prevent postoperative LSCD after nine clock hours of limbus were removed.<sup>8</sup> At two years of follow-up, the reported patient had no evidence of LSCD or recurrence of OSSN, but it should be noted that adjuvant MMC and radioactive plaque therapy were used after the initial surgery. Although early intervention may prevent complications of LSCD, introducing transplanted cell lines may add to diagnostic confusion of ocular surface changes and may further limit the ability to detect early recurrence of OSSN. The patient in the case presented here will require further monitoring and perhaps a repeat biopsy for more in-depth histopathologic analysis for neoplasia, given the recurrence of ocular surface irregularity. His complex clinical course serves as a reminder of the potential virulence of ocular surface squamous neoplasia and its complications. **REVIEW**

1. Shields JA, Shields CL, De Potter P. Surgical management of conjunctival tumors. *Arch Ophthalmol* 1997;115:6:808.
2. Kiire CA, Srinivasan S, Karp CL. Ocular surface squamous neoplasia. *Int Ophthalmol Clin* 2010;50:3:35-46.
3. Holcomb DJ, Lee G. Topical interferon alfa-2b for the treatment of recalcitrant ocular surface squamous neoplasia. *Am J Ophthalmol* 2006;142:4:568-571.
4. Karp CL, Moore JK, Rosa RH. Treatment of conjunctival and corneal intraepithelial neoplasia with topical interferon  $\alpha$ -2b1. *Ophthalmology* 2001;108:6:1093-1098.
5. Shields CL, Kaliki S, Kim HJ et al. Interferon for ocular surface squamous neoplasia in 81 cases: Outcomes based on the AJCC classification. *Cornea* 2013;32:3:248-256.
6. Kim BY, Riaz KM, Bakhtiari P, et al. Medically reversible limbal stem cell disease: Clinical features and management strategies. *Ophthalmology* 2014;121:10:2053-2058.
7. Jeng BH, Halfpenny CP, Meisler DM et al. Management of focal limbal stem cell deficiency associated with soft contact lens wear. *Cornea* 2011;30:1:18-23.
8. Mittal V, Narang P, Menon V, et al. Primary simple limbal epithelial transplantation along with excisional biopsy in the management of extensive ocular surface squamous neoplasia. *Cornea* 2016;35:12:1650-1652.



Local Eye Site  
JOBS IN EYE CARE

# Hiring Ophthalmic Staff?

More Ophthalmic  
Technicians Find Jobs On  
Local Eye Site Than  
Anywhere Else.

Save 20% with coupon code **REVOPH**

localeyesite.com



## REVIEW Advertising Index

**Akorn Pharmaceuticals** **18 A-H, 53**  
Phone (800) 932-5676  
www.akorn.com

**Alcon Laboratories** **21**  
Phone (800) 451-3937  
Fax (817) 551-4352

**Bausch + Lomb** **5, 47**  
Phone (800) 323-0000  
Fax (813) 975-7762

**Bio-Tissue, Inc.** **45**  
Phone (305) 412-4430  
Fax (305) 412-4429

**Bruder Ophthalmic Products** **49**  
Phone (888) 827-8337  
eyes@bruderophthalmic.com

**Compulink** **25**  
Phone (800) 456-4522  
www.compulinkadvantage.com

**Glaukos** **2**  
Phone (800) 452-8567  
www.glaukos.com

**Heidelberg Engineering** **55**  
Phone (800) 931-2230  
Fax (760) 598-3060

**Imprimis Pharmaceuticals, Inc.** **7**  
Phone (858) 704-4040  
Fax (858) 345-1745  
www.imprimispharma.com

**Johnson & Johnson Surgical Vision, Inc.** **11**  
https://surgical.jnjvision.com

**Katena** **13**  
Phone (800) 225-1195  
www.katena.com

**Keeler Instruments** **8**  
Phone (800) 523-5620  
Fax (610) 353-7814

**Lacrimedics, Inc** **51**  
Phone (800) 367-8327  
Fax (253) 964-2699  
info@lacrimedics.com  
www.lacrimedics.com

**NuSight Medical Operations** **15, 17**  
Phone (833) 468-5437  
www.NuSightMedical.com

**Oculus, Inc.** **29**  
Phone (888) 284-8004  
Fax (425) 867-1881

**Quidel** **43**  
Phone (800) 874-1517  
customerservice@quidel.com  
www.quidel.com

**Reliance Medical** **37**  
Phone (800) 735-0357  
Fax (513) 398-0256

**S4OPTIK** **33, 35**  
Phone (888) 224-6012

**Shire Ophthalmics** **67, 68**  
www.shire.com

**Topcon Medical Systems** **26-27**  
Phone (800) 223-1130  
Fax (201) 599-5250

**Varitronics** **6**  
Phone (800) 345-1244  
Fax (610) 356-1222

**Ziemer USA** **23**  
Phone (866) 708-4490  
www.ziemergroup.com

*This advertiser index is published as a convenience and not as part of the advertising contract. Every care will be taken to index correctly. No allowance will be made for errors due to spelling, incorrect page number, or failure to insert.*



## BRIEF SUMMARY:

Consult the Full Prescribing Information for complete product information.

## INDICATIONS AND USAGE

Xiidra® (lifitegrast ophthalmic solution) 5% is indicated for the treatment of the signs and symptoms of dry eye disease (DED).

## DOSAGE AND ADMINISTRATION

Instill one drop of Xiidra twice daily (approximately 12 hours apart) into each eye using a single-use container. Discard the single-use container immediately after using in each eye. Contact lenses should be removed prior to the administration of Xiidra and may be reinserted 15 minutes following administration.

## CONTRAINDICATIONS

Xiidra is contraindicated in patients with known hypersensitivity to lifitegrast or to any of the other ingredients in the formulation.

## ADVERSE REACTIONS

### Clinical Trials Experience

Because clinical studies are conducted under widely varying conditions, adverse reaction rates observed in clinical studies of a drug cannot be directly compared to rates in the clinical trials of another drug and may not reflect the rates observed in practice. In five clinical studies of dry eye disease conducted with lifitegrast ophthalmic solution, 1401 patients received at least 1 dose of lifitegrast (1287 of which received lifitegrast 5%). The majority of patients (84%) had  $\leq 3$  months of treatment exposure. 170 patients were exposed to lifitegrast for approximately 12 months. The majority of the treated patients were female (77%). The most common adverse reactions reported in 5-25 % of patients were instillation site irritation, dysgeusia and reduced visual acuity. Other adverse reactions reported in 1% to 5% of the patients were blurred vision, conjunctival hyperemia, eye irritation, headache, increased lacrimation, eye discharge, eye discomfort, eye pruritus and sinusitis.

### Postmarketing Experience

The following adverse reactions have been identified during postapproval use of Xiidra. Because these reactions are reported voluntarily from a population of uncertain size, it is not always possible to reliably estimate their frequency or establish a causal relationship to drug exposure.

Rare cases of hypersensitivity, including anaphylactic reaction, bronchospasm, respiratory distress, pharyngeal edema, swollen tongue, and urticaria have been reported. Eye swelling and rash have been reported.

## USE IN SPECIFIC POPULATIONS

### Pregnancy

There are no available data on Xiidra use in pregnant women to inform any drug associated risks. Intravenous (IV) administration of lifitegrast to pregnant rats, from pre-mating through gestation day 17, did not produce teratogenicity at clinically relevant systemic exposures. Intravenous administration of lifitegrast to pregnant rabbits during organogenesis produced an increased incidence of omphalocele at the lowest dose

tested, 3 mg/kg/day (400-fold the human plasma exposure at the recommended human ophthalmic dose [RHOD], based on the area under the curve [AUC] level). Since human systemic exposure to lifitegrast following ocular administration of Xiidra at the RHOD is low, the applicability of animal findings to the risk of Xiidra use in humans during pregnancy is unclear.

### Animal Data

Lifitegrast administered daily by intravenous (IV) injection to rats, from pre-mating through gestation day 17, caused an increase in mean preimplantation loss and an increased incidence of several minor skeletal anomalies at 30 mg /kg / day, representing 5,400-fold the human plasma exposure at the RHOD of Xiidra, based on AUC. No teratogenicity was observed in the rat at 10 mg /kg /day (460-fold the human plasma exposure at the RHOD, based on AUC ). In the rabbit, an increased incidence of omphalocele was observed at the lowest dose tested, 3 mg /kg /day (400-fold the human plasma exposure at the RHOD, based on AUC), when administered by IV injection daily from gestation days 7 through 19. A fetal No Observed Adverse Effect Level (NOAEL) was not identified in the rabbit.

### Lactation

There are no data on the presence of lifitegrast in human milk, the effects on the breastfed infant, or the effects on milk production. However, systemic exposure to lifitegrast from ocular administration is low. The developmental and health benefits of breastfeeding should be considered, along with the mother's clinical need for Xiidra and any potential adverse effects on the breastfed child from Xiidra.

### Pediatric Use

Safety and efficacy in pediatric patients below the age of 17 years have not been established.

### Geriatric Use

No overall differences in safety or effectiveness have been observed between elderly and younger adult patients.

## NONCLINICAL TOXICOLOGY

### Carcinogenesis, Mutagenesis, Impairment of Fertility

**Carcinogenesis:** Animal studies have not been conducted to determine the carcinogenic potential of lifitegrast.

**Mutagenesis:** Lifitegrast was not mutagenic in the *in vitro* Ames assay. Lifitegrast was not clastogenic in the *in vivo* mouse micronucleus assay. In an *in vitro* chromosomal aberration assay using mammalian cells (Chinese hamster ovary cells), lifitegrast was positive at the highest concentration tested, without metabolic activation.

**Impairment of fertility:** Lifitegrast administered at intravenous (IV) doses of up to 30 mg/kg/day (5400-fold the human plasma exposure at the recommended human ophthalmic dose (RHOD) of lifitegrast ophthalmic solution, 5%) had no effect on fertility and reproductive performance in male and female treated rats.



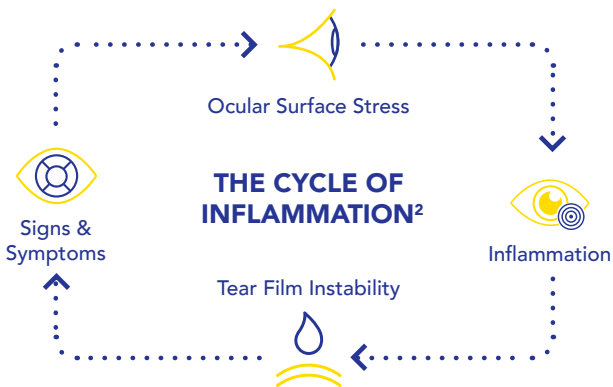
Manufactured for: Shire US Inc., 300 Shire Way, Lexington, MA 02421. For more information, go to [www.Xiidra.com](http://www.Xiidra.com) or call 1-800-828-2088. Marks designated ® and ™ are owned by Shire or an affiliated company. ©2018 Shire US Inc. SHIRE and the Shire Logo are trademarks or registered trademarks of Shire Pharmaceutical Holdings Ireland Limited or its affiliates. Patented: please see <https://www.shire.com/legal-notice/product-patents> Last Modified: 01/2018 S33769

# XIIDRA MAY INTERRUPT THE CYCLE OF INFLAMMATION CENTRAL TO DRY EYE DISEASE<sup>1</sup>

The exact mechanism of action of Xiidra in Dry Eye Disease is not known.<sup>1</sup>

**Xiidra blocks the interaction of ICAM-1 and LFA-1, which is thought to be a key mediator of the inflammation behind Dry Eye Disease.<sup>1</sup>**

*In vitro* studies have shown that Xiidra may inhibit the recruitment of previously activated T cells, the activation of newly recruited T cells, and the release of pro-inflammatory cytokines.<sup>1</sup>



.....  
[Check out Xiidra-ECP.com](http://Xiidra-ECP.com)  
.....

## Indication

Xiidra<sup>®</sup> (lifitegrast ophthalmic solution) 5% is indicated for the treatment of signs and symptoms of dry eye disease (DED).

## Important Safety Information

Xiidra is contraindicated in patients with known hypersensitivity to lifitegrast or to any of the other ingredients.

In clinical trials, the most common adverse reactions reported in 5-25% of patients were instillation site irritation, dysgeusia and reduced visual acuity. Other adverse reactions reported in 1% to 5% of the patients were blurred vision, conjunctival hyperemia, eye irritation, headache, increased lacrimation, eye discharge, eye discomfort, eye pruritus and sinusitis.

To avoid the potential for eye injury or contamination of the solution, patients should not touch the tip of the single-use container to their eye or to any surface.

Contact lenses should be removed prior to the administration of Xiidra and may be reinserted 15 minutes following administration.

Safety and efficacy in pediatric patients below the age of 17 years have not been established.

**For additional safety information, see accompanying Brief Summary of Safety Information on the adjacent page and Full Prescribing Information on Xiidra-ECP.com.**

## References:

1. Xiidra [Prescribing Information]. Lexington, MA: Shire US. 2. TFOS DEWS II Research Subcommittee. Report of the Research Subcommittee of the Tear Film & Ocular Surface Society Dry Eye Workshop II (2017). *Ocul Surf.* 2017;15(3):269-275.