

PROS AND CONS OF ONLINE VISION TESTS P. 19 • MID-YEAR CPT CODES P. 24
ELDERLY AND OHT: SHOULD YOU TREAT? P. 44 • SUCCEEDING WITH SCLERAL-SUTURED LENSES P. 48
ICRS AND CROSS-LINKING FOR ECTASIA P. 50 • WILLS RESIDENT CASE REPORT P. 63

REVIEW[®] of Ophthalmology

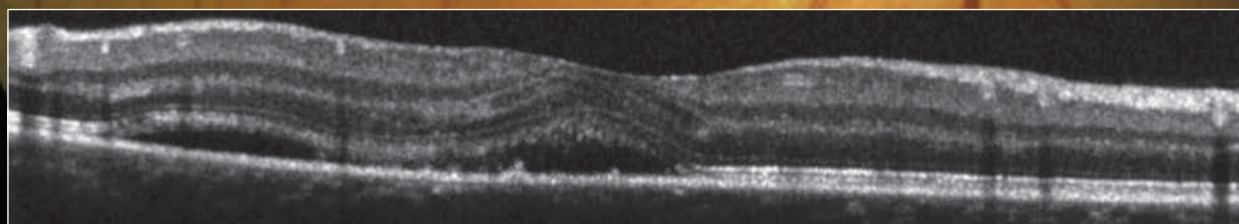
August 2018

reviewofophthalmology.com

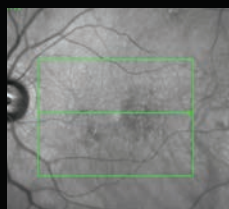ANNUAL RETINA ISSUE

OCT Before Cataract Surgery: Not Optional

OCT can catch retinal problems that will otherwise be blamed on your surgery, argues this surgeon. P. 32

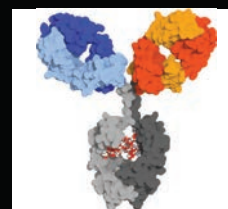


ALSO INSIDE:



Wet AMD: When
Your First-line Fails
P. 26

The nAMD
Pipeline: Full but
Not Fast **P. 38**





IMAGES THAT EMPOWER.



Welcome to a platform where every image is remarkably accurate. Reliably repeatable. Proven to enable confident clinical decision-making. And ready for the advanced image analytics necessary for success in a changing healthcare environment. It's a platform like none other. And now, one that's accessible for any practice.

Experience powerful images that empower you to do more for your patients and your practice. Experience Heidelberg Image Quality™.

To learn more, please call 800-931-2230 or visit [HeidelbergEngineering.com](https://www.HeidelbergEngineering.com)

New Guidelines for Cleaning Surgical Instruments

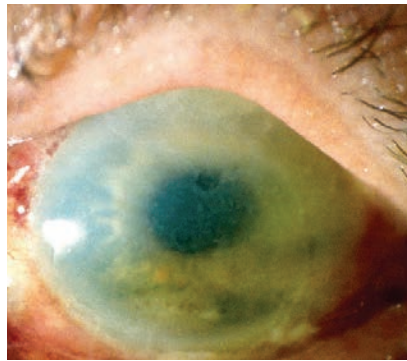
In the setting of cataract surgery, much attention is rightly paid to proper preoperative workup and postoperative care. Just as important, however, is the cleaning and sterilization of surgical instruments that go into the eye. Here, Nick Mamalis, MD, co-chair of the Ophthalmic Instrument Cleaning and Sterilization (OICS) Task Force, reviews the highlights of the comprehensive new “Guidelines for the Cleaning and Sterilization of Intraocular Surgical Instruments,” published in the *Journal of Cataract and Refractive Surgery*.¹

The OICS Task Force, chaired by David F. Chang, MD and Dr. Mamalis, consists of surgeons from three specialty organizations: ASCRS; the AAO; and the Ophthalmic Outpatient Surgical Society (OOSS).

Intraocular Tools are Different

Since the last specialty-specific guidelines for properly cleaning intraocular surgical tools were published in 2007, an update was necessary, according to Dr. Mamalis. “Our last guidelines were written almost 12 years ago, and so they were in need of updating,” he says. “What was also very important was the need to develop specialty-specific guidelines based on scientific evidence.”

The guidelines emphasize that best practices for sterilizing and cleaning surgical tools is not a one-size-fits-all proposition: Because intraocular procedures are generally quicker than



Nick Mamalis, MD

Even if bacteria are killed via sterilization, remnants of their tissue can cause toxic anterior segment syndrome.

general surgery, the surgical tools may be cleaned and reused more times per day than other instruments. Intraocular instruments are also typically much smaller than other tools. The authors add that although intraocular instruments don’t typically emerge from the eye with a large amount of tissue adherent to them, it only takes a little bit of residual tissue, OVD or enzymatic detergent to potentially cause a severe intraocular reaction, whereas similar exposures might not similarly affect other body parts.

Short-cycle Sterilization

Dr. Mamalis says that one important distinction set forth in the new guidelines clarifies that short-cycle sterilization of instruments is appropriate for intraocular surgical tools, and distinguishes the technique from a method used in emergent situations. “Some issues had come up because the Joint Commission, which does a

lot of the inspections and accreditations of ambulatory surgical centers, wanted to require that ophthalmic instruments be wrapped, put into the sterilizer for 45 minutes, which would mean it would take almost an hour per sterilization cycle in between uses. That would have huge consequences for surgical centers with high volume. You’d have to buy all kinds of additional instruments,” he explains.

“So we worked with the Joint Commission through the ASCRS and the AAO and we got them to modify their position to say that for ophthalmic instruments, the short cycle was safe,” he continues. “One of the first things that our task force did was set out to actually show that short-cycle steam sterilization used for sequential same-day ophthalmic surgery is safe and effective for killing bacteria. We designed a series of studies that looked at short-cycle steam sterilization of phacoemulsification handpieces. We used a standardized testing method to show that it did indeed adequately kill bacteria, by contaminating each handpiece with a specific amount of bacteria and testing them under specific conditions to show that the short-cycle steam sterilizations are adequate and safe. The results of these studies will be published in *Ophthalmology*.² Then we incorporated these results into the guidelines. I think that it was very important to actually use a scientific method and to put it into our guidelines.”

“Short-cycle sterilization for a contained or wrapped load is appropriate for sequential same-day instrument

use,” the new guidelines state. The guidelines also stipulate that the transit time of unwrapped instruments emptied from the sterilizer should be three minutes or less.

Additionally, the OICS Task Force has clarified that short-cycle steam sterilization is distinct from immediate-use steam sterilization (formerly called “flash” sterilization), a method used when a necessary instrument lands on the floor in the middle of a case, for instance. “We wanted to make clear to CMS that our short-cycle steam sterilization is something that is legitimate for ophthalmic surgical instruments, in that it is not the same as immediate-use sterilization,” explains Dr. Mamalis.

Enzymatic Cleaners

“Although the enzymatic detergents can remove tissue burden from instruments, if there’s any residue of the enzymatic detergent left on the instruments, it can actually cause toxic anterior segment syndrome, or TASS,” says Dr. Mamalis. “So we wanted to be very careful when we wrote these guidelines to make it clear that ophthalmic instruments should not routinely be subject to the use of enzymatic detergents. But we needed to back up our recommendations with scientific evidence.” They did so by conducting a study at the Moran Eye Center that was funded through a grant from ASCRS, which demonstrated that phaco tips rinsed thoroughly in accordance with manufacturer instructions can still harbor enzymatic detergent residue detectable via

Correction

In June’s Glaucoma Management, a layout error caused some of the text to be obscured by graphical elements on the page. To read the full text as intended, please see the version of the article on our website at reviewofophthalmology.com. Review regrets the error.

scanning electron microscopy and energy dispersive X-ray spectroscopy.³ “Then we went further and did a study in an animal model that showed that these residues could cause TASS,”⁴ says Dr. Mamalis.

“Though enzymatic detergents can remove tissue burden from instruments, if there’s any residue of the detergent left on the instruments, it can actually cause TASS.”
— Nick Mamalis, MD

In light of the study results, the new guidelines state, “It is our position that if intraocular instruments are thoroughly rinsed with critical water promptly after each use, the routine use of enzyme detergents is unnecessary and should not be required for routine decontamination of ophthalmic intraocular instruments.”

CMS, however, still insists that surgical facilities follow the manufacturers’ instructions for use (IFU) if they still require the use of enzymatic detergents. “The issue that’s come up since we’ve put out these guidelines is that if the manufacturer’s IFU states specifically that you have to use enzymatic detergents, CMS says we still have to follow those,” Dr. Mamalis explains, adding that the Task Force is engaging with other stakeholders to try to change this. “We have met with the manufacturers of the ophthalmic instruments we use to try to work with them to change their IFUs to make it so that enzymatic detergents aren’t

mandatory. We actually had a meeting with industry just this year during the spring ASCRS meeting. They responded very positively. We’re continuing to work with industry to try to update the instructions for use. We’re also going to meet again at the AAO meeting in Chicago this fall,” he says.

Ultrasound Options

Ultrasonic cleaners are another possible contamination point, according to the task force. “The issues arise when an ultrasound bath is not drained and thoroughly wiped down and cleaned between each use,” Dr. Mamalis explains. “A small amount of bacteria can remain within the ultrasound bath; they’re just filled with city tap water and even though it’s safe to drink, there are still minute amounts of bacteria in there. If you let those grow in a warm ultrasound bath for a period of time, there might be enough present that even if we put our instruments through the autoclave to kill bacteria, a heat-stable endotoxin from the bacterial cell wall can cause not an infection, but TASS.

“Therefore, one of the things that we really wanted to stress in our guidelines was that you shouldn’t need to use an ultrasound bath or enzymatic detergents if you adequately flush out and clean your instruments at the conclusion of the previous case,” he continues.

Greener, Leaner Choices

“Climate change, or global warming, is a serious public health concern, and the health-care industry is a major source of emissions, responsible for 10 percent of the total carbon footprint of the United States,” the authors write in the new guidelines. They also estimate that phaco in the U.K. emits as much CO₂ as driving an American car 340 miles, with most of the environmental impact attributable to single-use supplies. To that end, the new guidelines give surgeons the latitude to inspect

ILUVIEN[®]
(fluocinolone acetonide
intraocular implant) 0.19mg

REAL-WORLD RESULTS WITH ILUVIEN

CONTINUOUS MICRODOSING | CONSISTENT TREATMENT

Learn more at ILUVIEN.com



ILUVIEN[®] is a CONTINUOUS MICRODOSING™ Delivery System specifically engineered for the treatment of DME in patients who have been previously treated with a course of corticosteroids and did not have a clinically significant rise in intraocular pressure.

In pivotal studies, ILUVIEN demonstrated efficacy in visual acuity through 24 months (primary endpoint), which was sustained for up to 36 months.^{1,2,3}

Adverse reactions in the ILUVIEN Phase 3 clinical trials were consistent with other corticosteroid treatments.¹

INDICATION

ILUVIEN[®] (fluocinolone acetonide intraocular implant) 0.19 mg is indicated for the treatment of diabetic macular edema (DME) in patients who have been previously treated with a course of corticosteroids and did not have a clinically significant rise in intraocular pressure.

IMPORTANT SAFETY INFORMATION

Contraindications

- ILUVIEN is contraindicated in patients with active or suspected ocular or periocular infections including most viral diseases of the cornea and conjunctiva including active epithelial herpes simplex keratitis (dendritic keratitis), vaccinia, varicella, mycobacterial infections and fungal diseases.
- ILUVIEN is contraindicated in patients with glaucoma who have cup to disc ratios of greater than 0.8.
- ILUVIEN is contraindicated in patients with known hypersensitivity to any components of this product.

Warnings and Precautions

- Intraocular injections, including those with ILUVIEN, have been associated with endophthalmitis, eye inflammation, increased intraocular pressure, and retinal detachments. Patients should be monitored following the intraocular injection.
- Use of corticosteroids including ILUVIEN may produce posterior subcapsular cataracts, increased intraocular pressure and glaucoma. Use of corticosteroids may enhance the establishment of secondary ocular infections due to bacteria, fungi, or viruses. Corticosteroids are not recommended to be used in patients with a history of ocular herpes simplex because of the potential for reactivation of the viral infection.
- Patients in whom the posterior capsule of the lens is absent or has a tear are at risk of implant migration into the anterior chamber.

Adverse Reactions

- In controlled studies, the most common adverse reactions reported were cataract development (ILUVIEN 82%; sham 50%) and intraocular pressure elevation of ≥ 10 mm Hg (ILUVIEN 34%; sham 10%).

Please see Brief Summary of Full Prescribing Information on the following page.

1. Iluvien [package insert]. Alpharetta, GA: Alimera Sciences, Inc; 2014. 2. Campochiaro PA, Brown DM, Pearson A, et al. Long-term benefit of sustained delivery fluocinolone acetonide vitreous inserts for diabetic macular edema. *Ophthalmology*. 2011;118(4):626-635.e2. 3. Campochiaro PA, Brown DM, Pearson A, et al. Sustained delivery fluocinolone acetonide vitreous inserts provide benefit for at least 3 years in patients with diabetic macular edema. *Ophthalmology*. 2012;119(10):2125-2132.

CONTINUOUS MICRODOSING is a trademark of Alimera Sciences, Inc. Copyright © 2018 Alimera Sciences, Inc. All rights reserved. ILUVIEN is a registered trademark of Alimera Sciences, Inc. 1-844-445-8843. Printed in USA. US-ILV-MMM-0560. 03/2018

ALIMERA
SCIENCES

6120 Windward Parkway
Alpharetta, GA 30005
www.alimerasciences.com

BRIEF SUMMARY OF FULL PRESCRIBING INFORMATION

ILUVIEN® (fluocinolone acetonide intravitreal implant) 0.19 mg
For Intravitreal Injection

INDICATIONS AND USAGE

ILUVIEN® (fluocinolone acetonide intravitreal implant) 0.19 mg is indicated for the treatment of diabetic macular edema in patients who have been previously treated with a course of corticosteroids and did not have a clinically significant rise in intraocular pressure.

CONTRAINDICATIONS

Ocular or Periocular Infections: ILUVIEN is contraindicated in patients with active or suspected ocular or periocular infections including most viral disease of the cornea and conjunctiva including active epithelial herpes simplex keratitis (dendritic keratitis), vaccinia, varicella, mycobacterial infections and fungal diseases.

Glaucoma: ILUVIEN is contraindicated in patients with glaucoma, who have cup to disc ratios of greater than 0.8.

Hypersensitivity: ILUVIEN is contraindicated in patients with known hypersensitivity to any components of this product.

WARNINGS AND PRECAUTIONS

Intravitreal Injection-related Effects: Intravitreal injections, including those with ILUVIEN, have been associated with endophthalmitis, eye inflammation, increased intraocular pressure, and retinal detachments. Patients should be monitored following the intravitreal injection.

Steroid-related Effects: Use of corticosteroids including ILUVIEN may produce posterior subcapsular cataracts, increased intraocular pressure and glaucoma. Use of corticosteroids may enhance the establishment of secondary ocular infections due to bacteria, fungi, or viruses.

Corticosteroids are not recommended to be used in patients with a history of ocular herpes simplex because of the potential for reactivation of the viral infection.

Risk of Implant Migration: Patients in whom the posterior capsule of the lens is absent or has a tear are at risk of implant migration into the anterior chamber.

ADVERSE REACTIONS

Clinical Studies Experience: Because clinical trials are conducted under widely varying conditions, adverse reaction rates observed in the clinical trials of a drug cannot be directly compared to rates in the clinical trials of another drug and may not reflect the rates observed in practice.

Adverse reactions associated with ophthalmic steroids including ILUVIEN include cataract formation and subsequent cataract surgery, elevated intraocular pressure, which may be associated with optic nerve damage, visual acuity and field defects, secondary ocular infection from pathogens including herpes simplex, and perforation of the globe where there is thinning of the cornea or sclera.

ILUVIEN was studied in two multicenter, randomized, sham-controlled, masked trials in which patients with diabetic macular edema were treated with either ILUVIEN (n=375) or sham (n=185). Table 1 summarizes safety data available when the last subject completed the last 36-month follow up visit for the two primary ILUVIEN trials. In these trials, subjects were eligible for retreatment no earlier than 12 months after study entry. Over the three-year follow up period, approximately 75% of the ILUVIEN treated subjects received only one ILUVIEN implant.

Table 1: Ocular Adverse Reactions Reported by ≥1% of Patients and Non-ocular Adverse Reactions Reported by ≥5% of Patients

Adverse Reactions	ILUVIEN (N=375) n (%)	Sham (N=185) n (%)
Ocular		
Cataract ¹	192/235 ² (82%)	61/121 ² (50%)
Myodesopsia	80 (21%)	17 (9%)
Eye pain	57 (15%)	25 (14%)
Conjunctival haemorrhage	50 (13%)	21 (11%)
Posterior capsule opacification	35 (9%)	6 (3%)
Eye irritation	30 (8%)	11 (6%)
Vitreous detachment	26 (7%)	12 (7%)
Conjunctivitis	14 (4%)	5 (3%)
Corneal oedema	13 (4%)	3 (2%)
Foreign body sensation in eyes	12 (3%)	4 (2%)
Eye pruritus	10 (3%)	3 (2%)
Ocular hyperaemia	10 (3%)	3 (2%)
Optic atrophy	9 (2%)	2 (1%)
Ocular discomfort	8 (2%)	1 (1%)
Photophobia	7 (2%)	2 (1%)
Retinal exudates	7 (2%)	0 (0%)
Anterior chamber cell	6 (2%)	1 (1%)
Eye discharge	6 (2%)	1 (1%)

Table 1 (continued)

Adverse Reactions	ILUVIEN (N=375) n (%)	Sham (N=185) n (%)
Non-ocular		
Anemia	40 (11%)	10 (5%)
Headache	33 (9%)	11 (6%)
Renal failure	32 (9%)	10 (5%)
Pneumonia	28 (7%)	8 (4%)

¹ Includes cataract, cataract nuclear, cataract subcapsular, cataract cortical and cataract diabetic in patients who were phakic at baseline. Among these patients, 80% of ILUVIEN subjects vs. 27% of sham-controlled subjects underwent cataract surgery.

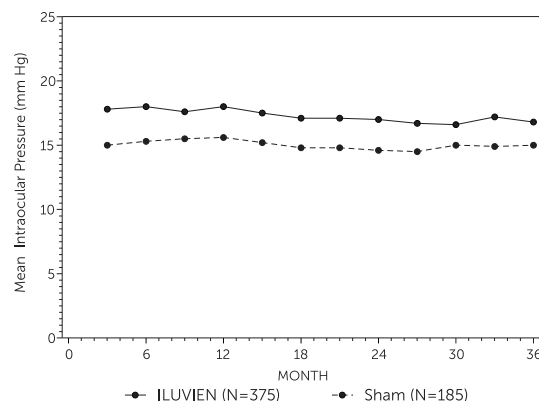
² 235 of the 375 ILUVIEN subjects were phakic at baseline; 121 of 185 sham-controlled subjects were phakic at baseline.

Increased Intraocular Pressure

Table 2: Summary of Elevated IOP-Related Adverse Reactions

Event	ILUVIEN (N=375) n (%)	Sham (N=185) n (%)
Non-ocular		
IOP elevation ≥ 10 mm Hg from baseline	127 (34%)	18 (10%)
IOP elevation ≥ 30 mm Hg	75 (20%)	8 (4%)
Any IOP-lowering medication	144 (38%)	26 (14%)
Any surgical intervention for elevated intraocular pressure	18 (5%)	1 (1%)

Figure 1: Mean IOP during the study



Cataracts and Cataract Surgery

At baseline, 235 of the 375 ILUVIEN subjects were phakic; 121 of 185 sham-controlled subjects were phakic. The incidence of cataract development in patients who had a phakic study eye was higher in the ILUVIEN group (82%) compared with sham (50%). The median time of cataract being reported as an adverse event was approximately 12 months in the ILUVIEN group and 19 months in the sham group. Among these patients, 80% of ILUVIEN subjects vs. 27% of sham-controlled subjects underwent cataract surgery, generally within the first 18 months (Median Month 15 for both ILUVIEN group and for sham) of the studies.

Postmarketing Experience: The following reactions have been identified during post-marketing use of ILUVIEN in clinical practice. Because they are reported voluntarily, estimates of frequency cannot be made. The reactions, which have been chosen for inclusion due to either their seriousness, frequency of reporting, possible causal connection to ILUVIEN, or a combination of these factors, include reports of drug administration error and reports of the drug being ineffective.

USE IN SPECIFIC POPULATIONS

Pregnancy: Pregnancy Category C.

There are no adequate and well-controlled studies of ILUVIEN in pregnant women. Animal reproduction studies have not been conducted with fluocinolone acetonide. Corticosteroids have been shown to be teratogenic in laboratory animals when administered systemically at relatively low dosage levels. ILUVIEN should be used during pregnancy only if the potential benefit justifies the potential risk to the fetus.

Nursing Mothers: Systemically administered corticosteroids are present in human milk and could suppress growth and interfere with endogenous corticosteroid production. The systemic concentration of fluocinolone acetonide following intravitreal treatment with ILUVIEN is low. It is not known whether intravitreal treatment with ILUVIEN could result in sufficient systemic absorption to produce detectable quantities in human milk. Exercise caution when ILUVIEN is administered to a nursing woman.

Pediatric Use: Safety and effectiveness of ILUVIEN in pediatric patients have not been established.

Geriatric Use: No overall differences in safety or effectiveness have been observed between elderly and younger patients.

phaco tips and reuse them per their best clinical judgment.

“This is an interesting new area,” says Dr. Mamalis. He cites the example of India’s Aravind Eye Care System, which reported an endophthalmitis rate of 0.02 percent in 555,550 consecutive cataract surgeries where patients received intracameral and topical antibiotic prophylaxis.^{5,6,7} The authors of the new guidelines note that doctors and staff at Aravind Eye Hospitals don’t re-scrub or change their gowns and gloves after every case, and surgeries are performed simultaneously with other cases in a single room. These are examples of “numerous practices that would be forbidden in any licensed North American surgical facility,” the guidelines state. The authors say that Aravind’s endophthalmitis rates are statistically identical to those extrapolated from the 2014 OOSS survey of ASCs in the United States.

“This is a new area of study and that’s why we wanted to include it in our guidelines,” Dr. Mamalis says. “We wanted to raise awareness among surgeons but also among regulatory bodies, that we can still be safe and avoid problems with infections and endophthalmitis without using so many resources.”

Dr. Mamalis acknowledges that both individual surgeons and their institutions are constrained by rules and regulations, but thinks the new guidelines provide food for thought about decreasing waste. “An individual surgeon can’t really make changes or take shortcuts,” he says. “This is where our guidelines come in: We can now provide the surgeon and the surgery center with some guidelines that will help them stay compliant and safe from difficulties with regulators if they follow them. But we can also provide surgeons and surgery centers with enough information to see if they can make some new decisions on how to use their resources.

“What’s paramount is that patients’ safety always stays at the top,” Dr. Ma-

malis continues. “If it’s been shown that we don’t compromise patient safety by being more efficient and eliminating some steps, then that’s something we wanted to raise in these guidelines. We want to make both surgeons and regulatory agencies aware that these are issues that should be considered.”

1. Chang DF, Mamalis N, Ophthalmic Instrument and Cleaning Sterilization Task Force. Guidelines for the cleaning and sterilization of intraocular surgical instruments. *J Cat Refract Surg* 2018;44:6:765-73.
2. Chang DF, Hurley N, Mamalis N, Whitman J. Evaluation of ophthalmic surgical instrument sterility using short-cycle sterilization for sequential same-day use. *Ophthalmol* 2018;125: in press.
3. Tsaousis KT, Werner L, Reiter N, et al. Comparison of different types of phacoemulsification tips. II: Morphological alterations induced by multiple steam sterilization cycles with and without use of enzyme detergent. *J Cat Refract Surg* 2016;42:1353-60
4. Mamalis N. Toxic anterior segment syndrome: role of enzymatic detergents used in the cleaning of intraocular surgical instruments (editorial). *J Cat Refract Surg* 2016;42:1249-50.
5. HariPriya A, Chang DF, Ravindran RD. Endophthalmitis reduction with intracameral moxifloxacin prophylaxis: An analysis of 600,000 surgeries. *Ophthalmology* 2017;124:768-775.
6. Chang DF, HariPriya A, Ravindran RD. Reply to letter RE: Endophthalmitis reduction with intracameral moxifloxacin prophylaxis: An analysis of 600,000 surgeries. *Ophthalmology* 2017;124:e78-e79. Available at: [http://www.aajournal.org/article/S0161-6420\(17\)30748-0/pdf](http://www.aajournal.org/article/S0161-6420(17)30748-0/pdf). Accessed July 15, 2018
7. HariPriya A, Chang DF. Intracameral antibiotics during cataract surgery: evidence and barriers. *Curr Opin Ophthalmol* 2018; 29:33-39.

CMS Proposes Changes

Last month, the Centers for Medicare & Medicaid Services issued a proposed rule that includes changes to many of the policies that currently govern reimbursement and how measurements of quality are made. Some of the proposed changes include alterations to evaluation and management policies in an effort to “reduce administrative burden and improve payment accuracy for E/M visits.”

Among other things, CMS proposes:

- to allow practitioners to choose to document office/outpatient E/M visits using medical decision-making or time instead of applying the current 1995 or 1997 E/M documentation guidelines, or, alternatively, practitioners could

continue using the current framework;

- to expand current options by allowing practitioners to use time as the governing factor in selecting visit level and documenting the E/M visit, regardless of whether counseling or care coordination dominate the visit;

- to expand current options regarding the documentation of history and exam, to allow practitioners to focus their documentation on what has changed since the last visit or on pertinent items that have not changed, rather than re-documenting information, provided they review and update the previous information; and

- to allow practitioners to review and verify certain information in the medical record that is entered by ancillary staff or the beneficiary, rather than re-entering it.

CMS is also proposing to allow physicians to be reimbursed for brief consultations via a telecommunication device to help decide if an office visit is necessary. Physicians would also be paid for reviewing photos or videos submitted by patients.

CMS also wants to “help curb excessive spending” on Part B drugs by changing the add-on amount that’s applied to the medications. The agency explains that many Part B drug payments are based on an average sales price methodology and, by statute, include an add-on payment of 6 percent of the ASP amount. Other Part B drug payments, though, are based on the wholesale acquisition cost, such as for single-source drugs that don’t have ASP data. CMS proposes that WAC-based payments for new Part B drugs have an add-on of just 3 percent rather than the 6 percent currently used during the first quarter of sales when the ASP is unavailable.

For a complete rundown of the proposed Medicare payment changes, visit <https://www.cms.gov/Newsroom/MediaReleaseDatabase/Fact-sheets/2018-Fact-sheets-items/2018-07-12-2.html>. **REVIEW**

Investment Opportunities: Due Diligence and Key Elements of the Pitch

In prior columns, we've covered a broad range of topics geared towards the physician-entrepreneur that are specific to product development and business deals. Today, more physicians are getting involved as investors. But whether one is evaluating an opportunity to invest in, or is involved in a new company for which they're seeking investors, there's a standard playbook for conducting due diligence on a new opportunity. The series of questions you consider when evaluating a new investment is similar to those you can expect an independent investor to ask you when you're developing your new company, and thus they're important to consider when developing a pitch for acquiring funds.

Over the years, we've seen a large number of opportunities, some of which fall under the heading of, "great idea, but wrong people to execute it and get a return on investment," and some under the heading of, "great people, but not the best idea for driving an investment return." We've also seen companies funded with seed capital from physician-investors, as well as those that reach pivotal clinical studies that are funded completely by individual angel investors, a large number of which are physicians. Doing your due diligence (specifically, performing a critical review of the clinical, regulatory, nonclinical, commercial and business components of a new opportunity), and having a solid list of questions, are critical in order to objectively evaluate a project that's seeking investment or collaboration from your colleagues, friends and/or family.

Here, we summarize a number of critical considerations we've learned by working with physician-entrepreneurs on their positioning, supporting due diligence on new projects and listening to feedback from investors and partners.

When evaluating an investment, or doing your due diligence, the main questions to ask are: What's the time to value creation? What's the cost of investment? What's the risk (i.e., the likelihood that this project converts to value and a return on invest-

ment)? The pitch needs to articulate how a project can most rapidly demonstrate its potential and fit in the product landscape, justify further investment and create value for the investor. Also, consider whether the proposed team leading the project is actually the best team for reaching all of the crucial development milestones.

Target Product Profile

Proper diligence (if you're evaluating an investment) or positioning of a pitch (if you're soliciting investment in your project), ultimately tie back to the target product profile, which sits at the intersection of regulatory strategy and clinical, nonclinical and commercial elements. Navigating this intersection requires insights into each of these areas. And, if you're making the pitch, the key is translating your insights into these areas into a message that's understand-



able, and differentiating yourself from other groups' ideas in a way that resonates with investors. Ultimately, you want to answer such questions as: Is the product safe? Can it be manufactured? Does it meet the level of clinical efficacy required? And, beyond just achieving regulatory approval, will the TPP support reimbursement for users of the product, and a commercial strategy that will drive a successful exit from the investment?

Define the Market

Defining the potential market for the product in development requires understanding not only the total market, but the addressable market: That's the basis of proper market modeling. What market segment is this product specifically targeting and how much of it can one expect to capture? This generally isn't 100 percent of the addressable market. Pitches that are realistic in terms

of the addressable market, and consider its unmet needs and the niche into which a product fits, demonstrate an appropriate level of thought and market understanding. Part of this assessment needs to consider the current alternatives to the proposed product, and whether, for example, the benefits of the new product outweigh the lower cost of a generic that's already entrenched in the market (even if the generic may have a slightly inferior efficacy profile).

It's important to consider not only those products already approved and marketed, but those in the pipeline, particularly those in the late trial stages or which may be in the market ahead of the product you're thinking of investing in or developing. The key is finding what differentiates your product from those others, and clearly positioning your product appropriately based on that. It's important to determine if that differentiation is large enough to drive the use of the product by end users, be they patients or eye-care professionals. For example, is it a product with solid clinical data but that, unfortunately, doesn't fill an unmet need from the physician's perspective? Such a competitive analysis should clearly demonstrate that there's both a clinical and a market unmet need for the product, and that it has commercial viability commensurate to the size of the investment.

Product and Development Pathway

It's important that you give investors a "reason to believe," a development term that describes having confidence in the product's mechanism of action and preclinical/early clinical data, as well as other data that supports that the product is likely to work, de-risks the program, differentiates it from other products, and promotes its potential adoption in the marketplace.

We've written many prior columns in this series about specific areas of development, such as chemistry, manufacturing and controls; pre-IND meetings with the FDA; indications; and elements of the TPP, so we won't go into further detail about those. The key to remember, though, is that each of these areas of development is a critical consideration for determining the TPP, defining differentiation and assessing technical

risk. Here are a couple prominent points to consider, based on recent product pitches we've heard:

- **CMC.** There needs to be (or needs to be a plan for) a stable formulation that will be comfortable if dosed locally. We have seen situations when small-lab batches that were assumed to be scalable and stable had issues when the process was scaled up, or they couldn't tolerate sterilization or weren't stable with validated methods. The importance of this area cannot be underestimated.


- **Regulatory.** Remember, when filing an IND, regulatory agencies are most concerned with safety. Generally speaking, the sponsor is free to select the endpoints that it feels best demonstrate proof-of-concept and reason to believe in the Phase II trial, but these may not necessarily be the endpoints accepted by regulatory agencies for Phase III to support registration. Particularly for the new physician-investor who may not be well-versed in regulatory science, be wary of claims in pitches that FDA has "accepted" exploratory endpoints at pre-IND meetings for Phase II studies, unless those endpoints are verified to be acceptable for Phase III.

- **Indication selection.** Often, where one specific indication is suitable for a larger target market, developers may select an indication with a smaller market as the lead indication due to shorter clinical-regulatory timelines, lower risk or other considerations. In some situations, this is smart when considering the time and cost to get the product to clinical proof-of-concept, define dose ranging, or achieve registration. In other cases, however, be mindful of how your ultimate partners will view the lead indication: Will they value the project based on just the smaller market, or consider the broader potential use in their valuation? Also consider how this smaller-market indication will impact user reimbursement out of the gate once it's approved. You can't blithely assume there will be off-label usage and simply incorporate that as part of the proposed model.


Intellectual Property

Proper IP due diligence is paramount to the business pitch. A great idea that fills an unmet need and has a well-defined development pathway won't gain a return on investment if it can't be sufficiently protected in the market. For some products, protection may rest simply on regulatory market exclusivity and a technical hurdle; for others the product may be protected by a broad estate of patents. While engaging a patent attorney

is always advisable, performing preliminary patent searches to assess patentability (e.g., is there prior art for what you're proposing?) and freedom to operate (FTO) should be performed as initial gut checks. Discovering existing IP in and of itself may not be a negative; perhaps there is opportunity to license new IP in order to broaden your protection. But remember that getting a patent granted is not the end game. It's all about the patent being protected against potential litigation in the future from competitors.



A great idea that fills an unmet need and has a well-defined development pathway won't gain a return on investment if it can't be sufficiently protected in the market.



While the United States, Europe and Japan are generally the leading markets in the world, it's inevitable that an entrepreneur or new company will have to decide what to do with IP in other regions, and whether or not to keep paying the legal fees necessary to maintain a presence in those territories. Early on, prior to larger funding, this decision may have to be made based on cost. But keep in mind that even if certain countries won't be expected to significantly impact a deal with a global pharmaceutical company, it may impact the ability to pursue regional deals that can serve as options for non-dilutive capital (i.e., investment that doesn't require selling shares of the company) during the program. At the very least, this should be a topic of discussion when planning IP strategy.

Investment Needs

It goes without saying that a business plan pitch needs to have clarity about the size of the investment. But there's a range of ways we've seen this presented. For the investment proposal to be understood, the pitch

should include the total budget for R&D and other activities/overhead necessary to get to the value inflection; the specific time period over which this will occur; and the time and cost needed to reach specific milestones. It's about balancing risk and reward, so the last component, the time and cost to specific steps which de-risk the program, is key. For example, is there a definable animal study, or formulation stability study, that de-risks the program early, before a company moves to the next stage of investment? What are the reasonable, definable stages (or tranches) that can be incorporated into the funding plan to balance different inflection points?

Exit Strategy

While situations may often change, it's important to clearly articulate the exit strategy, namely at which points there are key value inflections in the program where the chance for a corporate pharma deal or going public is highest. Aside from that, there also may be different scenarios in which the company can attract new investors and funds.

In some cases, there may be some interest from companies in partnering with you based on early preclinical data, but in others, even a single successful, well-controlled Phase II clinical trial may not be sufficient, and companies may desire to see confirmatory follow-up studies. Keep this in mind when assessing an opportunity or building the pitch. Have plans for how any follow-up work can be funded. Early dialogue with potential exit partners helps to inform this process and the development of your overall strategy.

In conclusion, the process of performing proper due diligence, or creating a pitch, is multifactorial. There need to be unique points of differentiation between the product in question and its competitors that can be communicated in a clear manner and which demonstrate a high likelihood that the project will succeed. We hope this brief article helps to highlight a few pearls on the thought process involved in reviewing and/or presenting a specific business opportunity, and spurs deeper thought on the primary elements involved in assessing a potential product.

Mr. Chapin is senior vice president of corporate development, and Mr. Abelson is president & CEO, at the consulting firm Ora Inc. The authors welcome your comments or questions regarding product development. Please send correspondence to mchapin@oraclinical.com or visit www.oraclinical.com.

CONTRIBUTORS

CHIEF MEDICAL EDITOR

Mark H. Blecher, MD

CONTACT LENSES

Penny Asbell, MD

CORNEA / ANTERIOR SEGMENT

Thomas John, MD

GLAUCOMA MANAGEMENT

Peter Netland, MD, PHD
Kuldev Singh, MD

MEDICARE Q & A

Paul M. Larson, MBA

PEDIATRIC PATIENT

Wendy Huang, MD

PLASTIC POINTERS

Ann P. Murchison, MD, MPH

REFRACTIVE/CATARACT ROUNDOFF

Arturo S. Chayet, MD

RETINAL INSIDER

Carl Regillo, MD, FACS
Emmett T. Cunningham Jr., MD, PHD, MPH

TECHNOLOGY UPDATE

Steven T. Charles, MD
Michael Colvard, MD

WILLS RESIDENT CASE SERIES

Thomas Jenkins, MD

ADVISORY BOARD

PENNY A. ASBELL, MD, NEW YORK CITY

WILLIAM I. BOND, MD, PEKIN, ILL.

ALAN N. CARLSON, MD, DURHAM, N.C.

Y. RALPH CHU, MD, EDINA, MINN.

ADAM J. COHEN, MD, DOWNERS GROVE, ILL.

UDAY DEVGAN, MD, FACS, LOS ANGELES

ERIC DONNENFELD, MD, ROCKVILLE CENTRE, N.Y.

DANIEL S. DURRIE, MD, KANSAS CITY, MO.

ROBERT EPSTEIN, MD, MCHENRY, ILL.

ROBERT D. FECHTNER, MD, NEWARK, N.J.

WILLIAM J. FISHKIND, MD, TUCSON, ARIZ.

JAMES P. GILLS, MD, TARPON SPRINGS, FLA.

HARRY GRABOW, MD, SARASOTA, FLA.

DOUGLAS K. GRAYSON, MD, NEW YORK CITY

THOMAS S. HARBIN, MD, MBA, ATLANTA

DAVID R. HARDTEN, MD, MINNEAPOLIS

KENNETH J. HOFFER, MD, SANTA MONICA, CALIF.

JACK T. HOLLADAY, MD, MSEE, HOUSTON

JOHN D. HUNKELER, MD, KANSAS CITY, MO.

THOMAS JOHN, MD, TINLEY PARK, ILL.

ROBERT M. KERSHNER, MD, MS, FACS, BOSTON

GUY M. KEZIRIAN, MD, PARADISE VALLEY, ARIZ.

TERRY KIM, MD, DURHAM, N.C.

TOMMY KORN, MD, SAN DIEGO

DAVID A. LEE, MD, HOUSTON

FRANCIS S. MAH, MD, PITTSBURGH

NICK MAMALIS, MD, SALT LAKE CITY

WILLIAM G. MARTIN, MD, OREGON, OHIO

MIKE S. MCFARLAND, MD, PINE BLUFF, ARK.

JEFFREY B. MORRIS, MD, MPH, ENCINITAS, CALIF.

MARLENE R. MOSTER, MD, PHILADELPHIA

ROBERT J. NOECKER, MD, FAIRFIELD, CONN.

ROBERT OSHER, MD, CINCINNATI

MARK PACKER, MD, BOULDER, CO.

STEPHEN PASCUCCI, MD, BONITA SPRINGS, FLA.

PAUL PENDER, MD, BEDFORD, N.H.

CHRISTOPHER J. RAPUANO, MD, PHILADELPHIA

AUGUST READER III, MD, SAN FRANCISCO

TONY REALINI, MD, MORGANTOWN, W.V.

KENNETH J. ROSENTHAL, MD, GREAT NECK, N.Y.

ERIC ROTHCHILD, MD, DELRAY BEACH, FLA.

SHERI ROWEN, MD, BALTIMORE

JAMES J. SALZ, MD, LOS ANGELES

INGRID U. SCOTT, MD, MPH, HERSHEY, PA.

JOEL SCHUMAN, MD, PITTSBURGH

GAURAV SHAH, MD, ST. LOUIS

DAVID R. STAGER JR., MD, DALLAS

KARL STONECIPHER, MD, GREENSBORO, N.C.

JAMES C. TSAI, MD, NEW YORK CITY

VANCE THOMPSON, MD, SIOUX FALLS, S.D.

FARRELL C. TYSON, MD, CAPE CORAL, FLA.

R. BRUCE WALLACE III, MD, ALEXANDRIA, LA.

ROBERT G. WILEY, MD, CLEVELAND

FRANK WEINSTOCK, MD, CANTON, OHIO

BUSINESS OFFICES

11 CAMPUS BOULEVARD, SUITE 100
NEWTOWN SQUARE, PA 19073
SUBSCRIPTION INQUIRIES (877) 529-1746
(USA ONLY); OUTSIDE USA, CALL (847) 763-9630

BUSINESS STAFF

PUBLISHER

JAMES HENNE

(610) 492-1017 JHENNE@JOBSON.COM

REGIONAL SALES MANAGER

MICHELE BARRETT

(610) 492-1014 MBARRETT@JOBSON.COM

REGIONAL SALES MANAGER

MICHAEL HOSTER

(610) 492-1028 MHOSTER@JOBSON.COM

CLASSIFIED ADVERTISING

(888)-498-1460

VICE PRESIDENT OF OPERATIONS

CASEY FOSTER

(610) 492-1007 CFOSTER@JOBSON.COM

PRODUCTION MANAGER

SCOTT TOBIN

(610) 492-1011 STOBIN@JOBSON.COM

SUBSCRIPTIONS

\$63 A YEAR, \$99 (U.S.) IN CANADA,
\$158 (U.S.) IN ALL OTHER COUNTRIES.

SUBSCRIPTIONS E-MAIL:

REVOPHTHALMOLOGY@CAMBEYWEST.COM

CIRCULATION

PO BOX 71, CONGERS, NY 10920-0071
(877) 529-1746

OUTSIDE USA: (845) 267-3065

SENIOR CIRCULATION MANAGER

HAMILTON MAHER

(212) 219-7870 hmaher@jhihealth.com

CEO, INFORMATION GROUP SERVICES

MARC FERRARA

SENIOR VICE PRESIDENT, OPERATIONS

JEFF LEVITZ

VICE PRESIDENT, HUMAN RESOURCES

TAMMY GARCIA

VICE PRESIDENT, CREATIVE SERVICES & PRODUCTION

MONICA TETTAMANZI

CORPORATE PRODUCTION DIRECTOR

JOHN ANTHONY CAGGIANO

VICE PRESIDENT, CIRCULATION

EVELDA BAREA



440 Ninth Avenue, 14th Floor
New York, N.Y. 10001

REVIEW OF OPHTHALMOLOGY (ISSN 1081-0226; USPS No. 0012-345) is published monthly, 12 times per year by Jobson Medical Information, 440 Ninth Avenue, 14th Floor, New York, N.Y. 10001. Periodicals postage paid at New York, NY and additional mailing offices. Postmaster: Send address changes to Review of Ophthalmology, PO Box 71, Congers, NY 10929-0071. Subscription Prices: US One Year \$63.00, US Two Year \$112.00, Canada One Year \$99.00, Canada Two Year \$181.00, Int'l One Year \$158.00, Int'l Two Year \$274.00. For subscription information call (877) 529-1746 (USA only); outside USA, call (845)-267-3065. Or email us at revophthalmology@cambeywest.com. Canada Post: Publications Mail Agreement #40612608. Canada Returns to be sent to Bleuphip International, P.O. Box 25542, London, ON N6C 6B2.

THE POWER OF PREEMPTION

OMIDRIA® is the first and only FDA-approved drug that provides continuous intracameral delivery of NSAID and mydriatic/anti-miotic therapy during cataract surgery¹

Coming October 1, 2018—Reinstatement of separate payment under Medicare Part B extends the benefit of OMIDRIA to more patients.

- Beginning **October 1, 2018**, OMIDRIA use in cataract and lens replacement surgery for patients with Medicare Part B coverage will be separately reimbursed for an additional 2 years
- Centers for Medicare & Medicaid Services (CMS) reimbursement will be managed under the same procedures that were in effect through 2017
- Omeros continues to support access to OMIDRIA through the OMIDRIAssure® Patient Assistance Program

INDICATIONS AND USAGE

OMIDRIA® (phenylephrine and ketorolac intraocular solution) 1% / 0.3% is added to ophthalmic irrigating solution used during cataract surgery or intraocular lens replacement and is indicated for maintaining pupil size by preventing intraoperative miosis and reducing postoperative ocular pain.

IMPORTANT SAFETY INFORMATION

OMIDRIA must be added to irrigating solution prior to intraocular use.

OMIDRIA is contraindicated in patients with a known hypersensitivity to any of its ingredients.

Systemic exposure of phenylephrine may cause elevations in blood pressure.

Use OMIDRIA with caution in individuals who have previously exhibited sensitivities to acetylsalicylic acid, phenylacetic acid derivatives, and other nonsteroidal anti-inflammatory drugs (NSAIDs), or have a past medical history of asthma.

The most commonly reported adverse reactions at $\geq 2\%$ are eye irritation, posterior capsule opacification, increased intraocular pressure, and anterior chamber inflammation.

Please see the Full Prescribing Information for OMIDRIA at www.omidria.com/prescribinginformation.

You are encouraged to report Suspected Adverse Reactions to the FDA.

Visit www.fda.gov/medwatch, or call 1-800-FDA-1088.

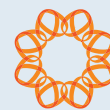
Reference: 1. OMIDRIA [package insert]. Seattle, WA: Omeros Corporation; 2017.

Visit www.omidria.com

Omeros does not guarantee reimbursement by any third-party payer. To be eligible for the "Equal Access" Patient Assistance Program, patients must be enrolled in OMIDRIAssure prior to surgery. For any patient for whom your facility received a free vial through the "Equal Access" Patient Assistance Program, the patient's insurance carrier(s) should not be billed for OMIDRIA. OMIDRIAssure program services are subject to change without notice.



OMEROS®, the OMEROS logo®, OMIDRIA®, the OMIDRIA logo®, and OMIDRIAssure® are registered trademarks of Omeros Corporation.
© Omeros Corporation 2018, all rights reserved. 2018-013



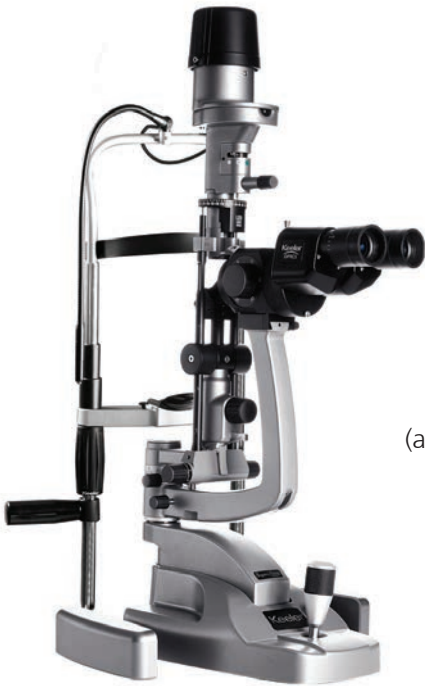OMIDRIA®

(phenylephrine and ketorolac
intraocular solution)
1% / 0.3%

The Keeler³ Trade In Program

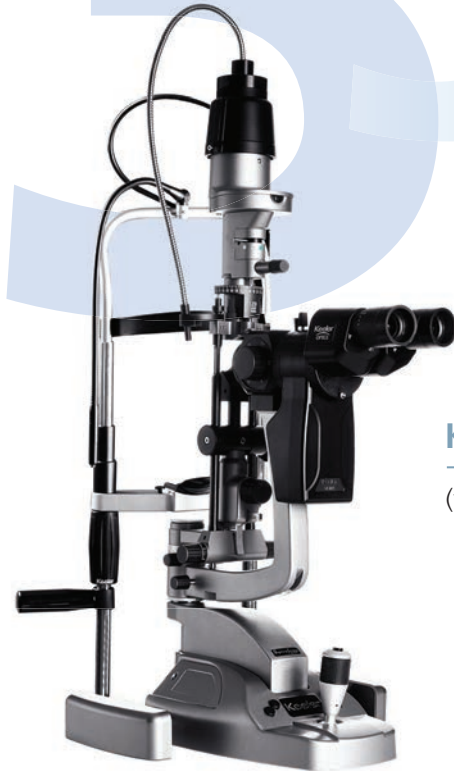Buy 3 // Trade 3 // Get 1 Free

The Power of 3. Purchase any 3 Keeler Slit Lamps and trade in 3 of your old Slit Lamps and we'll send you a 4th Keeler Slit Lamp absolutely free of charge.



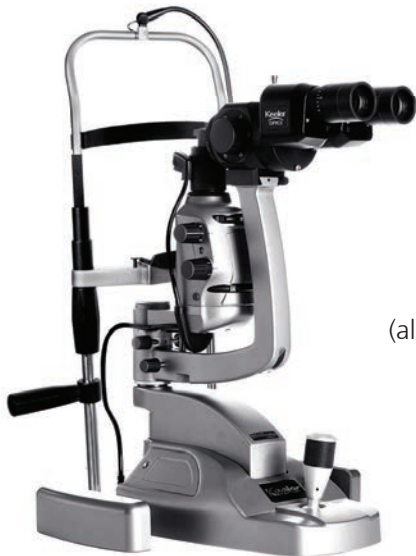KSL-H

(also in Digital Ready)



KSL-H-D

(full Digital)



KSL-Z

(also in Digital Ready)



KSL-H-D

(full Digital)

Keeler
OPTICS

Keeler Instruments, Inc. • 3222 Phoenixville Pike, bldg. 50 • Malvern, PA 19355
Tel: (800) 523-5620 • Fax: (610) 353-7814 • email: keeler@keelerusa.com

Offer valid until September 30, 2018.

Contact Keeler or one of our authorized dealers for more information.

REVIEW[®] of Ophthalmology

August 2018 • Volume XXV No. 8 | reviewofophthalmology.com

Cover Story

32 | **OCT Before Cataract Surgery: Not Optional**

Steve Charles, MD, FACS, FIC

It can reveal retinal issues that will otherwise be attributed to your surgery, argues this surgeon.

Cover Focus

26 | **Wet AMD: When Your First-line Fails**

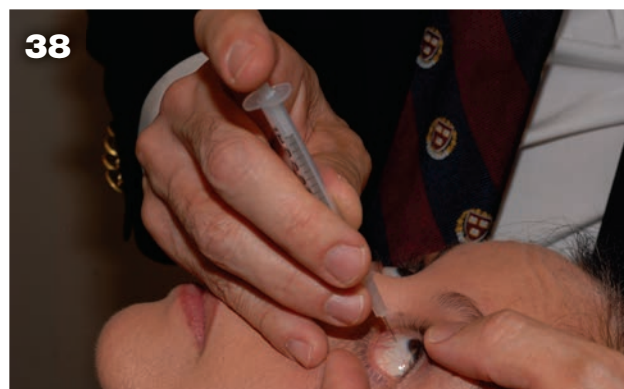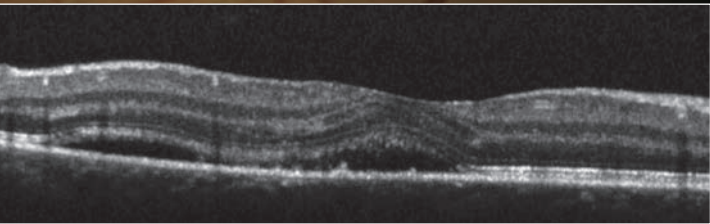
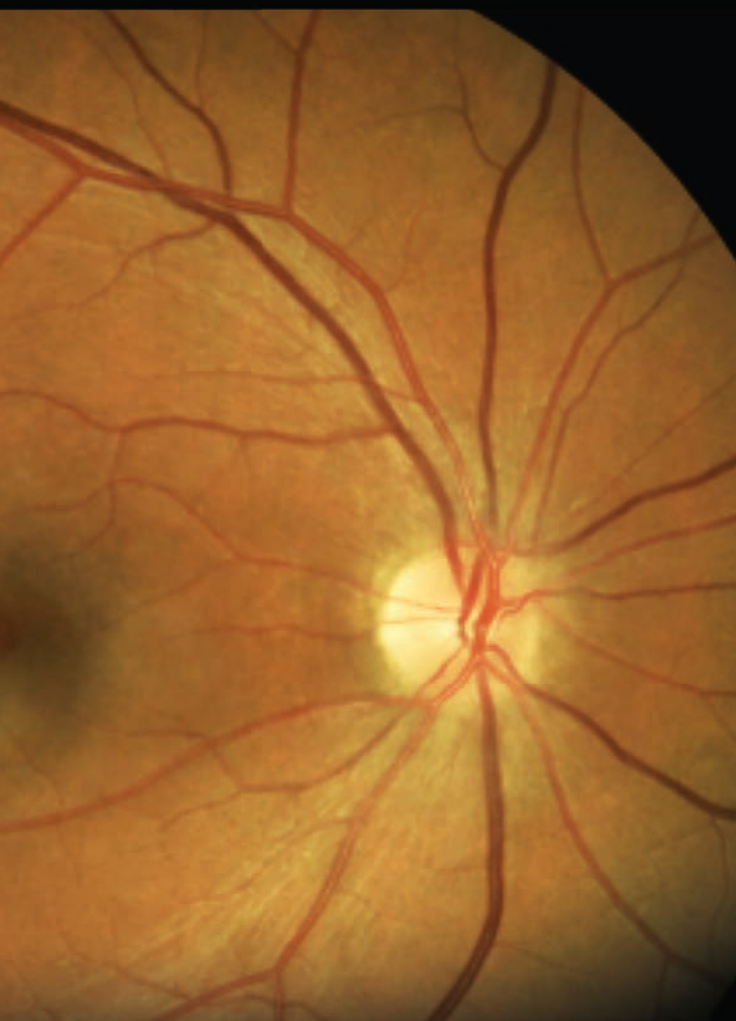
Chirag Shah, MD

When a wet AMD patient fails to respond to your treatment, all is not lost, says this physician.

38 | **The nAMD Pipeline: Full but Not Fast**

Kristine Brennan, Senior Associate Editor

Anti-VEGF revolutionized treatment. Easing the burden and new targets are the fresh priorities.



August 2018 | reviewofophthalmology.com | 13

Departments

3 | Review News

Editor's Page

16 | Make Room for Improvement

19 | Technology Update

Online Vision Tests: Time Saver or Risk Maker?

Testing apps can save patients time and money when renewing contacts or getting new glasses.

24 | Medicare Q & A

New Mid-year CPT Codes

The mid-year release comes with two Category III codes that practices need to be aware of.

44 | Glaucoma Management

Elderly and OHT: Should You Treat?

A number of factors have to be considered when deciding whether to put this type of patient on drops.

48 | Retinal Insider

Succeeding with Scleral-sutured Lenses

Two surgeons describe their go-to technique for working with IOLs that require scleral fixation.

50 | Cornea/Anterior Segment

ICRS and Cross-linking for Corneal Ectasia

A cornea surgeon explains the pros and cons of the two approaches, when used alone and in combination.

54 | Pediatric Patient

Myopia: Causes and Treatments

Due to the increasing prevalence of myopia, researchers are searching for better therapies.

58 | Research Review

Phaco vs. Femto Laser Cataract Surgery

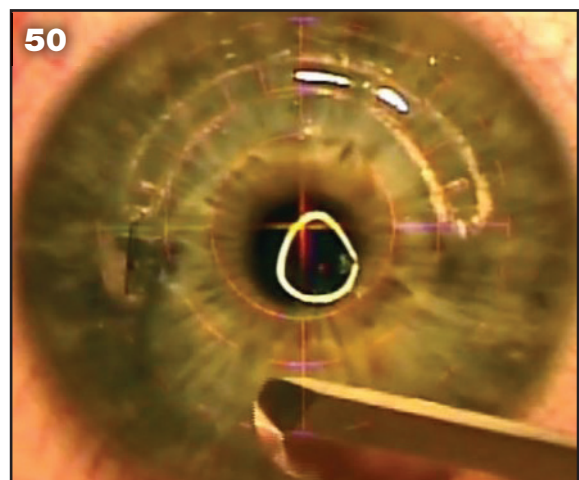
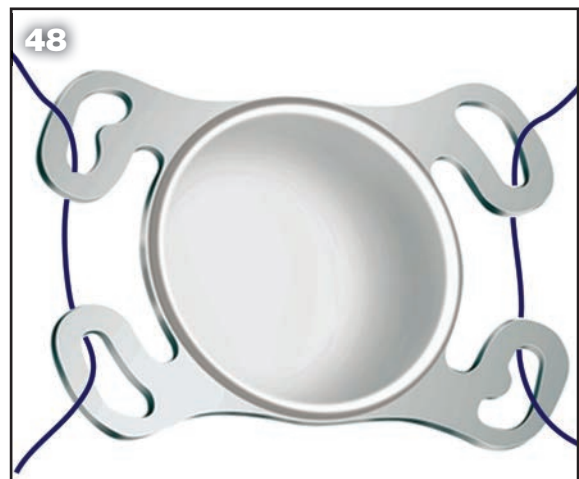
61 | Product News

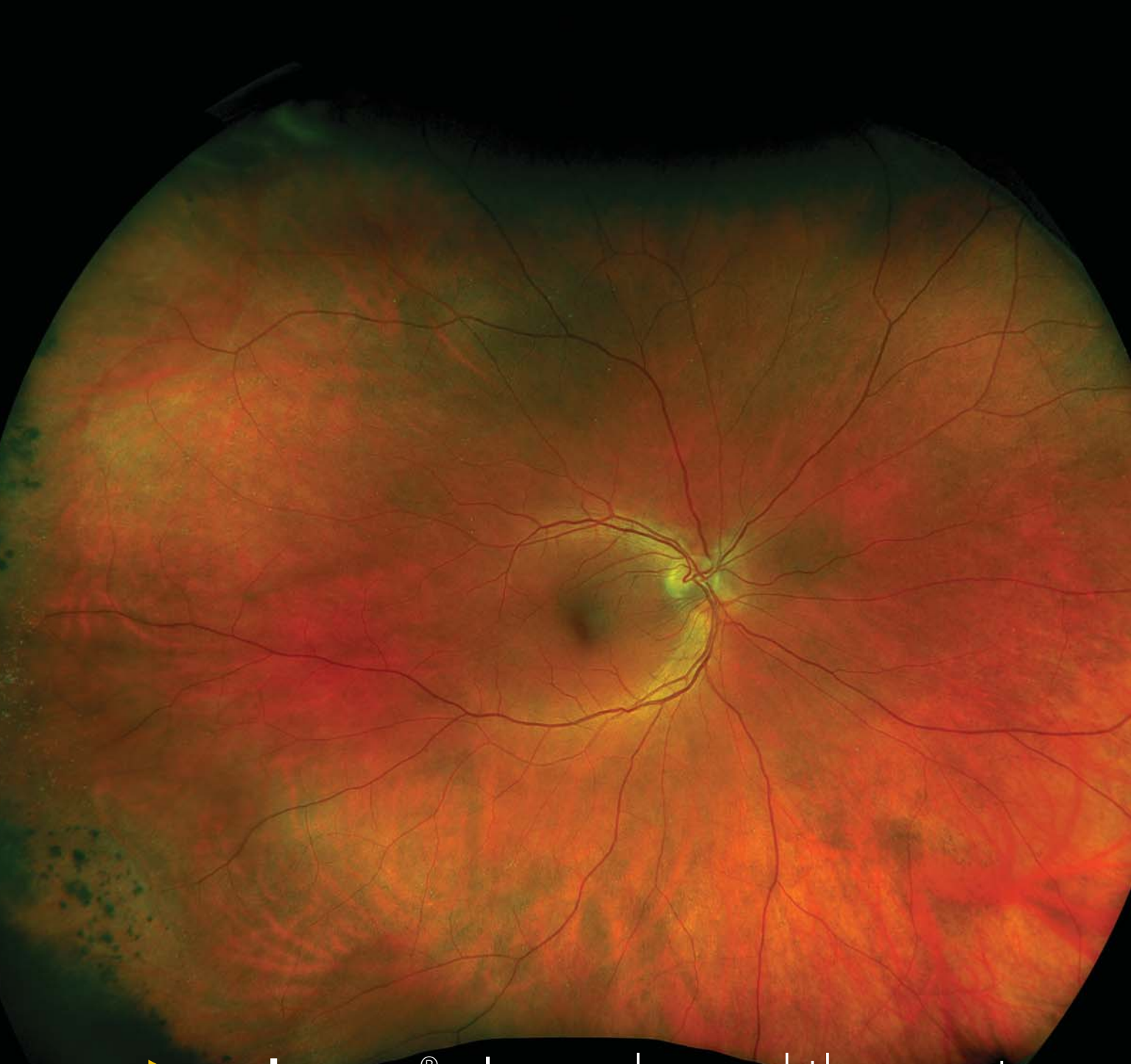FDA Approves iStent Inject

62 | Classifieds

63 | Wills Eye Resident Case Series

65 | Advertiser Index





▶ **optomap**[®] Image beyond the equator
in less than half a second

the **ONLY 200°** single-capture image

Contact us for your risk-free evaluation at 800-854-3039 or BDS@optos.com



A Nikon Company



Building *The Retina Company*

©2018 Optos. All rights reserved. Optos[®], optos[®] and optomap[®] are registered trademarks of Optos plc. PN GA-00315 /1

Editor in Chief

Walter C. Bethke
(610) 492-1024
wbethke@jobson.com

Senior Editor

Christopher Kent
(814) 861-5559
ckent@jobson.com

Senior Associate Editor

Kristine Brennan
(610) 492-1008
kbrennan@jobson.com

Associate Editor

Liam Jordan
(610) 492-1025
ljordan@jobson.com

Chief Medical Editor

Mark H. Blecher, MD

Art Director

Jared Araujo
(610) 492-1032
jaraujo@jobson.com

Senior Graphic Designer

Matt Egger
(610) 492-1029
megger@jobson.com

Graphic Designer

Ashley Schmouder
(610) 492-101048
aschmouder@jobson.com

International coordinator, Japan

Mitz Kaminuma
Reviewophthalgo@aol.com

Business Offices

11 Campus Boulevard, Suite 100
Newtown Square, PA 19073
(610) 492-1000
Fax: (610) 492-1039

Subscription inquiries:

United States — (877) 529-1746
Outside U.S. — (845) 267-3065
E-mail:

revophthalmology@CambeyWest.com

Website: www.reviewofophthalmology.com



Make Room for Improvement

In his popular book, “The 7 Habits of Highly Effective People,” author Steven R. Covey warns that, “We must never become too busy sawing to take time to sharpen the saw,” implying that just because you’re successfully humming along in your work doesn’t mean there won’t come a time when things get harder, or the methods that are working so well for you now suddenly become ineffective. Because of this possibility, it often pays to look for ways to improve on your current techniques and tools today, in order to minimize the difficulties of tomorrow. In this month’s retina issue, the authors and other ophthalmologists who share their insights have taken Mr. Covey’s advice to heart.

It’s most evident in Steve Charles, MD’s, cover story on the use of pre-operative optical coherence tomography on cataract-surgery patients (p. 32). Cataract surgery is the pinnacle of what a successful, modern-day surgery should look like: It’s minimally-invasive, quick, has a low rate of complications and a high rate of success, and it features that elusive “Wow” factor other surgeries lack, by virtue of restoring a patient’s eyesight. Dr. Charles argues, however, that there’s room for improvement. By using OCT to catch retinal pathology that would otherwise be invisible—even at the slit lamp—you help ensure even better outcomes and avoid any confusion on the part of these patients in terms of what might be causing less-than-ideal postoperative vision.

Speaking of successful treatments, not many interventions have been as successful as anti-VEGF injections for wet age-related macular degeneration. Even with anti-VEGF injections, however, says Boston retina specialist Chirag Shah (p. 26), there’s room for improvement in terms of handling non-responders. The challenge is that the treatment modality has been so successful, no one has put the time or funds into a randomized trial to determine what’s best for the unfortunate few in whom it’s not a success. Dr. Shah helps fill this research void with tips from his own practice, as well the latest data that does exist on the subject.

Finally, nothing embodies the spirit of innovation and the quest for improvement more than the new-product pipeline, which is highlighted in Senior Associate Editor Kristine Brennan’s article on page 38. Retinal researchers and companies are hard at work on myriad ways to attack VEGF, as well as other causes of AMD, which may be able to improve on today’s already excellent methods.

So, this month, pause for a minute, give these articles a read, and get ready to sharpen the saw.

—Walt Bethke, Editor in Chief

POWER TO PREVAIL

As demonstrated in phase 3 clinical trials evaluating BCVA,* as measured by ETDRS letters, in patients with Wet AMD, Macular Edema following RVO, DME, and by ETDRS-DRSS[†] in DR in Patients with DME,¹ as well as your clinical experience

Start with EYLEA for proven efficacy outcomes¹



AMD = Age-related Macular Degeneration; DME = Diabetic Macular Edema; DR = Diabetic Retinopathy; RVO = Retinal Vein Occlusion.

Dosing driving efficacy outcomes across all indications.¹
Learn more at EYLEA.us/dose

INDICATIONS AND IMPORTANT SAFETY INFORMATION

INDICATIONS

EYLEA® (aflibercept) Injection is indicated for the treatment of patients with

- Neovascular (Wet) Age-related Macular Degeneration (AMD): The recommended dose is 2 mg administered by intravitreal injection every 4 weeks (monthly) for the first 12 weeks (3 months), followed by 2 mg once every 8 weeks (2 months). Although EYLEA may be dosed as frequently as 2 mg every 4 weeks (monthly), additional efficacy was not demonstrated in most patients when EYLEA was dosed every 4 weeks compared to every 8 weeks. Some patients may need every 4 week (monthly) dosing after the first 12 weeks (3 months).
- Macular Edema following Retinal Vein Occlusion (RVO): The recommended dose is 2 mg administered by intravitreal injection every 4 weeks (monthly).
- Diabetic Macular Edema (DME) and Diabetic Retinopathy (DR) in Patients with DME: The recommended dose is 2 mg administered by intravitreal injection every 4 weeks (monthly) for the first 5 injections, followed by 2 mg once every 8 weeks (2 months). Although EYLEA may be dosed as frequently as 2 mg every 4 weeks (monthly), additional efficacy was not demonstrated in most patients when EYLEA was dosed every 4 weeks compared to every 8 weeks. Some patients may need every 4 week (monthly) dosing after the first 20 weeks (5 months).

CONTRAINDICATIONS

- EYLEA® (aflibercept) Injection is contraindicated in patients with ocular or periocular infections, active intraocular inflammation, or known hypersensitivity to aflibercept or to any of the excipients in EYLEA.

WARNINGS AND PRECAUTIONS

- Intravitreal injections, including those with EYLEA, have been associated with endophthalmitis and retinal detachments. Proper aseptic injection technique must always be used when administering EYLEA. Patients should be instructed to report any symptoms suggestive of endophthalmitis or retinal detachment without delay and should be managed appropriately. Intraocular inflammation has been reported with the use of EYLEA.

Please see adjacent Brief Summary.

*Best-corrected visual acuity.

[†]Early Treatment Diabetic Retinopathy Study–Diabetic Retinopathy Severity Scale: an established grading scale for measuring the severity of DR.

Reference: 1. EYLEA® (aflibercept) Injection full U.S. Prescribing Information. Regeneron Pharmaceuticals, Inc. May 2017.

EYLEA is a registered trademark of Regeneron Pharmaceuticals, Inc.

REGENERON

© 2017, Regeneron Pharmaceuticals, Inc. All rights reserved.
777 Old Saw Mill River Road, Tarrytown, NY 10591



EYLEA®
(aflibercept) Injection
For Intravitreal Injection

- Acute increases in intraocular pressure have been seen within 60 minutes of intravitreal injection, including with EYLEA. Sustained increases in intraocular pressure have also been reported after repeated intravitreal dosing with VEGF inhibitors. Intraocular pressure and the perfusion of the optic nerve head should be monitored and managed appropriately.
- There is a potential risk of arterial thromboembolic events (ATEs) following intravitreal use of VEGF inhibitors, including EYLEA. ATEs are defined as nonfatal stroke, nonfatal myocardial infarction, or vascular death (including deaths of unknown cause). The incidence of reported thromboembolic events in wet AMD studies during the first year was 1.8% (32 out of 1824) in the combined group of patients treated with EYLEA. The incidence in the DME studies from baseline to week 52 was 3.3% (19 out of 578) in the combined group of patients treated with EYLEA compared with 2.8% (8 out of 287) in the control group; from baseline to week 100, the incidence was 6.4% (37 out of 578) in the combined group of patients treated with EYLEA compared with 4.2% (12 out of 287) in the control group. There were no reported thromboembolic events in the patients treated with EYLEA in the first six months of the RVO studies.

ADVERSE REACTIONS

- Serious adverse reactions related to the injection procedure have occurred in <0.1% of intravitreal injections with EYLEA including endophthalmitis and retinal detachment.
- The most common adverse reactions (≥5%) reported in patients receiving EYLEA were conjunctival hemorrhage, eye pain, cataract, vitreous floaters, intraocular pressure increased, and vitreous detachment.

10/2017
US-LEA-13945



BRIEF SUMMARY—Please see the EYLEA package insert for full Prescribing Information.

1 INDICATIONS AND USAGE

EYLEA is a vascular endothelial growth factor (VEGF) inhibitor indicated for the treatment of: Neovascular (Wet) Age-Related Macular Degeneration (AMD); Macular Edema Following Retinal Vein Occlusion (RVO); Diabetic Macular Edema (DME); Diabetic Retinopathy (DR) in Patients with DME

4 CONTRAINDICATIONS

4.1 Ocular or Periocular Infections

EYLEA is contraindicated in patients with ocular or periocular infections.

4.2 Active Intraocular Inflammation

EYLEA is contraindicated in patients with active intraocular inflammation.

4.3 Hypersensitivity

EYLEA is contraindicated in patients with known hypersensitivity to aflibercept or any of the excipients in EYLEA. Hypersensitivity reactions may manifest as rash, pruritus, urticaria, severe anaphylactic/anaphylactoid reactions, or severe intraocular inflammation.

5 WARNINGS AND PRECAUTIONS

5.1 Endophthalmitis and Retinal Detachments. Intravitreal injections, including those with EYLEA, have been associated with endophthalmitis and retinal detachments [see *Adverse Reactions (6.1)*]. Proper aseptic injection technique must always be used when administering EYLEA. Patients should be instructed to report any symptoms suggestive of endophthalmitis or retinal detachment without delay and should be managed appropriately [see *Dosage and Administration (2.7)* and *Patient Counseling Information (7.1)*].

5.2 Increase in Intraocular Pressure. Acute increases in intraocular pressure have been seen within 60 minutes of intravitreal injection, including with EYLEA [see *Adverse Reactions (6.1)*]. Sustained increases in intraocular pressure have also been reported after repeated intravitreal dosing with vascular endothelial growth factor (VEGF) inhibitors. Intraocular pressure and the perfusion of the optic nerve head should be monitored and managed appropriately [see *Dosage and Administration (2.7)*].

5.3 Thromboembolic Events. There is a potential risk of arterial thromboembolic events (ATEs) following intravitreal use of VEGF inhibitors, including EYLEA. ATEs are defined as nonfatal stroke, nonfatal myocardial infarction, or vascular death (including deaths of unknown cause). The incidence of reported thromboembolic events in wet AMD studies during the first year was 1.8% (32 out of 1824) in the combined group of patients treated with EYLEA. The incidence in the DME studies from baseline to week 52 was 3.3% (19 out of 578) in the combined group of patients treated with EYLEA compared with 2.8% (8 out of 287) in the control group; from baseline to week 100, the incidence was 6.4% (37 out of 578) in the combined group of patients treated with EYLEA compared with 4.2% (12 out of 287) in the control group. There were no reported thromboembolic events in the patients treated with EYLEA in the first six months of the RVO studies.

6 ADVERSE REACTIONS

The following potentially serious adverse reactions are described elsewhere in the labeling:

- Hypersensitivity [see *Contraindications (4.3)*]
- Endophthalmitis and retinal detachments [see *Warnings and Precautions (5.1)*]
- Increase in intraocular pressure [see *Warnings and Precautions (5.2)*]
- Thromboembolic events [see *Warnings and Precautions (5.3)*]

6.1 Clinical Trials Experience. Because clinical trials are conducted under widely varying conditions, adverse reaction rates observed in the clinical trials of a drug cannot be directly compared to rates in other clinical trials of the same or another drug and may not reflect the rates observed in practice.

A total of 2711 patients treated with EYLEA constituted the safety population in seven phase 3 studies. Among those, 2110 patients were treated with the recommended dose of 2 mg. Serious adverse reactions related to the injection procedure have occurred in <0.1% of intravitreal injections with EYLEA including endophthalmitis and retinal detachment. The most common adverse reactions (≥5%) reported in patients receiving EYLEA were conjunctival hemorrhage, eye pain, cataract, vitreous floaters, intraocular pressure increased, and vitreous detachment.

Neovascular (Wet) Age-Related Macular Degeneration (AMD). The data described below reflect exposure to EYLEA in 1824 patients with wet AMD, including 1235 patients treated with the 2-mg dose, in 2 double-masked, active-controlled clinical studies (VIEW1 and VIEW2) for 12 months.

Table 1: Most Common Adverse Reactions (≥1%) in Wet AMD Studies

Adverse Reactions	EYLEA (N=1824)	Active Control (ranibizumab) (N=595)
Conjunctival hemorrhage	25%	28%
Eye pain	9%	9%
Cataract	7%	7%
Vitreous detachment	6%	6%
Vitreous floaters	6%	7%
Intraocular pressure increased	5%	7%
Ocular hyperemia	4%	8%
Corneal epithelium defect	4%	5%
Detachment of the retinal pigment epithelium	3%	3%
Injection site pain	3%	3%
Foreign body sensation in eyes	3%	4%
Lacrimation increased	3%	1%
Vision blurred	2%	2%
Intraocular inflammation	2%	3%
Retinal pigment epithelium tear	2%	1%
Injection site hemorrhage	1%	2%
Eyelid edema	1%	2%
Corneal edema	1%	1%

Less common serious adverse reactions reported in <1% of the patients treated with EYLEA were hypersensitivity, retinal detachment, retinal tear, and endophthalmitis.

Macular Edema Following Retinal Vein Occlusion (RVO). The data described below reflect 6 months exposure to EYLEA with a monthly 2 mg dose in 218 patients following CRVO in 2 clinical studies (COPERNICUS and GALILEO) and 91 patients following BRVO in one clinical study (VIBRANT).

Table 2: Most Common Adverse Reactions (≥1%) in RVO Studies

Adverse Reactions	CRVO		BRVO	
	EYLEA (N=218)	Control (N=142)	EYLEA (N=91)	Control (N=92)
Eye pain	13%	5%	4%	5%
Conjunctival hemorrhage	12%	11%	20%	4%
Intraocular pressure increased	8%	6%	2%	0%
Corneal epithelium defect	5%	4%	2%	0%
Vitreous floaters	5%	1%	1%	0%
Ocular hyperemia	5%	3%	2%	2%
Foreign body sensation in eyes	3%	5%	3%	0%
Vitreous detachment	3%	4%	2%	0%
Lacrimation increased	3%	4%	3%	0%
Injection site pain	3%	1%	1%	0%
Vision blurred	1%	<1%	1%	1%
Intraocular inflammation	1%	1%	0%	0%
Cataract	<1%	1%	5%	0%
Eyelid edema	<1%	1%	1%	0%

Less common adverse reactions reported in <1% of the patients treated with EYLEA in the CRVO studies were corneal edema, retinal tear, hypersensitivity, and endophthalmitis.

Diabetic Macular Edema (DME). The data described below reflect exposure to EYLEA in 578 patients with DME treated with the 2-mg dose in 2 double-masked, controlled clinical studies (VIVID and VISTA) from baseline to week 52 and from baseline to week 100.

Table 3: Most Common Adverse Reactions (≥1%) in DME Studies

Adverse Reactions	Baseline to Week 52		Baseline to Week 100	
	EYLEA (N=578)	Control (N=287)	EYLEA (N=578)	Control (N=287)
Conjunctival hemorrhage	28%	17%	31%	21%
Eye pain	9%	6%	11%	9%
Cataract	8%	9%	19%	17%
Vitreous floaters	6%	3%	8%	6%
Corneal epithelium defect	5%	3%	7%	5%
Intraocular pressure increased	5%	3%	9%	5%
Ocular hyperemia	5%	6%	5%	6%
Vitreous detachment	3%	3%	8%	6%
Foreign body sensation in eyes	3%	3%	3%	3%
Lacrimation increased	3%	2%	4%	2%
Vision blurred	2%	2%	3%	4%
Intraocular inflammation	2%	<1%	3%	1%
Injection site pain	2%	<1%	2%	<1%
Eyelid edema	<1%	1%	2%	1%

Less common adverse reactions reported in <1% of the patients treated with EYLEA were hypersensitivity, retinal detachment, retinal tear, corneal edema, and injection site hemorrhage.

6.2 Immunogenicity. As with all therapeutic proteins, there is a potential for an immune response in patients treated with EYLEA. The immunogenicity of EYLEA was evaluated in serum samples. The immunogenicity data reflect the percentage of patients whose test results were considered positive for antibodies to EYLEA in immunoassays. The detection of an immune response is highly dependent on the sensitivity and specificity of the assays used, sample handling, timing of sample collection, concomitant medications, and underlying disease. For these reasons, comparison of the incidence of antibodies to EYLEA with the incidence of antibodies to other products may be misleading.

In the wet AMD, RVO, and DME studies, the pre-treatment incidence of immunoreactivity to EYLEA was approximately 1% to 3% across treatment groups. After dosing with EYLEA for 24-100 weeks, antibodies to EYLEA were detected in a similar percentage range of patients. There were no differences in efficacy or safety between patients with or without immunoreactivity.

8 USE IN SPECIFIC POPULATIONS

8.1 Pregnancy

Risk Summary

Adequate and well-controlled studies with EYLEA have not been conducted in pregnant women. Aflibercept produced adverse embryofetal effects in rabbits, including external, visceral, and skeletal malformations. A fetal No Observed Adverse Effect Level (NOAEL) was not identified. At the lowest dose shown to produce adverse embryofetal effects, systemic exposures (based on AUC for free aflibercept) were approximately 6 times higher than AUC values observed in humans after a single intravitreal treatment at the recommended clinical dose [see *Animal Data*].

Animal reproduction studies are not always predictive of human response, and it is not known whether EYLEA can cause fetal harm when administered to a pregnant woman. Based on the anti-VEGF mechanism of action for aflibercept [see *Clinical Pharmacology (12.1)*], treatment with EYLEA may pose a risk to human embryofetal development. EYLEA should be used during pregnancy only if the potential benefit justifies the potential risk to the fetus.

All pregnancies have a background risk of birth defect, loss, or other adverse outcomes. The background risk of major birth defects and miscarriage for the indicated population is unknown. In the U.S. general population, the estimated background risk of major birth defects and miscarriage in clinically recognized pregnancies is 2-4% and 15-20%, respectively.

Data

Animal Data

In two embryofetal development studies, aflibercept produced adverse embryofetal effects when administered every three days during organogenesis to pregnant rabbits at intravenous doses ≥3 mg per kg, or every six days during organogenesis at subcutaneous doses ≥0.1 mg per kg.

Adverse embryofetal effects included increased incidences of postimplantation loss and fetal malformations, including anasarca, umbilical hernia, diaphragmatic hernia, gastroschisis, cleft palate, ectrodactyly, intestinal atresia, spina bifida, encephalomeningocele, heart and major vessel defects, and skeletal malformations (fused vertebrae, sternbrae, and ribs; supernumerary vertebral arches and ribs; and incomplete ossification). The maternal No Observed Adverse Effect Level (NOAEL) in these studies was 3 mg per kg. Aflibercept produced fetal malformations at all doses assessed in rabbits and the fetal NOAEL was not identified. At the lowest dose shown to produce adverse embryofetal effects in rabbits (0.1 mg per kg), systemic exposure (AUC) of free aflibercept was approximately 6 times higher than systemic exposure (AUC) observed in humans after a single intravitreal dose of 2 mg.

8.2 Lactation

Risk Summary

There is no information regarding the presence of aflibercept in human milk, the effects of the drug on the breastfed infant, or the effects of the drug on milk production/excretion. Because many drugs are excreted in human milk, and because the potential for absorption and harm to infant growth and development exists, EYLEA is not recommended during breastfeeding.

The developmental and health benefits of breastfeeding should be considered along with the mother's clinical need for EYLEA and any potential adverse effects on the breastfed child from EYLEA.

8.3 Females and Males of Reproductive Potential

Contraception

Females of reproductive potential are advised to use effective contraception prior to the initial dose, during treatment, and for at least 3 months after the last intravitreal injection of EYLEA.

Fertility

There are no data regarding the effects of EYLEA on human fertility. Aflibercept adversely affected female and male reproductive systems in cynomolgus monkeys when administered by intravenous injection at a dose approximately 1500 times higher than the systemic level observed humans with an intravitreal dose of 2 mg. A No Observed Adverse Effect Level (NOAEL) was not identified. These findings were reversible within 20 weeks after cessation of treatment [see *Nonclinical Toxicology (13.1)*].

8.4 Pediatric Use. The safety and effectiveness of EYLEA in pediatric patients have not been established.

8.5 Geriatric Use. In the clinical studies, approximately 76% (2049/2701) of patients randomized to treatment with EYLEA were ≥65 years of age and approximately 46% (1250/2701) were ≥75 years of age. No significant differences in efficacy or safety were seen with increasing age in these studies.

17 PATIENT COUNSELING INFORMATION

In the days following EYLEA administration, patients are at risk of developing endophthalmitis or retinal detachment. If the eye becomes red, sensitive to light, painful, or develops a change in vision, advise patients to seek immediate care from an ophthalmologist [see *Warnings and Precautions (5.1)*].

Patients may experience temporary visual disturbances after an intravitreal injection with EYLEA and the associated eye examinations [see *Adverse Reactions (6)*]. Advise patients not to drive or use machinery until visual function has recovered sufficiently.

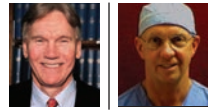Manufactured by:
Regeneron Pharmaceuticals, Inc.
777 Old Saw Mill River Road
Tarrytown, NY 10591

Issue Date: June 2017
Initial U.S. Approval: 2011

Based on the May 2017 EYLEA® (aflibercept) Injection full Prescribing Information.

EYLEA is a registered trademark of Regeneron Pharmaceuticals, Inc.
© 2017, Regeneron Pharmaceuticals, Inc. All rights reserved.

REGENERON



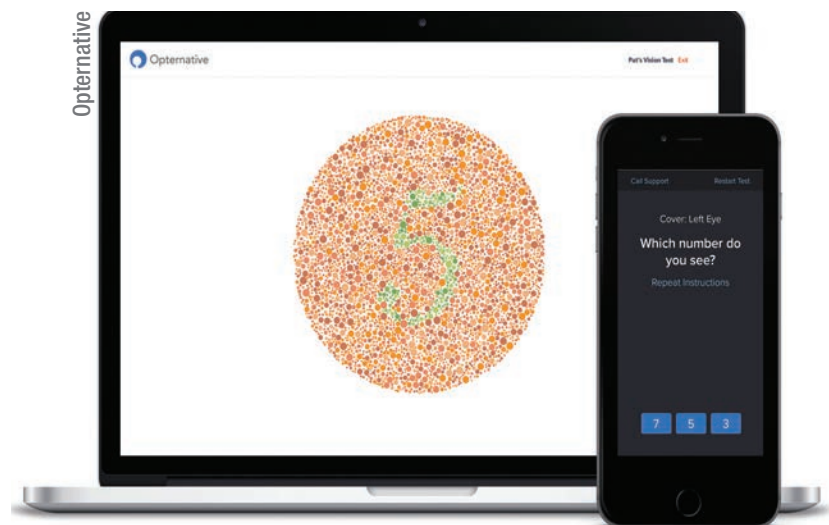
Online Vision Tests: Time Saver or Risk Maker?

Vision-testing apps can save low-risk patients time and money when it's time to renew contacts or get a new pair of glasses.

Kristine Brennan, Senior Associate Editor

Ordering glasses or contact lenses online is not new, but renewal of the script has traditionally entailed a trip to the ophthalmologist or optometrist for a dilated eye exam. Some doctors say that this office visit is needlessly burdensome for a large proportion of patients, who would benefit from the ease and cost-effectiveness of telemedicine. Online vision testing's advocates seek to spread the word about a service they say offers a safe, quick and affordable alternative to in-office visits. Other providers, however, vehemently oppose what they consider a dangerously incomplete eye-care paradigm.

Although some online vision tests involve real-time interaction with an eye-care provider, many exemplify “store-and-forward,” or asynchronous, telemedicine, wherein the provider reviews stored data after the patient completes testing. The online-glasses giant Warby Parker (New York) launched its app, Prescription Check, in 2017 to allow existing customers to renew their spectacle prescriptions. (Representatives from Warby Parker were not available for comment at press time.)



The online vision tests discussed here are examples of asynchronous telehealth apps, where the patient takes a test and then an eye-care professional evaluates the patient's responses or video recording remotely before renewing or issuing a prescription. Shown here: a color-vision item from Opternative's online vision test. Patients respond to prompts on the computer screen by entering answers using a smartphone.

Opternative (Chicago) founded in 2012, lets users renew or get updated scripts for glasses, contacts or both. Simple Contacts (New York), founded in 2015, offers a vision-test app called Rx Renewal to check contact-lens prescriptions only.

“Telemedicine could create a lot of different ways of reducing inefficien-

cy in the U.S. health-care system,” opines Saya Nagori, MD, medical director of Simple Contacts. “In the case of contact lenses, 80 percent of the time you end up getting the same prescription you came in with. But you still have to pay for the doctor's visit and schedule time out of your day.”

Steven Lee, OD, founder and chief science officer for Opternative, says that patients should be able to do more than confirm existing prescriptions remotely. He says that his company's online refraction testing "is the only one on the market that allows patients to receive a prescription for glasses and/or contact lenses, even if the prescription has changed.

"We are aware that online refraction is only one component of a person's overall eye health," Dr. Lee notes. "Because of this, we recommend that all patients go through a full eye exam with an eye-care professional at least once every two years." All three of the above vision-testing apps have language cautioning that their services are not intended as a substitute for a comprehensive eye exam, and they stress that ophthalmologists or optometrists evaluate the self-administered testing's results. Warby Parker's Prescription Check app cautions would-be patients, "The app will guide you through a series of tests to figure out how you're seeing through the prescription eyeglasses you're wearing. An eye doctor will assess your visual acuity, but Prescription Check isn't meant to replace a comprehensive eye exam and we aren't checking your eye health."

Simple Contacts founder and CEO Joel Wishkovsky thought it was "baloney" when he was directed to go get a comprehensive eye exam to renew his contact-lens prescription. His workaround (getting an ophthalmologist friend to renew his prescription based on his answers to health questions, video checks for redness and to demonstrate that he could read to 20/20 on an eye chart) inspired him to get into the telehealth market. "I immediately thought, 'I can build this into an app. I can build a website around it,'" he recalls.

Using a smartphone or computer, patients submit secure videos for

Recommended Eye-Exam Frequency for Low-risk Adults

Patient Age	Frequency
under 40	every 5-10 years
40-54	every 2-4 years
55-64	every 1-3 years
65-up	every 1-2 years

This table shows the recommended frequency of comprehensive medical eye examinations for healthy adults with no risk factors for eye disease, per guidance from the American Academy of Ophthalmology.¹ The online vision-testing apps discussed here emphasize that their services are not intended as a substitute for a comprehensive exam by an eye-care professional.

ophthalmologist review after they answer some health-history questions, including when they had their last dilated eye exam. "The redness test is a video eye exam. We ask users to look left, right up and down, looking for any eye irritation and any kind of redness," Dr. Nagori explains. "There's a built-in zoom feature on the administrative side, so as a doctor, I have the ability to zoom in much closer than the patient actually takes the video. The second part is a distance-calibrated Snellen chart, so the iPhone or Android is able to tell how far you are from the phone/camera and when you should initiate the vision test. That's done at 10 feet. We only renew patients who are able to read the 20/20 line in their contacts."

Mixed Reactions

Online vision tests have gotten a mixed reception from professional eye-care associations, and there's a wide gulf in acceptance between ophthalmologists and optometrists. "We've raised 30 million dollars, and a lot of that comes from ophthalmologists, not just from venture capitalists," says Mr. Wishkovsky. Dr. Nagori concurs that fellow ophthalmologists are supportive.

mologists are supportive.

The American Optometric Association, however, stands in firm opposition to online vision testing on the grounds that patients may be misled into believing that they're getting more health care than a simple verification of their vision prescription. A statement provided to *Review of Ophthalmology* from the American Optometric Association reads in part, "While there may be fine-print disclaimers that say these apps do not replace comprehensive eye examinations, consumers may still be under the impression they have received medical eye care."

The statement concludes with a warning: "Existing vision apps promise health care, but they deliver much less than the medically recognized standard of care. Through an in-person, comprehensive examination, doctors of optometry assure precise and healthy vision, identify and treat diseases such as dry eye, macular degeneration and glaucoma as well as ensure early diagnosis of immediate threats to overall health, including hypertension, stroke and diabetes, which may have no obvious signs or symptoms.

"The AOA will continue to hold companies accountable for any claims they make that potentially put consumer health at risk."

In 2016 the AOA sent a strongly-worded complaint letter to the U.S. Food and Drug Administration in which they alleged that Opternative was using its app in such a way that its testing constituted a novel medical device, without submitting a premarket application. The FDA subsequently issued a warning letter to Opternative that enjoined it to "immediately cease activities that result in the misbranding or adulteration of the On-Line Opternative Eye Examination Mobile Medical App device, such as the commercial distribution of the device through

your online website.”²

Dr. Nagori says that her company’s testing incorporates a Snellen eye chart with the sole purpose of determining visual acuity—not to calculate a new prescription. “We’re currently operating in 42 states. We’ve created a very comprehensive exam that’s very safe, and we took the strictest state’s requirements and applied them to all the states where we operate when devising our tests. That way, we don’t have any regulatory issues at the state level. In the case of ophthalmologists, refractions and contact-lens renewals are probably among the most benign things we do in the office; and I, along with several other ophthalmologists, have worked together to make sure we comply with the American Academy of Ophthalmology’s clinical guidelines. We feel that this test is extremely comprehensive for its purpose—which is for contact-lens renewals only,” she says.

Dr. Nagori adds, “There’s a healthy amount of research supporting the idea that lack of an easy way to renew your contact lenses is a factor in contact-lens-related infections. An app like ours, which prevents patients from using their lenses for too long, can actually help to prevent those issues, because one of the biggest reasons patients don’t renew their contact lenses on time is that they just can’t get in to see the doctor, or because of the expense. Creating telemedicine solutions improves access and also makes it affordable.”

The American Academy of Ophthalmology has taken an official stance of conditional openness to online testing. “The Academy is generally supportive of the use of new technologies to improve efficiency and widen access to eye-care services. These technologies can help make diagnostic tools more available in remote settings, enabling remote diagnosis and interpretation. They can also help reduce health-care costs and visits,” its statement reads in part. “But, as with any new medical technology, online vision testing needs to be evaluated over time for safety and efficacy.”³ The AAO’s guidance does diverge from Simple Contacts’ inclusion criteria with regard to patient age, stating, “These services may be appropriate for people 18 to 39 years of age with non-severe corrective eyeglass prescriptions and no symptoms of eye disease.”³ Simple Contacts does not have an upper age limit for users. The Academy also noted that it had “insufficient data” about online prescription renewal specifically for contact lenses at the time it issued guidance about online vision testing in general.

Dr. Nagori says that patients must be aged 18 or older with no major medical issues to use the Rx Renewal app. “They can’t have hypertension or diabetes, for example,” she says. “While those conditions affect the back of the eye and have little to do with contact lens wear, we want



NuLids™ transformational dry eye therapy

Transforms your patients' lives



Finally... A doctor-directed at-home treatment for dry eye disease that is safe, effective and easy to use.

A multi-center study¹ showed:

- 50% decrease in dry eye symptoms
- 65% improvement in TBUT
- 80% increase in meibomian glands yielding liquid secretions.

For more information visit
www.NuSightMedical.com/rophi8
or call us at 833-468-5437



¹ Schanzlin, Olkowski, Coble, Gross. NuLids II Study, April 2018



NuLids™

Doctor prescribed, at-home dry eye relief

to encourage those patients to go in to see the doctor. At this juncture, we feel that we should push them into the doctor's office. If you're healthy and free of medical issues, and you've had a dilated eye exam within the time frame that the AAO recommends, then you're eligible to use online prescription-renewal testing," she says.

Dr. Nagori estimates that about 500,000 patients have used Rx Renewal. "It's hard to tell how many people have gotten a script, because we do have some failures, which probably constitute about 8 to 10 percent of the people using the app," she says.

She adds that the failures help ensure safety. "The first broad screening is a questionnaire for issues that could affect eye health," she says. "But, sometimes if we notice something incidental that is not really immediately harmful, like a stye that doesn't look like it's at risk of turning into a cellulitis and looks pretty benign, we may give a limited renewal for a month or two and then recommend that they go to see a doctor to get that issue addressed. Sometimes, the things that trigger a fail are more serious: for example, an unusual eye movement that concerns me. I obviously can't examine them, so I'll suggest that they see a doctor instead. Even though that's not directly related to their use of contacts, I still want to motivate them to go in and see the doctor. Sometimes, fails are related to possible effects of contact-lens wear. So if a patient's eye appears red or irritated, we don't allow them to renew. They may also fail the vision test. Some patients think that they're seeing clearly when they're actually not able to read the

20/20 line: That's another reason we would send them back to their doctor to have their prescription refined and adjusted," she says.

In the case of a failure, the patient receives a notification instead of a renewed script. Mr. Wishkovsky says that the company facilitates commu-

nication with the reviewing ophthalmologist. "We have a mechanism that allows the doctor to call the patient," he says. "The patient can also call the doctor. Or they can have a conversation via text message. In most of these situations, the doctor sends instructions advising them of what they've detected and telling them they should see a doctor in person. Our team can work with that person to find them an appropriate provider in their area."

that online refraction technologies are not particularly novel, and he thinks they're safe when offered with care. "The technology has been tested with hundreds of thousands of patients receiving accurate prescriptions since 2015," he says. "The technology checks various components of a patient's prescription in a number of different ways to ensure that the prescription has been accurately measured. Additionally, all refractive-error measurements are reviewed by an eye-care professional before a patient is issued a new prescription."

Mr. Wishkovsky thinks that as online refraction gains ground, the model is readily applicable to other health-care contexts, such as remotely renewing birth-control prescriptions in healthy, low-risk patients. Dr. Nagori says that the company is already at work on adding specialty-specific features to Rx Renewal. "Right now we're working on developing an AI system that risk stratifies patients found by the test to have red eyes.

We want to find solutions that will alleviate not only issues for patients, but also unburden some of the health-care system where possible. With risk stratification, instead of waiting in the ER for four or five hours, a patient with a red eye could be triaged faster if an artificial intelligence system could predict the likelihood of needing to see an eye doctor immediately, versus the likelihood of something being a condition that could wait until the next morning, for example."

As a glaucoma specialist, Dr. Nagori thinks that telemedicine could benefit both patients and providers outside of the direct-to-consumer



Simple Contacts

The online testing services discussed here emphasize that they are not providing the equivalent of a comprehensive eye exam, but they do have basic mechanisms to screen out patients in poor ocular health. Shown: patient using the redness-check portion of the Rx Renewal app.

Future Advances?

Opternative's Dr. Lee emphasizes

space. “In glaucoma, I think a lot of the tests are things that patients could do at one location, but that could be read remotely by a physician,” she says, adding that she believes adoption of telehealth monitoring in glaucoma will take awhile, since such visits are necessarily much more frequent than dilated eye exams.

She also thinks that some postoperative exams could one day take place remotely. “Elderly patients could benefit—populations such as cataract- surgery patients, or those who undergo lid surgery for purely functional ptosis,” says Dr. Nagori. “It’s hard for them to come back into the office repeatedly. There are a few appointments that obviously would be crucial, but maybe fewer than we currently think. Maybe after the first or second in-person postop visit, we could offer a telehealth solution that could allow some of the more elderly patients a chance to complete some of their postop visits remotely, provided they had uncomplicated surgery and they were going in the right direction on postop day one and postop day seven. Those are solutions that we haven’t built out yet, but we intend to keep looking at this space in health care.”

Dr. Lee also thinks that ocular telemedicine can go beyond online refractions. “Opternative is working on other telemedicine innovations surrounding eye health, including methods of monitoring glaucoma and macular degeneration on a more consistent basis,” he says.

At the 2018 American Society of Refractive and Cataract Surgery meeting last spring in Washington, D.C., Dr. Nagori was a keynote speaker on the future possibilities of telemedicine. She says she’s optimistic that online vision testing is just the beginning in ophthalmology and other specialties.

“We risk stratify in every other field of medicine,” she notes. “Not everyone needs a Pap smear every year; not everyone starts getting their colonoscopies at 40. We should be risk stratifying in ophthalmology as well. We should allow those patients who are on the safer end of the spectrum to do certain things from the convenience of their homes, and we should find solutions that are not only more accessible, but also more affordable. As long as it’s safe, I think patients should have the freedom to make choices in their health care.” **REVIEW**

1. AAO PPP Committee, Hoskins Center for Quality Eye Care. Comprehensive adult medical eye evaluation—2015. Available at <https://www.aaao.org/preferred-practice-pattern/comprehensive-adult-medical-eye-evaluation-2015>. Accessed July 19, 2018.

2. U.S. Food and Drug Administration. Warning letter, Re: On-line Opternative eye examination mobile medical app device. October 30, 2017. Available at <https://www.fda.gov/iceci/enforcementactions/warningletters/2017/ucm600029.htm>. Accessed June 29, 2018.

3. American Academy of Ophthalmology. American Academy of Ophthalmology provides information to the public on online vision testing for corrective eyeglass prescriptions. September 22, 2015. Available at <https://www.aaao.org/newsroom/news-releases/detail/american-academy-of-ophthalmology-provides-informa>. Accessed July 3, 2018.

NuLids™ transformational dry eye therapy

Transforms your practice

The NuLids System helps reduce patient out-of-pocket expenses while creating an additional revenue stream for the practice – all without impacting overhead costs or disrupting other in-office treatments.

A multi-center study¹ showed 95% were satisfied or very satisfied with the treatment.

For more information visit
www.NuSightMedical.com/rophi8
or call us at 833-468-5437

¹ Schanzlin, Olkowski, Coble, Gross. NuLids II Study, April 2018



NuLids™

Doctor prescribed, at-home dry eye relief





New Mid-year CPT Codes

This mid-year release comes with two Category III codes that practices need to be aware of.

One of the less-well-known aspects of codes and coding is that CPT codes are actually released twice a year. Category I codes are what we know best, and those are released annually on January 1. Category III codes are released twice a year—on both January 1 and July 1. This July, there are two Category III codes (0506T and 0507T) affecting eye care that practitioners and practices should be aware of.

Q What is code 0506T?

A New category III code 0506T has the following code descriptor: “Macular pigment optical density measurement by heterochromatic flicker photometry, unilateral or bilateral, with interpretation and report.” The code can’t be used for reimbursement, but it’s used for research. There is at least one new instrument just on the market that measures the macular pigment optical density in just this way. The macular pigments zeaxanthin, lutein, and the metabolite meso-zeaxanthin in the retina shield it from damage related to short-wavelength, high-energy, visible blue light (400-495 nm). Such damage contributes to

the development of age-related macular degeneration. Measurement of MPOD over time can assess whether dietary changes and/or antioxidant supplementation may diminish the harmful effects. The National Eye Institute predicted a 50-percent increase in AMD in the U.S. population between 2004 and 2020.

Note that the code is used once whether one or both eyes are measured and requires an interpretation and report.

Q What is heterochromic flicker photometry?

A In the one device available now for MPOD measurement (others will likely be similar), the patient views a small circular stimulus that alternates between a blue wavelength (460 nm), and a green wavelength (540 nm), which are absorbed and not absorbed by the macular pigments, respectively. The patient sees a “flicker” when the macular pigment is saturated by the absorbed blue light and is instructed to press a response button at that moment. An MPOD measurement is then generated by the device.

Q What is code 0507T for?

A The code descriptor for 0507T is as follows: “Near-infrared dual imaging (i.e., simultaneous reflective and trans-illuminated light) of meibomian glands, unilateral or bilateral, with interpretation and report.” CPT also has a parenthetical note for this code, which states “For external ocular photography, use 92285. For tear film imaging, use 0330T.” Infrared imaging of the meibomian glands is currently available via a number of devices on the U.S. market.

As with the other July 1 code, this one is used one time whether one or both eyes are imaged and requires an interpretation and report.

Q Are there specifics regarding when these new codes can be used for Medicare?

A Yes. As mentioned above, both codes are for use as of July 1, 2018. Each of these codes has a “sunset” date of December 31, 2023. As a result, these can no longer be used as of January 1, 2024 unless they are

(Continued on page 59)

LOMBART PREMIUM LANE PACKAGE

LIMITED TIME OFFER

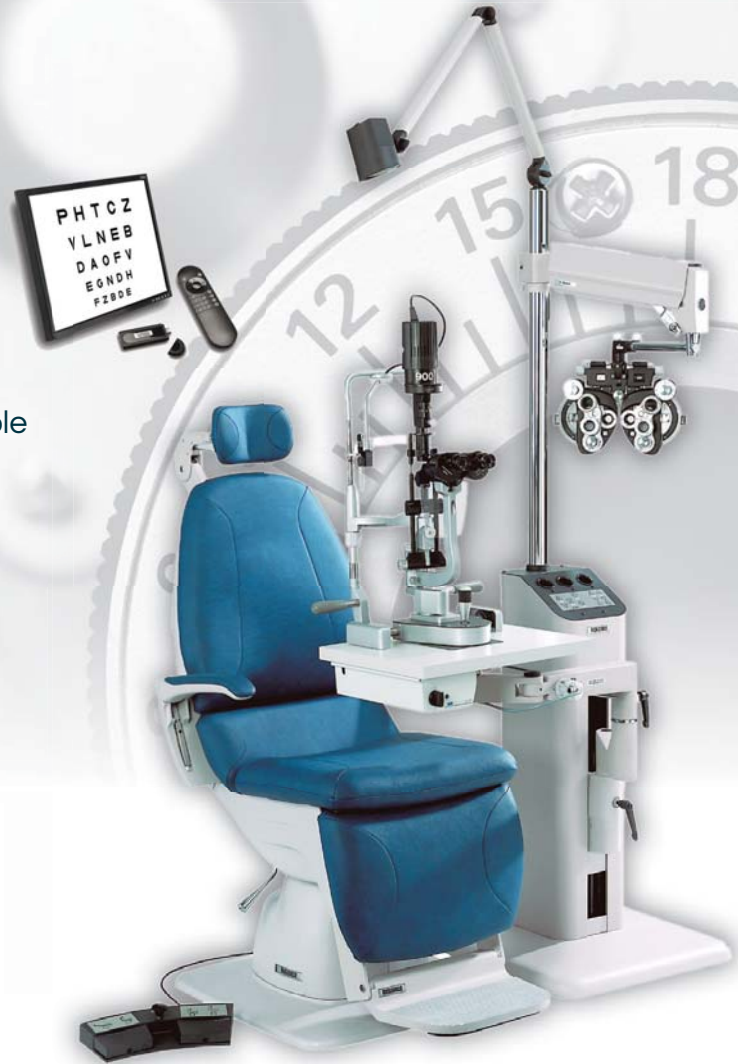\$28,990

SAVINGS OF \$3,277

- ✓ Reliance 7900 Instrument Stand with Console
- ✓ Reliance FX 920 Examination Chair
- ✓ Haag-Streit BM900 LED Slit Lamp
- ✓ Reichert Ultramatic RX Master Phoropter®
- ✓ Haag-Streit Tonometer
- ✓ Reliance Stool
- ✓ Lombart CVSe Acuity System

**ASK US ABOUT
QUICK DELIVERY!**

EXPIRES 8/31/18 | USE CODE: PREMIUM18



FREE Preventative Maintenance up to Two Years*

CALL US TODAY AT **1-800-LOMBART**

Wet AMD: When Your First-line Fails

Chirag P. Shah, MD, MPH, Boston

When an AMD patient fails to respond to your treatment, all is not lost, says this retinal specialist.

Anti-vascular endothelial growth factor therapy for wet age-related macular degeneration has been incredibly effective, as demonstrated both by large-scale clinical trials¹⁻⁴ and our real-world experience, with about 94 to 95 percent of patients losing fewer than 15 ETDRS letters after a year.¹ Our therapy for wet AMD may be a victim of its own success, however: The first-line anti-VEGF injections are so successful, there hasn't been a pressing need to perform large, randomized studies on how to properly treat the percentage of patients who fail their first anti-VEGF therapy. This leaves retinal specialists and comprehensive ophthalmologists with the task of developing their own protocols for second-line therapy via experience. In this article, I'll describe how I approach wet AMD patients who don't succeed with their initial therapy, and also review some of the pertinent literature.

Defining Suboptimal Response

To understand my second-line protocol, it helps to understand my initial treatment approach and how I define suboptimal responders.

My first anti-VEGF agent, used in almost all of my cases, is Avastin (bevacizumab). I start wet AMD

cases on Avastin for a few reasons: it tends to work well; it's inexpensive; it doesn't require preauthorization from the patient's insurance company; and my institution does not participate in the Lucentis (ranibizumab) and Eylea (aflibercept) sampling programs that allow on-label treatment at presentation. At the outset, I usually tell patients that I expect to see a steady improvement over time with their Avastin treatment. My clinical team will start the precertification process for Lucentis and Eylea during the first visit, so we know what our options are moving forward.

When the patient initially presents and is diagnosed with wet AMD, I always check an optical coherence tomography (OCT) scan and often get a baseline fluorescein angiogram. (I only have OCTA in one of my offices, but I suspect this technology will eventually replace fluorescein angiography for wet AMD.)

For the initial treatment, I use a treat-and-extend protocol in which I give the patient at least three to four monthly injections, without extending the interval, with the expectation that we'll see consistent improvement anatomically and, hopefully, visually. I continue to treat at four-week intervals until the retina is dry, and then I extend by two-week intervals. I use OCT

to follow the response to anti-VEGF treatment.

I monitor the patient's treatment response very carefully using registered OCT scans. If I see persistent fluid on OCT, particularly if it appears to be impacting the vision, I'll consider the patient a suboptimal responder to the drug. I expect to see consistent anatomic improvement; if I don't, even if it's only been one injection and the eye is noticeably worse or hasn't improved, I'll consider the response suboptimal.

The patient's visual acuity and symptoms play a significant role in my decision making. If the patient has a shallow sliver of subretinal fluid and is still 20/20 without symptoms, he may be a suboptimal responder, but I often do not feel compelled to change my treatment plan.

Occasionally, a patient is treated for some time with a particular drug, but eventually he or she will either begin to have a diminished response (tachyphylaxis) or the disease will get more aggressive—it's difficult to tell which of these two mechanisms is contributing to this effect. When this occurs, I consider the response suboptimal (though it may have been optimal previously) and I'll alter treatment.

Fallback Plans

If my first-line treatment fails and

I need to move on to something else, there are several options I consider. I will start by first switching the drug. If I don't achieve the desired response, I'll consider a higher dose of anti-VEGF, such as a double-dose of Eylea or Lucentis. Failing this, I sometimes consider anti-VEGF treatment every

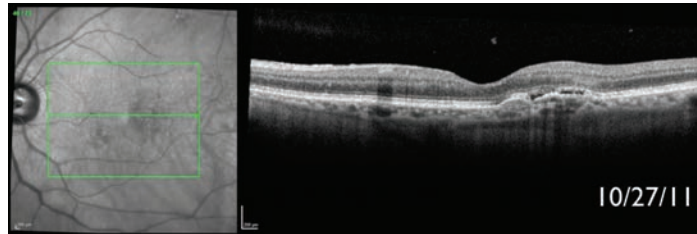
Eylea 2 mg and followed for six months. Of the 353 eyes, 28 eyes in 28 patients had persistent fluid after an average of 20 regular injections of Lucentis or Avastin (range: 7 to 37 injections). At one month after the first Eylea injection, 89 percent (25 eyes) showed anatomic improvement and 18 percent

two weeks instead of every four. Photodynamic therapy and, rarely, laser photocoagulation for extramacular choroidal neovascularization may also play roles.

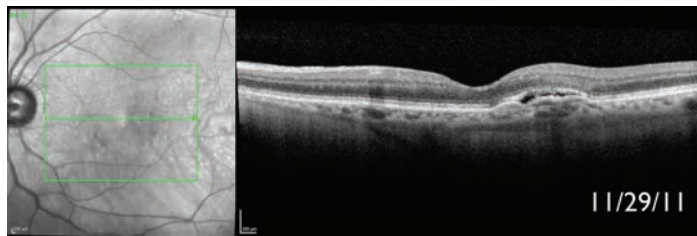
• **Switching drugs.**

Fortunately, we have three commonly used anti-VEGF drugs today—Avastin, Lucentis, and Eylea—with a fourth drug, brolicizumab, expected to hit the market in 2019. If a patient isn't responding to a particular drug, even after only one injection, I will switch to one of the other drugs in an effort to achieve a better response. Pharmacologically, Lucentis has a greater binding affinity for VEGF than Avastin, and Eylea has a greater binding affinity than Lucentis. It follows that these three drugs may result in varied responses among the most recalcitrant cases of wet AMD.

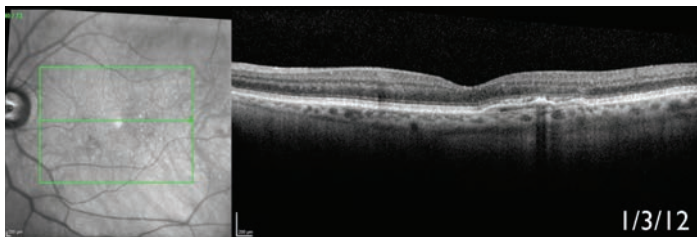
In our practice, we reported an enhanced response in refractory wet AMD cases switched to Eylea. We performed a retrospective study of 353 eyes with wet AMD who had persistent fluid despite being treated with Lucentis 0.5 mg or Avastin 1.25 mg and were subsequently switched to



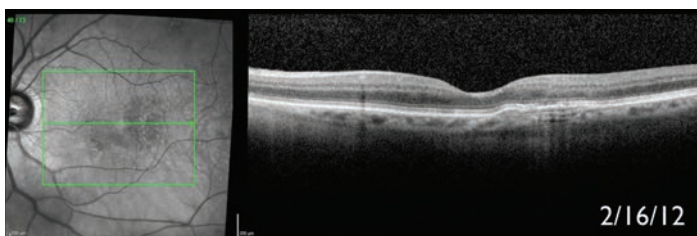
Persistent subretinal fluid despite intravitreal Avastin therapy (IVA). Shown here is the patient after IVA #37. Acuity is 20/20.



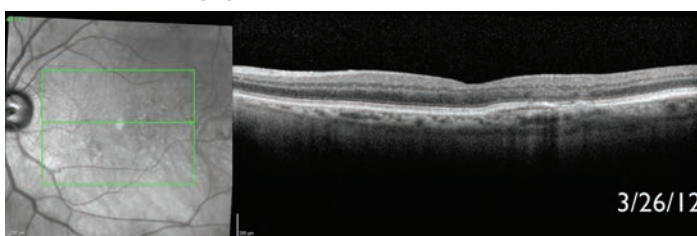
Persistent SRF in the same patient. First Eylea injection given. Vision 20/20.



Improved SRF. Eylea #2 given; vision remains 20/20.



Resolved SRF following Eylea #2. Vision is still 20/20.



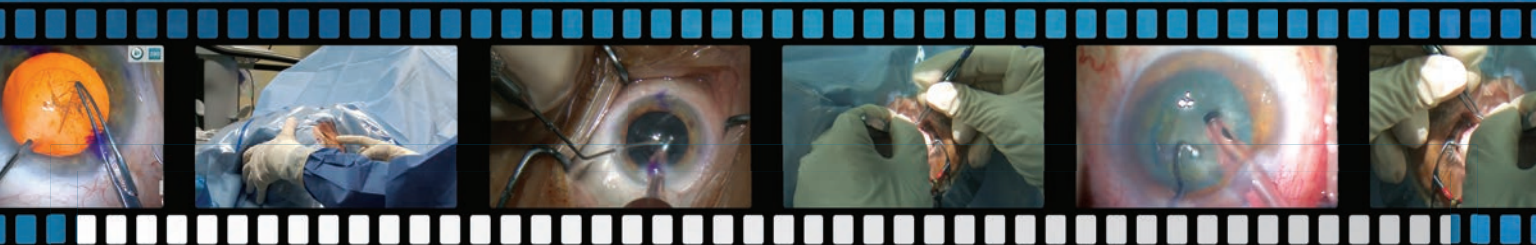
Stable, dry macula. Eylea #3 given. Vision is 20/20.



Monthly

MACKOOL ONLINE CME

CME SERIES | SURGICAL VIDEOS



To view CME video
go to:

www.MackoolOnlineCME.com

Episode 32: “Cataract, Vitreous Opacification and Zonular Weakness”

Surgical Video by:
Richard J. Mackool, MD

Video Overview:

For our viewers who have requested complexity, this one certainly fits the bill: a highly myopic eye with previous retinal detachment, scleral buckle and partial pars plana vitrectomy, residual anterior vitreous opacification, shallow anterior chamber, convex anterior capsule, extreme zonular weakness, infusion misdirection syndrome and 3 diopters of astigmatism requiring toric IOL implantation. Whew!

MackoolOnlineCME.com MONTHLY Video Series



Richard J. Mackool, MD

Welcome to the third year of Mackool Online CME! With the generous support of several ophthalmic companies, I am honored to have our viewers join me in the operating room as I demonstrate the technology and techniques that I have found to be most valuable, and that I hope are helpful to many of my colleagues. We continue to edit the videos into to either change camera perspective or to reduce down time – allowing you to observe every step of the procedure.

As before, one new surgical video will be released monthly, and physicians may earn CME credits or just observe the case. New viewers are able to obtain additional CME credit by reviewing previous videos that are located in our archives.

I thank the many surgeons who have told us that they have found our CME program to be interesting and instructive; I appreciate your comments, suggestions and questions. Thanks again for joining us on Mackool Online CME.



CME Accredited Surgical Training Videos Now Available Online: www.MackoolOnlineCME.com

Richard Mackool, MD, a world renowned anterior segment ophthalmic microsurgeon, has assembled a web-based video collection of surgical cases that encompass both routine and challenging cases, demonstrating both familiar and potentially unfamiliar surgical techniques using a variety of instrumentation and settings.

This educational activity aims to present a series of Dr. Mackool's surgical videos, carefully selected to address the specific learning objectives of this activity, with the goal of making surgical training available as needed online for surgeons motivated to improve or expand their surgical repertoire.

Learning Objective:

After completion of this educational activity, participants should be able to:

- Evaluate pre and intraoperative signs of zonule weakness
- Demonstrate removal of retrocapsular opaque vitreous
- Demonstrate injection and scleral fixation of a modified capsular tension ring by ab externo suturing
- Determine surgical treatment of infusion misdirection syndrome that was resistant to intracameral OVD injection

Satisfactory Completion - Learners must pass a post-test and complete an evaluation form to receive a certificate of completion. Your chosen sessions must be attended in their entirety. Partial credit of individual sessions is not available. If you are seeking continuing education credit for a specialty not listed below, it is your responsibility to contact your licensing/certification board to determine course eligibility for your licensing/certification requirement.



JOINTLY ACCREDITED PROVIDER™
INTERPROFESSIONAL CONTINUING EDUCATION

Physicians - In support of improving patient care, this activity has been planned and implemented by Amedco LLC and Postgraduate Healthcare Education. Amedco LLC is jointly accredited by the Accreditation Council for Continuing Medical Education (ACCME), the Accreditation Council for Pharmacy Education (ACPE), and the American Nurses Credentialing Center (ANCC), to provide continuing education for the healthcare team

Credit Designation Statement - Amedco designates this live activity for a maximum of .25 AMA PRA Category 1 Credits™. Physicians should claim only the credit commensurate with the extent of their participation in the activity.

Endorsed by:

Review of Ophthalmology®

Video and Web Production by:
JR Snowden, Inc

Jointly provided by:

AMEDCO & PHE

Supported by an unrestricted independent
medical educational grant from:

Alcon

Additionally Supported by:

**Glaukos
MST
Crestpoint Management
Carl Zeiss Meditec**

(five eyes) were dry. Central subfoveal thickness improved from 295 to 272 μm ($p < 0.001$). After an average of 4.4 Eylea injections (range: 3 to 6) over a period of six months, the central subfoveal thickness remained improved, 64 percent (18 eyes) showed anatomic improvement and a quarter of eyes (seven eyes) were dry. Visual acuity, however, didn't improve in most patients at one month (20/69, $p = 0.64$) or six months (20/76, $p = 0.49$).⁵

A prospective, open-label, single-arm clinical trial from Retina Consultants of Houston, funded by Regeneron, demonstrated a beneficial effect from switching to Eylea. Forty-six patients who were incomplete responders to multiple Lucentis injections were switched. They were seen monthly and given 2 mg Eylea at months one, two and four. *Pro re nata* treatment was administered at months three and five if there was evidence of disease on SD-OCT.

Before the Eylea treatment, the patients had a mean vision of 74 letters (20/32), and an average central subfield thickness of 347 μm . Their ETDRS letter score remained stable throughout the trial, and at month six the mean change in best-corrected vision was +0.2 letters (range: -10 to +13, $p = 0.71$). The mean CST decreased significantly at each visit, including -23.6 μm at the first month and -27.3 μm at month six. Seventy-one of 90 (79 percent) possible PRN injections were ultimately given, and a mean of 5.6 Eylea injections out of a maximum possible number of six were administered to each patient. Ten of the patients (22 percent) had no fluid on OCT at six months, and no patient lost more than 15 letters.⁶

Though some patients may respond to Eylea after incomplete response to either of the other two drugs, recent reports of inflammation after the use of Eylea give us pause. In a retrospective study we reported in 2014, we evaluated 20 cases of noninfectious

inflammation after Eylea injections. In our report, the overall rate of inflammation was low, 20 out of 5,356 injections (0.37 percent), and 19 out of 844 patients (2.25 percent). All patients presented with decreased vision; three (15 percent) had pain; and two (10 percent) had conjunctival injection.⁷ After topical steroids, all but one patient regained their pre-injection visual acuity. Four patients resumed Eylea injections, and one of them developed inflammation again after five injections. There was also a more recent nationwide cluster of inflammation cases after Eylea in late 2017 and early 2018. Regeneron attributed this outbreak to the syringes packaged with the drug.⁸ The company is no longer distributing kits with those particular syringes.

Switching to Lucentis is also an option, as it's an excellent drug with many clinical trials behind it that show good safety data. It also has the benefit of a prefilled syringe, and we recently presented an abstract at the annual meeting of the American Society of Retina Specialists that shows a lower rate of endophthalmitis with the Lucentis pre-filled syringe compared to the conventional Lucentis vial. This finding may be due to the reduced manipulation of withdrawing the drug from the vial.

In a retrospective study from Israel, physicians analyzed 114 eyes of 110 wet AMD patients who were switched from Avastin to Lucentis. Overall, the researchers say that switching didn't achieve a significant change in visual acuity, and that even though there was a significant reduction in central retinal thickness after the first three injections, it wasn't maintained by the end of the follow-up period. In 47.3 percent of the eyes, though, the mean central retinal thickness was reduced by at least 10 percent after the first three Lucentis injections and the reduction was maintained with additional injections. They note that eyes that lost at least 0.1 logMAR of visual acuity

before the switch were more likely to improve ($p = 0.013$) and eyes with at least a 10-percent increase in central retinal thickness before the switch were more likely to improve anatomically ($p = 0.0003$).⁹

• **Increasing the dose.** Physicians have also tried "super dosing" the anti-VEGF drugs for recalcitrant AMD cases. This is my preferred strategy when I don't achieve an adequate response from switching drugs. With Avastin, however, since it's compounded in individual syringes, it's difficult to get much more than 60 to 70 μl , which is only 10 to 20 μl more than the standard compounded dose. Thus, when I use a higher-dose drug, it is typically Lucentis 0.75 mg or 1 mg, or Eylea 3 mg or 4 mg.

In one retrospective, interventional case study, researchers first switched AMD patients unresponsive to monthly Lucentis or Avastin to Eylea 2 mg every eight weeks. If there was resistance to that, patients were escalated to every four weeks. If there still was no response, the dose was increased to 4 mg every four weeks. Thirty-three eyes of 28 patients were ultimately treated with 4-mg Eylea every four weeks, and followed for a mean of 16 months. Subjects had a dry retina (no intraretinal or subretinal fluid) after a mean of 3.8 months of Eylea 4 mg every four weeks. Central foveal thickness, maximum foveal thickness, intraretinal fluid, subretinal fluid and retinal pigment detachment height decreased significantly one month after initiating the 4-mg Eylea, and the researchers reported the morphologic therapeutic effect was sustained until the last visit. Forty-five percent of eyes gained at least a line of vision. New geographic atrophy developed in 9 percent of eyes during follow-up, but there were no ocular or systemic adverse events.¹⁰

Rather than switching to high-dose Eylea, one group instead treated recalcitrant cases with a higher dose (2 mg) of Lucentis in a prospective fashion.

The researchers split 88 patients into two groups: One group received the increased dose as-needed every four weeks (A), and another received it as-needed every six weeks (B). Seventy-nine patients completed the 12-month endpoint; they were given a mean of 11.6 (cohort A) and 8.6 (cohort B) treatments. Mean visual acuity gain over baseline was +2.5 letters at day seven (n=82), +3.7 letters at month one (n=87), +3.9 letters at month two (n=87) and +3.3 letters at month three (20/36 Snellen; $p=0.001$; n=86). The average BCVA gains of 4.1 letters following three monthly doses were sustained for a year in both cohorts. Anatomic improvements were sustained for 12 months for cohort A, but not for B, which demonstrated a gradual increase in mean central retinal thickness ($p=0.03$).^{11,12}

Interestingly, the HARBOR study found that outcomes with Lucentis 2 mg were similar to those with Lucentis 0.5 mg at two years in treatment-naïve patients.¹³

• **Modifying the dosing schedule.** If someone fails all three medications, I'll sometimes adjust the dosing schedule and treat him or her every two weeks instead of every four, in an attempt to achieve a better response. Due to insurance constraints, I'll typically alternate injections between Avastin and one of the other on-label drugs.

A retrospective study of 18 eyes with refractory wet AMD after a mean of 22 intravitreal anti-VEGF injections found improvement in visual acuity after four bi-weekly alternating Lucentis/Avastin intravitreal injections (20/95 to 20/65 [$p<0.001$]). The mean central foveal thickness also improved (455 μm to 387 μm [$p=0.029$]).¹⁴

• **Photodynamic therapy.** PDT can occasionally be a helpful adjunctive treatment modality to anti-VEGF injections for recalcitrant cases, or possibly in particular sub-classes of AMD. In our practice, if patients are still los-

ing vision and demonstrating persistent exudation despite very aggressive anti-VEGF treatment, we'll consider adding PDT.

In one paper, the Lucentis and PDT on polypoidal choroidal vasculopathy (LAPTOP) study, researchers randomized 93 patients with treatment-naïve polypoidal choroidal vasculopathy to receive either PDT or Lucentis monotherapy (0.5 mg) (three monthly injections) in a 1:1 ratio.¹⁵ Although the visual outcomes were better with Lucentis compared with PDT ($p=0.004$; month 24), PDT was able to induce regression of the PCV lesions.¹⁶

In another study, EVEREST, a Phase IV randomized, controlled trial that was the first to be primarily guided by indocyanine green angiography, researchers randomized 61 Asian patients to verteporfin PDT, Lucentis 0.5 mg or a combination of the two. Patients were administered verteporfin PDT/placebo and initiated with three consecutive monthly Lucentis/sham injections starting on day one, and were then re-treated (months three through five) based on predefined criteria. In the study, treatment with PDT plus Lucentis was superior to Lucentis alone for achieving regression of polyps at month six.¹⁷

• **Laser photocoagulation.** Anti-VEGF therapy is the standard of care for wet macular degeneration, but thermal laser occasionally plays a role for extramacular or peripapillary choroidal neovascularization. I will almost always start these patients on anti-VEGF therapy, to which they usually respond well. For cases that continue to progress, however, laser can be a useful adjunct. Of course, it's critical to avoid the fovea and perifoveal area to prevent a symptomatic scotoma (and also possible future choroidal neovascularization). When photocoagulation is an option—and when it works—it can help decrease the injection burden for patients, and potentially decrease the frequency of visits.

• **In the pipeline: brolocizumab and Cosopt.** Brolocizumab is a new anti-VEGF drug targeting VEGF A that's currently in trials. Its maker, Novartis, hopes that the drug may be able to demonstrate efficacy comparable to q8w Eylea but with q12w dosing. In the studies HAWK and HARRIER, just over half the brolocizumab patients were able to use that dosing regimen and still experience good efficacy.¹⁸ (For a complete discussion of brolocizumab and other agents in the pipeline, see this month's article, "The nAMD Pipeline: Full but Not Fast," on p. 38).

For wet-AMD eyes that have persistent exudation despite fixed-interval anti-VEGF injections, a pilot study from Wills Eye Hospital suggested that a combination of topical dorzolamide-timolol (Cosopt, Merck) and anti-VEGF injections might yield a beneficial effect. In the study, 10 eyes of 10 patients received a regimen of Cosopt b.i.d. and the same intravitreal injection of anti-VEGF, on the same schedule, that they were receiving before the study. Eight eyes received Eylea and two received Lucentis. The mean CST decreased from 419.7 μm at enrollment to 334.1 μm at the final visit ($p=0.01$). The mean maximum subretinal fluid height decreased from 126.6 μm at baseline to 49.5 μm at the final visit ($p=0.02$), and the mean maximum pigment epithelial detachment height decreased from 277.4 μm at enrollment to 239.9 μm ($p=0.12$). The mean logMAR visual acuity was 0.54 (a little worse than 20/63) at enrollment and 0.48 (slightly better than 20/63) at the final visit ($p=0.60$).¹⁹

Because of the success of this pilot study, several other researchers and I are conducting a larger-scale study using the same drug. In the study, subjects are randomly assigned to receive Cosopt or placebo along with their normally scheduled anti-VEGF injections at regular intervals as was done prior to enrollment. We're currently



enrolling patients in the study.

Though the mechanism behind Cosopt's possible positive effect is unknown, it may have to do with how intravitreal anti-VEGF drugs are cleared from the eye. Some studies have suggested that outflow through the anterior chamber may play a role. The hypothesis is that, by decreasing aqueous production with Cosopt, outflow may also be reduced, possibly slowing the rate at which the anti-VEGF is cleared. This may allow the latter drug a longer working time.²⁰

In conclusion, though anti-VEGF drugs have revolutionized the treatment of wet AMD, like driving on a straight road, we must often make adjustments along the way. There is minimal level-one evidence to guide us when treating sub-optimal responders to anti-VEGF monotherapy. I hope this review of current strategies helps you face these challenging cases with greater confidence. **REVIEW**

Dr. Shah practices at Ophthalmic Consultants of Boston. He is an assistant professor of ophthalmology at Tufts University School of Medicine in Boston, a lecturer at Harvard Medical School, and the co-director of the Tufts/OCB Vitreoretinal Surgery Fellowship Program.

Dr. Shah is a sub-investigator in clinical trials sponsored by Regeneron and Genentech, and consults for Regeneron.

1. The CATT Research Group. Ranibizumab and bevacizumab for neovascular age-related macular degeneration. *N Engl J Med* 2011;364:1897-1908.
2. Brown DM, Kaiser PK, Michels M, Soubrane G, Heier JS, Kim RY, et al. Ranibizumab versus verteporfin for neovascular age-related macular degeneration. *N Engl J Med*. 2006;355:1432-44.
3. Rosenfeld PJ, Brown DM, Heier JS, Boyer DS, Kaiser PK, Chung CY, et al. Ranibizumab for neovascular age-related macular degeneration. *N Engl J Med*. 2006;355:1419-31.
4. Heier JS, Brown DM, Chong V, Korobelnik JF, Kaiser PK, Nguyen QD, et al. Intravitreal aflibercept (VEGF trap-eye) in wet age-related macular degeneration. *Ophthalmology*. 2012;119:2537-48.
5. Cho H, Shah CP, Weber M, Heier JS. Aflibercept for exudative AMD with persistent fluid on ranibizumab and/or bevacizumab. *Br J Ophthalmol*. 2013 Aug;97:8:1032-5.
6. Wyckoff CC, Brown DM, Maldonado ME. Aflibercept treatment for patients with exudative age-related macular degeneration who were incomplete responders to multiple ranibizumab injections (TURF trial). *Br J Ophthalmol* 2014;98:7:951-5.
7. Goldberg RA, Shah CP, Wiegand TW, Heier JS. Noninfectious inflammation after intravitreal injection of aflibercept: clinical characteristics and visual outcomes. *Am J Ophthalmol* 2014;158:4:733-737.
8. <https://ncp.eylea.us/media/foi.pdf>. Accessed 10 July 2018.
9. Moisseiev E1, Katz G, Moisseiev J, et al. Switching treatment for neovascular age-related macular degeneration from bevacizumab to ranibizumab: Who is likely to benefit from the switch? *Retina* 2015;35:7:1323-30.
10. You QS, Gaber R, Meshi A, et al. High-dose high-frequency aflibercept for recalcitrant neovascular age-related macular degeneration. *Retina* 2018;38:6:1156-1165.
11. Wyckoff CC, Brown DM, Chen E. SAVE (Super-dose anti-VEGF) trial: 2.0 mg ranibizumab for recalcitrant neovascular age-related macular degeneration: 1-year results. *Ophthalmic Surg Lasers Imaging Retina* 2013;44:2:121-6.
12. Brown DM, Chen E, Mariani A, Major JC; SAVE Study Group. Super-dose anti-VEGF (SAVE) trial: 2.0 mg intravitreal ranibizumab for recalcitrant neovascular macular degeneration-primary end point. *Ophthalmology* 2013;120:2:349-54.
13. Ho AC, Busbee BG, Regillo CD, Wieland MR, Van Everen SA, Li Z, Rubio RG, Lai P; HARBOR Study Group. Twenty-four-month efficacy and safety of 0.5 mg or 2.0 mg ranibizumab in patients with subfoveal neovascular age-related macular degeneration. *Ophthalmology* 2014;121:11:2181-92.
14. Witkin AJ, Rayess N, Garg SJ, Maguire JL, Storey P, Kaiser RS, Hsu J, Vander JF, Ho AC. Alternating bi-weekly intravitreal ranibizumab and bevacizumab for refractory neovascular age-related macular degeneration with pigment epithelial detachment. *Semin Ophthalmol* 2017;32:3:309-315.
15. Oishi A, Kojima H, Mandai M, Honda S, Matsuoka T, Oh H, et al. Comparison of the effect of ranibizumab and verteporfin for polypoidal choroidal vasculopathy: 12-month LAPTROP study results. *Am J Ophthalmol*. 2013;156:644-51.
16. Oishi A, Miyamoto N, Mandai M, Honda S, Matsuoka T, Oh H, et al. LAPTROP study: A 24-month trial of verteporfin versus ranibizumab for polypoidal choroidal vasculopathy. *Ophthalmology* 2014;121:1151-2.
17. Koh A, Lee WK, Chen LJ, Chen SJ, Hashad Y, Kim H, et al. EVEREST study: Efficacy and safety of verteporfin photodynamic therapy in combination with ranibizumab or alone versus ranibizumab monotherapy in patients with symptomatic macular polypoidal choroidal vasculopathy. *Retina*. 2012;32:1453-64.
18. Dugel PU, Jaffe GJ, Sallstig P, et al. Brolucizumab versus aflibercept in participants with neovascular age-related macular degeneration: A randomized trial. *Ophthalmology* 2017;124:1296-1304.
19. Sidhar J, Hsu J, Shahlaee A. Topical dorzolamide-timolol with intravitreal anti-vascular endothelial growth factor for neovascular age-related macular degeneration. *JAMA Ophthalmol* 2016;134:4:437-43.
20. <https://www.centerwatch.com/clinical-trials/listings/190529/neovascular-age-related-macular-degeneration-dorzolamide-timolol-combination-anti-vascular-endothelial/>. Accessed 11 July 2018.

THE RICK BAY FOUNDATION

for Excellence in Eyecare Education

www.rickbayfoundation.org

Support the Education of Future Healthcare & Eyecare Professionals

Scholarships will be awarded to advance the education of students in both **Optometry** and **Ophthalmology**, and will be chosen by their school based on qualities that embody Rick's commitment to the profession, including integrity, compassion, partnership and dedication to the greater good.

About Rick

Rick Bay served as the publisher of *The Review Group* since 1991.

To those who worked for him, he was a leader whose essence was based in a fierce and boundless loyalty.




To those in the industry and the professions he served, he will be remembered for his unique array of skills and for his dedication to exceeding the expectations of his customers, making many of them fast friends.

Interested in being a partner with us?

Visit www.rickbayfoundation.org

(Contributions are tax-deductible in accordance with section 170 of the Internal Revenue Code.)



THE RICK BAY FOUNDATION

for Excellence in Eyecare Education

(The Rick Bay Foundation for Excellence in Eyecare Education is a nonprofit, tax-exempt organization under section 501(c)(3) of the Internal Revenue Code.)

OCT Before Cataract Surgery: Not Optional

Steve Charles, MD, FACS, FIC, Memphis, Tenn.

This technology can reveal retinal problems that will otherwise be attributed to your surgery, argues this surgeon.

There's no question that optical coherence tomography has had a profound impact on the field of ophthalmology. However, many surgeons still hesitate to use it unless it seems necessary.

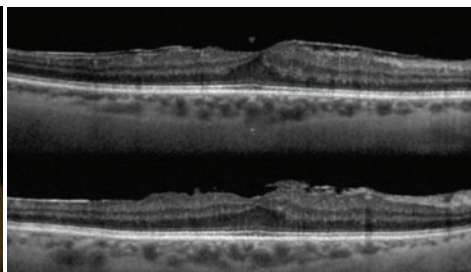
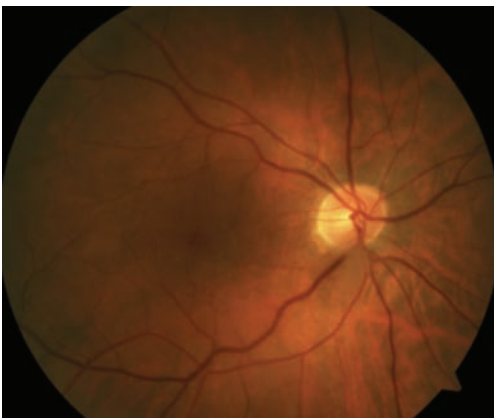One situation in which OCT is used infrequently is prior to cataract surgery on seemingly healthy patients. That may be a tactical error. It's common to hear doctors talk about "refractive surprises" when discussing ways to improve cataract surgery outcomes. However, sometimes a poor outcome isn't attributable to a refractive error; that's why I've coined the phrase "visual surprises." Visual surprises caused by macular problems that you failed to detect are just as upsetting to the patient as refractive surprises.

And while you can do a postoperative IOL exchange, you can't do a macular exchange.

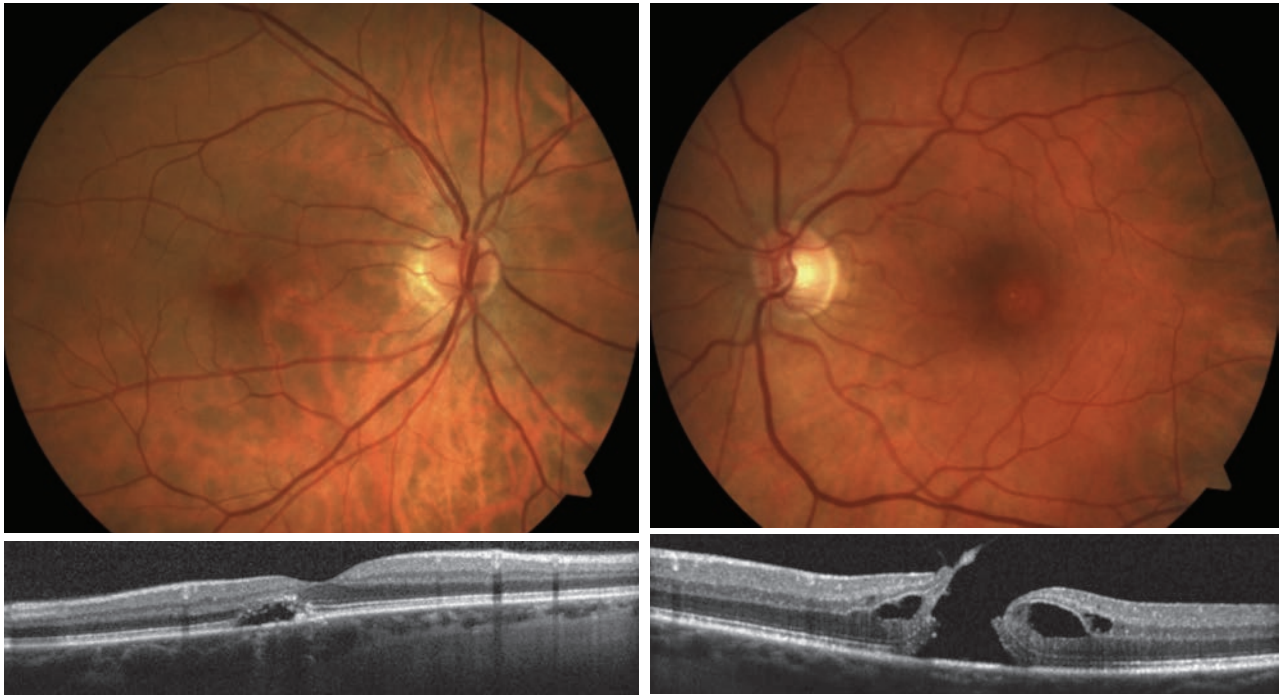
Performing an OCT scan of the retina is quick, safe and easy on the patient and staff, and there are many ways in which surgeons and patients stand to benefit from making the effort. Here are a few key reasons to use OCT to check the retina on every patient prior to cataract surgery.

- **Many retinal pathologies can only be detected with spectral-domain OCT.** Many types of retinal pathology are simply invisible through a microscope. Examples include: central serous retinopathy; vitreomacular traction syndrome; vitreomacular schisis; transparent epiretinal membranes; and some wet macular degeneration that hasn't bled and doesn't have any obvious choroidal neovascularization. These are invisible without an OCT scan. (In addition, the presence of the cataract may increase the difficulty of visualizing the condition of the macula.)

- **If you missed a problem, everyone will assume your surgery caused it.** If you find pathology in the macula or



Spectral-domain OCT can reveal macular problems that are otherwise invisible—problems that will be blamed on the cataract surgery if not caught beforehand. Here, a pre-existing epimacular membrane is revealed by OCT.



Above, left: Pigment epithelial detachment. Right: A full-thickness macular hole.

the peripheral retina before cataract surgery—particularly in the macula—it’s called a pre-existing condition. That’s how everyone, including the patient, will think of it. But regardless of the cause of that pathology, if it’s found after cataract surgery, it will be considered a complication—by the patient, by the referring optometrist and everyone else. That will be the case even if your cataract surgery didn’t cause it.

• ***In most cases, cataract surgery isn’t being performed by a retinal specialist.*** If you’re not a retina specialist, you’re less likely to be checking carefully for retinal problems that aren’t obvious. You’ll also have less training and knowledge of macular disease.

• ***Most preoperative exams are done in a hurry, with the focus on getting the refractive error correction right.*** The problem is: What if you make every possible measurement and the refractive outcome is perfect, but the patient can’t see well? That patient is not going to be happy. This is almost certain to happen to at least a

few of your cataract surgery patients if you don’t use OCT before surgery.

• ***Patient expectations are at an all-time high.*** Small-incision refractive cataract surgery, femto, wavefront technology, intraoperative aberrometry, new technology IOLs, LASIK and marketing have raised patient’s postop visual expectations. If your patient has visual difficulty after your cataract surgery in this environment, he or she will be very unhappy indeed.

Making the Most of OCT

To get the most benefit from OCT in this situation, I recommend using the following strategies:

• ***Use OCT before cataract surgery for EVERY patient—not just premium IOL patients.*** When I first began suggesting the use of OCT to examine patients before cataract surgery, surgeons would come up to me at meetings and say, “Oh, you mean for premium IOL patients.” I’d say, “No, I mean for all patients.” This is about creating satisfied patients who can see

well. Is that only an issue if the patient is paying extra? Surgeons would also ask who’s going to pay for it, and I’d point out that there’s no unit cost when using OCT. Then they’d ask, “How will we bill for this?” The truth is, I don’t know the answer to that question and I honestly don’t care. If you want to serve the patient and you want good outcomes, you need to examine the macula with OCT.

• ***Don’t do this using time-domain OCT.*** Time-domain OCT is obsolete. Spectral-domain or swept-source OCT is essential if you want to detect these vision-undermining pathologies.

• ***Don’t withhold OCT until something looks wrong at the slit lamp.*** Many surgeons don’t do an OCT unless the slit-lamp exam suggests that something is amiss. Since the pathologies we’re discussing can’t be detected during a slit-lamp exam, that’s a very bad premise. Even if you’re only dealing with a 1+ cataract, and you’re the world’s best retina expert looking with a 90-D lens at the slit lamp, a number of retinal pathologies will be invisible



SAVE THE DATE



OCTOBER 12-13, 2018

CSE GLAUCOMA FELLOWS

Fort Worth, Texas

Dear Fellowship Program Director and Coordinator,

We would like to invite you to review the upcoming 2018 Glaucoma Fellowship Program and Wet Lab in Fort Worth at the Renaissance Worthington hotel. The program offers a unique educational opportunity for fellows by providing the chance to meet and exchange ideas with some of the most respected thought leaders in glaucoma. The Glaucoma Fellows Program and Wet Lab is designed to provide your fellows with a state-of-the-art didactic and wet lab experience. The program also serves as an opportunity for your fellows to network with fellows from other programs.

After reviewing the material, it is our hope that you will select and encourage your fellows to attend this educational activity which is CME accredited to ensure fair balance.

Sincerely,
Postgraduate Healthcare Education

Course Director:

Kuldev Singh, MD
Stanford, CA

Wet Lab Directors:

Douglas J. Rhee, MD
Cleveland, OH

Ronald Fellman, MD
Dallas, TX

Faculty:

Lee Alward, MD	Brian Flowers, MD	Marlene Moster, MD	Arthur Sit, MD
Donald Budenz, MD	Steven Gedde, MD	Kelly Muir, MD	George Spaeth, MD
Joseph Caprioli, MD	Dale Heuer, MD	Pradeep Ramulu, MD	Josh Stein, MD
	Michele Lim, MD	Joel Schuman, MD	

For More Information & to Register:
www.revophth.com/2018cseglaucoma

Email: dholmes@postgradhealthed.com or call Denette Holmes 866-627-0714

Participants in this course must be enrolled in a glaucoma fellowship program at the time of the course. There is no registration fee for these activities. Air, ground transportation in Dallas Fort Worth Airport, hotel accommodations and modest meals will be provided through an educational scholarship for qualified participants.

Satisfactory Completion - Learners must pass a post-test and complete an evaluation form to receive a certificate of completion. Your chosen sessions must be attended in their entirety. Partial credit of individual sessions is not available. If you are seeking continuing education credit for a specialty not listed below, it is your responsibility to contact your licensing/certification board to determine course eligibility for your licensing/certification requirement.



JOINTLY ACCREDITED PROVIDER™
INTERPROFESSIONAL CONTINUING EDUCATION

Physicians - In support of improving patient care, this activity has been planned and implemented by Amedco LLC and Postgraduate Healthcare Education. Amedco LLC is jointly accredited by the Accreditation Council for Continuing Medical Education (ACCME), the Accreditation Council for Pharmacy Education (ACPE), and the American Nurses Credentialing Center (ANCC), to provide continuing education for the healthcare team

Credit Designation Statement - Amedco designates this live activity for *AMA PRA Category 1 Credits™*. Physicians should claim only the credit commensurate with the extent of their participation in the activity.

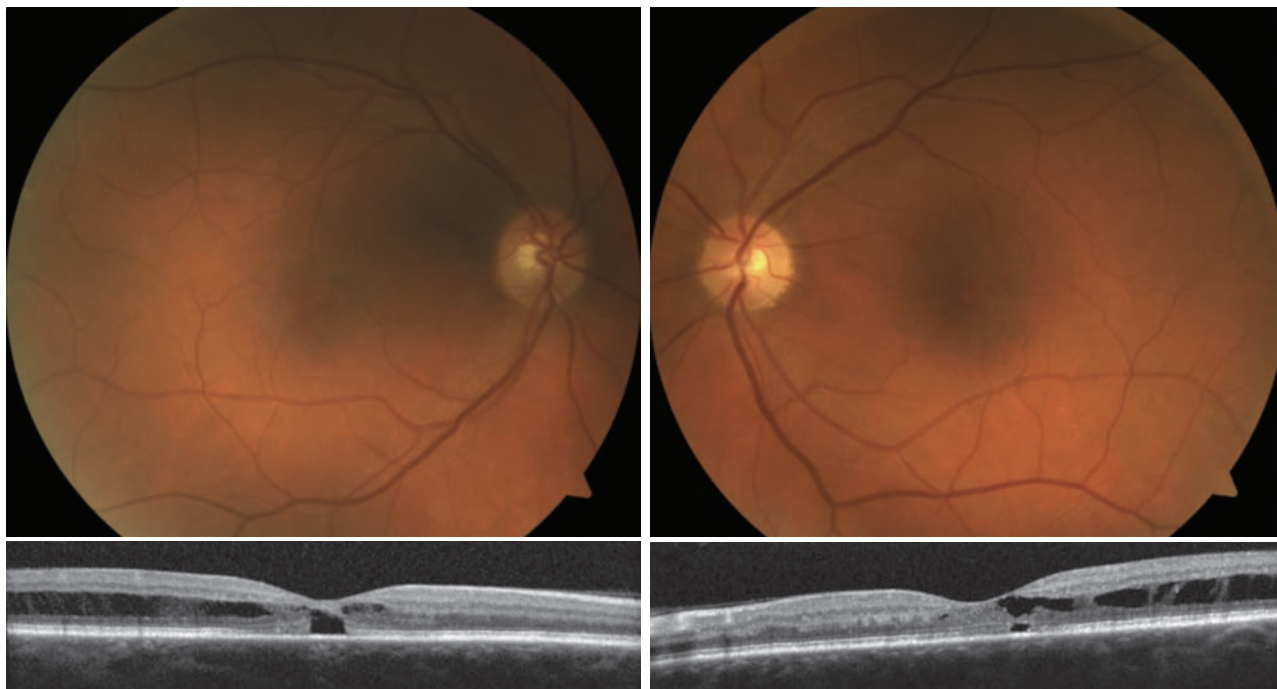
Jointly provided by

Endorsed by
Review of Ophthalmology®



Supported by an unrestricted independent
medical educational grant from

Alcon



Two examples of macular telangiectasia (Mac Tel) with macular schisis.

to you without OCT.

- **Beware of fragmentation between the operating surgeon and the preoperative examiner.** If you don't do the preop exam yourself, be sure that the doctor doing it scans the macula with OCT.

- **Never use pseudo-color algorithms (i.e., color encoding), thickness maps or 3-D maps.** This is not corneal topography. The aforementioned maps are generated using auto-segmentation algorithms, and the error rate is astronomical. The process of rendering them can cause crucial signs of pathology to be hidden.

- **Look at every black-and-white slice yourself.** I often hear surgeons say, "My EMR system allows the technician to import an image"—i.e., one image. If you're doing this for diagnostics—as opposed to just for billing—you need to look at every slice of that scan yourself. Think of it this way: If you're having a terrible headache and you go to the ER, do you want the X-ray technician to pick one film image and send it to the neuroradiologist to

determine whether you have an aneurysm? Or do you want to have him look at all of the slices by scrolling up with his thumbwheel on the mouse?

If you want to be sure there's no pathology present, look at every image yourself, using white images on a black background.

The Retina Factor

Here are a few other useful points to keep in mind when examining a patient before cataract surgery, and when working to avoid retina issues intraoperatively:

- **If at all possible, measure axial length with optical low-coherence interferometry rather than ultrasound.** If you have any macular pathology that causes elevation of the macula, such as fluid under the retinal membrane, macular edema, schisis or vitreomacular traction syndrome, the axial length measured by ultrasound will be inaccurate because the macula will appear to be forward of where it really is, causing an underestima-

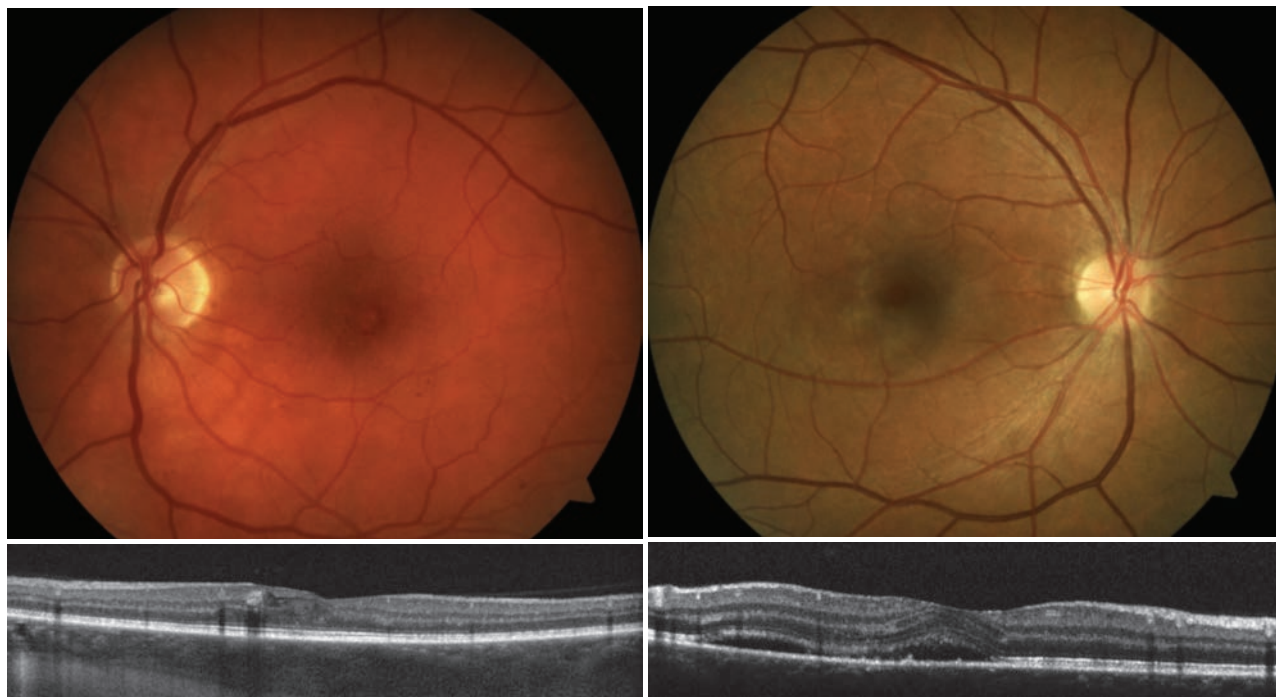
tion of the true axial length. If possible, measure the axial length with the Haag-Streit Lenstar or the Zeiss IOLMaster, which use optical low-coherence interferometry. They measure from the pigment epithelium, not the surface of the retina.

- **Use the best tools when you're examining at the slit lamp.** To maximize your ability to catch a problem at the slit lamp:

- Use a 78- to 90-D lens.
- The optimal view will be achieved if you use a plano fundus contact lens with anti-reflective coating.
- Blue-light autofluorescence is optimal for visualizing geographic atrophy in macular degeneration and cases of pre-existing central serous retinopathy.

Tools that are less helpful for macular evaluation before cataract surgery include angiography and ultra-wide-field imaging, which has inadequate resolution for this purpose.

Be sure to dilate the eye and perform a careful examination of the peripheral retina using indirect oph-



Left: Early nonproliferative diabetic retinopathy. Right: Central serous chorioretinopathy. Macular serous detachment is more pronounced when visualized on OCT.

thalmoscopy. Refer the patient to a retinal specialist if you find anything suspicious.

- **Don't interrupt the patient's anti-VEGF injection schedule because of cataract surgery.** There's no longer any reason to try to "stabilize" diabetic macular edema, wet AMD or retinal vein occlusion before cataract surgery. The surgery and the anti-VEGF protocol should proceed in parallel.

- **Schedule cataract surgery midway between anti-VEGF injections.** For example, if the patient is receiving injections on the first of the month, schedule the cataract surgery for the 15th of the month. Why? Because if you have an inflammatory response—or worse yet, endophthalmitis or hemorrhagic occlusive retinal vasculitis (HORV)—and you did the injection on Monday and the cataract surgery on Tuesday, from an epidemiology perspective, you won't know which caused the inflammation or endophthalmitis. It's far better to sepa-

rate them by doing the cataract surgery midway between the injections. If any problem occurs, it will be clear where to look for the explanation.

- **If you find any macular disease, avoid implanting a multifocal IOL.** Multifocal IOLs decrease contrast sensitivity and should be avoided in most patients with any macular disease. This includes patients with significant drusen (intermediate drusen or placoid drusen), hyperpigmentation and/or wet macular degeneration. The risk of geographic atrophy and neovascular macular degeneration increases with each decade of aging. For that reason, placing a multifocal IOL in a healthy 55-year-old with intermediate drusen is not a good idea.

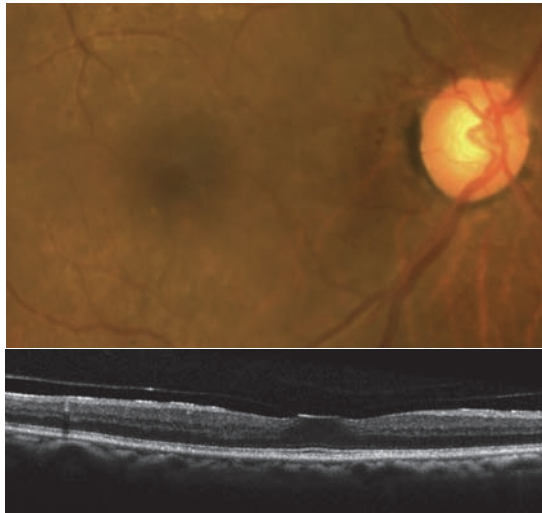
- **Don't confuse the presence of drusen with macular degeneration.** Because of the way billing and coding works, there's a tendency for doctors to tell patients that they have macular degeneration when in fact they just have drusen. That's like telling every fair-skinned Swede that he

has a melanoma. Yes, the presence of drusen does have consequences, but those consequences don't necessarily include macular degeneration. Drusen don't cause macular degeneration; they are simply associated with it. It's far better to tell such a patient that he's *at risk* for AMD, not that he has AMD. (For what it's worth, a finding of many large, placoid, confluent drusen indicates a greater risk than finding a few fine drusen. Also, drusen in the macula are of much more concern than extramacular drusen.)

Of course, if your patient is 50 years old and has a lot of drusen, you definitely should not implant a multifocal IOL that's going to decrease contrast sensitivity in that eye. But don't make the mistake of telling the patient that he has age-related macular degeneration just because you find drusen on the retina.

- **Don't worry about cataract surgery making macular degeneration or diabetic macular edema worse.** There is no relationship between post-

cataract-surgery CME and AMD, DME or epimacular membranes. You shouldn't modify your strategy for preventing CME because you find drusen, or because the patient has macular degeneration or an epimacular membrane. The only patients who need to be treated as being at high risk of CME are patients with inflammatory conditions such as pars planitis or sarcoid uveitis.



Vitreomacular adhesion with mild traction.

There was a time when many surgeons believed that cataract surgery caused macular degeneration to progress. But the Age-related Eye Disease Study showed that in more than 4,000 patients, cataract surgery did not make macular degeneration worse.¹ In addition, numerous people still believe that cataract surgery makes DME worse, but the evidence doesn't support that; cataract surgery just sometimes causes inflammatory cystoid macular edema that's interpreted as DME in a diabetic context. (Similarly, epimacular membranes do not cause more CME; the increase in thickness they can cause on OCT is sometimes misinterpreted as being CME. Also, vitreomacular traction syndrome does not make macular degeneration worse. They are unrelated conditions.)

• ***If the eye has an epimacular membrane, the order in which the surgeries are performed should depend on the grade of cataract.*** If the patient has a significant posterior subcapsular cataract of 3+ nuclear sclerosis, proceed with phaco and IOL implantation using the axial length—measured from the RPE—before performing macular surgery. If the eye has 1 to 2+ nuclear sclerosis, the macular surgery should be performed before the cataract surgery.

Better Safe than Sorry

“Refractive surprises” aren't the only reason you can end up with an unhappy patient after cataract surgery. Performing an OCT on every single patient preoperatively—not just premium IOL patients—will prevent “visual surprises.” Doing this is good for your patients and patient satisfaction, and there's no cost other than minor labor costs. Plus, it only takes a couple of minutes to accomplish. There's really no downside to it.

Then, if you find macular pathology—pathology you wouldn't otherwise have discovered—you can send the patient off for a proper retinal evaluation and treatment before you perform your cataract surgery. Preventing visual surprises will lead to a greater number of happy patients and better outcomes. So make a retinal OCT a standard part of your pre-cataract-surgery protocol. [REVIEW](#)

Dr. Charles is founder of the Charles Retina Institute in Memphis, and one of the world's leading vitreoretinal surgeons.

1. Foroughian F, Agrón E, et al; Age-Related Eye Disease Study Research Group. Visual acuity outcomes after cataract surgery in patients with age-related macular degeneration: Age-related eye disease study report no. 27. *Ophthalmology* 2009;116:11:2093-100.

S4OPTIK FULL POWERED

EXAMINATION CHAIR

2500-CH



**Powerful, precise,
automated.**

Choose the S4OPTIK 2500-CH Examination Chair for convenient, motorized reclining.

- KleenTech Lift System®
- Weight bearing armrests
- Robust footrest
- Precision engineered

S4OPTIK

250 Cooper Ave., Suite 100 Tonawanda NY 14150

www.s4optik.com | 888-224-6012

Sensible equipment. Well made, well priced.

For today's modern office.

The nAMD Pipeline: Full but Not Fast

By Kristine Brennan, Senior Associate Editor

Anti-VEGF therapies revolutionized treatment. Easing the burden and new targets are becoming fresh priorities.

Not long ago, patients diagnosed with neovascular age-related macular degeneration were limited to vitamin and mineral supplements, photodynamic therapy or laser photocoagulation. The advent of anti-vascular endothelial growth factor treatments has given many patients new hope. This hope comes at a cost, however: an often-lifelong treatment burden. Here, experts discuss what's in the pipeline with regard to anti-VEGFs, as well as some novel potential nAMD therapies.

Repackaging Anti-VEGF A

Michael W. Stewart, MD, professor and chair of ophthalmology at the Mayo Clinic Florida in Jacksonville, thinks it's important for surgeons to prioritize durability for the foreseeable future. "Since anti-VEGFs are the only thing we have right now, the duration of action is a big deal," he says. "Usually at the beginning, I tell my patients that this is a treatment, not a cure, and we're going to start off monthly and then we can determine the frequency, depending on how well they react to the drug. I try to set them up to expect that this is a long-term proposition, and we're going to see each other at some interval essentially forever."

Pravin U. Dugel, MD, managing partner at Retinal Consultants of Arizona and clinical professor at the Roski Eye Institute at the University of Southern California's Keck School of Medicine, says that the current treat-and-extend paradigm would be greatly aided by therapies that would reliably do any or all of the following: improve vision immediately; create lasting visual improvement over the long term; or have longer duration of action. "These are extremely variable diseases and some patients require very intense treatment. I have a few patients—thank goodness, only a few—who need treatment every two weeks. There are other patients who can be extended to every four months. The bottom line is that the labeling is not going to determine how we use a drug. But if we find a better anti-VEGF, I think there's definitely room for that, and we will definitely adopt it," he says.

"We basically have three drugs," he continues. "There's Avastin, which is compounded and not FDA-approved. We've got Lucentis, which is the one that we have the most experience with, and we have Eylea. All three have their pluses and minuses."

Two of the current anti-VEGF A's, Lucentis (Genetech; San Francisco) and Eylea (Regeneron; Tarrytown,

New York), are striving for enhanced therapeutic value through a new delivery system and relabeling, respectively.

Genentech says that its Ranibizumab Port Delivery System (RPDS) may ease the burden to patients, caregivers and health-care systems imposed by the current monthly intravitreal injection schedule for Lucentis. The RPDS is a refillable nanoparticle reservoir approximately the size of a grain of rice. The company says that implantation of the RPDS beneath the conjunctiva away from the visual axis takes less than 30 minutes. To refill the reservoir, a proprietary refill needle refreshes the Lucentis by putting in a new supply of drug while also draining any residual drug from the last fill.

Genentech says the RPDS is currently in Phase II studies (ClinicalTrials.gov Identifier: NCT02510794) to determine how long patients can go between refills. Results are tentatively expected before the end of the year. (At press time, initial results were to be presented at the ASRS meeting.)

First approved by the Food and Drug Administration in 2011 at a recommended dose of 2 mg intravitreally every eight weeks after three monthly loading doses, Eylea (aflibercept) was studied in the Phase III VIEW 1 and VIEW 2 trials,¹ in which patients were randomized into the following doses: 0.5 mg/month; 2 mg/month; 2 mg/two months of aflibercept (after monthly loading doses), or 0.5 mg/month of ranibizumab. All of the aflibercept groups were found to be noninferior (as measured by the proportion of patients losing 15 or fewer ETDRS letters at week 52) and clinically equivalent to the ranibizumab control. Based on re-evaluation of this data and subsequent research demonstrating the efficacy of treat-and-extend with Eylea in the ALTAIR study,² Regeneron submitted a supplemental biologics license application to the FDA for 12-week Eylea dosing. The decision date is August 11, 2018.

Peter Kaiser, MD, a retina specialist in the Department of Ophthalmology at the Cleveland Clinic's Cole Eye Institute, says, "Even though a fixed 12-week dosing arm was not included in either study, both the VIEW and ALTAIR studies offer strong and consistent clinical evidence that many patients with wet age-related macular degeneration treated with Eylea can maintain their vision gains with a 12-week dosing interval. If FDA-approved, the ability to administer Eylea every 12 weeks for wet AMD treatment would be welcome news for both ophthalmologists and patients."

Next-Gen Anti-VEGF A

New anti-VEGF A drugs may be coming down the pipeline that could have longer duration of action and/or better binding capabilities.

• **Brolucizumab.** Novartis (Basel, Switzerland) is preparing to bring brolucizumab (previously known as RTH258 and ESBA 1008), a humanized single-chain antibody fragment that inhibits VEGF A, to market. "Among the new anti-VEGF A drugs, brolucizumab is furthest along," says Dr. Dugel, who presented the results of Novartis' Phase III HAWK and HARRIER studies at the 2017 American Academy of Ophthalmology meeting.

HAWK and HARRIER were head-to-head, multicenter studies comparing 2 mg of aflibercept with 3 mg or 6 mg of intravitreal brolucizumab. All patients had three monthly loading doses, and were then assessed for disease activity at various pre-specified timepoints starting at week 16. If patients receiving brolucizumab were assessed by a masked investigator as having no disease activity, they were extended to q12-week dosing. The aflibercept group was dosed at q8-weeks after the three loading doses per label.

Based on this disease-activity assess-

S4OPTIK

LCD Visual Acuity System VA-1



Comprehensive Visual Acuity Solution

- Multiple optotype selections
- All acuity slides presented with ETDRS Spacing
- Contrast sensitivity testing
- Crowding bars (for pediatrics)
- Multimedia system and more!



S4OPTIK

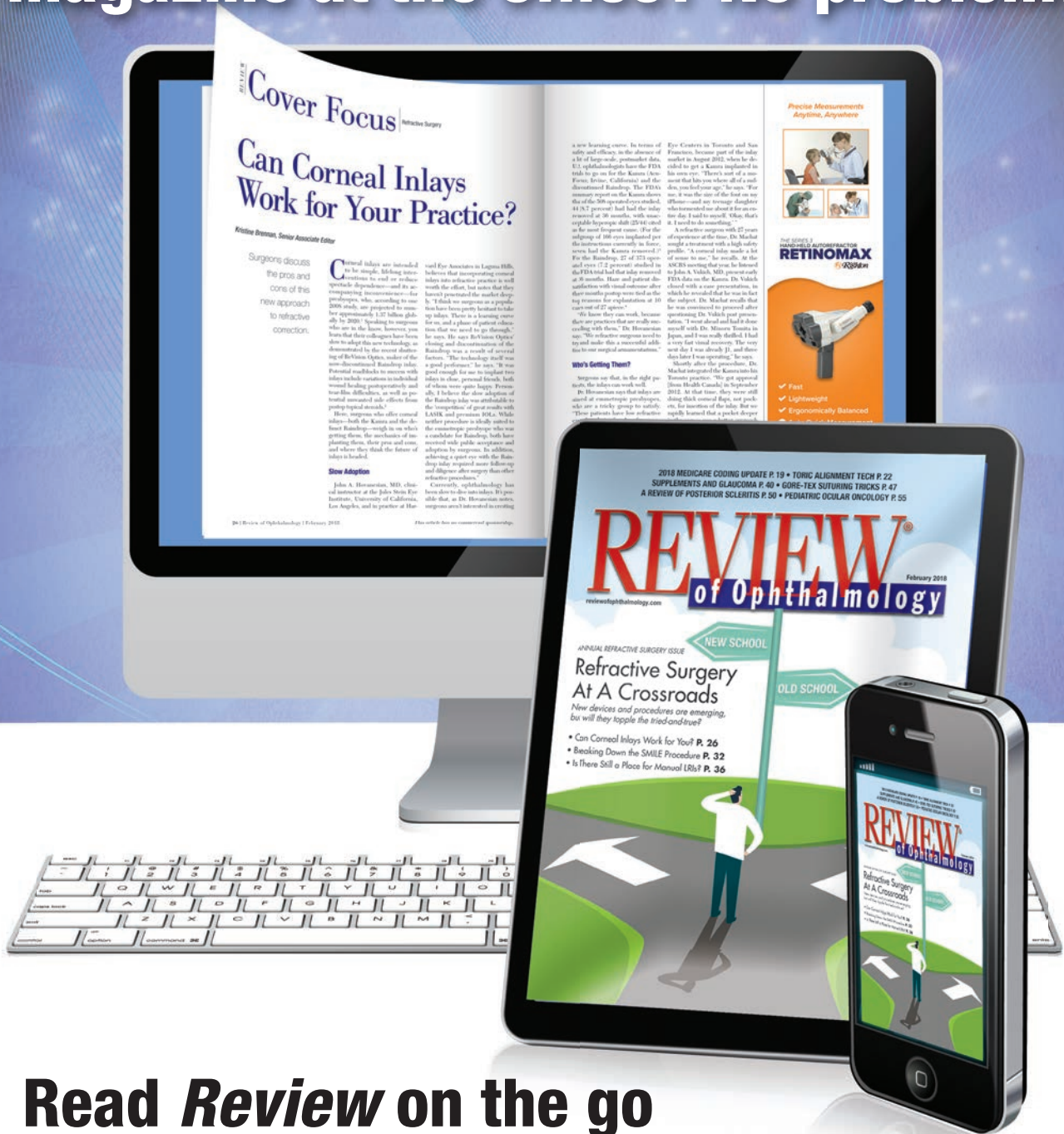250 Cooper Ave., Suite 100 Tonawanda NY 14150

www.s4optik.com | 888-224-6012

Sensible equipment. Well made, well priced.

For today's modern office.

Left your *Review of Ophthalmology* magazine at the office? No problem!



Read *Review* on the go from any mobile device!

Simply go to www.reviewofophthalmology.com and click on the digimag link to get your current issue.

ment, 57 percent of HAWK patients and 52 percent of HARRIER patients on brolicizumab 6 mg were extended to q12-week dosing up to week 48.³

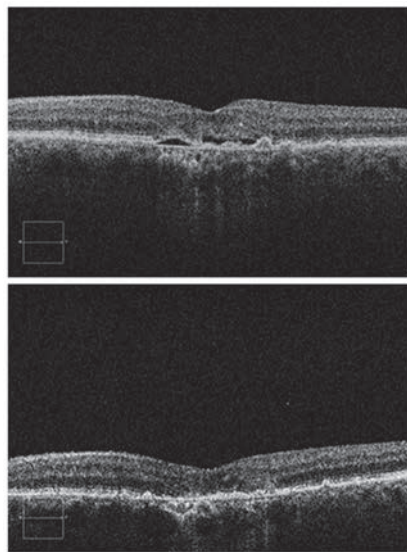
All brolicizumab groups in both HAWK and HARRIER achieved the primary endpoint of non-inferiority in mean change in BCVA at week 48 compared to aflibercept.

Dr. Dugel says the week 16 data is particularly important because it represents the end of a matched phase in which both drugs were given in an identical regimen. This timepoint represents the purest comparison between these two drugs, he says. In both HAWK and HARRIER, the 6-mg and 3-mg brolicizumab arms had less intraretinal and/or subretinal fluid, less sub-RPE fluid and greater reductions in central subfield thickness than the aflibercept groups at week 16.⁴ Also, there was less disease activity in both doses of brolicizumab compared to aflibercept. The superior OCT results and superior disease activity assessment results were statistically significant in favor of 6-mg brolicizumab. Aflibercept and brolicizumab had comparable safety profiles.

A secondary analysis of the data, presented at ARVO, showed that the brolicizumab patients who were extended in the first 12-week cycle after the loading doses had an 87-percent (HAWK) and 82-percent (HARRIER) predictability of maintaining that treatment cycle through week 48.⁵

“The advantage of brolicizumab is that the majority of patients will be able to be sustained on q12-week dosing after the initial loading dose. But in my mind the bigger advantage is that if you look at the head-to-head comparison at week 16 in both HAWK and HARRIER, brolicizumab was superior to aflibercept in all the anatomical parameters,” says Dr. Dugel.

Dr. Stewart, however, emphasizes that q12w dosing of brolicizumab may not pan out for many neovascular AMD patients. “Although the drug did



All images: Michael W. Stewart, MD

Top: Baseline SD-OCT image showing subretinal fluid and drusen due to choroidal neovascularization. Bottom: Four weeks after a single intravitreal bevacizumab injection, the subretinal fluid has completely resolved. Successful cases such as this set the bar high for future therapies.

well in Phase III, it was disappointing that it didn't last predictably for three months,” he says. “That was comparing it with aflibercept q8-weeks as the control. What the developers have elected to do is go to the FDA and ask for q8-week approval, but not q12-week, which is no surprise.”

• **Abicipar pegol.** Abicipar (Allergan; Dublin, Ireland) is a novel anti-VEGF A known as a DARPIn (designed ankyrin repeat protein). It's genetically modified to specifically target the proteins that induce angiogenesis. The manufacturer aims to create a drug with equivalent or superior efficacy to the anti-VEGFs currently available, so patients can undergo less-frequent intravitreal injections.

“Abicipar is a VEGF A inhibitor very much like all the other drugs we have. It works by binding in an almost irreversible manner to soluble VEGF A,” Dr. Stewart explains. “DARPins are a platform of drugs from which—with the right biochemical alterations—you could create a drug that

will bind almost anything. DARPins are also being looked at for oncology, but they're not as far advanced as they are for ophthalmology. The DARPIn is a small molecule bound to a pegolated moiety that is supposed to increase its duration of action. The developers are hoping that it will stay in the eye long enough to meaningfully extend the duration of action of anti-VEGF therapy. Some of that's based on a very small cohort in a Phase I diabetes trial, where they found an average half-life in the eye of about 13.4 days—which, if true, would really speak well for the extended duration of action. But it was only four patients, so it's pretty hard to know how accurate that was.”

A pair of Phase III studies, CEDAR and SEQUOIA, comparing two dosing schedules of abicipar (q12 weeks and q8 weeks) for safety and efficacy compared to a control group of patients receiving monthly ranibizumab injections, has been completed, and both dosing schedules met the primary endpoint of noninferiority to ranibizumab.

• **Conbercept.** Conbercept (Chengdu Kanghong Biotechnologies; Chengdu, Sichuan, China) is a novel anti-VEGF A that may be headed for the U.S. market. “Conbercept is a fusion protein like Eylea, except for the presence of domain 4 of VEGF receptor 2, which may give it greater binding ability and a lower isoelectric point. The hope is that it might be a better next-generation anti-VEGF A. It's already been approved in China, where it's currently being used for neovascular macular degeneration, as well as pathologic myopia,” says Dr. Dugel.

“Conbercept has many of the same features as aflibercept,” concurs Dr. Stewart. “It's approved for AMD in China, and they're just looking to start Phase III trials in the United States right now. We'll see what happens in the trials, but my guess is that it will prove very comparable to aflibercept.”

A small study of 100 patients treated 1:1 with either 0.5 mg of ranibizumab

or 0.5 mg of conbercept intravitreal injections per a treat-and-extend protocol found that both drugs produced equivalent visual gains and anatomic improvements at one year, but that the conbercept group had longer treatment intervals.⁶

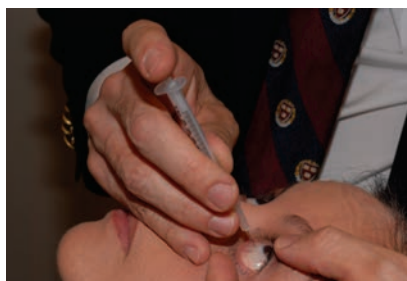Combination Therapies

nAMD combination therapies may be dual-action or co-formulations. “Angiogenesis is an extremely complicated biological process. If you look at the treatment of angiogenesis in oncology, just one drug against one target is simply not the strategy,” notes Dr. Dugel. “It’s a very complex process where many drugs are used against many targets. There are a lot of parallels to oncology and, therefore, a lot of interest in combination therapy.”

- **RG7716.** Genentech’s RG7716 (RO687461) is a novel, bispecific monoclonal antibody that binds to both VEGF A and angiopoietin-2. The AVENUE study (ClinicalTrials.gov Identifier: NCT02484690) is a multicenter, randomized, active comparator-controlled 52-week trial to compare change in baseline BCVA at week 40 in 76 patients, randomized into short-interval RG7716 intravitreal injections, long-interval intravitreal RG7716 injections and intravitreal ranibizumab.

“Of the combination agents, I would say the one that is most advanced in development, in the subcategory of angiopoietin inhibitors, is RG7716. This is a bispecific product: One fab arm is anti-ANG-2 and the other is anti-VEGF A,” says Dr. Dugel, who presented studies on RG7716 for diabetic macular edema earlier and will present data from the AVENUE and STAIRWAY studies for nAMD treatment at the 2018 Retina Society meeting in September.

- **GB-102.** Graybug Vision (Redwood City, California) has developed a dual VEGF/PDGF inhibitor called



Intravitreal injection performed without an eyelid speculum. Increased duration of action is the goal of many emerging therapies.

GB-102 (sunitinib malate) for intravitreal injection. Sunitinib, a tyrosine kinase inhibitor, is also used in oncology. Its formulation uses microparticles to minimize systemic effects and help it consolidate to form a biodegradable depot inside the eye. The company says that GB-102 displays neuroprotective properties with regard to retinal ganglion cells as it binds to multiple VEGFRs.

The ADAGIO trial (ClinicalTrials.gov Identifier: NCT03249740) is an ongoing Phase IIb, multicenter, double-masked study comparing two dose levels of GB-102 to aflibercept therapy for nAMD. In it, patients with wet AMD who were already receiving anti-VEGF A injections will be randomized into low-dose or high-dose GB-102 arms every six months or a control arm receiving 2 mg of aflibercept every two months. Mean change in BCVA is the primary endpoint.

“This is interesting because it’s a single injection that may last up to six months. It’s in Phase I/II studies, and they haven’t been released yet. We’re awaiting their release,” says Dr. Dugel.

- **X-82.** Tyrogenex (Rockville, Maryland) recently terminated the Phase II APEX study (ClinicalTrials.gov Identifier: NCT02348359) of X-82 (vorolanib), a dual VEGFR/PDGFR inhibitor, because it had achieved its primary endpoint of visual acuity change at 52 weeks from randomization in nAMD. It’s also being investigated as a can-

cer treatment. X-82 is unique among nAMD therapies because it’s administered orally.

The APEX study was a randomized, double-masked, placebo-controlled, dose-finding study. Wet AMD patients were treated for a total of 52 weeks with one of three doses of X-82 plus as-needed intravitreal anti-VEGF or intravitreal anti-VEGF plus oral placebo.

Dr. Stewart says that tyrosine kinase inhibitors like X-82 appear promising, but have formidable drawbacks. “The trouble with them is that they have significant side effects,” he notes.

Ashish Sharma, MD, a consultant in retina at Lotus Eye Hospital and Institute in Coimbatore, Tiruppur, India, believes that X-82, if approved, could have value when used with intravitreal anti-VEGF therapy. “It has potential to replace the antioxidants, as per AREDS recommendations,” he says. “It might allow more relaxation of a monthly injection approach.” But like Dr. Stewart, Dr. Sharma notes that systemic side effects may be a challenge. “One-sixth of patients had some adverse events such as diarrhea, nausea and fatigue in Phase I,” he says.

Other Targets

The search for wet AMD therapies with new mechanisms of action agnostic of VEGF A will require patience, according to Dr. Stewart. “I think we’re going to find something that will work, but I’m not sure that we’ll hit on anything very soon,” he says. “For that reason, I think that we’re locked into anti-VEGF therapy, probably as monotherapy, for quite a long time.”

Many experimental treatments in this category are designed to complement intravitreal anti-VEGF A’s. “I think agents that are targeting other molecules are looked at as combination therapies. I don’t think that any of them are truly looked upon as a substitute for VEGF inhibition,” Dr. Stewart says.

• **DE-122.** Santen (Emeryville, California) is studying DE-122 (carotuximab), a novel intravitreal ophthalmic formulation that is an endoglin antibody. Endoglin is a protein that's vital to angiogenesis.

DE-122 is being investigated as a therapy that will complement anti-VEGF treatment. It has shown bioactivity in trials, and is currently undergoing a randomized Phase IIa study (ClinicalTrials.gov Identifier: NCT03211234) comparing two different dosing levels of DE-122 combined with Lucentis injections versus Lucentis injections plus sham injections. The primary endpoint is mean change in BCVA at week 24.

• **OPT-302.** OPT-302 (Opthea; South Yarra, Victoria, Australia) is an anti-VEGF agent, but it inhibits VEGF C and D, rather than VEGF A. "This would be used in combination with anti-VEGF A. The idea is that if you suppress VEGF A there redundant pathways and you may actually increase VEGF C and D, and there are studies in oncology showing that VEGF C in particular, but also D, may be important in resistance or persistence of disease in VEGF A suppression," Dr. Dugel explains.

A Phase IIb study (ClinicalTrials.gov Identifier: NCT03345082) is currently underway, to see if adding OPT-302 to Lucentis monotherapy improves visual acuity or anatomy compared to Lucentis alone.

"The Phase IIa study was really interesting because in that study, approximately 50 percent of patients had no detectable choroidal neovascular membrane as read by a reading center, which was quite impressive," says Dr. Dugel.

• **ICON-1.** Iconic Therapeutics (San Francisco) is in Phase II studies of ICON-1, a tissue-factor inhibitor. Tissue factor is a protein involved in coagulation; when it's overexpressed, it's thought to lead to pathologic angiogenesis, cancerous tumors and neovascular

eye disease.

The Phase IIb DECO study (ClinicalTrials.gov Identifier: NCT03452527) will compare CNV size at nine months to baseline in newly diagnosed, treatment-naïve eyes that have received intravitreal Icon-1 either in combination with or after intravitreal aflibercept.

Gene Therapy

Gene therapies for nAMD have focused on gene production, as opposed to gene replacement. So far, the results "have been fairly disappointing," according to Dr. Dugel. He cites the Phase IIb investigation of AVA-101 (Avalanche Biotechnologies [now Adverum]; Menlo Park, California), a recombinant adeno-associated virus vector carrying an anti-VEGF protein that was injected into the study eyes of 32 patients to spur expression of the protein in the epithelium. After a year, patients gained an average of just 2.2 letters, experienced increased CRT and required a high number of anti-VEGF rescue injections.

"That was an attempt to insert genes into the photoreceptors of the RPE and into the outer retina in order to try to get them to overproduce a soluble VEGF receptor," Dr. Stewart explains. "Unfortunately, they failed to get really good results."

"Why that wasn't successful is still not really known: It may be because of where it was injected. It may be because of the amount of protein production. But I think that gene therapy will definitely have a role in the future," says Dr. Dugel.

Genzyme (Framingham, Massachusetts) is investigating stopping the progression of AMD with a genetically modified adeno-associated virus vector. (ClinicalTrials.gov Identifier: NCT01024998), as is Regenxbio (Rockville, Maryland) (ClinicalTrials.gov Identifier: NCT03066258).

Dr. Dugel and Dr. Stewart say that ophthalmologists have been "spoiled"

by the success of currently available anti-VEGF treatments. But Dr. Dugel says there's still ample room for improvement. "In almost all studies that go on past five years, unfortunately, even with treatment, vision tends to gradually decline to less than baseline. That's due to macular atrophy and fibrosis," he says, adding that most newly diagnosed patients can anticipate 15 or 20 years of life after the diagnosis of neovascular AMD.

"I'm disappointed," admits Dr. Stewart. "Of course, I've been elated by the fact that we have anti-VEGF therapy. That has been a game changer for patients and physicians. We had three great successes in a row with Avastin, Lucentis and Eylea. And then all of a sudden, we hit a brick wall. So unless we see a dramatic improvement in duration of action or patient comfort, I think most of us will probably just stay with injections," he concludes. **REVIEW**

Dr. Dugel has interests in Genentech, Regeneron, Novartis, Allergan, Chengdu Kanghong Biotechnologies, Graybug Vision, Santen, Opthea, Alcon and Avalanche. Dr. Stewart reports no relevant interests. Dr. Kaiser has interests in Regeneron, Allergan, Alcon, Bayer HealthCare, Chengdu Kanghong Biotechnologies, Novartis and Genentech. Dr. Sharma reports consultancy to and speaker's fees from Novartis India, Allergan India and Bayer India.

1. Heier JS, Brown DM, Chong V, et al. Intravitreal aflibercept (VEGF Trap-Eye) in wet age-related macular degeneration. *Ophthalmology* 2012;119:12:2537-2548.


2. Ohji M, Okada AA, Takahashi K, Kobayashi M, Terano Y. Two different treat and extend dosing regimens of intravitreal aflibercept for wAMD in Japanese patients: 52-week results of the ALTAIR Study. Barcelona: EuroRetina Meeting; 2017.

3. Dugel PU, Jaffe GJ, Sallstig P, et al. Brolicizumab versus aflibercept in participants with neovascular age-related macular degeneration: A randomized trial. *Ophthalmology* 2017;124:1296-1304.

4. Jaffe G, Koh AH, Ogura Y, et al. Phase III studies of brolicizumab versus aflibercept in nAMD: 48-week primary and key secondary outcomes from HAWK/HARRIER. *Invest Ophthalmol Vis Sci* 2018; ARVO e-Abstract 1624. Presented at the ARVO 2018 Annual Meeting; 30 April 2018; Honolulu, HI.

5. Dugel PU, et al. A comparison of the anatomical efficacy of brolicizumab and aflibercept in neovascular age-related macular degeneration (nAMD): An analysis over 16 weeks of matched treatment in the HAWK and HARRIER studies. Paper presented at the ARVO 2018 Annual Meeting; 30 April 2018; Honolulu, HI.

6. Cui J, Sun D, Lu H, et al. Comparison of effectiveness and safety between conbercept and ranibizumab for treatment of neovascular age-related macular degeneration. A retrospective case-controlled non-inferiority multiple center study. *Eye* 2018;32:391-99.



Elderly and OHT: Should You Treat?

A number of factors have to be considered when deciding whether to put this type of patient on drops.

Ruth D. Williams, MD, Chicago

When faced with a patient who has ocular hypertension but no glaucomatous damage, deciding whether to treat or simply monitor the patient is always a judgment call. We have to consider the risks and benefits of each option. How likely is it that this patient will develop glaucoma and progress? Is that risk great enough to offset the inconvenience and cost of treatment?

These questions become a bit trickier when the patient is elderly. How many more years is the patient likely to live? Can the patient manage drops? Will the patient be able to return for follow-up visits? Does the patient have other health issues?

For example, consider an 86-year-old male patient who has ocular hypertension; his pressure over the past two years has ranged

between 27 and 31 mmHg OD, and 27 and 33 mmHg OS. His corneas are a bit thin—523 μm OD, 520 μm OS. He has a small cup-to-disc ratio of 0.2 bilaterally and his visual fields are normal. OCT reveals that his retinal nerve fiber layer has been thinning over time—a case of so-called “green disease”—but it’s still within the normal range. He’s pseudophakic with mild macular degeneration, but he’s generally in good health and doesn’t have vasculopathic risk factors

such as high blood pressure, diabetes, hyperlipidemia, cardiovascular disease or history of stroke, all of which can predispose someone to a vein occlusion or anterior ischemic optic neuropathy.

Does this 86-year-old patient actually have early glaucoma? Is treatment really necessary? Here, I’d like to discuss some of the considerations that arise when deciding whether or not to treat a patient like this.

The Case for Not Treating

There are several reasonable arguments for monitoring this patient without treatment:

- **The risk of developing early glaucoma in at least one eye over five years is low.** Depending on how you calculate the risk, it’s between 10 and



Although it’s tempting to assume that elderly patients won’t live too many more years, many of these patients are vibrant, healthy and active.

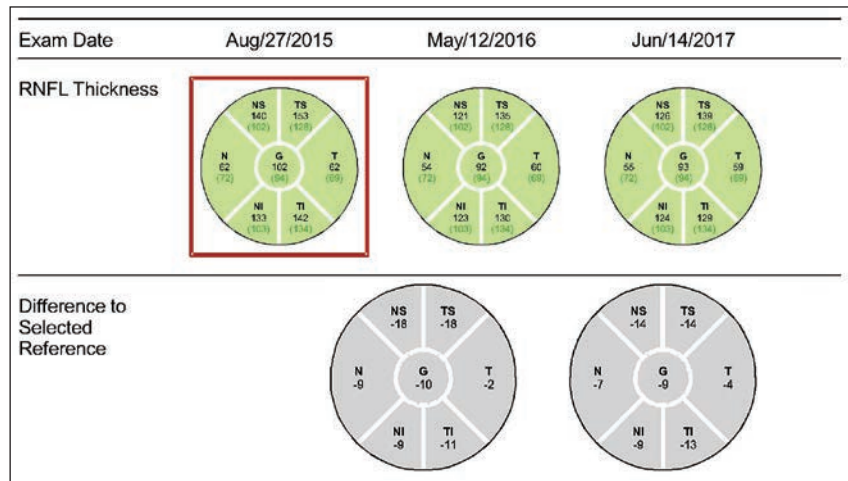
15 percent. Those odds are very much in favor of no damage occurring over the patient's expected lifespan.

As noted in a 2007 study of a model designed to predict the development of primary open-angle glaucoma in individuals with ocular hypertension, a predictive model should never replace clinical judgment.¹ Other factors, such as a patient's health, life expectancy and preferences must be considered. In our sample case, the patient is healthy and has no significant vasculopathic risk factors, so that would be an argument for not treating this patient and just watching.

• **A small amount of progression is unlikely to affect quality of life.** The possibility that an 86-year-old patient might progress isn't necessarily a reason to treat. Even if this patient does progress a little bit in the years ahead, it's unlikely to affect his quality of life.

When treating glaucoma patients, I think we tend to get caught up in the idea that we don't want anybody to progress. But preventing progression isn't ultimately our goal; what we're really trying to do is maintain quality of life. In that context, if a 96-year-old patient has a tiny bit of glaucoma, does it matter? If your patient has a little nasal step at age 86, should you be concerned? Of course, if that patient is a fast progressor and likely to develop an arcuate scotoma, yes, that matters. But a little nasal step probably won't affect that person's quality of life—and that's what this is all about.

• **It's very easy, practical, affordable and effective to follow our patients with OCT.** This is especially valuable when managing an older patient who may or may not be very good at doing visual field tests. So, you could leave this patient's elevated IOPs untreated, check the IOPs at reasonable intervals and do an OCT once a year. If the OCT continues to change, then you can



This 86-year-old patient's retinal nerve fiber layer has been thinning over time but is still within the normal range. His pressures are elevated and his corneas are about 520 μ m bilaterally, but cup-to-disc ratio is low and visual fields are normal. Would you treat?

implement treatment.

Glaucoma specialist Cynthia Mattox, MD, has noted her own move in this direction. She has said that earlier in her career she treated for IOP levels, but today, with OCT to help with monitoring and the data from OHTS, she's more comfortable following patients who have a low five-year risk of progression.

• **Some patients in this age group might have difficulty taking a drop.** If that's the case, a prescription would probably be ineffective and a waste of the patient's money.

• **Some patients could find the cost to be a burden.** In that situation, the patient is unlikely to use the drops even if you prescribe them.

The Case for Treating

Arguments in favor of treating this patient include:

• **He has several risk factors for progression.** One tool we've used to help guide our treatment is the data from the European Glaucoma Prevention Study and the Ocular Hypertension Treatment Study (OHTS), both of which looked at the risk of progression. This particular patient has several risk factors, including

his age, his fairly high IOP and his thin cornea, so his five-year risk of progression in one eye is about 10 to 15 percent. (Of course, he also has a small cup-to-disc ratio, and normal Humphrey visual fields and pattern standard deviation—which is why there's some debate about proceeding with treatment.)

• **This patient is very healthy and could live many more years.** It's entirely possible that this 86-year-old patient could live to be 100. Although his five-year risk of progression is low—around 15 percent—the longer he lives, the greater the risk.

Despite the lingering stereotype of elderly people as somewhat feeble individuals, many of the elderly patients I see are vigorous and in good health. Especially today, a person in his or her 80s and 90s can have a significant additional life expectancy. (In fact, I've observed that you don't live to be 95 unless you're a pretty healthy person.) With a younger patient it's safe to assume the individual will be around for many more years, but it's a lot more challenging to guess the life expectancy of an elderly patient.

One approach to estimating your patient's likely lifespan, and

Table 1: Life Expectancy by Age (as of 2015)*

Age	75	76	77	78	79	80	81	82	83	84	85	86	87	88	89	90	91	92	93	94	95
Life expectancy (male)	11.08	10.48	9.89	9.33	8.77	8.24	7.72	7.23	6.75	6.30	5.87	5.45	5.06	4.69	4.35	4.03	3.73	3.46	3.21	2.99	2.80
Life expectancy (female)	12.85	12.17	11.51	10.86	10.24	9.63	9.04	8.48	7.93	7.41	6.91	6.43	5.98	5.54	5.14	4.76	4.41	4.09	3.80	3.54	3.30

* From Social Security Actuarial Life Table, <https://www.ssa.gov/oact/STATS/table4c6.html>. Accessed July 9, 2018.

therefore the likelihood of developing glaucomatous damage, is to examine actuarial tables. These report the average length of time individuals in a given age group will live. (*See sample table, above.*) Based on this table, the average life expectancy for this patient is a bit more than five additional years. However, this is an average, and averages can't predict an individual case. And of course, the longer he lives, the greater the likelihood he'll experience progression and damage.

- **Treatment with a PGA once a day is relatively low-cost and low-risk.** Putting the patient on a PGA once a day is a very simple and reasonable treatment—assuming that the patient is able to put in a drop every day.

- **We don't know for sure that the patient will keep his follow-up appointment.** I practice in a suburb at the very edge of Chicagoland, and a lot of my patients come in from the western farmlands of Illinois. It may take them an hour and a half to get to my office. In addition, the patient's family situation could make it hard for the patient to come in regularly. If he doesn't return for follow-up appointments, our ability to catch any developing problem will be compromised. Those kinds of issues would make me feel more inclined to treat.

- **We're concerned that the elevated IOP might increase the risk of an AION, CRVO or branch vein occlusion.** Although there's an association between these vascular events and elevated IOP, we don't

know for sure that lowering IOP decreases the risk of these types of vascular events. In the OHTS study, for example, the data indicated no statistical difference in the incidence of retinal vein occlusion in subjects who were treated in order to lower IOP compared to subjects who were not treated.² Nevertheless, given the association between high IOP and these vascular issues, we tend to err on the side of wanting to lower the IOP, just to "play it safe."

Even if lowering IOP hasn't been shown to reduce the risk of a vascular event, clinicians may have reason to be cautious. If you let the IOP remain high and the patient does have a vascular event like an AION or branch vein occlusion later on—despite the lack of risk factors present when you examined the patient—you'll have a tough time defending your choice to monitor rather than treat. For this reason, some would argue that treating a patient like this is a good idea simply because of the medicolegal risks posed by the association between high IOP and vasculopathic events.

- **We're afraid of missing somebody who might be a fast progressor.** Treating the patient, in other words, is a way to hedge our bets that this patient might develop glaucoma more quickly than we expected.

Louis Cantor, MD, made the observation that we tend to overtreat glaucoma suspects and undertreat real glaucoma. I think that's true. It's easy to put people on drops, and we tend to do that whenever we're not sure

about whether to treat. Ironically, part of the motivation would seem to be to make ourselves feel better.

The Word on the Street

All of these arguments have some validity, but I was curious to see what ophthalmologists practicing in the real world would do in a situation like this.

To begin, I conducted an informal poll of several university employed and private practice glaucoma specialists to see whether or not they would choose to treat this elderly ocular hypertensive individual. There was no clear preference. Five colleagues said they'd monitor without treatment because the five-year risk of progression is fairly small. Seven of my colleagues said they would definitely treat with a PGA.

Three others said they might treat the patient with selective laser trabeculoplasty, especially if the patient had poor memory or dexterity or some other reason for having difficulty using drops. SLT is a great option if you have adherence concerns with an elderly patient, and it's less expensive than a drop because it's a one-time cost. However, SLT doesn't always work, and some might argue that it's a questionable idea because you're doing a procedure in a "normal" eye that doesn't have any damage yet.

I also polled the audience at one of my meeting presentations, and got a somewhat different response: The audience was overwhelmingly in fa-

vor of treating the patient with a PGA because of the high IOPs. I suspect the difference in responses may reflect a sampling error. The casual sampling of a group of colleagues at two academic meetings is likely to include glaucoma specialists who are highly data-driven, doctors who apply the OHTS and EGPS data to decision-making. In this instance, many of them recognized that the risk of progression was low and concluded that they wouldn't recommend treating. However, I think many clinicians out in the field are pretty uncomfortable letting a patient's pressure stay at 30 mmHg, regardless of other factors.

Getting the Patient On Board

What would I do? When faced with this situation, I'd let the patient help

me decide whether or not to treat. In my experience, patients are usually smart and fairly sophisticated, and they usually have an opinion. I'd present the data from OHTS and explain it to the patient. I'd tell her that it wouldn't be unreasonable to hold off on treating and simply monitor her condition, but I'd also tell her that high pressure is easy to treat.

In most cases, given the option, patients choose to go ahead with treatment—but not always. That's important, because if the patient declines treatment he's probably telling you that he won't use the drops, even if you prescribe them. On the other hand, if the patient helps make the decision to treat, that helps to motivate the patient to use the drops consistently.

Ultimately, some would say that the

best test of a decision is to ask whether you'd make the same decision if the patient were your own parent or child. My parents are 87 and 88 years old, and quite robust and healthy. Would I treat one of them if they had an intraocular pressure of 30, despite everything else appearing healthy? I probably would. **REVIEW**

Dr. Williams is a glaucoma consultant at Wheaton Eye Clinic in Wheaton, Ill., and past president of the American Academy of Ophthalmology. She is a consultant for Allergan and Aerie.

1. Ocular Hypertension Treatment Study Group; European Glaucoma Prevention Study Group, Gordon MO, Torri V, Miglior S, et al. Validated prediction model for the development of primary open-angle glaucoma in individuals with ocular hypertension. *Ophthalmology* 2007;114:1:10-9.

2. Barnett EM, Fantin A, Wilson BS, Kass MA, Gordon MO, for the Ocular Hypertension Treatment Study Group. The incidence of retinal vein occlusion in the ocular hypertension treatment study. *Ophthalmology* 2010;117:3:484-488.

Hiring Ophthalmic Staff?

More Ophthalmic Technicians Find Jobs On Local Eye Site Than Anywhere Else.

localeyesite.com



Local Eye Site
JOBS IN EYE CARE



Succeeding with Scleral-Sutured Lenses

Two surgeons describe their go-to technique for working with IOLs that require scleral fixation.

Christopher Aderman, MD, and Carl D. Regillo, MD, Philadelphia

Placement of secondary intraocular lenses is one of the more common procedures we perform as retina surgeons, so it's important for us to be comfortable with the various techniques and to understand our options. Implantation of an anterior-chamber IOL, refixation of a dislocated IOL and scleral fixation of an IOL can each be an appropriate choice, depending on clinical factors such as patient age, ocular comorbidities and the mechanism of lens dislocation.¹

In cases that require scleral fixation with sutures, nonabsorbable polytetrafluoroethylene (PTFE) monofilament suture (Gore-Tex; W.L. Gore) has largely replaced polypropylene (Prolene) due to its long-term stability. Although there are numerous methods for scleral fixation, the most common technique performed at our institution makes use of a Gore-Tex suture with either an Akreos AO60 IOL (Bausch + Lomb) or an enVista MX60 IOL (Bausch + Lomb). Each of these models provides stable four-point fixation. In this article, we review our technique for suturing these and discuss the pros and cons of each lens in this situation.

Sutured-lens Technique

Before performing vitrectomy and lens or IOL removal, create limited conjunctival peritomies nasally and temporally and use a toric lens marking set to mark the horizontal axis, in order to ensure proper sclerotomy placement and lens centration. Using calipers, mark the sclerotomy sites 4 to 5 mm apart, 3 mm posterior to the limbus, and centered around the horizontal axis. This positioning simulates in-the-bag placement, so standard IOL power calculation formulas can be used.

Place trocars (23-, 25-, or 27-gauge)^{2,3} superonasally and superotemporally, and use the empty trocar needle to create inferonasal and inferotemporal sclerotomies parallel to the limbus. Inserting the trocars perpendicularly without tunneling facilitates the rotation of the knot in the PTFE sutures at the end of the case. The acrylic lenses are easily folded and can fit through a 3-mm clear corneal incision or scleral tunnel.

Next, remove the needles of the 7-0 CV-8 Gore-Tex suture, and bisect and loop the suture through the

eyelets of the IOL before inserting it into the eye. It's critical to keep the suture strands organized. Grasp one end of the first suture with Ahmed Micro-Graspers forceps (MicroSurgical Technology), inserted through the corneal incision, and pass it using the handshake technique to MaxGrip forceps (Alcon) that have been inserted through one of the sclerotomies. Then, externalize the suture, and repeat the same procedure with the other end, securing one side of the IOL.

Some surgeons also externalize one or both ends of the suture on the other side of the IOL before folding and inserting the lens. This leaves the final suture to be externalized after the lens has been inserted. The PTFE sutures can then be trimmed and loosely secured by tying the first portion of a 3-1-1 knot or a slip knot, and the tension can be adjusted to perfectly center the lens before securing the suture and rotating the knot into the superonasal and superotemporal sclerotomies.

Leaky wounds can be sutured, but be wary of severing the PTFE sutures, in order to spare yourself a frustrating

lens retrieval within the vitreous cavity. Alternatively, a transconjunctival approach can be used, eliminating the need for peritomies at the start of the case. (A video of a sutured AO60 lens using a trans-conjunctival approach not requiring a peritomy accompanies the online version of this article at reviewofophthalmology.com.)

Lens Options

Your choice of intraocular lens will impact various aspects of the procedure, and each lens comes with pros and cons.

• **Akreos AO60.** This acrylic lens is a popular IOL choice for scleral fixation. It has four eyelets through which sutures can be looped, providing true, stable, four-point fixation. The benefit of this lens is its ease of use. Looping the sutures through the eyelets outside the eye (Figure 1) and externalizing the sutures before IOL insertion reduces the risk of crisscrossing sutures or flipping the lens.

Four-point fixation minimizes the risk of lens tilt, and the lens can be centered in the eye easily by adjusting the tension on the two sutures. (The lens can, however, bend or warp if sutured too tightly.) The major drawback of this lens is that it is composed of a hydrophilic acrylic material, and opacification can result from air or gas exposure. This opacification is rare, but if it occurs it may require a lens

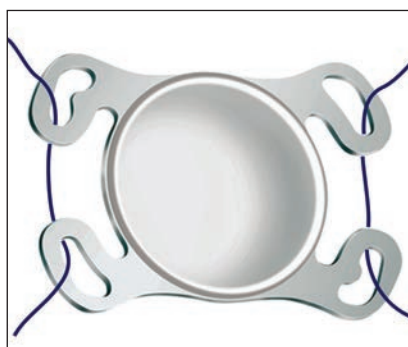


Figure 1. The four eyelets of the Akreos AO60 (Bausch + Lomb) allow true four-point fixation.

exchange. Take this into consideration in patients who have a high risk of retinal detachment. Such patients should be counseled regarding this risk.

• **enVista MX60.** The enVista MX60 is made with a hydrophobic acrylic material, so it's not susceptible to opacification in the presence of air or gas. Although this lens has only two triangular eyelets at the haptic-optic junctions, these allow pseudo four-point fixation. If the suture is looped over the haptic, under the eyelet, and

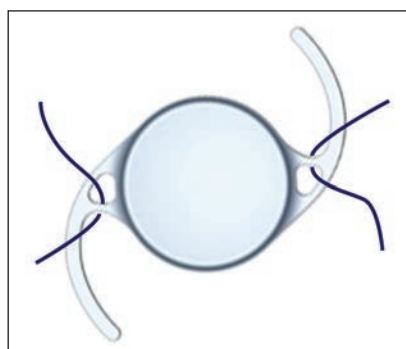


Figure 2. Looping the suture around the optic-haptic junction of the enVista MX60 (Bausch + Lomb) creates a pseudo four-point fixation.

then back over the haptic (Figure 2), the intraocular lens will remain stable without tilt when the sutures are externalized.

The setup for this lens is similar to the setup that's done for the AO60, with the sclerotomies being placed 3 mm posterior to the limbus and 4 or 5 mm apart.

Lens insertion is trickier with this IOL, as the suture can easily slip around the haptic and cause the lens to tilt. Make sure to keep tension on the externalized ends of the suture at all times to prevent the suture from looping back under the haptic. Folding the haptic inside the lens like a taco during insertion is one effective technique you can use to ensure that the suture stays properly positioned anterior to the haptic.

This lens is useful for patients with

retinal detachment or those at high risk of needing air or gas tamponade.

Other Considerations

No matter which secondary suture techniques or IOLs you become comfortable with, it's important to remember the basics of residency training and to carefully review lens power calculations on a case-by-case basis. Perform quality control checks to confirm reliable, up-to-date biometry measurements. Ensure that there are no discrepancies between axial lengths in the patient's eyes, and check that the technician correctly adjusted the software for the status of the eye (e.g., is there silicone oil in the eye now, or will there be at the end of the case?).

We use the Barrett II Universal IOL calculation method, because biometry measurements taken by referring physicians typically don't include calculations for our preferred IOLs. This approach has resulted in reliable refractive outcomes.

In conclusion, throughout our training and daily practice, we're exposed to numerous techniques. The key to consistently good results, however, is to know a few techniques very well.

The more standardized the physician's approach for each case, the more comfortable and confident he or she will be—and comfort and confidence are critical factors for maximizing visual outcomes. **REVIEW**

Dr. Aderman is currently completing a retina fellowship at Wills Eye Hospital in Philadelphia. Dr. Regillo is chief of the retina service at Wills Eye.

1. Stem MS, Todorich B, Woodward MA, Hsu J, Wolfe JD. Scleral-fixated intraocular lenses: Past and present. *J Vitreoretin Dis* 2017;1:2:144-152.
2. Khan MA, Gerstenblith AT, Dollin ML, Gupta OP, Spirm MJ. Scleral fixation of posterior chamber intraocular lenses using Gore-Tex suture with concurrent 23-gauge pars plana vitrectomy. *Retina* 2014;34:7:1477-1480.
3. Khan MA, Kuley A, Riemann CD, Berrocal MH, Laxhanpal RR, Hsu J, Sivalingam A, Ho AC, Regillo CD. Long-term visual outcomes and safety profile of 27-gauge pars plana vitrectomy for posterior segment disease. *Ophthalmology* 2018;125:3:423.



ICRS and Cross-linking For Corneal Ectasia

A cornea surgeon explains the pros and cons of the two approaches, when used alone and in combination.

Brandon Baartman, MD, Omaha, Neb.

The treatment of corneal ectasias such as keratoconus, pellucid marginal degeneration and post-refractive ectasia has undergone a significant shift in recent years. New treatment options offer not only stabilization of the progressive nature of these conditions, but also corneal flattening and improved visual outcomes, enabling surgeons to intervene earlier in the disease course and avoid penetrating keratoplasty.

Two technologies that have gained recent attention, both independently and used in conjunction with one another, are intracorneal ring segments and corneal collagen cross-linking. In this column, I'll describe my surgical approach of combining intracorneal ring segments with cross-linking for the management of ectatic corneal disorders, and discuss situations in which one approach might be preferable to the other.

Intacs

Intacs corneal ring segments (Addition Technology; Fremont, California) are the only ICRS available in the United States; they were originally

designed for the correction of low degrees of myopia. The intracorneal implants, when placed in the peripheral cornea outside of the optical zone, cause a flattening of the central cornea, thus reducing myopia and mild astigmatism. However, given the advancements and excellent outcomes of excimer laser ablation techniques, intracorneal ring segments like Intacs were largely relegated to treatment of irregular corneas. Intacs were subsequently FDA approved for the correction of myopia and astigmatism associated with keratoconus, in 2004. Candidates for Intacs are patients whose steepest K values are less than 58 D, who have clear visual axes and corneal thicknesses of at least 450 μm at the 7 mm optical zone.¹ Placement can be performed using either mechanical or femtosecond-created channels. Outside of the United States, Ferrara rings and Kerarings (Mediphacos; Belo Horizonte, Brazil) are the other two commonly used ICRS models.

One of the unique properties of ring segments, which are made of polymethylmethacrylate and come in a range of sizes, is the ability to

normalize a highly ectatic cornea by centralizing the cone and reducing maximum corneal curvature. Doing so can often decrease the amount of irregular astigmatism and higher-order aberrations seen in these patients, improve best spectacle-corrected visual acuity, and improve contact lens tolerance.² There are mixed results in the literature regarding regression of the flattening effect seen after Intacs implantation. Though not indicated for the stabilization of progression in keratoconus, some have reported stabilization associated with ring segment placement: A five-year study in patients treated with Intacs for progressive keratoconus noted that 92.9 percent of eyes showed no significant progression in steepest K value during the course of follow-up,³ while a separate study of patients with previously documented progressive keratoconus and Intacs or Keraring placement demonstrated regression in the mean K value by 3.36 D postoperatively at five years.⁴

Cross-linking

Corneal collagen cross-linking was

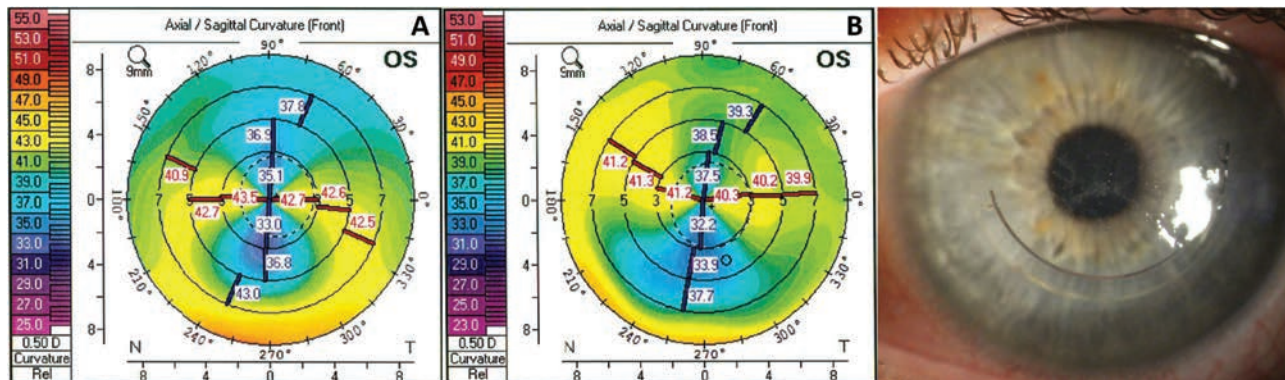


Figure 1. The left eye of a 51-year-old patient with unilateral topographic changes consistent with pellucid marginal degeneration. Anterior curvatures measured by the Pentacam are shown. A) Significant PMD-like ectasia pattern at presentation. B) Improved curvature pattern three months after single Intacs ring segment placement with same-day epithelium-off CXL. C) Slit lamp photograph showing the position of the single ring segment. The patient's topographic indices decreased after the procedure (steep K value decreased by 2.3 D, anterior corneal cylinder by 2.7 D).

approved by the FDA in July 2016 for the treatment of progressive keratoconus and post-refractive ectasia. The procedure, involving the saturation of the cornea stroma with riboflavin (vitamin B2) and subsequent UVA irradiation, increases the biomechanical stability of the tissue by forming chemical bonds between collagen fibrils.⁵ While only recently approved in the United States, there's a vast amount of data on the stability and visual acuity results of cross-linking for keratoconus in the literature due to its popularity abroad. Originally described in 2003, cross-linking has been shown to halt progression of the disease with improvement of visual

acuity and a variable amount of reduction in steepest K values.^{5,6} In addition to keratoconus, collagen cross-linking has been used with similar success in other forms of cornea ectasia, including pellucid marginal degeneration⁷ and post-refractive-surgery ectasia.⁸

Where Do the Technologies Fit?

In current practice, cornea specialists have both tools at their disposal, and both can play an important role in corneal ectasia management. But in which scenarios does cross-linking make sense? When does one consider ICRS? And does it ever make sense to use both in conjunc-

tion with one another?

- **The case for cross-linking.** In our practice, patients who have classic topographic changes on the anterior and posterior cornea, a clear central cornea and documented progression of myopia or astigmatism are generally offered cross-linking. Nearly all candidates will have a clear central optical axis and a minimum corneal thickness greater than 400 μm . In general, we find patients meeting these criteria to be in the earlier stages of disease progression. Age is a consideration, since the natural history of keratoconus is thought to be one of slowed progression with time. However, there is evidence in the lit-

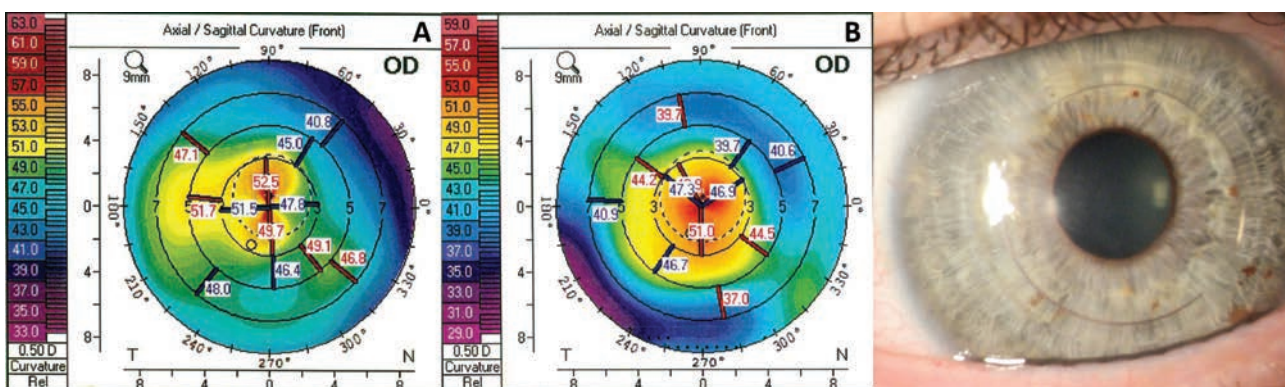


Figure 2. The right eye of a 45-year-old patient with bilateral progressive post-LASIK ectasia. Anterior curvatures measured by the Pentacam are shown. A) Severe steepening with eccentric cone with max K value of 58.2 D. B) Improved centralization of cone and decreased max K value of 55.2 D after paired Intacs ring segment placement with same-day epithelium-off CXL. C) Slit lamp photograph showing paired ring segments.

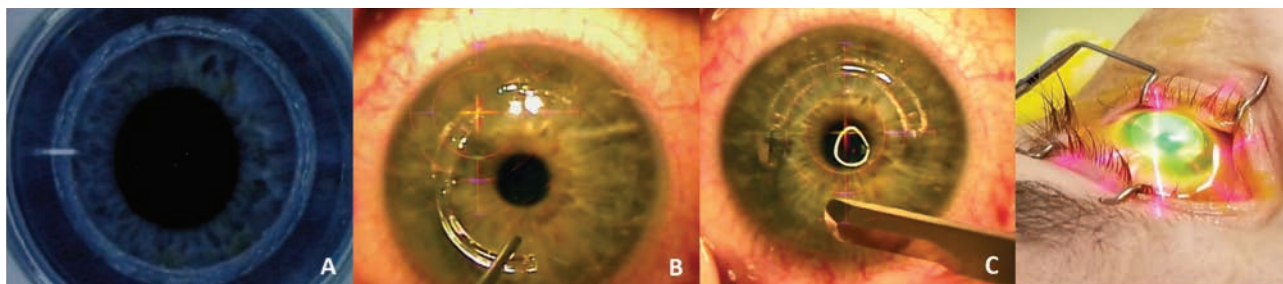


Figure 3. Combining Intacs with same-day corneal cross-linking: A) Femtosecond creation of ring-segment channels; B) placement and securing of Intacs; C) epithelial debridement; and D) standard corneal cross-linking following the Dresden protocol.

erature that keratoconus can continue to progress beyond age 30, suggesting that the benefit of cross-linking may not be limited to the young patient.⁹ Thus, progression in keratometric indices over sequential exams at any age should trigger consideration of corneal cross-linking.

Other types of patients who may benefit from cross-linking at an older age are those with suspected topographic progression and concomitant cataract, as the stabilization and flattening may improve the accuracy of the preoperative biometry and reduce the risk of progressive postoperative myopic shift.¹⁰ Literature on the subject is sparse, but stabilizing keratometric indices prior to intraocular lens power calculation in a case of progressive ectasia should be considered essential for the patient with corneal ectasia and cataract.

• **The case for Intacs.** While there has been documentation of slowing keratoconus progression after placement of Intacs, the largest benefit of ring segments seems to be the reduction in the amount of corneal cylinder and centralization of the cone. In our practice, the patients we consider the best candidates for Intacs are those with moderate to severe keratoconus and a clear central optical zone who have developed contact lens intolerance. As in the published literature, we have noted the greatest visual improvement gains in patients with more advanced disease.¹¹ A 2012 study found that in moderate to severe cases of corneal ectasia, Intacs were able to flatten the steepest K by an average 6.7 D, and allowed contact lens tolerance in all cases.¹² Ring segments may be placed in single or paired fashion with both methods

demonstrating significant effect on refractive parameters and visual acuity.¹³ (See Figures 1 and 2 for case examples.) In those patients for whom the Intacs don't completely eliminate intolerance to rigid gas permeable lenses, we have found success with fitting scleral contact lenses over the ring segments, which is supported by the literature.¹⁴

• **The case for the combination.** Given the unique strengths of both individual treatment types—the stabilizing effect of corneal collagen cross-linking and the flattening power of ICRS—one can imagine a potential synergistic effect of using both technologies. While there are mixed results in the literature regarding their additive effect on outcomes, many surgeons believe the mechanical flattening of ICRS can further potentiate the flattening effect of the cross-linking.²

Choosing to perform both procedures, versus one or the other, may depend on a number of factors, not the least of which is insurance coverage and the patient's ability to afford potentially uncovered services. From a patient-benefit standpoint, any case of progressive keratoconus should be considered a candidate for cross-linking, and ICRS can be considered in moderate to severe cones or patients presenting with contact lens intolerance. These more advanced cases, often with worse presenting BCVA and SE, may stand to gain the most from the combination of both thera-

Perspectives on Keratoconus

Keratoconus is a vision-compromising, often progressive degenerative disorder with the hallmark corneal signs of ectasia, thinning and epithelial iron lines (Fleischer ring), among other clinical features. Other disease processes that are grouped among ectatic corneal disorders include pellucid marginal degeneration, Terrien's marginal degeneration, keratoglobus and post-refractive-surgery (LASIK, PRK) ectasia. Such ectatic corneal changes have a direct impact on vision quality and often induce mixed, irregular, myopic corneal astigmatism, along with induced visual aberrations that may impact the quality of life of the patient and may limit or prevent contact lens use. In very advanced, end-stage disease, where the extreme corneal thinning often eliminates other treatment options, surgeons may settle on penetrating keratoplasty or deep anterior lamellar keratoplasty as the final limited surgical options. However, the large number of patients with lesser corneal involvement may be amenable to other therapeutic modalities that aim to both stabilize and dampen or prevent progression, as in keratoconus.

— Thomas John, MD

pies.¹⁵ In our practice, we follow some general guidelines for patient selection, as described in the accompanying description of the patient in the case discussed in Figure 1.

When using both cross-linking and ICRS, simultaneous or sequential therapy can be considered. However, there is debate about which treatment paradigm is more effective. Simultaneous therapy represents the least recovery time, which can be important in these patients, who are often younger, working-age individuals with progressive keratoconus. When directly compared, combining ICRS with same-day CXL has demonstrated greater reduction in cylinder and keratometric indices than ICRS alone.¹⁶ While individual protocols of riboflavin administration vary, some studies indicate transepithelial¹⁷ and intra-channel¹⁸ riboflavin may provide adequate saturation of corneal stroma without epithelial debridement, further decreasing recovery time.

Sequential ICRS and CXL has also been studied in the literature, with many authors theorizing that the flattening effect of CXL may be potentiated by the existing mechanical flattening of the cornea by the ring segments.¹⁹ This has been demonstrated in post-LASIK ectasia cases as well.²⁰

My Combined Procedure

We currently perform same-day combined Intacs with CXL when both are indicated. After prepping the eye in a way similar to that of other corneal refractive procedures, we use a femtosecond laser to create the intracorneal ring channels at two-thirds corneal depth. The rings are inserted under the laser microscope and a 10-0 nylon suture is placed at the channel entrance. Next, the epithelium is debrided from the optical zone and peripherally over the implanted ICRS. Riboflavin is then administered as de-

scribed in the Dresden protocol, and standard CXL is completed (Figure 3). The Dresden protocol consists of applying 0.1% riboflavin-5-phosphate and 20% dextran T-500 to the corneal surface 30 minutes before irradiation and at five-minute intervals during the course of a 30-minute exposure to 370-nm UVA with an irradiance of 3 mW/cm².

While there are mixed results in the literature regarding the additive effect on outcomes, many surgeons believe the mechanical flattening of ICRS can further potentiate the flattening effect of the cross-linking.

Regardless of the treatment pattern chosen, ICRS and CXL represent two major advances in the treatment of progressive corneal ectasia that together have dramatically reduced the need for penetrating keratoplasty. Whether used independently, in sequence or in combined fashion, there is an ever-increasing body of literature demonstrating good outcomes and safety profiles, giving corneal surgeons effective options for management of corneal ectasia. **REVIEW**

Brandon J. Baartman, MD, is in private practice at Vance Thompson Vision in Omaha, Nebraska. He can be reached at brandon.baartman@vancethompsonvision.com. Dr. John can be reached at 708-429-2223 or by

email at tjcornea@gmail.com.

Dr. Baartman has no financial interest in any of the products mentioned in the article.

1. Colin J, Cochener B, Savary G, Malet F, Holmes-Higgin D. INTACS inserts for treating keratoconus: One-year results. *Ophthalmology* 2001;108:1409–1414.
2. Avni-Zauberman N, Rootman DS. Cross-linking and intracorneal ring segments – review of the literature. *Eye & Contact Lens* 2014;40:365–370.
3. Bedi R, Touboul D, Pinsard L, Colin J. Refractive and topographic stability of Intacs in eyes with progressive keratoconus: Five-year follow-up. *J Refract Surg* 2012;28:6:392–396.
4. Vega-Estrada A, Alio JL, Plaza-Puche AB. Keratoconus progression after intrastromal corneal ring segment implantation in young patients: Five-year follow up. *J Cataract Refract Surg* 2015;41:1145–1152.
5. Gaster RN, Caiado Canedo AL, Rabinowitz YS. Corneal collagen cross-linking for keratoconus and post-LASIK ectasia. *Int Ophthalmol Clin* 2013;53:1:79–90.
6. Wollensak G, Spoerl E, Seiler T. Riboflavin/ultraviolet-A-induced collagen crosslinking for the treatment of keratoconus. *Am J Ophthalmol* 2003;135:620–627.
7. Mamoosa B, Razmjoo H, Peyman A, Ashtari A, Ghafouri I, Moghaddam AG. Short-term result of collagen crosslinking in pellucid marginal degeneration. *Adv Biomed Res* 2016;5:194.
8. Yildirim A, Cakir H, Kara N, Uslu H, Gurler B, Ozgurhan EB, Colak HB. Corneal collagen crosslinking for ectasia after laser in situ keratomileusis: Long-term results. *J Cataract Refract Surg* 2014;40:10:1591–1596.
9. Gokul A, Patel DV, Watters GA, McShee CN. The natural history of corneal topographic progression of keratoconus after age 30 in non-contact lens wearers. *Br J Ophthalmol* 2017;101:839–844.
10. Moshirfar M, Walker BD, Birdsong OC. Cataract surgery in eyes with keratoconus: A review of the current literature. *Curr Opin Ophthalmol* 2018;29:1:75–80.
11. Vega-Estrada A, Alio JL, Brenner LF, Javaloy J, Plaza Puche AB, Barraquer RI, Teus MA, Murta J, Henriques J, Uceda-Montanes A. Outcome analysis of intracorneal ring segments for the treatment of keratoconus based on visual, refractive and aberrometric impairment. *Am J Ophthalmol* 2013;155:3:575–584.
12. Khan MI, Injaria A, Muhtaseb M. Intrastromal corneal ring segments for advanced keratoconus and cases with high keratometric asymmetry. *J Cataract Refract Surg* 2011;38:129–136.
13. Yeung SN, Fu JYF, Lichtinger A, Low SAW, Kim P, Rootman DS. Efficacy of single or paired intrastromal corneal ring segment implantation combined with collagen crosslinking in keratoconus. *J Cataract Refract Surg* 2013;39:1146–1151.
14. Rathi VM, Mandathara PS, Dumpati S, Sangwan VS. Scleral lens after intracorneal ring segments in patients with keratoconus. *Cont Lens Anterior Eye* 2018;41:2:234–237.
15. Vincente L, Boxer-Wachler BS. Factors that correlate with improvement in vision after combined Intacs and trans-epithelial corneal crosslinking. *Br J Ophthalmol* 2010;94:1597–1601.
16. Chan CCK, Sharma M, Wachler BS. Effect of inferior-segment Intacs with and without C3-R on keratoconus. *J Cataract Refract Surg* 2007;33:75–80.
17. Ertan Q, Karacal H, Kamburoglu G. Refractive and topographic results of transepithelial cross-linking treatment in eyes with Intacs. *Cornea* 2009;28:719–723.
18. Kilic A, Kamburoglu G, Akinci A. Riboflavin injection into the corneal channel for combined collagen crosslinking and intrastromal corneal ring segment implantation. *J Cataract Refract Surg* 2012;38:878–883.
19. Coskunseven E, Jankov MR, Hafezi F, et al. Effect of treatment sequence in combined intrastromal corneal rings and corneal collagen crosslinking for keratoconus. *J Cataract Refract Surg* 2009;35:2084–2091.
20. Kamburoglu G, Ertan A. Intacs implantation with sequential collagen cross-linking treatment in postoperative LASIK ectasia. *J Refract Surg* 2008;24:726–729.



Myopia: Causes and Treatments

Due to the increasing prevalence of myopia across the globe, researchers and clinicians are searching for better therapies.

Gabrielle James, BS, and Jonathan H. Salvin, MD, Philadelphia

For many people, their world seems to be getting smaller: The prevalence of myopia, commonly due to an increase in axial length of the eye causing a distant image to be projected anterior to the retinal plane,¹ is increasing. The prevalence of myopia in the United States increased from 25 percent to 41.6 percent between the years 1971 and 2004.² Worldwide it is estimated that a total of 277 million people (4 percent of the global population) are myopic.³ This is projected to increase to 938 million (9.8 percent of the global population) by 2050.³ Myopia is also occurring earlier in children. In 2000, the highest prevalence of myopia was in people ages 25 to 29.

This increasing prevalence of myopia and its subsequent consequences pose a major public health concern. Although spectacle correction can improve vision, uncorrected refractive error is the most common cause of distance vision impairment and the second most common cause of blindness globally.⁴ It's associated with an increased risk of cataract, glaucoma, retinal detachment and myopic macular degeneration, all of which increase

the risk of uncorrectable vision loss.⁵ These risks increase with high myopia (greater than -6 D).⁶ Also, it's estimated that the global economic burden associated with uncorrected distance refractive error is \$202 to 268 billion per year.^{7,8} For these reasons, delaying the onset of myopia and/or slowing myopia progression has been the focus of significant study. In this article, we'll look at potential causes of this trend and the pros and cons of our current myopia treatments.

Etiology

Understanding the underlying cause of myopia could help identify potential targets for therapeutic intervention and slow or prevent progression and myopic complications. Evidence points to both a genetic and environmental basis for myopia. One study found 21 gene candidates for it.⁹ These genes are involved in several different pathways, including mannosylation, glycosylation, lens development, gliogenesis and Schwann cell differentiation.⁹ In addition, intrinsic circadian clock genes such as melatonin receptor and photopigment

melanopsin genes were found to be upregulated in an experimental model, suggesting that circadian rhythm might play a role in myopia development.⁴²

Myopia has also been linked to chronic inflammation. Researchers observed an increased prevalence of myopia in children with inflammatory disease such as type 1 diabetes mellitus, uveitis and systemic lupus erythematosus. Additionally, in hamsters with myopia they found an increased expression of proteins involved in inflammation such as c-Fos, (NFκB), interleukin 6 (IL-6) and tumor necrosis factor alpha (TNFα).³⁸ There was an increase in expression of these proteins seen in eyes treated with lipopolysaccharide and peptidoglycan, and a corresponding increase in myopia progression in hamsters. Similarly, there was a decrease in inflammatory protein expression and a corresponding decrease in myopia progression in hamsters treated with cyclosporine, an anti-inflammatory medication.³⁸

Environmentally, myopia could be driven by numerous changes in lifestyle that have occurred in recent generations. Children and adults

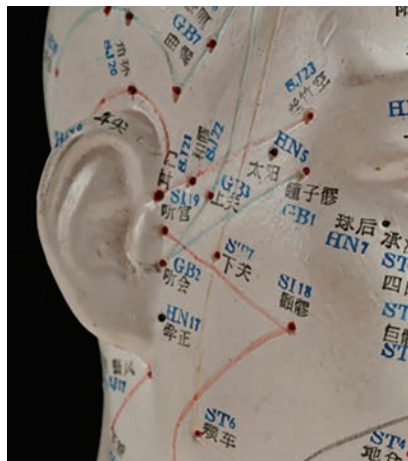
spending less time outdoors has been implicated as a causative factor.¹⁰ One study found that changes in luminance contrast were associated with hyperopic shifts whereas changes in color contrast were associated with myopic shifts.¹¹ Other lifestyle changes that have been suggested as playing a role in causing or exacerbating myopia include increased time performing near-work activities, peripheral hyperopia in the myopic eye and diet.^{1,10,12,13}

Treatments

In an effort to combat this increasingly prevalent condition, researchers and clinicians have developed many therapies, from the mundane to the exotic.

- **Contact lenses.** Soft contact lenses and rigid gas-permeable contact lenses have both been studied to see their effects on the progression of myopia. Research has shown that SCL wear by children is safe and not associated with an increase in myopia progression. SCLs don't increase axial length, corneal curvature or myopia when compared to spectacle lens wear in children, nor do they decrease myopic progression.¹⁴ RGP were found to decrease myopia progression in comparison to SCL wearers. However, this delay in progression was linked to a steepened corneal curvature, as opposed to a significant difference in axial growth, and therefore doesn't indicate viability for myopia control.¹⁵

- **Orthokeratology.** Orthokeratology is the use of overnight rigid contact lenses to reshape the cornea. It works by flattening the central cornea, thinning the central corneal epithelium, thickening the mid-peripheral cornea, and producing a myopic shift in the peripheral vision. This temporarily reduces or eliminates refractive error and decreases the need to wear contact lenses or spectacles in



One study found a synergistic effect of acupoint treatment (a model of the various acupoints is shown here) and low-dose atropine in decreasing the progression of myopia.

the daytime. Researchers found that orthokeratology is as effective as atropine in delaying myopic progression.

Although orthokeratology potentially eliminates the side effects of atropine, it has the potential for significant side effects of its own, including corneal infections, an increase in higher-order corneal aberrations and a decrease in contrast sensitivity.³² Orthokeratology also induces a temporary shift in corneal curvature that returns to baseline after the treatment is stopped. There is limited evidence of slowed long-term axial length changes.

- **Refractive undercorrection.** Studies in infant monkeys have supported the idea that undercorrection could alter the eye's growth and therefore change its refractive ability.¹⁶ Therapeutic undercorrection may also reduce the near-vision accommodative response which may be a factor in myopic progression. However, when studied, there was no significant difference in myopic progression in children prescribed with undercorrected lenses in comparison to children with fully corrected lenses.¹⁷

- **Part-time spectacle wear.** It's thought that optical defocus plays an

important role in the development of myopia. One study explored the effects of different patterns of lens wear on myopia progression. There was no significant difference in the three-year progression between the full-time lens wearers, those who switched from distance-only to full-time wear, distance-only wearers and non-wearers.¹⁸ This suggests that part-time lens wear is ineffective in the treatment of myopia progression.

- **Bifocal and multifocal spectacle correction.** It's been hypothesized that bifocal or multifocal glasses correction could reduce retinal defocus and thus slow myopia progression. However, several clinical trials have shown no significant difference in myopia progression.^{19,20} One study, though, reported that bifocal-only spectacles and bifocal spectacles with base-in prism slowed myopia progression by 39 percent and 50 percent, respectively, in Chinese-Canadian children.²¹⁻²³

- **Progressive-addition spectacle lenses.** Progressive-addition lenses, in comparison to single-vision lenses, were associated with a decrease in myopia progression, but this difference failed to reach clinical significance.²⁴ The authors concluded that although there was a small decrease in myopia progression, this didn't warrant a change in clinical guidelines.²⁴

- **Peripheral retinal defocus.** Studies have suggested that the peripheral retina and peripheral vision have roles in the pathogenesis of myopia. In primates, it was found that foveal ablation didn't have an effect on the emmetropization process.²⁵ The absence of central vision didn't affect the development of myopia, suggesting that peripheral vision has a more important role. However, in humans it was found that relative peripheral hyperopia had little association with the risk of myopia onset, myopia progression or axial growth.²⁶⁻²⁹ A study comparing children who wore spec-

tacle lenses that decreased relative peripheral hyperopia to children who wore single-vision spectacle lenses found no significant difference between the two groups. However, in children of myopic parents with higher rates of myopia progression, it was found that correction of relative peripheral hyperopia reduced myopia progression.³⁰



- **Pirenzepine.** Pirenzepine is a selective M1 muscarinic receptor antagonist. It's more selective than atropine (discussed below), and therefore results in less cycloplegia and mydriasis.³¹ It was shown that 12-month use of 2% topical pirenzepine ophthalmic gel twice a day is associated with a 40-percent reduction in axial length.²⁵ Unfortunately, pirenzepine gel isn't commercially available for use.³² Further studies on pirenzepine's long-term safety and efficacy are still warranted.

- **Atropine.** There has been extensive research on the use of atropine in the prevention of myopia progression. Atropine is a nonselective muscarinic antagonist thought to work on the five muscarinic receptor subtypes in the human eye, M1 through M5, and inhibit glycosaminoglycan synthesis in scleral fibroblasts.^{11,25} Additionally, it's been proposed that, like light, atropine activates the parasympathetic nervous system through the five muscarinic receptor subtypes found on the human iris sphincter, ciliary body, and throughout the retina, sclera and lens.¹¹ Not only is atropine thought to work directly on the muscarinic receptors in the eye, but it's also thought to increase or decrease the amount of these receptors.¹¹

Multiple studies in the literature have reported that atropine use has significantly delayed the progression of myopia and axial elongation.^{6,33-35} Atropine also downregulates inflammatory markers in the eye thought to be involved in myopia progression. Myopic hamsters treated with atro-

pine in the eyes had a decrease in expression of proteins such as c-Fos, NFκB, Il-6 and TNFα, indicating an inflammatory pathway related to myopia.³⁸

Myopic rebound is a concern after discontinuing use of high-dose atropine treatment. However, myopic rebound is seen to a lesser extent with low-dose atropine (0.01%).³³ Additionally, slowly tapering the frequency of atropine instead of abruptly stopping treatment might retain the beneficial effect on myopia progression. Immediately stopping high-dose atropine releases its inhibitory effect, causing a growth spurt that contributes to myopia progression.¹¹


There's been some evidence that combining atropine treatment with another myopia treatment could have an additive effect on decreasing myopia progression.


Initially, differences in iris color were another source of concern with atropine use. Having a lighter-color iris was considered a contraindication to atropine use due to an increase in reports of adverse events such as photophobia, allergy and poor near vision in such patients.³⁵ However, it was found that similar rates of these adverse events were reported in Asian children with dark-colored irises and Caucasian children with light-colored irises.³⁵ Therefore, light-colored irises should no longer be considered a contraindication to atropine use.

One difficulty with atropine is predicting which children will benefit the most from it. Some evidence has pointed to greater effects of atropine treatment in Asian children in comparison to Caucasians.³⁹ However, atropine has been shown to be effective in many different populations, including Caucasians, Asians and Indians.^{11,40} More research is needed to better understand the variability in responses to atropine treatment.

It's also been shown that atropine 0.5%, 0.1% and 0.01% are safe and effective, and there's no decrease in efficacy with decreasing dosage.^{35,36} This is important because a lower dosage of atropine is associated with fewer side effects such as poor near vision, loss of accommodation due to cycloplegia and glare, and is also associated with a decreased risk of needing an add power in glasses.³⁶ Additionally, atropine treatment doesn't have any adverse effects on intraocular pressure, optic nerve parameters or retinal nerve fiber layer thickness.⁴² Delay in myopic progression and corresponding axial length change by atropine use is thought to be sustained over the long term due to the natural slowing of eye growth.³⁷

One group of researchers postulated that low-dose atropine produces a sustained response in comparison to high-dose atropine by working more anteriorly in the eye and affecting various muscarinic receptors at different levels.¹¹

There's been some evidence that combining atropine treatment with another myopia treatment could have an additive effect in decreasing myopia progression. To test this idea, one group of researchers investigated the effects of low-dose atropine treatment with and without auricular acupoint stimulation in myopes.⁴³ They found that patients treated with this combination had less myopic progression, less axial length elongation, more anterior chamber deepening, and great-

er reductions in intraocular pressure in comparison to patients treated with just atropine.⁴³

Researchers are also studying how to improve atropine delivery to the eye. Two studies have shown that drug-eluting silicone hydrogel soft contact lenses can potentially deliver atropine.^{44,45} This could eliminate the need for regular drop instillation and improve compliance.

Ongoing studies are looking to answer questions such as which children would benefit most from atropine treatment, the optimal age to begin the treatment, the ideal length of treatment and whether treatments could be combined for better efficacy.

In conclusion, myopia and its associated complications are an increasing public health concern. While glasses and contact lens correction are valuable in treating the symptomatic vision changes associated with myopia, they don't change the anatomic progression of the myopic eye. Low-dose atropine use (0.01%) remains the most encouraging treatment choice available at this time, though we need more studies to identify its optimal use. Additional environmental studies will also help determine if there are lifestyle changes that could slow myopia's progression. In the meantime, vision screening and early detection remain essential for diagnosis and correction to avoid the loss of correctable, functional vision. **REVIEW**

Ms. James is a medical student at the Sidney Kimmel College of Medicine, Thomas Jefferson University in Philadelphia, where Dr. Salvin serves as a clinical associate professor of pediatrics and ophthalmology. Dr. Salvin is also affiliated with the Division of Ophthalmology at the Nemours/A.I. duPont Hospital for Children in Wilmington, Delaware, and Wills Eye Hospital.

1. Williams KM, Bertelsen G, Cumberland P, et al. Increasing prevalence of myopia in Europe and the impact of education.

Ophthalmology 2015;122:7:1489-1497.

2. Vitale S, Sperduto RD, Ferris FL, III. Increased prevalence of myopia in the United States between 1971-1972 and 1999-2004. Archives of Ophthalmology 2009;127:12:1632-1639.

3. Holden BA, Fricke TR, Wilson DA, et al. Global prevalence of myopia and high myopia and temporal trends from 2000 through 2050. Ophthalmology 2016;123:5:1036-1042.

4. Bourne RRA, Stevens GA, White RA, et al. Causes of vision loss worldwide, 1990-2010: A systematic analysis. The Lancet Global Health 2013;1:6:349.

5. Wong TY, Ferreira A, Hughes R, Carter G, Mitchell P. Epidemiology and disease burden of pathologic myopia and myopic choroidal neovascularization: An evidence-based systematic review. American Journal of Ophthalmology 2014;157:1:25.

6. Gong Q, Liu L. Therapeutic effect of atropine 1% in children with low myopia. Journal of American Association for Pediatric Ophthalmology and Strabismus 2016;20:4:379.

7. The Eye Diseases Prevalence Research, Group. The prevalence of refractive errors among adults in the United States, Western Europe and Australia. Archives of Ophthalmology 2004;122:4:495-505.

8. Smith TST, Frick KD, Holden BA, Fricke TR, Naidoo KS. Potential lost productivity resulting from the global burden of uncorrected refractive error. Bulletin of the World Health Organization 2009;87:6:431.

9. Flitcroft DJ, Loughman J, Wildsoet CF, et al. Novel myopia genes and pathways identified from syndromic forms of myopia. Investigative Ophthalmology & Visual Science 2018;59:1:338-348.

10. Morgan IG, Ohno-Matsui K, Saw S. Myopia. The Lancet 2012;379:9827:1739-1748.

11. Rucker F, Wallman J. Chicks use changes in luminance and chromatic contrast as indicators of the sign of defocus. Journal of Vision 2012;12:6:23.

12. Smith EL, Hung L, Arumugam B. Visual regulation of refractive development: Insights from animal studies. Eye (London, England) 2014;28:2:180.

13. Lim LS, Gazzard G, Low Y, et al. Dietary factors, myopia, and axial dimensions in children. Ophthalmology 2010;117:5:997.

14. Walline JJ, Jones LA, Sinnott L, et al. A randomized trial of the effect of soft contact lenses on myopia progression in children. Investigative Ophthalmology & Visual Science. 2008;49:11:4702-4706.

15. Walline JJ, Jones LA, Mutti DO, Zadnik K. A randomized trial of the effects of rigid contact lenses on myopia progression. Archives of Ophthalmology 2004;122:12:1760-1766.

16. Smith III EL, Hung L. The role of optical defocus in regulating refractive development in infant monkeys. Vision Research 1999;39:8:1415-1435.

17. Adler D, Millodot M. The possible effect of undercorrection on myopic progression in children. Clinical & Experimental Optometry 2006;89:5:315-321.

18. Ong E, Grice K, Held R, Thorn F, Gwiazda J. Effects of spectacle intervention on the progression of myopia in children. Optometry and Vision Science 1999;76:6:363-369.

19. Jensen H. Myopia progression in young school children. A prospective study of myopia progression and the effect of a trial with bifocal lenses and beta blocker eye drops. Acta ophthalmologica (Supplement) 1991:200:1.

20. Pärssinen O, Hemminki E, Klemetti A. Effect of spectacle use and accommodation on myopic progression: Final results of a three-year randomised clinical trial among schoolchildren. The British Journal of Ophthalmology 1989;73:7:547-551.

21. Cheng D, Woo GC, Drobe B, Schmid KL. Effect of bifocal and prismatic bifocal spectacles on myopia progression in children: Three-year results of a randomized clinical trial. JAMA Ophthalmology 2014;132:3:258-264.

22. Cheng D, Schmid KL, Woo GC, Drobe B. Randomized trial of effect of bifocal and prismatic bifocal spectacles on myopic progression: Two-year results. Archives of Ophthalmology 2010;128:1:12-19.

23. Cheng D, Woo GC, Schmid KL. Bifocal lens control of myopic progression in children. Clinical & Experimental Optometry

2011;94:1:24.

24. Gwiazda J, Hyman L, Hussein M, et al. A randomized clinical trial of progressive addition lenses versus single vision lenses on the progression of myopia in children. Investigative Ophthalmology & Visual Science. 2003;44:4:1492.

25. Leo SW, Scientific Bureau of World Society of Paediatric Ophthalmology and Strabismus (WSPPOS). Current approaches to myopia control. Curr Opin Ophthalmol 2017;28:3:267-275.

26. Smith EL, Ramamirtham R, Qiao-Grider Y, et al. Effects of foveal ablation on emmetropization and form-deprivation myopia. Investigative Ophthalmology & Visual Science 2007;48:9:3914.

27. Mutti DO, Hayes JR, Mitchell GL, et al. Refractive error, axial length, and relative peripheral refractive error before and after the onset of myopia. Investigative Ophthalmology & Visual Science 2007;48:6:2510.

28. Mutti DO, Sinnott LT, Mitchell GL, et al. Relative peripheral refractive error and the risk of onset and progression of myopia in children. Investigative ophthalmology & visual science 2011;52:1:199.

29. Sng CCA, Lin X, Gazzard G, et al. Change in peripheral refraction over time in Singapore Chinese children. Investigative Ophthalmology & Visual Science 2011;52:11:7880.

30. Sankaridurg P, Donovan L, Varnas S, et al. Spectacle lenses designed to reduce progression of myopia: 12-month results. Optometry and Vision Science 2010;87:9:631-641.

31. Huang J, Wen D, Wang Q, et al. Efficacy comparison of 16 interventions for myopia control in children: A network meta-analysis. Ophthalmology 2016;123:4:697-708.

32. Galvis V, Tello A, Parra MM, et al. Five-year clinical trial on atropine for the treatment of myopia 2: Myopia control with atropine 0.01% eyedrops. Ophthalmology 2016;123:6:41.

33. Chia A, Chua W, Wen L, Fong A, Goon YY, Tan D. Atropine for the treatment of childhood myopia: Changes after stopping atropine 0.01%, 0.1% and 0.5%. American Journal of Ophthalmology 2014;157:2:457.

34. Pineles SL, Kraker RT, VanderVeen DK, et al. Atropine for the prevention of myopia progression in children: A report by the American Academy of Ophthalmology. Ophthalmology 2017;124:12:1857-1866.

35. Gong Q, Janowski M, Luo M, et al. Efficacy and adverse effects of atropine in childhood myopia: A meta-analysis. JAMA Ophthalmology 2017;135:6:624-630.

36. Chia A, Chua W, Cheung Y, et al. Atropine for the treatment of childhood myopia: Safety and efficacy of 0.5%, 0.1%, and 0.01% doses (atropine for the treatment of myopia 2). Ophthalmology 2012;119:2:347-354.

37. Chia A, Lu Q, Tan D. Five-year clinical trial on atropine for the treatment of myopia 2: Myopia control with atropine 0.01% eyedrops. Ophthalmology 2016;123:2:391-399.

38. Lin H, Wei C, Chang C, et al. Role of chronic inflammation in myopia progression: Clinical evidence and experimental validation. EBioMedicine 2016;10:269-281.

39. Li S, Wu S, Kang M, et al. Atropine slows myopia progression more in Asian than white children by meta-analysis. Optometry and Vision Science 2014;91:3:342-350.

40. Kothari M, Rathod V. Efficacy of 1% atropine eye drops in retarding progressive axial myopia in Indian eyes. Indian Journal of Ophthalmology 2017;65:11:1178-1181.

41. Chan L, Hsieh Y, Hsu W, Cheng H, Shen EP. Optic disc parameters of myopic children with atropine treatment. Curr Eye Res 2017;42:12:1614-1619.

42. Stone RA, Pardue MT, Iuvone PM, Khurana TS. Pharmacology of myopia and potential role for intrinsic retinal circadian rhythms. Experimental Eye Research 2013;114:35-47.

43. Cheng H, Hsieh Y. The effect of low-concentration atropine combined with auricular acupoint stimulation in myopia control. Complementary Therapies in Medicine 2014;22:3:449-455.

44. Hui A, Bajgrowicz-Cieslak M, Phan CM, Jones L. In vitro release of two anti-muscarinic drugs from soft contact lenses. Clinical Ophthalmology 2017;1657-1665.

45. Lasowski F, Sheardown H. Atropine and roscovitine release from model silicone hydrogels. Optometry and Vision Science 2016;93:4:404-411.

Phaco vs. Femto Laser Cataract Surgery

Researchers from the Bascom Palmer Eye Institute in Miami conducted a retrospective case series to compare the outcomes in eyes with Fuchs' endothelial corneal dystrophy after standard phacoemulsification with those undergoing femtosecond laser-assisted cataract surgery.

The researchers reviewed charts from patients diagnosed with Fuchs' dystrophy who had phacoemulsification at Bascom Palmer between January 1, 2014, and January 1, 2017. The Institutional Review Board at the University of Miami Human Subjects Research Office approved the study protocol. Complicated surgeries and cases with concurrent keratoplasty, previous keratoplasty or glaucoma surgery, or a follow-up shorter than three months were excluded. The corrected distance visual acuity, central corneal thickness, and corneal edema at each visit were analyzed. Clinically significant corneal decompensation was defined as corneal edema with CDVA worse than 20/50 lasting more than three months, any case resulting in keratoplasty or both.

The study comprised 207 eyes of 207 patients (64 femtosecond laser-assisted cataract surgery, 143 conventional phacoemulsifica-

tion). Demographics and follow-up time (mean 30 months) were similar between groups ($p>0.05$). The proportion of cases progressing to clinically significant decompensation (13 percent) was similar between the groups ($p>0.05$). Univariate Cox survival analysis also found no difference (hazard ratio, 1.0; 95 percent confidence interval, 0.4 to 2.7; $p=0.96$).

From these results, the researchers concluded that compared with conventional phacoemulsification, femtosecond laser-assisted cataract surgery did not lower the rate of corneal decompensation in eyes with mild to moderate Fuchs' endothelial corneal dystrophy.

J Cataract Refract Surg 2018;44:534-540.

Zhu DC, Shah P, Feuer WJ, Shi W, Koo EH

Appointments: Medicaid vs. Private Insurance

In this prospective, cohort study conducted from January 1, 2017, to July 1, 2017, researchers made phone calls to a randomly selected sample of vision-care professionals in Michigan and Maryland stratified by neighborhood (urban vs. rural) and professional type (ophthalmologist vs. optometrist) to request the first available appointment. Appointments were sought

for an adult needing a diabetic eye examination and a child requesting a routine eye examination for a failed vision screening. Researchers called each practice twice, once requesting an appointment for a patient with Medicaid and the other time for a patient with Blue Cross Blue Shield insurance, and asked whether the insurance was accepted and, if so, when the earliest available appointment could be scheduled.

A total of 603 telephone calls were made to 330 eye-care professionals (414 calls [68.7 percent] to male and 189 calls [31.3 percent] to female doctors). The sample consisted of ophthalmologists (303 [50.2 percent]) and optometrists (300 [49.8 percent]) located in Maryland (322 [53.4 percent]) and Michigan (281 [46.6 percent]). The rates of successfully obtaining appointments among callers were 61.5 percent (95% CI, 56.0 to 67 percent) for adults with Medicaid and 79.3 percent (95% CI, 74.7 to 83.9 percent) for adults with BCBS ($p<0.001$) and 45.4 percent (95% CI, 39.8 to 51.0 percent) for children with Medicaid and 62.5 percent (95% CI, 57.1 to 68 percent) for children with BCBS ($p<0.001$). Mean wait time didn't vary significantly between the BCBS and

Medicaid groups for either adults or children.

Adults with Medicaid had significantly decreased odds of receiving an appointment compared with those with BCBS (odds ratio [OR], 0.41; 95% CI, 0.28 to 0.59; $p < 0.001$) but had increased odds of obtaining an appointment if they were located in Michigan vs. Maryland (OR, 2.40; 95% CI, 1.49 to 3.87; $p < 0.001$) or with an optometrist vs. an ophthalmologist (OR, 1.91; 95% CI, 1.31 to 2.79; $p < 0.001$). Children with Medicaid had significantly decreased odds of receiving an appointment compared with those with BCBS (OR, 0.41; 95% CI, 0.28 to 0.60; $p < 0.001$), and also had better odds of getting an appointment if they were in Michigan vs. Maryland (OR, 1.68; 95% CI, 1.04 to 2.73; $p = 0.03$), or with an optometrist vs. an ophthalmologist (OR, 8.00; 95% CI, 5.37 to 11.90; $p < 0.001$).

The researchers say that these results suggest a disparity in access to eye care based on insurance status, although confounding factors may have contributed to this finding. Improving access to eye-care professionals for those with Medicaid may improve health outcomes and decrease health-care spending in the long term, the investigators add.

JAMA Ophthalmol 2018;136:622-629.

Lee Y, Chen A, Varadaraj V, et al

Choroidal Thickness with Drusenoid PED

In a consecutive observational case series, researchers from New York City analyzed the changes in visual acuity and subfoveal choroidal thickness in patients with non-neovascular age-related macular degeneration and drusenoid pigment epithelium detachments.

The researchers conducted a

retrospective review of eyes diagnosed with drusenoid PED in a single clinical setting. Demographic and clinical data included age, sex, laterality, best-corrected visual acuity and subfoveal choroidal thickness measured at baseline, before and after the collapse of the PED, and at the last available follow-up. The presence of geographic atrophy was also assessed.

Thirty-seven eyes of 25 patients (18 female) were included in the analysis. Mean age at baseline was 71 ± 8.4 years. During a mean follow-up period of 4.9 ± 1.9 years, PED collapse was observed in 25 eyes (68 percent). Mean BCVA, mean maximum PED height, and mean subfoveal choroidal thickness significantly decreased from baseline to the last available follow-up ($p < 0.001$) in patients showing PED collapse. Choroidal thinning was faster during the PED collapse (speed rate of $35.9 \mu\text{m}/\text{year}$). From those, 23 eyes (92 percent) developed GA. A significant correlation between the area of GA and the decrease in choroidal thickness was found ($p = 0.010$).

Based on these results, choroidal thickness significantly decreased in eyes showing drusenoid PED collapse, but not in eyes in which the PED persisted. Researchers found a significant correlation with resultant GA area following PED collapse and the magnitude of choroidal thinning. They note that further studies are warranted to better understand the mechanisms involved in the occurrence of choroidal changes during the life cycle of drusenoid PEDs.

Am J Ophthalmol 2018;191:23-33.

Dolz-Marco R, Balaratnasingam C, Gattoussi S, et al.

(Continued from page 24)

extended, which isn't common. All Category III codes end in the letter "T" to denote their temporary nature.

Q What is the payment within Medicare?

A New Category III codes generally do not have coverage at all. Individual Medicare Administrative Contractors (MACs) get to decide whether to cover them—and at what reimbursement; since that may take some time with a new code, a financial waiver of some sort (ABN for Part B, for example) is a good idea since these will likely both be patient-pay at first.

Q Can I use another code that already has coverage instead of these so my patients don't have to pay out-of-pocket?

A No. New code 0507T already makes the case in the parenthetical note that 92285 (the most likely other code) is improper. Additionally, CPT has long noted that if there is a code of any sort that fits and is active, it must be used. Even an unlisted code such as 92499 (unlisted ophthalmological service or procedure) is not correct. CPT notes the following in the Overview to the Category III section of the book: "The following section contains a set of temporary codes for emerging technology, services, procedures and service paradigms. Category III codes allow data collection for these services/procedures." CPT also states: "Use of unlisted codes does not offer the opportunity for the collection of specific data. If a Category III code is available, this code must be reported instead of a Category I unlisted code." REVIEW

Mr. Larson is a senior consultant at the Corcoran Consulting Group. Contact him at plarson@corcoranccg.com.

25TH ANNUAL

OPHTHALMIC

Product Guide



Innovative products to
enhance your practice

The **future**
is in your
hands. One
tap, many
possibilities.

Experience the digital edition on your handheld device.
Use your smart device to scan the code below or visit:



www.reviewofophthalmology.com/publications/archive

Download a QR scanner app. Launch app and hold your mobile device over
the code to view www.reviewofophthalmology.com/publications/archive.

REVIEW[®]
of Ophthalmology

FDA Approval of iStent Inject

In late June, Glaukos announced that its iStent Inject Trabecular Micro-Bypass System received FDA approval. Glaukos says that the iStent Inject is indicated for the reduction of intraocular pressure in adult mild-to-moderate primary open-angle glaucoma patients who are undergoing concomitant cataract surgery.

The iStent Inject creates two patent bypasses through the trabecular meshwork, resulting in a multi-directional flow through Schlemm's canal. It includes two heparin-coated titanium stents preloaded into an auto-injection system that allows surgeons to precisely implant stents into two meshwork locations through a sin-

gle corneal entry point, Glaukos says. Each iStent Inject stent is 0.23 x 0.36 mm.

For more information on Glaukos' iStent Inject, visit glaukos.com.

FDA Approval for Nexy Robotic Retinal Imaging

In mid-June, the FDA approved the new Nexy retinal camera for sale in the United States. Nexy is being used in Europe for diabetic eye-screening and other health-care initiatives to provide access to care in minimally served locations, through an optional service in which an expert can read securely distributed images.

This form of telemedicine may

also be used to integrate with artificial intelligence to extract additional information from the captured images.

Nexy is developed and manufactured by Next Sight (Prodenone, Italy), and is distributed in the United States exclusively by Konan Medical. Nexy offers hands-off operation as well as features designed to integrate telemedicine and AI applications.

For more information on Nexy, visit nextsight.info.

Onefit Scleral Lens Cleared For Dry Eye

Blanchard Contact Lenses recently announced that its Onefit family of scleral lenses now has clearance from the FDA for therapeutic applications, including the treatment of dry eye, contingent on the use of the Optimum Extra, Optimum Extreme or Hexa 100 materials from lens-material maker Contamac.

Blanchard says that the FDA clearance marks an advancement in the treatment of patients suffering from ocular surface conditions such as dry eye, Sjögren's syndrome, graft-versus-host disease, keratitis and more.

For more information regarding Onefit's scleral lenses, visit blanchardlab.com.



The iStent allows for the injection of two stents through a single corneal entry point.

Practice For Sale



Practice Sales • Appraisals • Consulting
www.PracticeConsultants.com

**PRACTICES FOR SALE
NATIONWIDE**

Visit us on the Web or call us to learn more about our company and the practices we have available.

info@PracticeConsultants.com

800-576-6935

www.PracticeConsultants.com

Career Opportunities

OPHTHALMOLOGISTS

Danbury, CT

Ophthalmologists to share office with long standing Ophthalmologist in Danbury, CT. High quality equipment. \$2,250 per month or adjoining office without equipment- \$1,750 per month.

203-545-3539 or
email mehrimd@aol.com



**FOR CLASSIFIED
ADVERTISING
CONTACT US TODAY:**

Toll free: **888-498-1460**
E-mail: sales@kerhgroup.com



Career Opportunities



Targeting
Ophthalmologists?

**CLASSIFIED ADVERTISING
WORKS**



Contact us today
for classified advertising:
Toll free: **888-498-1460**
E-mail: sales@kerhgroup.com



FIND MORE PRACTICES FOR SALE ON



CONTACT US TODAY to list your practice:
888-498-1460
opticlassifieds@kerhgroup.com

www.opticlassifieds.com

An 88-year old man with a right medial canthal lesion is evaluated at the Wills Eye Oculoplastics Service.

Joshua Uhr, MD, and Edward H. Bedrossian, MD

Presentation

An 88-year-old Caucasian male with a history of basal cell carcinoma of the right cheek and right medial canthus was referred to the Wills Eye Oculoplastics Service for evaluation of a lesion near the right lower punctum and right medial canthus.

Medical History

Past medical history included BCC of the right cheek, status-post excision and reconstruction 27 years prior to presentation, with recurrence 19 years ago. The patient also underwent Mohs surgery for BCC of the right medial canthus (RMC) three years prior to presentation and subsequently had a dacryocystorhinostomy with a bicanalicular stent. He developed recurrence at the RMC a year prior to this exam and had excision and reconstruction with a mid-forehead flap and a tarsoconjunctival transposition (Hughes) flap.

Additional past medical history revealed prostate cancer, status-post radiation; papillary thyroid cancer with metastasis to cervical lymph nodes treated with total thyroidectomy; left parotid gland cancer, status-post parotidectomy; hypertension and gastroesophageal reflux disease. Past ocular history included bilateral lower eyelid ectropion repair, cataract surgery in the left eye and advanced glaucoma in the right eye. Social history was significant for being a former smoker with a 10 pack-year history. Family history was non-contributory.

Current medications were artificial tears in both eyes, tobramycin ointment in the right eye, levothyroxine, amlodipine, omeprazole, aspirin and a multivitamin.

Examination

External examination revealed a small ulcerated lesion with a pearly base at the right medial canthus (*Figure 1*). A 40 x 25-mm skin graft inferior to the right lower lid and a right-sided 20 x 25-mm forehead flap were present. Ptosis of the right upper lid was noted, with a margin reflex distance 1 of -2 mm and levator function of 12 mm; MRD1 and LF of the left upper lid were 5 mm and 18 mm, respectively. Visual acuity was count fingers OD and 20/20 OS. A right relative afferent pupillary defect was observed. Motility exam of the right eye demonstrated 100-percent abduction, 5-percent supraduction, 0-percent adduction, and 50-percent infraduction. Motility of the left eye was full. Confrontation visual fields revealed a superior field defect in the right eye and were full in the left eye. Intraocular pressures were normal in both eyes. Slit lamp examination was notable for trace injection and 2+ nuclear sclerosis in the right eye and a posterior chamber intraocular lens in the left eye. Dilated fundus examination revealed a glaucomatous optic nerve but was otherwise normal. Fundus examination of the left eye was normal.

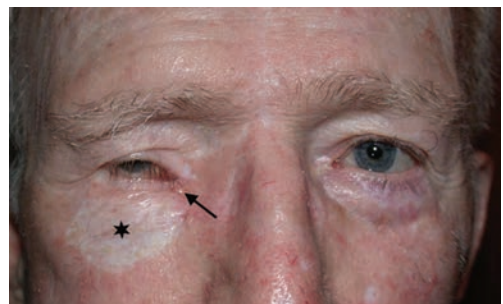

Figure 1. External eye photo showing a small, ulcerated lesion with a pearly base (arrow) at the right medial canthus and a skin graft (star) from a prior basal cell carcinoma.

What is your diagnosis? What further workup would you pursue? The diagnosis appears on p. 64.

Workup, Diagnosis and Treatment

Prior to referral to the Wills Eye Hospital, a surveillance MRI of the orbits had demonstrated an enhancing amorphous increase in soft tissue inseparable from the right medial canthal tendon and anterior margin of the medial rectus (*Figure 2A*); the lesion demonstrated deep adnexal involvement with extension inferiorly into the nasolacrimal duct (*Figure 2B*). An orbitotomy for biopsy of the orbital mass, ethmoid mucosa and lacrimal sac was performed, and histopathology from all sites was consistent with BCC. After discussing the treatment options, the patient decided to proceed with exenteration of the right orbit and ethmoidectomy in a combined case with the otolaryngology service. Frozen sections were obtained during the case, and the resection margins were negative for tumor. Permanent sections of the right exenterated or-

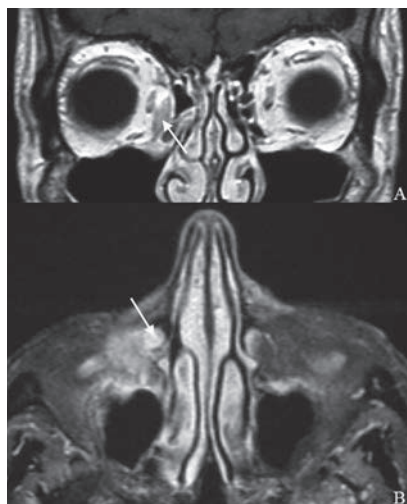


Figure 2. MRI of the orbits showing an enhancing increase in soft tissue in the right medial orbit (A, arrow) with extension inferiorly into the nasolacrimal duct (B, arrow).

bitar tissue, including the medial rectus, the inferior rectus and conjunc-

tiva, as well as the posterior ethmoid bone, were positive for tumor. Based on this finding, the patient opted for further surgery to resect the posterior ethmoid bone. Of note, during this case, the oculocardiac reflex was elicited when traction was placed near the optic nerve stump; the surgery was otherwise uneventful.

Approximately one year after exenteration, the patient underwent additional skull base surgery for recurrence, with placement of a skin flap over the empty orbit (*Figure 3*). Two years after exenteration, surveillance PET-CT revealed increased uptake in the right posterior maxilla with a 3-mm area of uptake in the left apical lung. Endoscopic biopsies revealed recurrent BCC of the orbit and bilateral frontal sinuses, for which the patient underwent adjuvant radiation therapy.

Discussion

Basal cell carcinoma is the most common malignancy in the world and is responsible for 90 percent of malignant eyelid tumors. More than 20 percent of basal cell carcinomas of the head and neck are periocular, with the lower lid being the most common site, followed by the medial canthus, upper lid and lateral canthus. BCC of the medial canthus is most likely to invade the orbit or present with aggressive histology, followed by the lower eyelid, the upper eyelid and the lateral canthus. Nevertheless, orbital invasion is rare, with reported incidence rates ranging from 1.6 to 2.5 percent.¹

Our patient presented to us for evaluation of a right medial canthal lesion with a history of multiple recurrences of basal cell carcinoma in that region. Imaging revealed invasion of the orbit with extension into

the nasolacrimal duct. Suspicion was high for recurrent BCC, which was confirmed by biopsy. Treatment options for periocular BCC consist of surgical excision (Mohs micrographic surgery or wide surgical excision with frozen sections), exenteration, radiotherapy, vismodegib (hedgehog pathway inhibitor), or imiquimod (topical immunotherapy), although vismodegib and imiquimod are newer therapies and were not yet available at the time of this patient's presentation. Topical, medical or radiation therapy may be used as adjuvant therapy or in patients who are poor surgical candidates, but surgical excision remains the treatment of choice in patients suitable for surgery. However, when there is bulbar extension or extensive orbital invasion, exenteration should be considered.^{1,2} In fact, intraorbital

spread of eyelid, globe or conjunctival malignancies is the most frequent indication for orbital exenteration.²

In an ambispective cohort study of 31 consecutive patients who underwent orbital exenteration for a malignant neoplasm invading the orbit, investigators found that the median (50 percent) survival period for all patients studied was 78.4 months. Median length of survival in patients with BCC was 60 months, although there was no significant difference in time to death when stratified by tumor histologic subtype (basal cell carcinoma, squamous cell carcinoma and other). The decision to perform orbital exenteration can be difficult since the operation results in substantial disfigurement and dysfunction for patients. However, the authors conclude that exenteration provides sufficiently good survival

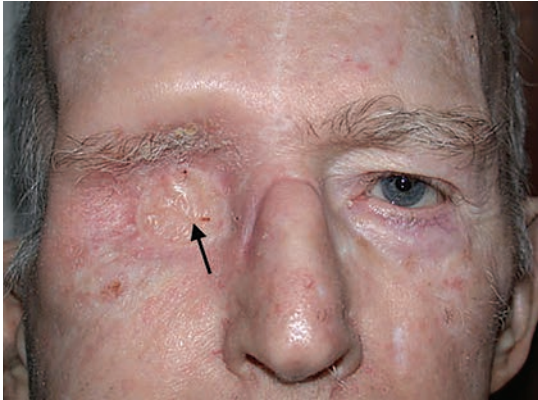

Figure 3. External photo showing the postoperative appearance after placement of a skin flap over the exenterated orbit.

outcomes to justify its use.²

Management options considered for our patient were radiation, surgical excision and orbital exenteration. Given the extent of this patient's orbital disease and his history of multiple recurrences, we thought that surgical excision or radiation would be unlikely to control his disease and exenteration would therefore offer him a better prognosis. In addition, given his visual acuity of count fingers in the right eye secondary to advanced glaucoma, exenteration would minimally impact his visual function. For these reasons, it was felt that the benefits of exenteration far outweighed the risks, and in fact, we questioned whether or not he would have benefited from exenteration earlier in his clinical course.

In addition to lending itself to a discussion of the management options of periorbital basal cell carcinoma, this case is also noteworthy for elicitation of the oculocardiac reflex from an empty orbit. This reflex was first reported in 1908 and has since become a well-documented clinical phenomenon.³ It has been reported to occur in a wide variety of ophthalmic procedures involving traction on the extraocular muscles,⁴⁻⁸ for which it is probably most familiar to ophthalmologists. In contrast, elicitation of the OCR from an empty orbit is rare, and only a handful of cases have been reported in the anesthesia lit-

erature.⁸⁻¹²

In conclusion, this is a case of an 88-year-old male with a history of multiple primary malignancies, including recurrent BCC of the right cheek and right medial canthus, who presented with recurrent right medial canthal basal cell carcinoma with orbital invasion and extension into the nasolacrimal duct. Given the extent of his orbital disease, the decision was made to proceed with exenteration. Despite an aggressive surgical approach, he developed skull base, orbital and frontal sinus recurrences, requiring multiple additional surgeries and radiation. **REVIEW**

1. Shi Y, Jia R, Fan X. Ocular basal cell carcinoma: A brief literature review of clinical diagnosis and treatment. *Onco Targets Ther* 2017;10:2483-2489.
2. Hoffman GR, Jefferson ND, Reid CB et al. Orbital exenteration to manage infiltrative sinonasal, orbital adnexal, and cutaneous malignancies provides acceptable survival outcomes: An institutional review, literature review, and meta-Analysis. *J Oral Maxillofac Surg* 2016;74:3:631-43.
3. Blanc VF, Hardy JF, Milot J et al. The oculocardiac reflex: A graphic and statistical analysis in infants and children. *Can Anaesth Soc J* 1983;30:4:360-9.
4. Apt L, Isenberg S, Gaffney WL. The oculocardiac reflex in strabismus surgery. *Am J Ophthalmol* 1973;76:4:533-6.
5. Anderson RL. The blepharocardiac reflex. *Arch Ophthalmol* 1978;96:8:1418-20.
6. Munden PM, Carter KD, Nerad JA. The oculocardiac reflex during enucleation. *Am J Ophthalmol* 1991;111:3:378-9.
7. Bailey JH. The oculocardiac reflex. *Am J Ophthalmol* 1935;18:1:22-25.
8. Kerr WJ, Vance JP. Oculocardiac reflex from the empty orbit. *Anesthesia* 1983;38:883-5.
9. Nicholson D, Kossler A, Topping K et al. Exaggerated oculocardiac reflex elicited by local anesthetic injection of an empty orbit: A case report. *AA Case Rep* 2017;9:12:337-8.
10. Tsai JC, Heitz JW. Oculocardiac reflex elicited during debridement of an empty orbit. *J Clin Anesth* 2012;24:5:426-7.
11. Ward B, Bass S. The oculocardiac reflex in a congenitally anophthalmic child. *Paediatr Anaesth* 2001;11:3:372-3.
12. Shanks AB, O'Carroll TM. Oculocardiac reflex from the empty orbit. *Anaesthesia* 1984;39:3:291-2.

For advertising opportunities contact:
 Michele Barrett (610) 492-1014
 or mbarrett@jobson.com
 James Henne (610) 492-1017
 or jhenne@jobson.com
 Michael Hoster (610) 492-1025
 or mhoster@jobson.com

Alimera Sciences, Inc. 5.6

Phone (844) 445-8843
www.alimerasciences.com

Heidelberg Engineering 2

Phone (800) 931-2230
 Fax (760) 598-3060

Keeler Instruments 12

Phone (800) 523-5620
 Fax (610) 353-7814

Lombart Instruments 25

Phone (800) 446-8092
 Fax (757) 855-1232

NuSight Medical Operations 21, 23

Phone (833) 468-5437
www.NuSightMedical.com

Omeros 11

Phone (206) 676-5000
 Fax (206) 676-5005

Optos North America 15

Phone (877) 455-8855 x 100
 Fax (508) 486-9310

Regeneron Pharmaceuticals, Inc. 17, 18

Phone (914) 847-7000
www.regeneron.com

S4OPTIK 37, 39

Phone (888) 224-6012

Shire Ophthalmics 67, 68

www.shire.com

This advertiser index is published as a convenience and not as part of the advertising contract. Every care will be taken to index correctly. No allowance will be made for errors due to spelling, incorrect page number, or failure to insert.

2ND YEAR OPHTHALMOLOGY RESIDENT WET LAB PROGRAMS

2018-2019 Residency Year

December 1-2, 2018
(Saturday-Sunday)
Fort Worth, TX

February 9-10, 2019
(Saturday-Sunday)
Fort Worth, TX

February 16-17, 2019
(Saturday-Sunday)
Fort Worth, TX

REGISTRATION OPEN

RESERVE SEAT

RESERVE SEAT

Dear Resident Program Director and Coordinator,

We would like to invite you to review the upcoming 2nd-Year Ophthalmology Resident Wet Lab Programs for the 2018-2019 Residency Year in Fort Worth. These programs offer a unique educational opportunity for second-year residents. To better familiarize beginning ophthalmologists with cataract surgery, these programs will consist of both didactic lectures and a state-of-the-art, hands-on wet lab experience. Technology and technique will be explained and demonstrated and surgeons will leave better prepared to optimize outcomes and manage complications when they arise.

The programs also serve as an opportunity for your residents to network with residents from other programs.

After reviewing the material, it is our hope that you will select and encourage your 2nd Year residents to attend one of these educational activities, which are CME accredited to ensure fair balance.

Sincerely,

Postgraduate Healthcare Education

www.revophth.com/CSE2ndyr2018-19

For more information: Visit the registration site above or

Email: dholmes@postgradhealthed.com • Call: Denette Holmes 866-627-0714

Courses are restricted to 2nd-year residents enrolled in an ophthalmology residency program at the time of the course. There is no registration fee for this activity. Air, ground transportation in Fort Worth, hotel accommodations, and modest meals will be provided through an educational scholarship for qualified participants.

Satisfactory Completion - Learners must complete an evaluation form to receive a certificate of completion. Your chosen sessions must be attended in their entirety. Partial credit of individual sessions is not available. If you are seeking continuing education credit for a specialty not listed below, it is your responsibility to contact your licensing/certification board to determine course eligibility for your licensing/certification requirement.

Physicians - In support of improving patient care, this activity has been planned and implemented by Amedco LLC and Postgraduate Healthcare Education. Amedco LLC is jointly accredited by the Accreditation Council for Continuing Medical Education (ACCME), the Accreditation Council for Pharmacy Education (ACPE), and the American Nurses Credentialing Center (ANCC), to provide continuing education for the healthcare team

Credit Designation Statement - This activity has been approved for *AMA PRA Category 1 Credits*™.



JOINTLY ACCREDITED PROVIDER
INTERPROFESSIONAL CONTINUING EDUCATION

Endorsed by:

Review of Ophthalmology®

Jointly provided by:

PHE

AMEDCO

Supported by an independent medical education grant from:

Alcon





BRIEF SUMMARY:

Consult the Full Prescribing Information for complete product information.

INDICATIONS AND USAGE

Xiidra® (lifitegrast ophthalmic solution) 5% is indicated for the treatment of the signs and symptoms of dry eye disease (DED).

DOSAGE AND ADMINISTRATION

Instill one drop of Xiidra twice daily (approximately 12 hours apart) into each eye using a single-use container. Discard the single-use container immediately after using in each eye. Contact lenses should be removed prior to the administration of Xiidra and may be reinserted 15 minutes following administration.

CONTRAINDICATIONS

Xiidra is contraindicated in patients with known hypersensitivity to lifitegrast or to any of the other ingredients in the formulation.

ADVERSE REACTIONS

Clinical Trials Experience

Because clinical studies are conducted under widely varying conditions, adverse reaction rates observed in clinical studies of a drug cannot be directly compared to rates in the clinical trials of another drug and may not reflect the rates observed in practice. In five clinical studies of dry eye disease conducted with lifitegrast ophthalmic solution, 1401 patients received at least 1 dose of lifitegrast (1287 of which received lifitegrast 5%). The majority of patients (84%) had ≤ 3 months of treatment exposure. 170 patients were exposed to lifitegrast for approximately 12 months. The majority of the treated patients were female (77%). The most common adverse reactions reported in 5-25 % of patients were instillation site irritation, dysgeusia and reduced visual acuity. Other adverse reactions reported in 1% to 5% of the patients were blurred vision, conjunctival hyperemia, eye irritation, headache, increased lacrimation, eye discharge, eye discomfort, eye pruritus and sinusitis.

Postmarketing Experience

The following adverse reactions have been identified during postapproval use of Xiidra. Because these reactions are reported voluntarily from a population of uncertain size, it is not always possible to reliably estimate their frequency or establish a causal relationship to drug exposure.

Rare cases of hypersensitivity, including anaphylactic reaction, bronchospasm, respiratory distress, pharyngeal edema, swollen tongue, and urticaria have been reported. Eye swelling and rash have been reported.

USE IN SPECIFIC POPULATIONS

Pregnancy

There are no available data on Xiidra use in pregnant women to inform any drug associated risks. Intravenous (IV) administration of lifitegrast to pregnant rats, from pre-mating through gestation day 17, did not produce teratogenicity at clinically relevant systemic exposures. Intravenous administration of lifitegrast to pregnant rabbits during organogenesis produced an increased incidence of omphalocele at the lowest dose

tested, 3 mg/kg/day (400-fold the human plasma exposure at the recommended human ophthalmic dose [RHOD], based on the area under the curve [AUC] level). Since human systemic exposure to lifitegrast following ocular administration of Xiidra at the RHOD is low, the applicability of animal findings to the risk of Xiidra use in humans during pregnancy is unclear.

Animal Data

Lifitegrast administered daily by intravenous (IV) injection to rats, from pre-mating through gestation day 17, caused an increase in mean preimplantation loss and an increased incidence of several minor skeletal anomalies at 30 mg /kg / day, representing 5,400-fold the human plasma exposure at the RHOD of Xiidra, based on AUC. No teratogenicity was observed in the rat at 10 mg /kg /day (460-fold the human plasma exposure at the RHOD, based on AUC). In the rabbit, an increased incidence of omphalocele was observed at the lowest dose tested, 3 mg /kg /day (400-fold the human plasma exposure at the RHOD, based on AUC), when administered by IV injection daily from gestation days 7 through 19. A fetal No Observed Adverse Effect Level (NOAEL) was not identified in the rabbit.

Lactation

There are no data on the presence of lifitegrast in human milk, the effects on the breastfed infant, or the effects on milk production. However, systemic exposure to lifitegrast from ocular administration is low. The developmental and health benefits of breastfeeding should be considered, along with the mother's clinical need for Xiidra and any potential adverse effects on the breastfed child from Xiidra.

Pediatric Use

Safety and efficacy in pediatric patients below the age of 17 years have not been established.

Geriatric Use

No overall differences in safety or effectiveness have been observed between elderly and younger adult patients.

NONCLINICAL TOXICOLOGY

Carcinogenesis, Mutagenesis, Impairment of Fertility

Carcinogenesis: Animal studies have not been conducted to determine the carcinogenic potential of lifitegrast.

Mutagenesis: Lifitegrast was not mutagenic in the *in vitro* Ames assay. Lifitegrast was not clastogenic in the *in vivo* mouse micronucleus assay. In an *in vitro* chromosomal aberration assay using mammalian cells (Chinese hamster ovary cells), lifitegrast was positive at the highest concentration tested, without metabolic activation.

Impairment of fertility: Lifitegrast administered at intravenous (IV) doses of up to 30 mg/kg/day (5400-fold the human plasma exposure at the recommended human ophthalmic dose (RHOD) of lifitegrast ophthalmic solution, 5%) had no effect on fertility and reproductive performance in male and female treated rats.



Manufactured for: Shire US Inc., 300 Shire Way, Lexington, MA 02421. For more information, go to www.Xiidra.com or call 1-800-828-2088. Marks designated ® and ™ are owned by Shire or an affiliated company. ©2018 Shire US Inc. SHIRE and the Shire Logo are trademarks or registered trademarks of Shire Pharmaceutical Holdings Ireland Limited or its affiliates. Patented: please see <https://www.shire.com/legal-notice/product-patents> Last Modified: 01/2018 S33769



Xiidra HAS BEEN STUDIED IN A LARGE DRY EYE DISEASE CLINICAL TRIAL PROGRAM

MORE THAN 2,500 PATIENTS ACROSS 5 CLINICAL TRIALS



Xiidra is the first and only eye drop FDA-approved to treat both the signs and symptoms of Dry Eye Disease. It has been studied in more patients than any other pivotal clinical trial program for a prescription Dry Eye Disease treatment to date. Learn more about why you and your patients should give Xiidra a try.

Check out Xiidra-ECP.com

Indication

Xiidra® (lifitegrast ophthalmic solution) 5% is indicated for the treatment of signs and symptoms of dry eye disease (DED).

Important Safety Information

Xiidra is contraindicated in patients with known hypersensitivity to lifitegrast or to any of the other ingredients.

In clinical trials, the most common adverse reactions reported in 5-25% of patients were instillation site irritation, dysgeusia and reduced visual acuity. Other adverse reactions reported in 1% to 5% of the patients were blurred vision, conjunctival hyperemia, eye irritation, headache, increased lacrimation, eye discharge, eye discomfort, eye pruritus and sinusitis.

To avoid the potential for eye injury or contamination of the solution, patients should not touch the tip of the single-use container to their eye or to any surface.

Contact lenses should be removed prior to the administration of Xiidra and may be reinserted 15 minutes following administration.

Safety and efficacy in pediatric patients below the age of 17 years have not been established.

For additional safety information, see accompanying Brief Summary of Safety Information on the adjacent page and Full Prescribing Information on Xiidra-ECP.com.