

EXPANDED INDICATIONS FOR FEMTO P. 14 • AVOIDING THOSE “EXCLUDED” FROM MEDICARE P. 18
LASIK: HOW TO QUELL THE CELLS P. 47 • STEM CELL THERAPY IN RETINA P. 52
BREAKING DOWN THE NEW GLAUCOMA DRUGS P. 56 • WILLS RESIDENT CASE REPORT P. 63

REVIEW[®] of Ophthalmology

June 2018

reviewofophthalmology.com



The MIGS Match Game in Glaucoma

MIGS 1



MIGS 2



MIGS 3

*Experts share their tips on how to
choose the right minimally
invasive glaucoma surgery for
each patient. P. 20*

ALSO INSIDE:



Can Sustained-release Glaucoma
Meds Deliver the Goods? **P. 34**

MIGS 4

IOP Tracking Around the Clock:
How Close Are We? **P. 38**

**NOW
AVAILABLE**



**CYPASS[®] ULTRA
SYSTEM**

**FOR THE REDUCTION OF IOP IN MILD TO MODERATE PRIMARY
OPEN-ANGLE GLAUCOMA AT THE TIME OF CATARACT SURGERY**



and done

**ONE CYPASS[®] MICRO-STENT IS ALL IT TAKES TO CONNECT
TO SAFE, CONSISTENT, LONG-TERM IOP CONTROL**

IN THE COMPASS STUDY AT TWO YEARS^{1,2}:

- **72.5%** of patients achieved a $\geq 20\%$ reduction in IOP (n=374)
- **93%** of responders were medication free*
- Safety profile similar to cataract surgery alone

FOR AN EXPERIENCE LIKE NO OTHER, CONNECT WITH AN ALCON REPRESENTATIVE TODAY.

*Those patients who attained an unmedicated mean diurnal IOP reduction of 20% or more as compared to baseline in the absence of IOP-affecting surgery during the study.

References: 1. CyPass[®] Micro-Stent Instructions for Use. 2. Vold S, Ahmed IK, Craven ER, et al. Two-year COMPASS trial results: supraciliary microstenting with phacoemulsification in patients with open-angle glaucoma and cataracts. *Ophthalmology*. 2016;123(10):2103-2112.



CyPass® ULTRA Micro-Stent

IMPORTANT PRODUCT INFORMATION

CAUTION: FEDERAL (USA) LAW RESTRICTS THIS DEVICE TO SALE BY OR ON THE ORDER OF A PHYSICIAN.

INDICATION: The CyPass® ULTRA Micro-Stent is indicated for use in conjunction with cataract surgery for the reduction of intraocular pressure (IOP) in adult patients with mild to moderate primary open-angle glaucoma (POAG).

CONTRAINDICATIONS: Use of the CyPass® ULTRA Micro-Stent is contraindicated in the following circumstances or conditions: (1) in eyes with angle closure glaucoma; and (2) in eyes with traumatic, malignant, uveitic or neovascular glaucoma or discernible congenital anomalies of the anterior chamber angle.

MRI INFORMATION: The CyPass® ULTRA Micro-Stent is magnetic resonance (MR) Safe: the implant is constructed of polyimide material, a non-conducting, non-metallic, non-magnetic polymer that poses no known hazards in all magnetic resonance imaging environments.

WARNINGS: Gonioscopy should be performed prior to surgery to exclude peripheral anterior synechiae (PAS), rubeosis, and other angle abnormalities or conditions that would prohibit adequate visualization of the angle that could lead to improper placement of the stent and pose a hazard.

PRECAUTIONS: The surgeon should monitor the patient postoperatively for proper maintenance of intraocular pressure. The safety and effectiveness of the CyPass® ULTRA Micro-Stent has not been established as an alternative to the primary treatment of glaucoma with medications, in patients 21 years or younger, eyes with significant prior trauma, chronic inflammation, eyes with an abnormal anterior segment, eyes with chronic inflammation, eyes with glaucoma associated with vascular disorders, pseudophakic eyes with glaucoma, eyes with uveitic glaucoma, eyes with pseudoexfoliative or pigmentary glaucoma, eyes with other secondary open angle glaucomas, eyes that have undergone prior incisional glaucoma surgery or cilioablativ procedures, eyes with laser trabeculoplasty performed ≤ 3 months prior to the surgical screening visit, eyes with unmedicated IOP less than 21 mmHg or greater than 33 mmHg, eyes with medicated IOP greater than 25 mmHg, in the setting of complicated cataract surgery with iatrogenic injury to the anterior or posterior segment, and when implantation is without concomitant cataract surgery with IOL implantation for visually significant cataract. The safety and effectiveness of use of more than a single CyPass® ULTRA Micro-Stent has not been established.

ADVERSE EVENTS: In a randomized, multicenter clinical trial comparing cataract surgery with CyPass® ULTRA Micro-Stent to cataract surgery alone, the most common post-operative adverse events included: BCVA loss of 10 or more letters at 3 months after surgery (8.8% for CyPass® vs. 15.3% for cataract surgery only); anterior chamber cell and flare requiring steroid treatment 30 or more days after surgery (8.6% vs. 3.8%); worsening of visual field mean deviation by 2.5 or more decibels (6.7% vs. 9.9%); IOP increase of 10 or more mmHg 30 or more days after surgery (4.3% vs. 2.3%); and corneal edema 30 or more days after surgery, or severe in nature (3.5% vs. 1.5%).

ATTENTION: PLEASE REFER TO THE PRODUCT INSTRUCTIONS FOR A COMPLETE LIST OF CONTRAINDICATIONS, WARNINGS, PRECAUTIONS AND ADVERSE EVENTS.

Alcon A Novartis Division

© 2018 Novartis 2/18 US-CYP-18-E-0312

25TH ANNUAL

OPHTHALMIC Product Guide

Innovative products to enhance your practice



The future
is in your
hands. One
tap, many
possibilities.

Experience the digital edition
on your handheld device.
Use your smart device to
scan the code below or visit:

www.reviewofophthalmology.com/publications/archive

Download a QR scanner app. Launch app and hold your
mobile device over the code to view
www.reviewofophthalmology.com/publications/archive.



REVIEW[®]
of Ophthalmology

Study: Differences in Stability Between Tecnis and Acrysof

A recently released study comparing the rotational stability of the two most widely used toric intraocular lenses—the AcrySof (Alcon) and the Tecnis (Johnson & Johnson Vision)—found that the AcrySof lens had significantly better rotational stability than the Tecnis.¹ The retrospective study reviewed 1,273 eyes treated by two surgeons from the same practice, using the same techniques and equipment; 626 eyes received an AcrySof, while 647 received a Tecnis.

Findings of the study included:

- The AcrySof group showed significantly better rotational stability. The mean absolute value of rotation was 2.72 degrees (95% CI, 2.35 to 3.08 degrees) for AcrySof and 3.79 degrees (95% CI, 3.36 to 4.22 degrees) for Tecnis ($p < 0.05$) at the first postoperative check. At the conclusion of surgery 91.9 percent of AcrySof eyes were aligned within 5 degrees of the axis, compared with 81.8 percent of Tecnis eyes ($p < 0.0001$).

- The AcrySof group had significantly more lenses rotate ≤ 10 degrees and 15 degrees from the target axis (97.8 vs. 93.2 percent, $p = 0.0002$, and 98.6 vs. 96.4 percent, $p = 0.02$, respectively).

- The Tecnis tended to rotate in a counterclockwise direction (mean: 2.15 degrees). The AcrySof didn't show the same tendency (mean: 0.38 degrees CCW, 95% CI, 0.04 degrees CW to 0.80 degrees CCW, $p < 0.05$).

- Despite these differences, the refractive outcomes were statistically equivalent between groups. The

mean postop cylinder was 0.30 D for the AcrySof and 0.31 D for the Tecnis ($p = 0.85$). Other postop cylinder and acuity measurements were also similar.

- Further analysis showed that only lower IOL spherical equivalent power was associated with IOL rotation greater than 5 degrees ($p = 0.011$). Both greater axial length ($p = 0.023$) and toric axis ($p = 0.005$ for with-the-rule target axis) were associated with IOL rotation greater than 10 degrees.

- Use of a capsular tension ring didn't show any statistical benefit in preventing rotation greater than 10 degrees for either lens.

Bryan S. Lee, MD, JD, in private practice at Altos Eye Physicians in Los Altos, California, and an adjunct clinical assistant professor of ophthalmology at Stanford University, is lead author of the study. (He has no financial interest in the devices.)

Dr. Lee says several factors make the study valuable. "First of all, we studied almost 1,300 eyes," he says. "They were consecutive patients from one practice, treated by two surgeons using the same technology and technique. Previous studies of rotation have had much smaller numbers of subjects, and variability in the techniques and technologies that were used."

Another significant difference between this study and previous analyses was the way rotation was measured. "The initial time point used to gauge the stability of the IOLs in the FDA studies was not at the end of surgery, which is clinically the most important time," he explains. "Instead, they used

measurements taken later, such as at the slit lamp a day after surgery, and then compared that to the six-to-12-month endpoint. That's a potential problem, because we now know that almost all toric IOL rotation happens in the first hour after surgery. This was documented in a study by Yasushi Inoue, MD.² We designed our study to look at the stability of the IOL from the conclusion of surgery."

As noted, the overall visual outcomes were similar in both groups despite the rotational stability difference. Dr. Lee doesn't think that takes away from the significance of the study, for several reasons. "Number one, in our study about half the patients in both groups had the lowest-power toricity," he points out. "When a very low-toricity IOL rotates off-axis, the rotation may not be as symptomatic in terms of the refractive outcome and cylinder. Second, when we're looking at improving our outcomes, as surgeons we have to focus on the things we can control. One of those is picking the technology we use, and these degrees of rotation eventually add up. Finally, these patients are paying extra for a premium IOL, and a greater degree of error may ultimately lead to more unhappy patients."

Asked about possible explanations for the difference in rotational stability, Dr. Lee says it's a difficult question to answer. "The lenses are quite different from each other," he points out. "The AcrySof lens acrylic is much softer and the haptic has a bulb at the end of it. It's also possible that the angle of the



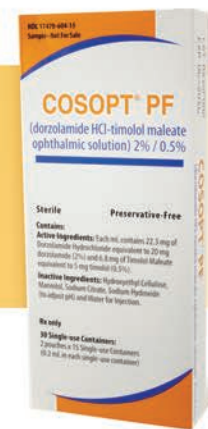100% PRESERVATIVE-FREE

ZIOPTAN[®]
(tafluprost ophthalmic solution) 0.0015%

Cosopt[®] PF
(dorzolamide HCl - timolol maleate ophthalmic solution) 2% / 0.5%



**ORDER
FREE SAMPLES**



Go to either website
and select "Request Sample"

www.Zioptan.com

www.CosoptPF.com

Cosopt is a registered trademark of Merck Sharp & Dohme Corp and is used under license. ZIOPTAN is a registered trademark of Merck Sharp & Dohme Corp and is used under license.

Santen ZIOPTAN is licensed by Santen Pharmaceutical Co., Ltd.

AKORN

©2017 Akorn, Inc. All rights reserved. P481(a) Rev 4/17

haptic is relevant. Unfortunately, we can only speculate. Ultimately, Johnson & Johnson will hopefully be able to figure that out.”

Asked to comment on the study's results, Jonathan Talamo, MD, chief medical officer at J & J Vision, said the company couldn't speculate on causes of rotation. “We do know that the Tecnis and AcrySof IOL platforms have several key differences in the way they're designed and how they best function,” he says. “What's worth noting is that the study found that a small amount of difference in toric IOL rotation alone was not a good predictor of refractive outcomes. In fact, both the Tecnis and AcrySof toric IOL treatment groups had 85 percent of patients within 0.5 D of [target] cylinder after surgery.”

There's also speculation about other lenses that use these toric platforms. “Our study didn't compare the toric Symphony and the toric ReSTOR,” Dr. Lee notes. “I'd say that in our practice—anecdotally—the toric Symphony has a tendency to rotate just like the Tecnis toric monofocal does. That's what you would expect, because it's the same platform, the same material and the same lens design. Our study doesn't prove that the toric Symphony is going to rotate more than the toric ReSTOR, but I think that would be a reasonable thing to be concerned about.”

Dr. Lee hopes the results of the study will result in improvements in the Tecnis. “Overall, I still think it's a great platform,” he says. “I think this discovery will ultimately be a good thing, not just for toric IOLs, but for future presbyopia-correcting lenses that may have an orientation requirement in order for them to work their best. I hope this will ultimately help get the best outcomes for patients and be beneficial for the profession.”

1. Lee BS, Chang DF. Comparison of the rotational stability of two toric intraocular lenses in 1273 consecutive eyes. *Ophthalmology* 2018 Mar 12. [Epub ahead of print]
2. Inoue Y, Takehara H, Oshika T. Axis misalignment of toric intraocular lens: Placement error and postoperative rotation. *Ophthalmology* 2017;124:1424-1425.

Omega-3s Questionable For Dry Eye

In early May, researchers from the Dry Eye Assessment and Management Study Research Group published a study that showed no significant differences between omega-3 fatty acids and placebo in relieving dry-eye symptoms.¹

In this multicenter, double-blind trial, researchers randomly assigned patients with moderate-to-severe dry eye to receive either a daily dose of 3,000 mg of omega-3 supplements (n=349) or an olive oil placebo (n=186).

The primary outcome of the study was the mean change from baseline in the score on the Ocular Surface Disease Index, based on the mean scores obtained at six and 12 months.

The mean change in the OSDI score wasn't significantly different between the supplement and the placebo groups (-13.9 points and -12.5 points, respectively). There were also no significant differences in the conjunctival and corneal staining scores, tear breakup time or Schirmer's results. In addition, the rates of adverse events were similar. The researchers concluded that there were no significantly better outcomes between the groups.

Richard Davidson, MD, from the University of Colorado School of Medicine, weighs in on the results: “It's a little bit confusing. If you really look at the study in detail, both the placebo and the omega group did show improvement, but there was no statistical difference between the two. So one could make the argument that in some patients, the omega supplement does help. According to the study and my experience, the omega supplement

helps more with the symptoms of dry eye rather than the dry eye itself.

“However, I'm not surprised by the study,” Dr. Davidson continues. “I've never really been a huge omega-3 advocate because I didn't really see that much of a difference in my practice. However, I have patients I've been seeing for 15 years who swear by them. In their opinion, they feel like it helps them—when they miss a few days, they feel worse. Are they getting the placebo effect? It's quite possible, but you don't always want to take that away from them. If my patients want to stay on them that's fine, but I'm not going to advocate them routinely.”

Despite the somewhat unexpected results, Dr. Davidson is excited about them. “I love the study,” he says. “It was really well done, and I'm glad we have it because it justifies my own clinical observations. But at the same time, if you look closely at it, you could argue that people showed improvement even though there was no difference between placebo and omega-3s. The blood levels of the omega-3 group did go up, meaning it did get into the blood. However, in the placebo group there was no change in blood levels, which supports even more that there was no difference between the groups. We don't yet have an explanation as to why the placebo group had improved symptoms so, hopefully, we'll see some further studies exploring this.”

Dr. Davidson says the study may affect some practices. “For me, in my practice, this won't really change anything,” he says. “It may change something for people who are heavy prescribers of omega-3 supplements, though. They'll have to switch to something that has shown efficacy. At the same time they might argue, however, ‘Yes, I see what the study says, but I have patients who say that it helps them, so I'm going to stick with it,’ which I totally understand.” **REVIEW**

1. <https://www.nejm.org/doi/full/10.1056/NEJMoa1709691>
Accessed 07 May 2018.

Editor in Chief

Walter C. Bethke
(610) 492-1024
wbethke@jobson.com

Senior Editor

Christopher Kent
(814) 861-5559
ckent@jobson.com

Senior Associate Editor

Kristine Brennan
(610) 492-1008
kbrennan@jobson.com

Associate Editor

Liam Jordan
(610) 492-1025
ljordan@jobson.com

Chief Medical Editor

Mark H. Blecher, MD

Art Director

Jared Araujo
(610) 492-1032
jaraujo@jobson.com

Senior Graphic Designer

Matt Egger
(610) 492-1029
megger@jobson.com

Graphic Designer

Ashley Schmouder
(610) 492-1027
aschmouder@jobson.com

International coordinator, Japan

Mitz Kaminuma
Reviewophthlmo@aol.com

Business Offices

11 Campus Boulevard, Suite 100
Newtown Square, PA 19073
(610) 492-1000
Fax: (610) 492-1039

Subscription inquiries:

United States — (877) 529-1746
Outside U.S. — (845) 267-3065

E-mail:



revophthalmology@cambeywest.com

Website: www.reviewofophthalmology.com



Long Term Clinical Efficacy with Phaco-ECP

Microincisional Glaucoma Treatment



*"Combined Phaco-ECP effectively lowers or maintains IOP and results in ocular hypertensive medication reduction up to 72 months."**

"ECP is an ideal way to address moderately controlled glaucoma and cataract in one procedure."

— Mr. Philip Bloom,
MBCbB, FRCS(Ed), FRCOphth

"Combining ECP with a variety of other MIGS procedures allows me to offer a balanced therapy that is tailored to each patient."

— Nathan Radcliffe, MD



For ordering information, please call customer service

Beaver-Visitec International, Inc.

US: 1-866-906-8080

EU: 44 (0) 1865 601256

bvmedical.com

*Khandan, Sarah; Siegel, Les., et.al. Long-term Follow-up of Combined Phaco and ECP in the Treatment of Mild to Moderate Glaucoma. AGS 2017

BVI, BVI Logo and all other trademarks (unless noted otherwise) are property of Beaver-Visitec International, Inc. ("BVI") © 2018 BVI

CONTRIBUTORS

CHIEF MEDICAL EDITOR

Mark H. Blecher, MD

CONTACT LENSES

Penny Asbell, MD

CORNEA / ANTERIOR SEGMENT

Thomas John, MD

GLAUCOMA MANAGEMENT

Peter Netland, MD, PHD
Kuldev Singh, MD

MASTERS OF SURGERY

Taliva D. Martin, MD
Sara J. Haug, MD, PhD

MEDICARE Q & A

Paul M. Larson, MBA

PEDIATRIC PATIENT

Wendy Huang, MD

PLASTIC POINTERS

Ann P. Murchison, MD, MPH

REFRACTIVE SURGERY

Arturo S. Chayet, MD

RETINAL INSIDER

Carl Regillo, MD, FACS
Emmett T. Cunningham Jr., MD, PHD, MPH

TECHNOLOGY UPDATE

Steven T. Charles, MD
Michael Colvard, MD

WILLS RESIDENT CASE SERIES

Thomas Jenkins, MD

ADVISORY BOARD

PENNY A. ASBELL, MD, NEW YORK CITY

WILLIAM I. BOND, MD, PEKIN, ILL.

ALAN N. CARLSON, MD, DURHAM, N.C.

Y. RALPH CHU, MD, EDINA, MINN.

ADAM J. COHEN, MD, DOWNERS GROVE, ILL.

UDAY DEVGAN, MD, FACS, LOS ANGELES

ERIC DONNENFELD, MD, ROCKVILLE CENTRE, N.Y.

DANIEL S. DURRIE, MD, KANSAS CITY, MO.

ROBERT EPSTEIN, MD, MCHENRY, ILL.

ROBERT D. FECHTNER, MD, NEWARK, N.J.

WILLIAM J. FISHKIND, MD, TUCSON, ARIZ.

JAMES P. GILLS, MD, TARPON SPRINGS, FLA.

HARRY GRABOW, MD, SARASOTA, FLA.

DOUGLAS K. GRAYSON, MD, NEW YORK CITY

THOMAS S. HARBIN, MD, MBA, ATLANTA

DAVID R. HARDTEN, MD, MINNEAPOLIS

KENNETH J. HOFFER, MD, SANTA MONICA, CALIF.

JACK T. HOLLADAY, MD, MSEE, HOUSTON

JOHN D. HUNKELER, MD, KANSAS CITY, MO.

THOMAS JOHN, MD, TINLEY PARK, ILL.

ROBERT M. KERSHNER, MD, MS, FACS, BOSTON

GUY M. KEZIRIAN, MD, PARADISE VALLEY, ARIZ.

TERRY KIM, MD, DURHAM, N.C.

TOMMY KORN, MD, SAN DIEGO

DAVID A. LEE, MD, HOUSTON

FRANCIS S. MAH, MD, PITTSBURGH

NICK MAMALIS, MD, SALT LAKE CITY

WILLIAM G. MARTIN, MD, OREGON, OHIO

MIKE S. MCFARLAND, MD, PINE BLUFF, ARK.

JEFFREY B. MORRIS, MD, MPH, ENCINITAS, CALIF.

MARLENE R. MOSTER, MD, PHILADELPHIA

ROBERT J. NOECKER, MD, FAIRFIELD, CONN.

ROBERT OSHER, MD, CINCINNATI

MARK PACKER, MD, WEST PALM BEACH, FLA.

STEPHEN PASCUCCI, MD, BONITA SPRINGS, FLA.

PAUL PENDER, MD, BEDFORD, N.H.

CHRISTOPHER J. RAPUANO, MD, PHILADELPHIA

AUGUST READER III, MD, SAN FRANCISCO

TONY REALINI, MD, MORGANTOWN, W.V.

KENNETH J. ROSENTHAL, MD, GREAT NECK, N.Y.

ERIC ROTHCHILD, MD, DELRAY BEACH, FLA.

SHERI ROWEN, MD, BALTIMORE

JAMES J. SALZ, MD, LOS ANGELES

INGRID U. SCOTT, MD, MPH, HERSHEY, PA.

JOEL SCHUMAN, MD, PITTSBURGH

GAURAV SHAH, MD, ST. LOUIS

DAVID R. STAGER JR., MD, DALLAS

KARL STONECIPHER, MD, GREENSBORO, N.C.

JAMES C. TSAI, MD, NEW YORK CITY

VANCE THOMPSON, MD, SIOUX FALLS, S.D.

FARRELL C. TYSON, MD, CAPE CORAL, FLA.

R. BRUCE WALLACE III, MD, ALEXANDRIA, LA.

ROBERT G. WILEY, MD, CLEVELAND

FRANK WEINSTOCK, MD, CANTON, OHIO

BUSINESS OFFICES

11 CAMPUS BOULEVARD, SUITE 100
NEWTOWN SQUARE, PA 19073
SUBSCRIPTION INQUIRIES (877) 529-1746
(USA ONLY); OUTSIDE USA, CALL (847) 763-9630

BUSINESS STAFF

PUBLISHER

JAMES HENNE

(610) 492-1017 JHENNE@JOBSON.COM

REGIONAL SALES MANAGER

MICHELE BARRETT

(610) 492-1014 MBARRETT@JOBSON.COM

REGIONAL SALES MANAGER

MICHAEL HOSTER

(610) 492-1028 MHOSTER@JOBSON.COM

CLASSIFIED ADVERTISING

(888)-498-1460

VICE PRESIDENT OF OPERATIONS

CASEY FOSTER

(610) 492-1007 CFOSTER@JOBSON.COM

PRODUCTION MANAGER

SCOTT TOBIN

(610) 492-1011 STOBIN@JOBSON.COM

SUBSCRIPTIONS

\$63 A YEAR, \$99 (U.S.) IN CANADA,
\$158 (U.S.) IN ALL OTHER COUNTRIES.

SUBSCRIPTIONS E-MAIL:

REVOPHTHALMOLOGY@CAMBEYWEST.COM

CIRCULATION

PO BOX 71, CONGERS, NY 10920-0071
(877) 529-1746

OUTSIDE USA: (845) 267-3065

SENIOR CIRCULATION MANAGER

HAMILTON MAHER

(212) 219-7870 hmaher@jhihealth.com

CEO, INFORMATION GROUP SERVICES

MARC FERRARA

SENIOR VICE PRESIDENT, OPERATIONS

JEFF LEVITZ

VICE PRESIDENT, HUMAN RESOURCES

TAMMY GARCIA

VICE PRESIDENT, CREATIVE SERVICES & PRODUCTION

MONICA TETTAMANZI

CORPORATE PRODUCTION DIRECTOR

JOHN ANTHONY CAGGIANO

VICE PRESIDENT, CIRCULATION

EVELDA BAREA

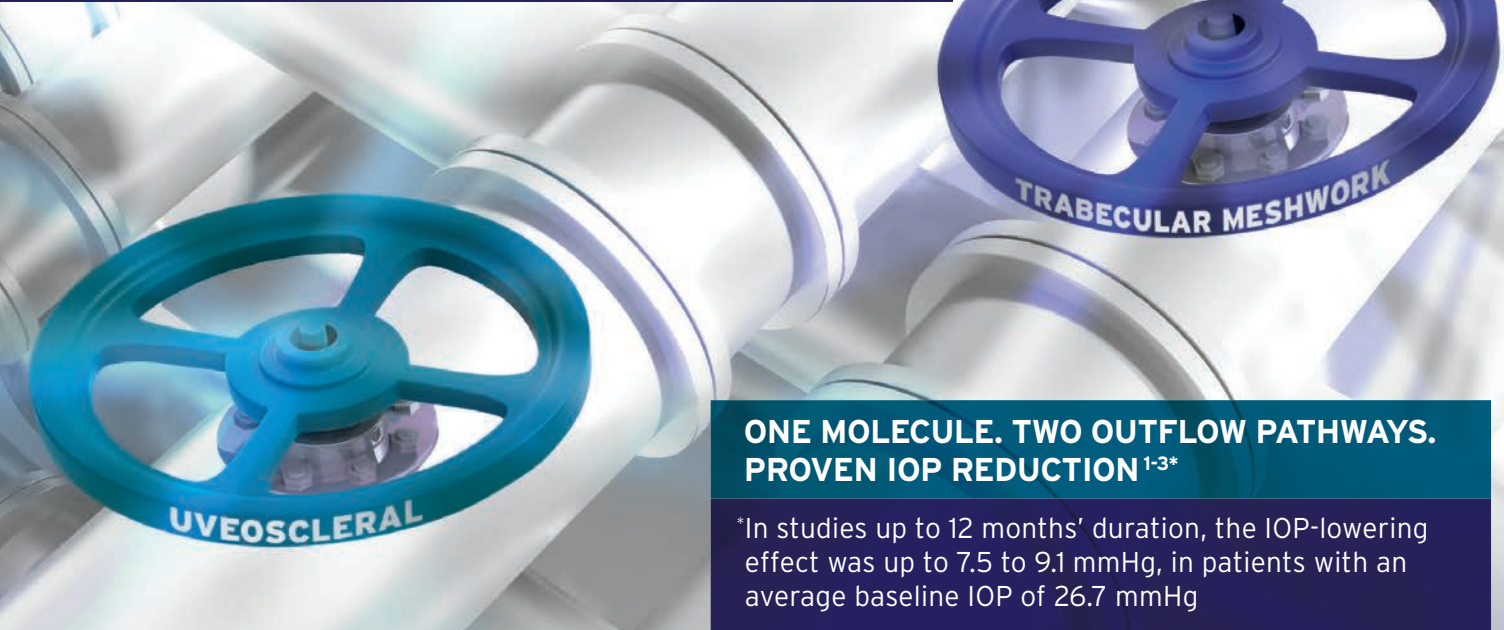


440 Ninth Avenue, 14th Floor
New York, N.Y. 10001

REVIEW OF OPHTHALMOLOGY (ISSN 1081-0226; USPS No. 0012-345) is published monthly, 12 times per year by Jobson Medical Information, 440 Ninth Avenue, 14th Floor, New York, N.Y. 10001. Periodicals postage paid at New York, NY and additional mailing offices. Postmaster: Send address changes to Review of Ophthalmology, PO Box 71, Congers, NY 10929-0071. Subscription Prices: US One Year \$63.00, US Two Year \$112.00, Canada One Year \$99.00, Canada Two Year \$181.00, Int'l One Year \$158.00, Int'l Two Year \$274.00. For subscription information call (877) 529-1746 (USA only); outside USA, call (845)-267-3065. Or email us at revophthalmology@cambeywest.com. Canada Post: Publications Mail Agreement #40612608. Canada Returns to be sent to Bleuchip International, P.O. Box 25542, London, ON N6C 6B2.

VYZULTA DELIVERS A DUAL MECHANISM OF ACTION

FOR THE REDUCTION OF IOP IN GLAUCOMA PATIENTS¹



**ONE MOLECULE. TWO OUTFLOW PATHWAYS.
PROVEN IOP REDUCTION^{1-3*}**

*In studies up to 12 months' duration, the IOP-lowering effect was up to 7.5 to 9.1 mmHg, in patients with an average baseline IOP of 26.7 mmHg

INDICATION

VYZULTA™ (latanoprostene bunod ophthalmic solution), 0.024% is indicated for the reduction of intraocular pressure (IOP) in patients with open-angle glaucoma or ocular hypertension.

IMPORTANT SAFETY INFORMATION

- Increased pigmentation of the iris and periorbital tissue (eyelid) can occur. Iris pigmentation is likely to be permanent
- Gradual changes to eyelashes, including increased length, increased thickness, and number of eyelashes, may occur. These changes are usually reversible upon treatment discontinuation
- Use with caution in patients with a history of intraocular inflammation (iritis/uveitis). VYZULTA should generally not be used in patients with active intraocular inflammation
- Macular edema, including cystoid macular edema, has been reported during treatment with prostaglandin analogs. Use with caution in aphakic patients, in pseudophakic patients with a torn posterior lens capsule, or in patients with known risk factors for macular edema

IMPORTANT SAFETY INFORMATION (CONTINUED)

- There have been reports of bacterial keratitis associated with the use of multiple-dose containers of topical ophthalmic products that were inadvertently contaminated by patients
- Contact lenses should be removed prior to the administration of VYZULTA and may be reinserted 15 minutes after administration
- Most common ocular adverse reactions with incidence $\geq 2\%$ are conjunctival hyperemia (6%), eye irritation (4%), eye pain (3%), and instillation site pain (2%)

For more information, please see Brief Summary of Prescribing Information on next page.

References:

1. VYZULTA Prescribing Information. Bausch & Lomb Incorporated. 2017.
2. Weinreb RN, Sforzolini BS, Vittitow J, Liebmann J. Latanoprostene bunod 0.024% versus timolol maleate 0.5% in subjects with open-angle glaucoma or ocular hypertension: the APOLLO study. *Ophthalmology*. 2016;123(5):965-973.
3. Medeiros FA, Martin KR, Peace J, Sforzolini BS, Vittitow JL, Weinreb RN. Comparison of latanoprostene bunod 0.024% and timolol maleate 0.5% in open-angle glaucoma or ocular hypertension: the LUNAR study. *Am J Ophthalmol*. 2016;168:250-259.

For more information about VYZULTA and how it works, visit vyzultanow.com

BAUSCH+LOMB

VYZULTA and the V design are trademarks of Bausch & Lomb Incorporated or its affiliates.
©2018 Bausch & Lomb Incorporated. All rights reserved. VYZ.0118.USA.18


VYZULTA™
(latanoprostene
bunod ophthalmic
solution), 0.024%

BRIEF SUMMARY OF PRESCRIBING INFORMATION

This Brief Summary does not include all the information needed to use VYZULTA safely and effectively. See full Prescribing Information for VYZULTA.

VYZULTA™ (latanoprostene bunod ophthalmic solution), 0.024%, for topical ophthalmic use.

Initial U.S. Approval: 2017

1 INDICATIONS AND USAGE

VYZULTA™ (latanoprostene bunod ophthalmic solution) 0.024% is indicated for the reduction of intraocular pressure (IOP) in patients with open-angle glaucoma or ocular hypertension.

4 CONTRAINDICATIONS

None

5 WARNINGS AND PRECAUTIONS

5.1 Pigmentation

VYZULTA™ (latanoprostene bunod ophthalmic solution), 0.024% may cause changes to pigmented tissues. The most frequently reported changes with prostaglandin analogs have been increased pigmentation of the iris and periorbital tissue (eyelid).

Pigmentation is expected to increase as long as latanoprostene bunod ophthalmic solution is administered. The pigmentation change is due to increased melanin content in the melanocytes rather than to an increase in the number of melanocytes. After discontinuation of VYZULTA, pigmentation of the iris is likely to be permanent, while pigmentation of the periorbital tissue and eyelash changes are likely to be reversible in most patients. Patients who receive prostaglandin analogs, including VYZULTA, should be informed of the possibility of increased pigmentation, including permanent changes. The long-term effects of increased pigmentation are not known.

Iris color change may not be noticeable for several months to years. Typically, the brown pigmentation around the pupil spreads concentrically towards the periphery of the iris and the entire iris or parts of the iris become more brownish. Neither nevi nor freckles of the iris appear to be affected by treatment. While treatment with VYZULTA™ (latanoprostene bunod ophthalmic solution), 0.024% can be continued in patients who develop noticeably increased iris pigmentation, these patients should be examined regularly [see Patient Counseling Information (17) in full Prescribing Information].

5.2 Eyelash Changes

VYZULTA may gradually change eyelashes and vellus hair in the treated eye. These changes include increased length, thickness, and the number of lashes or hairs. Eyelash changes are usually reversible upon discontinuation of treatment.

5.3 Intraocular Inflammation

VYZULTA should be used with caution in patients with a history of intraocular inflammation (iritis/uveitis) and should generally not be used in patients with active intraocular inflammation as it may exacerbate this condition.

5.4 Macular Edema

Macular edema, including cystoid macular edema, has been reported during treatment with prostaglandin analogs. VYZULTA should be used with caution in aphakic patients, in pseudophakic patients with a torn posterior lens capsule, or in patients with known risk factors for macular edema.

5.5 Bacterial Keratitis

There have been reports of bacterial keratitis associated with the use of multiple-dose containers of topical ophthalmic products. These containers had been inadvertently contaminated by patients who, in most cases, had a concurrent corneal disease or a disruption of the ocular epithelial surface.

5.6 Use with Contact Lens

Contact lenses should be removed prior to the administration of VYZULTA because this product contains benzalkonium chloride. Lenses may be reinserted 15 minutes after administration.

6 ADVERSE REACTIONS

The following adverse reactions are described in the Warnings and Precautions section: pigmentation (5.1), eyelash changes (5.2), intraocular inflammation (5.3), macular edema (5.4), bacterial keratitis (5.5), use with contact lens (5.6).

6.1 Clinical Trials Experience

Because clinical trials are conducted under widely varying conditions, adverse reaction rates observed in the clinical trials of a drug cannot be directly compared to rates in the clinical trials of another drug and may not reflect the rates observed in practice.

VYZULTA was evaluated in 811 patients in 2 controlled clinical trials of up to 12 months duration. The most common ocular adverse reactions observed in patients treated with latanoprostene bunod were: conjunctival hyperemia (6%), eye irritation (4%), eye pain (3%), and instillation site pain (2%). Approximately 0.6% of patients discontinued therapy due to ocular adverse reactions including ocular hyperemia, conjunctival irritation, eye irritation, eye pain, conjunctival edema, vision blurred, punctate keratitis and foreign body sensation.

8 USE IN SPECIFIC POPULATIONS

8.1 Pregnancy

Risk Summary

There are no available human data for the use of VYZULTA during pregnancy to inform any drug associated risks.

Latanoprostene bunod has caused miscarriages, abortion, and fetal harm in rabbits. Latanoprostene bunod was shown to be abortifacient and teratogenic when administered intravenously (IV) to pregnant rabbits at exposures ≥ 0.28 times the clinical dose.

Doses ≥ 20 $\mu\text{g}/\text{kg}/\text{day}$ (23 times the clinical dose) produced 100% embryofetal lethality. Structural abnormalities observed in rabbit fetuses included anomalies of the great vessels and aortic arch vessels, domed head, sternbral and vertebral skeletal anomalies, limb hyperextension and malrotation, abdominal distension and edema. Latanoprostene bunod was not teratogenic in the rat when administered IV at 150 mcg/kg/day (87 times the clinical dose) [see Data].

The background risk of major birth defects and miscarriage for the indicated population is unknown. However, the background risk in the U.S. general population of major birth defects is 2 to 4%, and of miscarriage is 15 to 20%, of clinically recognized pregnancies.

Data

Animal Data

Embryofetal studies were conducted in pregnant rabbits administered latanoprostene bunod daily by intravenous injection on gestation days 7 through 19, to target the period of organogenesis. The doses administered ranged from 0.24 to 80 mcg/kg/day. Abortion occurred at doses ≥ 0.24 mcg/kg/day latanoprostene bunod (0.28 times the clinical dose, on a body surface area basis, assuming 100% absorption). Embryofetal lethality (resorption) was increased in latanoprostene bunod treatment groups, as evidenced by increases in early resorptions at doses ≥ 0.24 mcg/kg/day and late resorptions at doses ≥ 6 mcg/kg/day (approximately 7 times the clinical dose). No fetuses survived in any rabbit pregnancy at doses of 20 mcg/kg/day (23 times the clinical dose) or greater. Latanoprostene bunod produced structural abnormalities at doses ≥ 0.24 mcg/kg/day (0.28 times the clinical dose). Malformations included anomalies of sternum, coarctation of the aorta with pulmonary trunk dilation, retroesophageal subclavian artery with absent brachiocephalic artery, domed head, forepaw hyperextension and hindlimb malrotation, abdominal distention/edema, and missing/fused caudal vertebrae.

An embryofetal study was conducted in pregnant rats administered latanoprostene bunod daily by intravenous injection on gestation days 7 through 17, to target the period of organogenesis. The doses administered ranged from 150 to 1500 mcg/kg/day. Maternal toxicity was produced at 1500 mcg/kg/day (870 times the clinical dose, on a body surface area basis, assuming 100% absorption), as evidenced by reduced maternal weight gain. Embryofetal lethality (resorption and fetal death) and structural anomalies were produced at doses ≥ 300 mcg/kg/day (174 times the clinical dose). Malformations included anomalies of the sternum, domed head, forepaw hyperextension and hindlimb malrotation, vertebral anomalies and delayed ossification of distal limb bones. A no observed adverse effect level (NOAEL) was established at 150 mcg/kg/day (87 times the clinical dose) in this study.

8.2 Lactation

Risk Summary

There are no data on the presence of VYZULTA in human milk, the effects on the breastfed infant, or the effects on milk production. The developmental and health benefits of breastfeeding should be considered, along with the mother's clinical need for VYZULTA, and any potential adverse effects on the breastfed infant from VYZULTA.

8.4 Pediatric Use

Use in pediatric patients aged 16 years and younger is not recommended because of potential safety concerns related to increased pigmentation following long-term chronic use.

8.5 Geriatric Use

No overall clinical differences in safety or effectiveness have been observed between elderly and other adult patients.

13 NONCLINICAL TOXICOLOGY

13.1 Carcinogenesis, Mutagenesis, Impairment of Fertility

Latanoprostene bunod was not mutagenic in bacteria and did not induce micronuclei formation in the *in vivo* rat bone marrow micronucleus assay. Chromosomal aberrations were observed *in vitro* with human lymphocytes in the absence of metabolic activation.

Latanoprostene bunod has not been tested for carcinogenic activity in long-term animal studies. Latanoprost acid is a main metabolite of latanoprostene bunod. Exposure of rats and mice to latanoprost acid, resulting from oral dosing with latanoprost in lifetime rodent bioassays, was not carcinogenic.

Fertility studies have not been conducted with latanoprostene bunod. The potential to impact fertility can be partially characterized by exposure to latanoprost acid, a common metabolite of both latanoprostene bunod and latanoprost. Latanoprost acid has not been found to have any effect on male or female fertility in animal studies.

13.2 Animal Toxicology and/or Pharmacology

A 9-month toxicology study administered topical ocular doses of latanoprostene bunod to one eye of cynomolgus monkeys: control (vehicle only), one drop of 0.024% bid, one drop of 0.04% bid and two drops of 0.04% per dose, bid. The systemic exposures are equivalent to 4.2-fold, 7.9-fold, and 13.5-fold the clinical dose, respectively, on a body surface area basis (assuming 100% absorption). Microscopic evaluation of the lungs after 9 months observed pleural/subpleural chronic fibrosis/inflammation in the 0.04% dose male groups, with increasing incidence and severity compared to controls. Lung toxicity was not observed at the 0.024% dose.

Distributed by:

Bausch + Lomb, a division of

Valeant Pharmaceuticals North America LLC

Bridgewater, NJ 08807 USA

U.S. Patent Numbers: 6,211,233; 7,273,946; 7,629,345; 7,910,767; 8,058,467.

VYZULTA is a trademark of Bausch & Lomb Incorporated or its affiliates.

© Bausch & Lomb Incorporated

Based on 9464800 11/2017 VYZ.0055.USA.16 Issued: 11/2017

REVIEW[®] of Ophthalmology

June 2018 • Volume XXV No. 6 | reviewofophthalmology.com

Cover Story

20 | **Choosing MIGS (for You and Your Patient)**

Christopher Kent, Senior Editor

With more options rapidly appearing, picking the right procedure can be challenging. Here's help.

Feature Articles

34 | **Can Sustained Release Deliver the Goods?**

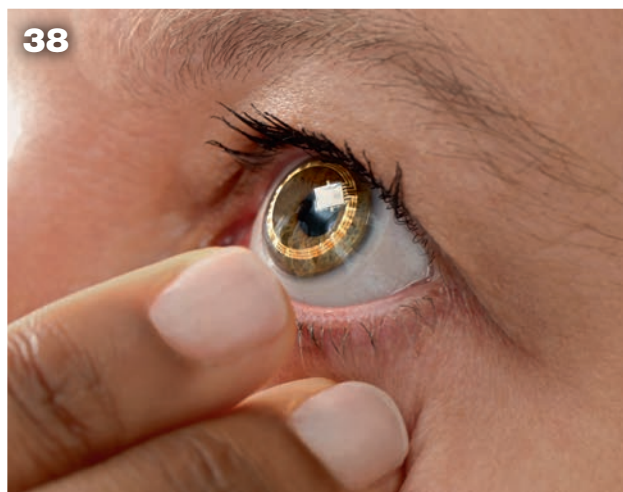
Michelle Stephenson, Contributing Editor

Physicians hope that sustained-release glaucoma drugs will overcome compliance challenges.

38 | **IOP Around the Clock: How Close Are We?**

Kristine Brennan, Senior Associate Editor

IOP fluctuates day and night. When will 24-hour monitoring inform treatment decisions?



Departments

4 | [Review News](#)

14 | [Technology Update](#)

New Indications for Three Femto Lasers

Corneal pockets and channels for intracorneal ring segments are among the additions.

18 | [Medicare Q & A](#)

Compliance Update: “Excluded” Employees

Why providers are excluded from Medicare and how to find out if a potential new hire has been excluded.

47 | [Refractive/Cataract Rundown](#)

Shutting the Door on Epithelial Ingrowth

Surgeons share when to watch and wait, and when to do something about ingrowth under the flap.

52 | [Retinal Insider](#)

Stem Cell Therapy in Retinal Disease

A look at how stem cells are generated, and the most promising approaches to employing them in the eye.

56 | [Glaucoma Management](#)

Two Unique Glaucoma Drugs Debut

Latanoprostene bunod and netarsudil offer surgeons new options in the battle to effectively lower IOP.

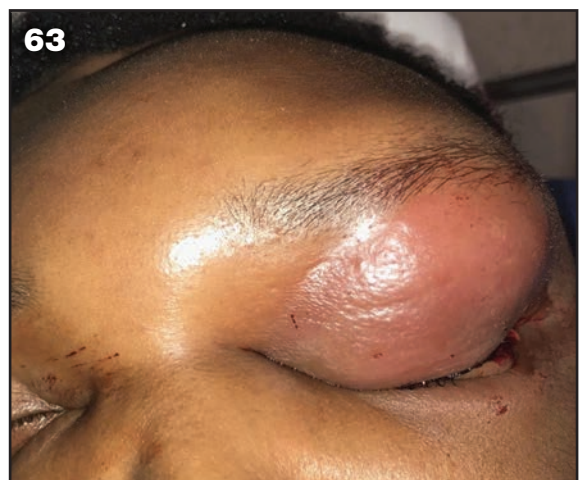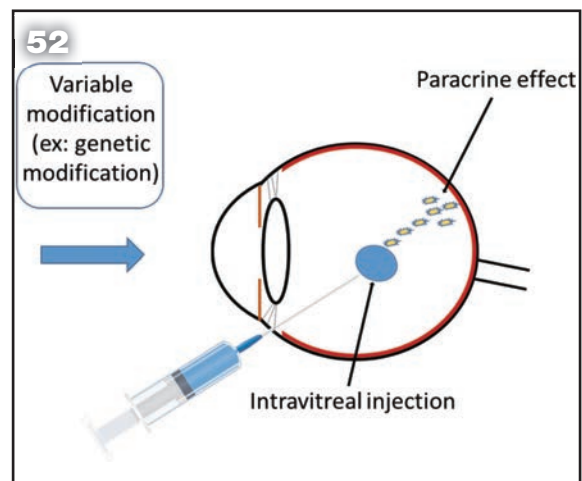
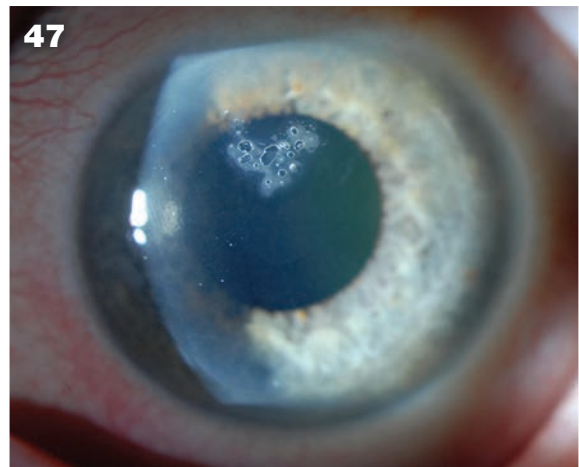
60 | [Product News](#)

First AI Diagnostic System Approved

61 | [Classifieds](#)

63 | [Wills Eye Resident Case Series](#)

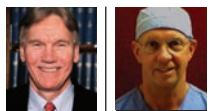66 | [Advertiser Index](#)





THE TRANSFORMATION STARTS SOON.

Speak to your
Glaukos sales representative today
or visit [TransformMIGS.com!](https://www.TransformMIGS.com)



Three Femtosecond Lasers Have New Indications

Manufacturers unveiled new 510(k) clearances from the Food and Drug Administration at the 2018 ASCRS meeting.

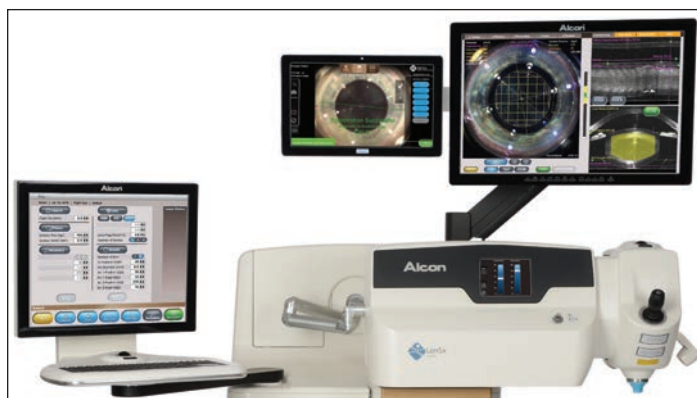
Kristine Brennan, Senior Associate Editor

Some surgeons consider the femtosecond laser to be the most disruptive technological contribution to cataract surgery in recent years.¹ Many surgeons rely on it during the formation of LASIK flaps and for capsulotomy creation. At the 2018 American Society of Cataract and Refractive Surgery meeting in Washington, D.C., three manufacturers announced new 510(k) clearances from the U.S. Food and Drug Administration that enable their femto systems to support presbyopia-correcting procedures, facilitate keratoconus treatments and address astigmatism. The manufacturers say that they're responding to a growing patient demand for treatments beyond refractive and cataract procedures that will aid spectacle independence, such as corneal inlays and intracorneal ring segments. Here's a rundown of what's new.

LenSx

The LenSx femtosecond laser

platform (Alcon; Fort Worth, Texas), first made commercially available in 2011, was the first in the category to receive FDA approval. In late March, the laser gained two new indications:



Updates to the LenSx include corneal pocket- and tunnel-cutting capabilities.

the creation of tunnels for the placement of corneal rings; and the creation of corneal pockets for the placement of presbyopia-correcting inlays. The company also says that new features include an enhanced graphical interface and updated software. The LenSx system will also be available with gold or white exterior skin colors to help

color-coordinate the surgical suite.

Michael Lawless, MBBS, FRANZCO, of Vision Eye Institute, Chatswood, New South Wales, and a clinical associate professor at Sydney Medical School in Australia, notes that although he doesn't commonly implant corneal rings in his practice, "it's helpful to have this capability. It will be available with the release of the new software."

Elizabeth Yeu, MD, partner at Virginia Eye Consultants and an assistant professor at Eastern Virginia Medical School in Norfolk, welcomes the changes coming to the LenSx, "including created greater automation of the steps and improved efficiencies. This newest change provides expanded capabilities to the system, including corneal flaps and tunnels; and the imaging upgrade allows for more precise placement of our cataract surgical wounds," she says. "While corneal refractive surgery can be performed in either an office-based laser suite or in the

THE POWER OF PREEMPTION

OMIDRIA® is the first and only FDA-approved drug that provides continuous intracameral delivery of NSAID and mydriatic/anti-miotic therapy during cataract surgery¹

Coming October 1, 2018—Reinstatement of separate payment under Medicare Part B extends the benefit of OMIDRIA to more patients.

- Beginning **October 1, 2018**, OMIDRIA use in cataract and lens replacement surgery for patients with Medicare Part B coverage will be separately reimbursed for an additional 2 years
- Centers for Medicare & Medicaid Services (CMS) reimbursement will be managed under the same procedures that were in effect through 2017
- Omeros continues to support access to OMIDRIA through the OMIDRIAssure® Patient Assistance Program

INDICATIONS AND USAGE

OMIDRIA® (phenylephrine and ketorolac intraocular solution) 1% / 0.3% is added to ophthalmic irrigating solution used during cataract surgery or intraocular lens replacement and is indicated for maintaining pupil size by preventing intraoperative miosis and reducing postoperative ocular pain.

IMPORTANT SAFETY INFORMATION

OMIDRIA must be added to irrigating solution prior to intraocular use.

OMIDRIA is contraindicated in patients with a known hypersensitivity to any of its ingredients.

Systemic exposure of phenylephrine may cause elevations in blood pressure.

Use OMIDRIA with caution in individuals who have previously exhibited sensitivities to acetylsalicylic acid, phenylacetic acid derivatives, and other nonsteroidal anti-inflammatory drugs (NSAIDs), or have a past medical history of asthma.

The most commonly reported adverse reactions at $\geq 2\%$ are eye irritation, posterior capsule opacification, increased intraocular pressure, and anterior chamber inflammation.

Please see the Full Prescribing Information for OMIDRIA at www.omidria.com/prescribinginformation.

You are encouraged to report Suspected Adverse Reactions to the FDA.

Visit www.fda.gov/medwatch, or call 1-800-FDA-1088.

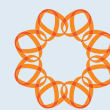
Reference: 1. OMIDRIA [package insert]. Seattle, WA: Omeros Corporation; 2017.

Visit www.omidria.com

Omeros does not guarantee reimbursement by any third-party payer. To be eligible for the "Equal Access" Patient Assistance Program, patients must be enrolled in OMIDRIAssure prior to surgery. For any patient for whom your facility received a free vial through the "Equal Access" Patient Assistance Program, the patient's insurance carrier(s) should not be billed for OMIDRIA. OMIDRIAssure program services are subject to change without notice.



OMEROS®, the OMEROS logo®, OMIDRIA®, the OMIDRIA logo®, and OMIDRIAssure® are registered trademarks of Omeros Corporation.
© Omeros Corporation 2018, all rights reserved. 2018-013

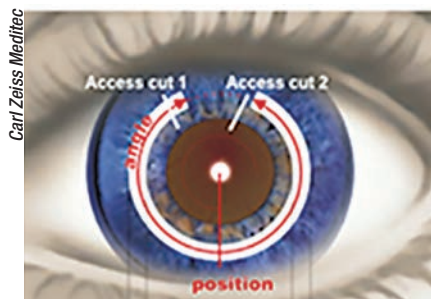


OMIDRIA®

(phenylephrine and ketorolac
intraocular solution)
1% / 0.3%

OR, this update provides an alternative option so surgeons can perform LASIK, corneal inlays and ring segments in the OR setting.”

VisuMax



Zeiss says VisuMax can cut tunnels to fit any ring dimensions, in arcs between 90 and 270 degrees or a full 360-degree arc.

In September 2016 the VisuMax femtosecond laser system (Carl Zeiss Meditec; Jena, Germany) got FDA approval for small-incision lenticule extraction, which enables surgeons to correct myopia without stromal ablation or flap-cutting. In time for ASCRS 2018, Zeiss announced that the VisuMax has received 510(k) clearance for its new corneal tunnel-cutting options, allowing surgeons to control many aspects of corneal ring placement for the treatment of keratoconus or astigmatism.

The company says that the VisuMax has the most flexible software for the creation of intracorneal ring tunnels, allowing surgeon adjustment of numerous parameters that can shape the clinical effect of ICRs. “The user chooses the tunnel width, diameter, depth and length in accordance with the intracorneal ring parameters and surgeon preference. These parameters are then saved as preferences for repeating procedures,” explains Steve Schallhorn, MD, Zeiss’ chief medical officer for global ophthalmic devices. “The ICR tunnels created by the VisuMax are very high precision, and are tailored to the surgeon’s preferences.”

Surgeons can select partial corneal-

tunnel incisions of 90 to 270 degrees, as well as full 360-degree arcs. The manufacturer claims that the VisuMax can be set to cut tunnels for any intracorneal ring dimension to control how tightly the ring or ring segment will fit. The user can also program the VisuMax to cut intracorneal ring tunnels at a tilt based on the outer ring diameter and the chosen depth of implantation. The ability to choose tunnel access cut width, shape and opening angle helps enhance patient comfort and prevent tissue tearing during ring insertion, according to Zeiss. The surgeon can choose to make zero, one or two access cuts; and the VisuMax supports surgeon preference for manual ring implantation.

Lensar

The Lensar femtosecond laser system with Streamline IV (Lensar; Orlando, Florida) also gained new FDA-cleared indications for corneal-pocket cuts and incisions. Lensar says the accompanying system upgrades expand the Lensar’s FDA-approved capabilities to support surgical presbyopia correction. The Windows operating system has also been updated from Windows 7 to Windows 10. A new Patient Interface Device (PID) Kit for use during pocket and flap cutting consists of a curved contact lens attached to the suction ring for enhanced stability. As an alternative to sterilization of the PID Kit using gamma radiation, Lensar has added the option of ethylene-oxide sterilization.

The company’s Streamline IV platform for pocket cuts includes a drop-down menu that allows the surgeon to choose pocket, flap or flocket settings. The surgeon can then enter a value for pocket depth, depending on the inlay

device being used, to create a stromal pocket of the FDA-recommended depth for that device.

The Lensar already provides precision control over the size of the capsular opening, the type and parameters of laser fragmentation treatment within the lens, and the size, architecture and location of full- and partial-thickness corneal incisions. The newly approved indication adds control of the size, architecture and depth of corneal pocket and flap cuts.

“Adapting the Lensar platform for stromal pockets and corneal flaps delivers on the company’s promise to expand the platform capabilities to facilitate presbyopia inlay procedures,” says Gregory Parkhurst, MD, FACS, of Parkhurst NuVision in San Antonio. “With more and more patients considering surgical alternatives to glasses and contacts to correct their near-vision issues, being able to leverage the features of the Lensar femtosecond platform for corneal inlays is a real benefit to surgeons.”

Lensar has also applied for CE approval of the new pocket-cutting features in the EU, and the FDA-cleared features will be made available to U.S. surgeons this year. **REVIEW**

Dr. Lawless and Dr. You are consultants for Alcon. Dr. Parkhurst is a consultant for Lensar, Alcon and Carl Zeiss Meditec.

1. Roberts TV, Lawless M, Sutton G, Hodge C. Update and clinical utility of the LenSx femtosecond laser in cataract surgery. *Clin Ophthalmol* 2016; 10: 2021–2029.



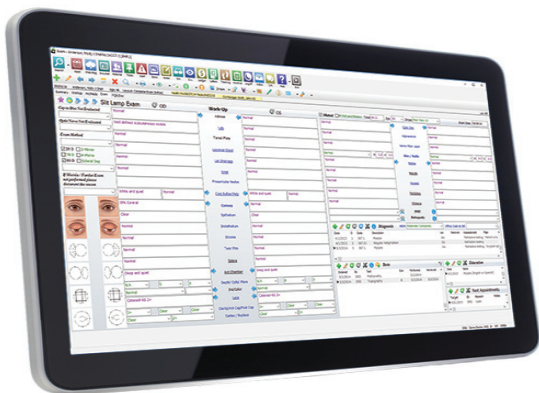In addition to flap- and pocket-cutting indications, the Lensar’s Windows operating system has been updated.

Ophthalmology's All-in-One EHR Solution

“As a physician leader at Georgia Eye Partners, one of the premier ophthalmology practices in America, Compulink helps me focus on our patients and not on the administrative processes of healthcare.”

Parul Khator, MD,
Georgia Eye Partners

EHR ■ PM ■ RCM ■ ASC ■ OPTICAL ■ ANALYTICS
PATIENT ENGAGEMENT ■ TELEHEALTH ■ AUDIT PROTECTION



- ✓ AI-Driven EHR Designed For Speed
- ✓ Supports ALL Ophthalmology Sub-Specialties
- ✓ Chart From A Single Screen

Ophthalmology's Leader for 33 Years!

Request a Demo Today

www.compulinkadvantage.com/onetab ■ 800.456.4522

compulink



Compliance Update: “Excluded” Employees

Why providers are excluded from Medicare and how to find out if a potential new hire has been excluded.

QI’ve heard that I should consider not hiring a provider who has been excluded from Medicare. Is that true?

AYes, if the exclusion remains in effect. If that person tells you that the exclusion is no longer applicable, you should check with the organization or program that excluded him and document the findings in your files.

QWhy would someone get excluded?

AOIG notes that people can be excluded for a number of reasons.¹ Most exclusions fall under the Social Security Act. For example, someone excluded from Medicare is excluded from all Federal and State health programs as well.² Section 1128 of the Social Security Act notes that there are both “mandatory” and “permissive” exclusions.³ Mandatory reasons for exclusion include:

- conviction for a program-related crime;
- conviction related to patient abuse; and
- felony conviction related to health-care fraud or a controlled substance.

Permissive exclusions are those for which the Secretary of Health and Human Services may choose to ex-

clude someone. The list is long, but includes in part:

- misdemeanor conviction related to fraud, theft, embezzlement, breach of fiduciary responsibility, or other financial misconduct;
- other nonhealth care program criminal offenses;
- conviction related to obstruction of justice of an investigation or audit;
- misdemeanor conviction related to a controlled substance;
- license revocation or suspension;
- claims for excessive charges or unnecessary services, and even “failure to furnish” medically necessary services;
- failure to supply information needed to determine proper payments or otherwise making false statements.

These are serious offenses and only apply after proper adjudication.

QDoes this consideration apply to other employees who work for me?

AYes. Exclusions can include your doctors but can also extend to people in nearly all other jobs within your organization—even those not in direct or indirect patient care.

QWhere can I find who is excluded?

AThe Office of the Inspector General of the Department of Health and Human Services publishes a List of Excluded Individuals and Entities that is updated frequently. There’s a look-up tool on its website (exclusions.oig.hhs.gov) as well as a downloadable file (oig.hhs.gov/exclusions/exclusions_list.asp).

QWhat does it mean if I discover (or hire) someone who is excluded?

AIt’s potentially quite serious if true—a large part or even all of your claims to the government could be invalid—and if already paid, you could have to give all of the affected funds back. OIG notes, “The effect of an OIG exclusion is that no Federal health care program payment may be made for any items or services furnished (1) by an excluded person or (2) at the medical direction or on the prescription of an excluded person ... [and the] payment prohibition applies to all methods of Federal health care program payment ... and applies even if the payment is made to a state agency or a person that is not excluded.”

QWhen should I check the OIG’s LEIE list?

AOIG says to “check it frequently.” Generally, you would do this before you make a decision to hire someone or even consider asking an entity to work alongside you. You would then do it at least annually. Other organizations might require you to do this more frequently (even as often as monthly), so be sure to check what each one requires and do what is needed. States might also have a separate list to search and have their own rules.

Q How do I prove I did these searches?

A Keep a record of the dates and results (even negative ones) of the exclusion searches that you do as evidence of performance.

Q What does this mean for me and my organization?

A It means that the excluded provider can't submit individually or even be employed by another entity or individual that submits claims or services to a federal health care program (such as Medicare – Parts A/B/C/D, Medicare Advantage or Medicaid, as well as the Veterans' Administration and TRICARE). The HHS' OIG office wrote a special bulletin on this as well.⁴ There can be fines and penalties of up to \$10,000 per item or service, and these can be trebled.

Q I know all my employed doctors are OK. Should I do more?

A Yes. You are required to check all your employees. OIG notes the “prohibition applies even if the administrative and management services are not separately billable ... an excluded individual may not provide other types of administrative and management services, such as health information technology services and support, strategic planning, billing and accounting, staff training, and human resources, unless wholly unrelated to federal health care programs.” **REVIEW**

Mr. Larson is a senior consultant at the Corcoran Consulting Group. Contact him at plarson@corcoranccg.com.


1. US Department of Health and Human Services. Office of the Inspector General. Exclusion Authorities. Accessed 05/13/18.

2. Social Security Administration. Compilation Of The Social Security Laws. Exclusion of Certain Individuals and Entities from Participation in Medicare and State Health Care Programs. Section 1128. [42 U.S.C 1320a-7]. Accessed 05/13/18.

3. US Department of Health and Human Services. Office of the Inspector General. Exclusions FAQ. Accessed 05/13/18.

4. US Department of Health and Human Services. Office of the Inspector General. Special advisory Bulletin on the Effect of Exclusion from Participation in Federal Health Care Programs. May 8, 2013. Accessed 05/13/18.

DRY EYE DISEASE: NOT ONLY A MEDICAL CONDITION, BUT A QUALITY-OF-LIFE CONDITION!



"I love long bike rides off the beaten path. Eye drops limited my freedom. Occlusion Therapy not only relieved my dry eye symptoms, but eliminated the need for eye drops. The back country is mine again!"

**VisiPlugs® and
LacriPro® Punctum Plugs:
For all your
dry eye patients!**



Lacrimedics

(800) 367-8327

E-mail: info@lacrimedics.com

www.lacrimedics.com

¹Dramatization. Not a real patient.

©2017 Lacrimedics, Inc.

Choosing MIGS (for You and Your Patient)

Christopher Kent, Senior Editor

With more options rapidly appearing, picking the right procedure can be challenging. Here's help.

The number of glaucoma surgeries that could be considered MIGS expands every year. In theory, at least, that makes the choice of a MIGS procedure more challenging simply because the number of options keeps growing. Given this broadening array, two questions come to mind: First, which MIGS procedures—and how many—should you learn? And second, if you have more than one MIGS option to offer your patients, how do you choose the best one for a given patient?

To answer either of these questions, we need to clarify two things: First, what qualifies a procedure to be considered a MIGS procedure? And second, how can we subdivide MIGS into more manageable categories to simplify the choice?

MIGS: An Overview

“One of the defining characteristics of MIGS procedures is that they use an *ab interno* approach,” says Ronald L. Fellman, MD, attending surgeon and clinician at Glaucoma Associates of Texas, adjunct clinical professor of ophthalmology at North Texas Eye Research Institute and clinical associate professor emeritus at the University of Texas Southwestern Medical Center in Dallas. “This is obviously

very different from our past glaucoma surgeries, which were all *ab externo*. Also, all MIGS must have a very high safety profile. In days past we only had one or two glaucoma procedures, and we were more likely to talk about the risk of surgery, which was considerable. That's why we didn't resort to surgery until we were convinced the patient would go blind without it. It's a very different mindset today.”

Like many glaucoma surgeons, Dr. Fellman subdivides the MIGS procedures into categories based on the spaces that they target—although surgeons may disagree about whether every category qualifies as MIGS. “First is the trabecular space, including Schlemm's canal, which is the conventional outflow path,” Dr. Fellman says. “Today, the device most commonly used in the trabecular meshwork is the iStent, but others in that space include the Trabectome, the Kahook Dual Blade and circumferential trabeculotomy, with or without viscodilation. The Hydrus should also be available pretty soon, as well as new iStent models. Second is the supraciliary space, for which only the CyPass is currently approved. Third is the subconjunctival space. The only device currently approved for that is the XEN, with the InnFocus on the horizon.”

A PUBLICATION BY **REVIEW**
of Ophthalmology

RETINA SPECIALIST

Retina Specialist focuses on the latest advances in the diagnosis, medical management and surgical treatment of diseases of the retina, along with practical, real-world advice from leading clinicians and other experts on managing the successful retina practice.



The new addition to the *Review* family serves the entire Retina Specialist marketplace.

Look for your issues in 2018:

- » **MARCH**
- » **JUNE**
- » **SEPTEMBER**
- » **NOVEMBER**

For inquiries contact

RETINASPECIALIST@JOBSON.COM

Advertising opportunities

JIM HENNE • PUBLISHER • 610-492-1017 • JHENNE@JOBSON.COM

MICHELE BARRETT • 215-519-1414 • MBARRETT@JOBSON.COM

MICHAEL HOSTER • 610-492-1028 • MHOSTER@JOBSON.COM

www.retina-specialist.com

Dr. Fellman notes that there's some disagreement among surgeons regarding whether it's legitimate to categorize subconjunctival procedures such as the XEN as MIGS surgeries. "Some people call these procedures 'MIGS-plus,' but I think it's reasonable to consider the XEN a MIGS procedure because it's very different from a standard trabeculectomy," he says. "We're hoping that the XEN, which has a set internal lumen size of 45 µm, will produce a more manageable, standardized bleb. However, it's not that simple. A third of the people implanted with a XEN have to be needled, usually in the office. The reality is, most general ophthalmologists don't want to mess with a bleb, so they tend to stay away from the subconjunctival space, and if you're not comfortable dealing with a bleb you shouldn't be doing the XEN. Furthermore, in the MIGS arena, any subconjunctival procedure is going to be less predictable than some of the other MIGS procedures. Nevertheless, I believe it is legitimate to consider the XEN a MIGS procedure.

"Finally, I believe endoscopic cyclophotocoagulation should be included in the MIGS group in a fourth category, as a means to decrease aqueous humor production," he concludes. "So there are four broad spaces that you can approach *ab interno*: three outflow, one inflow." (Some surgeons might include micropulse transscleral cyclophotocoagulation in the fourth category, although it has been associated with some complications that lead many to view it as not belonging under the MIGS mild, "less-invasive" umbrella.¹)

Which MIGS Should You Learn?

Because so many MIGS procedures are available—with more waiting in the wings—should you learn to do more than one? And if so, how many?

Most experts agree that every ophthalmologist should be able to per-

MIGS by Category *

Trabecular outflow:

iStent
Trabectome
Kahook Dual Blade
Hydrus
ab interno canaloplasty
circumferential trabeculotomy (GATT, Trab360)

Ciliary outflow:

CyPass Micro-stent
iStent Supra

Subconjunctival outflow:

XEN-45
InnFocus

Aqueous humor reduction:

Endoscopic cyclophotocoagulation

* There's still considerable debate regarding whether some procedures should be considered MIGS; this list is not exhaustive.

form at least two—preferably three—MIGS procedures. They offer the following advice:

- **Learn MIGS procedures that reduce pressure in different ways.**

This makes sense for at least two reasons: One, a given approach may not work with a particular patient. Two, if your first choice works but doesn't produce sufficient pressure reduction, you'll have a second option to add.

"Even if you're a general ophthalmologist, if you have a favorite MIGS procedure that you're comfortable with, you should be able to do something different in case that procedure doesn't work or the anatomy doesn't favor it," says Brian Francis, MD, MS, a professor of ophthalmology in the glaucoma service and the Rupert and Gertrude Stieger Endowed Chair at the Doheny Eye Institute, part of the David Geffen School of Medicine at the University of California, Los Angeles. "If you're a glaucoma specialist, you should be able to choose an option from three, or even all four MIGS categories. The point is that you don't want to use one procedure for every situation. You want to have

some ability to tailor the procedure to your patient."

Dr. Fellman notes the benefits of being able to add together the efficacy of multiple MIGS. "Let's say you do a phaco-CyPass, tapping into the uveoscleral outflow system, and it doesn't lower the pressure enough," says Dr. Fellman. "You could go back later and perform various trabecular outflow procedures, because many are approved as standalone procedures. Now you've tapped into both natural outflow systems. This approach might actually be the most effective strategy, but no one has done a study to prove that—so far. The XEN is another follow-up option in this situation, because it's also a standalone that doesn't have to be paired with phaco. But don't get into the XEN unless you're willing to be a blebologist and needle blebs."

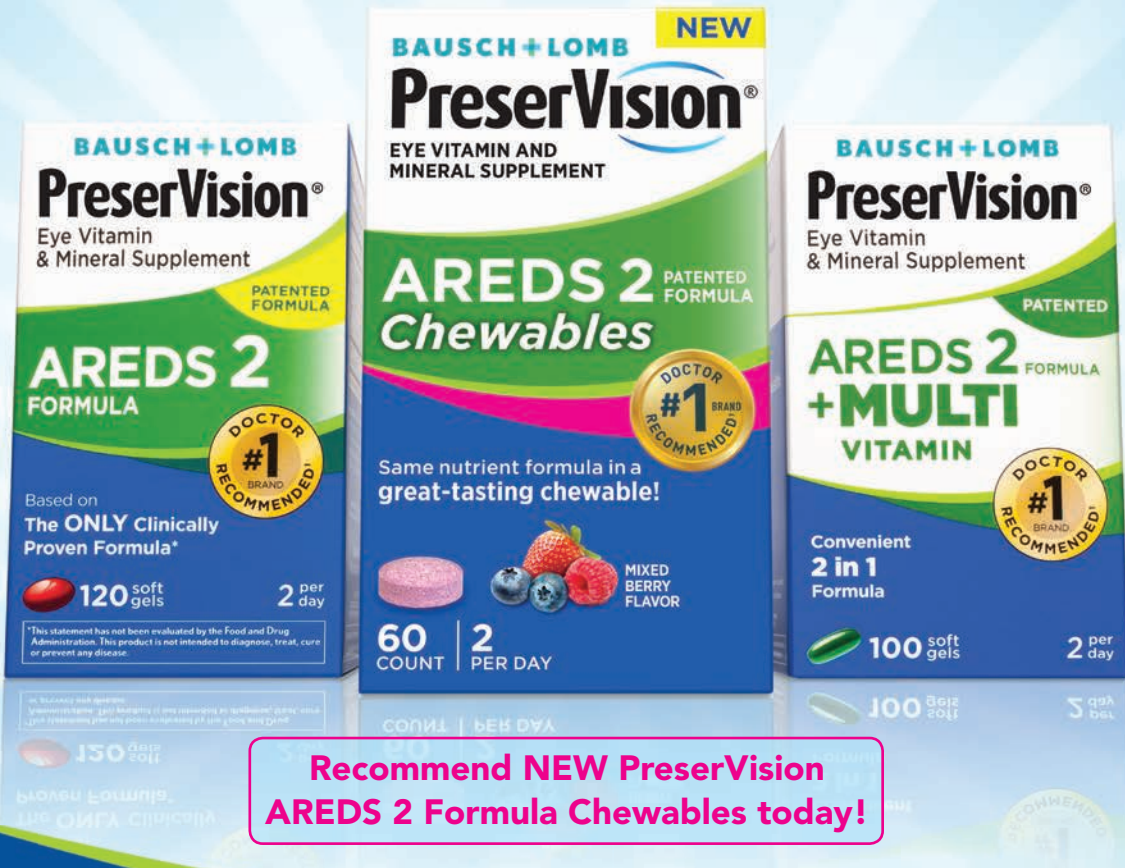- **Learn more than one trabecular meshwork procedure.** Dr. Fellman believes it's worthwhile to be able to perform more than one canal-based procedure. "It's good to know not only how to bypass the meshwork with an iStent, but how to either remove it with something like the Dual Blade, or cleave it open with the GATT procedure," he says. "They work differently, and one might be a little more aggressive than the other."

Brian E. Flowers, MD, managing partner/glaucoma specialist at Ophthalmology Associates of Fort Worth in Texas, agrees that ophthalmologists could benefit from being able to perform two Schlemm's canal-based procedures such as the iStent and Kahook Dual Blade—as well as one supraciliary procedure. "The iStent and Kahook Dual Blade are fairly straightforward," he notes. "A glaucoma specialist will probably be more comfortable working in the angle, so he or she might want to master a few of the more challenging MIGS procedures as well."

- **Be able to perform a MIGS**

Welcome a **new** addition to the PreserVision® family

Same proven nutrient formula, now in a convenient **chewable**



Recommend NEW PreserVision AREDS 2 Formula Chewables today!

Now, with new PreserVision® Chewables, it's even easier for patients to get all the benefits of the clinically proven AREDS 2 Formula*:

- Contains the exact levels of nutrients recommended by the National Eye Institute^{1,2†}
- Ideal for patients who have difficulty swallowing pills
- Great-tasting mixed berry flavor

Because it's their vision. PreserVision
www.preservision.com

*These statements have not been evaluated by the Food and Drug Administration. This product is not intended to diagnose, treat, cure or prevent any disease.

[†]To help reduce the risk of progression for patients with moderate-to-advanced age-related macular degeneration.

References: 1. Yong JJ, Scott IU, Greenberg PB. *Ophthalmology*. 2015;122(3):595-599. 2. Age-Related Eye Disease Study 2 Research Group. *JAMA*. 2013;309(19):2005-2015.

PreserVision is a trademark of Bausch & Lomb Incorporated or its affiliates. AREDS and AREDS2, studies conducted by the National Eye Institute (NEI), are registered trademarks of the United States Department of Health and Human Services (HHS). ©2018 Bausch & Lomb Incorporated. PVC.0018.USA.18

BAUSCH+LOMB
See better. Live better.

procedure that you can do without cataract surgery. “Most MIGS procedures—though not all—are approved only in conjunction with cataract surgery,” Dr. Francis notes. “You should be able to perform at least one that’s approved for use when the patient doesn’t need cataract surgery.”

• *If you’re willing to work with a bleb, learn one of the subconjunctival MIGS procedures.* “These appear to have a reduced risk profile compared to a tube shunt or trabeculectomy,” Dr. Francis points out. “I think it’s worthwhile to master at least one of those.”

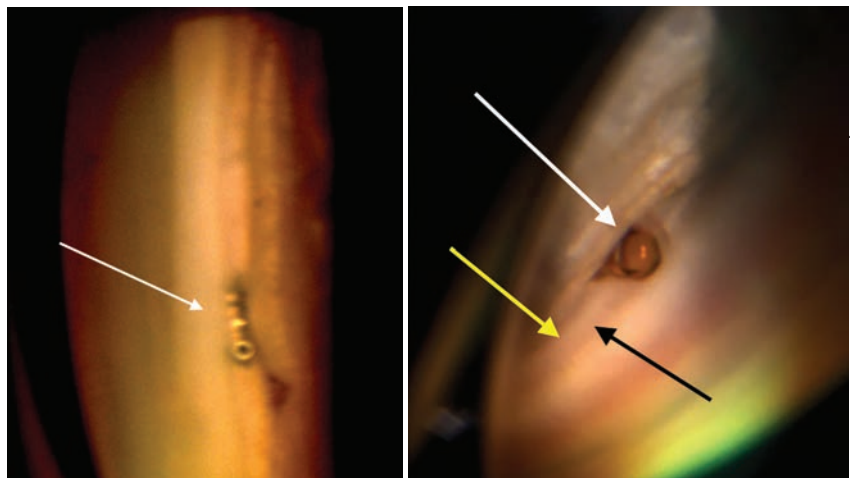
In the final analysis, of course, each surgeon will probably find that certain MIGS procedures are more comfortable and produce better results in his or her hands. “The most important thing,” says Dr. Fellman, “is to use the MIGS procedures that you’re most comfortable with, the ones that work the best for you.”

Mastering MIGS

Once you’ve decided which MIGS you’d like to add to your armamentarium, these strategies can help to smooth your path:

• *At the outset, stick with one procedure that you want to learn.* “If you’re not just concentrating on one procedure, you’re not giving yourself the best opportunity to learn it well,” says Dr. Fellman. “It’s a bad idea to say, ‘Let me try this, let me try that.’ Commit to learning one procedure, get it down, and then move on.”

• *Practice the positioning and maneuvers before attempting the surgery.* “Performing MIGS requires a very different proprioceptive feedback loop on the part of the surgeon,” notes Dr. Fellman. “When performing something like phaco, you’re looking through the microscope at the tips of the two instruments in your hands. Your brain becomes accustomed to knowing where your hands are, based



Ronald L. Fellman, MD

Left: An iStent is well positioned in Schlemm’s canal, bypassing the diseased trabecular meshwork. Right: A CyPass, well positioned in the nasal angle (white arrow). The collar is flush with the anterior edge of the trabecular meshwork (black arrow) but inserted below the scleral spur (yellow arrow).

on that view. But that proprioceptive loop is gone when you work in the angle. You have to establish a new mental feedback loop, and that takes a while.

“To work in the angle, you have to turn the patient’s head, and you have to turn the microscope,” he continues. “Nobody’s initially used to working in that position. Then, you have to learn how to put the gonio lens on the eye so that you balance it without excessive pressure. Over the years I’ve worked with many surgeons learning to do angle procedures, and the most common initial problem is a poor view because of excessive pressure on the cornea with the nondominant hand.”

Dr. Fellman says the way to iron out these issues before attempting surgery is to practice these movements on patients who don’t need a MIGS procedure. “You can practice these maneuvers with some of your glaucoma patients when you’re performing phaco,” he says. “At the end of the procedure—or at the beginning if that makes you more comfortable—you can turn the patient’s head away from you and turn the microscope towards you and use the Swann-Jacob gonio lens (which is a lens, not a prism) and

see what you can see. This will give you a chance to experience what it’s like to balance a gonio lens on the eye with your nondominant hand and do it well enough to maintain a pristine, excellent view of the chamber angle.

“Then, with your dominant hand, make a few simple motions,” he continues. “You can even put an instrument in your hand just to feel what it would be like if you were working in the angle. But the important part is to practice that until you get a really good view. That will give you a leg up when you do your first MIGS case.”

• *Take advantage of educational resources.* “Look at lots of videos,” advises Dr. Fellman. “Most device makers have a course you can take and some lab models you might be able to use. If you’re lucky enough to be in an area where someone is already doing the procedure, you may want to go and watch.”

Dr. Flowers notes that the companies tied to MIGS procedures provide a lot of resources to help surgeons master them. “They offer wet labs and will even send someone into the OR with you as a mentor,” he points out. “In addition, they offer access to experienced MIGS surgeons on a consulta-

E

V E R Y

D O S E

C O U N T S

STRIVE TO SEE THE BEST RESULTS POSSIBLE

Regular fixed-interval dosing of long-term treatment with anti-VEGFs has been shown to provide better gains and maintenance of vision, compared to PRN or treat-and-extend dosing regimens, in some patients with Wet AMD and DME.¹⁻⁶

Ask your Regeneron representative what we can do to help ensure patients come in for their scheduled treatment.

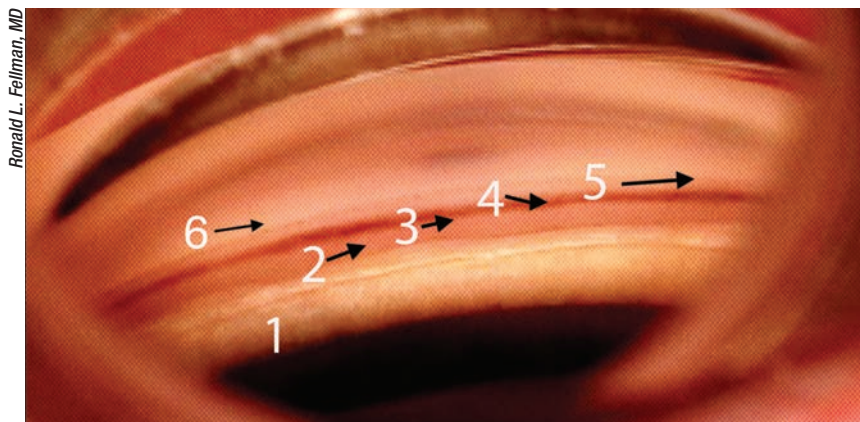
anti-VEGF = anti-vascular endothelial growth factor; AMD = Age-related Macular Degeneration; DME = Diabetic Macular Edema.

References: 1. Heier JS et al. *Ophthalmology*. 2016;123(11):2376-2385. 2. Rosenfeld PJ et al. *N Engl J Med*. 2006;355(14):1419-1431. 3. Ho AC et al. *Ophthalmology*. 2014;121(11):2181-2192. 4. Nguyen QD et al. *Ophthalmology*. 2012;119(4):789-801. 5. Kaiser PK et al. *Ophthalmol Retina*. 2017;1(4):304-313. 6. Peden MC et al. *Ophthalmology*. 2015;122(4):803-808.

REGENERON

© 2018, Regeneron Pharmaceuticals, Inc. All rights reserved.
777 Old Saw Mill River Road, Tarrytown, NY 10591

01/2018 US-OPH-13911



Ronald L. Fellman, MD

A good understanding of angle anatomy is crucial to performing MIGS. 1) Area close to pupil. 2) Ciliary body band. 3) Scleral spur. 4) Trabecular meshwork. 5) Schwalbe's line. 6) The area above Schwalbe's line, where a XEN would typically be placed.

tive basis for questions and issues with individual patients. Probably the most important thing is to brush up your gonioscopy skills and make sure you're comfortable with what you're seeing. Practice gonioscopy on a regular basis. That can't be overstated."

"All those things come together in the end to make you a little more confident when you go into the OR," Dr. Fellman says. "As you know, confidence is always important to a surgeon. You don't want to go into the OR feeling unsure about whether you can do this. Your frame of mind is just as important as the frame of the angle! So pick out one MIGS procedure to start, practice the type of positioning and movements you'll need in surgery, and take advantage of every educational resource you can. You'll be off to a great start."

Which MIGS for Which Patient?

Once you've learned to perform two or more MIGS, you'll have to decide which MIGS makes the most sense for the patient you're currently managing. The choice you make will depend on a number of factors, ranging from the patient's angle anatomy to your comfort with the surgical requirements of a given option. When making a choice, the following 12 strategies will help:

1. Know your anatomy. "The area of concern with MIGS procedures is the iridocorneal angle, which goes from the iris to the cornea," Dr. Fellman points out. "The picture above shows the different parts of the angle anatomy clearly. The area marked 1 is close to the pupil. To do an ECP, you go in behind the iris with your ECP probe and locate the ciliary body processes. Number 2 marks the ciliary body band, which attaches to the scleral spur, a vital landmark that divides up the iridocorneal angle and determines where you're going to place your MIGS. Uveoscleral outflow occurs below, or posterior to, the scleral spur, going out through the ciliary body, while trabecular outflow occurs above the spur (the trabecular meshwork, labeled 4). So the scleral spur differentiates where the iStent and CyPass go.

"In this picture the meshwork has pigment, about 3+," he continues. "This is where an iStent would be placed, and the location for the Dual Blade, Trabectome, trabeculectomy-viscodilation and GATT. Number 5 is Schwalbe's line; that's where the cornea starts. Right above Schwalbe's line—the area labeled 6—is where you typically want to place your XEN."

2. Keep your gonioscopy skills in

top shape. "To perform MIGS, you have to be comfortable working in the angle," notes Dr. Francis. "You have to be comfortable with operative and preoperative gonioscopy. Knowing the anatomy in that space is key to identifying which procedure to do, and to targeting the correct tissue during the procedure."

Dr. Fellman agrees. "Being able to identify and visualize the structure that your procedure targets is obviously crucial to a successful surgery," he says. "Because the angle anatomy is so important, in order to successfully perform MIGS a surgeon has to be more than just good at gonioscopy; you have to be a superb gonioscopist."

"I find that many comprehensive ophthalmologists—and even glaucoma specialists—who are really interested in MIGS haven't done enough gonioscopy," he adds. "That's not entirely surprising, because when you do a trabeculectomy or a tube shunt, gonioscopy is not as important as it is with MIGS. As a result, gonioscopy is underutilized. In contrast, gonioscopy is critical to the success of all of the MIGS outflow procedures."

3. Focus on the most important factors. If you're not yet certain about which things you should pay attention to when choosing a MIGS procedure for your patient, Dr. Fellman suggests using the acronym "ABCDE" to remember five key factors.

"You can say that 'A' stands for the angle," he explains. "The key landmark in the angle is the scleral spur, which separates the trabecular outflow area from the uveoscleral outflow area. That's important to be able to see and identify, because different MIGS procedures require access to one space or the other. Identifying these locations and determining how well you can see them will help you decide what you can do safely in a given eye."

"B" stands for the blood-aqueous barrier," he continues. "The condition

Be open.



Kahook Dual Blade® Perform without limits.



Minimally invasive procedures shouldn't be limited to being performed with other procedures. The Kahook Dual Blade's intuitive design enables safe and precise excision of trabecular meshwork to access multiple collector channels, any time it is needed.

Visit KDBcert.com to learn how the Kahook Dual Blade lets you perform without limits.



A Few MIGS Pearls

These strategies can make MIGS procedures go more smoothly:

- **In the operating room, if you can't find the trabecular meshwork, try lowering the pressure.** "Everybody thinks the trabecular meshwork is pigmented, but sometimes it has no pigment, or a minimal amount," notes Ronald L. Fellman, MD, attending surgeon and clinician at Glaucoma Associates of Texas. "In those cases, it becomes almost invisible. If you're planning a trabecular meshwork procedure and you're in the OR and looking at the angle but can't see the trabecular meshwork, try lowering the pressure with a paracentesis. Once you lower the pressure in the eye below the episcleral venous pressure, blood will often flow into the canal. It will look like a red streak."
- **If you're combining an implant with ECP, use the endoscope to check the implant.** "The endoscope, which is part of the ECP unit, has a camera and light built into it," notes Dr. Fell-

man. "So, if you're doing an ECP after implanting a MIGS device, you can use the camera to look at the implant up close and make sure it's seated properly in the right location."

- **If your MIGS patient has been on drops for a long time, make sure to explain that the MIGS procedure may not eliminate the need for drops.** "Some patients assume that because they're having glaucoma surgery, they won't need to use drops anymore," Dr. Fellman points out. "However, if the patient has been on drops for a long time, there may still be a need to use some drops after MIGS—though probably fewer. The extent to which this is true is probably an issue of how long the patient has been using drops, as well as how many they've been using. By making sure the patient has reasonable expectations, you'll avoid ending up with an unhappy patient."

—CK

of the blood-aqueous barrier helps reveal the integrity of the environment inside the anterior chamber. For example, if you have a lot of flare and cell, that's not a good sign for wound healing. You wouldn't want to do any kind of filtering surgery—including the XEN—in an eye like that. You need a pristine blood-aqueous barrier to have a good shot at successfully implanting a XEN.

"C" stands for the conjunctiva," he says. "If the conjunctiva is damaged or scarred, that also should lead you away from a filtering procedure and towards a trabecular or uveoscleral approach.

"D" represents the disc," he continues. "Many of the MIGS procedures are only approved for mild to moderate glaucoma damage, so if the patient's nerve is badly damaged you'll want to use a procedure that will give you a lower pressure in a more predictable fashion. This is especially important if you're just learning one of the MIGS procedures; that surgery is not going to be as predictable as a procedure you've been doing for years, such as a standard trabeculectomy or tube shunt.

"E" stands for your level of exper-

tise," he concludes. "Of course, there's a learning curve to everything, but you can reduce the learning curve by getting certified, by watching other surgeons in the OR who've done the procedure a lot, and by watching online videos."

4. Be alert for scarring. "If you have conjunctival scarring from a scleral buckle or other cause, then you're going to want to steer away from the subconjunctival filtration procedures, such as XEN or InnFocus," notes Dr. Francis. "If you have scarring in the angle from, say, chronic angle closure, then you may want to stay away from the trabecular outflow procedures. Instead, you might go with something that decreases aqueous production, or go with subconjunctival filtration. You have to take into consideration what the anatomy is giving you.

"In most patients, knowing the condition of the collector channels before surgery is difficult or impossible, at least with today's technology," he continues. "However, you might encounter a patient with severe scarring that you know will affect the collector channels, whether as a result of chemical trauma or a disease such as

ocular cicatricial pemphigoid. In that situation, you'd want to steer away from trabecular-outflow-enhancing procedures.

"This gets to the concept of targeting," he says. "Let's say you have a device that only accesses a certain portion of the angle, such as an iStent or Hydrus. In that situation you'd want to try to identify target collector channels by determining where the outflow already exists and can be recruited. On the other hand, with a supraciliary stent like the CyPass, you're not as worried about collector channels because you're not using them. The same should be true for decreasing aqueous humor production and subconjunctival filtration.

"It's worth noting that the MIGS procedures that unroof Schlemm's canal are a little different from the stents, because you're accessing more of the angle," he adds. "For instance, the Trabectome, the Goniotome and the Kahook Dual Blade all treat about 180 degrees of the angle, and the Trab 360 and GATT procedures both treat 360 degrees of the angle. With those procedures, there's less need to worry about targeting specific collector channels and outflow pathways."

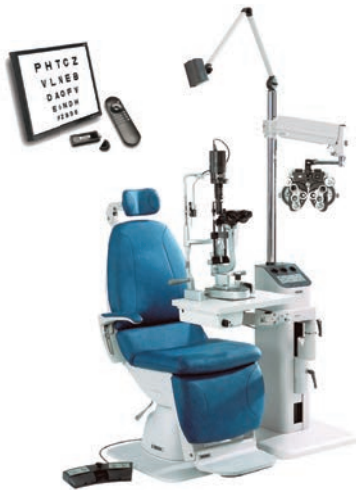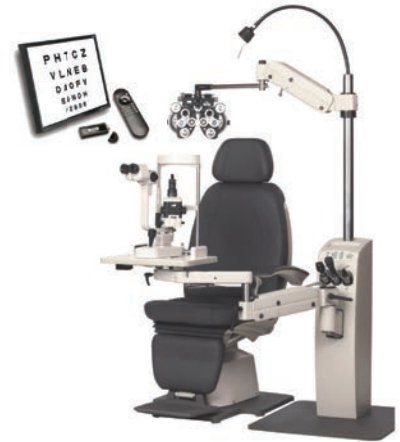LOMBART LANE PACKAGES

VALUE LANE PACKAGE

\$13,995

Savings of \$2,585

- ✓ LOMBART CS-5 Instrument Stand & Exam Chair
- ✓ Topcon SL-2G Slit Lamp
- ✓ Topcon VT-10 Refractor
- ✓ LOMBART CVSe Acuity System



PREMIUM LANE PACKAGE

\$28,990

Savings of \$3,277

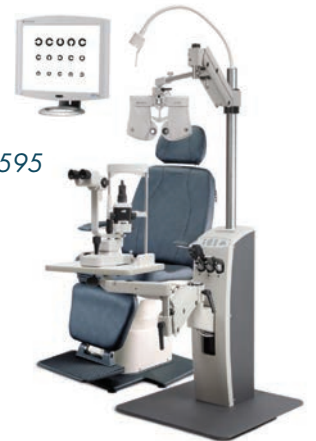- ✓ Reliance 7900 Instrument Stand with Console
- ✓ Reliance FX 920 Examination Chair
- ✓ Haag-Streit BM900 LED Slit Lamp
- ✓ Reichert Ultramatic RX Master Phoropter®
- ✓ Haag-Streit Tonometer
- ✓ Reliance Stool
- ✓ LOMBART CVSe Acuity System

DIGITAL REFRACTION PACKAGE

\$29,485

Savings of up to \$4,595

- ✓ LOMBART CS-5 Instrument Stand & Exam Chair
- ✓ Topcon SL-2G Slit Lamp
- ✓ Premium Digital Refractor (Reichert or Topcon)
- ✓ Corresponding Acuity System



2-Year Warranty Included in ALL Lombart Lane Packages

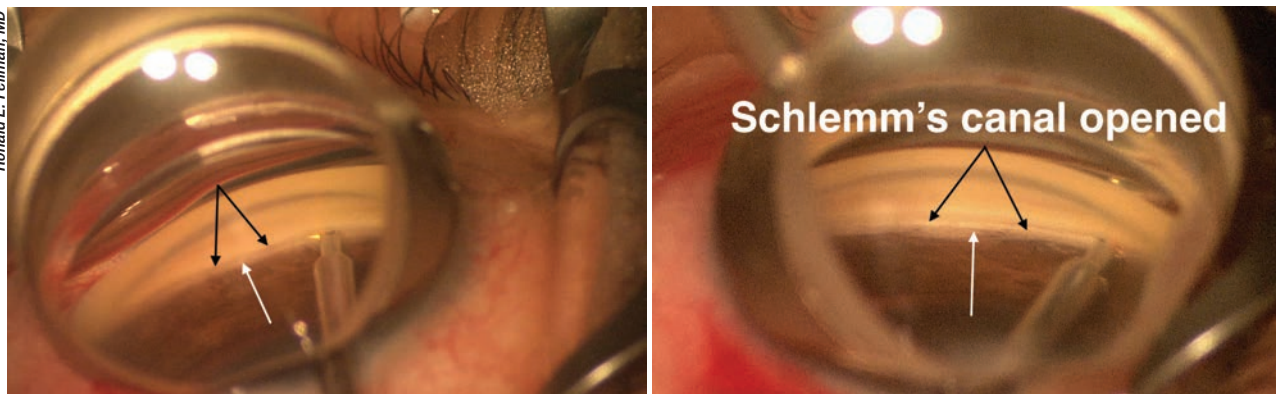
CALL US TODAY AT **1-800-LOMBART**



LOMBART
YOUR OPHTHALMIC PARTNER

800.LOMBART www.lombartinstrument.com

Ronald L. Fellman, MD



Left: A Trabectome positioned adjacent to the trabecular meshwork (black arrows). The white arrow points to the scleral spur. Right: The Trabectome has removed part of the trabecular meshwork and inner wall of Schlemm's canal. The white stripe (black arrows) is the back wall of the canal; the white arrow denotes the scleral spur. The Trabectome is then aimed in the other direction to ablate the remaining TM.

5. For an eye with a narrow angle or plateau iris, consider using ECP. “Narrow angles are not a big deal when performing most MIGS procedures that are approved with cataract surgery,” notes Dr. Flowers. “Once you take the cataract out, the angle is no longer narrow, allowing you to perform any of the MIGS procedures. Of course, doing so would be off-label, because these procedures are not specifically approved for narrow-angle cases, but they would certainly work in that scenario.”

Dr. Fellman notes that many surgeons do phaco-ECP in a narrow-angle eye. “Narrow-angle eyes are more prone to postop complications such as aqueous misdirection that can occur when the pressure gets too low,” he points out. “Phaco-ECP is a very safe way to handle a narrow-angle eye because by deepening the chamber with phaco you’re going to increase the outflow and lower the pressure, while the ECP will decrease the inflow. This is also very effective in eyes with plateau iris, because you can do the ECP a little bit more anteriorly to shrink the peripheral iris and open up the angle a bit more.

“You can do even more for a narrow-angle patient by performing goniosynechialysis,” he continues. “If you encounter four or five clock hours of peripheral anterior synechiae, which

is not uncommon in these eyes, you can push the iris posteriorly and break those adhesions during the surgery. That’s going to open up the angle as well. Now you have three mechanisms that are lowering the pressure: the phaco, by deepening the chamber; the goniosynechialysis, by opening up the meshwork to the flow of aqueous; and finally the ECP, which is reducing aqueous inflow.”

However, Dr. Flowers notes that PAS are not always breakable. “PAS are only easy to break if they’ve been in the angle for six months or less,” he says. “After that, they can be difficult or impossible to break, and that will definitely make most MIGS procedures impossible to perform. Certainly a XEN procedure would be impossible under these conditions.”

6. Consider how much pressure reduction the patient needs. “In most cases, the more severe the disease, the lower your target pressure will be,” says Dr. Francis. “If you’re trying to reach a target pressure in the low teens, for example, you don’t want to be limited by episcleral venous pressure or other physiologic constraints. You’re probably going to want to consider a subconjunctival filtration procedure. If you’re not going to do one of those, then you might want to combine multiple other MIGS pro-

cedures. You could combine a suprachoroidal shunt and a procedure that reduces aqueous humor production; or combine a trabecular meshwork procedure with aqueous humor reduction.”

“In glaucoma,” notes Dr. Flowers, “one of the axioms is, ‘The more you do, the more you get.’ For example, if you’re working in the trabecular meshwork, you might be debating whether to implant an iStent or a Hydrus. [The Hydrus has completed its clinical trials, but it hasn’t been approved as of this writing.] The iStent is a small device that opens up a very localized segment of the trabecular meshwork, while the Hydrus opens up an entire quadrant of Schlemm’s canal. Our group participated in the Hydrus clinical trial, and the data was just published; its IOP-lowering effect appears to be greater than that achieved with one iStent. Of course, the caveat is that the trial designs weren’t exactly the same. Nevertheless, based on our best interpretation of the data, the Hydrus has a better long-term IOP effect that a single iStent does. That goes along with the idea that the more you do, the more pressure reduction you get.

“Generally, the same could be said for the Kahook Dual Blade vs. the GATT procedure,” he continues. “The Dual Blade opens up a limited portion

of Schlemm's canal, whereas a GATT-type procedure opens up the entire canal and can potentially give you a better pressure effect. Of course, that's a supposition, because there's no head-to-head study comparing the two. However, I think most surgeons would expect to achieve a greater effect by opening up the entire trabecular meshwork than just part of it."

In terms of comparing options that affect different outflow pathways, Dr. Flowers notes that the clinical studies done to test the CyPass and Hydrus implants had almost identical designs. "Because the designs were so close, I think you can draw some comparisons there," he says. "They showed pretty similar IOP-lowering effects. Of course, it's not a perfect comparison, because they weren't in the same trial together."

Regarding balancing safety and efficacy, Dr. Flowers says that each comparison of MIGS procedures is different. "It might be true that the GATT procedure carries a little more risk than the Kahook Dual Blade," he says. "The more angle you disrupt, the greater your risk of bleeding in the short and long term. On the other hand, I'd say that's probably not true for the Hydrus vs. the iStent, because the risk of those two procedures appears to be about the same."

Dr. Flowers points out a seldom-discussed consideration relating to your choice of MIGS when a more significant drop in pressure would be ideal. "One important distinction between a supraciliary procedure and the trabecular-meshwork-based MIGS is that some patients will have a dramatic drop in pressure with a ciliary body procedure—the kind of drop you'll never see with the trabecular meshwork options. This is easy to miss if you only look at the mean IOP-lowering data. In the CyPass IDE trial, for example, the average pressure lowering was 2 mmHg greater than was achieved with cataract surgery

alone—but some patients had much more significant drops in pressure.² That means that this type of procedure at least has the potential to have that kind of impact.

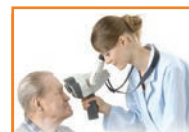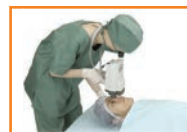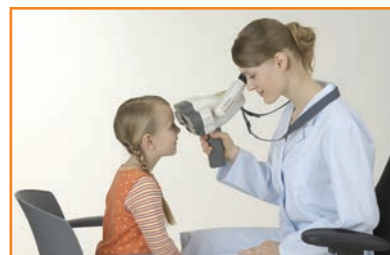"At the moment we don't know why some patients have that more dramatic response, although one would think that it has to do with the healing response," he continues. "When you do a supraciliary implant like a CyPass, you're creating a dialysis—ideally a limited dialysis—and then a healing process takes place. As with many surgeries, if it heals over too aggressively, the function decreases or is eliminated. So, patients who keep their limited dialysis open for an extended period of time will have a more dramatic, sustained drop in their pressure."

Dr. Flowers says he keeps this possibility in mind when choosing a MIGS procedure. "If I'm trying to achieve a significant drop in pressure, I know a supraciliary procedure at least has the potential to achieve that, for a minimal—possibly even theoretical—increase in risk," he says. "That's definitely a factor in my decision process."

Of course, it's also possible to do more than one MIGS procedure at the same time in order to achieve a larger pressure reduction. Dr. Flowers says that with only a few exceptions, however, he prefers not to perform multiple MIGS simultaneously. "So far, I've only done that in one circumstance," he says. "I had a patient with chronic inflammation and multiple failed filtration surgeries. We went in and did a GATT plus ECP, and that controlled his pressure. So there are situations in which doing ECP plus some kind of angle procedure can be beneficial in certain populations."

7. Aim for the safest option. "Ultimately, the reason MIGS exists is for safety," Dr. Flowers notes. "Every glaucoma procedure has an efficacy side and a safety side, and there's a continuum of surgeries that range

Precise Measurements Anytime, Anywhere



THE SERIES 3 HAND-HELD AUTOREFRACTOR **RETINOMAX** Righton



- ✓ Fast
- ✓ Lightweight
- ✓ Ergonomically Balanced
- NEW Auto Quick Measurement
- NEW Auto Pupil Measurement
- ✓ Small Pupil 2.3mm Measurement Acquisition
- ✓ Flexible Positioning—Sitting, Standing, Supine

S4OPTIK

www.s4optik.com | 888-224-6012

Sensible equipment. Well made, well priced.
For today's modern office.

from being highly effective pressure-reducers that carry many more safety risks, to those that are incredibly safe but produce nominal pressure benefit. I'd argue that the relationship is not linear, however—meaning there are surgeries that can achieve slightly better pressure benefit without changing the safety factor very much.

“For me, the deciding factor when I'm choosing a MIGS procedure is the safety side first, although both factors matter,” he concludes. “I consider how much I believe this particular patient can tolerate in terms of risk, and then balance that against the amount of pressure reduction I need to get. I pick the MIGS procedure that I believe yields the best balance—but I do lean towards safety first.”

8. Consider the patient's age.

Dr. Francis notes that the age of the patient can influence the surgeon's choice of MIGS procedures for a couple of reasons. “If the patient is very elderly, you might choose to be less aggressive about lowering their pressure,” he says. “You may want to stay away from the transconjunctival procedures and go with a more traditional MIGS. On the other hand, age also decreases the amount of scarring you encounter. A younger patient would be more likely to produce a lot of scarring with a transconjunctival procedure such as XEN, so that might not be as appropriate in a young patient.”

Dr. Flowers says the age of the patient doesn't influence his choice of MIGS procedure, except in one respect. “In glaucoma it's always important to be planning for the next procedure, because every procedure has a lifespan that follows the Kaplan-Meier curve,” he says. “If you do 100 procedures, 90 percent of them will be working a year later. At two years, 80 percent of them will be working, and so on. So, you always want to be thinking about not foreclosing future opportunities by creating conditions

that will make it impossible to do the next procedure the patient may need. That's one of the main reasons I'm not a big primary tube shunt guy. Once you stick a tube in the eye, you're starting to foreclose future opportunities for other surgeries.”

A MIGS procedure can be effective even after a failed trabeculectomy or tube shunt.

Although MIGS seem relatively harmless in terms of reducing future options, Dr. Flowers points out that the GATT procedure, which disrupts the entire trabecular meshwork, would eliminate any future possibility of putting a device into Schlemm's canal. “For example, if the Hydrus or future-generation iStents become available and you've already done a GATT, you won't be able to use them,” he says. “That definitely makes me hesitate to choose a MIGS procedure that's going to destroy the trabecular meshwork.”

Dr. Fellman notes that the age of the patient is a double-edged sword. “The longer you've had glaucoma—especially being on drops for decades—the less likely it is that your collector channels will be salvageable,” he says. “You may think you're not going to get much flow through the patient's natural drainage system because they've had the disease for so long. On the other hand, it's a pretty simple thing to add on a trabecular MIGS procedure, and there's very little downside to it; the safety issues are minimal, and every point of IOP reduction you can obtain may be meaningful. Also, if you're thinking about a XEN, older patients may actually do better because they're less likely to scar. It's still unpredictable, but young patients definitely scar

more.” (Dr. Fellman adds that the episcleral venous fluid wave, seen in the operating room as a clue to outflow capacity, is a very helpful hint regarding the postoperative IOP outcome.)

9. Don't abandon MIGS because a previous one didn't work.

“If one MIGS procedure has failed to produce the desired pressure reduction, I'd try a MIGS in a different category,” says Dr. Francis. “For example, if you've done an iStent and it didn't work, I wouldn't abandon MIGS. You could take out the iStent and do a Trabectome or KDB, or use ECP to decrease aqueous production. Or, if you've done a KDB or Trabectome or Goniotome, you could add a CyPass or perform ECP. You just want to try something that works in a different way from what you've already tried.”

10. Don't worry about which medications the patient has been on.

“I don't think it makes a difference which medications the patient has been on,” says Dr. Francis. “The efficacy of drops and surgery can be very different. For example, surgery to reduce aqueous humor production might be far more effective than drops that have that effect.”

Dr. Flowers agrees that the impact of a drop on a given outflow pathway is going to be tiny compared to the impact of a MIGS procedure. “It's not even in the same ballpark,” he says. “A drop might give you a tiny bit of enhanced flow, but even a tiny opening in the ciliary space, for example, will allow a deluge of fluid to pass through compared to what the drop accomplishes. The ultimate issue is how long the outflow pathway stays open.”

11. Avoid using procedures off-label.

“There's more and more data coming out that these procedures are very efficacious as standalone procedures, but from an insurance and surgery-center-logistics perspective, go-

ing off-label is a nightmare,” says Dr. Fellman. “Most patients can’t afford to pay for these procedures. You’re talking about a surgery center bill, an anesthesiologist bill, a surgeon bill and a device bill. That’s going to add up to thousands of dollars.”

Dr. Francis agrees. “Whether or not the patient has visually significant cataracts is very important from a logistics standpoint,” he says. “Some devices, such as the iStent, Hydrus and CyPass, are only FDA-approved for implantation at the time of cataract surgery. There’s no reason these devices wouldn’t work in a pseudophakic patient, but it wouldn’t be on-label because those are only FDA-approved for use with cataract surgery. It’s more of a logistical issue; if you do a procedure off-label, you won’t get paid. That’s not a small consideration for most surgeons. Your insurance claim will be denied and you’ll have to charge the patient cash.”

“Fortunately, a few MIGS procedures are approved for use apart from cataract surgery,” Dr. Fellman adds. “The Dual Blade and Trabectome, for example, are approved for use as standalone procedures, so they can handle those cases that don’t have to be done in combination with phaco.”

12. Remember that a MIGS procedure can be effective even after a failed trabeculectomy or tube. “Following a trabeculectomy, you’ve abandoned the patient’s natural drainage system,” Dr. Fellman points out. “Let’s say you did a trabeculectomy or tube on a phakic patient. Then the patient eventually develops a cataract and the trabeculectomy slowly fails. You could easily do a phaco-iStent, or phaco-Trabectome, or Dual Blade or CyPass. There’s a decent chance that this eye will then end up with a pressure low enough that the patient does OK. In fact, our group has shown that the GATT procedure, which opens up 360 degrees of the trabecular

meshwork and the inner wall of Schlemm’s canal, is very effective in eyes that already had a trabeculectomy or tube.³ In other words, you don’t have to abandon the patient’s natural drainage system because of a prior filtering procedure. You might be able to increase the flow capacity of the patient’s natural drain with MIGS surgery even after a failed tube or trabeculectomy.” (Dr. Francis notes that previous laser trabeculoplasty doesn’t seem to impact the efficacy of MIGS, either.)

Dr. Fellman adds that even a XEN, which shares some characteristics with a trabeculectomy or tube, can work when a trabeculectomy or tube has failed. “We’ve had many patients in that category who now have a successful XEN,” he says. “In this situation you have to make sure the conjunctiva is in adequate shape, meaning that it’s mobile over the area where you’re going to put the XEN. But there’s less trauma to the tissues associated with a XEN than with a trabeculectomy—even using mitomycin-C—and the flow is more standardized through the XEN. Of course,” he adds, “you still have to be a blebologist, and you still have to be able and willing to needle the eye if scarring is more excessive than you anticipated.” **REVIEW**

Dr. Francis is a surgical trainer for NeoMedix and consultant for Glaukos and BVI Endo Optiks; he has received research support from Allergan, InnFocus, Iridex and Ivantis. Dr. Flowers has participated in most of the MIGS clinical trials; he has consulting relationships with Alcon, Glaukos, Ivantis, Sight Sciences and InnFocus. Dr. Fellman is a consultant for Endo Optiks.

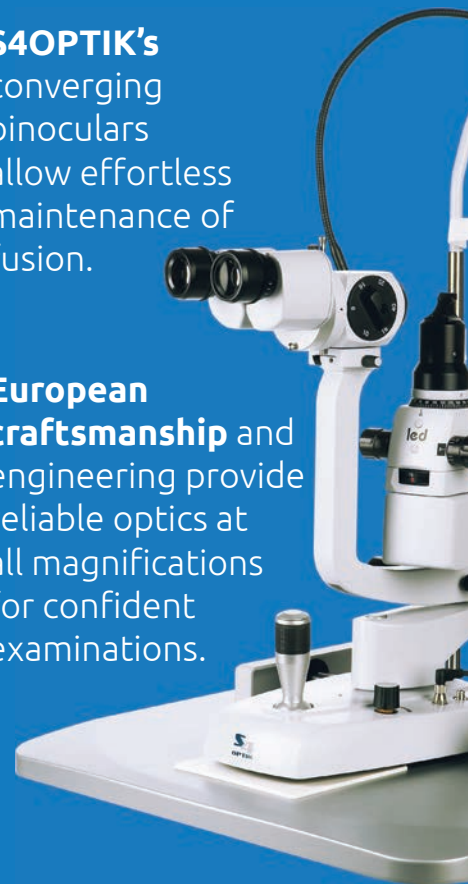1. Emanuel ME, Grover DS, Fellman RL, et al. Micropulse cyclophotocoagulation: Initial results in refractory glaucoma. *J Glaucoma* 2017;26:8:726–729.
2. Vold S, Iqbal IK, Craven ER, et al. Two-year COMPASS trial results: Suprachiliary microstenting with phacoemulsification in patients with open-angle glaucoma and cataracts. *Ophthalmol* 2016;123:10:2103–2112.
3. Grover DS, Godfrey DG, et al. Outcomes of gonioscopy-assisted transluminal trabeculectomy in eyes with prior incisional glaucoma surgery. *Journal of Glaucoma* 2017;26:41–45.

S4OPTIK SLIT LAMPS

SEE MORE - Exceptional Optics

S4OPTIK’s converging binoculars allow effortless maintenance of fusion.

European craftsmanship and engineering provide reliable optics at all magnifications for confident examinations.



Vertical and compact configurations available.

S4OPTIK

250 Cooper Ave., Suite 100 Tonawanda NY 14150

www.s4optik.com | 888-224-6012

Sensible equipment. Well made, well priced.

For today’s modern office.

Can Sustained Release Deliver the Goods?

Michelle Stephenson, Contributing Editor

The hope is that sustained-release glaucoma drugs will overcome compliance challenges.

Drops continue to be the mainstay of glaucoma treatment, even though they are less than ideal. One of the main obstacles to successful glaucoma treatment is lack of patient compliance with drop regimens. Additionally, constant drop instillation takes a toll on the ocular surface. In this article, experts in sustained-release medications, which might help avoid some of drops' problems, discuss the pros and cons of the burgeoning technology.

Several companies are exploring sustained-release delivery of drugs, though none of the devices are currently FDA-approved. "Enhancing adherence to therapy is one significant advantage of sustained-release depots," says Malik Kahook, MD, professor and the Slater Family Chair in Ophthalmology, The University of Colorado School of Medicine in Aurora. "It's widely known that patients fail to take many of the medications prescribed to them, and glaucoma drops are no exception. Having access to a therapy that could deliver drug over a long period of time without reliance on patient dosing would be one way to overcome this issue. Long-term depots may also lessen side effects associated with topical application of drops, which result in significant patient morbidity. Another potential

benefit, which remains unproven, is the possibility of decreasing IOP fluctuations that result from pulsed dosing of drugs, via continuous delivery of drug to targeted tissues. However, it should be noted that some of our best therapeutics, such as prostaglandin analogs, may function better as a pulsed dose rather than a continuous delivery. This may be one reason the various sustained-delivery platforms studied to date have failed to achieve prostaglandin-like efficacy."

One side effect of topical drops is ocular surface disease, including meibomian gland dysfunction. A recent study found that mild to moderate meibomian gland dysfunction is frequently encountered in patients with medically treated glaucoma.¹ This was a cross-sectional analysis that included 70 patients with glaucoma who were on long-term (more than one year) topical hypotensive medications. Meibomian gland dysfunction was defined as the presence of signs consistent with meibomian gland terminal duct obstruction. Dysfunction was categorized between grades 1 and 4 according to clinical severity. The Ocular Surface Disease Index questionnaire was completed at enrollment. Ocular surface tests consisted of tear breakup time, ocular surface staining with lissamine green and Schirmer test with

anesthesia. Additionally, 45 healthy control subjects with no evidence of intraocular or ocular surface disease were included.

Meibomian gland dysfunction was observed in 56 (80 percent) of study participants with glaucoma. Forty-seven patients (67.1 percent) had the obstructive type and nine (12.9 percent) had the atrophic type of meibomian gland dysfunction. Of these 56 cases, 47 (83.9 percent) had signs consistent with mild to moderate meibomian gland dysfunction. The ocular surface test results of patients with glaucoma with meibomian gland dysfunction and those without meibomian gland dysfunction were significantly worse for all parameters, compared with healthy controls. However, there were no significant differences between Ocular Surface Disease Index scores, tear breakup time, lissamine green scores or Schirmer results between patients with glaucoma who did and did not have meibomian gland dysfunction.

Another recent study examined the relationship between ocular surface disease and topical antiglaucoma therapy.² It found that ocular surface disease is more prevalent in patients who use topical glaucoma medications than in patients who don't use them. The main factors impacting ocular surface disease were drops with preservatives, longer treatment duration and older age.

The study included 211 eyes of 211 patients with open-angle glaucoma or ocular hypertension on topical medication. The control group included 51 eyes of 51 healthy age- and gender-matched volunteers. Investigators recorded the IOP-lowering eyedrops used, the number of medications used and daily and cumulative preservative concentrations for each patient. Main outcome measures were fluorescein corneal staining score (Oxford scale), lower tear meniscus height (as measured by spectral-domain optical coherence tomography), noninvasive tear-film breakup time (measured by Oculus Keratograph 5M) and the OSDI questionnaire.

The medication group had significantly higher OSDI scores (median: 10.24 vs. 2.5 in the control group) and corneal staining scores (≥ 1 : 64.93 percent in the medication group vs. 32.61 percent in the control group). Noninvasive tear-film breakup time and lower tear meniscus height were similar between the groups. A higher daily preservative concentration was associated with a lower tear meniscus height.

Sustained-release Options

There are five sustained-release delivery systems targeting glaucoma that are currently under investigation: bimatoprost SR and the bimatoprost ocular insert from Allergan (Dublin, Ireland); iDose from Glaukos Corporation (San Clemente, California); and the OTX-TP and -TIP implants from Ocular Therapeutix (Bedford, Massachusetts).

- **Bimatoprost SR.** Bimatoprost SR is a depot implant



PASSIONATE ABOUT PATIENT CARE?

His sight depends on your confidence.





Ocular Response Analyzer® G3

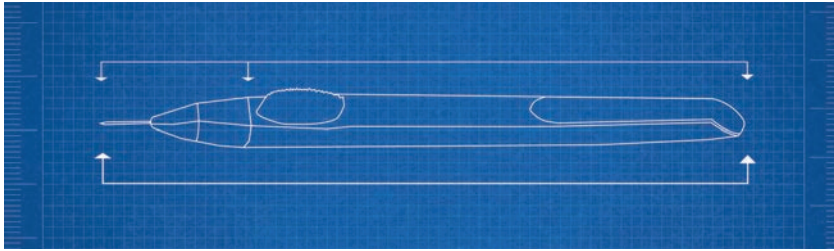
Corneal Hysteresis, a more objective predictor of glaucoma progression. CPT code 92145.

Watch the videos at reichert.com/ora

Reichert
TECHNOLOGIES

AMETEK © 2018 AMETEK, Inc. & Reichert, Inc. (6-2018) · Made in USA

Ocular Response Analyzer is a registered trademark of Reichert, Inc. · www.reichert.com ·    



A diagram of the device used to inject Allergan's bimatoprost SR sustained-release implant. The implant has released the drug for up to six months in trials.

injected into the anterior chamber. In a Phase I/II clinical trial, bimatoprost SR demonstrated favorable efficacy and safety through six months.³ The study included 75 open-angle glaucoma patients who were administered bimatoprost SR (6 µg, 10 µg, 15 µg and 20 µg) intracamerally in the study eye. The fellow eye received topical bimatoprost 0.03% once daily. The primary endpoint was IOP change from baseline.

The investigators found that bimatoprost SR provided rapid, sustained IOP lowering. The overall mean IOP reduction from baseline through week 16 was 7.2, 7.4, 8.1, and 9.5 mmHg with the 6 µg, 10 µg, 15 µg and 20 µg dose strengths of implant, respectively. Topical bimatoprost caused a mean IOP reduction of 8.4 mmHg. Rescue treatment/retreatment wasn't required in 91 percent and 71 percent of study eyes up to week 16 and month 6, respectively. Adverse events in the study eyes usually occurred within two days after the injection procedure and were transient. Conjunctival hyperemia was more common with topical bimatoprost than bimatoprost SR onset later than two days after the injection procedure (17.3 percent vs. 6.7 percent of eyes).

According to E. Randy Craven, MD, FACS, an associate professor at Johns Hopkins' Wilmer Eye Institute, patients' mean pressure at enrollment in the study was just over 23 mmHg, and it dropped to between 16 and 17 mmHg after treatment. "It stayed that way for many months after implanta-

tion for many of the patients," he says. "Safety-wise, patients' main complaint was that their eye was a little irritated on the day of implantation. Despite that irritation, patients tolerated the implant better than they did drops. With bimatoprost SR, there is a lower rate of hyperemia and a lower rate of eyelash growth and irritation on the surface of the eye. So, we have seen pretty encouraging results."

• **Bimatoprost Ocular Ring Insert.** This is a flexible, ring-shaped device that's placed under the upper eyelid into the fornix and then under the lower lid. It's left in place to release clinically effective concentrations of the agent over six months. Phase II results have shown the ring achieves clinically significant reductions in intraocular pressure over a six-month period with what the investigators deemed an acceptable level of safety and tolerability.⁴

Of more than 300 patients who participated in Phase I and II trials, 90 percent or more have said the ring is comfortable, while it achieves an average IOP lowering of 4 to 6 mmHg over six months. Additionally, 88.5 percent of patients retained the rings without assistance for six months, and adverse events were in line with bimatoprost or timolol exposure.

• **iDose Travoprost.** Glaukos' iDose Travoprost implant is filled with a special formulation of travoprost and is designed to continuously elute therapeutic levels of the medication within the eye for extended periods of time. When depleted, the iDose Tra-

voprost can be removed and replaced in a similar subsequent procedure.

A Phase II trial (12-month interim cohort) found that iDose Travoprost achieves a sustained IOP reduction and has a favorable safety profile.⁵ This 154-patient, multicenter, randomized, double-blind trial was designed to evaluate two models of the iDose delivery system with two different travoprost-elution rates, compared to topical timolol ophthalmic solution 0.5%, and with a primary efficacy endpoint of non-inferiority to topical timolol.

This interim cohort includes 74 patients: 49 were implanted with one of the iDose travoprost implant models and 25 patients were in the timolol comparator group. Average IOP reductions observed in this cohort of implant patients during the first 12 months showed that iDose Travoprost achieved an approximate 30-percent reduction in mean IOP compared with baseline IOP. Additionally, the mean number of glaucoma medications ranged from 0.54 to 0.56 at 12 months in the fast and slow iDose Travoprost elution implant groups, respectively, compared to a mean of 0.72 medications in the timolol group. The most recent Phase II data also continued to confirm a favorable safety profile for iDose Travoprost, with no hyperemia reported to date in either elution group.

• **OTX-TP.** Ocular Therapeutix' OTX-TP is administered as an intracanalicular depot through the punctum and is designed to deliver travoprost to the ocular surface for up to 90 days. A phase IIb study including 73 patients at 11 clinical sites in the United States was conducted to assess its efficacy and safety as compared to timolol.⁶

At day 60, which was the primary efficacy measure, the OTX-TP group's mean IOP was lowered by 4.8 mmHg, compared with 6.4 mmHg for the timolol arm. At day 90, the OTX-TP group's IOP had decreased by 5.2

mmHg, compared with an IOP lowering effect of 7.3 mmHg in the timolol arm.

Depots were found to be retained in 91 percent of patients at day 60 and in 88 percent of patients at day 75 when evaluating all patients completing the study through its 90-day duration. Retention was 48 percent at day 90, reflecting the corresponding absorption and clearance of the depots with the duration of drug release.

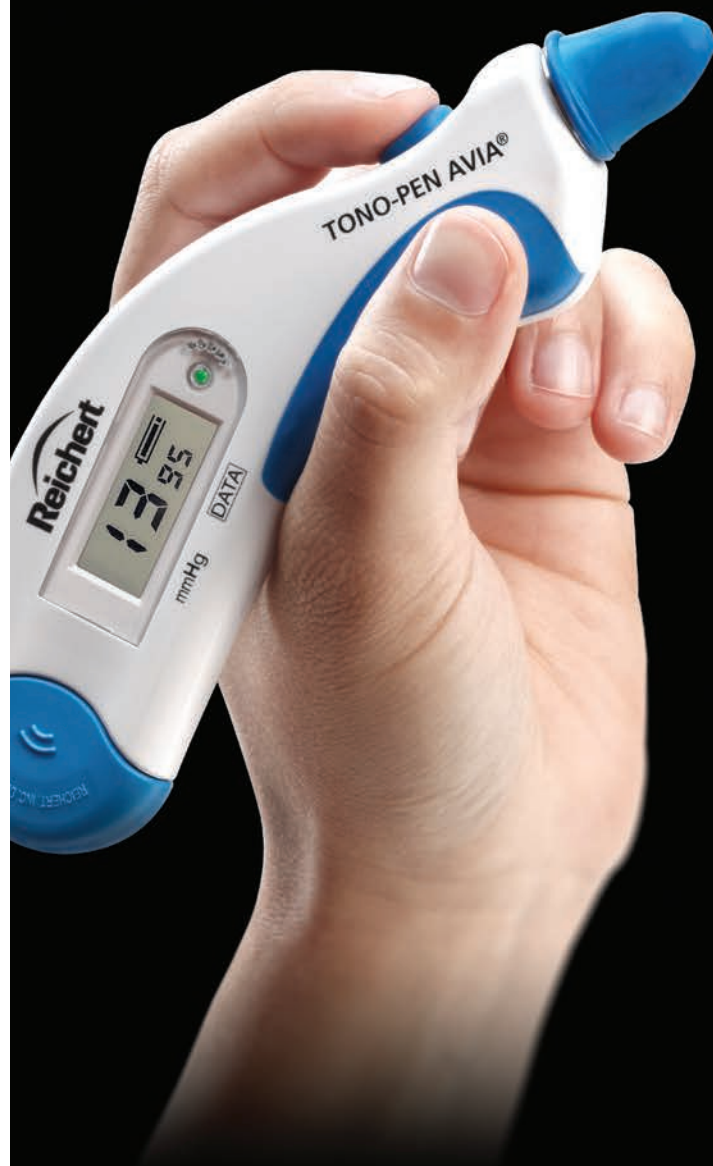• **OTX-TIP.** Recently, Ocular Therapeutix announced the treatment of the first patient in a Phase I, open-label, proof-of-concept clinical trial being conducted in the United States for OTX-TIC, a bioresorbable travoprost implant delivered via an intracameral injection for the reduction of intraocular pressure in patients with glaucoma and ocular hypertension. According to the company, the multicenter, prospective trial will evaluate the safety, efficacy, durability and tolerability of OTX-TIC. The implant is designed to release the drug over a period of four to six months.

Final Thoughts

According to Dr. Kahook, there are several downsides to these delivery systems. “A major disadvantage to some sustained-delivery platforms is increased invasiveness compared to topical therapy,” he says. “Injectables might achieve enhanced adherence for some patients but, at the same time, they can expose them to complications such as infections that aren’t associated with topical therapeutics. The cost/benefit analysis of transitioning patients from topical therapy to more invasive drug depots also requires further contemplation and may present a significant barrier to widespread adoption by both patients and physicians.” Surgeons say this cost barrier could be more significant initially, since the implants might not be covered by insurance immediately after they’re approved. [REVIEW](#)

Dr. Kahook has received patent royalties from Alcon, J&J Vision, New World Medical and IanTech Medical. He receives ownership royalties from Equinox and Ivantis, and he is a consultant for Allergan, Alcon, New World Medical, and Equinox.

1. Uzunosmanoglu E, Mocan MC, Kocabeyoglu S, Karakaya J, Irkec M. Meibomian gland dysfunction in patients receiving long-term glaucoma medications. *Cornea* 2016;35:8:1112-1116.
2. Perez-Bartolome F, Martinez-de-la-Casa JM, Arriola-Villalobos, Fernandez-Perez C, Polo V, Garcia-Fejoo J. Ocular surface disease in patients under topical treatment for glaucoma. *Eur J Ophthalmol* 2017;[Epub ahead of print].
3. Lewis RA, Christie WC, Day DG, et al; Bimatoprost SR Study Group. Bimatoprost sustained-release implants for glaucoma therapy: 6-month study results from a phase I/II clinical trial. *Am J Ophthalmol* 2017;175:137-147.
4. Brandt JD, DuBiner HB, Benza R, et al. Long-term safety and efficacy of a sustained-release bimatoprost ocular ring. *Ophthalmology*. Published online: May 17, 2017.
5. <http://investors.glaukos.com/investors/press-releases/press-release-details/2018/Glaukos-Corporations-iDose-Travoprost-Achieves-Sustained-IOP-Reduction-and-Favorable-Safety-Profile-in-12-Month-Interim-Cohort/default.aspx>. Accessed 21 May 2018.
6. <https://www.biospace.com/article/releases/ocular-therapeutix-s-otx-tp-can-t-match-timolol-in-phase-ii-b-glaucoma-study-/>. Accessed 18 May 2018.



PASSIONATE ABOUT PATIENT CARE?

Clinicians trust Tono-Pen® most.

Tono-Pen AVIA® Handheld Tonometer

Always ready-to-use and calibration-free. Fast, reliable IOP measurements. Technician Friendly.

Watch the video at reichert.com/tonopenavia

Reichert
TECHNOLOGIES

AMETEK® © 2018 AMETEK, Inc. & Reichert, Inc. (6-2018) · Made in USA

Tono-Pen & Tono-Pen AVIA are registered trademarks of Reichert, Inc. · www.reichert.com

IOP Around the Clock: How Close Are We?

Kristine Brennan, Senior Associate Editor

Intraocular
pressure
fluctuates every
day and night.
When will 24-
hour monitoring
inform treatment
decisions?

The burdens glaucoma imposes on patients, families and ophthalmologists continue to increase: The global incidence of open-angle glaucoma is anticipated to reach 65.5 million cases by 2020.¹ Speaking at the recent 2018 American Society of Cataract and Refractive Surgery summit in Washington, D.C., Stanford University's Kuldev Singh, MD, noted that despite variations in the natural history of the disease from patient to patient, individuals are living longer with glaucoma, uniformly increasing the risk of progression to blindness. Lowering a patient's mean IOP is currently the first defense against progression, but a user-friendly, round-the-clock IOP-monitoring system remains just out of reach. Here, experts discuss the state of 24-hour IOP monitoring devices meant for use outside the clinic.

"Considerations include portability, costs, ease of use and accuracy," said Dr. Singh at the ASCRS summit. Two devices with relatively recent FDA approval facilitate home IOP monitoring, each with its own capabilities and limitations. Another internal IOP monitor, CE marked in Europe, may prove to advance the quest for user-friendly monitoring further still. Cost may remain a bar-

rier to out-of-clinic IOP monitoring in medically underserved populations, however, and so a computer scientist has devised a prototype in the hopes of making basic IOP monitoring accessible globally.

The Icare Home

The Icare Home (Icare USA; Raleigh, North Carolina), which gained FDA approval in March of 2017, is a rebound tonometer that doesn't require the user to instill a topical anesthetic. The patient depresses a button, and a small probe with a soft, disposable cover quickly touches the ocular surface before retracting back into the tonometer. Automatic OS/OD recognition and red and green lights guide proper alignment of the device over the eye, and patients can select the device's sequencing to take one reading at a time or a cluster of six in rapid succession. The Icare Home stores data, which health care providers can retrieve using proprietary software.

A 2017 study² compared Icare Home measurements done by 130 glaucoma patients and suspects to measurements done by an ophthalmologist using the device and Goldmann Applanation Tonometry (GAT) measurements done by an

SPARKtacular features in one device



OCULUS Easyfield® C: Fast, Small, Affordable
A complete perimeter with a small footprint

SAVE TIME

SPARK strategy for
threshold perimetry
in 3 minutes

SAVE SPACE

Compact size,
low space requirement

SAVE MONEY

Minimum price,
maximum performance

ophthalmologist. Ninety-eight percent (128/130) of patients were able to use the Icare properly. Mean IOP ranges were 7 to 20 mmHg with GAT; 6 to 24 mmHg with Icare measurements done by the patient, and 6 to 25 mmHg with Icare measurements



done by the ophthalmologist. The mean difference between HOME_p (patient) and HOME_o (ophthalmologist) was 0.21 mmHg ($p=0.068$; paired t-test). The mean difference between the HOME_p and GAT measurements was 0.70 mmHg ($p<0.001$; paired t-test), and between the HOME_o and GAT measurements it was 1.00 mmHg ($p<0.001$; paired t-test).² The investigators found that the Icare Home tonometer demonstrated a tendency to capture higher IOP values than GAT overall, but deemed it feasible for self-monitoring IOP. Another study suggested that patients could use the Icare Home comparably to a specialist and that they found it acceptable to use.³

“That [latter] study assessed patient acceptability of using self-tonometry,” says Kaweh Mansouri, MD, MPH, who practices at the Glaucoma Centre, Montchoisi Clinic, Lausanne, Switzerland, and serves as an adjunct associate professor at University Colorado-Denver. “They found that most patients were happy to use this device themselves, and that the measurements they obtained were similar to what the physician would measure using the same device.”

Dr. Mansouri acknowledges that the Icare is limited by the patient’s activities and wakefulness. “The Icare measures IOP in snapshots. It’s not continuous, and it doesn’t measure IOP while the patient is asleep, or during different activities,” he notes.

Steven L. Mansberger, MD, MPH, vice chair and director of the glaucoma service at Legacy Devers Eye Institute in Portland, Oregon, doesn’t think evidence of the Icare Home’s therapeutic value

is compelling enough for him to recommend it to patients at this time. “The Icare device is validated in some ways, but in other ways, we don’t really understand how it corresponds with glaucoma,” he says. “It doesn’t really fully assess the risk factor of intraocular pressure, meaning that it doesn’t check it at night. It doesn’t check it when the patient is lying supine. It doesn’t allow pressure measurements during normal activities like showering or exercise or things like that. So it’s unclear how the device itself really represents this risk factor that we call ‘elevated intraocular pressure.’ If patients check their pressure three or four times a day, how much value does that add? That’s what we really haven’t been able to figure out,” he notes.

The Icare Home that’s commercially available in the United States stores data internally, so patients aren’t able to see their IOP readings. At ASCRS this spring, Dr. Singh opined that this is an important consideration if you’re going to integrate round-the-clock IOP monitoring into your practice. “Make sure you have control of the data, or the patient may become overly fixated on data,” he said. “Patients fixate on IOP and

not vision; and they over-fixate on IOP.”

“People can get neurotic about their pressures,” Dr. Mansberger concurs. “To paraphrase a noted glaucoma specialist, ‘Ask not what your pressure is, but ask how your optic nerve or your visual field looks.’ It could be that variability in pressure is a normal physiologic phenomenon that has nothing to do with glaucoma’s progression,” he observes, although he adds that home monitoring of IOP could encourage people to make lifestyle changes that may help control their glaucoma, just as home glucose monitoring can encourage patients with diabetes to take better care of their health.

Triggerfish CLS

The Triggerfish contact lens sensor (Sensimed AG; Lausanne, Switzerland) consists of a soft, single-use contact lens available in three base curves (8.4, 8.7, and 9 mm), measuring 14.1 mm in diameter and 585 μm thick in the central zone. The lens incorporates two strain gauges, a microprocessor, and single-use adhesive that fits around the patient’s orbit and holds a receiver antenna. There’s also a disposable recorder sleeve for the microprocessor. Intended to be worn for up to 24 hours at a time, the Triggerfish lens has a telemetric sensor that takes 30 seconds of readings at five-minute intervals over each 24-hour period of wear.

Unlike the Icare Home, the Triggerfish passively records data while the patient performs waking activities or sleeps. Importantly, it’s not an IOP monitor in the strict sense of the term: The FDA approved the Triggerfish as a diurnal pattern recorder in 2017. It captures IOP fluctuations in millivolts, rather than measuring absolute IOP in millimeters of mercury.

“The Icare measures IOP in abso-

new!

thera
tears®

EXTRA



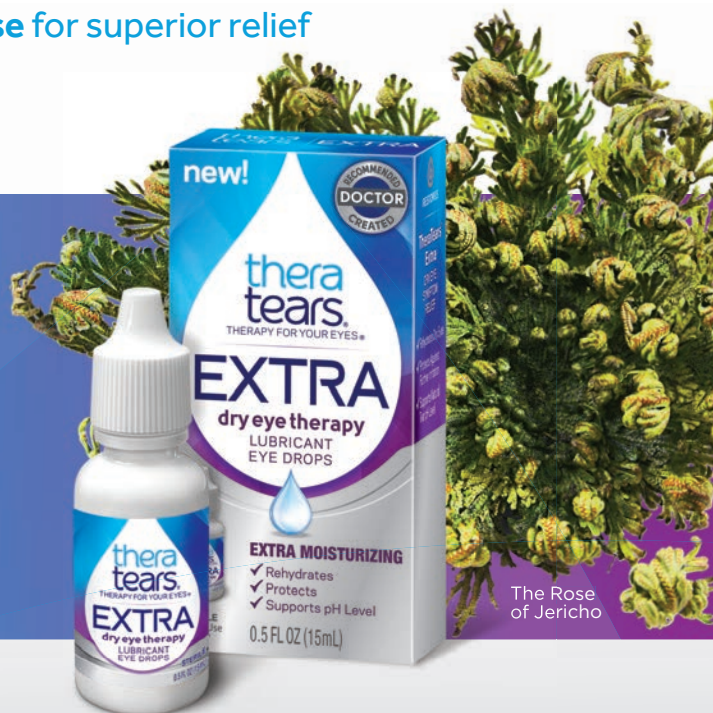HARNESS EXTRA POWER FROM A NATURAL WONDER

NEW TheraTears® Extra Dry Eye Therapy
is enhanced with trehalose for superior relief

Trehalose is a natural disaccharide found in plants with moisture retention properties that help organisms survive in absence of water. In ophthalmic products, trehalose enhances active ingredients to help:

- Protect corneal cells from desiccation
- Restore osmotic balance to the ocular surface
- Maintain the homeostasis of corneal cells

-2017 DEWS II Report



The Rose of Jericho

Learn about our complete line of
dry eye therapy products at theratears.com

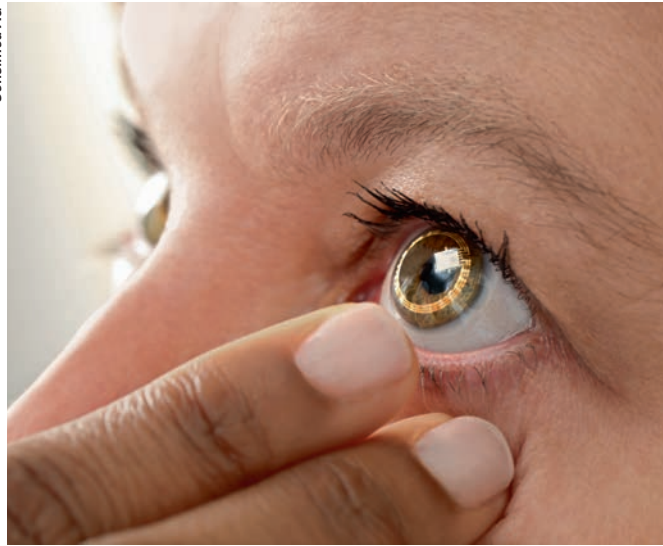Reference: 1. Jones L, Downie L, Korb D, et al. TFOS Dews II Management and Therapy Report. The Ocular Surface Jul 2017; 575-628.
© 2018 Akorn Consumer Health | A Division of Akorn, Inc. | M17-047

lute values, while the Triggerfish measures different parameters, of which IOP is one,” explains Dr. Mansouri. “The Triggerfish measures strain differences. You could also call it ‘strain tonometry.’ Strain differences, which the Triggerfish measures, reflect changes in IOP, but also changes in intraocular volume; and they reflect ocular elasticity and the rigidity of the globe. All three of these are included in the Triggerfish signal. And rather than millimeters of mercury, they are relative values. So you cannot compare them one to

one with conventional tonometry. This may be both a disadvantage and an advantage. The disadvantage is, of course, that you can’t obtain the standard units of tonometry. The advantage is that these other factors that the Triggerfish measures—these strain-related factors—may be a more accurate reflection of any given eye’s susceptibility to glaucomatous damage,” he says.

Dr. Mansouri cites a study⁴ that showed how the IOP-related measurements that the Triggerfish collected correlated with glaucoma’s progression in a group of patients with treated disease—a correlation that could help ophthalmologists identify patients in need of ongoing enhanced monitoring. “This study showed that the Triggerfish signal was related to patient progression, meaning that one session of Triggerfish monitoring could help predict which patients might be at risk for having fast glaucoma progression in the future,” he says. “The study points to the fact that it probably measures more than just IOP, and that these measurements may be a more accurate reflection of the sus-

Sensimed AG



The Triggerfish contact lens sensor, shown here without the receiver taped around the orbit, has tiny strain gauges and telemetry circuits embedded inside.

ceptibility of an eye to suffer from glaucomatous progression in the future.”

Because patients don’t have to stop their activities to take a reading while wearing the Triggerfish, the data it collects may reveal associations between IOP spikes and certain activities and postures. Dr. Mansberger cites the work of J. Crawford Downs, PhD, and colleagues on the continuous telemetric IOP monitoring of rhesus macaques^{5,6} as evidence that blinking and circadian rhythms cause IOP fluctuation, and that postural changes may have significant and persistent effects on IOP in humans. “They show that with a blink reflex, the pressure goes high; with sleep, the pressure becomes really stable. Activity creates lots of variability in the pressures. From his data, it suggests that it’s common for eye pressure to fluctuate quite widely,” he says.

Dr. Mansouri, who uses the Triggerfish for short-term round-the-clock monitoring of patients, relates how the contact lens sensor’s tracking of IOP fluctuations in the course of different activities can influence

patient behavior. “One patient would practice yoga, including head-stand positions,” he recalls, “and we’d measure the IOP around the clock with the Triggerfish. You could see how the values just skyrocketed when that patient assumed specific yoga positions. Based on that, it was easier to say, ‘Maybe you should refrain from those specific positions where you know your IOP will become elevated,’” he says.

Another study of head-down yoga poses and continuous IOP

monitoring also suggests that these postures induce IOP spikes, so ophthalmologists might consider recommending against their performance in certain patients.⁷ Dr. Mansouri says that the Triggerfish and the Icare might both help influence behavior in patients who’ve been progressing despite normal in-clinic values. “Glaucoma is very abstract,” he says. “Patients don’t see anything. They don’t see their visual fields or atrophy getting worse. Aside from measuring IOP itself and knowing how IOP behaves, it’s very abstract. These tools can help the patient to remain adherent. The less abstract we can make the disease, the better for adherence. One way of doing so is to empower patients by allowing them to obtain IOP measurements, or by allowing them to have a look at their IOP measurements.”

Dr. Mansberger notes that the Triggerfish is not very user-friendly. “The Triggerfish is tough,” he says. “It’s not too comfortable. The patient has to wear something almost like a probe with electrodes coming out of it above their eye. It’s not very comfortable; it’s not very attractive.

You can't use it for very long because of irritation from the contact lens," he says. Reported adverse events associated with wearing the Triggerfish contact lens sensor include corneal epithelial defects, conjunctival erythema and pain, although these resolved soon after discontinuation of use.⁸

The Eyemate

The Eyemate (Implandata; Hannover, Germany), CE-certified in 2017 for commercial use in the European Union, is an implantable device intended for continuous, long-term IOP monitoring. A flexible, ring-shaped sensor 12 mm in diameter is designed for sulcus implantation at the time of cataract surgery through the surgical incision. Seated in front of the intraocular lens and behind the iris, the device doesn't impede vision and remains inconspicuous, according to the manufacturer. The other component of the Eyemate is a small handheld mesograph that telemetrically reads IOP when the patient holds it close to the implanted eye. The mesograph displays IOP measurements and stores them. When fitted with a GSM module, the Eyemate can also transfer measurements to an Internet database to share round-the-clock records with the ophthalmologist.

Dr. Mansouri currently uses the Eyemate for research purposes. He says that the underlying concept is simple. "The company took sensors used in the automobile industry in Germany to measure tire pressure. They miniaturized those for implantation in front of an IOL in the sulcus," he explains.

"Two big studies have been conducted showing that the device was safe during surgery and over the long term," he continues. "The company has about five years of data showing that the device stays in the eye, is well tolerated, and is safe over the long term. The other question was whether it would measure IOP in a comparable manner to tonometry, and those studies essentially showed that the measurements were accurate. Sometimes there were discrepancies, for which they don't always have an explanation, between the device and Goldmann applanation."

The Eyemate is CE-marked and cleared for commercialization in the EU; and Dr. Mansouri, who consults for the company, hopes it will become available on the market soon. "It is being used in clinical trials with several select research centers primarily in Europe, and hopefully in the future, in other parts of the world as well," he says.

A Low-Cost Concept

At Florida International University, S.S. Iyengar, PhD, Ryder Professor of Computer Science and direc-



NuLids™ transformational dry eye therapy

Transforms your patients' lives



Finally... A doctor-directed at-home treatment for dry eye disease that is safe, effective and easy to use.

A multi-center study¹ showed:

- 50% decrease in dry eye symptoms
- 65% improvement in TBUT
- 80% increase in meibomian glands yielding liquid secretions.

For more information visit www.NuSightMedical.com or call us at 833-468-5437

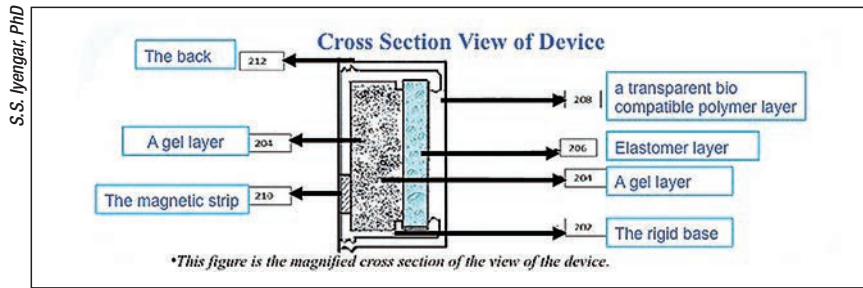


¹ Schanzlin, Olkowski, Coble, Gross. NuLids II Study, April 2018



NuLids™

Doctor prescribed, at-home dry eye relief



Cross section of Dr. Iyengar's intraocular IOP-monitoring device, which is made of elastomer and gel layers on a rigid base. The elastic layers expand across a fixed background to produce color change as IOP increases.

tor of computer and information science, is seeking investors to test and refine a color-changing IOP monitoring chip that sits between the cornea and the inferior iris, implanted through a minor incision. The as-yet unnamed device consists of two pieces: the implant, which is 1 mm tall, 2 mm long, and 1 mm deep; and a handheld binocular viewing device weighing 10 oz. The chip, made of elastomers and an inner hydrogel layer, is visible up close in the eye and appears to change color in response to intraocular pressure changes.

"Presently there are many methods of measuring intraocular pressure, but this is an implantable device with pressure sensors based on electrical resistance," says Dr. Iyengar. He believes that his user-friendly device could be produced very cheaply. "The pattern in one diffraction grating will change due to the interference effect of light," he explains. "The pattern is a hologram that changes to contrast with the background pattern and the rigid base, which remains constant. A perceived color change serves to indicate changes in the IOP level." The viewer and chip need no outside energy source. The viewer consists of magnifiers and mirrors, and a color key that lets patients grade their IOP level. When the chip appears blue, the patient's IOP is acceptable; magenta means caution; red means that pressure is unacceptably high and the patient should seek ophthalmic care.

Like the Triggerfish lens, this intraocular sensor doesn't measure absolute IOP. Blue color represents zero; color changes indicate gradations of IOP, theoretically allowing patients at risk of glaucoma to know at a glance when to seek medical attention. Dr. Iyengar says that established glaucoma patients could determine how well their current treatment regimen is working to stabilize their IOP. He wants to further refine his invention, however. "We have very broad levels of distinction of IOP now, indicating the best, the baseline and the worst IOPs. In order to become more precise, what we really want to do is make 150 to 200 of these devices to test in rabbits, eventually leading to very precise readings as to what level we can consider the threshold that reaches glaucoma," he says. Dr. Iyengar would also like to develop the device as a contact lens.

"I'm not interested in making money," he adds. "I'm originally from India. I saw a lot of people get glaucoma and by the time they reached about 45 or 50 years old, they lost their eyesight. That was a really strong motivator to come up with something. I came up with this idea with a few friends and tested it. I've spent around \$10,000 to \$15,000 of my own money so far to get the U.S. patent. Now I'm looking for some investors. My goal is to help financially disadvantaged people everywhere in the world by donating the technolo-

gy. I'm very passionate about this because I want to give back to economically disadvantaged people who lose their productive lives to glaucoma."

How to Use IOP Data?

An ideal round-the-clock IOP monitoring system would be accurate, convenient, easy to use, easily standardized, and low- to no-maintenance. While our current technologies hold great promise, experts say that nothing commercially available checks all of the boxes yet. "The Holy Grail is an implantable monitoring system, and we're close," said Dr. Singh at the ASCRS meeting, adding that an implantable transducer-based system could detect "under-the-radar action" of IOP fluctuations frequently missed during sleep or at night. Researchers have been looking for this since their findings have suggested that even glaucomatous eyes with normal in-office IOP measurements are subject to fluctuations in IOP, and that these appear to be independent risk factors in disease progression.⁹

"There are companies that are working on implantable devices to measure IOP continuously," Dr. Mansberger says. "I still think the jury's out about how much it adds. But from an epidemiology perspective, it would seem that having a more comprehensive assessment of intraocular pressure would be important and valuable," he says.

"In glaucoma, it is wholly insufficient to have one daytime IOP reading every three or six months," says Dr. Mansouri. "But unfortunately, there is no longitudinal study that looks at the impact of round-the-clock or day and nighttime IOP measurements and their impact on lowering rates of progression and controlling glaucoma. This is something insurance companies will ask for before they provide adequate re-

imburement: They're going to ask for socioeconomic data on the usefulness of these values; and that's really up to us in the medical community and manufacturers to provide."

Dr. Mansouri already uses the Icare Home and the Triggerfish with his patients, and says that both devices have helped him with clinical decision-making. "Using both methods has helped some patients to identify whether peak IOPs occurred in the daytime or nighttime. Sometimes, having a more accurate view of the patient's circadian IOP rhythm can help us make a better choice about drugs or about the timing of drop application. In some patients, it has given us more data to decide to go into surgery, rather than continuing to change the IOP-lowering drop regimen," he says. "More importantly, we empower patients by giving them either the possibility of obtaining the measurements themselves, or of viewing the data with us to get a visual look at the IOP, helping to make glaucoma a less-abstract disease. This can improve adherence to topical medications."

Dr. Mansberger, who currently doesn't use round-the-clock IOP monitoring outside the clinic with his patients, points out that while many ophthalmologists believe these technologies are important, they don't yet definitively know how to use the data they obtain. "The question is, how much does self-monitoring IOP improve care, prevent blindness or prevent glaucoma's progression?" he asks. "We don't have any verdict on that. There are just so many unknown factors in glaucoma." **REVIEW**

Dr. Mansouri is a consultant for Implants and Sensimed AG. Dr. Mansberger reports no financial interests relevant to this article. Dr. Iyengar holds the patent for his device, and can be contacted at iyengar@cis.fu.edu.

1. Kapetanakis W, Chang MP, Foster PJ, et al. Global variations and time trends in the prevalence of primary open angle glaucoma (POAG): A systematic review and meta-analysis. *Br J Ophthalmol* 2016;100: 86-93.
2. Takagi D, Sawada A, Yamamoto T. Evaluation of a new rebound self-tonometer, Icare HOME: Comparison with Goldmann applanation tonometer. *J Glaucoma* 2017;26:7:613-18.
3. Pronin S, Brown L, Megaw R, Tatham A. Measurement of intraocular pressure by patients with glaucoma. *JAMA Ophthalmol* 2017;135:10:1-7
4. De Moraes CG, Jasiem JV, Simon-Zoula S, et al. Visual field change and 24-hour IOP-related profile with a contact lens sensor in treated glaucoma patients. *Ophthalmology* 2016;123:4:744-53.
5. Downs JC, Burgoyne CF, Seigfried WP, et al. 24-hour IOP telemetry in the nonhuman primate: Implant system performance and initial characterization of IOP at multiple timescales. *Invest Ophthalmol Vis Sci* 2011;52:10:7365-7375.
6. Turner DC, Samuels BC, Huisingh C, Girkin CA, Downs JC. The magnitude and time course of IOP change in response to body position change in nonhuman primates measured using continuous IOP telemetry. *Invest Ophthalmol Vis Sci* 2017;58:14:6232-6240.
7. Jasiem JV, Jonas JB, de Moraes CG, Ritch R. Intraocular pressure rise in subjects with and without glaucoma during four common yoga positions. *Plos One* 2015; <https://doi.org/10.1371/journal.pone.0144505>
8. Dunbar GE, Shen BY, Aref AA. The Sensimed Triggerfish contact lens sensor: efficacy, safety, and patient perceptions. *Clin Ophthalmol* 2017;11:875-882.
9. Asrani S, Zeimer R, Wilensky J, Gieser D, Vitale S, Lindenmuth K. Large diurnal fluctuations in intraocular pressure are an independent risk factor in patients with glaucoma. *J Glaucoma* 2000;9:2:134-42.

NuLids™ transformational dry eye therapy

Transforms your practice

The NuLids System helps reduce patient out-of-pocket expenses while creating an additional revenue stream for the practice – all without impacting overhead costs or disrupting other in-office treatments.

A multi-center study¹ showed 95% were satisfied or very satisfied with the treatment.

For more information visit
www.NuSightMedical.com
or call us at 833-468-5437

¹ Schanzlin, Olkowski, Coble, Gross. NuLids II Study, April 2018



NuLids™

Doctor prescribed, at-home dry eye relief

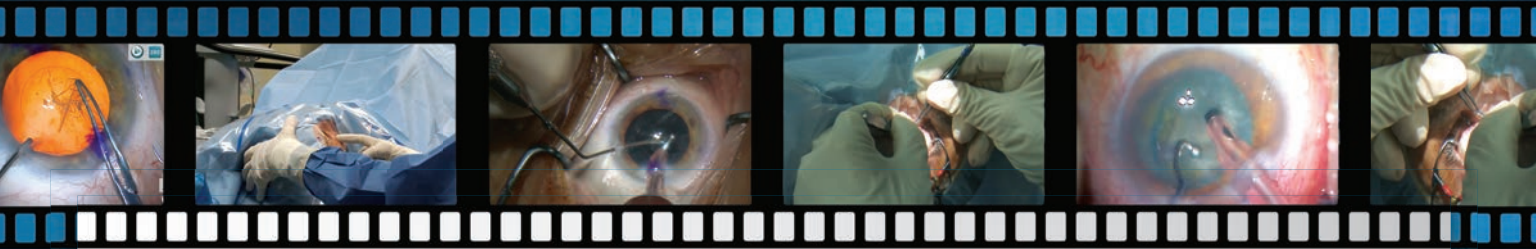




Monthly

MACKOOL ONLINE CME

CME SERIES | SURGICAL VIDEOS



To view CME video
go to:

www.MackoolOnlineCME.com

Episode 30: “Dense Nucleus with Pseudoexfoliation”

Surgical Video by:
Richard J. Mackool, MD

Video Overview:

In this case I demonstrate techniques used to remove a dense nucleus in an eye with pseudoexfoliation. Signs of Infusion Misdirection Syndrome and methods to protect the posterior capsule when this problem exists are also presented.

MackoolOnlineCME.com MONTHLY Video Series



Richard J. Mackool, MD

Welcome to the third year of Mackool Online CME! With the generous support of several ophthalmic companies, I am honored to have our viewers join me in the operating room as I demonstrate the technology and techniques that I have found to be most valuable, and that I hope are helpful to many of my colleagues. We continue to edit the videos only to either change camera perspective or to reduce down time - allowing you to observe every step of the procedure.

As before, one new surgical video will be released monthly, and physicians may earn CME credits or just observe the case. New viewers are able to obtain additional CME credit by reviewing previous videos that are located in our archives.

I thank the many surgeons who have told us that they have found our CME program to be interesting and instructive; I appreciate your comments, suggestions and questions. Thanks again for joining us on Mackool Online CME.



CME Accredited Surgical Training Videos Now Available Online: www.MackoolOnlineCME.com

Richard Mackool, MD, a world renowned anterior segment ophthalmic microsurgeon, has assembled a web-based video collection of surgical cases that encompass both routine and challenging cases, demonstrating both familiar and potentially unfamiliar surgical techniques using a variety of instrumentation and settings.

This educational activity aims to present a series of Dr. Mackool's surgical videos, carefully selected to address the specific learning objectives of this activity, with the goal of making surgical training available as needed online for surgeons motivated to improve or expand their surgical repertoire.

Learning Objective:

After completion of this educational activity, participants should be able to:

- Demonstrate techniques used to remove a dense nucleus in an eye with pseudoexfoliation
- Recognize signs of Infusion Misdirection Syndrome and methods to protect the posterior capsule when this problem exists

Satisfactory Completion - Learners must pass a post-test and complete an evaluation form to receive a certificate of completion. Your chosen sessions must be attended in their entirety. Partial credit of individual sessions is not available. If you are seeking continuing education credit for a specialty not listed below, it is your responsibility to contact your licensing/certification board to determine course eligibility for your licensing/certification requirement.



JOINTLY ACCREDITED PROVIDER™
INTERPROFESSIONAL CONTINUING EDUCATION

Physicians - In support of improving patient care, this activity has been planned and implemented by Amedco LLC and Postgraduate Healthcare Education. Amedco LLC is jointly accredited by the Accreditation Council for Continuing Medical Education (ACCME), the Accreditation Council for Pharmacy Education (ACPE), and the American Nurses Credentialing Center (ANCC), to provide continuing education for the healthcare team

Credit Designation Statement - Amedco designates this live activity for a maximum of .25 AMA PRA Category 1 Credits™. Physicians should claim only the credit commensurate with the extent of their participation in the activity.

Endorsed by:

Review of Ophthalmology®

Video and Web Production by:
JR Snowdon, Inc

Jointly provided by:

AMEDCO & PHE

Supported by an unrestricted independent
medical educational grant from:

Alcon

Additionally Supported by:

**Glaukos
MST
Crestpoint Management
Carl Zeiss Meditec**



Shutting the Door on Epithelial Ingrowth

Surgeons share when to watch and wait, and when to do something about ingrowth under the flap.

Kristine Brennan, Senior Associate Editor

Epithelial ingrowth may prove benign or become a real threat to good vision. Decisions about when and how to spring into therapeutic action are multifactorial, and there are several potential modalities from which to choose. Here, surgeons share their insights on when to intervene, and their preferred methods of banishing—and keeping out—epithelial ingrowth.

Jeffery J. Machat, MD, FRCSC, DABO, medical director of Nvision Eye Centers in Toronto and San Francisco, notes that surgeons saw much more epithelial ingrowth in the days of mechanical flaps than they do now. “Today, with femto-second laser-created flaps, the incidence is about one-tenth what it used to be, or around 0.2 percent,” he says. “Most mechanical flaps are created with a blade with an angle of 26 degrees, as opposed to a more perpendicular side cut created with a femtosecond laser, usually about 75 to 110 degrees. This difference in architecture makes it far more difficult for epithelial cells to enter the interface of a femtosecond laser flap.”

Another reason that epithelial cells infiltrate femto-created flaps less often, according to Dr. Machat, is their firmer adhesion over time, although late enhancements still increase the risk. “If one performs an enhancement at 18 months or longer, then the risk of epithelial ingrowth will increase once again,” he explains. “For this reason, many surgeons have turned to PRK on the surface of the flap, to creating a side cut and then lifting the flap, or to cutting an entirely new flap.”

Bennie H. Jeng, MD, professor and chair of the Department of Ophthalmology and Visual Sciences at the University of Maryland School of Medicine, adds that LASIK flaps relifted and dislodged by trauma are another cause of ingrowth. “There are two main circumstances where we see epithelial ingrowth: One is after re-treatment; the other is after some traumatic event to the flap, where the patient is poked in the eye or something like that as late as 10 years or longer post LASIK. However it happens, if you relift the flap and put it back down, you’ll have a higher incidence of epithelial

ingrowth,” he says.

When to Treat

“The first thing to understand is that epithelial ingrowth will typically be noted at the slit lamp between one week and one month,” says Dr. Machat. One way to stage epithelial ingrowth is with Dr. Machat’s own grading scale, which ranks it from Grades 1 to 3.¹ “If it is what I term Grade 1 ingrowth, you’ll simply see cells within 1 to 2 mm of the flap edge. As long as there’s a demarcation line, an area of scarring at the anterior edge of the epithelium, then we know that the epithelium will not grow any further. Grade 1 is usually just a very flat layer of epithelial cells that are noted incidentally near the flap edge. They just don’t progress, and no treatment is indicated,” he says. Grade 3 describes gray, necrotic geographic ingrowth and flap changes that include melting.

“You don’t go after it just because it’s there,” says Dr. Jeng. Let’s say somebody had LASIK redone about two years ago; they come in for

REVIEW | Refractive/Cataract Rundown

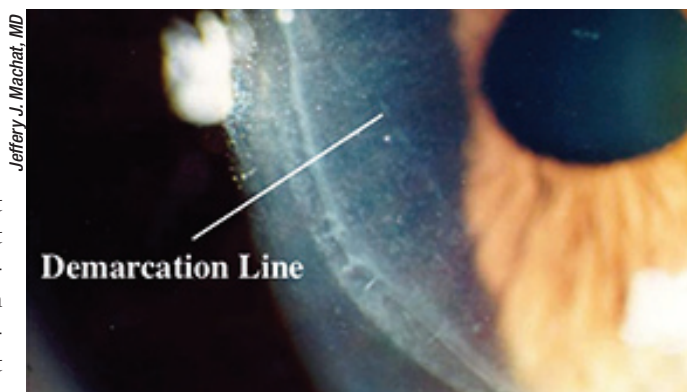
follow-up and they have epithelial ingrowth. I might see them about three months later to make sure it hasn't moved. I'll also take a picture of it. But if it's not causing any visual symptoms, then I don't do anything. If it is extensive, or if it enters into the visual axis, then obviously it's become a problem. If it's progressing, or if it's causing some overlying flap melting, then you have to lift it," he says.

"Indications for treatment are: a symptomatic patient; a raised flap edge that is causing a foreign-body sensation; distortion of visual acuity; encroachment on the visual axis; induction of astigmatism, and asymmetrical glare," says Dr. Machat. He warns that there are clear signs that demand immediate treatment. Grade 2 ingrowth "is where there is no demarcation line, and it looks like there's a little peninsula of cells that comes in from the flap-edge margin. Often, the cells are vacuolated. They start to have a geographic appearance, almost like map dot dystrophy. These dead epithelial cells are the reason surgeons worry about epithelial ingrowth: They contain collagenase, which can then melt the corneal flap. So progressive ingrowth with no demarcation line, elevation of the flap edge, induced cylinder, changes on topography, dry spots, symptomatic glare, or necrotic cells should be treated on an urgent basis."

Lift, Scrape, Seal

Once you've decided to treat, Dr. Machat and Dr. Jeng emphasize the importance of getting rid of all the cells and then approximating and

securely re-sealing the flap to prevent their return. If you spot it early enough, says Dr. Machat, treatment can be very simple. "Sometimes, if it's very minimal at the flap edge and you see necrotic cells, you can take a Sinskey-type spatula right at the slit lamp and just get those cells out from underneath the edge, and then use a dry spear and approximate the flap without taking the patient back to the laser suite. "It's a nice technique because you can directly visualize what you're doing through the slit lamp.



A rolled LASIK flap edge can result from untreated epithelial cell ingrowth that advances in a line. Even after the ingrowth is treated, the change in flap architecture leaves a path for cells to re-enter.

However, you have to have a cooperative and steady patient."

More often, however, "Treatment involves lifting the flap and scraping both the bed and the under-surface of the flap," Dr. Machat continues. "I use a 64 Beaver blade (Beaver-Visitec; Waltham, Massachusetts), followed by dry surgical spears with copious irrigation," says Dr. Machat. "Some surgeons will use PTK. In a dark room, epithelial cells will light up, and they should just do 5 μm [of PTK depth]. The key is to recognize whether the edges of the flap realign tightly," he stresses. "If there is a rolled edge or a scalloped edge from corneal melt, a recurrence of epithelial ingrowth is far more likely. In these cases, tissue glue can be used; so can interrupted

sutures."

In addition to carefully debriding both the stromal bed and underside of the flap to get rid of all the cells, Dr. Jeng emphasizes that it's critical to find their source. "You really want to see where these cells are coming in; generally they're coming in from just one area under the flap. You have to look for that very carefully at the slit lamp. The key after doing this is that you have to suture the flap down: You have to—for sure—put a suture where the epithelium was coming in. I generally also do a few more around the flap," he says. "If you do it right, the cells won't come back. I really think that suturing it down is the main thing you have to consider; all the rest is sort of an adjunct."

Although fibrin glue has also produced good results preventing significant recurrence of epithelial ingrowth in post-LASIK eyes after debridement,² Dr. Jeng doesn't use it to seal out the cells. "I think suturing is better," he says. "I think a lot of people like the adhesive because it's easy to use. But the tradeoff for easy is that it's also easy for it to dislodge. If it doesn't hold for long enough, you can still get ingrowth underneath. Adhesive is also very expensive."

As an alternative to flap relift and debridement, some surgeons use a neodymium:YAG laser to eliminate symptomatic epithelial ingrowth after LASIK. YAG (0.6 to 0.8 mJ) photodisruption has been shown to significantly improve UCVA and astigmatism symptoms and topography in phakic, post-LASIK retreatment eyes with Grade 2 to 3 ingrowth affecting visual acuity.³

"Some surgeons, if they see an ep-



SAVE THESE DATES



3RD YEAR RESIDENT PROGRAMS & WET LAB

Dear CSE 3rd-Year Resident Program Director and Coordinator,

We would like to invite you to review the upcoming 3rd-Year Ophthalmology Resident Programs and Wet Lab for 2018 in Fort Worth, Texas. The programs offer a unique educational opportunity for third-year residents by providing the chance to meet and exchange ideas with some of the most respected thought leaders in ophthalmology. The programs are designed to provide your residents with a state-of-the-art didactic and wet lab experience. The programs also serve as an opportunity for your residents to network with residents from other programs.

After reviewing the material, it is our hope that you will select and encourage your residents to attend one of these educational activities, which are CME accredited to ensure fair balance.

Best regards,
Kendall Donaldson, MD, Yousuf Khalifa, MD, and Mitch Weikert, MD
(Course Directors)



Third-Year Resident Wet Lab Programs 2018:

August 10-11
Fort Worth, TX
Course Director:
Yousuf Khalifa, MD

August 17-18
~~Meeting is Full~~
Course Director:
Kendall Donaldson, MD

September 21-22
~~Meeting is Full~~
Course Director:
Mitch Weikert, MD

LIMITED SPACE
REGISTER NOW

REGISTER FOR
WAIT LIST

REGISTER FOR
WAIT LIST

www.revophth.com/ResEdu2018

For more information: Visit the registration site above or
Email: dholmes@postgradhealthed.com • Call: Denette Holmes 866-627-0714

Courses are restricted to US-based 3rd-year residents enrolled in a US-based ophthalmology resident program and within their third year at the time of the course. There is no registration fee for these activities. Air, ground transportation in Fort Worth, hotel accommodations and modest meals will be provided through an educational scholarship for qualified participants.

Satisfactory Completion - Learners must complete an evaluation form to receive a certificate of completion. Your chosen sessions must be attended in their entirety. Partial credit of individual sessions is not available. If you are seeking continuing education credit for a specialty not listed below, it is your responsibility to contact your licensing/certification board to determine course eligibility for your licensing/certification requirement.



Physicians - In support of improving patient care, this activity has been planned and implemented by Amedco LLC and Postgraduate Healthcare Education. Amedco LLC is jointly accredited by the Accreditation Council for Continuing Medical Education (ACCME), the Accreditation Council for Pharmacy Education (ACPE), and the American Nurses Credentialing Center (ANCC), to provide continuing education for the healthcare team

JOINTLY ACCREDITED PROVIDER™
INTERPROFESSIONAL CONTINUING EDUCATION

Credit Designation Statement - Amedco designates this live activity for *AMA PRA Category 1 Credits™*. Physicians should claim only the credit commensurate with the extent of their participation in the activity.

Endorsed by:

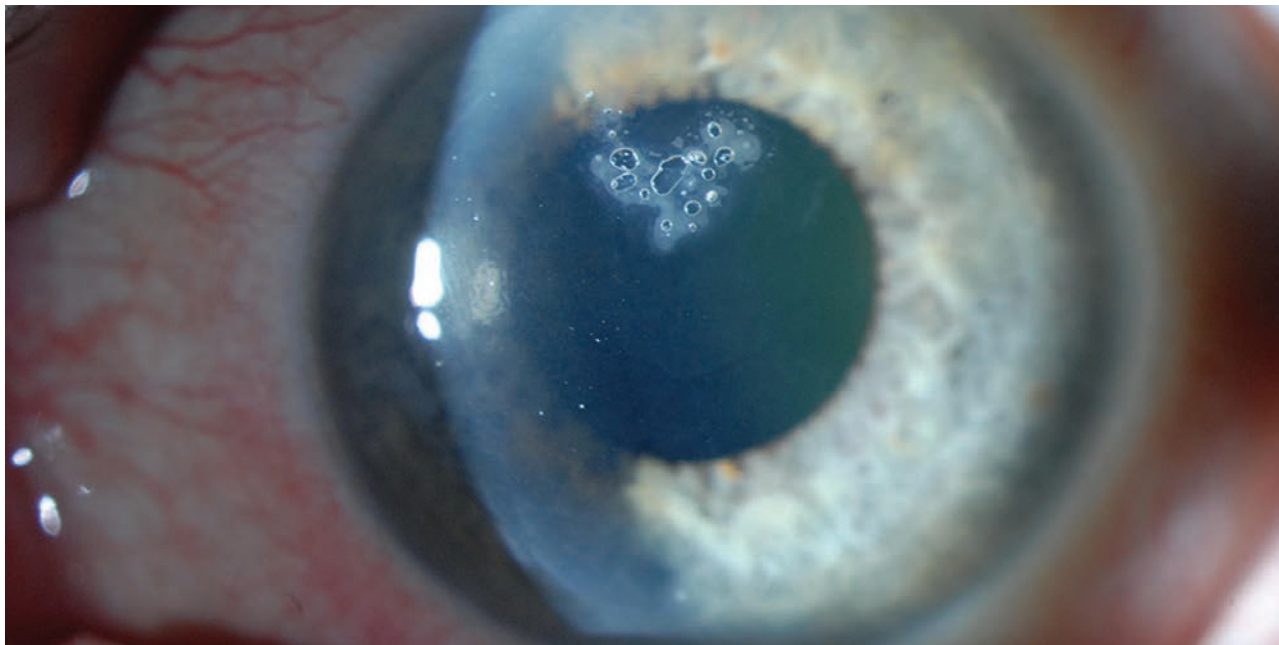
Jointly provided by:

Supported by an independent medical education grant from:

Review of Ophthalmology®



Alcon



Christopher J. Rapuano, MD

A neodymium-yttrium (YAG) laser can be effective for killing epithelial cells that have encroached on the visual axis. An eye immediately post YAG treatment is shown here, with bubbles over the targeted ingrowth.

epithelial nest that was actually introduced by the surgeon during treatment and not contiguous with the edge of the flap, use a YAG laser to kill the cells so they don't grow," says Dr. Machat, who adds, "I've never used that technique—I worry too much."

"I find it very unsettling to YAG the cornea," agrees Dr. Jeng. For epithelial ingrowth that's infiltrating the eye through an opening other than a LASIK flap, such as a wound, however, he will consider changing up his strategy of debridement. "I might focally cryo the area," he states. "If the ingrowth was severe enough, that's something that I would consider, but then you'd kill off an area of the stem cells so that it can't grow the epithelium."

Repeat as Necessary

"I'm going to say this, and then I'm knocking on wood, but I've never had epithelial ingrowth recur after I've stitched the flap down," says Dr. Jeng. "That said, just because it recurs, that

doesn't mean you have to intervene. But if it does recur, and if it does continue to progress, you have to relift it. Presumably, this would be at a point after you've already taken out your original set of sutures if you're following the patient. I think that if you lift the flap again and go through the same steps, you can use any of the adjunctive methods you want. I'm not a huge fan of mitomycin-C, since I'm not really sure that it works. Isopropyl alcohol is more of a local thing that goes away once it's done its job, so the epithelium will kind of grow back over it," he says.

"We're only about 80-percent effective in eliminating epithelial ingrowth once it's occurred," Dr. Machat estimates. "If you have to re-treat, then it's about 80-percent odds again. Only if the ingrowth is very minimal, your first treatment can be around 98-percent effective; but if you let ingrowth progress to, say, Grade 3, then it's only 80-percent effective."

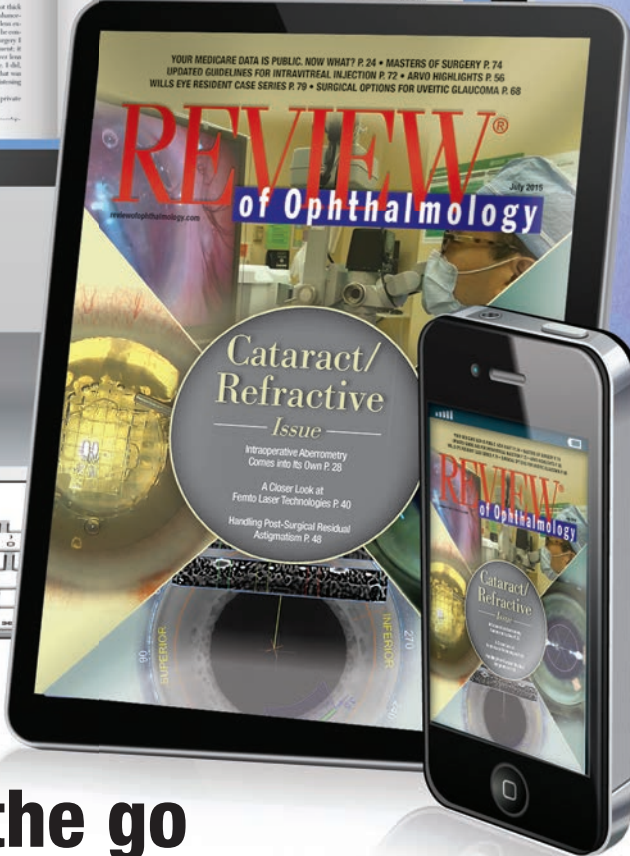
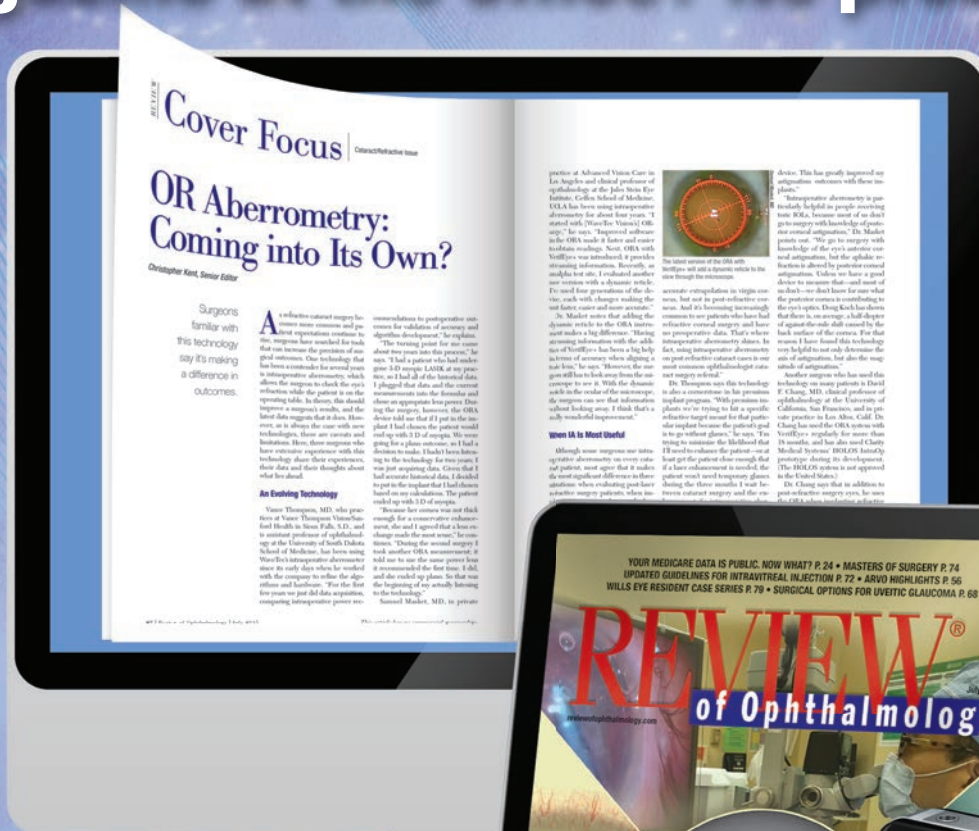Epithelial cells that sneak under the LASIK flap, like unwanted guests you've politely shooed away, have

some propensity to come back even after you make it clear they're not welcome. "The biggest thing is that if you don't treat rapidly advancing epithelial ingrowth that has no demarcation lines, or necrotic epithelial cells, the wall of cells that moves in can literally pull the flap edge underneath it, so it's rolled," says Dr. Machat. "I describe it to patients as similar to a worn-in walking path in a park or forest: That path has been created, and cells will grow back all over again." With careful observation, clinical judgment and persistence, your patient's LASIK flap needn't be a gateway to rogue epithelial cells. **REVIEW**

Neither Dr. Machat nor Dr. Jeng reports any financial interests relevant to this article.

1. Machat JJ, Slade SG, Probst LE. The art of LASIK. 2nd ed. Thorofare, NJ: Slack; 1999.
2. Hardten DR, Fahmy MM, Vora GK, Berdahl JP, Kim T. Fibrin adhesive in conjunction with epithelial ingrowth removal after laser in situ keratomileusis: Long-term result. *J Cataract Refract Surg* 2015;41:1400-05.
3. Fuentes-Paez G, Soler Jr, T, Ddo, BS. Epithelial ingrowth: Visual acuity and astigmatism results one year after YAG laser treatment. *J Clin Exp Ophthalmol* 2015;6:5. <http://dx.doi.org/10.4172/2155-9570.1000471>. Accessed 25 April 2018.

Left your *Review of Ophthalmology* magazine at the office? No problem!



Read *Review* on the go from any mobile device!

Simply go to www.reviewofophthalmology.com and click on the digimag link to get your current issue.



Stem Cell Therapy in Retinal Disease

A look at how stem cells are generated, and the most promising approaches to employing them in the eye.

Peter Bracha, MD, and Thomas A. Ciulla, MD, MBA, Indianapolis

Stem cells, currently under investigation for the treatment of age-related macular degeneration and other retinal disorders, are characterized by the ability to differentiate into multiple cell lineages, and an unlimited self-renewal capacity. These traits make them excellent candidates as potential treatments for various diseases. To date, however, no stem cell-based therapy for retinal disease has been approved by the U.S. Food and Drug Administration, though there are several candidates in development. In this article, we'll focus on human studies of stem cell-based ocular therapy.

Stem Cell Primer

Pluripotent stem cells (PSCs), by definition, are able to differentiate into all endodermal, mesodermal and ectodermal lineages. Human embryonic stem cells (hESCs) were first cultured in 1998 and have the potential to differentiate into all cell types (Figure 1). They are a promising source for stem cell-based therapy but, like fetal progenitor cells, raise potential ethical considerations. In-

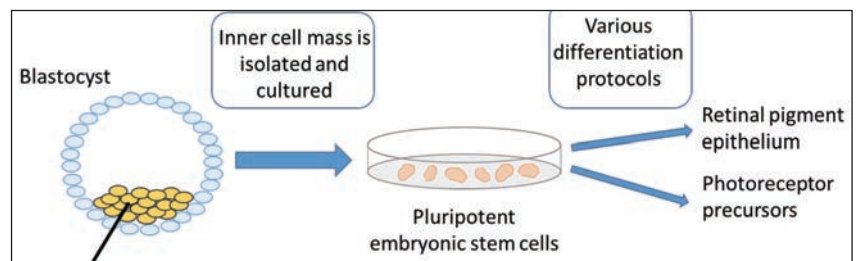


Figure 1. Embryonic stem cell-based therapy. The inner cell mass is isolated from the blastocyst and cultured. The pluripotent embryonic stem cells are then differentiated into retinal pigment epithelium, photoreceptor precursors or other cell types using various methods.

duced pluripotent stem cells (iPSCs) are a subtype of pluripotent stem cells that originate from a differentiated cell source, such as skin fibroblasts or blood cells (Figure 2); they may be considered less controversial, and may negate some immunological issues associated with hESC-based therapies. Somatic stem cells, such as bone marrow, adipose, central nervous system and umbilical stem cells, are different than ESC- or iPSC-based therapies because they're not pluripotent, but can generate some of the cell types of their host organ. While they normally assume a regenerative role in their host organ (i.e., corneal limbus epithelial stem cells), somatic stem cells

typically assume a trophic role in stem cell therapy (Figure 3).

It turns out that the eye is a good candidate for stem cell clinical research, given the unmet therapeutic need, the relatively immune-privileged site and the clear ocular media that facilitates direct visualization of transplanted cells. Furthermore, the size of the eye requires smaller quantities of therapeutic tissue in comparison to other organs.

In the eye, stem cells can potentially serve two different therapeutic roles: regenerative or trophic. For example, stem cells have the potential to replace or regenerate tissue, such as retinal ganglion cells in glaucoma, or

Table 1. Ongoing or Recently Completed Stem Cell-based Therapies in Retinal Disease

Type of Stem Cell Therapy	Transplantation Method	Ocular Pathology	Clinicaltrials.gov Number	Sponsor	Study Phase
Autologous bone marrow-derived stem cells	Intravitreal	nAMD, atrophic AMD, Stargardt	NCT01518127	University of Sao Paulo	Phase I and II
Autologous bone marrow-derived stem cells	Intravitreal	retinal degenerations, glaucoma	NCT02330978	University of Sao Paulo	Phase I and II
Autologous bone marrow-derived stem cells	Intravitreal	atrophic AMD	NCT02016508	Al-Azhar University	Phase I and II
Autologous bone marrow-derived stem cells	Retrobulbar, sub-Tenon's, intravenous, intravitreal, subretinal	various, including AMD	NCT01920867	Retina Associates of South Florida	Not documented
Autologous bone marrow-derived stem cells	Intravitreal	atrophic AMD, including other retinal pathologies	NCT01736059	University of California, Davis	Phase I
Autologous induced pluripotent stem cell-derived RPE cells	Subretinal	atrophic AMD	NCT02464956	Moorfields Eye Hospital NHS Foundation Trust	Phase I
Allogenic HLA-matched iPSC-derived RPE cells	Subretinal	nAMD	--	RIKEN	Phase I
Human central nervous system stem cells	Subretinal	atrophic AMD	NCT01632527	StemCells	Phase I and III
Human embryonic stem cell-derived RPE	Subretinal	nAMD	NCT03102138	Pfizer	Phase I
hESC-derived RPE	Subretinal	AMD, Stargardt	NCT02749734	Southwest Hospital, China	Phase I
hESC-derived RPE	Subretinal	atrophic AMD	NCT03046407	Chinese Academy of Sciences	Phase I
hESC-derived RPE	Subretinal	atrophic AMD	NCT02755428	Chinese Academy of Sciences	Phase I
hESC-derived RPE	Subretinal	atrophic AMD	NCT01674829	CHA Biotech	Phase I and II
OpRegen: hESC-derived RPE	Subretinal	atrophic AMD	NCT02286089	Cell Cure Neurosciences	Phase I and II
hESC-derived RPE	Subretinal	atrophic AMD	NCT01344993	Astellas Institute of Regenerative Medicine	Phase I and II
hESC-derived RPE on a parylene membrane	Subretinal	atrophic AMD	NCT02590692	Regenerative Patch Technologies	Phase I and II
hESC-derived RPE suspension (Arm 1) and hESC-derived RPE seeded on a substrate (Arm 2)	Subretinal	nAMD, atrophic AMD, Stargardt	NCT02903576	Federal University of Sao Paulo	Phase I and II
Human retinal progenitor cells (source not specified)	Intravitreal	retinitis pigmentosa	NCT0373733	jCyte	Phase II
hRPC (source not specified)	Subretinal	retinitis pigmentosa	NCT02464436	ReNeuron	Phase I and II

retinal pigment epithelium in retinitis pigmentosa or AMD-related geographic atrophy (GA). They can alternatively or simultaneously assume a trophic role, producing growth factors and cytokines, such as brain-derived neurotrophic factor, that have a supportive paracrine effect on local structures within the macula. (It's worth noting that most current approaches using somatic stem cells to treat retinal disease use an intravitreal deliv-

ery method, in contrast to subretinal transplantation.¹)

RPE Transplantation

Transplant of retinal pigment epithelium cells is a popular application of stem cell therapy in ophthalmology, with researchers taking different approaches:

- **Embryonic stem cells in RPE transplantation.** The first human

studies of stem cell-based RPE transplants in AMD and Stargardt Disease were published in 2012.¹ Steven D. Schwartz, MD, of the Stein Eye Institute in Los Angeles, and his colleagues performed two prospective clinical trials of subretinal transplantation of hESC-derived RPE cells in nine patients with Stargardt macular dystrophy and nine with atrophic AMD.² Following surgery combined with immunosuppression, 72 percent

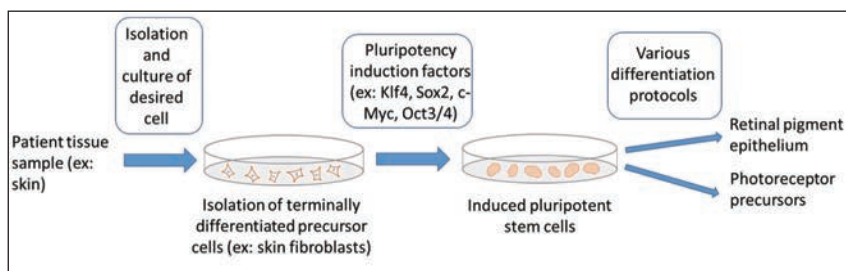


Figure 2. The process of inducing pluripotency followed by differentiation of cells into the desired cell type. First, a tissue is harvested from the adult patient. The tissue is then processed and the desired cell type isolated and cultured. The cells are then induced into pluripotency through the introduction of particular factors and growth conditions. Once pluripotency is established, the cells can be differentiated into the desired cell type, such as retinal pigment epithelium or photoreceptor precursor cells.

of patients had increased subretinal pigmentation at the location of the transplant, suggesting the presence of the injected cells.² No serious adverse outcomes were observed in visual acuity, visual field, static perimetry, electroretinography or reading speed, and there were no signs of acute rejection. Even after four years, none of the eyes developed abnormal growth suggestive of a teratoma, a tumor composed of two or more germ layers which could originate from stem cells, and no eyes developed proliferative vitreoretinopathy or a retinal detachment.^{2,3}

In 2015, Won Kyung Song, MD, of Korea's Bundang Medical center, and co-workers published preliminary results of subretinal hESC-derived RPE transplantation in two patients

with advanced atrophic AMD and two patients with Stargardt disease.⁴ Similar to Dr. Schwartz's study, no patients developed teratomas, graft rejection, PVR or a significant visual decline. However, this study did note some challenges expected with surgery surrounding retinotomy sites, as well as intolerance of immunosuppression in one patient.⁴

A recent Phase I trial of hESC transplants on a coated, synthetic basement membrane in two patients with advanced exudative AMD was suggestive of survival of the graft through 12 months. The study highlighted the feasibility of transplantation of RPE cells on the synthetic membrane, but also identified perioperative challenges, including a retinal detachment due to PVR, dislo-

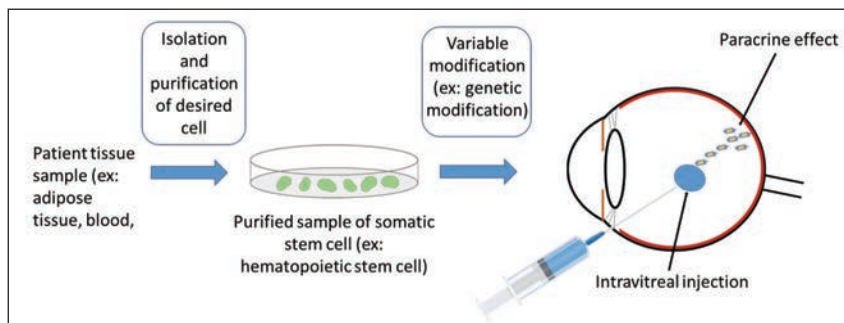


Figure 3. Somatic stem cell therapy. First, tissue is harvested from the patient and the desired cell is isolated and purified. The cells can then variably be modified and are typically injected intravitreally where they have a paracrine effect. Alternatively, the tissue can be injected subretinally and some investigators are investigating periocular injections.

cation of a fluocinolone implant used for immunosuppression and worsening of diabetes from the use of oral steroids.⁵

• **Induced pluripotent stem cells in RPE transplantation.** The use of iPSC-derived RPE transplants in human trials has lagged behind the use of ESCs. The first human trial using iPSC-derived RPE subretinal transplants was initiated by RIKEN, a research institute in Kobe, Japan, in September 2014.⁶ A 70-year-old Japanese woman became the first person to receive an iPSC-derived therapy for any indication.⁷ She didn't receive immunosuppression, in contrast to ESC-derived RPE transplantation studies.^{2,4} The subject demonstrated no adverse ocular effects at one year, the transplanted sheets remained intact and her vision decline had stabilized.⁸ This study was suspended after mutations were observed in a second subject's iPSCs, which weren't detectable in the patient's original fibroblasts.⁶

In 2016, RIKEN planned to resume the study, with a significant modification: Instead of autologous cells, its researchers are investigating human leukocyte antigen-matched allogenic iPSC-derived RPE cells.⁶

The use of autologous cells is costly and may require up to three months to develop from harvesting to intravitreal implantation.⁷ In contrast, the use of allogenic cells facilitates verification of genomic stability and expedites the time from patient selection to implantation.⁶

A potential downside of using allogenic cells, however, is the increased risk of rejection due to the presentation of non-self antigens and the possible need for immunosuppression.

Trophic Roles for Stem Cells

Human intravitreal, autologous bone marrow-derived mononuclear transplantation was first published in

2008, and demonstrated no significant safety issues in an eye with advanced diabetic retinopathy with optic nerve atrophy and retinal detachment.⁹ The same group expanded the study to include two additional patients, including a patient with advanced atrophic AMD. Two of the three patients underwent pars plana vitrectomy followed by intravitreal transplantation of suspended cells, and the third patient had the transplant injected into silicone oil. In all patients, the cells disappeared within four weeks, and other than a mild increase in intraocular pressure (absolute readings of 15 to 30 mmHg), no adverse events were published.¹⁰

A separate group investigated the intravitreal injection of autologous CD34+ bone marrow stem cells in various retinal pathologies. In contrast to the studies mentioned above, this group didn't perform PPV prior to intravitreal injection. The transplant was tolerated well with no intraocular inflammation or tumor formation. At six months postoperatively, five of the six study eyes demonstrated VA stabilization, but one eye developed progression of AMD-related GA with a visual decline.¹¹ Overall, these studies suggest the basic tolerability of the procedure, with further studies needed to clarify safety and efficacy. Other human studies have investigated the use of autologous bone marrow-derived mononuclear cells in patients with retinitis pigmentosa, retinal vein occlusion and cone-rod dystrophy.¹²⁻¹⁴

Postoperatively, patients injected with mesenchymal or hematopoietic stem cell-based therapies may be at increased risk of proliferation of cells within the vitreous. For example, following intravitreal injection of CD34-positive stem cells, a 71-year-old female patient developed a visually significant epiretinal membrane within four months.¹⁵ Another patient, a 60-year-old man with Stargardt disease, developed a retinal detachment

two months following subretinal injection of autologous mesenchymal stem cells.¹⁶ Most recently, Ajay E. Kuriyan, MD, at the University of Rochester Medical Center in Rochester, New York, published an account of a tragic case series of three patients who experienced vitreous proliferation, retinal detachment and profound loss of vision following adipose tissue-derived mesenchymal stem cell intravitreal transplants at one center in Florida.¹⁷ One of the patients saw the treatment on www.clinicaltrials.gov, and erroneously interpreted the listing as a clinical trial with government approval and oversight, even though the center billed patients directly for the therapy (which is very unusual in a true clinical trial). It's imperative for physicians to appropriately educate patients about the possible downsides of unproven stem cell therapies being conducted outside of a true controlled clinical trial setting.

In conclusion, stem cell-based therapies have intriguing potential, but this field is still in its infancy. In the last several years, ESC-, iPSC-, and somatic stem cell-based therapies have advanced from *in vitro* and animal models to human trials with limited efficacy data. The major limitation of applying stem cell-based therapies to patients with AMD and similar pathologies is the chronic and complex disease process. For example, years of oxidative stress, an impaired inflammatory state with complement activation, and aging with choriocapillaris atrophy and ischemia create a microenvironment in AMD that challenges successful tissue replacement, engraftment and survival. Furthermore, given the polarity of RPE cells, transplanting sheets of cells with a scaffold, instead of suspensions, may be more physiologic, and some groups are consequently developing this concept further. Furthermore, surgical technique and immunosuppression will require additional clarification. **REVIEW**

Peter Bracha, MD, is chief resident and Thomas A. Ciulla, MD, MBA, is a volunteer clinical professor of ophthalmology at Indiana University School of Medicine. Dr. Ciulla also serves on the board of directors of Midwest Eye Institute and has an employment relationship with Spark Therapeutics. Neither Dr. Bracha nor Dr. Ciulla have financial interests in the subject matter.

1. Schwartz SD, Hubschman JP, Heilwell G, et al. Embryonic stem cell trials for macular degeneration: A preliminary report. *Lancet* 2012;379:9817:713-20.
2. Schwartz S, Regillo CD, Lamet BL, et al. Human embryonic stem cell-derived retinal pigment epithelium in patients with age-related macular degeneration and Stargardt's macular dystrophy: follow-up of two open-label phase 1/2 studies. *Lancet* 2015;385:9967:509-16.
3. Schwartz, SD, Tan G, Hosseini H, Nagiel A. Subretinal Transplantation of Embryonic Stem Cell-Derived Retinal Pigment Epithelium for the Treatment of Macular Degeneration: An Assessment at 4 Years. *Invest Ophthalmol Vis Sci* 2016;57:5:1-9.
4. Song, WK, Park KM, Kim HJ, et al. Treatment of macular degeneration using embryonic stem cell-derived retinal pigment epithelium: Preliminary results in Asian patients. *Stem Cell Reports* 2015;4:5:860-72.
5. da Cruz L, Fynes K, Georgiadis O, et al. Phase I clinical study of an embryonic stem cell-derived retinal pigment epithelium patch in age-related macular degeneration. *Nat Biotechnol* 2018. 36:4:328-337.
6. Garber K. RIKEN suspends first clinical trial involving induced pluripotent stem cells. *Nat Biotechnol* 2015;33:9:890-1.
7. Chakradhar S. An eye to the future: Researchers debate best path for stem cell-derived therapies. *Nat Med* 2016;22:2:116-9.
8. Mandai M. Autologous Induced Stem-Cell-Derived Retinal Cells for Macular Degeneration. *N Engl J Med* 2017;376:11:1038.
9. Jonas JB. Intravitreal autologous bone marrow-derived mononuclear cell transplantation: a feasibility report. *Acta Ophthalmol* 2008;86:2:225-6.
10. Jonas JB. Intravitreal autologous bone-marrow-derived mononuclear cell transplantation. *Acta Ophthalmol* 2010;88:4:e131-2.
11. Park SS, Bauer G, Abedi M, et al. Intravitreal autologous bone marrow CD34+ cell therapy for ischemic and degenerative retinal disorders: preliminary phase 1 clinical trial findings. *Invest Ophthalmol Vis Sci* 2014;56:1:81-9.
12. Siqueira RC, Messias A, Voltarelli JC, et al. Intravitreal injection of autologous bone marrow-derived mononuclear cells for hereditary retinal dystrophy: a phase I trial. *Retina* 2011;31:6:1207-14.
13. Siqueira RC, Messias A, Voltarelli JC, et al. Resolution of macular oedema associated with retinitis pigmentosa after intravitreal use of autologous BM-derived hematopoietic stem cell transplantation. *Bone Marrow Transplant* 2013;48:4:612-3.
14. Siqueira RC, Rubens C, Siqueira AM, Gurgel VP, et al. Improvement of ischaemic macular oedema after intravitreal injection of autologous bone marrow-derived haematopoietic stem cells. *Acta Ophthalmol* 2015;93:2:e174-6.
15. Kim JY, You YS, Kim SH, et al. Epiretinal membrane formation after intravitreal autologous stem cell implantation in a retinitis pigmentosa patient. *Retin Cases Brief Rep* 2017;11:3:227-231.
16. Leung EH, HW Flynn, TA Albini, et al. Retinal detachment after subretinal stem cell transplantation. *Ophthalmic Surg Lasers Imaging Retina* 2016;47:6:600-1.
17. Kuriyan AE, TA Albini, JH Townsend, et al. Vision loss after intravitreal injection of autologous "stem cells" for AMD. *N Engl J Med* 2017;376:11:1047-1053.



Two Unique Glaucoma Drugs Debut

Latanoprostene bunod and netarsudil offer surgeons new options in the battle to effectively lower IOP.

Albert S. Khouri, MD, Newark, N.J.

For those of us treating glaucoma, these are exciting times. The last new class of glaucoma medications—the prostaglandin analogues—became available back in 1996. Now, more than 20 years later, we find ourselves able to prescribe two new drugs that represent entirely new classes of glaucoma medication. Vyzulta (latanoprostene bunod ophthalmic solution 0.024%, from Bausch + Lomb) and Rhopressa (netarsudil ophthalmic solution 0.02%, from Aerie Pharmaceuticals) each have mechanisms of action different from those of the drugs that were previously available. Both of these are promising and should serve as important primary or adjunctive glaucoma therapies.

Today, most ophthalmologists' glaucoma treatment paradigm starts with prescribing a prostaglandin analogue as first-line therapy. That's true for three main reasons: Prostaglandins are currently the most effective class of IOP-lowering drug; they're safe in terms of their side-effect profile; and they're used once daily, which minimizes the impact on patients' quality of life and maximizes adherence. Both of the new drugs do

well in the same three categories: Both are effective (though not equally effective) IOP-reducers; both have favorable systemic side-effect profiles; and both are once-a-day medications.

Here, I'd like to discuss the benefits, limitations and potential drawbacks of each medication and offer some thoughts on how they might fit into our treatment paradigm.

Latanoprost Redux

Latanoprostene bunod (Vyzulta) is a molecule that is metabolized into latanoprost, which we've had many years of experience with, and a moiety that donates nitric oxide once the medication is in the eye. Latanoprost works primarily by increasing uveoscleral outflow, while nitric oxide increases trabecular outflow, which is a novel mechanism of action. Because of these complementary mechanisms, combining the two molecules offers favorable IOP reduction.

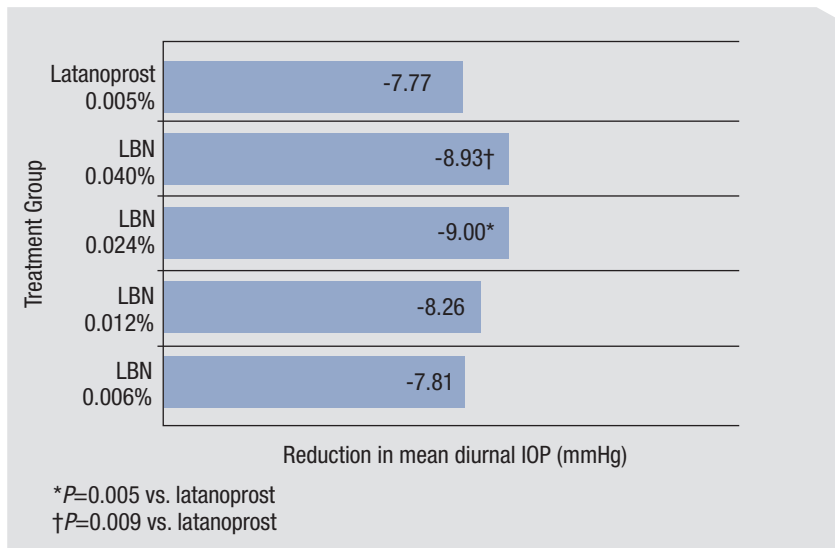
The data from the clinical trials shows robust efficacy for latanoprostene bunod. The reduction in mean diurnal pressure at about a month was almost 9 mmHg.¹ For a single agent

used once a day to deliver 9 mmHg IOP reduction at peak effectiveness is impressive. Also, at that time point, latanoprostene bunod was superior to latanoprost alone, and the difference was statistically significant.

In terms of the side-effect profile, studies have found that Vyzulta is safe systemically. That's very favorable for glaucoma patients, who are often on other systemic medications to treat cardiovascular or pulmonary diseases. The most common ocular side effect with Vyzulta was hyperemia, which is not unexpected since this is a prostaglandin. There were other adverse effects related to topical instillation, such as irritation and dry eye, which are not unique to latanoprostene bunod and are encountered with other glaucoma topical therapies. Overall, discontinuation due to adverse effects has been rare with latanoprostene bunod in published studies.²

Of course, one advantage of latanoprostene bunod is that we have many years of experience with latanoprost, a key component of the new drug. As a result, we're well acquainted with its adverse effects.

Efficacy: Latanoprostene Bunod vs. Latanoprost



In the VOYAGER trial, latanoprostene bunod 0.024% produced a reduction in mean diurnal IOP of 9.0 mmHg. LBN was also significantly superior to latanoprost alone at peak effect.¹

knowing what we're dealing with.

The Dawn of ROCK-inhibitors

What's most exciting about netarsudil (Rhopressa) is that it's the first in a new class of glaucoma medications. Unlike the other classes of medications available to us, rho kinase inhibitors have a different mechanism of action: They work by enhancing trabecular meshwork outflow. In contrast, prostaglandins increase uveoscleral outflow, while other medications, such as alpha agonists, topical carbonic anhydrase inhibitors and beta blockers mainly decrease aqueous production. Combining some of the current medications with similar mechanisms of action simply maximizes that effect, and the IOP reductions may not be additive. Because rho kinase inhibitors affect trabecular meshwork outflow, netarsudil may combine well synergistically with some of the other currently available medications. As adjunctive therapy, that's very favorable.

In terms of efficacy, netarsudil

criteria vs. timolol in the ROCKET-1 study, in which baseline washout IOP was between 20 and 27 mmHg. However, a post-hoc analysis revealed that netarsudil was non-inferior to timolol for patients with a post-washout IOP lower than 25 mmHg. The most recent data is from the ROCKET-4 trial, with a six-month extension study. This was presented at the 2018 meeting of the American Glaucoma Society. In that trial, once-daily netarsudil was compared to timolol b.i.d. in patients with primary open-angle glaucoma and ocular hypertension. Basically, the study showed that netarsudil was not inferior to timolol at all time points from week two to month six.

Overall, in the ROCKET series of trials, including ROCKET-4, netarsudil q.d. was noninferior to timolol (dosed twice daily) at a range of baseline IOPs. To restate that from a clinician's standpoint, reductions in IOP were similar to timolol. We know that timolol generally delivers a 20- to 25-percent pressure reduction, depending on how high the baseline pressure is and how responsive the

patient is to beta blockers. We expect netarsudil to fall within that range.

In terms of adverse effects, like latanoprostene bunod, netarsudil is a patient-friendly medication that's used once a day and has no cardiac or pulmonary impact; the most common adverse effect is conjunctival hyperemia. In the ROCKET trials, about half the patients using once-a-day netarsudil reported hyperemia. This is a higher rate than we've seen with beta blockers. However, the hyperemia was not present at every visit; it was intermittent and for the most part was mild and transient and reported by the investigator rather than the patient.³

Rho kinase inhibitors do have two unique adverse effects that we've learned of from the clinical trials that are not typical of other currently used glaucoma medications. One is conjunctival hemorrhages. Interestingly, these were very small—typically described as “pinpoint hemorrhages.” In fact, they were so small that they were usually only observed by the investigators; most patients didn't notice them. They were considered mild in the vast majority of cases, and as you might expect, they resolved on their own. They were not seen as a justification for discontinuation of the medication.

The other unique adverse effect that's been observed with netarsudil—and rho kinase inhibitors in general—is corneal verticillata (5 to 9 percent in ROCKET-1 and -2). This is a benign condition in which lipid deposits form in the corneal epithelium. This phenomenon was graded as mild in most patients. In fact, the verticillata were not symptomatic; because they occur in the superficial layers of the corneal epithelium, they tend to not be visually significant. Patients didn't notice any changes in their vision, so this phenomenon was only noted by the investigators. Furthermore, the verticillata resolved once the

medication was discontinued. (Of note, other FDA-approved medications can cause verticillata; amiodarone is the classic example. However, this may be the first example of verticillata being caused by a topical glaucoma medication.)

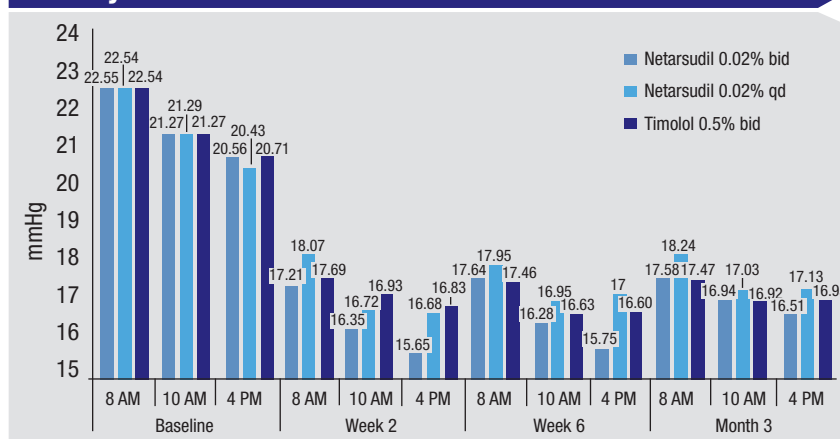
It's important to keep in mind that all of this data regarding latanoprostene bunod and netarsudil comes from clinical trials, not from clinical use in the field. Until both medications are widely used after their launch, we won't be able to say definitively how significant or insignificant these findings may be.

First-line or Adjunct?

The way in which these two novel medications will end up being used is difficult to predict at this point, but their relative efficacy may be a significant factor. For example, latanoprostene bunod is one of the most effective medications we currently have, in addition to being used once a day. This will position it well as a first-line medication when you're trying to achieve significant (on the order of 30 percent or greater) reduction in pressure to get to a target at which you can stabilize the disease. It also makes sense for patients in terms of avoiding having to dose medications multiple times a day, and for patients who have cardiovascular disease, where you're trying to avoid medications that can interact with systemic illnesses and medications. Most patients are on prostaglandins as first-line therapy, and latanoprostene bunod is in line with that.

The challenge with latanoprostene bunod, as with many medications that are newly released, is commercial insurance coverage. When a medication is first released, it's often not covered by a lot of plans. Until that situation changes, it may limit the access many patients have to latanoprostene bunod and netarsudil.

Efficacy: Netarsudil 0.02% vs. Timolol 0.5%



Netarsudil 0.02% used once a day in the ROCKET-2 trial was not inferior to timolol 0.5% dosed twice a day up to three months.³

with coverage is dynamic and is likely to improve or change over time.

Netarsudil, which causes IOP reductions closer to timolol, would make total sense as an adjunctive therapy. I'd say about half of our glaucoma patients require adjunctive therapy to get to their target or goal pressures. Currently we have a choice of several medications as adjunctive treatments, but all of them have to be used two or three times daily. (Beta blockers can be used once a day, but they have systemic side effects.) So netarsudil is well-positioned to be a choice adjunctive agent.

There will definitely be some patients for whom prostaglandin analogues are not ideal choices for first-line treatment for a number of possible reasons. For example, this would be the case for patients with active uveitis and patients who are concerned about iris color changes. I have a few patients in my own practice who have mixed iris colors, and they don't want to risk changing this, so they refuse the medication. Also, prostaglandins can cause periorbital fat atrophy. Some patients see the appearance of their upper eyelids change over time, and you end up having to take them off of the

more in patients who are only being treated in one eye.) In our practice, we currently offer these patients laser trabeculoplasty or one of the other adjunctive therapies, all of which have to be used twice a day or more. Netarsudil is a possible choice for those patients because it's once a day, which is a big advantage.

One obvious question is whether the two new medications might be complementary. Both medications have an effect on outflow through the trabecular meshwork, but we currently have no data on how they'll interact. We do know that their mechanisms of action are not the same, just as many drugs that reduce aqueous humor production use different mechanisms of action. It's possible that either of them alone might optimize trabecular meshwork outflow, but it's also possible that their interaction could be synergistic. It will probably require post-launch studies and clinical experience over time to answer that question.

What Lies Ahead?

Given that these medications just became available, I think it's too soon to guess how clinicians and patients

will interact with them. I can definitely vouch for the level of excitement about these new medications, as many glaucoma patients in my practice have inquired about them. Currently, we have data from the clinical trials, which was certainly favorable for both of these drugs. But what I've learned from my own experience is that until we get our hands on them and use them clinically, their full potential will remain unknown, and many questions about their side effects will remain unanswered.

The reality is that clinical trial data doesn't always match what we find in clinical practice. For example, historically there were three very large clinical trials of latanoprost in the United States and abroad. We learned a lot about the side effects and the efficacy profile of the drug from

those trials, but we completely missed the side effect of eyelash growth. That was only picked up later on after the medication was widely used.

The point to make is that it can be hard to translate clinical trial data into real-world data. We'll need to observe the drugs' real-world efficacy, how our patients react to them, what kind of side-effect profiles we see in day-to-day use and how each drug combines with other medications, which is a key aspect of treating glaucoma. Clinical trials give us baseline information and clean data on the efficacy of the medications and their safety, but it remains to be seen how the drugs will perform once widely launched and used. Our experience could very well mirror what was discovered during the clinical trials, or it could be different. That's something we will

learn in the months to come once we start using these two drugs. **REVIEW**

Dr. Khouri is an associate professor of ophthalmology, as well as director of the glaucoma division and the residency program, at Rutgers New Jersey Medical School. He has received grant support from Allergan, Bausch + Lomb and Aerie Pharmaceuticals, is a consultant for Aerie, and is on the speaker bureau for Bausch + Lomb, Allergan and Novartis.

1. Weinreb RN, Ong T, et al. A randomised, controlled comparison of latanoprostene bunod and latanoprost 0.005% in the treatment of ocular hypertension and open angle glaucoma: the VOYAGER study. *Br J Ophthalmol* 2015;99:6:738-45.
2. Medeiros FA, Martin KR, et al. Comparison of latanoprostene bunod 0.024% and timolol maleate 0.5% in open-angle glaucoma or ocular hypertension: The LUNAR study. *Am J Ophthalmol* 2016;168:250-259.
3. Serle JB, Katz LJ, McLaurin E, et al. Two phase 3 clinical trials comparing the safety and efficacy of netarsudil to timolol in patients with elevated intraocular pressure: Rho Kinase Elevated IOP Treatment Trial 1 and 2 (ROCKET-1 and ROCKET-2). *Am J Ophthalmol* 2018;186:116-127.

Hiring Ophthalmic Staff?

More Ophthalmic
Technicians Find
Jobs On Local Eye Site
Than Anywhere Else.

localeyesite.com



Local Eye Site
JOBS IN EYE CARE

First AI Diagnostic System Approved

IDx has announced that the U.S. Food and Drug Administration has granted the company's de novo request to market IDx-DR, an AI-based diagnostic system for the autonomous detection of diabetic retinopathy. This is the first autonomous, AI-based diagnostic system authorized for commercialization by the FDA.

IDx says that the IDx-DR can be used to provide immediate, reliable screening for diabetic retinopathy, including macular edema, during a routine office visit in a primary care setting. The exam is performed in minutes and produces a diagnostic interpretation and associated report, including care instructions that are aligned with the American Academy of Ophthalmology's preferred practice pattern for diabetic retinopathy.

For more information on IDx-DR and its availability, visit eyediagnosis.net.

Bausch + Lomb's Lumify Now Available

In early May, Bausch + Lomb announced the launch of Lumify (brimonidine tartrate ophthalmic solution 0.025%) in the United States. Lumify is the first over-the-counter eye drop developed with low-dose brimonidine tartrate for the treatment of eye redness.

Researchers conducted six clinical studies in more than 600 patients to evaluate the safety and efficacy of Lumify, including studies with both pediatric and geriatric subjects. Bausch + Lomb says that the strong efficacy and safety profile of Lumify includes not only significant redness reduction for up to eight hours, but a low risk of allergic reactions among all patient groups.

For more information on Lumify, visit Bausch.com.

Alcon's Systane Complete

Alcon recently announced the addition of Systane Complete, a new formula designed to provide relief for dry eye, to its Systane family of dry-eye drops. Alcon says that Systane Complete is an ideal first-line treatment option for people who suffer from evaporative, aqueous-tear-deficient or mixed dry eye.

Alcon says Systane Complete uses intelligent moisture and lipid delivery to enhance transmission of the active ingredient across the surface of the eye to stabilize the tear film. It also comes equipped with nano-droplet technology that allows for fast-acting hydration, tear evaporation protection and long-lasting relief for a patient's eyes, the company says. Systane

Complete drops include the active demulcent propylene glycol, which spreads across the surface of the eye, Alcon adds.

For more information on this new addition to the Systane family, visit alcon.com.

New Lucentis Approval

In late March, Genentech announced that the FDA approved the Lucentis (ranibizumab injection) 0.3-mg prefilled syringe as a method of administering the medicine used in treating all forms of diabetic retinopathy, in people with or without diabetic macular edema. The Lucentis 0.3-mg PFS is now the first syringe prefilled with an antivascular endothelial growth factor agent FDA-approved to treat both diabetic retinopathy and DME.

The syringe is packaged in a single-use sterile sealed tray, allowing physicians to eliminate several steps in the preparation and administration process. Genentech says that with the Lucentis PFS, physicians snap off the syringe cap, attach the injection needle to the syringe and adjust the dose prior to administration. It's expected to be available in the second quarter of 2018, the company says.

For more on Lucentis, visit gene.com.

Practice For Sale



Practice Sales • Appraisals • Consulting
www.PracticeConsultants.com

**PRACTICES FOR SALE
 NATIONWIDE**

Visit us on the Web or call us to learn more about our company and the practices we have available.

info@PracticeConsultants.com

800-576-6935

www.PracticeConsultants.com

Career Opportunities

OPHTHALMOLOGISTS

Danbury, CT

Ophthalmologists to share office with long standing Ophthalmologist in Danbury, CT. High quality equipment. \$2,250 per month or adjoining office without equipment- \$1,750 per month.

203-545-3539 or
 email mehrimd@aol.com

Career Opportunities



Targeting
 Ophthalmologists?

**CLASSIFIED ADVERTISING
 WORKS**



Contact us today
 for classified advertising:
 Toll free: **888-498-1460**
 E-mail: sales@kerhgroup.com



FIND MORE PRACTICES FOR SALE ON



CONTACT US TODAY to list your practice:
 888-498-1460
opticlassifieds@kerhgroup.com

www.opticlassifieds.com



**FOR CLASSIFIED
 ADVERTISING
 CONTACT US TODAY:**

Toll free: **888-498-1460**
 E-mail: sales@kerhgroup.com





THE RICK BAY FOUNDATION

for Excellence in Eyecare Education

www.rickbayfoundation.org

Support the Education of Future Healthcare & Eyecare Professionals



About Rick

Rick Bay served as the publisher of *The Review Group* for more than 20 years.



To those who worked for him, he was a leader whose essence was based in a fierce and boundless loyalty.


To those in the industry and the professions he served, he will be remembered for his unique array of skills and for his dedication to exceeding the expectations of his customers, making many of them fast friends.

Scholarships are awarded to advance the education of students in both **Optometry** and **Ophthalmology**, and are chosen by their school based on qualities that embody Rick's commitment to the profession, including integrity, compassion, partnership and dedication to the greater good.

Interested in being a partner with us?

Visit www.rickbayfoundation.org

(Contributions are tax-deductible in accordance with section 170 of the Internal Revenue Code.)



THE RICK BAY FOUNDATION®
for Excellence in Eyecare Education

(The Rick Bay Foundation for Excellence in Eyecare Education is a nonprofit, tax-exempt organization under section 501(c)(3) of the Internal Revenue Code.)



A 22-year-old man with eyelid swelling and sinus congestion is evaluated in the Wills Eye Hospital Emergency Room.

Douglas Matsunaga, MD, Matthew Zhang, MD, and Robert Penne, MD

Presentation

A 22-year-old man presented to the Wills Eye Hospital Emergency Room with worsening pain and swelling of his left upper eyelid that began three days prior to evaluation. The patient reported sinus congestion with yellow-green drainage for at least one month. He also noted poor appetite and fevers, and was unable to open his eye on the day of presentation. The patient initially presented to an outside emergency room where he was given intravenous antibiotics. A lateral canthotomy was attempted, and the patient was then transferred to the Wills Eye Hospital Emergency Room.

Medical History

The patient had a past medical history of chronic sinus infections. He otherwise denied any significant medical, surgical or ocular history. There was no pertinent family history, allergies or social history, and the patient was not taking any medications.

Examination

On initial examination, the patient was found to have a fever of 38.3 degrees Celsius (100.9 F), heart rate of 77 beats per minute, blood pressure of 158/74 mmHg, and a normal oxygen saturation on room air. Ocular examination revealed uncorrected visual acuity of 20/20 in the right eye and hand motion without improvement with pinhole in the left. Visualization of the left eye was severely limited by upper-lid edema, but pupils appeared round and reactive without obvious relative afferent pupillary defect and extraocular motility was grossly full. Intraocular pressure was 18 mmHg in the right eye, and greater than 70 mmHg in the left eye by Tono-Pen.

Anterior examination of the left eye showed tense upper-lid edema with tenderness and erythema, mild lower-lid edema and a cut lateral canthus (*Figure 1*). The globe appeared grossly formed with diffuse conjunctival injection and hemorrhagic chemosis greatest laterally and inferiorly. Desmarres retractors were used to evaluate the eye and further examination was otherwise normal. Anterior and posterior examination of the right eye was within normal limits.

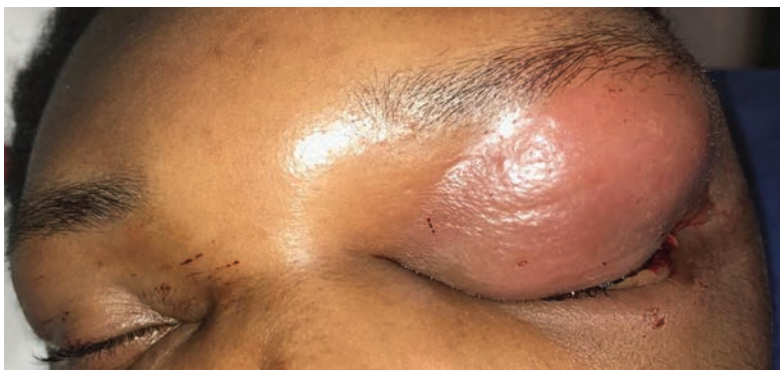

Figure 1. External photograph of the patient on initial presentation showing severe upper-lid edema and erythema.

What is your diagnosis? What further workup would you pursue? The diagnosis appears on p. 64.

Workup, Diagnosis and Treatment

The differential diagnosis for a severely swollen eyelid with associated conjunctival injection includes a range of etiologies, including preseptal or orbital cellulitis, orbital abscess, necrotizing fasciitis, neoplastic processes, orbital pseudotumor, trauma, carotid-cavernous fistula and thyroid ophthalmopathy. In combination with high intraocular pressure, trauma complicated by an orbital compartment syndrome arises as an urgent consideration; however, inflammatory and infectious etiologies may also present in this fashion. Given the patient's history of sinus disease and fever, and the absence of trauma, infectious etiologies such as orbital cellulitis and/or abscess were deemed most likely.

Immediate attention was drawn to the high IOP and the lateral canthotomy was urgently completed with the addition of an inferior cantholysis. After the canthotomy the appearance of the eye remained unchanged and the intraocular pressure was measured at 38 mmHg with a visual acuity of 20/400. Medical therapy was instituted with three rounds of timolol-dorzolamide and brimonidine drops every 15 minutes, and an intravenous infusion of 100 g of mannitol. One hour after the medications were finished the intraocular pressure was found to be 30 mmHg.

Ancillary imaging was obtained with a CT scan of the orbits with contrast that showed a large multi-lobulated abscess of the left upper lid tracking posteriorly into the orbit, disrupting normal anatomy and deforming the superior aspect of the globe (Figure 2A). Extensive opacification of bilateral maxillary, ethmoid and frontal sinuses was also seen (Figure 2B). The frontal sinus openly communicated with one of the lobules of the superior orbital abscess (Figure 2C). The patient was taken urgently to the operating room where a left superior orbitotomy with irrigation and drainage was performed. Twenty milliliters of pus was drained from the area, and a Penrose drain was placed. The Otolaryngology Service then performed functional endoscopic sinus surgery with drainage of the bilateral ethmoid, maxillary, sphenoid and frontal sinuses.

Postoperatively, the patient was treated with intravenous cefepime, metronidazole and vancomycin. Examination of the affected eye after surgery showed

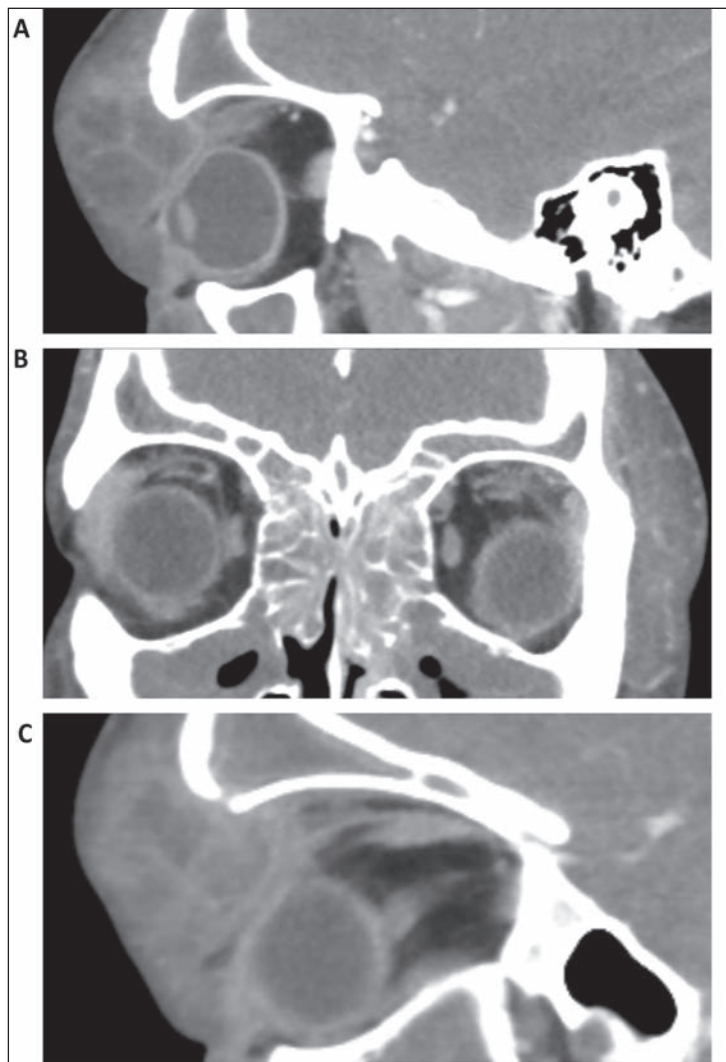


Figure 2. (A) Sagittal CT image on initial presentation showing a large multi-lobulated abscess with direct compression of the orbit. (B) Coronal CT image showing diffuse sinusitis of the maxillary, ethmoidal and frontal sinuses. (C) Sagittal CT image showing the frontal sinus openly communicating with one of the lobules of the orbital abscess.

visual acuity of 20/200 and an intraocular pressure of 26 mmHg. By postoperative day two the patient had a visual acuity of 20/40, IOP of 23 mmHg and improved lid swelling. On day three, cultures grew *Streptococcus anginosus*, and the patient was switched from cefepime and vancomycin to intravenous ceftriaxone. On postoperative day five the patient continued to show significant improvement in swelling, and his visual acuity was 20/20 with an IOP of 16 mmHg. The patient was subsequently discharged on oral amoxicillin/clavulanate with close outpatient follow-up.

Discussion

Orbital cellulitis is an infectious process involving orbital tissue posterior to the orbital septum. It's more common in the pediatric population, with an estimated incidence of 1.6 per 100,000 children versus 0.1 per 100,000 adults.¹ The most common risk factor for orbital cellulitis is paranasal sinusitis, with the ethmoid sinus most frequently involved.² Direct extension of the infection is likely facilitated by a number of orbital anatomical factors, including the thin medial orbital wall, lack of lymphatics, valveless veins and multiple foramina.³ Other predisposing associations include upper respiratory infection, trauma, surgery and orbital foreign body.²

In our particular case, orbital cellulitis presented as an uncommon manifestation of Pott's puffy tumor—a rare complication of frontal sinusitis where frontal bone osteomyelitis occurs with associated subperiosteal abscess. First described by Sir Percival Pott in 1768 as a result of trauma,⁴ PPT is now more typically associated with infectious etiologies and can extend through bone to involve the skin, brain or orbit. Classically, PPT presents with localized tender forehead swelling, but may also include headache, orbital symptoms, fever, vomiting and purulent rhinorrhea depending on the involved anatomy.^{5,6} Orbital involvement has been described in 33 to 45 percent of PPT cases.^{6,7}

Close attention to potential complications of orbital infection is essential, as these can be severe, with vision- and life-threatening consequences. Extension of an orbital infection can lead to optic neuropathy, endophthalmitis, meningitis and central nervous system involvement. PPT is especially worrisome, as intracranial involvement is a relatively common and dangerous complica-

tion.^{5,8,9} Thrombophlebitis of orbital veins or mechanical compression of the central retinal artery can also cause severe ocular ischemic damage. As in our patient, abscesses can occur in orbital infections, and studies have shown abscesses to be more common in adults than children.^{2,10}

The infection may also cause external pressure on the eye, and our case demonstrates the importance of recognizing the underlying mechanics of this pressure. While a classical orbital compartment syndrome involves a buildup of pressure behind the eye that may be relieved by anterior release with a lateral canthotomy and cantholysis, pressure from an anterior etiology pushing back on the globe, as in our case, may not respond to this approach. In such cases, it's most beneficial to directly address the etiology of anterior pressure with urgent surgical intervention.

Diagnostic imaging may be critical in orbital cellulitis and CT is considered the modality of choice, given its superior bony imaging, speed and availability. Imaging is indicated in all cases of periorbital inflammation where proptosis, ophthalmoplegia, decreased visual acuity, concern for foreign body, neurological signs or lack of improvement over 24 hours with treatment are present.^{2,11} In addition to identifying or ruling out other etiologies of orbital inflammation, imaging may provide information regarding the degree of extension of the infection, including intracranial or cavernous sinus involvement; identify subperiosteal or orbital abscesses; assess for concurrent sinusitis and/or identify foreign bodies in the orbit. In our patient, CT imaging was critical in identifying PPT with findings of infectious erosion through bone from the frontal sinus into the orbit (*Figure 2C*).

In a majority of microbiologi-

cal studies, *Staphylococcus aureus* and *Streptococcus* species are the most common causative organisms of orbital cellulitis.^{2,11-13} An increasing incidence of methicillin-resistant *Staphylococcus aureus* has been noted and should be factored into antibiotic management.^{2,13} Age is also a significant consideration, as patients younger than 9 years with subperiosteal abscesses are more likely to have single aerobes isolated, while older patients trend towards polymicrobial infection with anaerobes.¹⁴ *Haemophilus influenzae* was once one of the most commonly isolated bacteria in children with orbital cellulitis; however, since the advent of the HiB vaccine in 1990, incidence has sharply declined.^{15,16} *H. influenzae* is considered relatively aggressive, with a higher association with bacteremia and neurological complications. It's been hypothesized that its decline may partially explain the decrease in incidence of neurological complications from orbital cellulitis, as less-virulent bacteria now predominate.^{2,13,17} In immunocompromised or diabetic patients, fungal infections should be considered. Cultures from abscesses and infected sinuses typically provided the highest yield (90 percent) with blood cultures producing low to minimal positive results (0 to 8 percent).^{10,12}

In our patient, *Streptococcus anginosus* was the predominant organism. *S. anginosus* falls into a subgroup of *S. viridans* and is considered normal flora of the human oral cavity and gastrointestinal tract. Despite this, *S. anginosus* is known for its pathogenicity and propensity for abscess formation with aggressive pyogenic invasion of tissue including the CNS, head, neck and thorax.¹⁸ In one genetic analysis of *S. anginosus* isolates, numerous virulence factors shared with *S. pyogenes* were identified in-

Akorn Consumer Health	41
Phone (800) 579-8327 www.akornconsumerhealth.com	
Akorn Pharmaceuticals	5
Phone (800) 932-5676 www.akorn.com	
Alcon Laboratories	2, 3
Phone (800) 451-3937 Fax (817) 551-4352	
Bausch + Lomb	9, 10, 23
Phone (800) 323-0000 Fax (813) 975-7762	
Beaver-Visitec International, Inc.	7
Phone (866) 906-8080 Fax (866) 906-4304 www.beaver-visitec.com	
Compulink	17
Phone (800) 456-4522 www.compulinkadvantage.com	
Glaukos	13
Phone (800) 452-8567 www.glaukos.com	
Keeler Instruments	67
Phone (800) 523-5620 Fax (610) 353-7814	
Lacrimedics, Inc.	19
Phone (800) 367-8327 Fax (253) 964-2699 info@lacrimedics.com www.lacrimedics.com	
Lombart Instruments	29
Phone (800) 446-8092 Fax (757) 855-1232	
New World Medical, Inc.	27
Phone (800) 832-5327 Fax (909) 466-4305 www.newworldmedical.com	
NuSight Medical Operations	43, 45
Phone (833) 468-5437 www.NuSightMedical.com	
Oculus, Inc.	39
Phone (888) 284-8004 Fax (425) 867-1881	
Omeros	15
Phone (206) 676-5000 Fax (206) 676-5005	
Regeneron Pharmaceuticals, Inc.	25
Phone (914) 847-7000 www.regeneron.com	
Reichert Technologies	35, 37
Phone (888) 849-8955 Fax (716) 686-4545 www.reichert.com	
S4OPTIK	31, 33
Phone (888) 224-6012	
Shire Ophthalmics	68
www.shire.com	

This advertiser index is published as a convenience and not as part of the advertising contract. Every care will be taken to index correctly. No allowance will be made for errors due to spelling, incorrect page number, or failure to insert.

cluding genes for antibiotic resistance, superantigens and DNase.¹⁹ In one study of 104 patients with complications from sinusitis ranging from orbital cellulitis to cavernous sinus thrombosis and intracerebral abscesses, *S. anginosus* was the most commonly isolated organism.²⁰ Interestingly, several case series of orbital cellulitis have identified *S. anginosus* as the most commonly isolated pathogen.^{21,22} However, in one review of 32 cases with PPT, only two cases isolated *S. anginosus* and neither case involved the orbit.⁸ Clinically, *S. anginosus* infection responds well to cephalosporins, but the potential for resistance exists, and timely surgical drainage is often required.¹⁸

Rapid institution of IV antibiotics with appropriate surgical drainage is the mainstay of treatment for orbital cellulitis and Pott's puffy tumor. Antibiotic therapy may be guided by local sensitivities, but typically a broad-spectrum antibiotic such as a third-generation cephalosporin with consideration for anaerobic and MRSA coverage is an appropriate initial therapy.² Surgical drainage of orbital and subperiosteal abscesses in orbital cellulitis is often necessary, especially when more severe signs are present, such as decreased vision, pupillary changes, increased IOP or failure to respond to treatment, or in the presence of an orbital foreign body. PPT almost always requires surgical intervention.⁵ A multidisciplinary approach with functional endoscopic sinus surgery is also typically indicated in cases of PPT or orbital cellulitis with significant concurrent bacterial sinusitis. **REVIEW**

- Murphy C, Livingstone I, Foot B, Murgatroyd H, MacEwen CJ. Orbital cellulitis in Scotland: Current incidence, aetiology, management and outcomes. *Br J Ophthalmol*. 2014;98:11:1575-1578.
- Tsirouki T, Dastiridou AI, Ibanez Flores N, et al. Orbital cellulitis. *Surv Ophthalmol* 2017 Dec 15. [epub ahead of print]
- Kloek CE, Rubin PA. Role of inflammation in orbital cellulitis. *Int Ophthalmol Clin* 2006;46:2:57-68.
- Flamm ES. Percivall Pott: An 18th century neurosurgeon. *J Neurosurg* 1992;76:2:319-326.
- Ketenci I, Unlü Y, Tucer B, Vural A. The Pott's puffy tumor: A

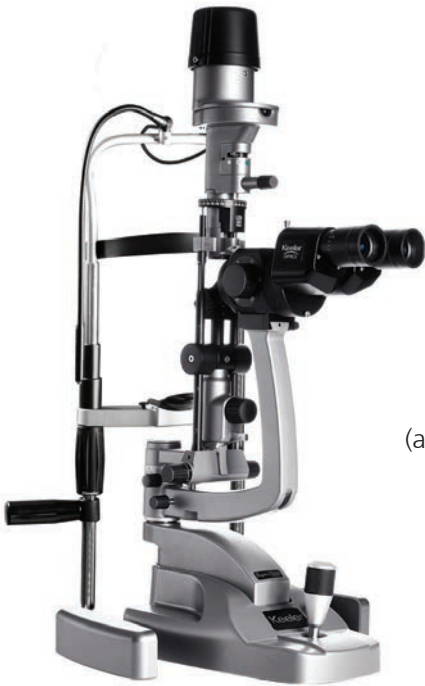dangerous sign for intracranial complications. *Eur Arch Otorhinolaryngol* 2011;268:12:1755-1763.

- Low SA, Hussain A, Gill HS, Monteiro E, Liu ES. Pott's puffy tumour presenting as a necrotic eyelid lesion. *Can J Ophthalmol* 2017;52:1:e25-e28.
- Nisa L, Landis BN, Giger R. Orbital involvement in Pott's puffy tumor: a systematic review of published cases. *Am J Rhinol Allergy* 2012;26:2:e63-70.
- Akiyama K, Karaki M, Mori N. Evaluation of adult Pott's puffy tumor: our five cases and 27 literature cases. *Laryngoscope* 2012;122:11:2382-2388.
- Tsai BY, Lin KL, Lin TY, et al. Pott's puffy tumor in children. *Childs Nerv Syst* 2010;26:1:53-60.
- Ferguson MP, McNab AA. Current treatment and outcome in orbital cellulitis. *Aust N Z J Ophthalmol* 1999;27:6:375-379.
- Chaudhry IA, Shamsi FA, Elzaridi E, et al. Outcome of treated orbital cellulitis in a tertiary eye care center in the Middle East. *Ophthalmology* 2007;114:2:345-354.
- Georgakopoulos CD, Eliopoulou MI, Stasinou S, Exarchou A, Pharmakakis N, Varvarigou A. Periorbital and orbital cellulitis: A 10-year review of hospitalized children. *Eur J Ophthalmol* 2010;20:6:1066-1072.
- Pandian DG, Babu RK, Chaitra A, Anjali A, Rao VA, Srinivasan R. Nine years' review on preseptal and orbital cellulitis and emergence of community-acquired methicillin-resistant *Staphylococcus aureus* in a tertiary hospital in India. *Indian J Ophthalmol* 2011;59:6:431-435.
- Harris GJ. Subperiosteal abscess of the orbit. Age as a factor in the bacteriology and response to treatment. *Ophthalmology* 1994;101:3:585-595.
- Ambati BK, Ambati J, Azar N, Stratton L, Schmidt EV. Periorbital and orbital cellulitis before and after the advent of *Haemophilus influenzae* type B vaccination. *Ophthalmology* 2000;107:8:1450-1453.
- Donahue SP, Schwartz G. Preseptal and orbital cellulitis in childhood. A changing microbiologic spectrum. *Ophthalmology* 1998;105:10:1902-1905;discussion 1905-1906.
- Amin N, Syed I, Osborne S. Assessment and management of orbital cellulitis. *Br J Hosp Med (Lond)* 2016;77:4:216-220.
- Sunwoo BY, Miller WT. *Streptococcus anginosus* infections: Crossing tissue planes. *Chest* 2014;146:4:e121-e125.
- Babbar A, Kumar VN, Bergmann R, et al. Members of a new subgroup of *Streptococcus anginosus* harbor virulence related genes previously observed in *Streptococcus pyogenes*. *Int J Med Microbiol* 2017;307:3:174-181.
- Oxford LE, McClay J. Complications of acute sinusitis in children. *Otolaryngol Head Neck Surg* 2005;133:1:32-37.
- Quintanilla-Dieck L, Chinnadurai S, Goudy SL, Virgin FW. Characteristics of superior orbital subperiosteal abscesses in children. *Laryngoscope* 2017;127:3:735-740.
- Seltz LB, Smith J, Durairaj VD, Enzenauer R, Todd J. Microbiology and antibiotic management of orbital cellulitis. *Pediatrics* 2011;127:3:e566-572.

The Keeler³ Trade In Program

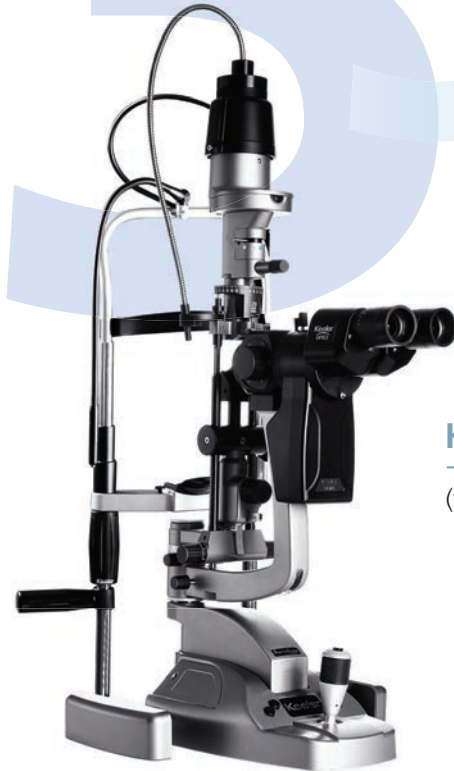Buy 3 // Trade 3 // Get 1 Free

The Power of 3. Purchase any 3 Keeler Slit Lamps and trade in 3 of your old Slit Lamps and we'll send you a 4th Keeler Slit Lamp absolutely free of charge.



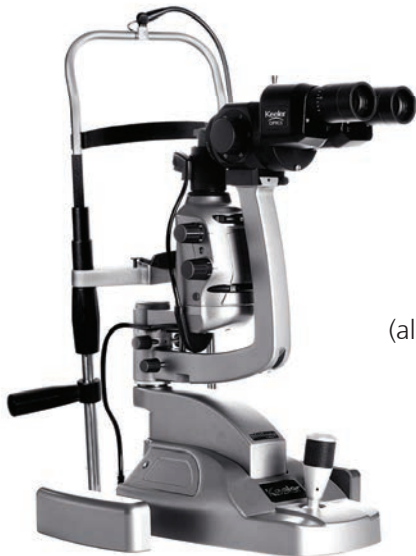KSL-H

(also in Digital Ready)



KSL-H-D

(full Digital)



KSL-Z

(also in Digital Ready)



KSL-H-D

(full Digital)

Keeler
OPTICS

Keeler Instruments, Inc. • 3222 Phoenixville Pike, bldg. 50 • Malvern, PA 19355
Tel: (800) 523-5620 • Fax: (610) 353-7814 • email: keeler@keelerusa.com

Offer valid until September 30, 2018.

Contact Keeler or one of our authorized dealers for more information.



the results are in,
and they're eye-opening

just about
half of those with
dry eye
symptoms

said they'd

give up time with their
friends

before

they'd give up their



Surprised? See the rest of the survey results.
myeyelove-ecp.com



About the survey

The survey was conducted online within the United States by Edelman Intelligence on behalf of Shire between November 14, 2017 and December 3, 2017. The consumer arm of the survey included a total of 1,001 U.S. adults ages 18+ with self-reported Dry Eye symptoms or diagnosed with Dry Eye, and the professional arm of the survey included 1,000 eye care professionals in the U.S. who are optometrists (n=500) or ophthalmologists (n = 500) (ECPs).

