

HIGH-TECH IOLs IN THE PIPELINE P. 12 • LVC IN COLLAGEN VASCULAR DISEASE P. 22
DIGGING DEEPER INTO PROTOCOL U P. 60 • REVIEWING THE LATEST LITERATURE P. 64
DIAGNOSING EARLY GLAUCOMA P. 66 • WILLS RESIDENT CASE REPORT P. 71

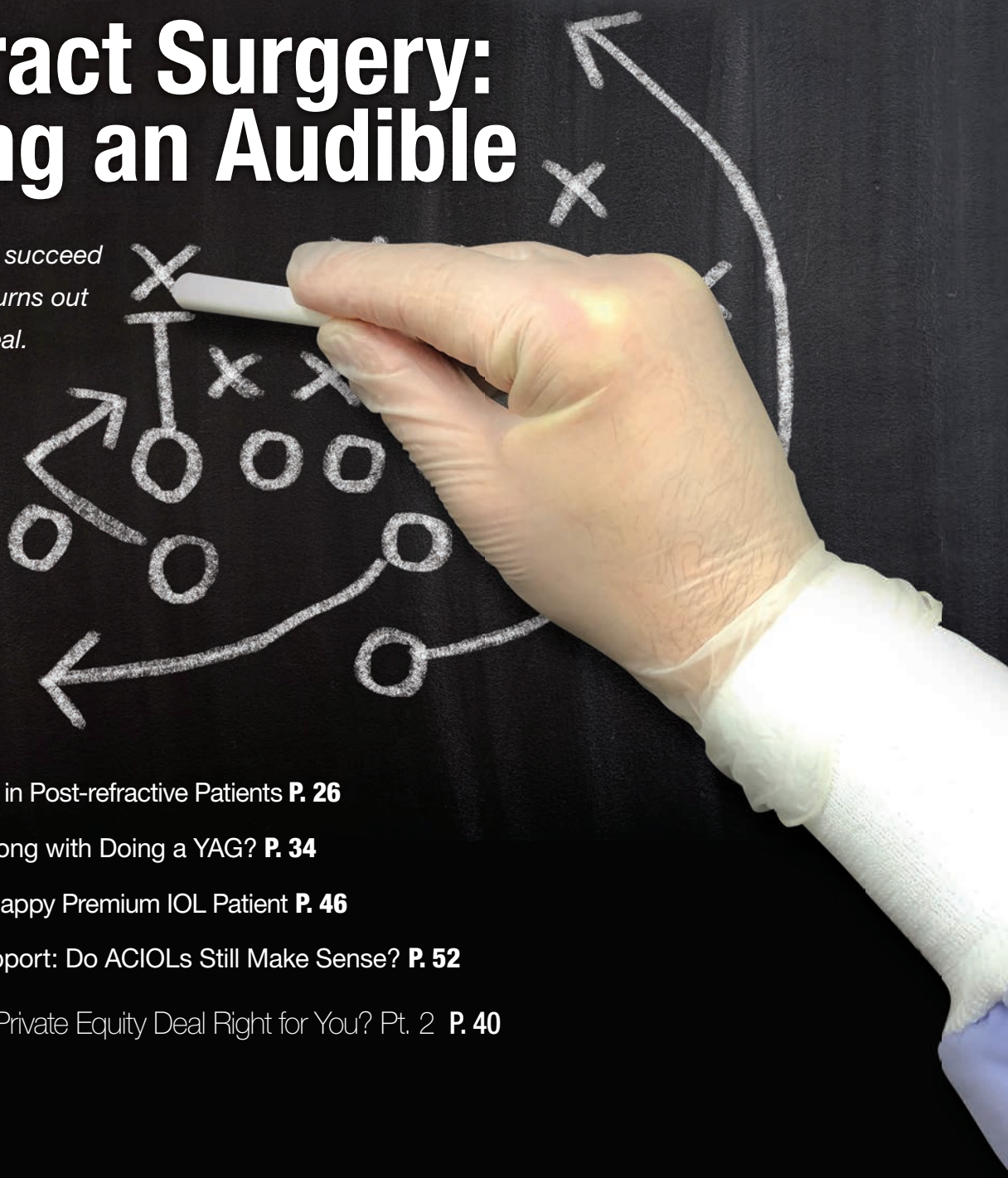
REVIEW[®] of Ophthalmology

reviewofophthalmology.com

May 2018

Cataract Surgery: Calling an Audible

*How to adapt and succeed
when a situation turns out
to be less than ideal.*



- Planning Surgery in Post-refractive Patients **P. 26**
- PCO: What's Wrong with Doing a YAG? **P. 34**
- Handling the Unhappy Premium IOL Patient **P. 46**
- No Capsular Support: Do ACIOLs Still Make Sense? **P. 52**

ALSO INSIDE: Is a Private Equity Deal Right for You? Pt. 2 **P. 40**

JUST GO

The CATALYS® System

TAKE THE
FAST TRACK
TO SURGICAL
EXCELLENCE

MAKE YOUR MOVE

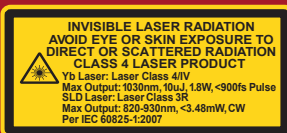

CATALYS®
Precision Laser System

INDICATIONS AND IMPORTANT SAFETY INFORMATION FOR THE CATALYS® PRECISION LASER SYSTEM

Rx Only

INDICATIONS: The OptiMedica® CATALYS® Precision Laser System is indicated for use in patients undergoing cataract surgery for removal of the crystalline lens. Intended uses in cataract surgery include anterior capsulotomy, phacofragmentation, and the creation of single-plane and multi-plane arc cuts/incisions in the cornea, each of which may be performed either individually or consecutively during the same procedure. **CONTRAINDICATIONS:** Should not be used in patients with corneal ring and/or inlay implants, severe corneal opacities, corneal abnormalities, significant corneal edema or diminished aqueous clarity that obscures OCT imaging of the anterior lens capsule, patients younger than 22 years of age, descemetocele with impending corneal rupture, and any contraindications to cataract surgery. **IMPORTANT SAFETY INFORMATION:** Mild petechiae and subconjunctival hemorrhage can occur due to vacuum pressure of the suction ring. Potential complications and adverse events include any of those generally associated with cataract surgery. **CAUTION:** Should be used only by qualified physicians who have extensive knowledge of the use of this device and have been trained and certified by Abbott Medical Optics/OptiMedica. **ATTENTION:** Reference the labeling for a complete listing of Important Indications and Safety Information.



AMD Patients Recover Vision After Stem Cell Treatment

In a clinical trial designed as a Phase I, open-label, safety and feasibility study, researchers from London studied the implantation of a human embryonic stem cell (hESC) retinal pigment epithelium patch in two patients with acute wet age-related macular degeneration and recent rapid vision decline. They reported their primary and secondary outcomes from the first two patients of the series in an article published in the journal *Nature Biotechnology* in March. Based on the results, the researchers say that this stem-cell-based tissue transplantation is a potentially effective strategy for treating neurodegenerative diseases with otherwise irreversible cell loss.

The researchers used a surgical delivery tool to place one RPE patch in the subretinal space, under the fovea, in the affected eye of each patient. They verified its placement with stereo-biomicroscopy, fundus photography and spectral domain optical coherence tomography.

For both patients, hESC-RPE was present over the full area of the patch at 12 months. The patches showed uneven autofluorescence, which the researchers say suggests functioning RPE phagocytosis. The investigators add that the patients also presented with darker-pigmented areas contiguous with the patch, which may represent RPE cell migration from the patch onto adjacent RPE-deficient areas. These areas spread from the patch edge outward over the first six months after surgery.

The researchers observed visual re-

covery in both cases. The Early Treatment Diabetic Retinopathy Study letter chart was used to define best-corrected vision, which improved over 12 months from 10 to 39 and from 8 to 29 letters in patients one and two, respectively. There was no increase in intraocular pressure in either patient.

Lyndon da Cruz, PhD, FRCOphth, FRACO, one of the study's authors, says the treatment may home in on the ocular anatomy that's crucial for a good outcome. "In AMD, the primary part of the eye that's affected is the retinal pigment epithelium," he notes. "If that's damaged but the rest of the structures remain the same, what we've been able to do is replace it with a perfect copy we've grown in the laboratory. That's the breakthrough. Theoretically, this could conceivably work for any disease where it is isolated in that layer and all other [layers] remain the same.

"Now because this is our first test of this in humans, we're taking a select group that has very sudden or severe vision loss, so that if it doesn't work, there's no vision loss involved," Dr. da Cruz continues. "But if it does work, then we have these great visual recoveries. This is what we've been able to achieve while showing the proof-of-principle. It's a lower risk to patients and a clear-cut signal that the transplant of the layer works because they have a visual recovery. We were able to replace the damaged layer of the retina."

Dr. da Cruz says patients with sudden vision loss were a key part of the

study's design. "We're looking at severe or sudden vision loss because due to its sudden nature—they were able to see the day before—we know all the ocular structures must be intact," he says. "We know that the disease is centered in this area. These conditions are optimal for the particular type of transplant that we're doing. Specifically, we want to look at patients with sudden vision loss with a large hemorrhage or a pigment epithelial tear. When they present, we can resolve whatever has happened to cause their sudden vision loss, while sliding the patch into the layer so we can also recover their vision. However, we also know if you leave the bleeding—or whatever the problem is—for six to eight weeks, the rest of the layers will be damaged, so there's a small window right after they've suddenly lost their vision during which we can perform this procedure."

Dr. da Cruz is excited about the future of the study. "The first cases are the hardest," he says. "We'd like to do more in order to show that this is as reproducible as the first two patients. We want to show this works, then go on to a more definitive study involving a control group and maybe look at a licensing study. We'd also want to look at a broader array of patient groups, maybe including people with early dry macular degeneration or, in some cases, we may look at patients with early inherited retinal dystrophies and then run a pilot study to see if there's any chance this implant will work for them, as well." **REVIEW**

Drug Repurposing: A Case Study of Accelerated Development

As a new physician-entrepreneur, you may have an idea for targeting a specific pharmacologic mechanism and are weighing your options regarding which type of lead drug to focus on: You can synthesize a new chemical entity and take advantage of fresh intellectual property on a novel composition of matter; license and repurpose an approved medication; use a known compound available generically; or make use of an existing platform that's being developed by another company for other, non-ocular indications. Discussions of repurposing are relevant in ophthalmology, due to the diverse disease mechanisms seen in the eye. Furthermore, since most ophthalmic drugs are administered locally, generally speaking, the systemic exposure to these agents is well within the safety margins of the toxicology identified in studies of the drugs' other indications. This makes repurposing one of these agents an attractive option.

In prior columns, we've analyzed examples of some of the options listed above. This month, we'll look at the case of licensing the ocular rights for a drug in development for non-ocular indications but which isn't yet FDA-approved for those other indications. Along the way, we'll also examine some key considerations that we've encountered in such cases, and describe a current example of a program currently in development.

Review of Regulations

First, let's look at a few key regulatory considerations when taking a repurposing approach.

Section 505 of the Food, Drug and Cosmetic Act outlines three types of new drug applications: 1) A New Drug Application that contains full reports of investigations of safety and effectiveness; 2) an application where at least some of the information required for approval comes from studies not conducted by or for the applicant and for which the applicant has not obtained a right of reference [section 505(b)(2)]; and 3) an application for a generic drug that

shows the proposed product is identical to a previously approved product [section 505(j)].

We've looked at the 505(b)(2) approach previously, but there are different cases where reference to other regulatory files come into play that are treated differently. A 505(b)(2) application can rely on information from published literature or the FDA's previous finding of safety and/or effectiveness for an approved product. One key difference to understand when planning a filing strategy is that, according to its purpose, a 505(b)(2) can help avoid duplication of data that already exists but also requires the applicant to provide notice of certain patent information to the NDA holder and patent owner for the product(s) being referenced. Sometimes there's an option to pursue either a full NDA or 505(b)(2), and there are multiple factors influencing that



decision, one of which is the intellectual property disclosure requirement.

How does a 505(b)(2) relate to a product that's not yet approved but which is being developed for another indication (or a study that's already been terminated)? An example of this is a situation in which key information is referenced from a publication that the applicant doesn't own or have *right of reference* to (right of reference refers to the ability to refer to studies of a drug conducted by someone else). Even though the approach to this situation is clearly outlined in an FDA Guidance Document [FDA Guidance: Applications Covered by Section 505(b)(2)], we raise the point here because we've received questions about how to reference information from programs in which an IND was active for a non-ophthalmic indication but the product wasn't

FDA-approved. In this situation, one can't simply ask the FDA to rely on these other findings of safety and/or efficacy, because that product is not yet approved and hasn't been fully reviewed and deemed safe. To use that data in a development program for a product not yet approved, you need a right of reference with the other applicant.

Case Example: Okogen

The Okogen experience is a great example of a company leveraging the right-to-reference approach. Okogen has been successful in recognizing and forming a plan around an unmet need (viral conjunctivitis), identifying a drug with a novel approach to a non-ocular indication currently in development, securing funding, and moving a program towards Phase II trials. A large part of its strategy and success in securing funding was leveraging the ability to reference a product from a separate indication in order to reduce the risk involved with pursuing approval of the drug, and to accelerate its advance to a clinical trial.

Okogen was founded by a small team of industry veterans. With firsthand experience in business development at Allergan and Shire, Chief Executive Officer Brian M. Strem saw a large unmet need in viral conjunctivitis, and precedents for deal structures in that arena. The company's lead drug is based on the active pharmaceutical ingredient ranpirnase, a low-molecular-weight protein extracted from the eggs of *Rana pipiens* (northern leopard frog). Ranpirnase preferentially enters into the cytoplasm of virally infected cells due to electrostatic interactions, halts protein synthesis by targeted degradation of mammalian tRNA, blocks NFκB (pro-inflammatory) downstream signaling, and induces cellular apoptosis. These mechanisms drive inhibition of viral replication, reduce inflammation and induce virally-infected cell death. This triple mechanism of activity contributes to the ultimate target product profile, reducing viral burden and subsequent length of contagion, and acceleration of sign-and-symptom resolution.

Ranpirnase was initially developed as an intravenous anti-cancer drug, Onconase, and, as such, its preclinical safety fully

supported clinical trials in cancer patients through Phase III. Unfortunately, it missed the primary efficacy endpoint in the second of the global Phase IIIb trials in patients with unresectable malignant mesothelioma, and the oncology program was discontinued. Alfacell, the sponsor of those studies, was restructured into Tamir Biotechnology. Prior to restructuring, scientists had identified the broad-spectrum antiviral potential of ranpirnase and the new management team at Tamir is leading the effort to develop ranpirnase as the first approved antiviral for human papillomavirus genital warts.

The company had demonstrated efficacy in preclinical models against a wide range of viruses, including adenovirus. Okogen identified the opportunity for repurposing it, and licensed the ocular use for ranpirnase, effectively using existing IP for methods for treating viral infections. As part of that arrangement, Tamir has granted Okogen full rights of reference to existing data and regulatory filings, including preclinical studies, as well as the safety data collected from all clinical studies completed with the IV drug. The existing information on genotoxicity and toxicology following systemic administration was used to support the assertion of a reasonable safety margin based on absorption from ocular dosing. With the additional toxicology work, per Good Laboratory Practices, done by Okogen for ocular dosing, the ocular studies then completed the package as a basis for initiating the Phase II trial.

Another question that comes up is whether or not non-GLP systemic studies from the reference program can be used. In order for prior work to be useful, and to definitely avoid the need to repeat studies, those systemic studies need to have been conducted as per GLP regulations, unless there's a specific justification to deviate from GLP. (Cost savings isn't an acceptable justification for the FDA.) Make sure to verify that GLP was observed in the studies if you're considering referencing other work.

For a new drug, the FDA usually requires ocular toxicology from two species. In the context of repurposing a drug, however, the question of whether the agency will accept the IND with ocular toxicology from just one species depends on the situation. Unless there's a specific justification, if the reference drug isn't yet approved for other purposes, then you will most likely need two species for GLP ocular toxicology. So, it's best to plan for the use of two species until the FDA confirms otherwise.

As we've discussed in previous columns, there's a benefit to having an early pre-IND meeting with the FDA in order to help refine budgets for the IND-enabling work. Typically, it's most useful to include in the pre-IND package a description of the intended final formulation and a justification of how you plan to bridge the ocular use to the already completed toxicology safety data derived from systemic dosing. The latter may require some preliminary, possibly non-GLP, data on systemic absorption following ocular dosing. Having such data ensures that the FDA has enough information to provide you with complete responses and guidance that can help you plan and budget your remaining IND-enabling activities.

In the case of Okogen, in addition to safety information, since ranpirnase had previously been in clinical trials under an IND, significant chemistry, manufacturing and control information was also available for use, including the other company's analytical methods, manufacturing process and specifications. Further, as new inventions are generated, Okogen is building its own, wholly-owned IP portfolio, providing multiple layers of patent protection.

Conclusions

In our ongoing survey of business issues and case studies within the industry, the case of Okogen demonstrates the successful referencing of a drug from a previously failed systemic program. Because it was able to structure and execute a license for the drug and relevant data package for repurposing, it realized significant cost savings in its development program, and with Okogen's recent \$10 million financing round, the company's able to deploy funds and rapidly move toward a Phase II trial.

Ultimately, it's important to understand the best way to reference prior data, whether it's from an existing approved drug (with or without right to reference), a primary peer-reviewed publication, or from another ongoing development program. Early interaction with the FDA can help clarify the proper path to approval and confirm which parts of a development program you can avoid.

Mr. Chapin is senior vice president of corporate development at Ora Inc. The author welcomes your comments and questions regarding product development. Send correspondence to mchapin@oraclinical.com or visit www.oraclinical.com.

Editor in Chief

Walter C. Bethke

(610) 492-1024

wbethke@jobson.com

Senior Editor

Christopher Kent

(814) 861-5559

ckent@jobson.com

Senior Associate Editor

Kristine Brennan

(610) 492-1008

kbrennan@jobson.com

Associate Editor

Liam Jordan

(610) 492-1025

ljordan@jobson.com

Chief Medical Editor

Mark H. Blecher, MD

Art Director

Jared Araujo

(610) 492-1032

jaraujo@jobson.com

Senior Graphic Designer

Matt Egger

(610) 492-1029

megger@jobson.com

International coordinator, Japan

Mitz Kaminuma

Reviewophthalmo@aol.com

Business Offices

11 Campus Boulevard, Suite 100

Newtown Square, PA 19073

(610) 492-1000

Fax: (610) 492-1039

Subscription inquiries:

United States — (877) 529-1746

Outside U.S. — (845) 267-3065

E-mail:

revophthalmology@cambeywest.com

Website: www.reviewofophthalmology.com



CONTRIBUTORS

CHIEF MEDICAL EDITOR

Mark H. Blecher, MD

CONTACT LENSES

Penny Asbell, MD

CORNEA / ANTERIOR SEGMENT

Thomas John, MD

GLAUCOMA MANAGEMENT

Peter Netland, MD, PHD
Kuldev Singh, MD

MASTERS OF SURGERY

Taliva D. Martin, MD
Sara J. Haug, MD, PhD

MEDICARE Q & A

Paul M. Larson, MBA

PEDIATRIC PATIENT

Wendy Huang, MD

PLASTIC POINTERS

Ann P. Murchison, MD, MPH

REFRACTIVE SURGERY

Arturo S. Chayet, MD

RETINAL INSIDER

Carl Regillo, MD, FACS
Emmett T. Cunningham Jr., MD, PHD, MPH

TECHNOLOGY UPDATE

Steven T. Charles, MD
Michael Colvard, MD

WILLS RESIDENT CASE SERIES

Thomas Jenkins, MD

ADVISORY BOARD

PENNY A. ASBELL, MD, NEW YORK CITY

WILLIAM I. BOND, MD, PEKIN, ILL.

ALAN N. CARLSON, MD, DURHAM, N.C.

Y. RALPH CHU, MD, EDINA, MINN.

ADAM J. COHEN, MD, DOWNERS GROVE, ILL.

UDAY DEVGAN, MD, FACS, LOS ANGELES

ERIC DONNENFELD, MD, ROCKVILLE CENTRE, N.Y.

DANIEL S. DURRIE, MD, KANSAS CITY, MO.

ROBERT EPSTEIN, MD, MCHENRY, ILL.

ROBERT D. FECHTNER, MD, NEWARK, N.J.

WILLIAM J. FISHKIND, MD, TUCSON, ARIZ.

JAMES P. GILLS, MD, TARPON SPRINGS, FLA.

HARRY GRABOW, MD, SARASOTA, FLA.

DOUGLAS K. GRAYSON, MD, NEW YORK CITY

THOMAS S. HARBIN, MD, MBA, ATLANTA

DAVID R. HARDTEN, MD, MINNEAPOLIS

KENNETH J. HOFFER, MD, SANTA MONICA, CALIF.

JACK T. HOLLADAY, MD, MSEE, HOUSTON

JOHN D. HUNKELER, MD, KANSAS CITY, MO.

THOMAS JOHN, MD, TINLEY PARK, ILL.

ROBERT M. KERSHNER, MD, MS, FACS, BOSTON

GUY M. KEZIRIAN, MD, PARADISE VALLEY, ARIZ.

TERRY KIM, MD, DURHAM, N.C.

TOMMY KORN, MD, SAN DIEGO

DAVID A. LEE, MD, HOUSTON

FRANCIS S. MAH, MD, PITTSBURGH

NICK MAMALIS, MD, SALT LAKE CITY

WILLIAM G. MARTIN, MD, OREGON, OHIO

MIKE S. MCFARLAND, MD, PINE BLUFF, ARK.

JEFFREY B. MORRIS, MD, MPH, ENCINITAS, CALIF.

MARLENE R. MOSTER, MD, PHILADELPHIA

ROBERT J. NOECKER, MD, FAIRFIELD, CONN.

ROBERT OSHER, MD, CINCINNATI

MARK PACKER, MD, WEST PALM BEACH, FLA.

STEPHEN PASCUCCI, MD, BONITA SPRINGS, FLA.

PAUL PENDER, MD, BEDFORD, N.H.

CHRISTOPHER J. RAPUANO, MD, PHILADELPHIA

AUGUST READER III, MD, SAN FRANCISCO

TONY REALINI, MD, MORGANTOWN, W.V.

KENNETH J. ROSENTHAL, MD, GREAT NECK, N.Y.

ERIC ROTHCHILD, MD, DELRAY BEACH, FLA.

SHERI ROWEN, MD, BALTIMORE

JAMES J. SALZ, MD, LOS ANGELES

INGRID U. SCOTT, MD, MPH, HERSHEY, PA.

JOEL SCHUMAN, MD, PITTSBURGH

GAURAV SHAH, MD, ST. LOUIS

DAVID R. STAGER JR., MD, DALLAS

KARL STONECIPHER, MD, GREENSBORO, N.C.

JAMES C. TSAI, MD, NEW YORK CITY

VANCE THOMPSON, MD, SIOUX FALLS, S.D.

FARRELL C. TYSON, MD, CAPE CORAL, FLA.

R. BRUCE WALLACE III, MD, ALEXANDRIA, LA.

ROBERT G. WILEY, MD, CLEVELAND

FRANK WEINSTOCK, MD, CANTON, OHIO

BUSINESS OFFICES

11 CAMPUS BOULEVARD, SUITE 100
NEWTOWN SQUARE, PA 19073
SUBSCRIPTION INQUIRIES (877) 529-1746
(USA ONLY); OUTSIDE USA, CALL (847) 763-9630

BUSINESS STAFF

PUBLISHER

JAMES HENNE

(610) 492-1017 JHENNE@JOBSON.COM

REGIONAL SALES MANAGER

MICHELE BARRETT

(610) 492-1014 MBARRETT@JOBSON.COM

REGIONAL SALES MANAGER

MICHAEL HOSTER

(610) 492-1028 MHOSTER@JOBSON.COM

CLASSIFIED ADVERTISING

(888)-498-1460

VICE PRESIDENT OF OPERATIONS

CASEY FOSTER

(610) 492-1007 CFOSTER@JOBSON.COM

PRODUCTION MANAGER

SCOTT TOBIN

(610) 492-1011 STOBIN@JOBSON.COM

SUBSCRIPTIONS

\$63 A YEAR, \$99 (U.S.) IN CANADA,
\$158 (U.S.) IN ALL OTHER COUNTRIES.

SUBSCRIPTIONS E-MAIL:

REVOPHTHALMOLOGY@CAMBEYWEST.COM

CIRCULATION

PO BOX 71, CONGERS, NY 10920-0071
(877) 529-1746

OUTSIDE USA: (845) 267-3065

SENIOR CIRCULATION MANAGER

HAMILTON MAHER

(212) 219-7870 hmaher@jhihealth.com

CEO, INFORMATION GROUP SERVICES

MARC FERRARA

SENIOR VICE PRESIDENT, OPERATIONS

JEFF LEVITZ

VICE PRESIDENT, HUMAN RESOURCES

TAMMY GARCIA

VICE PRESIDENT, CREATIVE SERVICES & PRODUCTION

MONICA TETTAMANZI

CORPORATE PRODUCTION DIRECTOR

JOHN ANTHONY CAGGIANO

VICE PRESIDENT, CIRCULATION

EVELDA BAREA



440 Ninth Avenue, 14th Floor
New York, N.Y. 10001

REVIEW OF OPHTHALMOLOGY (ISSN 1081-0226; USPS No. 0012-345) is published monthly, 12 times per year by Jobson Medical Information, 440 Ninth Avenue, 14th Floor, New York, N.Y. 10001. Periodicals postage paid at New York, NY and additional mailing offices. Postmaster: Send address changes to Review of Ophthalmology, PO Box 71, Congers, NY 10929-0071. Subscription Prices: US One Year \$63.00, US Two Year \$112.00, Canada One Year \$99.00, Canada Two Year \$181.00, Int'l One Year \$158.00, Int'l Two Year \$274.00. For subscription information call (877) 529-1746 (USA only); outside USA, call (845)-267-3065. Or email us at revophthalmology@cambeywest.com. Canada Post: Publications Mail Agreement #40612608. Canada Returns to be sent to Bleuchip International, P.O. Box 25542, London, ON N6C 6B2.

E

V E R Y

D O S E

C O U N T S

STRIVE TO SEE THE BEST RESULTS POSSIBLE

Regular fixed-interval dosing of long-term treatment with anti-VEGFs has been shown to provide better gains and maintenance of vision, compared to PRN or treat-and-extend dosing regimens, in some patients with Wet AMD and DME.¹⁻⁶

Ask your Regeneron representative what we can do to help ensure patients come in for their scheduled treatment.

anti-VEGF = anti-vascular endothelial growth factor; AMD = Age-related Macular Degeneration; DME = Diabetic Macular Edema.

References: 1. Heier JS et al. *Ophthalmology*. 2016;123(11):2376-2385. 2. Rosenfeld PJ et al. *N Engl J Med*. 2006;355(14):1419-1431. 3. Ho AC et al. *Ophthalmology*. 2014;121(11):2181-2192. 4. Nguyen QD et al. *Ophthalmology*. 2012;119(4):789-801. 5. Kaiser PK et al. *Ophthalmol Retina*. 2017;1(4):304-313. 6. Peden MC et al. *Ophthalmology*. 2015;122(4):803-808.

REGENERON

© 2018, Regeneron Pharmaceuticals, Inc. All rights reserved.
777 Old Saw Mill River Road, Tarrytown, NY 10591

01/2018 US-OPH-13911

REVIEW[®] of Ophthalmology

May 2018 • Volume XXV No. 5 | reviewofophthalmology.com

Cover Focus

- 
- 26 | Planning for the Best Outcomes**
Kristine Brennan, Senior Associate Editor
Do more than just hope for them with intelligent cataract surgery planning for post-refractive eyes.
- 34 | PCO: What's Wrong with Doing a YAG?**
Leslie Sabbagh, Contributing Editor
A lot of effort is being devoted to avoiding PCO, but some surgeons say a YAG isn't that bad.
- 46 | Handling Unhappy Premium IOL Patients**
Asim Piracha, MD
An ounce of prevention is worth a pound of cure, says this surgeon.
- 52 | No Capsular Support: Do ACIOLs Still Make Sense?**
Christopher Kent, Senior Editor
New alternatives have surgeons shying away from ACIOLs, but there's still a place for them.

Feature Article

- 40 | Is Private Equity Right for You? (Pt 2)**
Christopher Kent, Senior Editor
Surgeons and business experts answer doctors' key questions. (Part two of two.)

Departments

3 | [Review News](#)

12 | [Technology Update](#)

High-tech IOL Options in the Pipeline

Three revolutionary ideas may help to raise the bar for post-surgery refractive outcomes.

22 | [Refractive/Cataract Rundown](#)

Is LVC Possible in CVD Patients?

Collagen vascular disease may not always be a bar for carefully selected patients.

60 | [Retinal Insider](#)

Digging Deeper into Protocol U

The DRCR Network's study of two treatments for DME revealed the pros and cons of the approaches.

63 | [Product News](#)

New Vitrectomy Cutters Approved

64 | [Research Review](#)

Outcomes of Laser Peripheral Iridotomy

66 | [Glaucoma Management](#)

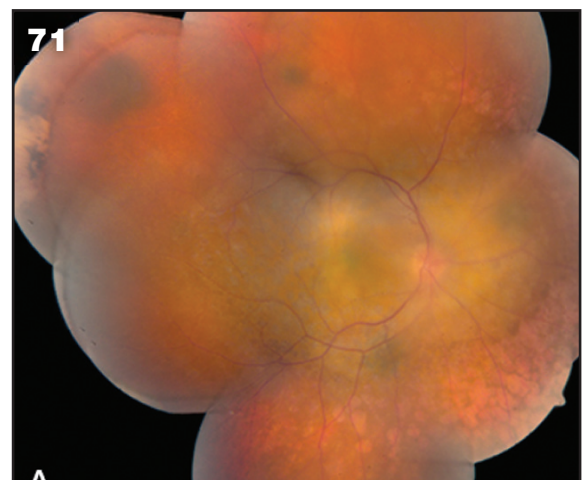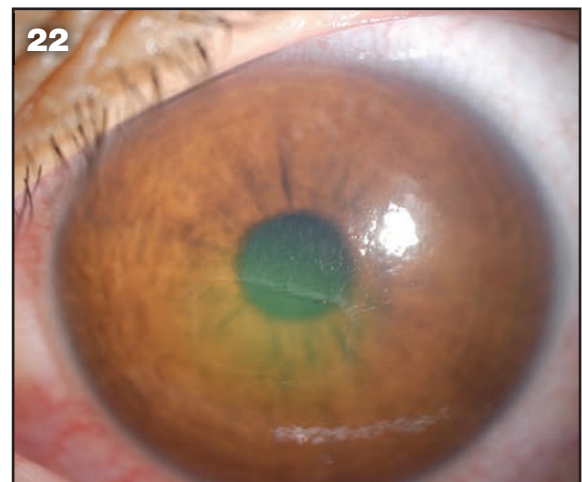

Diagnosing Early Glaucoma: Pearls and Pitfalls

In our ongoing attempts to detect the disease at its earliest stages, new technologies are showing promise.

69 | [Advertising Index](#)

70 | [Classifieds](#)

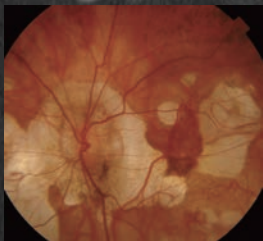
71 | [Wills Eye Resident Case Series](#)



It's time for Triton.

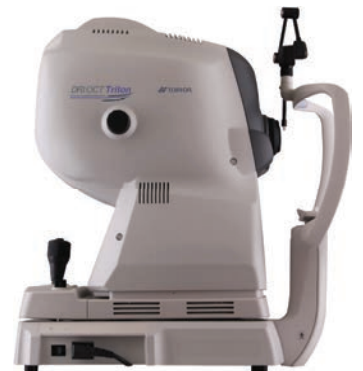It's all about the light source.

FDA CLEARED



SS-OCT

Contact your local Topcon Representative today or visit newsgram.topconmedical.com/triton.



DRI OCT Triton™ Series
A Multimodal Swept Source OCT



New High-Tech IOL Options in the Pipeline

Three revolutionary ideas may help to raise the bar for post-surgery refractive outcomes and patient satisfaction.

Christopher Kent, Senior Editor

As every cataract surgeon knows, getting an ideal refractive outcome when implanting an intraocular lens is a challenge. It's still impossible to know for sure exactly where the implanted lens will end up sitting inside the eye; there are a limited number of options for correcting a poor refractive outcome (should it occur); and addressing presbyopia via a premium implant is far from a sure thing.

Not surprisingly, a number of new technologies that may offer solutions to these problems are in the pipeline. Here, three of the most promising are profiled by surgeons familiar with them.

Postop Refractive Adjustment

One of the most interesting new refractive options under development is the Perfect Lens (Perfect Lens LLC, Irvine, California). Despite its name, the product is not actually an intraocular lens; instead, it's a system that's capable of altering the refractive power of an IOL that's already been implanted inside the eye, using a laser.

The laser system comprises a femtosecond laser and an optical focusing

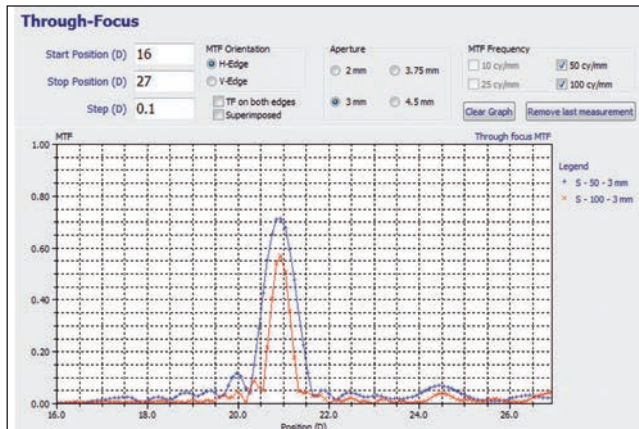
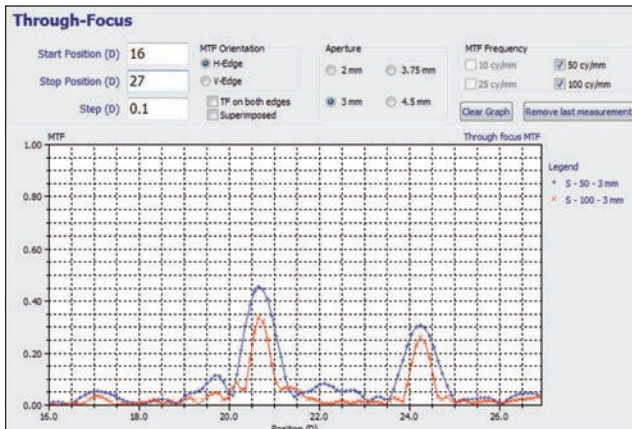
system. Once the focusing system is placed on the eye, the software is able to locate the implanted lens and then direct the laser to a 50- μm area inside the lens, where it makes whatever refractive adjustment is desired without having any disruptive effect on the optical characteristics of the lens, or the comfort or vision of the patient. (According to the company, the laser energy used is far less than the amount required for YAG procedures or cataract surgery.) The goal is to correct refractive errors remaining after the implantation of a lens, or to make other adjustments requested by the patient. Perhaps most remarkable, this technology appears to work on almost any implanted lens, from any manufacturer.

Y. Ralph Chu, MD, founder and medical director of Chu Vision Institute in Bloomington, Minnesota, and adjunct associate professor of ophthalmology at the University of Minnesota, is on the scientific advisory board for Perfect Lens. (He has no financial interest in the technology.) He notes that the version of the technology that he's seen uses a femtosecond laser that's similar to what today's

surgeons use. "The laser has a docking system similar to the cone-based system," he says. "The patient lies down on a bed. There's a unit that stabilizes the eye itself; then the laser docks to a ring, so the eye can be held steady during the procedure. It's a very quick procedure that takes only a few seconds.

"It's almost like creating a lens within a lens," he continues. "The change doesn't add any thickness or alter the shape of the overall lens; instead, it changes the hydrophilicity of the lens. The laser excites certain molecules inside the lens, causing the refractive index to change. The bottom line is, instead of cutting a flap and doing corneal surgery, you just change the power of the lens and you're done. The changes take place inside the eye, so there's no pain, no corneal dryness and no recovery period. Furthermore, it's not specific to just one company's lens. Right now they're working with acrylic lenses, and so far, they can do this with any one of them, including lenses from J&J Vision, Bausch + Lomb, Zeiss and Alcon, among others. That's why it's so exciting."

Dr. Chu says that Ruth Sahler, ex-



The Perfect Lens laser system uses a femtosecond laser to make refractive adjustments to a previously implanted intraocular lens. So far, the process appears to work on lenses from any manufacturer. Changes appear to be extremely precise and can range up to 10 D, and include the ability to change a multifocal to a monofocal, or vice versa. The graphs above show the refractive profile of a multifocal IOL before (left) and after adjustment (right). Lenses can be altered multiple times, and the refractive changes appear to be stable.

ecutive vice president and director of research and development at Perfect Lens, developed the optical pattern system that changes the refraction or dioptric power of the IOL with the assistance of Josef Bille, vice president at the company. “The system is very precise, down to 0.01 D,” Dr. Chu says. “At one point they took about 15 different IOLs and altered their refractions to make them 20 D. The lenses ended up being within 0.01 D of each other. Meanwhile, the process leaves the optical quality of the lens unchanged, so the modulation transfer function curves look excellent. There’s very little degradation.”

Dr. Chu notes that today, the focus in cataract surgery is on getting a precise outcome. “A big part of that has been managing the challenge of predicting where the lens will sit in the bag,” he points out. “That’s challenging because every eye is different. But with this technology, you can simply wait until the foundation for the lens is set and the IOL is settled, and then adjust the power to get the precise outcome you’re trying to achieve.”

Dr. Chu says he’s not aware of any limit to how much the refractive power can be changed. “The data so far suggests the system can make changes of 10 D or more,” he says. “You could

basically put in a 20-D lens in every patient. If the patient needs a 24-D lens, you could make a 4-D adjustment—and it could be made in either direction, plus or minus.

“What may be of particular interest to surgeons is that this technology can reverse multifocality,” he continues. “It can take a monofocal and make it multifocal, or take a multifocal lens and make it monofocal. (See example, above.) It’s like an eraser. This will be a boon to surgeons offering premium lenses such as multifocals because of the difficulty of predicting who will tolerate a multifocal lens. If the patient isn’t happy, we can eliminate the multifocality of the lens. It’s not an IOL exchange; we simply reverse it. Furthermore, I think this capability will be useful for every surgeon that wants to do refractive cataract surgery, even if you don’t offer premium IOLs. If a patient wants to try monovision using monofocal IOLs, you’ll be able to adjust one eye. If they don’t like the result, you can adjust it back.”

Dr. Chu adds that apart from limited space inside the IOL, there’s no apparent limit to how many times a lens can be changed or how far into the future changes can be made. “In the lab they’ve switched refractive power back and forth multiple times,”

he says. “They’ve taken a multifocal and turned it into a monofocal; then back into a multifocal; then back into a monofocal. There’s no time limit that I’m aware of. There’s no leaching of material and no alteration in the adjusted refraction over time, from what they’ve seen in the lab in animals. It’s not like it wears off in a year and then you have to do it again. The lens is solid. You’re just making a change inside the lens, and it stays that way.”

One obvious question is how this technology differs from the Light Adjustable Lens (RxSight) which was recently approved by the U.S. Food and Drug Administration. Dr. Chu says he has no firsthand experience with the LAL, but notes there are significant differences between the two products. “Because of the LAL’s technology, the altered prescription is ‘locked in’ using ultraviolet light,” he notes. “That requires implanting their proprietary lens, then protecting your eyes from UV light with special glasses until the right moment, which could take weeks, and potentially coming back to the office multiple times to lock in the prescription. In contrast, the Perfect Lens technology doesn’t require the patient to wear protective glasses. You simply implant your lens of choice and give it four to six

weeks to stabilize. Then, if the patient desires, you can perform—for lack of a better term—an enhancement to the IOL. The patient just goes about living life, and if you want to change the prescription next month, or six months from now, or 20 years from now, you can do it.”

Dr. Chu says the company is gearing up to begin human trials in the United States. “I believe that will start this year at the University of Utah,” he says. “At the moment the technology is still in the prototype phase, but things are moving forward quickly. I believe any obstacles we encounter will be surmountable, because we’re using two familiar technologies: femtosecond lasers and IOLs. Marrying the two is an exciting prospect.”

A Small-aperture IOL

Most ophthalmologists are familiar with the KAMRA corneal inlay from SightLife Surgical (originally developed by AcuFocus), which works by using the pinhole effect—aka small-aperture optics—to alleviate distortion and expand depth-of-field. AcuFocus has now created a monofocal intraocular lens that uses the same principle to achieve similar refractive results. The IC-8 IOL is a 6-mm-diameter one-piece hydrophobic acrylic lens that incorporates a 3.23-mm doughnut-shaped opaque mask with a central 1.36-mm hole through which light can pass. (*See picture, above right.*) The lens is available in powers of 15.5 to 27.5 D in 0.5-D steps. It’s implanted via a single-use injector through a 3.2- to 3.5-mm incision.

“The IC-8 IOL is an aspheric monofocal IOL that has an opaque mini-ring embedded in it to extend depth-of-focus from near to far without gaps in vision,” says Dr. H. Burkhard Dick, chairman of the University Eye Hospital in Bochum, Germany, and lead investigator of the clinical trials involving the IC-8 IOL. “The lens de-



The IC-8 intraocular lens from AcuFocus uses the pinhole effect to extend depth-of-focus dramatically and compensate for factors such as astigmatism, corneal aberrations and failure to hit the intended post-surgical refractive target.

sign is based on the well-established small-aperture principle; it works by allowing only the central, focused light to reach the retina, removing the blur caused by peripheral defocused light. This results in the highest quality of vision over the broadest continuous range of any premium IOL currently available. It provides up to 3 D of range-of-vision with excellent visual quality, providing relief from presbyopia. Currently, the IC-8 IOL is implanted monocularly, usually in the nondominant eye. Binocular implantation has been done in a small

cohort of patients, and work is being done to optimize this option for surgeons and patients.”



Dr. Dick says a recent multicenter study of the small-aperture IOL showed excellent visual performance, safety, patient satisfaction and tolerance to residual astigmatism six months after implantation. “At six months, patients achieved, on average, 20/16 for distance, 20/20 for intermediate and 20/25 for near uncorrected visual acuity,” he says. “Outcomes can be further optimized by achieving the refractive targets

of -0.75 D in the IC-8 IOL eye and plano in the companion eye. Ninety-six percent of the patients said they would have the surgery again.”¹

Dr. Dick points out that a lens based on the small-aperture principle may have several advantages over multifocal IOLs. “First, the IC-8 produces high quality, full-range vision without blurry zones,” he says. “Second, the lens is very tolerant of refractive error misses. A deviation of more than 0.5 D from the intended refractive target will result in a loss of one or two lines of vision with a typical monofocal or multifocal IOL; the IC-8 IOL will provide a reliable range of vision with as much as a 1-D deviation from the intended refractive target. In clinical studies, 100 percent of patients receiving the IC-8 IOL maintained 20/40 or better UDVA, even with a [postoperative] refractive error ranging from 0.50 to -1.50 D.² Third, if the eye has an irregular cornea, multifocality can result in poor quality of vision and severe photic phenomena, among other issues. The small-aperture design of the IC-8 IOL eliminates peripheral defocus and aberrated light, resulting in improved quality and range of vision.”

Dr. Dick adds another important benefit of the small-aperture optics; the IC-8 compensates for up to 1.25 D of corneal astigmatism, with no effect on visual acuity. “This means the 82 percent of patients who present for cataract surgery with less than 1.5 D of corneal astigmatism can enjoy the benefit of astigmatism correction without the risks associated with toric IOLs,” he says. “Furthermore, if astigmatism is induced during surgery, the effects are mitigated by the small-aperture optics. This also simplifies the surgical process for the surgeon, as there is no IOL axis to align and, as a result, no marking or intraoperative alignment equipment needed to implant the lens. Additionally, post-implantation IOL rotation

has no influence on the efficacy of the IC-8 lens.”


Patients of any age, regardless of their work-lighting conditions, can be considered as candidates for the IC-8 implant.
— *H. Burkhard Dick, MD*


A common concern with small-aperture optics is the possibility of consequences caused by the reduced amount of light reaching the retina. “Although the retina receives less light due to the elimination of peripheral rays, binocular contrast sensitivity is equivalent to that of a monofocal IOL,” Dr. Dick says. “At the 2017 European Society of Cataract and Refractive Surgeons meeting, Pablo Artal, PhD, reported that patients treated with a small-aperture implant over time adapt to the reduced light and actually perceive there to be between 30 and 60 percent more light than what is actually reaching the retina. So, after a period of adaptation, patients are unlikely to notice the reduced light, unless they compare the IC-8 eye directly to the fellow eye. Other research has shown that, over time, neuroadaptation produces a stereoacuity effect similar to normal binocular vision, wherein the dominant eye negates poor visual performance resulting from low lighting.^{3,4} Patients of any age, regardless of their work-lighting conditions, can be considered as candidates for the IC-8 implant.”

Asked whether the embedded ring might interfere with postoperative


retinal exams, Dr. Dick says the impact is minimal. “Despite the posterior positioning of the IC-8 IOL, fundus photography and angiography are entirely possible,” he says. “Physicians treating patients with the early small-aperture IOL implants report few differences in retinal imaging from the fellow eye implanted with a monofocal IOL. I myself have performed retinal surgeries including membrane peel, vitrectomy with indentation, air fluid exchange, cryotherapy and retinal lasering with success. The presence of the mask does require surgeons to modify their technique, but visualization and stereopsis are still good and procedures can be performed without incident.”

The Omega Gemini Capsule

Another unique development relating to intraocular lenses is the Gemini Refractive Capsule, from Omega. The Gemini Refractive Capsule is a three-dimensional device designed to be implanted inside the capsular bag, holding the space open and allowing controlled placement of a refractive lens—and potentially other items—at a known distance relative to the front and back of the eye.

The company notes that traditional cataract surgery has an inherent “Achilles heel.” A standard IOL is about one-fifth the thickness of the cataractous lens that’s being removed. That makes it difficult or impossible to determine the final position of the lens implant inside the eye. This device is intended to eliminate that concern, while simultaneously creating the possibility of other uses for the intracapsular space. (The company notes that the device is associated with more than 40 patents issued and pending in the United States and around the world.)

“This device is designed to keep the capsular bag open, and it allows for modularity,” explains John Berdahl,



The Gemini Refractive Capsule from Omega is a three-dimensional device designed to be implanted inside the capsular bag, holding the space open and allowing controlled placement of a refractive lens at a known distance relative to the front and back of the eye. Other items such as sensors and drug-delivery devices could also be placed in the Capsule.

MD, a partner at Vance Thompson Vision in Sioux Falls, South Dakota, and associate professor at the University of South Dakota. (Dr. Berdahl is a consultant to Omega.) “It contains tiny shelves designed to allow placement of an IOL in a particular position relative to the cornea. The idea is that because you’ll know exactly where the Gemini Capsule is, you’ll know exactly what the position of the lens is. Furthermore, you can later move the lens to a different shelf if you need to. That should result in fewer postoperative enhancements, as well as letting the surgeon alter the refraction in the future as the eye ages, even if you nailed the refraction in the original surgery. In addition, the device is designed to work with intraoperative aberrometry, so those kind of adjustments could be made while the patient is on the operating table.

“The extra shelves could also be used to add other inserts,” he con-

tinues. “One possibility would be an extra lens to alter the refractive result, whether that involves simply adjusting the refraction or adding some new multifocal technology that comes along in the future. Sensors of different types could also be placed inside the capsule. That area is important real estate that can allow us to gain a lot of insights into how the eye is functioning and how the body is functioning. Drug-delivery devices could be placed there as well.”

Obviously, the device is larger than a typical intraocular lens. “We definitely want this to be able to go through a small incision,” notes Dr. Berdahl. “That’s part of the reason the device is modular; the two separate, flexible parts of the device will be inserted in two steps so you don’t have to put the full volume of the device through the incision all at once.”

Given the size of the device, might it obscure the surgeon’s view of the

retinal periphery when it’s in position? “I don’t think that will be the case,” Dr. Berdahl says. “Even with a lens like the AcuFocus IC-8, you’re still able to see light from the peripheral retina because the lens is located near the nodal point. Furthermore, the capsule opacifies when it contracts around a traditional IOL, but that doesn’t obstruct the surgeon’s view. So any opacity that’s created by the peripheral frame of the Gemini Capsule is unlikely to affect our ability to see the peripheral retina.”

Asked if he’s aware of any drawbacks to this technology, Dr. Berdahl says it’s too early to know if any will arise. (The device has been implanted in humans, but the company hasn’t initiated U.S. Food and Drug Administration trials yet.) “Once we evaluate the implant in humans and see how predictable it is and how well it responds, we’ll know more,” he says. “The principles behind it are sound, but we always learn things when we go into clinical trials. We’re excited to see what those data show.” The company notes that the design incorporates tried-and-true optical principles and materials, which should minimize obstacles to FDA approval.

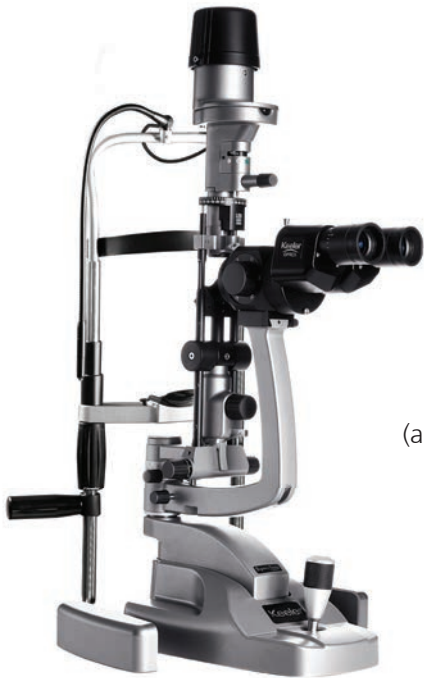Dr. Berdahl believes the future of cataract surgery and IOLs will be a conversation about the adjustability of lenses, rather than their upgradability and exchangeability. “It’s an exciting time for IOLs because we’re doing things to them after they’re placed in the eye, in order to get better outcomes,” he says. “I think that’s where things are heading.” **REVIEW**

1. Dick H, Piovella M, Vukich J, Vilupuru S, Lin L. Prospective multicenter trial of a small aperture intraocular lens in cataract surgery. *J Cataract Refract Surg* 2017;43:7:956-968.
2. Paley GL, Chuck RS, Tsai LM. Corneal-based surgical presbyopic therapies and their application in pseudophakic patients. *J Ophthalmol* 2016;2016:5263870.
3. Fernandez EJ, Schwarz C, Prieto PM, Manzanera S, Artal P. Impact on stereo-acuity of two presbyopia correction approaches: Monovision and small aperture inlay. *Biomed Opt Express* 2013; 4:822-830.
4. Schwarz C, Manzanera S, Artal P. Binocular visual performance with aberration correction as a function of light level. *J Vision* 2014;14:14:6.

The Keeler³ Trade In Program

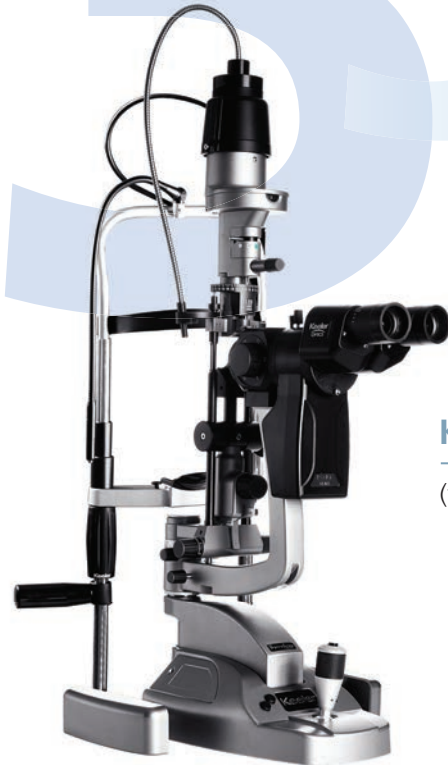Buy 3 // Trade 3 // Get 1 Free

The Power of 3. Purchase any 3 Keeler Slit Lamps and trade in 3 of your old Slit Lamps and we'll send you a 4th Keeler Slit Lamp absolutely free of charge.



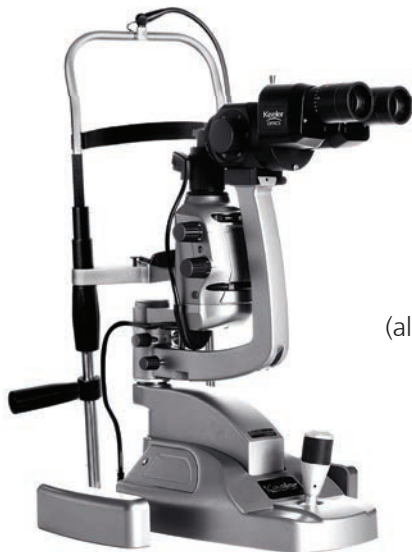KSL-H

(also in Digital Ready)



KSL-H-D

(full Digital)



KSL-Z

(also in Digital Ready)



KSL-H-D

(full Digital)



Keeler Instruments, Inc. • 3222 Phoenixville Pike, bldg. 50 • Malvern, PA 19355
Tel: (800) 523-5620 • Fax: (610) 353-7814 • email: keeler@keelerusa.com

Offer valid until June 30, 2018.

Contact Keeler or one of our authorized dealers for more information.



Trehalose & Eye Care



A Molecule Poised to Revolutionize Ocular Surface Care

By Marguerite McDonald, MD, FACS

Ocular surface disease and dry eye disease are prevalent and pervasive diseases impacting the eye health of patients. The Dry Eye Workshop II (DEWS II) and current research offer new insights on the characteristics of pathophysiology of Dry Eye Disease (DED), as well as best practices for treatment and management.

Therapeutic strategies that support the ocular surface, counteract hyperosmolarity and restore the tear film can aid in rehabilitating the eye's structures. This knowledge offers an opportunity to introduce new ways to stabilize the tear film and improve patient comfort through rehydration, reduction of surface inflammation, and protection against future desiccation.

An expanding pool of clinical data is supporting the benefits and sustained efficacy of therapies that include bioprotectants such as trehalose to protect cells against hyperosmolarity and promote exit of the vicious cycle of DED pathophysiology.¹

As such, lubricant eye drops enhanced with trehalose can provide patients with a new, successful way to rehabilitate the tear film in Ocular Surface Disease (OSD) and DED.

OSD & DED Prevalence & Impact

The 2017 Gallup Study of Dry Eye (conducted by Multi-sponsor Surveys, Inc.) revealed that 56% of adults report experiencing dry eyes frequently (14%) or occasionally (42%).² Projected to the U.S. population, this translates to a staggering 140 million dry eye sufferers.²

From a pathophysiological standpoint, DED amplifies hyperosmolarity in an unforgiving cycle either directly or by inducing a cascade of inflammatory events, contributing to a loss of epithelial and goblet cells that decreases surface wettability and promotes early tear film breakup.³

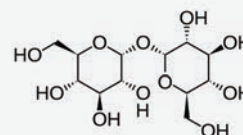
In addition to the physical toll this disease takes on patients, it also has

significant quality-of-life impacts. A number of studies have reported measurable negative effects of DED on daily-living tasks such as reading, carrying out professional tasks and driving.

Insights on Addressing the Problem

The Tear Film & Ocular Surface Society (TFOS) published the Dry Eye

What is Trehalose?



Trehalose—a bisacetal, non-reducing homodisaccharide in which two glucose units are linked together in a α -1,1-glycosidic linkage (α -D-glucopyranosyl- α -D-glucopyranoside; mycose, mushroom sugar)¹—is found abundantly in nature and in the biological world. The “extraordinary” properties of trehalose are responsible for this molecule’s bioprotective role.¹

1. Jain NK, Roy I. Effect of trehalose on protein structure. *Protein Sci.* 2009 Jan;18(1):24-36.

Trehalose – Enhancing as an Excipient

Excipient—an inactive substance that serves as the vehicle or medium for a drug or other active substance. It confers a therapeutic enhancement on the active component in the form of, for example, additional absorption, solubility or strength.

Essentially, an excipient serves to enhance the effectiveness of an active ingredient.

Workshop II report, which includes a more comprehensive DED definition that keenly accounts for the pivotal role that tear film hyperosmolarity plays, often resulting in ocular surface inflammation. As well, DEWS II, an evidence-based report involving 150 worldwide experts, further illuminates the pathophysiology of dry eye and its central mechanism of evaporative water loss leading to hyperosmolar tissue damage.³

When it comes to DED treatment, longstanding research advocates the use of lubricating eye drops as a palliative technique for symptom relief to rehabilitate some of the eye structures, such as the cornea and con-

junctiva, which may have suffered the sequelae of dry eye.

New research shows that recent attempts to counteract tear hyperosmolarity in DED have included bioprotectant features and small organic molecules used in many cell types throughout the natural world to restore cell volume and stabilize protein function.¹ These molecules may directly protect cells against hyperosmolarity and promote exit from the vicious circle of DED physiopathology.¹ There is an expanding pool of clinical data on the efficacy of DED therapies that include trehalose, whose unique properties have shown exceptional osmotic and bioprotectant abilities enabling them to act as a water replacement and prevent against desiccation stress.^{1,4,5}

How Trehalose Works

Trehalose maintains cell protein integrity during drying and rehydration, and it has been shown to protect against oxidative strain and stabilize protein function.⁶

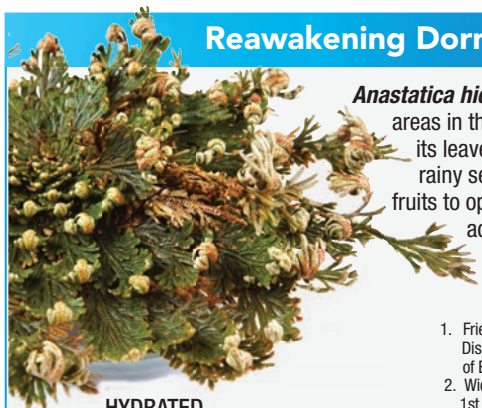
The mechanism by which this member of the polyhydroxyl compound molecules works is by increasing compactness and stability in organisms, thereby aiding in the overcoming of stress conditions such as heat, cold

Clinical Support for Trehalose

Studies have shown that trehalose offers the following ocular surface benefits:

- Protection of human corneal epithelial cells from desiccation-induced death in culture.⁷ One trehalose-containing solution was found to be “effective and safe” for treatment of moderate to severe dry eye syndrome.
- Increased tear film thickness after instillation of one trehalose-containing drop up to 240 minutes compared with drops without trehalose.⁸
- Better patient satisfaction and a therapeutic advancement in treatment of moderate to severe DED when comparing an eyedrop containing hyaluronic acid-trehalose with an HA-only eyedrop.⁹
- Increased tear production at day 14 of treatment in a dry eye mouse model.¹⁰
- Decreased eye surface apoptosis at day 14 of treatment in a dry eye mouse model.¹⁰
- Improved appearance of ocular surface epithelial disorders through suppression of apoptosis and serum-like response upon topical application, as well as maintained corneal health.¹⁰
- Suppressed inflammatory and proteolytic MMP-9 and HSP70 expression and keratinization, and restored ocular surface integrity in mice with dry eye damaged by a desiccative model.¹¹

Reawakening Dormant Desert Life



HYDRATED

Anastatica hierochuntica or white mustard flower, commonly called Rose of Jericho, is found in arid areas in the Middle East and the Sahara Desert.¹ After the rainy season, the plant dries up, drops its leaves and curls its branches into a tight ball to hibernate. Once re-wetted in a subsequent rainy season, the ball uncurls and awakens from its dormant state, causing the capsular fruits to open and disperse seeds. The plant's extraordinary ability to achieve this reawakening activity is attributed to the presence of trehalose, a disaccharide sugar involved in several mechanisms of cryptobiosis.²



DEHYDRATED

1. Friedman J, Stein J. The Influence of Seed-Dispersal Mechanisms on the Dispersion of *Anastatica Hierochuntica* (Cruciferae) in the Negev Desert, Israel. *Journal of Ecology* 1980;68(1):43-50.

2. Wickens GE. *Ecophysiology of Economic Plants in Arid and Semi-Arid Lands* 1st ed. Berlin, Germany: Springer-Verlag Heidelberg; 1998.

Trehalose Use in Dry Eye Disease

Trehalose has been shown to:

1. Rehydrate Tear Film

- Retain moisture when drying out
- Help increase tear film thickness⁸

2. Protect Against Future Irritation

- Help improve corneal staining⁷
- Help protect corneal epithelial cells from apoptosis after desiccation^{3,5}

3. Support Homeostasis of Tear Film

- Restore osmotic balance to ocular surface¹⁰
- Help maintain homeostasis of corneal cells¹⁰

and desiccation.⁶ As a result, trehalose has the unique ability to stabilize proteins and the lipid bilayer.⁶

Remarkably, trehalose can also act as a water substitute. Classified as a kosmotrope or water-structure maker, this molecule is involved in various bioprotective actions.⁶

Future of Treatment

New trehalose-containing solutions are becoming available to help eye care professionals offer patients an alternative treatment and management strategy. As one example, TheraTears[®] is launching a new lubricant eye drop, TheraTears[®] EXTRA Dry Eye Therapy, which contains trehalose as an excipient, serving to enhance the action of the solution's active ingredient, Carboxymethylcellulose (CMC). Doctors are excited about the potential of

“Trehalose helps retain moisture in the tear film when the patient is in a desiccating environment, thereby assisting in increasing tear film thickness. It decreases future irritation by protecting corneal epithelial cells from apoptosis after desiccation. It also supports homeostasis of the tear film by restoring osmotic balance to the ocular surface.”— Marguerite McDonald, MD, FACS

lubricant eye drops enhanced with trehalose.

With dry eye, trehalose helps retain moisture in the tear film when the patient is in a desiccating environment, thereby assisting in increasing tear film thickness. It decreases future irritation by protecting corneal epithelial cells from apoptosis after desiccation. It also supports homeostasis of the tear film by restoring osmotic balance to the ocular surface.

The increased bioprotective features and enhancement of tear film thickness contribute to greater patient comfort and less fluctuating vision—the end goal of any ocular surface therapy.

Clinicians should absolutely consider using these drops as a first-line treatment against OSD and DED. Artificial tears are considered first tier treatment for even the mildest of dry eyes, and continue to be a part of the treatment algorithm for moderate and severe dry eyes.

For more advanced cases, eye care professionals should consider using trehalose-containing lubricants in conjunction with a prescription medication.

I think that trehalose will increase the efficacy of artificial tears in the treatment of dry eye. This unique disaccharide offers the bioprotective benefits that lead to comfort and maintenance of a stable tear film, which yields better and more stable vision.

Dr. McDonald practices at Ophthalmic Consultants of Long Island, a Dry Eye Center of Excellence in Lynbrook, New York.

1. Baudouin C, Aragona P, Messmer EM, et al. Role of hyperosmolarity in the pathogenesis and management of dry eye disease: proceedings of the OCEAN group meeting. *Ocul Surf*. 2013 Oct;11(4):246-58.
2. The 2017 Gallup Study of Dry Eye Sufferers (conducted by Multi-sponsor Surveys, Inc.).
3. Nelson JD, Craig JP, Esen A, et al. TFOS DEWS II Report. *Ocul Surf* 2017; 2017 July;15(3):269-650.
4. Jones L, Downie LE, Korb D, et al. TFOS DEWS II management and therapy report. *Ocul Surf*. 2017 Jul;15(3):575-628.
5. Matsuo T. Trehalose protects corneal epithelial cells from death by drying. *Br J Ophthalmol*. 2001;85:610-2.
6. Jain NK, Roy I. Effect of trehalose on protein structure. *Protein Sci*. 2009 Jan;18(1):24-36.
7. Matsuo T, Tsuchida Y, Morimoto N. Trehalose eye drops in the treatment of dry eye syndrome. *Ophthalmology*. 2002 Nov;109(11):2024-9.
8. Schmidl D, Schmetterer L, Witkowska KJ, et al. Tear film thickness after treatment with artificial tears in patients with moderate dry eye disease. *Cornea*. 2015 Apr;34(4):421-6.s
9. Chiambaretta F, Doan S, Labetoulle M, et al. A randomized, controlled study of the efficacy and safety of a new eyedrop formulation for moderate to severe dry eye syndrome. *Eur J Ophthalmol*. 2017 Jan 19;27(1):1-9.
10. Chen W, Zhang X, Liu M, et al. Trehalose protects against ocular surface disorders in experimental murine dry eye through suppression of apoptosis. *Exp Eye Res*. 2009 Sep;89(3):311-8.
11. Li J, Roubeix C, Wang Y, et al. Therapeutic efficacy of trehalose eye drops for treatment of murine dry eye induced by an intelligently controlled environmental system. *Mol Vis* 2012;18:317-29.

Trehalose Current and Future Uses

- Major industries: Food, cosmetics, medicine
- An excipient in each of: Herceptin[®], Avastin[®], Lucentis[®] and Advate[®]
- Future applications: Solid dosage formulations, most notably in quick-dissolving tablets

new!

thera
tears®

EXTRA



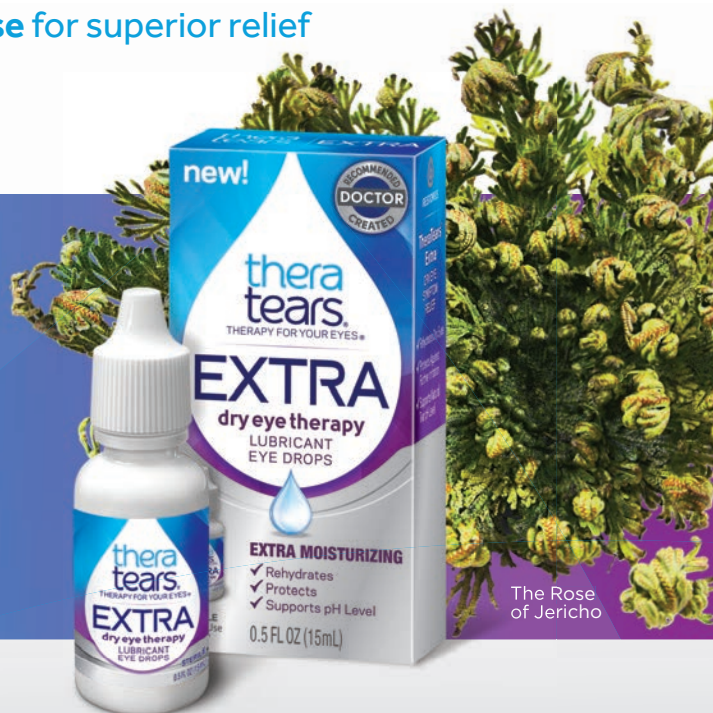HARNESS EXTRA POWER FROM A NATURAL WONDER

NEW TheraTears® Extra Dry Eye Therapy
is enhanced with trehalose for superior relief

Trehalose is a natural disaccharide found in plants with moisture retention properties that help organisms survive in absence of water. In ophthalmic products, trehalose enhances active ingredients to help:

- Protect corneal cells from desiccation
- Restore osmotic balance to the ocular surface
- Maintain the homeostasis of corneal cells

-2017 DEWS II Report



The Rose
of Jericho

Learn about our complete line of
dry eye therapy products at theratears.com

Reference: 1. Jones L, Downie L, Korb D, et al. TFOS Dews II Management and Therapy Report. The Ocular Surface Jul 2017; 575-628.
© 2018 Akorn Consumer Health | A Division of Akorn, Inc. | M17-047



Is LVC Possible In CVD Patients?

Long considered an absolute contraindication, collagen vascular disease may not always be a bar for carefully selected patients.

Kristine Brennan, Senior Associate Editor

Collagen vascular diseases comprise a group of autoimmune diseases in which the body's own immune system attacks connective tissues, skin and organs. Examples include rheumatoid arthritis, systemic lupus erythematosus, Sjögren's syndrome and scleroderma. While blanket prevalence estimates are hard to come by, arthritis and rheumatic conditions present large public-health challenges.¹ So it stands to reason that some patients looking for laser corneal refractive surgery will have one (or more) of these conditions. Should you always turn them away? Below, an expert corneal refractive surgeon shares his thoughts on balancing his duty to protect his patients with allowing a select few to have these procedures.

Until fairly recently, operating on CVD patients was practically verboten, according to Majid Moshirfar, MD, FACS, research director of the HDR Research Center and professor of ophthalmology at the University of Utah's Moran Eye Center. The FDA's original approval of LASIK designated CVDs and autoimmune diseases as absolute contraindications, although many surgeons currently consider

them a strong, but relative, contraindication in affected patients. At the time FDA approval studies were done for LASIK and PRK, known CVD patients were excluded and, as a group, tended to present clinically as more symptomatic than they do now. "There was a time when our patients with RA, for example, were not really controlled with any medication and were pretty sick, so they didn't really even ask for such refractive surgeries," Dr. Moshirfar recalls.

"But as refractive surgery outcomes and predictability became better thanks to the increasing precision of equipment and lasers, people began asking themselves, 'Now that the flaps are better and we have better ways of doing things, why not try?'" he continues, adding that rheumatologic treatments for CVD have also improved. "Rheumatologists can now diagnose these patients at much younger ages, when they're healthier. They can also treat them with immunosuppressive and immune-modulating medications that were previously unavailable," he says.

"I remember when Robert Maloney co-wrote a paper² about a group

of patients with CVD," Dr. Moshirfar continues, citing a 2006 study that followed 49 eyes that underwent LASIK in patients with conditions including SLE, RA and psoriatic arthritis over a period spanning more than six years. The authors concluded that LASIK could be safe for patients with autoimmune diseases under good control. "That was one study that helped make it seem a little bit more acceptable for these patients to undergo refractive surgery," he says.

Dr. Moshirfar emphasizes that the literature on refractive cornea surgery in CVD remains "very skimpy," however, cautioning, "There's no reason to get on a loudspeaker and offer LASIK to patients with lupus, for example. We must not be cavalier about doing corneal refractive surgery on patients with CVD."

To be considered for these surgeries, Dr. Moshirfar has a list of criteria patients must meet:

- **The treating rheumatologist must be involved.** CVD patients with good topographic maps, TBUT, staining, and no sign of cataract formation must also be in active treatment with a rheumatologist. "The ophthalmologist



SAVE THESE DATES



3RD YEAR RESIDENT PROGRAMS & WET LAB

Dear CSE 3rd-Year Resident Program Director and Coordinator,

We would like to invite you to review the upcoming 3rd-Year Ophthalmology Resident Programs and Wet Lab for 2018 in Fort Worth, Texas. The programs offer a unique educational opportunity for third-year residents by providing the chance to meet and exchange ideas with some of the most respected thought leaders in ophthalmology. The programs are designed to provide your residents with a state-of-the-art didactic and wet lab experience. The programs also serve as an opportunity for your residents to network with residents from other programs.

After reviewing the material, it is our hope that you will select and encourage your residents to attend one of these educational activities, which are CME accredited to ensure fair balance.

Best regards,
Program Directors



Third-Year Resident Wet Lab Programs 2018:

August 10-11
Fort Worth, TX

August 17-18
Fort Worth, TX

September 21-22
Meeting is Full
Fort Worth, TX

REGISTRATION OPEN

REGISTRATION OPEN

REGISTER FOR WAIT LIST

www.revophth.com/ResEdu2018

For more information: Visit the registration site above or

Email: dholmes@postgradhealthed.com • Call: Denette Holmes 866-627-0714

Courses are restricted to US-based 3rd-year residents enrolled in a US-based ophthalmology resident program and within their third year at the time of the course. There is no registration fee for these activities. Air, ground transportation in Fort Worth, hotel accommodations and modest meals will be provided through an educational scholarship for qualified participants.

Satisfactory Completion - Learners must complete an evaluation form to receive a certificate of completion. Your chosen sessions must be attended in their entirety. Partial credit of individual sessions is not available. If you are seeking continuing education credit for a specialty not listed below, it is your responsibility to contact your licensing/certification board to determine course eligibility for your licensing/certification requirement.



JOINTLY ACCREDITED PROVIDER™
INTERPROFESSIONAL CONTINUING EDUCATION

Physicians - In support of improving patient care, this activity has been planned and implemented by Amedco LLC and Postgraduate Healthcare Education. Amedco LLC is jointly accredited by the Accreditation Council for Continuing Medical Education (ACCME), the Accreditation Council for Pharmacy Education (ACPE), and the American Nurses Credentialing Center (ANCC), to provide continuing education for the healthcare team

Credit Designation Statement - Amedco designates this live activity for *AMA PRA Category 1 Credits™*. Physicians should claim only the credit commensurate with the extent of their participation in the activity.

Endorsed by:

Jointly provided by:

Supported by an independent medical education grant from:

Review of Ophthalmology®



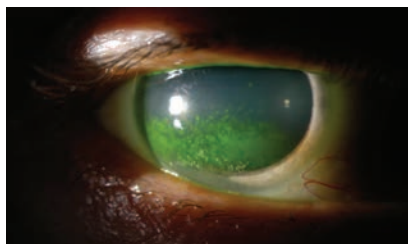
Alcon

needs an official document from the rheumatologist acknowledging that the patient wants to undergo surgery. You need a new rheumatologic examination and a new titer of serologic testing. The rheumatologist needs to certify that the patient hasn't had a relapse of any systemic problems in their body or joints in the last 18 months, in my opinion," says Dr. Moshirfar.

• **Find out why the patient wants LVC—and give strong warnings.** "Once patients meet the medical conditions, you as a physician need to find out why the patient is looking for surgery," says Dr. Moshirfar. "Are they contact-lens intolerant? If not, that makes things somewhat more promising; but if they are becoming contact-lens intolerant, then you need to really dwell on the question of whether or not to do this surgery.

"Do not be cavalier in making recommendations," he warns. "These procedures are still a strong relative contraindication in these patients. I always tell them, 'You may go blind. You may develop corneal melt. You may need a corneal transplant. Your life may change as a result of this.' I say that to all my patients—and most definitely to patients in this category." After this conversation, Dr. Moshirfar sends patients home for further deliberation. "I tell patients to go home and talk with family, and to really think about it before calling us back," he says. "Don't let patients make the decision on the spot right after you've talked to them."

• **Enhance your informed consent.** A key element of Dr. Moshirfar's due diligence is customized informed-consent language. "I write into the informed consent that the laser that we're going to use is not FDA-approved for patients with autoimmune diseases; that we have very limited literature, and that we currently don't know what the long-term results will be. Then I sign it and have the patient countersign it. This is an addendum to the standard informed consent," he says.



Mehdi Moshirfar, MD, FACS

Keratoconjunctivitis sicca due to Sjogren's syndrome. Although select CVD patients may be able to safely undergo LVC, SS may remain strongly contraindicated.

• **Choose the procedure wisely.** Dr. Moshirfar prefers LASIK to PRK for these patients, and it appears he's not alone. On the question of whether to perform LASIK or PRK on patients with CVD, A 2014 review of the literature on laser vision correction in CVD and other conditions led the authors, from the Wilmer Eye Institute, to lean towards LASIK over PRK due to LASIK's faster healing time in corneas with potentially compromised epithelial cells, and LASIK's relatively lower risk of stromal haze and scarring in these eyes.³

"I think PRK carries a higher risk of stromal reactions, melt, thinning and necrosis of the keratocytes. In LASIK, the boundary of the epithelium is not insulted as much," he says. "With PRK you've taken the epithelium and Bowman's layer off; for six or seven days, the stroma is exposed, even though you place a bandage contact lens. I'm not saying you can never do PRK on a patient with RA, but if I ever had to do a refractive procedure on a patient with well-controlled RA, I'd prefer to do SMILE or LASIK."

Although he hasn't performed SMILE on any CVD patients, Dr. Moshirfar has on patients with sub-clinical dryness on the ocular surface; patients with lagophthalmos; and Bell's palsy patients. "There are patients who will walk into our offices with Sjögren's syndrome, RA, and SLE, and we'll likely decide that we don't want to give

them LASIK. But what about SMILE? When you do LASIK on these patients, you're cutting the corneal nerves and creating a neurotrophic keratopathy, and they may not heal as well as other patients. Maybe SMILE would be better because instead of creating a 270-degree incision all the way around, you're just making a little 30-degree incision superiorly underneath the eyelid, possibly reducing the risk of a problem," he says.

• **Treat topically and systemically.** "If you proceed with any laser vision correction, you'll have to aggressively optimize the corneal surface. Studies suggest that if you put these patients on cyclosporine, you improve the nerve-growth factors," says Dr. Moshirfar. "You basically do the surgery on several weeks of prior cyclosporine. After surgery, if these patients become a lot drier than expected, that's when you need to be aggressive. You basically throw everything but the kitchen sink at them: I think that these patients respond really well to tacrolimus 0.03% or 0.01%. I sometimes also put these patients on 5% albumin. I also think blood serum has a role, but not at 20%—more like 50%—for these patients. Plug them, and use both oil-based and aqueous artificial tears. If we don't respect the integrity of the epithelium within the first eight to nine weeks postop, these patients will definitely regress and become more myopic, and they will not only have very bad UCDVA; they will also have very poor best-corrected vision," he emphasizes.

Increased risk of corneal melt means that topical NSAIDs need to be used judiciously, if at all. Signs of melt should prompt a call to the rheumatologist to discuss doubling up on immunosuppressant drugs, says Dr. Moshirfar. "If they develop a flap-edge necrosis and start to have actual melts, you need to topically and systemically ramp up everything," he says. "You most likely need to talk with the rheumatologist

and increase the dosages of the existing immunosuppressants. Working with the rheumatologist, add another medicine to the existing medications. Let's say they're on methotrexate; add Cellcept to it. If they're on Cellcept, add valproic acid. Also immediately put them on oral prednisone, usually 1 to 5 mg/kg/day, for anywhere from two to 10 weeks. The systemic steroid is important in the acute phase of exacerbation."

Amped-up immunosuppression can create additional risks, however, including postop herpes. "These patients are at risk for viral keratitis and bacterial infections, especially during the acute phase, specifically because they're immunosuppressed. In doing LASIK on these patients, I haven't had a case like that, probably because they're on steroids for a short interval. But I've had patients referred to me who were on long-term topical steroid drops, and they can run into problems," says Dr. Moshirfar.

Dr. Moshirfar has also seen on referral the results of ill-advised laser corneal refractive surgery. "Unfortunately, I've encountered that," he says. "The patient had scleroderma, which in my opinion is an absolute contraindication to corneal refractive surgery. This patient had definite scleroderma findings that you could see even without a workup. In cases like this, you need to use contact lenses; sometimes you have to use therapeutic bandage contact lenses. The patient may even need to be fitted long-term with the PROSE contact lens (BostonSight; Needham, Massachusetts)."

The Unknowns Persist

The only consensus on corneal refractive surgery in CVD appears to be that the research must evolve. The review of the literature conducted by researchers at the Wilmer Eye Institute led them to conclude that patients with mild and well-controlled

CVD with no history of ocular involvement; no systemic multidrug regimen; a minimum of six months without symptom flare; clearance from a treating rheumatologist and/or uveitis specialist; normal preop testing, including Schirmer's and TBUT; and informed consent regarding the off-label nature of LASIK and PRK for them, may be suitable candidates.³ The authors also recommended that patients have negative serology for Sjögren's, and concluded that a large, multicenter, controlled trial should take place examining the safety and efficacy of LRS for patients with CVD and other systemic diseases. A 2016 retrospective case series looking at a larger population of patients with CVDs (622 patients; 1,224 eyes) led the authors to conclude that excimer laser refractive surgery could be safely performed on patients with well-controlled disease, although they recommended against it for Sjögren's patients or patients with keratoconjunctivitis sicca.⁴ The authors also acknowledged the study's retrospective nature as a limitation.

Dr. Moshirfar says that LVC patients with CVDs and other autoimmune diseases are not as uncommon as one might think, and agrees that they merit more study. "We all have a few such patients that have undergone surgery, and some are 10 or 15 years out," he says. "If you talk with a group of surgeons, you'll hear, 'Yeah, I have patients like that.' We need to collect more data in order to help the literature advance." **REVIEW**

Dr. Moshirfar reports no relevant financial interests.

1. Helmick CG, Felson DT, Lawrence RC, et al. Estimates of the prevalence of arthritis and other rheumatic conditions in the United States. Part I. *Arthritis Rheum* 2008;58:1:15-25.
2. Smith RJ, Maloney RK. Laser in situ keratomileusis in patients with autoimmune diseases. *J Cat Refract Surg* 2006;32:1292-5.
3. Alkharashi M, Bower KS, Stark WJ, Daoud YJ. Refractive surgery in systemic and autoimmune disease. *Middle East Afr Ophthalmol* 2014;21:1:18-24.
4. Schallhorn JM, Schallhorn SC, Hettlinger KA, Venter JA, et al. Outcomes and complications of excimer laser surgery in patients with collagen vascular and other immune-mediated inflammatory diseases. *J Cat Refract Surg* 2016;42:1742-52.

S4OPTIK SLIT LAMPS

NEW LED Illumination

More than 50,000
hours of clear, cool
illumination.



Easier observation of
minute details.

Color temperature
maintained through the full
range of illumination
adjustment.

S4OPTIK

250 Cooper Ave., Suite 100 Tonawanda NY 14150

www.s4optik.com | 888-224-6012

Sensible equipment. Well made, well priced.

For today's modern office.

Planning for the Best Outcomes

Kristine Brennan, Senior Associate Editor

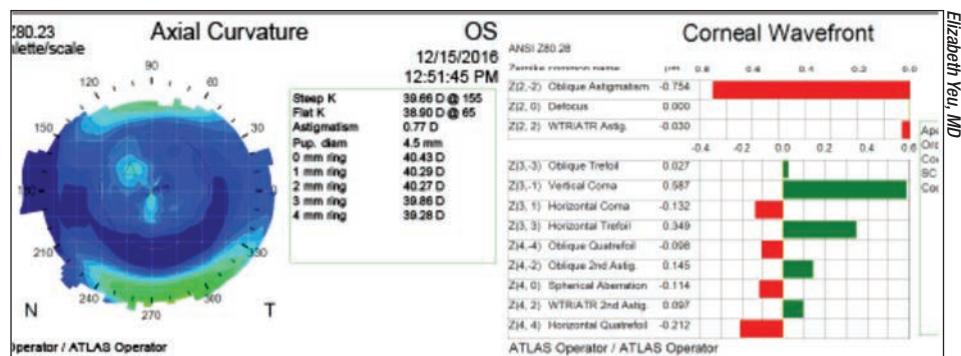Do more than just hope for them with intelligent cataract surgery planning for post-refractive eyes.

What happens when patients who've demonstrated the willingness to pursue spectacle independence through laser refractive surgery develop cataracts? Can they realistically expect excellent visual outcomes with IOLs? According to surgeons, the answer is a qualified "yes." Here, they share their pointers for yielding the best possible results with these tricky eyes.

Two things happen with laser refractive surgery, says Daniel H. Chang, MD, of Empire Eye and Laser Center in Bakersfield, California. "Number one, the ratio of the anterior and posterior corneal curvature changes, so assumptions used by keratometers to measure

K's break down. Number two, the assumptions used by IOL calculation formulas to calculate effective lens position break down, because the determined keratometry no longer reflects the shape of the anterior chamber."

"In these eyes, we are making assumptions about the relationship between the curvature of the anterior and posterior corneal surface—a relationship that is different once you alter the anterior surface of the cornea," concurs Elizabeth Yeu, MD, partner at Virginia Eye Consultants and an assistant professor at Eastern Virginia Medical School in Norfolk. "The bigger picture is that if you don't adjust your preop planning, you'll end up with



Corneal topography of a post myopic LASIK eye shows irregular astigmatism within the central cornea and a high degree of coma. Such an eye is a poor candidate for an EDof lens, and may be better suited to a monofocal IOL.

hyperopic outcomes in your post-myopic LASIK patients and myopic outcomes in your post-hyperopic LASIK patients,” she says.

Another thing that makes these eyes challenging when it's time for cataract surgery is the fact that laser ablative techniques and their effects have changed over time. “Not all post-refractive eyes are the same,” says Michael Lawless, MBBS, FRANZCO, of Vision Eye Institute, Chatswood, New South Wales, and a clinical associate professor at Sydney Medical School in Australia. “Some patients come in having had PRK or LASIK for high myopia in the 1990s, for example. These eyes have a large amount of induced spherical aberration and are often very long in terms of axial length. They also commonly have some induced irregular corneal astigmatism, a reflection of the laser technology, lack of tracking, etc., from that period,” he says.

Measure for Success

Although there's not a single, perfect way to work up a post-refractive eye for cataract surgery, thoroughness on each step of the process is important. “You should do your best preop. Each step increases your chance of getting it right,” says Dr. Chang.

Dr. Yeu, whose practice has surgical counselors on staff, always starts with the nondominant eye in post-refractive patients. “The reason for that is that if you have similar axial lengths and similar flat Ks in a post-myopic patient, for example, the response to the first-eye surgery, in terms of residual refractive error, can truly help guide what you need to do with the second eye. This is even more important than in a naïve cornea. These patients in particular have average Ks of around 38.5 and axial lengths of about 26 mm

in both eyes,” she says. “The post-operative refractive results can lend insight to the second-eye planning.

“Accurate keratometry is one of the core pieces to really refine your outcomes to be within a half- or quarter-diopter spherical equivalent of your prediction error,” Dr. Yeu continues. She uses an Atlas topographer (Carl Zeiss Meditec; Jena, Germany) as her primary topographer in post-refractive eyes. “With the Atlas specifically, you can enter the central 4 mm zone into the ASCRS post-refractive calculator,” she says. “We also get extra diagnostic information for post-refractive eyes.” In addition to collecting more data with the Cassini corneal shape analyzer (Cassini Technologies; The Hague, The Netherlands) and the Lenstar (Haag-Streit; Keoniz, Switzerland) for these patients, she also uses anterior segment OCT.

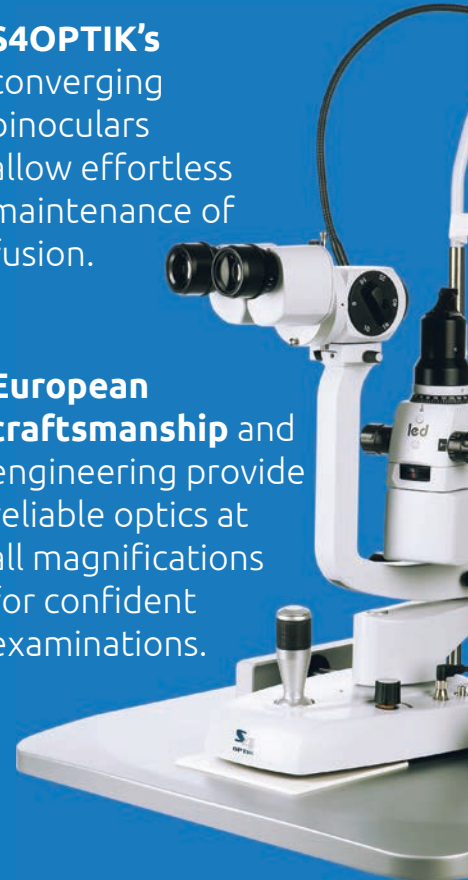Dr. Chang starts by trying to assess how important spectacle independence is to patients, plus their satisfaction with the prior refractive surgery. “I like to ask them how happy they had been with their vision after the initial refractive surgery. Sometimes, mostly with RK, but often with commercial LASIK and PRK as well, they'll say, ‘You know, it was never quite right.’ These patients should be approached with caution, since some factor such as irregularity, decentration or the like may continue to affect their quality of vision after cataract surgery as well. However, if they say, ‘It was great, but then it recently got worse,’ then you can assume the cataract made vision worse, so cataract surgery will help them,” he says. He adds that this line of questioning also helps alert him to hard-to-please personality types. “If they were big complainers after their first surgery, then there's a good chance they'll be complain-

S4OPTIK SLIT LAMPS

SEE MORE - Exceptional Optics

S4OPTIK's converging binoculars allow effortless maintenance of fusion.

European craftsmanship and engineering provide reliable optics at all magnifications for confident examinations.



Vertical and compact configurations available.

S4OPTIK

250 Cooper Ave., Suite 100 Tonawanda NY 14150

www.s4optik.com | 888-224-6012

Sensible equipment. Well made, well priced.

For today's modern office.

IOL Calculator for Eyes with Prior Myopic LASIK/PRK (Your data will not be saved. Please print a copy for your record.)					
Please enter all data available and press "Calculate"					
Doctor Name	<input type="text"/>	Patient Name	<input type="text"/>	Patient ID	<input type="text"/>
Eye	<input type="text"/>	IOL Model	<input type="text"/>	Target Ref (D)	<input type="text"/>
Pre-LASIK/PRK Data:					
Refraction*	Sph(D) <input type="text"/>	Cyl(D)* <input type="text"/>	Vertex (If empty, 12.5 mm is used) <input type="text"/>		
Keratometry	K1(D) <input type="text"/>	K2(D) <input type="text"/>			
Post-LASIK/PRK Data:					
Refraction*§	Sph(D) <input type="text"/>	Cyl(D)* <input type="text"/>	Vertex (If empty, 12.5 mm will be used) <input type="text"/>		
Topography	EyeSys EffRP <input type="text"/>	Tomey ACCP Nidek#ACP/APP <input type="text"/>	Galilei TCP <input type="text"/>	<input checked="" type="radio"/> TCP2 <input type="radio"/> TCP1	
Atlas Zone value	Atlas 9000 4mm zone <input type="text"/>	Pentacam TNP_Apex_4.0 mm Zone <input type="text"/>			
Atlas Ring Values	0mm <input type="text"/>	1mm <input type="text"/>	2mm <input type="text"/>	3mm <input type="text"/>	
OCT (RTVue or Avanti XR)	Net Corneal Power <input type="text"/>	Posterior Corneal Power <input type="text"/>	Central Corneal Thickness <input type="text"/>		
Optical/Ultrasound Biometric Data:					
Ks	K1(D) <input type="text"/>	K2(D) <input type="text"/>	Device Keratometric Index (n) <input checked="" type="radio"/> 1.3375 <input type="radio"/> 1.332 <input type="radio"/> Other <input type="text"/>		
	AL(mm) <input type="text"/>	ACD(mm) <input type="text"/>	Lens Thick (mm) <input type="text"/>	WTW (mm) <input type="text"/>	
Lens Constants**	A-const(SRK/T) <input type="text"/>	SF(Holladay1) <input type="text"/>			
	Haigis a0 (If empty, converted value is used) <input type="text"/>	Haigis a1 (If empty, 0.4 is used) <input type="text"/>	Haigis a2 (If empty, 0.1 is used) <input type="text"/>		
<p>*If entering "Sph(D)", you must enter a value for "Cyl(D)", even if it is zero. §Most recent stable refraction prior to development of a cataract. # Magellan ACP or OPD-Scan III APP 3-mm manual value (personal communication Stephen D. Klyce, PhD). **Enter any constants available; others will be calculated from those entered. If ultrasonic AL is entered, be sure to use your ultrasound lens constants. It is preferable to use optimized a0, a1, and a2 Haigis constants.</p>					
Calculate			Reset Form		

Even though the ASCRS calculator has fields for historical data regarding prior refractive surgery, many surgeons enter current measurements from placido disc and Scheimpflug topography systems to get suggested IOL powers for their post-refractive patients.

ing after this surgery as well.

“On exam, I look at the quality and condition of the cornea, assessing the quality of the optical zone and any possible incisions (e.g., LASIK flap or RK incisions) that are present,” continues Dr. Chang, who gets placido disk topography with an Atlas. “The topography tells me two things: number one is whether they’ve had a myopic or hyperopic refractive procedure. Number two is the size, centration, and degree of the previous treatment zone.”

Like Dr. Yeu, Dr. Lawless includes

intraoperative aberrometry in his measurements. “These eyes are hard to get right, and benefit from intraoperative aberrometry,” he says. “They may also benefit from IOLs that can be manipulated postop to refine a residual refractive error.”

Selecting IOLs

Patients with prior refractive surgery can choose from a variety of IOL types. The Light-Adjustable Lens (RxSight; Aliso Viejo, California), approved by the FDA in late

2017, is a new option that may help mitigate some of the variability in visual outcomes that can plague these eyes after cataract surgery. “There are two ways of approaching the problem of post-refractive eyes,” says Dr. Chang. “Number one is to make better calculations and measurements. Number two is to make better implants. You could use lenses with some refractive forgiveness, or the Light-Adjustable Lens, where you don’t have to hit the target, but can instead lock them in later. In my experience,

it's always better to hit the target, however."

Although Dr. Lawless also says that light-adjustable lenses may merit consideration in surgical planning for post-refractive eyes, he notes that he can get excellent results without them. "By paying attention to everything and optimizing the ocular surface, I expect to be within +/- 0.5 D for both sphere and cylinder 90 percent of the time. So it's hard to justify using an IOL that can be manipulated postop in fewer than 10 percent of eyes, especially when any errors can readily be treated with a small amount of PRK," he says.

Dr. Chang finds that extended depth-of-focus lenses are suitable for some of his post corneal refractive surgery patients, and may offer better visual range than monofocals. "With EDOFs, theoretically, you can get better-quality vision through a range of refractive change, but I don't promise that to patients, because as a practical matter it's difficult to achieve."

Dr. Yeu says that EDOFs can work well for patients who are interested in crisp distance vision and willing to consider fine-tuning their refractive outcomes postop. While EDOF IOLs can be successfully implanted in post-refractive eyes, corneal topography is vital to this determination. "If patients are looking for distance vision with EDOF lenses, they should have a well-centered ablation zone with no evidence of irregular astigmatism. If they go with a refractive package like this in our practice, then postop enhancements—for which these eyes are at higher risk—are performed after postoperative month two or three at no additional charge," she says.

She adds that improved lens offerings, together with thorough preoperative workups, have helped make presbyopia-correcting lenses a

real option for post-refractive eyes. "I never used to actually consider a diffractive multifocal or diffractive-optic IOL for post-refractive patients seeking spectacle independence and a range of vision. But now, patients who have nice, well-centered ablations and who do not have astigmatism do very nicely using the EDOF lenses, in my experience. The pseudoaccommodating platform, such as the Crystalens or Trulign (both Bausch + Lomb; Rochester, New York), is also an option in all post-refractive eyes with good vision potential, although I have much more experience with the EDOF IOL platform," she says.

"I tell post-refractive patients that whatever I do, there's going to be a higher chance of being off, and a higher chance of enhancement. You should essentially be prepping your patient for that because of the increased variability in outcomes with these eyes. I think that's important."

—Daniel Chang, MD

Another viable option for these patients appears to be low-add diffractive multifocal IOLs. In a small retrospective chart-review study¹ partially funded by Alcon, post-LASIK eyes implanted with the Acrysof IQ ReSTOR +2.5 (Alcon Laboratories)

achieved distance visual acuity and refractive results equivalent to post-LASIK eyes implanted with Alcon's Acrysof SN60WF monofocal IOL, while also achieving very good intermediate and good near vision. Only 4/44 eyes studied from both groups had a spherical equivalent refractive error >0.5 D from the intended refractive target; all of these had a history of hyperopic LASIK.

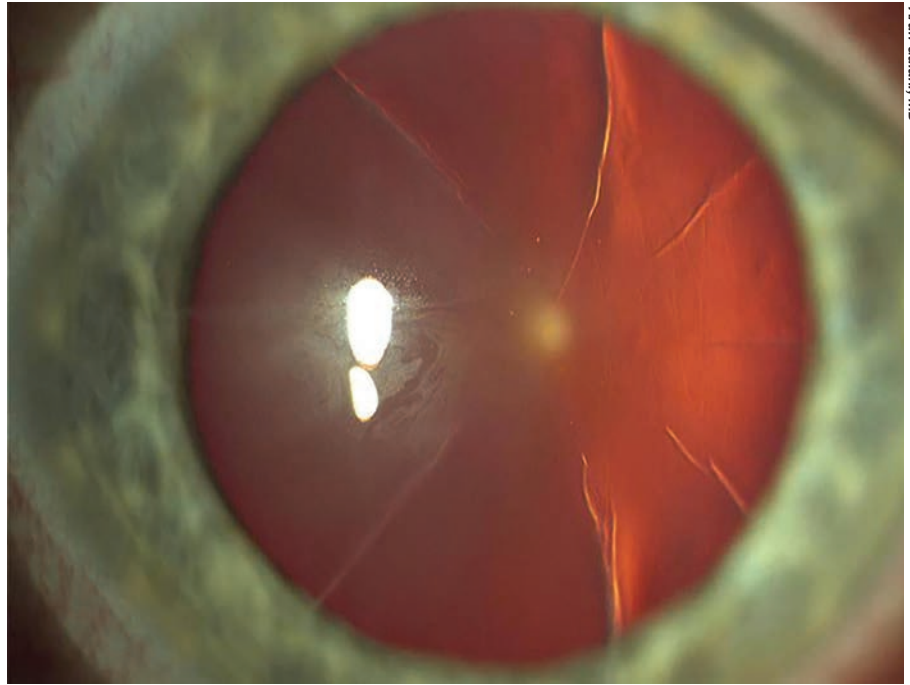
Dr. Chang notes that gaining some refractive forgiveness with an EDOF is not as simple as aiming for plano and implanting the lens, however. "With the Symphony, you actually have to target a little bit hyperopic to gain the EDOF advantage," he says. "This EDOF lens has a better depth of focus only on the myopic side of the defocus curve. Therefore, to maintain good visual quality at optical infinity, you actually have to aim a little positive to gain that advantage. Consequently, the sacrifice involved is to the reading, or near vision, but in return I have the ability to give patients with corneal aberrations a higher potential of getting great distance vision without correction. In these patients, I'll take a Symphony and aim for +0.5 D. The main goal is uncorrected distance vision, and as long as you tell patients this in advance, they'll be happy. If they do get some good near vision, that's great: But if not, they're already primed in terms of their expectations," he explains.

For post-refractive patients who aren't good candidates for premium IOLs, Dr. Yeu selects the sphericity of monofocals with care. "In general if there's any question at all, I'm using zero-sphericity monofocal IOLs. This helps to at least avoid adding any further aberrations. When you look at the higher-order aberrations profile, while there is a significant range, on average, flattened corneas have a greater amount of positive spherical aberration. So you could

go with either a zero-sphericity lens, or with a negative-spherical-aberration lens. For a more prolate hyperopic-LASIK eye, which has greater amounts of negative spherical aberration in the cornea, zero-sphericity IOLs are great: You wouldn't want to use a negative-spherical-aberration lens, like a lot of the today's aspheric monofocals. You actually want to use a zero-sphericity IOL, or an older, positive-spherical-aberration lens for these patients to neutralize what's going on with the cornea," she says. Dr. Yeu and colleagues conducted a prospective study that showed a positive correlation between higher-order aberrations and depth of focus in eyes with prior myopic or hyperopic PRK and LASIK. That study also influenced her practice patterns when choosing the sphericity of IOLs for post-refractive eyes.²

Calculating Lens Power

When it's time to calculate suggested lens powers, the ASCRS IOL Calculator (iolcalc.ascrs.org) and the Barrett True K formula are valued resources for post-refractive eyes. "I'm really grateful for the contributions of Doug Koch and Li Wang and Graham Barrett," Dr. Yeu says. "It's been further refined over time, especially with greater input utilizing Galilei information and anterior segment OCT. In my experience, my results validate what we see in the literature: The information that you get with the calculator for the suggested lens powers is even more accurate than just having the historical method, where you begin with the original surgical data. So we use the ASCRS Calculator, plus the Barrett True K formula, on everybody. Inputting the concentric mires of



Arjun Gulati, MD

Patients with prior RK should be counseled to expect a hyperopic outcome in the early postoperative days due to the RK's flattening effect on the cornea. Refractive stability should settle in at close to plano at around six weeks post cataract surgery, surgeons say.

the first 4 mm of placido disk rings from the Atlas into the ASCRS post-refractive calculator really helps to zero in on the lens calculations."

Dr. Chang also uses the ASCRS calculator for these eyes. "I put my topography data into the ASCRS calculator," he says. "It prints out one page with all the potential formulas applicable to my biometry, topography and imaging data, and provides suggested IOL powers. It's a really nice resource. You can click myopic or hyperopic laser vision correction, punch in your name, your patient name, some basic information, plug in all the biometric measurements you have, and it spits out the IOL numbers. The way I see it, the more formulas you compare, the better, and the calculator makes that easy."

One recent update in the ASCRS calculator involves the addition of the Barrett True K formula for myopic and hyperopic LASIK and PRK, as well as eyes with a history of RK.

Dr. Lawless, who with colleagues conducted a review of refractive results of known IOL formulas for post-refractive eyes,³ says that the Barrett True K most consistently produces refractive outcomes close to emmetropia in post-refractive eyes. "We have internal data on a large number of eyes to satisfy us that this is the best formula," he says. The Asia Pacific Association of Cataract and Refractive Surgeons (www.apacrs.org) advances the Barrett True K for IOL power calculations in post-refractive eyes.

"Between the Barrett True K and the ASCRS post-refractive calculator, enhancements are, fortunately, few and far between," says Dr. Yeu, who offers this pearl when entering data from post-refractive eyes into the ASCRS calculator: "For post-refractive eyes, when you're putting data into the ASCRS post-refractive calculator, don't use the 'optimize axial length' adjustment. You want to put the patient's original axial

length into the calculator,” she says, because optimizing would produce myopic results. “Two weeks post-operatively, if the patient still ends up being a little bit more myopic than you expected, you can sometimes use that information to guide you with regard to what IOL option you’re going to use in the second eye, if that patient’s preop ocular keratometry and axial lengths were similar.”


Dr. Yeu’s second pearl is that post-refractive eye data entered into the calculator should yield suggested IOL powers within a specific range—and if not, it should alert you that something is probably off. “Generally speaking, you’ll be getting IOL numbers that are going to be average because they’re post-refractive,” she says. “So the IOL-power numbers should be somewhere in the range of about 19 to 24. If they’re not, then I always go back and look at the information to see why they may not be in that average-power range. Sometimes it’s because they’ve regressed over time; or they may have evidence of ectasia or something else going on. But in general, these eyes should have average IOL powers popping up in the calculator as recommendations.”

Making History Optional

Dr. Yeu and Dr. Chang both say that current preoperative measurement and IOL power calculation techniques for post-refractive eyes yield excellent results without data from prior refractive procedures. “Five-plus years ago, I really harped on trying to find the historical data if I could,” Dr. Yeu recalls. “But as it turns out, we often aren’t able to get that historical data, and in my clinical experience, using the calculator and having good K-value input from multiple devices actually gives

more accurate power calculations without it.”

Dr. Chang agrees that K values collected during the preop workup for cataract surgery are a more reliable basis for lens calculation than those from some prior refractive surgery would be. “Previous refractive surgery data is not any better than any of the current measurement and IOL calculation formu-


*“In post-RK eyes,
they’ll have a
hyperopic outcome for
about the first three
to six weeks. It’s just
the effect of the RK
wounds. So they start
off a little hyperopic
and you expect that. In
a post-RK eye, on day
one, that conversation
needs to be had.”*
—Elizabeth Yeu, MD

las,” he says. “The general thinking is moving away from using historical data, which is nice. I think one big factor is that pre-LASIK Ks were probably just sim Ks measured to guide the laser ablation and were never meant to be used for IOL calculations. Therefore, there’s no real benefit to having prior surgical data. I like to keep things simple. If you do more work getting prior data, it doesn’t hurt to look at it. But we don’t track prior data, and we haven’t tracked it for years. Most people don’t have it and it’s hard to get.”

Educating Your Patients

For all the advancements in IOL selection, measurement and power calculation for post-refractive eyes, visual outcomes are still more subject to variability than in virgin corneas.² “The most important thing is not to over-promise,” says Dr. Chang. “I tell post-refractive patients that whatever I do, there’s going to be a higher chance of being off, and a higher chance of needing an enhancement. You should essentially be prepping your patient for that because of the increased variability in outcome with these eyes. I think that’s important.”

Dr. Yeu says that her practice’s clinical counselors initiate that important conversation with post-refractive patients. “They discuss the fact that our outcomes, while they’re very good, are not as accurate as those calculated for a naïve cornea in an average eye, because of the changes to the cornea induced by the prior surgery. So these patients are advised that they’re at a slightly higher risk of requiring a touch-up to get them to the uncorrected vision that they’re looking for, or that they’re at higher risk of needing glasses for all ranges of vision,” she says.

Dr. Yeu adds that one subcategory of post-refractive eyes calls for extra patient education, since the early postop refractive outcome is off as a matter of course. “In post-RK eyes, they’ll have a hyperopic outcome for about the first three to six weeks,” she says. “It’s just the effect of the RK wounds. So they start off a little hyperopic and you expect that. In a post-RK eye, on day one, that conversation needs to be had. I usually tend to wait about six weeks in between eyes for those patients because it takes a little bit longer for their final refractive outcome to settle in. I always caution them, ‘Your vision will

BARRETT TRUE K FORMULA - FOR PRIOR MYOPIC OR HYPEROPIC LASIK/PRK

Patient Data **Universal Formula** Formula Guide K INDEX 1.3375 K INDEX 1.332

Calculate Reset Form ENTER DATA AND CALCULATE

Doctor Name Patient Name Patient ID

Lens Factor (-2.0~5.0) or A Constant (112~125) Personal Constant

History OD: Myopic Lasik History OS: Myopic Lasik

Pre-Lasik Ref. (R) Post-Lasik Ref. (R) Pre-Lasik Ref. (L) Post-Lasik Ref. (L)

Measurements:	OD	OS
Axial Length (R)	<input type="text"/> (12-38 mm)	Axial Length (L) <input type="text"/> (12-38 mm)
Measured K1 (R)	<input type="text"/> (30-60 D)	Measured K1 (L) <input type="text"/> (30-60 D)
Measured K2 (R)	<input type="text"/> (30-60 D)	Measured K2 (L) <input type="text"/> (30-60 D)
Optical ACD (R)	<input type="text"/> (0-6 mm)	Optical ACD (L) <input type="text"/> (0-6 mm)
Target Ref. (R)	<input type="text"/> 0 (-10~10 D)	Target Ref. (L) <input type="text"/> 0 (-10~10 D)

Optional:

Lens Thickness (R) (2-8 mm) Lens Thickness (L) (2-8 mm)

WTW (R) (8-14 mm) WTW (L) (8-14 mm)

The Barrett True K formula for eyes with a prior history of LASIK or PRK has found favor with ophthalmologists tasked with planning cataract surgery. The Asia Pacific Association of Cataract and Refractive Surgeons provides a calculator at www.apacrs.org.

be blurred at first.' If they end up at around +2 to start with, that's exactly where I want them to be, because at week six, they'll end up being close to plano. On the other hand, if they end up plano and 20/25 on day one, and they've got an eight-cut RK or more, then by week six they're going to end up being myopic. It's just because of the hyperopic flattening effect of the RK wounds, even when you don't see any clinically evident corneal edema. They can have a pristine-looking cornea on day one; it's just a side effect of having the RK wounds. These are the trickiest post-refractive eyes to deal with," she says.

Post-refractive patients are a self-

selected group of people who've already demonstrated a desire for spectacle independence and good vision. "Someone who's had previous refractive surgery has obviously demonstrated a desire for spectacle independence at some point in his or her life. You have to consider that," says Dr. Chang of cataract surgery planning for post-refractive eyes. By enhancing your already-careful preop workup by collecting some extra measurements, and carefully weighing your patients' suitability for premium IOLs, you can get the odds of good outcomes for these eyes firmly on your side. **REVIEW**

Dr. Lawless is a consultant for

Alcon. Dr. Yeu reports that she has consulted for Bausch + Lomb, Alcon and Johnson & Johnson Vision. Dr. Chang has consulted with Carl Zeiss Meditec on the IOLMaster and IOLMaster 700, and with Johnson & Johnson Vision for products related to cataract, including the Symphony IOL and multifocal IOLs.

1. Fisher B, Potvin R. Clinical outcomes with distance-dominant multifocal and monofocal intraocular lenses in post-LASIK cataract surgery planned using an intraoperative aberrometer. *Clin Exp Ophthalmol*. 2018 Jan 23. doi: 10.1111/ceo.13153. [Epub ahead of print]. Accessed 2 April 2018.
2. Yeu E, Wang L, Koch DD. The effect of corneal wavefront aberrations on corneal pseudoaccommodation. *Amer J Ophthalmol* 2012;153:972-81.
3. Hodge C, McAlinden C, Lawless M, Chan C, Sutton G, Martin A. Intraocular lens power calculation following laser refractive surgery. *Eye and Vision* 2015;2:7. <https://doi.org/10.1186/s40662-015-0017-3>. Accessed February 3, 2018.

25TH ANNUAL

OPHTHALMIC

Product Guide



Innovative products to
enhance your practice

The **future**
is in your
hands. One
tap, many
possibilities.

Experience the digital edition on your handheld device.
Use your smart device to scan the code below or visit:



www.reviewofophthalmology.com/publications/archive

Download a QR scanner app. Launch app and hold your mobile device over
the code to view www.reviewofophthalmology.com/publications/archive.

REVIEW[®]
of Ophthalmology

PCO: What's Wrong With Doing a YAG?

By Leslie Sabbagh, Contributing Editor

A lot of effort is being devoted to avoiding PCO, but some surgeons say a YAG isn't that bad.

By most accounts, it's one of the most common and trusted procedures in ophthalmology, with a long track record. Cataract surgeons have banked on its efficacy and reliability for decades.

So why are some experts rethinking the risk/benefit ratio of Neodymium:YAG (Nd:YAG) laser capsulotomy for posterior capsule opacification after phacoemulsification and intraocular lens implantation? Controversy swirls around old vs. new data, long-term side effects, and the true rate of retinal and other complications. Here, surgeons weigh in on the topic.

Old Data vs. New Techniques

The risk of causing retinal detachment is the first factor cataract surgeons cite when debating the need for a posterior capsulotomy. And even though the conventionally accepted incidence of 1 to 2 percent is low, the reality may be much lower, according to research¹ conducted by Christopher Rudnisky, MD, a professor at the University of Alberta in Edmonton, Canada.

Dr. Rudnisky evaluated the incidence of RD from an administrative dataset of patients from all age groups who received foldable implants with

square edges and were followed-up at 90, 120 and 150 days, and then six months and one year post-Nd:YAG capsulotomy. Some were followed out to 10 years (2003 to 2013). He found the conventionally cited 1 to 2 percent RD rate “overstates the truth ... the rate is substantially lower, between 0.5 and 1 percent.”¹

The incidence of retinal detachment was 0.87 percent at five months post Nd:YAG; the rate of retinal tears after Nd:YAG capsulotomy at five months was 0.29 percent. The findings suggest that RD risk is highest in the first five months post-procedure. Dr. Rudnisky says that when RD occurs two years post-Nd:YAG it would be hard to prove the YAG caused it.

Older surgical and YAG capsulotomy techniques and older implant technology may account for the discrepancy between “what the textbooks and literature said and what we saw in practice. I tell patients the risk is about one in 200 or 0.5%,” he says. “Even though our paper shows that the incidence of retinal detachment is lower than what we thought, it's still not zero. It's a life-changing event for the patient who develops one.”

Michael Snyder, MD, associate professor of ophthalmology at the University of Cincinnati, is somewhat skeptical that the YAG causes most RDs

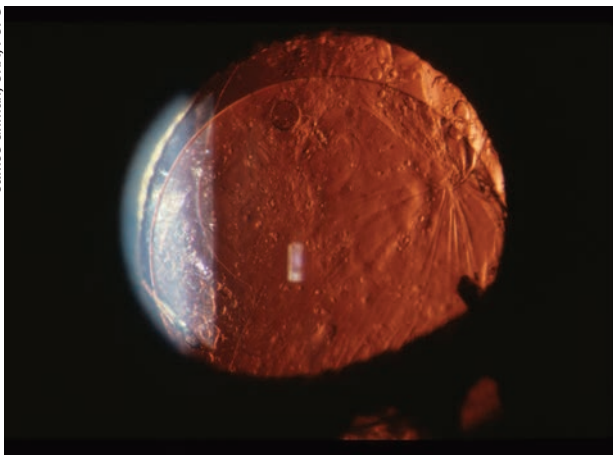
after capsulotomy. “Rather, coincidence with the natural history of retinal detachment plays a bigger role than stresses induced at the time of capsulotomy,” he says. Dr. Snyder acknowledges that the YAG procedure is “a cost and an inconvenience, and access to care can be a problem in some rural communities, but it remains a good solution.”

Many surgeons agree the 1 to 2 percent RD rate following Nd:YAG capsulotomy may not be representative of today’s clinical practice. Among them is Eric Donnenfeld, MD, clinical professor of ophthalmology at New York University. “This rate is often questioned as being too high,” he notes. However, some sub-populations are at more risk—specifically men with high myopia in their 50s and early 60s, says Douglas Koch, MD, professor and chair at the Cullen Eye Institute, Baylor College of Medicine in Dallas. “Their incidence of retinal tears/detachments just after cataract surgery alone could be 5 percent or higher, and that rate probably increases after posterior capsulotomy,” he says.

The Incidence of PCO

Although today’s technologies and techniques appear to have decreased the incidence of PCO, they may only have delayed its onset. The prevention of PCO through IOL design, and the elimination of proliferating lens epithelial cells with various capsule polishing techniques, chemicals and lasers has been attempted for decades. But “the bottom line is we haven’t achieved anything that approaches a good way

James Gilman, CRA, FOPS



Polishing techniques, chemical treatments and other types of lasers have been tried in the war against PCO.

to eliminate PCO,” Dr. Koch says.

Opinions also differ as to the actual incidence of PCO over time. Most surgeons agree, however, that early or later onset is correlated with IOL type, length of follow-up, and whether the cataract surgery was performed in a developing country. “The percentage of patients who get PCO is highly variable and dependent on the type of IOL implanted, surgical technique, cleaning of cortical material, and care in removing lens epithelial cells from the anterior capsule,” notes Dr. Snyder. In his practice, long-term PCO development is under 20 percent. “But it depends on how long patients live—eventually they all might develop

PCO,” he says. “At two years, that rate is low single digits.”

Dr. Koch puts the rate of PCO development at five to seven years postop at “probably 75 percent, even with contemporary square-edged IOLs. I tell my patients most will get this between two and four years postop.”

So, despite initial low PCO rates reported at three years postop with high-quality hydrophobic acrylic IOLs with true sharp edges and slim haptic-optic junctions, “PCO rates at five and eight years


may still increase sharply,” according to Rupert Menapace, MD, PhD, FEBO, a professor at the Medical University of Vienna. He notes this delayed “barrier failure” is caused by Soemmering’s ring formation. Dr. Menapace says the reality may be even bleaker for patients in the developing parts of the world where “cheap one-piece hydrophilic IOLs with broader haptic-optic junctions are often used.” His evaluation of two hydrophilic, small-incision IOLs showed early and high PCO rates resulting in YAG laser rates of up to 49 percent.²

More Complications

Not all ophthalmologists agree on YAG laser capsulotomy’s overall safety record. “The incidence of retinal detachment is reported to be 0.6 to 2.5 percent and 0.1 to 3.6 percent for cystoid macular edema,” Dr. Menapace notes.³

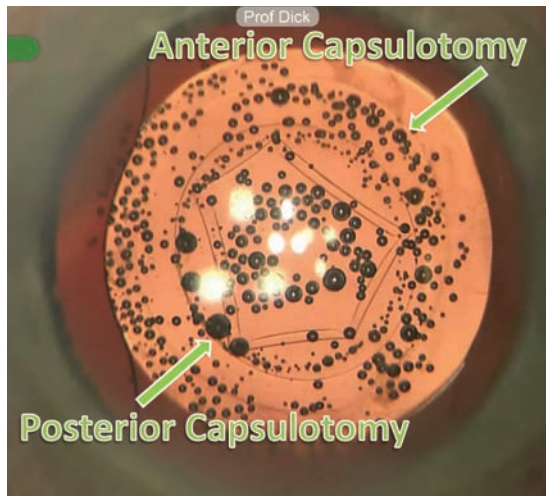

The sheer number of patients undergoing the procedure makes an assumed 1 percent retinal detachment rate not insignificant: “If you’re in that 1 percent, you will probably not consider it safe,” says H. Burkhard Dick, MD, PhD,

James Gilman, CRA, FOPS



Surgeons say to hold off on a posterior YAG capsulotomy for about three months postop just in case a lens exchange is warranted.

Tim Schultz, MD



Left: View through the infrared camera of the femtosecond laser during primary posterior laser capsulotomy. The treatment is performed at the end of surgery, after IOL implantation. Right: Immediately after the treatment, the posterior capsule starts to curl up.

lous surgery is the first, best way to prevent PCO, but techniques differ. With standard in-the-bag IOL implantation, the best method to avoid PCO today, Dr. Menapace believes, is to create a “perfectly sized and centered anterior capsule opening which ensures a 0.25 to 0.5 mm circumferential overlap of the IOL optic.” He ad-

director and chairman of the department of ophthalmology at the University of Bochum Eye Hospital in Bochum, Germany.

Neodymium:YAG laser capsulotomy almost always disrupts the anterior vitreous face, and the capsulotomy itself increases the complexity and the risks of an IOL exchange, surgeons say. “Retinal surgical outcomes are rarely clear cut ... high myopes may have more problematic retinal detachments, including giant retinal tears--these rates are still low, but [the problem] is not trivial,” Dr. Koch notes.

Late consequences after the procedure don’t end with retinal detachments: Epiretinal gliosis, macular edema and damaged IOLs are also seen. Another, less-well-known problem is possible in patients with trabeculectomies. A recent study postulates that Nd:YAG laser capsulotomy may have a negative impact on the filtering bleb, causing subsequent loss of IOP control.⁴ The researchers recommend caution when using the Nd:YAG in eyes that have undergone filtering surgery.

In the first few days following laser capsulotomy many patients note increased floaters, which eventually become less noticeable. In a small per-

centage of frustrated patients, however, the floaters persist. Dr. Koch describes a typical scenario: “Patients recover vision after cataract surgery, then lose vision due to PCO, have a YAG, and then develop a new set of problematic visual symptoms.”

There are additional aspects that some surgeons find even more controversial than RD and floaters. “Many patients present with bilateral PCO,” says Dr. Menapace. “Typically, one eye has severe PCO and the second eye has clinically disturbing PCO. Though many patients don’t realize when PCO develops in one eye, unilateral PCO actually reduces binocularity and stereopsis, which could be a factor for the increased incidence of falling and fractures.”

Finally, the financial burden is significant. At \$1.1 billion annually, cataract surgery with IOL tops Medicare payments for ambulatory surgery procedures; complex cataract surgery comes in at number five (\$96 million); and YAG capsulotomy’s \$65 million cost puts the procedure at number 10, according to Becker’s ASC Review.⁵

Is PCO Prevention Possible?

Most experts agree that meticu-

lous surgery is the first, best way to prevent PCO, but techniques differ. With standard in-the-bag IOL implantation, the best method to avoid PCO today, Dr. Menapace believes, is to create a “perfectly sized and centered anterior capsule opening which ensures a 0.25 to 0.5 mm circumferential overlap of the IOL optic.” He ad-

vises using IOLs that truly have sharp posterior edges and slim haptic-optic junctions. Dr. Menapace also recommends “thorough removal of cortical material from the capsular equator while keeping the anterior lens epithelial layer on the posterior side of the anterior capsular rim intact.”

Ophthalmic companies, researchers and clinicians have spent decades devising new technologies and techniques to eliminate PCO. Better cortical cleanup, square-edged IOLs and laser-generated capsulotomies have been touted as keys to preventing PCO.

Another technique, originally called Dodick phacolysis, was derived from Dr. Jack Dodick’s initial work in the 1990s, and uses Nd:YAG laser energy to emulsify the lens. The company behind the current technology is A.R.C. Laser of Nuremberg, Germany. In this approach, the emulsified material is aspirated out of the eye through the handpiece in a manner similar to phacoemulsification. The laser can also be used to remove the laminin layer of the posterior capsule, which can prevent posterior capsule opacification. The system is available in Europe and has just been FDA approved. The other new technology

that may make a difference is the Zepto to capsulotomy device. “The Zepto has been shown to reduce PCO,” Dr. Donnenfeld says. “It’s a nice way to make capsulotomies. The problem is that it’s not reimbursable, so that adds cost to the procedure. However, it’s become part of many surgeons’ premium cataract packages.”

Less high-tech, but still effective, Dr. Menapace explains, is a manual posterior capsulorhexis. He says the procedure is controlled and safe. “It can and should be learned by all cataract surgeons,” he declares. “It works with any IOL design and material, and should be a routine part of cataract surgery.” He says that manual posterior capsulorhexis can be performed on virtually all cataract cases. “Additional posterior entrapment of the optic into the posterior capsulorhexis opening completely eradicates PCO,” he says, citing an evaluation of 1,000 consecutive cases showing “excellent long-term efficacy and safety.”⁶ Some surgeons have pointed out the drawbacks of this technique: It’s technically more challenging than conventional cataract surgery, as it requires opening the posterior capsule, possibly inviting the vitreous to come forward. Also, if a lens removal or exchange is required later, an anterior vitrectomy will also be necessary.

Dr. Dick also thinks opening the posterior capsule at cataract surgery prevents PCO. He advocates a primary posterior laser capsulotomy using the femtosecond laser (he uses the Catalys Precision Laser System from J&J Vision) after IOL implantation. The laser targets the posterior capsule in front of Berger’s space, a tiny anatomical gap between the posterior capsule and the anterior hyaloid membrane. He says the femtosecond laser’s three-dimensional optical coherence tomography imaging functions permit the surgeon to survey the altered topography of the anterior segment immediately after surgery. Minutes

after IOL implantation, Dr. Dick says this OCT scan “demonstrates that 70 percent of patients have a Berger’s space of sufficient depth to perform a safe PPLC This is a safe technique with consistent results and represents a solution to prevent PCO.”

Other ways to eliminate or retard PCO rely on mechanical or chemical methods to destroy LECs. Despite its initial appeal, however, total elimination of LECs may not be a panacea, warns Dr. Koch. Although rare, he says that “dead bag syndrome” can occur, in which there’s no secondary proliferation of lens epithelial cells. If this happens, the capsule becomes diaphanous and floppy, unable to support the IOL, and subsequently dislocates. “If, for some reason, you have to suture through the capsule, it falls apart,” Dr. Koch says.

Nick Mamalis, MD, professor of ophthalmology and director of ocular pathology at the University of Utah’s John Moran Eye Center in Salt Lake City, says “There are fairly good data that show polishing LECs decreases the ACO incidence, but does not lower the PCO rate [after aggressive anterior capsule polishing].” He says that one widely accepted reason is that the anterior and posterior capsule don’t fuse as rapidly, so migrating cells are more likely to get past the edge of a square-edged IOL before the fusion occurs.

The balance between overly aggressive and not enough capsule cleanup is a delicate one. But most surgeons agree that some residual LECs help fibrose the capsule and stabilize the IOL. “We try to determine how to control this amount ... so that we get just the right amount of capsule fibrosis to hold onto the lens, but not so much that PCO occurs,” says William Barlow Jr., MD, assistant professor at the Moran Eye Center.

Pediatric cases, which tend to have much more aggressive PCO, and cataract surgery in developing countries

where access to the Nd:YAG laser is limited at best, are among the “most compelling reasons to eliminate YAG capsulotomy,” Dr. Barlow says.

Whether laser-assisted capsulorhexis is worth the expense and time continues to be debated, and proponents for the Zepto, femtosecond laser or manual continuous circular capsulorhexis cite both research and personal experience to support their individual preferences.⁸⁻¹²

To YAG or Not To YAG

Despite a relatively safe track record, timing and circumstances are critical factors when performing a YAG laser capsulotomy. Examples include dysphotopsias related to multifocal IOLs or lenses in general. “Unfortunately, often the surgeon’s first reaction is to YAG that patient,” says Dr. Mamalis. “There are a lot of potential risks involved. If you open the capsule, then an IOL exchange becomes more difficult to perform. I would very much recommend looking hard at the patient’s symptoms prior to considering a YAG laser.”

For example, the majority of negative dysphotopsias (a temporal hooding or darkening of vision) resolve in about three months, surgeons say. Patients with positive dysphotopsias (dazzling, disabling light) may not get better over time. “YAG laser does not improve this,” Dr. Mamalis notes.

He recommends holding off a minimum of three months before doing a YAG laser in patients with side effects such as blurry vision, glare and halos. “Unfortunately, in our tertiary care center we frequently see patient referrals after a YAG was performed for IOL-related symptoms, but we end up having to perform an IOL exchange, which can be very difficult due to the open bag,” Dr. Mamalis says. The exchanged lens may have to be sulcus fixated and, when the capsule is open, it’s difficult to remove the IOL with-

out disturbing the vitreous. Surgeons note that these cases also have an increased incidence of cystoid macular edema.

Future Directions

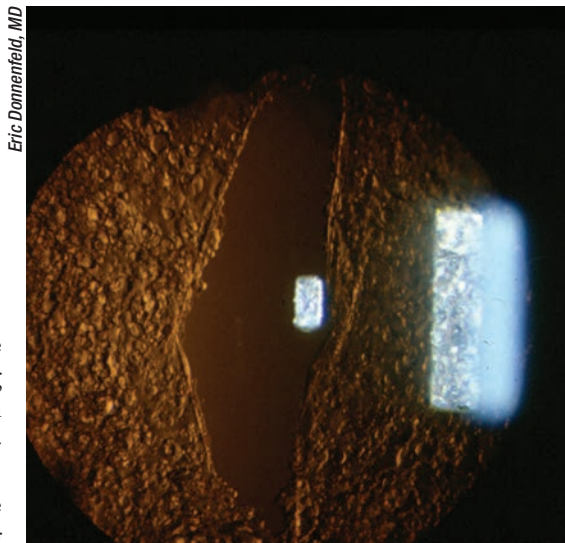
If the future holds a truly accommodating IOL, what are the patient's prospects for good vision post-YAG? That's why the attention of some who are trying to eliminate PCO is focused on the design of new IOL technology.

Whether PCO itself can be prevented, thereby eliminating any YAG-capsulotomy-related problems, is debatable, surgeons say. Posterior, square-edged acrylic IOLs delay the onset of PCO, but despite the material or lens design, significant incidence of PCO eventually occurs. "We really need to look at different ways of retarding or preventing PCO," Dr. Mamalis says.

Current research suggests a large, bulky IOL that totally fills the capsular bag will decrease PCO. "Power Vision's IOL has large balloon-shaped haptics that are involved in the accommodating mechanism. In the rabbit model, when the lens fills the capsular bag completely, the development of PCO is delayed," Dr. Mamalis explains.

So, why does this model work? One reason may be that an open capsular bag allows aqueous humor to circulate through part of the bag. Presumably, different substances in the aqueous may retard the opacification. Also, if the anterior and posterior bag edges are open and a broad haptic fills the capsular bag and precludes capsule contact, PCO might be prevented, surgeons say.

New research is focusing on ways to modulate the LECs so that they don't fibrose and don't cause capsule opacity, yet still keep the capsule elastic. At one time, Dr. Mamalis says, "peo-



Eric Donnemfeld, MD

A YAG laser posterior capsulotomy won't improve positive dysphotopsias.

ple wanted to remove all LECs. Now we're saying maybe there's benefit to retaining some LECs to maintain the bag and keep it healthy."

Preventing PCO will be of increased importance as new, accommodating IOLs that rely on intact posterior capsules become available. A truly accommodating IOL that changes its shape requires a flexible capsule, and in these cases, fibrosis/contraction becomes the bigger issue.

Dr. Donnemfeld says that he uses multifocals and extended-depth-of-focus intraocular lenses about 15 percent of the time. "But there are more glare and halos associated with them compared to single-focus IOLs," he says. "On the horizon are newer accommodating IOLs in trials that will reduce opacification by separating the anterior and posterior capsule leaflets."

There are IOLs both in development and already in clinical trials that rest within the capsular bag and require continuous flexibility of the capsule to respond to ciliary body movement. The concern for capsule-fixed accommodating IOLs is that IOL movement in the capsule will diminish with LEC proliferation, re-

ducing or possibly eliminating the accommodative IOL power change. "That said, there are accommodative IOLs showing good response up to two years postoperatively, but longer follow-up is needed," Dr. Koch notes.

No matter what side of the PCO/YAG debate you're on, it's clear that unwanted side effects of YAG laser procedures in certain eyes, patients' increasing demand for sharp vision postoperatively and the development of truly accommodating IOLs will play important roles in PCO management and avoidance in the future. **REVIEW**

None of the surgeons have a financial interest in the products that they discussed.

1. Wesolosky JD, Tennant M, Rudnisky CJ. Rate of retinal tear and detachment after neodymium:YAG capsulotomy. *J Cataract Refract Surg* 2017;43:923-928.
2. Schriefel SM, Leydolt C, Stifter E, Menapace R. Posterior capsular opacification and Nd:YAG capsulotomy rates with the iMics Y-60H and Micro AY intra-ocular lenses: 3-year results of a randomized clinical trial. *Acta Ophthalmol*. 2015;93:4:342-7.
3. Steinert R. Nd:YAG Laser Posterior Capsulotomy, AAO ONE Network. <https://www.aaopt.org/current-insight/ndyag-laser-posterior-capsulotomy-3>. Accessed 2 April 2018.
4. Diagourtas A, Petrou P, Georgalas I, et al. Bleb failure and intraocular pressure rise following Nd:Yag laser capsulotomy. *BMC Ophthalmol* 2017;17:1:18.
5. Becker's ASC Review. <https://www.beckersasc.com/asc-coding-billing-and-collections/medicare-payment-for-10-top-asc-procedures-by-case-volume.html>. Accessed 2 April 2018.
6. Menapace R. Posterior capsulorhexis combined with optic buttonholing: An alternative to standard in-the-bag implantation of sharp-edged intraocular lenses? A critical analysis of 1,000 consecutive cases. *Graefes Arch Clin Exp Ophthalmol* 2008;246:6:787-801.
7. Gimbel HV, Neuhann T. Development, advantages, and methods of the continuous circular capsulorhexis technique. *J Cataract Refract Surg* 1990;16:1:31-7.
8. Chang D. Zepto precision pulse capsulotomy: A new automated and disposable capsulotomy technology. *Indian J Ophthalmol* 2017;65:12:1411-1414.
9. Ewe SY, Abell RG, Vote BJ. Femtosecond laser-assisted versus phacoemulsification for cataract extraction and intraocular lens implantation. *Curr Opin Ophthalmol* 2018;29:1:54-60.
10. Mastropasqua L, Toto L, Caliendo R, Mattei PA, Mastropasqua A, Vecchiario L, Di Iorio D. Scanning electron microscopy evaluation of capsulorhexis in femtosecond laser-assisted cataract surgery. *JCRS* 2013;39:10:1581-1586.
11. Chang DF, Mamalis N, Werner L. Precision pulse capsulotomy: Preclinical safety and performance of a new capsulotomy technology. *Ophthalmology* 2016;123:2:255-264.

A PUBLICATION BY **REVIEW**
of Ophthalmology

RETINA SPECIALIST

Retina Specialist focuses on the latest advances in the diagnosis, medical management and surgical treatment of diseases of the retina, along with practical, real-world advice from leading clinicians and other experts on managing the successful retina practice.



The new addition to the *Review* family serves the entire Retina Specialist marketplace.

Look for your issues in 2018:

- » **MARCH**
- » **JUNE**
- » **SEPTEMBER**
- » **NOVEMBER**

For inquiries contact

RETINASPECIALIST@JOBSON.COM

Advertising opportunities

JIM HENNE • PUBLISHER • 610-492-1017 • JHENNE@JOBSON.COM

MICHELE BARRETT • 215-519-1414 • MBARRETT@JOBSON.COM

MICHAEL HOSTER • 610-492-1028 • MHOSTER@JOBSON.COM

www.retina-specialist.com



Is a Private Equity Deal Right for You? (Pt 2)

Christopher Kent, Senior Editor

Surgeons and business experts answer ophthalmologists' main questions. (Part two of two.)

As noted last month in Part 1 of this article, the phenomenon of private equity firms buying ophthalmology practices has proliferated in recent years. Given the widespread nature of this phenomenon and the huge potential ramifications for a practice that undertakes such a partnership, doctors are asking a host of questions. In this article, two surgeons who have successfully partnered with private equity firms, and two consultants who have helped doctors navigate these waters, address 15 of the most often-asked questions.

In Part 1 of this article our experts discussed nine questions regarding the historical context of this phenomenon; the potential benefits and downsides of partnering with a private equity firm; and which kinds of practices are more likely to do well in this situation. This month, they address the six remaining questions, covering the ways in which a private equity deal is likely to impact your practice (as well as the field of health care), and steps you can take to ensure a positive outcome if you decide to proceed with a private equity deal.

10 *How will these partnerships impact the care we provide our patients?*

John Pinto, president of J. Pinto & Associates, an ophthalmic practice management consulting firm, points out that it's early to predict the potential impact that private equity may have on patient care. "In my experience, there hasn't been any change at all in how practices are run following private equity deals," he says. "The private equity companies I've followed are being relatively hands-off. They're trying to centralize some services, but I haven't heard of any cases in which the private equity company has said to the doctor, 'We don't want you to have that updated laser,' or, 'We don't want you to hire the techs that you need in the back office,' or, 'We think you should get out of this or that line of service because it's not profitable.'

"We're not seeing that type of granular encroachment, and we may never see it," he continues. "The private equity companies are buying up practices they deem to be acceptable—or better—in terms of their current operations and their quality of care. They wouldn't buy a practice otherwise. Remember: The private equity people are not in the medical business; they're in the finance business. From what I've seen, they're sticking to their jobs—they're not

trying to play doctor at all. Of course, there are exceptions. And that could change further down the line if some of the companies get in trouble, or if some of them decide that improving the practice is something they should be doing.”

Even if the private equity company doesn't attempt to alter practice management, wouldn't the fact that doctors are receiving a smaller salary discourage, for example, the purchase of a new laser? “First of all, it's not a fixed amount of money that the private equity takes out of the practice,” Mr. Pinto explains.

“Typically, the private equity company will take a percentage of earnings. So if the doctor who just got a really big check for his buyout feels that there's a piece of equipment that he needs, both the company and the doctor will be paying for it. The doctor might still want to go ahead and buy that piece of equipment.”

11 *How will lower salaries impact my practice?*

In return for investing in the purchased practice, the private equity partner takes a share of practice profits. This means that at least some of the doctors in the practice will be taking home a smaller amount of money each year.

“Today, private equity companies are buying up practices at about six to eight times the practice's annual profit—in some cases much more than that,” Mr. Pinto explains. “The reason a private equity company can do that is that they're taking money from investors—money that's lever-



Though a private equity company will have a say in how much you can spend on such things as new capital equipment, doctors say the companies often are OK with such purchases if they grow the business.

aged and borrowed—in order to buy these practices, which they see as earning streams. These transactions are highly tax-favored, and the model works, seen strictly through the eyes of the private equity company. But the transaction leaves the acquired practice with fewer dollars available for doctors' salaries.

“That's a perfectly great tradeoff if you're a senior doctor who is looking for a payout,” he continues. “The payout from a private equity transaction can be twice or more what you would get if you sold your practice to a fellow physician. For some clients, it's a marvelous succession option to consider, but I think it's going to leave others quite disappointed.

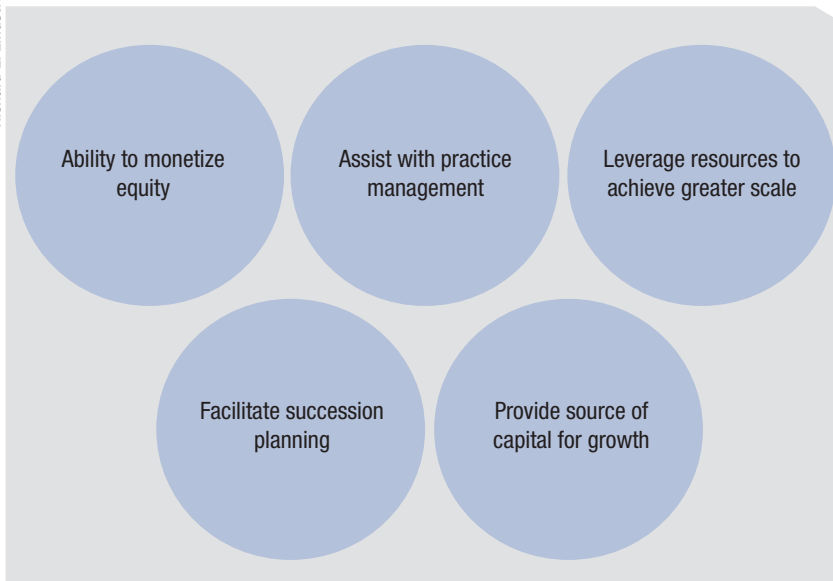“For example, suppose your practice has a mix of older and younger doctors,” he says. “The senior doctors are going to be in the boardroom raising their hands and saying, ‘Let's do this deal.’ The smaller salary in the years ahead won't impact them as much because they're taking their

lump sum and retiring. That's not the case for the younger doctors, who will have reduced earnings for years to come. That's one of the built-in traps in this situation, and it's just as much an issue today as it was in the 90s. That's why I have mixed feelings about what I'm seeing right now.”

Richard L. Lindstrom, MD, managing partner at Minnesota Eye Consultants—now part of Unifeye Vision Partners—explains how his practice evaluated the cut in salary that would accompany proceeding with their private equity deal. “Our group has 10 partners,” he explains. “We sat around the table, and asked everybody to write down what they needed to make over the next decade to live comfortably. Eventually, we came to a consensus that we'd all be comfortable making X. We thought we might end up taking about a 30-percent reduction in income after the deal, but everyone still found the numbers acceptable. Then we calculated how much practice profit would remain.

Richard L. Lindstrom, MD

The “Promise” of a Private Equity Partnership



If there was nothing left, private equity wouldn't work, because they value the practice in terms of a multiple of residual earnings. As it turned out, there was money left over, so the deal could work.

“Interestingly, at the end of our first year, we appear to have only taken about a 15-percent reduction in income,” he adds. “That's better than we expected. Of course, it's possible that if the practice growth really takes off we might even earn back the money we've given up, thanks to increased profits. The hype is always that we're going to grow, we're going to expand our cash-pay opportunities, we're going to do some additional marketing, we'll do more premium IOLs, and so forth. However, that could turn out to be nothing more than hype, so you have to discount that possibility a little bit.”

12 *Is this arrangement bad for the younger doctors in the practice?*

Brett W. Katzen, MD, FACS, president of Katzen Eye Group, based in Baltimore, has been part of two successful private equity partnerships.

He points out that how a private equity deal affects the younger doctors in a practice will depend on how the deal is negotiated. “In our deal, the younger doctors didn't take a pay cut,” he explains. “We've always had an arrangement that doctors get a percentage of the revenue they bring in. If you're an owner, you would also get a percentage of the profit made by the business. That percentage of the business's profit is what the owners are investing in exchange for the cash and/or stock, so the owners are taking home less money.

“Our deal didn't change what the employee doctors are earning at all,” he continues. “In fact, they should be incentivized to make more—and many of my doctors *are* making more now. My main cataract surgeon had his best year ever last year, partly because the private equity company invested so much in our infrastructure. The employee doctors earn the same percentage they did before, but now they have better patient flow and higher-quality instrumentation, so they at least have the potential to earn more than before.”

Dr. Lindstrom agrees that the

private equity partnership can be a great way for a doctor close to retirement to cash out. “For an older doctor like me, it's a great way to leave,” he says. “Our specific deal will allow a doctor to exit if he or she wants to, and the amount we leave with will be much greater than what our partners would have been able to pay. In theory, I could retire now; I'm one doctor out of 26, so it wouldn't be an issue if I went away. But I decided to recommit and stay another five years through the next transaction.” (He notes, however, that no private equity company is going to buy a practice and let all of the primary revenue generators leave.)

What about the impact of the deal on the younger doctors in the practice? Dr. Lindstrom says that because of the way his practice's deal was set up, it was arguably even a better deal for the younger doctors in the practice than for the doctors closer to retirement. “In addition to a cash payment, we made sure the younger doctors would be paid an adequate salary,” he says. “Meanwhile, let's say you get a million dollars today, and you put that in a tax-deferred environment such as an IRA. If you're getting 8 percent annual interest, that amount of money will double every 10 years. If you're just starting out, you've got three doublings ahead, from one to two to four to eight million dollars. If you start with \$2 million, you're up to \$16 million by the time you're ready to retire. There's no way a young doctor could save that much money in any other way. And along the way, if you need to borrow for your kid's education, you can.

“Not only that,” he continues, “those doctors are going to get two or three bites of the apple as the group is resold, with more opportunities to invest. All of the younger doctors in our practice did choose to invest in the group, and they'll have the

chance for another recapitalization in five or six years. In theory, this will repeat every five or six years, possibly reaching an opportunity for an IPO somewhere along the line. So our deal has turned out to be good even for the younger doctors.”

13 Will this undercut our ability to recruit doctors in the future?

“Younger doctors who are looking for a career and considering joining a practice that’s owned by a private equity company will realize that some of their potential earnings have already been pledged to the private equity firm and taken off the table,” notes Mr. Pinto. “That’s a problem because it’s getting harder and harder to recruit doctors. We have fewer residency slots, and more older doctors are retiring, so the demand is going up. That trend is blotting up all of the available doctors, and base salaries for new doctors are going to continue to rise materially in the years ahead. As a result, the private equity companies will find it more and more difficult to hire young doctors as the senior doctors retire. I think it’s a ticking time bomb for many of these companies.”

Mr. Pinto acknowledges that some of this might be offset in certain situations. “If an organization has become very large-scale, with revenue over \$100 million, and it’s located in a desirable market that’s attractive to younger doctors, it may work out fine,” he says. “A group in that situation will have the scale to allow more efficiency with operations, and will be able to be effective when negotiating managed-care contracts. But many others won’t have the scale to be able to overcome these difficulties. And they may not be located in parts of the country that are easy to recruit to. So the reduced salaries they’ll have to offer to young doctors won’t be sufficient to attract the doc-

Sample Acquisition Considerations	
Size / Structure Considerations	<ul style="list-style-type: none"> • Have a range of \$1 to \$5M of EBITDA • Able to invest a finite amount of equity over the life of the deal
Practice Considerations	<ul style="list-style-type: none"> • Dense regional presence (ideally the leading group in the geographic area) • Diversified group of physicians (not dependent on one or two key physicians for the majority of revenue) • Have infrastructure to facilitate growth • Surgery center ownership • Physician alignment/ownership

tors they need.”

Dr. Lindstrom says that so far, his group hasn’t had any trouble hiring new young doctors, despite the new arrangement. “Our goal is to recruit the best and brightest, and so far we haven’t seen a problem there,” he says. “The package we offer is still competitive, both in salary and in terms of opportunity to earn equity. For example, we recently hired a glaucoma/cataract surgeon, and those are among the most highly in-demand ophthalmologists today. That individual had many other offers but still chose to join us. At the same time, I would say that our buy-in, because our practice is pretty valuable, was intimidating to a lot of young doctors. Given the uncertainties that exist about the future, some would take a look and say, ‘You’re asking me to pay something that has a lot of zeroes behind it to be an equal partner in your practice. I’m already in debt, and that’s scary.’ So I think the reaction new young doctors will have to joining us will depend on the individual. Hopefully, the fact that we can offer an equity opportunity will make a difference.”

Dr. Katzen says that because of the way his deal is structured, it hasn’t undercut the group’s ability to hire new doctors. “If you’re not an owner, you’re paid a percentage of your pro-

duction,” he says. “Nobody’s lowered that percentage.”

14 How is this trend likely to work out in the long run?

Mr. Pinto sees the current wave of private equity purchases as a limited phenomenon, rather than something that will become a huge, sweeping trend. “We’re certainly not going to end up in a world in which 90 percent of practices are owned by private equity companies,” he says. “But we are moving inexorably toward more consolidation, whether it’s in the form of private equity, or hospitals buying practices, or large practices buying smaller practices. This era of increased consolidation will probably continue for some years.

“What we’re seeing right now is a series of private equity transactions that are allowed to happen because of broad financial conditions, taxation policy, and other current factors,” he continues. “I would forecast on the negative side for most of these transactions because for most of them, the underlying enterprise model is flawed. I’ve spoken to about half of the private equity companies, and a significant percentage of them are going down the same rabbit hole that we did in the 1990s. Yes, there are a few thoughtful folks doing this

Should I Wait or Act Now?

“Windows of opportunity open and close,” notes Minneapolis surgeon Richard Lindstrom, whose practice has entered into an agreement with a private equity firm. “The PPMC window opened and closed—although I’m sure some people were happy they missed it! Similarly, this private equity window will probably only be ‘hot’ for a short period of time. Right now private equity companies have discovered ophthalmology, and the financial benefits of a deal like this—if that’s what’s driving you—are a little better than average because ophthalmology is hot and the economy is doing reasonably well. This may not be true a few years from now. A stock market correction is likely in the years ahead, for example, and if that occurs there will be a lot of anxiety and gnashing of teeth and a pullback. The window of opportunity may close for a while.

“Again, a private equity deal is not going to make sense for most practices,” he concludes. “But right now in ophthalmology for private equity, it’s a seller’s market. If you’re a quality practice looking to expand, you’ll probably find multiple interested buyers, and you’ll be able to choose the culture you want. It could be that in five years no one will be interested even if you’re willing to give your practice away. I think you have to consider that, if you’re interested in the opportunity.”

—CK

now that will probably survive. Some will evolve their transaction model and the way their business works, and they’ll do well. But I think in two or three years people will look back at this as a bubble.”

If the bubble collapses, will it happen the way it happened 20 years ago? “I think things will unwind a little faster this time, because back then the companies were public companies,” Mr. Pinto says. “Public companies have better access to capital. Back then we were able to keep the party going because someone kept bringing more rum and putting it in the punch.”

What if the model fails five or six years from now? “I don’t believe it’s going to fail, but in the current world, anything is possible,” Dr. Lindstrom acknowledges. “Of course, there’s some question about what a second transaction will be like, but we’ve already seen one private equity company sell to a second investor; that was Varsity, and that went well. We’ve also seen several private equity transactions in dermatology and other fields, and we’ve seen a few of the very mature groups go public. So, at this point we haven’t seen

any failures or crashes like those we saw with the PPMCs. Of course, it’s perfectly reasonable to be concerned that this could end badly, but so far, so good.”

15 How can we maximize the chance of a good outcome?

If you’ve decided that pursuing a private equity partnership could work for you and your practice, these strategies will help ensure a positive result:

- **Don’t pursue this unless your goal is to grow.** “Just as with a growth stock, the private equity company fertilizes the practice with capital, both human and financial, and good business judgment, helping to enhance practice growth,” says Dr. Lindstrom. “For that reason, the right practices [for this type of partnership] are those that have the opportunity to grow, and equally important, *want* to grow. At the very least, you need to have a goal, a reason to pursue this option, a business plan. You shouldn’t pursue this just because somebody calls and waves a big number in front of your eyes. If you have a clear goal, then you can de-

cide whether or not a private equity partner will enhance or detract from your chances of achieving that goal.”

- **Be willing to share control of your practice.** “If an individual is a solo practitioner who is fiercely independent and cannot or simply doesn’t want to work with a partner, private equity may not make sense,” Dr. Lindstrom says. “Mavericks who want to run things their own way probably wouldn’t be happy having others involved in decisions. At the same time, a private equity group probably wouldn’t want that individual either, so it will end up being a self-fulfilling prophecy.”

- **Surround yourself with advisors you know and trust.** Bruce Maller, founder, president and chief executive officer of The BSM Consulting Group, says that a key to ending up with a good deal is to understand your limitations. “Don’t let your ego guide your assessment and decision-making,” he says. “Instead, surround yourself with people you know and trust—including legal, accounting and business consulting people. Those individuals can help you clarify your vision and build consensus among the partners about what’s the best course of action. Perhaps most important, they can help educate you. I spend a lot of time educating clients about the positives and negatives, helping to guide them to a good business decision. If it’s a decision to go ahead, I guide them on retaining good legal counsel and tax counsel, because these transactions are very complicated. It’s important to make sure you won’t be looking back and wondering, ‘Why did we do that?’ ”

- **When negotiating a deal, keep the long term in mind.** “You have to be smart about how you construct these arrangements so that they’re likely to be sustainable for the next 10 to 20 years,” says Mr. Maller. “That’s not necessarily how a private

equity firm thinks. They think about creating value in the next three to five to seven years and then selling that interest, to make sure that they satisfy their obligations to their private equity investors.”

• **Make your decisions for the right reasons.** “The worst possible reason to go down this path is because someone you know did it and got a big payoff,” notes Mr. Maller. “Even with a big paycheck you can end up very unhappy. If money is the only thing you’re thinking about, your decisions are not likely to produce ideal results.”

• **Consider how the deal is going to impact younger employee physicians in your practice.** “Your younger employees may be at the greatest risk,” Mr. Maller points out. “They may not have been involved in the original transaction, and they’re most likely to suffer if the next investor, a few years down the line, isn’t as friendly or as concerned about how a deal affects them as the first investor hopefully was.”

• **Be aware that a big payoff can alter a doctor’s level of motivation.** “Key doctors in the practice may become less motivated as a result of the financial change,” says Mr. Maller. “Once physicians have sold the practice and put money in the bank, some may lose their interest and passion, realizing they don’t need to work so hard to ensure their financial future. In fact, some may not even be motivated to stay. After a while some may say, ‘This isn’t very much fun anymore, I’m just coming to work and collecting a paycheck. I got all that money up front; maybe I should terminate. I’ve signed a noncompete, so maybe I’ll take a couple of years off. Maybe later I’ll come back and start over again!’ Of course, their interest and passion is what made the practice great in the first place, so this is not a good thing for the practice.”

Mr. Pinto says that one of the biggest unforeseen problems that occurred back in the 90s was the reaction of many doctors to the influx of cash. “Each of these doctors had a pretty good-sized check coming in at the front end for the purchase,” he notes. “Some of what they received was stock, but some was cash. That caused a lot of them to back off their productivity. A lot of doctors said, ‘Now that I’m over my financial retirement finish line, I don’t need to work so intensely.’”

“[When negotiating a deal] surround yourself with people you know and trust—including legal, accounting and business consulting people.”

—Bruce Maller

“Unfortunately, if a doctor cuts his patient volume by just 10 percent, the profits of the practice can do down as much as 20 percent,” he says. “That’s a risk the private equity companies are taking, and I’m sure that they’re going to be experiencing that as well.”

• **See if the deal passes the two-part “acid test.”** Mr. Pinto says his advice to a physician considering this type of a deal is to use a simple two-part “acid test.” “A deal like this can be an absolutely fantastic thing to do, and very appropriate as a business and professional next step, under two conditions: The first is that the money you receive up front in the transaction is enough to take you comfortably over your personal financial finish line,” he says. “I’m not

talking about something that can be clawed back later on, but the irrevocable payment you receive at the front end when the ink is drying.

“The second condition is that you’re not emotionally attached to what happens to the practice next,” he continues. “Some doctors would be carried over their financial finish line by such a deal, but they’d be anguished if their practice was run into the ground, or if key policies were changed, or key staff members were dismissed. Such a doctor should not sell to a private equity firm.”

For Better or Worse

In the final analysis, is this trend going to be a good thing for the field of ophthalmology?

“I’m torn about what I’m seeing,” says Mr. Pinto. “I see many of these companies heading in the wrong direction. It’s too early to observe the consequences, but I think in a few years we’ll see a significant number of practices partnered with private equity firms that will be unhappy with the level of administrative support they get, or the limitations that they’ll find themselves dealing with, financially and operationally.”

Mr. Maller says he’s not “for” or “against” this trend. “I think a private equity investor can bring a tremendous amount of value to a practice in the right situation,” he says. “The right situation is where you have the right type of practice, and everybody goes in with their eyes wide open, and no one loses sight of what it takes to build a great business over the next 25 years.”

Dr. Katzen notes that there are plenty of naysayers when it comes to the private equity phenomenon. “They can come up with plenty of reasons to be negative,” he notes. “But the reality is, this can work. I’m proof of that, because I’ve already succeeded.” **REVIEW**

Handling the Unhappy Premium IOL Patient

Asim Piracha, MD, Louisville, Ky.

An ounce of prevention is worth a pound of cure, says this surgeon.

Even the best products and experiences in life will fall short of expectations from time to time: Your new sedan doesn't shift gears crisply enough, the summer home's air conditioning never seems to work when you want it to, and yes, sometimes, a patient's vision with a new premium intraocular lens isn't as good as he'd hoped it would be. Whether the problem is with the patient, the surgery or a mix of both, it's your job to ferret out the cause and correct it as best you can. In this article, I'll share some techniques that will help.

A Rare Problem

The reality is that the vast majority of patients receiving premium intraocular lens implants are very happy and would have the procedure again. In fact, patients are very likely to recommend a modern premium lens to friends and family—as many as 94 percent in the Concerto Study and 98 percent in the Harmony Study.¹ In the U.S. FDA trials for newer-generation multifocal IOLs, 94 to 97 percent would choose to have the lens again as compared to only 88 percent with a monofocal lens.² But, for those who aren't fully satisfied with their quality of vision, uncorrected vision or func-

tion after premium lens implants, we need to be able to address our patients' concerns and symptoms.

Preop Measures

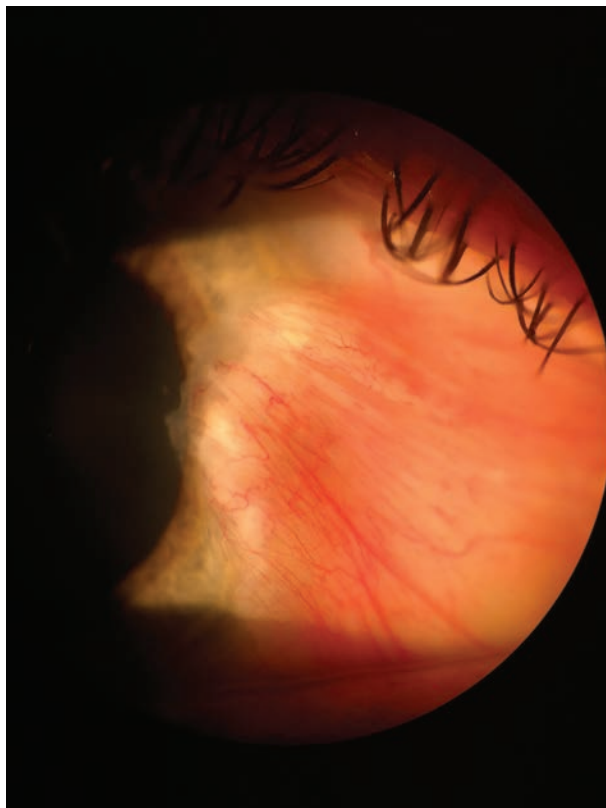There's an old maxim among playwrights who are struggling with a script: "Third-act problems are actually first-act problems." The same is true in many cases of less-than-successful premium IOL surgery. Thoroughly discussing the pros and cons of the procedure with patients ahead of time, and performing a careful exam, can avoid many postop issues.

- **Talk to the patient.** The first step to better patient satisfaction with premium IOLs is to talk and listen to the patient and understand what she expects to achieve through the surgery. Be sure to conduct a thorough exam, review all of the patient's measurements and engage in a detailed discussion about the surgical options. During this discussion, it's important to get to know the patient's personality, occupation, hobbies and visual needs. The surgeon should also explain to the patient what each lens or surgical procedure is capable of achieving and the true limitations of the technology, with a heavy emphasis on the fact that no surgery or lens can do everything for everyone.

It's also very important to understand what the patient's goals are after surgery—not just what your goals are for him. Some individuals are perfectly fine wearing glasses after surgery and don't feel the need to spend the extra money on premium lenses or femtosecond lasers. Others would prefer to see well at near and wear glasses for distance activities, while some patients prefer high quality daytime and night vision with glasses rather than good vision without correction for near and distance. Along these lines, I'm reluctant to recommend MF IOLs when the patient is very happy with monovision; the use of multifocal IOLs not only adds the need for the patient to neuro-adapt to manage postop tasks, but patients also have to pay extra for the lenses.

• **The exam.** Preoperatively, you have to evaluate every patient carefully, looking at everything from the ocular surface to the macula. When considering IOLs, be sure to choose the correct technology for a patient's current refractive error and his visual needs and wants. In the end, patients may not be good candidates for premium lenses due to either their clinical findings or their expectations and ability to function within the limitations of the current premium IOL technology.

On clinical examination, I look for ocular surface issues like dry eyes, poor tear film, epithelial basement membrane dystrophy, Salzmann's nodular degeneration and pterygium. If any of these are present, I address them preoperatively. I'll initiate aggressive dry-eye treatment with artificial tears, lid hygiene, oral omega-3 fatty acids and topical anti-inflammatory drops (i.e., Lotemax, Restasis or Xiidra). If there is EBMD or SND present, I treat these surgically with a burr kera-



When preparing the ocular surface for premium surgery, conditions such as this pterygium must be treated.

tectomy preoperatively and won't proceed with surgery until the ocular surface is healthy and the refraction is stable. We've seen refractive improvements of up to 1.25 D (mean: 0.64 D) after EBMD treatments, and up to 6 D sphere (mean: 1.71 D) and 4.5 D of cylinder (mean: 1.57 D) after treating SND. (For more on these treatments, see "The Benefits of Pre-treating Corneas" in *Review's* April 2010 issue).

If there's any significant pterygia present, we prefer to treat these first with excision and conjunctival autografts. It takes two to three months for the refraction to stabilize after these procedures—sometimes longer if there is any concurrent dry eye or lid margin disease.

A detailed dilated exam is important for ruling out any macular or optic nerve disease. The most common finding that prevents the implantation

of premium IOLs is visually significant epiretinal membrane formation or macular degeneration. Not only can ERM affect patients' best-corrected vision and quality of vision, there is also a higher risk of cystoid macular edema that should alter your postoperative drop regimen to include an NSAID for at least six weeks postop.^{3,4}

If the ERM is mild, optical coherence tomography can help determine if it's clinically significant. Due to some loss of contrast sensitivity with multifocal IOLs (less so with extended-depth-of-focus lenses) and imaging artifacts, the visual function and postop OCT measurements may be less reliable. There may also be zonular instability in glaucoma patients that could affect the long-term concentration of the IOL.

The other concern is that the ERM or glaucoma can progress, so even mild cases of ERM or glaucoma may not have excellent long-term outcomes with multifocal and EDOF lenses. For these reasons, we're cautious in recommending multifocal and EDOF lenses in patients with macular or optic nerve diseases. I'm more comfortable with monofocal toric IOLs in these cases, as long as there's no zonulopathy.

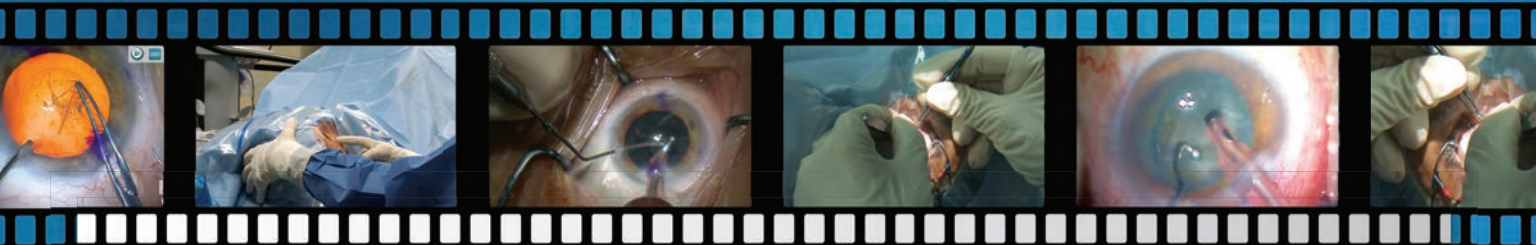
Once we determine that the patient is a good candidate for a premium lens based on the clinical exam, we then review all the measurements and studies to rule out irregular astigmatism, abnormal topography and high Purkinje vs. limbal chord lengths. Regarding the last factor, I evaluate the distance between the center of the limbus, or horizontal white-to-white measurement, (i.e., the optical center)



Monthly

MACKOOL ONLINE CME

CME SERIES | SURGICAL VIDEOS



To view CME video
go to:

www.MackoolOnlineCME.com

Episode 29: "The Use of Intraoperative Aberrometry to Confirm Toric IOL Power Calculation in a Highly Myopic Eye"

Surgical Video by:
Richard J. Mackool, MD

Video Overview:

After first removing the anterior subcapsular cataract in a highly myopic patient, I then demonstrate the use of intraoperative aberrometry to confirm the toric IOL power calculation. Discussions include how to best manage a significantly deep chamber and how to correct the rare occurrence of a toric IOL that rotates postoperatively.

MackoolOnlineCME.com MONTHLY Video Series



Richard J. Mackool, MD

Welcome to the third year of Mackool Online CME! With the generous support of several ophthalmic companies, I am honored to have our viewers join me in the operating room as I demonstrate the technology and techniques that I have found to be most valuable, and that I hope are helpful to many of my colleagues. We continue to edit the videos only to either change camera perspective or to reduce down time - allowing you to observe every step of the procedure.

As before, one new surgical video will be released monthly, and physicians may earn CME credits or just observe the case. New viewers are able to obtain additional CME credit by reviewing previous videos that are located in our archives.

I thank the many surgeons who have told us that they have found our CME program to be interesting and instructive; I appreciate your comments, suggestions and questions. Thanks again for joining us on Mackool Online CME.



CME Accredited Surgical Training Videos Now Available Online: www.MackoolOnlineCME.com

Richard Mackool, MD, a world renowned anterior segment ophthalmic microsurgeon, has assembled a web-based video collection of surgical cases that encompass both routine and challenging cases, demonstrating both familiar and potentially unfamiliar surgical techniques using a variety of instrumentation and settings.

This educational activity aims to present a series of Dr. Mackool's surgical videos, carefully selected to address the specific learning objectives of this activity, with the goal of making surgical training available as needed online for surgeons motivated to improve or expand their surgical repertoire.

Learning Objective:

After completion of this educational activity, participants should be able to:

- Demonstrate and discuss problems frequently encountered when performing phacoemulsification on a highly myopic eye with an extremely deep anterior chamber
- Demonstrate the use of the intraoperative aberrometry to verify IOL power

Satisfactory Completion - Learners must pass a post-test and complete an evaluation form to receive a certificate of completion. Your chosen sessions must be attended in their entirety. Partial credit of individual sessions is not available. If you are seeking continuing education credit for a specialty not listed below, it is your responsibility to contact your licensing/certification board to determine course eligibility for your licensing/certification requirement.



JOINTLY ACCREDITED PROVIDER™
INTERPROFESSIONAL CONTINUING EDUCATION

Physicians - In support of improving patient care, this activity has been planned and implemented by Amedco LLC and Postgraduate Healthcare Education. Amedco LLC is jointly accredited by the Accreditation Council for Continuing Medical Education (ACCME), the Accreditation Council for Pharmacy Education (ACPE), and the American Nurses Credentialing Center (ANCC), to provide continuing education for the healthcare team

Credit Designation Statement - Amedco designates this live activity for a maximum of .25 AMA PRA Category 1 Credits™. Physicians should claim only the credit commensurate with the extent of their participation in the activity.

Endorsed by:

Review of Ophthalmology®

Video and Web Production by:
JR Snowden, Inc

Jointly provided by:

AMEDCO & PHE

Supported by an unrestricted independent
medical educational grant from:

Alcon

Additionally Supported by:

**Glaukos
MST
Crestpoint Management
Carl Zeiss Meditec**

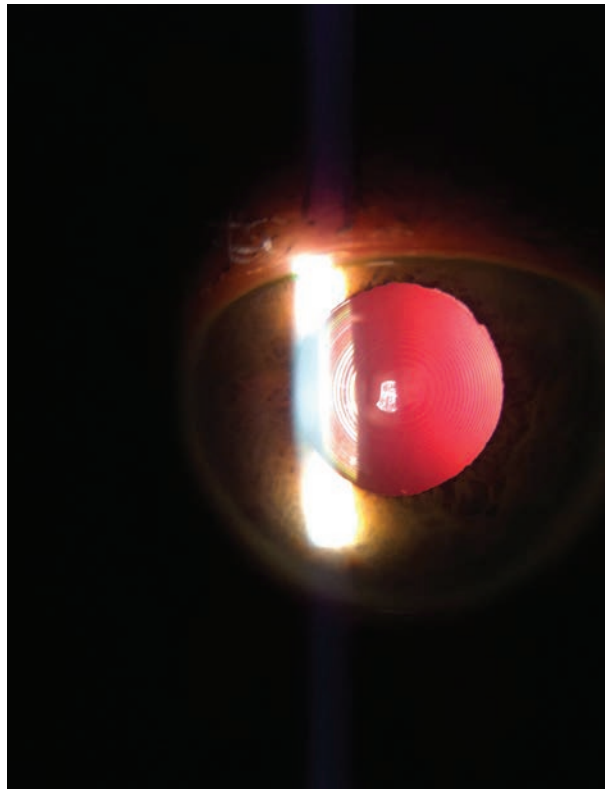
and the corneal apex (i.e., the visual axis). If this distance is greater than 0.5 mm, then there will be some induced higher-order aberrations and decreased quality of vision. In my own case series, we found a higher percentage of 20/20 uncorrected visual acuity at near and distance when this value was less than 0.5 mm. This measurement is also helpful with toric IOLs and even aspheric monofocal IOLs—not just multifocal/EDOF lenses.

If the topography shows irregular astigmatism or signs of ectasia, I avoid presbyopic IOLs; however, I may consider a toric IOL to reduce the cylinder, but only after a detailed discussion explaining the “off-label” use and the expectation of some residual astigmatism.

Premium IOL surgery is, in effect, refractive surgery, and patients should be screened in the same way as they would for a LASIK evaluation, since enhancements must be an option to correct any residual refractive error. This means that the ocular surface and topography/tomography should be normal and that there should be no contraindications for laser vision correction. If the patient is not an LVC candidate, then he should be educated preoperatively that there may be limited options after surgery to fully correct his vision.

The extra time and effort taken to educate the patient preop will reduce the number of postop issues and also help screen out patients that may not be a good fit for premium lenses.

• **Formula factors.** Although enhancements are a reality with IOL surgery, by using modern IOL formulas like the Hill-RBF and the Barrett Universal formula, advanced bi-



If the distance between the optical center and visual axis (angle alpha) is greater than 0.5 mm, more aberrations will be induced. This multifocal IOL is centered on the visual axis and has a low angle alpha measurement.

ometry from the IOL Master 700 or Lenstar, and multiple K readings, you can reduce the number of refractive surprises you experience. I personally use multiple formulas and review the K readings from three different devices (IOL Master 700, Pentacam and Tracey iTrace) before calculating the IOL power. If the measurements have outliers, such as long or short axial lengths, high or low Ks, or narrow chamber depths, inform the patient that she is more likely to need an enhancement once the refraction is stable. If there’s a big difference between the two eyes or between the measurements, then this may be a sign that the ocular surface is unstable.

Intraoperative Tips

“Perfect” cataract/intraocular lens

surgery without complications is always the goal, especially with premium IOL implants. To make the surgery as precise as possible, we prefer to use a femto-second laser, the Catalys, for all premium IOL cases. We address corneal astigmatism with an intrastromal astigmatic keratotomy procedure or make preop corneal marks to facilitate toric IOL alignment. We also reduce the capsulotomy from a standard diameter of 5 mm down to 4.8 mm for toric IOLs (both monofocal and extended-depth-of-focus) to reduce the incidence of IOL rotation postoperatively. In addition, I prefer to fragment the lens in order to reduce elapsed phaco time and achieve clear corneas on postop day one.^{5,6,7}

The Postop Period

Even when you follow the aforementioned advice, there may still be the occasional patient who is unhappy.

When meeting with a dissatisfied premium IOL patient, you shouldn’t become defensive or dismissive of his complaints. It’s critical to listen to his issues early and often in order to understand his concerns and create a game plan to address the issues. I’ve seen a handful of unhappy premium IOL patients whose visual function could have been markedly improved with a couple of very simple treatments—but they were either not offered or the patient didn’t understand what he was being offered.

It’s also important to understand the duration and timing of the complaints, since some issues will improve over time with neuroadaptation and some may be chronic and need to

be addressed. For instance, night-vision disturbances and learning how to function better at near tasks definitely improve during the first three to six months postop. In many cases in which premium IOL patients are unhappy with their results, after listening to them carefully and being their advocate, we're able to allay their fears and regain their trust. This helps us educate them on the limitations of the lens technology that they had implanted. In doing so, we've been able to improve their visual function. Since no premium lens is perfect, there may be cases in which the best solution is to exchange the lens for a standard IOL. This is the exception, however, and I typically only recommend this if all the other less-invasive options have been exhausted.

In the postop period, there are several areas that can be addressed to improve patient satisfaction and function with premium lenses:

- **Ocular surface disease.** The ocular surface can severely affect the quality of vision, patient comfort and visual function, and any problems with the surface should always be treated aggressively. Dry eyes are very common, and the ocular surface should be fully rehabilitated to improve patient satisfaction, and to prepare the eye for an enhancement, if needed.

- **Residual refractive error.** This is the most common reason patients aren't functioning well without correction postop. Residual refractive error affects everything; near; intermediate; distance; and night vision. If there's a high spherical refractive error, then an IOL exchange or secondary piggyback IOL are good options. I prefer an IOL exchange over piggyback lenses unless the capsule or zonules aren't intact.

For compound or mixed astigmatism, LASIK and PRK are excellent options. I prefer LASIK if the patient is a good candidate, due to the quicker visual recovery and comfort. If the patient has mixed astigmatism with an

essentially plano spherical equivalent, then you can offer an AK or LRI, either of which works well if the cylinder is undercorrected from the surgery.

*It may take patients
three days, three
months or six months
to learn how to adapt
to their new vision with
a premium lens.*

If there's residual cylinder after a toric IOL, I determine if the IOL is on the ideal postop axis; if it isn't, then I'll use one of the many online calculators (such as www.astigmatismfix.com and www.assort.com) or instrumentation that assesses the proper alignment of the lens and the expected residual refractive error (such as the iTrace or the OPD-Scan III from Nidek). If I determine that there will still be significant residual refractive error even after ideal alignment of the IOL, then I prefer an LVC enhancement to avoid needing two separate surgeries.

If a cornea-based enhancement is necessary, the ideal time is about six weeks postop to allow for the refraction and ocular surface to stabilize. If you're going to be rotating a toric IOL, I recommend doing this one to two weeks postop but not earlier, as the IOL can shift again if the rotation is performed too soon postoperatively. If there is any zonular instability or decentration of the lens or high axial lengths/WTW measurements, I prefer to place a capsular tension ring at the time of the rotation to reduce the risk of recurrent rotation.

- **Posterior capsular opacification.** If there's any significant PCO present and there are night-vision difficulties or quality-of-vision com-

plaints, a YAG capsulotomy is indicated. This can be performed as soon as six weeks postoperatively, but it's best to wait longer to ensure that the IOL is stable and to reduce the potential for developing CME. You should also wait on performing a posterior capsulotomy if you're still considering an IOL exchange or rotation.

- **Cystoid macular edema.** An SD-OCT is indicated to rule out CME; if detected, CME must be treated until fully resolved. If ERM is present and thought to be a cause of persistent CME or decreased quality of vision, then consider a referral to a retinal specialist.

- **Neural adaptation.** We expect patients' near vision and night vision to improve over time. It may take them three days, three months or six months to adjust and learn how to adapt to their new vision. Some patients may not ever adapt and, for them, we should be ready to exchange a multifocal or EDOF lens for a monofocal IOL.

- **Good surgery, wrong patient.** Often, the surgery is nearly perfect, with excellent outcomes as predicted ... but the patient still isn't satisfied. Maybe he's not tolerant of night-vision difficulties or isn't willing to give his problems a chance to resolve over time, or maybe he expected a perfect range of vision from near to far during both day and night. Many patients are disappointed if they need glasses for any function, even if you informed them multiple times preoperatively that they shouldn't expect to be 100-percent free of spectacle correction for all activities. For these patients, it's a challenging discussion after surgery and, therefore, it's best to do all you can preoperatively to avoid these situations, and then do all you can after surgery to optimize their outcomes, given the inherent limitations of the technology we have available today.

In summary, premium IOLs have

come a long way in the past decade, and can provide excellent visual function and spectacle independence for the great majority of patients. Some, however, will not be happy with their outcomes. A detailed history, examination, biometry/IOL calculations and discussion are critical to preventing misunderstandings and poor outcomes with premium lens implants. In completing this process, treat a premium lens patient like a refractive surgery patient in terms of her preop evaluation, and make it a point to rule out conditions that may lead to poor outcomes or limit her options for improving her vision after surgery.

The only way to completely eliminate unhappy postoperative premium lens patients from our practice is to not perform the surgery. However, by using the preop, intraop and postop management tips outlined in this article, you can expect very high success rates and patient satisfaction with premium IOLs. [REVIEW](#)

Dr. Piracha is an associate professor of ophthalmology at the University of Louisville and the University of Kentucky. He is a consultant to Carl Zeiss Meditec.

1. DOF2016CT0024 (Concerto Study Report) and DOF20150TH0009 (Symphony Harmony Observational Study).
2. Patient information brochure: J&J Tecnis ZKB00 and ZLB00.
3. Henderson BA, Kim JY, Ament CS, et al. Clinical pseudophakic cystoid macular edema. Risk factors for development and duration after treatment. *J Cataract Refract Surg* 2007;33:9:1550-1558.
4. Wittpenn JR, Silverstein S, Heier J, et al. A randomized, masked comparison of topical ketorolac 0.4% plus steroid vs steroid alone in low-risk cataract surgery patients. *Am J Ophthalmol* 2008;146:4:554-560.
5. Conrad-Hengerer I, Hengerer FH, Al Juburi M, Schultz T, Dick HB. Femtosecond laser-induced macular changes and anterior segment inflammation in cataract surgery. *J Refract Surg* 2014;30:4:222-6.
6. Hengerer FH, Dick HB. Corneal endothelial cell loss and corneal thickness in conventional compared with femtosecond laser-assisted cataract surgery: Three-month follow-up. *J Cataract Refract Surg* 2013;39:1307-1313.
7. Takacs AI. Central corneal volume and endothelial cell count following femtosecond laser-assisted refractive cataract surgery compared to conventional phacoemulsification. *J Refract Surg* 2012; 28:387-39.

Improve Your Surgical Efficiency

With Premium Quality Single-Use Instruments

- Market leading portfolio
- Designed for excellent clinical performance



BVI Portfolio Features Malosa™ Single-Use Instruments

For ordering information, please call customer service

Beaver-Visitec International, Inc.

US: 1-866-906-8080

EU: 44 (0) 1865 601256

bvimedical.com

No Capsular Support: Do ACIOLs Still Make Sense?

Christopher Kent, Senior Editor

New alternatives have many surgeons shying away from ACIOLs—but there's still a place for them.

A few years ago, when a cataract surgeon was faced with an eye that had minimal or no capsular support, there were only two surgical options: insert an anterior chamber lens or suture a lens into the posterior chamber. Today, the options for posterior lens fixation have proliferated, changing the nature of that choice.

“Lack of capsular support is something we’ve always been concerned about and tried to prepare for in cataract surgery, but our options for managing this situation have increased through the years,” says Kendall E. Donaldson, MD, MS, medical director of Bascom Palmer Eye Institute’s Plantation, Florida, location and associate professor of ophthalmology and co-director of the corneal fellowship at Bascom Palmer Eye Institute. “Today we see more iris-fixated posterior chamber lenses. We have glued IOLs, thanks to Amar Agarwal, MD, in India. We have the relatively new Yamane technique, which involves placing the haptic through a channel and then cauterizing the tip, which causes it to enlarge so we can tuck it into the sclera. And, we have the option of using long-lasting Gore-Tex to suture an Akreos lens in place. In the past, we would have used prolene to suture a lens to the sclera.” (She explains that although suturing with prolene is still

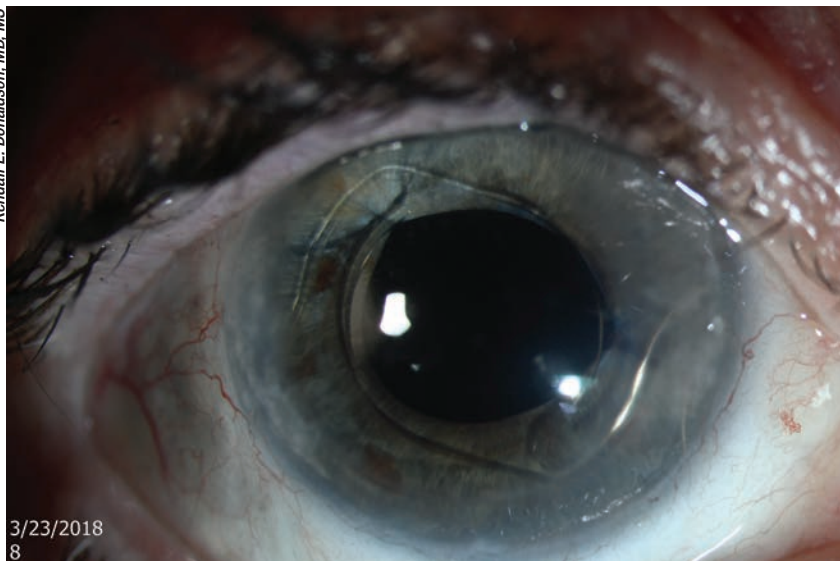
a widely-used technique, the prolene can erode over time, often resulting in the lens dropping to the back of the eye 10 years later. In contrast, Gore-Tex doesn’t erode.)

“Today, we have options that are more cornea-friendly and angle-friendly,” agrees Nicole Fram, MD, managing partner at Advanced Vision Care in Los Angeles and a clinical instructor of ophthalmology at the Stein Eye Institute, University of California, Los Angeles. “There have been many exciting advances in scleral fixation. If you can offer someone a more physiologically appropriate procedure with the lens placed away from the cornea and iris, I think you should.”

Given the expansion of management alternatives in this situation, the question arises: Is the placement of an anterior chamber lens—with its attendant possible complications—still a viable option? Here, surgeons experienced in anterior and posterior lens placement share their experiences and opinions.

ACIOLs: A Riskier Option?

One of the most obvious reasons to question the validity of placing an anterior chamber lens is that ACIOLs sit in a place that nature didn’t intend to hold a lens. That makes this option



Anterior chamber IOLs like the one above can work well, with minimal side effects, when the anterior chamber is deep and the IOL is properly sized and positioned. However, new ways of fixating posterior chamber IOLs have many surgeons favoring that alternative.

susceptible to a list of potential complications that can result in damage to the cornea, iris or angle.

“Posterior chamber lenses are generally thought of as being healthier for the eye because they’re farther from the corneal endothelium,” says Dr. Donaldson. “They’re at a more physiologic location, behind the iris. Anterior chamber lenses sit close to the corneal endothelium, and as a result the patient will lose some endothelial cells over time. That could lead to corneal edema—or even a corneal transplant. For that reason, many surgeons think of anterior chamber IOLs as making the most sense when a patient is older. Older patients will have fewer decades for corneal issues to develop.”

Working in a tertiary referral practice, Dr. Fram often encounters those problems. “We see many complications caused by malpositioned—and even properly placed—anterior chamber IOLs,” she says. “In the vast majority of cases we see at least one of the following complications: endothelial failure with corneal edema; chronic intraocular inflammation, or uveitis-glaucoma-hyphema (UGH)

syndrome; or cystoid macular edema. Sometimes we see all three. Most disappointing is when we find chronic inflammation, a decompensated cornea and mismanagement of iris defects, resulting in extensive peripheral anterior synechiae with secondary glaucoma. That limits the possibility of using more cutting-edge procedures for visual rehabilitation that would result in faster recovery, such as Descemet’s membrane endothelial keratoplasty (DMEK). There’s no question that over time, a malpositioned ACIOL will eventually induce one or all of these co-morbidities.

“In contrast, I believe that if you have the patience and skill set to fixate posterior chamber IOLs, whether it’s intrascleral fixation or suture scleral fixation, and you obey the basic tenets of performing proper anterior vitrectomy or pars-plana-assisted anterior vitrectomy, you won’t have as high an incidence of complications,” she says. “Any secondary IOL-fixation technique can result in endothelial failure, chronic inflammation or CME. However, in our experience, those are far less common with fixated poste-

rior chamber IOLs than with ACIOL placement.

“Of course,” she adds, “all of this is only true if you’re properly trained in the technique you’re using.”

Challenges Placing an ACIOL

Another concern that can exacerbate the inherent potential problems with a lens sitting close to the cornea is that anterior chamber lenses are challenging to fit. Mitchell P. Weikert, MD, associate professor at the Cullen Eye Institute at the Baylor College of Medicine in Houston, says he believes that anterior chamber lenses still have a place when performing surgery on a patient with weakened zonules—if they fit well. “If they fit well in the anterior chamber, they usually do very well and have very few complications,” he says. “However, proper fitting can be a challenge, for several reasons.

“For one thing, we have limited sizes available to us,” he says. “For example, Alcon offers three sizes of anterior chamber lenses; Bausch + Lomb offers two sizes. The size of everyone’s anterior chamber is a little different, so it can sometimes be challenging to find the right lens. Second, the dimensions of the anterior chamber horizontally and vertically can be a little different. Third, not every OR stocks a full array of the ACIOLs that are available. Although we may plan to use an ACIOL in some cases, they’re more commonly used following a complication that precludes the use of a posterior chamber IOL. Unless you’ve ordered a special lens ahead of time, the OR may not have the one you need.”

Dr. Weikert also notes another problem. “These lenses fit in the angle, so we ideally need to know the angle-to-angle measurement,” he points out. “Typically we don’t have that. We can get it with ultrasound biomicroscopy or with an optical coherence tomography scan that spans the entire anterior segment, but these measurements are

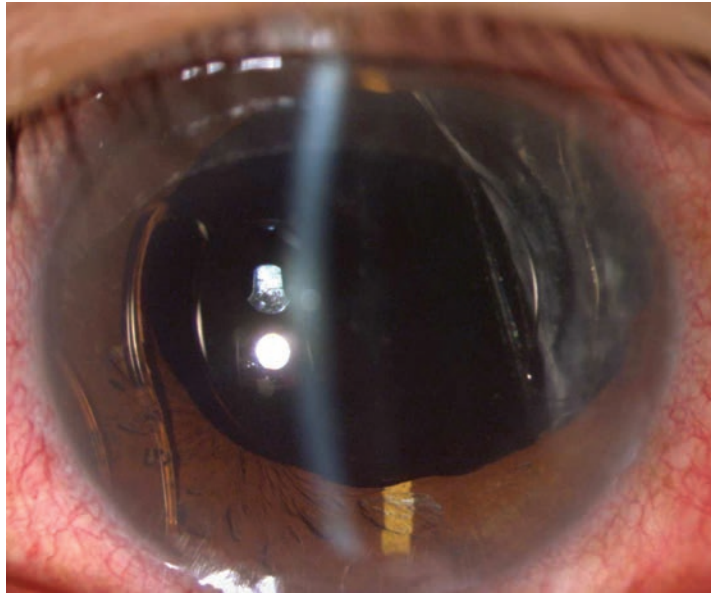
not typically performed preoperatively in all patients. Instead, if we're in the OR and need to implant an ACIOL, we'll just measure the white-to-white distance and add a millimeter. Doing that is common practice, but it's been shown to have fairly poor correlation to the actual angle-to-angle measurement, or even the sulcus measurement.

"Fortunately," he adds, "the lenses are forgiving; they'll adapt a little bit to different anterior chamber sizes, although some lenses are more flexible than others. Generally, a Kelman-design lens with four-point fixation is preferable."

Dr. Weikert also points out that you need a large, 6-mm incision to insert an anterior chamber lens. "Implanting an anterior chamber lens typically requires a scleral incision, so you have to take down conjunctiva, and you need to have enough real estate on the eye to accommodate the large incision," he says. "Of course, you can do a corneal incision for an anterior chamber lens; many surgeons will simply enlarge their clear corneal incision to 6 mm to insert the lens if they encounter complications during cataract surgery. However, that's when you're at risk for creating astigmatism. Also, you'll have to leave the sutures in for a while, so it can take a long time to heal. In contrast, sclerally fixating a smaller, foldable lens that you can fit through a small incision is less likely to create astigmatism, and may lead to a quicker recovery."

Posterior Fixated Lens Issues

Although implanting an ACIOL comes with several caveats, so do most techniques for fixating a posterior



A malpositioned anterior chamber IOL. These can be associated with endothelial failure with corneal edema; chronic intraocular inflammation, or uveitis-glaucoma-hyphema (UGH) syndrome; and cystoid macular edema.

lens is more technically difficult. "Suturing or gluing a posterior chamber IOL is much more technically difficult than placing an anterior chamber IOL, which usually only takes five to 10 minutes," notes Dr. Donaldson. "There is definitely much more technique that has to be learned in order to place a posterior chamber lens in the absence of capsular support. I was recently at a symposium at which there was a whole two-hour section dedicated to the

chamber lens. That makes the choice of which option to pursue a little more challenging.

Issues with lenses fixated in the posterior chamber include:

- **Posterior chamber lenses can also have complications.** "Posterior chamber fixated lenses are more likely to end up with lens tilt, and anticipating effective lens position will always be an issue," notes Dr. Donaldson.

Dr. Fram agrees. "Obviously, the lenses can tilt, and any time you're in the pars plana suturing you're at a higher risk for retinal tear or detachment," she says. "For all of my cases, I perform a careful retinal exam at one week, three weeks and two months. Patients are then followed every six months for maintenance. If the patient has a significant vitreous hemorrhage, or a retinal detachment warning sign such as flashes or floaters, I'll send the patient to a retinal specialist to verify that there's no retinal tear or detachment. You have to treat these cases and patients with the respect they deserve and monitor them carefully."

- **Fixating a posterior chamber**

Yamane technique. One section was focused on complications; people were showing their nightmares, everything they did wrong. Other speakers shared the proper technique. If we can talk about that for two hours, obviously these techniques are not something you just run out and do without proper preparation and practice.

"For that reason, surgeon experience will be a factor here," she continues. "The less-experienced the surgeon, the more likely it is that complications of one type or another will occur. So the answer as to which of these procedures is best for the patient may have a lot to do with how much experience the surgeon has had with the available surgical options."

Dr. Donaldson acknowledges that there is also a small learning curve associated with placing an anterior chamber lens. "You have to do a peripheral iridotomy," she says. "You have to know how to suture properly so you don't induce a lot of corneal astigmatism, and you have to know how to make a good wound. There are a lot of small details that can make a big difference when putting in an

Nicole Fram, MD

Keep Learning

Given that new techniques for fixating posterior chamber lenses keep appearing, it makes sense to take the time to learn at least a few of them. “Lack of capsular support is a situation we all encounter,” notes Kendall E. Donaldson, MD, MS, medical director of Bascom Palmer Eye Institute’s Plantation, Florida location. “If you didn’t encounter it in residency, it will definitely happen to you later on. So, be prepared to perform multiple types of procedures.

“To learn a new procedure, watch videos, talk to colleagues and observe colleagues performing the procedure in question, because we can really learn a lot from each other,” she continues. “You’ll find many videos of any given procedure online, or at the ASCRS or Academy websites. And there are plenty of seminars and symposia at meetings where we discuss these topics and everyone shares their good and bad videos. Those can be great learning experiences.”

Nicole Fram, MD, a clinical instructor of ophthalmology at the Stein Eye Institute, University of California, Los Angeles, points

out that today it’s possible to practice the newer, more challenging procedures using simulation technology. “Simulation training systems such as the SimulEye surgical training models allow us to practice these techniques before a situation occurs at the time of surgery,” she says. “You can practice your anterior vitrectomy technique using triamcinolone, or practice different IOL-fixation suturing techniques.

“For example,” she continues, “you can practice intrascleral fixation with the Yamane double-needle fixation technique. Then, when you need to use it during surgery, you have the muscle memory and the step-by-step process already in your head. Or, you can practice these techniques in a non-stressful environment by taking on a case of a patient who’s aphakic, where the eye is vitrectomized. Later, when you’re in a situation in which you lose the capsule or the zonules, you’re going to be more technically and emotionally prepared for it.”

—CK

anterior chamber lens, but they’re easily learned. I just think the learning curve is longer with some of the posterior chamber techniques, compared to properly placing an anterior chamber lens.”

• **Posterior surgeries take longer.** “This can be a problem if the patient has retinal issues or a history of uveitis,” notes Dr. Donaldson. “You’re more likely to have a vitreous hemorrhage or retinal complications with a longer, more complex case that involves suturing to the sclera, and you may experience iris chafing or uveitis with iris-sutured lenses. And of course, the likelihood of these problems will be greater in an older patient or a complex case when the patient has several pre-existing conditions.”

Do We Have a Winner?

Given that both anterior and posterior chamber lenses have drawbacks, should surgeons favor posterior chamber IOLs?

“In a retrospective study I participated in at Bascom Palmer in the early 2000s, we compared the outcomes in eyes with poor capsular support

that received anterior chamber IOLs to those receiving sutured posterior chamber IOLs,” says Dr. Donaldson. “We found more postoperative astigmatism in the posterior chamber lenses, but overall, we found a similar incidence of complications in the two groups.”¹

Dr. Fram agrees that the research published to date suggests that whether an anterior or posterior lens is chosen, the outcomes tend to be similar. “The Wagoner paper from 2003 compared properly placed anterior chamber IOLs to scleral- and iris suture-fixation techniques and found that all of the options were equivalent,” she says.²

“Of course, we don’t have long-term data for some of the newer techniques for scleral fixation, to compare them to anterior chamber fixation,” Dr. Weikert notes. “But to date, the literature shows them to be about the same under comparable circumstances.”

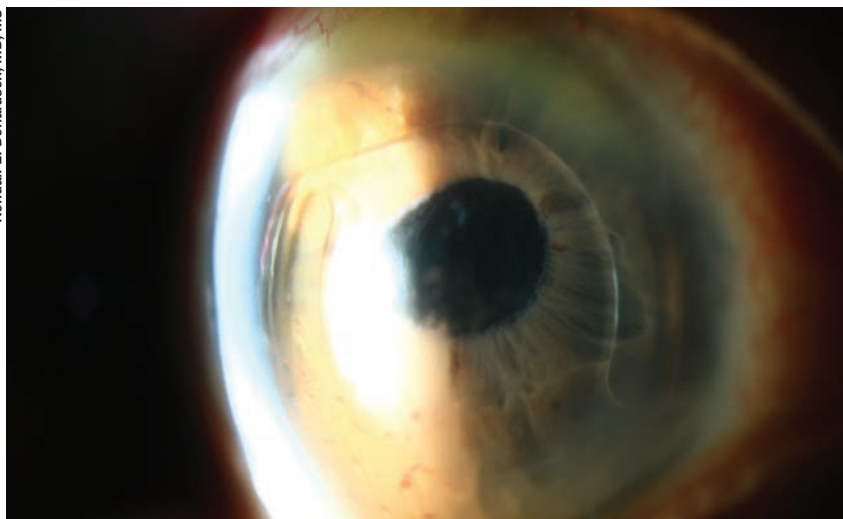
Dr. Donaldson adds that despite all of its potential problems, the anterior chamber lens option is less problematic than it was in the old days, thanks to improvements in lens design. “Thirty or 40 years ago we had closed-loop

anterior chamber lenses,” she points out. “Today we have open-loop anterior chamber lenses that cause less fibrosis and less inflammation in the angle. The older lenses had a higher incidence of UGH syndrome; it was so common with those older model anterior chamber lenses that we developed a name for it! We still see it, but it’s not as common as it used to be. Patients do much better with the modern anterior chamber lenses.”

Nevertheless, Dr. Fram says she prefers to use a fixated posterior lens. “I’ve never met an anterior chamber IOL that I liked over the long term,” she says. “That’s why I was determined to learn other secondary IOL-fixation techniques.”

Dr. Donaldson notes that the option a surgeon chooses is usually based on factors such as surgeon experience, patient age and any co-morbid conditions such as glaucoma or retinal problems. Dr. Weikert offers another perspective: “Ultimately,” he says, “you’re choosing between potential intraoperative complications and potential postoperative complications.”

Surgeons offer the following tips for managing a situation involving weak or



An anterior chamber lens that has developed uveitis-glaucoma-hyphema (UGH) syndrome.

nonexistent zonular support and deciding whether to implant an ACIOL or fixate a posterior chamber lens.

Before Going to Surgery

If you know that you're dealing with limited capsular support:

- **When choosing your approach, consider the patient's age.** Dr. Weikert says that if you know ahead of time that you're likely to be managing limited capsular support, it's important to keep in mind the patient's endothelial cell count and the long-term effect an anterior chamber lens might have. "I'm less inclined to use an anterior chamber lens if the patient is younger," he says. "If a 50-year-old patient comes in who's had trauma, or is aphakic and needs a secondary lens, if the eye has no capsule support I'll favor scleral fixation. If the patient is 75 and has a good cornea, I might decide to implant an anterior chamber lens."

- **Get additional measurements.** "About 90 percent of the time we can anticipate which patients will be at higher risk for an issue with lack of capsular support," notes Dr. Donaldson. "In that situation, preoperative planning is key. We should already have the depth of the anterior chamber. Ideally we'd also get specular mi-

croscopy to look at the endothelial cells."

- **Talk to the patient.** Dr. Donaldson says it's important to address the reality that this surgery could be complex when prepping the patient for surgery. She notes that many patients with preop zonular problems are older. "They might be 90 or 93 years old," she says. "They may have unpredictable eyes, and you may see pseudoexfoliative material on the anterior lens capsule. If the patient has pseudoexfoliation syndrome and you know the capsular support is somewhat compromised, you can talk to the patient about it preoperatively. That makes for a much easier conversation after surgery if a complication occurs."

"For example, I'll say, 'Your eye appears to be weaker than the average eye.' I explain what pseudoexfoliation syndrome is. I may also mention other factors, such as having a very narrow angle that doesn't give us much space in which to work. I tell them, 'We're going to do everything we can to put the lens exactly where we want it to be, but if your eye isn't strong enough to tolerate a lens where we'd like it to be, I'll be prepared to put the lens in an alternative position. Fortunately, we have some options, and we'll do everything we can to get you the best

possible outcome.'

"Once you have that conversation before surgery, the postoperative conversation is easier," she says. "You can either say that everything went perfectly and the lens is right where you wanted it to be, or you can say, 'As expected, we found that your eye was weaker than average, but we were still able to place the lens. We'll just be using extra drops and so forth to handle it.' It opens the window for further discussion."

- **Be prepared to deal with unexpected challenges.** "Dr. Masket always says that you have to have plans A, B and C ready when you go into the OR," Dr. Fram notes. "If you know a patient has pseudoexfoliation and the zonules could be affected, or if you know that a patient has had three vitrectomies and you find phacodonesis on the slit lamp exam, you have to be prepared with multiple options. It's your obligation as a surgeon to be ready. The real difficulties arise when you're not ready and a problem catches you off guard."

"Once you learn to manage the possible nonroutine scenarios, you can think on your feet," she adds. "Until you do that, you'll find it tough to think calmly and clearly in those situations."

- **If the case will be complex, schedule it when you have plenty of time.** "If you know you're doing a complicated case, schedule that case toward the end of the day," says Dr. Donaldson. That way you'll have extra time if you need it, so you don't have to be as stressed. Do your easy cases first and save the more stressful cases for later."

In the OR

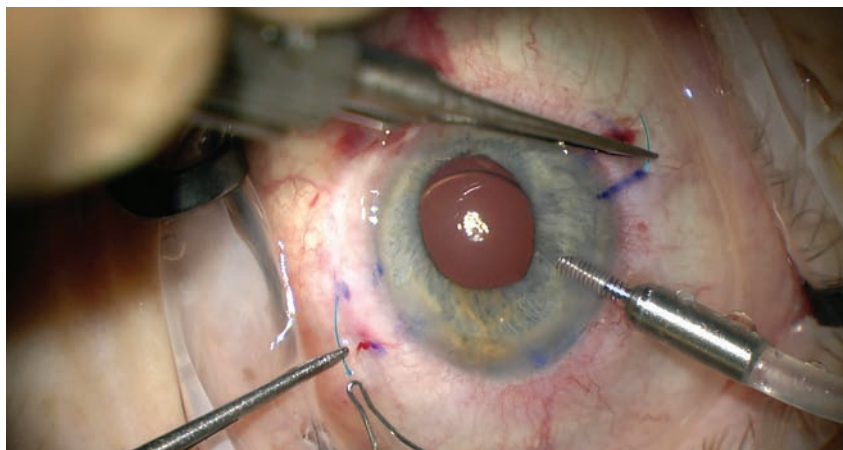
Once you're ready to operate:

- **Have the tools you might need for any of several options on hand.** "Even when I'm planning to use one technique, I'll make sure that I have other options available," says Dr.

Weikert. “If I’m planning for scleral fixation with, say, the Yamane technique, I’ll also make sure an anterior chamber lens is available, just in case. We recently had a case at our veterans hospital where we were going to use the Yamane technique, but we encountered some difficulties with our scleral passages; so, we just changed gears and placed an anterior chamber lens. The patient was older—late 60s, early 70s—and had a good cornea. The bottom line is, no matter what you do, it’s always best to have multiple options.”

Dr. Donaldson agrees. “In a lot of these complicated cases in which we know that the eye is not normal, we might go in with two or three different IOLs,” she says. “We’ve already done the calculations for them. We also make sure we have the extra tools that can help us normalize a compromised capsule and allow us to put a posterior chamber lens in the bag, such as capsular tension rings and Ahmed segments. We wouldn’t have been able to do that years ago, and I’m thankful to our colleagues that have come up with these tools.”

• **Be careful when choosing the size of an anterior segment lens.** “The problem is, we were taught to measure the white-to-white length and then add 1 mm [when gauging the size of the space],” Dr. Fram notes. “That may not be accurate for a given patient. For one thing, the measurement will be different if you measure the white-to-white horizontally or vertically, so placement and location of the lens haptics matter. It could be that white-to-white plus 0.5 mm is more appropriate in some patients. Furthermore, many surgery centers and hospitals don’t stock all the different lens sizes, so surgeons often end up putting in a lens that’s too big or too small. A lens that’s too small ends up bouncing around and causing pigment dispersion and corneal endothelial failure. If it’s too big, you can get



The Yamane technique (above) is one of a number of recently developed ways to fixate a posterior chamber IOL. Fixating a lens posteriorly is presumed to be safer for the cornea than anterior chamber placement, but these techniques can be challenging and time-consuming to perform, and lenses in this location are also associated with complications.

chronic iritis and CME, and eventually have corneal decompensation. It’s better to leave a patient aphakic and come back to place a secondary IOL than to place a malpositioned IOL.”

• **When implanting an anterior chamber lens, make sure you seat it in the angle carefully.** “If you see any iris distortion or ovalization of the pupil, recheck how the lens footplates are seated in the angle,” says Dr. Weikert. “If you can’t get the ovalization to go away by repositioning the lens, consider putting in a smaller lens, leaving the patient aphakic or shifting to scleral fixation.

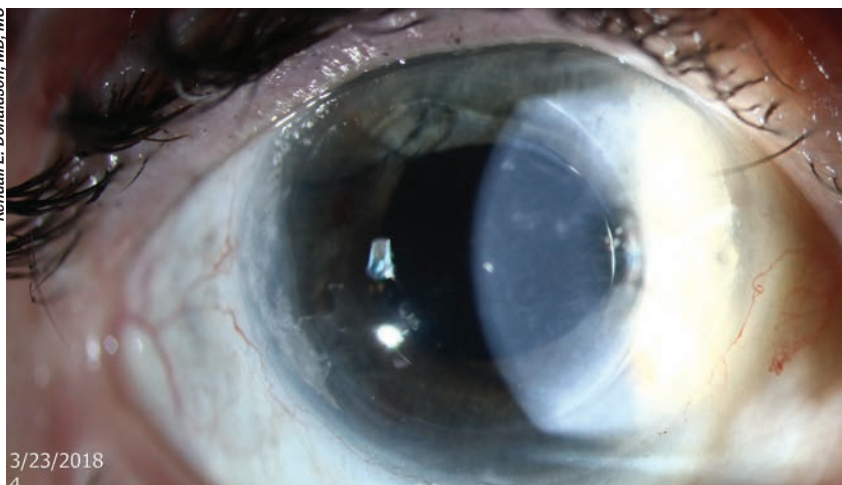
“The dimensions of the anterior chamber are usually a little shorter vertically than horizontally,” he adds. “That means you can always rotate the lens inside the anterior chamber if you think it might sit better. If your incision is temporal and the lens appears loose after insertion, it may actually sit better in a vertical position.”

• **Don’t be afraid to leave the eye aphakic.** “If things didn’t go as planned, and you don’t feel confident that you’re going to end up with a good result after placing a lens at the time of primary surgery, just leave the patient aphakic and come back later,” says Dr. Weikert. “If it’s been a long,

difficult surgery, the cornea is barely hanging on and/or the patient is getting restless, you might create other issues if you try to implant an IOL.

“For example,” he continues, “in our practice we’ve seen complications such as UGH syndrome or cystoid macular edema resulting from single-piece IOLs being placed in the ciliary sulcus because the surgeon didn’t feel comfortable leaving the patient aphakic after a surgical complication. If the appropriate IOL model isn’t available, it’s far better to leave the patient aphakic and come back on a different day to implant an IOL under optimal conditions.”

Dr. Fram points out that in some stressful situations a surgeon might be tempted to try performing a procedure that he or she has only done a few times before, such as suturing a posterior chamber IOL to the iris or sclera. “That might not be the best choice,” she says. “If you’re caught off guard and you don’t know whether the eye is a good candidate for an anterior chamber lens, there’s nothing wrong with leaving the patient aphakic and cleaning everything up and coming back another day. If I’m doing a surgery and it’s an unstable situation and it’s already been two-and-a-half hours



Placement of an ACIOL led to corneal decompensation requiring DSEK surgery for visual rehabilitation for this monocular patient with a history of macular degeneration and retinal detachment repair.

in the OR, I'm not going to start a scleral suture fixation at that point. It's often better to clean up the eye with a proper triamcinolone-assisted vitrectomy, let the eye calm down and come back at a later date. Although it may seem sacrilegious to leave the patient aphakic, in many situations, that's the best thing to do. Admittedly, it does take courage."

Dr. Fram notes that she herself rarely ends up leaving her patients aphakic because her mentors at Wills Eye Hospital and UCSF, and her practice partner for many years, Samuel Masket, MD, trained her to perform the complex anterior segment surgeries. "I've been fortunate to have been trained to perform these surgeries by giants," she says.

ACIOLs: Still Worth Using?

"I do believe there's still a place for an ACIOL, especially if that's your best skill set," Dr. Fram says. "If you get the measurements right, the chamber is deep, you're well-trained to make a scleral tunnel with a frown incision to generate minimal astigmatic changes, and you know how to properly position the anterior chamber IOL, of course that should be your procedure.

But those patients need to be monitored closely, and the lens should be exchanged if problems arise. Of course, this is also the case for scleral-fixated IOLs, because suture or haptic erosion can lead to endophthalmitis if not detected promptly. This is why we see patients every six months irrespective of the stability of the IOL and the refractive outcome."

Dr. Fram says that although she prefers posterior segment placement, she does occasionally implant an anterior segment lens. "You have to consider the age of the patient, the patient's coagulation status and how high-risk the surgery may become," she says. "I probably put in one or two ACIOLs each year, when I believe the patient can't afford to stop [systemic] anticoagulants, or the eye can't support an intrascleral or suture-fixation technique. However, in that situation it's important to evaluate the anterior chamber depth and corneal health prior to placement, and to have appropriate lenses available based on a true white-to-white or sulcus measurement.

"Whether you end up using an ACIOL that's been carefully planned or you perform a scleral-fixated posterior chamber IOL, that's your choice

as the surgeon," she adds. "Until a prospective study comes out showing the true superiority of one technique over another, we're going to have to say that the options are equivalent. Just do the surgery well, and make sure you watch for corneal edema, glaucoma, UGH syndrome and CME. And if a complication happens, deal with it early and consider an IOL exchange."

Dr. Donaldson says she believes there is definitely still a place for anterior chamber lenses when capsular support is weak or missing. "Through the years our options have proliferated, so clearly there's no perfect option that's appropriate in every case," she says. "I think all of our residents and fellows need to be trained to place an anterior chamber lens. Putting in an anterior chamber lens is quick and easy, and may be the best choice in a sick eye or for an older patient who can't undergo a more complicated surgery. And despite the concern about long-term complications, I have some patients who've had anterior chamber lenses for many years and have done very well. The anterior chamber lens has kind of gotten a bad rap."

Dr. Fram says ultimately you should use the technique you feel most comfortable performing. "It doesn't matter what secondary IOL technique you're using as long as the IOL is properly chosen, fixated and monitored," she says. "Just be sure to do your procedure well and reproducibly, and check the patient afterwards to make sure that your interventions are successful and safe for the patient." **REVIEW**

Dr. Fram has previously consulted for Alcon. Drs. Donaldson and Weikert have no financial ties to any company mentioned.

1. Donaldson KE, Gorscak JJ, Budenz DL, et al. Anterior chamber and sutured posterior chamber intraocular lenses in eyes with poor capsular support. *J Cataract Refract Surg* 2005;31:5:903-9.
2. Wagoner MD, Cox TA, Ariyasu RG, Jacobs DS, Karp CL; American Academy of Ophthalmology. Intraocular lens implantation in the absence of capsular support: A report by the American Academy of Ophthalmology. *Ophthalmology* 2003;110:4:840-59.

ENRICH YOUR PRACTICE

Review of Ophthalmology delivers current and comprehensive information focusing on topics such as disease diagnosis, surgical techniques and new technologies.

The *Review Group's Ophthalmic Product Guide* brings you the latest products and technology on the market. Published every February and July.



The *Review Group* also distributes a variety of supplements, guides and handbooks with your subscription to *Review of Ophthalmology*. These publications are designed to keep you informed on what's new and innovative in the industry on topics ranging from cataract refractive surgery to ocular surface disease.

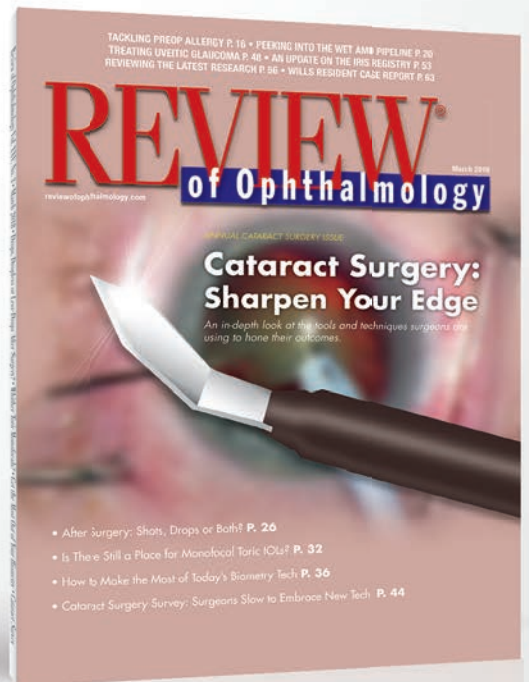


The *Review Group* also offers valuable continuing medical education sessions in both print and online formats, allowing a convenient way for you to earn CME credits. In addition, we also offer an impressive fleet

of free e-newsletters—such as *Review of Ophthalmology Online* and *Review of Ophthalmology's Retina Online*—so you can keep up to date on breaking news and the latest research.



The *Review Group* offers eyecare practitioners quality informational resources dedicated to the growth and education of the profession. The *Review Group* offers a variety of print and online products to enrich your patient care and practice needs.



The *Review Group* also spearheads meetings and conferences, bringing together experts in the field and providing a forum for practitioners that allows you to educate, and learn from others in the profession. These meetings cover a broad range of topics in the form of educational or promotional roundtables and forums.

www.reviewofophthalmology.com



Jobson Medical Information LLC
The *Review Group*



Digging Deeper Into Protocol U

The DRCR Network's study of two treatments for diabetic macular edema revealed the pros and cons of the approaches.

Raj Maturi, MD, Indianapolis

The DRCR Network recently completed Protocol U, a short-term study comparing the addition of a dexamethasone implant (Ozurdex) to ranibizumab (Lucentis) in patients who have continued diabetic macular edema.¹ The impetus for this study was to see whether combined treatment with a corticosteroid and an anti-VEGF agent would improve vision, since, on average, about 40 percent of patients with DME will continue to have retinal thickening as well as reduced vision despite regular anti-VEGF injections over six months. This result was shown in DRCR Protocol I (in the Lucentis groups), as well as in Protocol T (where aflibercept groups had even lower rates of residual edema).

In this article, I'll explain how we DRCR network researchers designed Protocol U, and what its findings might mean for the clinician.

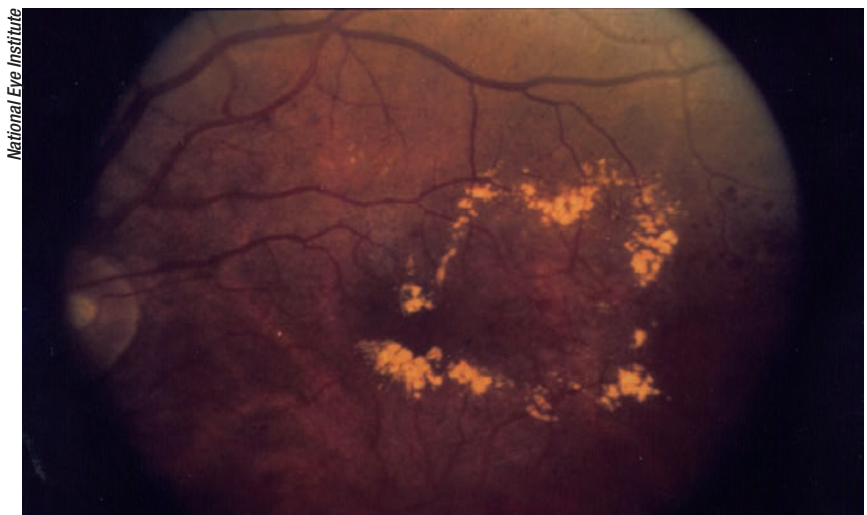
The Study's Design

In Protocol U, we wanted to see whether adding a steroid implant every three months to eyes that continued to have edema would result in improved visual acuity and decreased macular

edema over the next six months compared to Lucentis alone.

For the study, we enrolled 236 patients who had received at least three injections of any anti-VEGF over the prior 20 weeks, but who continued to have macular edema and visual loss. These subjects were all given additional injections of Lucentis every four weeks for 12 weeks (i.e., three additional doses). At the end of this enrollment period, subjects were evaluated to see whether they still had macular edema (over 300 μm on SD-OCT) and

visual loss (worse than BCVA of 20/25 on a standardized ETDRS refraction). A total of 129 subjects who still had edema and vision loss were randomized to either receive a combination of Ozurdex and Lucentis or to continue with Lucentis alone. It's important to note that among those who were not eligible for randomization, many had either resolution of macular edema or improvement of vision before randomization with three additional injections of Lucentis, again demonstrating the benefit of contin-



ued anti-VEGF treatment.


While patients had to have persistent edema despite at least three injections of Lucentis prior to enrollment, we found that providing these same eyes with three additional injections of Lucentis in the enrollment phase resulted in continued improvement in vision and edema. Their vision in the enrollment phase improved on average by three letters, and their edema was reduced by more than 50 μm on average. In fact, about a third of the enrolled subjects either showed resolution of macular edema or achieved vision better than 20/25, and thus were exited from the study. The remaining eligible 129 subjects were randomized per protocol and received an average of 5.6 injections of Lucentis over the next 24 weeks, with the combination group receiving nearly two dexamethasone implants, on average, over the study period as well. Thus, subjects had close to maximal treatment through the duration of the study.

Results of the primary endpoint analysis were consistent with results from previous smaller single-center trials: We found no overall differences in visual acuity between the two groups (Lucentis alone vs. Lucentis + dexamethasone implant). Both groups improved by approximately three additional letters in the randomized, 24th-week phase of the study. However, on pre-planned subgroup analysis, we found that there was a greater proportion of subjects with a 15-letter or greater improvement in vision in the combination vs. the Lucentis-alone group (11 percent vs. 2 percent, $p=0.03$). We also found that the combination group had a small increase in the proportion of patients with a decrease in vision greater than 10 letters (13 percent vs. 6 percent, $p=0.09$), though this wasn't statistically significant.

We also found that the central subfield thickness decreased significantly more in the combination group compared to the Lucentis-alone group (110 μm vs. 62 μm , $p<0.001$). Moreover, about half of the combination group had a flat retina at week 24 compared to 31 percent of the Lucentis-alone group ($p=0.02$), and the improvement in OCT thickness was rapid and sustained in the combination group. This would be expected, as dexamethasone implants were provided every 12 weeks, and not every 24 weeks as per the label, since we felt that the duration of action of these implants required implantation at shorter intervals.

The entry criteria for the study were rather strict with regard to potential subjects not having any history of corticosteroid responsiveness. For example, subjects with a history of developing ocular hypertension in response to topical corticosteroids in the fellow eye at any time in their history were excluded. Despite this careful exclusion, about 30 percent of the combination group had a significant rise in intraocular pressure, with 20 percent of subjects in the combination group requiring treatment for increased IOP.

We found no visual acuity benefit in the combination group



PASSIONATE ABOUT PATIENT CARE?

His sight depends on your confidence.





Ocular Response Analyzer® G3

Corneal Hysteresis, a more objective predictor of glaucoma progression. CPT code 92145.

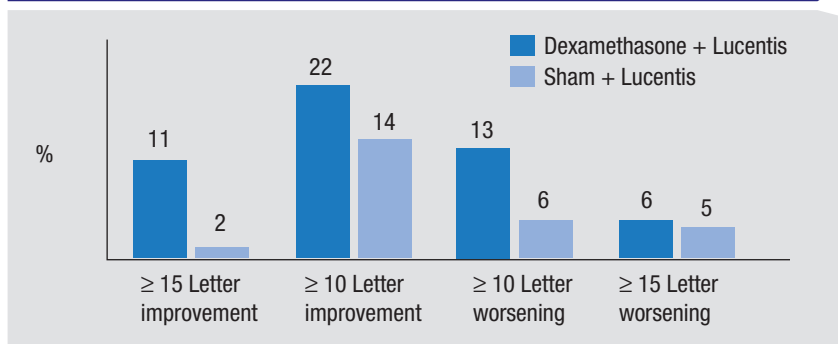
Watch the videos at reichert.com/glaucomaconfidence

Reichert
TECHNOLOGIES

AMETEK © 2018 AMETEK, Inc. & Reichert, Inc. (03-2018) · Made in USA

Ocular Response Analyzer is a registered trademark of Reichert, Inc. · www.reichert.com ·    

Protocol U Visual Acuity Results after DME Treatment¹



over the Lucentis-alone group six months after randomization. It's possible that we would have had different results had the study been longer in duration. However, the visual benefits of adding steroids appear limited in this population. While there was a significant improvement in macular thickness in the combination group, this benefit must be balanced by the high incidence of IOP rise.

Subgroup Analyses

We did multiple subgroup analyses on these subjects:

- **Pseudophakic patients.** The study was initially conceived as a pseudophakic subject-only study. However, it was very difficult to recruit for the study, so we finally expanded the study to include phakic subjects. We examined the pseudophakic subgroup and found that the visual acuity tracked in line with the phakic subgroup acuity through week 20. At the end of the study (week 24 after randomization) the pseudophakic subgroup on combination treatment had a five-letter gain in acuity while the phakic subgroup treated with Lucentis alone had a gain of two letters. This difference at this single time point didn't reach statistical significance.

- **Duration of DME.** Approximately half the subjects had only three injections of anti-VEGF prior to

enrollment, and thus received three additional injections in the run-in phase. Therefore, many subjects in the combination group received only six total injections of anti-VEGF prior to receiving dexamethasone implants. This group's visual acuity didn't improve compared to subjects who had a longer duration of anti-VEGF prior to enrollment. Thus, in this study, earlier treatment with dexamethasone implants didn't appear to result in improved acuity over anti-VEGF alone. Again, the relevance of this finding is limited by the small sample size.

Personal Experience

In my clinical practice, I use intraocular corticosteroids, mostly dexamethasone implants, in select cases. I'm most likely to use the implant in patients who continue to have mild edema despite the use of anti-VEGF therapy, particularly when they're scheduled for cataract surgery in the near future. Pretreatment with a dexamethasone implant in these cases seems to prevent a worsening of macular edema that can occur following surgery. Otherwise, I believe there's only a very limited role for corticosteroids in phakic patients.

There may be a benefit to having a retina without edema vs. a retina that continues to have edema, even if the measured ETDRS visual acuity is the same. The DRCR studies

show that a patient can have stable and even improving vision in the presence of edema for at least two years. However, we may be missing some visual function that is useful for the patient, even if it's not measurable with high contrast ETDRS testing. For example, a patient's low-contrast acuity, useful in the dark, may be limited with increased edema. We just don't know, as few studies look at such variables closely.

Despite the potential benefit of corticosteroids for reducing edema by about 50 percent more than anti-VEGF alone, the side-effect profile of intraocular corticosteroids makes them a less desirable choice. In phakic patients, the risk of cataracts is sufficiently high that I try to avoid their use. Other studies have shown comparable benefit to using steroids with anti-VEGF vs. steroids alone, finding that this approach may limit both the treatment and the cost burdens. However, before going this route, it's best to confirm that the underlying diabetic retinopathy is well-controlled, as I believe corticosteroids don't regress diabetic retinopathy as well as anti-VEGF agents do. In addition, while dexamethasone implant placement may require treatment only every 12 weeks, many patients will require intraocular pressure monitoring every four to eight weeks.

In summary, there are definite anatomic benefits to using Ozurdex over using Lucentis as studied in Protocol U. However, though overall acuity was similar in both groups in the study, the benefits of steroids, and therefore their usage, are limited by their side-effect profile. [REVIEW](#)

Dr. Maturi is an associate professor at the Indiana University School of Medicine. He receives grant support from Allergan and Genentech.

1. Maturi RK, et al. Effect of adding dexamethasone to continued ranibizumab treatment in patients with persistent diabetic macular edema. A DRCR Network phase II randomized clinical trial. JAMA Ophthalmol 2017; DOI:10.1001/jamaophthalmol.2017.4914.

Bausch + Lomb's New Vitrectomy Cutters

In late March, Bausch + Lomb announced the introduction of 25- and 27-gauge Bi-Blade dual port vitrectomy cutters for the Stellaris Elite vision enhancement system.

Bausch + Lomb says its Bi-Blade cutters cut in both the forward and backward directions, enabling two cuts per cycle, as opposed to single-port cutters. The design used with the Stellaris Elite surgical platform offers up to 15,000 cuts per minute, allowing for increased flow efficiency and control.



For more information

on Bausch +

Lomb's new vitrectomy cutters, visit Bausch.com.

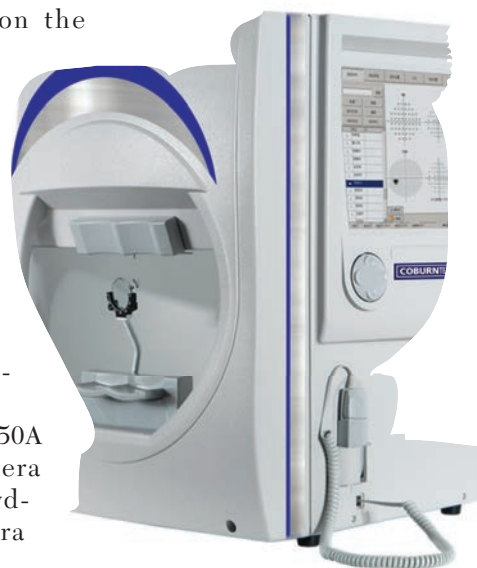Coburn's New Visual Field Analyzer and Retinal Camera

Coburn Technologies recently introduced two new products: the SK-850A visual field analyzer and the SK-650A retinal camera.

The SK-850A comes in two different models (standard and expert), with the expert design coming equipped with enhanced features for more advanced testing. The SK-850A also includes auto gaze tracking (3D fixation monitoring with infrared light tracking of

the pupil on the x, y and z planes), easy-to-read and print reports, and automatic calibration and brightness measurement.

The SK-650A retinal camera is a nonmydriatic camera



that is also DICOM-compatible. The device features an auto mosaic function (a nine-point fixation system allowing for auto-mosaic photography over a large retinal area), red-free visual testing for comparison of nerve fiber layer images over time, and a new optical design that Coburn says features full 45-degree image capture in order to avoid losing fundus information.

For more information on Coburn's new visual field analyzer and retinal camera, visit coburntechnologies.com. [REVIEW](#)



Outcomes of Laser Peripheral Iridotomy

In a retrospective chart review, researchers from the department of ophthalmology at the University of Edinburgh, U.K., examined the outcomes of laser peripheral iridotomy for primary angle closure and determined predictors of future lens extraction.

The investigators analyzed 218 eyes from 128 consecutive patients who underwent LPI between 2010 and 2012 at a university hospital. Baseline factors included age, peak intraocular pressure before LPI, diagnosis (primary angle closure suspect, primary angle closure, primary angle closure glaucoma) and acute or nonacute presentation.

Ninety-one of 218 eyes (41.7 percent) initially treated with LPI had LE during follow-up. For eyes with nonacute presentation, 12 percent, 25 percent and 32 percent had LE at one, two and three years, respectively. For eyes with acute presentation, 27 percent, 42 percent and 50 percent had LE at one, two and three years, respectively. In univariable analysis, older age, higher IOP, worse visual field and primary angle closure glaucoma diagnosis were associated with LE, with older age and higher IOP remaining significant in multivariable analysis. There was a 1.09-fold increase in odds of

LE for each year older at baseline. Each 1 mmHg higher IOP was associated with 1.08-fold increased odds of LE.

Based on these results, a large portion of patients with angle closure treated with LPI went on to require LE. Patients with features associated with higher odds of needing LE might be considered for LE as a primary procedure, the researchers say.

J Glaucoma 2018;27:275-280
Bo J, Vhangulani T, Cheng ML, Tatham AJ

Riboflavin Dosing Intervals in Corneal Cross-linking

Researchers from the Cornea Research Foundation of America in Indianapolis investigated whether riboflavin dosing frequency affects corneal cross-linking efficacy and/or safety, given that isotonic riboflavin solution is viscous and each instillation coats the corneal surface with a film that absorbs some of the incident ultraviolet-A light.

In this prospective, randomized, single-center equivalence trial, researchers studied patients (n=510) with progressive keratoconus or ectasia after refractive surgery. One eye per patient was prospectively randomized to two-minute or five-minute riboflavin dosing intervals with standard corneal cross-linking. Block randomiza-

tion resulted in comparable representation of keratoconus and ectasia after refractive surgery in the two treatment arms. Fellow eyes (n=207) were treated with five-minute dosing and considered in the safety analysis.

The mean reduction in maximum keratometry from baseline was statistically equivalent in the two- and five-minute riboflavin dosing intervals at six months (0.97 and 0.76 D, respectively; 90 percent confidence interval for treatment difference, -0.23 to 0.66; per-protocol population). With both dosing intervals, the mean improvement in corrected distance visual acuity was 3.5 letters at six months. Of the 635 study and fellow eyes examined at six months, 134 (21 percent) gained and 32 (5 percent) lost two or more lines of CDVA. Three eyes (0.4 percent) developed sterile infiltrates, one (0.1 percent) had delayed epithelial healing with dendrites and three (0.4 percent) had recurrent epithelial defects. Three eyes (0.4 percent) were retreated.

The researchers concluded that the two riboflavin dosing regimens produced equivalent reduction in the maximum keratometry value, with a favorable safety profile.

Ophthalmol 2018;125:505-511
Price MO, Fairchild K, Feng MT, Price FW Jr.

Long-term Remission of Neovascular AMD

Researchers from the Shiley Eye Institute, University of California, conducted a study to determine the presenting characteristics of patients with neovascular age-related macular degeneration with long-term remission, which was defined as the absence of intraretinal/subretinal fluid or hemorrhage, and the absence of leakage on fluorescein angiography, for longer than six months while on as-needed antivasular endothelial growth factor treatment.

The presenting characteristics of patients with LTR were compared with a control group including 32 eyes of 28 age-, gender- and ethnicity-matched patients who did not achieve LTR.

Seventy-four percent of patients in the LTR group had Type-1 choroidal neovascular membrane, and 18.5 percent had retinal angiomatous proliferation. In the control group, 28 eyes had Type-1 choroidal neovascular membrane (87.5 percent), and none of the patients had retinal angiomatous proliferation. Overall, there was a significant difference in lesion types between the two groups ($p=0.036$). Eyes with LTR at presentation had significantly thinner subfoveal choroidal thickness (147 vs. 178 μm , $p=0.04$). There was more intraretinal fluid and less subretinal fluid at presentation in the remission group (59.3 percent intraretinal fluid and 11.1 percent subretinal fluid) compared with the control group (28.1 percent intraretinal fluid and 34.4 percent subretinal fluid, $p=0.03$).

According to the results of the study, the presence of retinal angiomatous proliferation, thinner choroidal thickness, more intraretinal fluid and less subretinal fluid at presentation were associated with LTR in patients receiving as-needed treatment for AMD.

Retina 2018;38:516-522

Muftuoglu IL, Alam M, You QS, et al.

Association Between BMI and Open-angle Glaucoma

A study was conducted to investigate the association between body mass index and open-angle glaucoma in a sample of the South Korean population.

The researchers looked at a group that consisted of a cross-sectional, population-based sample of 10,978 participants, 40 years of age and older, enrolled in the 2008 to 2011 Korean National Health and Nutrition Examination Survey. All participants had measured intraocular pressure <22 mmHg and open anterior chamber angles. OAG was defined using disc and visual field criteria established by the International Society for Geographical and Epidemiological Ophthalmology. Multivariable analyses were performed to determine the association between BMI and OAG. These analyses were also performed in a sex-stratified and age-stratified manner.

After adjusting for potential confounding variables, lower BMI (<19 kg/m) was associated with greater risk of OAG compared with normal BMI (19 to 24.9 kg/m) [odds ratio, 2.28; 95 percent confidence interval (CI), 1.22-4.26]. In sex-stratified analyses, low BMI remained related to glaucoma in women (OR, 3.45; 95 percent CI, 1.42-8.38) but not in men (OR, 1.72; 95 percent CI, 0.71-4.20). In age-stratified analyses, lower BMI was related to glaucoma among subjects 40 to 49 years old (OR, 5.16; 95 percent CI, 1.86-14.36) but differences in glaucoma prevalence weren't statistically significant between those with low versus normal BMI in other age strata.

Based on these results, lower BMI was associated with increased odds of OAG in this population. Multivariate analysis revealed the

association to be statistically significant in women and those in the youngest age stratum.

J Glaucoma 2018;27:239-245

Lin SC, Pasquale LR, Singh K, Lin SC

Trabeculectomy Alone vs. Trabs with Ex-Press Shunts

Scientists compared postoperative interventions and outcomes between conventional trabeculectomy and trabeculectomy with the Ex-Press mini glaucoma shunt device, as part of a retrospective, comparative, single-facility study.


They analyzed the cases of 108 individuals with glaucoma who underwent trabeculectomy and were followed for longer than a year. Thirty-nine eyes underwent a conventional trabeculectomy (conventional group), and 69 eyes underwent a trabeculectomy with an Ex-Press. Scientists examined postoperative intraocular pressure, the surgical success rate, postoperative complications, and the number of days to laser suture lysis and needling.

The trabeculectomy significantly decreased IOP values from 27.8 \pm 7.9 to 11.1 \pm 3.9 mmHg in the conventional group ($p<0.001$) and from 27.7 \pm 9.2 to 11.5 \pm 3.7 mmHg in the Ex-Press group ($p<0.001$) after one year. The success rate wasn't significantly different between groups. The timing of the first laser suture lysis was significantly sooner in the Ex-Press group, but the Ex-Press group showed significantly less choroidal detachment due to low IOP.

The authors concluded that, in individuals whose trabeculectomy treatment included an Ex-Press, earlier laser suture lysis was required to obtain outcomes comparable to those of conventional trabeculectomy.

Clin Ophthalmol 2018;12:643-50.

Tojo N, Otsuka M, Hayashi A, et al.



Diagnosing Early Glaucoma: Pearls and Pitfalls

In our ongoing attempts to detect the disease at its earliest stages, new technologies are showing promise.

Angelo P. Tanna, MD, Chicago

When it comes to managing glaucoma, we want to stop damage as early in the disease as possible. For that reason, earlier diagnosis and treatment is obviously desirable, and thanks to technology such as optical coherence tomography, we can better detect structural damage early in the disease course, often before functional abnormalities are detectable with perimetry. This almost certainly should result in fewer patients suffering significant vision loss as a result of glaucoma. Simultaneously, however, we must avoid making an inaccurate diagnosis of glaucoma in patients with anomalies that can be mistaken for disease.

Challenges to Early Diagnosis

One of the biggest challenges when trying to diagnose glaucoma in its earliest stages is the significant variation in the appearance of the optic disc and peripapillary region found in normal eyes. Some anomalous optic discs can be very difficult or impossible to distinguish from glaucomatous discs. Eyes with such optic discs may even have abnormal visual-field

findings that can be confused with glaucomatous field defects. The same is true for the retinal nerve fiber layer and macular ganglion cell complex—anomalous structural characteristics can confound our ability to accurately distinguish between glaucomatous and normal eyes. The normative databases we use every day in the United States to see if our patients fall into the green, yellow or red zones are primarily composed of patients who are not highly myopic and do not have anomalous structural findings; they are “squeaky clean” normals. That’s not always a fair comparison, and it can lead one to incorrectly diagnose glaucoma.

In a patient with an anomalous optic disc, or other ocular characteristics such as high axial length, the best way to accurately establish a diagnosis of glaucoma may be to follow the patient over time, in order to look for significant structural or functional change. If a substantial loss of neural tissue is detected, and other causes have been ruled out, one can establish the diagnosis of glaucoma with a higher degree of certainty. To complicate matters further, however,

there is a certain amount of loss that occurs in both neural tissue thickness and visual function simply as a result of normal aging. That means even a healthy patient will show some losses over time. The interesting twist to this is the fact that automated perimetry software inherently accounts for normal, age-related changes in visual function; however, no optical coherence tomography imaging platform currently makes such an adjustment.

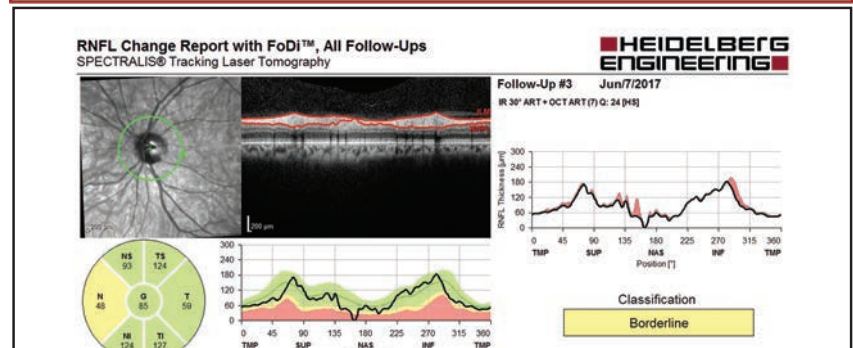
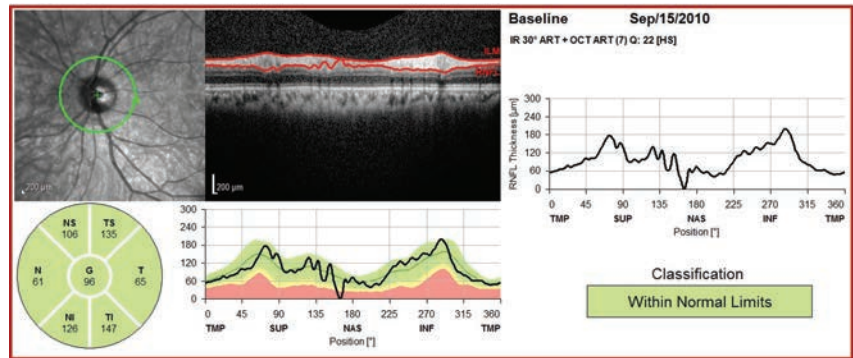
The issue is further complicated when trying to make a diagnosis in a patient with high myopia. Myopic eyes often have a glaucomatous-looking optic disc, even in the absence of glaucoma. That’s a bit of a double-edged sword, because myopia is a risk factor for developing the disease. That means you could be looking at someone who has myopia and suspicious-looking optic nerves, and you might attribute those structural anomalies to the myopia rather than glaucoma. Of course, you might be correct, but that patient will still need to be monitored regularly because myopia is a risk factor for glaucoma. The presence of myopia simply makes it harder to make the diagnosis.

Monitoring with OCT

The reference standard for detecting progressive structural damage used to be comparing stereo photographs of the optic nerve taken over time. With the advent of OCT, that approach is used less frequently, in part because it's more time-consuming than using the automated methods built into the various OCT platforms. There's no question that it's important to use one of these options, but I don't believe it's necessary to use both. If I had a choice of only one of these, I'd rather rely on OCT imaging, but others may disagree. They'd point out the one notable advantage of photographs: Unlike OCT, some argue that this technology doesn't change over time, so you can always compare photographs. OCT technology changes periodically, sometimes making it difficult to compare current data to older data.

With photography, however, technology can change as well. For example, when Kodachrome film was no longer available, the color balance in photographic images changed. In addition, if exposure values differ between photographs, the cup can look larger in the image that's relatively overexposed. Finally, progressive cataract can be more problematic for photographs than for OCT, particularly if the OCT signal strength is good—for example, 7 or higher with Zeiss' Cirrus OCT.

When we use OCT for glaucoma diagnosis and monitoring, there are two things we usually focus on: the thickness of the peripapillary retinal nerve fiber layer and the thickness of the macular ganglion cell layer. (Different OCT platforms use different anatomical criteria for macular thickness that may or may not include the retinal nerve fiber layer and/or the inner plexiform layer, for example.) It can also be helpful to use OCT to assess the optic



This 52-year-old Caucasian man with moderate myopia had ocular hypertension with IOPs ranging from 19 to 26 mmHg. Central corneal thickness was about 560 µm OU; baseline average peripapillary RNFL thickness was 96 µm OS (top). Less than seven years later, an 11-µm decline in thickness was observed (bottom). The visual field remained normal. Imaging studies were of good quality and signal strength, with no segmentation errors, and the change was reproducible at a subsequent follow-up visit. The fairly focal nature of the change in RNFL thickness is highly characteristic of progression.

disc, looking at such factors as the cup-to-disc ratio; cup volume; the rim area; the rim volume; and the BMO-MRW (Bruch's membrane opening, minimum rim width). At the moment I find assessing the optic disc with OCT less valuable than the other measurements because the measurement is not as reproducible as the RNFL and macular thickness measurements—at least using today's technology. BMO-MRW can be very useful, however, in eyes with RNFL imaging artifacts.

What do studies teach us about the relative diagnostic ability of the different things we can measure with OCT? One study published in 2013 compared the sensitivity and specificity of different spectral-domain-OCT measures for diagnosing preperimetric glaucoma.¹ Basically, whether you're looking at the retinal

nerve fiber layer, or the vertical C/D ratio or the ganglion cell complex, the diagnostic accuracy is better for the peripapillary retinal nerve fiber layer thickness and macular ganglion cell thickness than for optic disc characteristics.

One promising possibility for detection of early disease relates to a theory that in patients with POAG, the initial site of injury to the optic nerve is at the level of the lamina cribrosa. Damage to the lamina cribrosa may cause an interruption in the axons' axoplasmic transport, eventually leading to the loss of the axons. It's increasingly feasible to image the lamina cribrosa with OCT, so it's possible that ultimately, this could prove to be the best place to look for early glaucomatous damage.

Many studies have shown the utility of measuring the peripapillary

RNFL thickness for diagnosing and monitoring glaucoma. One particularly strong recent prospective study demonstrated that progressive RNFL thinning determined by GPA (Guided Progression Analysis) is predictive of detectable functional decline in glaucoma.² If you choose to use this approach, these pearls are important to keep in mind:

- **Make sure that you have good, reliable baseline and follow-up images.** This means that the images don't have artifacts and were obtained with good signal strength.

- **When you're monitoring the patient over time, know how much change is significant.** A $\geq 5\text{-}\mu\text{m}$ change in the average retinal nerve fiber layer thickness could be important, because that amount exceeds the OCT test/retest variability. It's also important to remember that the 95 percent confidence interval for normal age-related change in average RNFL thickness is very close to 1 μm per year.³ So if you see a change that exceeds that rate, you have strong evidence that your patient's disease process is worsening. Additionally, a very nice study that followed normal subjects for three years showed that if the baseline average RNFL thickness is very high, the rate of normal, age-related change that occurs can be even greater than 1 μm per year.⁴

- **If your measurements indicate that deterioration may have occurred, repeat the test to verify the progression is real.** This principle also applies to visual field tests.

Alternative Testing Methods

As technology has evolved, new ways to potentially detect and confirm the diagnosis of glaucoma in its earliest stages have appeared, and some of them show promise. In terms of functional testing to detect glaucoma, there is strong evidence that 10-2 visual fields can sometimes detect

abnormalities in glaucoma earlier than standard 24-2 or 30-2 visual fields. The same is true for frequency doubling technology. However, most of us have abandoned short-wavelength automated perimetry because of its poor specificity.

There are also a number of electrophysiological testing strategies that can be used to diagnose glaucoma, such as pattern electroretinography (ERG). Vittorio Porciatti, DSc, at Bascom Palmer, was an early investigator in the use of pattern ERG to detect glaucoma. His group showed that many eyes with ocular hypertension show improvement in pattern ERG amplitudes when their intraocular pressure is lowered. There's a prevailing, widely accepted belief that structural damage occurs before functional damage in glaucoma, but these results suggest that this may depend on how you're looking at structural and functional damage. They also raise the possibility that other approaches to looking at function, such as pattern ERG, might actually be superior to visual field testing, although in my opinion this is still investigational.

A relatively new approach to detecting early glaucoma that's showing promise is OCT angiography. This technology rapidly scans the same tissue area multiple times and analyzes changes in the tissues, thus revealing the presence of blood vessels and the amount of blood flow. There is some early evidence that the reduction in blood flow detectable with this technology is predictive of RNFL thinning. For example, a 2017 study demonstrated that vessel density attenuation in both affected and intact hemiretinas was associated with the extent of visual field damage in the corresponding hemifields.⁵

Using All the Information

Of course, a clinician might well

ask whether pushing the envelope on being able to detect glaucoma earlier truly benefits patients. In reality, glaucoma is usually a slow disease process. There's no overwhelming, convincing evidence that you're on a slippery slope once the disease has progressed a very small amount. So going to heroic lengths to conduct tests that might reveal very early disease is arguably not necessary.

Obviously it's useful to be attentive when monitoring patients who are glaucoma suspects, and it makes sense to try to get a diagnosis while the disease is still at an early stage. In some cases you may find an early visual field defect that matches a defect in the nerve fiber layer that's visible on OCT, for example, so it's possible to detect glaucoma early without going to unusual lengths. For the time being, I don't believe that excessive and repetitive testing—especially testing that's still on the boundaries of what is proven to be useful, such as pattern ERG—has any utility outside of research. However, I do believe strongly that standard perimetry and OCT imaging of the macula and peripapillary RNFL on an annual basis is important.

When it comes to making a diagnosis of early glaucoma and deciding whether to initiate treatment, these strategies are worth keeping in mind:

- **Use all of the data that are available to you.** This should certainly include information about the optic disc appearance, the visual field test results and imaging data.

- **Know what to look for.** Different patterns of damage can result from glaucoma. When following a patient over time, focal damage—in which an area of the visual field, or the retinal nerve fiber layer or the ganglion cell complex is distinctly damaged compared to surrounding tissue—is generally easier to detect than diffuse damage, such as when the entire nerve fiber layer has thinned.

• **Take into account the quality of the data you've captured.** In particular, be on the lookout for measurement artifacts associated with the technology you're using.

• **When you see a change or a new abnormality, repeat the test to verify that the findings are accurate.** Given test-retest variability, avoid drawing conclusions based on a single test result without confirming that result first.

• **Take into account other important risk factors that are associated with glaucoma.** If the patient has a suspicious retinal nerve fiber layer and an optic disc hemorrhage, that definitely increases the likelihood that the patient has glaucoma.

• **Take family history into account.** In the Ocular Hypertension Treatment Study, family history was not identified as risk factor for conversion to glaucoma; however, most of us believe that this was because the patients' histories may not have been ascertained accurately in the study.

• **Take the patient's age and general health into account.** This could be relevant in terms of deciding how important it is to diagnose glaucoma very early, and even whether to initiate treatment.

Doing What We Can

There's no question that there's an advantage to detecting glaucoma early. Unfortunately, the earlier you try to detect glaucoma, the more sensitive your testing algorithm has to be, and the more testing you have to do. In general, when trying to diagnose glaucoma early using the diagnostic methodologies available to us today, higher sensitivity of the diagnostic algorithm comes at the cost of lower specificity. In other words, the earlier we try to establish the diagnosis of glaucoma, the higher

the likelihood that we'll arrive at that diagnosis incorrectly. So the real question is, how early do we need to detect glaucoma, and to what degree should we compromise specificity in order to accomplish that? Since glaucoma is usually slowly progressive, we usually have the luxury of time; if we monitor our glaucoma suspect patients on an annual or semiannual basis, it's very unlikely that patients with early disease will progress in a fashion that results in noticeable visual impairment. There's little risk in waiting until you're sure.

I think it's important to explain this to patients who are being monitored as glaucoma suspects. We can tell them that at this point in time it's not possible to be certain about their diagnosis. However, we can also reassure them that the disease generally progresses slowly. I tell patients that with careful monitoring we will be able to detect any significant changes early because of all of the advanced testing we're able to do. And as soon as we do detect concrete evidence of a problem—if we ever do—we can initiate therapy. I think that's an important message to be able to give patients. **REVIEW**

Dr. Tanna is an associate professor of ophthalmology, director of glaucoma and vice chair of the Department of Ophthalmology at the Feinberg School of Medicine at Northwestern University in Chicago.

1. Lisboa R, Paranhos A Jr, Weinreb RN, et al. Comparison of different spectral domain OCT scanning protocols for diagnosing preperimetric glaucoma. *Invest Ophthalmol Vis Sci* 2013;13:54:5:3417-25.
2. Yu M, Lin C, Weinreb RN, et al. Risk of visual field progression in glaucoma patients with progressive retinal nerve fiber layer thinning: a 5-year prospective study. *Ophthalmology* 2016;123:6:1201-10.
3. Leung CK, Ye C, Weinreb RN, Yu M, Lai G, Lam DS. Impact of age-related change of retinal nerve fiber layer and macular thicknesses on evaluation of glaucoma progression. *Ophthalmology* 2013;120:12:2485-92.
4. Leung CK, Yu M, Weinreb RN, Ye C, Liu S, Lai G, Lam DS. Retinal nerve fiber layer imaging with spectral-domain optical coherence tomography: a prospective analysis of age-related loss. *Ophthalmology* 2012;119:4:731-7.
5. Yarmohammadi A, Zangwill LM, Diniz-Filho A, et al. Peripapillary and macular vessel density in patients with glaucoma and single-hemifield visual field defect. *Ophthalmology* 2017;124:5:709-719.

For advertising opportunities contact:
Michele Barrett (215) 519-1414
or mbarrett@jobson.com

James Henne (610) 492-1017
or jhenne@jobson.com

Michael Hoster (610) 492-1028
or mhoster@jobson.com

Akorn Consumer Health 18-21

Phone (800) 579-8327
www.akornconsumerhealth.com

Beaver-Visitec International, Inc. 51

Phone (866) 906-8080
Fax (866) 906-4304
www.beaver-visitec.com

Johnson & Johnson Surgical Vision, Inc. 2

https://surgical.jnjvision.com

Keeler Instruments 17

Phone (800) 523-5620
Fax (610) 353-7814

Regeneron Pharmaceuticals, Inc. 7

Phone (914) 847-7000
www.regeneron.com

Reichert Technologies 61

Phone (888) 849-8955
Fax (716) 686-4545
www.reichert.com

S4OPTIK 25, 27

Phone (888) 224-6012

Shire Ophthalmics 75, 76

www.shire.com

Topcon Medical Systems 10-11

Phone (800) 223-1130
Fax (201) 599-5250

This advertiser index is published as a convenience and not as part of the advertising contract. Every care will be taken to index correctly. No allowance will be made for errors due to spelling, incorrect page number, or failure to insert.

Practice For Sale



Practice Sales • Appraisals • Consulting
www.PracticeConsultants.com

**PRACTICES FOR SALE
NATIONWIDE**

Visit us on the Web or call us to learn more about our company and the practices we have available.

info@PracticeConsultants.com

800-576-6935

www.PracticeConsultants.com

Career Opportunities

OPHTHALMOLOGISTS
Danbury, CT

Ophthalmologists to share office with long standing Ophthalmologist in Danbury, CT. High quality equipment. \$2,250 per month or adjoining office without equipment- \$1,750 per month.

**203-545-3539 or
email mehrimd@aol.com**



**FOR CLASSIFIED
ADVERTISING
CONTACT US TODAY:**

Toll free: **888-498-1460**

E-mail: sales@kerhgroup.com



Career Opportunities



Targeting
Ophthalmologists?

**CLASSIFIED ADVERTISING
WORKS**



Contact us today
for classified advertising:
Toll free: **888-498-1460**
E-mail: sales@kerhgroup.com



FIND MORE PRACTICES FOR SALE ON



CONTACT US TODAY to list your practice:

888-498-1460

opticlassifieds@kerhgroup.com

www.opticlassifieds.com

A middle-aged man with esophageal cancer presents with a presumed case of central serous chorioretinopathy.

Samir N. Patel, MD, and Carol L. Shields, MD

Presentation

A 58-year-old man noted progressive vision loss in both eyes. He was seen by a retina specialist and found to have subretinal fluid in the right eye suggestive of central serous chorioretinopathy. He was initially followed for one month but developed progressive vision loss in the right eye with subsequent involvement of the left. His symptoms didn't improve with one injection of intravitreal bevacizumab, and he was referred to the Ocular Oncology Service at Wills Eye Hospital for a second opinion.

Medical History

Six months prior to presentation, he was diagnosed with stage IV esophageal cancer with nodal metastasis involving the supraclavicular, mediastinal and retroperitoneal region. He had completed five cycles of docetaxel for the malignancy. Additional medications included dexamethasone, prochlorperazine, lorazepam, oxycodone and granisetron. Past ocular history was notable for a retinal detachment in the right eye that had been repaired with surgery 12 years prior. Family history was noncontributory and social history was notable for being a former smoker. He was allergic to ciprofloxacin.

Examination

On ophthalmic examination the uncorrected visual acuity was counting fingers with no pinhole improvement in the right eye and 20/40 with no pinhole improvement in the left. The pupils were equal, round and reactive to light without afferent pupillary defect. Applanation tonometry revealed intraocular pressure of 17 mmHg in the right eye and 12 mmHg in the left eye.

External examination was unremarkable. Anterior segment examination revealed symmetric conjunctival injection and bilateral cataract with moderate nuclear sclerosis, and anterior and posterior subcapsular opacification in both eyes.

On dilated fundoscopic examination, both eyes had multifocal subtle pigmented choroidal lesions. There were six lesions in the right eye, ranging from 1 mm to 6 mm in diameter, and there was extensive subretinal orange pigment, particularly nasally and inferonasally (*Figure 1A*). The left eye showed similar but less advanced findings with three pigmented choroidal lesions, all measuring 1 mm or less in diameter with diffuse overlying orange pigment (*Figure 1B*).

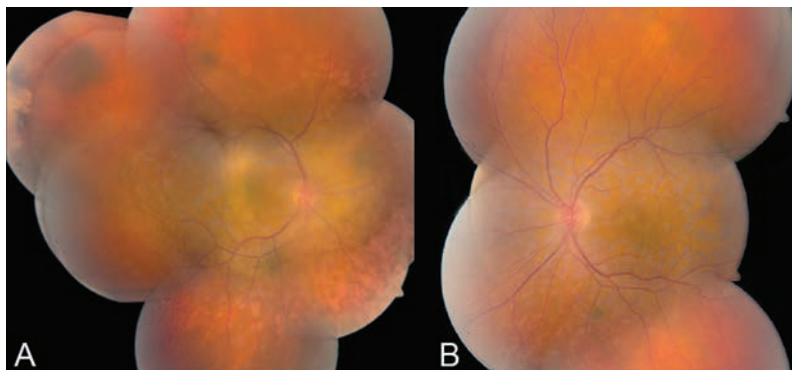


Figure 1. Montage color fundus photograph of the right eye (A) and left eye (B) revealing bilateral multifocal subtle pigmented choroidal lesions and diffuse nummular retinal pigment epithelial loss, submacular and peripheral geographic orange lipofuscin pigment, and subretinal fluid.

What is your diagnosis? What further workup would you pursue? The diagnosis appears on p. 72.

Workup, Diagnosis and Treatment

Fundus photography was performed (*Figure 1*). Optical coherence tomography showed multiple areas of fresh subretinal fluid and macular edema (*Figure 2*). Fluorescein angiography in the right eye revealed extensive multifocal sites of early hyperfluorescence, presumed to represent “window defects” of retinal pigment epithelial loss. There was circumpapillary staining. The pigmented choroidal lesions were hypofluorescent (*Figure 3*). Similar findings were noted in the left eye.

In summary, this patient had stage IV esophageal cancer and new-onset bilateral multifocal pigmented choroidal lesions with subretinal fluid, cystoid macular edema, extensive RPE mottling and prominent subretinal orange lipofuscin pigment. The differential diagnosis included:

- multifocal choroidal nevi;
- melanoma;
- metastases;
- bilateral diffuse uveal melanocytic proliferation (BDUMP);
- cancer-associated retinopathy;
- acute exudative polymorphous paraneoplastic vitelliform maculopathy; and
- medication-associated retinopathy from docetaxel.

Given the bilateral multifocal pigmented choroidal tumors and associated rapid-onset cataracts and conjunctival injection, the leading diagnosis was BDUMP.

Plasmapheresis was considered, but after discussion with the patient’s primary oncologist, the patient’s

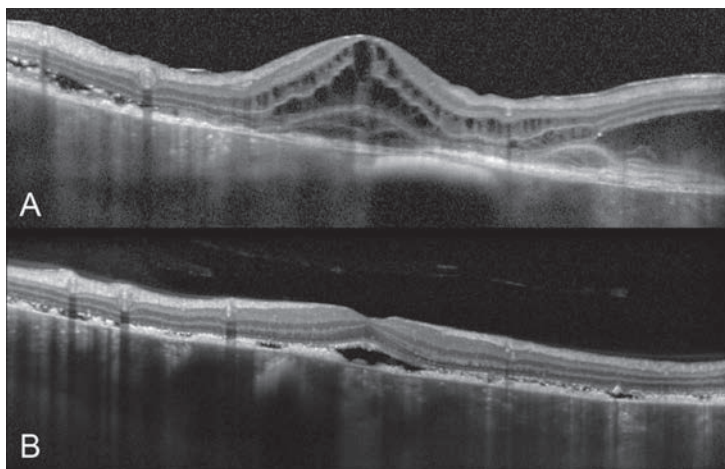


Figure 2. Spectral domain optical coherence tomography of the right and left eyes. A) The right eye demonstrates multiple areas of subretinal and intraretinal fluid with focal destruction of the retinal layers and nodularity of the retinal pigment epithelium. B) The left eye demonstrates multiple areas of subretinal fluid with RPE nodularity. Note the diffuse choroidal thickening with loss of choroidal vascular details, suggestive of infiltration.

clinical status was considered inappropriate for plasmapheresis at that time. The patient declined to undergo anti-retinal antibody testing. He was started on oral prednisone 80 mg per day. Follow-up one month later revealed persistent poor vision of counting fingers in the right eye, with a decline to 20/150 in the left eye. The fundoscopic examination revealed unchanged findings. The patient was tapered off the oral corticosteroids and started on an intraocular corticosteroid with 2 mg of intravitreal triamcinolone. The patient was subsequently lost to follow-up.

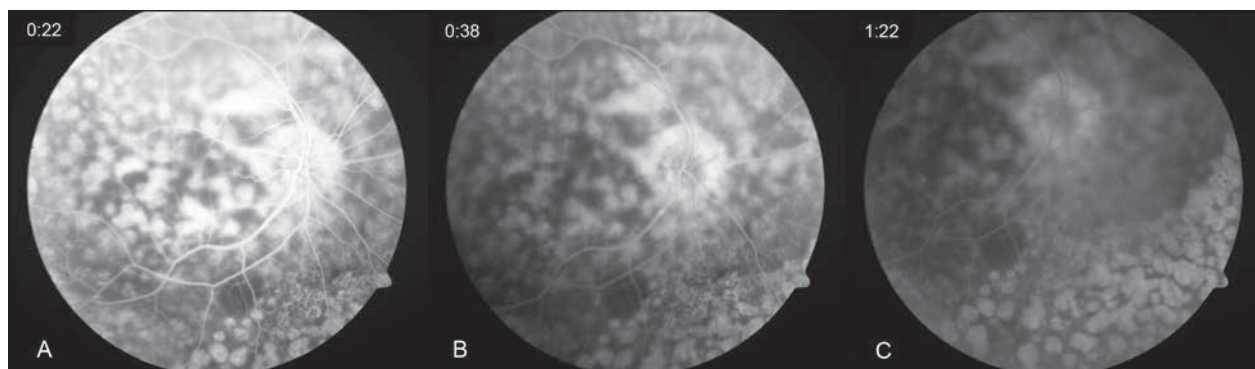


Figure 3. Fluorescein angiography of the right eye. Early-phase angiogram (A) revealing a “window defect” hyperfluorescence of the multiple nummular retinal pigment epithelial atrophic lesions. Mid- (B) and late-phase (C) angiograms showing persistent hyperfluorescence of RPE defects and mild staining. Similar findings were observed in the left eye.

Discussion

BDUMP is a rare paraneoplastic syndrome resulting in severe bilateral vision loss and proliferation of choroidal melanocytes. Retina specialist J. Donald Gass and co-workers described the five cardinal signs for the diagnosis of BDUMP, including: 1) multiple, subtle, round, orange-red subretinal patches in the fundus; 2) multifocal early hyperfluorescence of these patches on fluorescein angiography; 3) focally elevated pigmented and non-pigmented uveal melanocytic tumors with diffuse choroidal thickening; 4) exudative retinal detachment; and 5) rapidly progressive cataract formation.¹ A characteristic “giraffe pattern” on fundus autofluorescence can be seen in BDUMP. It is believed to be secondary to nummular or polygonal RPE alterations and lipofuscin accumulation.^{2,3}

In nearly half of the cases of BDUMP, there is a current or remote diagnosis of non-ocular malignancy at the time of diagnosis.⁴ BDUMP has no gender predilection and is associated with multiple visceral malignancies including cancer of the lung, colon, pancreas, gallbladder, ovary, uterus and cervix.⁴ Salient aspects of its causes and management include the following:

- **Pathogenesis.** The pathogenesis of BDUMP is poorly understood, but multiple theories have been suggested.⁵⁻⁷ One proposed hypothesis is that there may be production of melanocytic growth factors by the remote cancer cells with subsequent release into the circulation. A group of investigators recently studied the serum of patients with BDUMP and isolated an IgG antibody called cultured melanocyte elongation and proliferation (CMEP) factor that was involved in human melanocyte proliferation.⁵ This proliferation was found to be selective for melanocyte growth factor, since other cell

lines—including human dermal fibroblasts, keratinocytes and ovarian cancer cells—that were treated with plasma from BDUMP patients containing the CMEP factor didn't show proliferation.

Another study further supported these findings by demonstrating changes in melanocyte proliferation based on the presence or absence of the CMEP factor in BDUMP patients undergoing plasmapheresis.⁸ In this study, the plasma of a patient with BDUMP before systemic treatment induced growth of cultured melanocytes, confirming the presence of the CMEP factor; however, plasma from a patient treated with plasmapheresis did not induce melanocyte proliferation.⁸ Collectively, these findings suggested that treatment of the underlying malignancy and plasmapheresis eliminated CMEP and potentially reduced ocular manifestations of BDUMP. Indeed, the presence of the circulating CMEP factor may explain why approximately 26 percent of BDUMP patients have pigmented lesions in extraocular tissues such as the skin and mucous membranes.⁵ Our patient declined to undergo serum testing due to cost considerations.

Other studies have suggested a possible role of anti-retinal antibodies in photoreceptor destruction, as these circulating antibodies have been detected in BDUMP patients; however, their significance is unclear as these studies were confounded by the presence of multiple paraneoplastic retinopathies.^{7,9} Some investigators have proposed that there may be a common oncogenic stimulus initiating both the ocular and nonocular tumors.^{6,7}

- **Management.** Treatment options for BDUMP are poorly understood and produce variable responses. As BDUMP is stimulated by a

systemic malignancy, varied treatments of the primary malignancy by combinations of surgery, radiation and/or chemotherapy may confound reported visual outcomes. Based on a recent review article, the treatment options for BDUMP include no treatment, primary tumor treatment, intraocular surgery (e.g., retinal detachment surgery with subretinal fluid drainage), ocular radiation, local and systemic steroid treatment, cataract surgery, intravitreal bevacizumab injection and plasmapheresis.¹⁰

BDUMP is partly characterized by cataract formation, which can occur rapidly. This is hypothesized to result from ciliary body tumor invasion, leading to inadequate aqueous volume or poor nutrient composition.¹¹ Cataract surgery is a common treatment option and serves as a temporizing measure for visual acuity improvements but hasn't been shown to improve vision permanently when used as a sole intervention.^{4,10,11}

Recently, plasmapheresis has emerged as a promising novel treatment for improving visual acuity in patients with BDUMP. Based on the suspicion of a circulating CMEP factor, plasmapheresis theoretically could remove the inciting factor from the serum. There have been several cases identified in the literature employing plasmapheresis for the treatment of BDUMP.^{8,9,12-18} One group postulated the use of plasmapheresis in BDUMP and described an example of a 71 year-old woman with metastatic papillary serous adenocarcinoma of the endometrium with a visual acuity of 20/40 OU and fundoscopic findings consistent with BDUMP.¹³ She underwent a course of plasmapheresis with seven volume exchange sessions every other day. She continued on the chemotherapy regimen for malignancy control and

eventually underwent bilateral cataract extraction. At 13-month follow up, the pigmented fundus lesions remained stable in size, and her visual acuity was 20/25 OU. Another study documented a similar case of a 59 year-old woman with metastatic ovarian cancer and visual acuity of 20/150 OU who was diagnosed with BDUMP.¹⁴ The patient declined chemotherapy and underwent plasmapheresis three times per week and reported subjective improvement in her vision in both eyes at four months follow-up.

In summary, BDUMP should be considered in the differential diagnosis of patients with bilateral multifocal pigmented choroidal lesions, whether or not a known history of malignancy exists. Patients with a diagnosis of BDUMP have a poor prognosis, but novel treatments continue to evolve in order to improve

their quality of life and visual outcomes. **REVIEW**

- Gass JD, Gieser RG, Wilkinson CP, Beahm DE, Pautler SE. Bilateral diffuse uveal melanocytic proliferation in patients with occult carcinoma. *Arch Ophthalmol* 1990;108:4:527-533.
- Wu S, Slakter JS, Shields JA, Spaide RF. Cancer-associated nummular loss of the pigment epithelium. *Am J Ophthalmol* 2005;139:5:933-935.
- Rahimy E, Soheilian M. Giraffe pattern of bilateral diffuse uveal melanocytic proliferation. *Ophthalmology* 2016;123:3:483.
- Rahimy E, Sarraf D. Paraneoplastic and non-paraneoplastic retinopathy and optic neuropathy: Evaluation and management. *Surv Ophthalmol* 2013;58:5:430-458.
- Miles SL, Niles RM, Pittcock S, et al. A factor found in the IgG fraction of serum of patients with paraneoplastic bilateral diffuse uveal melanocytic proliferation causes proliferation of cultured human melanocytes. *Retina* 2012;32:9:1959-1966.
- Barr CC, Zimmerman LE, Curtin VT, Font RL. Bilateral diffuse melanocytic uveal tumors associated with systemic malignant neoplasms. A recently recognized syndrome. *Arch Ophthalmol* 1982;100:2:249-255.
- Saito W, Kase S, Yoshida K, et al. Bilateral diffuse uveal melanocytic proliferation in a patient with cancer-associated retinopathy. *Am J Ophthalmol* 2005;140:5:942-945.
- Jansen JC, Van Calster J, Pulido JS, et al. Early diagnosis and successful treatment of paraneoplastic melanocytic proliferation. *Br J Ophthalmol* 2015;99:7:943-948.
- Mets RB, Golchet P, Adamus G, et al. Bilateral diffuse uveal melanocytic proliferation with a positive ophthalmoscopic and visual response to plasmapheresis. *Arch Ophthalmol* 2011;129:9:1235-1238.
- Moreno TA, Patel SN. Comprehensive review of treatments for bilateral diffuse uveal melanocytic proliferation: A focus on plasmapheresis. *Int Ophthalmol Clin* 2017;57:1:177-194.
- O'Neal KD, Butnor KJ, Perkinson KR, Proia AD. Bilateral diffuse uveal melanocytic proliferation associated with pancreatic carcinoma: A case report and literature review of this paraneoplastic syndrome. *Surv Ophthalmol* 2003;48:6:613-625.
- Navajas EV, Simpson ER, Krema H, et al. Cancer-associated nummular loss of RPE: Expanding the clinical spectrum of bilateral diffuse uveal melanocytic proliferation. *Ophthalmic Surg Lasers Imaging* 2011;42:e103-106.
- Jaben EA, Pulido JS, Pittcock S, Markovic S, Winters JL. The potential role of plasma exchange as a treatment for bilateral diffuse uveal melanocytic proliferation: A report of two cases. *J Clin Apher* 2011;26:6:356-361.
- Alasil T, Coody PA, Koudsi S, Mathur M, Materin MA. Bilateral diffuse uveal melanocytic proliferation: A case report. *Retin Cases Brief Rep* 2017;11:1:71-74.
- Schelvergem KV, Wirix M, Nijs I, Leys A. Bilateral diffuse uveal melanocytic proliferation with good clinical response to plasmapheresis and treatment of the primary tumor. *Retin Cases Brief Rep* 2015;9:2:106-108.
- Alrashedi S, Aziz AA, Krema H. Bilateral diffuse uveal melanocytic proliferation: A management dilemma. *BMJ Case Rep.* May 22, 2014. doi: 10.1136/bcr-2014-204387.
- Pulido JS, Flotte TJ, Raja H, et al. Dermal and conjunctival melanocytic proliferations in diffuse uveal melanocytic proliferation. *Eye (Lond)* 2013;27:9:1058-1062.
- Katz MSJ, Leder HA, Choudhury T. Successful treatment of bilateral diffuse uveal melanocytic proliferation with plasmapheresis. *Journal of VitreoRetinal Diseases* 2017;2474126417724656.

Hiring Ophthalmic Staff?

More Ophthalmic Technicians Find Jobs On Local Eye Site Than Anywhere Else.

localeyesite.com



Local Eye Site
JOBS IN EYE CARE



BRIEF SUMMARY:

Consult the Full Prescribing Information for complete product information.

INDICATIONS AND USAGE

Xiidra® (lifitegrast ophthalmic solution) 5% is indicated for the treatment of the signs and symptoms of dry eye disease (DED).

DOSAGE AND ADMINISTRATION

Instill one drop of Xiidra twice daily (approximately 12 hours apart) into each eye using a single-use container. Discard the single-use container immediately after using in each eye. Contact lenses should be removed prior to the administration of Xiidra and may be reinserted 15 minutes following administration.

CONTRAINDICATIONS

Xiidra is contraindicated in patients with known hypersensitivity to lifitegrast or to any of the other ingredients in the formulation.

ADVERSE REACTIONS

Clinical Trials Experience

Because clinical studies are conducted under widely varying conditions, adverse reaction rates observed in clinical studies of a drug cannot be directly compared to rates in the clinical trials of another drug and may not reflect the rates observed in practice. In five clinical studies of dry eye disease conducted with lifitegrast ophthalmic solution, 1401 patients received at least 1 dose of lifitegrast (1287 of which received lifitegrast 5%). The majority of patients (84%) had ≤ 3 months of treatment exposure. 170 patients were exposed to lifitegrast for approximately 12 months. The majority of the treated patients were female (77%). The most common adverse reactions reported in 5-25 % of patients were instillation site irritation, dysgeusia and reduced visual acuity. Other adverse reactions reported in 1% to 5% of the patients were blurred vision, conjunctival hyperemia, eye irritation, headache, increased lacrimation, eye discharge, eye discomfort, eye pruritus and sinusitis.

Postmarketing Experience

The following adverse reactions have been identified during postapproval use of Xiidra. Because these reactions are reported voluntarily from a population of uncertain size, it is not always possible to reliably estimate their frequency or establish a causal relationship to drug exposure.

Rare cases of hypersensitivity, including anaphylactic reaction, bronchospasm, respiratory distress, pharyngeal edema, swollen tongue, and urticaria have been reported. Eye swelling and rash have been reported.

USE IN SPECIFIC POPULATIONS

Pregnancy

There are no available data on Xiidra use in pregnant women to inform any drug associated risks. Intravenous (IV) administration of lifitegrast to pregnant rats, from pre-mating through gestation day 17, did not produce teratogenicity at clinically relevant systemic exposures. Intravenous administration of lifitegrast to pregnant rabbits during organogenesis produced an increased incidence of omphalocele at the lowest dose

tested, 3 mg/kg/day (400-fold the human plasma exposure at the recommended human ophthalmic dose [RHOD], based on the area under the curve [AUC] level). Since human systemic exposure to lifitegrast following ocular administration of Xiidra at the RHOD is low, the applicability of animal findings to the risk of Xiidra use in humans during pregnancy is unclear.

Animal Data

Lifitegrast administered daily by intravenous (IV) injection to rats, from pre-mating through gestation day 17, caused an increase in mean preimplantation loss and an increased incidence of several minor skeletal anomalies at 30 mg /kg / day, representing 5,400-fold the human plasma exposure at the RHOD of Xiidra, based on AUC. No teratogenicity was observed in the rat at 10 mg /kg /day (460-fold the human plasma exposure at the RHOD, based on AUC). In the rabbit, an increased incidence of omphalocele was observed at the lowest dose tested, 3 mg /kg /day (400-fold the human plasma exposure at the RHOD, based on AUC), when administered by IV injection daily from gestation days 7 through 19. A fetal No Observed Adverse Effect Level (NOAEL) was not identified in the rabbit.

Lactation

There are no data on the presence of lifitegrast in human milk, the effects on the breastfed infant, or the effects on milk production. However, systemic exposure to lifitegrast from ocular administration is low. The developmental and health benefits of breastfeeding should be considered, along with the mother's clinical need for Xiidra and any potential adverse effects on the breastfed child from Xiidra.

Pediatric Use

Safety and efficacy in pediatric patients below the age of 17 years have not been established.

Geriatric Use

No overall differences in safety or effectiveness have been observed between elderly and younger adult patients.

NONCLINICAL TOXICOLOGY

Carcinogenesis, Mutagenesis, Impairment of Fertility

Carcinogenesis: Animal studies have not been conducted to determine the carcinogenic potential of lifitegrast.

Mutagenesis: Lifitegrast was not mutagenic in the *in vitro* Ames assay. Lifitegrast was not clastogenic in the *in vivo* mouse micronucleus assay. In an *in vitro* chromosomal aberration assay using mammalian cells (Chinese hamster ovary cells), lifitegrast was positive at the highest concentration tested, without metabolic activation.

Impairment of fertility: Lifitegrast administered at intravenous (IV) doses of up to 30 mg/kg/day (5400-fold the human plasma exposure at the recommended human ophthalmic dose (RHOD) of lifitegrast ophthalmic solution, 5%) had no effect on fertility and reproductive performance in male and female treated rats.

Shire

Manufactured for: Shire US Inc., 300 Shire Way, Lexington, MA 02421.

For more information, go to www.Xiidra.com or call 1-800-828-2088.

Marks designated ® and ™ are owned by Shire or an affiliated company.

©2018 Shire US Inc. SHIRE and the Shire Logo are trademarks or registered trademarks of Shire Pharmaceutical Holdings Ireland Limited or its affiliates.

Patented: please see <https://www.shire.com/legal-notice/product-patents>

Last Modified: 01/2018 S33769



SIGNS & SYMPTOMS HAVE MET THEIR MATCH

Xiidra is the only treatment FDA-approved
to treat both signs and symptoms of Dry Eye



Proven to treat
signs of inferior corneal staining
AT 12 WEEKS
in 3 of 4 trials



Proven to treat
symptoms of eye dryness
AT 6 AND 12 WEEKS
in all 4 trials

Xiidra is contraindicated in patients with known hypersensitivity to lifitegrast or to any of the other ingredients.

Xiidra is the only prescription
eye drop to show symptom relief from
eye dryness in 2 out of 4 clinical trials
IN AS LITTLE AS 2 WEEKS

Check it out at Xiidra-ECP.com

Four randomized, double-masked, 12-week trials evaluated the efficacy and safety of Xiidra versus vehicle as assessed by improvement in the signs (measured by Inferior Corneal Staining Score on a scale of 0 to 4) and symptoms (measured by Eye Dryness Score on a scale of 0 to 100) of Dry Eye Disease (N=2133).

Indication

Xiidra® (lifitegrast ophthalmic solution) 5% is indicated for the treatment of signs and symptoms of dry eye disease (DED).

Important Safety Information

Xiidra is contraindicated in patients with known hypersensitivity to lifitegrast or to any of the other ingredients.

In clinical trials, the most common adverse reactions reported in 5-25% of patients were instillation site irritation, dysgeusia and reduced visual acuity. Other adverse reactions reported in 1% to 5% of the patients were blurred vision, conjunctival hyperemia, eye irritation, headache, increased lacrimation, eye discharge, eye discomfort, eye pruritus and sinusitis.

To avoid the potential for eye injury or contamination of the solution, patients should not touch the tip of the single-use container to their eye or to any surface.

Contact lenses should be removed prior to the administration of Xiidra and may be reinserted 15 minutes following administration.

Safety and efficacy in pediatric patients below the age of 17 years have not been established.

For additional safety information, see accompanying Brief Summary of Safety Information on the adjacent page and Full Prescribing Information on Xiidra-ECP.com.