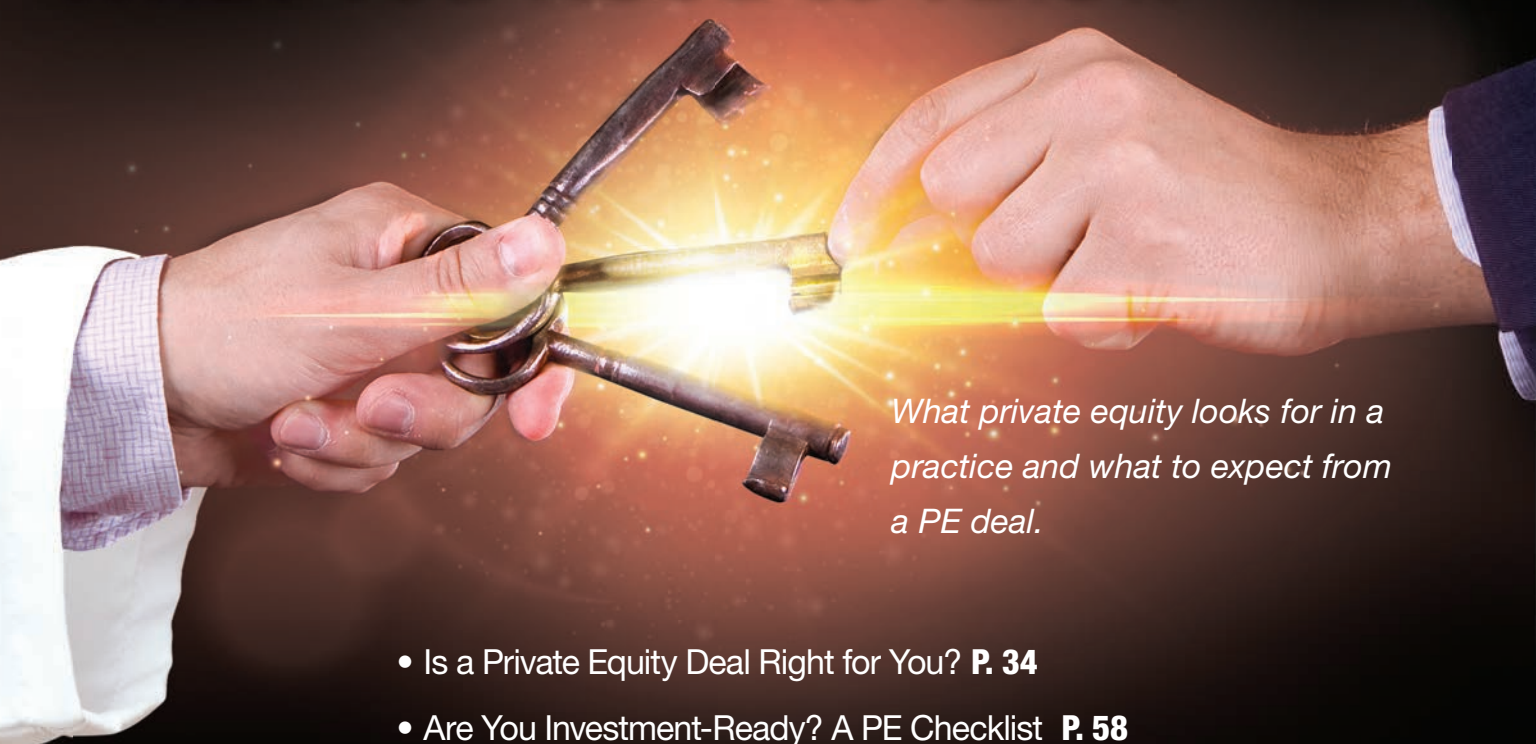


REVIEW[®] of Ophthalmology

April 2018

reviewofophthalmology.com

Private Equity in Ophthalmology: What You Need to Know



What private equity looks for in a practice and what to expect from a PE deal.

- Is a Private Equity Deal Right for You? **P. 34**
- Are You Investment-Ready? A PE Checklist **P. 58**

ALSO INSIDE:

- Vitreous Floaters: What Can Be Done? **P. 48**
- Angle Closure: Peripheral Laser Iridotomy vs. Cataract Surgery **P. 53**

WHITESTAR
SIGNATURE® PRO

**CHOOSE A SYSTEM
THAT EMPOWERS YOUR
EVERY MOVE.**

Technique is more than just the motions.

Purposefully engineered for exceptional versatility and high-quality performance, the **WHITESTAR SIGNATURE® PRO** Phacoemulsification System gives you the clinical flexibility, confidence and control to free your focus for what matters most in each procedure.

It's all in

**your
hands.**

Let's talk.

Contact your phaco specialist today.
WHITESTARSIGNATUREPRO.COM

Rx Only

INDICATIONS: The WHITESTAR SIGNATURE® PRO System is a modular ophthalmic microsurgical system that facilitates anterior segment (cataract) surgery. The modular design allows the users to configure the system to meet their surgical requirements. **IMPORTANT SAFETY INFORMATION:** Risks and complications of cataract surgery may include broken ocular capsule or corneal burn. This device is only to be used by a trained, licensed physician. **ATTENTION:** Reference the labeling for a complete listing of Indications and Important Safety Information.

WHITESTAR SIGNATURE is a trademark of Johnson & Johnson Surgical Vision, Inc.

© Johnson & Johnson Surgical Vision, Inc. 2018 | www.WhitestarSignaturePRO.com | PP2018CT0258

Johnson & Johnson VISION

A Guidepost for Diabetic Macular Edema Treatment?

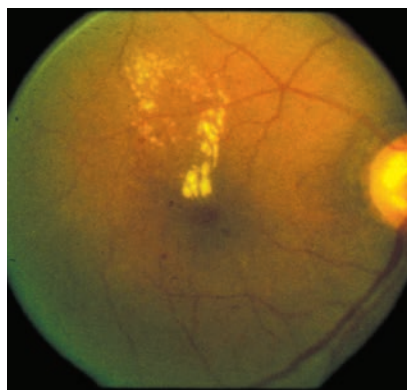A group of researchers from Canada, the United Kingdom and Australia say that a common inflammatory molecule in the eye may be able to tip off physicians about which DME patients will respond best to therapy.

In an article published online in *JAMA Ophthalmology*, the investigators set out to discover if levels of inflammatory cytokines in the aqueous had any bearing on DME patients' response to the anti-vascular endothelial growth factor drug ranibizumab (Lucentis, Genentech).

"Over the years, what we've noticed with anti-VEGF injection for DME is that, though anti-VEGF has been a great class of drugs that's saved a lot of patients' vision, there's a subset of patients who don't respond well to anti-VEGF drugs," says study co-author Rajeev Muni, MD, assistant professor in the Department of Ophthalmology and Vision Sciences at the University of Toronto. The researchers proceeded to look for biomarkers that might clue them in to the non-responders.

In the prospective multicenter cohort study, 49 patients with diabetes mellitus complicated by center-involving DME received monthly injections of ranibizumab 0.5 mg for three months. They each had a central subfield thickness of 310 μm or greater on spectral-domain optical coherence tomography. At baseline and two months, the researchers obtained aqueous fluid for cytokine analysis. They performed multiplex immunoassays in duplicate for the following:

- VEGF;



- placental growth factor;
- transforming growth factor beta 2;
- intercellular adhesion molecule 1 (ICAM-1);
- interleukin 6 (IL-6), IL-8, IL-10;
- vascular intercellular adhesion molecule; and
- monocyte chemoattractant protein 1.

"We demonstrated that there are two cytokines that are particularly important," Dr. Muni says. "One is VEGF, which makes sense because the drug we use blocks it. However, VEGF was only associated after correcting for certain other variables. The other, more surprising, cytokine that was important was ICAM-1, which was highly associated with patients' response to treatment. Patients with high levels of ICAM-1 were much more likely to respond to treatment with intravitreal ranibizumab injections, while those with lower levels were less likely to respond to the drug. With VEGF, though, the lower the level, the more likely they were to respond. The higher the level of VEGF, the

less likely they were to respond." Specifically, every additional 100 pg/mL of baseline ICAM-1 was associated with a reduction of 0.0379 mm^3 of macular volume after treatment ($p=0.01$), and every additional 100 pg/mL of baseline VEGF was associated with an increase of 0.0731 mm^3 . ($p=0.02$). The latter was also associated with lower odds of that patient being a central subfield thickness responder (odds ratio, 0.868; 95% CI, 0.755-0.998). Dr. Muni says the section of the study discussing the probability of a patient responding to treatment might be particularly interesting to clinicians. "It's interesting that for every 100-pg/ml increase in ICAM-1, the odds of response increase by 27 percent," he says. "So, if someone has a 200- or 300-pg/ml level of ICAM-1, the chance of responding rises significantly. In the same way, for every 100 pg/ml increase in VEGF, their odds go *down* by 20 percent. So, this might potentially be powerful in determining who's going to respond and who isn't."

"The main finding of this study is that this kind of represents the beginning of a more personalized approach to measuring a patient's cytokine levels and using them to help us determine what the best treatment approach would be for that particular patient, or how likely they would be to respond to the drug," Dr. Muni says. "It could help us guide our treatment for diabetic macular edema in a more targeted, personalized way."

(Continued on p. 6)

CONTRIBUTORS

CHIEF MEDICAL EDITOR

Mark H. Blecher, MD

CONTACT LENSES

Penny Asbell, MD

CORNEA / ANTERIOR SEGMENT

Thomas John, MD

GLAUCOMA MANAGEMENT

Peter Netland, MD, PHD
Kuldev Singh, MD

MASTERS OF SURGERY

Taliva D. Martin, MD
Sara J. Haug, MD, PhD

MEDICARE Q & A

Paul M. Larson, MBA

PEDIATRIC PATIENT

Wendy Huang, MD

PLASTIC POINTERS

Ann P. Murchison, MD, MPH

REFRACTIVE SURGERY

Arturo S. Chayet, MD

RETINAL INSIDER

Carl Regillo, MD, FACS
Emmett T. Cunningham Jr., MD, PHD, MPH

TECHNOLOGY UPDATE

Steven T. Charles, MD
Michael Colvard, MD

WILLS RESIDENT CASE SERIES

Thomas Jenkins, MD.

ADVISORY BOARD

PENNY A. ASBELL, MD, NEW YORK CITY

WILLIAM I. BOND, MD, PEKIN, ILL.

ALAN N. CARLSON, MD, DURHAM, N.C.

Y. RALPH CHU, MD, EDINA, MINN.

ADAM J. COHEN, MD, DOWNERS GROVE, ILL.

UDAY DEVGAN, MD, FACS, LOS ANGELES

ERIC DONNENFELD, MD, ROCKVILLE CENTRE, N.Y.

DANIEL S. DURRIE, MD, KANSAS CITY, MO.

ROBERT EPSTEIN, MD, MCHENRY, ILL.

ROBERT D. FECHTNER, MD, NEWARK, N.J.

WILLIAM J. FISHKIND, MD, TUCSON, ARIZ.

JAMES P. GILLS, MD, TARPON SPRINGS, FLA.

HARRY GRABOW, MD, SARASOTA, FLA.

DOUGLAS K. GRAYSON, MD, NEW YORK CITY

THOMAS S. HARBIN, MD, MBA, ATLANTA

DAVID R. HARDTEN, MD, MINNEAPOLIS

KENNETH J. HOFFER, MD, SANTA MONICA, CALIF.

JACK T. HOLLADAY, MD, MSEE, HOUSTON

JOHN D. HUNKELER, MD, KANSAS CITY, MO.

THOMAS JOHN, MD, TINLEY PARK, ILL.

ROBERT M. KERSHNER, MD, MS, FACS, BOSTON

GUY M. KEZIRIAN, MD, PARADISE VALLEY, ARIZ.

TERRY KIM, MD, DURHAM, N.C.

TOMMY KORN, MD, SAN DIEGO

DAVID A. LEE, MD, HOUSTON

FRANCIS S. MAH, MD, PITTSBURGH

NICK MAMALIS, MD, SALT LAKE CITY

WILLIAM G. MARTIN, MD, OREGON, OHIO

MIKE S. MCFARLAND, MD, PINE BLUFF, ARK.

JEFFREY B. MORRIS, MD, MPH, ENCINITAS, CALIF.

MARLENE R. MOSTER, MD, PHILADELPHIA

ROBERT J. NOECKER, MD, FAIRFIELD, CONN.

ROBERT OSHER, MD, CINCINNATI

MARK PACKER, MD, WEST PALM BEACH, FLA.

STEPHEN PASCUCCI, MD, BONITA SPRINGS, FLA.

PAUL PENDER, MD, BEDFORD, N.H.

CHRISTOPHER J. RAPUANO, MD, PHILADELPHIA

AUGUST READER III, MD, SAN FRANCISCO

TONY REALINI, MD, MORGANTOWN, W.V.

KENNETH J. ROSENTHAL, MD, GREAT NECK, N.Y.

ERIC ROTHCHILD, MD, DELRAY BEACH, FLA.

SHERI ROWEN, MD, BALTIMORE

JAMES J. SALZ, MD, LOS ANGELES

INGRID U. SCOTT, MD, MPH, HERSHEY, PA.

JOEL SCHUMAN, MD, PITTSBURGH

GAURAV SHAH, MD, ST. LOUIS

DAVID R. STAGER JR., MD, DALLAS

KARL STONECIPHER, MD, GREENSBORO, N.C.

JAMES C. TSAI, MD, NEW YORK CITY

VANCE THOMPSON, MD, SIOUX FALLS, S.D.

FARRELL C. TYSON, MD, CAPE CORAL, FLA.

R. BRUCE WALLACE III, MD, ALEXANDRIA, LA.

ROBERT G. WILEY, MD, CLEVELAND

FRANK WEINSTOCK, MD, CANTON, OHIO

BUSINESS OFFICES

11 CAMPUS BOULEVARD, SUITE 100
NEWTOWN SQUARE, PA 19073
SUBSCRIPTION INQUIRIES (877) 529-1746
(USA ONLY); OUTSIDE USA, CALL (847) 763-9630

BUSINESS STAFF

PUBLISHER

JAMES HENNE

(610) 492-1017 JHENNE@JOBSON.COM

REGIONAL SALES MANAGER

MICHELE BARRETT

(610) 492-1014 MBARRETT@JOBSON.COM

REGIONAL SALES MANAGER

MICHAEL HOSTER

(610) 492-1028 MHOSTER@JOBSON.COM

CLASSIFIED ADVERTISING

(888)-498-1460

VICE PRESIDENT OF OPERATIONS

CASEY FOSTER

(610) 492-1007 CFOSTER@JOBSON.COM

PRODUCTION MANAGER

SCOTT TOBIN

(610) 492-1011 STOBIN@JOBSON.COM

SUBSCRIPTIONS

\$63 A YEAR, \$99 (U.S.) IN CANADA,
\$158 (U.S.) IN ALL OTHER COUNTRIES.

SUBSCRIPTIONS E-MAIL:

REVOPHTHALMOLOGY@CAMBEYWEST.COM

CIRCULATION

PO BOX 71, CONGERS, NY 10920-0071
(877) 529-1746

OUTSIDE USA: (845) 267-3065

SENIOR CIRCULATION MANAGER

HAMILTON MAHER

(212) 219-7870 hmaher@jhihealth.com

CEO, INFORMATION GROUP SERVICES

MARC FERRARA

SENIOR VICE PRESIDENT, OPERATIONS

JEFF LEVITZ

VICE PRESIDENT, HUMAN RESOURCES

TAMMY GARCIA

VICE PRESIDENT, CREATIVE SERVICES & PRODUCTION

MONICA TETTAMANZI

CORPORATE PRODUCTION DIRECTOR

JOHN ANTHONY CAGGIANO

VICE PRESIDENT, CIRCULATION

EVELDA BAREA



440 Ninth Avenue, 14th Floor
New York, N.Y. 10001

REVIEW OF OPHTHALMOLOGY (ISSN 1081-0226; USPS No. 0012-345) is published monthly, 12 times per year by Jobson Medical Information, 440 Ninth Avenue, 14th Floor, New York, N.Y. 10001. Periodicals postage paid at New York, NY and additional mailing offices. Postmaster: Send address changes to Review of Ophthalmology, PO Box 71, Congers, NY 10929-0071. Subscription Prices: US One Year \$63.00, US Two Year \$112.00, Canada One Year \$99.00, Canada Two Year \$181.00, Int'l One Year \$158.00, Int'l Two Year \$274.00. For subscription information call (877) 529-1746 (USA only); outside USA, call (845)-267-3065. Or email us at revophthalmology@cambeywest.com. Canada Post: Publications Mail Agreement #40612608. Canada Returns to be sent to Bleuchip International, P.O. Box 25542, London, ON N6C 6B2.

FOR THE REDUCTION OF IOP IN MILD TO MODERATE PRIMARY
OPEN-ANGLE GLAUCOMA AT THE TIME OF CATARACT SURGERY



1 and done

ONE CYPASS® MICRO-STENT IS ALL IT TAKES TO CONNECT
TO SAFE, CONSISTENT, LONG-TERM IOP CONTROL

IN THE COMPASS STUDY AT TWO YEARS^{1,2}:


- 72.5% of patients achieved a $\geq 20\%$ reduction in IOP (n=374)
- 93% of patients were medication free*
- Safety profile similar to cataract surgery alone



FOR AN EXPERIENCE LIKE NO OTHER, CONNECT WITH AN ALCON REPRESENTATIVE TODAY.

*Those patients who attained an unmedicated mean diurnal IOP reduction of 20% or more as compared to baseline in the absence of IOP-affecting surgery during the study.

References: 1. CyPass® Micro-Stent Instructions for Use. 2. Vold S, Ahmed IK, Craven ER, et al. Two-year COMPASS trial results: supraciliary microstenting with phacoemulsification in patients with open-angle glaucoma and cataracts. *Ophthalmology*. 2016;123(10):2103-2112.



CyPass® Micro-Stent

IMPORTANT PRODUCT INFORMATION

CAUTION: FEDERAL (USA) LAW RESTRICTS THIS DEVICE TO SALE BY OR ON THE ORDER OF A PHYSICIAN.

INDICATION: The CyPass® Micro-Stent is indicated for use in conjunction with cataract surgery for the reduction of intraocular pressure (IOP) in adult patients with mild to moderate primary open-angle glaucoma (POAG).

CONTRAINDICATIONS: Use of the CyPass Micro-Stent is contraindicated in the following circumstances or conditions: (1) in eyes with angle-closure glaucoma; and (2) in eyes with traumatic, malignant, uveitic, or neovascular glaucoma or discernible congenital anomalies of the anterior chamber angle.

MRI INFORMATION: The CyPass Micro-Stent is magnetic resonance (MR) Safe: the implant is constructed of polyimide material, a non-conducting, non-metallic, non-magnetic polymer that poses no known hazards in all magnetic resonance imaging environments.

WARNINGS: Gonioscopy should be performed prior to surgery to exclude peripheral anterior synechiae (PAS), rubeosis, and other angle abnormalities or conditions that would prohibit adequate visualization of the angle that could lead to improper placement of the stent and pose a hazard.

PRECAUTIONS: The surgeon should monitor the patient postoperatively for proper maintenance of intraocular pressure. The safety and effectiveness of the CyPass Micro-Stent has not been established as an alternative to the primary treatment of glaucoma with medications, in patients 21 years or younger, in eyes with significant prior trauma, chronic inflammation, eyes with an abnormal anterior segment, eyes with chronic inflammation, eyes with glaucoma associated with vascular disorders, pseudophakic eyes with glaucoma, eyes with uveitic glaucoma, eyes with pseudoexfoliative or pigmentary glaucoma, eyes with other secondary open-angle glaucomas, eyes that have undergone prior incisional glaucoma surgery or cilioablativ procedures, eyes with laser trabeculoplasty performed ≤ 3 months prior to the surgical screening visit, eyes with unmedicated IOP less than 21 mmHg or greater than 33 mmHg, eyes with medicated IOP greater than 25 mmHg, in the setting of complicated cataract surgery with iatrogenic injury to the anterior or posterior segment, and when implantation is without concomitant cataract surgery with IOL implantation for visually significant cataract. The safety and effectiveness of use of more than a single CyPass Micro-Stent has not been established.

ADVERSE EVENTS: In a randomized, multicenter clinical trial comparing cataract surgery with the CyPass Micro-Stent to cataract surgery alone, the most common postoperative adverse events included: BCVA loss of 10 or more letters at 3 months after surgery (8.8% for the CyPass Micro-Stent vs. 15.3% for cataract surgery only); anterior chamber cell and flare requiring steroid treatment 30 or more days after surgery (8.6% vs. 3.8%); worsening of visual field mean deviation by 2.5 or more decibels (6.7% vs. 9.9%); IOP increase of 10 or more mmHg 30 or more days after surgery (4.3% vs. 2.3%); and corneal edema 30 or more days after surgery, or severe in nature (3.5% vs. 1.5%).

ATTENTION: PLEASE REFER TO THE INSTRUCTIONS FOR A COMPLETE LIST OF CONTRAINDICATIONS, WARNINGS, PRECAUTIONS, AND ADVERSE EVENTS.

Alcon A Novartis Division

© 2017 Novartis 9/17 US-CYP-17-E-2272

REVIEW | News |

(Continued from p. 3)

Restasis Patent Evaluation Proceeds

In late February, a U.S. administrative court ruled that it has the authority to evaluate the validity of Allergan's Restasis patents despite its transfer to the Saint Regis Mohawk Tribe. The Patent Trial and Appeal Board (overseen by the U.S. patent office) dismissed a request to throw out the litigation of a competing drug company, Mylan NV, challenging Allergan's handling of its patents on the dry-eye drug Restasis.

In September of 2017, Allergan transferred its patents on Restasis to the New York-based Native American tribe. It was argued that the tribe's status as a sovereign entity, gave immunity to *inter partes* reviews of the patents. This had the potential to eliminate the competition that Allergan would normally face from generic companies such as Mylan. The Restasis patents are scheduled to expire in 2024. Until then, unless these patents are invalidated in court, Allergan reserves the sole right to manufacture Restasis. Around the same time as the patent sale to the tribe was occurring, the U.S. District Court for the Eastern District of Texas invalidated four of the six Restasis patents. The judge in that decision also commented on the company's arrangement with St. Regis Mohawk as the "renting" of tribal sovereignty to serve as a shield from *inter partes* patent reviews.

However, the Patent Trial and Appeal Board recently denied the Tribe's motion to dismiss Mylan's challenge, on multiple grounds. The board ruled that tribal immunity doesn't apply to patent-review proceedings, dealing a setback to Allergan. In addition, the tribunal ruled that because Allergan had retained ownership interest in the challenged patents, the proceedings could continue without the tribe's participation or consent, as they had no ownership over them. They also ruled that the tribe failed to establish the doctrine of tribal sovereign immunity. An oral hearing is set for April 3, followed by a written decision that will be due by June 6.

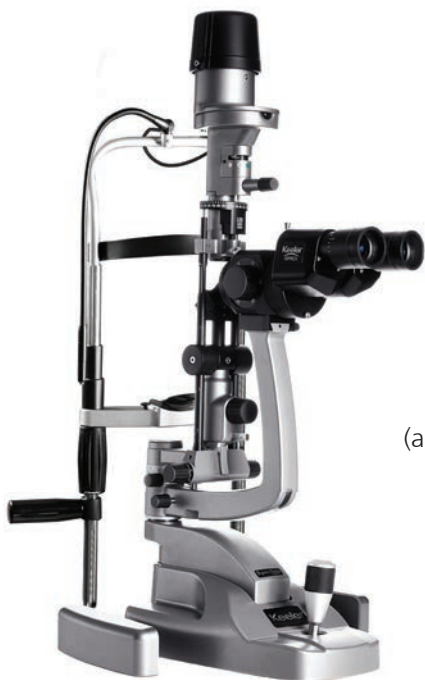"Mylan has always been vocal in its efforts to challenge and break down barriers to access," said Mylan's chief executive officer Heather Bresch in a prepared statement. "We will continue to be steadfast in our efforts on both the legal and regulatory fronts to bring a generic version of Restasis to patients as quickly as possible."

Allergan declined to comment. **REVIEW**

The Keeler³ Trade In Program

Buy 3 // Trade 3 // Get 1 Free

The Power of 3. Purchase any 3 Keeler Slit Lamps and trade in 3 of your old Slit Lamps and we'll send you a 4th Keeler Slit Lamp absolutely free of charge.



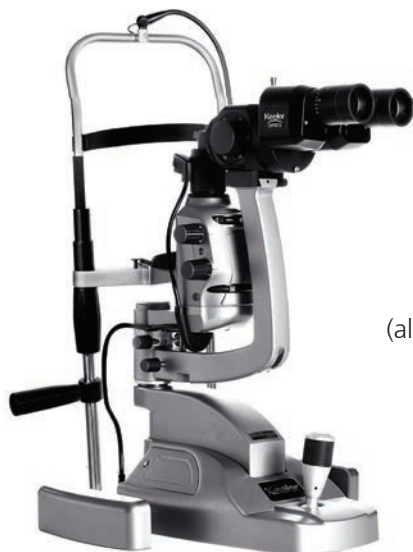KSL-H

(also in Digital Ready)



KSL-H-D

(full Digital)



KSL-Z

(also in Digital Ready)



KSL-H-D

(full Digital)




Keeler Instruments, Inc. • 3222 Phoenixville Pike, bldg. 50 • Malvern, PA 19355
Tel: (800) 523-5620 • Fax: (610) 353-7814 • email: keeler@keelerusa.com

Offer valid until June 30, 2018.

Contact Keeler or one of our authorized dealers for more information.

icare
HOME



IOP SELF-TONOMETRY
24 HOUR INSIGHT

VISIT ASCRS 2018 **BOOTH #1150** FOR **SHOW SPECIAL!**

Learn more: info@icare-usa.com or www.icare-usa.com

REVIEW[®] of Ophthalmology

April 2018 • Volume XXV No. 4 | reviewofophthalmology.com

Cover Focus

34 | **Is a Private Equity Deal Right for You?**

Christopher Kent, Senior Editor

How PE works, and how to decide if it's the right way to help grow your practice.

58 | **Are You Investment-Ready?**

Kristine Brennan, Senior Associate Editor

Learn what attracts private equity investors, and see how your practice stacks up.

Features

48 | **Vitreous Floaters: What Can Be Done?**

Walter Bethke, Editor in Chief

Advice on when to use vitrectomy or YAG for these common, annoying optical phenomena.

53 | **Angle Closure: PI vs. Cataract Surgery**

Michelle Stephenson, Contributing Editor

Expert advice on how to choose between these two procedures to help control IOP.



Departments

3 | [Review News](#)

15 | [Technology Update](#)

3-D Printing Technology in Ophthalmology

Making custom, cost-effective instruments and implants.

23 | [Plastic Pointers](#)

Managing Dacryoceles and Dacryocystitis

Diagnosis and treatment of these troublesome cysts.

30 | [Medicare Q & A](#)

Quality Payment Program/MIPS: Year Two

A status update, and tips on how to avoid penalties for the year 2020.

64 | [Retinal Insider](#)

How to Manage Intraocular Lymphoma

Diagnosing and choosing appropriate therapy when faced with this potentially aggressive malignancy.

70 | [Pediatric Patient](#)

How to Manage Pediatric Optic Neuritis

It can happen in the youngest patients, too.

74 | [Glaucoma Management](#)

Pseudoexfoliation During Cataract Surgery

Tips for succeeding with these difficult eyes.

78 | [Refractive/Cataract Rundown](#)

Two for One: Bilateral Cataract Surgery

In certain cases, some surgeons says it's as safe as staged procedures.

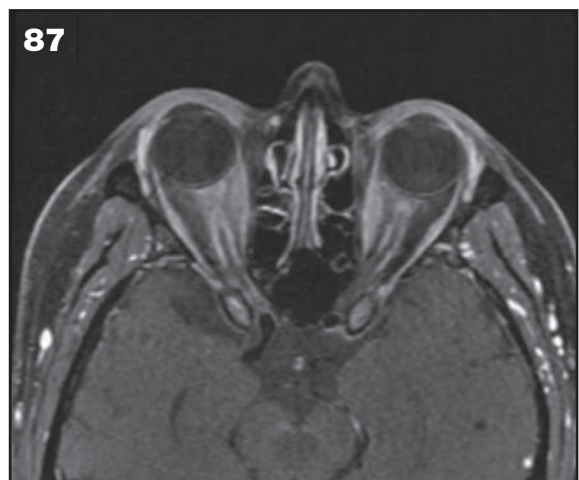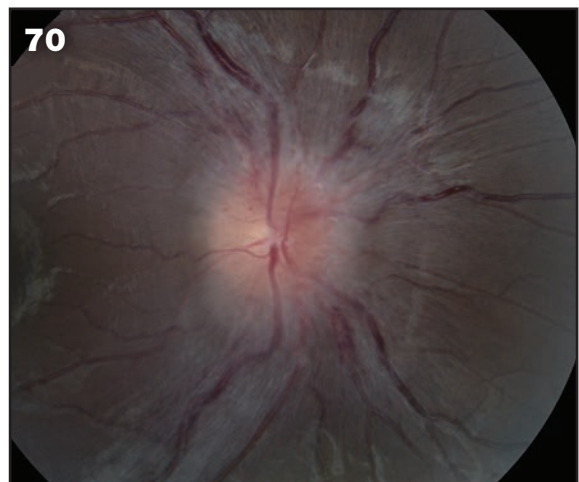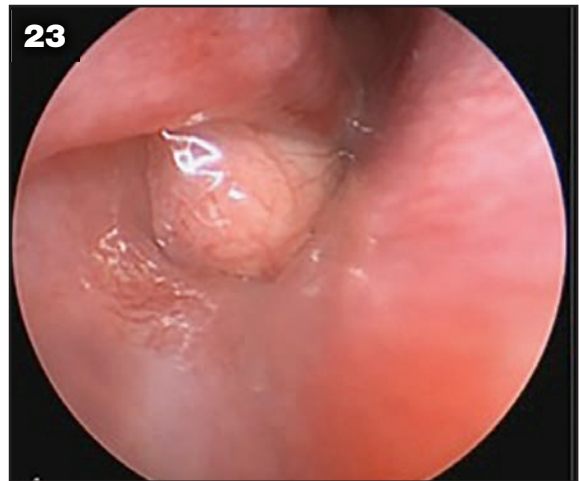82 | [Research Review](#)

85 | [Product News](#)

86 | [Classifieds](#)

87 | [Wills Eye Resident Case Series](#)

90 | [Advertising Index](#)





THE TRANSFORMATION STARTS SOON.

Speak to your
Glaukos sales representative today
or visit [TransformMIGS.com!](https://www.TransformMIGS.com)

Editor in Chief

Walter C. Bethke
(610) 492-1024
wbethke@jobson.com

Senior Editor

Christopher Kent
(814) 861-5559
ckent@jobson.com

Senior Associate Editor

Kristine Brennan
(610) 492-1008
kbrennan@jobson.com

Associate Editor

Liam Jordan
(610) 492-1025
ljordan@jobson.com

Chief Medical Editor

Mark H. Blecher, MD

Art Director

Jared Araujo
(610) 492-1032
jaraujo@jobson.com

Senior Graphic Designer

Matt Egger
(610) 492-1029
megger@jobson.com

International coordinator, Japan

Mitz Kaminuma
Reviewophthalgo@aol.com

Business Offices

11 Campus Boulevard, Suite 100
Newtown Square, PA 19073
(610) 492-1000
Fax: (610) 492-1039

Subscription inquiries:

United States — (877) 529-1746
Outside U.S. — (845) 267-3065

E-mail:

revophthalmology@cambeywest.com

Website: www.reviewofophthalmology.com



Safety is Uber Important

Last month, two events occurred that stood in stark contrast with each other.

First, in early March, the U.S. House of Representatives rejected the “right-to-try” bill, which essentially would have removed the Food and Drug Administration from any decisions regarding using unapproved medication on terminally ill patients, leaving it to patients, their doctors and the drug companies. There were impassioned speeches from both sides. Eventually, later in the month, the bill passed the House on its second try and heads to the Senate. However, for our purposes here, it’s not whether the bill passed or not that’s important, but that the safety and the rights of patients and the public at large were given a lot of weight in the discussion.

That brings us to the other event.

Later in the month, an autonomous vehicle—a car meant to navigate the roads by itself without the need for a human operator—struck and killed a pedestrian at night in Tempe, Arizona. Though there was an operator behind the wheel, it appears the car was in autonomous mode at the time of the crash. Some pundits have speculated that the vehicle’s advanced radar and other sensors should have detected the woman as she walked her bike across the wide, flat road,¹ while others have said, preliminarily at least, that the experimental car’s owner, Uber, isn’t at fault for the fatal collision.² The real issue, however, isn’t whether the accident could have been avoided,

it’s why it was allowed to happen at all.

The woman who was killed didn’t realize she was taking part in a potentially dangerous product test, and neither she, nor the other residents of the state, signed any informed-consent documents. However, if she were to undergo medical experimentation where there was a risk of death, she’d be inundated with reams of informed-consent papers, hours of discussions and months of intense monitoring. But all autonomous vehicle companies have to do to use people as beta testers is to get a state permit.

The FDA gets a lot of flak for its approval process, and is often accused of stifling innovation or limiting patients’ access to drugs. On the other end of the spectrum, however, is the practice of just going out and involving the general public in your testing without their consent. No doubt there’s a middle ground between the two extremes, and eventually a very wise person will hit upon the right combination of safety and expediency that satisfies both sides. For now, however, I prefer the “flawed” FDA approach.

—Walt Bethke, Editor in Chief

1. Kerr D. Was Uber’s driverless car crash avoidable? Experts say yes. Available at <https://www.cnet.com/news/was-ubers-driverless-car-crash-avoidable-some-experts-say-the-self-driving-car-should-have-braked/>. Accessed 23 March 2018.

2. Maki S, Sage A. Self-driving Uber car kills Arizona woman crossing street. <https://www.reuters.com/article/us-autos-self-driving-uber/self-driving-uber-car-kills-arizona-woman-crossing-street-idUSKBN1GV296>. Accessed 23 March 2018.

POWER TO PREVAIL

As demonstrated in phase 3 clinical trials evaluating BCVA,* as measured by ETDRS letters, in patients with Wet AMD, Macular Edema following RVO, DME, and by ETDRS-DRSS[†] in DR in Patients with DME,¹ as well as your clinical experience

Start with EYLEA for proven efficacy outcomes¹



Dosing driving efficacy outcomes across all indications.¹
Learn more at EYLEA.us/dose

AMD = Age-related Macular Degeneration; DME = Diabetic Macular Edema;
DR = Diabetic Retinopathy; RVO = Retinal Vein Occlusion.

INDICATIONS AND IMPORTANT SAFETY INFORMATION

INDICATIONS

EYLEA® (aflibercept) Injection is indicated for the treatment of patients with

- Neovascular (Wet) Age-related Macular Degeneration (AMD): The recommended dose is 2 mg administered by intravitreal injection every 4 weeks (monthly) for the first 12 weeks (3 months), followed by 2 mg once every 8 weeks (2 months). Although EYLEA may be dosed as frequently as 2 mg every 4 weeks (monthly), additional efficacy was not demonstrated in most patients when EYLEA was dosed every 4 weeks compared to every 8 weeks. Some patients may need every 4 week (monthly) dosing after the first 12 weeks (3 months).
- Macular Edema following Retinal Vein Occlusion (RVO): The recommended dose is 2 mg administered by intravitreal injection every 4 weeks (monthly).
- Diabetic Macular Edema (DME) and Diabetic Retinopathy (DR) in Patients with DME: The recommended dose is 2 mg administered by intravitreal injection every 4 weeks (monthly) for the first 5 injections, followed by 2 mg once every 8 weeks (2 months). Although EYLEA may be dosed as frequently as 2 mg every 4 weeks (monthly), additional efficacy was not demonstrated in most patients when EYLEA was dosed every 4 weeks compared to every 8 weeks. Some patients may need every 4 week (monthly) dosing after the first 20 weeks (5 months).

CONTRAINDICATIONS

- EYLEA® (aflibercept) Injection is contraindicated in patients with ocular or periocular infections, active intraocular inflammation, or known hypersensitivity to aflibercept or to any of the excipients in EYLEA.

WARNINGS AND PRECAUTIONS

- Intravitreal injections, including those with EYLEA, have been associated with endophthalmitis and retinal detachments. Proper aseptic injection technique must always be used when administering EYLEA. Patients should be instructed to report any symptoms suggestive of endophthalmitis or retinal detachment without delay and should be managed appropriately. Intraocular inflammation has been reported with the use of EYLEA.

Please see adjacent Brief Summary.

*Best-corrected visual acuity.

[†]Early Treatment Diabetic Retinopathy Study–Diabetic Retinopathy Severity Scale: an established grading scale for measuring the severity of DR.

Reference: 1. EYLEA® (aflibercept) Injection full U.S. Prescribing Information. Regeneron Pharmaceuticals, Inc. May 2017.

EYLEA is a registered trademark of Regeneron Pharmaceuticals, Inc.

REGENERON

© 2017, Regeneron Pharmaceuticals, Inc. All rights reserved.
777 Old Saw Mill River Road, Tarrytown, NY 10591



EYLEA®
(aflibercept) Injection
For Intravitreal Injection

- Acute increases in intraocular pressure have been seen within 60 minutes of intravitreal injection, including with EYLEA. Sustained increases in intraocular pressure have also been reported after repeated intravitreal dosing with VEGF inhibitors. Intraocular pressure and the perfusion of the optic nerve head should be monitored and managed appropriately.
- There is a potential risk of arterial thromboembolic events (ATEs) following intravitreal use of VEGF inhibitors, including EYLEA. ATEs are defined as nonfatal stroke, nonfatal myocardial infarction, or vascular death (including deaths of unknown cause). The incidence of reported thromboembolic events in wet AMD studies during the first year was 1.8% (32 out of 1824) in the combined group of patients treated with EYLEA. The incidence in the DME studies from baseline to week 52 was 3.3% (19 out of 578) in the combined group of patients treated with EYLEA compared with 2.8% (8 out of 287) in the control group; from baseline to week 100, the incidence was 6.4% (37 out of 578) in the combined group of patients treated with EYLEA compared with 4.2% (12 out of 287) in the control group. There were no reported thromboembolic events in the patients treated with EYLEA in the first six months of the RVO studies.

ADVERSE REACTIONS

- Serious adverse reactions related to the injection procedure have occurred in <0.1% of intravitreal injections with EYLEA including endophthalmitis and retinal detachment.
- The most common adverse reactions (≥5%) reported in patients receiving EYLEA were conjunctival hemorrhage, eye pain, cataract, vitreous floaters, intraocular pressure increased, and vitreous detachment.

10/2017
US-LEA-13945

1 INDICATIONS AND USAGE

EYLEA is a vascular endothelial growth factor (VEGF) inhibitor indicated for the treatment of: Neovascular (Wet) Age-Related Macular Degeneration (AMD); Macular Edema Following Retinal Vein Occlusion (RVO); Diabetic Macular Edema (DME); Diabetic Retinopathy (DR) in Patients with DME

4 CONTRAINDICATIONS

4.1 Ocular or Periocular Infections

EYLEA is contraindicated in patients with ocular or periocular infections.

4.2 Active Intraocular Inflammation

EYLEA is contraindicated in patients with active intraocular inflammation.

4.3 Hypersensitivity

EYLEA is contraindicated in patients with known hypersensitivity to aflibercept or any of the excipients in EYLEA. Hypersensitivity reactions may manifest as rash, pruritus, urticaria, severe anaphylactic/anaphylactoid reactions, or severe intraocular inflammation.

5 WARNINGS AND PRECAUTIONS

5.1 Endophthalmitis and Retinal Detachments. Intravitreal injections, including those with EYLEA, have been associated with endophthalmitis and retinal detachments [see *Adverse Reactions (6.1)*]. Proper aseptic injection technique must always be used when administering EYLEA. Patients should be instructed to report any symptoms suggestive of endophthalmitis or retinal detachment without delay and should be managed appropriately [see *Dosage and Administration (2.7)* and *Patient Counseling Information (7.1)*].

5.2 Increase in Intraocular Pressure. Acute increases in intraocular pressure have been seen within 60 minutes of intravitreal injection, including with EYLEA [see *Adverse Reactions (6.1)*]. Sustained increases in intraocular pressure have also been reported after repeated intravitreal dosing with vascular endothelial growth factor (VEGF) inhibitors. Intraocular pressure and the perfusion of the optic nerve head should be monitored and managed appropriately [see *Dosage and Administration (2.7)*].

5.3 Thromboembolic Events. There is a potential risk of arterial thromboembolic events (ATEs) following intravitreal use of VEGF inhibitors, including EYLEA. ATEs are defined as nonfatal stroke, nonfatal myocardial infarction, or vascular death (including deaths of unknown cause). The incidence of reported thromboembolic events in wet AMD studies during the first year was 1.8% (32 out of 1824) in the combined group of patients treated with EYLEA. The incidence in the DME studies from baseline to week 52 was 3.3% (19 out of 578) in the combined group of patients treated with EYLEA compared with 2.8% (8 out of 287) in the control group; from baseline to week 100, the incidence was 6.4% (37 out of 578) in the combined group of patients treated with EYLEA compared with 4.2% (12 out of 287) in the control group. There were no reported thromboembolic events in the patients treated with EYLEA in the first six months of the RVO studies.

6 ADVERSE REACTIONS

The following potentially serious adverse reactions are described elsewhere in the labeling:

- Hypersensitivity [see *Contraindications (4.3)*]
- Endophthalmitis and retinal detachments [see *Warnings and Precautions (5.1)*]
- Increase in intraocular pressure [see *Warnings and Precautions (5.2)*]
- Thromboembolic events [see *Warnings and Precautions (5.3)*]

6.1 Clinical Trials Experience. Because clinical trials are conducted under widely varying conditions, adverse reaction rates observed in the clinical trials of a drug cannot be directly compared to rates in other clinical trials of the same or another drug and may not reflect the rates observed in practice.

A total of 2711 patients treated with EYLEA constituted the safety population in seven phase 3 studies. Among those, 2110 patients were treated with the recommended dose of 2 mg. Serious adverse reactions related to the injection procedure have occurred in <0.1% of intravitreal injections with EYLEA including endophthalmitis and retinal detachment. The most common adverse reactions (≥5%) reported in patients receiving EYLEA were conjunctival hemorrhage, eye pain, cataract, vitreous floaters, intraocular pressure increased, and vitreous detachment.

Neovascular (Wet) Age-Related Macular Degeneration (AMD). The data described below reflect exposure to EYLEA in 1824 patients with wet AMD, including 1225 patients treated with the 2-mg dose, in 2 double-masked, active-controlled clinical studies (VIEW1 and VIEW2) for 12 months.

Table 1: Most Common Adverse Reactions (≥1%) in Wet AMD Studies

Adverse Reactions	EYLEA (N=1824)	Active Control (ranibizumab) (N=595)
Conjunctival hemorrhage	25%	28%
Eye pain	9%	9%
Cataract	7%	7%
Vitreous detachment	6%	6%
Vitreous floaters	6%	7%
Intraocular pressure increased	5%	7%
Ocular hyperemia	4%	8%
Corneal epithelium defect	4%	5%
Detachment of the retinal pigment epithelium	3%	3%
Injection site pain	3%	3%
Foreign body sensation in eyes	3%	4%
Lacrimation increased	3%	1%
Vision blurred	2%	2%
Intraocular inflammation	2%	3%
Retinal pigment epithelium tear	2%	1%
Injection site hemorrhage	1%	2%
Eyelid edema	1%	2%
Corneal edema	1%	1%

Less common serious adverse reactions reported in <1% of the patients treated with EYLEA were hypersensitivity, retinal detachment, retinal tear, and endophthalmitis.

Macular Edema Following Retinal Vein Occlusion (RVO). The data described below reflect 6 months exposure to EYLEA with a monthly 2 mg dose in 218 patients following CRVO in 2 clinical studies (COPERNICUS and GALILEO) and 91 patients following BRVO in one clinical study (VIBRANT).

Table 2: Most Common Adverse Reactions (≥1%) in RVO Studies

Adverse Reactions	CRVO		BRVO	
	EYLEA (N=218)	Control (N=142)	EYLEA (N=91)	Control (N=92)
Eye pain	13%	5%	4%	5%
Conjunctival hemorrhage	12%	11%	20%	4%
Intraocular pressure increased	8%	6%	2%	0%
Corneal epithelium defect	5%	4%	2%	0%
Vitreous floaters	5%	1%	1%	0%
Ocular hyperemia	5%	3%	2%	2%
Foreign body sensation in eyes	3%	5%	3%	0%
Vitreous detachment	3%	4%	2%	0%
Lacrimation increased	3%	4%	3%	0%
Injection site pain	3%	1%	1%	0%
Vision blurred	1%	<1%	1%	1%
Intraocular inflammation	1%	1%	0%	0%
Cataract	<1%	1%	5%	0%
Eyelid edema	<1%	1%	1%	0%

Less common adverse reactions reported in <1% of the patients treated with EYLEA in the CRVO studies were corneal edema, retinal tear, hypersensitivity, and endophthalmitis.

Diabetic Macular Edema (DME). The data described below reflect exposure to EYLEA in 578 patients with DME treated with the 2-mg dose in 2 double-masked, controlled clinical studies (VIVID and VISTA) from baseline to week 52 and from baseline to week 100.

Table 3: Most Common Adverse Reactions (≥1%) in DME Studies

Adverse Reactions	Baseline to Week 52		Baseline to Week 100	
	EYLEA (N=578)	Control (N=287)	EYLEA (N=578)	Control (N=287)
Conjunctival hemorrhage	28%	17%	31%	21%
Eye pain	9%	6%	11%	9%
Cataract	8%	9%	19%	17%
Vitreous floaters	6%	3%	8%	6%
Corneal epithelium defect	5%	3%	7%	5%
Intraocular pressure increased	5%	3%	9%	5%
Ocular hyperemia	5%	6%	5%	6%
Vitreous detachment	3%	3%	8%	6%
Foreign body sensation in eyes	3%	3%	3%	3%
Lacrimation increased	3%	2%	4%	2%
Vision blurred	2%	2%	3%	4%
Intraocular inflammation	2%	<1%	3%	1%
Injection site pain	2%	<1%	2%	<1%
Eyelid edema	<1%	1%	2%	1%

Less common adverse reactions reported in <1% of the patients treated with EYLEA were hypersensitivity, retinal detachment, retinal tear, corneal edema, and injection site hemorrhage.

6.2 Immunogenicity. As with all therapeutic proteins, there is a potential for an immune response in patients treated with EYLEA. The immunogenicity of EYLEA was evaluated in serum samples. The immunogenicity data reflect the percentage of patients whose test results were considered positive for antibodies to EYLEA in immunoassays. The detection of an immune response is highly dependent on the sensitivity and specificity of the assays used, sample handling, timing of sample collection, concomitant medications, and underlying disease. For these reasons, comparison of the incidence of antibodies to EYLEA with the incidence of antibodies to other products may be misleading.

In the wet AMD, RVO, and DME studies, the pre-treatment incidence of immunoreactivity to EYLEA was approximately 1% to 3% across treatment groups. After dosing with EYLEA for 24-100 weeks, antibodies to EYLEA were detected in a similar percentage range of patients. There were no differences in efficacy or safety between patients with or without immunoreactivity.

8 USE IN SPECIFIC POPULATIONS

8.1 Pregnancy

Risk Summary

Adequate and well-controlled studies with EYLEA have not been conducted in pregnant women. Aflibercept produced adverse embryofetal effects in rabbits, including external, visceral, and skeletal malformations. A fetal No Observed Adverse Effect Level (NOAEL) was not identified. At the lowest dose shown to produce adverse embryofetal effects, systemic exposures (based on AUC for free aflibercept) were approximately 6 times higher than AUC values observed in humans after a single intravitreal treatment at the recommended clinical dose [see *Animal Data*].

Animal reproduction studies are not always predictive of human response, and it is not known whether EYLEA can cause fetal harm when administered to a pregnant woman. Based on the anti-VEGF mechanism of action for aflibercept [see *Clinical Pharmacology (12.1)*], treatment with EYLEA may pose a risk to human embryofetal development. EYLEA should be used during pregnancy only if the potential benefit justifies the potential risk to the fetus.

All pregnancies have a background risk of birth defect, loss, or other adverse outcomes. The background risk of major birth defects and miscarriage for the indicated population is unknown. In the U.S. general population, the estimated background risk of major birth defects and miscarriage in clinically recognized pregnancies is 2-4% and 15-20%, respectively.

Data

Animal Data

In two embryofetal development studies, aflibercept produced adverse embryofetal effects when administered every three days during organogenesis to pregnant rabbits at intravenous doses ≥3 mg per kg, or every six days during organogenesis at subcutaneous doses ≥0.1 mg per kg.

Adverse embryofetal effects included increased incidences of postimplantation loss and fetal malformations, including anasarca, umbilical hernia, diaphragmatic hernia, gastroschisis, cleft palate, ectrodactyly, intestinal atresia, spina bifida, encephalomeningocele, heart and major vessel defects, and skeletal malformations (fused vertebrae, sternbrae, and ribs; supernumerary vertebral arches and ribs; and incomplete ossification). The maternal No Observed Adverse Effect Level (NOAEL) in these studies was 3 mg per kg. Aflibercept produced fetal malformations at all doses assessed in rabbits and the fetal NOAEL was not identified. At the lowest dose shown to produce adverse embryofetal effects in rabbits (0.1 mg per kg), systemic exposure (AUC) of free aflibercept was approximately 6 times higher than systemic exposure (AUC) observed in humans after a single intravitreal dose of 2 mg.

8.2 Lactation

Risk Summary

There is no information regarding the presence of aflibercept in human milk, the effects of the drug on the breastfed infant, or the effects of the drug on milk production/excretion. Because many drugs are excreted in human milk, and because the potential for absorption and harm to infant growth and development exists, EYLEA is not recommended during breastfeeding.

The developmental and health benefits of breastfeeding should be considered along with the mother's clinical need for EYLEA and any potential adverse effects on the breastfed child from EYLEA.

8.3 Females and Males of Reproductive Potential

Contraception

Females of reproductive potential are advised to use effective contraception prior to the initial dose, during treatment, and for at least 3 months after the last intravitreal injection of EYLEA.

Fertility

There are no data regarding the effects of EYLEA on human fertility. Aflibercept adversely affected female and male reproductive systems in cynomolgus monkeys when administered by intravenous injection at a dose approximately 1500 times higher than the systemic level observed humans with an intravitreal dose of 2 mg. A No Observed Adverse Effect Level (NOAEL) was not identified. These findings were reversible within 20 weeks after cessation of treatment [see *Nonclinical Toxicology (13.1)*].

8.4 Pediatric Use. The safety and effectiveness of EYLEA in pediatric patients have not been established.

8.5 Geriatric Use. In the clinical studies, approximately 76% (2049/2701) of patients randomized to treatment with EYLEA were ≥65 years of age and approximately 46% (1250/2701) were ≥75 years of age. No significant differences in efficacy or safety were seen with increasing age in these studies.

17 PATIENT COUNSELING INFORMATION

In the days following EYLEA administration, patients are at risk of developing endophthalmitis or retinal detachment. If the eye becomes red, sensitive to light, painful, or develops a change in vision, advise patients to seek immediate care from an ophthalmologist [see *Warnings and Precautions (5.1)*].

Patients may experience temporary visual disturbances after an intravitreal injection with EYLEA and the associated eye examinations [see *Adverse Reactions (6)*]. Advise patients not to drive or use machinery until visual function has recovered sufficiently.

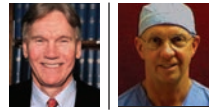Manufactured by:
Regeneron Pharmaceuticals, Inc.
777 Old Saw Mill River Road
Tarrytown, NY 10591

Issue Date: June 2017
Initial U.S. Approval: 2011

Based on the May 2017 EYLEA® (aflibercept) Injection full Prescribing Information.

EYLEA is a registered trademark of Regeneron Pharmaceuticals, Inc.
© 2017, Regeneron Pharmaceuticals, Inc. All rights reserved.

REGENERON



3-D Printing Technology In Ophthalmology

This process makes it possible to create instrument prototypes and custom implants at a reasonable price.

Christopher Kent, Senior Editor

Many technological developments that impact ophthalmology come from doctors or researchers within the field. Occasionally, however, advances in other areas become of interest to ophthalmologists. One such technology is 3-D printing, which allows anyone to design and create a three-dimensional object without many of the practical difficulties associated with older manufacturing methods.

Brett Kotlus, MD, a New York City-based oculoplastic surgeon specializing in cosmetic and reconstructive eye and face procedures, has become interested in this technology, and he's already using it in creative ways to enhance patient care. "3-D printing is not a new technology; it's actually been around for 30 years," he says. "It's become more accessible in the past eight to 10 years because we now have more affordable printers and more materials that we can use in them."

How 3-D Printing Works

The 3-D printing process, called additive manufacturing, creates a three-dimensional object by deposit-

ing layer after layer of material until the finished object is constructed. The process is guided by a computer. "In contrast, traditional manufacturing uses either injection molding to create an object, or so-called reduction technology, which removes layers of material from a block to create a final shape," Dr. Kotlus notes. "Those approaches can be very time-consuming and expensive when you're aiming to make something customized or unique."

Dr. Kotlus explains that 3-D printers use one of two main methods to add successive layers as the object is being created. "One is extrusion, in which the material is pushed out of the tip of a nozzle, much the way a glue gun works," he says. "Usually, the material used in that situation is melted plastic. The other method is sintering, in which a powder or liquid is deposited one layer at a time; then a light or laser shines on it to harden the material selectively. Either way, the layers add up to create a solid object.

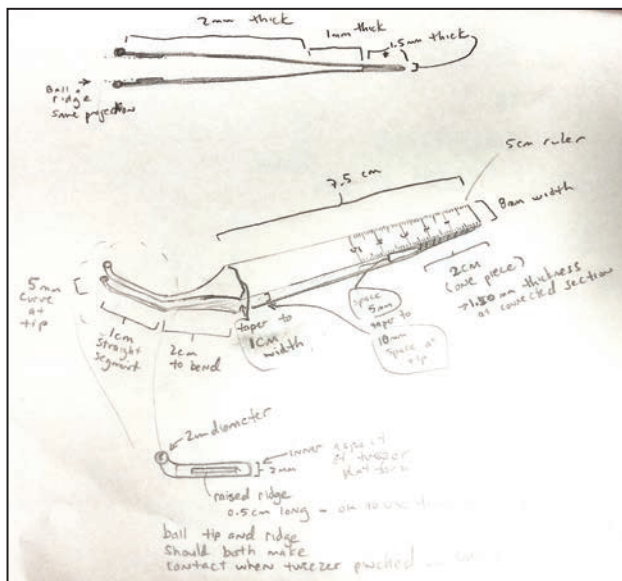
"The limits of this technology come down to what materials are available and the resolution at which current machines can print," he continues. "It's now possible to print an object

in almost any material. I've printed in ceramic and metal, and you can even print in living tissue. One approach to doing the latter is to print a scaffold through extrusion and then populate that scaffold with living cells or tissue. However, other approaches are also being studied right now. As far as how small you can go, I think the resolution is relatively unlimited. I don't see why we couldn't do microscopic 3-D printing, similar to the way circuit boards are created."

Designing Instruments

Dr. Kotlus notes that there are several ways in which 3-D printing could be useful in ophthalmology. "Those uses include prototyping and creating new surgical tools; helping with surgical planning; creating custom implants; and helping patients visualize the potential benefits of a procedure," he says.

Dr. Kotlus has already used 3-D printing to develop new tools that he can use in his practice. "My practice is exclusively oculoplastic and cosmetic surgery, so I've developed instruments to help with the blepharoplasty evaluation and procedure," he



A new tool can be designed (left) and 3-D printed (above) in small quantities for a reasonable price, allowing testing in the clinic, leading to improved versions without involving a major manufacturer.

says. One of the tools he’s designed is something he calls an eyelid wand. [See photo, above right.] “It’s a tool you can use to demonstrate to the patient what it would look like if we didn’t offer blepharoplasty, and we left the skin as it is,” he says. “The shape of the wand matches the shape of the eyelid, and it has a ruler on it so I can do my measurements without having to use a separate instrument.”

Dr. Kotlus explains that he hand-draws the shape and dimensions of the object he’d like to create [see example, above] and then hires a designer, who turns it into a digital rendering. “Then I send it to a 3-D printing bureau service in New York City called Shapeways,” he says. “They print it for me in the material I select. The cost to print an item depends on the material used and the size of the item; my instruments range from \$8 to \$40 per print. One of the advantages of doing it this way is that the bureau can print in materials I can’t, such as stainless steel. At the moment, printers capable of doing that can cost six or seven figures to acquire.”

Dr. Kotlus says that after he designed his blepharoplasty tool he had 20 copies made using 3-D printing. “I sent them out to some of my col-

leagues around the country, asking for their feedback,” he says. “They emailed me with suggestions for ways to improve the design, allowing me to modify it based on their feedback. It’s like a crowd-sourced project. Now, instead of having to make a new mold—the way I would if this were an injection-molded tool—I can just have my designer make a change to the file and then print the new version.”

Dr. Kotlus notes that right now, 3-D printing is more cost-effective than the older methods for creating something such as a surgical tool, as long as it’s a custom item or you’re doing a limited run. “If you have to make a large number of items, traditional manufacturing methods will be faster and more affordable,” he notes. “But if you’re looking to create something that’s custom-made, then 3-D printing is often a better way to go, assuming the right material is available.

The reality is, it’s hard to get vendors interested in a custom instrument if they don’t think there will be a sizable market,” he says. “The cost of design and molding—not to mention marketing—can be significant. As a result, it’s often faster and easier to cut out the middleman when creating a niche item, or in the early stages of development, and do it yourself with 3-D printing. Once you have proof of

concept it can be easier to approach the bigger industry players.”

Other Uses in Ophthalmology

In terms of helping with surgical planning, Dr. Kotlus describes a couple of ways this technology might be useful. “For example, you can use this technology to print out a duplicate of the patient’s anatomy and look at it in 3-D,” he says. “If you’re doing something that involves cutting or rearranging bones, you can duplicate the patient’s skeletal structure and practice the surgery on the model before you do it on the patient. This helps you to visualize approaches and structures in three dimensions, which may increase your understanding of the problem and can make a procedure go more smoothly.”

In terms of printing custom implants, such as a drug-dispensing device or retinal prosthesis, Dr. Kotlus says the sky’s the limit—in theory. “Whatever we can think of should be feasible, as long as we have the technology to work with the appropriate materials,” he says. “I haven’t personally printed any custom implants because of the limited selection of approved materials to date, although there is one rigid material that’s FDA-approved for craniofacial reconstruction. I own a patent for a custom implant process that uses silicone, but it currently requires the use of injection

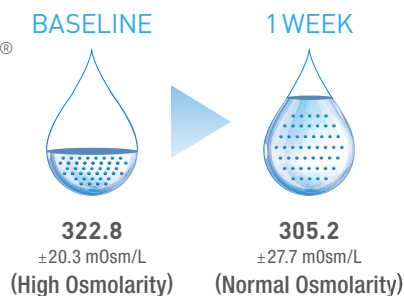
TheraTears® is clinically proven to reduce the signs and symptoms of dry eyes¹



TheraTears® Dry Eye Therapy Lubricant Eye Drops with Osmo-Correction®

- Reduced patient symptoms (OSDI) up to 33%
- Restored tears to normal osmolarity levels within one week

Average Tear Osmolarity Level



More than eye drops,
dry eye therapy™

theratears.com

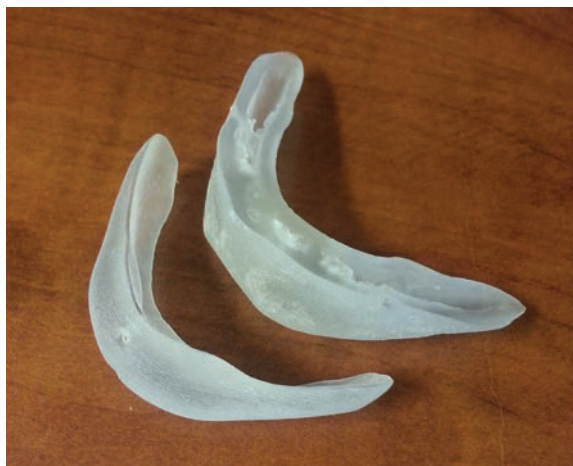Study sponsored by Akorn

Reference: 1. Ng L, Nguyen A, Karpecki P, Houtman D. Evaluation of Tear Osmolarity Over Time with Sustained Use of TheraTears® Lubricant Eye Drops. Poster presented at: The American Academy of Optometry Annual Meeting; November 9-12, 2016; Anaheim, CA.

© 2017 Akorn Consumer Health | A Division of Akorn, Inc. | M16-039

molding. There are still some hurdles to overcome in terms of creating silicone implants with 3-D printing.”

Dr. Kotlus says 3-D printing can also be used to help patients visualize the probable outcome of a procedure. “I’ve used 3-D imaging for what you might call preoperative morphing,” he explains. “You can show a patient what a chin implant would like, or a change to the nose. With our 3-D imaging software, the images we create can be printed into a physical model that patients can hold in their hands.”



3-D printing can be used to create custom implants. Above: A custom acrylic chin implant, next to a 3-D printed copy of the patients’ mandible.

Challenges to Overcome

Dr. Kotlus says a big challenge with this technology is having the capital and resources to develop new materials. “New materials will have to be developed and then approved for medical purposes,” he notes. “For example, let’s say you want to create an intraocular lens. You’d need a material that would be able to withstand the 3-D printing process while maintaining its clarity and shape and size. Obviously, we’re not there yet. The FDA approval process is also in its infancy because medical use of this technology is relatively new. However, they do have new guidelines for medical 3-D printing. The FDA has recognized that this is a growing field that’s going to play a role in medicine.

“Printer resolution may also be an obstacle, depending on what you’re trying to print and the material involved,” he continues. “But one of the biggest obstacles is having really useful content to create. It’s easy to say that we can prototype instruments; but if you don’t have a solid idea for an instrument, then the technology will only take you so far. Without that part of the equation, 3-D printing will be of limited use.”

Dr. Kotlus points out one future development that should be particularly useful in the field of medicine: the ability to use multiple materials in the same implant. “For example, if you have a 3-D bioprinter that can use different types of cells, you could potentially print organs,” he says. “That sounds like science fiction, but I think it’s possible. It’s simply a matter of the technology progressing along the same path it has been, and the approvals moving along with it.”

Making the Most of 3-D Tech

Dr. Kotlus notes that 3-D printers have become quite affordable. “You can purchase a 3-D printer that uses plastic for less than \$500,” he says. “You can then download models from the Internet that you can print in your home. Or, instead of purchasing a printer, you can go to places that have printers available such as office supply stores or Home Depot and print the files yourself. At Shapeways, the 3-D printing bureau service in New York City that I use, you can browse through models that designers have created; they’ll print it for you and ship it to you.” (Dr. Kotlus notes that he’s created designs of his own that are available through Shapeways, in-

cluding a model for silver cufflinks, and one for a container in which you can store razor blades. He gets a royalty if one of his designs is used, but he’s also made the files available online so anyone can download them and print them on their own.)

Dr. Kotlus admits that most ophthalmologists probably don’t need this technology in their offices today, given the limited medical uses available so far. “Many dentists now use them in their offices to create dental implants, but in a medical office it’s not really neces-

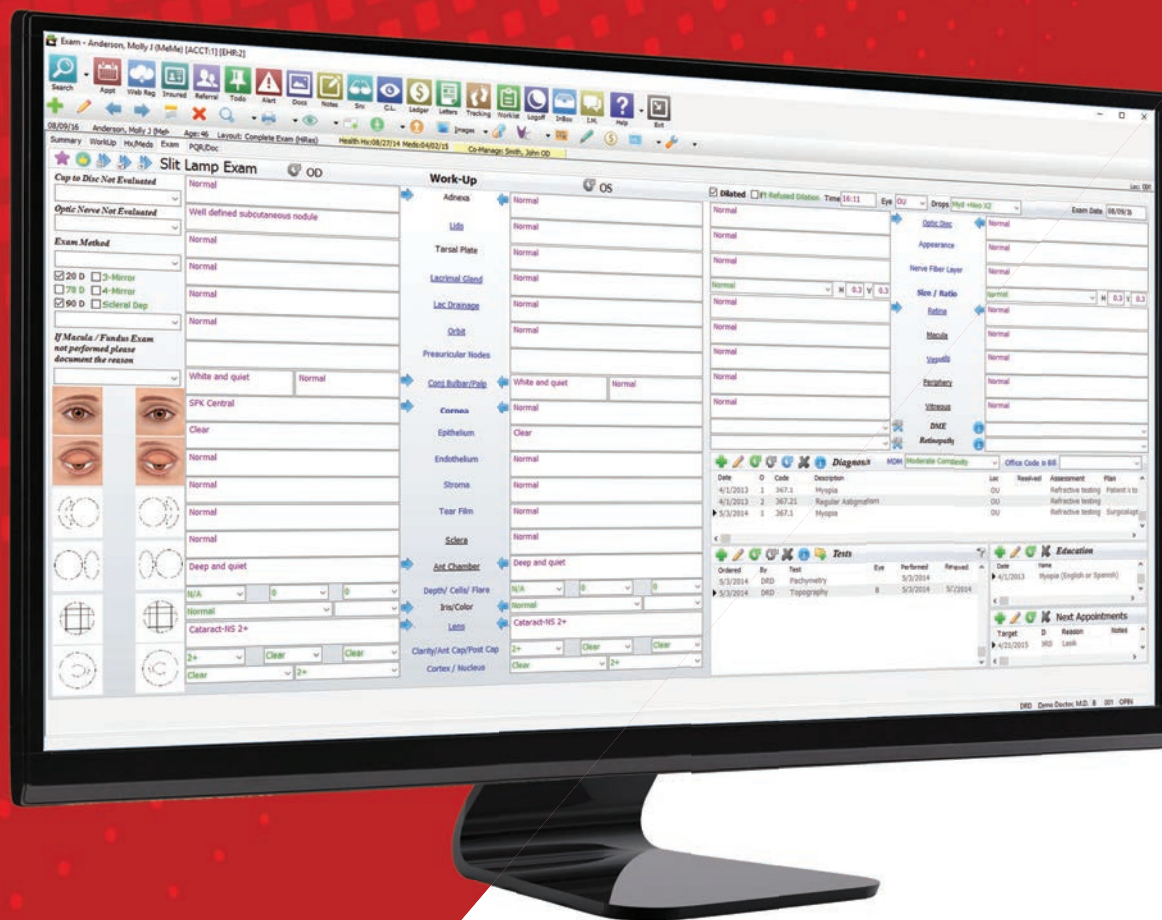
sary yet,” he says. “If you’re interested in experimenting with the technology, or if you have kids interested in it, that might be a reason to get a device. But professionally, if you’re interested in creating something such as an instrument prototype, it’s probably easier to do it the way I did.

“Already this technology is being utilized more than you might think,” he adds. “The University of Michigan has been creating implants to help children with congenitally narrow tracheas. They’ve implanted them and saved lives, and there have been reports of other successful reconstructive 3-D-printed implants. There’s also a project called ‘E-nable’ that pairs hobbyists who have 3-D printers with children who need prosthetics such as hands. The project provides the blueprints that can create the prosthetic limb; Boy Scout troops and elementary school classes are then able to create those limbs and provide them to children who need them. They can even make them in superhero colors. This program helps these children to integrate and function in a social setting. I think we’ll be seeing more of all of these kinds of uses.

“This is clearly an evolving field,” he concludes. “I’m excited to see what will happen next.” **REVIEW**

Ophthalmology's All-in-One Solution

2015 ONC Certified
Money-Back Satisfaction Guarantee



**Ophthalmology's
Leader for
33 Years!**

- Chart From A Single Screen
- Cloud/Server Enterprise Solution
- Data Conversion Guarantee
- Sub-Specialty Layouts
- Low Start-up Costs

**EHR ■ PM ■ RCM ■ ASC ■ OPTICAL ■ ANALYTICS
PATIENT ENGAGEMENT ■ TELEHEALTH ■ AUDIT PROTECTION**

See it Live.
ASCRS Annual Meeting ■ Booth 1214

www.compulinkadvantage.com/onetab ■ 800.456.4522

compulink



Indications and Usage

BromSite® (bromfenac ophthalmic solution) 0.075% is a nonsteroidal anti-inflammatory drug (NSAID) indicated for the treatment of postoperative inflammation and prevention of ocular pain in patients undergoing cataract surgery.

Recommended Dosing

One drop of BromSite® should be applied to the affected eye twice daily (morning and evening) 1 day prior to surgery, the day of surgery, and 14 days postsurgery.

Important Safety Information

- **Slow or Delayed Healing:** All topical nonsteroidal anti-inflammatory drugs (NSAIDs), including BromSite®, may slow or delay healing. Topical corticosteroids are also known to slow or delay healing. Concomitant use of topical NSAIDs and topical steroids may increase the potential for healing problems.
- **Potential for Cross-Sensitivity:** There is the potential for cross-sensitivity to acetylsalicylic acid, phenylacetic acid derivatives, and other NSAIDs, including BromSite®.

Therefore, caution should be used when treating individuals who have previously exhibited sensitivities to these drugs.

- **Increased Bleeding Time of Ocular Tissue:** With some NSAIDs, including BromSite®, there exists the potential for increased bleeding time due to interference with platelet aggregation. There have been reports that ocularly applied NSAIDs may cause increased bleeding of ocular tissues (including hyphemas) in conjunction with ocular surgery. It is recommended that BromSite® be used with caution in patients with known bleeding tendencies or who are receiving other medications which may prolong bleeding time.
- **Keratitis and Corneal Effects:** Use of topical NSAIDs may result in keratitis. In some susceptible patients, continued use of topical NSAIDs may result in epithelial breakdown, corneal thinning, corneal erosion, corneal ulceration or corneal perforation. Patients with evidence

The **FIRST** and **ONLY** NSAID indicated to prevent ocular pain in cataract surgery patients¹

A DROP OF PREVENTION

FOR YOUR CATARACT SURGERY PATIENTS

Defend against ocular pain and combat postoperative inflammation with the penetrating power of BromSite® formulated with DuraSite®¹

- DuraSite® increases ocular surface retention time, resulting in increased bromfenac absorption²⁻⁵
- Provides 24-hour coverage with BID dosing¹
- Available in 5 mL bottle

Visit bromsite.com to find out more.

BromSITE®
(bromfenac ophthalmic solution) 0.075%

Formulated with **DURASITE® DELIVERY SYSTEM**

of corneal epithelial breakdown should immediately discontinue use of topical NSAIDs, including BromSite®, and should be closely monitored for corneal health. Patients with complicated ocular surgeries, corneal denervation, corneal epithelial defects, diabetes mellitus, ocular surface diseases (e.g., dry eye syndrome), rheumatoid arthritis, or repeat ocular surgeries within a short period of time may be at increased risk for corneal adverse events which may become sight threatening. Topical NSAIDs should be used with caution in these patients. Post-marketing experience with topical NSAIDs also suggests that use more than 24 hours prior to surgery or use beyond 14 days postsurgery may increase patient risk for the occurrence and severity of corneal adverse events.

- **Contact Lens Wear:** BromSite® should not be administered while wearing contact lenses. The preservative in BromSite®, benzalkonium chloride, may be absorbed by soft contact lenses.

- **Adverse Reactions:** The most commonly reported adverse reactions in 1% to 8% of patients were anterior chamber inflammation, headache, vitreous floaters, iritis, eye pain, and ocular hypertension.

Please see brief summary of Full Prescribing Information on the adjacent page.

NSAID=nonsteroidal anti-inflammatory drug.

References: **1.** BromSite® [package insert]. Cranbury, NJ: Sun Pharmaceutical Industries, Inc.; 2016. **2.** Hosseini K, Hutcheson J, Bowman L. Aqueous humor concentration of bromfenac 0.09% (Bromday™) compared with bromfenac in DuraSite® 0.075% (BromSite™) in cataract patients undergoing phacoemulsification after 3 days dosing. Poster presented at: ARVO Annual Meeting; May 5-9, 2013; Seattle, Washington. **3.** ClinicalTrials.gov. Aqueous humor concentration of InSite Vision (ISV) 303 (bromfenac in DuraSite) to Bromday once daily (QD) prior to cataract surgery. <https://clinicaltrials.gov/ct2/show/results/NCT01387464?sect=X70156&term=insite+vision&rank=1>. Accessed March 2, 2017. **4.** Si EC, Bowman LM, Hosseini K. Pharmacokinetic comparisons of bromfenac in DuraSite and Xibrom. *J Ocul Pharmacol Ther.* 2011;27(1):61-66. **5.** Bowman LM, Si E, Pang J, et al. Development of a topical polymeric mucoadhesive ocular delivery system for azithromycin. *J Ocul Pharmacol Ther.* 2009;25(2):133-139.

Sun Ophthalmics is a division of Sun Pharmaceutical Industries, Inc. © 2017 Sun Pharmaceutical Industries, Inc. All rights reserved. BromSite and DuraSite are registered trademarks of Sun Pharma Global FZE. SUN-OPH-BRO-219 03/2017



BromSite® (bromfenac ophthalmic solution) 0.075%

Brief Summary

INDICATIONS AND USAGE

BromSite® (bromfenac ophthalmic solution) 0.075% is indicated for the treatment of postoperative inflammation and prevention of ocular pain in patients undergoing cataract surgery.

CONTRAINDICATIONS

None

WARNINGS AND PRECAUTIONS

Slow or Delayed Healing

All topical nonsteroidal anti-inflammatory drugs (NSAIDs), including BromSite® (bromfenac ophthalmic solution) 0.075%, may slow or delay healing. Topical corticosteroids are also known to slow or delay healing. Concomitant use of topical NSAIDs and topical steroids may increase the potential for healing problems.

Potential for Cross-Sensitivity

There is the potential for cross-sensitivity to acetylsalicylic acid, phenylacetic acid derivatives, and other NSAIDs, including BromSite® (bromfenac ophthalmic solution) 0.075%. Therefore, caution should be used when treating individuals who have previously exhibited sensitivities to these drugs.

Increased Bleeding Time of Ocular Tissue

With some NSAIDs, including BromSite® (bromfenac ophthalmic solution) 0.075%, there exists the potential for increased bleeding time due to interference with platelet aggregation. There have been reports that ocularly applied NSAIDs may cause increased bleeding of ocular tissues (including hyphemas) in conjunction with ocular surgery.

It is recommended that BromSite® be used with caution in patients with known bleeding tendencies or who are receiving other medications which may prolong bleeding time.

Keratitis and Corneal Reactions

Use of topical NSAIDs may result in keratitis. In some susceptible patients, continued use of topical NSAIDs may result in epithelial breakdown, corneal thinning, corneal erosion, corneal ulceration or corneal perforation. These events may be sight threatening. Patients with evidence of corneal epithelial breakdown should immediately discontinue use of topical NSAIDs, including BromSite® (bromfenac ophthalmic solution) 0.075%, and should be closely monitored for corneal health.

Post-marketing experience with topical NSAIDs suggests that patients with complicated ocular surgeries, corneal denervation, corneal epithelial defects, diabetes mellitus, ocular surface diseases (e.g., dry eye syndrome), rheumatoid arthritis, or repeat ocular surgeries within a short period of time may be at increased risk for corneal adverse events which may become sight threatening. Topical NSAIDs should be used with caution in these patients.

Post-marketing experience with topical NSAIDs also suggests that use more than 24 hours prior to surgery or use beyond 14 days postsurgery may increase patient risk for the occurrence and severity of corneal adverse events.

Contact Lens Wear

BromSite® should not be administered while wearing contact lenses. The preservative in BromSite®, benzalkonium chloride, may be absorbed by soft contact lenses.

ADVERSE REACTIONS

The following serious adverse reactions are described elsewhere in the Brief Summary:

- Slow or Delayed Healing
- Potential for Cross-Sensitivity
- Increased Bleeding Time of Ocular Tissue
- Keratitis and Corneal Reactions
- Contact Lens Wear

Clinical Trial Experience

Because clinical trials are conducted under widely varying conditions, adverse reaction rates observed in the clinical trials of a drug cannot be directly compared to rates in the clinical trials of another drug and may not reflect the rates observed in clinical practice.

The most commonly reported adverse reactions in 1–8% of patients were: anterior chamber inflammation, headache, vitreous floaters, iritis, eye pain and ocular hypertension.

USE IN SPECIFIC POPULATIONS

Pregnancy

Risk Summary

There are no adequate and well-controlled studies in pregnant women to inform any drug associated risks. Treatment of pregnant rats and rabbits with oral bromfenac did not produce teratogenic effects at clinically relevant doses.

Clinical Considerations

Because of the known effects of prostaglandin biosynthesis-inhibiting drugs on the fetal cardiovascular system (closure of ductus arteriosus), the use of BromSite® during late pregnancy should be avoided.

Data

Animal Data

Treatment of rats with bromfenac at oral doses up to 0.9 mg/kg/day (195 times a unilateral daily human ophthalmic dose on a mg/m² basis, assuming 100% absorbed) and rabbits at oral doses up to 7.5 mg/kg/day (3243 times a unilateral daily dose on a mg/m² basis) produced no structural teratogenicity in reproduction studies. However, embryo-fetal lethality, neonatal mortality and reduced postnatal growth were produced in rats at 0.9 mg/kg/day, and embryo-fetal lethality was produced in rabbits at 7.5 mg/kg/day. Because animal reproduction studies are not always predictive of human response, this drug should be used during pregnancy only if the potential benefit justifies the potential risk to the fetus.

Lactation

There are no data on the presence of bromfenac in human milk, the effects on the breastfed infant, or the effects on milk production; however, systemic exposure to bromfenac from ocular administration is low. The developmental and health benefits of breastfeeding should be considered along with the mother's clinical need for bromfenac and any potential adverse effects on the breast-fed child from bromfenac or from the underlying maternal condition.

Pediatric Use

Safety and efficacy in pediatric patients below the age of 18 years have not been established.

Geriatric Use

There is no evidence that the efficacy or safety profiles for BromSite® differ in patients 65 years of age and older compared to younger adult patients.

NONCLINICAL TOXICOLOGY

Carcinogenesis, Mutagenesis and Impairment of Fertility

Long-term carcinogenicity studies in rats and mice given oral doses of bromfenac up to 0.6 mg/kg/day (129 times a unilateral daily dose assuming 100% absorbed, on a mg/m² basis) and 5 mg/kg/day (540 times a unilateral daily dose on a mg/m² basis), respectively revealed no significant increases in tumor incidence.

Bromfenac did not show mutagenic potential in various mutagenicity studies, including the bacterial reverse mutation, chromosomal aberration, and micronucleus tests.

Bromfenac did not impair fertility when administered orally to male and female rats at doses up to 0.9 mg/kg/day and 0.3 mg/kg/day, respectively (195 and 65 times a unilateral daily dose, respectively, on a mg/m² basis).

Rx Only

Distributed by: Sun Pharmaceutical Industries, Inc. Cranbury, NJ 08512



Managing Dacryocele And Dacryocystitis

Exploring the origin of these troublesome cysts, as well as strategies for diagnosis and treatment.

Lama Khatib, MD, Beirut, Lebanon, and William R. Katowitz, MD, Philadelphia

Intranasal nasolacrimal duct cysts are nasal mucosal cysts emanating from under the inferior turbinate. They result from the accumulation of nasolacrimal secretions into blunted mucosal tissue at the level of an imperforate valve of Hasner. Although they are usually associated with dacryocele or dacryocystitis in infancy, they can occur in infants with varying symptoms of nasolacrimal duct obstruction.^{1,2} In this review we'll examine the embryological origin of these cysts, their epidemiology, as well as the diagnostic criteria and management options. We'll also discuss the pros and cons of new surgical techniques and devices used in the management of these intranasal cysts.

Embryology and Pathogenesis

As the 5-to-6-week-old embryo develops *in utero*, the lateral nasal and maxillary prominences fuse and entrap a double layer of epithelial cells, which later undergoes canalization between the eighth week of gestation and birth to form the duct.³ Incomplete canalization leads to nasolacrimal duct obstruction at the level

where the canalization process failed to occur, and the obliteration can be purely membranous (mucosal soft tissue) or may have an osseous component (agenesis of the distal nasolacrimal duct). In fact, an autopsy of 15 stillborn infants demonstrated that 73 percent of newborns had imperforate nasolacrimal ducts.⁴ Attempts at injecting fluid into the upper and lower canaliculi resulted in ballooning of mucosal tissue under the inferior turbinate in this study, which clinically resembled the appearance of intranasal cysts.

An imperforate nasolacrimal system will invariably lead to pressure buildup and may lead to backflow of material, resulting in symptoms of nasolacrimal duct obstruction such as tearing or discharge. Alternatively, as the pressure builds up within the nasolacrimal system, ballooning of the lacrimal sac occurs, and a one-way valve effect may result between the lacrimal sac and canaliculi. This is also thought to occur in cases where a common canaliculus is absent, and the upper and lower canaliculi open in the sinus of Maier at an acute angle, preventing the backflow of material

through the canaliculi and punctae; this will manifest as a dacryocystocele or dacryocystitis. Intranasal cysts may therefore occur in the setting of symptoms of nasolacrimal duct obstruction, dacryocele or dacryocystitis, unilaterally or bilaterally.⁵

Background and Epidemiology

The incidence of intranasal cysts is typically observed and reported in the setting of an established diagnosis of dacryocele, dacryocystitis or nasolacrimal duct obstruction. Infantile dacryocele occurs in about 1 to 4 percent of patients with symptoms of nasolacrimal duct obstruction, and acute dacryocystitis occurs in 2 to 3 percent of children with nasolacrimal duct obstruction.^{1,4,6-9} The average age at presentation for dacryocele ranges from birth to one to two weeks, with a female preponderance of 63 to 80 percent.¹⁰⁻¹⁴ Dacryocystitis may occur anytime from as early as two days after birth to a few months of age.^{1,12} Evolution from a congenital dacryocele to an acute dacryocystitis may occur in 20 to 72.5 percent of patients.^{7,10-16}

The association between intranasal

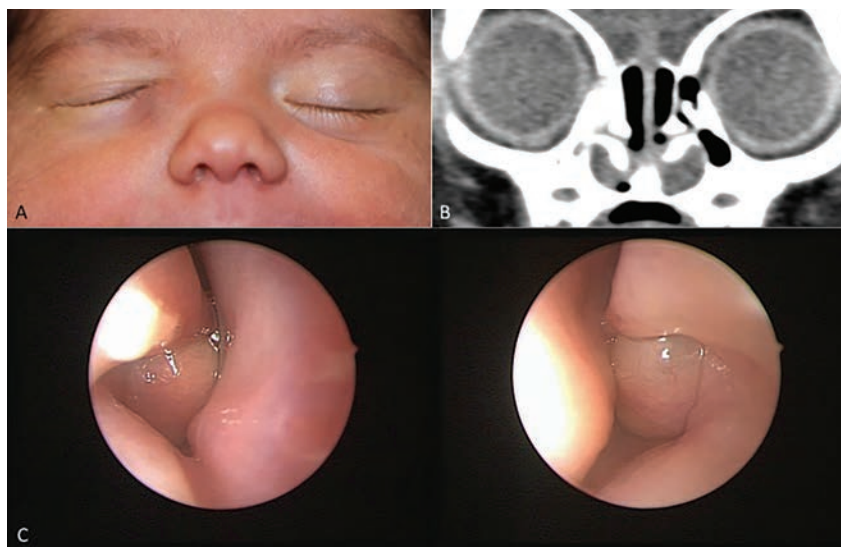


Figure 1. Bilateral intranasal cysts in a patient presenting with a unilateral right dacryoceale: A) 1-month-old infant with a right-sided mass below the medial canthus. B) CT of the sinuses with bilateral intranasal cysts below the inferior turbinates. C) Endonasal, endoscopic view of each intranasal cyst below the inferior turbinates.

cysts and nasolacrimal duct obstruction was first noted in 1982.¹⁷ It wasn't recognized until later that infantile dacryocystitis or dacryocystocele are almost invariably associated with findings of an intranasal cyst, according to several studies.^{1,2} One study found that 23/24 infants (95.8 percent) aged 4 days to 10 weeks with dacryocystoceles had associated intranasal cyst on nasal endoscopy. In another paper, a group of 33 patients (16 with acute dacryocystitis and 17 with dac-

ryocystoceles) was found to have a 100-percent incidence of intranasal cysts. Furthermore, nasolacrimal duct cysts were found in 44 percent of infants younger than 6 months old with severe symptoms of nasolacrimal duct obstruction, and 6 percent of children older than 18 months at the initial time of their probing.^{1,18}

Evaluation and Diagnosis

Infantile dacryocystocele usually

occurs in the first few weeks of life, and typically presents as a bluish soft tissue swelling medial and inferior to the medial canthus (Figure 1). Patients should be thoroughly investigated for any signs of infection such as fever, or purulent discharge upon massage of the lesion. In dacryocystitis, however, there might be overt evidence of an infected system such as fever, redness and swelling over the tear sac, and purulent discharge (Figure 2). Occasionally, infants may also have difficulty breathing, especially while feeding. Prompt diagnosis is necessary as neonates are relatively immune-compromised and at risk for sepsis and even meningitis if left untreated. Dacryocystitis may evolve into a lacrimal abscess, so the skin overlying the infected area should be examined for the presence of a fistula.

Other conditions that may mimic the presentation of a dacryoceale/dacryocystitis include:

- encephaloceles;
- infantile hemangiomas;
- orbital cellulitis;
- dermoid and epidermoid cysts;
- Zimmerman's Tumor (phacomatous choristoma);
- venolymphatic malformations (lymphangioma); and
- malignant tumors (neuroblastoma, rhabdomyosarcoma).

Imaging

The diagnosis of infantile dacryocystitis or dacryocystocele is typically a clinical one and does not require imaging. However, in cases such as infants in respiratory distress, in severe and/or rapidly progressive cases, and whenever there is proptosis or globe displacement, imaging can provide a useful adjunct for proper diagnosis, and to rule out other etiologies (venolymphatic malformations, infantile hemangiomas, etc.).^{10,13,15} Computed tomography and magnetic resonance imaging are helpful in delineating the

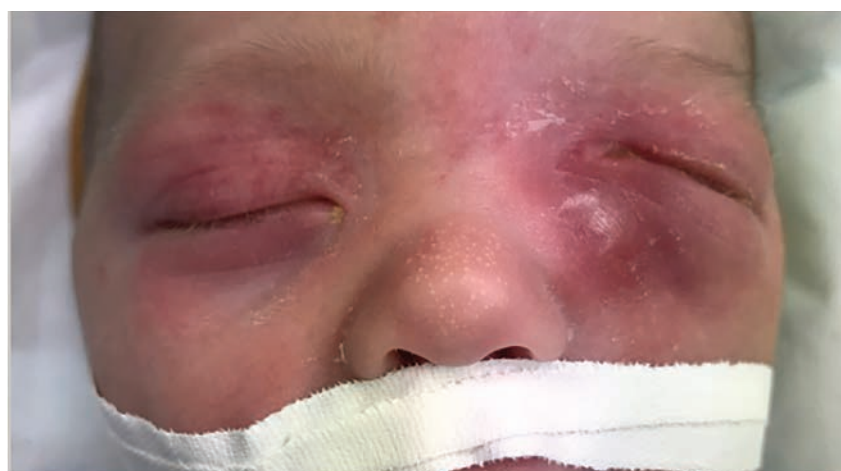

Figure 2. Left-sided dacryocystitis in a patient photographed just before surgery.

Visit us at
ASCRS
Booth #1042

**EXCLUSIVE
TO LENSTAR**

ACD

K

CCT



LENSTAR IS THE WORLD'S ONLY BIOMETER
WITH THE **HILL-RBF METHOD BUILT IN.**

Now you can optimize both outcomes and workflow. Fully integrated into Lenstar's proprietary EyeSuite software at no additional charge, the ground-breaking Hill-RBF approach to IOL calculation uses advanced pattern recognition, data interpolation and a validating boundary model to substantially improve IOL power prediction, with minimal refractive surprises.

Lenstar + Hill-RBF. True accuracy. Confidence. And now, convenience.
[Learn more today at mylenstar.com.](http://mylenstar.com)

888-myLENSTAR
myLENSTAR.com



© 2018 Haag-Streit USA. All Rights Reserved.

HAAG-STREIT
USA

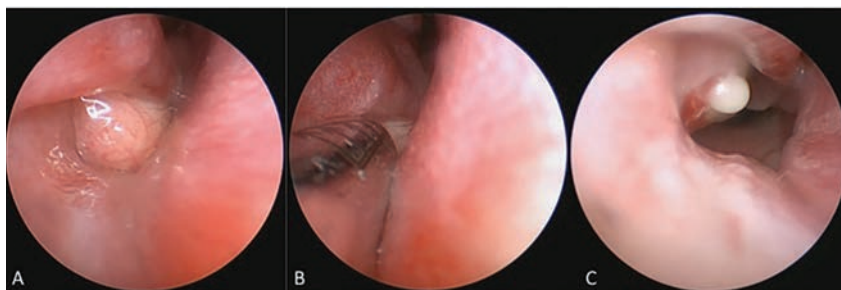


Figure 3. Intranasal cyst treatment with a microdebrider. A) An intranasal cyst associated with the right valve of Hasner is visible under the right inferior turbinate. B) Microdebridement of the cyst. C) Immediately post-microdebridement, mild pressure on the distended lacrimal sac expresses the contents into the intranasal space.

lacrimal sac, detecting nasolacrimal duct distention and identifying the intranasal cysts (Figure 1B). Imaging is especially helpful in ruling out other potential etiologies of a medial canthal mass such as encephaloceles or vascular malformations. High-frequency ultrasonography has also been suggested as a useful adjunct in

the diagnosis of neonatal dacryoceles/dacryocystitis that doesn't require sedation, as opposed to magnetic resonance imaging and computed tomography.¹⁹ A subcutaneous heteroechoic cystic lesion without vascular flow is typical of a dacryoceles, whereas prominent vascular flow within the lesion on color Doppler is a typi-

cal finding in infantile hemangioma. When a component of dacryocystitis is present, peripheral Doppler signal can be detected as a result of inflammation at the level of the abscess wall.

In summary, whenever you suspect a vascular lesion, ultrasonography may help with the diagnosis without exposing the infant to sedation.

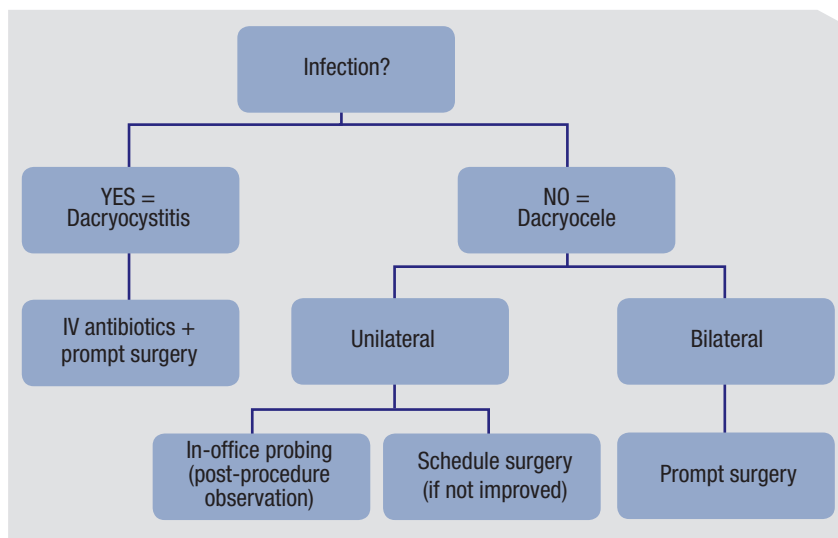
Management

Once a diagnosis of a dacryoceles or dacryocystitis is made in an infant, proper counseling with the parents about the potential gravity of this condition should follow. Assessment of respiratory distress is paramount as the presence of intranasal cysts can obstruct the nasal airway (Figure 1c). Infants with a dacryoceles should be followed closely on an outpatient basis, whereas patients with an established diagnosis of dacryocystitis should be admitted for observation and treatment. An algorithm for the treatment of a mass over the lacrimal sac in an infant is summarized in Table 1.

In general, patients with unilateral dacryoceles without signs of infection can be managed conservatively with attempted massage and antibiotic ointment if there are no signs of respiratory distress, and an in-office probing and irrigation may be successful in treating the condition.

When bilateral dacryoceles are present there is a significant risk for airway obstruction, and it's highly recommended that the patient be admitted to the hospital with a prompt plan for surgical care. In cases of suspected dacryocystitis, intravenous antibiotics should be added. Strongly consider surgical drainage under direct visualization and collecting the specimens for microbial cultures if there's no improvement after 24 hours of intravenous antibiotic treatment. If a unilateral dacryocystoceles is persistent two weeks after an in-office probing and attempted lacrimal massage, surgical

Table 1. Managing Dacryoceles and Dacryocystitis in Infants



With the presence with erythema (with or without fever) over a mass below the medial canthus, dacryocystitis should be the presumed diagnosis. An infant should be admitted to a hospital and started on IV antibiotics. If there is no improvement over a short course of treatment (24 hours), strongly consider immediate surgery. If you don't suspect an infection and have a presumed diagnosis of unilateral dacryoceles, you can attempt in-office probing. A child must be observed after this procedure for acute respiratory distress and then can be sent home with instructions to massage the tear duct with the application of topical antibiotics. If the dacryoceles recurs, consider surgery. In patients with bilateral dacryoceles, don't attempt in-office probing due to the risk of respiratory distress; instead, consider prompt surgical microdebridement.

100 MILLION MOMENTS MADE.

100
MILLION
IMPLANTED WORLDWIDE
Only
with AcrySof®



Thanks to you, AcrySof® IOLs have created more memories than any other lens.

Over the last 25 years, the AcrySof® portfolio of monofocal, toric and multifocal IOLs has been chosen with confidence. **Ask your Alcon representative what makes AcrySof® the most implanted lens in the world*.**

* Alcon data on file.

Alcon A Novartis
Division

 AcrySof® IQ IOL Family

 **Advancing**
CATARACT SURGERY

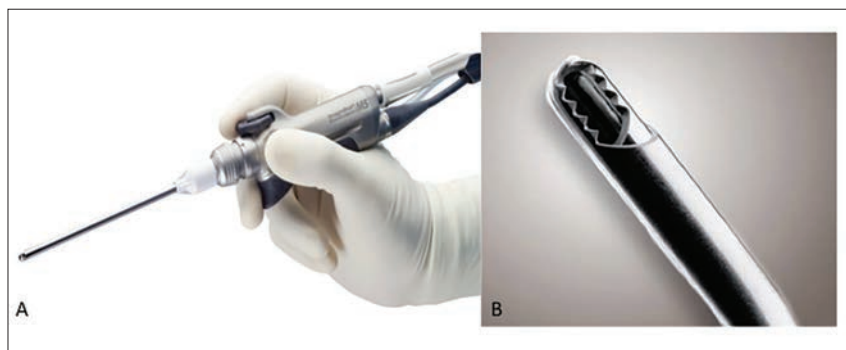


Figure 4. The Straightshot M4 Microdebrider (A) with a 2.9 mm Tricut blade (B)

drainage is recommended.

Surgery

Surgery is performed under general anesthesia. First, the nasal cavity is decongested with ¼" cottonoids soaked in a solution of 1 ml of 0.25% oxy-metazoline and 1 ml of 1:1,000 (0.1%) epinephrine. Be sure to examine both sides, as a significant proportion of patients with unilateral symptoms have bilateral intranasal cysts. Next, visualize the intranasal cavity with a 0- or 30-degree pediatric endoscope and examine it for the presence of nasolacrimal duct cysts before you exert any pressure on the lacrimal sac. Use a Freer elevator where necessary to gently elevate the inferior turbinate and facilitate access to the intranasal space, which is typically tight in infants. Care must be taken to replace the inferior turbinate at the completion of the procedure as failure to do this may cause respiratory compromise, since neonates are obligate nasal breathers. When you identify a cyst, you can apply gentle pressure to the lacrimal sac area; that may reveal bulging of the cyst intranasally.

Though surgeons have described different surgical instruments for the rupture/marsupialization of the cyst—from an alligator forceps or a sickle-cell blade passed through the nostrils, to a Bowman probe passed through the nasal duct and moved in a seesaw fashion to puncture the cyst^{1,12,20}—we

recently shifted to using a microdebrider instrument for the purpose of cyst marsupialization (Figure 3). In the following section, we'll describe how the microdebrider works and the best way to employ it.

Microdebrider-assisted Marsupialization

The modern microdebrider as we know it today was first introduced in 1994 by Stryker for use in endoscopic sinus surgery.²¹⁻²³ It's a powered instrument that can simultaneously irrigate, aspirate and remove tissue, leading to decreased operative time, better hemostasis and improved visualization. It consists of three parts: a power unit or console; a handpiece that can be connected to a suction source; and a disposable blade that can be connected to an irrigation source through separate tubing. Available microdebriders include the Diego Elite (Olympus America, Center Valley, Pennsylvania), the ESSx Microdebrider (Stryker, Kalamazoo, Michigan) and the Straightshot M4 (Medtronic, Jacksonville, Florida).

In most microdebriders, the blade sits at the tip of the device when connected to the handpiece and comes in different sizes, designs and shapes. The blade itself consists of two hollow concentric outer and inner cylinders, with the inner cylinder or shaft containing the blade edge that rotates or oscillates within the outer shaft and

aligns with the outer shaft's lumen at the oscillating cycle interval (Figure 4). Suction pulls the tissue into the lumen when the window of the outer shaft is open. The blade of the inner shaft then shears/cuts the tissue as it closes the window/opening, and irrigation and suction help remove the debrided tissue through the inner shaft lumen.²¹

The blades of the microdebrider are manufactured in different shapes, and those used in sinus surgery are usually angled for better access to the different sinus cavities. For the purpose of intranasal cyst removal, however, we typically use the Straightshot M4 Microdebrider with a 2.9 mm Tricut blade that oscillates at 5,000 RPM (which is the recommended manufacturer's setting for soft tissue removal).

Since the microdebrider is very effective at removing tissue from the surgical field, you have to make sure not to aspirate all the fluid out of the intranasal cysts. Therefore, gentle use of the microdebrider is recommended, followed by intranasal culturing of the extruded fluid. Although fluid can be recovered from the downstream suction cup for cultures and histopathology, this fluid is diluted with the irrigation fluid: Hence you can get better results from direct culture swabs of the infected fluid.

Once adequate cultures have been acquired, you can accomplish complete marsupialization until there's an adequate opening in the mucosal tissue while, at the same time, taking care not to injure the inferior turbinate. A 23-gauge cannula can be used to inject fluorescein-diluted solution into the lacrimal system. Patency is confirmed when the free flow of dye is visualized endoscopically. We prefer to intubate the nasolacrimal system with a monicanalicular stent at the completion of the procedure, which is then removed three months postoperatively. The inferior turbinate is replaced as previously mentioned, and the patient is admitted for postoperative observation.

That being said, the microdebrider is a surgical commodity that might not be readily available or accessible to all surgical centers. Furthermore, its cost may not justify its use in certain cases; hence, we suggest the use of the microdebrider be reserved for select or appropriate cases.

Conclusion

Intranasal cysts result from an imperforate nasolacrimal system and are almost invariably present in infants presenting with dacryoceles and dacryocystitis. Prompt diagnosis and management is critical for optimal care. When conservative measures have failed in the management of dacryoceles, or in cases of imminent or established dacryocystitis, microdebrider-assisted marsupialization represents a safe, time-saving and precise technology for surgical treatment. **REVIEW**

Dr. Khatib is a consultant ophthalmologist at Clemenceau Medical Center (affiliated with Johns Hopkins Medicine International) in Beirut. Dr. Katowitz is an attending surgeon in the division of ophthalmology at the Children's Hospital of Philadelphia. They have no financial interest in any product mentioned.

1. Lueder GT. The association of neonatal dacryocystoceles and infantile dacryocystitis with nasolacrimal duct cysts (an American ophthalmological society thesis). *Trans Am Ophthalmol Soc* 2012; 110:74-93.
2. Levin AV, Wynnanski-Jaffe T, Forte V, et al. Nasal endoscopy in the treatment of congenital lacrimal sac mucoceles. *Int J Pediatr Otorhinolaryngol* 2003;67:3:255-61.
3. Duke-Elder S, Cook C. Normal and abnormal development. Part I: Embryology. In: Duke-Elder S, ed. *System of Ophthalmology*, Vol. 3. St. Louis: CV Mosby, 1963:241-245.
4. Cassidy JV. Dacryocystitis of infancy: A review of one hundred cases. *Arch Ophthalmol* 1948;39:4:491-507.
5. Jones LT, Wobig JL. Congenital anomalies of the lacrimal system. In: *Surgery of the eyelids and the lacrimal system*. Birmingham: Aesculapius Publishing Company, 1976:157-173.
6. Becker F. Zum Membranösen Verschluss des oberen und unteren endedesTranennasenganges. *Klin Monbl Augenheilkd* 1938;101:569-570.
7. Shekunov J, Griepentrog GJ, Diehl NN, et al. Prevalence and clinical characteristics of congenital dacryocystocele. *J AAPOS* 2010;14:4:17-20.
8. Fooks OO. Lacrimal abscess in the newborn. *Br J Ophthalmol* 1961;45:8:562-565.
9. Pollard ZF. Treatment of acute dacryocystitis in neonates. *J*

- Pediatr Ophthalmol Strabismus* 1991;28:6:341-343.
10. Mansour AM, Cheng KP, Mumma JV, et al. Congenital dacryoceles. A collaborative review. *Ophthalmology* 1991;98:1744-51.
 11. Paysse EA, Coats DK, Bernstein JM, et al. Management and complications of congenital dacryoceles with concurrent intranasal mucocele. *J AAPOS* 2000;4:46-53.
 12. Becker BB. The treatment of congenital dacryocystocele. *Am J Ophthalmol* 2006;142:835-8.
 13. Ali MJ, Psaltis AJ, Brunworth J, et al. Congenital dacryoceles with large intranasal cyst: Efficacy of cruceate marsupialization, adjunctive procedures, and outcomes. *Ophthal Plast Reconstr Surg* 2014;30:346-51.
 14. Shashy RG, Durairaj V, Holmes JM, et al. Congenital dacryocystocele associated with intranasal cysts: Diagnosis and management. *Laryngoscope* 2003;113:37-40.
 15. Boynton JR, Drucker DN. Distention of the lacrimal sac in neonates. *Ophthalmic Surg* 1989;20:103-7.
 16. Wong RK, VanderVeen DK. Presentation and management of congenital dacryocystocele. *Pediatrics* 2008;122:e1108-12.
 17. Rafiq GT, Horton JA, Sprinkle PM. An unusual intranasal anomaly of the lacrimal drainage system. *Ophthalmic Surg* 1982;13:9:741-744.
 18. Lueder GT. Endoscopic treatment of intranasal abnormalities associated with nasolacrimal duct obstruction. *J AAPOS* 2004;8:2:128-32.
 19. Vázquez-Osorio I, Hernández-Martín A. Usefulness of ultrasonography in the diagnosis of neonatal dacryocystocele. *Pediatr Dermatol* 2017;34:2:209-210.
 20. Ali MJ. Pediatric acute dacryocystitis. *Ophthal Plast Reconstr Surg* 2015;31:5:341-7.
 21. Tang D, Lobo BC, D'Anza B, Woodard TD, Sindwani R. Advances in microdebrider technology: Improving functionality and expanding utility. *Otolaryngol Clin North Am* 2017;50:3:589-598.
 22. Setliff RC, Parsons DS. The "Hummer": New instrumentation for functional endoscopic sinus surgery. *Am J Rhinology* 1994;8:6:275-8.
 23. Dogan E, Yüksel NG, Ecevit MC, et al. Microdebrider assisted endoscopic marsupialization of congenital intranasal nasolacrimal duct cysts. *Int J Pediatr Otorhinolaryngol* 2012;76:4:488-91.

FREE DESIGN SERVICE!



ASCRS / ASOA
April
14th-16th
Booth
#760
WASHINGTON, D.C. • WASHINGTON

FASHION
Optical
DISPLAYS
NATIONWIDE

**ANY SPACE,
ANY BUDGET,
LET US SHOW YOU
THE POSSIBILITIES**

**FREE DISPENSARY DESIGN
U.S. MANUFACTURING
PROFESSIONAL INSTALLATION**

800.824.4106
FASHIONOPTICAL.COM



Quality Payment Program: Year Two

With the second year of QPP underway, it's important for practitioners to be aware of what's changed.

Q What's not different from year-one MIPS?

A One major similarity from year-one to year-two MIPS include that there are still four areas: Quality; Improvement Activities (IA); Advancing Care Information (ACI); and Resource Use (Cost). There's still a penalty or bonus possible, but any bonuses are likely to be small, since avoiding the penalty is straightforward, and this part is budget-neutral. The "exceptional performers" bonus of up to 10 percent remains and is non-budget-neutral since it has the same 70-point MIPS Composite Score threshold as in year one.

Q What are some major things to know about MIPS in year two?

A First, the minimum total Composite Score to avoid a MIPS penalty rose from three points for reporting-year 2017 (year one) to a still manageable 15 points for reporting-year 2018 (year two). As before, nearly all eye-care providers will remain on the MIPS side of QPP, as opposed to the Advanced Alternative Payment Model side under QPP. Any bonuses and penalties for year two happen in

payment-year 2020.

Second, the possible 2020 MIPS penalties or bonuses rise from 4 percent in year one to 5 percent in year two, so it's even more important to avoid a 2020 penalty by getting at least 15 points in 2018.

The Cost component under MIPS is now 10 percent, which is up from zero in 2017. The methodology for attribution of costs remains contentious. ACI and IA remain unchanged at 25 percent and 15 percent, respectively. The Quality component of MIPS decreased to 50 percent, but can be re-weighted upwards (more on that below). The Quality component is now in effect for the entire reporting year, while the ACI and IA components can be in effect for as few as 90 consecutive days.

There was a recent "Technical Correction" to the original April 2015 MACRA law that was just passed in February 2018 as part of the budget reconciliation bill to continue funding the federal government. It made some subtle but permanent changes to the MACRA regulatory language that have a significant positive impact for ophthalmologists. The words "items and services" under MACRA were changed to "covered professional services." This means that Part

B drugs (which are billed by the provider from the office) are no longer subject to the MIPS eligibility and penalty provisions. CMS will now make all these determinations only on covered professional services (e.g., eye exams, surgeries and tests). No longer are your 2020 payments for intravitreal drugs such as bevacizumab, ranimizumab and aflibercept at risk under MIPS.

Q How can I get to 15 points for reporting year 2018 and avoid a 5-percent penalty?

A Making three points in 2017 was fairly easy—successful reporting in any of the four MIPS areas basically carried at least three points with it. Going all the way to 15 is a bit more work, but it is still relatively easy to get there. Among the many ways to get to 15 for a 2018 MIPS Composite score are the following:

- **Successfully report for IA.** A perfect score here (40/40 = 100 percent) has a 15-percent weight and would therefore yield 15 points.

— As in year one, CMS has allowed small practices a bit of a leg up in this area. Small practices only have to score 20 and CMS will double the score to 40.

— Large practices need to score the 40 points the usual way.

— Medium-weighted IA are worth 10 points each; high-weighted ones are worth 20 points each. Any combination of high- and medium-activities works.

- **Get at least 15 points from ACI.**

— Making the base score section within ACI is half (50) of the maximum 100-point score achievable in this category, so after weighting, this would be 12.5 pts.

— Anything in the performance section of ACI that adds three more points after weighting can contribute.

- **Score 15 in Quality only.**

— This could be done by scoring three or more points in each of the six highest-scoring quality measures a provider chooses.

— There is a large variety of measures to report in this part of MIPS, but the particular measures available depend on the reporting method chosen.

Any other combination of ACI, Quality or IA that totals 15 points also avoids the 5-percent penalty in 2020.

Q Are there still exemptions from MIPS available?


A Yes, and they are much more favorable than in year one, which was \$30,000 in allowed Part B charges or 100 Part B patients. The 2018 thresholds for an individual provider reporting alone are now \$90,000 in allowed Part B charges or 200 Part B patients, so many more providers are likely off the hook and won't be subject to MIPS at all in 2018. They therefore cannot be penalized in 2020.

Q Can the areas in MIPS be re-weighted?

A Yes. Re-weighting might occur in a couple of scenarios:

- If a provider has a hardship exemption for ACI, that 25 percent from ACI would go to Quality, which would then carry a 75-percent weight.
- If there were no Costs assigned to a provider, the 10 percent from Resource Use would go to Quality.
- It's possible that you might have both of the above, so Quality could be as high as 85 percent of the composite MIPS score. [REVIEW](#)

Mr. Larson is a senior consultant at the Corcoran Consulting Group. Contact him at plarson@corcoranccg.com.



Lacrimedics' VisiPlug is not like "other" punctum plugs. We have no reported "pop-outs" since VisiPlug's introduction in 2003... and it's distributed in over forty countries!

FDA approved for the treatment of the Dry Eye components of varying Ocular Surface Diseases (OSD), after surgery to prevent complications due to Dry Eye Disease, and to enhance the efficacy of topical medications.

**VisiPlug® –
a visibly better plug
to treat dry eye!**



Lacrimedics

(800) 367-8327

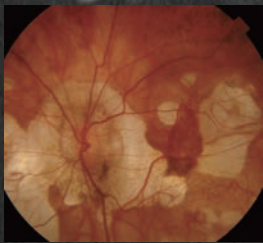
E-mail: info@lacrimedics.com
www.lacrimedics.com

¹Dramatization. Not a real patient.
©2017 Lacrimedics, Inc.

It's time for Triton.

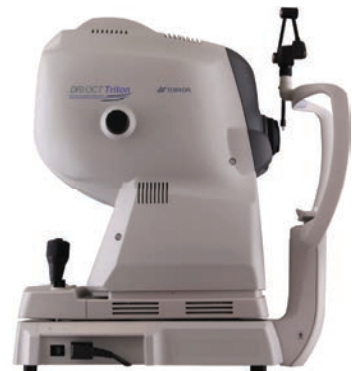It's all about the light source.

FDA CLEARED



SS-OCT

Contact your local Topcon Representative today or visit newsgram.topconmedical.com/triton.



DRI OCT Triton™ Series
A Multimodal Swept Source OCT



Is a Private Equity Deal Right for You?

Christopher Kent, Senior Editor

Surgeons and business experts answer ophthalmologists' main questions. (Part one of two.)

One of the most interesting things occurring in the field of ophthalmology today is the phenomenon of private equity firms buying ophthalmology practices. These partnerships have huge financial ramifications, as well as the potential to impact the health-care system and patient care.

The basic premise is that a private equity firm offers to form a partnership with an ophthalmology practice that it believes has the potential to grow. It provides funding to the practice owners, including an upfront payment in cash and/or stock, in exchange for a percentage of future profits. Ultimately, the goal is to increase the value of the practice by investing in its growth—often partly by consolidating it with other practices—so that in a few years it can be resold to another private equity firm for a significant profit.

“Private equity’s interest in the specialty of ophthalmology started three or four years ago when private equity firm Varsity Partners did a transaction with the Katzen Eye Group,” says Bruce Maller, founder, president and chief executive officer of The BSM Consulting Group. “A few smaller deals had been done previously, but that was the first significant deal in ophthalmology. Before you knew it,

many of these firms—as well as some investment banking firms—were cold-calling doctors. Our firm started getting calls from many of our clients asking what we thought about this, and in some cases we were contacted by the private equity firms, who wanted to know more about the field. In the meantime, transactions began to happen. Today, I believe nearly 20 private equity transactions have occurred, although I’m not keeping careful track.”

The widespread nature of this phenomenon has been confirmed at recent ophthalmology meetings. Richard L. Lindstrom, MD, an attending surgeon at the Phillips Eye Institute and Minnesota Eye Laser and Surgery Center in Minneapolis and managing partner at Minnesota Eye Consultants—now part of Unifeye Vision Partners, as a result of partnering with a private equity firm—spoke at this year’s Hawaiian Eye meeting. He reports that a survey of the audience indicated that about 35 percent of the audience had received a call from a private equity company. “About a third of the audience was currently interested in the model,” he adds, “and about 60 percent said they might consider it at some time in the next five years.”

In this article, part one of a two-part series on private equity and



One obvious advantage of selling a practice to private equity is an influx of capital. Katzen Eye Group's multiple private equity transactions have enabled extensive renovations of the physical plant. Left: The new aesthetic surgery waiting area. Right: A redesigned front desk area greets patients. Other changes have included new exam rooms, an expanded room for diagnostic retinal testing, a large pediatric section with waiting area and exam rooms (formerly a call center for the practice) and an upscale concierge area for cataract patients.

ophthalmology, several of the crucial questions doctors are currently asking about this phenomenon are answered by those who are actively involved in these deals.

1 *Why is this happening now?* “Right now private equity is very well capitalized,” notes Dr. Lindstrom. “The high-quality private equity groups are not just opportunists; they have a business plan and they’re looking for specific criteria in a practice. They’ve done well by operating and expanding businesses in several other fields, especially dermatology, which is a little bit like ophthalmology. In particular, they’re looking for specialties that are not hospital-based, and ophthalmology practices are perfect. We’re out in the community with our ambulatory surgery centers and our own offices, much like dermatology or plastic surgery or dentistry.”

John Pinto, president of J. Pinto & Associates, an ophthalmic practice management consulting firm, notes a number of factors that are stimulating the current wave of private equity offers. “For one thing, we have a bolus of doctors, baby boomers in their late 50s and 60s approaching retirement,” he points out. “Those doctors are most likely to benefit from a private equity

deal, and they probably have the power to make it happen, even if younger doctors in the practice are less certain about going down this path. A second factor is that tax regulations are very favorable for the private equity companies and their investors right now. Third, capital has been very readily available—at least until recently, now that capital markets are beginning to tighten again. We’re very late in the post-2008 Great Recession business cycle. We’re still cooking along if you read the stock pages, but the expansion is getting pretty long in the tooth. The Fed is now tightening interest rates, so it’s going to be harder to get access to cheap capital. That will not work in favor of the private equity companies.”

2 *How does this trend compare to the PPMC wave 20 years ago?*

Mr. Pinto’s experience with similar financial constructs 20 years ago has left him with some serious concerns about the current wave of private equity groups purchasing ophthalmology practices. “I know that for a certain class of surgeon—older surgeons or surgeons who are in over their heads operationally or financially, divesting to a private equity company could be a

great thing to do,” he says. “However, in this current trend I see elements of the errors many companies made back in the 1990s with the so-called ‘physician practice management companies,’ or PPMCs. Most of those were aggregates of private, independent practices, combined into large, publicly held companies like the one I was involved with—Physicians Resource Group.

“The history of that wave of commercial experiments was pretty dreadful,” he continues. “A lot of very entrepreneurial doctors were involved. We all thought we were really bright, but we had our heads handed to us. Virtually all of the firms that were developed went away. Along the way a lot of doctors were financially harmed, and even those who weren’t financially harmed had to undergo a lot of frustration.”

Are there differences this time around? “These are private, not public companies,” Mr. Pinto points out. “That changes the source of the funding and the nature of the risk. Nevertheless, the transaction model today has a lot in common with the previous PPMs model. There’s an agreed-upon amount of earnings that the acquired practice is expected to throw off, which will typically reduce the in-

comes of the doctors in the practice.”

Dr. Lindstrom notes another difference as well. “With private equity you’re not just selling a little bit of your revenue, you’re actually selling your practice into a ‘mutual fund’ of practices,” he says. “The last time, the doctors could hold the PPMCs hostage; in this case, it’s the other way around. If the doctor becomes really unhappy, he or she will be the one that leaves, not the company.”

3 What does a practice stand to gain by partnering with a private equity firm?

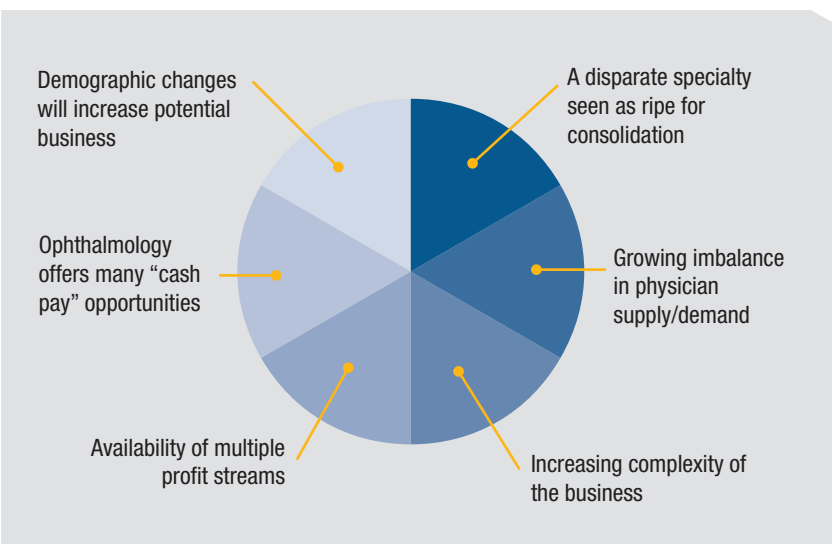
Two doctors with successful private equity partnerships say there have been multiple benefits for the doctors and practices:

- **Monetizing practice value.** “Minnesota Eye Consultants is now 29 years old, with 11 partners,” notes Dr. Lindstrom. “Generally when you sell that value to a younger associate, you do so at a relatively discounted value. Private equity, on the other hand, is willing to pay full value—or even a premium—for a high-quality practice. So our partnership was an opportunity to convert equity in Minnesota Eye Consultants into cash, along with obtaining some equity in the larger group, Unifeye Vision Partners, if we wished.

“As it turned out, all 10 of our partners wanted to invest forward, because in five or six years, once we and the four other markets are built up to around the \$500 million top-line revenue level, there will probably be a recapitalization,” he continues. “Another private equity company will come in and acquire Unifeye Vision Partners—hopefully at a premium. Then, as time goes by, it will become a \$1- to \$3-billion top-line-revenue eye care delivery system. Ultimately, it could become a public company.”

- **Funding infrastructure growth.** Brett W. Katzen, MD, FACS, president of Katzen Eye Group, based in

Why Private Equity is Interested in Ophthalmology



Richard L. Lindstrom, MD

Baltimore, has been part of two successful private equity ventures: first with Varsity Healthcare Partners (considered the first major ophthalmology-private equity partnership in the current wave) and later, Harvest Partners. Dr. Katzen says Varsity invested a lot of money into his practice infrastructure. “They invested significantly into my ambulatory surgery center, created a larger oculoplastics area and a larger pediatrics center, and built a first-class concierge center for refractive cataract surgery,” he says. “They shut down one of my offices and replaced it with a new office almost three times as big, with more equipment and more lanes. They enlarged my preoperative and postoperative areas, and they moved the nurses and administrators into a less-posh space so the first space could be used for clinical work. They got me a brand new femto laser, replacing the one I already had, and they moved my femto out of the OR into another room so we could have four ORs and a separate laser room. They also bought us a bunch of new microscopes.”

- **Relieving doctors’ personal debt load.** Dr. Lindstrom says that funding from the private equity company relieved the doctors of personal

debt that had accrued from financing capital improvements themselves. “We were growing at a rate of about 8 percent per year, but we were capitalizing that growth with personally guaranteed bank debt,” he says. “We were getting ready to build a major office in St. Paul—about a \$6 million investment—and some of my partners were becoming uncomfortable with the amount of debt they were guaranteeing. We knew this partnership would relieve us of that debt load.”

Dr. Katzen concurs that after you’ve borrowed a lot of money to invest in your practice, it can become a burden. “I was far enough in debt to the bank that I couldn’t borrow more money to build a new office or concierge center,” he says. “I couldn’t afford to move my LenSx laser out of the room it was in. I’d been funding everything myself, to the point where if I spent 10 grand or more, I had to tell the bank. It was cumbersome, smothering. Now, that’s not an issue. I’m out of debt and the private equity company is happy to invest in things they believe will make the business more profitable.”

- **Helping to broker consolidation and enlargement to remain—or become—a force in the marketplace.**

Be open.



Kahook Dual Blade® Perform without limits.



Minimally invasive procedures shouldn't be limited to being performed with other procedures. The Kahook Dual Blade's intuitive design enables safe and precise excision of trabecular meshwork to access multiple collector channels, anytime it is needed.

Visit Booth #1320 to learn how the Kahook Dual Blade lets you perform without limits.
KDBcert.com



Dr. Lindstrom says this was a way to fund their business plan to grow significantly over the next 10 years. “In the future I see situations in which small practices may be left out of large insurance panels,” he says. “That’s starting to happen in some states. In our market we want to be ‘too big to ignore.’ We want to be the practice that everyone bills around, if you will, as a third-party payer. There’s no way to ignore Twin City Orthopedics, because they have 60 percent of the orthopedic surgeons in the Twin Cities, and they have an office in every nook and cranny. We hope there will also be no way to ignore us, although our critical mass will be much smaller. Currently we represent about 10 to 15 percent of the eye-care marketplace in the Twin Cities. We hope to end up being 25 percent, which we believe will make us impossible for insurance companies to ignore.”

Dr. Katzen agrees that this kind of deal can help a practice survive in the current environment. “We have to compete against the hospitals and the insurance companies and the Kaiser Permanentes,” he says. “They have an advantage because of their size. This option gives us an avenue to consolidate and scale and still provide great eye care.”

- **Allowing more equity incentivization.** Dr. Lindstrom notes that the new group doesn’t have some of the legal limitations associated with a professional corporation. “In Minnesota Eye Consultants we had no way to allow a senior administrator such as a president or COO to own equity in the practice,” he points out. “However, they can own equity in Unifeye Vision Partners. So we can now equity-integrate, including our senior management team, giving them equity incentive.”

- **Making difficult decisions a doctor would prefer to avoid.** Despite his fondness for the business part of this, Dr. Katzen points out that doc-

tors often have the wrong personality to make difficult business decisions. “We want to be nice to everybody and do what feels good,” he says. “In business, you have to make decisions that don’t always feel good. The private equity people make those decisions for you.”

“By selling to a private equity company we did give up some control—but everybody in a group practice has already lost control.”
—Richard Lindstrom, MD

4 How much risk are we taking?

Mr. Pinto notes that much of the risk in the current situation falls on the private equity companies. “They’re taking considerable risk,” he says. “For the doctors in the practice, the biggest risk falls on the younger doctors who could find themselves locked into a relationship with the owner of the practice and taking a pay cut for many, many years. Of course, you’re not a slave. If it doesn’t go well, once your contract is up you can leave.”

“Back in the ‘90s, if you owned stock in a PPMC and you never sold it and the PPMC failed, you basically ended up getting nothing,” Dr. Lindstrom points out. “That was the case for a lot of doctors. But in this model, it won’t be the doctors who suffer. If the private-equity-based group fails, we’ll end up buying our practice back at a discount, as we did when the PPMCs failed—but this time the doctors will have cash in the bank.”

Dr. Lindstrom notes that future disruptions in America’s health-care

system or the economy in general are possible, if not likely. “I think the biggest disruptions that might happen would be going into a major recession, or the legislature saying we can’t afford health care and voting in a single-payer system,” he says. “They could decree that no doctor can own an ambulatory surgery center or an optical shop; they could say, ‘We’re going to pay every doctor a salary, and all a doctor can do is see patients.’ If you don’t think that could happen, I don’t think you’re looking carefully at what’s going on in Washington.”

“The question is, who would get hurt if that happened?” he continues. “The private equity company, not the doctor. All of a sudden, the holdings of that company that have been underwritten by the endowments of major institutions and wealthy individuals would decline in value. The doctor who did the private equity deal would be buffered to some extent, with money in the bank and no debt. The private equity company would have to sell off some assets, probably at a loss. The doctor just has to say, ‘OK, I used to make \$300,000 a year, now I make \$150,000, so I’ll have to adjust my lifestyle.’”

“The bottom line is that although doctors tend to think they’re taking all of the risk, there’s risk on the other side, too,” he says. “In fact, having a well-capitalized partner may help mitigate some of that risk as we go through future bumps in the road—which, in my opinion, are definitely coming.”

5 How much control are we giving up?

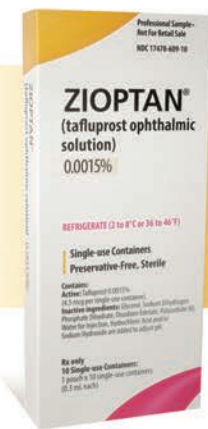Dr. Lindstrom acknowledges that doing an equity deal does involve giving up some amount of practice control. “We don’t get to decide everything by ourselves anymore,” he says. “Now we have an additional person at the table. That additional person’s primary control is over the checkbook,



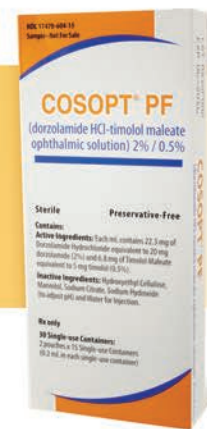100% PRESERVATIVE-FREE

ZIOPTAN[®]
(tafluprost ophthalmic solution) 0.0015%

Cosopt[®] PF
(dorzolamide HCl - timolol maleate ophthalmic solution) 2% / 0.5%



ORDER FREE SAMPLES



Go to either website
and select "Request Sample"

www.Zioptan.com

www.CosoptPF.com

Cosopt is a registered trademark of Merck Sharp & Dohme Corp and is used under license. ZIOPTAN is a registered trademark of Merck Sharp & Dohme Corp and is used under license.

Santen ZIOPTAN is licensed by Santen Pharmaceutical Co., Ltd.



One Practice's Story

So far, no one is reporting any terrible outcomes resulting from the private equity-ophthalmology practice partnership trend (although the trend has only existed for a few years). As noted in the main article, Katzen Eye Group has done very well. Here, Richard L. Lindstrom, MD, an attending surgeon at the Phillips Eye Institute and Minnesota Eye Laser and Surgery Center in Minneapolis and managing partner at Minnesota Eye Consultants—now part of Unifeye Vision Partners—shares his story.

“Our group, Minnesota Eye Consultants, currently consists of 14 ophthalmologists and 12 optometrists serving the Minneapolis-St. Paul marketplace,” Dr. Lindstrom says. “If you draw a circle 50 miles around us, that area subsumes about 3.6 million people, and we’ve been watching consolidation of medical practices occur in our marketplace for almost 30 years. There have been several different models; hospitals have acquired many practices, and there have been a lot of mergers creating ‘supergroups.’ For example, 30 years ago there were about 40 two-, three- or four-person orthopedic groups in the area. Today we have Twin City Orthopedics, which has about 120 orthopedic surgeons, and two slightly smaller groups with about 80 and about 50 orthopedic specialists each.

“It seemed clear to us that to be a meaningful player in our marketplace today, you need to have some scale,” he continues. “However, we really didn’t want to follow the orthopedic model.

Our practice is an academic, private practice; we do a lot of clinical trials and we frequently consult with industry. We felt that bringing other groups into our practice might mean forcing them to adapt to our practice culture, which might be different from theirs. So, we were looking for an alternative model.

“Then, about three years ago, we encountered the private equity model,” he says. “Probably the best way to describe a typical private equity arrangement is that it creates a ‘mutual fund’ of practices. Your practice equity becomes integrated with the other practices. As a result, it matters to me how those other practices do, and it matters to them how our practice does. We watched this type of deal occurring in dermatology and dentistry, and to some extent in radiology and anesthesiology. That got our attention, so we started to do a little research. At the same time, of course, private equity was researching ophthalmology.”

Dr. Lindstrom says in order to pursue this possibility, they hired a broker, Provident Health Care Partners. “We also worked with Bruce Maller and Associates and a law firm in New York City,” he says. “We wanted a PE partner that would take a hands-off approach; a group that was going to more or less let us continue to run our own practice, not come in and replace our leadership. We spent a lot of time looking carefully to find the right partner, making sure that our values were aligned with the group we chose. We

(continued on p. 42)

making decisions involving capital investment such as building a new ambulatory surgery center or opening another office. They also have the deciding vote on when we’re going to add another practice to our mutual fund of practices and how they’re going to compensate that practice to join the group. However, I think that could be a good thing, because these are smart businesspeople.

“When I was in solo practice, I pretty much decided everything,” he notes. “Then, as I added partners, I had to share decision-making with them. I now have 10 partners, and I don’t get to decide things just because I’m the senior doctor. So before the equity transaction took place, we were already a democracy with 11 votes. By selling to a private equity company we did give up some control—but everybody in a group practice has already lost control.”

6 Which practices are good candidates for a private equity partnership?

One thing everyone agrees on: Partnering with a private equity company is not a good idea for every practice. So, what makes a practice a good candidate?

Mr. Maller says that when doctors call and say they’re considering doing a deal, his first question is: Why? “Why would you want to do this?” he asks. “What are your objectives? What are you trying to achieve that you think this might help you with? Typically, the doctors are intrigued by the possibility of monetizing some of the equity in their practice. They like the idea of having a strong, disciplined financial partner who will help them build infrastructure and grow the practice to be more competitive and efficient. But usually the overarching consideration is, ‘Oh my goodness, somebody

is willing to pay me a lot more money for my practice than I could ever have gotten from a younger associate or a hospital.’ Clearly, the financial part of the offer stimulates a lot of interest.

“My advice always starts with this: As a practice and/or surgical facility, you need to be clear about your long-term vision for your practice,” Mr. Maller continues. “You have to ask yourself if having a financial partner is going to help you to attain near-term and longer-term objectives. Because if you don’t have a vision that involves building something substantial, then you and private equity are not likely to be a good match.”

Mr. Maller explains that private equity firms take money into their investment funds from a variety of high-net-worth individuals and institutions. “Private equity is normally a small slice of an investor’s portfolio,” he says. “However, it’s considered the

IF YOUR FEMTOSECOND CATARACT LASER HASN'T EVOLVED, IT'S PROBABLY EXTINCT



The intelligent LENSAR® Laser System is always evolving to find new ways to help you deliver incrementally better outcomes to your patients. Today, with Streamline® IV, LENSAR provides you with exceptional insights to help you confidently and precisely manage astigmatism, like no other femtosecond cataract laser. It's survival of the fittest—don't let your technology put you at risk for extinction.

**Join the Evolution at Booth #842.
Manage Astigmatism With LENSAR, Now With Streamline IV.**



LENSAR
CATARACT LASER WITH AUGMENTED REALITY

One Practice's Story (continued)

(continued from p. 40)

started by evaluating about 100 private equity companies. Then we narrowed that group down to 10, then three, then two, and finally one: Waud Capital Partners, a group out of Chicago. Then it took us about three years to negotiate the deal—it was a long process. It resulted in the creation of Unifeye Vision Partners.

“Now, when we have a partner meeting, a member of the Unifeye Vision Partners capital leadership is in the room as well,” he explains. “They want our growth to accelerate, but if we’re going to spend \$6 million, as we did on our office space, they’re going to look carefully at the size of the opportunity, the population we might serve, the return on investment, and so forth. We’ve been adding a surgeon about every other year, and an optometrist on alternate years. They’d like to see us accelerate that growth, probably adding a doctor every year. They’d like to see us grow at 10 or 12 percent per year instead of 8 percent, and double in size within six or seven years. Of course, the way they accelerate our growth is by adding capital.”

Dr. Lindstrom says that Unifeye Vision Partners’ ultimate goal is to assemble practices from five ophthalmic markets (out of about 80 ophthalmic markets in the United States) and build a \$100 million top-line-revenue integrated eye-care delivery system. “Given the size and strength of our practice, Unifeye Vision Partners is about halfway to the financial part of that goal,” he notes. “We’d like to bring some other practices in our area into Unifeye Vision

Partners as well, although as already noted, we don’t necessarily want those practices to merge into Minnesota Eye Consultants. We’d be very happy just to have a busy clinical group that wants to do clinical work, and we’d like them to be able to keep their own name on the door.

“Now that we’ve done the deal, we’re building a big office in St. Paul,” he says. “None of our partners has any debt; we all have money in the bank. We still own equity, but not in Minnesota Eye Consultants. Now, our equity is in Unifeye Vision Partners. That’s one of the positive aspects of an arrangement like this; it’s an opportunity to have equity integration and benefit from the growth that you generate.

“So far, everyone is still feeling good about the new arrangement,” he adds. “We haven’t noticed any change in the way we practice; we haven’t noticed any problems, or seen any interference when we decide to add new technologies. To some extent, we’ve been encouraged to invest more than we might have been comfortable doing on our own.”

What about horror stories? Dr. Lindstrom points out that so far, private equity deals don’t appear to have led to any disastrous outcomes. “When I was doing my due diligence, I studied the dermatology field very carefully, since they’ve been doing these deals longer than we have,” he says. “I couldn’t find a bad private equity experience in dermatology, either.”

—CK

highest-risk type of investment. For that reason it demands the highest return, and the only way an investor is going to get a high rate of return from investing in your practice is if you have a significant trajectory to grow cash flow. A business or practice that’s not motivated to build or grow is not a good platform target for private equity.

“The exception would be that your practice might be a good ‘fold-in’ acquisition,” he notes. “You might want to make a deal because you’re in the latter part of your career, and you’ve done fine but you don’t want to sell your practice to young associates. In that situation it doesn’t really matter that you don’t have a great plan to build and grow, because you’re planning to retire. The private equity-backed investor will put young physicians into your spot—presumably for a lower cost of labor, producing more

cash flow as a result. At least, that’s the theory.”

“A private equity deal might make sense for 10 to 30 percent of U.S. practices, but it won’t make sense for the rest,” says Dr. Lindstrom. “In actuality, only a very select group of practices will even have the opportunity to do a deal of this kind. If you receive an offer to buy your practice for a lot of money, you may do your due diligence and decide it’s not a good deal. Or, you might want to do a private equity deal and not be able to find a buyer.”

Mr. Maller adds that overall, he’s advised the majority of his clients not to proceed with a private equity partnership.

7 What about the second transaction—the one you can’t control?

Dr. Lindstrom understands that

doctors considering partnering with a private equity company may be concerned about what will happen down the road when and if a second buyer takes over. “The doctors get to negotiate the deal with the first partner,” he notes. “They know who the people across the table are, they know their culture, they can look them in the eye, check their history, and so forth. But there’s no way to know who the buyer will be if a second or third transaction takes place in a few years. I’m sure people worry that the group might be sold to the devil. The new owners could come in and fire employees, or tell the doctors they have to work 80 hours a week.

“However, I think that’s unlikely,” he says. “Look at similar transactions in the corporate world when mergers and acquisitions occur. You don’t usually see extremely onerous working

E

V E R Y

D O S E

C O U N T S

STRIVE TO SEE THE BEST RESULTS POSSIBLE

Regular fixed-interval dosing of long-term treatment with anti-VEGFs has been shown to provide better gains and maintenance of vision, compared to PRN or treat-and-extend dosing regimens, in some patients with Wet AMD and DME.¹⁻⁶

Ask your Regeneron representative what we can do to help ensure patients come in for their scheduled treatment.

anti-VEGF = anti-vascular endothelial growth factor; AMD = Age-related Macular Degeneration; DME = Diabetic Macular Edema.

References: 1. Heier JS et al. *Ophthalmology*. 2016;123(11):2376-2385. 2. Rosenfeld PJ et al. *N Engl J Med*. 2006;355(14):1419-1431. 3. Ho AC et al. *Ophthalmology*. 2014;121(11):2181-2192. 4. Nguyen QD et al. *Ophthalmology*. 2012;119(4):789-801. 5. Kaiser PK et al. *Ophthalmol Retina*. 2017;1(4):304-313. 6. Peden MC et al. *Ophthalmology*. 2015;122(4):803-808.

REGENERON

© 2018, Regeneron Pharmaceuticals, Inc. All rights reserved.
777 Old Saw Mill River Road, Tarrytown, NY 10591

01/2018 US-OPH-13911

conditions coming in. Yes, you might see some adjustments made, but usually an acquiring company's primary goal is to retain the value of the assets they acquire and add additional capital to grow it again so they can re-sell it."

Dr. Katzen has already experienced a second transaction; he describes what happened. "My first private equity partner invested a lot of money into my platform," he says. "Together, we formed a management team of executives that ran the company and took it to the next level. Once it became really successful, my private equity partner said, 'Brett, I'm out. We're selling.' The people at Harvest said, 'We really like your management team and structure. We want to buy that from you.'

"When Varsity sold to Harvest our contract didn't change," he continues. "They bought the company 'as-is.' So for the doctors it was pretty much a seamless transition. At the same time, our doctors were happy because they realized a bump in the value of their stock. Most of them just rolled it into the next company, because things have been going so well. In fact, many other doctors in the practice who were nervous about taking stock when the first sale happened decided to jump in on the second hit. Now everybody's pushing everyone to work hard and make this an even bigger success, hopefully leading to another financial payoff."

Dr. Katzen says that when Harvest took over, the first thing they did was hire even more best-in-class leadership. "They brought in C-suite executives who'd run big companies and built big businesses," he says. "Now my compliance officer is a health-care attorney. My CFO is also an attorney, and he's run big businesses. My COO was the chief executive at another large business. Harvest created revenue-cycle management teams in each region, so they can take care of this on a local basis. Marketing, human resources, compliance, benefits, IT and

Timeline of a Private Equity Transaction

Activity	Mo 1	Mo 2	Mo 3	Mo 4	Mo 5	Mo 6
Complete due diligence		✓		✓		
Develop transaction documents					✓	
Complete contracts and assignments					✓	
Address operational issues					✓	
Progress to closing						✓

Richard Lindstrom, MD, notes that working out a private equity deal involves an evaluation phase; time spent negotiating business terms; and then a closing process. In his case, the practice began considering a deal 18 months before engaging with the company. Once a potential partner was chosen, the deal still took months to complete, as shown above. The first due-diligence process led to the creation of contracts at two months; then another two-month period was spent doing further due diligence on the contracts themselves. At six months, the deal was finally closed.

physician recruiting are all handled centrally. Harvest also revamped my infrastructure, with better revenue-cycle management, computers, next-generation EMR systems, you name it. They put a ton of money into IT, and they centralized all of our phones into one phone-answering center for the whole area."

Dr. Katzen acknowledges that worrying about the nature of a second purchase is reasonable. "However, we didn't have a bad experience," he says. "We were bought by people who understand that the doctors are the lifeblood of the organization. They understand that if you don't have happy and healthy doctors doing their job, the business goes sour. As a result, they're not changing the nature of our job, just trying to make it even more efficient. Meanwhile, we've moved from being part of a \$200-million fund to being part of a \$2.3-billion fund."

8 Will the private equity company base its decisions on money alone?

Obviously, money is the prime motivation when a private equity company purchases a practice, so it's not unreasonable to worry that decisions might be made that will undermine the practice (or its patients) simply because those decisions might improve the bal-

ance sheet for the next buyer. Along those lines, Mr. Pinto repeats a story he often tells when giving presentations on this topic. "Back in the '90s, I was sitting with a venture-capital guy putting a deal together," Mr. Pinto recalls. "I remarked that I was happy to be a part of this because I'd always worked to help make practices work better. He leaned over the table and said, 'I'm not sure you understand our business model. We're not going to make these practices better; we're not going to manage them, even though we're called a practice management company. We're going to go public, sell our stock and then move on to our next deal.' Of course, that was 20 years ago, but to a large extent that's also where we are now."

One way in which such an attitude might manifest would be having the new partner come in and start eliminating resources in a quest to improve profitability. Clearly, many people in other industries have experienced the phenomenon of private equity companies firing employees and closing lines of business to make the books look better for the next potential buyer. However, Mr. Pinto says he doesn't think that's likely to happen with an ophthalmology practice. "In most practices in operation right now, you wouldn't increase profit much by

reducing costs, because most costs involved in running a practice are fixed,” he points out. “The best way to increase profit in an ophthalmology practice is to enhance revenue. For example, in a typical practice, if the doctor sees just three more patients per day, that generates \$100,000 more per year in profit. So I don’t think you’re going to see a lot of cost-cutting measures taken. Anybody who is thoughtful is going to be working on revenue enhancement; adding surgery centers where they don’t already exist, adding an optical where it doesn’t already exist, and so forth.”

“Of course private equity companies care about the money, but they’re also about the business being successful,” notes Dr. Katzen. “They’ll never be able to sell to another partner unless they build a great business.”


9 Will the private equity company help manage the practice? If so, how?

Mr. Pinto says that a big part of the problem during the PPMC wave 20 years ago was that doctors expected the PPMCs to help manage their practices. “After all, the name of that phenomenon implied that these were practice-management companies,” he points out. “I suspect that a lot of practitioners who are being courted by private equity companies now are laboring under the same expectations. They think, ‘My practice is getting harder to manage, it’s outside of my comfort zone, so I think I’ll join a private equity company. That firm will help me manage my practice better.’”

“The reality is, many of these companies are not in the business of improving practice management,” he says. “Their purpose is to aggregate earnings from the practices they pull together, with the aim of generating a subsequent transaction a few years from now in which they’ll take that aggregated value and sell it to an even larger consolidator. It’s about making a profit for their investors, not helping doctors manage their practices. What I’ve seen so far is that most of these companies are in a ‘land rush’ right now, anxious to write deals.”

“Imagine that you’re an executive in a private equity company,” he continues. “You have a certain amount of capital and a limited amount of time to get these deals done. Would you put all of those resources into sending your people out, negotiating, doing analysis and closing deals, or would you take some of your resources and deploy them improving, managing, fine-tuning and enhancing the practices that you already added to your quiver? You’d probably put everything into acquisition.”

“During negotiations, when a private equity company is discussing the transaction and listing the benefits for the selling doctor, the promise of better management and taking all of these nonmedical chores off your hands is prominent,” Mr. Pinto notes. “But when I talk to the



PASSIONATE ABOUT PATIENT CARE?

His sight depends on your confidence.

Ocular Response Analyzer® G3

Corneal Hysteresis, a more objective predictor of glaucoma progression. CPT code 92145.

ASCRS #532 · reichert.com/ora

Reichert
TECHNOLOGIES

AMETEK © 2018 AMETEK, Inc. & Reichert, Inc. (03-2018) · Made in USA

Ocular Response Analyzer is a registered trademark of Reichert, Inc. · www.reichert.com ·

folks on the private equity side of the world, most of them don't appear to be very interested in making practices better. Think about this: The bonuses received by young private equity executives are going to be based on how many deals they did, how big an earning stream they've brought into the company. They're not going to be rewarded by whether this or that practice is running more smoothly."

On the other hand, Dr. Katzen points out that a private equity company can't just make a purchase of this kind and then remain 'hands-off.' "When you buy practices, you have to integrate them successfully," he says. "You can't just say, 'OK, doctors, mail us our portion of the check.' That wouldn't work, because a practice would probably spend as much as they could, especially knowing that someone else is going to take whatever profit is left over. To make this work, the private equity people really have to manage and integrate these practices skillfully."

Mr. Maller says that in his experience, private equity companies influence how a practice is being run indirectly. "What the private equity investor brings is business knowledge, experience and discipline—primarily financial discipline," he says. "They're not going to run your practice, but they know how to find talent. So, they'll help you identify gaps in your talent pool and assist you with recruitment to make sure you bring in the right people to help you achieve your objectives. They'll also help with infrastructure to ensure that your business gets stronger over time. Ideally, they'll be guiding you, coaching you, supporting your team and being good partners with your management team."

"In order to do this, when these firms come in and make an investment, they create a governing board," he continues. "The governing board is often composed of two or three physicians and two or three members of

the firm. Sometimes they'll also bring in independent experts or consultants for an outside perspective. The operating team reports to the governing committee, so the governing board is influencing the management of the company, but they're not the ones doing the work."

Mr. Pinto adds that some private equity companies will have an unpleasant wake-up call if they do try to manage ophthalmology practices. "Ophthalmology practices are materially more complex than what people encounter in other business circles," he says. "I know of a \$50-million practice that was not able to find a CEO in the health-care field, so the doctors decided to hire a fellow who had previously been the number-two person in command of a worldwide engineering firm—a \$2-billion company employing something like 8,000 engineering professionals. I got a call from him six months into the new job. He said that running the \$50-million practice was much more complex than running the \$2-billion company. He was thinking about throwing in the towel! So companies who think that stepping in to manage a large ophthalmology practice will be straightforward may be in for a shock."

10 *How do you find a good partner?*

Obviously, as in marriage, choosing the right partner is the most important part of the deal.

• **Take your time and research potential companies thoroughly before making a decision.** "I've met and talked to 15 or 18 of the private equity firms," says Mr. Maller. "Out of all of those, I've encountered three or four that clearly set themselves apart. How? It's the people; their attention to detail; their sensitivity; their awareness and understanding of our business; and their willingness to support doing the right thing for patients, staff and doctors. Those are the firms that I

think will be very successful with this model."

Dr. Katzen says that it's important to not be in a hurry. "I spent at least five years doing my homework before I pulled the final trigger," he notes.

"There are some private equity companies where the first thing they do is fire the current leadership and take over," Dr. Lindstrom says. "We wanted a partner that wasn't going to do that, and in our first transaction we achieved that goal. The partner we chose wasn't intending to increase earnings by reducing overhead; their priority was to grow the practice at an accelerated pace. I think you can probably delineate that with your first partner pretty easily, but you still have to do your homework and choose your partner wisely."

Dr. Lindstrom adds that if you're not the first group to join the 'mutual fund' of practices, it's important to look at who the other partners are. "If the practices already involved don't seem like a good selection—or if they're practices you wouldn't want to partner with—then that group is not going to be a good choice for you," he notes.

• **Consider the motivation of the company you're partnering with.**

"The investor's motivation isn't necessarily aligned with the motivation of the doctors," says Mr. Maller. "The thing that makes a practice successful is usually an entrepreneurial, passionate physician or group of physicians who want to create a great business, a great brand, and provide great patient care. You run the risk of losing that when financial people come in. They might say, 'You guys were willing to keep all these people on, but we're not hitting our targets, so we're going to let 30 percent of the staff go.'"

Mr. Maller says in his experience, however, many private equity companies do understand that if you don't treat the practice well, you won't make money. "The private equity firms that I recommend to my clients are run by

honest and decent individuals,” he says. “They understand that if you don’t operate this the right way, if you don’t take care of the doctors and the management, the model may break down. Making money and providing the great patient care are not mutually exclusive.”

Mr. Maller adds that it would be naïve to think that a practice owner isn’t also at least partly motivated by making money. “That doesn’t prevent a doctor from delivering extraordinary care and great service,” he points out. “And, a good private equity firm can play a very important role in helping to build and grow a great enterprise.”

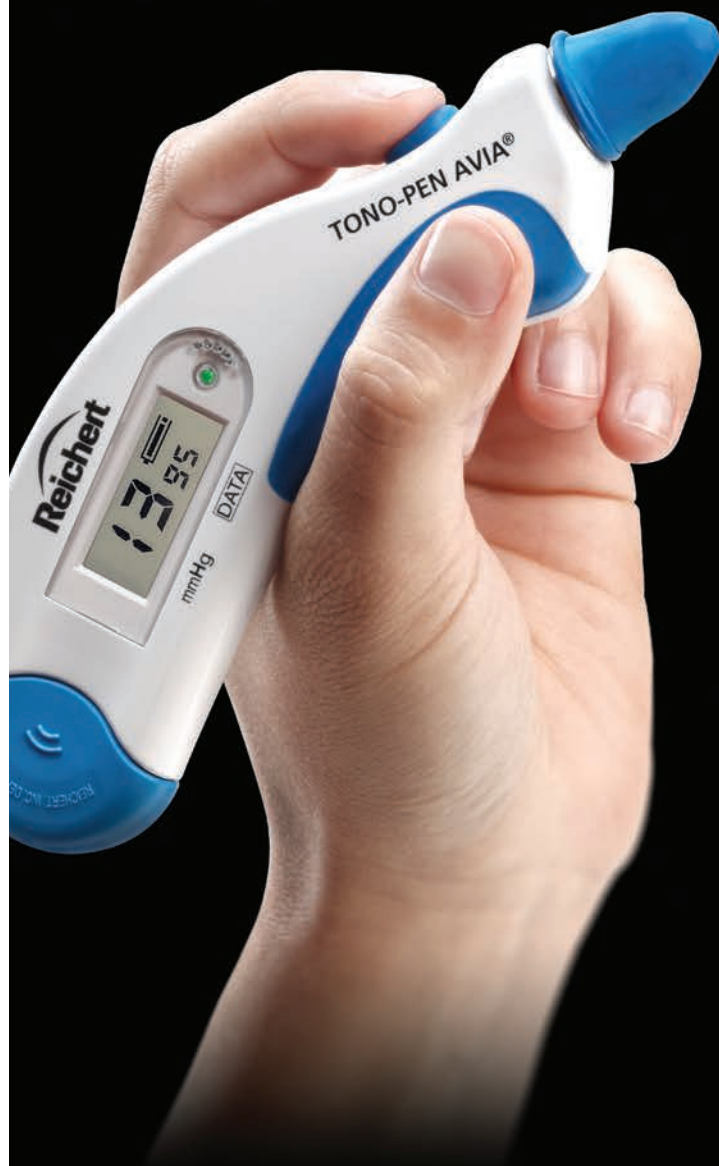• **Be prepared for potential deals to falter.** Dr. Katzen says he met with 15 different private equity companies when researching the first deal. “I negotiated a deal with another group that I liked,” he says. “They were going to be a minority owner, and I was going to sign that deal because I loved the group, and they were going to let me and my team run the business. But at the eleventh hour, it turned out that their stock would be ‘A’ class, whereas mine would be ‘B’ class. That meant that even though I was majority owner, they’d still have all the control. That wasn’t going to work for me.”

11 *What will happen to the practice if the deal works out badly?*

“In some cases, that would be resolved in the courts,” says Mr. Pinto. “In some cases, the bond holders will take a haircut. In some cases, the doctors will end up buying their assets back for cents on the dollar. Back in the ‘90s, a lot of doctors ended up buying their practices back from the PPMCs. Some of them made out very well, but they went through a lot of pain and suffering. And obviously, this would be very problematic for a doctor near retirement. If you’re planning to retire in five years and something happens to your private equity company at the two-year mark, having to buy the practice back—even at a discount—will put a lot of wobble into your last few years of practice.

“That’s why you want to use the ‘acid test’ before taking the plunge,” he says. “First, make sure the irrevocable monies that you get at the front end take you over your financial finish line. Second, make sure you don’t have any emotional investment in what happens afterwards. If you follow that strategy, you’re now financially and emotionally independent. If the private equity company blows up, you just haul up the truck, and you’re done. This happens in the rest of the business world all the time. It’s an abrupt, shocking denouement compared to the genteel worlds most of us live and work in.” **REVIEW**

Next month, experts address questions such as the impact of the deal on patient care as well as the effect of lower salaries on an ophthalmic practice.



PASSIONATE ABOUT PATIENT CARE?

Clinicians trust Tono-Pen® most.

Tono-Pen AVIA® Handheld Tonometer

Always ready-to-use and calibration-free. Fast, reliable IOP measurements. Technician Friendly.

ASCRS #532 · reichert.com/tonopen

Reichert
TECHNOLOGIES

AMETEK © 2018 AMETEK, Inc. & Reichert, Inc. (03-2018) · Made in USA

Tono-Pen & Tono-Pen AVIA are registered trademarks of Reichert, Inc. · www.reichert.com ·

Vitreous Floaters: What Can Be Done?

Walter Bethke, Editor in Chief

There aren't a lot of options for minor types of floaters, but the YAG laser shows promise.

Vitreous floaters are one of those perennial patient complaints that, traditionally, ophthalmologists simply had to respond to by saying, in the most sympathetic manner possible, “There’s nothing we can really do for them. Hopefully, with time, you won’t notice them as much.” In recent years, however, some surgeons have begun looking into treatments for floaters in certain patients. In this article, retina specialists weigh in on the current state of treatment for vitreous floaters.

The Vitrectomy Option

The main reason ophthalmologists had little recourse when faced with floaters was, for the longest time, the only “treatment” for them was a vitrectomy, which, in many cases, seemed like using a bazooka to kill roaches. However, for certain patients with significant floaters, it can be a worthwhile option, surgeons say.

“Vitrectomy for floaters is a field with much more data than YAG vitreolysis,” says Boston retinal specialist Chirag Shah, MD, MPH, referring to the trend of using the YAG laser to break up floaters. “We have significantly more experience with vitrectomy and are much more comfortable with it. Vitrectomy is also more effective at

removing floaters than YAG vitreolysis, which vaporizes and fractionates floaters without actually removing them. The downside, though, is that there are more risks with vitrectomy. For instance, phakic patients who undergo vitrectomy will develop a cataract. Importantly, there is also a small risk of retinal detachment, which ranges from 0 to 10.9 percent in the literature; I estimate the risk to be around 2 to 3 percent based on my experience. There are other risks, too, including the risk of infection, which is around 1:1,000, and the risks associated with local anesthesia.”

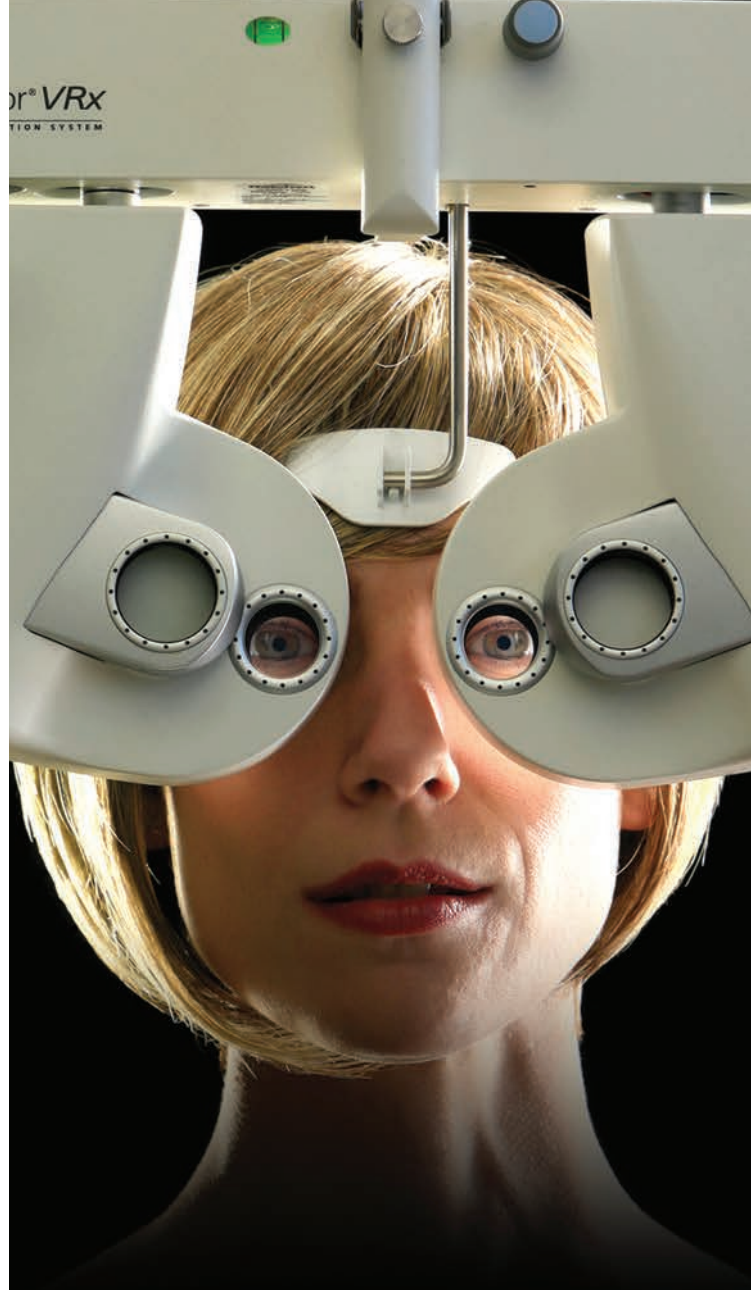In addition to these risks, there are rarer, but still possible, risks, says Jennifer Lim, MD, professor of ophthalmology and director of the retina service at the University of Illinois, Eye and Ear Infirmary in Chicago. “A more catastrophic complication of vitrectomy could be a suprachoroidal hemorrhage—it’s very rare but it could happen, especially in certain at-risk populations,” she says. “Another rare occurrence is inadvertently striking the retina with the vitrector, which could lead to subretinal bleeding or retinal tear formation. Also, although this is unlikely to occur, a patient could potentially cough or make a sudden movement, causing the surgeon to hit the retina or the wall of the eye with

the instrument. Though these are rare, extreme examples of complications that could occur, we have to acknowledge them when considering a vitrectomy for floaters. You can't just blithely schedule a vitrectomy for floaters and think that everything is going to be fine."

Surgeons say that even though vitrectomy is obviously effective, the severity of the patient's floaters must be commensurate with the risks involved with full-blown intraocular surgery. "For patients who come in with complaints of floaters, and they say they're being bothered by them, my most-common response is to recommend observation for a minimum of six months," Dr. Lim says. "It sounds kind of harsh, but a lot of time these are fresh posterior vitreous detachments, and, over time, the floaters diminish and the opacities settle down. If you've ever talked to a person who's had a PVD, their symptoms are dramatic in the beginning. Then, on the follow-up visit, when we're still checking for any retinal holes or tears—the patient usually isn't as anxious or bothered. Then, at six months, many patients come in saying that the condition is much better and they're fine. For many patients, in addition to observation, I also recommend that they don't have their ambient lighting so high that it causes high contrast in their environment. Such high contrast makes it easier to notice the floaters. I also teach them how to hold their reading material at an angle so they get less glare and reflections, which can make the floaters less noticeable. It's important to note that the risk for a retinal tear and/or detachment after an acute PVD is highest in the first six weeks following the PVD, and diminishes at six months. In many cases, if the tear or detachment is going to happen, it will happen by a year after the PVD."

Though observation and modifying the patient's environment can help in a lot of cases, there are more severe cases of floaters that surgeons say do need to be addressed surgically. "Most of the patients with acute PVD complain that they see a cellophane-like membrane accompanied by hundreds of black dots floating around their vision," Dr. Lim says. "If this doesn't clear, this would be a type of patient presentation for which I'd consider a vitrectomy. There are also the patients with whom I discuss the risks of vitrectomy—I let them know the worst—who still come back months later and say, 'I'm really still bothered by them.' For them, I'll consider the surgery. However, in all cases I have to actually be able to see vitreous opacities. I have to see that the vitreous is cloudy and/or there are a lot of floaters and/or vitreous opacities drifting around."

"Other than patients with floaters and with pathologic conditions, such as a dense vitreous hemorrhage or a retinal tear, which need to be addressed with a vitrectomy, the patients on whom I've performed vitrectomy just for bothersome floaters were often graphic designers who worked on the computer all day and were really bothered by their



PASSIONATE ABOUT PATIENT EXPERIENCE?

The most advanced Phoroptor® ever.





Phoroptor® VRx Digital Refraction System

A premium refraction experience. Incredibly fast.
Ultra-quiet. Effortless integration. Made in USA.

ASCRS #532 · reichert.com/vrx

Reichert
TECHNOLOGIES

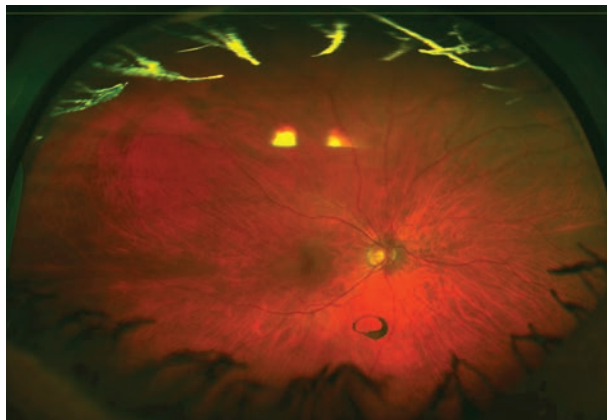
AMETEK © 2018 AMETEK, Inc. & Reichert, Inc. (03-2018) · Made in USA

Phoroptor is a registered trademark of Reichert, Inc. · www.reichert.com ·    

condition,” Dr. Lim adds. “They told me that their floaters affected their job performance by limiting their concentration and visualization of the computer images. One patient even said he’d rather have me remove his eye than live with the floaters any longer. This patient wound up going to a psychologist about it, and got a letter from him stating that the floaters were making him depressed and negatively affecting his lifestyle.” Despite such patients meriting a vitrectomy, Dr.

Lim says she still doesn’t proceed with the surgery lightly. “You must remember that a lot of these folks with floaters are also high myopes, who are at higher risk for retinal detachment,” she says. “These are long eyes and, if you do an incomplete vitrectomy like some physicians advocate, eventually that hyaloid is going to pull off. It may happen soon after the surgery and the patient may get a retinal detachment. We’ve seen such cases. On the other hand, the other argument is that if you do a complete vitrectomy, you could tear the retina in two in a very high myope. On the eyes in which I’ve done the surgery, I do try to go for a PVD, and they’ve done well. I’ve done maybe five such surgeries over the past five years.” She says another situation where vitrectomy might be warranted is patients who see 20/20 but have a lot of contrast sensitivity problems stemming from the floaters. “I would recommend performing contrast sensitivity testing before surgery to demonstrate that it’s decreased because of the floaters,” she says.

Dr. Shah says his threshold for performing vitrectomy on visually significant floaters is lower now during the era of 27-ga. vitrectomy, compared to the days of 20-ga. vitrectomy. “I have a lower threshold because, at least in principle, with 27-ga. the wounds are



Some vitreoretinal surgeons say a well-defined Weiss ring such as this indicates a good candidate for YAG laser vitreolysis.

All Images: Chirag Shah, MD

small, so there’s less risk of hypotony and infection. Still, I only perform about one vitrectomy per year for significant floaters.”

A New Option: YAG

In an effort to ease the burden of patients who are complaining of floaters, but to avoid the risks of intraocular surgery, some ophthalmologists have turned to YAG laser vitreolysis. Some surgeons say this approach may be a middle ground between observation and surgery but, just like vitrectomy, it appears it’s not for every patient.

Michael Tibbetts, MD, is a medical retina specialist in Ft. Myers, Florida, who offers YAG vitreolysis for certain floater patients, and can speak about who is a good prospective patient for the procedure. “A good candidate is someone who has had symptomatic vitreous floaters for at least four months,” he says, “and who has definite evidence of a posterior vitreous detachment on exam. The floaters or vitreous opacities should be correlated with the patient’s symptoms on a thorough fundus examination. Symptomatic patients who are candidates for treatment report impairment in vision with a specific activity, for example with reading, watching television or driving, and this complaint should be documented in the medi-

cal record. There are many patients who may report intermittent floaters that aren’t affecting their quality of life, and I don’t think they’re candidates for YAG treatment.” He says the YAG patient also shouldn’t have any other retinal pathology such as retinal tears or detachments, and shouldn’t have any significant opacities in the cornea or lens that would impair the physician’s view of the vitreous. If there is a posterior capsular opacity or significant cataract, Dr. Tibbetts advises treating

those problems first.

“A good presentation would be someone with a solitary Weiss ring—which is the vitreous tissue that was previously attached around the nerve head—that’s very dense and, importantly, located in the sweet spot not too close to the retina or too close to the lens,” says Dr. Lim.

Dr. Shah, who doesn’t perform YAG laser vitreolysis in his practice, but analyzed the modality in a small pilot study, says at least one particular type of floater may also not be amenable to YAG laser vitreolysis. “In some cases, there’s a Weiss ring plus a fluffy, white ‘caterpillar-like’ floater in the inferior/anterior vitreous,” he explains. “Dr. Karickhoff termed this a ‘floater duet.’ When a patient with a floater duet looks down, the fluffy white floater will drift superiorly and impact vision. A floater duet is very difficult to treat with YAG laser vitreolysis. I inadvertently included a floater-duet patient in our study, and realized that one can treat the Weiss ring, but the symptoms are often unchanged because of the hidden floater duet. If treated with the laser, the floater duet tends to fractionate, creating many small, mobile floaters. This particular patient’s symptoms were not improved after YAG vitreolysis.”

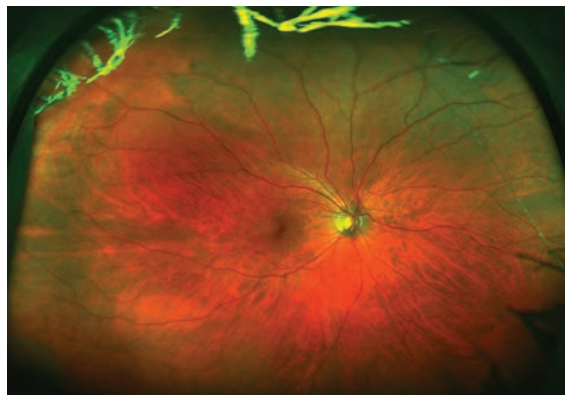
Though there haven’t been any

large, randomized studies of YAG laser for floaters, there have been several small case series, as well as the one small, prospective study by Dr. Shah, that show the potential risks include damage to the crystalline lens or an intraocular lens, if present; an increase in intraocular pressure, retinal damage and/or retinal tear or detachment.^{1,2,3,4} Dr. Tibbetts says, in the 75 to 100 procedures he's done, he's seen rare instances of retinal tears on scleral depression postop, but that they all were effectively treated with laser photocoagulation.

"The YAG laser vitreolysis can be performed in the office, with topical anesthesia," Dr. Tibbetts says. "It can be performed in patients who are phakic or pseudophakic, and it's a procedure many ophthalmologists have access to by virtue of having access to a YAG laser, though lasers with coaxial illumination are better suited for the procedure.

"YAG laser vitreolysis is effective in treating well-defined vitreous opacities," Dr. Tibbetts continues. "For more diffuse vitreous opacities, pars plana vitrectomy may be a better option."

When approaching the procedure itself, Dr. Tibbetts says visualization is key. "The surgeon can only treat what he can see, so if you can't see the opacity, you can't provide an effective treatment," he explains. "Using a YAG laser specifically designed with coaxial illumination, and the appropriate lens, is critical for illuminating the mid-vitreous. For treatment, the surgeon must use sufficient energy to definitively treat the opacity, at least 3 to 4 mJ, as well as a sufficient number of laser pulses. A treatment usually consists of 150 to 200 pulses and, to treat the opacity effectively, sometimes over 300 pulses are necessary. I'd advise starting with patients who



The patient shown on the opposite page following YAG laser vitreolysis for the Weiss ring opacity.

are pseudophakic for your first 20 to 30 cases before you consider treating phakic patients." Dr. Tibbetts performs a careful fundus exam after the treatment and checks the IOP. He then follows up with the patient a week later and performs a dilated fundus exam with scleral depression and checks the pressure again. He asks the patient to score their symptomatic improvement from 0 to 100 percent (100 percent equals complete symptom resolution) and compares this assessment with the fundus findings.

"Once patients report a 70- to 80-percent improvement in their symptoms, I advise observation and a follow-up exam in one to two months," Dr. Tibbetts says. "If the examination demonstrates residual opacities and the patient is not satisfied with the symptomatic improvement, I may offer an additional laser treatment at the one week postop visit."

• **What the literature says.** As mentioned earlier, Dr. Shah and his colleagues performed the only prospective, randomized study of YAG laser for floaters. Although it was a small study, it contains some findings that surgeons can look to for guidance, or for structuring future studies.

In the study, Dr. Shah and his colleague Jeffrey Heier, MD, randomized patients with symptomatic Weiss ring

floaters following PVD to either YAG laser or sham YAG. Thirty-six patients received the treatment, and the rest got the sham.

The YAG laser group reported a 54-percent improvement in their symptoms, vs. just 9 percent of the controls ($p<0.001$). On a 10-point visual disturbance score, the patients in the YAG group improved by 3.2 points vs. 0.1 for the sham group ($p<0.001$).

Nineteen patients in the YAG group (53 percent) reported significantly or completely improved symptoms vs. none of the controls ($p=0.04$). On the National Eye Institute's Visual Functioning Questionnaire 25, the treatment group showed improved general vision, better peripheral vision, fewer "role difficulties" (i.e., difficulty performing tasks without help from others due to vision) and less dependency than the control group.⁴

"One striking finding from the study was the significant proportion of patients who had an excellent objective response to YAG vitreolysis, but no subjective response," Dr. Shah says. "Specifically, eight of 32 patients reported 0-percent improvement in symptoms after YAG vitreolysis, but 7/8 had significant objective improvement based on before and after color photography as determined by a masked grader. This was interesting—and concerning—because it means that even though, objectively, a surgeon can vaporize most of a Weiss ring, there are still some residual particles that bother the patient as much as the initially large Weiss ring floater. This speaks to the importance of patient selection, not just floater selection. Many patients who are bothered by floaters have high visual demands and can be difficult to satisfy. So, it seems that for

(Continued on page 83)



SAVE THESE DATES



3RD YEAR RESIDENT PROGRAMS & WET LAB

Dear CSE 3rd-Year Resident Program Director and Coordinator,

We would like to invite you to review the upcoming 3rd-Year Ophthalmology Resident Programs and Wet Lab for 2018 in Fort Worth, Texas. The programs offer a unique educational opportunity for third-year residents by providing the chance to meet and exchange ideas with some of the most respected thought leaders in ophthalmology. The programs are designed to provide your residents with a state-of-the-art didactic and wet lab experience. The programs also serve as an opportunity for your residents to network with residents from other programs.

After reviewing the material, it is our hope that you will select and encourage your residents to attend one of these educational activities, which are CME accredited to ensure fair balance.

Best regards,
Program Directors



Third-Year Resident Wet Lab Programs 2018:

August 10-11
Fort Worth, TX

August 17-18
Fort Worth, TX

September 21-22
Fort Worth, TX

www.revophth.com/ResEdu2018

For more information: Visit the registration site above or
Email: dholmes@postgradhealthed.com • Call: Denette Holmes 866-627-0714

Courses are restricted to US-based 3rd-year residents enrolled in a US-based ophthalmology resident program and within their third year at the time of the course. There is no registration fee for these activities. Air, ground transportation in Fort Worth, hotel accommodations and modest meals will be provided through an educational scholarship for qualified participants.

Accreditation Statement - In support of improving patient care, this activity has been planned and implemented by Amedco and Postgraduate Healthcare Education, LLC. Amedco is jointly accredited by the American Council for Continuing Medical Education (ACCME), the Accreditation Council for Pharmacy Education (ACPE), and the American Nurses Credentialing Center (ANCC), to provide continuing education for the healthcare team.

Credit Designation Statement - These activities have been approved for AMA PRA Category 1 Credits™.

Endorsed by:

Review of Ophthalmology®

Jointly provided by:

PHE

AMEDCO

Supported by an independent medical education grant from:

Alcon

Angle-Closure: PIs vs. Cataract Surgery

Michelle Stephenson, Contributing Editor

Surgeons discuss the advantages and disadvantages of the two approaches.

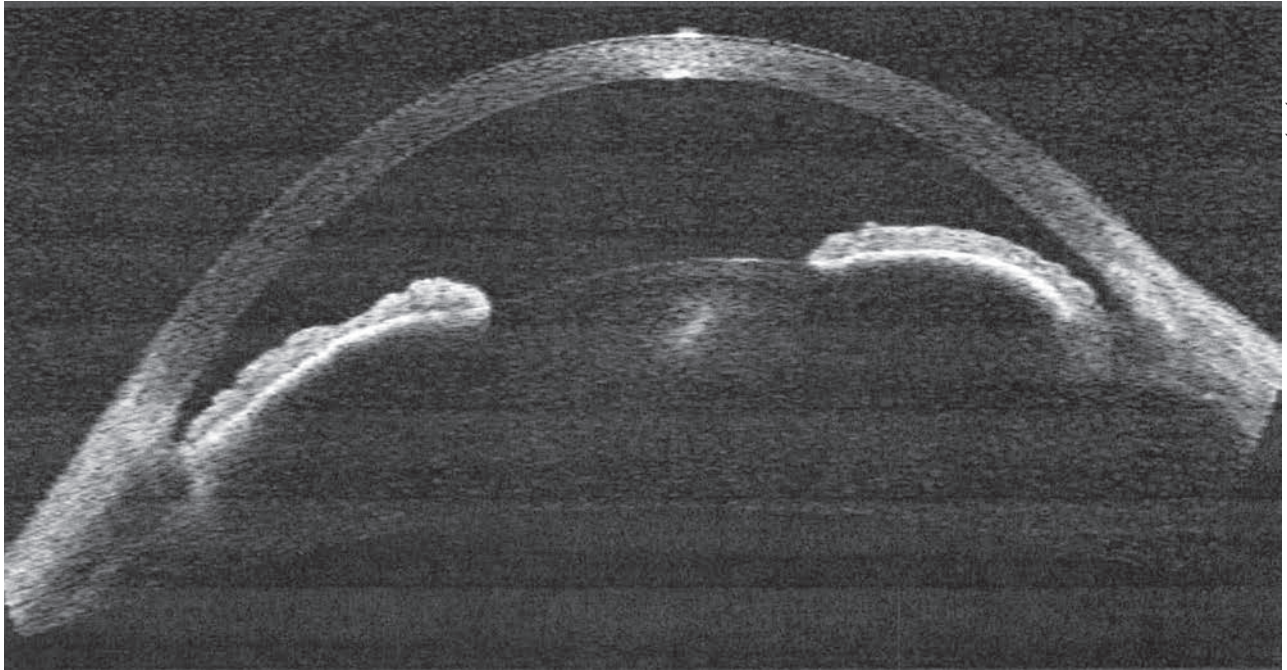
When faced with the problem of deciding between laser iridotomy and cataract surgery for angle-closure patients, a surgeon once quipped, “Do you want to treat the problem or cure it?” Indeed, due to cataract surgery’s excellent efficacy in these patients, some surgeons advocate it as a first-line treatment for angle-closure glaucoma. Other surgeons, however, believe that cataract surgery should be reserved for patients whose intraocular pressure cannot be controlled by laser iridotomy and medications. In this article, experts weigh the pros and cons of both options.

“These two treatments are not interchangeable. It’s easier to do an iridotomy, which takes a couple of minutes, versus a cataract operation, which is kind of a big deal,” says Reay Brown, MD, from Atlanta Ophthalmology Associates. “If a patient has angle-closure glaucoma and elevated pressure, cataract surgery is more effective than an iridotomy for lowering the pressure. However, when you perform a cataract procedure, the patient is exposed to significant risks, such as infection, bleeding and retinal detachment. In contrast, iridotomies have very little risk. So, if a pa-

tient has a narrow angle and normal pressures, I wouldn’t even consider cataract surgery. But, if a patient has elevated pressure that can’t be controlled with medical therapy, an iridotomy is unlikely to help them, while cataract surgery might help them a lot.”

Dr. Brown bases his treatment choice on the severity of the patient’s situation. “It’s weighing risk and benefit,” he says. “If a patient has a pressure of 22 mmHg without IOP-lowering medication, and angle closure, I would perform an iridotomy and possibly add a topical medication unless he or she has decreased vision from a cataract. You must match the risk you’re going to expose the patient to with the severity of the glaucoma. Patients who have optic nerve damage and significantly elevated pressures in the high 20s and even 30s on maximal medical therapy should undergo a trabeculectomy or cataract surgery. Cataract surgery is much safer than trabeculectomy, and in many cases can provide long-lasting pressure lowering.”

Dr. Brown explains that the most important difference between cataract surgery and iridotomy is that cataract surgery deepens the anterior chamber and opens the angle to



Peter Neiland, MD, PhD

Narrow angle in a nanophthalmic eye. Cataract surgery in narrow-angle patients creates an almost normal open-angle depth.

almost a normal open-angle depth, whereas an iridotomy does not deepen the angle or the anterior chamber significantly. “In cataract surgery, you are creating more space, which sort of converts a patient from angle closure to open angle,” he explains. “In other words, the mechanism of angle closure is at least partially counteracted by cataract surgery. An iridotomy will probably prevent an acute attack of angle closure, but there is still the risk of continuing pressure elevation and chronic angle closure. We may be able to completely eliminate these issues with cataract surgery.”

Dr. Brown notes that the data are overwhelmingly in favor of cataract surgery. “However, it’s important to emphasize that this is true in patients with a serious problem. It’s not for patients in whom the angle is just a little narrow,” he says.

Sanjay Asrani, MD, professor of ophthalmology at Duke University, and medical director of the Duke Eye Center of Cary, North Carolina, agrees that treatment depends

“An iridotomy will probably prevent an acute attack of angle closure, but there’s still the risk of continuing pressure elevation and chronic angle closure.”

—Reay Brown, MD

on whether the patient has acute or chronic narrow-angle glaucoma. “Let’s start with acute narrow-angle glaucoma,” he says. “In these patients, there is no choice but to proceed with the laser iridotomy as a temporary procedure to normalize the IOP levels and then proceed with cataract surgery at a later time. The surgeon is basically just performing a laser iridotomy so that the pressure comes down and the in-

flammation is controlled quickly, so that elective cataract surgery can be performed in the near future. ‘Near future’ should be emphasized.”

In comparison, patients who have a narrow angle, raised pressure and a normal optic nerve are considered to be pre-glaucoma. “In such cases, if the lens is clear, the treatment would be laser iridotomy and controlling the pressure with eye drops and managing the glaucoma medically,” Dr. Asrani explains. “I do not proceed with cataract surgery in these cases because I may be able to control the pressure medically after a laser iridotomy, and the patient’s lens is clear, so he or she doesn’t require cataract extraction.”

In patients with a narrow angle, optic nerve cupping, and a lens that’s clear or doesn’t have a visually significant cataract, Dr. Asrani will try performing an iridotomy and controlling the pressure with eye drops. “If I find that the target pressure is not achieved with the use of maximum tolerated medical therapy and/or the glaucoma is worsening with

the maximum tolerated medical therapy, I will proceed with cataract surgery,” he adds.

Dr. Asrani recommends proceeding with cataract surgery in patients in whom the angle is narrow, the pressure is high, the optic nerve is cupped and the cataract is visually significant, meaning that the patient is already having symptoms of a cataract. “This should help the problem. However, I do not tell patients that cataract surgery is the solution to their problems, only because in many cases the pressure stays high after cataract extraction,” he says. “The reason is that the trabecular meshwork has already been damaged and compromised. Removing the cataract reduces the pressure somewhat, but doesn’t bring the pressure down as far as you would expect. Some doctors advocate removing the cataract when the pressure starts rising and the angle is narrow, to prevent damaging the trabecular meshwork. The concern is that cataract surgery is not without complications. So, you take a person who is 20/20 with high pressure and perform cataract surgery. This is a risk I typically don’t take, unless, once again, I have not been able to control the pressure, the glaucoma is getting worse, or the cataract is visually significant.”

The EAGLE Study

Surgeons agree that cataract surgery should be considered in patients with a visually significant cataract, but the EAGLE (Effectiveness of early lens extraction with intraocular lens implantation for the treatment of primary angle-closure glaucoma) Study found clear-lens extraction is also efficacious and cost-effective.

In the EAGLE Study, between January 2009 and December 2011 researchers enrolled patients from 30 hospitals in five countries.¹ Patients were randomized to undergo clear-lens extraction or laser peripheral iridotomy and topical medical treatment. Patients were eligible to participate in the study if they were 50 years of age or older, didn’t have cataracts, and had newly diagnosed primary angle closure with an intraocular pressure of 30 mmHg or greater, or primary angle-closure glaucoma.

The study included 419 participants: 155 had primary angle closure and 263 had primary angle-closure glaucoma. Of these 419 patients, 208 underwent clear-lens extraction and 211 were assigned to standard care. Eighty-four percent of patients (351) had complete data on health status, and 87 percent (366) had complete data on intraocular pressure.

The mean health status score (0.87), assessed with the European Quality of Life-5 Dimensions question-



SERVICE SOLUTIONS

A CONFIDENT DIAGNOSIS STARTS WITH YOUR EQUIPMENT.

Ophthalmic equipment wears down over time. Lombart’s dedicated, factory-trained technicians are fully equipped with the latest calibration and repair tools to help restore your instruments to like-new condition.

WE OFFER:

Lane Tune-Ups

Phoropter Cleaning

Comprehensive Preventative Maintenance Programs

Chair Upholstery Services

Equipment Repairs

Practice Move Services

and more!

FOR ADDITIONAL INFORMATION, GO TO:
LOMBARTINSTRUMENT.COM/SERVICESPECIALS

WHEN YOU THINK OPHTHALMIC INSTRUMENTS,
THINK LOMBART



Ongoing Support



Reliable Service

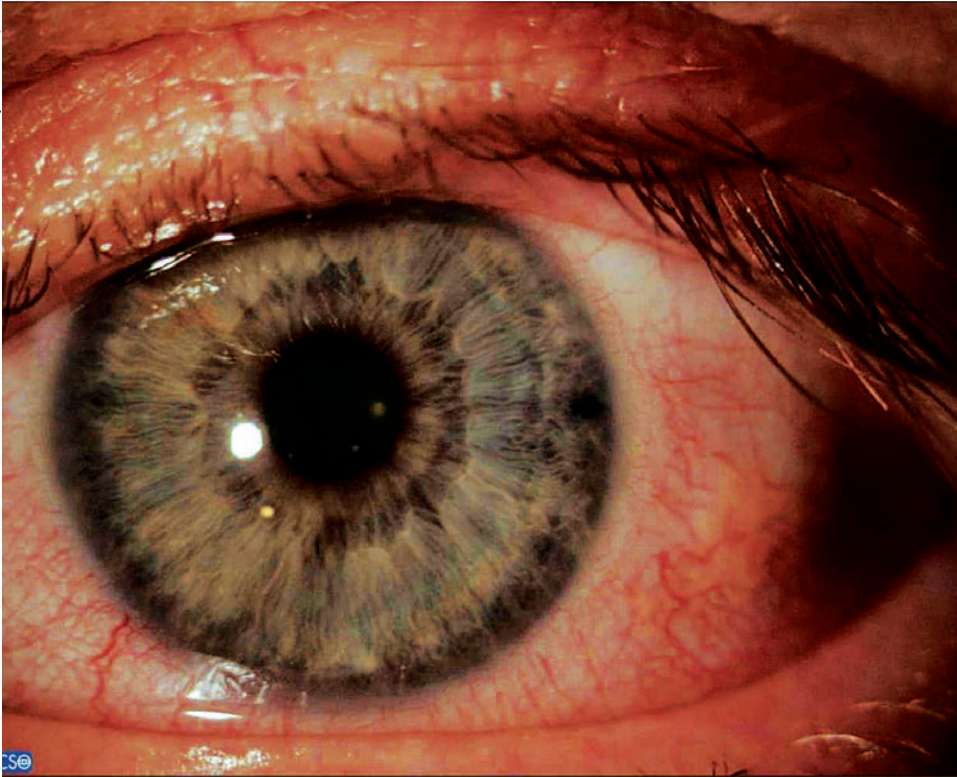


Nationwide Coverage

800.LOMBART

WWW.LOMBARTINSTRUMENT.COM

2018.02-PRINTAD1-04



Placing a laser peripheral iridotomy temporally rather than superiorly appears to reduce postop dysphotopsias and cause less pain during surgery.

naire, was 0.052 higher (95% CI 0.015–0.088, $p=0.005$) and mean intraocular pressure (16.6 mmHg) was 1.18 mmHg lower after clear-lens extraction than after iridotomy and medical treatment.

The incremental cost-effectiveness ratio was \$19,721.92 for initial lens extraction versus standard care. One patient who underwent clear-lens extraction and three who received iridotomy and medical treatment experienced irreversible loss of vision. No patients had serious adverse events.

This study found that clear-lens extraction was more effective and more cost-effective than laser peripheral iridotomy and should be considered as an option for first-line treatment.

David Friedman, MD, PhD, Alfred Sommer Professor of Ophthalmology at Johns Hopkins University's Wilmer Eye Institute and

director of Wilmer's Dana Center for Preventive Ophthalmology, believes that, based on the results of the EAGLE Study, "it's perfectly reasonable to recommend early cataract extraction for patients who have angle-closure glaucoma or angle closure and elevated IOP. It's really a shared decision-making process with the patient."

Dr. Friedman goes on to explain that recommendations and treatment choices depend on defining the population. "For people who have very high eye pressure—which was defined in the EAGLE study as 30 mmHg or higher—and angle closure, or who have angle-closure glaucoma and somewhat elevated pressure, I think the doctor should offer early lens extraction, because those people were shown to have better outcomes with early lens extraction," he says. "They are typically older and are going to need

cataract surgery in the next decade in the majority of cases. By operating earlier, the surgeon is just moving the process forward for the patient, removing the need for medications in many cases, and reducing the risk of further surgery to control IOP. The EAGLE Study showed that, if the lens was removed, there were far fewer additional surgeries needed, fewer medications and better control of pressure. Additionally, patients reported slightly better quality of life. I believe that if you look at the road the patient will be going down in the future, he or she will need cataract surgery, so it makes sense to take the lens out early.

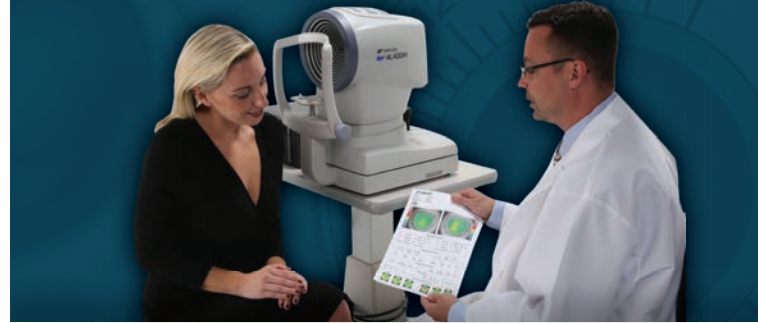However, if someone is just an angle-closure suspect and his or her IOP is normal, I would never take the lens out. I would always consider iridotomy. Lens extraction is not indicated in those cases."

Insurance Reimbursement

Dr. Asrani notes that he is "a pro-iridotomy guy." He says that, in the EAGLE Study, the investigators included patients with high pressures and no glaucoma damage. "This means that the pressures had not been high for very long," he explains. "In these patients, when you remove the cataract, the pressure will come down because the trabecular meshwork has not been damaged for a long time.

"The issue is that the investigators took out cataracts when they were not visually significant," he adds. Here, in our insurance scenario, it is not easy to get approval for clear-

ASCRS EXCLUSIVE PROMOTIONS



LOMBART INVENTORY CLEAR OUT

DEMO TOPCON ALADDIN 2.0 BIOMETER WITH TOPOGRAPHER

\$17,495

-90 Day Warranty

- Includes Delivery & Training

ONLY 10 UNITS AVAILABLE

FEATURES:

- Axial Length
- Keratometry
- Anterior Chamber Depth
- White-to-White
- Pupilometry & Angle Kappa
- Full Function Corneal Topography
- Corneal Wavefront Analysis

Includes 5 Standard IOL

Calculations Including:
SRK II, SRK/T, HOFFER Q,
HOLLADAY 1, and HAIGIS

Includes 2 Post-Refractive

Calculations Including:
Camellin Calossi and Shammass

FOR MORE INFORMATION, VISIT:
LOMBARTINSTRUMENT.COM/ASCRS

WHEN YOU THINK OPHTHALMIC INSTRUMENTS,
THINK LOMBART



Ongoing Support



Reliable Service



Nationwide Coverage

800.LOMBART

WWW.LOMBARTINSTRUMENT.COM

2018.03-PRINTAD2-05

lens extraction just for the sake of lowering pressure, especially if you haven't tried maximal medical therapy and/or laser iridotomy, or proven that the glaucoma is getting worse despite all your efforts. Then, the insurance carriers might cover cataract surgery for glaucoma, but, otherwise, it's not an easy task to get approval for clear-lens extraction for narrow angles."

Dr. Asrani encourages surgeons to strongly consider performing simultaneous glaucoma surgery and cataract surgery if the patient has significant cupping or if glaucoma has damaged the optic nerve. "This is especially true if there is cupping that involves the superior neuroretinal rim," he says.

According to Dr. Asrani, cataract surgery should be reserved for those whose pressure isn't controlled with maximum tolerated medical therapy, or for those whose glaucoma is getting worse. "If their glaucoma is getting worse or their pressure is not coming under control under their maximum tolerated medical therapy, then, even if the cataract is not visually significant, I will go ahead and get insurance approval and proceed with cataract surgery," he says.

Dr. Friedman agrees that there are some issues with reimbursement. "The volumes have been relatively small, so I'm not sure how exactly to code for these things," he avers. "I think this is going to have to come up in coding discussions, but I'm not sure where that process is on the national level."

In younger patients, Dr. Friedman still recommends offering cataract surgery as an option. "In the EAGLE Study, the minimum age was 50 to avoid inducing presbyopia," he recalls. "This study also excluded certain people, such as those with extremely shallow anterior chambers, because these people are at increased risk of complications during cataract surgery. Cataract surgery should be used to treat angle-closure glaucoma in patients in whom lens extraction is likely to be very straightforward with very few complications. And in the EAGLE Study, there was a 1-percent posterior capsule rupture rate, despite the fact that lens extraction was performed by many surgeons over a very large number of hospitals. That's the basis on which I'm making my decision. The patient is part of the discussion and should be offered cataract surgery." **REVIEW**

1. Azuara-Blanco A, Burr J, Ramsay C, et al, for the EAGLE study group. Effectiveness of early lens extraction for the treatment of primary angle-closure glaucoma: A randomized controlled trial. *Lancet* 2016;388:1389-1397.

Suggested Reading

1. Brown RH, Zhong L, Lynch, MG. Lens-based glaucoma surgery: Using cataract surgery to reduce intraocular pressure. *J Cataract Refract Surg* 2014;40:1255-1262.



Are You Investment-Ready? A PE Checklist

Kristine Brennan, Senior Associate Editor

If you want to test the PE waters, make sure your practice is shipshape.

As the costs of running a medical practice go up and reimbursements go down, private equity investors can be an attractive option for ophthalmology practice owners. Private equity groups are certainly attracted to them right now, and seemingly flush with cash in exchange for majority ownership. While signing a PE agreement can mean a personal financial windfall, more freedom from bureaucratic tasks and a clarified transition plan for late-career surgeons, it also usually spells loss of control of one's day-to-day practice life. Private equity has already penetrated dermatology and dentistry, and is now reaching out to ophthalmology. Here, experts discuss what PE looks for when deciding where to invest its dollars, and offer some insights on the PE trend and alternative ways to reap some of PE's practice-growing benefits without fully committing to the model.

Ophthalmology's Appeal

Matt Owens, JD, a partner at Arnold & Porter in Washington, D.C., represents medical practices negotiating private equity deals. He thinks that ophthalmology practices are interesting to private equity investors for a variety of reasons. "You've

got a large baby-boomer population that's starting to need more ophthalmic care," he says. "Relatively few doctors are entering ophthalmology, compared to those who are retiring. There also seems to be a general view that the younger doctors entering ophthalmology aren't as driven to own and run their own practices; they're more attracted to a different work/life balance than in the past."

Private equity's ability to consolidate the strengths of multiple practices and its centralized management can give parties entering into such agreements greater bargaining power to negotiate better rates for products, services and covered lives with vendors and insurers. "Ophthalmology is an expensive specialty," says Paul Koch, MD, founder and medical director of Koch Eye Associates in Warwick, Rhode Island. The Boston-based private equity group Candescant Partners purchased Koch Eye Centers in 2011, making it part of Claris Vision, and then recently resold it to CV Global Holdings. "Doctors today may be thinking, 'How much support am I going to have for the things I need to build my practice? I can't get a piece of equipment or offer a new procedure and amortize it that fast on my own.' Outside investors can help with

that,” he says.

The comparative stability of health care service providers as an investment, versus real estate, for example, has lured would-be stakeholders to ophthalmology before. Professional medical management companies (PMMCs) emerged in the late 1990s and wrought havoc on many ophthalmologists who accepted stocks in exchange for control of their practices, when the practices went public and the promised payouts failed to

materialize. A rebounding economy after the recession of 2007 to 2009 has again given rise to private investors looking for places to put their funds to use. “It has come back up in the last couple of years because private equity companies are looking for other ways to invest, because they’ve raised all this money and they have to put it somewhere,” says Tom Harbin, MD, MBA, an ophthalmologist and ophthalmic business expert from Atlanta. “Their investors expect them to grow their dollars and make a profit. So that’s part of the reason that this has suddenly come back to the fore after many years.”

How It Works

Private equity groups will pay owner/doctors a multiple of their practice’s strategic value to gain control

of it, in order to increase its revenues for eventual resale. The practice’s strategic value differs from its market value in that it’s based on projected future earnings, which is what surgeons are really selling to PE. The valuation is a multiple of a practice’s EBITDA (Earnings Before Interest, Taxes, Depreciation and Amortization). “It really comes down to the practice’s EBITDA,” says Mr. Owens. “In my experience, the multiple is in the range of five to the low double digits—generally seven to 10, but up to the teens for some practices.”

“Private equity will agree to purchase you for some number, and they will ask you to take most of it, usually about 60 percent, in cash. They’ll ask you to leave the rest behind as equity to help fund the rest of their activities,” Dr. Koch explains. “They will then finance the growth of the or-

ganization using the residual equity, which may or may not give returns to the doctors who leave it behind.

“They think of things not in terms of long-term growth, but in very short-term time increments,” Dr. Koch continues. “Whereas we might plan to buy some new equipment or hire new people with an eye to how things will look 10 years from now, PE will make decisions based on how things will look 90 days from now. In order to eventually sell to somebody else for a lot of money, they have to be able to show quarterly increases in earnings to demonstrate that they’ve got a model that they’ve managed well so that it’s attractive to other buyers.”

The time frame from PE purchase to the secondary sale varies, and the shorter the time horizon, the more sweeping and rapid the changes to a



Paul Koch, MD

Koch Eye Associates, based in Warwick, Rhode Island, has been through a sale to private-equity investors, who made administrative changes to the practice to increase revenues in preparation for a secondary sale. The resale, which took place recently, was to a group that has a pattern of buying and holding its investments.

practice tend to be. “A span of seven years or so to the flip is not unheard of, because there are those groups that buy and then hold on longer,” says Mr. Owens. “But it’s still private equity, and doctors in the practice still look forward to that second bite at the apple.”

Understand PE’s Goal

Understanding how PE works is key to understanding a particular group’s goals for your practice—and making sure you’re comfortable helping to facilitate them. Dr. Koch says that the time horizon is typically shorter than seven years, and practices should make sure they understand what any prospective PE investors expect to accomplish. “First, determine what they would like to achieve with the acquisition,” he advises. “If the PE people can’t negotiate a situation where they’re going to make a lot of money, they’re not going to make a deal. They want to make their money in a time frame. They want to buy the practice; they want to run up profits by 250 percent in a short time period. For a PE firm, three years would be a nice turnover; five years would be a satisfactory one; and if it goes to seven years, that’s a long-term deal—and many PE groups don’t like that.”

With the understanding that private equity groups are tapping into ophthalmology to make money for themselves at top of mind, some surgeons are joining forces with them and also benefiting. How can an individual practice make itself stand out to private equity and insure a favorable valuation?

ASC and Receive

Geographic reach and access to an ambulatory surgery center are two features that PE prizes. Being an established presence in your cor-

ner of the world is critical to attracting private equity. PE looks first for “platform” practices: These are practices that are already well regarded in their communities that pull from a good-sized geographic area, ideally with an ambulatory surgery center.

“We were a platform practice: We were a large, well-run multispecialty practice with a very strong presence in the community. If they wanted to get into ophthalmology, we were a very prime organization for PE to deal with. So when our investment banker approached the investors, we fit the profile of an acquisition pretty much to a ‘T.’ ”

—Paul Koch, MD

According to Dr. Koch, Koch Eye Associates already ticked off those boxes when they were looking for the best way to continue growing. “We looked at all the usual options. We were such a large entity in our market that none of those things were feasible. My brother, the business manager, finally asked the question, ‘If we were a widget factory what would we do?’ Well, we would hire

an investment banker to start with, so we did that, made a nice portfolio and shopped it around. That’s how we got involved in the private equity market. We were a platform practice: We were a large, well-run multispecialty practice with a very strong presence in the community. If they wanted to get into ophthalmology, we were a very prime organization for PE to deal with. So when our investment banker approached the investors, we fit the profile of an acquisition pretty much to a ‘T,’ ” he says.

“Private equity firms will buy a platform practice in an area with practices nearby, either practices that can feed referrals into the platform practice or practices that will add value,” says Dr. Harbin. “The goal of this, from the time that the first set of deals comes together, is to keep growing and then sell. It’s been done in a number of other situations, like dentistry, where after they build up a platform practice, they sell.”

Are small or solo practices shut out of the PE trend? A smaller practice in a region where PE is active in ophthalmology could attract such investors as a “bolt-on”—a practice purchased and then subsumed into a larger platform practice that they’ve already acquired. PE investors can assemble large regional practices by bolting multiple small offices onto their platform practice. “Practices of all sizes can attract a private-equity deal if that’s what they want,” says Mr. Owens. “It really depends on their EBITDA, and whether these kinds of transactions are happening in their part of the country. There are still a lot of geographic areas where private equity really hasn’t taken hold, though, and if you’re located in one of them, you’re pretty much out in the cold for now.”

Mind Your Business

A PE deal will leverage the ex-

Enhance your Practice with Physician-formulated Ocular Supplements

Introducing our premium line of Certified Vegan,
gluten-free, non-GMO ocular supplements*



— PROTECT —

Macutene® Protect provides 25mg of lutein and 5mg of zeaxanthin (RR and meso-zeaxanthin) at the exact 5:1 ratio found in nature

— NOURISH —

Pristene® is based on clinical trials and formulated by leading eye care professionals for healthy tear production*

Make it available for your patients through your practice

Learn more about our products and visit eyecheckpro.com or call [1-855-622-8836](tel:1-855-622-8836)

New Business model: No inventory • Autoships directly to patients

eyeCheck
Integrated Visual Health

©2018 Eyecheck® LLC. All rights reserved.

*These statements have not been evaluated by the Food and Drug Administration. These products are not intended to diagnose, treat, cure or prevent any disease.

Macutene® Protect and Pristene® are intended for healthy adults, 18 years of age or older. Do not take either product if you are pregnant or nursing. Please consult with a licensed, qualified, healthcare professional before using Macutene® Protect, Pristene® or any dietary supplement product. EC009

expertise of outside management to spur revenue growth, but investors aren't eager to pay good money to rehabilitate problem practices. Just as you should carefully vet any PE groups that express an interest in your practice, you should expect intense scrutiny from the other side of the negotiating table. "Besides the obvious—which would be to strive to be a platform practice with good community presence and access to a surgery center—I would say that practices need to make sure that they are in good compliance, because no investor wants to come in and discover that a practice that appears fiscally sound actually isn't all that it seems because it's not billing properly, for example," says Mr. Owens. Specifically, PE groups will shine a spotlight on your practice's billing to make sure that your office's CPT codes align with procedures performed and to make sure that no upcoding and unbundling are taking place. They'll also examine your legal exposures, including malpractice. Practices that are interested in attracting private equity should audit their finances, and make sure that they have secure EHR if possible.

"A well-run practice of any type would be attractive to PE investors," says Dr. Koch. "They want to find a well-run practice that they can influence to generate greater profits for the eventual flip, or 'event.' I know people in solo practices using paper charts that have been acquired. I know of very sophisticated practices that have been paperless for years that have been acquired. They can deal with all kinds of models, just as long as the numbers add up for them."

Mix it up

In addition to access to an ASC, any onsite optical dispensaries and cash procedures that add to the mix

Alternatives to Private Equity

With or without private equity, consolidation is increasing in ophthalmology and all of health care. For some doctors, private equity asks them to cede too much control over the practices they've built for years. Or they may remember the bad old days of the first go-round of private equity and fear having to buy back their practices under unfavorable conditions should things "go south," as described by Tom Harbin, an ophthalmologist and ophthalmic business expert from Atlanta.

One alternative model is the Managed Services Organization. MSOs take over the administrative components of a practice such as HIPAA compliance, billing, professional certifications, and negotiating the best prices for supplies and professional services. Entering an agreement with an MSO doesn't mean that it owns your practice, although some agreements do require you to sell your tangible assets to the MSO, which leases them back to you.

Another option: Practices can choose to stay independent while still pooling their resources, reputation and bargaining power by forming their own practice mergers. When neither the PE nor the MSO model felt quite right, the leaders of seven established ophthalmic practices formed Vantage EyeCare, LLC in January 2018 to comprise what they say is the largest private ophthalmology group in Pennsylvania, New Jersey and Delaware.

"We like to think of ourselves as the anti-PE," explains Julia Lee, JD, chief executive officer of Vantage EyeCare, adding that the merger sprung out of an ongoing conversation between five—then eventually seven—established practices that had been talking to private equity groups. "They went through the process to a point before deciding that they wanted an alternative," she says. "We're a single, large, consolidated practice group made up of previously standalone practices that function as divisions within our new group. There's a lot of support being provided at the corporate level, similar to an MSO, but we are a little different. Instead of selling to a private equity firm, all of these groups came together to realize the same size, scale and related advantages while retaining ownership and control. We are hoping to achieve the same things in terms of better-coordinated care and making sure that we cover the full scope of services. But the biggest difference, obviously, is remaining physician-owned and physician-led.

"The individual practice leaders are very committed to fair succession planning," Ms. Lee continues. "The younger owners wanted to make sure there were protections in place, so in our operating agreement we've actually carved out provisions that give sale to private equity and other third parties very special, heightened voting requirements. For us to sell to private equity, for example, it would take close to a unanimous vote. Then there are additional provisions giving divisions the ability to exit if they don't want to sell to private equity."

While there is a high bar to vote for sale to private equity, Ms. Lee acknowledges that the new practice group has enhanced its attractiveness to PE investors through their merger. "When we brought our group together, there was a recognition that if we were attractive to a private equity groups individually, then we were going to be even more attractive as this large, consolidated group, because we've essentially done the work for them by bringing all of these practices together," she notes.

—K.B.

in your practice will make PE groups take notice. Out-of-pocket products and services like premium IOLs, LASIK, LipiFlow treatments, Botox, peels and facial fillers will augment the revenue stream created by reimbursed medical services and add to the picture of a healthy practice.

As platforms absorb smaller prac-

tics that enter PE agreements, the opportunity to increase the number of different subspecialties within a practice arises organically. If your smaller practice doesn't already feature more than one subspecialty, another way of diversifying your practice and increasing its allure for PE would be to acquire or merge with

another like-minded smaller practice to increase both organizations' reach and scope.

"There are other ways to do it," avers Mr. Owens. "Some platform-type practices may want to make themselves more attractive to private equity by making acquisitions of smaller bolt-on-type practices by themselves first, but others will find that the administrative and logistical work that involves may be best left to outside investors. So smaller practices may want to see if larger platforms will purchase them, or they might form groups with similarly-sized practices to increase their attractiveness."

(For more on alternatives to PE investment, see sidebar, facing page.)

Be Alert for Change

Dr. Koch's perspective is informed by Koch Eye's positive experience with private equity, but he now believes that the model's heyday has already come and gone. "We were among the first to do it, and I think we were also among the first out of it," he states. "And I think the whole trend of private equity has already come and gone. I think that the deals that are going to be helpful for everybody—a win for the PE, a win for the practice and a win for the patients—have come and gone. Private equity people are specialists in making money. We are specialists in taking care of patients."

Dr. Harbin emphasizes that the PE model could change abruptly, leaving surgeons looking for other ways to attract capital. "People need to consider the question of whether this model will survive," he says. "I remember the days of private equity swallowing up a bunch of ophthalmology practices, when things suddenly went south and a lot of surgeons had to buy their practices back. For those of us with some experience and some white

hair, those are not pleasant memories. I happen to think that the model today has a better chance of surviving because a lot more cash is going into it, but there's always the chance that it won't. People need to keep that in mind when entertaining these deals."

Dr. Koch says that the secondary sale of Koch Eye Associates from Candescant Partners to present owner CV Global Holdings conformed to a newer model. "When our people were ready to sell us, they were very good about giving us some voice in who would purchase us from them. We were next purchased by a private holding company, a group that has been buying businesses for many years and has never sold one. Every business they buy is a buy-and-hold. Unlike PE, which came to us asking for 90-day and 180-day plans, we've been asked to generate five-, 10- and 30-year plans for our business. In addition, young doctors are welcome to invest in the practice, and their investment is guaranteed at the multiple of sale. I think that is going to be the model that will be preferred going forward, and I think the private-equity model is probably one that is going to start petering out pretty soon. I think that doctors generally want to see their practices operate on a long-term basis, rather than on a series of short-term deadlines," he says.

Whether or not the current model is headed for obsolescence, right now PE deals continue. For ophthalmologists who are open to working collaboratively with the new management that accompanies a sale to private equity, their practices can grow leaner and more remunerative, with a payout up front and a chance for more upon resale. By taking a few steps to make your practice more investment-ready, you can encourage PE groups to come knocking on your door. **REVIEW**

Optimize space and functionality.



Affordable, space-saving chair & stand solutions.

Small footprint
41.2" x 34.2"

S4OPTIK

www.s4optik.com | 888-224-6012

Sensible equipment. Well made, well priced.
For today's modern office.



How to Manage Intraocular Lymphoma

What to look for diagnostically, and which therapies to pursue, when you're faced with this potentially aggressive malignancy.

Lynn Hassman, MD, PhD, and Akbar Shakoor, MD, Salt Lake City

Intraocular lymphoma is a rare entity, and it may masquerade as ocular inflammatory disease, often partially responding to corticosteroid treatment. As a result, diagnosis and treatment can be delayed for years with a significant impact on both vision and mortality. Therefore, awareness of this disease and the subtleties of its presentation, along with clinical suspicion, is critical. In this article, we'll share diagnostic tips and treatment strategies for this insidious type of cancer.

Definitions and Classifications

Intraocular lymphoma is categorized as vitreoretinal or uveal based on the site involved, with the latter subdivided into choroidal, ciliary body or iris. In addition, it's classified as either primary, when only the eye is involved, or secondary when it's associated with pre-existing systemic or central nervous system lymphomas. Primary vitreoretinal lymphoma (PVRL) is closely related to primary central nervous system lymphoma (PCNSL), and is an aggressive malignancy. In contrast, primary uveal lymphomas

are more typically indolent, similar to ocular adnexal or orbital lymphomas in terms of aggressiveness.

The predilection of lymphocytes for cancer lies in the essence of their function. Early in the development of both T and B lymphocytes, the genes responsible for antigen recognition undergo rearrangements, insertions and deletions, resulting in an enormous repertoire of immune cells. Upon antigen recognition, B cells undergo rapid proliferation and additional somatic hypermutation of immunoglobulin and non-immunoglobulin genes, as well as double-stranded breaks and recombination during class switching, in order to produce highly specific antibodies. Concurrently, normal cellular checks on mutagenesis, including DNA-damage responses and apoptosis, are down-regulated, and cellular differentiation is transcriptionally repressed.

These processes, critical to the immune system's ability to eliminate pathogens, also place T and B-lymphocytes at risk for the chromosomal translocations and other mutations that characterize lymphomas. These

processes typically occur within germinal centers, and can give rise to the likes of diffuse large B cell lymphoma (DLBCL), the subtype that is most commonly found in PVRL. Similar processes occur outside the germinal centers at sites of repeated pathogen exposure, potentially giving rise to marginal zone (MZ) or mucosal-associated lymphoid tissue (MALT) lymphomas. Specifically, repeated antigen stimulation associated with orbital infection by *Chlamydia pistaccii* or Sjögren's syndrome can give rise to extranodal marginal zone lymphomas (EZML)^{1,2} more typical of orbital lymphoma, as well as many uveal lymphomas.

I. PVRL

Following are the salient features of primary vitreoretinal lymphoma:

- **Clinical presentation.** PVRL presents as vitritis without retinal involvement in middle-aged or elderly patients, and rarely in younger patients. It has no clear racial or gender predilection.³ The presentation and clinical examination findings can vary, but patients most commonly com-

COMBO
COMBINE WITH OUR
UNIQUE STAND

plain of blurred vision and floaters. There is usually moderate vitreous cell, appearing as large homogeneous single cells, and haze, as well as retinal pigment epithelium pigmentary changes, with a quiet anterior segment. There are obvious yellow sub-retinal infiltrates in half of patients which can sometimes lead to solid RPE detachments. Focal nodular projections from the RPE or sub-RPE infiltrates can be seen on optical coherence tomography in most eyes and fluorescein angiography may reveal hypofluorescent focal lesions. Macular edema and retinal vascular leakage are rare findings, and the optic nerve is variably involved. Although the anterior segment is often quiet, iritis and keratic precipitates can be seen.⁴ There are myriad atypical findings, including retinal vasculitis, inflammatory glaucoma, neurotrophic keratopathy, choroidal detachment, retinal degeneration, hyphema, hypopyon, retinal vein occlusion and optic disc edema.⁵

• **T cell primary vitreoretinal lymphoma.** T cell PVRL presents with anterior uveitis more commonly than B cell PVRL and is more likely to have invaded the iris. CNS involvement occurs at rates similar to B-PVRL, but the presence of systemic lymphoma is more common. The tumors are generally less responsive to methotrexate, though this agent can be used alongside other chemotherapies; it results in less-common remission than in B-PVRL. Mortality is variable, but generally survival is less than one year.⁶

Adult T cell leukemia/lymphoma (ATL), caused by the human T-lymphotrophic virus type 1 (HTLV-1), is a rare cause of intraocular lymphoma associated with cutaneous and CNS lymphoma. The HTLV-1 virus is endemic in Japan, the Caribbean and Central Africa; it causes anterior, intermediate or panuveitis, as well as a spastic paresis and myopathy. ATL is

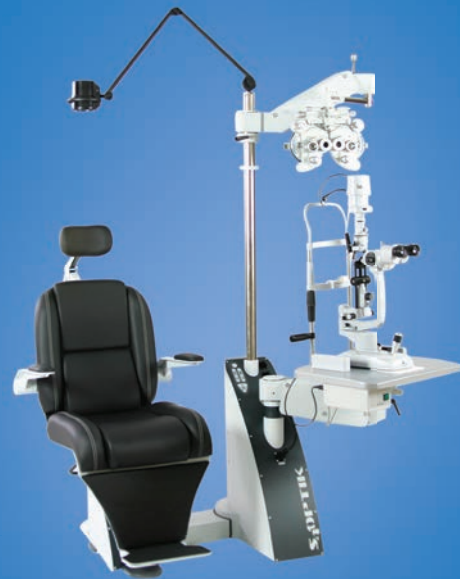rare among HTLV-1 carriers, presenting in less than 5 percent of patients in the fourth to sixth decades of life. It's characterized by deep retinal infiltrates starting in the mid-periphery and progressing posteriorly, which distinguish this entity from HTLV-1 uveitis.⁷ Vasculitis and symptomatic vitritis, as well as leopard spotting on FA, can be seen. Beyond the retina and vitreous, corneal, conjunctival and orbital tumor involvement have been described.⁸ ATL presents as one of four subtypes along a transformation continuum, from benign to aggressive, with the latter resistant to chemotherapy and associated with mortality within four to six months.⁸

Diagnosis

Diagnosis of intraocular lymphoma was historically made by the histologic finding of atypical lymphoid cells with large irregular nuclei and prominent nucleoli isolated from the vitreous.

These studies were augmented with immunohistochemical staining primarily for B and T lymphocyte markers. Modern methodology involves flow cytometry, which allows the simultaneous assessment of multiple surface markers to profile the sample more completely. Additionally, polymerase chain reaction can be used to detect clonal rearrangements in immunoglobulin genes or the T cell receptor. Finally, analysis of extracellular interleukin (IL)-10 and the ratio of IL-10 to IL-6 via aqueous or vitreous tap has been used to indicate lymphoma with sensitivities of 0.80 to 0.90 and specificities of 0.90 to 1.00.^{4,9} IL-10 is a regulatory cytokine more strongly associated with anti-tumor immune responses, whereas IL-6 is central to most infectious and inflammatory uveitic responses. While the relative elevation in these cytokines is often a good discriminator of neoplastic versus inflammatory processes, it is not an absolute diagnostic indicator,

Effortless instrument positioning



Advanced ergonomics



S4OPTIK

www.s4optik.com | 888-224-6012

Sensible equipment. Well made, well priced.
For today's modern office.

Table 1. Characteristics of Intraocular Lymphomas^{3,18,19,24}

	PVRL	Choroidal lymphoma	Iris/ciliary body lymphoma
Mean Age (range)	60s (40s to 80s)	50s (30s to 80s)	58 (20s to 70s)
Symptoms	floaters, blurry vision	blurry vision, or no symptoms	blurry vision, eye pain
Laterality	bilateral up to 50%	bilateral up to 50%	usually unilateral
Anterior Exam	usually quiet	+/- anterior uveitis, +/- infiltration of iris or ciliary body, rubeosis, angle closure	anterior uveitis, iris lesions, conjunctival salmon patch
Vitreous	large cells and haze	mild or no signs	mild-moderate
Fundus	RPE changes, subretinal infiltrates	multifocal creamy white choroidal lesions	minimal, +/-choroidal involvement
Additional Findings	—	ocular/adnexal extension, +/- ocular hypertension	ocular hypertension, rubeosis
OCT	tumor above Bruch's; focal nodular RPE projections, sub-RPE infiltrate	tumor below Bruch's (EDI-OCT); RPE and outer retinal reactive changes, alteration in retinal contour	anterior segment iris involvement, iridocorneal touch, ciliary body infiltration
FA	hypofluorescent focal lesions	early hypofluorescence and late hyperfluorescence	vascular supply to iris tumor
Diagnostic Testing	vitreous, retina or chorioretinal biopsy	transvitreal or transcleral choroidal biopsy	tissue biopsy

as demonstrated by several researchers, including Esen Akpek, MD, and her group at the Wilmer Eye Institute.¹⁰

Undiluted samples as large as 4.5 ml can be obtained using a standard three-port, 20- to 25-gauge vitrectomy with the infusion turned off so as not to dilute the specimen. Air or perfluoron infusion can be used during the procedure to prevent hypotony while maintaining an undiluted specimen. The diagnostic yield is reported to be between 10 and 75 percent using this technique.¹¹ (This variability is likely a due to variations in specimen processing.) Alternatively, vitreous samples can be obtained in the office via a vitreous tap, or with a 23-ga. handheld portable vitrectomy unit (Intretractor, Insight Instruments, Stuart, Florida),¹² though this approach is limited by the smaller sample size and hasn't been validated in cases of

suspected intraocular lymphoma.

The challenges to cytologic diagnosis of PVRL from vitreous samples include the large infiltration of reactive T lymphocytes and macrophages, which can outnumber lymphoma cells, as well as the fragility of the lymphoma cells. Intuitively, it might seem that gentle aspiration through a large-bore needle or larger-gauge vitrector may preserve lymphoma cell integrity better than smaller-gauge vitrectomy, but the superiority of one technique hasn't been conclusively demonstrated.¹¹ Instead, immediate addition of cell culture media supplemented with fetal calf serum, cold transport and rapid processing is recommended to optimize the diagnostic yield.¹³ Importantly, inclusion of multiple parameters (histology, flow cytometry, cytokine and PCR analysis) will increase the diagnostic yield.

Preoperative consultation with the

pathologist is also critical. Ideally, specimens would be obtained before treatment with corticosteroids; but these cases are often only suspected after an inadequate or transient steroid response. Despite these efforts, repeat vitrectomy or retinal/chorioretinal biopsy may ultimately be required.

Approximately 65 to 90 percent of patients with PVRL will have PCNSL at presentation, or will eventually develop it.³ For this reason, thorough evaluation and careful monitoring of patients for CNS involvement is critical. Contrast-enhanced magnetic resonance imaging should be performed as well, and cerebrospinal fluid analysis must be obtained in consultation with an oncologist. CSF cytological analysis, although generally low-yield, may spare the patient a more invasive vitreous or chorioretinal biopsy.

Treatment

PVRLs are generally radiosensitive and respond well to methotrexate¹⁴ and, in the case of B cell PVRL, rituximab.¹⁵ Treatment is best coordinated with an oncologist and may ultimately reflect patient preferences. Though there have been no randomized controlled treatment trials, the recommendations of the International Primary CNS Lymphoma Collaborative Group Symposium are to treat unilateral ocular disease with local therapy composed of intravitreal methotrexate and rituximab, either alone or in combination with 30 to 35 Gy external beam radiation therapy. Bilateral ocular disease can be treated locally or with systemic chemotherapy, preferentially with adjunctive intravitreal chemotherapy. Finally, when the CNS is involved, systemic high-dose methotrexate and rituximab, along with intravitreal chemotherapy, is recommended, since systemic therapy has limited vitreous penetration. Whole-brain irradiation

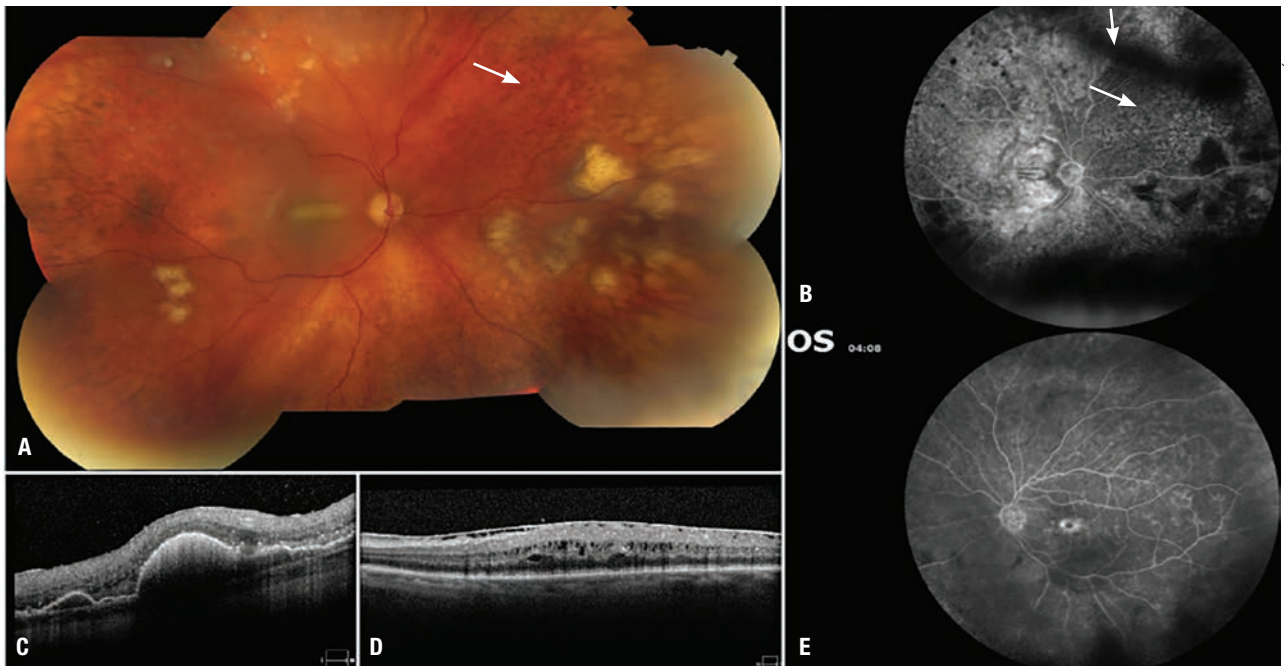


Figure 1. A 70-year-old woman presented with a history of blurry vision and constant sparkly flashes in the right eye which began more than one year prior. She had been treated with cataract surgery, then voriconazole after she developed vitritis and white creamy subretinal lesions. When her lesions failed to respond and she developed vitritis in the left eye, she was referred to our institute. On presentation, her vision was counting fingers in the right eye and 20/50 in the left. Examination revealed mild anterior chamber inflammation with fine keratic precipitates and lens deposits, 1+ vitritis, 2+ haze and inferior snowballs, as well as (A) a macular fold and scattered creamy yellow-white subretinal infiltrates, as well as leopard-spot RPE changes (arrow). (B) Fluorescein angiography of the right eye revealed blocking by the larger subretinal lesions as well as the vitreous debris (arrowhead), mild patchy staining in the macula and patchy window defects in the area of leopard-spot RPE changes (arrow). (C) OCT through one of the nasal lesions revealed punctate hyperreflectivity possibly representing lymphoma cells in the outer retina and pigment epithelial detachments with sub-RPE deposits of hyperreflective material. Examination of the left eye showed 0.5+ vitreous cell and haze, an unremarkable fundus other than the cystoid macular edema, seen also on OCT (D) with punctate hyperreflective foci similar to those seen in the right eye. (E) FA revealed petaloid foveal leakage and diffuse patchy staining throughout the retina. Vitreous and subretinal biopsy from the right eye revealed CD19+CD5+CD10- B cell lymphoma cells. MRI revealed no lesions and the patient was treated with intravitreal methotrexate (400 mcg/0.1 ml) and rituximab (1 mg/0.1 ml). She subsequently developed headache, facial pressure and imbalance, as well as a left visual field defect and was found to have involvement of the posterior right temporal and left frontal lobes. She was then treated with systemic high-dose methotrexate and rituximab.

with ocular radiotherapy is reserved for chemoresistant disease.³

The visual prognosis for PVRL is generally limited unless treatment is started shortly after clinical symptoms begin, and ocular recurrence occurs in 22 percent of cases after treatment.¹⁶ CNS disease occurs concurrently or following diagnosis of PVRL in 65 to 90 percent of patients, and is thought to represent multiple, often subclinical, foci of concurrent disease.³ Systemic therapy, therefore, is advocated by some to treat or prevent subclinical disease. Typical treatment for CNS lymphoma is an intense regimen of

methotrexate-based intravenous chemotherapy, which is often combined with intrathecal chemotherapy and/or whole-brain radiation and carries significant morbidity. The largest, albeit retrospective, study of PVRL to date¹⁶ involved 78 patients and found no significant difference in the occurrence of CNS disease between patients treated locally, systemically or with a combination approach. On average, 36 percent of patients developed CNS involvement in this European study, compared to 47 percent of individuals in an international study,¹⁷ which also found no difference in

CNS involvement between treatment groups.

II. Uveal Lymphoma

For uveal lymphoma, there are some diagnostic clues and aspects of treatment to keep in mind:

- **Clinical presentation.** While PVRL has no gender predilection, uveal lymphoma, on the other hand, presents more commonly in men, in the sixth and seventh decades of life, most commonly with blurry vision or no symptoms. The presentation is usually unilateral, though bilateral

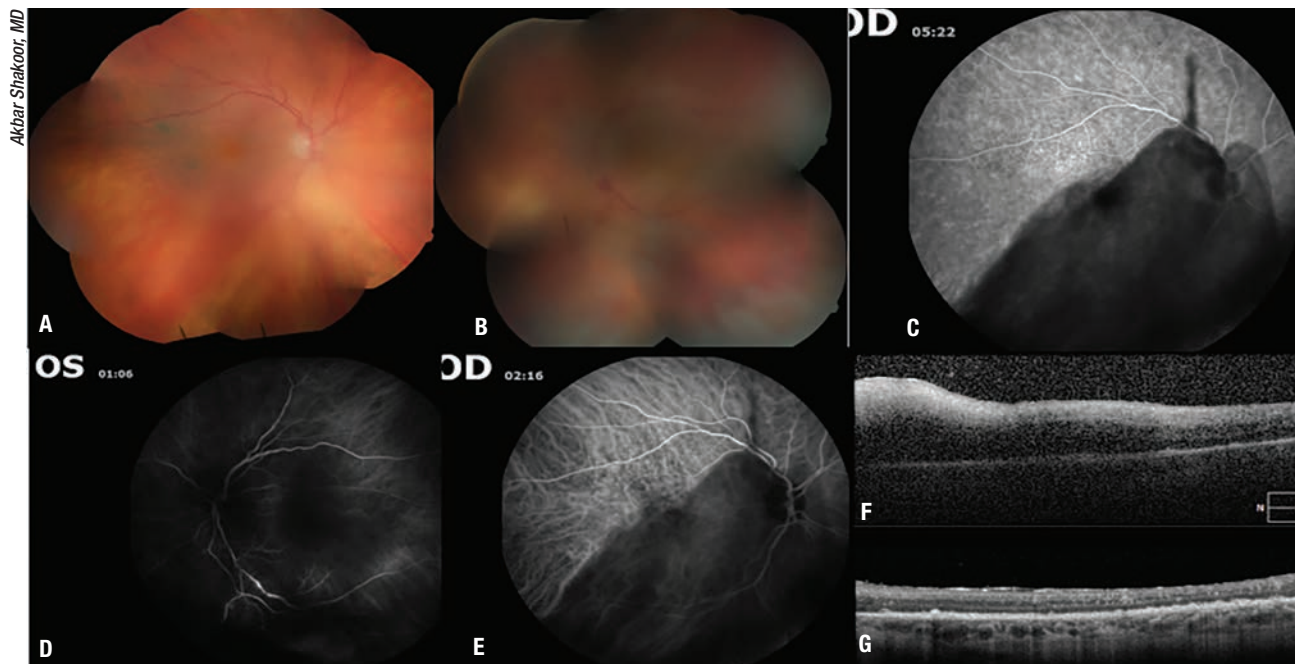


Figure 2. An 89-year-old man presented with a “cobweb” in his left eye for six months that didn’t improve with topical or sub-Tenon’s steroids, as well as new floaters in the right eye. On presentation, his vision was 20/30 in the right eye and hand-motion with an afferent pupillary defect in the left. Examination showed 2+ vitreous cells with mild macular pigment changes in the right eye (A) and 3+ vitreous cells and haze, disc edema/infiltrate, obliterative vasculitis and retinal whitening in the left (B). FA showed mild leopard-spot granularity in the right macula (C) and an occlusive vasculitis in the left eye (D). ICG showed a few hypopigmented spots in the right macula (E). An OCT through the left macula showed a diffuse macular infiltrate (F). The right macula had small subretinal deposits (not shown).

Lymphoma was high on the broad differential and the patient was started on oral sulfamethoxazole/trimethoprim and valgancyclovir, and a diagnostic vitrectomy with intravitreal injection of methotrexate, ganciclovir, foscarnet and clindamycin was performed the following day. The vitrectomy specimen revealed only CD19+CD5-CD10- weak kappa large B cells. Workup for systemic or CNS lymphoma was negative. The diffuse retinal infiltrate improved after three weeks (G) although his vision never improved, likely due to the optic nerve involvement. The patient was further treated with intravitreal methotrexate and rituximab in both eyes until he developed an occlusive vasculopathy in the right eye after rituximab injection. He was continued on intravitreal methotrexate for nearly a year before developing a pars plana lesion which is concerning for recurrence in the right eye.

disease in tertiary referral centers has been reported in up to 54 percent of cases.¹⁸ Most patients don’t have systemic lymphoma. Ocular findings include multifocal, creamy, yellow-white choroidal lesions,¹⁹ often with early hypofluorescence and late hyperfluorescence on FA; chorioretinal folds, obscuration of choroidal vessels, retinal detachments and, less commonly, uveal effusion.¹⁸

The differential diagnosis is broad and includes amelanotic uveal melanoma and metastases, as well as infections, particularly tuberculosis, sarcoidosis, multifocal choroidopathies, posterior scleritis and uveal effusion.

Ocular adnexal involvement or extension is common; it often manifests as a pink subconjunctival or sub-Tenon’s lesion. Additional features, more common in iris and ciliary body lymphoma, include anterior segment inflammation, glaucoma/ocular hypertension caused by infiltration of the angle structures, elevation in episcleral venous pressure by extraocular extension and rubeosis with angle closure.¹⁹

OCT reveals retinal changes that reflect the underlying choroidal tumor growth, with smaller tumors associated with a smooth or calm retinal contour and larger tumors associated

with a rippled or undulating retinal topography, as well as irregularities in the RPE and outer retina.²⁰ Enhanced-depth-imaging OCT may give details on the underlying tumor. B-scan ultrasound reveals an acoustically hollow choroidal thickening, measuring from 0.9 to 8.9 mm, and variable vitritis.²¹

Iris lymphomas present with blurred vision and painful red eyes. Examination reveals anterior chamber inflammation or pseudohypopyon, keratic precipitates, posterior synechiae and ciliary injection. While these tumors can masquerade as anterior uveitis, several distinguishing fea-

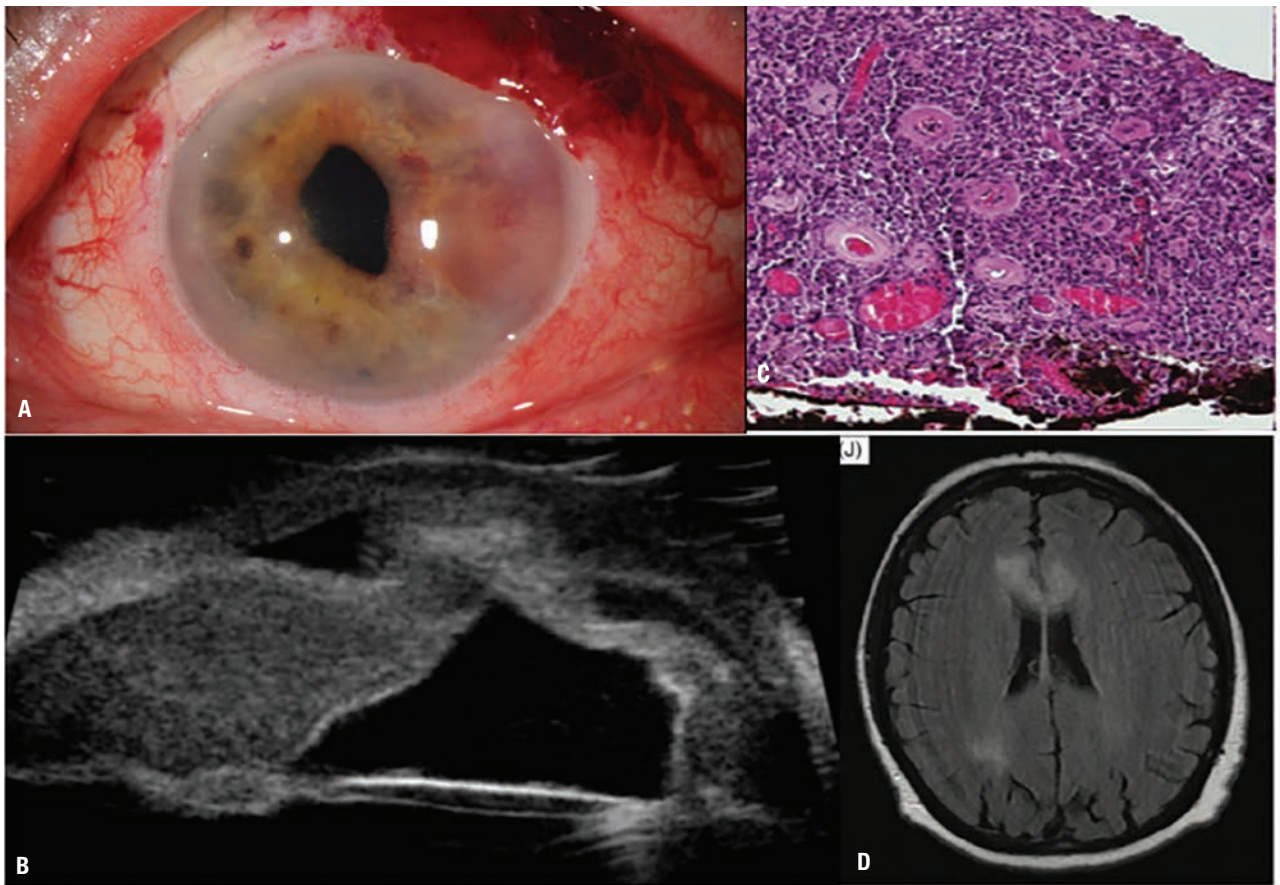


Figure 3. A 77-year-old woman presented with blurry vision, pain and tearing in the left eye. Her visual acuity measured 20/20 in the right eye and 20/60 in the left. Intraocular pressure was 11 mmHg OD and 25 mmHg OS. She had 2+ cell in the left eye with mutton-fat keratic precipitates throughout the inferior cornea. She was treated with topical steroids and cycloplegia for a granulomatous unilateral uveitis. Her eye pressure rose to 52 mmHg and she eventually underwent glaucoma filtration surgery and cataract extraction. When she returned three months later, there was a neovascular infiltrative iris lesion as well as vitritis (A). Ultrasound revealed iridocorneal touch and retro-iridal opacities suggestive of a lymphoproliferative or inflammatory lesion (B). She received an injection of bevacizumab and underwent a surgical iris biopsy which revealed iris stroma diffusely infiltrated by medium-sized lymphocytes with occasional clumped chromatin and rare nucleoli (C). Flow cytometric findings were most consistent with a diffuse large B-cell lymphoma, with high proliferative rate (>90 percent by MIB-1 immunohistochemical stain). The flow cytometric immune profile was positive for CD20, BCL-2, BCL-6 and MUM-1, negative for CD5 and CD10. The proliferative fraction was 90 percent. An MRI revealed right parietal and bilateral corpus callosum lesions and multifocal CNS involvement (D). The patient refused systemic treatment and was treated only locally with methotrexate. She later passed away from complications related to systemic lymphoma.

tures include infiltrative iris or ciliary body lesions, aberrant iris vessels, hyphema and conjunctival salmon-patch lesions. Lymphoid tumors of the iris can be nonmalignant lymphoproliferative lesions, but they're often higher-grade B cell or even T cell lymphomas. In one series, about half of the patients had primary iris lymphomas and half had systemic metastases.²²

• **Pathophysiology.** Debatably regarded as lymphoid hyperplasia,

lymphoid neoplasia and extranodal marginal zone lymphoma (EMZL), immunohistochemistry and PCR results suggest that uveal lymphomas represent a spectrum from lymphoproliferative lesions to low-grade lymphomas. They are primarily IgM+, usually monotypic with respect to Ig light chain, with variable levels of similarities to systemic EMZL. Some cases demonstrate monoclonality by PCR. Interestingly, the extraocular

extensions are usually composed of more benign-appearing cells or even completely reactive infiltrates²³ and the reactive cells are primarily small CD20+ B cells with far fewer reactive T cells than in PVRL.²⁴

• **Secondary uveal lymphoma.** The most common secondary or metastatic choroidal lymphoma is DLBCL, followed by multiple myeloma, B cell chronic leukemia,
(Continued on pg. 84)



How to Manage Pediatric Optic Neuritis

Though optic neuritis more commonly occurs in adult patients, it pays to be prepared for it in pediatric patients, as well.

Jason H. Peragallo, MD, Atlanta

Optic neuritis is defined as an inflammatory disease of the optic nerve. Though this disease is more common in adults, the pediatric ophthalmologist should also be aware of it, as well as its evaluation and treatment, because associations between optic neuritis and other neuro-inflammatory syndromes may affect final visual and systemic outcomes. Differences in presentation and underlying causes of optic neuritis in children are important to understand in order to avoid misdiagnosis and to guide neuroimaging and laboratory testing. In this article, we'll cover the various aspects of optic neuritis in pediatric patients that the ophthalmologist needs to know.

Presentation

Optic neuritis is commonly defined as the clinical presentation of decreased vision, impaired color vision or visual field defects with pain on eye movement, often in the presence of a relative afferent pupillary defect unless the disease is bilateral and symmetric. Patients in the pediatric age range may present with differ-

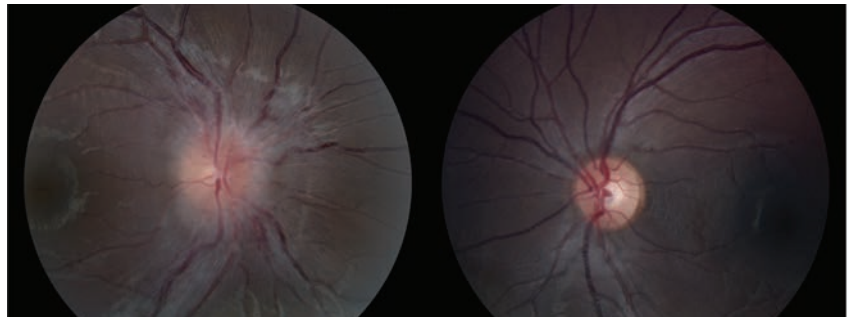


Figure 1. Fundus photographs of a patient with optic neuritis in the right eye demonstrating optic nerve edema.

ent clinical characteristics than those found in adults.¹

Obtaining a clear history of the illness can be difficult, if not impossible, in children. As a result, determining exactly when vision loss occurred may not be feasible. Children with optic neuritis may go without detection of the disease until one eye is incidentally covered or closed for some reason, leading the child to complain that he can't see and prompting a visit to the ophthalmologist or the emergency room. Bilateral involvement is more common in children than in adults, and often a child will present to the emergency room only if bilateral simultaneous disease occurs, or after

the second eye becomes involved. A meta-analysis of isolated pediatric optic neuritis studies found that 72 percent of children under the age of 10 presented with bilateral involvement, while in children older than 10 years, 70 percent presented with unilateral optic neuritis.²

Pain or pain with eye movement isn't a consistent feature of pediatric optic neuritis; therefore the absence of pain doesn't rule out optic neuritis.³ Severe vision loss to worse than 20/200 is common in children with optic neuritis (90 to 95 percent), in contrast to adults in the optic neuritis treatment trial, of whom 64 percent had visual acuities better than

20/200.^{4,5} However, final visual outcomes are usually very good, with visual acuities better than 20/40 in most cases.^{4,6,7} Children with optic neuritis will present more frequently with an anterior optic neuritis, rather than the retrobulbar optic neuritis more common in adults, with the majority of cases presenting with optic nerve edema (*Figure 1*).^{8,9} Optic nerve pallor commonly develops following resolution of the optic neuritis. Visual field defects in patients with optic neuritis are variable, and some patients are too young to perform formal visual field testing with any reliability. Optical coherence tomography of the retinal nerve fiber layer may initially demonstrate thickening

followed by thinning as optic nerve pallor develops.^{10,11} One study found that ganglion cell layer thickness can be affected in any pediatric demyelinating disease, with thinning occurring with or without the presence of optic neuritis.¹²

Epidemiology

In contrast to adult optic neuritis, optic neuritis in children is a relatively rare event. Incidence estimates for adults were 5.1/100,000 in one population-based study; incidence in the pediatric population is 0.5/100,000.^{13,14} As a result of the incidence of pediatric optic neuritis being approximately 10 percent of the adult rate, studying pediatric optic neuritis in a systematic manner is more difficult. However, research has found that in children

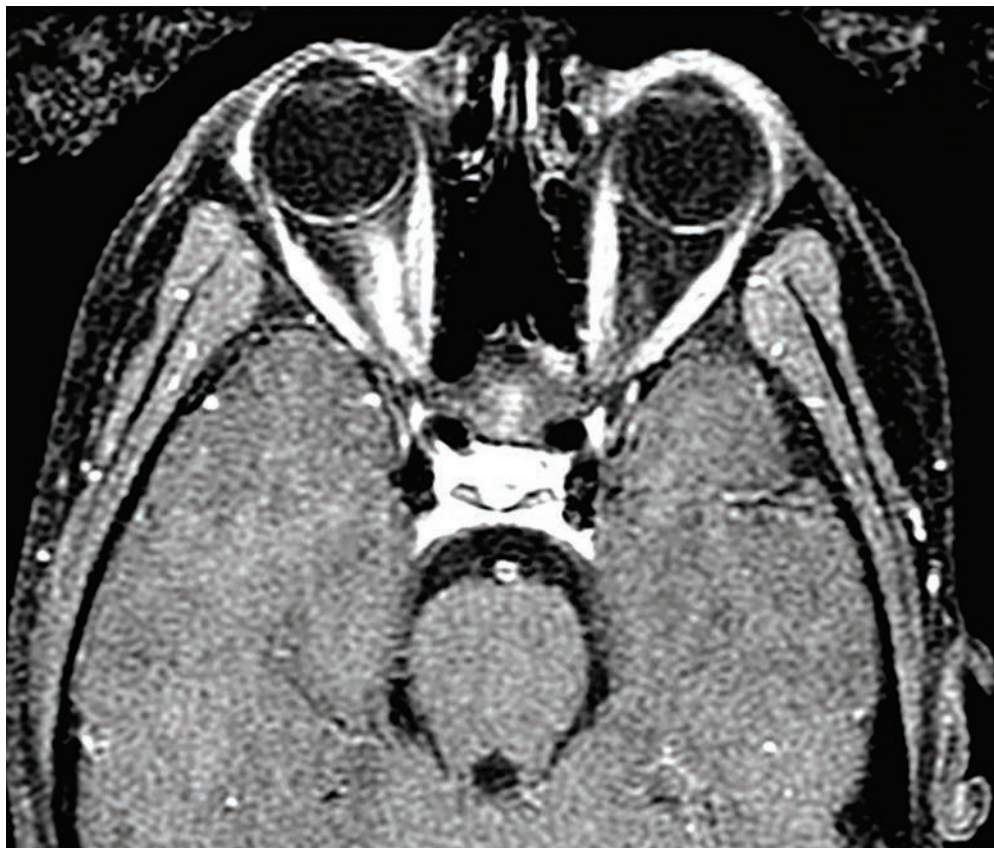

Figure 2. T1-weighted fat-saturated MRI of the orbits, post-gadolinium, of the patient in Figure 1, demonstrating longitudinally extensive right optic neuritis.

assumed to be pre-pubertal, the female:male ratio for involvement of optic neuritis is close to 1:1 according to one study, while post-pubertal children mimic the adult population with a female:male preponderance of 2:1.¹⁵

Evaluation & Underlying Causes

As opposed to adults, in whom optic neuritis is most often of the idiopathic demyelinating type, an underlying cause can be found more frequently in the pediatric population.¹ Often a history of a flu-like illness preceding the onset of vision loss by a week or so can be elicited from the parents, and these cases can be attributed to a post-infectious optic neuritis.¹ Optic neuritis can also follow vaccination. Other causes for optic neuritis in children can include, but are not

limited to, sarcoidosis, syphilis, tuberculosis, varicella zoster, Epstein-Barr virus and treatment with etanercept or infliximab. Differentiating between optic neuritis and neuroretinitis or Leber hereditary optic neuropathy may be difficult at initial presentation, but neuroimaging and the appropriate laboratory workup in addition to clinical history (such as bilateral sequential painless vision loss with negative neuroimaging in Leber hereditary optic neuropathy) can help to make the appropriate diagnosis in these patients.

Neuroimaging in pediatric optic neuritis is essential. Given the absence of typical symptoms associated with adult optic neuritis and the frequently bilateral nature of pediatric optic neuritis, neuroimaging is key in ruling out the possibility of an un-

derlying intracranial lesion that could cause bilateral optic disc edema, and confirming the presence of optic nerve enhancement (*Figure 2*).

Children should undergo an MRI of the brain and orbits with and without contrast to evaluate for other white matter lesions as well, such as in acute disseminated encephalomyelitis (ADEM) and multiple sclerosis. Some children will also require neuroimaging of the spinal cord if you suspect neuromyelitis optica, or if the patient has signs of spinal cord dysfunction. Working with a pediatric neurologist is extremely helpful in these situations.

A lumbar puncture may be indicated to look for oligoclonal bands that are present in multiple sclerosis if the patient has white matter lesions on brain MRI.

Other Disorders

Acute disseminated encephalomyelitis is usually a monophasic illness with multifocal involvement of the central nervous system and encephalopathy, which may include optic neuritis.¹⁶

Informed parents will ask the physician, “What is our child’s risk for developing multiple sclerosis?” Overall, the risk for developing multiple sclerosis appears to be lower for the pediatric population following isolated optic neuritis in comparison to adults. However, similar to the adult population, the presence of white matter lesions on initial brain MRI is associated with a 27-fold increased risk of developing multiple sclerosis.² In addition, as the age at presentation of pediatric optic neuritis increases, the risk of developing multiple sclerosis increases by 32 percent per year.² Currently, a wide range of results have been published regarding the rates of conversion to multiple sclerosis from isolated pediatric optic neuritis.¹⁷

Neuromyelitis optica (NMO) and

neuromyelitis optica spectrum disorder (NMO-SD) are more devastating immune-mediated neuroinflammatory disorders that may present initially with optic neuritis. Making the diagnosis is important as immunomodulatory agents can prevent disease flares and loss of function. In NMO, the discovery of the aquaporin-4 antibody has revolutionized making the diagnosis. The International Panel for NMO Diagnosis published criteria for making the diagnosis of NMO-SD, with stratification based on the presence or absence of aquaporin-4 antibodies,¹⁸ which are highly specific for NMO-SD. The panel’s criteria have since been deemed appropriate for use in the pediatric population.¹⁹ Treatment of NMO-SD should be performed with a neuroimmunologist where available.

The treatment regimen often prescribed for adults with typical isolated demyelinating optic neuritis is dictated by the Optic Neuritis Treatment Trial, though no such trial exists for children.

A more recent discovery that’s been shown to be involved in neuroinflammatory disorders is anti-myelin oligodendrocyte glycoprotein (MOG) antibody, though testing for this antibody is not yet commercially available in the United States. Anti-MOG antibody positivity appears to be

associated with ADEM in younger patients, and with optic neuritis in older patients.²⁰ A positive anti-MOG antibody appears to exclude the possibility of being aquaporin-4 antibody positive.²¹ The clinical implications of anti-MOG positivity are still being studied, but it appears associated with an NMO-SD-like disease that’s different from aquaporin-4 antibody-mediated NMO-SD.

Treatment Regimen

The treatment regimen often prescribed for adults with typical isolated demyelinating optic neuritis is dictated by the Optic Neuritis Treatment Trial. No such trial has yet been performed for children with optic neuritis. As a result, there’s no standard regimen for treatment of pediatric optic neuritis, and the choice of treatment is dependent upon the clinician.

Using data on adults from the ONTT and applying it to children, the initial treatment of choice for pediatric optic neuritis is intravenous methylprednisolone for three to five days (20 to 30 mg/kg/d, 1 g maximum).¹⁷ Some physicians follow this with an oral prednisone taper similar to that in the ONTT. In cases of refractory vision loss or more extensive CNS involvement, intravenous immunoglobulin or plasma exchange are used as well. Lack of improvement despite treatment should raise your level of suspicion for neuromyelitis optica or NMO-SD.

Treatment of neuromyelitis optica and multiple sclerosis is beyond the scope of this article, and should be managed by a pediatric neurologist or neuroimmunologist, with vision monitoring performed by the ophthalmologist.

Future Directions

Many questions remain concerning pediatric optic neuritis, and future evaluations are likely to depend

more upon molecular biomarkers to classify disease. Also, a standardized consensus regarding the treatment of pediatric optic neuritis remains to be developed. The Pediatric Eye Disease Investigator Group currently has a pediatric optic neuritis registry that's enrolling patients under the age of 16 with optic neuritis with an onset of symptoms within two weeks.²² This registry will systematically evaluate patient outcomes and, hopefully, lead to a prospective treatment trial for pediatric optic neuritis patients. Elucidating the role of anti-MOG antibodies in pediatric demyelinating diseases may help to define a distinct disease entity, similar to what has occurred for aquaporin-4 antibody-positive NMO-SD. **REVIEW**

Dr. Peragallo is an assistant professor in the departments of ophthalmology and pediatrics at Emory University School of Medicine in Atlanta. He has no financial interest in any

products mentioned in the article.

1. Brodsky, MC. The swollen optic disc in children. In Pediatric Neuro-Ophthalmology, 3rd Edition. New York, NY, Springer, 2016:121-198.
2. Waldman AT, Stull LB, Galetta SL, Balcer LJ, Liu GT. Pediatric optic neuritis and risk of multiple sclerosis: Meta-analysis of observational studies. J AAPOS 2011;15:441-6.
3. Yeh EA, Graves JS, Benson LA, Wassmer E, Waldman A. Pediatric optic neuritis. Neurology 2016;87:S53-8.
4. El-Dairi MA, Ghasia F, Bhatti MT. Pediatric optic neuritis. Int Ophthalmol Clin 2012;52:29-49.
5. Beck RW, Cleary PA, Anderson MM Jr, Keltner JL, Shults WT, Kaufman DI, et al. A randomized, controlled trial of corticosteroids in the treatment of acute optic neuritis. The Optic Neuritis Study Group. N Engl J Med 1992;326:581-8.
6. Liu GT, Volpe NJ, Galetta SL. Visual loss: Optic neuropathies. In Neuro-ophthalmology: Diagnosis and Management, 2nd ed. Saunders Elsevier, Philadelphia, 2011;103-198.
7. Wan MJ, Adebona O, Benson LA, Gorman MP, Heidary G. Visual outcomes in pediatric optic neuritis. Am J Ophthalmol 2014;158:503-7.
8. Wijeto M, Shroff M, Buncic JR, Kennedy J, Goia C, Banwell B. The clinical features, MRI findings, and outcome of optic neuritis in children. Neurology 2006;67:258-62.
9. Morales DS, Siatkowski RM, Howard CW, Warman R. Optic neuritis in children. J Pediatr Ophthalmol Strabismus 2000;37:254-9.
10. Yeh EA, Weinstock-Guttman B, Lincoff N, Reynolds J, Weinstock A, Madurai N, et al. Retinal nerve fiber layer thickness in inflammatory demyelinating diseases of childhood onset. Mult Scler 2009;15:802-10.
11. Kupersmith MJ, Mandel G, Anderson S, Meltzer DE, Kardon R. Baseline, one and three month changes in the peripapillary retinal nerve fiber layer in acute optic neuritis: Relation to baseline vision and MRI. J Neurol Sci 2011;308:117-23.
12. Yeh EA, Marrie RA, Reginald YA, Buncic JR, Noguera AE,

- O'Mahony J, et al. Functional-structural correlations in the afferent visual pathway in pediatric demyelination. Neurology 2014; 83:2147-52.
13. Rodriguez M, Siva A, Cross SA, O'Brien PC, Kurland LT. Optic neuritis: A population-based study in Olmstead County, Minnesota. Neurology 1995;45:244-50.
14. Langer-Gould A, Zhang JL, Chung J, Yeung Y, Waubant E, Yao J. Incidence of acquired central nervous system demyelinating syndromes in a multiethnic cohort of children. Neurology 2011;77:1143-1148.
15. Boomer JA, Siatkowski RM. Optic neuritis in adults and children. Semin Ophthalmol 2003;18:174-80.
16. Pohl D, Alper G, Van Haren K, Kornberg AJ, Lucchinetti CF, Tenenbaum S, Belman AL. Acute disseminated encephalomyelitis: Updates on an inflammatory CNS syndrome. Neurology 2016;S38-45.
17. Borchert M, Liu GT, Pineles S, Waldman AT. Pediatric optic neuritis: What is new. J Neuroophthalmol 2017;37 Suppl 1:S14-S22.
18. Wingerchuk DM, Banwell B, Bennett JL, Cabre P, Carroll W, Chitnis T, et al. International consensus diagnostic criteria for neuromyelitis optica spectrum disorders. Neurology 2015; 85:177-89.
19. Chitnis T, Ness J, Krupp L, Waubant E, Hunt T, Olsen CS, et al. Clinical features of neuromyelitis optica in children: United States Network of Pediatric MS Centers report. Neurology 2016;86:245-52.
20. Fernandez-Carbonell C, Vargas-Lowy D, Musallam A, Healy B, McLaughlin K, Wucherpfennig KW, Chitnis T. Clinical and MRI phenotype of children with MOG antibodies. Mult Scler 2016;22:174-84.
21. Hacoohen Y, Mankad K, Chong WK, Barkhof F, Vincent A, Lim M, et al. Diagnostic algorithm for relapsing acquired demyelinating syndromes in children. Neurology 2017;89:269-78.
22. Pineles SL, Liu GT, Waldman AT, Lazar E, Kupersmith MJ, Repka MX; Pediatric Eye Disease Investigator Group and the Neuro-Ophthalmology Research Disease Investigator Consortium. Pediatric Optic Neuritis Prospective Outcomes Study. J Neuroophthalmol 2016;36:115-7.

Hiring Ophthalmic Staff?


More Ophthalmic Technicians Find Jobs On Local Eye Site Than Anywhere Else.



localeyesite.com



Local Eye Site
JOBS IN EYE CARE



Managing Pseudoexfoliation During Cataract Surgery

Using a few simple strategies can go a long way toward preventing problems when dealing with these eyes.

Alan Crandall, MD, Salt Lake City

When performing cataract surgery on an average patient, we know there's a 99.9-percent chance everything will go beautifully. However, that's not the case when a patient has pseudoexfoliation; in that situation there's a good chance you'll encounter problems. You're likely to be dealing with a small pupil, and you may have issues creating the capsulorhexis or rotating the nucleus. The zonules are weak, making late postoperative subluxation of the lens a real possibility.

For these reasons, if you know

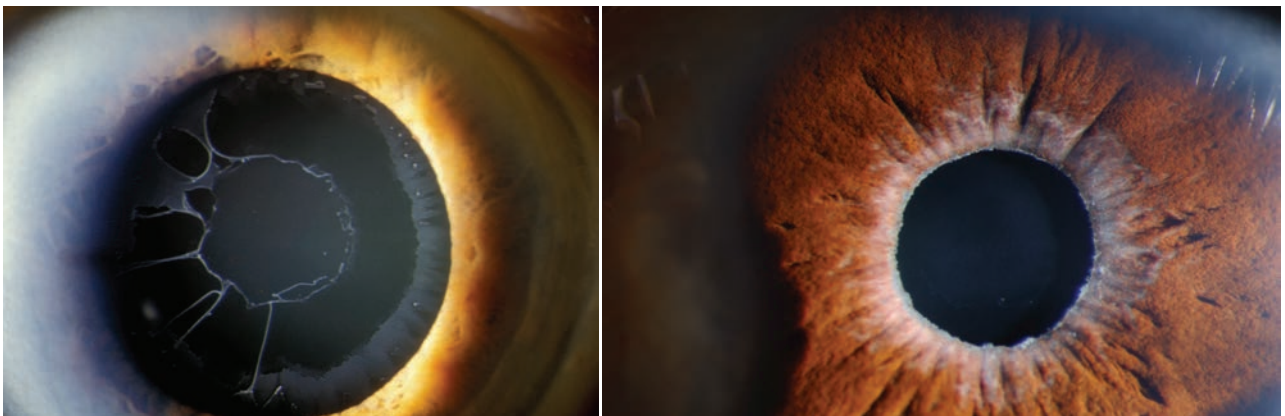
your patient has pseudoexfoliation you should come to the table with a backup plan. How will you deal with complications if they occur? And what can you do to minimize the likelihood of late subluxation?

Hiding in Plain Sight


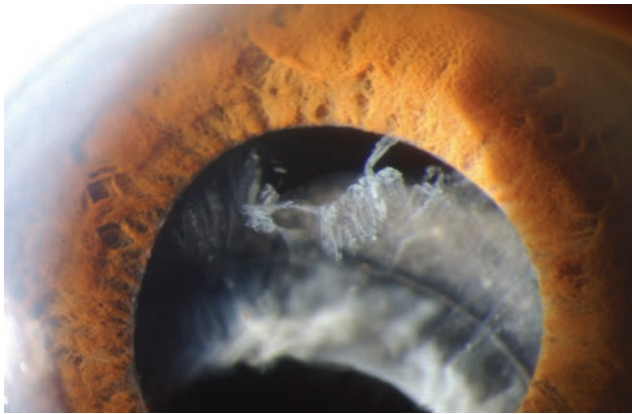
Because our practice is a referral center, we see more pseudoexfoliation than many surgeons do. (Some surgeons only encounter one or two cases a year; I perform cataract surgery on one or two pseudoexfoliation pa-

tients every week.) For that reason, our surgeons are in a good position to work on this issue. We're always trying to find ways to minimize late subluxation in these patients.

One factor that complicates the prevention of late subluxation is that surgeons often fail to identify the presence of pseudoexfoliation, even during the surgery. In about 70 percent of the cases in one reported series of subluxed lenses—many of which were in bags containing capsular tension rings—the surgeon's notes stated that the eye had no



Two classic signs of pseudoexfoliation. Left: Pseudoexfoliation material on the cataractous lens. Right: A small pupil with signs of roughness and whitish deposits.



What the surgeon may see when there's late subluxation of the lens. The zonules are not functional, so the lens drops.

pseudoexfoliation.¹ The removed lenses, however, proved them wrong. Although the pseudoexfoliation wasn't clinically obvious, the pseudoexfoliation material could be seen in the capsular bag afterwards.

This suggests at least three things:

1. It's easy to miss the presence of pseudoexfoliation.
2. A capsular tension ring doesn't prevent late subluxation (although it does make the lens easier to center, easier to refixate, and easier to retrieve if it falls back).
3. If you encounter a late subluxation, the odds are good that it was caused by the presence of pseudoexfoliation.

Helpful Strategies

Admittedly, it's difficult to determine how much a given preventive strategy will impact late subluxation, because subluxation usually doesn't happen until eight to nine years after uncomplicated surgery. Nevertheless, when performing surgery on a glaucoma patient, we should treat every eye as if it has pseudoexfoliation and may develop late subluxation. That means several things:

• **Assume that pseudoexfoliation may be present and operate carefully.** Do every cataract surgery on a glaucoma patient elegantly, assuming that pseudoexfoliation may

be a problem. Don't do a rush job; that will increase the likelihood of complications and late subluxation. As noted earlier, histology has shown that surgeons often fail to see signs of pseudoexfoliation even when it's present. That's why it pays to simply assume it may be there.

• **Don't work through a small pupil.** A small pupil, one of the hallmarks of pseudoexfoliation, is one of the main warning signs—if not *the* main warning sign—of potential intraoperative complications. In past years we taught courses on how to do phaco working through a 3-mm pupil. It is possible to do that, but in retrospect it was a mistake for us to be teaching that; it probably hastened some of the subluxations we're seeing today, 10 or 15 years later. Doing the phaco through a small pupil was simply too hard on the eye.

Today, we have a range of tools that can be used to widen a small pupil, so leaving it small is unnecessary. One simple approach that may suffice in some cases is injecting a cohesive viscoelastic to move the iris (after injecting a dispersive viscoelastic to protect the cornea). Sometimes that's enough to enlarge the pupil, avoiding the need to use mechanical means to widen it.

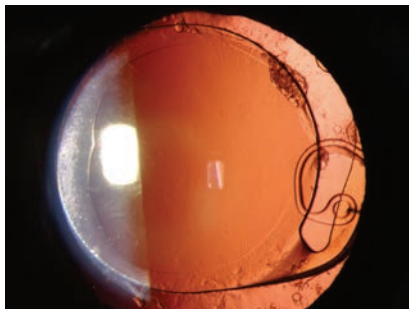
In terms of mechanical options for enlarging the pupil, we used to just manually spread it with a handheld

tool, more or less tearing or cutting the iris. Today, we have many options for widening the pupil: We can use iris hooks; the Malyugan ring; the APX System; or devices from Morcher, Graether or Perfect Pupil. All of these tools widen the pupil and thereby decrease the complication rate from cataract surgery. It may take you an extra 30 seconds to do this, but doing surgery through a small pupil is unnecessary and may well backfire.

• **Be alert for wrinkling of the anterior capsule.** It's not always possible to be aware of zonular weakness ahead of time, but one sign that should alert you to this problem during surgery is wrinkling of the capsule when you touch it at the start of capsulorhexis. (*See image, next page.*) That should put you on guard that you're dealing with a weakened zonule.

• **Don't create a small rhexis.** If you try to rotate the lens working through a small rhexis, you can cause zonular damage.

• **Use a capsular tension ring if necessary, but don't expect it to prevent late subluxation.** Placing a capsular tension ring can definitely help to center the lens. It may also help to make the lens easier to deal with in cases of late subluxation, because the ring makes the capsule and its contents easier to grab onto. (Many surgeons place a capsular



A Cionni ring inside a capsular bag. Capsular tension rings may help to center the lens and make the capsule easier to grab in cases of late subluxation, but they don't appear to prevent phimosis or late subluxation.

tension ring in every case where they suspect pseudoexfoliation.)

Recently, we've begun to see a clear association between late subluxation and pseudoexfoliation with capsular bag shrinkage, i.e., capsular phimosis. There are other causes for late subluxation, including trauma, but this now appears to be the most common cause. Capsular phimosis is another warning sign of weakened zonules because the capsule is tugging on the zonular space. Unfortunately, studying subluxed lenses that have been retrieved has made it clear that a capsular tension ring doesn't prevent phimosis, and thus doesn't prevent late subluxation.

- **If the nucleus is hard, consider using a prechopper and/or an ultrachopper (Alcon).** These tools will help to break up the cataract without using as much energy inside the eye, helping to lessen the likelihood of complications and late subluxation. A modern version of a snare called the MiLoop (Iantech) can be used with hard cataracts and loose capsular bags to bisect the nucleus.

- **Perform any rotation carefully.** Even with a large rhexis, this can be a source of zonular stress.

- **Get all of the cortex out.** Leaving cortex behind increases the likelihood of inflammation and can lead to Sommering rings later; that

may lead to lens tilt and even pigment dispersion due to contacting the iris.

- **Remove the cortex tangentially, not radially.** Stripping the cortex tangentially is actually faster than radial stripping—and it's safer. For many years we've been teaching that the surgeon should grab a piece of cortex, bring it to the center and remove it. Most of us were taught to do it that way, but doing it that way actually increases the zonular stress. In contrast, doing it tangentially decreases the stress on the zonules.

- **Remove lens epithelial cells from the anterior capsule to reduce phimosis.** Although some ophthalmic surgeons take the time to do this, the average cataract surgeon probably doesn't, for at least three reasons: it's time-consuming; it requires using an extra instrument; and you have to know how to do it. Usually, lens epithelial cell removal takes an extra 30 seconds, which can add up over the course of the day if you're performing 100 cases a day. But the reality is that these cells are what leads to phimosis, so if you have any reason to suspect pseudoexfoliation, you'd better take the time to do it. (I do it on 100 percent of these patients.)

- **Keep learning, because new information can make a big difference.** As noted, we used to think it was OK to work through a small pupil, and

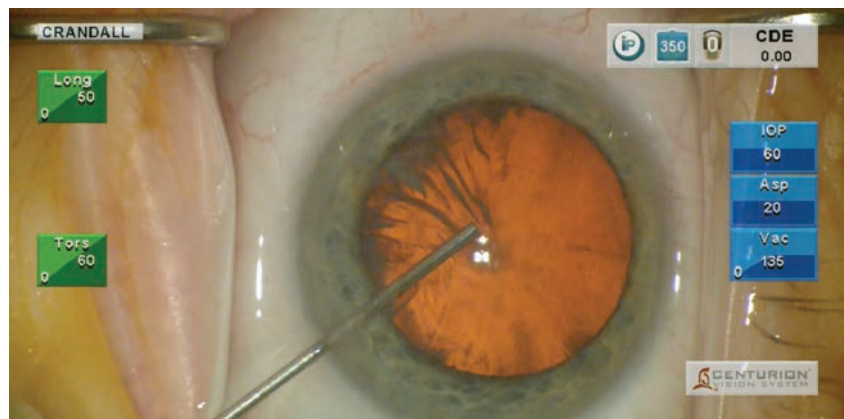
that radial stripping was better than tangential stripping. Now we know better. The moral is, you shouldn't be doing the same thing you're doing today a year from now, because that means you're behind the times. We all need to keep learning and adapting and incorporate the new techniques and information into our surgeries.

Playing It Safe

Although the presence of pseudoexfoliation is obvious in some patients, we currently have no way of knowing for certain if any given patient has pseudoexfoliation that we can't see. That's the reason we should always assume that pseudoexfoliation is a potential problem. It's a very real risk, particularly in the glaucoma setting—but if we approach every case as if it's a potential problem and perform the surgery accordingly, the risk for complications and late subluxation should decrease dramatically. [REVIEW](#)

Dr. Crandall is clinical professor, senior vice chair of ophthalmology and visual sciences, and director of glaucoma and cataract at the Moran Eye Center at the University of Utah.

1. Zaugg B, Werne L, Neuhann T, et al. Clinicopathologic correlation of capsulorhexis phimosis with anterior flexing of single-piece hydrophilic acrylic lens haptics. *J Cat Refract Surg* 2010;36:1605-1609.



One sign that the zonules are weak is wrinkling of the capsule when you touch it at the start of capsulorhexis.

A PUBLICATION BY **REVIEW**
of Ophthalmology

RETINA SPECIALIST

Retina Specialist focuses on the latest advances in the diagnosis, medical management and surgical treatment of diseases of the retina, along with practical, real-world advice from leading clinicians and other experts on managing the successful retina practice.



The new addition to the *Review* family serves the entire Retina Specialist marketplace.

Look for your issues in 2018:

» **MARCH**

» **JUNE**

» **SEPTEMBER**

» **NOVEMBER**

For inquiries contact

RETINASPECIALIST@JOBSON.COM

Advertising opportunities

JIM HENNE • PUBLISHER • 610-492-1017 • JHENNE@JOBSON.COM

MICHELE BARRETT • 215-519-1414 • MBARRETT@JOBSON.COM

MICHAEL HOSTER • 610-492-1028 • MHOSTER@JOBSON.COM

www.retina-specialist.com



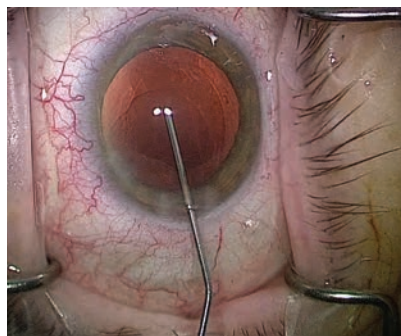
Two for One: Bilateral Cataract Surgery

Some say immediate sequential bilateral cataract surgery is as safe as staggered procedures.

Kristine Brennan, Senior Associate Editor

The 65-and-over population is expected to increase globally over the next several decades; with it, the proportion of people with cataract and frailty should grow correspondingly.¹ While cataract patients with age-related physical disability represent one group that might benefit from getting bilateral cataracts removed at the same time, staggering cataract surgeries is still standard practice in the United States. Here, surgeons who offer immediate bilateral cataract surgery describe why, how and for whom they do it.

“I do it, but very rarely and in accordance with very strict criteria,” says Derek W. DelMonte, MD, assistant professor of ophthalmology at the University of Colorado in Denver. “I’ll do same-day bilateral cataract surgery when the whole-body benefits to the patient clearly outweigh the drawbacks of doing each eye separately. Some patients will have trouble getting to the operating room twice, and some cannot cooperate with me and will require general anesthesia because of some physical or mental disability. For those patients, I’ll do both eyes on the same day. I’ll operate on



Derek W. DelMonte, MD

Avoidance of enzymatic detergents when cleaning surgical tools, or using disposable components where possible, may minimize the risk of bilateral TASS.

both eyes in one day for my patients with Down syndrome, for example.”

Dr. DelMonte thinks even more of his patients could benefit from same-day bilateral procedures, but reimbursement issues are another factor prompting his selectivity. “Economically, it does benefit the patient in terms of less downtime and less follow-up, but since Medicare will only reimburse the second eye of a same-day bilateral procedure at 50 percent, I think that continues to limit the number of same-day procedures,” he says. “There are systems like Kaiser Permanente where surgeons are

doing same-day procedures a great deal and enjoying great success with them. But for now, I generally don’t perform same-day procedures, except where the benefit to the whole patient is clear.”

The Kaiser Permanente medical group isn’t subject to Medicare’s reimbursement model for Medicare Advantage patients: Patient care is allocated in prepaid, capitated lump sums. Its providers have been offering immediate bilateral cataract surgery (IBCS) since around 2010. Prior to that, Neal H. Shorstein, MD, of Kaiser Permanente’s ophthalmology and quality departments in Walnut Creek, California, collaborated with colleagues to investigate its safety and outcomes in their 21 independent surgical centers. “In Walnut Creek, we had patients several years ago ask about whether we’d do both eyes on the same day. At the time we weren’t doing it. There were ophthalmologists in some of our other medical centers doing it,” he recalls. “In other places—Canada and the Canary Islands in particular back then—some surgeons did a lot of bilateral same-day surgery. A group of surgeons and other stake-

holders at Kaiser Permanente looked at this, and they found some controversy in the literature with regard to outcomes.”

Infection and Inflammation Risk

Specifically, Dr. Shorstein says their review spotlighted three main concerns about IBCS: fear of bilateral endophthalmitis; fear of bilateral toxic anterior segment syndrome (TASS); and the idea that the first eye’s visual outcome informs IOL selection for the second eye, making staggered surgeries superior.

“Regarding endophthalmitis, there have been no reported cases of bilateral endophthalmitis, except in developing countries where the recommended procedures of doing bilateral surgery weren’t followed,” he says.²

Dr. DelMonte says intracameral injections help to minimize endophthalmitis risk. “I think that cataract surgery has become so safe, thanks in part to intracameral injections, that the risk of monocular endophthalmitis and other complications is miniscule, and bilateral risks are similarly low—although I know that if a patient were to be affected bilaterally, that would be a very dire situation,” he says.

Dr. Shorstein, who uses intracameral antibiotic at the close of surgery, cites the International Society of Bilateral Cataract Surgeons (iSBCS) with regard to sterilizing equipment and maintaining a separate surgical tray for each eye. “Steve Arshinoff, a leader of the iSBCS, recommends having two separate surgical trays, and also recommends separating as many of the pharmaceutical products as possible in terms of their lot numbers. Then, if there was some manufacturing abnormality or irregularity, it wouldn’t affect both eyes,” he says.

Dr. Shorstein says that TASS has become less prevalent in recent years. “In the past five years or so, there have not been a lot of publications re-

porting TASS,” he says. “I think that’s because the ophthalmologic community has now recognized the best practices to prevent it.” He attributes the apparent reduction of TASS cases after cataract surgery to increased attentiveness to cleaning viscoelastic out of the phaco handpiece and to better cleaning of the tips after surgery. “Refraining from the use of enzymatic detergents is helpful, but if you must use enzymatic detergents to clean something as required per manufacturer instructions, then I think thoroughly rinsing away the detergent has also been very helpful in reducing TASS. We did a top-down risk analysis by going through all the steps of our cleaning and sterilization,” he says.

In addition to the established practice of using intracameral antibiotic injections, Kaiser Permanente—which does not promulgate rules for its surgeons, but does have established policies and procedures for its surgery centers—recommended the following:

- **Use separate surgical trays for each eye.** “We emphasize that it’s very important to separate surgical trays. When you’re done with one eye, completely take down the draping and gloves, and re-scrub as you would for a completely new patient for the second eye, with a new tray,” says Dr. Shorstein.

- **Consider going disposable.** “Our content experts felt that for any instruments that have very small lumens, like cannulas, the risk of TASS is small if they’re cleaned very thoroughly. But they still tended to recommend disposable cannulas for these cases, and I agree.” Dr. Shorstein says.

- **Use intracameral antibiotic preparations with a different lot number for each eye.** “Since there’s still no intracameral antibiotic manufacturer in this country, it has to be compounded. We use a 503(B)-compliant outsourcing facility,” says

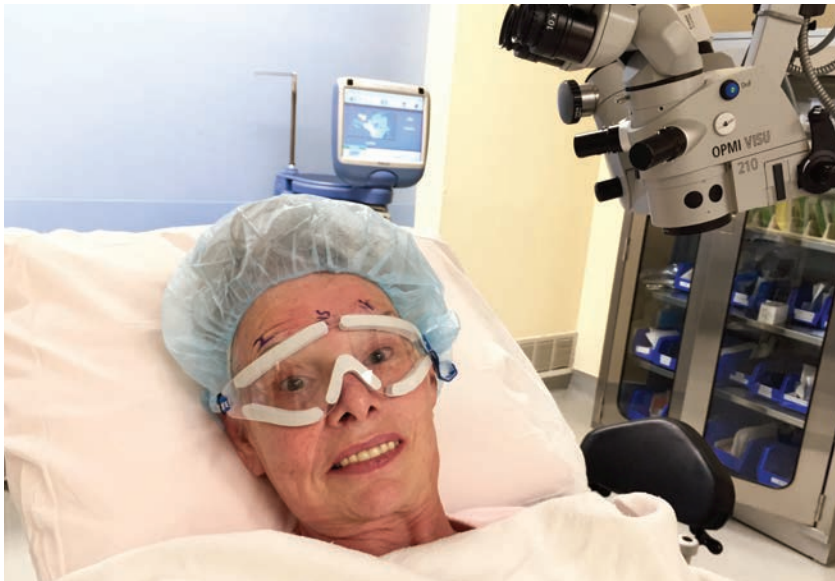Dr. Shorstein. “We separate the intracameral antibiotics by lots in case of any potential irregularity. Then, if the worst-case scenario occurs, we’ve decreased the risk of bilateral TASS or endophthalmitis because we’re using different lot numbers.”

Dr. Shorstein says that his practice setting isn’t currently separating viscoelastic by lot numbers in IBCS cases, however. The iSBCS goes further, recommending the separation of surgical products by lot number wherever it’s “reasonable...and possible.”³

Refractive Outcome Concerns

“Another concern about same-day cataract surgery has been about forgoing the opportunity to refract the first eye a few weeks postoperatively. Theoretically, you could adjust the IOL selection in the second eye if you missed the target uncorrected vision for the first eye,” says Dr. Shorstein. His research group decided to test that theory in a 2017 retrospective comparative study that looked at visual outcomes of 13,711 delayed sequential bilateral cataract surgery (DSBCS) patients and 3,561 immediate sequential bilateral cataract surgery (ISBCS) patients who had noncomplex surgeries performed as members of Kaiser Permanente Northern California from January 1, 2013 through June 30, 2015. They found no significant difference in postoperative BCVA or refractive error between the two groups, and no increase in the risk of complications, including endophthalmitis.⁴

“There’ve been a bunch of studies done in the past generally showing that if you were off on the first eye, then selecting an adjustment for the second eye of half the correction would likely get the second eye close to where you’d want to be visually,” explains Dr. Shorstein. “For example, if the first eye turned out to be -1 D (for a target of plano), then you’d want to select an IOL with 0.5 D less power



Neal H. Shorstein, MD

Enrolled members of the Kaiser Permanente medical group in Northern California can routinely undergo noncomplex, immediate bilateral sequential cataract surgery. Benefits to the patient include lower cost and a quicker return to work, driving and other activities.

for the second eye. But what we concluded was that it didn't appear that a lot of correction was going on in the different-day patients. This wasn't a prospective study, so we can't say that there was absolutely no effect from giving up the ability to correct the second eye based on the first eye by doing bilateral same-day procedures: But we can say that given this retrospective look-back, there was no evidence that much correcting was happening. That's because commercially available IOLs only come in half-steps to begin with, so you'd have to be off by a diopter or more in the first eye to really fiddle with your IOL selection in the second eye. To change it by a half-diopter, you'd have to be off by one or more."

For two particular patient groups, Dr. DelMonte performs only delayed sequential bilateral surgeries. "I will always stagger the surgeries for patients who are getting premium IOLs and for post-refractive eyes, because I think it's important to get information about the refractive outcome from the first eye to fine-tune power calculation and lens-selection consid-

erations for the second eye. I've had some patients ask for a little more near for reading in the second eye, for example, so I'll use the results from the first to help zero in on what those patients want. But I do understand that there are other surgeons who like to do premium IOLs at the same time in order to help their patients adapt more quickly to the technology in terms of depth of focus, stereopsis, etc. It's really about what patients want when they're getting premium lenses," he says. "I also think that the first eye needs time to heal before you arrive at a stable refractive outcome, but I think that information becomes clear and reliable within about one week postop."

The iSBCS recommends writing the target refractive information for both eyes on a board visible to everyone in the OR. Dr. Shorstein's group says consent-form language should always clearly stipulate each eye's IOL type and targeted working distance vision, and that it's critical to clearly delineate these between the patient's left and right eyes in ISBCS by keeping the fully signed consent form with

a biometry printout for the operative eye in the OR, for only one eye at a time, during immediate bilateral procedures.⁴

Safety and Savings

In the Kaiser Permanente study, 25 cases of planned ISBCS became DSBCS because the first-eye surgery was not uncomplicated, and so the second-eye procedure was rescheduled. "In our organization, if there's a complication in the first eye that could in any way impact the vision or healing of that eye, the consensus is to stop and not proceed to the second eye," says Dr. Shorstein. "We let the first eye heal. It's easier for the patient—and probably the surgeon as well."

Same-day bilateral cataract surgery is still relatively uncommon in the United States, but for the right patients and with some extra precautions, advocates say it can save downtime and money, restoring patients to full visual function faster. "I think that as the procedure becomes safer and safer, we'll see more people offering this," says Dr. DelMonte. "I also think that statistically, the inherent risk of driving to your follow-up appointments for delayed sequential bilateral procedures is higher than that of complications stemming from same-day bilateral surgery." **REVIEW**

Dr. DelMonte and Dr. Shorstein have no financial interests relevant to any products mentioned in this article.

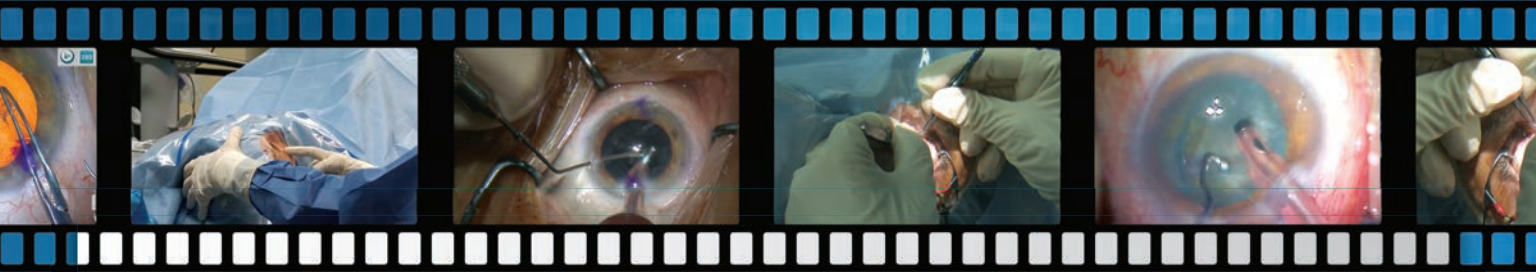
1. Fukuoka H, Afshari NA. Importance of age-related cataract on of frailty in an aging global population. *Curr Opin Ophthalmol* 2017;28:1:93-7.
2. Li O, Kapetanakis V, Claoue C. Simultaneous bilateral endophthalmitis after immediate sequential bilateral cataract surgery: What's the risk of functional blindness? *Am J Ophthalmol* 2014;157:749-51.
3. Arshinoff S, Claoue C, Johansson B. iSBCS General Principles for Excellence in ISBCS 2009; 2009. <http://isbcs.org/wp-content/uploads/2011/03/2010-07-20-FINAL-ISBCS-SBCS-suggestions-from-ESCRS-Barcelona.pdf>. Accessed March 5, 2018.
4. Herrinton LJ, Liu L, Alexeeff S, Carolan J, Shorstein NH. Immediate sequential vs. delayed sequential bilateral cataract surgery: Retrospective comparison of postoperative visual outcomes. *Ophthalmol* 2017;124:1126-35.



Monthly

MACKOOL ONLINE CME

CME SERIES | SURGICAL VIDEOS



To view CME video
go to:

www.MackoolOnlineCME.com

Episode 28: “Phakic Refractive IOL Explantation and Simultaneous Cataract- IOL Implantation”

Surgical Video by:
Richard J. Mackool, MD

Video Overview:

In order to perform cataract surgery upon this non-English speaking patient, I first have to remove an iris-fixated anterior chamber lens implanted 11 years previous. This case highlights removal of the phakic IOL, the value of a translator during surgery and the use of intraoperative aberrometry to determine the correct IOL power.

MackoolOnlineCME.com MONTHLY Video Series



Richard J. Mackool, MD

Welcome to the third year of Mackool Online CME! With the generous support of several ophthalmic companies, I am honored to have our viewers join me in the operating room as I demonstrate the technology and techniques that I have found to be most valuable, and that I hope are helpful to many of my colleagues. We continue to edit the videos only to either change camera perspective or to reduce down time – allowing you to observe every step of the procedure.

As before, one new surgical video will be released monthly, and physicians may earn CME credits or just observe the case. New viewers are able to obtain additional CME credit by reviewing previous videos that are located in our archives.

I thank the many surgeons who have told us that they have found our CME program to be interesting and instructive; I appreciate your comments, suggestions and questions. Thanks again for joining us on Mackool Online CME.



CME Accredited Surgical Training Videos Now Available Online: www.MackoolOnlineCME.com

Richard Mackool, MD, a world renowned anterior segment ophthalmic microsurgeon, has assembled a web-based video collection of surgical cases that encompass both routine and challenging cases, demonstrating both familiar and potentially unfamiliar surgical techniques using a variety of instrumentation and settings.

This educational activity aims to present a series of Dr. Mackool's surgical videos, carefully selected to address the specific learning objectives of this activity, with the goal of making surgical training available as needed online for surgeons motivated to improve or expand their surgical repertoire.

Learning Objective:

After completion of this educational activity, participants should be able to:

- Provide information regarding surgical technique and planning issues for simultaneous phakic/refractive IOL removal and cataract-implant surgery.

Satisfactory Completion - Learners must pass a post-test and complete an evaluation form to receive a certificate of completion. Your chosen sessions must be attended in their entirety. Partial credit of individual sessions is not available. If you are seeking continuing education credit for a specialty not listed below, it is your responsibility to contact your licensing/certification board to determine course eligibility for your licensing/certification requirement.



JOINTLY ACCREDITED PROVIDER™
INTERPROFESSIONAL CONTINUING EDUCATION

Physicians - In support of improving patient care, this activity has been planned and implemented by Amedco LLC and Postgraduate Healthcare Education. Amedco LLC is jointly accredited by the Accreditation Council for Continuing Medical Education (ACCME), the Accreditation Council for Pharmacy Education (ACPE), and the American Nurses Credentialing Center (ANCC), to provide continuing education for the healthcare team

Credit Designation Statement - Amedco designates this live activity for a maximum of .25 AMA PRA Category 1 Credits™. Physicians should claim only the credit commensurate with the extent of their participation in the activity.

Endorsed by:

Review of Ophthalmology®

Video and Web Production by:
JR Snowdon, Inc

Jointly Provided by:

AMEDCO & PHE

Supported by an unrestricted independent
medical educational grant from:

Alcon

Additionally Supported by:

**Glaukos
MST
Crestpoint Management
Carl Zeiss Meditec**

Trabeculectomy After Glaucoma Drainage

Researchers from the Stein Eye Institute and the Doheny Eye Institute in Los Angeles evaluated the outcomes of trabeculectomy with adjunctive mitomycin C in patients with uncontrolled intraocular pressure after glaucoma drainage device implantation.

Consecutive patients who had undergone a trabeculectomy after GDD were reviewed. The primary outcome was surgical success with stratified IOP targets based on the following criteria: IOP < 18 mmHg and IOP reduction of 20 percent; IOP < 15 mmHg and IOP reduction of 25 percent; and IOP < 12 mmHg with an IOP reduction of 30 percent. Secondary outcomes were the number of glaucoma medications, complications and need for additional glaucoma surgery.

Twenty eyes (19 patients) were analyzed. Median follow-up and age were 3.7 years and 64.2 years, respectively. Mean IOP dropped from 19.3 ± 4.2 mmHg preoperatively to 9.8 ± 2.2 mmHg at one year, 8.8 ± 3.2 mmHg at three years and 8.4 ± 1.5 mmHg at five years ($p < 0.001$ for all). Hypotony maculopathy was the only serious complication (10 percent; 2/19 patients) that needed surgical revision. The cumulative success rate for criteria 1 and 2 were 73.2 ± 10 percent and 68.2 ± 9.5 percent, re-

spectively, between the first and fifth year of follow-up. For criterion three, it was 49.1 ± 10.8 percent at the first year and 32.7 percent (± 12 percent) between the second and fifth year of follow-up.

Based on these results, researchers say trabeculectomy is a viable surgical option to treat IOP that is uncontrolled after GDD implantation.

J Glaucoma 2018;27:2:133-139
Alizadeh R, Akil H, Tan J, Law SK, Caprioli J

Antithrombotics' Risk for Intraocular Bleeding

Researchers from the University of Pennsylvania's Perelman School of Medicine conducted a retrospective cohort study to evaluate the risk of developing intraocular hemorrhages with a novel oral antithrombotic therapy compared with that of traditional antithrombotic agents.

These researchers used a large national insurance claims database to generate two parallel analyses. All patients with incident use of dabigatran etexilate or rivaroxaban between January 1, 2010, and September 30, 2015, were compared with patients with incident use of warfarin sodium. Similarly, patients with new use of prasugrel hydrochloride were compared with those with new use of clopi-

dogrel bisulfate. Both analyses required the patient to be enrolled in the insurance plan for at least 24 months prior to initiation of therapy and excluded patients with any previous diagnosis of intraocular hemorrhages or any prescription for the comparator medications.

Furthermore, the antiplatelet analysis required a diagnosis of acute coronary syndrome or a myocardial infarction within 60 days of initiation of pharmacologic therapy. The anticoagulant analysis excluded patients with end-stage renal disease, renal transplants and those with heart-valve disease.

A total of 146,137 patients taking warfarin (76,714 women and 69,423 men; mean age, 69.8 years) were compared with 64,291 patients taking dabigatran or rivaroxaban (31,576 women and 32,715 men; mean age, 67.6 years). Cox proportional hazards regression revealed a decreased hazard for developing an intraocular hemorrhage with dabigatran or rivaroxaban at 365 days (HR, 0.75; 95% CI, 0.58 to 0.97; $p = 0.03$), but not at 90 days (HR, 0.73; 95% CI, 0.22 to 2.63; $p = 0.13$). A total of 103,796 patients taking clopidogrel (37,578 women and 66,218 men; mean age, 68 years) were compared with 8,386 patients taking prasugrel (1,988 women and 6,380 men; mean age, 61 years),

and no increased hazard for developing an intraocular hemorrhage with prasugrel was seen at 90 days (HR, 0.75; 95% CI, 0.29 to 1.92; $p=0.55$) or 365 days (HR, 1.19; 95% CI, 0.69 to 2.04; $p=0.53$).

According to these results, researchers say that there appears to be a decreased risk of intraocular hemorrhage associated with novel direct thrombin inhibitors and direct factor Xa inhibitors, but no difference for P2Y12 inhibitors compared with traditional vitamin K anticoagulation and antiplatelet therapy, respectively.

JAMA Ophthalmol 2018;136:2:122-130
Uyhazi KE, Miano T, Pan W, VanderBeek BL

Predictive Factors for Neovascular AMD

In a retrospective study, researchers from Italy investigated the risk factors predictive for the development of neovascular age-related macular degeneration, by means of spectral-domain optical coherence tomography.

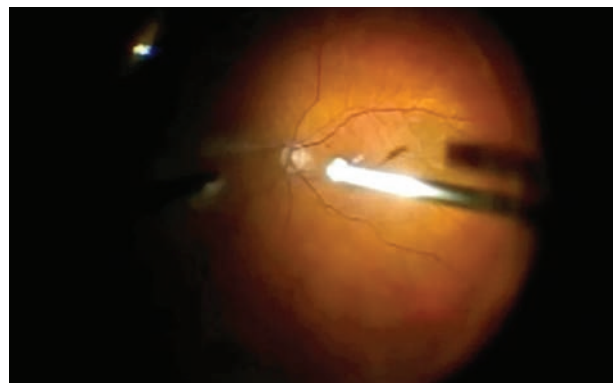
The study looked at 73 eyes graded Stage 2 and Stage 3 according to the AMD International Grading System, with a minimum follow-up of 24 months. Drusenoid pigment epithelial detachment, hyperreflective foci, external limiting membrane, inner ellipsoid band and retinal pigment epithelium integrity were analyzed at baseline and last follow-up. Researchers used a binary logistic regression model (represented by [Exp B]) to analyze significant predictors of neovascular conversion.

The discontinuity of external limiting membrane, inner ellipsoid band and retinal pigment epithelium bands were significantly more prevalent in the NVAMD group at baseline and last follow-up ($p<0.001$). Hyperreflective foci represented the single most important predictor of neovascular conversion (Exp [B], 15.15 times greater odds; $p=0.005$) as confirmed by Kaplan-Meier curve ($p=0.002$). Drusenoid pigment epithelial detachment width was significantly greater in the NVAMD group than in control subjects at baseline and last follow-up ($p<0.001$), and its delta value also resulted in a significant neovascular predictor (Exp [B], 0.99; $p=0.04$).

Researchers say that, based on these results, hyperreflective foci significantly increase the risk of NVAMD progression. The delta width of drusenoid pigment epithelial detachment also predicts disease progression, integrating the stratification of NVAMD progression risk.

Retina 2018;38:2:245-252
Fragiotta S, Rossi T, Cutini A, et al.

(Continued from page 51)



The intervention with almost 100-percent success for floaters is vitrectomy, shown here removing a Weiss ring.

this subgroup of patients, very little can be done outside of vitrectomy to satisfy them. For the remainder of the cohort in our study, however, when there was a good objective result, there was a correlated good subjective response. That is the difficulty with this field: There's so much subjectivity that it can be hard to select patients. This is why it's important to select patients who are easier to satisfy, and who have floaters that are more discrete. Patients with one Weiss ring floater and realistic expectations seem to be easier to satisfy with YAG laser vitreolysis than those with hundreds of diffuse floaters and/or significant anxiety about their floaters."

Surgeons say there are still many unanswered questions about YAG laser vitreolysis, such as: Are there different efficacies with different lasers? What personality types are best suited for the procedure? What are the long-term complications and effects? How many times should patients be treated? For all these questions, given the lack of trial data, Dr. Shah says that surgeons just aren't certain of the answers. "It's unknown at the moment," he avers. "We're doing an extension to our original pilot study in which we're bringing patients back two or three years after their YAG laser procedure to see if there are any long-term complications and/or degradation of effect. My feeling is that some patients may lose the treatment effect over time due to progressive myopic vitreopathy. We need much more data. At the moment, I consider YAG laser vitreolysis to be experimental. We need larger, multicenter trials, with longer follow-up, to answer these questions." **REVIEW**

1. Delaney YM, Oyinloye A, Benjamin L. Nd:YAG vitreolysis and pars plana vitrectomy: Surgical treatment for vitreous floaters. *Eye (Lond)* 2002;16:1:21-26.
2. Toczolowski J, Katski W. [Use of Nd:YAG laser in treatment of vitreous floaters.] *Klin Oczna* 1998;100:3:155-157.
3. Tsai WF, Chen YC, Su CY. Treatment of vitreous floaters with neodymium YAG laser. *Br J Ophthalmol* 1993;77:8:485-488.
4. Shah CP, Heier JS. YAG laser vitreolysis vs sham YAG vitreolysis for symptomatic vitreous floaters: A randomized clinical trial. *JAMA Ophthalmol* 2017;135:9:918-923.

(Continued from pg. 69)

extramedullary plasmacytoma, lymphoplasmocytic lymphoma, EMZL and Waldenstrom's macroglobulinemia.^{3,21} Iris and ciliary body involvement is much more common in secondary uveal lymphoma (20 to 30 percent vs. only 4 to 8 percent in primary uveal lymphoma) and these anterior uveal lymphomas tend to be somewhat higher-grade malignancies.²¹

Diagnosis

Diagnosis of uveal lymphoma can sometimes be made by sampling the epibulbar, conjunctival or orbital components of the disease. However, as noted above, these are more likely to be lymphoproliferative or reactive inflammatory cells than the uveal components.

Alternatively, samples can be obtained via transvitreal or transscleral needle aspiration of choroidal lesions, or by direct iris or ciliary body biopsy. The vitreous component is also more commonly lymphoproliferative or reactive, and not necessarily diagnostically useful. Systemic investigation for lymphoma should include MRI of the brain as well as complete blood count, serum protein electrophoresis, abdominal and chest computed tomography or PET scan, and bone-marrow biopsy.

Treatment

The prognosis for primary choroidal lymphoma is very good, with the vast majority achieving complete remission after radiotherapy and stability or incomplete remission after chemotherapy. The prognosis for metastatic choroidal lymphoma depends on the primary diagnosis, but a third of patients succumbed to their cancer in one study.²¹ While eventual CNS involvement is fairly common in PVRL, development of systemic

or CNS lymphoma is rare in primary choroidal lymphoma.^{25,26}

The prognosis for primary choroidal lymphoma is very good, with the vast majority achieving complete remission after radiotherapy and stability or incomplete remission after chemotherapy.

In summary, though intraocular lymphomas are rare and clinically variable, certain scenarios should raise suspicion for these potentially devastating tumors. In particular, isolated chronic vitritis, unilateral multifocal choroidal lesions and poorly responsive unilateral posterior uveitis in patients older than 40 should prompt further evaluation, such as ultrasound, FA, OCT of individual lesions and vitreous biopsy, or referral to a uveitis specialist or ocular oncologist. **REVIEW**

Dr. Hassman is a uveitis fellow and Dr. Shakoor is an assistant professor at the Moran Eye Center at the University of Utah. Neither author has a financial interest in any product mentioned in the article.

1. van den Brand M, Scheijen B, Hess CJ, van Krieken JHJ, Groenen P. Pathways towards indolent B-cell lymphoma - Etiology and therapeutic strategies. *Blood Rev* 2017;31:6:426-435.
2. Coupland SE. Molecular pathology of lymphoma. *Eye (Lond)* 2013;27:2:180-189.
3. Chan CC, Rubenstein JL, Coupland SE, et al. Primary vitreoretinal lymphoma: A report from an International Primary Central Nervous System Lymphoma Collaborative Group symposium. *Oncologist* 2011;16:11:1589-1599.
4. Davis JL. Intraocular lymphoma: A clinical perspective. *Eye (Lond)* 2013;27:2:153-162.
5. Abusamra K, Oray M, Ebrahimiadib N, Lee S, Anesi S, Foster CS.

Intraocular lymphoma: Descriptive data of 26 patients including clinico-pathologic features, vitreous findings, and treatment outcomes. *Ocul Immunol Inflamm* 2016;20:1-6.

6. Chapat F, Amer R, Baglivo E, et al. Intraocular T-cell lymphoma: Clinical presentation, diagnosis, treatment, and outcome. *Ocul Immunol Inflamm* 2017;25:5:639-48.

7. Merle H, Hage R, Meniane JC, et al. Retinal manifestations in adult T-cell leukemia/lymphoma related to infection by the human T-cell lymphotropic virus Type-1. *Retina* 2016;36:7:1364-1371.

8. Liu MM, Furusato E, Cao X, Shen D, Chan CC. Ocular manifestations and pathology of adult T-cell leukemia/lymphoma associated with human T-lymphotropic virus type 1. *Rare Tumors* 2010;2:4:e63.

9. Wang Y, Shen D, Wang VM, Sen HN, Chan CC. Molecular biomarkers for the diagnosis of primary vitreoretinal lymphoma. *Int J Mol Sci* 2011;12:9:5684-5697.

10. Akpek EK, Maca SM, Christen WG, Foster CS. Elevated vitreous interleukin-10 level is not diagnostic of intraocular-central nervous system lymphoma. *Ophthalmology* 1999;106:12:2291-2295.

11. Kanavi MR, Soheilian M, Hosseini SB, Azari AA. 25-gauge transconjunctival diagnostic vitrectomy in suspected cases of intraocular lymphoma: A case series and review of the literature. *Int J Ophthalmol* 2014;7:3:577-581.

12. Koch FH, Koss MJ. Microincision vitrectomy procedure using Intretor technology. *Arch Ophthalmol* 2011;129:12:1599-1604.

13. Rantny ML, Laurent C, Aziza J, et al. Improving the cytological diagnosis of intraocular lymphoma from vitreous fluid. *Histopathology* 2015;67:1:48-61.

14. Smith JR, Rosenbaum JT, Wilson DJ, et al. Role of intravitreal methotrexate in the management of primary central nervous system lymphoma with ocular involvement. *Ophthalmology* 2002;109:9:1709-1716.

15. Larkin KL, Saboo US, Comer GM, et al. Use of intravitreal rituximab for treatment of vitreoretinal lymphoma. *Br J Ophthalmol* 2014;98:1:99-103.

16. Riemens A, Bromberg J, Touitou V, et al. Treatment strategies in primary vitreoretinal lymphoma: A 17-center European collaborative study. *JAMA Ophthalmol* 2015;133:2:191-197.

17. Grimm SA, Pulido JS, Jahnke K, et al. Primary intraocular lymphoma: An International Primary Central Nervous System Lymphoma Collaborative Group report. *Ann Oncol* 2007;18:11:1851-1855.

18. Aronow ME, Portell CA, Sweetenham JW, Singh AD. Uveal lymphoma: Clinical features, diagnostic studies, treatment selection, and outcomes. *Ophthalmology* 2014;121:1:334-341.

19. Coupland SE, Foss HD, Hummel M, Stein H. Extranodal marginal zone B-cell lymphoma of the lacrimal gland associated with crystal-storing histiocytosis. *Ophthalmology* 2002;109:1:105-110.

20. Shields CL, Arepalli S, Pellegrini M, Mashayekhi A, Shields JA. Choroidal lymphoma shows calm, rippled, or undulating topography on enhanced depth imaging optical coherence tomography in 14 eyes. *Retina* 2014;34:7:1347-1353.

21. Mashayekhi A, Shukla SY, Shields JA, Shields CL. Choroidal lymphoma: Clinical features and association with systemic lymphoma. *Ophthalmology* 2014;121:1:342-351.

22. Mashayekhi A, Shields CL, Shields JA. Iris involvement by lymphoma: A review of 13 cases. *Clin Exp Ophthalmol* 2013;41:1:19-26.

23. Cockerham GC, Hidayat AA, Bijwaard KE, Sheng ZM. Re-evaluation of "reactive lymphoid hyperplasia of the uvea": An immunohistochemical and molecular analysis of 10 cases. *Ophthalmology* 2000;107:1:151-158.

24. Erickson B, Mantopoulos D, Schoenfeld L, Cebulla CM. Multimodal imaging and clinicopathologic correlation in primary uveal lymphoma. *Case Rep Ophthalmol* 2016;7:1:39-43.

25. Dirani A, Allaire G, Callejo S, et al. Choroidal extranodal marginal zone lymphoma diagnosed by full-thickness retinochoroidal biopsy: Case report and review of the literature. *Int Med Case Rep J* 2017;10:153-158.

26. Bayraktar S, Stefanovic A, Montague N, Davis J, Murray T, Lossos IS. Central nervous system manifestations of marginal zone B-cell lymphoma. *Ann Hematol* 2010;89:10:1003-1009.

CooperVision's MyDay Toric in Plus Powers

CooperVision recently announced the addition of plus powers to its line of MyDay toric daily disposable contact lenses. These extended parameters, available April 2, include the range from +0.5 D to +6 D in 0.5-D steps.

First introduced in January, CooperVision's MyDay toric lenses are new premium silicone hydrogel one-day lenses that combine the advantages of silicone hydrogel, uncompromised comfort and handling, lens stability and visual acuity, CooperVision says.

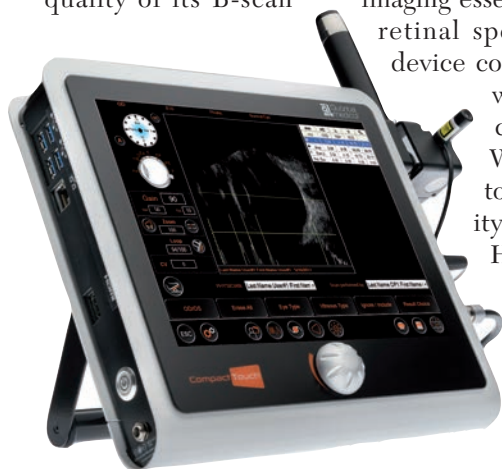For more information on MyDay toric lenses, visit PrescribeMyDay.com/toric.

Quantel's Ultrasound Approved

In early March, Quantel Medical announced that it received FDA approval for its next-generation Compact Touch ophthalmic ultrasound platform. Launched originally in 2008, the Compact Touch line offers high-quality images, intuitive software, compact design and versatility, Quantel says.

The company adds that the latest generation of Compact Touch includes a 15-MHz probe to increase the quality of its B-scan imaging essential to vitreo-

retinal specialists. The

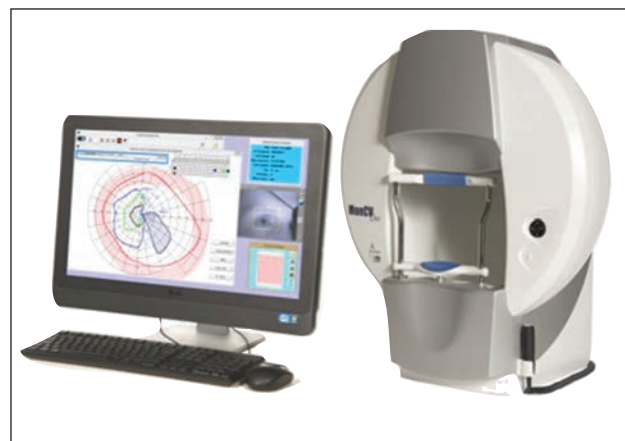

device comes equipped with DICOM compatibility, WiFi and Bluetooth connectivity, as well as an HDMI video output. It also features a touch-screen interface, while also being

fanless and silent, minimizing distractions. Quantel says these new software enhancements improve workflow.

For more information on Quantel's new Compact Touch, visit quantel-medical.com.

Metrovision's MonCvONE Full-field Perimeters



In mid-March, French company Metrovision announced its entry into the U.S. market with its MonCvONE line of full-field perimeters. The company says that the MonCvONE has a number of features that other perimeters may not, such as: computer-assisted Goldmann perimetry; the ability to measure at photopic, mesopic and scotopic levels; pupillometry; dark adaptometry; infant perimetry; and binocular-synchronized video imaging.

Metrovision says its perimeters are useful for glaucoma, retina, neuro-ophthalmic and pediatric specialists. The new product line includes the MonCvONE SAP and MonCvONE PRO for clinical practices. All three perimeters come with a two-year warranty.

For more information on the MonCvONE line of perimeters, visit srdvision.com.

Practice For Sale



Practice Sales • Appraisals • Consulting
www.PracticeConsultants.com

**PRACTICES FOR SALE
NATIONWIDE**

Visit us on the Web or call us to learn more about our company and the practices we have available.

info@PracticeConsultants.com

800-576-6935

www.PracticeConsultants.com

Career Opportunities

OPHTHALMOLOGISTS
Danbury, CT

Ophthalmologists to share office with long standing Ophthalmologist in Danbury, CT. High quality equipment. \$2,250 per month or adjoining office without equipment- \$1,750 per month.

**203-545-3539 or
email mehrimd@aol.com**



**FOR CLASSIFIED
ADVERTISING
CONTACT US TODAY:**

Toll free: **888-498-1460**

E-mail: sales@kerhgroup.com



Career Opportunities



Targeting
Ophthalmologists?

**CLASSIFIED ADVERTISING
WORKS**



Contact us today
for classified advertising:
Toll free: **888-498-1460**
E-mail: sales@kerhgroup.com



FIND MORE PRACTICES FOR SALE ON



CONTACT US TODAY to list your practice:

888-498-1460

opticlassifieds@kerhgroup.com

www.opticlassifieds.com



Eye pain and decreased vision bring a middle-aged woman in to Wills Eye Hospital's ER.

Erin Nichols, MD, and Adam DeBusk, DO

Presentation

A 49-year-old Caucasian female presented to the Wills Eye Hospital emergency room with progressively worsening eye pain and decreased vision OU over the past three months. The patient reported photophobia, headache, scalp tenderness and pain with eye movement. She denied a change in appetite or weight.

Medical History

Her past medical history was significant for metastatic melanoma, panhypopituitarism, hypertension and obesity. Metastatic melanoma had been diagnosed 16 months prior, and she had undergone wide local excision and treatment with systemic therapies including ipilimumab and vemurafenib. Her clinical course was complicated by local recurrence and bilateral lymph node involvement. At the time of presentation, she was enrolled in a clinical trial investigating the use of pembrolizumab with or without talimogene laherparepvec versus an oral placebo. She denied alcohol intake and smoking.

Her medications at presentation included bisoprolol-hydrochlorothiazide, bupropion, cetirizine, citalopram, lorazepam, zolpidem, naproxen-esomeprazole, prednisone, promethazine, diphenhydramine, docusate, fluticasone, levothyroxine and pembrolizumab (Keytruda) +/- talimogene laherparepvec.

Examination

On examination, visual acuity was 20/50 in the right eye with pinhole improvement to 20/30, and 20/30 in the left eye with pinhole improvement to 20/20. Both pupils were equal, round and reactive to light without relative afferent pupillary defect. Intraocular pressure was 16 mmHg OU, motility was normal and confrontational visual fields were full. Color plates were full bilaterally. Anterior slit lamp examination was unremarkable. Fundus examination revealed bilateral optic nerve edema with associated hemorrhages. The macula and peripheral retina appeared normal in both eyes.

What is your diagnosis? What further workup would you pursue? The diagnosis appears on p. 88.

Workup, Diagnosis and Treatment

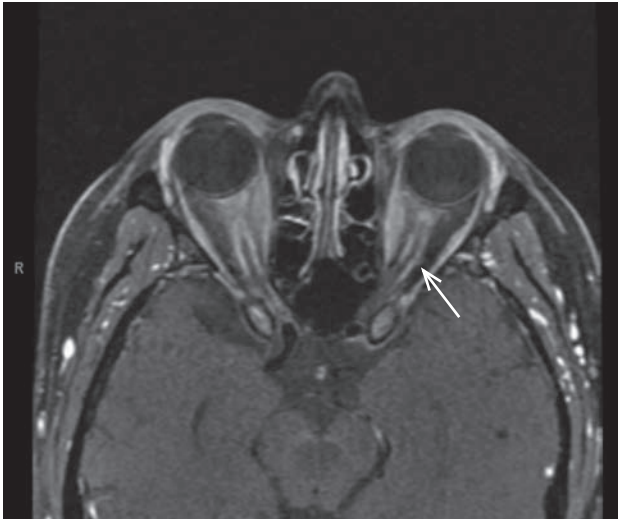


Figure 1. Axial T1 post-contrast MRI on initial presentation showing enhancement of bilateral optic nerve sheaths (“tram-track” sign)¹ and adjacent orbital fat streaking.

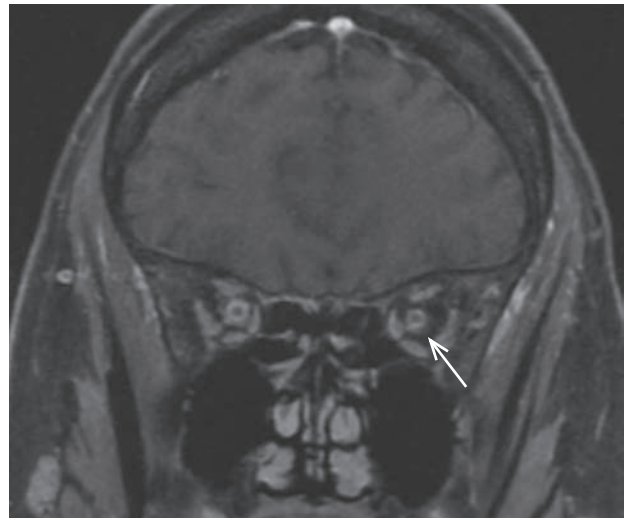


Figure 2. Coronal T1 post-contrast MRI on initial presentation showing enhancement of bilateral optic nerve sheaths (“doughnut” sign).²

Initial serologic evaluation for potential causes of bilateral optic nerve edema included QuantiFERON-TB Gold for tuberculosis and RPR/FTA-ABS for syphilis, both of which were negative. Angiotensin converting enzyme levels were within normal limits. Lyme disease antibodies were non-reactive. Complete blood count, basic metabolic panel and liver function tests were unremarkable. Erythrocyte sedimentation rate was elevated to 79 mm/hr (normal: 0 to 29 mm/hr). Lumbar puncture was performed with an opening pressure of 22 cm H₂O. Cerebrospinal fluid was colorless with 16 red blood cells and two white blood cells. There was an absence of oligoclonal bands. Infectious PCR panels, gram stain and CSF

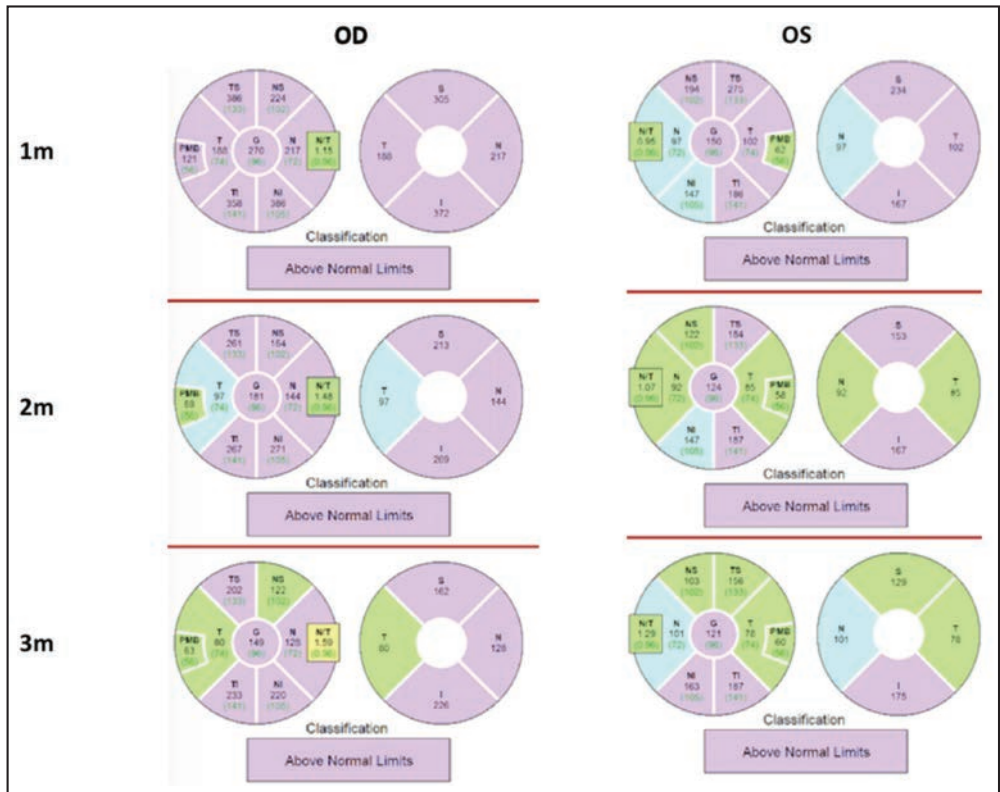


Figure 3. Retinal nerve fiber layer thickness reports showing bilateral elevation of the optic nerves one month following initial presentation and initiation of steroids.

culture were negative, as was cytology. MRI of the brain and orbits with and without contrast revealed enhance-

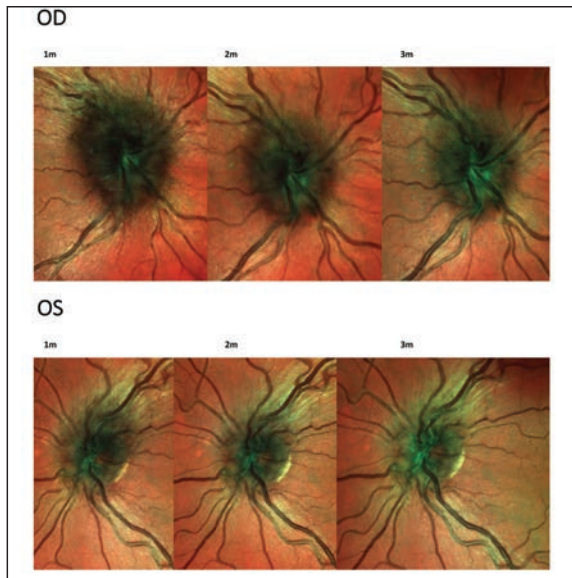


Figure 4. Spectral-domain OCT multicolor imaging of the right and left optic nerves, revealing bilateral edema of the retinal nerve fiber layer one, two and three months after initial presentation and initiation of steroids.

Discussion

Bilateral optic disc edema has a broad differential that includes increased intracranial pressure as well as paraneoplastic optic neuropathies, both of which warrant special consideration in patients with known metastatic malignancy. Additionally, physicians must be cognizant that the mechanisms of action of the systemic immunotherapies used to treat various malignancies can themselves lead to far-reaching immune dysregulation impacting various organs, including the globe, orbit and optic nerve.¹⁻³

In the case of our patient, early use of MRI imaging of the brain and orbits and magnetic resonance venography enabled an evaluation for metastatic space-occupying lesions and venous thrombosis, and also allowed for visualization of intra-orbital optic nerve inflammation. In our patient's case, MRI narrowed our differential diagnosis based on the characteristic MRI findings consistent with optic perineuritis, namely the “doughnut”

and “tram-track” signs on axial and coronal T1 post-contrast images.^{4,5}

Optic perineuritis is a rare form of optic nerve sheath inflammation that is a part of the orbital inflammatory disease spectrum.⁴ Secondary causes of optic perineuritis include infections such as syphilis, Lyme disease, tuberculosis and herpes zoster, as well as inflammatory conditions such as granulomatosis with polyangiitis, giant cell arteritis, sarcoidosis, inflammatory bowel disease and Behcet's disease.⁶⁻¹² Despite the diversity of secondary causes of optic perineuritis, the majority of cases ultimately have a negative workup and are considered idiopathic.

In our patient's case, the timing of her symptom onset and resolution corresponded to exposure to pembrolizumab and/or talimogene laherparepvec. Pembrolizumab is an anti-PD1 antibody, which is a part of the broader class of medications referred to as immune checkpoint inhibitors. Broadly speaking, ICIs

ment of bilateral optic discs and optic nerve sheaths (*Figures 1 and 2*). A partially empty sella was also noted. MRV was unremarkable.

Following the initial workup, the patient was diagnosed with bilateral optic perineuritis. She was admitted and started on intravenous methylprednisolone. Concurrently, her clinical trial medications (pembrolizumab with or without talimogene laherparepvec) were discontinued. After these interventions, the patient noted subjective improvement in her visual acuity and pain. She was discharged on a tapered regimen of oral prednisone.

At a one-month follow-up appointment in the Neuro-ophthalmology Service, visual acuity was 20/25 in the right eye and 20/20 in the left eye. Color plates remained full. There was no rAPD. Over the course of three months of follow-up, she continued to report an overall subjective improvement in vision, but noted some rebound discomfort with extraocular movements accompanying each steroid taper. Spectral-domain OCT revealed thickening of the retinal nerve fiber layer bilaterally (*Figures 3 and 4*). Over the course of follow-up, there was notable improvement in RNFL thickness bilaterally (*Figures 3 and 4*).

disrupt tolerance-inducing checkpoints that would normally function to inhibit T-cells from attacking host tissues. Such inhibition is strategic with respect to targeting tumors, as malignant cells utilize immune-escape strategies to evade being targeted by the immune system. Despite the clear advantages associated with enhancing the immune system's ability to eradicate cancer cells, this approach has been associated with a class of complications known as immune-related adverse events.² In a recent review of the existing literature on this topic, the incidence of irAEs secondary to a single ICI was estimated at 15 to 90 percent, but notably only 0.5 to 13 percent were severe enough to require ICI discontinuation.¹³ The incidence of ocular irAEs was <1 percent.¹⁴

Importantly, like many patients with advanced metastatic melanoma, our patient had been exposed to multiple ICIs, namely pembrolizumab at the time of presentation and ipilim-

For advertising opportunities contact:

Michele Barrett (610) 492-1014 or mbarrett@jobson.com

James Henne (610) 492-1017 or jhenne@jobson.com

Michael Hoster (610) 492-1028 or mhoster@jobson.com

Akorn Consumer Health 17

Phone (800) 579-8327
www.akornconsumerhealth.com

Akorn Pharmaceuticals 39

Phone (800) 932-5676
www.akorn.com

Alcon Laboratories 5, 6, 27

Phone (800) 451-3937
Fax (817) 551-4352

Compulink 19

Phone (800) 456-4522
www.compulinkadvantage.com

Eyecheck 61

Phone (855) 622-8836
Fax (855) 622-8836
support@eyecheck.com
www.eyecheck.com

Fashion Optical Displays 29

Phone (800) 824-4106
Fax (530) 877-2013

Glaukos 11

Phone (800) 452-8567
www.glaukos.com

Haag-Streit 25

Phone (800) 627-6286
Fax (603) 742-7217

Icare USA 8

Phone (888) 389-4022
www.icare-usa.com

Johnson & Johnson Vision (formerly AMO) 2

www.vision.abbott

Keeler Instruments 7

Phone (800) 523-5620
Fax (610) 353-7814

Lacrimedics, Inc 31

Phone (800) 367-8327
Fax (253) 964-2699
info@lacrimedics.com
www.lacrimedics.com

LENSAR 41

Phone (888) 536-7271
getit@lensar.com
www.lensar.com

Lombart Instruments 55, 57

Phone (800) 446-8092
Fax (757) 855-1232

New World Medical, Inc. 37

Phone (800) 832-5327
Fax (909) 466-4305
www.newworldmedical.com

Regeneron Pharmaceuticals, Inc. 13, 14, 43

Phone (914) 847-7000
www.regeneron.com

Reichert Technologies 45, 47, 49

Phone (888) 849-8955
Fax (716) 686-4545
www.reichert.com

S4OPTIK 63, 65

Phone (888) 224-6012

Shire Ophthalmics 91, 92

www.shire.com

Sun Ophthalmics 20-21, 22

SunsOnTheRise.com

Topcon Medical Systems 32-33

Phone (800) 223-1130
Fax (201) 599-5250

This advertiser index is published as a convenience and not as part of the advertising contract. Every care will be taken to index correctly. No allowance will be made for errors due to spelling, incorrect page number, or failure to insert.

umab approximately one year prior. Though individual ICIs have been associated with various ocular irAEs, there is potential for a synergistic, potentiating effect on immune dysregulation with exposure to multiple ICIs with differing mechanisms of action. Furthermore, as our patient was enrolled in a clinical trial comparing pembrolizumab and placebo versus pembrolizumab and talimogene laherparepvec, we must consider the potential impact of talimogene laherparepvec on overall immune activation. Importantly, talimogene laherparepvec is a genetically modified HSV-1 oncolytic virus, which has been hypothesized to target tumor cells by both direct destruction and by enhanced immune response secondary to a shift in the proportion of cytotoxic and regulatory T cells.¹⁵

Though our patient's exposure to multiple systemic immune-dysregulating medications prior to and at the time of presentation suggests a role for iatrogenic inflammation secondary to a loss of immune tolerance, we must also consider the possibility of idiopathic optic perineuritis, as this remains the most common cause. Furthermore, though symptoms and examination findings improved with discontinuation of immune modulating agents, this intervention coincided with the initiation of corticosteroids, which are known to cause a dramatic resolution of idiopathic optic perineuritis.⁴ Regardless, we believe this case highlights special considerations in the evaluation of bilateral optic nerve edema in the setting of known malignancy and adds to the evolving body of literature detailing the diverse secondary effects of strategic systemic immune dysregulation. **REVIEW**

- Papavasileiou E, Prasad S, Freitag SK, et al. Ipilimumab-induced ocular and orbital inflammation—A case series and review of the literature. *Ocul Immunol Inflamm* 2016;24:2:140-6.
- Michot JM, Bigenwald C, Champiat S, et al. Immune-related adverse events with immune checkpoint blockade: A comprehensive review. *Eur J Cancer* 2016;54:1:39-48.
- de Velasco G, Bermas B, Choueiri TK. Autoimmune arthropathy and uveitis as complications of programmed death 1 inhibitor treatment. *Arthritis Rheumatol* 2016;68:2:556-7.
- Purvin V, Kawasaki A, Jacobson DM. Optic perineuritis: Clinical and radiographic features. *Arch Ophthalmol* 2001;119:9:1299-306.
- Fay AM, Kane SA, Kazim M, et al. Magnetic resonance imaging of optic perineuritis. *J Neuroophthalmol* 1997;17:4:247-9.
- O'Connell K, Marnane M, McGuigan C. Bilateral ocular perineuritis as the presenting feature of acute syphilis infection. *J Neurol* 2012;259:1:191-2.
- Elamin M, Alderazi Y, Mullins G, et al. Perineuritis in acute Lyme neuroborreliosis. *Muscle Nerve* 2009;39:6:851-4.
- McClelland C, Zaveri M, Walsh R, et al. Optic perineuritis as the presenting feature of Crohn disease. *J Neuroophthalmol* 2012;32:4:345-7.
- Ryu WY, Kim JS. Optic perineuritis simultaneously associated with active pulmonary tuberculosis without intraocular tuberculosis. *Int J Ophthalmol* 2017;10:9:1477-1478.
- Purvin V, Kawasaki A. Optic perineuritis secondary to Wegener's granulomatosis. *Clin Exp Ophthalmol* 2009;37:7:712-7.
- Morotti A, Liberini P, Padovani A. Bilateral optic perineuritis as the presenting feature of giant cell arteritis. *BMJ Case Rep*. Jan 29, 2013. pii: bcr2011007959.
- Yu-Wai-Man, P. Optic perineuritis as a rare initial presentation of sarcoidosis. *Clin Exp Ophthalmol* 2007;35:7:682-4.
- Kang SJ, Zhang Q, Patel SR, et al. In vivo high-frequency contrast-enhanced ultrasonography of choroidal melanoma in rabbits: Imaging features and histopathologic correlations. *Br J Ophthalmol* 2013;97:7:929-33.
- Kumar V, Chaudhary N, Garg M. Current diagnosis and management of immune related adverse events (irAEs) induced by immune checkpoint inhibitor therapy. *Front Pharmacol* 2017;8:49.
- Bommareddy PK, Patel A, Hossain S, et al. Talimogene laherparepvec (T-VEC) and other oncolytic viruses for the treatment of melanoma. *Am J Clin Dermatol* 2017;18:1:1-15.



BRIEF SUMMARY:

Consult the Full Prescribing Information for complete product information.

INDICATIONS AND USAGE

Xiidra® (lifitegrast ophthalmic solution) 5% is indicated for the treatment of the signs and symptoms of dry eye disease (DED).

DOSAGE AND ADMINISTRATION

Instill one drop of Xiidra twice daily (approximately 12 hours apart) into each eye using a single-use container. Discard the single-use container immediately after using in each eye. Contact lenses should be removed prior to the administration of Xiidra and may be reinserted 15 minutes following administration.

CONTRAINDICATIONS

Xiidra is contraindicated in patients with known hypersensitivity to lifitegrast or to any of the other ingredients in the formulation.

ADVERSE REACTIONS

Clinical Trials Experience

Because clinical studies are conducted under widely varying conditions, adverse reaction rates observed in clinical studies of a drug cannot be directly compared to rates in the clinical trials of another drug and may not reflect the rates observed in practice. In five clinical studies of dry eye disease conducted with lifitegrast ophthalmic solution, 1401 patients received at least 1 dose of lifitegrast (1287 of which received lifitegrast 5%). The majority of patients (84%) had ≤ 3 months of treatment exposure. 170 patients were exposed to lifitegrast for approximately 12 months. The majority of the treated patients were female (77%). The most common adverse reactions reported in 5-25 % of patients were instillation site irritation, dysgeusia and reduced visual acuity. Other adverse reactions reported in 1% to 5% of the patients were blurred vision, conjunctival hyperemia, eye irritation, headache, increased lacrimation, eye discharge, eye discomfort, eye pruritus and sinusitis.

Postmarketing Experience

The following adverse reactions have been identified during postapproval use of Xiidra. Because these reactions are reported voluntarily from a population of uncertain size, it is not always possible to reliably estimate their frequency or establish a causal relationship to drug exposure.

Rare cases of hypersensitivity, including anaphylactic reaction, bronchospasm, respiratory distress, pharyngeal edema, swollen tongue, and urticaria have been reported. Eye swelling and rash have been reported.

USE IN SPECIFIC POPULATIONS

Pregnancy

There are no available data on Xiidra use in pregnant women to inform any drug associated risks. Intravenous (IV) administration of lifitegrast to pregnant rats, from pre-mating through gestation day 17, did not produce teratogenicity at clinically relevant systemic exposures. Intravenous administration of lifitegrast to pregnant rabbits during organogenesis produced an increased incidence of omphalocele at the lowest dose

tested, 3 mg/kg/day (400-fold the human plasma exposure at the recommended human ophthalmic dose [RHOD], based on the area under the curve [AUC] level). Since human systemic exposure to lifitegrast following ocular administration of Xiidra at the RHOD is low, the applicability of animal findings to the risk of Xiidra use in humans during pregnancy is unclear.

Animal Data

Lifitegrast administered daily by intravenous (IV) injection to rats, from pre-mating through gestation day 17, caused an increase in mean preimplantation loss and an increased incidence of several minor skeletal anomalies at 30 mg /kg / day, representing 5,400-fold the human plasma exposure at the RHOD of Xiidra, based on AUC. No teratogenicity was observed in the rat at 10 mg /kg /day (460-fold the human plasma exposure at the RHOD, based on AUC). In the rabbit, an increased incidence of omphalocele was observed at the lowest dose tested, 3 mg /kg /day (400-fold the human plasma exposure at the RHOD, based on AUC), when administered by IV injection daily from gestation days 7 through 19. A fetal No Observed Adverse Effect Level (NOAEL) was not identified in the rabbit.

Lactation

There are no data on the presence of lifitegrast in human milk, the effects on the breastfed infant, or the effects on milk production. However, systemic exposure to lifitegrast from ocular administration is low. The developmental and health benefits of breastfeeding should be considered, along with the mother's clinical need for Xiidra and any potential adverse effects on the breastfed child from Xiidra.

Pediatric Use

Safety and efficacy in pediatric patients below the age of 17 years have not been established.

Geriatric Use

No overall differences in safety or effectiveness have been observed between elderly and younger adult patients.

NONCLINICAL TOXICOLOGY

Carcinogenesis, Mutagenesis, Impairment of Fertility

Carcinogenesis: Animal studies have not been conducted to determine the carcinogenic potential of lifitegrast.

Mutagenesis: Lifitegrast was not mutagenic in the *in vitro* Ames assay. Lifitegrast was not clastogenic in the *in vivo* mouse micronucleus assay. In an *in vitro* chromosomal aberration assay using mammalian cells (Chinese hamster ovary cells), lifitegrast was positive at the highest concentration tested, without metabolic activation.

Impairment of fertility: Lifitegrast administered at intravenous (IV) doses of up to 30 mg/kg/day (5400-fold the human plasma exposure at the recommended human ophthalmic dose (RHOD) of lifitegrast ophthalmic solution, 5%) had no effect on fertility and reproductive performance in male and female treated rats.



Manufactured for: Shire US Inc., 300 Shire Way, Lexington, MA 02421. For more information, go to www.Xiidra.com or call 1-800-828-2088. Marks designated ® and ™ are owned by Shire or an affiliated company. ©2018 Shire US Inc. SHIRE and the Shire Logo are trademarks or registered trademarks of Shire Pharmaceutical Holdings Ireland Limited or its affiliates. Patented: please see <https://www.shire.com/legal-notice/product-patents> Last Modified: 01/2018 S33769



MAKE XIIDRA YOUR FIIIRST CHOICE

When artificial tears aren't enough, consider prescribing Xiidra for symptomatic Dry Eye patients.

Proven to treat the signs of inferior corneal staining in 12 weeks and symptoms of eye dryness in 12, 6, and as little as 2.

Xiidra helped provide symptom relief from eye dryness in some patients at week 2—and a measurable reduction in signs of inferior corneal staining in just 12 weeks. Consider Xiidra to help your Dry Eye patients find the relief they've been waiting for.

Check it out at Xiidra-ECP.com

Four randomized, double-masked, 12-week trials evaluated the efficacy and safety of Xiidra versus vehicle as assessed by improvement in the signs (measured by Inferior Corneal Staining Score) and symptoms (measured by Eye Dryness Score) of Dry Eye Disease (N=2133).

Indication

Xiidra® (lifitegrast ophthalmic solution) 5% is indicated for the treatment of signs and symptoms of dry eye disease (DED).

Important Safety Information

Xiidra is contraindicated in patients with known hypersensitivity to lifitegrast or to any of the other ingredients.

In clinical trials, the most common adverse reactions reported in 5-25% of patients were instillation site irritation, dysgeusia and reduced visual acuity. Other adverse reactions reported in 1% to 5% of the patients were blurred vision, conjunctival hyperemia, eye irritation, headache, increased lacrimation, eye discharge, eye discomfort, eye pruritus and sinusitis.

To avoid the potential for eye injury or contamination of the solution, patients should not touch the tip of the single-use container to their eye or to any surface.

Contact lenses should be removed prior to the administration of Xiidra and may be reinserted 15 minutes following administration.

Safety and efficacy in pediatric patients below the age of 17 years have not been established.

For additional safety information, see accompanying Brief Summary of Safety Information on the adjacent page and Full Prescribing Information on Xiidra-ECP.com.