

TACKLING PREOP ALLERGY P. 16 • PEEKING INTO THE WET AMD PIPELINE P. 20
TREATING UVEITIC GLAUCOMA P. 48 • AN UPDATE ON THE IRIS REGISTRY P. 53
REVIEWING THE LATEST RESEARCH P. 56 • WILLS RESIDENT CASE REPORT P. 63

REVIEW[®] of Ophthalmology

March 2018

reviewofophthalmology.com

ANNUAL CATARACT SURGERY ISSUE

Cataract Surgery: Sharpen Your Edge

An in-depth look at the tools and techniques surgeons are using to hone their outcomes.

- After Surgery: Shots, Drops or Both? **P. 26**
- Is There Still a Place for Monofocal Toric IOLs? **P. 32**
- How to Make the Most of Today's Biometry Tech **P. 36**
- Cataract Surgery Survey: Surgeons Slow to Embrace New Tech **P. 44**



Indications and Usage

BromSite® (bromfenac ophthalmic solution) 0.075% is a nonsteroidal anti-inflammatory drug (NSAID) indicated for the treatment of postoperative inflammation and prevention of ocular pain in patients undergoing cataract surgery.

Recommended Dosing

One drop of BromSite® should be applied to the affected eye twice daily (morning and evening) 1 day prior to surgery, the day of surgery, and 14 days postsurgery.

Important Safety Information

- **Slow or Delayed Healing:** All topical nonsteroidal anti-inflammatory drugs (NSAIDs), including BromSite®, may slow or delay healing. Topical corticosteroids are also known to slow or delay healing. Concomitant use of topical NSAIDs and topical steroids may increase the potential for healing problems.
- **Potential for Cross-Sensitivity:** There is the potential for cross-sensitivity to acetylsalicylic acid, phenylacetic acid derivatives, and other NSAIDs, including BromSite®.

Therefore, caution should be used when treating individuals who have previously exhibited sensitivities to these drugs.

- **Increased Bleeding Time of Ocular Tissue:** With some NSAIDs, including BromSite®, there exists the potential for increased bleeding time due to interference with platelet aggregation. There have been reports that ocularly applied NSAIDs may cause increased bleeding of ocular tissues (including hyphemas) in conjunction with ocular surgery. It is recommended that BromSite® be used with caution in patients with known bleeding tendencies or who are receiving other medications which may prolong bleeding time.
- **Keratitis and Corneal Effects:** Use of topical NSAIDs may result in keratitis. In some susceptible patients, continued use of topical NSAIDs may result in epithelial breakdown, corneal thinning, corneal erosion, corneal ulceration or corneal perforation. Patients with evidence

The **FIRST** and **ONLY** NSAID indicated to prevent ocular pain in cataract surgery patients¹

A DROP OF PREVENTION

FOR YOUR CATARACT SURGERY PATIENTS

Defend against ocular pain and combat postoperative inflammation with the penetrating power of BromSite[®] formulated with DuraSite[®]¹

- DuraSite[®] increases ocular surface retention time, resulting in increased bromfenac absorption²⁻⁵
- Provides 24-hour coverage with BID dosing¹
- Available in 5 mL bottle

Visit bromsite.com to find out more.

BromSITE[®]
(bromfenac ophthalmic solution) 0.075%

Formulated with **DURASITE[®]** DELIVERY SYSTEM

of corneal epithelial breakdown should immediately discontinue use of topical NSAIDs, including BromSite[®], and should be closely monitored for corneal health. Patients with complicated ocular surgeries, corneal denervation, corneal epithelial defects, diabetes mellitus, ocular surface diseases (e.g., dry eye syndrome), rheumatoid arthritis, or repeat ocular surgeries within a short period of time may be at increased risk for corneal adverse events which may become sight threatening. Topical NSAIDs should be used with caution in these patients. Post-marketing experience with topical NSAIDs also suggests that use more than 24 hours prior to surgery or use beyond 14 days postsurgery may increase patient risk for the occurrence and severity of corneal adverse events.

- **Contact Lens Wear:** BromSite[®] should not be administered while wearing contact lenses. The preservative in BromSite[®], benzalkonium chloride, may be absorbed by soft contact lenses.

- **Adverse Reactions:** The most commonly reported adverse reactions in 1% to 8% of patients were anterior chamber inflammation, headache, vitreous floaters, iritis, eye pain, and ocular hypertension.

Please see brief summary of Full Prescribing Information on the adjacent page.

NSAID=nonsteroidal anti-inflammatory drug.

References: 1. BromSite[®] [package insert]. Cranbury, NJ: Sun Pharmaceutical Industries, Inc.; 2016. 2. Hosseini K, Hutcheson J, Bowman L. Aqueous humor concentration of bromfenac 0.09% (Bromday[™]) compared with bromfenac in DuraSite[®] 0.075% (BromSite[™]) in cataract patients undergoing phacoemulsification after 3 days dosing. Poster presented at: ARVO Annual Meeting; May 5-9, 2013; Seattle, Washington. 3. ClinicalTrials.gov. Aqueous humor concentration of InSite Vision (ISV) 303 (bromfenac in DuraSite) to Bromday once daily (QD) prior to cataract surgery. <https://clinicaltrials.gov/ct2/show/results/NCT01387464?sect=X70156&term=insite+vision&rank=1>. Accessed March 2, 2017. 4. Si EC, Bowman LM, Hosseini K. Pharmacokinetic comparisons of bromfenac in DuraSite and Xibrom. *J Ocul Pharmacol Ther.* 2011;27(1):61-66. 5. Bowman LM, Si E, Pang J, et al. Development of a topical polymeric mucoadhesive ocular delivery system for azithromycin. *J Ocul Pharmacol Ther.* 2009;25(2):133-139.

Sun Ophthalmics is a division of Sun Pharmaceutical Industries, Inc. © 2017 Sun Pharmaceutical Industries, Inc. All rights reserved. BromSite and DuraSite are registered trademarks of Sun Pharma Global FZE. SUN-OPH-BRO-219 03/2017



BromSite® (bromfenac ophthalmic solution) 0.075%

Brief Summary

INDICATIONS AND USAGE

BromSite® (bromfenac ophthalmic solution) 0.075% is indicated for the treatment of postoperative inflammation and prevention of ocular pain in patients undergoing cataract surgery.

CONTRAINDICATIONS

None

WARNINGS AND PRECAUTIONS

Slow or Delayed Healing

All topical nonsteroidal anti-inflammatory drugs (NSAIDs), including BromSite® (bromfenac ophthalmic solution) 0.075%, may slow or delay healing. Topical corticosteroids are also known to slow or delay healing. Concomitant use of topical NSAIDs and topical steroids may increase the potential for healing problems.

Potential for Cross-Sensitivity

There is the potential for cross-sensitivity to acetylsalicylic acid, phenylacetic acid derivatives, and other NSAIDs, including BromSite® (bromfenac ophthalmic solution) 0.075%. Therefore, caution should be used when treating individuals who have previously exhibited sensitivities to these drugs.

Increased Bleeding Time of Ocular Tissue

With some NSAIDs, including BromSite® (bromfenac ophthalmic solution) 0.075%, there exists the potential for increased bleeding time due to interference with platelet aggregation. There have been reports that ocularly applied NSAIDs may cause increased bleeding of ocular tissues (including hyphemas) in conjunction with ocular surgery.

It is recommended that BromSite® be used with caution in patients with known bleeding tendencies or who are receiving other medications which may prolong bleeding time.

Keratitis and Corneal Reactions

Use of topical NSAIDs may result in keratitis. In some susceptible patients, continued use of topical NSAIDs may result in epithelial breakdown, corneal thinning, corneal erosion, corneal ulceration or corneal perforation. These events may be sight threatening. Patients with evidence of corneal epithelial breakdown should immediately discontinue use of topical NSAIDs, including BromSite® (bromfenac ophthalmic solution) 0.075%, and should be closely monitored for corneal health.

Post-marketing experience with topical NSAIDs suggests that patients with complicated ocular surgeries, corneal denervation, corneal epithelial defects, diabetes mellitus, ocular surface diseases (e.g., dry eye syndrome), rheumatoid arthritis, or repeat ocular surgeries within a short period of time may be at increased risk for corneal adverse events which may become sight threatening. Topical NSAIDs should be used with caution in these patients.

Post-marketing experience with topical NSAIDs also suggests that use more than 24 hours prior to surgery or use beyond 14 days postsurgery may increase patient risk for the occurrence and severity of corneal adverse events.

Contact Lens Wear

BromSite® should not be administered while wearing contact lenses. The preservative in BromSite®, benzalkonium chloride, may be absorbed by soft contact lenses.

ADVERSE REACTIONS

The following serious adverse reactions are described elsewhere in the Brief Summary:

- Slow or Delayed Healing
- Potential for Cross-Sensitivity
- Increased Bleeding Time of Ocular Tissue
- Keratitis and Corneal Reactions
- Contact Lens Wear

Clinical Trial Experience

Because clinical trials are conducted under widely varying conditions, adverse reaction rates observed in the clinical trials of a drug cannot be directly compared to rates in the clinical trials of another drug and may not reflect the rates observed in clinical practice.

The most commonly reported adverse reactions in 1–8% of patients were: anterior chamber inflammation, headache, vitreous floaters, iritis, eye pain and ocular hypertension.

USE IN SPECIFIC POPULATIONS

Pregnancy

Risk Summary

There are no adequate and well-controlled studies in pregnant women to inform any drug associated risks. Treatment of pregnant rats and rabbits with oral bromfenac did not produce teratogenic effects at clinically relevant doses.

Clinical Considerations

Because of the known effects of prostaglandin biosynthesis-inhibiting drugs on the fetal cardiovascular system (closure of ductus arteriosus), the use of BromSite® during late pregnancy should be avoided.

Data

Animal Data

Treatment of rats with bromfenac at oral doses up to 0.9 mg/kg/day (195 times a unilateral daily human ophthalmic dose on a mg/m² basis, assuming 100% absorbed) and rabbits at oral doses up to 7.5 mg/kg/day (3243 times a unilateral daily dose on a mg/m² basis) produced no structural teratogenicity in reproduction studies. However, embryo-fetal lethality, neonatal mortality and reduced postnatal growth were produced in rats at 0.9 mg/kg/day, and embryo-fetal lethality was produced in rabbits at 7.5 mg/kg/day. Because animal reproduction studies are not always predictive of human response, this drug should be used during pregnancy only if the potential benefit justifies the potential risk to the fetus.

Lactation

There are no data on the presence of bromfenac in human milk, the effects on the breastfed infant, or the effects on milk production; however, systemic exposure to bromfenac from ocular administration is low. The developmental and health benefits of breastfeeding should be considered along with the mother's clinical need for bromfenac and any potential adverse effects on the breast-fed child from bromfenac or from the underlying maternal condition.

Pediatric Use

Safety and efficacy in pediatric patients below the age of 18 years have not been established.

Geriatric Use

There is no evidence that the efficacy or safety profiles for BromSite® differ in patients 65 years of age and older compared to younger adult patients.

NONCLINICAL TOXICOLOGY

Carcinogenesis, Mutagenesis and Impairment of Fertility

Long-term carcinogenicity studies in rats and mice given oral doses of bromfenac up to 0.6 mg/kg/day (129 times a unilateral daily dose assuming 100% absorbed, on a mg/m² basis) and 5 mg/kg/day (540 times a unilateral daily dose on a mg/m² basis), respectively revealed no significant increases in tumor incidence.

Bromfenac did not show mutagenic potential in various mutagenicity studies, including the bacterial reverse mutation, chromosomal aberration, and micronucleus tests.

Bromfenac did not impair fertility when administered orally to male and female rats at doses up to 0.9 mg/kg/day and 0.3 mg/kg/day, respectively (195 and 65 times a unilateral daily dose, respectively, on a mg/m² basis).

Rx Only

Distributed by: Sun Pharmaceutical Industries, Inc. Cranbury, NJ 08512

Survey Shows Ophthalmology's EHR Growing Pains

In February, *JAMA Ophthalmology* published a survey authored by Michele Lim, MD, UC Davis Health, regarding doctor perceptions of electronic health records systems.

In the population-based, cross-sectional study,¹ researchers looked at a random sample of ophthalmologists from the American Academy of Ophthalmology's active membership database. They found that the adoption rate of EHRs among the 348 responding ophthalmologists was 72.1 percent. The study determined, however, that despite the EHR adoption rate doubling since a previous survey in 2011, ophthalmologists report that net revenues and productivity declined and that practice costs rose with EHR use.

When asked about these surprising results, Dr. Lim says, "It's interesting because metrics like the number of patients seen and revenues did not actually seem to change much after implementing EHRs. I think the most surprising thing is [finding out] that both of those changed for the negative. I would expect that to be a little more mixed.

"It's pretty easy to imagine the rising costs that these EHR systems bring," Dr. Lim continues. "You have to pay for expensive hardware equipment that you previously haven't had to. Paper charts are a lot cheaper. Even though you can downsize people in terms of having to curate paper charts, you have to upsize positions

where people monitor these systems, and that obviously takes a lot more skill. You're hiring higher-skilled people who are going to cost more. Every practice using a cloud-based solution needs a network specialist to



help them deal with all the intricacies of that, so the rising costs aren't much of a surprise. It's just something you have to keep in mind when implementing these systems."

In terms of suggestions or solutions to help ophthalmologists better use these systems, Dr. Lim offers some advice. "I'm hoping that we, the Academy and other ophthalmologist groups, use this paper as a point at which we can begin to have a conversation, and to realize that there's a growing sentiment among ophthalmologists that EHRs are not efficient because they may not be necessarily following what physicians would do naturally in their practices," she says.

"Some things need to be more intuitive. For example, why is it so hard to write a letter to a referring doctor? It definitely takes a lot of stakeholders to engage in trying to build a better system, however, so we hope that this paper starts that process.

"Some of that is on us as doctors, but there is definitely room for improvement with some of these systems," Dr. Lim adds. "Programs like meaningful use (the federal incentive) seem to be detrimental in a lot of ways. On the one hand, it was great because there was a clear explosion of EHR use after those incentives and penalties came out. However, I think that when that happened, EHR vendors paid too much attention to system design to just satisfy the meaningful-use reporting and

turned their attention away from the workflow-efficiency aspect of these systems. It's as if we've been focusing on the wrong thing. So there's room for improvement, ideally with feedback from the doctors that are using these systems."

A representative from a company that engineers these EHR systems—who chose to remain anonymous—weighed in on the results of the study. "It is surprising to see," he says. "Obviously when you design and sell these programs, you expect them to succeed, so you hate to see something like that. But at the same time, we have standards and incentives that we have to meet with these programs. It's

Editor in Chief

Walter C. Bethke
(610) 492-1024
wbethke@jobson.com

Senior Editor

Christopher Kent
(814) 861-5559
ckent@jobson.com

Senior Associate Editor

Kristine Brennan
(610) 492-1008
kbrennan@jobson.com

Associate Editor

Liam Jordan
(610) 492-1025
ljordan@jobson.com

Chief Medical Editor

Mark H. Blecher, MD

Art Director

Jared Araujo
(610) 492-1032
jaraujo@jobson.com

Senior Graphic Designer

Matt Egger
(610) 492-1029
megger@jobson.com

International coordinator, Japan

Mitz Kaminuma
Reviewophthalgo@aol.com

Business Offices

11 Campus Boulevard, Suite 100
Newtown Square, PA 19073
(610) 492-1000
Fax: (610) 492-1039

Subscription inquiries:

United States — (877) 529-1746
Outside U.S. — (845) 267-3065

E-mail:

revophthalmology@cambeywest.com

Website: www.reviewofophthalmology.com



just difficult to nail down what's working and what isn't when we don't tangibly see how it affects or betters a practice. But this study is starting to reveal those effects, so there will certainly be interesting discussions going forward as to how we can modify and optimize our programs. Hopefully we will be working closely with physicians to see how to best optimize the programs for their practices."

Another representative, also anonymous, from a competing company shared his thoughts about the study, saying, "Honestly, we're not seeing a lot of complaints with our system. There are definitely things we can tweak, but we try to consistently update our EHR. I think a lot of these surprising results fall to the doctors who are using the systems. Maybe they're just not using the systems efficiently, or don't have a staff that understands or takes advantage of the systems. We have absolutely seen it work in practices. There's a learning curve, but there's not much we can do about that on our end."

1. Lim MC, Boland MV, McCannel CA, et al. Adoption of electronic health records and perceptions of financial and clinical outcomes among ophthalmologists in the United States. *JAMA Ophthalmol* 2018;136:2:164-170.

ReVision Shuts Down

In late January, ReVision Optics, maker of the Raindrop corneal inlay for the treatment of presbyopia, closed its doors. The Raindrop was only the second such inlay approved in the United States, and the shuttering leaves the AcuFocus Kamra inlay as the only approved corneal device available for this indication in the U.S.

Patients or physicians who visited the ReVision homepage the day of the closure were met with this message from the company: "ReVision Optics, the maker of the Raindrop Near Vi-

sion Inlay, made great strides to build a market for the surgical correction of presbyopia, but respectful of our best efforts, it is with regret that we have to close our doors. The Raindrop Inlay will not be sold to ophthalmic practices or distributors as of Tuesday, January 30, 2018. As a result, the Raindrop Rebate will not be honored past this date. To address any questions you may have in the near-term, we have established a Hotline Number, 1-866-934-6592, which will be staffed through April 30, 2018 ..."

John Hovanesian, MD, a Raindrop user who also participated in the inlay's FDA trial, says his experience was positive, but that the inlay may have faced an uphill battle from the start. "The decision by ReVision Optics' board to close their operation is an unfortunate side effect of too-slow market adoption of a new technology," he says. "From my perspective as a user of their products, an investigator in two of their trials and a close advisor to the company, I have always been impressed with their management, their research and development group, and their commercial operations. The technology itself was a good performer—good enough that I implanted two inlays in close, personal friends, both of whom were quite happy. Personally, I believe the slow adoption of the Raindrop inlay was attributable to the 'competition' of LASIK and premium IOLs' great results. While neither procedure is ideally suited to the emmetropic presbyope who was a candidate for Raindrop, both have received wide public acceptance and adoption by surgeons. In addition, achieving a quiet eye with the Raindrop inlay required more follow-up and diligence after surgery than other refractive procedures.

"AcuFocus has an aperture IOL in the pipeline that, if approved, may pave the way for broader acceptance of small-aperture inlays," he continues. "That may be our best hope of having broad market acceptance of inlay procedures." **REVIEW**

CUTS
ENERGY

CUTS
TIME

CUTS
STRESS AND

CUTS
CATARACTS

INTRODUCING A **PEN-LIKE DEVICE** FOR ZERO-ENERGY LENS FRAGMENTATION



ianTECH PRESENTS

MAKING THE CUT

BRINGING A **MICRO-INTERVENTIONAL APPROACH** TO CATARACT SURGEONS **SUPER-ELASTIC MEMORY SHAPED NITINOL** FILAMENT DESIGNED FOR **CONSISTENT, FULL THICKNESS** FRAGMENTATION **OUT-TO-IN CENTRIPAL DISSECTING** ACTION DESIGNED TO **REDUCE FORCE** ON CAPSULAR BAG AND ZONULES

Go to www.iantechmed.com to see surgical videos and request miLOOP for your upcoming cases

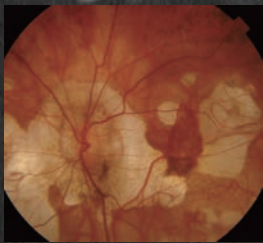
NOW PLAYING AT A SURGICAL THEATER NEAR YOU

data on file ©2018 ianTECH all rights reserved

It's time for Triton.

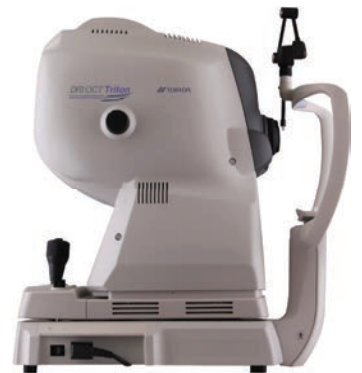It's all about the light source.

FDA CLEARED



SS-OCT

Contact your local Topcon Representative today or visit [newsgram.topconmedical.com/triton](https://www.newsgram.topconmedical.com/triton).



DRI OCT Triton™ Series
A Multimodal Swept Source OCT

CONTRIBUTORS

CHIEF MEDICAL EDITOR

Mark H. Blecher, MD

CONTACT LENSES

Penny Asbell, MD

CORNEA / ANTERIOR SEGMENT

Thomas John, MD

GLAUCOMA MANAGEMENT

Peter Netland, MD, PHD
Kuldev Singh, MD

MASTERS OF SURGERY

Taliva D. Martin, MD
Sara J. Haug, MD, PhD

MEDICARE Q & A

Paul M. Larson, MBA

PEDIATRIC PATIENT

Wendy Huang, MD

PLASTIC POINTERS

Ann P. Murchison, MD, MPH

REFRACTIVE SURGERY

Arturo S. Chayet, MD

RETINAL INSIDER

Carl Regillo, MD, FACS
Emmett T. Cunningham Jr., MD, PHD, MPH

TECHNOLOGY UPDATE

Steven T. Charles, MD
Michael Colvard, MD

WILLS RESIDENT CASE SERIES

Thomas Jenkins, MD.

ADVISORY BOARD

PENNY A. ASBELL, MD, NEW YORK CITY

WILLIAM I. BOND, MD, PEKIN, ILL.

ALAN N. CARLSON, MD, DURHAM, N.C.

Y. RALPH CHU, MD, EDINA, MINN.

ADAM J. COHEN, MD, DOWNERS GROVE, ILL.

UDAY DEVGAN, MD, FACS, LOS ANGELES

ERIC DONNENFELD, MD, ROCKVILLE CENTRE, N.Y.

DANIEL S. DURRIE, MD, KANSAS CITY, MO.

ROBERT EPSTEIN, MD, MCHENRY, ILL.

ROBERT D. FECHTNER, MD, NEWARK, N.J.

WILLIAM J. FISHKIND, MD, TUCSON, ARIZ.

JAMES P. GILLS, MD, TARPON SPRINGS, FLA.

HARRY GRABOW, MD, SARASOTA, FLA.

DOUGLAS K. GRAYSON, MD, NEW YORK CITY

THOMAS S. HARBIN, MD, MBA, ATLANTA

DAVID R. HARDTEN, MD, MINNEAPOLIS

KENNETH J. HOFFER, MD, SANTA MONICA, CALIF.

JACK T. HOLLADAY, MD, MSEE, HOUSTON

JOHN D. HUNKELER, MD, KANSAS CITY, MO.

THOMAS JOHN, MD, TINLEY PARK, ILL.

ROBERT M. KERSHNER, MD, MS, FACS, BOSTON

GUY M. KEZIRIAN, MD, PARADISE VALLEY, ARIZ.

TERRY KIM, MD, DURHAM, N.C.

TOMMY KORN, MD, SAN DIEGO

DAVID A. LEE, MD, HOUSTON

FRANCIS S. MAH, MD, PITTSBURGH

NICK MAMALIS, MD, SALT LAKE CITY

WILLIAM G. MARTIN, MD, OREGON, OHIO

MIKE S. MCFARLAND, MD, PINE BLUFF, ARK.

JEFFREY B. MORRIS, MD, MPH, ENCINITAS, CALIF.

MARLENE R. MOSTER, MD, PHILADELPHIA

ROBERT J. NOECKER, MD, FAIRFIELD, CONN.

ROBERT OSHER, MD, CINCINNATI

MARK PACKER, MD, WEST PALM BEACH, FLA.

STEPHEN PASCUCCI, MD, BONITA SPRINGS, FLA.

PAUL PENDER, MD, BEDFORD, N.H.

CHRISTOPHER J. RAPUANO, MD, PHILADELPHIA

AUGUST READER III, MD, SAN FRANCISCO

TONY REALINI, MD, MORGANTOWN, W.V.

KENNETH J. ROSENTHAL, MD, GREAT NECK, N.Y.

ERIC ROTHCHILD, MD, DELRAY BEACH, FLA.

SHERI ROWEN, MD, BALTIMORE

JAMES J. SALZ, MD, LOS ANGELES

INGRID U. SCOTT, MD, MPH, HERSHEY, PA.

JOEL SCHUMAN, MD, PITTSBURGH

GAURAV SHAH, MD, ST. LOUIS

DAVID R. STAGER JR., MD, DALLAS

KARL STONECIPHER, MD, GREENSBORO, N.C.

JAMES C. TSAI, MD, NEW YORK CITY

VANCE THOMPSON, MD, SIOUX FALLS, S.D.

FARRELL C. TYSON, MD, CAPE CORAL, FLA.

R. BRUCE WALLACE III, MD, ALEXANDRIA, LA.

ROBERT G. WILEY, MD, CLEVELAND

FRANK WEINSTOCK, MD, CANTON, OHIO

BUSINESS OFFICES

11 CAMPUS BOULEVARD, SUITE 100
NEWTOWN SQUARE, PA 19073
SUBSCRIPTION INQUIRIES (877) 529-1746
(USA ONLY); OUTSIDE USA, CALL (847) 763-9630

BUSINESS STAFF

PUBLISHER

JAMES HENNE

(610) 492-1017 JHENNE@JOBSON.COM

REGIONAL SALES MANAGER

MICHELE BARRETT

(610) 492-1014 MBARRETT@JOBSON.COM

REGIONAL SALES MANAGER

MICHAEL HOSTER

(610) 492-1028 MHOSTER@JOBSON.COM

CLASSIFIED ADVERTISING

(888)-498-1460

VICE PRESIDENT OF OPERATIONS

CASEY FOSTER

(610) 492-1007 CFOSTER@JOBSON.COM

PRODUCTION MANAGER

SCOTT TOBIN

(610) 492-1011 STOBIN@JOBSON.COM

SUBSCRIPTIONS

\$63 A YEAR, \$99 (U.S.) IN CANADA,
\$158 (U.S.) IN ALL OTHER COUNTRIES.

SUBSCRIPTIONS E-MAIL:

REVOPHTHALMOLOGY@CAMBEYWEST.COM

CIRCULATION

PO BOX 71, CONGERS, NY 10920-0071
(877) 529-1746

OUTSIDE USA: (845) 267-3065

SENIOR CIRCULATION MANAGER

HAMILTON MAHER

(212) 219-7870 hmaher@jhihealth.com

CEO, INFORMATION GROUP SERVICES

MARC FERRARA

SENIOR VICE PRESIDENT, OPERATIONS

JEFF LEVITZ

VICE PRESIDENT, HUMAN RESOURCES

TAMMY GARCIA

VICE PRESIDENT, CREATIVE SERVICES & PRODUCTION

MONICA TETTAMANZI

CORPORATE PRODUCTION DIRECTOR

JOHN ANTHONY CAGGIANO

VICE PRESIDENT, CIRCULATION

EVELDA BAREA



440 Ninth Avenue, 14th Floor
New York, N.Y. 10001

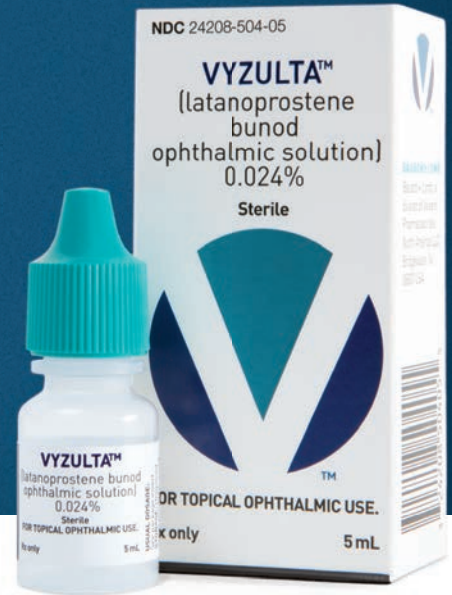REVIEW OF OPHTHALMOLOGY (ISSN 1081-0226; USPS No. 0012-345) is published monthly, 12 times per year by Jobson Medical Information, 440 Ninth Avenue, 14th Floor, New York, N.Y. 10001. Periodicals postage paid at New York, NY and additional mailing offices. Postmaster: Send address changes to Review of Ophthalmology, PO Box 71, Congers, NY 10929-0071. Subscription Prices: US One Year \$63.00, US Two Year \$112.00, Canada One Year \$99.00, Canada Two Year \$181.00, Int'l One Year \$158.00, Int'l Two Year \$274.00. For subscription information call (877) 529-1746 (USA only); outside USA, call (845)-267-3065. Or email us at revophthalmology@cambeywest.com. Canada Post: Publications Mail Agreement #40612608. Canada Returns to be sent to Bleuchip International, P.O. Box 25542, London, ON N6C 6B2.

VYZULTA™
(latanoprostene
bunod ophthalmic
solution), 0.024%

VYZULTA

NOW AVAILABLE

IN PHARMACIES NATIONWIDE



YOU CAN NOW START PRESCRIBING VYZULTA FOR YOUR GLAUCOMA PATIENTS.

- > VYZULTA delivers a dual mechanism of action for the reduction of IOP in glaucoma patients¹
- > VYZULTA coupons are available for eligible patients
- > There is no A/B generic equivalent to VYZULTA. Please share this information with your patients in case they experience a switch at the pharmacy

For more information about VYZULTA, visit vyzultanow.com

INDICATION

VYZULTA™ (latanoprostene bunod ophthalmic solution), 0.024% is indicated for the reduction of intraocular pressure (IOP) in patients with open-angle glaucoma or ocular hypertension.

IMPORTANT SAFETY INFORMATION

- Increased pigmentation of the iris and periorbital tissue (eyelid) can occur. Iris pigmentation is likely to be permanent
- Gradual changes to eyelashes, including increased length, increased thickness, and number of eyelashes, may occur. These changes are usually reversible upon treatment discontinuation
- Use with caution in patients with a history of intraocular inflammation (iritis/uveitis). VYZULTA should generally not be used in patients with active intraocular inflammation
- Macular edema, including cystoid macular edema, has been reported during treatment with prostaglandin analogs. Use with caution in aphakic patients, in pseudophakic patients with a torn posterior lens capsule, or in patients with known risk factors for macular edema
- There have been reports of bacterial keratitis associated with the use of multiple-dose containers of topical ophthalmic products that were inadvertently contaminated by patients
- Contact lenses should be removed prior to the administration of VYZULTA and may be reinserted 15 minutes after administration
- Most common ocular adverse reactions with incidence $\geq 2\%$ are conjunctival hyperemia (6%), eye irritation (4%), eye pain (3%), and instillation site pain (2%)

REFERENCE

1. VYZULTA Prescribing Information. Bausch & Lomb Incorporated. 2017.

BAUSCH + LOMB

VYZULTA and the V design are trademarks of Bausch & Lomb Incorporated or its affiliates. ©2017 Bausch & Lomb Incorporated. All rights reserved. VYZ.0351.USA.17

For more information, please see Brief Summary of Prescribing Information on next page.

BRIEF SUMMARY OF PRESCRIBING INFORMATION

This Brief Summary does not include all the information needed to use VYZULTA safely and effectively. See full Prescribing Information for VYZULTA.

VYZULTA™ (latanoprostene bunod ophthalmic solution), 0.024%, for topical ophthalmic use.

Initial U.S. Approval: 2017

1 INDICATIONS AND USAGE

VYZULTA™ (latanoprostene bunod ophthalmic solution) 0.024% is indicated for the reduction of intraocular pressure (IOP) in patients with open-angle glaucoma or ocular hypertension.

4 CONTRAINDICATIONS

None

5 WARNINGS AND PRECAUTIONS

5.1 Pigmentation

VYZULTA™ (latanoprostene bunod ophthalmic solution), 0.024% may cause changes to pigmented tissues. The most frequently reported changes with prostaglandin analogs have been increased pigmentation of the iris and periocular tissue (eyelid).

Pigmentation is expected to increase as long as latanoprostene bunod ophthalmic solution is administered. The pigmentation change is due to increased melanin content in the melanocytes rather than to an increase in the number of melanocytes. After discontinuation of VYZULTA, pigmentation of the iris is likely to be permanent, while pigmentation of the periocular tissue and eyelash changes are likely to be reversible in most patients. Patients who receive prostaglandin analogs, including VYZULTA, should be informed of the possibility of increased pigmentation, including permanent changes. The long-term effects of increased pigmentation are not known.

Iris color change may not be noticeable for several months to years. Typically, the brown pigmentation around the pupil spreads concentrically towards the periphery of the iris and the entire iris or parts of the iris become more brownish. Neither nevi nor freckles of the iris appear to be affected by treatment. While treatment with VYZULTA™ (latanoprostene bunod ophthalmic solution), 0.024% can be continued in patients who develop noticeably increased iris pigmentation, these patients should be examined regularly [see Patient Counseling Information (17) in full Prescribing Information].

5.2 Eyelash Changes

VYZULTA may gradually change eyelashes and vellus hair in the treated eye. These changes include increased length, thickness, and the number of lashes or hairs. Eyelash changes are usually reversible upon discontinuation of treatment.

5.3 Intraocular Inflammation

VYZULTA should be used with caution in patients with a history of intraocular inflammation (iritis/uveitis) and should generally not be used in patients with active intraocular inflammation as it may exacerbate this condition.

5.4 Macular Edema

Macular edema, including cystoid macular edema, has been reported during treatment with prostaglandin analogs. VYZULTA should be used with caution in aphakic patients, in pseudophakic patients with a torn posterior lens capsule, or in patients with known risk factors for macular edema.

5.5 Bacterial Keratitis

There have been reports of bacterial keratitis associated with the use of multiple-dose containers of topical ophthalmic products. These containers had been inadvertently contaminated by patients who, in most cases, had a concurrent corneal disease or a disruption of the ocular epithelial surface.

5.6 Use with Contact Lens

Contact lenses should be removed prior to the administration of VYZULTA because this product contains benzalkonium chloride. Lenses may be reinserted 15 minutes after administration.

6 ADVERSE REACTIONS

The following adverse reactions are described in the Warnings and Precautions section: pigmentation (5.1), eyelash changes (5.2), intraocular inflammation (5.3), macular edema (5.4), bacterial keratitis (5.5), use with contact lens (5.6).

6.1 Clinical Trials Experience

Because clinical trials are conducted under widely varying conditions, adverse reaction rates observed in the clinical trials of a drug cannot be directly compared to rates in the clinical trials of another drug and may not reflect the rates observed in practice.

VYZULTA was evaluated in 811 patients in 2 controlled clinical trials of up to 12 months duration. The most common ocular adverse reactions observed in patients treated with latanoprostene bunod were: conjunctival hyperemia (6%), eye irritation (4%), eye pain (3%), and instillation site pain (2%). Approximately 0.6% of patients discontinued therapy due to ocular adverse reactions including ocular hyperemia, conjunctival irritation, eye irritation, eye pain, conjunctival edema, vision blurred, punctate keratitis and foreign body sensation.

8 USE IN SPECIFIC POPULATIONS

8.1 Pregnancy

Risk Summary

There are no available human data for the use of VYZULTA during pregnancy to inform any drug associated risks.

Latanoprostene bunod has caused miscarriages, abortion, and fetal harm in rabbits. Latanoprostene bunod was shown to be abortifacient and teratogenic when administered intravenously (IV) to pregnant rabbits at exposures ≥ 0.28 times the clinical dose.

Doses ≥ 20 $\mu\text{g}/\text{kg}/\text{day}$ (23 times the clinical dose) produced 100% embryofetal lethality. Structural abnormalities observed in rabbit fetuses included anomalies of the great vessels and aortic arch vessels, domed head, sternebral and vertebral skeletal anomalies, limb hyperextension and malrotation, abdominal distension and edema. Latanoprostene bunod was not teratogenic in the rat when administered IV at 150 $\text{mcg}/\text{kg}/\text{day}$ (87 times the clinical dose) [see Data].

The background risk of major birth defects and miscarriage for the indicated population is unknown. However, the background risk in the U.S. general population of major birth defects is 2 to 4%, and of miscarriage is 15 to 20%, of clinically recognized pregnancies.

Data

Animal Data

Embryofetal studies were conducted in pregnant rabbits administered latanoprostene bunod daily by intravenous injection on gestation days 7 through 19, to target the period of organogenesis. The doses administered ranged from 0.24 to 80 $\text{mcg}/\text{kg}/\text{day}$. Abortion occurred at doses ≥ 0.24 $\text{mcg}/\text{kg}/\text{day}$ latanoprostene bunod (0.28 times the clinical dose, on a body surface area basis, assuming 100% absorption). Embryofetal lethality (resorption) was increased in latanoprostene bunod treatment groups, as evidenced by increases in early resorptions at doses ≥ 0.24 $\text{mcg}/\text{kg}/\text{day}$ and late resorptions at doses ≥ 6 $\text{mcg}/\text{kg}/\text{day}$ (approximately 7 times the clinical dose). No fetuses survived in any rabbit pregnancy at doses of 20 $\text{mcg}/\text{kg}/\text{day}$ (23 times the clinical dose) or greater. Latanoprostene bunod produced structural abnormalities at doses ≥ 0.24 $\text{mcg}/\text{kg}/\text{day}$ (0.28 times the clinical dose). Malformations included anomalies of sternum, coarctation of the aorta with pulmonary trunk dilation, retroesophageal subclavian artery with absent brachiocephalic artery, domed head, forepaw hyperextension and hindlimb malrotation, abdominal distention/edema, and missing/fused caudal vertebrae.

An embryofetal study was conducted in pregnant rats administered latanoprostene bunod daily by intravenous injection on gestation days 7 through 17, to target the period of organogenesis. The doses administered ranged from 150 to 1500 $\text{mcg}/\text{kg}/\text{day}$. Maternal toxicity was produced at 1500 $\text{mcg}/\text{kg}/\text{day}$ (870 times the clinical dose, on a body surface area basis, assuming 100% absorption), as evidenced by reduced maternal weight gain. Embryofetal lethality (resorption and fetal death) and structural anomalies were produced at doses ≥ 300 $\text{mcg}/\text{kg}/\text{day}$ (174 times the clinical dose). Malformations included anomalies of the sternum, domed head, forepaw hyperextension and hindlimb malrotation, vertebral anomalies and delayed ossification of distal limb bones. A no observed adverse effect level (NOAEL) was established at 150 $\text{mcg}/\text{kg}/\text{day}$ (87 times the clinical dose) in this study.

8.2 Lactation

Risk Summary

There are no data on the presence of VYZULTA in human milk, the effects on the breastfed infant, or the effects on milk production. The developmental and health benefits of breastfeeding should be considered, along with the mother's clinical need for VYZULTA, and any potential adverse effects on the breastfed infant from VYZULTA.

8.4 Pediatric Use

Use in pediatric patients aged 16 years and younger is not recommended because of potential safety concerns related to increased pigmentation following long-term chronic use.

8.5 Geriatric Use

No overall clinical differences in safety or effectiveness have been observed between elderly and other adult patients.

13 NONCLINICAL TOXICOLOGY

13.1 Carcinogenesis, Mutagenesis, Impairment of Fertility

Latanoprostene bunod was not mutagenic in bacteria and did not induce micronuclei formation in the *in vivo* rat bone marrow micronucleus assay. Chromosomal aberrations were observed *in vitro* with human lymphocytes in the absence of metabolic activation.

Latanoprostene bunod has not been tested for carcinogenic activity in long-term animal studies. Latanoprost acid is a main metabolite of latanoprostene bunod. Exposure of rats and mice to latanoprost acid, resulting from oral dosing with latanoprost in lifetime rodent bioassays, was not carcinogenic.

Fertility studies have not been conducted with latanoprostene bunod. The potential to impact fertility can be partially characterized by exposure to latanoprost acid, a common metabolite of both latanoprostene bunod and latanoprost. Latanoprost acid has not been found to have any effect on male or female fertility in animal studies.

13.2 Animal Toxicology and/or Pharmacology

A 9-month toxicology study administered topical ocular doses of latanoprostene bunod to one eye of cynomolgus monkeys: control (vehicle only), one drop of 0.024% bid, one drop of 0.04% bid and two drops of 0.04% per dose, bid. The systemic exposures are equivalent to 4.2-fold, 7.9-fold, and 13.5-fold the clinical dose, respectively, on a body surface area basis (assuming 100% absorption). Microscopic evaluation of the lungs after 9 months observed pleural/subpleural chronic fibrosis/inflammation in the 0.04% dose male groups, with increasing incidence and severity compared to controls. Lung toxicity was not observed at the 0.024% dose.

Distributed by:

Bausch + Lomb, a division of

Valeant Pharmaceuticals North America LLC

Bridgewater, NJ 08807 USA

U.S. Patent Numbers: 6,211,233; 7,273,946; 7,629,345; 7,910,767; 8,058,467.

VYZULTA is a trademark of Bausch & Lomb Incorporated or its affiliates.

© Bausch & Lomb Incorporated

Based on 9464800 11/2017 VYZ.0055.USA.16 Issued: 11/2017

REVIEW® of Ophthalmology

March 2018 • Volume XXV No. 3 | reviewofophthalmology.com

Cover Focus

26 | **After Surgery: Shots, Drops or Both?**

Kristine Brennan, Senior Associate Editor

Surgeons share their insights on preventing endophthalmitis and CME.

32 | **Whither Toric Monofocal IOLs?**

Liam Jordan, Associate Editor

Where do monofocal toric lenses fit into an increasingly multifocal-centric market?

36 | **Making the Most of Today's Biometry Tech**

Christopher Kent, Senior Editor

Today's advanced technology improves outcomes, but caution and training still pay off.

44 | **E-Survey on Cataract Surgery: Surgeons Slow to Embrace New Tech**

Walter Bethke, Editor in Chief

Most surgeons use traditional techniques, though femto surgeons are using the laser more often.

Departments

5 | [Review News](#)

16 | [Refractive/Cataract Rundown](#)

Stop the Sneeze to Fight the Haze

The “Pittsburgh Protocol” calms local allergy for better cataract and refractive outcomes.

20 | [Retinal Insider](#)

Addressing the Anti-VEGF Treatment Burden

Solutions in the pipeline—both drugs and delivery systems—might help ease the treatment hassle.

48 | [Glaucoma Management](#)

Treating Uveitic Glaucoma: What Works?

Because these patients have two conditions, treatment can be a challenge.

53 | [Technology Update](#)

An Early-2018 IRIS Registry Update

With the seemingly exponential growth of the IRIS Registry, it’s a good time to check its progress.

55 | [Product News](#)

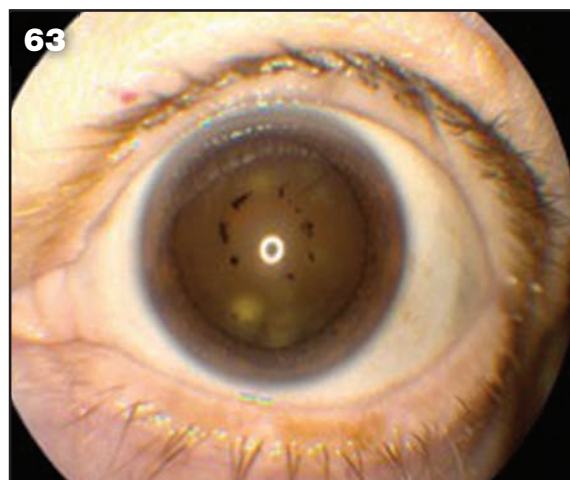
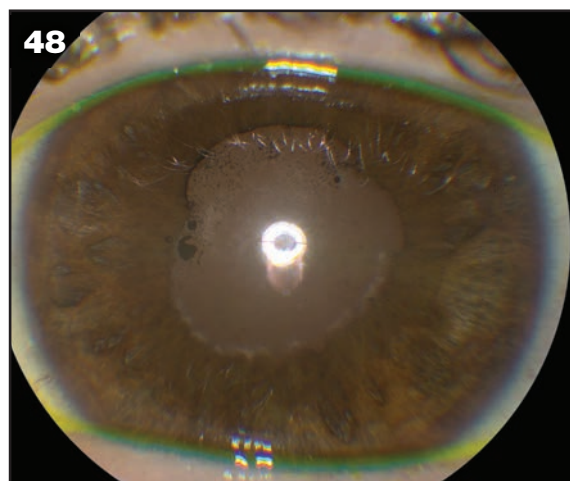
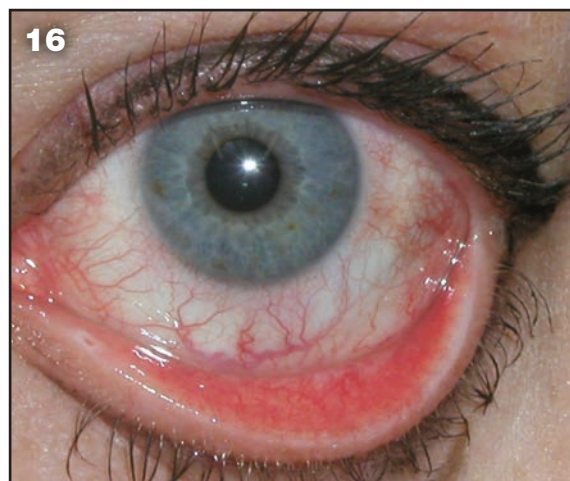56 | [Research Review](#)

Bevacizumab Injection After MIs

60 | [Classifieds](#)

63 | [Wills Eye Resident Case Series](#)

65 | [Ad Index](#)



LEAVE A LEGACY OF SEAMLESS BRILLIANCE.

Start with **ME.**

TECNIS *Symfony*[®] and TECNIS *Symfony*[®] Toric IOLs deliver state-of-the-art presbyopia mitigation and astigmatism correction* while providing a full range of high-quality, continuous vision. I've never let anything keep me from seeing the big picture. Why would you?

Don't wait to leave a legacy of seamless brilliance. Start now with TECNIS *Symfony*[®] and TECNIS *Symfony*[®] Toric Extended Depth of Focus IOLs.

*TECNIS *Symfony*[®] Toric IOLs only

The First and Only Extended Depth of Focus IOL

INDICATIONS AND IMPORTANT SAFETY INFORMATION FOR THE TECNIS SYMFONY[®] AND TECNIS SYMFONY[®] TORIC EXTENDED RANGE OF VISION IOLs

Rx Only

INDICATIONS: The TECNIS *Symfony*[®] Extended Range of Vision IOL, model ZXR00, is indicated for primary implantation for the visual correction of aphakia, in adult patients with less than 1 diopter of pre-existing corneal astigmatism, in whom a cataractous lens has been removed. The lens mitigates the effects of presbyopia by providing an extended depth of focus. Compared to an aspheric monofocal IOL, the lens provides improved intermediate and near visual acuity, while maintaining comparable distance visual acuity. The model ZXR00 IOL is intended for capsular bag placement only. The TECNIS *Symfony*[®] Toric Extended Range of Vision IOLs, models ZXT150, ZXT225, ZXT300, and ZXT375, are indicated for primary implantation for the visual correction of aphakia and for reduction of residual refractive astigmatism in adult patients with greater than or equal to 1 diopter of preoperative corneal astigmatism, in whom a cataractous lens has been removed. The lens mitigates the effects of presbyopia by providing an extended depth of focus. Compared to an aspheric monofocal IOL, the lens provides improved intermediate and near visual acuity, while maintaining comparable distance visual acuity. The model series ZXT IOLs are intended for capsular bag placement only. **WARNINGS:** May cause a reduction in contrast sensitivity under certain conditions, compared to an aspheric monofocal IOL. Inform patients to exercise special caution when driving at night or in poor visibility conditions. Some visual effects may be expected due to the lens design, including: perception of halos, glare, or starbursts around lights under nighttime conditions. These will be bothersome or very bothersome in some people, particularly in low-illumination conditions, and on rare occasions, may be significant enough that the patient may request removal of the IOL. Rotation of the TECNIS *Symfony*[®] Toric IOLs away from their intended axis can reduce their astigmatic correction, and misalignment greater than 30° may increase postoperative refractive cylinder. If necessary, lens repositioning should occur as early as possible prior to lens encapsulation. **ATTENTION:** Reference the Directions for Use for a complete listing of Indications and Important Safety Information.

TECNIS and TECNIS SYMFONY are trademarks owned by or licensed to Abbott Medical Optics Inc., its subsidiaries or affiliates.
© 2017 Abbott Medical Optics Inc. | www.TeenisIOL.com | PP2017CT1901



Stop the Sneeze to Fight the Haze

The “Pittsburgh Protocol” calms local allergy symptoms for better cataract and refractive outcomes.

Kristine Brennan, Senior Associate Editor

You’ve taken pains to make sure that your patient is a suitable candidate for LASIK, PRK, or cataract surgery, refracting and measuring with care and setting realistic expectations regarding the visual outcome. Surgery goes well. But a subsequent phone call, or perhaps the postop follow-up visit, first clues you in that something’s amiss. You hear complaints of haze and irritation, and observe more inflammation than you’d reasonably anticipate, or a damaged flap. You begin ticking off boxes on your mental checklist of what could possibly have gone wrong.

Untreated allergies may be the culprit, according to Deepinder K. Dhaliwal, MD, L.Ac., professor of ophthalmology at the University of Pittsburgh School of Medicine, director of refractive surgery and the cornea service at UPMC Eye Center and founder and director of the university’s Center for Integrative Eye Care. “The bottom line is that allergy promotes inflammation,” she says. “When you’re an allergic individual and you have untreated allergies, you have more inflammatory mediators circulating and causing damage.

We know that in PRK, people that are atopic have more haze and regression. Patients with LASIK and allergies have a higher chance of having DLK. Even in cataract surgery, if someone’s really atopic, they could have more inflammation or they could want to rub their eye, which could result in problems with wound deposition.” To help ensure good visual outcomes and patient well-being, Dr. Dhaliwal has instituted the “Pittsburgh Protocol” to control local allergy symptoms perioperatively and to maintain that control after surgery.

Identifying Problems

“For refractive surgery, we do two evaluations: One is just to see if you’re a candidate; the other is to dilate your eyes and get the precise measurements. So at the first visit, we identify all allergy patients and start them on the correct therapy,” says Dr. Dhaliwal. “I will not operate on anyone who has untreated allergies. So at the University of Pittsburgh, what we do now is ask everybody, ‘What are you allergic

to?’ We always ask about allergies, but a lot of times patients may not even know the specific things they’re allergic to. That’s why it’s really important to question them and get an appropriate history taken. Then, on the exam, we’ll rule out any dryness,” she says.

Itching is the main symptom of allergic conjunctivitis: If it’s absent, then ocular allergy may not be the culprit. Dr. Dhaliwal distinguishes between seasonal allergic conjunctivitis, which is episodic in nature depending on the specific allergen (airborne pollen from grasses, plants or trees), and perennial allergic conjunctivitis arising from chronic exposure to dust mites, molds and pet dander.

Before tailoring the treatment to the allergy symptom, Dr. Dhaliwal also needs to find out what medications patients already take. “We have them write down every single thing that they take,” she says, noting that that’s another way she gets tipped off to a patient’s underlying allergy issues. “A lot of people don’t think an allergy pill is medication,” she observes. “Because they get it over

NOW AVAILABLE FROM AN

FDA-REGISTERED 503B OUTSOURCING FACILITY

INJECTABLE

Tri-Moxi®

(Triamcinolone and moxifloxacin hydrochloride) 15mg/1mg/mL

Dex-Moxi® New!

(Dexamethasone and moxifloxacin hydrochloride) 1mg/5mg/mL

Dex-Moxi-Ketor™ New!

(Dexamethasone, moxifloxacin hydrochloride and ketorolac) 1mg/0.5mg/0.4mg/mL

Moxifloxacin

5mg/mL

TOPICAL

Pred-Gati™

(Prednisolone acetate and gatifloxacin) 1%/0.5%

Pred-Brom™

(Prednisolone acetate and bromfenac) 1%/0.075%

Pred-Gati-Brom™

(Prednisolone acetate, gatifloxacin and bromfenac) 1%/0.5%/0.075%

Gati-Dex New!

(Gatifloxacin and dexamethasone) 0.5%/0.1%

Prednisolone Acetate Preservative-Free 1% New!

Mydriatic 3 New!

(Tropicamide/Cyclopentolate/Phenylephrine) 1/1/2.5%

SUBLINGUAL

MKO Melt® Sublingual Lemon New!

(Midazolam, ketamine HCl and ondansetron) 3mg/25mg/2mg

IMPRIMIS PROVIDES STERILE COMPOUNDED FORMULATIONS* YOU CAN TRUST

- Release and stability testing performed at FDA-registered labs
- Sterility, endotoxin and potency testing performed on each batch
- Continuous environmental monitoring to maintain product quality standards

Visit us at ASCRS Booth #2218
Order Today at: www.imprimisrx.com/ReviewofOph2018

*For professional use only. Imprimis Pharmaceuticals specializes in customizing medications to meet unique patient and practitioner needs. No compounded medication is reviewed by the FDA for safety or efficacy. Imprimis Pharmaceuticals does not compound copies of commercially available products. References available upon request.

Tri-Moxi, Dex-Moxi-Ketor, Dex-Moxi, Pred-Gati, Pred-Gati-Brom, Pred-Brom, MKO Melt and ImprimisRx are trademarks of Imprimis Pharmaceuticals, Inc.

©2018 Imprimis Pharmaceuticals, Inc. All Rights Reserved.

imprimis Rx®
844.446.6979

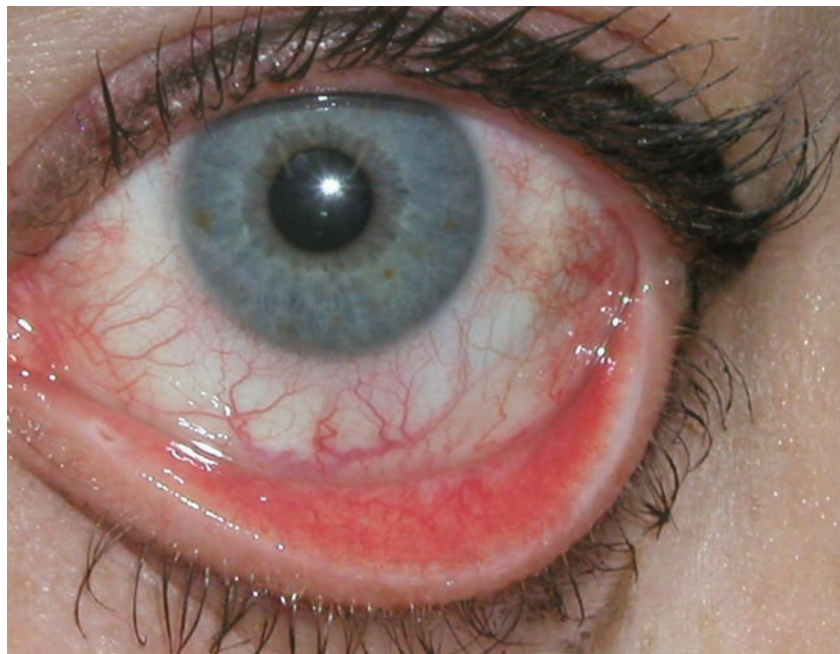IMPO0126 Rev1 2/18

the counter, they consider it more as a supplement or something like that. The problem is that systemic antihistamines cause drying that's detrimental to the ocular surface and leads to more problems down the road." Dr. Dhaliwal seeks alternative therapies for allergic patients taking oral antihistamines. "In the *Visx* manual, it even says that patients on Claritin had a much longer time to re-epithelialization. I wouldn't purposely have somebody on oral antihistamines if their ocular surface was dry, because I know that they'll have healing issues," she says.

Topical Treatment Options

Once she's confirmed a problem and sussed out medicines that could contribute to ocular dryness, Dr. Dhaliwal works to find the right treatment or combination of treatments to target a patient's allergy symptoms. "The most important thing is to identify the patient's issues and treat them locally. We treat what's causing their symptoms: Do they have allergic conjunctivitis? Allergic rhinitis? Or do they have more of a pharyngeal asthma? Allergic conjunctivitis is very well treated with topical combination antihistamine/mast-cell-inhibitor drops like Zaditor (Alcon). Those are really great. There are so many different varieties, and they're available over the counter now," she says. Other combination mast-cell-inhibitor/antihistamine drops include olopatadine HCL (Patanol); ketotifen fumarate (Alaway); azelastine HCL (Optivar); epinastine HCL (Elestat); and bepotastine (Bepreve). Topical steroid drops include loteprednol etabonate (Alrex and Lotemax). Topical drops may have the added benefit of helping to wash out some offending allergens.¹

"If they have more of a rhinitis, there's Flonase (GlaxoSmithKline),



Patients with ocular allergies may benefit from targeted multisymptom relief, including combination antihistamine/mast-cell-stabilizer eye drops.

which is fluticasone, a nasal steroid. For patients with more of an allergic-asthma component to their symptoms, we ask them to try Singulair (Merck). It's a wonderful pill because it helps to curb the allergic response, but it does not cause any drying of the eyes. So those types of medicines have really been our mainstay of therapy," she explains. "Some people do fine with just the drops; some people need drops and nasal spray; and some people need all three—drops, nasal spray and Singulair. Whatever the problem is, we treat perioperatively."

Dr. Dhaliwal says that this period of localized treatment dovetails with the approximately three-week period when patients must abstain from contact lenses prior to surgery. "They need to keep their contact lenses out for about three weeks, so typically, we'll try to optimize them in two to three weeks, and then we do surgery," she explains, adding that the Pittsburgh Protocol allergy-treatment regimen also extends for

about a week postoperatively.

It doesn't necessarily follow that patients will discontinue their targeted pharmacotherapy once they're through the early postop period, however. Dr. Dhaliwal says that some of her refractive and cataract surgery patients with severe allergy symptoms seek longer-term relief, consulting with allergists for comprehensive testing and the initiation of immunotherapy. "We have people get allergy tests, and then allergy shots if they need them," she says. "That's been very beneficial for a bunch of patients who have significant allergies. Some people initially put up a bit of a stink about it and say, 'Allergy shots? I thought that was just for kids!' Obviously, instituting immunotherapy takes much longer, and it's not as though I'd have them start doing allergy shots before their surgery: That would take too long. But we do educate patients, telling them, 'You know, you don't have to live like this.'"

Dr. Dhaliwal notes that a patient

seeking the lasting relief immunotherapy provides may no longer be limited to subcutaneous treatment. "What's really cool is that now they have sublingual immunotherapy, so you can take a pill to help you get over your allergy to, say, ragweed." FDA-approved sublingual immunotherapies include tablets to combat allergic reactions to grass pollens, ragweed and dust mites. "I don't currently have any patients who've had experience with that, but I'm looking forward to seeing it work," she says. "It's something that could be really beneficial."

Allergen Avoidance

Nonpharmacologic options for allergic refractive and cataract surgery patients include cold compresses to stop itching and prevent eye rubbing; artificial tears; and simple allergen avoidance. Dr. Dhaliwal says that this last measure is frequently overlooked. "People forget this, but if you just avoid going outside when the pollen levels are high, for example, you're going to be okay," she says. "When you come inside after a high-pollen day, you've got to take a shower, wash your hair and change your clothes immediately upon getting in the house. But a lot of people don't do that: They end up rubbing their eyes. They sleep on a pillow that has pollen all over it from their hair, and then they wonder why they wake up with itchy eyes in the morning. We do a lot of basic education. We spend a lot of time with our patients talking about allergy avoidance, whether it's environmental, triggered by animals or anything else. If patients are allergic to cats and dogs, but have pets that sleep in the same bed with them, we have them change the sheets and make sure that the animals are not in the room during the perioperative and postoperative periods. I tell them,

'Have at least one room that is going to be animal-free. After surgery, take your nap there, and that's your special place to stay, where you can just rest and recover without any animal dander near you to make you itch.' Obviously, if patients rub their eyes after LASIK, it's a big problem," she says, since they might disrupt the flap or set the stage for epithelial ingrowth.

"We really don't want people to be exposed to their allergens," she stresses, adding that avoidance of seasonal allergens can dictate the timing of surgery if necessary. "If a patient has a springtime issue, we can always do it later in the year," she says. "I just ask them, 'When are your allergies the worst?' and then try to avoid operating during that time period, if possible."

Although she has not done any comparative studies on the outcomes of her allergic patients since instituting the Pittsburgh Protocol, Dr. Dhaliwal is convinced of its value. "I haven't done any head-to-head studies because if I have a patient with allergies, I treat them," she says. Localized treatment with rapid onset of action and extended duration has helped her cataract and refractive surgery patients enjoy better visual outcomes, and sometimes even long-term allergy-symptom relief.

"It's funny, but very many people are really happy after getting off their systemic antihistamines," Dr. Dhaliwal reports. "I've had patients say, 'I feel better off of them, and I'm going to continue on this localized therapy even though I'm healed postoperatively.'" **REVIEW**

Dr. Dhaliwal is a consultant for Bausch + Lomb and a Visx trainer.

1. McGill JI, Holgate ST, Anderson DF, Bacon A. Allergic eye disease mechanisms. *Br J Ophthalmol* 1998;82:1203-14.

S4OPTIK FULL POWERED

EXAMINATION CHAIR

2500-CH



**Powerful, precise,
automated.**

**Choose the S4OPTIK 2500-CH
Examination Chair for convenient,
motorized reclining.**

- KleenTech Lift System®
- Weight bearing armrests
- Robust footrest
- Precision engineered

S4OPTIK

250 Cooper Ave., Suite 100 Tonawanda NY 14150

www.s4optik.com | 888-224-6012

Sensible equipment. Well made, well priced.

For today's modern office.



Addressing the Anti-VEGF Treatment Burden

There are solutions in the research pipeline—both drugs and delivery systems—that might help ease the task of treatment.

Rehan M. Hussain, MD, Miami, and Thomas A. Ciulla, MD, MBA, Indianapolis

Intravitreal injections have become an increasingly common clinic-based treatment for a variety of exudative retinal diseases since anti-vascular endothelial growth factor pharmacotherapy was introduced in the early 2000s. One study regarding the evolution of treatment of diabetic macular edema over the past decade reported a linear decrease in frequency of laser therapy, while anti-VEGF therapy frequency exponentially increased, leading to a threefold increase in clinic visits from a mean of three visits per year to nine.¹ This increased visit frequency related to anti-VEGF agent administration has created service pressures on ophthalmology clinics and also places a significant burden on patients and their caregivers, with barriers to compliance including patient anxiety/discomfort, financial burden, time constraints and lack of transportation.²

Various treatment regimens, such as treat-and-extend and as-needed administration, have been adopted to minimize treatment burden and potentially improve compliance, while also personalizing treatment regimens away from fixed-dosing regimens.

However, real-world outcomes of anti-VEGF therapy are generally worse than those obtained in clinical trials, possibly due to undertreatment.³ A large, retrospective analysis of a U.S. medical claims database showed that 19,000 newly diagnosed nAMD patients received a mean of only 4.6 and 6.9 injections of bevacizumab and ranibizumab over 12 months, respectively. A meta-analysis of anti-VEGF treatment regimens for nAMD suggests that there is a positive linear correlation with visual acuity gains and number of bevacizumab or ranibizumab injections over 12 months, although there was a ceiling effect in which more than nine injections annually didn't result in further gains.⁴ Theoretically, such a regimen could be arranged as three monthly loading doses followed by a six-week injection interval thereafter, but this regimen would represent a departure from the trend towards personalized medicine and personalized treatment regimens. Aflibercept, which is FDA-approved for three monthly loading doses followed by two-month dosing afterward, can be dosed in as few as eight injections over the first 12 months.

Given the limitations of anti-VEGF therapy, along with the burdensome need for repeated intravitreal injections to sustain efficacy, long-acting formulations of anti-VEGF drugs, as well as topical and oral formulations, are being developed. Brolucizumab and abicipar pegol are two novel intravitreal anti-VEGF treatments that could potentially be approved for 12-week (quarterly) dosing after three monthly loading doses, which would result in six injections over the first 12 months (fewer than all three currently available anti-VEGF agents). However, a deeper dive into the data raises important questions. Some novel anti-VEGF treatments, currently in clinical trials, are summarized below, with a more comprehensive overview in the table.

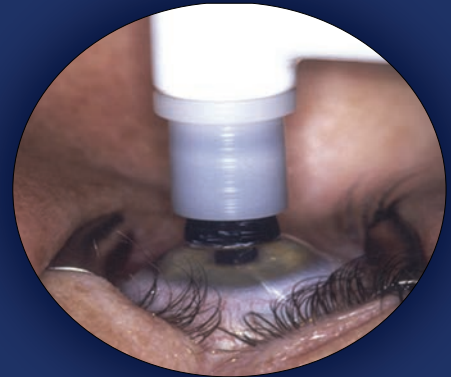Long-acting Anti-VEGF Agents

Rather than use a sustained-delivery approach, some agents that are being studied are designed to require less-frequent dosing.

- **Brolucizumab.** Brolucizumab (Novartis) is a humanized single-chain antibody fragment inhibitor of

Visit us at ASCRS 2018 in
Booth #1750

Achieve superior results with
AMOILS EPITHELIAL SCRUBBER



Uniform epithelium removal
in 5–7 seconds

Corneal Xlinking

Improved clinical outcomes
of CXL and PRK with
Amoils Epithelial Scrubber

- Minimize total procedure time
- Avoid alcohol damage to surrounding tissue
- No need for subsequent scraping

VEGF-A that has a smaller molecular weight (26 kDa) compared to aflibercept (115 kDa) and ranibizumab (48 kDa). Its molecular properties allow a higher molar concentration to be prepared in a 0.05 ml intravitreal injection, which may allow for an extended duration of effect and improved ocular tissue penetration.

The Phase III HAWK and HARRIER trials (ClinicalTrials.gov identifiers: NCT02307682, NCT02434328) compared aflibercept 2 mg to brolucizumab 3 mg and brolucizumab 6 mg. This study enrolled more than 1,800 patients across 400 centers worldwide. After three monthly loading doses, the brolucizumab groups were treated every 12 weeks, with the option of switching to eight-week dosing in case of recurrent disease activity.⁵ A Novartis press release from June 2017 announced that the brolucizumab 6-mg group met the primary endpoint of non-inferiority compared to aflibercept every eight weeks (measured by mean change in BCVA from baseline to week 48). A majority of patients, 57 percent (HAWK) and 52 percent (HARRIER), were maintained exclusively on a 12-week interval immediately following the three-month loading phase through week 48. The press release didn't specify the mean number of injections that patients received after their three loading doses, a key metric for comparison to current therapies and regimens. The rate of ocular and non-ocular adverse events were comparable between aflibercept and brolucizumab.⁶

• **Abicipar pegol.** Abicipar pegol (Allergan and Molecular Partners) is a monoDARPin (Designed Ankyrin Repeat Protein) that blocks all isoforms of VEGF-A. The Phase IIb trial data suggested that it has more potent VEGF-A inhibition, smaller molecular size (34 kDa), and longer duration (12 weeks) than the currently available anti-VEGF-A agents. In a 20-week study, Abicipar 2 mg given

every four weeks for three loading doses followed by monthly sham outperformed ranibizumab 0.5 mg given every four weeks. At the 20-week follow-up, the abicipar group gained a mean of nine letters, while the ranibizumab group gained only 4.7 letters with continued monthly dosing.⁷ (It's worth noting that the ranibizumab group underperformed compared to previous major trials involving ranibizumab, such as the MARINA, CATT and ANCHOR trials, in which a mean of just over six, 6.5 and 10 letters were gained at 20-week follow-up, respectively.⁸⁻¹⁰) Quarterly dosing of ranibizumab 0.5 mg was tested in the EXCITE and PIER trials, and visual gains weren't as favorable as those obtained in treatment arms of monthly ranibizumab treatment, although 18 percent and 13 percent of patients respectively gained ≥ 15 ETDRS letters on this regimen.^{11,12}

The abicipar Phase III trials (NCT02462486) will compare treatment arms of abicipar every eight weeks (duration equal to aflibercept), abicipar every 12 weeks (duration superior to aflibercept), and ranibizumab every four weeks.¹³ In May of 2017, Allergan announced completion of patient recruitment in these two global AMD Phase III studies. If quarterly dosing of abicipar is found to be non-inferior to monthly ranibizumab and bimonthly aflibercept, this would represent a major step forward in reducing treatment burden.

In the Phase IIb study, approximately 10 percent of patients who received abicipar experienced episodes of ocular inflammation.¹⁴ Allergan has worked to improve the abicipar formulation and purification process with the goal of reducing the incidence of inflammation in Phase III trials. Similar problems with inflammation were encountered with ranibizumab during early clinical trials, which were successfully resolved in later trials. The retina community



order online
www.innovativexcimar.com

T.800.461.1200

Table 1. AMD Therapies in the Research Pipeline

Compound	Company	Stage of Development	Structure/Mechanism of Action
Brolucizumab	Novartis	Phase III	small MW humanized single-chain Fab anti-VEGF-A
Abicipar pegol	Allergan	Phase III	DARPin antagonist of VEGF-A
OPT-302	Ophthea	Phase IIb	anti-VEGF-C/VEGF-D
Pegpleranib (Fovista)	Ophthotech	Phase III did not meet end point	anti-PDGF-B aptamer
Rinucumab-aflibercept	Regeneron	Phase II did not meet end point	anti-PDGF-B/anti-VEGF co-formulation
DE-120	Santen	Phase II	dual TKI of VEGF-A/PDGF
Nesvacumab-aflibercept	Regeneron	Phase II	Ang-2/VEGF-A mAb co-formulation
RG7716	Roche	Phase II	bispecific Ang-2/VEGF-A antibody
ARP-1536	Aerpio	Preclinical	Tie-2 receptor activation (via VE-PTP inhibition)
X-82	Tyrogenex	Phase II	oral anti-VEGF-A/PDGFR
Pazopanib	GlaxoSmithKline	Phase IIb did not meet endpoint	TKI of VEGF-A/PDGF
PAN-90806	PanOptica	Phase I/II	TKI of VEGF-A/PDGF
Regorafenib	Bayer Healthcare	Phase IIa did not meet endpoint	TKI of VEGF-A/PDGF
LHA510	Alcon	Phase II	VEGF-A inhibitor
Ranibizumab PDS	Genentech	Phase II	refillable port of VEGF-A mAb
GB-102	GrayBug Vision	Preclinical	bioerodible nanoparticles encapsulate TKI of VEGFR/PDGFR
NT-503 ECT	Neurotech	Phase II terminated	VEGF-A receptor fusion protein
Hydrogel depot	Ocular Therapeutix	Preclinical	sustained-release anti-VEGF-A
Durasert	pSivida	Preclinical	TKI of VEGF-A/PDGF
ENV1305	Envisia Therapeutics	Preclinical	sustained-release anti-VEGF-A
AVA-101	Adverum Biotechnologies	Phase IIa results were mixed	AAV sFLT
AVA-201	Adverum Biotechnologies	Preclinical	AAV sFLT
ADVM-022/ADVM-032	Adverum Biotechnologies	Preclinical	AAV encoding anti-VEGF-A cDNA
AAV2-sFLT01	Genzyme (Sanofi)	Phase I	AAV sFLT
RGX-314	Regenxbio	Preclinical	AAV8 encoding anti-VEGF-A
Retinostat	Oxford Biomedica	Phase I	EIAV encoding endostatin and angiostatin

Abbreviation Key:

MW = molecular weight Fab = fragment antibody VEGF = vascular endothelial growth factor DARPin = designed ankyrin repeat protein PDGF = platelet-derived growth factor TKI = tyrosine kinase inhibitor Ang-2 = angiotensin-2 PDS = port delivery system ECT = encapsulated cell therapy	mAb = monoclonal antibody VE-PTP = vascular endothelial-protein tyrosine phosphatase PDGFR = platelet-derived growth factor receptor bFGF = beta Fibroblast Growth Factor VEGFR = vascular endothelial growth factor receptor AAV = adeno-associated virus sFLT = soluble fms-like tyrosine-kinase 1 cDNA = complementary deoxyribonucleic acid
---	--

eagerly looks forward to more clinical trial information, especially the mean number of injections per year, in order to compare abicipar to the non-fixed dosing regimens of our currently used agents.

Sustained Delivery Treatments

The need for frequent intravitreal injections has spurred several companies to develop sustained-release anti-VEGF-A devices.

• **Ranibizumab Port Delivery System.** The ranibizumab Port De-

livery System (PDS), a nonbiodegradable port fixed to the sclera, has a 0.05-ml reservoir that can be refilled in the office. Phase I results indicated that it improved visual acuity comparable to monthly ranibizumab injections as reported in the MARINA and

ANCHOR studies. The 20 patients in the trial gained a mean of 10 ETDRS letters and had received a mean of 4.8 refills by the 12-month follow-up. Three serious adverse events (related to the implantation procedure) were reported, including endophthalmitis and persistent vitreous hemorrhage.

In 2015, Genentech initiated a Phase II study, the LADDER trial (Long Acting Delivery of Ranibizumab, NCT02510794), to test the safety and efficacy of the port delivery system on a larger scale, with a focus on optimizing the treatment dose and refill intervals.¹⁵

- **GB-102.** GB-102 (GrayBug Vision) is sunitinib maleate, a multitargeted tyrosine kinase inhibitor with activity against both VEGF-A and platelet derived growth factor. It's an injectable depot designed for twice-per-year formulation. The drug is encapsulated within bioerodible polymer nanoparticles that slowly degrade over time. The GrayBug formulation is designed to avoid the inflammatory response seen with other nanoparticles, and the nanoparticles remain at the injection site to avoid clouding the visual axis. In a rabbit laser CNV model, GB-102 was found to be superior to aflibercept, according to data published on the GrayBug website. Aflibercept is maximally effective when given at the same time as the laser injury, whereas GB-102 demonstrated equal efficacy when given 10 weeks prior to it. Phase I studies are in development.¹⁶

Topical Treatments

Another method for reducing the treatment burden is to eliminate the need for an injection, a path taken by the following investigational therapies:

- **PAN-90806.** PAN-90806 (PanOptica) is a VEGF-A inhibitor eye drop that has been shown to produce an anti-VEGF-A response compar-

able to currently available anti-VEGF-A therapies in half of 50 treatment-naïve nAMD patients, according to a Phase I/II study (NCT02022540). According to a presentation from the 2016 meeting of the Ophthalmic Innovation Summit, PanOptica planned to initiate a Phase I/II clinical trial of an updated formulation for patients with nAMD in late 2017 or early 2018. This newer suspension was designed to reduce the incidence of punctate keratopathy as a side effect.¹⁷

- **LHA510.** Alcon has developed a topical anti-VEGF-A medication, LHA510, that's been tested as maintenance therapy for patients with nAMD. The Phase II study (NCT02355028) compares initial ranibizumab plus topical LHA510 for 84 days versus initial ranibizumab plus placebo, with the primary endpoint being number of patients requiring rescue ranibizumab injections before day 84.¹⁷

Oral Anti-VEGF Therapy: X-82

X-82 (Tyrogenex) is an oral anti-PDGF and VEGF-A inhibitor. In the Phase I dose-escalation study (NCT02348359), 10 of 35 patients (29 percent) didn't complete the 24-week endpoint, with six (17 percent) withdrawing due to adverse events. The most common adverse events were diarrhea (n=6), nausea (n=5), fatigue (n=5) and elevated transaminase enzymes (n=4) that reversed with cessation of X-82.

In terms of efficacy, 24 of the 25 patients that completed the 24-week trial maintained or improved their visual acuity (mean +3.8 letters), and 15 of 25 (60 percent) did so without the need for rescue ranibizumab injections (as specified by predefined retreatment criteria). Mean central subfield thickness was reduced by a mean of 50 μ m, and eight patients (all receiving at least 100 mg daily) maintained sustained reductions without

the need for rescue ranibizumab injection.¹⁸

The Phase II APEX study (NCT02348359) is comparing X-82 with as-needed aflibercept injections to aflibercept monotherapy in patients with AMD.

Gene Therapy

Recently, the eye has become a target for investigational gene therapy due to the monogenic nature of many inherited retinal diseases, its accessibility, the tight blood-ocular barrier, the ability to non-invasively monitor for functional and anatomic outcomes, and its relatively immune-privileged state. Gene therapy for nAMD offers the promise of long-term continuous expression of anti-VEGF protein with a single administration. Viral vectors are conduits for transferring desired genetic information to host cells.

Vectors currently used in ocular gene therapy clinical trials include adeno-associated virus (small single-stranded DNA viruses of the parvovirus family) and lentivirus (RNA viruses of the retrovirus family). Both can transduce non-dividing cells, but AAV are non-integrating, while lentivirus integrate their genome into the host cell genome and have larger transgene capacity (approximately 10 kb vs 4.5-5.0 kb for AAV). After successful transduction of the genome, the target cells transcribe and translate the viral genetic material into therapeutic protein, which then modulates the pathogenesis of the targeted disease process.

Gene therapy for AMD is still in its early phases of development and has not yet translated to consistently meaningful visual gains in AMD patients, but nonetheless represents an exciting area for future research.¹⁹ Gene therapies for AMD are summarized in Table 1 on the opposite page.

When we take stock in the current state of ophthalmology, there are

many experimental anti-VEGF agents and drug delivery systems under development that aim to decrease the treatment burden associated with frequent intravitreal injections. If one or more of these becomes a successful part of our everyday practice, treatment paradigms could be dramatically disrupted, improving the lives of an expanding population of seniors with AMD. **REVIEW**

Dr. Hussain is a vitreoretinal surgery fellow at Bascom Palmer Eye Institute. Dr. Ciulla is the past co-director of the retina service and ocular angiogenesis research laboratory at Indiana University School of Medicine, and remains a volunteer clinical professor of ophthalmology. He serves on the board of directors of Midwest Eye Institute and is currently the medical strategy lead in ophthalmology at Spark Therapeutics. Neither Dr. Hussain nor Dr. Ciulla have financial interests in anti-VEGF therapies.

1. Jusufbegovic D, Mugaiv MO, Schaal S. Evolution of controlling diabetic retinopathy: Changing trends in the management of diabetic macular edema at a single institution over the past decade. *Retina* 2015;35:929-934.
2. Smith AG, Kaiser PK. Emerging treatments for wet age-related macular degeneration. *Expert Opin Emerg Drugs* 2014;19:157-164.
3. Holekamp NM, Liu Y, Yeh WS, et al. Clinical utilization of anti-VEGF agents and disease monitoring in neovascular age-related macular degeneration. *Am J Ophthalmol* 2014;157:825-833 e821.
4. Hussain RM, Hariprasad SM, Ciulla TA. Treatment burden in neovascular AMD: Visual acuity outcomes are associated with anti-VEGF injection frequency. *Ophthalmic Surg Lasers Imaging Retina* 2017;48:780-784.
5. Dugel P, Warburton J, Weichselberger A, Sallstig P. A 2-year study comparing the efficacy and safety of brolicizumab vs aflibercept in subjects with neovascular age-related macular degeneration: Testing an alternative treatment regimen. Presented at: Association for Research in Vision and Ophthalmology Annual Meeting; 2016 May 1-5; Seattle, WA.
6. Novartis RTH258 (brolicizumab) demonstrates robust visual gains in nAMD patients with a majority on a 12-week injection interval. Available at: <https://www.novartis.com/news/media-releases/novartis-rth258-brolicizumab-demonstrates-robust-visual-gains-namd-patients>. Accessed 12 February 2018.
7. Abicipar Pegol (Anti-VEGF DARPIn) and Bimatoprost Sustained-Release Implant for Glaucoma. Available at: https://www.allergan.com/miscellaneous-pages/allergan-pdf-files/rd_investor_presentation_jun30_2014. Accessed 12 February 2018.
8. Rosenfeld PJ, Brown DM, Heier JS, et al. Ranibizumab for neovascular age-related macular degeneration. *N Engl J Med* 2006;355:1419-1431.
9. CATT Research Group, Martin DF, Maguire MG, et al. Ranibizumab and bevacizumab for neovascular age-related macular degeneration. *N Engl J Med* 2011;364:1897-1908.
10. Brown DM, Kaiser PK, Michels M, et al. Ranibizumab versus verteporfin for neovascular age-related macular degeneration. *N Engl J Med* 2006;355:1432-1444.
11. Schmidt-Erfurth U, Eldem B, Guymer R, et al. Efficacy and safety of monthly versus quarterly ranibizumab treatment in neovascular age-related macular degeneration: The EXCITE study. *Ophthalmology* 2011;118:831-839.
12. Regillo CD, Brown DM, Abraham P, et al. Randomized, double-masked, sham-controlled trial of ranibizumab for neovascular age-related macular degeneration: PIER study year 1. *Am J Ophthalmol* 2008;145:239-248.
13. Safety and efficacy of abicipar pegol in patients with neovascular age-related macular degeneration. Available at: <https://clinicaltrials.gov/ct2/show/NCT02462486>. Accessed 12 February 2018.
14. Positive top-line data reported from Phase II study for DARPIn abicipar pegol in wet AMD. Available at: <https://www.molecularpartners.com/positive-top-line-data-reported-from-phase-2-study-for-darpin-abicipar-pegol-in-wet-amd/>. Accessed 12 February 2018.
15. Study of the efficacy and safety of the ranibizumab port delivery system (RPDS) for sustained delivery of ranibizumab in participants with subfoveal neovascular age-related macular degeneration (AMD) (LADDER). Available at: <https://clinicaltrials.gov/ct2/show/NCT02510794>. Accessed 31 January 2018.
16. GB-102 for Treatment of nAMD. Available at: <http://www.graybug.com/pipeline-technology/gb-102/>. Accessed 12 February 2018.
17. LHA510 proof-of-concept study as a maintenance therapy for patients with wet AMD. Available at: <https://clinicaltrials.gov/ct2/show/NCT02355028>. Accessed 12 February 2018.
18. Jackson TL, Boyer D, Brown DM, et al. Oral tyrosine kinase inhibitor for neovascular age-related macular degeneration: A Phase 1 dose-escalation study. *JAMA Ophthalmol* 2017;135:761-767.
19. Moore NA, Bracha P, Hussain RM, et al. Gene therapy for age-related macular degeneration. *Expert Opin Biol Ther* 2017;17:1235-1244.

25TH ANNUAL OPHTHALMIC Product Guide

Innovative products to enhance your practice

The **future** is in your hands.
One tap, many possibilities.

Experience the digital edition on your handheld device.
Use your smart device to scan the code below or visit:

www.reviewofophthalmology.com/publications/archive



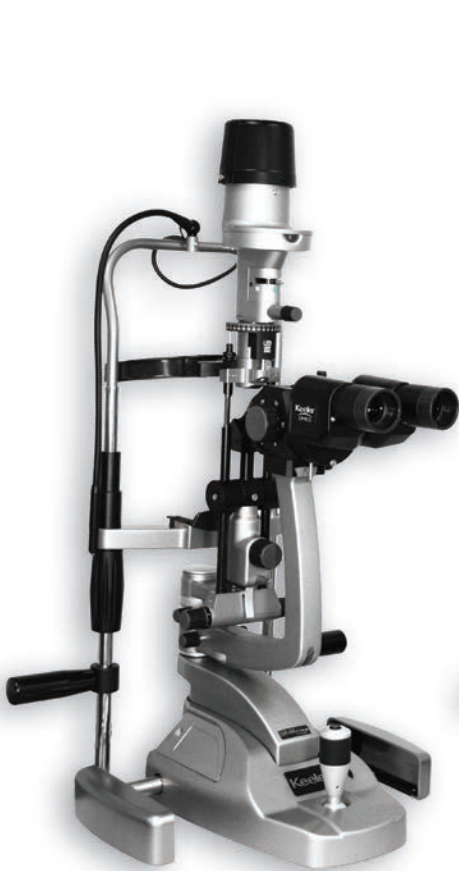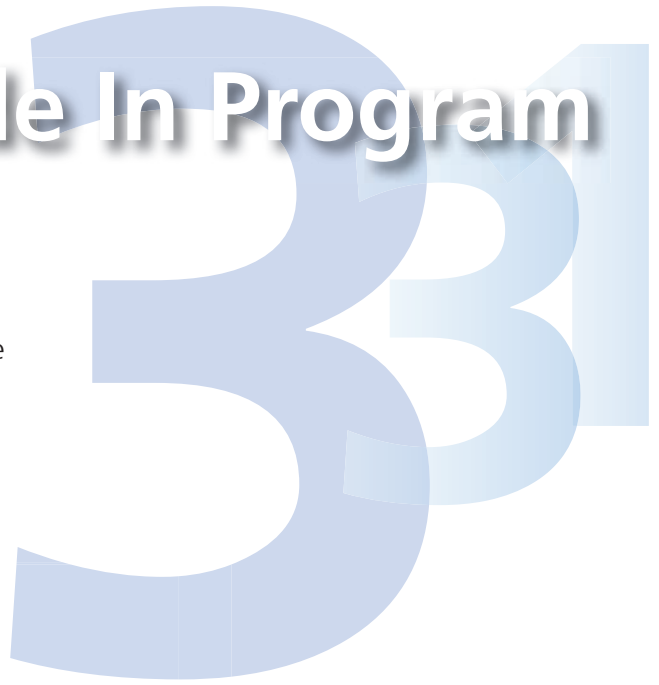Download a QR scanner app. Launch app and hold your mobile device over the code to view
www.reviewofophthalmology.com/publications/archive.



The Keeler³ Trade In Program

Buy 3 // Trade 3 // Get 1 Free

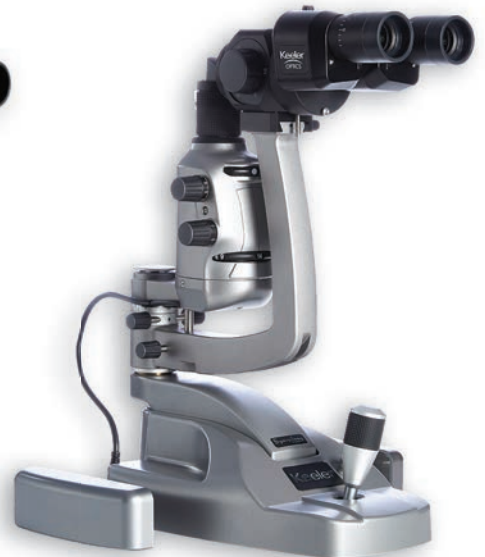The Power of 3. Purchase any 3 Keeler Slit Lamps and trade in 3 of your old Slit Lamps and we'll send you a 4th Keeler Slit Lamp absolutely free of charge.



K Series



Q Series



Z Series



Keeler Instruments, Inc. • 3222 Phoenixville Pike, bldg. 50 • Malvern, PA 19355
Tel: (800) 523-5620 • Fax: (610) 353-7814 • email: keeler@keelerusa.com

Offer valid until June 30, 2018.

Contact Keeler or one of our authorized dealers for more information.

After Surgery: Shots, Drops Or Both?

Kristine Brennan, Senior Associate Editor

Surgeons share their insights on preventing endophthalmitis and CME.

Fortunately, endophthalmitis after cataract surgery is rare, but that matters little to the patient who develops it. The landmark 2007 ESCRS study, a prospective multicenter study of 16,603 patients randomized into four treatment arms, found an approximately fivefold decrease in the risk of developing postoperative endophthalmitis in those who received 1 mg of intracameral cefuroxime at the close of surgery¹ versus patients who did not; adding postoperative topical drops to the intracameral drug didn't provide any demonstrable benefit. Some subsequent retrospective cohort studies^{2,3} suggest that endophthalmitis cases decrease as a practice pattern incorporates intracameral antibiotic injections. While many surgeons view this data as compelling and encouraging, many others await definitive proof of the efficacy of intraocular antibiotics. Here, left to their own devices with regard to the drops/less-drops/dropless question, surgeons describe their endophthalmitis- and inflammation-prevention regimens and the reasoning behind their choices.

Battling the Bugs

Steve A. Arshinoff MD, FRCSC, associate professor at the University

of Toronto's department of ophthalmology and vision sciences, employs intracameral injections to prevent endophthalmitis. "I was the first in the world to use intracameral moxifloxacin in 2004, and I still do," he says.

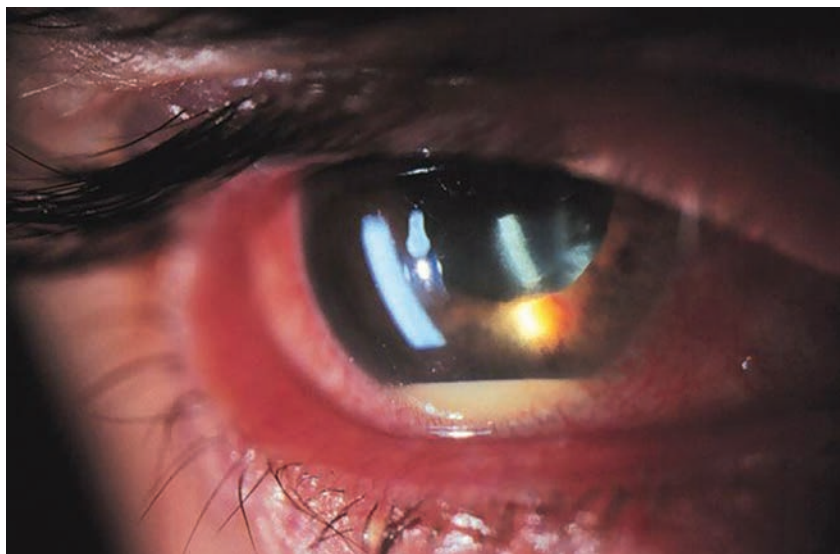Dr. Arshinoff's infection-control protocol doesn't involve any preoperative drops before the patient walks into the OR. "I think it is a really bad idea to give patients topical antibiotics for a few days preop. If you do that, microbiologically, the drug kills off all the sensitive bacteria, but it leaves the nutrients on the conjunctiva for resistant bacteria to grow," he says. "You encourage resistant strains because you're selecting for them by killing off the bacteria that are sensitive to the drug. When patients come to the operating room, they're not there for long preoperatively, so then I give them topical Vigamox (Alcon, Novartis) three times over 15 minutes: It kills off all the sensitive bacteria that are there, but there isn't enough time to grow resistant strains to colonize the ocular surface."

Steven M. Silverstein, MD, FACS, in practice at Silverstein Eye Centers, Kansas City, Missouri, who takes a drops-only approach, notes that some causative factors are un-

controllable, regardless of prophylaxis used. “There are some factors beyond our control,” he says. “Even if patients are not asked to take any eye drops, patients can still rub their eyes, go to the bathroom without washing their hands, touch doorknobs, shake hands—all kinds of things we can’t control. People can contaminate their eyes in a way that antibiotics alone may not necessarily prevent, regardless of the route of administration.”

Dr. Silverstein also uses fluoroquinolone drops, but he has patients use them for two days prior, and then administers them three times right before surgery in the preop area. “They also get a topical NSAID for two days before surgery,” he says.

At the close of surgery, Dr. Arshinoff injects Vigamox into the anterior chamber. “I give my patients 600 micrograms diluted into 0.4 cc. We dilute basically the whole bottle of Vigamox—3 cc—and add 7 cc of BSS. The concentration is such that you inject 0.4 cc—a little less than the volume of the pseudophakic anterior chamber (0.5 cc). You get a totally safe dilution and a perfectly reasonable concentration to use,” he says, cautioning that other branded and generic moxifloxacin preparations have not been demonstrated to be safe for intraocular use. “Avelox (Merck) has a pH of 4.1 to 4.6, which is totally intolerable in the eye. I want to warn everyone: Don’t use Avelox. Don’t use Moxeza (Novartis). It’s not worth trying to save five dollars to get some other solution that appears to be the same as Vigamox, but isn’t,” he stresses. “Vigamox is so safe that it’s the only drug ever approved for sale as a topical eye drop without a preservative: Nothing will grow in the bottle. You can take it directly from the bottle and dilute it. It’s simple to dilute, and even if you don’t dilute it but you inject only 0.1 cc, it’s not dangerous.”



Steven M. Silverstein, MD, FACS

Endophthalmitis with hypopyon. Most infections occur during the early postoperative period, but endophthalmitis can develop many months after cataract surgery.

Zachary Zavodni, MD, in practice at The Eye Institute of Utah and an adjunct clinical associate professor at the John A. Moran Eye Center of the University of Utah in Salt Lake City, also gives his cataract patients intracameral Vigamox, but more often uses compounded moxifloxacin. “Intraoperatively, I have been using intracameral antibiotics for several years, as the preponderance of data supporting such a practice is compelling,” he says. “Like many surgeons, I used to use intracameral vancomycin because its coverage against gram positive bugs is so good. Approximately two years ago, however, I stopped because of the possible association between vancomycin and HORV. I now use 0.1 mL of intracameral moxifloxacin 0.05%. I inject approximately 0.05 to 0.075 mL directly into the anterior chamber at the conclusion of my case, and I use the remainder to hydrate the paracentesis wound. Depending on the setting I’m in (i.e., hospital vs. private-practice ASC) and the supply available, I will use either an unopened bottle of Vigamox or compounded moxifloxacin from an

in-house compounding pharmacy or a national commercial supplier such as Imprimis or JCB Labs. Most of the time, I end up using medication compounded for intracameral use.”

Dr. Silverstein will give pericocular antibiotics at the close of surgery in a select few cases. “In high-risk patients, those with vitreous loss, a prior history of endophthalmitis, or significant lid-margin disease, I will give a sub-Tenon’s injection of antibiotics, a depot injection for slow release, in conjunction with the pre- and post-operative fluoroquinolone antibiotic drops that they receive,” he says.

Dr. Silverstein thinks the extant evidence for intracameral injections is exciting, but insufficient to change his practice pattern. “The European study was compelling enough to make us engage in serious conversation, and to look toward a new U.S.-based study with more consistent parameters,” he notes, adding that he has seen robust proposed study designs that interest him. He remains skeptical of transzonular injections. “When there is posterior capsular rupture, or even in an intact capsule, where medicine is deliberately

squirted into the posterior segment through the zonular network, the potential for macular and retinal toxicity is real, especially for aminoglycosides,” he says. “Perhaps it’s not as great with the fluoroquinolones, but we haven’t really had enough experience to comment definitively about that. Without concrete data, it’s not something that I advocate at this time.”

Dr. Arshinoff says that his choice of moxifloxacin is well supported by research. “We wrote a paper fairly recently that explains why moxifloxacin is better.⁴ In addition, Peter Libre published a paper that demonstrated that the only drug that really kills off all the bacteria is moxifloxacin.⁵ I’m also currently writing a paper comparing the abatement rates of the different drugs and what happens to their concentrations, and it turns out moxifloxacin is by far the best,” he says.

Dr. Arshinoff distinguishes documented cases of uveitis-like conditions with transilluminating iris depigmentation associated with oral moxifloxacin,⁶ and “one or two” iritis cases arising from intravitreal delivery, from his preferred intracameral administration technique through the side-port incision at a safe concentration. “As time goes by in medicine, whenever we devise ways to give a drug directly to the area where we want it to work, it’s by far the safest way you can do it,” he says. “If you have a high systemic dose, it traverses the iris into the vitreous. It actually washes the tissues en route, where it may cause iritis. But when we put it into the anterior chamber, it’s not washing through to the iris. It’s just in the anterior chamber and the capsular bag. In a lower dose, it’s very safe,” he says.

A suspected anaphylactic response to topical moxifloxacin before cataract surgery has been documented,⁷ but Dr. Arshinoff says he hasn’t en-

countered any adverse reactions to it in intracameral use in an estimated 10,000 patients. “I’ve had patients tell me they’ve had a bad response to systemic moxifloxacin, so when they come into the operating room, I give them a drop of Vigamox while they’re waiting,” Dr. Arshinoff says. “If anything happens to them, then I won’t give them the intracameral.”

Dr. Zavodni makes exceptions to intracameral moxifloxacin use for patients with suspected fluoroquinolone sensitivities. “The only scenario in which I may vary my protocol is when a patient has a history of allergic anaphylaxis to either Betadine (Mundipharma) or fluoroquinolones. In these cases I may use topical chlorhexidine to prep the eye before surgery. As an alternative to postoperative topical fluoroquinolones, I will typically use polymyxin B sulfate/trimethoprim,” he says.

While Dr. Zavodni stopped using intracameral vancomycin because of its relatively recent association with HORV, Dr. Silverstein stopped years ago after he and his colleagues at the time determined that it didn’t appear to be effective at preventing endophthalmitis in their patients. “I was in a practice around 2000 or so, when we did a study with all of the cataract surgeons in the group to look at our practice’s endophthalmitis rates. We were using intracameral vancomycin, which was a popular product to use prophylactically at the time,” he recalls. “Looking at 9,000 cases, we saw no difference in the incidence of endophthalmitis with or without the vancomycin. We stopped using it because there was absolutely no evidence to support its use.”

Citing concerns about HORV, Dr. Arshinoff concurs that vancomycin does not belong at the forefront of endophthalmitis prophylaxis. “The risk of HORV is extremely low, but it’s an immunological condition, and often you don’t know if a patient has

received vancomycin for something else before: If they were primed immunologically, then they might get a reaction to it. It’s also a drug we want to keep as a last resort,” he explains.

Postop Protocols

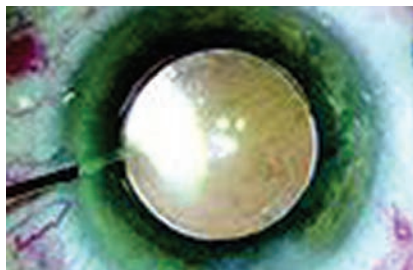
Ocular and periocular steroid injections—alone or together with compounded antibiotic—are part of the dropless cataract surgery trend. None of the three doctors here currently use them, however. “I think they’re a bad idea, because I think the risk lies in giving the needle. If the patient moves during that injection, it can get into their eye. I don’t think there’s enough benefit to justify doing it,” says Dr. Arshinoff, who gives Pred Forte (Allergan) drops postoperatively. “Because they only get the steroid for five to 10 days, and a pressure spike usually takes around five days to develop, I ask the patient to come back in five days. “If their pressure is high, then I will stop the Pred Forte, and I will tell them to take more ketorolac, six times a day until their 10 mL bottle is finished, and then they’re fine.”

In addition to Pred Forte and ketorolac, Dr. Arshinoff prescribes topical Vigamox postoperatively. “Those particular medications are extremely cheap in Canada: It probably costs patients \$20 to get enough drops for both eyes, maybe \$40. But in the U.S., it might cost a few hundred,” he says. He adds that he also gives drops because he thinks they help curb his patients’ postoperative behavior. “I do 90 percent bilateral cataract surgery. Bilateral cataract surgery patients may think that their surgery is trivial because they sit up and can see clearly right away out of both eyes. I don’t want my patients to think that their surgery is trivial: When I give them drops, they think they’d better be careful for the first few days. They don’t rub their eyes; they’re

more attentive to how they're healing and more careful overall. After the first three days, I back them off the drops from six to three or four times a day until the bottles are finished," he says.

Dr. Zavodni doesn't inject intracameral or intravitreal steroids at close of surgery, either. Because of their short half-life he says, "These medications require either transzonular placement or pars plana injection at the end of the case. Potential drawbacks include: possible IOP rise; rebound inflammation once the steroid is gone; and some of the injected steroids are opaque, causing increased floaters postoperatively." Dr. Zavodni does prescribe topical drops postoperatively because they remain the standard of care. "I am still using topical fluoroquinolones for the first week after surgery. I am aware that there aren't any randomized controlled trials to support such a practice, and that Herrinton's retrospective study out of Kaiser Permanente in 2016² demonstrated that topical antibiotic used in conjunction with intracameral was not better than intracameral alone," he acknowledges. "Nonetheless, the use of topical antibiotics is still considered standard of care across the United States [98 percent of ASCRS surgeons reported postoperative use of topical antibiotics in a 2014 survey], and I haven't felt comfortable deviating until prospective data exists proving that it's not providing any benefit. I also use both topical steroids and NSAIDs following surgery, although the efficacy of NSAIDs is highly debated."

Dr. Silverstein's all-drops regimen includes postoperative topical NSAIDs and steroids as well as an antibiotic. "My patients receive preoperative fluoroquinolone drops for two days before surgery, and then three times prior to surgery in the preop area. They continue postop-



Intracameral injection of an antibiotic preparation at close of surgery has been more widely adopted outside of the United States.

eratively until the bottle runs out, which will get them two to three weeks of additional antibiotics. If it's a high-risk case, I'll supplement that with periocular gentamycin or gentamycin and Kefzol (Lilly) sub-Tenon's," he explains. "They get a topical NSAID for two days before surgery, on the day of, and then after surgery. If they're not patched, they continue the NSAID till the bottle runs out, which could be two to four weeks. It's the same with the steroids: They'll get the steroid after surgery if they're not patched until the bottle runs out, which will cover them for two to four weeks."

To dropless-surgery advocates who claim that keeping patients on topical eye drops is burdensome to staff, Dr. Silverstein says that his practice has devised patient education that is "streamlined, matter-of-fact, and easy.

"Really, the only criticism of drop therapy—until we have a definitive answer about efficacy—is compliance," he says. "That's really the only legitimate argument dropless proponents have that that I agree with." To simplify drop compliance, Dr. Silverstein says that a postop nurse sits with patients and family members to review all post-surgical care and restrictions, including the drop regimen. "They're handed a sheet that spells out the drops they should take and at what frequency," he explains.

This encounter comes after prior interventions to help patients and caregivers get a handle on topical eye drops. "From the preoperative counselors, they've already gotten a handout with this information on it, and a life-sized color picture of the bottles of medicine they're going to be using. And then it's written down for them again on postop day one, when we review the instructions and decide whether or not we want to increase or decrease the frequency of anything. If someone has a significant amount of inflammation, we may temporarily increase the frequency of the steroid, for example. If there was a capsular rupture, we may increase the frequency of the steroid and the NSAID to help prevent CME. It really is no issue whatsoever," he states.

One alternative to the treatment burden of topical steroids recently received FDA approval. DEXYCU (Icon Bioscience Inc.; Newark, California) is an extended-release dexamethasone suspension intended for injection behind the iris and in front of the IOL at close of surgery. DEXYCU's intracameral dose is 5 μ L (equivalent dexamethasone dose: 517 μ g) "The medication dissolves over three weeks and removes the need for a topical corticosteroid for most patients," says Eric D. Donnenfeld, MD, clinical professor of ophthalmology, New York University and trustee, Dartmouth Medical School, and lead investigator for the DEXYCU clinical studies. Dr. Donnenfeld says the manufacturer hopes to make DEXYCU available sometime in 2018.

Until the Verdict Comes in

Dr. Zavodni, who uses both intracameral Vigamox and compounded preparations, summarizes the dilemma faced by surgeons who want to proceed with injections to prevent

infection. “The use of intracameral antibiotics in the United States is on the rise (41 percent of ASCRS surgeons in 2017 clinical survey results),” he observes. “Yet, two large barriers to ubiquitous adoption remain: First, there is no FDA-approved antibiotic, and as a result there is no uniform/commercially produced, single-use sterile product available here. Secondly, there are safety concerns regarding medication toxicity and compounding errors.

“Currently, to use intracameral antibiotics, one must either tackle the legal and logistical challenges of preparing a medication packaged and approved for topical use in the eye (i.e., Vigamox), or rely on a compounding pharmacy to prepare such medications,” he continues. “Despite 503B status-designation standards for certain compounding pharmacies, there will always be some level of risk of dilution error and contamination, given such a production model. Concentration errors with intracameral cefuroxime have been associated with toxic anterior segment syndrome and retinal toxicity. Compared to cefuroxime, vancomycin and moxifloxacin are technically more easily compounded. However, there is concern about an association between intracameral vancomycin and HORV, which has curtailed its use in the U.S. Thus far, intracameral moxifloxacin seems to be relatively safe at standard concentrations ranging from 0.25% to 0.5%, so it has become the most popular intracameral choice of U.S. surgeons,” he says.

The “less-drops” approach—giving patients compounded fixed combinations of topical antibiotic/anti-inflammatory postoperatively, instead of separate antibiotic, steroid, and NSAID drops—has been adopted by some surgeons attempting to decrease costs to patients and increase their compliance. One small study found a fixed-dose antibiotic/steroid

Steps Taken to Avoid Infection (in Addition to Iodine)

Topical anti-inflammatory and antibiotic drops postop:	67%
Intraocular injection of combined antibiotic/steroid:	7
Combined topical mixture of antibiotic/anti-inflammatory:	5
Topical antibiotic and a combined mixture of steroid/NSAID:	14
Other:	9

Respondents (n=83) to the e-survey published in this month's *Review of Ophthalmology* showed a strong preference for topical antibiotic and anti-inflammatory drops to prevent infection and CME after cataract surgery.

drop to be just as effective at post-phaco inflammation control as an intracameral antibiotic/steroid injection, and no cases of endophthalmitis occurred in any eyes studied.⁸ Another compared eyes that received fixed-combination antibiotic/steroid drops with eyes receiving the components of those drops separately after cataract surgery. The fixed-dose combination was just as effective as the individual drops in preventing infection and controlling inflammation after surgery.⁹ One study, funded by a grant from Imprimis Pharmaceuticals, compared postop eyes that got a transzonular injection of the company's compounded Tri-Moxi-Vanc with eyes receiving topical Pred-Moxi-Ketor drops (one week postop) followed by Pred-Ketor (two to four weeks postop). Both treatment modes appeared to have equal therapeutic benefits, but patients reported greater satisfaction with the injection.¹⁰

Dr. Silverstein says that his concerns about the sourcing and handling of ingredients deters him from using compounded drugs. He also worries about the potential for the presence of pharmacologic fillers that could trigger rare but serious hypersensitivities in some patients. “Especially because we’re talking about something that goes into the eye, I’m not a strong fan of compounded medicines because of these rare but potential complications,” he says.

To help ensure the efficacy of what does go into his patients’ eyes, Dr. Silverstein uses only branded eye drops. “One thing that people rarely discuss is that generic steroids and NSAIDs are not as uniformly effective as their branded counterparts,” he says. “I’ll occasionally see someone come in with postop uveitis, and I’ll insist that they get off generics and switch to reliable branded topical drops.”

Dr. Arshinoff sticks to a branded agent for intraocular injection. “One problem that we have now is that all Vigamox is becoming genericized, with multiple generic versions being sold in both Canada and the U.S. So if I was going to use them—and I don’t—I would check with the company that it was the same formulation before I’d use it in someone’s eye,” he cautions. “Sandoz is owned by Alcon (Novartis) and Alcon has assured me that the Sandoz generic moxifloxacin is identical to Vigamox.”

One generally accepted component of endophthalmitis prophylaxis is povidone-iodine.¹¹ “Everyone uses Betadine. We all clean the lashes and drape them carefully and use Betadine 10% to wash the face and 5% eye drops for at least five to 10 minutes before surgery,” says Dr. Arshinoff.

“The only thing we know to decrease periocular and perioperative bacterial load—and most likely

(Continued on page 61)

ONLY

AzaSITE[®]

(azithromycin ophthalmic solution) 1%



Now included in the
EyeRx Direct[®] Service

Patients save significantly on their
prescription and AzaSite[®] can be
delivered to their home for free

Visit azasite.com to learn more



Whither Monofocal Toric IOLs?

Liam Jordan, Associate Editor

Where do monofocal toric lenses fit into an increasingly multifocal-centric market?

With the Symphony extended-depth-of-focus lens, RESTOR multifocal torics, and the Trulign IOL, doctors can now combine the features of multifocality/presbyopic correction and toric correction into one lens. Despite these advancements, Kevin Miller, MD, a professor of clinical ophthalmology, David Geffen School of Medicine at UCLA, says, “There are quite a few instances where we like to use monofocal lenses in lieu of multifocals. I probably put in as many toric monofocals as toric multifocals. It’s not a small sample size.”

This leads to the question, when would a patient or doctor prefer to implant a monofocal toric lens over the ostensibly more advanced and multitasking presbyopic IOL option? In this article, we’ll delve into some of these reasons.

Mono- vs. Multifocal Torics

Despite the popularity of premium IOL options, experts say that there are plenty of reasons to recommend a monofocal toric rather than its premium counterpart.

- **Coexisting conditions.** Perhaps the largest limiting factor for toric multifocal lenses are patients who present with coexisting ocular pathologies. Dr. Miller describes some of the many

pathologies that would make implanting a toric multifocal inappropriate. “You’ll see patients with amblyopia, epiretinal membranes, macular degeneration, macular edema, macular holes, macular schisis, vitreoretinal traction, advanced glaucoma, ocular misalignments, loose zonules, dry eye, basement membrane degeneration, et cetera,” he says. “There are a thousand-different corneal, retinal, optic nerve, and central pathologies that could result in a poor visual outcome if you implanted a multifocal lens. These comorbidities basically close the lid on multifocals, but they don’t close the lid on a monofocal toric to correct astigmatism.”

Cynthia Matossian, MD, an ophthalmologist based in Doylestown, Pennsylvania, also weighs in on the significance of these ocular pathologies. “One group of patients where I wouldn’t recommend a multifocal toric lens is those that have coexisting pathologies that affect the macula, retina and the optic nerve. If they have macular degeneration (typically early to moderate) with a strong family history, or if they have other kinds of macular diseases, as long as it’s not that progressive, I’d go with a monofocal,” she says. “They could have a macular hole or epiretinal membrane. Addressing these preop will absolutely

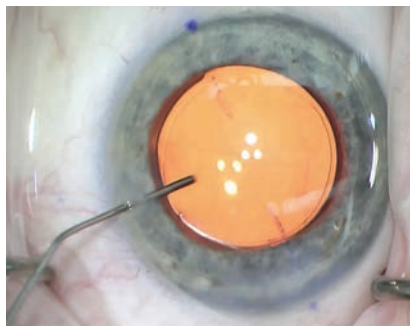
help their astigmatism and outcomes, but they won't do well with a multifocal because their vision is already compromised; giving them a clearer refractive option is great but splitting the light or adding potential light phenomena like starburst, halos or spiderwebbing will make things much worse. In this group of patients, where a lot of people fall, a monofocal toric is definitely the way to go.

"Glaucoma is also a big issue with multifocal toric lenses," Dr. Matossian continues. "These patients have compromised optic nerves, so, implanting a multifocal toric in patients who are already having issues with depth of field is asking for trouble. They won't do as well as they would with a monofocal toric."

Robert Lehmann, MD, an ophthalmologist based in Nacogdoches, Texas, reaffirms the issues that arise when implanting a multifocal toric in patients with less-than-healthy eyes. "I don't push multifocality—especially in patients who have glaucoma, Fuchs' dystrophy, severe dry eye, et cetera. There are corneal issues where I wouldn't want to use a multifocal lens because the results aren't going to be good. If you're dead-set on implanting a multifocal toric lens, ideally, the patient would have a virgin cornea. Outside of that, I would be hesitant to implant one over a monofocal to correct their astigmatism."

When discussing where the Bausch + Lomb Trulign fits into this landscape, Dr. Lehmann says, "Typically, I consider the Trulign in much older patients, usually above 75 years old, because we don't see as many issues with glare, halos or contrast sensitivity. But if you implant a multifocal and decrease their contrast sensitivity when they're younger than that, you're not doing them any favors because they might be at risk for a condition that will later on decrease their contrast sensitivity on top of that."

• **Level of astigmatism.** Aside from the obvious red flags of ocular history and coexisting conditions, a patient's



When deciding to implant a monofocal lens, take into account patient preference.

level of astigmatism may also dictate whether or not a monofocal toric is more appropriate than a multifocal lens. "There is quite a bit of room for monofocal implants in our spectrum of patients scheduled for cataract surgery," Dr. Matossian says. "A substantial portion of those patients have astigmatism of 1 D or greater where these toric monofocal lenses would be a great choice. Unfortunately, we don't have low-cylinder IOLs in this country. They start at 1 or 1.25 D."

Dr. Miller specifies the issues involved when a patient's corneal astigmatism exceeds the toric powers available. "You wouldn't implant a multifocal lens in an eye with corneal astigmatism that exceeds the dioptric correction available in the marketplace. If you have a patient with 3.75 D of corneal astigmatism, industry simply doesn't sell a lens at that toric power in the United States. So really there's no choice—you would implant a monofocal toric instead."

• **Patient preferences.** Despite the numerous medical reasons to choose a monofocal toric lens over its multifocal counterpart, sometimes, it's up to the patient. "I see a lot of patients who have read things about how bad multifocals are," Dr. Miller says. "They've read about the glare and halos or maybe they have friends who said, 'I would never do this again,' and so they decide they just don't want a multifocal."

"You also encounter patients who have worn glasses or contact lenses all

of their lives to correct astigmatism, and they would be delighted if all they had to do was wear reading glasses for near vision," Dr. Miller continues. "If they're fine with reading glasses, monofocal torics are the way to go."

Dr. Lehmann also shares some of his insights into patients deciding to stick with a monofocal lens. "The patient that sits there and says, 'I'm very happy with glasses,' is a terrible candidate for these newer multifocal torics. We hear from some, 'My grandchildren wouldn't know who I was without my glasses,' so they're not likely to benefit from a multifocal."

"Occasionally, you'll see people who are in a work environment where they wear glasses all the time and it doesn't bother them. Again, a monofocal toric to correct their astigmatism is going to be better for their lifestyle," Dr. Lehmann says. "What's interesting is patients oftentimes begin the conversation by saying, 'Well I've worn glasses for X years,' and you can't predict the other half of the sentence. Seventy percent say, 'I'm content with glasses.' The other 30 percent say, 'I hate them! There's a way to eliminate them?' You just need to pay attention to their habits and lifestyles."

In addition to the habits of patients, doctors may also need to take into account personalities to see if a patient is going to be satisfied with a multifocal toric. When asked about identifying patients whose personalities would benefit more from a monofocal toric, Dr. Matossian says it's hard to pinpoint. "Some studies or authors say if someone is an extreme perfectionist, they may not do well with a multifocal," she says. "They won't be satisfied if they work under dim lighting conditions because a multifocal lens splits the light—about 40 percent to distance, 40 percent to near, and the rest is lost. So it's not ideal for people who work in dim conditions. Invariably, they are going to have issues."

"Say you're a limo or taxi driver," she continues. "They're not ideal multifo-

cal candidates because of all the nighttime driving that comes with those occupations. They would benefit from a different lens because the monofocal toric would correct their astigmatism and help them see that much better.”

Dr. Lehmann agrees, adding that it can be difficult to pin down who would be a better monofocal toric candidate based on personality alone. “We tried to come up with an evaluation of some sort—a way to measure a patient’s psychology to predict which way the wind is blowing in their mind. I think we’re still flailing and failing, having not developed a psychology of multifocal lenses.”

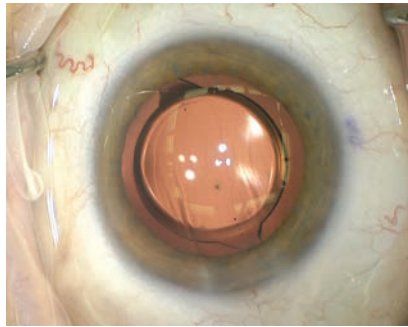
Dr. Miller, however, finds that personality types don’t determine whether he implants a multifocal or toric monofocal lens. “I find that those cautions we used to hear, like ‘don’t implant engineers, don’t implant type-A personalities or whiny people, don’t implant pilots, et cetera,’ to be untrue,” he says. “The final word on happiness with multifocal implants is simple—it’s refractive error. If it’s significant, no matter how happy-go-lucky the patient, he or she is not going to be satisfied with the results. You don’t need to select based on personality type.”

Qualitative Issues

Despite the advancement of multifocal toric lenses, patients and doctors still keep the qualitative issues with these lenses in mind when deciding whether to use them.

“I would not implant a multifocal in people who are very prone or sensitive to halos, starbursts, spiderwebbing or any kind of light phenomenon because of their careers,” Dr. Matossian avers. “I’ll go with a monofocal toric because they won’t have the associated lighting issues. It still corrects their astigmatism without inducing any light phenomenon.”

In a 2016 study evaluating the efficacy of both multifocal and mono-



The risk of qualitative vision issues may push patients toward monofocal torics.

focal intraocular lenses after cataract extraction, researchers found that despite patients with a multifocal lens relying less on glasses, there were significant instances of halos and glare.¹

In the realm of extended-depth-of-focus lenses, in the Symphony’s FDA trial, researchers compared it to a monofocal lens. The data examined visual symptoms of the Symphony group over the past seven days at six months. In a comparison between the Symphony (n=147) and a monofocal implant (n=148) looking specifically at halos, starbursts and glare, the Symphony group reported no halos in 40.8 percent (n=60) of implants versus 70.9 percent (n=105) in the monofocal group, no starbursts in 42.2 percent (n=62) for the Symphony versus 74.3 percent (n=110) in the monofocal group, and no glare in 42.8 percent (n=62) for the Symphony versus 57.4 percent (n=85) in the monofocal group. In both groups, <10 percent of patients were “very bothered” by these symptoms.²

Financing

Another issue that might inform a patient’s decision to go with a monofocal toric is cost. “I’ve certainly recommended a monofocal lens over a multifocal because of cost,” Dr. Lehmann says. “You wouldn’t want a patient to feel that they’re getting second-best because they can’t afford this particular

technology. You can still get the job done very well and get them results that they’re happy with using a monofocal. The technology we have now basically guarantees that a patient is receiving a reliable and effective treatment, and not getting the short end of the stick, so to speak.

“In any field there are technologies that cost more money, and if a patient is unable to afford those, obviously you can try to make it affordable with financing and other options,” Dr. Lehmann continues. “But I think it’s not a healthy thing to make a patient go with a multifocal they would struggle to afford when he’s going to see well with a monofocal and likely to be very pleased. I also don’t want them leaving the office feeling that they really settled for some kind of worse option because, frankly, that’s just not the case.”

Dr. Matossian also discusses her experience with financing issues regarding multifocal lenses. “Even though some patients have astigmatism,” she says, “they just don’t have the funds to pay for both a toric and simultaneously multifocal IOL because there’s a pricing difference. I would opt for a monofocal in that case.”

Despite the availability of multifocal toric lenses, doctors and patients are often opting to go with monofocal torics due to finances, personal preference and which lens will give them the best outcomes. “All together, these categories account for at least half, or maybe close to 65 percent of my practice,” Dr. Miller says. “I would say the toric multifocals are a small subset.” **REVIEW**

Dr. Miller is a consultant for Alcon and J&J Vision. Dr. Matossian is a consultant for Alcon and Bausch + Lomb. Dr. Lehmann is a consultant for Alcon.

1. Multifocal versus monofocal intraocular lenses after cataract extraction. <http://onlinelibrary.wiley.com/doi/10.1002/14651858.CD003169.pub4/abstract> accessed 12 January 2018.

2. Summary of safety and effectiveness data (SSED). https://www.accessdata.fda.gov/cdrh_docs/pdf/P980040S065B.pdf accessed 8 February 2018.

E

V E R Y

D O S E

C O U N T S

STRIVE TO SEE THE BEST RESULTS POSSIBLE

Regular fixed-interval dosing of long-term treatment with anti-VEGFs has been shown to provide better gains and maintenance of vision, compared to PRN or treat-and-extend dosing regimens, in some patients with Wet AMD and DME.¹⁻⁶

Ask your Regeneron representative what we can do to help ensure patients come in for their scheduled treatment.

anti-VEGF = anti-vascular endothelial growth factor; AMD = Age-related Macular Degeneration; DME = Diabetic Macular Edema.

References: 1. Heier JS et al. *Ophthalmology*. 2016;123(11):2376-2385. 2. Rosenfeld PJ et al. *N Engl J Med*. 2006;355(14):1419-1431. 3. Ho AC et al. *Ophthalmology*. 2014;121(11):2181-2192. 4. Nguyen QD et al. *Ophthalmology*. 2012;119(4):789-801. 5. Kaiser PK et al. *Ophthalmol Retina*. 2017;1(4):304-313. 6. Peden MC et al. *Ophthalmology*. 2015;122(4):803-808.

REGENERON

© 2018, Regeneron Pharmaceuticals, Inc. All rights reserved.
777 Old Saw Mill River Road, Tarrytown, NY 10591

01/2018 US-OPH-13911

Making the Most of Today's Biometry Tech

Christopher Kent, Senior Editor

Today's advanced technology improves outcomes, but caution and training still pay off.

Over the past 50 years, biometry has become an essential part of cataract surgery, thanks in part to an ever-increasing desire for “perfect” refractive outcomes. In a kind of feedback loop, better technology for making the relevant measurements has resulted in better outcomes, raising patient expectations and necessitating even more refinement in the technology. That evolutionary loop continues today.

A key turning point in the evolution of biometry occurred with the switch from ultrasound measurement to optical biometry. “The advent of refractive cataract surgery really began with the use of optical biometry, starting with the first IOLMaster more than a decade ago,” notes Eric D. Donnenfeld, MD, a clinical professor of ophthalmology at New York University Medical Center and a partner at Ophthalmic Consultants of Long Island. “For the first time, we had the ability to more accurately predict IOL power in patients having cataract surgery.” Since that development, a host of additional technological improvements have pushed the envelope even further, steadily increasing the accuracy and reproducibility of modern biometry devices.

With ever-more-powerful tools at ophthalmologists’ disposal, the im-

portance of using them effectively to create optimal outcomes increases every year. Here, ophthalmologists with extensive experience in optical biometry discuss how the technology has evolved in recent years, and share their advice for making the most of today’s instruments.

New vs. Old Technology

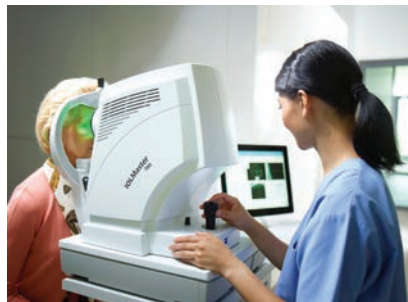Today’s biometry devices serve today’s ophthalmologists better than the older instruments, for a number of reasons. One reason is the increasing number of patients who’ve undergone previous refractive surgery. “It used to be that the person who had prior refractive surgery was sort of a curiosity—an unusual situation for a cataract surgeon to encounter,” says Terrence P. O’Brien, MD, a professor of ophthalmology and director of the Refractive Surgery Service at Bascom Palmer Eye Institute of the Palm Beaches. “I can recall when we only saw a few cases. They’d throw our routine off; we’d have to step back and perform a lot of extra calculations and try to figure everything out. Now, people who’ve had prior refractive surgery of one type or another are presenting routinely every week.

“This is where some of those bells and whistles on the new devices are

valuable,” he continues. “Despite all of the changes we’ve seen, axial length and keratometry still have to be determined accurately, and thanks to today’s technology, axial-length measurement has come a long way. That process used to involve a one-dimensional A-scan ultrasound; it was subject to a lot of variability that could have a significant impact on the outcome. The patient wasn’t obliged to fixate or look in one direction, but if the patient wasn’t properly aligned the measurement might not represent the actual distance to the fovea. That was a big problem.

“Of course, even back then there were ways to try to determine whether the measurement was accurate,” he says. “You could examine the peaks on the printout, and with some experience you could tell if the patient was looking askew, meaning you weren’t getting reliable data. But today, determining the axial length optically has revolutionized this, especially with the partial-coherence interferometry technology found in the IOLMaster and Lenstar. This is now a noncontact, one-click measurement requiring only topical anesthesia. What used to be a very challenging, arduous task with suboptimal reliability is now much simpler, with several orders of magnitude better accuracy.”

Dr. O’Brien adds that these instruments also have improved the reliability of keratometry measurements. “That’s the other key variable for predicting the optimal lens power,” he notes. “It’s a challenge to obtain these measurements, because the measurement process isn’t the only issue; the ocular surface may change over time. That means obtaining good keratometry may require repeat measurements to make sure the ocular surface is stable. Also, when manual keratometry was the gold standard for measuring corneal power, user skill and experience were very important. If you didn’t make the measurements



All images: Steven C. Schallhorn, MD

Today’s biometry devices perform multiple functions with minimal technician management, but technicians still need thorough training to catch warning signs that a reading isn’t reliable.

yourself, you weren’t always sure of the quality and accuracy of the data. Today, automated keratometry is built into the popular optical biometers, so that process is now systematized into a single device and the data is obtainable with a single click in most cases. That increases accuracy and makes it easy to obtain repeat measurements.”

Do You Need the Very Latest?

Given the rapid advances in biometry technology and frequent addition of new features, surgeons today are faced with the question of when it’s worth upgrading to the “latest and greatest” iteration.

“All of the modern optical biometers are good when it comes to measuring axial length,” says Dr. Donnenfeld. “What the newest machines do, particularly the IOLMaster 700, is use swept-source OCT to verify the location of the macula. That helps prevent axial-length measurement errors. In fact, errors in the keratometry, rather than the axial-length measurement, have become the number-one reason patients have erroneous IOL power predictions. But even the keratometry is more reproducible because the IOLMaster 700 uses telecentric keratometry. That technology makes the measurements more reproducible even when the user doesn’t have the keratometry in perfect focus.”

“The latest versions of the IOLMaster and Lenstar are really terrific,” agrees Dr. O’Brien. “They allow us to measure additional parameters, including lens thickness, corneal pachymetry and anterior chamber depth. And now several of the latest instruments, like the IOLMaster 700 and some competitors, have added swept-source optical coherence tomography. They acquire the measurements even more quickly, and even with a very dense cataract we can obtain a reliable measurement with a two-dimensional configuration of the foveal anatomy.”

Steven C. Schallhorn, MD, former director of cornea and refractive surgery at the Naval Medical Center in San Diego, now in private practice in San Diego, believes the latest generation of biometers will improve the predictability of outcomes. “It’s not that outcomes were unsatisfactory with earlier-generation biometers,” he says. “This is simply an evolutionary step forward. The latest-generation devices provide measurements for the most advanced power calculation formulas, and they make it easier to ensure the accuracy of their measurements. Having more accurate measurements and added parameters for certain formulas will collectively drive better outcomes.”

Dr. Schallhorn notes that historically, surgeons relied on simple keratometry, which measures only two points on the cornea. “Basic keratometry makes a number of assumptions about the corneal shape, such as that the cornea is spherical (which it isn’t), and it applies a simplistic adjustment for the power of the posterior cornea,” he points out. “Those assumptions have been considered reasonable for the majority of patients, but they are not reasonable, for example, in patients who’ve had prior refractive surgery. Corneal asphericity and other anomalies can significantly impact proper IOL power selection. Biometers that

derive more information from the cornea are going to help improve outcomes.”

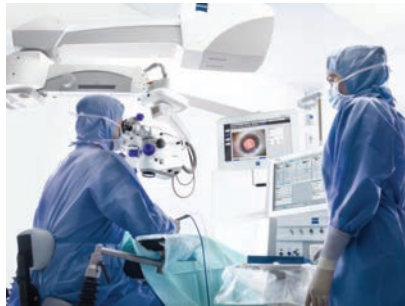Dr. Donnenfeld agrees, but with a qualification. “The more advanced technologies give patients a better chance of achieving the spectacle independence they’re looking for,” he says. “Every time you have an improvement in technology there’s an incremental improvement in the quality of the measurements, and we’ll continue to see incremental improvements as the technologies get better over the next couple of years. But these are incremental improvements, not disruptive ones. The older technologies are still very good, and the delta is not that great. I think the most important factor is using optical biometry instead of A-scan ultrasonography.

“As we all know, better technology generally yields better results, so it’s nice to have the latest technology,” he adds. “In addition, the new technology has dramatically reduced the amount of time required to take these tests. The new IOLMaster 700, for example, takes less than 30 seconds to perform a reading. However, at the practical level it’s always a cost-effectiveness decision the surgeon has to make.”

Before Taking the Measurements

To help ensure the most accurate and reproducible biometry data, surgeons recommend these strategies:

- **Make sure your technicians are well-trained.** The latest instruments have definitely reduced the likelihood of operator error, but errors still can (and do) happen. A significant factor in preventing errors and correcting them quickly if they occur is having an astute, well-trained technician doing the data capture. “The person you’re trusting to make the biometry measurements should be well-trained and capable,” says Dr. Schallhorn. “You need to be confident that the technician knows what he or she is doing and



Surgeons should always take the time to double-check the biometry data for tell-tale warning signs of an unreliable reading before proceeding with surgery.

can obtain a proper capture.”

How much training do technicians need? “It depends on the technician,” says Dr. Donnenfeld. “I’d say one half-hour to an hour of training would suffice. The more modern the technology, the more reproducible the results become, which means there will be less variability between technicians. The older technology was much more technician-dependent, which is why many surgeons relied on one technician to do all of the readings.”

- **Rely on just a few technicians to acquire your biometry measurements.** “This is not a situation in which you want to cross-train dozens of people,” says Dr. O’Brien. “It’s better to have one or two designated individuals in your practice who do this repeatedly. When someone does this over and over, they’re more likely to know when the measurement needs to be redone; they’re less likely to miss something that violates the validation criteria. That means you’ll be getting better reliability and higher reproducibility. Having five or six people sharing this task will introduce more variability into your practice. Of course, you might want to cross-train a few technicians in case of illness or absence, but it’s better to have just a couple of ‘go-to’ people who do this over and over again. This will provide more reliable, reproducible data.”

- **Be sure to ask whether the patient wears contact lenses.** “Many

patients old enough to have cataracts don’t wear contact lenses, but some do, and that’s critical to note,” Dr. Schallhorn points out. “That can affect the accuracy of your biometry measurements, especially if the contacts are gas permeable.”

Dr. Donnenfeld agrees. “We ask patients to remove their soft contact lenses for at least three days prior to biometry—a week ahead if the soft lenses are toric,” he says. “If the patient wears gas-permeable lenses, we have the patient leave them out for a month so the cornea can return to its normal shape. This helps to ensure that both the biometry and keratometry are accurate.”

Dr. Schallhorn adds that the surgeon should be on the lookout for any patient that has a recent history of orthokeratology. “As with RGP contact lens wearers, those contact lenses can alter the corneal shape for weeks or months after discontinuing.”

- **Make sure the ocular surface and tear film are stable.** “Because patients are eager to complete their cataract surgery and the team is trying to expedite that process, there may be a little bit of a rush to the OR,” notes Dr. O’Brien. “In reality, some patients may have significant ocular surface disease that should be treated adequately before biometry is repeated. So make certain that the patient’s ocular surface is stable before relying on these measurements.”

“Patients with ocular surface disease have been shown to have markedly reduced accuracy on their keratometry,” Dr. Donnenfeld points out. “For that reason we want to optimize the tear film prior to performing IOL calculations. To that end, we like to use artificial tears, and if necessary, immunomodulation with cyclosporine or lifitegrast. We also believe having the patient take an omega-3 supplement will help to improve the quality of the tear film.”

- **Don’t use eye drops of any kind**

How Biometry Has Changed in the Past 25 Years

Terrence P. O'Brien, MD, a professor of ophthalmology and director of the Refractive Surgery Service at Bascom Palmer Eye Institute of the Palm Beaches, recalls that when biometry was far more primitive than it is today, ophthalmologists' ideas about what outcomes were "acceptable" were very different. "A few decades ago, biometry was difficult to perform and outcomes were much less predictable," he recalls. "I remember seeing papers discussing how many patients would fall within a certain standard deviation that would be considered acceptable if we just implanted the same-power lens in every eye! At that point, having an outcome within 2 D of the target was considered reasonable, and if we implanted a 20-D 'standard' lens in everyone, about 70 percent would be within 2 D of plano. We hoped those patients would be happy wearing glasses postoperatively. Needless to say, biometry

has come a long way since then."

Dr. O'Brien notes another thing that's changed since then: the recognition that biometry is an integral part of the procedure. "Today, we understand that preoperative preparation—planning and careful biometry and lens power calculation—are of pivotal importance to a good clinical outcome," he says. "Those steps are every bit as important as what takes place during the surgery. They're especially important today because patient expectations are so high. I often quote an old formula: Patient satisfaction equals the clinical outcome minus the patient's expectations. That means that if the patient comes in with very high expectations, the clinical outcome has to be very close to the target in order to achieve overall satisfaction. Biometry is an essential part of that."

—CK

right before taking corneal measurements. Jack T. Holladay, MD, MSEE, FACS, a clinical professor of ophthalmology at Baylor College of Medicine and the developer of the Holladay I, II and Refractive formulas, notes that although the intention when using drops before taking a measurement may be to offset dry eye in the interest of obtaining a more accurate reading, the drops can cause corneal steepening or punctate epithelial keratitis. "A better approach is to simply ask the patient to blink frequently," he says. "The measurement should be taken about one second after the final blink, which will allow the tear film to stabilize."

• **Postpone biometry in patients with obvious superficial punctate keratitis in the visual axis.** "Measurements taken under these conditions will almost certainly be inaccurate," Dr. Donnenfeld notes.

When Taking the Measurements

These strategies will help prevent inaccurate measurements:

• **Make sure your technician is paying attention to patient fixation.** "This is a key source of inaccurate measurements," says Dr. Schallhorn. "If your unit includes OCT with

macula-imaging technology, you can check the image of the foveola to confirm fixation. However, most units don't have OCT yet. That means the technician has to be paying particular attention to this issue."

"This may be an especially big problem in patients who are highly myopic," adds Dr. Donnenfeld. "Actually visualizing the biometry location with new OCT biometers such as the IOLMaster 700 gives the surgeon certainty that the biometry is focused in the right place."

• **If you perform auto-K, make sure the keratometries agree.** "It's good to verify that the keratometry found on the optical biometer correlates with the keratometry on auto-Ks or topography, whether you're using the IOLMaster or the Lenstar," says Dr. Donnenfeld. "A lot of people verify these results with a different reading. Clinicians in general have stopped using manual keratometry, but many doctors still do autokeratometry and topography."

Dr. Schallhorn agrees. "If the biometer-derived keratometry is substantially different from manual or topographic keratometry, that's a sign of trouble," he says.

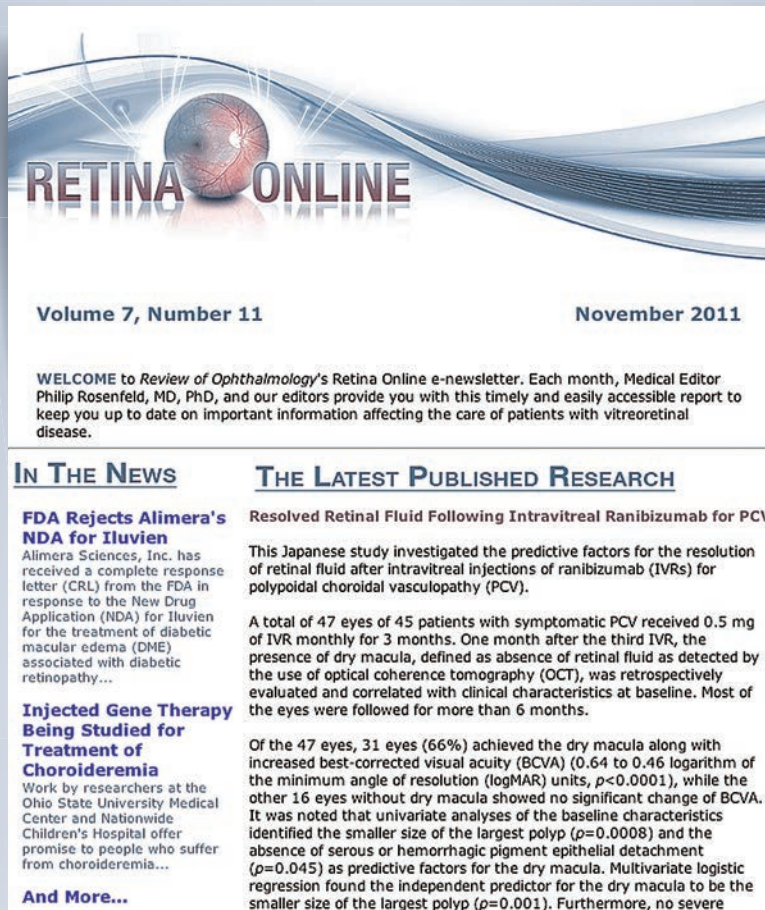• **Teach your technician to check the standard deviation on the**

printout. "The IOLMaster, the Lenstar and the Pentacam AXL all provide a standard deviation reading on their printouts, based on the multiple K-readings they take, usually three," notes Dr. Holladay. "Doctors usually see standard deviation expressed in diopters, because diopters are meaningful for ophthalmologists at a practical level. They know that a standard deviation greater than 0.2 D indicates a problematic reading, which generally happens in about 30 percent of eyes. In most normal patients with a healthy cornea, that number should be close to zero."

"However, these printouts present this information in millimeters or microns instead of diopters," he continues. "It's the same measurement, just expressed in different units. K-readings take a measurement of the anterior corneal radius in millimeters and convert it to a diopter power. For example, a cornea that's 7.5 mm in radius has 45 D in keratometric power. So a standard deviation of 0.2 D will be presented as the equivalent radius measurement, which is 0.03 mm, or 30 μ m. That means that if the standard deviation on the printout is that amount or greater, it's exactly the same as a standard deviation of 0.2 D or greater. It's a warning flag that the

RETINA ONLINE

E-NEWSLETTER



Once a month, Medical Editor Philip Rosenfeld, MD, PhD, and our editors provide you with timely information and easily accessible reports that keep you up to date on important information affecting the care of patients with vitreoretinal disease.

3 EASY WAYS TO SUBSCRIBE!

<http://www.jobson.com/globalemail/>

Fax: 610.492.1039 or Call: 610.492.1029

REVIEW[®]
of Ophthalmology

measurement can't be trusted because it's not repeatable.

"The problem is, if the technician doesn't understand the significance of this number, he or she will ignore it," he says. "So, you need to make sure the technician knows about this and checks this number. If the number is high, then the patient should be taken to the topographer or tomographer to confirm the measurement, and the technician should try to determine the reason for the problem. The patient may have dry eye, irregular astigmatism, keratoconus or other issues. By the time the doctor sees the report, the IOL calculation is done; it shows the lens and power. So, the technician needs to be aware of this to catch the problem before the IOL calculation is performed."

- ***Make sure the technician checks the signal-to-noise ratio of the axial-length measurement.*** "If that ratio is less than 2, it's not a reliable measurement," says Dr. Holladay. "The ratio can go as high as 12, which is good; if it's 2 or less, you shouldn't use that axial length measurement. The technician should go back and redo it. If a good ratio can't be obtained using that instrument, it may be necessary to use an ultrasound machine to measure the length of the eye. So, be sure your technicians check this number and don't accept the measurement if the signal-to-noise ratio is below 2."

- ***Be on the lookout for disparities between the left and right eyes.*** "Unless there's a good reason for the disparity—and there could be—a great disparity between the two eyes is another indication that at least one of the measurements is inaccurate," says Dr. Schallhorn.

Knowledge is Power

Although it's easy to simply rely on technology to carry the day, the odds of catching an error go up significantly

if you have a solid understanding of what the technology is doing.

"To achieve high-quality outcomes, a basic understanding of the technology and formulas is essential."
—Terrence O'Brien, MD

"In order to achieve high-quality refractive outcomes, having a basic understanding of the technology and formulas is essential," says Dr. O'Brien. "That understanding makes it possible to readily determine the quality and reliability of your preoperative data and formula predictions. Fortunately, it's become increasingly simple to obtain reliable, high-quality measurements using today's noncontact optical biometers. These devices also have the advantage that many of them come with the most advanced IOL power calculation formulas built right into the platform. Nevertheless, the better you understand what's happening, the more likely you are to have consistently good outcomes. That's especially true when you're dealing with complex cases, such as eyes that fall outside of the average range, or eyes that have had prior surgery—in particular, prior refractive surgery."

For example, it's helpful to know that different prior refractive surgeries will affect the corneal radius of curvature differently. "Both the front and back surfaces of the cornea have refractive power, and that has to be accounted for when predicting the optimal lens power to implant," notes Dr. O'Brien. "For that reason, after you acquire your measurements, an index of refraction is applied to approximate the effective keratometric power of

the entire cornea. That's where you may sometimes encounter problems, because that index of refraction is not the actual refractive index of your patient's cornea. It's a number that's based on the anterior and posterior surfaces in an average eye.

"This complicates matters when an eye has had previous refractive surgery because of the changes in corneal curvature caused by that surgery," he continues. "If the patient had radial keratotomy, with radial incisions in the periphery to flatten the central cornea, both the anterior and posterior curvatures will have been flattened together. In contrast, PRK and LASIK change the anterior curvature while leaving the posterior curvature relatively unchanged. That means the fudge factor for the radius of curvature is likely to be inaccurate in these eyes. That's significant because most of the power formulas calculate the total corneal power and the effective lens position based on the anterior surface radius of curvature measurements, so an error in that number can lead to myopic or hyperopic surprises after cataract surgery."

Dr. O'Brien notes that the latest formulas are getting better at taking this problem into account. "The latest devices and formulas are designed to help determine a more accurate corneal power in these eyes, to account for the keratometric changes following refractive surgery," he says. "Some of our organizations are also working to help streamline this process for cataract surgeons. The American Society of Cataract and Refractive Surgery has a post-refractive IOL calculator that's online and accessible, that allows surgeons to use many of these formulas in order to compare and select the optimal power for an individual patient."

Practical Concerns

A few more strategies can help ensure optimal refractive outcomes:

• **Take time to verify for yourself that the readings make sense.** “The technician should look at the standard deviation of the axial-length readings to make sure the standard deviations make sense and the numbers are reproducible,” notes Dr. Donnenfeld. “However, it’s always a good thing to have surgeon verification.”

Dr. Schallhorn agrees. “The surgeon is ultimately responsible for ensuring that biometry was done properly and the correct IOL was selected and implanted,” he says. “A good technician will pick up a problem and address it immediately, but the surgeon should double-check the biometry numbers. Is there an unexplained disparity between the left and right eyes? Is there a good correlation between repeated captures? Is there a reasonable match between manual and biometry keratometry? Does the biometry keratometry reasonably match the topography? These are all things that the surgeon should look at to confirm that the calculation is going to be based on an accurate measurement.”

• **If you have OCT, consider checking the macula before planning your surgery.** “Even if OCT is not built into your biometer, it’s worth performing in a cataract patient,” says Dr. Schallhorn. “It can reveal abnormalities on the macula itself, such as an epiretinal membrane. An epiretinal membrane can be hard to detect clinically, but it’s relatively easy for an OCT to detect. If an epiretinal membrane is partly or mostly responsible for the decrease in vision, that’s very important information to help drive optimal care.”

• **Be sure to use the latest correction if the eye measures longer than 25 mm with optical biometry.** “Surgeons should be aware that very long eyes produce inaccurate axial-length measurements when measured using current optical biometry,” says Dr. Holladay. “The result tends to be a hyperopic surprise. Doug Koch, MD,

figured this out a few years ago and co-developed the Wang-Koch regression formula to correct for the error, to produce a better outcome. However, the formula tends to result in switching the hyperopic error to a smaller myopic error.

“Recently, I was able to analyze this measurement problem using a much larger database—20,000 eyes from Kaiser-Permanente’s database, compared to the 200 eyes Doug Koch worked with,” he continues.¹ “That allowed us to run a nonlinear regression. As it turns out, the measurement error becomes progressively greater the longer the eye, so correcting for it with a curve rather than a straight line produces better results; hence the nonlinear regression is more accurate than the linear regression. It results in zero mean error rather than a myopic or hyperopic error.”

Dr. Holladay says that as of November 2017 the new nonlinear regression formula has been implemented in the Holladay IOL Consultant software, so that it can be used with the Holladay I and II formulas. “It’s also available online at hicssoap.com under the calculator tab,” he says. “There are more than 1,000 surgeons out there using our software, but the other 9,000 need to be addressing this problem in long eyes, too. In the meantime, we’ve made the nonlinear regression available to the IOLMaster people so they can modify the formula in the instrument as well.”

• **Keep tracking your outcomes.** “Despite the advances in the technology that help make the whole process more user-friendly, reliable and accurate, surgeons should not stop tracking clinical outcomes,” advises Dr. O’Brien. “That’s a very important part of this process. The lens constant that’s a component of the IOL calculation formulas should be optimized for the individual surgeon’s outcomes, for each IOL that you might use. Optimization is a way to fine-tune this process

and gain even greater accuracy and higher-quality refractive outcomes.”

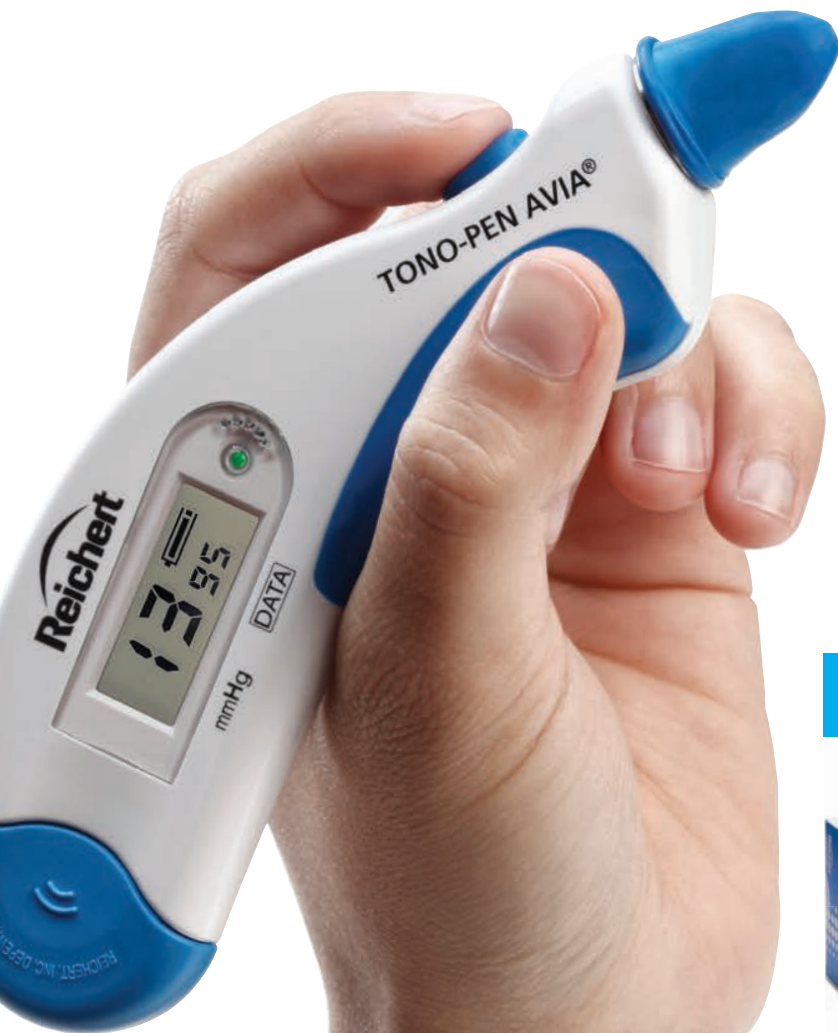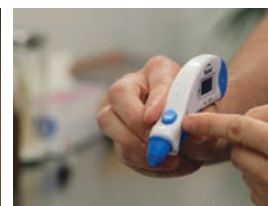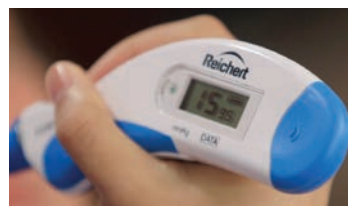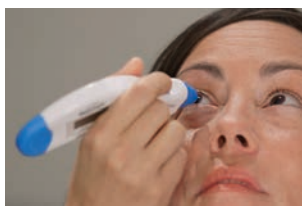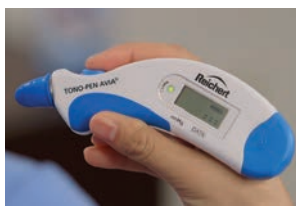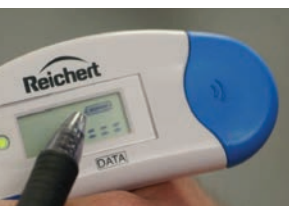What Lies Ahead?

The trend toward ever-improving biometric technology shows no sign of stopping, and the upcoming years will bring even more advances. Those advances will include technology that can analyze the posterior corneal surface. “It’s only been within the past several years that we’ve appreciated the role that the posterior cornea plays in IOL power selection,” says Dr. Schallhorn. “We now understand that to better estimate the optical power of the cornea, we need to accurately assess the posterior corneal shape. For example, whether posterior astigmatism is with-the-rule or against-the-rule has an impact on the outcome, and if the patient has had laser vision correction, the difference between the posterior and anterior corneal shape has been altered. That can play a significant role in the IOL power calculation.

“Unfortunately, that technology is not yet available in biometers,” he says. “Right now we have topography devices that can measure the posterior shape of the cornea; that allows us to take the posterior cornea into account in our calculations. However, because the measurement is not made in the biometer itself, it can be time-consuming, costly and inefficient. Next-generation biometers will address this.” **REVIEW**

Dr. Schallhorn is chief medical officer for Carl Zeiss Meditec. Dr. Donnenfeld is a consultant for Alcon and Zeiss. Dr. Holladay is president of Holladay Consulting, which is the distributor of the Holladay IOL Consultant Software (hicssoap.com). He is a consultant to Carl Zeiss Meditec. Dr. O’Brien has no financial ties to any product mentioned.

1. Melles RB, Holladay JT, Chang WJ. Accuracy of intraocular lens calculation formulas. *Ophthalmology* 2018;125:2:169–178.



Clinicians trust Tono-Pen[®] most.

Tono-Pen AVIA[®], the most advanced Tono-Pen[®] tonometer, fits comfortably in your hand. Its calibration-free and technician-friendly operation fits your busy practice.

Over 30 years of clinician-trusted accuracy and reliability fits your highest expectations.

Tono-Pen AVIA just fits.

Visit us at **ASCRS #532** for special show pricing or online at reichert.com/tonopenavia



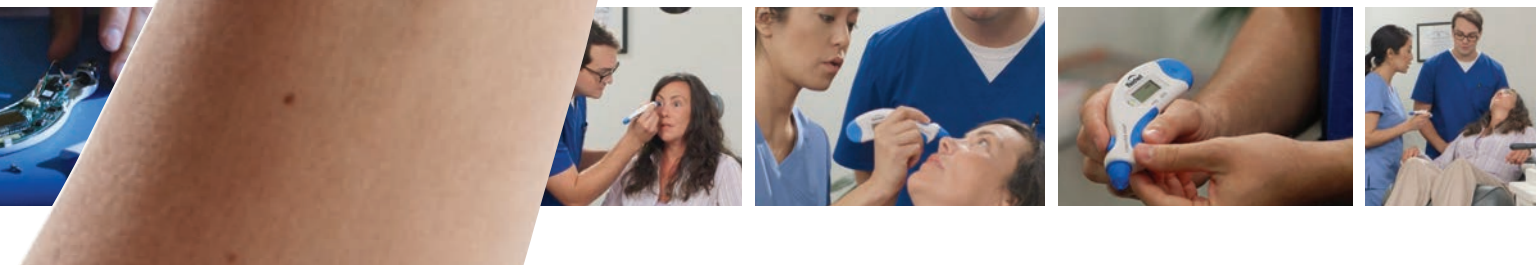
Genuine brand **Ocu-Film[®]** protects your patients and your Tono-Pen.



Advancing Eye Care. American Innovation.

AMETEK[®] © 2018 AMETEK, Inc. & Reichert, Inc. (03-2018)

Made in USA  · www.reichert.com ·     



Surgeons Slow To Embrace New Tech

Walter Bethke, Editor in Chief

Most surgeons use traditional techniques, though femto surgeons say they're using the laser more often.

In this year's cataract surgery technique survey, many of the surgeons' preferences, such as nucleofractis technique and the affinity for femtosecond cataract, are similar to those of previous years. One thing that has changed, however, is the usage patterns of surgeons who use the femtosecond laser for cataract procedures. Though most of their colleagues on the survey are shying away from the technology, these femto surgeons say they are getting more deeply involved, and are using the laser more frequently for the different phases of the surgery when compared to previous year's surveys.

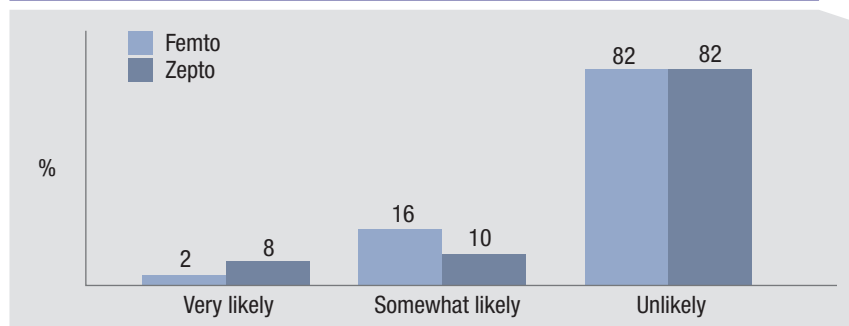
Surgeons' use of femtosecond lasers is just one aspect of this month's e-survey. This month, 997 surgeons of the 7,564 who received the survey

opened it (13.2 percent open rate) and, of those, 83 fully completed the survey. To compare your practice pattern with theirs, read on.


Friends of Femto

As mentioned earlier, the percentages of surgeons who use/don't use a femtosecond laser for some aspect of their cataract procedures are similar to previous years: Thirty-six percent use it and the rest don't (32 and 36 percent said they used the technology for cataract surgery in 2017 and 2016, respectively). However, while 88 percent of those using it say they used it for the capsulorhexis and 81 percent used it for nuclear fragmentation in 2017, this year, 97 percent and 93 percent, respectively, say they use it

Likelihood of Performing Femto- or Zepto-assisted Cataract Surgery Within a Year



Preferred Phacoemulsification Technique



for these steps.

Chicago surgeon Jonathan B. Rubenstein, MD, says he appreciates what the femto brings to his practice. “It decreases phaco energy, phaco time and turbulence during the phaco portion,” he says. “It’s especially good in dense cataracts and patients with endothelial compromise.”

Lisa K. Feulner, MD, PhD, from Bel Air, Maryland says, “I find that the femto laser provides clean, accurate, and reliable LRIs, entry wound incisions and paracenteses. The paracentesis is well centered in the bag which, I believe, allows for symmetric fibrosis of the capsule over time, and therefore reduces rotation and tilting of the IOLs. Nucleus fragmentation with the femto reduces the phaco time and energy and is gentler on the cornea.”

Christian Klein, MD, of Rochester, New York, says that using the femto has highlighted some pros and cons for him. “I like the size and centration of the capsulorhexis,” he says, “but I dislike the following: the added time;

the fact that it requires reliable and expert technical support which is not always available; the frequent pupil miosis that makes an otherwise routine case become unnecessarily more complex (or expensive if I then have to add Omidria to the bag); the difficulty in seeing the fluid wave in hydrodissection when using the ‘waffle pattern’ [for nuclear segmentation]; and it’s sometimes more difficult to remove cortex. Frankly, I think it offers minimal improvement for the added time burden and increased chances of the above-mentioned issues occurring intraoperatively in our particular setting (a university).”

Though a number of surgeons use the femto, as in previous years, a large proportion, 82 percent, say they’re unlikely to take up the femto or the new Zepto capsulotomy device for use in their surgeries. Eight percent say they’re “very likely” to use the Zepto in the coming year (vs. 2 percent who say the same for the femto), though 16 percent say they’re “somewhat likely”

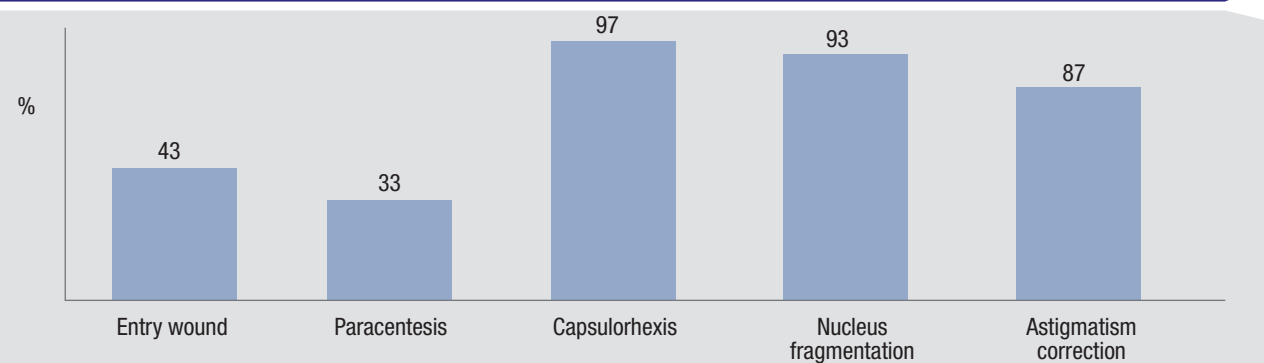
to use the femto vs. 10 percent who are somewhat likely to try the Zepto.

“There’s no significant benefit to patient outcome but an increased out-of-pocket cost to the patient,” avers Gregory Cox, MD, of Hamilton, New Jersey, in reference to the femtosecond laser.

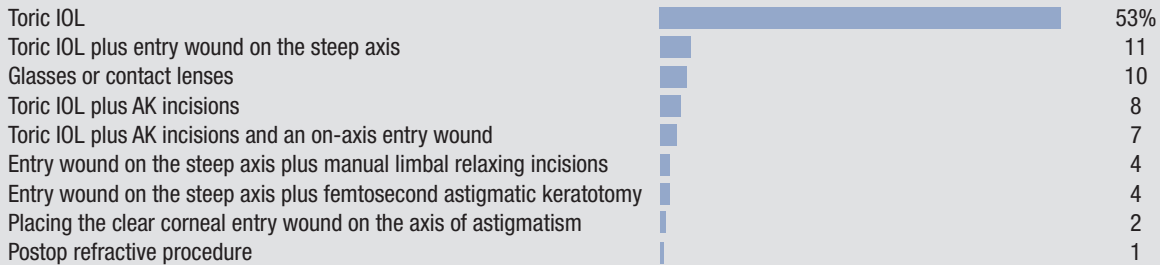
Robert Mobley, MD, of Clinton Township, Michigan, says he’s unlikely to try the new technology, due to benefit/cost issues. “I don’t find any real advantage to femto,” he says. “Plus, it takes up time and is an unnecessary cost to the patient. I also found the integrity of the capsulorhexis to not be as good as manual, in my limited experience. I’m not familiar with Zepto, however.”

Some surgeons, however, see some potential in the technologies, and are willing to try them down the road. “Zepto may be safer for white cataracts,” says a surgeon from Wisconsin. Another surgeon says he’s somewhat likely to try the technology due to a “new practice opportunity coming up.”

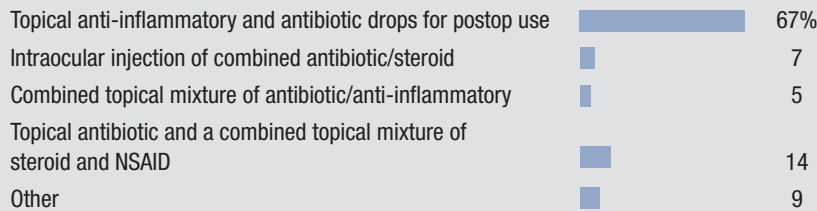
Surgeons’ Use of the Femtosecond Laser for Cataract Surgery



Preferred Method for Managing Pre-existing Astigmatism



Preferred Anti-infection/inflammation Method Postop



Astigmatism Management

Surgeons also weighed in on their preferred method for managing astigmatism in cataract patients.

Similar to previous years, the use of a toric intraocular lens was the most popular option, at 53 percent. The second option was a toric IOL combined with placing the entry wound on the steep axis (11 percent). The range of options chosen appear in the graph above.

With regard to toric lenses, Dr. Mo-

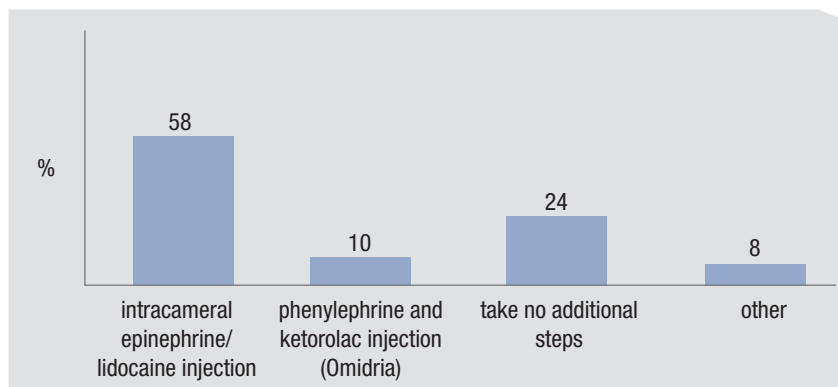
bley says, “They’re very reliable and stable over time for >1 D of corneal astigmatism. I do astigmatic keratotomy for lower levels of astigmatism.” Ligaya Prystowsky, MD, of Nutley, New Jersey, prefers toric lenses in most cases, but keeps her options open. “I have confidence in the toric lenses but they are limited, so I initially enter in the steep axis and add sutures if needed with a toric IOL,” she says. “I have been able to have residual astigmatism of only -1.50 D from a preop value of -6 D. The pa-

tients are happy. I find the level of astigmatic correction is limited to -2 D max with sutures alone.”

A surgeon from West Virginia uses toric lenses plus the entry incision on the steep axis. “This approach is reliable and not dependent upon patient healing,” he says, “which is a variable I care to eliminate.” Sean Lalin, MD, of Morristown, New Jersey, combines a toric IOL with femtosecond laser astigmatic keratotomy, and describes his approach: “I use the femto to address up to 1.25 D of astigmatism, but use a combination of a toric lens and femto for higher degrees of astigmatism,” he says, “especially with multifocal lenses where my goal is to reduce the residual astigmatism to less than 0.5 D.”

A surgeon from Texas combines the cataract wound with the femtosecond. “I use both entry wound on the steep axis plus femtosecond astigmatic keratotomy on patients with less than 1 D of astigmatism,” he says. “For those patients with greater than 1 D of astigmatism, I will put in a toric IOL. These are the best ways to eliminate or reduce astigmatism in my hands.”

Preferred Way to Promote Pupil Dilation Intraop



Other Topics

Surgeons also shared their views on other aspects of surgery:

- **Intraoperative aberrometry.** The use of wavefront sensing in order to hone the selection of a patient’s IOL is still relatively uncommon among respondents, with 22 percent

saying they use it, vs. 28 percent the year before. The doctors shared their views on its pros and cons.

“It helps with long/short eyes and multifocal and torics,” says John Fitz, MD, of Farmington, Missouri. “Sometimes, though, it gives results that do not make sense—and you then go with preop plan.” Audrey Rostov, MD, of Seattle feels similarly, saying, “It’s helpful but doesn’t capture on some difficult cases where it could benefit most.”

“It’s great for post-LASIK and abnormal eyes but time-consuming,” says Dr. Lalin. Ismail A. Shalaby, MD, of Baltimore says the technology is useful but can pose some logistical problems. “Benefits: More accurate IOL selection,” he says. “Shortcomings: It takes extra time, and you need a lot of IOLs in stock for it to be useful.”

• **Managing miosis.** When faced with a pupil that won’t cooperate, the option chosen by most surgeons on the survey is a homemade combination of intracameral epinephrine/lidocaine injection, chosen by 58 percent. Twenty-four percent take no additional steps. The results from this question appear in the graph on page 46.



• **Nucleo-fracture preferences.** The most popular option on the survey was quadrant division, chosen by 48 percent of the surgeons. Tied for second place are phaco chop, and stop and chop, each at 17 percent.

Dr. Prystowsky prefers quadrant division. “I combine with initial debulking in the center, then quadrant division, and chopping later as the pieces come depending on the density of the lens,” she says. “I have a population with very dense lenses and fear of surgery is prevalent.”

A surgeon who prefers to do phaco chop says of the technique: “Phaco chop is less time-consuming, uses less phaco energy, is safer than sculpting techniques and is better in cases of zonular weakness.”

Christopher Ketcherside, MD, of

Kansas City, Missouri, an advocate for stop and chop, says he uses it mainly because that’s how he was trained. “I will also change the technique based on the case, of course,” he says. “We use femto about 35 percent of the time, and when I don’t stop and chop, I will flip and tilt.” A surgeon from Utah also likes stop and chop, because, he says, “The initial groove makes room for cracking and eventual chopping.”


Regarding nucleofracture, the most popular option on the survey was quadrant division, chosen by 48 percent of the surgeons. Tied for second place are phaco chop, and stop and chop, each at 17 percent.


Surgical Tips

The respondents also took the opportunity to share surgical pearls:

Keith Skolnick, MD, Plantation, Florida has advice for proper IOL injection. “Since the 2.4-mm wound is tight, inject the IOL in a planar fashion parallel to the iris,” he says. “If you angle the injector you’re less likely to be able to go through smaller incisions.”

John J. Brozetti, MD, Johnstown, Pennsylvania, advises, “Don’t proceed with the case unless the pupil is 5 mm or larger,” he says. “Use intracameral shugarcaine +/- pupil stretching for inadequate pupil size for every case.”

Dr. Klein has advice for breaking up the nucleus. “While I will still

do a “primary” chop at the start of phacoemulsification for some cases, I’ve begun to sculpt a bowl more frequently at the start of nuclear disassembly,” he says. “This really improves the ability to get the phaco tip deeper into the nuclear wall and makes getting a successful chop much more reproducible.”

Dr. Fitz says simplification is one of the keys to success. “Try to maintain the KISS principle: keep it simple, stupid,” he says. “And, don’t overpromise. Some of these innovations are more trouble than they are worth; I’m frustrated that ORA and femto slow things down, and getting people to spend extra is hard and raises expectations, so don’t push hard.”

James E. Lusk, MD, Shreveport, Louisiana, advises surgeons to “Release fluid/viscoelastic simultaneously using the heel of the angled cannula during hydrodissection to assure elevation of the lens in the capsule bag to attain the ability to rotate the nucleus. The rest of the case goes routinely.”

Dr. Rubenstein says it can help to customize your approach. “Use three different methods in conventional phaco: 1) stop and chop for dense lenses; 2) split and swirl for medium lenses; 3) bowl and roll for soft lenses.”

Rather than giving nuts-and-bolts advice, some surgeons gave more qualitative tips to mull over:

• “Fast is slow; smooth is fast,” says a surgeon from Dallas.

• “Stay focused,” says a California surgeon.

• “Enjoy yourself in the OR,” says Ron Glassman, MD, of Teaneck, New Jersey

• “Perfect is the enemy of good,” says Robert Mahanti, MD, of Flagstaff, Arizona.

Dr. Ketcherside says it’s always good to learn various pearls, but then, “Find what works for you, and get really good at that,” he says. “Know that you’ll have to refine as you go, but also that there’s no ‘one right way.’” **REVIEW**



Treating Uveitic Glaucoma: What Works?

Because these patients have two conditions, treatment can be a challenge. However, today's options are improving the prognosis.

Peter A. Netland, MD, PhD, Charlottesville, Virginia

About 25 percent of patients with uveitis will develop elevated intraocular pressure at some time during their clinical course. (Different studies have found percentages ranging from 10 to 39 percent.) In chronic uveitis the percentage is higher, approaching 50 percent. This increase in pressure often appears to be due to multiple mechanisms.

In the past, managing these patients was a challenge. Even though the number of patients in this situation is limited, treatments often failed to produce ideal outcomes. However, with today's ever-growing set of treatment options, that has changed. Here, I'd like to discuss the main options we currently have available for helping these patients, and review what the published evidence reveals about each option's effectiveness in this situation.

Medical Management

Nearly all of these patients ultimately require treatment with glaucoma medications, although about a quarter of them also require glaucoma surgery to control their pressures. Not

surprisingly, some options work better than others.

In the case of uveitic glaucoma, we're addressing two conditions at the same time: inflammation and glaucoma. Initially it's important to try to get control of the inflammation. Cycloplegic drugs, corticosteroids, nonsteroidal anti-inflammatory drugs and immunomodulatory therapy are all approaches that may be effective for this purpose.

Immunomodulatory medications are often the preferred drugs for long-term management of these patients. In fact, a major advance in the management of these cases has been having a greater choice of immunomodulatory medications, along with a better understanding of them. However, most ophthalmologists are not comfortable selecting these medications and monitoring patients for any side effects. For that reason it's important to work with a uveitis specialist, rheumatologist, internist or other clinician who can help manage these patients.

Once the inflammation is under control we can address the elevated pressure. Options include:

- **Aqueous suppressants, including beta blockers and carbonic anhydrase inhibitors.** These are still the mainstay for therapy in these patients. They can reduce IOP even when conventional outflow is impaired in uveitic glaucoma.

- **Alpha-2-agonists.** These drugs may reduce IOP effectively despite the impaired outflow caused by uveitic glaucoma.

- **Hyperosmotic drugs.** These can be very useful for marked elevations of IOP, especially at presentation; they have a rapid onset of action and can be very effective at lowering IOP. Glycerol has its peak effect approximately 20 minutes after administration. Mannitol is another option, but it requires intravenous administration, while oral administration of glycerol is easier and probably safer. (Recent evidence indicates that increased blood sugar is not a major concern after administration of glycerol, even in diabetics.)

- **Prostaglandins.** These are OK to use in this situation, but they have a slow onset of action. That's not terribly helpful in a patient who has an acute presentation of high

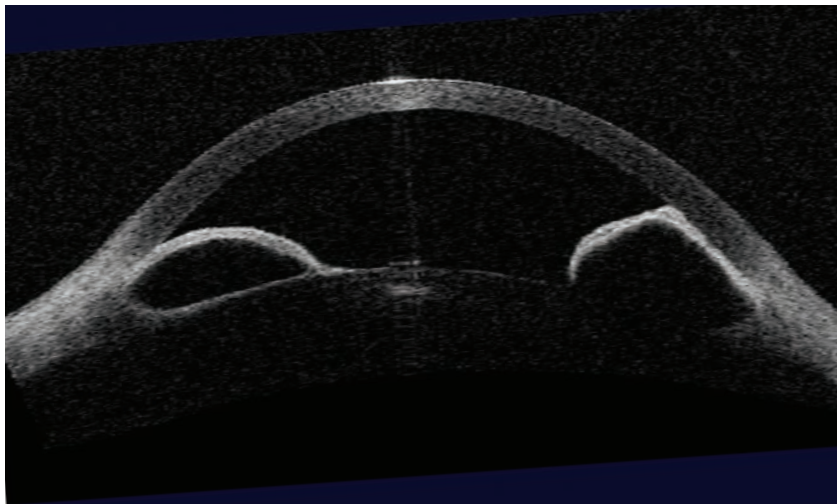
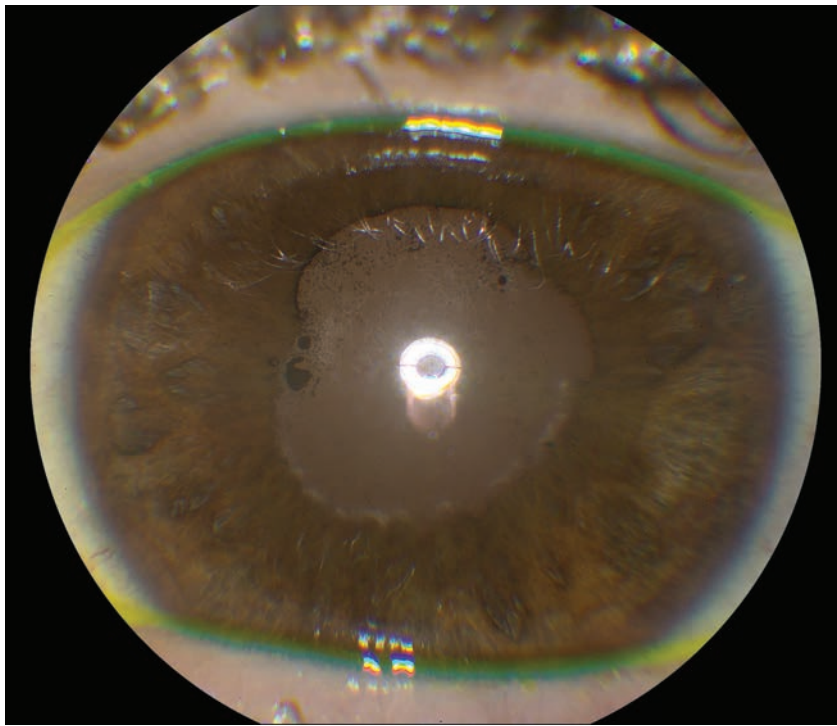


Figure 1. This patient with chronic uveitis presented at a follow-up visit with posterior synechiae and pupillary block. The anterior segment OCT image shows the iris bombé configuration prior to laser iridotomy.

pressures. However, prostaglandins can be very helpful for patients over the long term, especially if they have well-controlled uveitis.

Laser Therapy

There is a somewhat limited role for laser therapy when managing a patient with uveitic glaucoma. Laser

iridotomy does work and can be very helpful as a means to address pupillary block; however, it has a higher failure rate in uveitic glaucomas.¹ For that reason, surgical iridectomy is sometimes done instead of laser iridotomy. Figure 1 (*above*) shows a patient who presented with posterior synechiae and pupillary block while being followed for chronic uveitic

glaucoma. This problem responded well to laser iridotomy.

Laser trabeculoplasty (argon laser trabeculoplasty or diode laser trabeculoplasty) is, generally speaking, not very effective in these patients. In addition, there's a greater risk of complications, so we generally skip this option in a patient with glaucoma and uveitis. However, at least one study has shown that if the uveitis is very well controlled and the patient has a chronic elevation of pressure, selective laser trabeculoplasty can have a positive impact.² Some clinicians have used transscleral cyclophotocoagulation in these patients, even as primary therapy. However, there is a risk of vision loss and hypotony, so these are usually used with caution or in eyes with low visual potential.

Incisional Surgery

Incisional surgery usually means trabeculectomy or drainage implants, and both work well in these patients. If trabeculectomy is performed using antifibrosis drugs (most commonly mitomycin-C today) the success rate can range up to 80 or 90 percent in these patients, according to several relatively short-term studies—although some have found success rates as low as 50 percent. If trabeculectomy is done without the use of antifibrosis drugs, it has a very poor rate of success—53 percent at five years, according to one study.³ Ultimately, if the uveitis is very well controlled or inactive and there's been no previous surgery, the success rates achieved with trabeculectomy are very similar to those seen in patients with primary open-angle glaucoma.^{4,5} Predictably, given the nature of trabeculectomy, there are some long-term complications and failures. Nevertheless, trabeculectomy can be a useful option in patients with well-controlled uveitis.

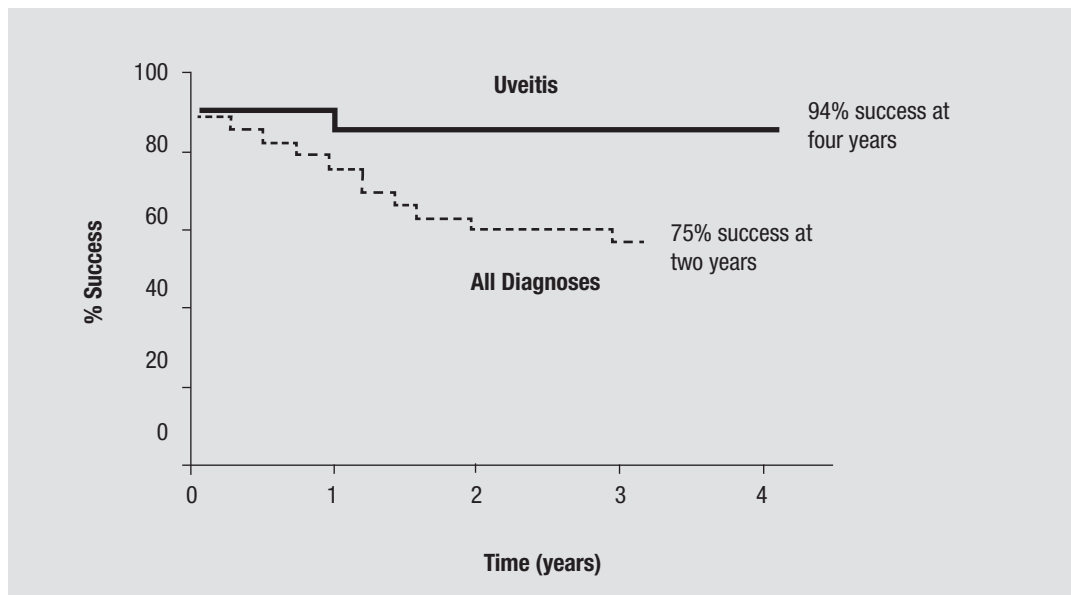


Figure 2. A comparison of the outcomes of two studies, one involving uveitis patients with glaucoma⁷ and another involving patients with any glaucoma diagnosis.⁸ Uveitis patients were well-controlled with immunomodulatory drugs; they had close pre- and postop monitoring for inflammation. Compared to the glaucoma patients with any glaucoma diagnosis, outcomes were favorable in the uveitis patient group.

Glaucoma drainage implants are also effective in these patients. Currently, this is a popular choice among clinicians treating uveitic glaucoma. Like trabeculectomy, the success rate with drainage implants seems to be tied to how well the uveitis is controlled. Meta-analysis has shown that better control of uveitis is associated with higher success rates, compared with poor control of uveitis.⁶

Figure 2 compares the outcomes achieved after implanting drainage devices in two groups (from two different studies). The first study evaluated the safety and efficacy of Ahmed glaucoma valve implantation in 19 patients (21 eyes) with chronic uveitis and glaucoma; it found a 94-percent success rate (defined as an IOP between 5 and 18 mmHg) at four years follow-up.⁷ For comparison, a second study (a retrospective case series) reviewed the data from 159 eyes of 144 patients diagnosed with any type of glaucoma that were implanted with Ahmed valves. That

study found a 75-percent success rate (defined as an IOP between 5 and 22 mmHg without additional glaucoma surgery and without loss of light perception) at two years.⁸ Given this comparison, implanting a drainage device in a uveitic glaucoma patient is a very reasonable option.

Other Surgical Procedures

Nonpenetrating surgery in patients with uveitis and glaucoma has been evaluated in a few studies, but there's no proven superiority to trabeculectomy.^{9,10} In contrast, the new minimally invasive glaucoma procedures, or MIGS, are under intensive evaluation. Many of these surgeries, using tools such as the Trabectome, the Kahook Dual Blade (KDB) or the Trab 360, which can perform a 360-degree trabeculotomy through a single clear corneal incision, seem to be effective in adult patients. One study involving 24 adult patients treated with the Trabectome found a 74-percent success rate at up

to five years of follow-up, with some significant reductions in IOP—up to 40 percent—during that period.¹¹ So this can be a promising approach.

It's worth noting that some of the MIGS devices that have small lumens may experience some blockage caused by inflammatory debris. The EXPRESS device, for example,

has a 50- μ m lumen at its narrowest point, and we've seen a small rate of obstruction with inflammatory debris in these patients. This may also be an issue in other small-lumen MIGS devices, such as the Xen, iStent and others. Surgeons are currently trying these in uveitic glaucoma patients, but we haven't seen any published reports yet.

When it comes to angle surgery for uveitic glaucoma patients, pediatric patients are an interesting niche group. Sharon Freedman, MD, and David Walton, MD, have shown that goniotomy can be a useful approach for chronic childhood uveitis. Most of these patients are idiopathic in their diagnosis, but the success rate is reported to be around 75 percent at three years, which is pretty good for a very low-complication procedure.^{12,13} The age of these patients ranged up to near 20; the average age was 15. So you can use this procedure in teenage uveitic glaucoma patients.

Another option for the pediatric group is MIGS. Many of these

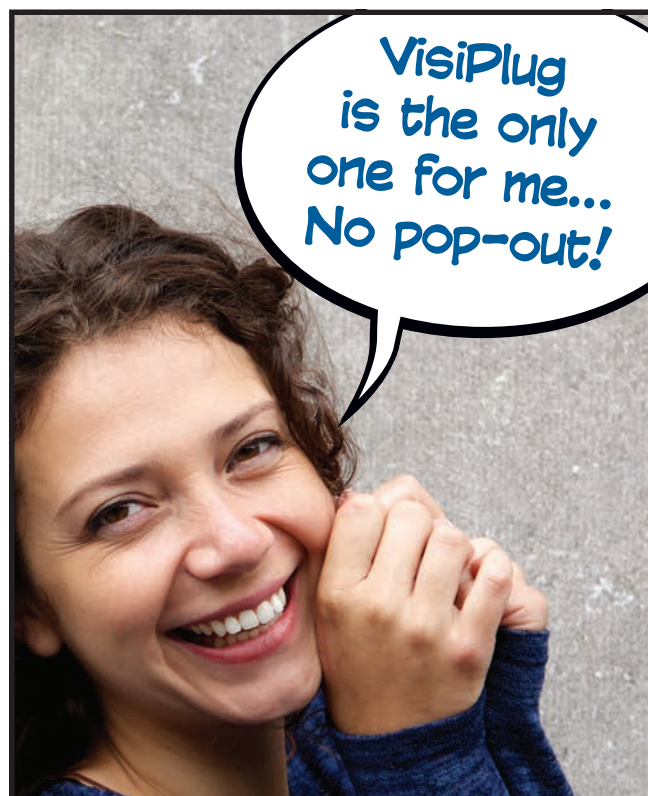surgeries, using tools such as the Trabectome, the Kahook Dual Blade or the Trab 360, also seem to be effective in pediatric uveitic glaucoma patients. So far, we've had positive results with these patients and we're hearing positive anecdotal reports from others about this as well. We're awaiting publications, which I'm sure will be forthcoming.

Today, the prognosis for these patients has greatly improved compared to a few years ago.

Outlook: Good

Today, the prognosis for uveitic glaucoma patients has greatly improved compared to a few years ago. This is at least partly the result of our more aggressive and comprehensive medical control of the uveitis, which often involves the use of immunomodulatory medications. In terms of the elevated pressure, most of these patients are currently treated with glaucoma medications. However, the literature has clearly demonstrated that drainage implants are effective for surgical therapy, and many surgeons now consider this a "go-to" procedure. Goniotomy-related procedures also appear promising in pediatric patients and even adults. Other glaucoma surgical options—including MIGS—may also be effective in these patients, but those approaches are still under evaluation. [REVIEW](#)

1. Spencer NA, Hall AJ, Stawell RJ. Nd:YAG laser iridotomy in uveitic glaucoma. *Clin Exp Ophthalmol* 2001;29:217-219.
2. Maleki A, Swan RT, Lasave AF, Ma L, Foster CS. Selective laser trabeculoplasty in controlled uveitis with steroid-induced glaucoma. *Ophthalmology* 2016;123:2630-2.
3. Stavrou P, Murray PI. Long-term follow-up of trabeculectomy without antimetabolites in patients with uveitis. *Am J Ophthalmol* 1999;128:434-439.
4. Kaburaki T, Koshino T, Kawashima H, Numaga J, Tomidokoro A, Shirato S, Araie M. Initial trabeculectomy with mitomycin C in eyes with uveitic glaucoma with inactive uveitis. *Eye* 2009;23:1509-1517.
5. Almobarak FA, Alharbi AH, Morales J, Aljadaan I. Intermediate and long-term outcomes of mitomycin C-enhanced trabeculectomy as a first glaucoma procedure in uveitic glaucoma. *J Glaucoma* 2017;26:478-485.
6. Chaku M, Bajwa A, Hao M, Lee JK, Netland PA. Treatment of uveitis and outcomes of glaucoma drainage implant surgery: a meta-analysis. *Clin Ophthalmol*, in press, 2018.
7. DaMata A, Burk SE, Netland PA, Baltatzis S, Christen W, Foster CS. Management of uveitic glaucoma with Ahmed Glaucoma Valve implantation. *Ophthalmology*. 1999;106:2168-2172.
8. Huang MC, Netland PA, Coleman AL, Siegner SW, Moster MR, Hill RA. Intermediate-term clinical experience with the Ahmed Glaucoma Valve Implant. *Am J Ophthalmol* 1999;127:27-33.
9. Auer C, Mermoud A, Herbert CP. Deep sclerectomy for the management of uncontrolled uveitic glaucoma: preliminary data. *Klin Monbl Augenheilkd* 2004;221:339-42.
10. Dupas B, Fardeau C, Cassoux N, Bodaghi B, LeHoang P. Deep sclerectomy and trabeculectomy in uveitic glaucoma. *Eye* 2010;24:310-314.
11. Anton A, Heinzelmann S, Neb T, et al. Trabeculectomy ab interno with the Trabectome as a therapeutic option for uveitic secondary glaucoma. *Graefes Arch Clin Exp Ophthalmol* 2015;253:1973-1976.
12. Freedman SF, Rodrigues-Rosa RE, Rojas MC, Enyedi LB. Goniotomy for glaucoma secondary to chronic childhood uveitis. *Am J Ophthalmol* 2002;133:617-621.
13. Ho CL, Wong EY, Walton DS. Goniosurgery for glaucoma complicating chronic childhood uveitis. *Arch Ophthalmol*. 2004;122:838-844.



Lacrimedics' VisiPlug is not like "other" punctum plugs. We have *no* reported "pop-outs" since VisiPlug's introduction in 2003... and it's distributed in over forty countries!

Don't let your patients become a victim of PPP (Punctum Plug Pop-out) Syndrome *in addition* to their Dry Eye Disease.

**VisiPlug® –
a visibly better plug
to treat dry eye!**



Lacrimedics®

(800) 367-8327

E-mail: info@lacrimedics.com

www.lacrimedics.com

¹Dramatization. Not a real patient.

©2017 Lacrimedics, Inc.

A PUBLICATION BY **REVIEW**
of Ophthalmology

RETINA SPECIALIST

Retina Specialist focuses on the latest advances in the diagnosis, medical management and surgical treatment of diseases of the retina, along with practical, real-world advice from leading clinicians and other experts on managing the successful retina practice.



The new addition to the *Review* family serves the entire Retina Specialist marketplace.

Look for your issues in 2018:

» **MARCH**

» **JUNE**

» **SEPTEMBER**

» **NOVEMBER**

For inquiries contact

RETINASPECIALIST@JOBSON.COM

Advertising opportunities

JIM HENNE • PUBLISHER • 610-492-1017 • JHENNE@JOBSON.COM

MICHELE BARRETT • 215-519-1414 • MBARRETT@JOBSON.COM

MICHAEL HOSTER • 610-492-1028 • MHOSTER@JOBSON.COM

www.retina-specialist.com



An Early-2018 IRIS Registry Update

With the seemingly exponential growth of the IRIS Registry, it's a good time to check its progress.

Liam Jordan, Associate Editor

In November of 2013, The American Academy of Ophthalmology launched its Intelligent Research In Sight registry, and, since then, the registry has shown a lot of promise. Given IRIS's staggering growth and recent collaboration with DigiSight, it's a good time to take a look at the registry and some of the opportunities it offers.

William Rich III, MD, AAO's medical director of health policy and chairman of the executive committee of the IRIS registry, is excited by the success of the program. "We were overwhelmed with the rate of growth, initially," he says. "It's exciting to have 45.75 million patients and 189.62 million charts in a registry. So, in the last quarter of 2017, we decided to take a breath and look at the data.

"Typically, if you have a great, solid trial, the number of years it takes for that practice or technique to be adopted by practitioners is around 10 years," he says. "IRIS is actually turning that on its head. We're seeing immediate improvement.

"Within the data, we found some really surprising things, the first of which is a gap in care," Dr. Rich continues. "Much to our shock, 40 percent of patients under the treatment of a

physician with diagnosed diabetic macular edema did not have any treatment in the first 12 months, for example."

Another surprising finding was in the realm of rare genetic diseases. "If it's a rare disease, there will only be a few hundred cases," says Dr. Rich. "How do you find them in the millions? This registry nails down the rare cases that have similar through-lines of treatment that physicians can use for educational purposes or even informed treatment options."

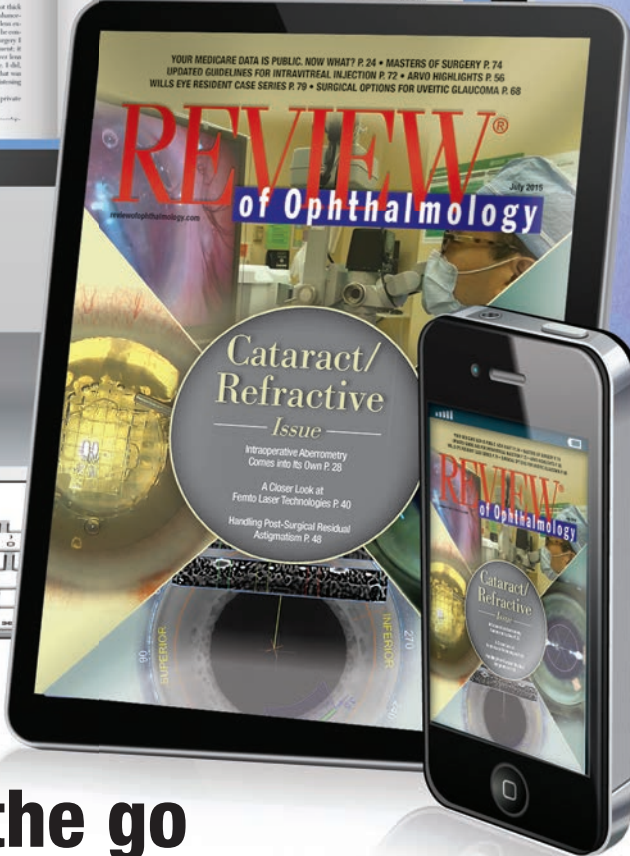
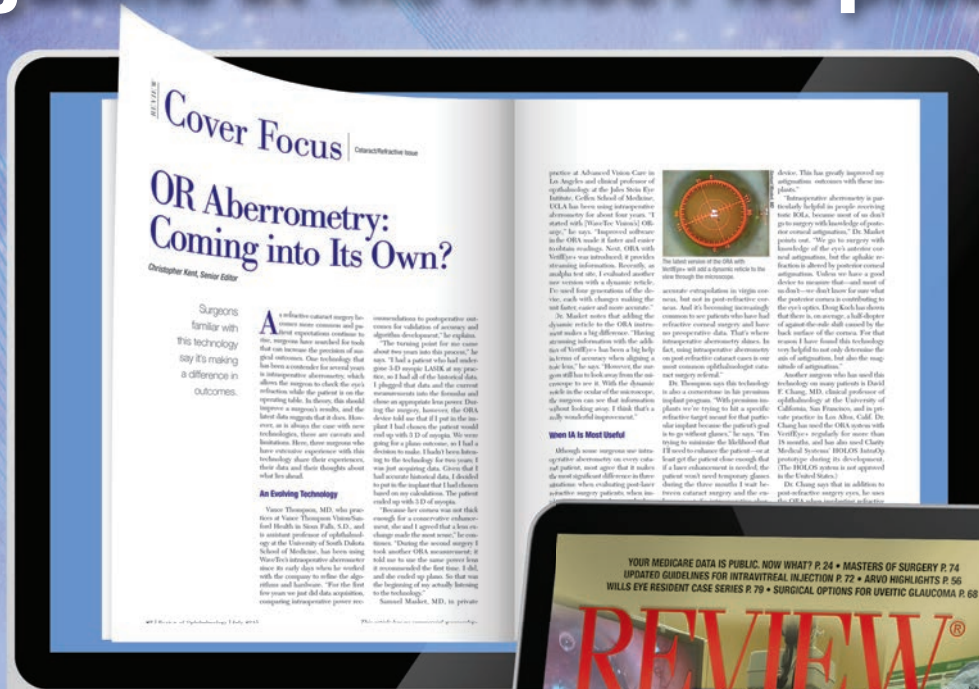A lot of the results from IRIS fall right in line with the initial expectations of the registry, however. "One of the things we looked at is disparity in care—we talk about that a lot now," Dr. Rich continues. "Sometimes there are groups of patients that don't do well even if they are in the health-care system. With IRIS data, we now have mechanisms through which we can look at similarities or trends across demographics."

Dr. Rich says the registry has also helped physicians improve the quality of their care. "That's what this is all about," he says. "A basic tenet of the registry is that if you look at performance compared to your partners or 17,000 other ophthalmologists, and

you see that your performance is lacking, you can query the database and see why that is. We've seen aggressive improvement through specific outcome and quality measurements as a result of evaluating ourselves on a monthly basis. I think that's huge. It was our dream that this would be a resource of expanding clinical knowledge that would be widely available for analysis, and it's finally there. It's happening a lot sooner than we anticipated."

Another big move for IRIS occurred in an effort to bring in revenue to help fund the registry. Allowing ophthalmic companies to conduct studies using the "Big Data" of IRIS will bring in revenue and further the growth of IRIS, Dr. Rich avers. However, the academy required an entity experienced with "big data" and pricing such studies. "Our partnership with DigiSight was finalized in November," Dr. Rich says. "DigiSight is a contractor for the Academy. We couldn't figure out a way to price or value these studies and trials. That's where DigiSight comes in. They understand the significance of big medical data and how to price a study. Because of them, the Academy gets some revenue stream and ongoing funds for IRIS and clinical research." **REVIEW**

Left your *Review of Ophthalmology* magazine at the office? No problem!



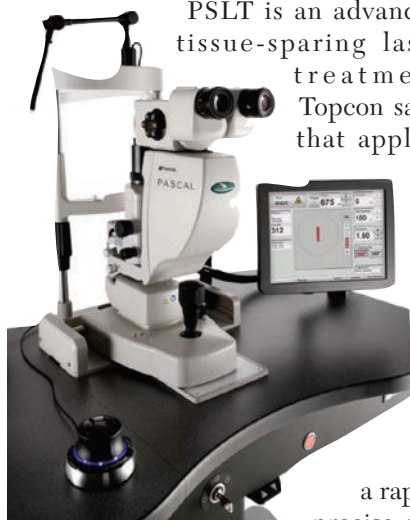Read *Review* on the go from any mobile device!

Simply go to www.reviewofophthalmology.com and click on the digimag link to get your current issue.

FDA Clearance for Topcon's PSLT

Topcon Medical Systems recently announced that its Pascal laser received FDA clearance to use Pattern Scanning Laser Trabeculoplasty Software. The software is used for the reduction of intraocular pressure associated with open-angle glaucoma.

PSLT is an advanced tissue-sparing laser treatment, Topcon says, that applies



a rapid, precise and minimally-traumatic computer-guided treatment sequence of patterns onto the trabecular meshwork. The automated rotation of consecutive patterns ensures that treatment steps are placed without overlap or excessive gaps. Topcon says it provides an average IOP reduction of 24 percent at six months.

To learn more about Pascal and PSLT, visit pascalvision.com/science/#pslt.

SynergEyesCL Line Expands Duette Progressive

SynergEyes recently announced the expansion of its Duette Progressive hybrid contact lens line with the addition of a customizable center-distance lens. The new design comes with center-distance FlexOptics and an adjustable center-distance zone size ranging from 1.8 mm to 4 mm. The lens is driven by photopic pupil size. Its add powers range from +0.75 to +5 D. The center-distance design provides a customized vision solution for emerging to advanced presbyopes, including those with astigmatism, allowing for the Duette Progressive line to cover most patients with presbyopia, SynergEyes says.

SynergEyes adds that its Duette Progressive hybrid lenses are customizable by base curve, add power and center-distance zone to help cover most presbyopic needs. The hybrid design eliminates the rotation issues commonly associated with soft toric lenses, SynergEyes says. These lenses may be fit empirically without the need for diagnostic sets or fluorescein.

More information on the Duette Progressive hybrid line is available

at synergieyes.com.

Topcon's DRI OCT Triton

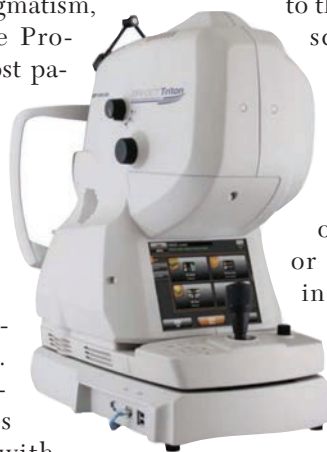Topcon Medical Systems' DRI OCT Triton Series has received FDA 510(k) clearance.

Topcon says that the DRI OCT Triton features easy image capture and a 1- μ m, 1050-nm light source with a scanning speed of 100,000 A-scans/second. The multimodal instrument also incorporates a built-in retinal camera and eye tracking for use during the capture of selected scans.

According to Topcon, in addition to the anterior segment scanning, the DRI OCT Triton can visualize deeper pathology, rapidly penetrating ocular tissues regardless of media opacities or hemorrhages. The instrument features widefield OCT scanning (12 mm x 9 mm) with a reference database. In addition,

it displays high-resolution fundus images with clear retinal vessel and macular mapping.

For more information on Topcon's DRI OCT Triton series, visit topconmedical.com.



Bevacizumab Injections After MIs

Noting that intraocular injections of anti-vascular endothelial growth factor agents are the main therapy in age-related macular degeneration, researchers analyzed the mortality associated with intravitreal injections of bevacizumab for AMD in individuals previously diagnosed with acute myocardial infarct.

Using a national database, researchers identified individuals with bevacizumab-treated AMD with diagnosis of MI prior to the first bevacizumab injection (delivered between September 2008 and October 2014 [n=2,100]). They then generated subgroups treated within three months (n=11), six months (n=24), 12 months (n=52) and 24 months (n=124) after MI. Researchers compared those individuals to age- and gender-matched members who had MI at the same time but were never exposed to anti-VEGF. They performed a survival analysis using propensity score-adjusted Cox regression.

Bevacizumab-treated individuals were slightly and insignificantly older than controls (mean age, 83.25 vs. 83.19 year; $p=0.75$). Gender distribution was similar. Researchers reported increased mortality rates associated with the use of intravitreal bevacizumab in AMD cases after MI, compared with age- and gender-matched post-MI cases with no exposure to anti-VEGF agents. Researchers found

the following differences in mortality:

- within three months between MI and initiation of bevacizumab treatment, OR=6.22 (CI, 1.08 to 35.97, $p<0.05$);
- within six months, OR=2.37 (CI, 0.93 to 6.02, $p=0.071$);
- within 12 months, OR=3 (CI, 1.44 to 6.28, $p<0.01$);
- within 24 months after MI, OR=2.24 (CI, 1.35 to 3.70, $p<0.01$); and
- MI any time prior to first bevacizumab injection, OR=1.71 (CI, 1.53 to 1.92, $p<0.001$).

They advised that caution should be taken when offering bevacizumab to individuals with AMD after MI.

Graefes Arch Clin Exp Ophthalmol 2018; Feb. 10. [Epub ahead of print]. Hanhart J, Comaneshter DS, Freier-Dror Y, et al.

Ultrasonography Assessment of Optic Nerve Sheath Diameter

Investigators wrote that the standard method for monitoring intracranial pressure can result in complications and pain, making noninvasive, repeatable methods a valuable option. They examined how ultrasonographic optic nerve sheath diameter correlated with noninvasive and dynamically monitored ICP changes.

Investigators measured the ONSD before lumbar puncture in 60 individuals on admission. Those with elevat-

ed ICP were divided into group one ($200 < LP \leq 300$ mmH₂O) and group two ($LP > 300$ mmH₂O). Individuals underwent follow-up ONSD and LP measurements within one month. Investigators analyzed correlations between the ONSD and ICP on admission, and between changes in ONSD and ICP, i.e., respective changes in ONSD and ICP from admissions to follow-up. Main outcomes and measures included the ultrasonographic ONSD and ICP measured at admission and follow-up, correlations between ONSD and ICP on admission, and changes in ONSD and ICP using Pearson correlation analyses.

Investigators reported that for 60 individuals (mean age 36.2 ± 12.04 years; 29 [48 percent] female) at admission (group one), ONSD and ICP values were strongly correlated, with an r of 0.798 (CI, 0.709 to 0.867; $p<0.001$).

For 25 individuals with elevated ICP who completed the follow-up (group two):

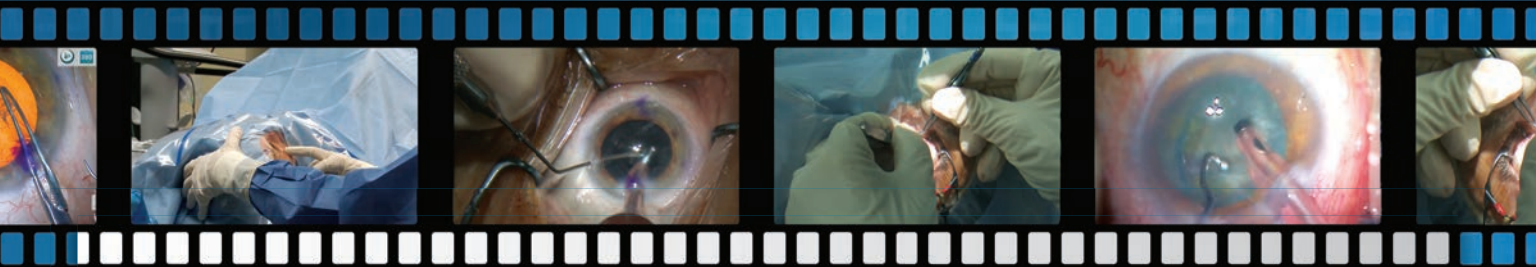
- upon admission, the mean ONSD was 4.50 ± 0.54 mm, and mean ICP was 302.40 ± 54.26 mm H₂O;
- upon admission, ONSD and ICP values obtained were strongly correlated with an r of 0.724 (CI, 0.470 to 0.876; $p<0.001$);
- the mean change in ICP was 126.64 ± 52.51 mm H₂O (range: 20 to 210 mm H₂O) (CI, 106.24 to 146.07),



Monthly

MACKOOL ONLINE CME

CME SERIES | SURGICAL VIDEOS



To view CME video
go to:

www.MackoolOnlineCME.com

Episode 27: “Determination of IOL Power in Keratoconic Eyes”

Surgical Video by:
Richard J. Mackool, MD

Video Overview:

This case demonstrates the use of intraoperative aberrometry plus the Aphakic Refraction Technique to best determine the final IOL power in a keratoconic eye.

Tips for visualization, a comparison of phaco chop and divide and conquer and the advantages of a high IOP setting round out this very educational case.

MackoolOnlineCME.com MONTHLY Video Series



Richard J. Mackool, MD

Welcome to the third year of Mackool Online CME! With the generous support of several ophthalmic companies, I am honored to have our viewers join me in the operating room as I demonstrate the technology and techniques that I have found to be most valuable, and that I hope are helpful to many of my colleagues. We continue to edit the videos only to either change camera perspective or to reduce down time – allowing you to observe every step of the procedure.

As before, one new surgical video will be released monthly, and physicians may earn CME credits or just observe the case. New viewers are able to obtain additional CME credit by reviewing previous videos that are located in our archives.

I thank the many surgeons who have told us that they have found our CME program to be interesting and instructive; I appreciate your comments, suggestions and questions. Thanks again for joining us on Mackool Online CME.



CME Accredited Surgical Training Videos Now Available Online: www.MackoolOnlineCME.com

Richard Mackool, MD, a world renowned anterior segment ophthalmic microsurgeon, has assembled a web-based video collection of surgical cases that encompass both routine and challenging cases, demonstrating both familiar and potentially unfamiliar surgical techniques using a variety of instrumentation and settings.

This educational activity aims to present a series of Dr. Mackool's surgical videos, carefully selected to address the specific learning objectives of this activity, with the goal of making surgical training available as needed online for surgeons motivated to improve or expand their surgical repertoire.

Learning Objective:

After completion of this educational activity, participants should be able to:

- Demonstrate the Divide and Conquer methods of nucleus disassembly, and also a method of calculating IOL power in eyes with keratoconus.

Accreditation Statement - In support of improving patient care, this activity has been planned and implemented by Amedco and Postgraduate Healthcare Education, LLC. Amedco is jointly accredited by the American Council for Continuing Medical Education (ACCME), the Accreditation Council for Pharmacy Education (ACPE), and the American Nurses Credentialing Center (ANCC), to provide continuing education for the healthcare team.

Credit Designation Statement - Amedco designates this live activity for a maximum of .25 AMA PRA Category 1 Credits™. Physicians should claim only the credit commensurate with the extent of their participation in the activity.

Endorsed by:

Review of Ophthalmology®

Video and Web Production by:
JR Snowdon, Inc

Jointly Provided by:

AMEDCO & PHE

Supported by an unrestricted independent
medical educational grant from:

Alcon

Additionally Supported by:

**Glaukos
MST**

**Crestpoint Management
Carl Zeiss Meditec**

and in ONSD was 1 ± 0.512 mm (range: 0.418 to 2.37 mm) (CI, 0.83 to 1.20); and

- the change in ONSD was strongly correlated with that in ICP, with an r of 0.702 (CI, 0.425 to 0.870; $p < 0.001$).

Follow-up evaluations revealed that elevated ICP and dilated optic nerve sheath diameters returned to normal, and no evidence of difference was found in the mean ONSDs between group one (3.49 mm; CI, 3.34 to 3.62 mm) and group two (3.51 mm; CI, 3.44 to 3.59 mm) ($p = 0.778$) at follow-up.

Investigators found that the dilated ONSDs decreased along with the elevated ICP reduction. They concluded that ultrasonographic ONSD measurements may be a useful, noninvasive tool for dynamically evaluating ICP.

JAMA Ophthalmol 2018;Feb. 1 [Epub ahead of print].
Wang LJ, Chen LM, Chen Y, et al.

Trabeculectomy with MMC in Angle-closure Patients

Researchers from the University of California-Los Angeles' Jules Stein Eye Institute say that, because there had never been a large study of trabeculectomy with the use of adjunctive mitomycin-C in patients suffering from primary angle-closure glaucoma, they undertook a study looking at the long-term tonometric results in these cases.

In a retrospective cohort study, the investigators used three criteria to judge the success of the procedure, with or without adjunctive drugs: intraocular pressure ≤ 18 mmHg and IOP reduction of 20 percent (criterion A); IOP ≤ 15 mmHg and IOP reduction of 25 percent (criterion B); and IOP ≤ 12 mmHg and IOP reduction of 30 percent (criterion C). In total, the researchers included 136 eyes (102 patients) with PACG who underwent trabeculectomy with MMC. A total

Table 1. Outcomes of Trab + MMC in Angle-closure Glaucoma

Success Criterion	1-year Follow-up	3-years Follow-up	5-years Follow-up
Criterion A: IOP ≤ 18 mmHg and IOP reduction of 20 percent	92 \pm 2.2 percent	78 \pm 3.8 percent	72 \pm 4.3 percent
Criterion B: IOP ≤ 15 mmHg and IOP reduction of 25 percent	86 \pm 3.0 percent	65 \pm 4.4 percent	59 \pm 4.7 percent
Criterion C: IOP ≤ 12 mmHg and IOP reduction of 30 percent	62 \pm 4.2 percent	40 \pm 4.5 percent	32 \pm 4.4 percent

of 196 eyes (157 patients) who had surgery between February 1994 and August 2015 were initially included in the study. However, 60 eyes (30.6 percent) were excluded due to having undergone combined trabeculectomy with MMC and phacoemulsification surgery; having less than three months of follow-up; or having previously undergone surgery in which the conjunctiva was manipulated in some way.

The qualified success rates of the surgery appear in Table 1.

The study also identified risk factors for failure of the procedure. The researchers say that eyes that had their crystalline lenses before their trabeculectomy procedure had a higher rate of failure for all criteria (hazard ratio of 1.9 for criterion A; HR of 2.9 for criterion B; HR of 3.6 for criterion C). A family history of glaucoma was associated with a higher rate of failure with criterion A (HR: 2.8). Eyes with no previous laser peripheral iridotomy had a higher risk of failure when criteria B and C were used to judge success (HR for both: 2.5). Worse baseline intraocular pressure was a risk factor for failure with criterion C (HR: 1.1).

Ultimately, the researchers say that trabeculectomy combined with MMC effectively reduces IOP in PACG,

achieving long-term IOP levels in the mid-teens.

J Glaucoma 2018;27:2:101-107.
Romero P, Hirunpatravong P, Alizadeh R, et al.

Outcomes of Cataract Surgery in Epiretinal Membrane Cases

A team of researchers from different countries explored the outcomes of cataract surgery performed in patients with primary epiretinal membranes.

In a retrospective clinical database study, the investigators collected data from July 2003 to March 2015 from eight centers in the United Kingdom. They drew cataract surgery data from 217,557 eyes from the electronic medical record of the UK National Health Service. After excluding 57,561 eyes that had combined surgery, prior vitrectomy, co-pathology and/or complications, the researchers analyzed 812 eyes with primary ERM and 159,184 reference eyes. In the study, the primary outcome measures were visual acuity, the incidence of cystoid macular edema and the need for ERM surgery.

Epiretinal membrane eyes assessed at four to 12 weeks postoperatively gained 0.27 (0.32) logMAR (approximately three Snellen lines), with 200 of 448 (44.6 percent) improving by

0.30 logMAR or more (≥ 3 lines) and 32 of 448 (7.1 percent) worsening by 0.30 logMAR or more. The reference eyes' vision gained a mean of 0.44 ± 0.26 logMAR (approximately four Snellen lines), with 48,583 of 77,408 (62.8 percent) improving by 0.30 logMAR or more and 2,125 of 77,408 (2.7 percent) worsening by 0.30 logMAR or more. Although all eyes with preoperative VA of 20/40 or less improved, only reference eyes with preoperative visual acuity of better than 20/40 showed improvement.

Cystoid macular edema developed in 57 of 663 eyes that had epiretinal membranes (8.6 percent) (95% CI, 6.69-10.98) and 1,731 of 125,435 reference eyes (1.38 percent) (95% CI, 1.32-1.45) ($p < 0.001$). Epiretinal membrane surgery was performed in 43 of 663 of the eyes with membranes (6.5 percent).

JAMA Ophthalmol 2018;136:2:148-154.

Romero P, Hirunpatravong P, Alizadeh R, et al.

Replacing a Failed Ahmed Valve with a Baerveldt

Investigators analyzed outcomes in eyes that underwent surgery to replace a failed Ahmed valve with a Baerveldt glaucoma implant in the same quadrant, as part of a retrospective case series of nine glaucoma patients.

The parameters analyzed in the study included age, glaucoma type, prior surgery, complications, intraocular pressure, visual acuity, and number of glaucoma medications before and after the surgery. Surgical success was defined as an IOP measurement below 21 mmHg or a 20 percent IOP reduction, with or without a hypotensive agent.

The mean follow-up duration in the study was 47 months. After surgery, at the time of final follow-up, the mean IOP decreased from 29.9 to 16.7 mmHg (36 percent of mean IOP reduction, $p = 0.008$). Investigators found a significant reduction of

hypotensive agents, from a mean of 4.33 to 2.22 ($p = 0.02$). Visual acuity didn't show a significant deterioration ($p = 0.07$). In the final office visit, five of nine individuals met the success criteria and two individuals were qualified successes. Two cases failed after 69 and 125 months of follow-up, respectively. The cumulative probability of success after six months was 76 percent, and this rate remained stable until the sixth year. One individual developed bullous keratopathy. Two individuals had early postoperative pressure spikes: The first individual was treated by trabeculectomy and the second underwent a vitrectomy.

Investigators suggested that replacing a failed Ahmed glaucoma valve with a new Baerveldt glaucoma implant in the same quadrant could be a reasonable choice to control refractory glaucoma.

J Glaucoma 2018; Feb.16. [Epub ahead of print].

Zuo W, Lesk MR.

Time To Hire?

More Eye Care Professionals Will See Your Job Listing On Local Eye Site Than Anywhere Else.



localeyesite.com



Local Eye Site
JOBS IN EYE CARE

Practice For Sale



Practice Sales • Appraisals • Consulting
www.PracticeConsultants.com

**PRACTICES FOR SALE
NATIONWIDE**

Visit us on the Web or call us to learn more about our company and the practices we have available.

info@PracticeConsultants.com

800-576-6935

www.PracticeConsultants.com

Career Opportunities

OPHTHALMOLOGISTS
Danbury, CT

Ophthalmologists to share office with long standing Ophthalmologist in Danbury, CT. High quality equipment. \$2,250 per month or adjoining office without equipment- \$1,750 per month.

203-545-3539 or
email mehrimd@aol.com



**FOR CLASSIFIED
ADVERTISING
CONTACT US TODAY:**

Toll free: **888-498-1460**

E-mail: sales@kerhgroup.com



Career Opportunities



Targeting
Ophthalmologists?

**CLASSIFIED ADVERTISING
WORKS**



Contact us today
for classified advertising:
Toll free: **888-498-1460**
E-mail: sales@kerhgroup.com



FIND MORE PRACTICES FOR SALE ON



CONTACT US TODAY to list your practice:

888-498-1460

opticlassifieds@kerhgroup.com

www.opticlassifieds.com

(Continued from page 30)

decrease the risk of endophthalmitis and postoperative infection—is the Betadine prep around the eye and diluted drops in the eye for a few minutes before surgery. It’s the only thing we know works,” adds Dr. Silverstein.

“Nothing has proven more efficacious in preventing endophthalmitis than the use of topical povidone-iodine,” states Dr. Zavodni. “My patients receive a drop of Betadine directly into the conjunctival sac during preop and in the operating room. This is, of course, in addition to the prepping of periocular skin and lashes with Betadine before placing the surgical drapes.”

As for an FDA-approved, single-use injectable intracameral antibiotic preparation indicated for endophthalmitis prophylaxis, the prospects are not so cut and dried. “I don’t really see any company investing the money needed to have the FDA approve it. It’s just not reasonable from an economic standpoint,” says Dr. Arshinoff. “We have to look at reality, and if I were running the company, I would not be eager to go to all the expense when my drug will rapidly be genericized and the chance of recouping the investment is miniscule.”

He cites one potential off-label alternative, though. “Moxifloxacin solutions for intracameral injection that come in pre-loaded syringes are already available from a company in India (Entod Pharma). Unfortunately, they are not sold in North America. I think the company that makes it is opening a branch in the U.K., which may help to get these things available in North America. Hopefully, they will make it in the dilute formulation (to inject 0.4 mL of 150 µg per 0.1 mL) prepackaged for single use,” he says.

Even if pre-filled moxi syringes

eventually become readily available, they’ll remain off-label for endophthalmitis prophylaxis, as there is no economic incentive for manufacturers to repurpose an existing generic drug, since they would be barred from having exclusive rights. “Without a foreseeable economic return, there has not been any industry incentive to push for FDA approval, which is a great detriment to our patients,” says Dr. Zavodni. “The ASCRS Research Council has thankfully begun development of a prospective research trial, which will hopefully lead to FDA approval and, ultimately, a product that all surgeons can feel confident using.”

Dr. Silverstein acknowledges that the evidence for intraocular injections to prevent endophthalmitis is growing, but he awaits tightly controlled, prospective multicenter studies to elevate the certainty of that evidence. “There are a couple of very bold and aggressive American studies being proposed now to try to answer the question definitively: Does an intracameral medication such as moxifloxacin, cefuroxime, etc., decrease the incidence of endophthalmitis? Of course, the rate-limiting factor to these kinds of studies has always been a large enough *n* to declare statistical significance. Thankfully, because the incidence of endophthalmitis is so low, you’d have to study many thousands of patients in order to make such a claim,” he says.

The daunting expenditures of time and money, as well as the vast statistical sample that a probative study would demand, mean that for the foreseeable future, cataract surgeons will have to continue following the succinct advice of a recent Cochrane Review when pondering antibiotics for endophthalmitis prevention: “Practitioners should rely on current evidence to make informed decisions regarding prophylaxis choices.”¹² **REVIEW**

Dr. Silverstein has never been compensated and has no other financial interest in any of the products discussed in this article, although he has participated in research on antibiotics, topical NSAIDs and steroids throughout his career.

Dr. Arshinoff is a consultant for Alcon, but not with regard to Vigamox. He reports no other financial interests in medications mentioned in this article.

Dr. Zavodni reports no relevant financial interests.

1. ESCRS Endophthalmitis Study Group. Prophylaxis of postoperative endophthalmitis following cataract surgery: Results of the ESCRS multicenter study and identification of risk factors. *J Cataract Refract Surg* 2007;22:978-88.
2. Herrinton LJ, Shorstein NH, Paschal JF, et al. Comparative effectiveness of antibiotic prophylaxis in cataract surgery. *Ophthalmology* 2016;123:287-94
3. HariPriya A, Chang DF, Ravindran RD. Endophthalmitis reduction with intracameral moxifloxacin prophylaxis: Analysis of 600,000 surgeries. *Ophthalmol* 2017;124:6:768-75.
4. Arshinoff SA, Modabber M. Dose and administration of intracameral moxifloxacin for prophylaxis of postoperative endophthalmitis. *J Cataract Refract Surg* 2016;42:1730-41.
5. Libre PE, Matthews S. Endophthalmitis prophylaxis by intracameral antibiotics: In vitro model comparing vancomycin, cefuroxime, and moxifloxacin. *J Cataract Refract Surg* 2017; 43:833-38.
6. Knape RM, Sayyad FE, Davis JL. Moxifloxacin and bilateral acute iris transillumination. *J Ophthalmic Inflamm Infect* 2013;14;3:1-10.
7. Ullman MA, Midgley KJ, Kim J, Ullman S. Anaphylactic reaction secondary to topical preoperative moxifloxacin. *J Cataract Refract Surg* 2016;42:1830-37.
8. Simaroj P, Sinsawad P. Effects of intracameral triamcinolone and gentamicin injections following cataract surgery. *J Med Assoc Thailand* 2011;94:7:819-25.
9. Cunha PA, Shinzato FA, Tecchio GT, et al. Efficacy and tolerability of a gatfloxacin/prednisolone acetate fixed combination for topical prophylaxis and control of inflammation in phacoemulsification: A 20-day double-blind comparison to its individual components. *Clinics* 2013;68:6:834-9.
10. Fisher BL, Potvin R. Transzonular vitreous injection vs a single drop compounded topical pharmaceutical regimen after cataract surgery. *Clin Ophth* 2016;10:1297-1303.
11. Speaker M G, Menikoff J A. Prophylaxis of endophthalmitis with topical povidone-iodine. *Ophthalmology* 1991;98:1769-1775.
12. Gower EW, Lindsley K, Tulenko SE, Nanji AA, Leyngold I, McDonnell PJ. Perioperative antibiotics for prevention of acute endophthalmitis after cataract surgery. *Cochrane Database of Systematic Reviews* 2017, Issue 2. Art. No.: CD006364. DOI: 10.1002/14651858.CD006364.pub3.

EVERY MONDAY
E-NEWS YOU CAN USE





Have you been receiving and reading custom e-blasts from *Review of Ophthalmology*?

If not, you're missing out on valuable information!

You're a busy practitioner and not surprisingly, your e-mail inbox is often full. Fortunately, when you scan through the sender list, determining which messages to delete and which to save or read, you can feel confident knowing that e-blasts from *Review of Ophthalmology*, a Jobson Medical Information LLC publication, contain the most current and comprehensive information available in the field to keep you on the cutting edge.

Review of Ophthalmology's online stable of products includes editorial newsletters and promotional information about new products, treatments and surgical techniques, as well as alerts on continuing education courses for ophthalmologists.

 Our FREE weekly e-newsletter, *Review of Ophthalmology Online*, brings you the latest in ophthalmic research, as well as industry news. In an effort to keep eyecare professionals informed, this resource is waiting in your inbox **every Monday morning**.

 *Retina Online*, our free monthly e-newsletter, is for retina specialists and general ophthalmologists interested in enhancing their knowledge on the topics of retina and related disease diagnosis and treatment, as well as the latest in surgical procedures.

Your time is valuable — and so is your practice. These e-products are the most effective way for you to receive updates on breaking news and research — all just a click away.

DON'T MISS OUT!

Unfamiliar with our products? Visit www.reviewofophthalmology.com and check out our newsletter archives.

Go to www.jobson.com/globalEmail/default.aspx to sign up for the e-newsletters that interest you.

A woman with unilateral floaters after a colonoscopy is evaluated at Wills Eye Hospital.

Rebecca Russ Soares, MD, MPH, and James P. Dunn, MD

Presentation

A 63-year-old Caucasian female without past ocular history presented with two to three weeks of black floaters in her vision. She reported an abrupt onset of the spots in her left eye upon waking the day after an incomplete colonoscopy for left lower quadrant abdominal pain, which had to be aborted due to incomplete bowel preparation. She underwent a second colonoscopy the next week, the findings of which were benign. Over the course of the next few weeks, she had progressively worsening headaches, light sensitivity and redness in her left eye. Review of systems was negative for new rashes, new onset joint pain or shortness of breath, though she did have persistent left lower quadrant pain.

Medical History

Past medical history was significant for depression, hypothyroidism, chronic left lower quadrant abdominal pain of unclear etiology, and diverticulosis. Of note, no inflammatory bowel disease, cancer or infection was found on her colonoscopy. She had an allergy to sulfa. She never smoked, used illicit drugs or drank alcohol.

Her medication list included levothyroxine 75 mcg daily and multiple antidepressants and anxiolytics, including bupropion 100 mg, risperidone 2 mg, duloxetine 30 mg, armodafinil 150 mg and trazodone 50 mg, all dosed daily or nightly, and clonazepam 0.5 mg as needed.

Examination

The patient's vital signs were stable and within normal limits. Ocular examination demonstrated a best corrected visual acuity of 20/40 OD and CF at 1 foot OS. She had full extraocular movements. There was no relative afferent pupillary defect. Her visual fields were full OD but globally diminished OS. The periorbital and adnexae were normal.

Anterior slit lamp examination of the right eye was normal. The left eye had corneal haze with 1 to 2+ Descemet's membrane folds and diffuse inferior non-granulomatous keratic precipitates. The anterior chamber had 2+ cell without hypopyon. The iris revealed broken posterior synechiae with a ring of pigment on the anterior capsule of the lens (*Figure 1*). Intraocular pressure was 14 mmHg OD and 7 mmHg OS.

Fundoscopy examination was normal in the right eye. There was a hazy view to the back of the left eye with 1+ vitreous cells, and fluffy white-yellow lesions with a "string of pearls" appearance (*Figure 2*). The optic disc was normal. The vessels were without sheathing or vasculitis. The macular exam showed no edema, thickening or hemorrhage. However, there was focal chorioretinitis in the posterior pole.

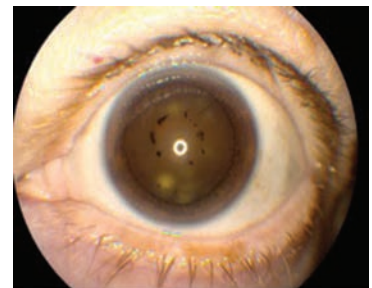

Figure 1. Anterior segment photograph of the left eye demonstrating broken posterior synechiae leaving a ring of pigment on the anterior capsule.

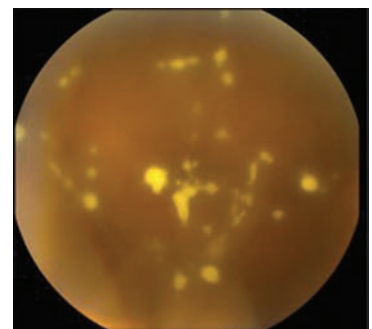


Figure 2. Color fundus photograph of the left eye demonstrating "string of pearls" vitritis and posterior pole focal chorioretinitis.

What is your diagnosis? What further workup would you pursue? The diagnosis appears on p. 64.

Workup, Diagnosis and Treatment

Our differential diagnosis included infectious etiologies such as endophthalmitis, with endogenous endophthalmitis thought to be more likely in light of the history of recent colonic instrumentation. Fungal etiologies like *Candida* or *Aspergillus* were thought to be more likely than bacterial (including syphilis and tuberculosis) or toxoplasmosis. Other considerations included inflammatory conditions such as sarcoidosis, Vogt-Koyanagi-Harada syndrome, and Behçet disease. Masquerade syndromes like large cell lymphoma were also on our differential. Sympathetic ophthalmia, postoperative retained lens material and retained intraocular foreign body were ruled out in the absence of eye trauma or surgery.

For further diagnostic clarity, our patient underwent intravitreal tap and injection with voriconazole 1,000 mcg/0.1 ml. She was empirically started on voriconazole 200 mg twice daily. Her anterior uveitis was treated with prednisolone acetate 1% every two hours in the left eye. Unfortunately, the cultures taken had

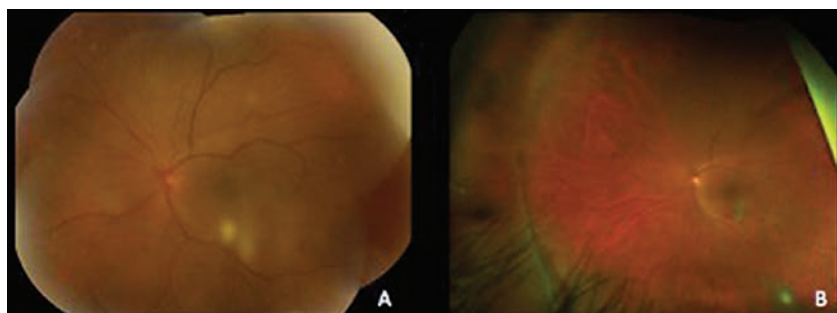


Figure 3. (A) Color fundus photograph of the left eye two months after initiation of antifungal therapy. (B) Wide-field color fundus photo of the left eye three months after initiation of antifungal therapy.

no yield.

Over the next three months, her visual acuity in the left eye improved from count fingers to 20/80 while on antifungal therapy. Her examination showed resolving anterior chamber, vitreous and chorioretinal inflammation (Figure 3). She was subsequently tapered off prednisolone acetate. However, at her next visit, her vision in the left eye had deteriorated to 20/200. Optical coherence tomography and fluorescein angiography showed interval development of cystoid macular edema in the left

eye (Figure 4). She underwent injection of sub-Tenon's triamcinolone acetonide. Upon follow-up, her vision improved to 20/70, though her CME persisted, for which she was next treated with intravitreal bevacizumab 1.25 mg. Given full resolution of her panuveitis, her voriconazole was discontinued, and her diagnosis was consistent with presumed fungal endogenous endophthalmitis. Unfortunately, her macular edema and epiretinal membrane persisted, requiring a pars plana vitrectomy and epiretinal membrane peel.

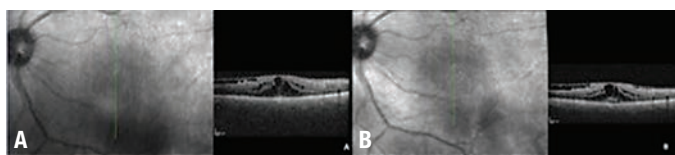

Figure 4. Optical coherence tomography of the left eye before (A) and after (B) sub-Tenon's triamcinolone acetonide.

Discussion

Fungal endogenous endophthalmitis, caused by hematogenous seeding of the choroid with subsequent posterior and anterior segment involvement, can lead to devastating visual outcomes. The predominant microorganisms implicated are *Candida* and *Aspergillus* species. Patients with a relative immunosuppression from diabetes, liver disease, renal failure, malignancy, organ transplantation or HIV are at risk for developing this infection, as are those undergoing instrumentation of the GI tract or abdominal surgery, those with indwelling catheters, and intravenous drug users.¹

As in our case, which was ultimately culture-negative, the

cornerstone of diagnosis remains clinical suspicion, given the abrupt onset following complicated colonoscopy, examination with classic findings like “string of pearls” vitritis and yellow-white chorioretinitis, and response to empiric treatment. Fungal culture via intravitreal tap is often low-yield, as is anterior chamber paracentesis, compared to diagnostic vitrectomy.²

Once fungal endogenous endophthalmitis is suspected, empiric treatment with antifungals should be initiated. Prior to the development of voriconazole, intravitreal amphotericin B with or without pars plana vitrectomy was considered

standard-of-care. However, systemic voriconazole, introduced in 2002, has excellent bioavailability and less retinal toxicity. Thus, systemic treatment with or without intravitreal voriconazole is more frequently used.³ While no randomized controlled trial has been performed regarding the efficacy of pars plana vitrectomy in fungal endogenous endophthalmitis, common indications for vitrectomy include diagnostic vitrectomy, non-clearing inflammatory vitreous debris, uncontrolled infection despite medical management, and release of vitreoretinal traction to treat retinal detachments and other structural sequelae.^{1,3} Some recent case series suggest improved outcomes with immediate total vitrectomy.^{4,5}

Another sequela seen in our patient was the development of epiretinal membrane.⁶ Though literature surrounding the specific treatment of epiretinal membrane after fungal endophthalmitis is sparse, small series of patients with epiretinal membrane-induced tractional retinal detachments achieved good structural outcomes after pars plana vitrectomy and membrane peeling.^{7,8}

The largest contributor to our patient's poor visual outcome was cystoid macular edema. Periocular, intravitreal, implanted and systemic steroids have been shown to be effective in the control of uveitic macular edema,⁹ but must be used with caution in patients with infectious uveitis and fungal endophthalmitis. A case series from L. V. Prasad Eye Institute in India showed improvement in inflammation in patients with fungal endophthalmitis concomitantly given antifungals and steroids, without clear evidence of reactivation of the infection.¹⁰ Steroids may be beneficial in infectious uveitic macular edema as well—in a series of eight patients, intravitreal dexamethasone implants showed improvement in visual acuity and resolution of edema without reactivation of infection.¹¹ There have only been a few small stud-

ies evaluating the use of anti-VEGF agents such as bevacizumab for the treatment of uveitic macular edema. Anti-VEGF agents may prove to be a successful and safer alternative for treatment of infectious and non-infectious uveitic macular edema for those at risk of increased intraocular pressure and with steroid refractory macular edema.¹²⁻¹⁵ Randomized, controlled trials are underway examining the use of different approaches, including intravitreal ranibizumab, periocular steroid injections, intravitreal methotrexate and intravitreal steroid injections and implants.¹⁶⁻¹⁸ REVIEW

- Lingappan A, Wykoff CC, Albini TA, et al. Endogenous fungal endophthalmitis: Causative organisms, management strategies, and visual acuity outcomes. *Am J Ophthalmol* 2012;153:1:162-6.e1.
- Liu K, Fang F, Li H. Reliability of vitreous histological detection of pathogenic fungi in the diagnosis of fungal endophthalmitis. *Eye (Lond)* 2015;29:3:424-7.
- Chee YE, Elliott D. The role of vitrectomy in the management of fungal endophthalmitis. *Semin Ophthalmol* 2017;32:1:29-35.
- Behera UC, Budhwani M, Das T, et al. Role of early vitrectomy in the treatment of fungal endophthalmitis. *Retina* 2017; May 23. [Epub ahead of print]
- Birnbaum FA, Gupta G. The role of early vitrectomy in the treatment of fungal endogenous endophthalmitis. *Retin Cases Brief Rep* 2016;10:3:232-5.
- Smiddy WE. Treatment outcomes of endogenous fungal endophthalmitis. *Curr Opin Ophthalmol* 1998;9:3:66-70.
- Naoi N, Sawada A. Effect of vitrectomy on epiretinal membranes after endogenous fungal endophthalmitis. *Jpn J Ophthalmol* 1996;40:3:434-8.
- McDonald HR, De Bustros S, Sipperley JO. Vitrectomy for epiretinal membrane with Candida chorioretinitis. *Ophthalmology* 1990;97:4:466-9.
- Karim R, Sykakis E, Lightman S, Fraser-Bell S. Interventions for the treatment of uveitic macular edema: A systematic review and meta-analysis. *Clin Ophthalmol* 2013;7:1109-44.
- Majji AB, Jalali S, Das T, Gopinathan U. Role of intravitreal dexamethasone in exogenous fungal endophthalmitis. *Eye (Lond)* 1999;13(Pt 5):660-5.
- Fonollosa A, Llorens V, Artaraz J, et al. Safety and efficacy of intravitreal dexamethasone implants in the management of macular edema secondary to infectious uveitis. *Retina* 2016;36:9:1778-85.
- Al-Dhibi H, Hamade IH, Al-Halafi A, et al. The effects of intravitreal bevacizumab in infectious and noninfectious uveitic macular edema. *J Ophthalmol* 2014;2014:729465.
- Bae JH, Lee CS, Lee SC. Efficacy and safety of intravitreal bevacizumab compared with intravitreal and posterior sub-Tenon triamcinolone acetate for treatment of uveitic cystoid macular edema. *Retina* 2011;31:1:111-8.
- Cervantes-Castaneda RA, Giuliani GP, Gallagher MJ, et al. Intravitreal bevacizumab in refractory uveitic macular edema: One-year follow-up. *Eur J Ophthalmol* 2009;19:4:622-9.
- Cordero Coma M, Sobrin L, Onal S, et al. Intravitreal bevacizumab for treatment of uveitic macular edema. *Ophthalmology* 2007;114:8:1574-9.e1.
- The LIMO study: Lucentis for treatment of uveitic patients with refractory cystoid macular oedema. ClinicalTrials.gov Identifier: NCT01564108; Moorfields Eye Hospital NHS Foundation Trust.
- PeriOcular and INTravitreal Corticosteroids for Uveitic Macular Edema Trial (POINT). ClinicalTrials.gov Identifier: NCT02374060; JHSPH Center for Clinical Trials and National Eye Institute (NEI).
- Macular Edema Ranibizumab v. Intravitreal Anti-inflammatory Therapy Trial (MERIT). ClinicalTrials.gov Identifier: NCT02623426; JHSPH Center for Clinical Trials and National Eye Institute (NEI).

Akorn Pharmaceuticals 31
Phone (800) 932-5676
www.akorn.com

Bausch + Lomb 11, 12
Phone (800) 323-0000
Fax (813) 975-7762

ianTECH 7
admin@iantechmed.com
www.iantechmed.com

Imprimis Pharmaceuticals, Inc. 17
Phone (858) 704-4040
Fax (858) 345-1745
www.imprimispharma.com

Johnson & Johnson Vision (formerly AMO) 15
www.vision.abbott

Keeler Instruments 25
Phone (800) 523-5620
Fax (610) 353-7814

Lacrimedics, Inc 51
Phone (800) 367-8327
Fax (253) 964-2699
info@lacrimedics.com
www.lacrimedics.com

Regeneron Pharmaceuticals, Inc. 35
Phone (914) 847-7000
www.regeneron.com

Reichert Technologies 43
Phone (888) 849-8955
Fax (716) 686-4545
www.reichert.com

S4OPTIK 19, 21
Phone (888) 224-6012

Shire Ophthalmics 67, 68
www.shire.com

Sun Ophthalmics 2-3, 4
SunsOnTheRise.com

Topcon Medical Systems 8-9
Phone (800) 223-1130
Fax (201) 599-5250

This advertiser index is published as a convenience and not as part of the advertising contract. Every care will be taken to index correctly. No allowance will be made for errors due to spelling, incorrect page number, or failure to insert.

ENRICH YOUR PRACTICE

Review of Ophthalmology delivers current and comprehensive information focusing on topics such as disease diagnosis, surgical techniques and new technologies.

The *Review Group's Ophthalmic Product Guide* brings you the latest products and technology on the market. Published every February and July.



The *Review Group* also distributes a variety of supplements, guides and handbooks with your subscription to *Review of Ophthalmology*. These publications are designed to keep you informed on what's new and innovative in the industry on topics ranging from cataract refractive surgery to ocular surface disease.

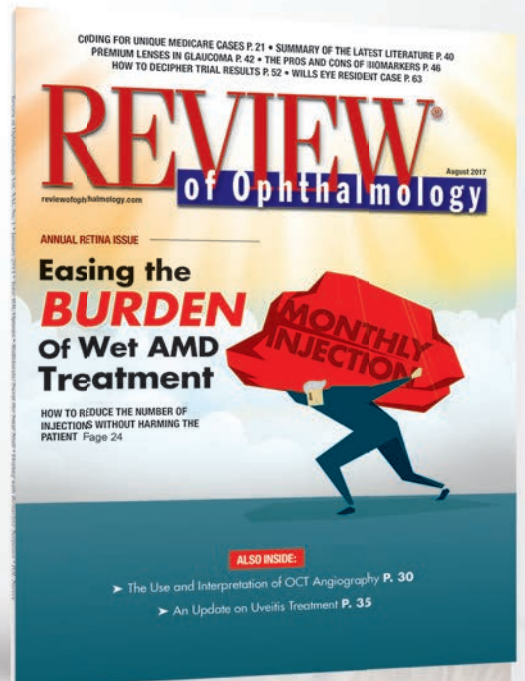

The *Review Group* also offers valuable continuing medical education sessions in both print and online formats, allowing a convenient way for you to earn CME credits. In addition, we also offer an impressive fleet

of free e-newsletters—such as *Review of Ophthalmology Online* and *Review of Ophthalmology's Retina Online*—so you can keep up to date on breaking news and the latest research.



The *Review Group* offers eyecare practitioners quality informational resources dedicated to the growth and education of the profession. The *Review Group* offers a variety of print and online products to enrich your patient care and practice needs.



The *Review Group* also spearheads meetings and conferences, bringing together experts in the field and providing a forum for practitioners that allows you to educate, and learn from others in the profession. These meetings cover a broad range of topics in the form of educational or promotional roundtables and forums.

www.reviewofophthalmology.com



Jobson Medical Information LLC
The *Review Group*



BRIEF SUMMARY:

Consult the Full Prescribing Information for complete product information.

INDICATIONS AND USAGE

Xiidra® (lifitegrast ophthalmic solution) 5% is indicated for the treatment of the signs and symptoms of dry eye disease (DED).

DOSAGE AND ADMINISTRATION

Instill one drop of Xiidra twice daily (approximately 12 hours apart) into each eye using a single-use container. Discard the single-use container immediately after using in each eye. Contact lenses should be removed prior to the administration of Xiidra and may be reinserted 15 minutes following administration.

CONTRAINDICATIONS

Xiidra is contraindicated in patients with known hypersensitivity to lifitegrast or to any of the other ingredients in the formulation.

ADVERSE REACTIONS

Clinical Trials Experience

Because clinical studies are conducted under widely varying conditions, adverse reaction rates observed in clinical studies of a drug cannot be directly compared to rates in the clinical trials of another drug and may not reflect the rates observed in practice. In five clinical studies of dry eye disease conducted with lifitegrast ophthalmic solution, 1401 patients received at least 1 dose of lifitegrast (1287 of which received lifitegrast 5%). The majority of patients (84%) had ≤ 3 months of treatment exposure. 170 patients were exposed to lifitegrast for approximately 12 months. The majority of the treated patients were female (77%). The most common adverse reactions reported in 5-25 % of patients were instillation site irritation, dysgeusia and reduced visual acuity. Other adverse reactions reported in 1% to 5% of the patients were blurred vision, conjunctival hyperemia, eye irritation, headache, increased lacrimation, eye discharge, eye discomfort, eye pruritus and sinusitis.

Postmarketing Experience

The following adverse reactions have been identified during postapproval use of Xiidra. Because these reactions are reported voluntarily from a population of uncertain size, it is not always possible to reliably estimate their frequency or establish a causal relationship to drug exposure.

Rare cases of hypersensitivity, including anaphylactic reaction, bronchospasm, respiratory distress, pharyngeal edema, swollen tongue, and urticaria have been reported. Eye swelling and rash have been reported.

USE IN SPECIFIC POPULATIONS

Pregnancy

There are no available data on Xiidra use in pregnant women to inform any drug associated risks. Intravenous (IV) administration of lifitegrast to pregnant rats, from pre-mating through gestation day 17, did not produce teratogenicity at clinically relevant systemic exposures. Intravenous administration of lifitegrast to pregnant rabbits during organogenesis produced an increased incidence of omphalocele at the lowest dose

tested, 3 mg/kg/day (400-fold the human plasma exposure at the recommended human ophthalmic dose [RHOD], based on the area under the curve [AUC] level). Since human systemic exposure to lifitegrast following ocular administration of Xiidra at the RHOD is low, the applicability of animal findings to the risk of Xiidra use in humans during pregnancy is unclear.

Animal Data

Lifitegrast administered daily by intravenous (IV) injection to rats, from pre-mating through gestation day 17, caused an increase in mean preimplantation loss and an increased incidence of several minor skeletal anomalies at 30 mg /kg /day, representing 5,400-fold the human plasma exposure at the RHOD of Xiidra, based on AUC. No teratogenicity was observed in the rat at 10 mg /kg /day (460-fold the human plasma exposure at the RHOD, based on AUC). In the rabbit, an increased incidence of omphalocele was observed at the lowest dose tested, 3 mg /kg /day (400-fold the human plasma exposure at the RHOD, based on AUC), when administered by IV injection daily from gestation days 7 through 19. A fetal No Observed Adverse Effect Level (NOAEL) was not identified in the rabbit.

Lactation

There are no data on the presence of lifitegrast in human milk, the effects on the breastfed infant, or the effects on milk production. However, systemic exposure to lifitegrast from ocular administration is low. The developmental and health benefits of breastfeeding should be considered, along with the mother's clinical need for Xiidra and any potential adverse effects on the breastfed child from Xiidra.

Pediatric Use

Safety and efficacy in pediatric patients below the age of 17 years have not been established.

Geriatric Use

No overall differences in safety or effectiveness have been observed between elderly and younger adult patients.

NONCLINICAL TOXICOLOGY

Carcinogenesis, Mutagenesis, Impairment of Fertility

Carcinogenesis: Animal studies have not been conducted to determine the carcinogenic potential of lifitegrast.

Mutagenesis: Lifitegrast was not mutagenic in the *in vitro* Ames assay. Lifitegrast was not clastogenic in the *in vivo* mouse micronucleus assay. In an *in vitro* chromosomal aberration assay using mammalian cells (Chinese hamster ovary cells), lifitegrast was positive at the highest concentration tested, without metabolic activation.

Impairment of fertility: Lifitegrast administered at intravenous (IV) doses of up to 30 mg/kg/day (5400-fold the human plasma exposure at the recommended human ophthalmic dose (RHOD) of lifitegrast ophthalmic solution, 5%) had no effect on fertility and reproductive performance in male and female treated rats.



Manufactured for: Shire US Inc., 300 Shire Way, Lexington, MA 02421. For more information, go to www.Xiidra.com or call 1-800-828-2088. Marks designated ® and ™ are owned by Shire or an affiliated company. ©2018 Shire US Inc. SHIRE and the Shire Logo are trademarks or registered trademarks of Shire Pharmaceutical Holdings Ireland Limited or its affiliates. Patented: please see <https://www.shire.com/legal-notice/product-patents> Last Modified: 01/2018 S33769



SIGN & SYMPTOM IMPROVEMENT

The only prescription eye drop FDA-approved to treat both the signs and symptoms of Dry Eye Disease

Xiidra improved patient-reported symptoms of eye dryness and improved signs of inferior corneal staining. So help patients get to know Xiidra.

Check it out at Xiidra-ECP.com

Four randomized, double-masked, 12-week trials evaluated the efficacy and safety of Xiidra versus vehicle as assessed by improvement in the signs (measured by Inferior Corneal Staining Score) and/or symptoms (measured by Eye Dryness Score) of Dry Eye Disease (N=2133).

The safety of lifitegrast was evaluated in 5 clinical studies. 1401 patients received at least one dose of lifitegrast (1287 of which received Xiidra). The most common adverse reactions (5-25%) were instillation site irritation, dysgeusia, and reduced visual acuity.

Indication

Xiidra® (lifitegrast ophthalmic solution) 5% is indicated for the treatment of signs and symptoms of dry eye disease (DED).

Important Safety Information

Xiidra is contraindicated in patients with known hypersensitivity to lifitegrast or to any of the other ingredients.

In clinical trials, the most common adverse reactions reported in 5-25% of patients were instillation site irritation, dysgeusia and reduced visual acuity. Other adverse reactions reported in 1% to 5% of the patients were blurred vision, conjunctival hyperemia, eye irritation, headache, increased lacrimation, eye discharge, eye discomfort, eye pruritus and sinusitis.

To avoid the potential for eye injury or contamination of the solution, patients should not touch the tip of the single-use container to their eye or to any surface.

Contact lenses should be removed prior to the administration of Xiidra and may be reinserted 15 minutes following administration.

Safety and efficacy in pediatric patients below the age of 17 years have not been established.

For additional safety information, see accompanying Brief Summary of Safety Information on the adjacent page and Full Prescribing Information on Xiidra-ECP.com.