

FIRST RETINAL GENE THERAPY APPROVED P. 3 • GONIOSYNECHIALYSIS AND CATARACT P. 47
EMERGING TREATMENTS FOR UVEITIS P. 52 • RESEARCH ON TORIC ALIGNMENT P. 57
A RUNDOWN OF NEW PRODUCTS P. 59 • WILLIS EYE RESIDENT CASE P. 61

REVIEW[®] of Ophthalmology

January 2018

reviewofophthalmology.com

ANNUAL IOL ISSUE

ANSWERING YOUR

TOP 10 IOL-FORMULA QUESTIONS

P. 16

ALSO INSIDE:

- Pros/Cons of the Newly-approved Light-adjustable IOL **P. 12**
- Choose Patients Wisely for Presbyopic IOLs **P. 30**
- Premium IOLs: Spotting Poor Candidates **P. 38**
- Survey on IOL Preferences **P. 42**

WHAT SETS THE ACTIVEFOCUS™ DESIGN APART?

THE DIFFERENCE
IS IN THE DISTANCE.



ACTIVEFOCUS™
Optical Design



AcrySof IQ
ReSTOR. +2.5
MULTIFOCAL IOL

ACTIVEFOCUS™ Toric
Optical Design



AcrySof IQ
ReSTOR. Toric +2.5
MULTIFOCAL IOL

FDA Approves First-ever Retinal Gene Therapy

On December 19, 2017, the U.S. Food and Drug Administration approved a new gene therapy, voretigene neparvovec-rzyl (Luxturna), manufactured by Spark Therapeutics in Philadelphia. Luxturna is the first gene therapy approved in the United States that's directly administered into the eye, targeting diseases caused by mutations in the gene RPE65. Mutations in this gene can produce Leber's congenital amaurosis or retinitis pigmentosa, both rare but potentially blinding diseases.

The RPE65 gene provides genetic instructions for making an enzyme that converts light to an electrical signal in the retina; mutations in the gene cause reduced or no enzyme activity, resulting in impaired vision. Luxturna uses a naturally occurring adeno-associated virus, modified using recom-

binant DNA techniques, to deliver a healthy RPE65 gene to the retinal cells via a subretinal injection to restore vision. Treatment is followed by a short course of oral prednisolone to limit any potential immune reaction. (Each eye must be treated on separate days, at least six days apart.) In the pivotal study, the most common adverse reactions to treatment included conjunctival hyperemia, cataract, increased intraocular pressure and retinal tear.

The safety and efficacy of Luxturna were established in a clinical development program involving 41 patients with confirmed RPE65 mutations between the ages of 4 and 44 years. A Phase III study with 31 participants measured the change in a subject's ability to navigate an obstacle course at various light levels, from baseline to one year. Patients that received Luxturna demonstrated significant improvements in their ability to complete the obstacle course at low light levels, compared to the control group.

Jean Bennett, MD, PhD, is a professor of ophthalmology and director of the Center for Advanced Retinal and Ocular Therapeutics at the University of Pennsylvania in Philadelphia. She's also scientific co-founder of Spark, and was the scientific director for the RPE65 deficiency clinical trials. "This is the second gene therapy approved by the FDA," she notes, "but it's the first one to target a genetic disease, and the first in which the gene is delivered directly into the person, rather than first being delivered into a cell in a dish. It's also the first gene therapy approved worldwide for a retinal disease. Seventeen years ago, our team demonstrated that we could reverse blindness in a dog born with the same mutation that causes blindness in children, Leber's congenital amaurosis. Since then we've been moving this through clinical trials. The approval comes upon finishing a Phase III study, which was the first controlled, randomized gene therapy clinical trial for a genetic disease."

As for availability of the treatment, Dr. Bennett says Spark Therapeutics is establishing centers of excellence that will be set up to deliver the drug to qualified candidates. "This involves surgical delivery and a training plan for retinal surgeons at these centers," she explains. "The estimate I've been given for availability is six months from now. We'll be setting up a center here at the University of Pennsylvania,

IMPORTANT PRODUCT INFORMATION FOR THE ACRYSOFTM IQ RESTORTM FAMILY OF IOLs

CAUTION: Federal (USA) law restricts this device to the sale by or on the order of a physician.

INDICATIONS: The AcrySof® IQ ReSTOR® Posterior Chamber Intraocular Multifocal IOLs include AcrySof® IQ ReSTOR® and AcrySof® IQ ReSTOR® Toric and are intended for primary implantation for the visual correction of aphakia secondary to removal of a cataractous lens in adult patients with and without presbyopia, who desire near, intermediate and distance vision with increased spectacle independence. In addition, the AcrySof® IQ ReSTOR® Toric IOL is intended to correct pre-existing astigmatism. The lenses are intended to be placed in the capsular bag.

WARNINGS/PRECAUTIONS: Careful preoperative evaluation and sound clinical judgment should be used by the surgeon to decide the risk/benefit ratio before implanting a lens in a patient with any of the conditions described in the Directions for Use labeling for each IOL. Physicians should target emmetropia, and ensure that IOL centration is achieved. Care should be taken to remove viscoelastic from the eye at the close of surgery.

The ReSTOR Toric IOL should not be implanted if the posterior capsule is ruptured, if the zonules are damaged, or if a primary posterior capsulotomy is planned. Rotation can reduce astigmatic correction; if necessary lens repositioning should occur as early as possible prior to lens encapsulation.

Some patients may experience visual disturbances and/or discomfort due to multifocality, especially under dim light conditions. A reduction in contrast sensitivity may occur in low light conditions. Visual symptoms may be significant enough that the patient will request explant of the multifocal IOL. Spectacle independence rates vary; some patients may need glasses when reading small print or looking at small objects.

Posterior capsule opacification (PCO), when present, may develop earlier into clinically significant PCO with multifocal IOLs. Prior to surgery, physicians should provide prospective patients with a copy of the Patient Information Brochure available from Alcon informing them of possible risks and benefits associated with the AcrySof® IQ ReSTOR® IOLs.

Do not resterilize; do not store over 45° C; use only sterile irrigating solutions such as BSS® or BSS PLUS® Sterile Intraocular Irrigating Solutions.

ATTENTION: Reference the Directions for Use labeling for each IOL for a complete listing of indications, warnings and precautions.

Editor in Chief

Walter C. Bethke
(610) 492-1024
wbethke@jobson.com

Senior Editor

Christopher Kent
(814) 861-5559
ckent@jobson.com

Senior Associate Editor

Kristine Brennan
(610) 492-1008
kbrennan@jobson.com

Associate Editor

Liam Jordan
(610) 492-1025
ljordan@jobson.com

Chief Medical Editor

Mark H. Blecher, MD

Art Director

Jared Araujo
(610) 492-1032
jaraujo@jobson.com

Senior Graphic Designer

Matt Egger
(610) 492-1029
megger@jobson.com

International coordinator, Japan

Mitz Kaminuma
Reviewophthalgo@aol.com

Business Offices

11 Campus Boulevard, Suite 100
Newtown Square, PA 19073
(610) 492-1000
Fax: (610) 492-1039

Subscription inquiries:

United States — (877) 529-1746
Outside U.S. — (845) 267-3065

E-mail:

revophthalmology@cambeywest.com

Website: www.reviewofophthalmology.com



and that matches our time estimate.”

Current estimates of the cost of the procedure are very high, ranging up to \$500,000 per eye. Dr. Bennett says pricing issues are outside of her purview. “I’ve been assured by Spark Therapeutics that they’ll do their best to accommodate people who could benefit from the procedure,” she says. “Part of the challenge of pricing this is that it’s unusual for a drug company to be selling a one-shot drug treatment, rather than something that requires repeated dosing over time, and it’s a procedure that will have ramifications for the person’s life and career and reduce the need for family and caregivers to help the person. We certainly hope it will get less expensive over time.”

Dr. Bennett notes that one benefit of this FDA approval is that there was previously no FDA pathway for the development of a gene therapy. “I hope that having that pathway will expedite the development of other drugs for diseases for which we don’t have good treatments now,” she says. In that vein, the FDA plans to begin issuing guidance documents to help with the development of specific gene therapy products for high-priority diseases next year. Meanwhile, the manufacturer plans to conduct a post-marketing observational study of patients treated with Luxturna to further evaluate its long-term safety.

Clinical Alert Issued On Intracameral Epinephrine

The American Society of Cataract

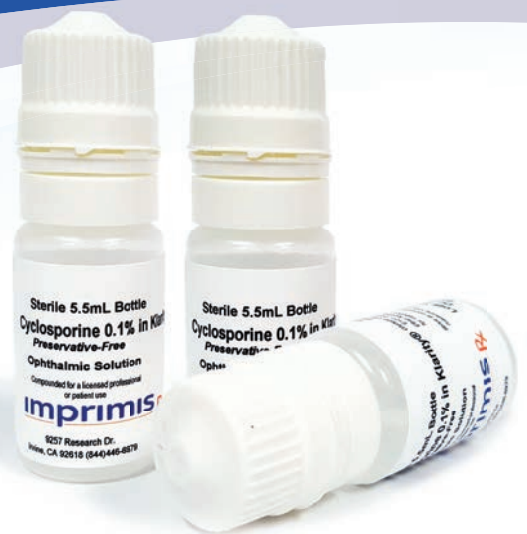and Refractive Surgery recently issued a clinical alert to warn surgeons that PAR Pharmaceutical (Chestnut Ridge, N.Y.) has updated its epinephrine formula, rendering it inappropriate for intraocular use: ASCRS recommends that surgeons make sure their centers are not ordering the new epinephrine for ophthalmic use, and offers advice on how to safely use epinephrine from alternative sources.

Last January, PAR started making and shipping epinephrine containing 0.457 mg/ml of sodium metabisulfite (bisulfites can damage the corneal epithelium at concentrations of 0.1%) and 2.25 mg/ml of tartaric acid (no published data or reports exist regarding intracameral tartaric acid). Although PAR has disseminated new prescriber information and its 30-ml bottles of the new epinephrine are labeled “Not for Ophthalmic Use,” its single-dose, 1-ml vials don’t have this warning. ASCRS would like to avoid inducing TASS as a result of using the product.

ASCRS adds that even “preservative-free” epinephrine from alternative sources is likely to contain bisulfite as a stabilizer, but that studies have demonstrated that corneas exposed to sodium bisulfite 0.05% show no endothelial changes. Therefore, diluting preservative-free epinephrine containing bisulfite 0.1% 1:4 with BSS should be safe for intracameral use, as should mixing epi-Shugarcaine (9 cc BSS Plus; 4 cc 1:1000 epinephrine; and 3 cc nonpreserved lidocaine 4%). ASCRS also says that diluting bisulfite-containing epinephrine in the irrigating bottle is safe, but recommends avoiding epinephrine with tartaric acid, regardless of concentration, until more data becomes available.

The full ASCRS clinical alert can be found at: <http://www.ascrs.org/about-ascrs/news-about/clinical-alert-intraocular-use-epinephrine-maintain-mydrisis-during-cataract-surgery>. **REVIEW**

Are your patients complaining about their current DRY EYE drops?



Now available: Klarity-C Drops

(Cyclosporine 0.1% Chondroitin Sulfate Ophthalmic Emulsion*)

Only **\$99⁹⁹** for your patient's first 3-month supply!

No Coupons

No Prior Authorizations

No Call Backs

www.totaltears.com

*For professional use only. Imprimis Pharmaceuticals specializes in customizing medications to meet unique patient and practitioner needs. Imprimis dispenses these formulations only to individually identified patients with valid prescriptions. No compounded medication is reviewed by the FDA for safety or efficacy. Imprimis Pharmaceuticals does not compound essentially copies of approved drug products. References available upon request.

imprimis **Rx**[®]
844.446.6979

CONTRIBUTORS

CHIEF MEDICAL EDITOR

Mark H. Blecher, MD

CONTACT LENSES

Penny Asbell, MD

CORNEA / ANTERIOR SEGMENT

Thomas John, MD

GLAUCOMA MANAGEMENT

Peter Netland, MD, PHD
Kuldev Singh, MD

MASTERS OF SURGERY

Taliva D. Martin, MD
Sara J. Haug, MD, PhD

MEDICARE Q & A

Paul M. Larson, MBA

PEDIATRIC PATIENT

Wendy Huang, MD

PLASTIC POINTERS

Ann P. Murchison, MD, MPH

REFRACTIVE SURGERY

Arturo S. Chayet, MD

RETINAL INSIDER

Carl Regillo, MD, FACS
Emmett T. Cunningham Jr., MD, PHD, MPH

TECHNOLOGY UPDATE

Steven T. Charles, MD
Michael Colvard, MD

WILLS RESIDENT CASE SERIES

Thomas Jenkins, MD.

ADVISORY BOARD

PENNY A. ASBELL, MD, NEW YORK CITY

WILLIAM I. BOND, MD, PEKIN, ILL.

ALAN N. CARLSON, MD, DURHAM, N.C.

Y. RALPH CHU, MD, EDINA, MINN.

ADAM J. COHEN, MD, DOWNERS GROVE, ILL.

UDAY DEVGAN, MD, FACS, LOS ANGELES

ERIC DONNENFELD, MD, ROCKVILLE CENTRE, N.Y.

DANIEL S. DURRIE, MD, KANSAS CITY, MO.

ROBERT EPSTEIN, MD, MCHENRY, ILL.

ROBERT D. FECHTNER, MD, NEWARK, N.J.

WILLIAM J. FISHKIND, MD, TUCSON, ARIZ.

JAMES P. GILLS, MD, TARPON SPRINGS, FLA.

HARRY GRABOW, MD, SARASOTA, FLA.

DOUGLAS K. GRAYSON, MD, NEW YORK CITY

THOMAS S. HARBIN, MD, MBA, ATLANTA

DAVID R. HARDTEN, MD, MINNEAPOLIS

KENNETH J. HOFFER, MD, SANTA MONICA, CALIF.

JACK T. HOLLADAY, MD, MSEE, HOUSTON

JOHN D. HUNKELER, MD, KANSAS CITY, MO.

THOMAS JOHN, MD, TINLEY PARK, ILL.

ROBERT M. KERSHNER, MD, MS, FACS, BOSTON

GUY M. KEZIRIAN, MD, PARADISE VALLEY, ARIZ.

TERRY KIM, MD, DURHAM, N.C.

TOMMY KORN, MD, SAN DIEGO

DAVID A. LEE, MD, HOUSTON

FRANCIS S. MAH, MD, PITTSBURGH

NICK MAMALIS, MD, SALT LAKE CITY

WILLIAM G. MARTIN, MD, OREGON, OHIO

MIKE S. MCFARLAND, MD, PINE BLUFF, ARK.

JEFFREY B. MORRIS, MD, MPH, ENCINITAS, CALIF.

MARLENE R. MOSTER, MD, PHILADELPHIA

ROBERT J. NOECKER, MD, FAIRFIELD, CONN.

ROBERT OSHER, MD, CINCINNATI

MARK PACKER, MD, WEST PALM BEACH, FLA.

STEPHEN PASCUCCI, MD, BONITA SPRINGS, FLA.

PAUL PENDER, MD, BEDFORD, N.H.

CHRISTOPHER J. RAPUANO, MD, PHILADELPHIA

AUGUST READER III, MD, SAN FRANCISCO

TONY REALINI, MD, MORGANTOWN, W.V.

KENNETH J. ROSENTHAL, MD, GREAT NECK, N.Y.

ERIC ROTHCHILD, MD, DELRAY BEACH, FLA.

SHERI ROWEN, MD, BALTIMORE

JAMES J. SALZ, MD, LOS ANGELES

INGRID U. SCOTT, MD, MPH, HERSHEY, PA.

JOEL SCHUMAN, MD, PITTSBURGH

GAURAV SHAH, MD, ST. LOUIS

DAVID R. STAGER JR., MD, DALLAS

KARL STONECIPHER, MD, GREENSBORO, N.C.

JAMES C. TSAI, MD, NEW YORK CITY

VANCE THOMPSON, MD, SIOUX FALLS, S.D.

FARRELL C. TYSON, MD, CAPE CORAL, FLA.

R. BRUCE WALLACE III, MD, ALEXANDRIA, LA.

ROBERT G. WILEY, MD, CLEVELAND

FRANK WEINSTOCK, MD, CANTON, OHIO

BUSINESS OFFICES

11 CAMPUS BOULEVARD, SUITE 100
NEWTOWN SQUARE, PA 19073
SUBSCRIPTION INQUIRIES (877) 529-1746
(USA ONLY); OUTSIDE USA, CALL (847) 763-9630

BUSINESS STAFF

PUBLISHER

JAMES HENNE

(610) 492-1017 JHENNE@JOBSON.COM

REGIONAL SALES MANAGER

MICHELE BARRETT

(610) 492-1014 MBARRETT@JOBSON.COM

REGIONAL SALES MANAGER

MICHAEL HOSTER

(610) 492-1028 MHOSTER@JOBSON.COM

CLASSIFIED ADVERTISING

(888)-498-1460

VICE PRESIDENT OF OPERATIONS

CASEY FOSTER

(610) 492-1007 CFOSTER@JOBSON.COM

PRODUCTION MANAGER

SCOTT TOBIN

(610) 492-1011 STOBIN@JOBSON.COM

SUBSCRIPTIONS

\$63 A YEAR, \$99 (U.S.) IN CANADA,
\$158 (U.S.) IN ALL OTHER COUNTRIES.

SUBSCRIPTIONS E-MAIL:

REVOPHTHALMOLOGY@CAMBEYWEST.COM

CIRCULATION

PO BOX 71, CONGERS, NY 10920-0071
(877) 529-1746

OUTSIDE USA: (845) 267-3065

SENIOR CIRCULATION MANAGER

HAMILTON MAHER

(212) 219-7870 hmaher@jhihealth.com

CEO, INFORMATION GROUP SERVICES

MARC FERRARA

SENIOR VICE PRESIDENT, OPERATIONS

JEFF LEVITZ

VICE PRESIDENT, HUMAN RESOURCES

TAMMY GARCIA

VICE PRESIDENT, CREATIVE SERVICES & PRODUCTION

MONICA TETTAMANZI

CORPORATE PRODUCTION DIRECTOR

JOHN ANTHONY CAGGIANO

VICE PRESIDENT, CIRCULATION

EVELDA BAREA



440 Ninth Avenue, 14th Floor
New York, N.Y. 10001

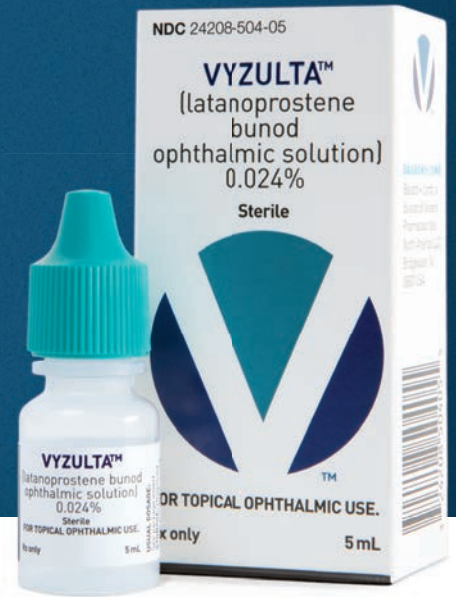REVIEW OF OPHTHALMOLOGY (ISSN 1081-0226; USPS No. 0012-345) is published monthly, 12 times per year by Jobson Medical Information, 440 Ninth Avenue, 14th Floor, New York, N.Y. 10001. Periodicals postage paid at New York, NY and additional mailing offices. Postmaster: Send address changes to Review of Ophthalmology, PO Box 71, Congers, NY 10929-0071. Subscription Prices: US One Year \$63.00, US Two Year \$112.00, Canada One Year \$99.00, Canada Two Year \$181.00, Int'l One Year \$158.00, Int'l Two Year \$274.00. For subscription information call (877) 529-1746 (USA only); outside USA, call (845)-267-3065. Or email us at revophthalmology@cambeywest.com. Canada Post: Publications Mail Agreement #40612608. Canada Returns to be sent to Bleuchip International, P.O. Box 25542, London, ON N6C 6B2.


VYZULTA™
(latanoprostene
bunod ophthalmic
solution), 0.024%

VYZULTA

NOW AVAILABLE

IN PHARMACIES NATIONWIDE



YOU CAN NOW START PRESCRIBING VYZULTA FOR YOUR GLAUCOMA PATIENTS.

- > VYZULTA delivers a dual mechanism of action for the reduction of IOP in glaucoma patients¹
- > VYZULTA coupons are available for eligible patients
- > There is no A/B generic equivalent to VYZULTA. Please share this information with your patients in case they experience a switch at the pharmacy

For more information about VYZULTA, visit vyzultanow.com

INDICATION

VYZULTA™ (latanoprostene bunod ophthalmic solution), 0.024% is indicated for the reduction of intraocular pressure (IOP) in patients with open-angle glaucoma or ocular hypertension.

IMPORTANT SAFETY INFORMATION

- Increased pigmentation of the iris and periorbital tissue (eyelid) can occur. Iris pigmentation is likely to be permanent
- Gradual changes to eyelashes, including increased length, increased thickness, and number of eyelashes, may occur. These changes are usually reversible upon treatment discontinuation
- Use with caution in patients with a history of intraocular inflammation (iritis/uveitis). VYZULTA should generally not be used in patients with active intraocular inflammation
- Macular edema, including cystoid macular edema, has been reported during treatment with prostaglandin analogs. Use with caution in aphakic patients, in pseudophakic patients with a torn posterior lens capsule, or in patients with known risk factors for macular edema
- There have been reports of bacterial keratitis associated with the use of multiple-dose containers of topical ophthalmic products that were inadvertently contaminated by patients
- Contact lenses should be removed prior to the administration of VYZULTA and may be reinserted 15 minutes after administration
- Most common ocular adverse reactions with incidence $\geq 2\%$ are conjunctival hyperemia (6%), eye irritation (4%), eye pain (3%), and instillation site pain (2%)

REFERENCE

1. VYZULTA Prescribing Information. Bausch & Lomb Incorporated. 2017.

BAUSCH + LOMB

VYZULTA and the V design are trademarks of Bausch & Lomb Incorporated or its affiliates.
©2017 Bausch & Lomb Incorporated. All rights reserved. VYZ.0351.USA.17

**For more information, please see Brief Summary
of Prescribing Information on next page.**

BRIEF SUMMARY OF PRESCRIBING INFORMATION

This Brief Summary does not include all the information needed to use VYZULTA safely and effectively. See full Prescribing Information for VYZULTA.

VYZULTA™ (latanoprostene bunod ophthalmic solution), 0.024%, for topical ophthalmic use.

Initial U.S. Approval: 2017

1 INDICATIONS AND USAGE

VYZULTA™ (latanoprostene bunod ophthalmic solution) 0.024% is indicated for the reduction of intraocular pressure (IOP) in patients with open-angle glaucoma or ocular hypertension.

4 CONTRAINDICATIONS

None

5 WARNINGS AND PRECAUTIONS

5.1 Pigmentation

VYZULTA™ (latanoprostene bunod ophthalmic solution), 0.024% may cause changes to pigmented tissues. The most frequently reported changes with prostaglandin analogs have been increased pigmentation of the iris and periorbital tissue (eyelid).

Pigmentation is expected to increase as long as latanoprostene bunod ophthalmic solution is administered. The pigmentation change is due to increased melanin content in the melanocytes rather than to an increase in the number of melanocytes. After discontinuation of VYZULTA, pigmentation of the iris is likely to be permanent, while pigmentation of the periorbital tissue and eyelash changes are likely to be reversible in most patients. Patients who receive prostaglandin analogs, including VYZULTA, should be informed of the possibility of increased pigmentation, including permanent changes. The long-term effects of increased pigmentation are not known.

Iris color change may not be noticeable for several months to years. Typically, the brown pigmentation around the pupil spreads concentrically towards the periphery of the iris and the entire iris or parts of the iris become more brownish. Neither nevi nor freckles of the iris appear to be affected by treatment. While treatment with VYZULTA™ (latanoprostene bunod ophthalmic solution), 0.024% can be continued in patients who develop noticeably increased iris pigmentation, these patients should be examined regularly [see Patient Counseling Information (17) in full Prescribing Information].

5.2 Eyelash Changes

VYZULTA may gradually change eyelashes and vellus hair in the treated eye. These changes include increased length, thickness, and the number of lashes or hairs. Eyelash changes are usually reversible upon discontinuation of treatment.

5.3 Intraocular Inflammation

VYZULTA should be used with caution in patients with a history of intraocular inflammation (iritis/uveitis) and should generally not be used in patients with active intraocular inflammation as it may exacerbate this condition.

5.4 Macular Edema

Macular edema, including cystoid macular edema, has been reported during treatment with prostaglandin analogs. VYZULTA should be used with caution in aphakic patients, in pseudophakic patients with a torn posterior lens capsule, or in patients with known risk factors for macular edema.

5.5 Bacterial Keratitis

There have been reports of bacterial keratitis associated with the use of multiple-dose containers of topical ophthalmic products. These containers had been inadvertently contaminated by patients who, in most cases, had a concurrent corneal disease or a disruption of the ocular epithelial surface.

5.6 Use with Contact Lens

Contact lenses should be removed prior to the administration of VYZULTA because this product contains benzalkonium chloride. Lenses may be reinserted 15 minutes after administration.

6 ADVERSE REACTIONS

The following adverse reactions are described in the Warnings and Precautions section: pigmentation (5.1), eyelash changes (5.2), intraocular inflammation (5.3), macular edema (5.4), bacterial keratitis (5.5), use with contact lens (5.6).

6.1 Clinical Trials Experience

Because clinical trials are conducted under widely varying conditions, adverse reaction rates observed in the clinical trials of a drug cannot be directly compared to rates in the clinical trials of another drug and may not reflect the rates observed in practice.

VYZULTA was evaluated in 811 patients in 2 controlled clinical trials of up to 12 months duration. The most common ocular adverse reactions observed in patients treated with latanoprostene bunod were: conjunctival hyperemia (6%), eye irritation (4%), eye pain (3%), and instillation site pain (2%). Approximately 0.6% of patients discontinued therapy due to ocular adverse reactions including ocular hyperemia, conjunctival irritation, eye irritation, eye pain, conjunctival edema, vision blurred, punctate keratitis and foreign body sensation.

8 USE IN SPECIFIC POPULATIONS

8.1 Pregnancy

Risk Summary

There are no available human data for the use of VYZULTA during pregnancy to inform any drug associated risks.

Latanoprostene bunod has caused miscarriages, abortion, and fetal harm in rabbits. Latanoprostene bunod was shown to be abortifacient and teratogenic when administered intravenously (IV) to pregnant rabbits at exposures \geq 0.28 times the clinical dose.

Doses \geq 20 μ g/kg/day (23 times the clinical dose) produced 100% embryofetal lethality. Structural abnormalities observed in rabbit fetuses included anomalies of the great vessels and aortic arch vessels, domed head, sternebral and vertebral skeletal anomalies, limb hyperextension and malrotation, abdominal distension and edema. Latanoprostene bunod was not teratogenic in the rat when administered IV at 150 mcg/kg/day (87 times the clinical dose) [see Data].

The background risk of major birth defects and miscarriage for the indicated population is unknown. However, the background risk in the U.S. general population of major birth defects is 2 to 4%, and of miscarriage is 15 to 20%, of clinically recognized pregnancies.

Data

Animal Data

Embryofetal studies were conducted in pregnant rabbits administered latanoprostene bunod daily by intravenous injection on gestation days 7 through 19, to target the period of organogenesis. The doses administered ranged from 0.24 to 80 mcg/kg/day. Abortion occurred at doses \geq 0.24 mcg/kg/day latanoprostene bunod (0.28 times the clinical dose, on a body surface area basis, assuming 100% absorption). Embryofetal lethality (resorption) was increased in latanoprostene bunod treatment groups, as evidenced by increases in early resorptions at doses \geq 0.24 mcg/kg/day and late resorptions at doses \geq 6 mcg/kg/day (approximately 7 times the clinical dose). No fetuses survived in any rabbit pregnancy at doses of 20 mcg/kg/day (23 times the clinical dose) or greater. Latanoprostene bunod produced structural abnormalities at doses \geq 0.24 mcg/kg/day (0.28 times the clinical dose). Malformations included anomalies of sternum, coarctation of the aorta with pulmonary trunk dilation, retroesophageal subclavian artery with absent brachiocephalic artery, domed head, forepaw hyperextension and hindlimb malrotation, abdominal distention/edema, and missing/fused caudal vertebrae.

An embryofetal study was conducted in pregnant rats administered latanoprostene bunod daily by intravenous injection on gestation days 7 through 17, to target the period of organogenesis. The doses administered ranged from 150 to 1500 mcg/kg/day. Maternal toxicity was produced at 1500 mcg/kg/day (870 times the clinical dose, on a body surface area basis, assuming 100% absorption), as evidenced by reduced maternal weight gain. Embryofetal lethality (resorption and fetal death) and structural anomalies were produced at doses \geq 300 mcg/kg/day (174 times the clinical dose). Malformations included anomalies of the sternum, domed head, forepaw hyperextension and hindlimb malrotation, vertebral anomalies and delayed ossification of distal limb bones. A no observed adverse effect level (NOAEL) was established at 150 mcg/kg/day (87 times the clinical dose) in this study.

8.2 Lactation

Risk Summary

There are no data on the presence of VYZULTA in human milk, the effects on the breastfed infant, or the effects on milk production. The developmental and health benefits of breastfeeding should be considered, along with the mother's clinical need for VYZULTA, and any potential adverse effects on the breastfed infant from VYZULTA.

8.4 Pediatric Use

Use in pediatric patients aged 16 years and younger is not recommended because of potential safety concerns related to increased pigmentation following long-term chronic use.

8.5 Geriatric Use

No overall clinical differences in safety or effectiveness have been observed between elderly and other adult patients.

13 NONCLINICAL TOXICOLOGY

13.1 Carcinogenesis, Mutagenesis, Impairment of Fertility

Latanoprostene bunod was not mutagenic in bacteria and did not induce micronuclei formation in the *in vivo* rat bone marrow micronucleus assay. Chromosomal aberrations were observed *in vitro* with human lymphocytes in the absence of metabolic activation.

Latanoprostene bunod has not been tested for carcinogenic activity in long-term animal studies. Latanoprost acid is a main metabolite of latanoprostene bunod. Exposure of rats and mice to latanoprost acid, resulting from oral dosing with latanoprost in lifetime rodent bioassays, was not carcinogenic.

Fertility studies have not been conducted with latanoprostene bunod. The potential to impact fertility can be partially characterized by exposure to latanoprost acid, a common metabolite of both latanoprostene bunod and latanoprost. Latanoprost acid has not been found to have any effect on male or female fertility in animal studies.

13.2 Animal Toxicology and/or Pharmacology

A 9-month toxicology study administered topical ocular doses of latanoprostene bunod to one eye of cynomolgus monkeys: control (vehicle only), one drop of 0.024% bid, one drop of 0.04% bid and two drops of 0.04% per dose, bid. The systemic exposures are equivalent to 4.2-fold, 7.9-fold, and 13.5-fold the clinical dose, respectively, on a body surface area basis (assuming 100% absorption). Microscopic evaluation of the lungs after 9 months observed pleural/subpleural chronic fibrosis/inflammation in the 0.04% dose male groups, with increasing incidence and severity compared to controls. Lung toxicity was not observed at the 0.024% dose.

Distributed by:

Bausch + Lomb, a division of

Valeant Pharmaceuticals North America LLC

Bridgewater, NJ 08807 USA

U.S. Patent Numbers: 6,211,233; 7,273,946; 7,629,345; 7,910,767; 8,058,467.

VYZULTA is a trademark of Bausch & Lomb Incorporated or its affiliates.

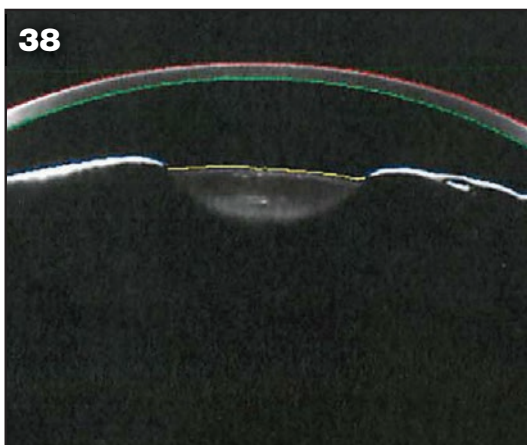

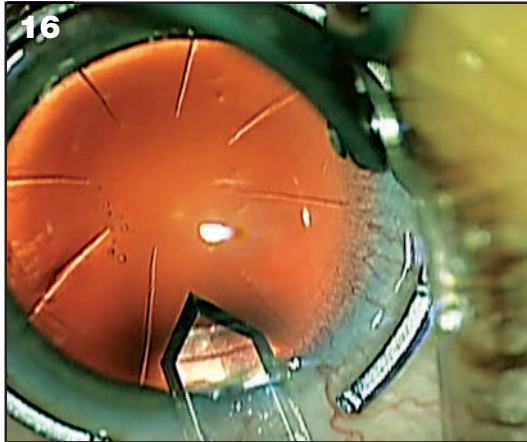
© Bausch & Lomb Incorporated

Based on 9464800 11/2017 VYZ.005.USA.16 Issued: 11/2017

REVIEW[®] of Ophthalmology

January 2018 • Volume XXV No. 1 | reviewofophthalmology.com

Cover Focus



16 | **IOL Power Formulas: 10 Questions Answered**

Christopher Kent, Senior Editor

Help ensure optimum outcomes through a better understanding of lens power calculations.

30 | **Presbyopic IOLs: Choosing Wisely**

Kristine Brennan, Senior Associate Editor

How to watch and listen to your patients to enhance your success rate.

38 | **Premium IOLs: How to Spot Poor Candidates**

Liam Jordan, Associate Editor

How to weed out candidates who will be dissatisfied with these IOLs.

42 | **Surgeons Share Their Views on IOLs**

Walter Bethke, Editor in Chief

Opinions on monofocals, multifocals, torics and handling lens complications.

Departments

3 | [Review News](#)

12 | [Refractive/Cataract Rundown](#)

RxLAL: Say Goodbye to Postop Surprise?

A first look at the safety, efficacy and potential usage of the newly approved light-adjustable lens.

47 | [Glaucoma Management](#)

Goniosynechialysis and Cataract Surgery

An often underused procedure, GSL can be a significant contributor to pressure control.

52 | [Retinal Insider](#)

A Look at Emerging Treatments for Uveitis

Companies and researchers are hard at work on new drugs as well as innovative delivery systems.

57 | [Research Review](#)

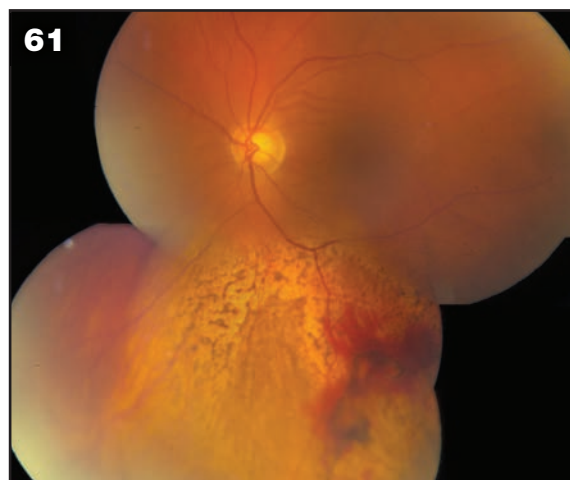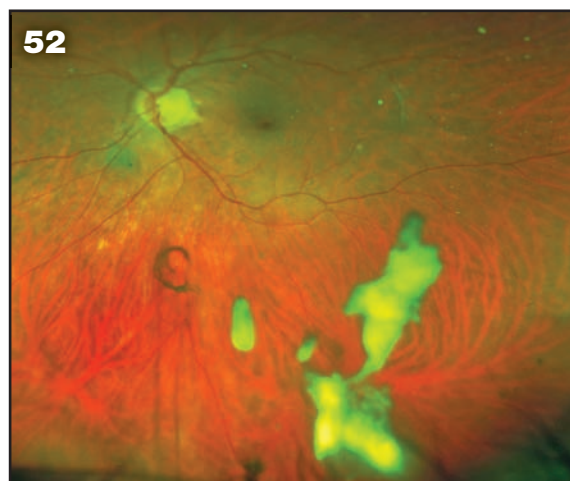

Corneal Marking for Toric IOLs

59 | [Product News](#)

60 | [Classifieds](#)

61 | [Wills Eye Resident Case Series](#)

65 | [Ad Index](#)





THE RICK BAY FOUNDATION

for Excellence in Eyecare Education

www.rickbayfoundation.org

Support the Education of Future Healthcare & Eyecare Professionals



About Rick

Rick Bay served as the publisher of *The Review Group* for more than 20 years.



To those who worked for him, he was a leader whose essence was based in a fierce and boundless loyalty.


To those in the industry and the professions he served, he will be remembered for his unique array of skills and for his dedication to exceeding the expectations of his customers, making many of them fast friends.

Scholarships are awarded to advance the education of students in both **Optometry** and **Ophthalmology**, and are chosen by their school based on qualities that embody Rick's commitment to the profession, including integrity, compassion, partnership and dedication to the greater good.

Interested in being a partner with us?

Visit www.rickbayfoundation.org

(Contributions are tax-deductible in accordance with section 170 of the Internal Revenue Code.)



THE RICK BAY FOUNDATION®
for Excellence in Eyecare Education

(The Rick Bay Foundation for Excellence in Eyecare Education is a nonprofit, tax-exempt organization under section 501(c)(3) of the Internal Revenue Code.)



RxLAL: Say Goodbye to Postop Surprise?

A first look at the safety, efficacy and potential implementation of the newly approved light-adjustable lens.


Walter Bethke, Editor in Chief

In the fall of 2017, the Food and Drug Administration approved RxSight's (formerly Calhoun Vision) Light Adjustable Lens (RxLAL), opening the floodgates for speculation on just how effective—and disruptive—this technology might prove to be. With the lens offering the ability to adjust a patient's spherical and cylindrical refractions post-implantation, would this mean obsessing over intraocular lens calculations, intraoperative aberrometry pros and cons and the myriad ways to mark the toric axis would be quaint curiosities of the past? Though it's a little early to pass judgment on those counts, in this article, surgeons who worked with the lens in the clinical trial discuss its performance, advantages and disadvantages, and the ways it might be integrated into ophthalmic practice.

The Technology

Though the Light Adjustable Lens has been available in Europe and Mexico since 2008, information about the lens and interest in it the United States have waxed and waned for more than a decade, as it made its way

through various studies, so it probably helps to have a refresher on how the lens works:



The RxLAL is a three-piece, foldable lens with a squared posterior optic edge; it's made out of "photo-reactive silicone." The last part of the description is key to the lens's unique operation: When it undergoes selective exposure to UV light from RxSight's proprietary Light Delivery Device, exposure produces modifications in the lens curvature that result in spherical and/or spherocylindrical power changes postoperatively as the lens sits in the patient's eye. When the

refraction is where the patient wants it, the surgeon then uses the Light Delivery Device to perform a "lock-in" exposure to the light energy which stabilizes the final lens power.

Sioux Falls, South Dakota, surgeon Vance Thompson, who participated in the study, explains the adjustment and lock-in process further. After the UV light spatially polymerizes the photoreactive silicone, over the next two days, through the process of diffusion the lens changes shape, he says. "So, if you want an increase in curvature, you illuminate the central portion of the lens, polymerizing more of the material," he explains. "Then, there will be an increase in thickness in that area. It does this very specifically, with very specific mathematics. If you want to take away power, you would expose the peripheral part of the optic, and the unpolymerized material would diffuse to that area. This causes an increase in the peripheral curvature and takes away power from the optic. This can be done in a toric fashion, too—basically in whatever pattern you can describe mathematically. You have your shape change after two days, at which point you can schedule patients



MAKE XIIDRA YOUR FÜRST CHOICE

When artificial tears aren't enough, consider prescribing Xiidra for symptomatic Dry Eye patients.

Proven to treat the signs of inferior corneal staining in 12 weeks and symptoms of eye dryness in 12, 6, and as little as 2.

Xiidra helped provide symptom relief from eye dryness in some patients at week 2—and a measurable reduction in signs of inferior corneal staining in just 12 weeks. Consider Xiidra to help your Dry Eye patients find the relief they've been waiting for.

Check it out at Xiidra-ECP.com

Four randomized, double-masked, 12-week trials evaluated the efficacy and safety of Xiidra versus vehicle as assessed by improvement in the signs (measured by Inferior Corneal Staining Score) and symptoms (measured by Eye Dryness Score) of Dry Eye Disease (N=2133).

Indication

Xiidra® (lifitegrast ophthalmic solution) 5% is indicated for the treatment of signs and symptoms of dry eye disease (DED).

Important Safety Information

In clinical trials, the most common adverse reactions reported in 5-25% of patients were instillation site irritation, dysgeusia and reduced visual acuity. Other adverse reactions reported in 1% to 5% of the patients were blurred vision, conjunctival hyperemia, eye irritation, headache, increased lacrimation, eye discharge, eye discomfort, eye pruritus and sinusitis.

To avoid the potential for eye injury or contamination of the solution, patients should not touch the tip of the single-use container to their eye or to any surface.

Contact lenses should be removed prior to the administration of Xiidra and may be reinserted 15 minutes following administration.

Safety and efficacy in pediatric patients below the age of 17 years have not been established.

For additional safety information, see accompanying Brief Summary of Safety Information and Full Prescribing Information on Xiidra-ECP.com.



BRIEF SUMMARY:

Consult the Full Prescribing Information for complete product information.

INDICATIONS AND USAGE

Xiidra® (lifitegrast ophthalmic solution) 5% is indicated for the treatment of the signs and symptoms of dry eye disease (DED).

DOSAGE AND ADMINISTRATION

Instill one drop of Xiidra twice daily (approximately 12 hours apart) into each eye using a single use container. Discard the single use container immediately after using in each eye. Contact lenses should be removed prior to the administration of Xiidra and may be reinserted 15 minutes following administration.

ADVERSE REACTIONS

Clinical Trials Experience

Because clinical studies are conducted under widely varying conditions, adverse reaction rates observed in clinical studies of a drug cannot be directly compared to rates in the clinical trials of another drug and may not reflect the rates observed in practice. In five clinical studies of dry eye disease conducted with lifitegrast ophthalmic solution, 1401 patients received at least 1 dose of lifitegrast (1287 of which received lifitegrast 5%). The majority of patients (84%) had ≤ 3 months of treatment exposure. 170 patients were exposed to lifitegrast for approximately 12 months. The majority of the treated patients were female (77%). The most common adverse reactions reported in 5-25 % of patients were instillation site irritation, dysgeusia and reduced visual acuity. Other adverse reactions reported in 1% to 5% of the patients were blurred vision, conjunctival hyperemia, eye irritation, headache, increased lacrimation, eye discharge, eye discomfort, eye pruritus and sinusitis.

USE IN SPECIFIC POPULATIONS

Pregnancy

There are no available data on Xiidra use in pregnant women to inform any drug associated risks. Intravenous (IV) administration of lifitegrast to pregnant rats, from pre-mating through gestation day 17, did not produce teratogenicity at clinically relevant systemic exposures. Intravenous administration of lifitegrast to pregnant rabbits during organogenesis produced an increased incidence of omphalocele at the lowest dose tested, 3 mg/kg/day (400-fold the human plasma exposure at the recommended human ophthalmic dose [RHOD], based on the area under the curve [AUC] level). Since human systemic exposure to lifitegrast following ocular administration of Xiidra at the RHOD is low, the applicability of animal findings to the risk of Xiidra use in humans during pregnancy is unclear.

Animal Data

Lifitegrast administered daily by intravenous (IV) injection to rats, from pre-mating through gestation day 17, caused an increase in mean preimplantation loss and an increased incidence of several minor skeletal anomalies at 30 mg /kg /day, representing 5,400-fold the human plasma exposure at the RHOD of Xiidra, based on AUC. No teratogenicity was observed in the rat at 10 mg /kg /day (460-fold the human plasma exposure at the RHOD, based on AUC). In the rabbit, an increased incidence of omphalocele was observed at the lowest dose tested, 3 mg /kg /day (400-fold the human plasma exposure at the RHOD, based on AUC), when administered by IV injection daily from gestation days 7 through 19. A fetal No Observed Adverse Effect Level (NOAEL) was not identified in the rabbit.

Lactation

There are no data on the presence of lifitegrast in human milk, the effects on the breastfed infant, or the effects on milk production. However, systemic exposure to lifitegrast from ocular administration is low. The developmental and health benefits of breastfeeding should be considered, along with the mother's clinical need for Xiidra and any potential adverse effects on the breastfed child from Xiidra.

Pediatric Use

Safety and efficacy in pediatric patients below the age of 17 years have not been established.

Geriatric Use

No overall differences in safety or effectiveness have been observed between elderly and younger adult patients.

NONCLINICAL TOXICOLOGY

Carcinogenesis, Mutagenesis, Impairment of Fertility

Carcinogenesis: Animal studies have not been conducted to determine the carcinogenic potential of lifitegrast.

Mutagenesis: Lifitegrast was not mutagenic in the *in vitro* Ames assay. Lifitegrast was not clastogenic in the *in vivo* mouse micronucleus assay. In an *in vitro* chromosomal aberration assay using mammalian cells (Chinese hamster ovary cells), lifitegrast was positive at the highest concentration tested, without metabolic activation.

Impairment of fertility: Lifitegrast administered at intravenous (IV) doses of up to 30 mg/kg/day (5400-fold the human plasma exposure at the recommended human ophthalmic dose (RHOD) of lifitegrast ophthalmic solution, 5%) had no effect on fertility and reproductive performance in male and female treated rats.



Manufactured for: Shire US Inc., 300 Shire Way, Lexington, MA 02421.

For more information, go to www.Xiidra.com or call 1-800-828-2088.

Marks designated ® and ™ are owned by Shire or an affiliated company.

©2016 Shire US Inc.

US Patents: 8367701; 9353088; 7314938; 7745460; 7790743; 7928122; 9216174; 8168655; 8084047; 8592450; 9085553; 8927574; 9447077; 9353088 and pending patent applications.

Last Modified: 12/2016 S26218

REVIEW | Refractive/Cataract Rundown

for the lock-in, which we did at three days postop in the clinical trial. At that three-day postop point, you can do the lock-in or another adjustment, if necessary [two adjustments were allowed in the trial]. The lock-in step involves illuminating the entire lens. After the lock-in, the whole lens is polymerized.”

To decrease the chances of ambient UV light affecting the lens before the lock-in step, the protocol requires the patients to wear UV-blocking glasses, mostly while outdoors. “We had zero issues with patients complying with that requirement,” Dr. Thompson says. “When you tell a patient that, for the first time ever, we can customize the implant in his eye to his visual needs, but in order to do that we need a little bit of healing, and a little bit of light adjustment until we fully lock in the lens, and he needs to protect his eyes from the sun, the patient usually says that it’s no problem.”

Lens Performance

In the FDA study of the lens, 390 eyes were implanted with the RxLAL, while 195 received a traditional monofocal lens and acted as a control group. The RxLAL group was actually targeted for slight hyperopia.

“The FDA wanted to see if the technology actually worked,” says Kevin Miller, MD, professor and chair of ophthalmology at UCLA’s David Geffen School of Medicine. Dr. Miller also participated in the RxLAL trial. “In the clinical trial, we were forced to leave the patients with some hyperopia—+0.5 or +0.75 D or so—because it’s easier to take them in the myopic direction than the hyperopic direction. So, the patient’s impression of his vision in the first three weeks would be, ‘It’s OK, but it’s not great.’ Then, when we’d do the first adjustment, three or five days later they’d say, ‘Whoa! My vision’s so much better!’”

Citing the study, Dr. Thompson

says that 99.7 percent of the patients saw 20/40 or better uncorrected postop, and 91.6 percent were 20/25 without glasses. “Getting 91.6 percent of patients to 20/25 or better has never happened before in cataract surgery in any FDA-monitored study,” Dr. Thompson avers. “These are LASIK-like results.

“After the adjustment, 92 percent of the patients were within 0.5 D of intended, and 99.5 percent were within 1 D,” Dr. Thompson continues. “On average, there were 1.65 adjustments required. If I wanted to perform postop PRK or LASIK, in comparison, I’d need to wait three months for the wound to stabilize. With this, since we’re adjusting the power of the optic, we can start at three weeks postop.”

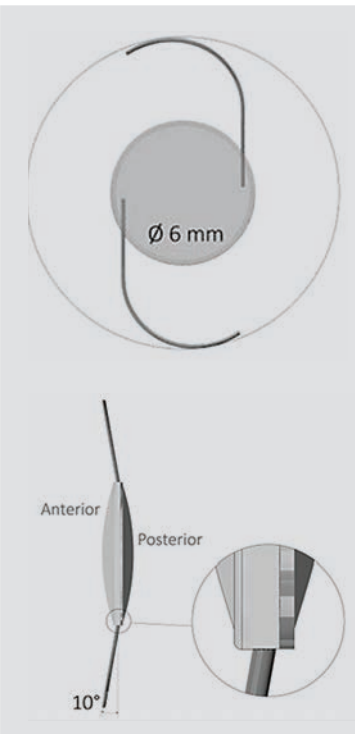
In terms of the toric adjustment, 82 percent of subjects had no more than 0.5 D of astigmatism at six months, and 98.5 percent had no more than 1 D. There were zero postop rotations due to axis misalignment. “It’s ex-

tremely stable,” Dr. Thompson says. “Even though other lenses can rotate in the early postop period, they’re typically stable by three weeks due to capsular contraction. But with this, we’re not adjusting it until the three-week mark, so it’s not only very stable, it’s locked in [place].”

The lens has some potential pitfalls, as well, though. “The primary problem we had in the study was getting patients’ pupils large enough to do the light adjustments,” recalls Dr. Miller. “You have to be able to see the full 6-mm diameter of the lens in order to do them. That means the patient has to dilate to a minimum of 6.5 to 7 mm. But some patients can’t dilate very well—they only dilate to about 5 mm. So, for them, if there’s a 6-mm lens in there, there will be a portion of the lens that you can’t treat; some of the molecules are hiding out in the periphery and you can’t treat them.

(Continued on page 66)

Light-Adjustable Lens Specifications¹



The diagram illustrates the lens structure. The top part shows a circular lens with a diameter of 6 mm. The bottom part shows a cross-section of the lens with the anterior and posterior surfaces labeled. The haptic angle is indicated as 10 degrees.

Lens Optic

- Material: Photoreactive UV-absorbing silicone
- Light transmission: UV cut-off at 10 percent T 385 ± 2 nm for all lens powers
- Index of refraction: 1.43
- Power: +10 to +15.0 D and +25.0 to +30.0 D in 1-D increments; +16.0 to +24.0 D in 0.5-D increments
- Optic type: Biconvex
- Optic edge: Square on posterior surface and round on anterior surface
- Overall diameter: 13 mm
- Optic diameter: 6 mm

Haptics

- Configuration: Modified C
- Material: Blue core polymethylmethacrylate (PMMA) monofilament
- Haptic angle: 10 degrees

IOL Power Formulas: 10 Questions Answered

By Christopher Kent, Senior Editor

Understanding how formulas calculate the optimum lens power can help ensure good outcomes.

Few subjects in the field of ophthalmology are as complex as the formulas surgeons use to predict the best intraocular lens power for a given patient. As at least one expert has noted, creating and improving upon these formulas is a job best managed with the help of physicists, mathematicians and optical engineers. Nevertheless, these formulas are an essential part of performing cataract surgery.

Understandably, most surgeons like being able to simply plug numbers into a machine or an online calculator that does the work and produces an answer, without the surgeon having to worry about the details. Nevertheless, the better we understand something, the more likely we are to use it to its best advantage. With that in mind, four experts in this area, all known for their work developing IOL power formulas, share their answers to 10 questions a clinician might ask about these formulas, covering issues such as how they work; how best to use them; and what the future may hold.

1 *Is it so bad to just keep using the older formulas?*

Most surgeons today are aware that the more recent formulas are capable of producing more accurate power predictions than the older formulas,

yet many surgeons continue to use the older ones. To understand how much difference switching to a more advanced formula can make, it's important to look at outcomes.

Warren E. Hill, MD, medical director of East Valley Ophthalmology in Mesa, Arizona, and creator of the Hill-RBF formula, is in a unique position to compare the outcomes of surgeons using old or new formulas, since he's reviewed data from more than a quarter-million surgeries (mostly calculated using the older formulas). "After the removal of outliers, and following lens-constant optimization, the average ophthalmologist gets about 78 percent of patients within ± 0.5 D of the target refraction," he says. "Six percent of surgeons are at 84 percent or better. Fewer than 1 percent of surgeons in that database are at 92 percent or better. Different studies around the world have found rates ranging from 55 to 80 percent. So 71 to 80 percent is sort of the acceptable range. That's what most people achieve using the older formulas.

"Now, as we begin to see the newer biometers and newer formulas, like the Barrett and Hill-RBF, being used by surgeons who also take their time making the measurements and then apply validation criteria, that's changing," he continues. "We're starting

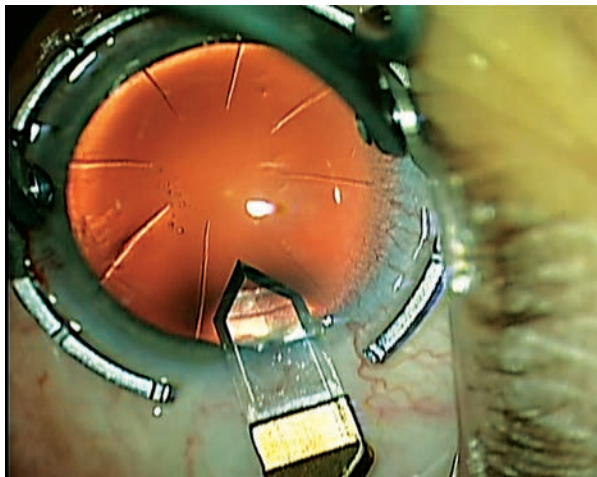
to see physician databases in the 90-percent range. Two or three years ago, only 1 or 2 percent of surgeons achieved that; now everybody can potentially reach that level.

“This is a huge sea change in the accuracy of lens-power calculation,” he notes. “We’re all creatures of habit, but fortunately, surgeons are beginning to switch to the newer formulas—what we jokingly refer to as ‘formulas from this century.’ An 80-percent ± 0.50 D accuracy level is acceptable, but 90-percent ± 0.50 D accuracy is now achievable. We should always strive for what’s achievable.”

Graham D. Barrett, MD, a clinical professor of ophthalmology at the Lions Eye Institute and the University of Western Australia, consultant to the ophthalmology department at Sir Charles Gardiner Hospital, in Perth, Australia, and creator of the Barrett Universal II formula, agrees. “There’s good data to show that the latest generation of formulae, whether it’s mine, the Olsen, Hill-RBF or Holladay II, outperform the earlier generation of formulae,” he says. “Surgeons who are still using the earlier-generation formulae can certainly do better for their patients.”

2 *Should I plug my numbers into multiple formulas and compare the results?*

This question is one of the few that evokes a range of opinions from the experts. Douglas D. Koch, MD, professor and Allen, Mosbacher, and Law Chair in Ophthalmology at the Cullen Eye Institute, Baylor College of Medicine in Houston, employs multiple formulas. “Today we have some formulas that often do much better on all kinds of eyes than in the past,” he says. “That’s a really fantastic advance for us. They’ve all raised the bar and



Uday Deygan, MD, FACS

Post-refractive-surgery eyes are particularly challenging in terms of predicting ideal IOL power because the alterations to the cornea created by the refractive surgery disrupt the anterior corneal curvature and invalidate correlations that would otherwise help the surgeon estimate posterior corneal curvature and effective lens position.

improved our outcomes. However, we still don’t have one formula that we can always rely upon in every case. You can choose to use just one formula, like the Barrett or Hill formulas, and you’ll get great results. But at least for the time being, there are certain eyes that remain problematic, even using the most advanced formulas. And the predictions made by those formulas can still be off, even in ‘normal’ eyes.”

Dr. Koch says that’s why he still plugs his numbers into multiple formulas, even in unexceptional eyes. “I’ve been burned by all of the formulas, in terms of errors,” he says. “Postoperative surprises are not the exclusive territory of one formula; I’ve seen it with every single one of them. So in routine eyes I typically run the Holladay I, the Barrett and the Hill. If one of them differs from the others, I tend to lean toward the other two in my IOL selection. Some may think this is no longer necessary, but we keep track of our surgical outcomes: We’re getting 90 percent of our patients within ± 0.5 D.”

Dr. Barrett says he doesn’t believe that averaging the predictions of multiple formulas is necessary anymore. “It may be worth looking at two formu-

las that you have a lot of confidence in, but there’s really no reason to plug your numbers into four or five formulas and try to average them,” he says.

He notes, however, that he sometimes finds it useful to compare the predictions of his own formula and the Hill-RBF formula. “Mine is basically a theoretical, paraxial ray-tracing formula—although there is an element of data-driven enhancement as well, so in that sense it’s a hybrid,” he explains. “Warren’s formula, the Hill-RBF, is purely data-driven, using artificial intelligence. These two formulas tackle the same problem from very different

directions. So it’s quite nice to compare those two distinctive methodologies when you look at a particular patient. It’s fascinating how often they come up with a similar prediction, when they couldn’t be more different in how they go about doing the job.”

Dr. Hill agrees that if you’re determined to compare two formulas in a given situation, the Barrett Universal II and Hill-RBF might be good choices. “That’s true for several reasons,” he notes. “First, they’re both current. Second, they’re far more sophisticated than anything that’s come before. Third, they use completely different premises. Dr. Barrett’s formula is based on Gaussian optics; the predictions made by Hill-RBF are derived using artificial intelligence. What’s remarkable is that both of these methods often give recommendations that are within 0.25 D of each other. What this suggests is a convergence of technologies. We’re arriving at something that’s very close to the right answer using completely different approaches.”

Dr. Hill adds an important point regarding the use of multiple formulas for comparison. “If you’re in a situation in which every formula might run



into trouble and you want to compare the results, at least make sure the formulas you're using are well-suited to the task," he says. "For example, take the extreme axial myope. There are three formulas that do very well with those eyes: the Wang-Koch modification of Holladay I; the Barrett Universal II formula; and the expanded version of Hill-RBF. Comparing the predictions made by those three formulas makes sense because all three of them are uniquely suited to this particular task. You wouldn't use an uncorrected version of SRK/T with an extreme axial myope—or an extreme hyperope—because it doesn't do a good job in those situations. If you add formulas that don't do well into the mix, all you're doing is adding mathematical noise."

3 *How are the newer formulas different from each other?*

With an ever-increasing number of formulas appearing over time, it's become common practice to categorize them by order of appearance: first-generation; second-generation; and so forth. However, Dr. Koch says he believes this isn't very useful. "I think we should label formulas in terms of how they calculate the IOL power," he says. "For example, there are regression formulas, such as the SRK/T. Then there are vergence formulas, based on regular optics. The most commonly used vergence formulas include the two Holladay formulas; the Hoffer Q; the SRK/T; the Haigis; and the Barrett formulas. That group can be further classified by the number of variables they incorporate. The ones that most doctors use—the Holladay I, SRK/T and Hoffer Q—only use two variables. The Haigis uses three variables. Barrett uses five, and the Holladay II uses seven.

"A third category is formulas based on artificial intelligence," he continues. "Currently, the only formula in that category is the Hill-RBF, which

is based on big data. Finally, there are formulas based on ray-tracing. These include the Olsen formula and one from Germany called Okulix, which has not been as well distributed. Other ray-tracing-based formulas exist, but to the best of my knowledge they're not commercially available.


"If you're going to switch to a more advanced formula, make sure you have a device that can take advantage of it."
 — Douglas Koch, MD


"The advantage of a ray-tracing formula over a standard vergence formula is that it takes into account the asphericities and other aberrations of the cornea and the lens implant," he explains. "Vergence formulas use an average value for those factors. As a result, a ray-tracing formula will have some advantages in terms of understanding the power of the IOL and cornea that you're not going to get with a vergence formula. However, ray-tracing formulas have not achieved their full potential because they still depend on an accurate estimate of effective lens position. Until we do a better job of knowing where the implant is going to sit in the eye, we're not going to achieve better than 85- or 90-percent accuracy.

"Despite that limitation, the ray-tracing approach is very promising for the future," he concludes. "That's what I believe we'll end up using in the long run. However, at their current level of development those formulas are not outperforming the standard ones, so people don't have a reason to switch.

In fact, a recent article in *Ophthalmology* showed that the Barrett formula, on average, ends up producing the best outcomes."¹

Dr. Hill explains how his formula, which bases its predictions on the analysis of hundreds of thousands of actual outcomes, differs from the alternatives. "With the theoretical formulas, you enter your numbers and get a power prediction," he notes. "Then, you implant the lens and hope for the best. My method is different. First of all, it's not actually a formula; it's an artificial intelligence algorithm.

"Because it works in this way, it can generate an internal validation process based in multiple pair-wise boundary models," he continues. "Stated differently, this calculation method is self-validating; you not only get an IOL power, you also get an indication of the calculation's accuracy. Using boundary models, the Hill-RBF can estimate the likelihood of ending up within ± 0.5 D of your target. (*See examples, p. 20 and 21.*)

"For example, if you go to the online calculator at RBFCalculator.com and put in a sample case, you'll either get an 'in bounds' or 'out of bounds' indication," he explains. "'Out of bounds' means that, at present, the artificial intelligence database doesn't have enough data paralleling your specific case to support the calculation at a 90-percent accuracy level. On the other hand, if you get an 'in bounds' indication, that means the system has enough data and experience to support a 90-percent ± 0.50 D level of accuracy. It's the first time in ophthalmology that something like this has been offered." Dr. Hill notes that validating boundary models are frequently used in other fields. "We're combining ophthalmology with mathematical tools that are commonly used in engineering," he explains.

Dr. Hill says it took seven years to develop the Hill-RBF method in its present form. "This was a team ef-

The OCULUS Pentacam® AXL Always an Axial Length Ahead



Pre-Order Now!

The gold standard, now with axial length measurement – versatile, profitable, indispensable!

Once again, the Pentacam® defines the “measure of all things.” The AXL version, featuring integrated optical biometry, makes it a comprehensive, indispensable instrument for cataract surgery. As a full-scale system, the Pentacam® AXL also provides for safe and swift IOL calculation – even in difficult cases.

Visit www.pentacam.com for more information.

    Follow us!

Tollfree 888-519-5375

sales@oculususa.com www.oculususa.com

 OCULUS®

fort involving 39 investigators in 19 countries, with Doug Koch, MD, and Li Wang, MD, PhD, at Baylor University; Adi Abulafia, MD, in Tel Aviv, Israel; David Goldblum, MD, at the University of Basel in Switzerland; and the engineers and mathematicians at MathWorks as our core investigators,” he says. “The engineers and mathematicians at MathWorks did the heavy lifting for algorithm development.”

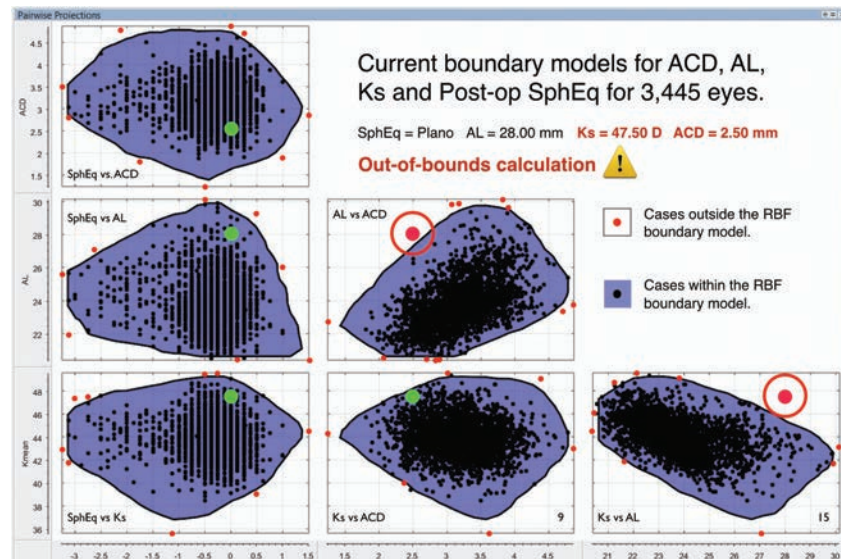
4 *If I want to switch to a better formula, how do I choose?*

Dr. Hill says the first thing to do when choosing a new formula is to listen to people who have experience in this area. “Surgeons shouldn’t make these kinds of decisions in a vacuum,” he says. “Go to meetings. Take CME. Join the ASCRS discussion group—a very good way to stay current in this area. Reading the literature is helpful too, but be careful: Some of what’s been published isn’t grounded in good data. Studies need to have a large, clean database, with standards for refraction and validation criteria applied to the measurements.”

Dr. Barrett points out that several recently published papers have compared almost every formula that’s out there in a comprehensive fashion. “Doctors can discern from the published data which formulae tend to be most accurate,” he says. “As you might expect, I prefer to use my own, but it’s up to the ophthalmologist to be familiar with what’s been published and combine that with his or her own experience to make a decision.”

Dr. Hill adds that if a surgeon wants to use only one formula, he recommends the Barrett Universal II. “In my opinion, it’s the best theoretical formula currently available,” he says. “I believe it’s the standard.”

Dr. Koch raises an important practical point. “If you’re going to switch to a more advanced formula, the first thing you need to do is make sure you have a device that can take advantage of it,”



The Hill-RBF method is an artificial intelligence algorithm that bases its predictions on large amounts of previous surgical data. It’s self-validating, using six data pairings to rate the probable accuracy of its lens-power prediction. The label “in bounds” means its database has sufficient data to confirm that its prediction is likely to be accurate; the label “out of bounds” indicates that it cannot make that guarantee. (Continued on facing page)

he says. “The IOLMaster 500 doesn’t measure lens thickness, for example, so you can’t avail yourself of the more sophisticated aspects of the Barrett or Olsen formulas. You can use the Hill-RBF formula, because it doesn’t require lens thickness. But if you want to make the best use of the Barrett and Olsen formulas you need to upgrade to either the Lenstar or the new swept-source devices: the IOLMaster 700, Tomey’s OA-2000 optical biometer, the Argos from Movu, or, in the future, the new Lenstar. All of these devices are very fast and efficient, and they measure lens thickness in addition to the other parameters.

“This practical concern means that moving to a better formula is a two-part process,” he continues. “You also need to move forward with the devices you’re using. Of course, doing so will have other benefits as well: By transitioning from the IOLMaster 500 to one of the newer devices, for example, you’re going to increase the accuracy of your corneal power measurements, particularly with regard to astigmatism. That will help to improve your

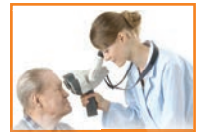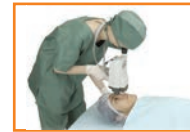selection of the appropriate power and result in better alignment of toric IOLs. The newest generation swept-source OCT devices also do a pretty remarkable job of penetrating through dense cataracts. That means you won’t need to rely as much on ultrasound when dealing with a posterior subcapsular or dense cortical cataract. That’s a double plus. Using a more advanced instrument can make a big difference in outcomes.”

5 *What’s the best way to deal with very short or long eyes?*

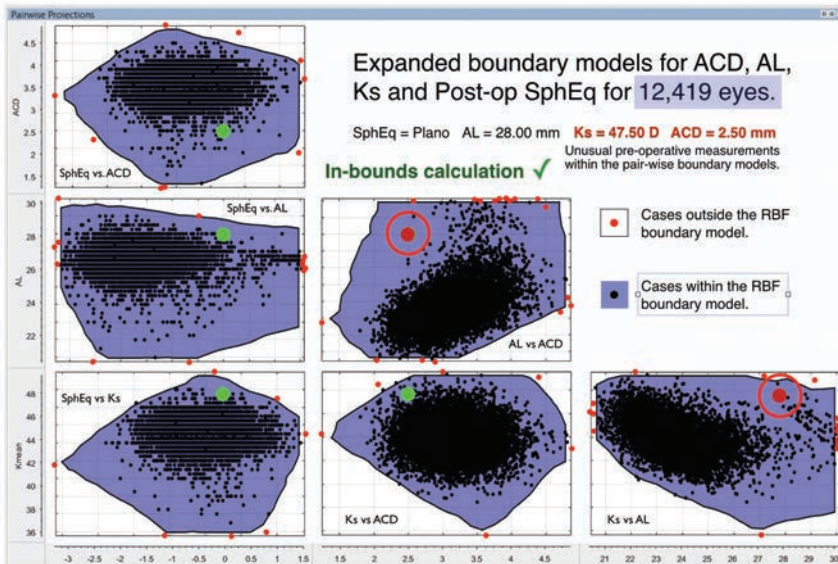
Unusual eyes are still problematic when it comes to predicting the best IOL power, and extreme axial lengths are among the more challenging cases.

“In the past it was common practice to use specific formulae for different axial lengths, because some formulae seemed to produce better outcomes in these subgroups,” says Dr. Barrett. “And it’s not just axial length that can challenge formulae; a very flat or steep K can be a source of prediction error if a formula is not really designed to manage those situations. However,

Precise Measurements
Anytime, Anywhere



Marzen E. Hill, MD



Over time, as the data bank grows larger, cases that would have been “out of bounds” become “in bounds.” For the case shown above, when the database contains 3,445 eyes (facing page), two of the six data pairs fall out of bounds (circled red dots). But when more eyes are added to the database (above), all six data pairs now fall within the boundaries covered by the larger database, meaning the new prediction is very likely to be accurate.

most of the latest-generation formulae, which some refer to as fourth- or fifth-generation, perform quite uniformly, even when dealing with short or long eyes or flat or steep Ks. As a result, I don’t believe the practice of using a different formula for different types of eyes is as prevalent today. Most surgeons select their preferred up-to-date formula and are quite happy to use it throughout the full range of axial lengths.”

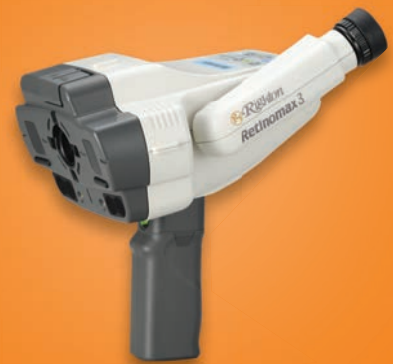However, Dr. Barrett admits that even the best formula can run into trouble with very short eyes. “There are reasons for this,” he points out. “For one thing, small errors in measurement have a much greater impact in short eyes. Also, we still don’t know for certain the exact parameters of a given manufactured lens, and small differences have a greater impact in a short eye because the lens has a much higher power than in an average or long eye.”

Dr. Koch agrees. “Short eyes still remain a major source of difficulty,” he says. “These eyes are very susceptible to small variations in effective lens po-

sition, and none of our formulas have enough data to do a great job of predicting this. In fact, in my experience, these eyes produce the least accurate outcomes, regardless of which formula you use. We’ve actually found the Holladay I to be just as good in these eyes as any of the so-called advanced formulas.

“The typical error that I see in a short eye is an unexpectedly myopic outcome,” he continues. “The result could be off in either direction, but the big surprises are usually on the myopic side, where the IOL ends up sitting more anteriorly than anticipated. In fact, this outcome occurs primarily—though not predictably—in those eyes that have a shallow anterior chamber preoperatively. One issue is that we still don’t know whether the anterior chamber shallowness is an anatomical feature of the eye, or whether it has something to do with increased lens thickness that has occurred with aging and the development of the cataract. All of the formulas try to figure this out; particularly the Holladay II, Barrett and Olsen. But errors are com-

THE SERIES 3
HAND-HELD AUTOREFRACTOR
RETINOMAX
Righton



- ✓ Fast
- ✓ Lightweight
- ✓ Ergonomically Balanced
- NEW Auto Quick Measurement
- NEW Auto Pupil Measurement
- ✓ Small Pupil 2.3mm Measurement Acquisition
- ✓ Flexible Positioning—Sitting, Standing, Supine

S4OPTIK

www.s4optik.com | 888-224-6012

Sensible equipment. Well made, well priced.
For today’s modern office.

The Importance of Correcting Astigmatism

Graham D. Barrett, MD, a clinical professor of ophthalmology at the Lions Eye Institute and the University of Western Australia, and creator of the Barrett Universal II formula, says that in today's world, it's preferable not to leave patients with significant residual astigmatism. "Here in Australia about 50 percent of the lenses we implant are toric IOLs," he notes. "In my own practice, about 80 percent of the lenses I implant are torics. It's a paradigm shift. Just as you care about ensuring that patients have a spherical outcome that's as close to plano as possible, you also want your patients to end up with less than 0.5 D of astigmatism. That's the threshold at which astigmatism becomes symptomatic. If you accept this premise, then using toric IOLs will be required in about 80 percent of patients undergoing cataract surgery."

Dr. Barrett notes that while this philosophy is fairly well-accepted in Australia, it has stalled somewhat in Europe and the United States. "That's partly because of cost issues," he says. "Here in Australia, toric lenses are reimbursed by private insurance, which isn't always true in other countries. Also, in the United States,

T2-equivalent toric lenses—lenses that can address less than 1 D of astigmatism—are not yet approved. In the U.S., surgeons still utilize limbal relaxing incisions for those low levels of astigmatism.

"In reality," he continues, "low-level toric IOLs are a much more effective way to deal with low levels of astigmatism—although using those lenses means that your measurements and predictions and formulae have to be quite sophisticated."

Jack T. Holladay, MD, MSEE, FACS, the developer of the Holladay I, II and Refractive formulas, agrees that astigmatism needs to be addressed. "Seventy-two percent of eyes having cataract surgery have 0.5 D or more corneal astigmatism and would benefit from a toric IOL," he notes. "The toric calculators we recommend are the AMO online calculator, the open-access toric calculator at hicssoap.com under the Calculator tab, and the Holladay IOL Consultant software. These are based on vergence formulas and have equally good toric results for long or short eyes, and for low or high IOL powers."

—CK

mon. So in that kind of situation, I believe it's still good to plug your numbers into more than one formula and compare the results."

Dr. Koch says that when he's working with a short eye, he plugs the numbers into five different formulas. "I use the Holladay I, Holladay II, Barrett, Olsen and Hill formulas," he says. "I look at all of their predictions and select a median value among those five."

Long eyes can also be challenging. "In terms of long eyes, results have vastly improved with recent advances, beginning with the Wang-Koch formula, and, more recently, Hill and Barrett," notes Dr. Koch. "Studies have shown mixed outcomes with regard to which of the three is better in this situation. Fram and Masket found the Wang-Koch formula to be more accurate;² it is a bit more aggressive in that it's less likely to leave eyes hyperopic, but it's a bit more likely to produce mild postoperative myopia. It is still our go-to."

The problem appears to have a lot to do with biometry tending to measure the axial length as longer than it

actually is in these eyes. Jack T. Holladay, MD, MSEE, FACS, the developer of the Holladay I, II and Refractive formulas, notes that there's a tendency to end up with a hyperopic surprise when dealing with eyes deeper than 24 mm. "Factors such as optical biometry using an average index of refraction for the entire eye, or the shape of the IOL, still can't account for the eye being measured as longer than it actually is," he says. "So far, no one has been able to explain this error, but whatever the cause is, we can compensate for it by using regressions, fudge factors and adjustments to our formulas."

"Doug Koch and Li Wang were the first to report the axial length measurement problem in long eyes," he continues. "They published a study presenting two regressions [to help compensate for this], referred to as the '1-center' and '2-center' regressions.³ They recommend using the 1-center regression, which is the more aggressive of the two."

"We recently published an article in *Ophthalmology* demonstrating that using this regression produces, on av-

erage, a myopic error, and confirming that it is rather aggressive,"⁴ he notes. "I then used the 14,000 cases in the study to generate nonlinear equations for both the Holladay I and II formulas in long eyes. "The results are less aggressive than the 1-center study, producing equal myopic and hyperopic errors. The regression begins at 24 mm—the arithmetic mean of the axial lengths—and has no upper limit. Therefore, in long eyes, we recommend using the Holladay II formula with the Holladay nonlinear regression. This combination can be found, open-access, at hicssoap.com under the Calculator tab. It's also part of the Holladay IOL Consultant software and is being implemented in the IOL-Master."

"Eventually," he concludes, "this type of adjustment will evolve to compensate for variations in all of the variables—axial length, K-readings, anterior chamber depth, lens thickness and white-to-white length—to further reduce outcome errors."

Dr. Hill adds that there's a lot of "conventional wisdom" that comes

with the older formulas regarding which one should be used with a given type of eye—much of which is incorrect. “For example, many surgeons use the Hoffer Q formula for short eyes, when actually Holladay I may do a better job,” he says. “For some reason it got stuck in everybody’s head that you’re supposed to use Hoffer Q. In any case, the newer calculation methods like Barrett and Hill-RBF do much better in those eyes.”

6 What’s the best way to manage post-refractive-surgery eyes?

“The post-refractive-surgery eye remains a disappointing proposition, in the sense that we’re still only getting 70 to 75 percent of these eyes within ± 0.5 D,” says Dr. Koch. “I think that will improve in the future as we see more patients who’ve had more uniform ablations, making it a little easier to measure corneal power.”

Why are post-refractive surgery eyes so problematic? Dr. Koch notes three challenges. “The first challenge is knowing what anterior corneal curvature to select, due to variability in this dimension,” he says. “Second, it’s very difficult to accurately measure posterior corneal curvature in these eyes. In a normal eye you can fairly accurately predict the posterior corneal curvature from the anterior curvature, but those assumptions break down after you change the anterior corneal curvature with refractive surgery. That same caveat also applies to using a toric lens in a post-LASIK eye. Finally, the effective lens position calculation is more challenging, since most formulas use corneal power in their equations to estimate ELP.”

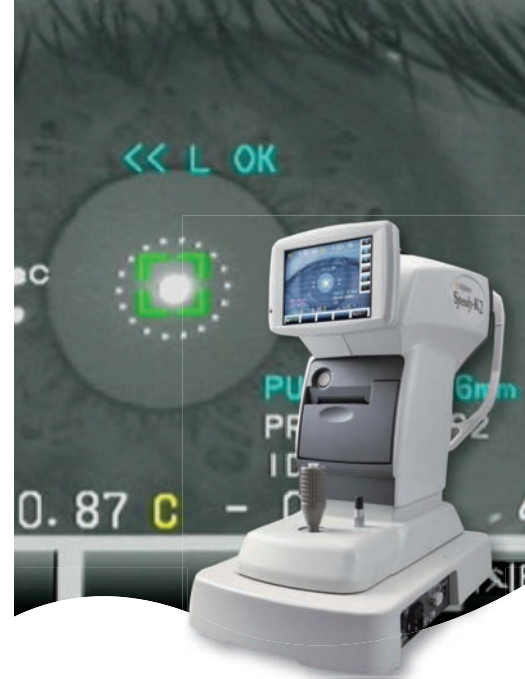Dr. Holladay agrees that the problem is not the IOL formula itself, but the axial length and corneal power measurements that are being used, as well as the estimate of the effective lens position. “As a result, there are three factors that make lens-power

prediction in post-refractive-surgery eyes challenging,” he says. “First of all, these are usually long eyes, so the axial length must be adjusted using a regression formula. Second, the cornea has been altered, so standard keratometry is no longer accurate. Third, the current K can’t be used to estimate the effective lens position. Instead, we need to use the K that was measured before the cornea was altered, often referred to as the Double K method.”

Dr. Koch says that if you’re faced with a post-refractive-surgery eye, he recommends getting as many measurements as you can and using formulas found on the ASCRS website. “We like several formulas,” he notes. “We use the Masket formula if we know the change in refraction caused by the previous refractive surgery. We like the Barrett and the Haigis formulas, and we often use the RTVue OCT formula. If you have two or three formulas whose results cluster together, those are more likely to be accurate. We also use intraoperative aberrometry.” He notes, however, that despite having all of these options, he’s seen significant errors with every formula.

“When faced with eyes that have undergone prior refractive surgery, I’d recommend using the online ASCRS calculator that Doug Koch, Li Wang and I created,” says Dr. Hill. “That’s become a very popular tool for this purpose. In addition, surgeons should stay current with the literature. There have been a series of recent articles discussing how to get the best results with these eyes.”

Dr. Barrett notes that there are a multitude of formulas that can be applied with these patients. “Once again, you have to look at the published data,” he says. “Some formulae do better than others with these eyes. What a lot of people do is look at the online ASCRS calculator, because the authors of that—Doug Koch, Li Wang and Warren Hill—critically examine the formulae they include and



THE NEW
AUTO-REFRACTOR KERATOMETER
SPEEDY-K2
Righton

- ✓ Extremely Fast with Accurate Measurements
- ✓ Variable Target Illumination with Automatic Dimming for Small Pupil
- ✓ Central and Peripheral Keratometry (3.2 and 6.8)
- ✓ 5.7” Touch Panel with 45° Tilt Function
- ✓ Cornea Diameter Measurement (0-16mm)
- ✓ Retro Illumination for Cataract Observation

S4OPTIK

www.s4optik.com | 888-224-6012

Sensible equipment. Well made, well priced.
For today’s modern office.

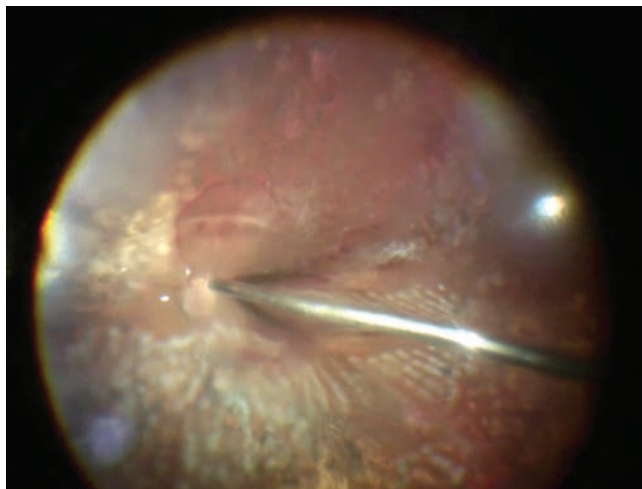
limit them to the ones that they've found provide better outcomes, so you don't have to choose between 15 or more different formulae.

"Personally, I tend to use my own formula because it can be used for myopic, hyperopic and radial keratotomy eyes," he continues. "Also, it can be used with or without the history of the change in refraction that was produced by the refractive procedure. If you do know the pre- and post-LASIK, -PRK or -RK refractions, the outcomes will tend to be even more accurate; but if you don't, the True K formula still gives you a pretty good prediction."

"The most robust method for estimating the effective corneal power is with topography/tomography where one uses thousands of points on the front and back of the cornea to estimate the ELP," says Dr. Holladay. "Our group prefers the EKR65 measurement in the Pentacam's Holladay report. This uses more than 10,000 points on the front and back of the cornea to determine the effective power over a 4.5-mm zone. Results have demonstrated a standard deviation of ± 0.56 D for LASIK and ± 0.96 D for RK. Sixty-seven percent of the cases will be within this tolerance."

Dr. Holladay notes that different post-refractive formulas take the corneal refractive error caused by various amounts of treatment and generate a formula to compensate for that error. "The results will depend on the specific laser used for the treatment, since that will affect the postoperative shape of the cornea," he points out. "Those formulas can work well for a specific laser."

Dr. Holladay adds that using the K that was measured before the cornea was altered and the refractive change



Eyes containing silicone oil are problematic because the oil has a different refractive index that must be accounted for in the power calculation—unless the surgeon is certain that the silicone oil will be removed soon after the cataract surgery.

Rachael Trussart, MD, FRCS(C)

from the procedure, often referred to as the historical method, is still the gold standard for estimating the current corneal power. "If the pre-refractive Ks were accurate and the refractive change is stable—which is normally true for LASIK, though not for RK—then this method works well," he says. "However, if the refraction has been affected by lenticular changes caused by the cataract, it doesn't work."

7 What's the best way to manage an eye with silicone oil?

Dr. Barrett notes that predicting the correct IOL power in an eye that contains silicone oil is challenging. "The problem with optical biometry in this situation is that the refractive index is different for a lens facing a medium of silicone oil, resulting in inaccurate predictions," he says. "That makes determining the required lens power quite complex. Using a convex plano lens, in which the back surface of the lens is plano, will help because the silicone oil won't impact the calculation of required IOL power to the same extent. Unfortunately, those lenses are hard to find."

Dr. Koch suggests that when you encounter an eye with silicone oil,

the first question to ask is: Will the silicone eventually be removed? "I usually assume the patient is going to have the silicone oil removed, but I verify this with the retinal surgeon," he says. "Also, most of these eyes have limited visual potential, which must be discussed with the patient."

"Fortunately, most optical biometers measure eyes with silicone oil with minimal difficulty," he continues. "If you use ultrasound, then you have to use immersion ultrasound and segment the eye, in-

serting the refractive index for that particular silicone oil when you're calculating the axial length. Of course, if you leave the silicone oil in and put in a standard IOL, the patient is going to be very hyperopic until the silicone oil is removed. But being hyperopic for a brief period will be worth it for the patient in the long run."

"Luckily," notes Dr. Barrett, "encountering an eye with silicone oil is not a common occurrence, and removing the oil prior to cataract surgery will avoid the complexities of formulae prediction."

8 Does using a toric lens alter the spherical correction?

"An astigmatism correction [in the IOL] shouldn't affect the spherical calculation significantly," says Dr. Barrett. "In theory this could be an issue, because an astigmatism correction could potentially alter the lens structure and the principal planes, impacting the spherical correction. However, the manufacturer can compensate for that. The more sophisticated companies utilize optic designs that ensure that the principal planes of the lens remain equivalent for a given spherical-equivalent lens power, regardless



FOR YOUR CATARACT SURGERY PATIENTS

RING IN THE NEW YEAR WITH BROMSITE®

Warm wishes for a happy new year from the **FIRST**
and **ONLY NSAID** indicated to prevent ocular pain
in cataract surgery patients¹

In 2018, defend against ocular pain and combat
postoperative inflammation with the penetrating power
of BromSite® formulated with DuraSite®⁰¹

Visit bromsite.com to find out more.

BromSITE®
(bromfenac ophthalmic solution) 0.075%

Formulated with **DURASITE® DELIVERY SYSTEM**

Indications and Usage

BromSite® (bromfenac ophthalmic solution) 0.075% is a nonsteroidal anti-inflammatory drug (NSAID) indicated for the treatment of postoperative inflammation and prevention of ocular pain in patients undergoing cataract surgery.

Recommended Dosing

One drop of BromSite® should be applied to the affected eye twice daily (morning and evening) 1 day prior to surgery, the day of surgery, and 14 days postsurgery.

Important Safety Information

- **Slow or Delayed Healing:** All topical nonsteroidal anti-inflammatory drugs (NSAIDs), including BromSite®, may slow or delay healing. Topical corticosteroids are also known to slow or delay healing. Concomitant use of topical NSAIDs and topical steroids may increase the potential for healing problems.
- **Potential for Cross-Sensitivity:** There is the potential for cross-sensitivity to acetylsalicylic acid, phenylacetic acid derivatives, and other NSAIDs, including BromSite®. Therefore, caution should be used when treating individuals who have previously exhibited sensitivities to these drugs.
- **Increased Bleeding Time of Ocular Tissue:** With some NSAIDs, including BromSite®, there exists the potential for increased bleeding time due to interference with platelet aggregation. There have been reports that ocularly applied NSAIDs may cause increased bleeding of ocular tissues (including hyphemas) in conjunction with ocular surgery. It is recommended that BromSite® be used with caution in patients with known bleeding tendencies or who are receiving other medications which may prolong bleeding time.
- **Keratitis and Corneal Effects:** Use of topical NSAIDs may result in keratitis. In some susceptible patients, continued use of topical NSAIDs may result in epithelial breakdown, corneal thinning, corneal erosion, corneal ulceration or corneal

perforation. Patients with evidence of corneal epithelial breakdown should immediately discontinue use of topical NSAIDs, including BromSite®, and should be closely monitored for corneal health. Patients with complicated ocular surgeries, corneal denervation, corneal epithelial defects, diabetes mellitus, ocular surface diseases (e.g., dry eye syndrome), rheumatoid arthritis, or repeat ocular surgeries within a short period of time may be at increased risk for corneal adverse events which may become sight threatening. Topical NSAIDs should be used with caution in these patients. Post-marketing experience with topical NSAIDs also suggests that use more than 24 hours prior to surgery or use beyond 14 days postsurgery may increase patient risk for the occurrence and severity of corneal adverse events.

- **Contact Lens Wear:** BromSite® should not be administered while wearing contact lenses. The preservative in BromSite®, benzalkonium chloride, may be absorbed by soft contact lenses.
- **Adverse Reactions:** The most commonly reported adverse reactions in 1% to 8% of patients were anterior chamber inflammation, headache, vitreous floaters, iritis, eye pain, and ocular hypertension.

Please see brief summary of Full Prescribing Information on the adjacent page.

NSAID=nonsteroidal anti-inflammatory drug.

Reference: 1. BromSite® [package insert]. Cranbury, NJ: Sun Pharmaceutical Industries, Inc.; 2016.

Sun Ophthalmics is a division of Sun Pharmaceutical Industries, Inc.
© 2017 Sun Pharmaceutical Industries, Inc. All rights reserved.
BromSite and DuraSite are registered trademarks of Sun
Pharma Global FZE. SUN-OPH-BRO-365 11/2017



BromSite® (bromfenac ophthalmic solution) 0.075%

Brief Summary

INDICATIONS AND USAGE

BromSite® (bromfenac ophthalmic solution) 0.075% is indicated for the treatment of postoperative inflammation and prevention of ocular pain in patients undergoing cataract surgery.

CONTRAINDICATIONS

None

WARNINGS AND PRECAUTIONS

Slow or Delayed Healing

All topical nonsteroidal anti-inflammatory drugs (NSAIDs), including BromSite® (bromfenac ophthalmic solution) 0.075%, may slow or delay healing. Topical corticosteroids are also known to slow or delay healing. Concomitant use of topical NSAIDs and topical steroids may increase the potential for healing problems.

Potential for Cross-Sensitivity

There is the potential for cross-sensitivity to acetylsalicylic acid, phenylacetic acid derivatives, and other NSAIDs, including BromSite® (bromfenac ophthalmic solution) 0.075%. Therefore, caution should be used when treating individuals who have previously exhibited sensitivities to these drugs.

Increased Bleeding Time of Ocular Tissue

With some NSAIDs, including BromSite® (bromfenac ophthalmic solution) 0.075%, there exists the potential for increased bleeding time due to interference with platelet aggregation. There have been reports that ocularly applied NSAIDs may cause increased bleeding of ocular tissues (including hyphemas) in conjunction with ocular surgery.

It is recommended that BromSite® be used with caution in patients with known bleeding tendencies or who are receiving other medications which may prolong bleeding time.

Keratitis and Corneal Reactions

Use of topical NSAIDs may result in keratitis. In some susceptible patients, continued use of topical NSAIDs may result in epithelial breakdown, corneal thinning, corneal erosion, corneal ulceration or corneal perforation. These events may be sight threatening. Patients with evidence of corneal epithelial breakdown should immediately discontinue use of topical NSAIDs, including BromSite® (bromfenac ophthalmic solution) 0.075%, and should be closely monitored for corneal health.

Post-marketing experience with topical NSAIDs suggests that patients with complicated ocular surgeries, corneal denervation, corneal epithelial defects, diabetes mellitus, ocular surface diseases (e.g., dry eye syndrome), rheumatoid arthritis, or repeat ocular surgeries within a short period of time may be at increased risk for corneal adverse events which may become sight threatening. Topical NSAIDs should be used with caution in these patients.

Post-marketing experience with topical NSAIDs also suggests that use more than 24 hours prior to surgery or use beyond 14 days postsurgery may increase patient risk for the occurrence and severity of corneal adverse events.

Contact Lens Wear

BromSite® should not be administered while wearing contact lenses. The preservative in BromSite®, benzalkonium chloride, may be absorbed by soft contact lenses.

ADVERSE REACTIONS

The following serious adverse reactions are described elsewhere in the Brief Summary:

- Slow or Delayed Healing
- Potential for Cross-Sensitivity
- Increased Bleeding Time of Ocular Tissue
- Keratitis and Corneal Reactions
- Contact Lens Wear

Clinical Trial Experience

Because clinical trials are conducted under widely varying conditions, adverse reaction rates observed in the clinical trials of a drug cannot be directly compared to rates in the clinical trials of another drug and may not reflect the rates observed in clinical practice.

The most commonly reported adverse reactions in 1–8% of patients were: anterior chamber inflammation, headache, vitreous floaters, iritis, eye pain and ocular hypertension.

USE IN SPECIFIC POPULATIONS

Pregnancy

Risk Summary

There are no adequate and well-controlled studies in pregnant women to inform any drug associated risks. Treatment of pregnant rats and rabbits with oral bromfenac did not produce teratogenic effects at clinically relevant doses.

Clinical Considerations

Because of the known effects of prostaglandin biosynthesis-inhibiting drugs on the fetal cardiovascular system (closure of ductus arteriosus), the use of BromSite® during late pregnancy should be avoided.

Data

Animal Data

Treatment of rats with bromfenac at oral doses up to 0.9 mg/kg/day (195 times a unilateral daily human ophthalmic dose on a mg/m² basis, assuming 100% absorbed) and rabbits at oral doses up to 7.5 mg/kg/day (3243 times a unilateral daily dose on a mg/m² basis) produced no structural teratogenicity in reproduction studies. However, embryo-fetal lethality, neonatal mortality and reduced postnatal growth were produced in rats at 0.9 mg/kg/day, and embryo-fetal lethality was produced in rabbits at 7.5 mg/kg/day. Because animal reproduction studies are not always predictive of human response, this drug should be used during pregnancy only if the potential benefit justifies the potential risk to the fetus.

Lactation

There are no data on the presence of bromfenac in human milk, the effects on the breastfed infant, or the effects on milk production; however, systemic exposure to bromfenac from ocular administration is low. The developmental and health benefits of breastfeeding should be considered along with the mother's clinical need for bromfenac and any potential adverse effects on the breast-fed child from bromfenac or from the underlying maternal condition.

Pediatric Use

Safety and efficacy in pediatric patients below the age of 18 years have not been established.

Geriatric Use

There is no evidence that the efficacy or safety profiles for BromSite® differ in patients 65 years of age and older compared to younger adult patients.

NONCLINICAL TOXICOLOGY

Carcinogenesis, Mutagenesis and Impairment of Fertility

Long-term carcinogenicity studies in rats and mice given oral doses of bromfenac up to 0.6 mg/kg/day (129 times a unilateral daily dose assuming 100% absorbed, on a mg/m² basis) and 5 mg/kg/day (540 times a unilateral daily dose on a mg/m² basis), respectively revealed no significant increases in tumor incidence.

Bromfenac did not show mutagenic potential in various mutagenicity studies, including the bacterial reverse mutation, chromosomal aberration, and micronucleus tests.

Bromfenac did not impair fertility when administered orally to male and female rats at doses up to 0.9 mg/kg/day and 0.3 mg/kg/day, respectively (195 and 65 times a unilateral daily dose, respectively, on a mg/m² basis).

Rx Only

Distributed by: Sun Pharmaceutical Industries, Inc. Cranbury, NJ 08512

of whether it's a T2 or T9 toric equivalent. Of course, different companies manufacture their toric lenses differently, so it's possible that this concern may not always be addressed. But in my experience—using the more common toric lenses—I haven't found any difference in spherical outcomes using a toric vs. a non-toric lens."

9 What steps can I take to maximize the likelihood of getting better outcomes?

These strategies will help:

- **Optimize your lens constants.**

Dr. Hill notes that the lens constants provided by the manufacturer can be more than a half-diopter different from a surgeon's own lens constants. "If you want to improve your outcomes, lens constant optimization is essential," he says.

- **Validate your measurements.**

Dr. Hill notes that inaccurate measurements are a common source of refractive surprises. "The numbers we generate in the preoperative process come from a biometer, and from time to time the biometer may be wrong," he says. "There are many places where things can go off the rails, so you have to look carefully at your measurements and make sure they're correct. The staff should be first in line to check measurement validity, before the patient gets up and leaves the office. Perhaps there's a serious inconsistency from one measurement to the next, or perhaps there's something else out of the ordinary. Hopefully the technician picks up on this and either resolves the issue or brings it to the attention of the physician.

"The best way to check the accuracy of your measurements is by using validation criteria," he notes. "Both Zeiss and Haag-Streit have validation criteria available for the IOLMaster and the LenStar, respectively, so the technician should take the measurements and apply the validation criteria before letting the patient go. The phy-

sician should do the same when he or she reviews the measurements, and if something on the final review doesn't look right, the whole process should stop until the problem is resolved." (Dr. Hill notes that you can learn more about using the validation criteria by reading his editorial in the July 2017 issue of *The Journal of Cataract and Refractive Surgery*.⁵)

"With good biometry and a good formula, the 90-percent-within-0.5-D goal is becoming achievable."
—Graham Barrett, MD

- **Don't remove yourself from the process.** "Unfortunately, many surgeons let their staff run the show," says Dr. Hill. "We're all very busy and typically running behind schedule, so we don't have time to look over the shoulders of our staff and make sure everything is correct. However, that can lead to a scenario in which everything is automated or delegated. In some practices, a key staff member does all of the measurements and calculations and the physician just selects a lens on a piece of paper.

"That won't lead to a bad outcome most of the time," he continues. "However, if there's something unusual—let's say the patient has very steep or flat Ks, or an unusual anterior chamber, or a big difference in measurements between eyes—it's likely to get lost using this kind of protocol. Fortunately, a new form of surgical planning is now emerging, in which the validation is carried out by the planning software in much the same manner as the most knowledgeable and careful surgeons. Zeiss' new surgi-

cal planner Veracity holds the promise of being able to manage this for the surgeon.

"The bottom line is that the physician is the most knowledgeable person on the team," he continues. "Furthermore, physicians are being judged by their patients and their peers based on their refractive outcomes. The staff needs to look at the measurements and make sure they're right, but the final arbiter making the final decision regarding IOL calculations needs to be the physician.

"After the surgery, the doctor also oversees the process of tracking outcomes, to ensure that the practice is producing the desired level of results," he adds. "The surgeon initiates the process of lens-constant optimization, and overall, he or she also offers guidance and keeps the entire process current so the staff doesn't just keep doing the same thing year after year. The surgeon has to be the person in charge."

- **Spend extra time counseling patients with short eyes or previous refractive surgery.** Dr. Koch notes that these patients are most likely to have a refractive surprise. "These patients need to understand that their eyes fall into a category in which it's difficult to guarantee a perfect outcome," he says. "One has to be prepared to counsel the patient about the possibility of a two-stage procedure. I always show the patient the calculation sheet to point out that I have many lenses to choose from, and that I cannot be sure which is best. I explain that I'll use my best judgment about which one to implant, but the outcome could be off. Also, I tell the patient to be ready for the possibility of needing glasses or some form of postoperative modification, and what the cost of that would be."

- **Don't just keep doing what you've always done: Stay informed about the latest developments.** "This is a field that changes quickly,"

notes Dr. Hill. “What’s considered to be ‘best practice’ shifts at regular intervals. Last month I updated the online Hill-RBF calculator, extending the range of calculation down to -5 D, and the range of in-bounds indications for the very short eye was increased by the addition of 1,000 exceptionally short eyes.

“The point is that you need to stay current,” he says. “Go to meetings; attend webinars; read the journals. That way you’ll know what tools are in the toolbox to help you with the more challenging lens calculations. If you simply do what you’ve always done, inevitably you’ll fall behind the competition. The guy down the street will be keeping up, and you won’t be able to compete.”

10 *Will we ever have one formula that works for every eye?*

“Running different formulas for unusual axial lengths, Ks, and so forth is time-consuming, and the breakpoints vary with the formulas,” notes Dr. Holladay. “Improving formulas so that they work well for all eyes is our goal.”

Reaching that goal may be a ways off, however—if it’s even possible. “The limitations we have right now are as much about measurement technology as formula shortcomings,” observes Dr. Hill. “There are two problems. First, we have a measurement floor, which means that there’s a limit to how accurate we can be when we’re measuring living tissue. Second, we have a calculation ceiling, which means that we can only be so accurate in the face of technology limitations. As Jack Holladay recently pointed out, we’re starting to see that using current measurement technologies, and given the way intraocular lenses are offered to ophthalmologists, 90 or 92 percent within ± 0.5 D of the target outcome is probably the ceiling for accuracy.”

Nevertheless, Dr. Hill says he believes that one day it will be possible

to achieve a ± 0.50 D accuracy in excess of 95 percent of patients. “This will require an improvement in measurement technology, and calculation methods will have to be optimized to work with these improved measurements,” he says. “In addition, industry may one day be able to deliver us IOLs that have the exact, measured power as part of the labeling process.” (Adjustable lens technology may improve these numbers as well, with lenses such as the recently approved Light-adjustable Lens [discussed on p. 12] enabling surgeons to modify the power of the IOL postoperatively.)

Dr. Barrett notes that our ability to measure the posterior corneal surface is evolving. “Being able to measure the eye in a more sophisticated fashion should improve our predictions,” he points out. “We’re on the verge of a new generation of biometers that will do that. New technologies such as Scheimpflug devices and swept-source OCT can measure the posterior cornea quite accurately. That can impact not only our toric predictions but our spherical outcomes as well.

“Now, we’re beginning to have formulae that are customized to utilize this new information,” he continues. “Just in the past few weeks I’ve added an option to my toric calculator, which is online at the APACRS (Asia-Pacific Association of Cataract and Refractive Surgeons) and ASCRS websites, that will allow the user to incorporate that new information. I think that will enhance our outcomes in a variety of segments, not just in toric or post-refractive eyes, but even spherical outcomes in average eyes.”

But will we end up with a single formula that works for every eye? “I doubt it,” says Dr. Barrett. “Of course, most formulae are based on theoretical physics and optics, so you might think they’d all tell us the same thing. The issue, however, is trying to predict where the lens will end up—the effective lens position. That’s often

where the author of a particular formula uses a different algorithm; some algorithms are data-driven, some are based on different eye models. To put it another way, the formulae are based on fundamental optics and physics, but there are also elements of hand-crafting, and I don’t think that’s going to change.

“However, there is a convergence,” he adds. “The latest generation of formulae are getting closer to producing precise outcomes. The ceiling that we tend to hit even with a great formula isn’t a sign that the formula is wrong; it’s the result of entering noisy data, including the postoperative refraction (which helps us determine accuracy) and issues such as imperfect lens manufacture. But with good biometry and a good formula, the 90-percent-within-0.5-D goal is becoming achievable.” **REVIEW**

Dr. Koch is a consultant for Carl Zeiss, Alcon and Johnson & Johnson Vision. Dr. Hill is a consultant for Zeiss, Haag-Streit, Alcon, Omega Ophthalmics, Optos and Veracity Surgical. Dr. Holladay is the developer of the Holladay 1, 2 and Refractive Formulas and is president of Holladay Consulting, which is the distributor of the Holladay IOL Consultant Software (licsoap.com). Dr. Barrett has licensed his formulas to multiple companies, but notes that they are freely available to all online.

1. Melles RB, Holladay JT, Chang WJ. Accuracy of intraocular lens calculation formulas. *Ophthalmology* 2017 Sep 23. pii: S0161-6420(17)31428-8. doi: 10.1016/j.ophtha.2017.08.027. [Epub ahead of print]
2. Fram NR, Masket S, Wang L. Comparison of intraoperative aberrometry, OCT-based IOL formula, Haigis-I, and Masket formulae for IOL power calculation after laser vision correction. *Ophthalmology* 2015;122:1096-101.
3. Wang L, Shirayama M, Ma XJ, et al. Optimizing intraocular lens power calculations in eyes with axial lengths above 25.0 mm. *J Cataract Refract Surg* 2011;37:11:2018-27.
4. Melles RB, Holladay JT, Chang WJ. Accuracy of intraocular lens calculation formulas. *Ophthalmology* 2017; Sep 23. pii: S0161-6420(17)31428-8. doi: 10.1016/j.ophtha.2017.08.027. [Epub ahead of print]
5. Hill WE, Abulafia A, Wang L, Koch DD. Pursuing perfection in IOL calculations. II. Measurement foibles: Measurement errors, validation criteria, IOL constants, and lane length. *J Cataract Refract Surgery* 2017;43:7:869-70.

Free Educational Webinars

Learn from leading experts as they share their in-depth knowledge of corneal transplantation.

Download today at SightLifeSurgical.com/Education

DMEK: Beyond the Learning Curve

by Nicole Fram, M.D.

- ✓ Preoperative Considerations: Careful choices that will result in a successful outcome.
- ✓ Intraoperative Challenges: How to manage challenging eyes. The real deal!
- ✓ Postoperative Monitoring and Imaging: Utilization of anterior segment OCT to monitor graft attachment, function and timing to rebubbling.

How Thin is Ultra-Thin?

by Edward J. Holland, M.D.

- ✓ Be one of the first to learn about the thinnest DSEK to date.
- ✓ Get pearls on using this new DSEK tissue.
- ✓ Discover how to make using this ultra-thin tissue easy and consistent.

DSAEK with Ultra-Thin Tissue vs. DMEK

by Bennie Jeng, M.D.

- ✓ Comparing the two types of surgeries and their impacts on patients who have had successful recoveries.
- ✓ A look at the current and past research published by other leading surgeons in the field.
- ✓ Surgical techniques in relation to doing corneal transplants with ultra-thin tissue.

Cornea Crosslinking

by John Berdahl, M.D.

- ✓ The science, protocols, and economics of crosslinking.
- ✓ What options and alternatives are available to you.
- ✓ Methods to make crosslinking work in your practice and for your patients.
- ✓ How to increase accessibility for your patients.

The Successful DMEK Transition: Pearls, Obstacles, and Answers

by Neda Shamie, M.D.

- ✓ Detailed explanations paired to video clips of Dr. Shamie's own DMEK procedures.
- ✓ Insight into what obstacles you can expect during DMEK.
- ✓ In-depth solutions for how to best circumvent challenges.

DMEK: Tips and Tricks for Effective, Efficient, and Safe DMEK Surgeries

by Matt Giegengack, M.D.

- ✓ How to use pre-punched tissue to reduce prep time and potential problems.
- ✓ Insight into what obstacles you could expect during DMEK procedure.
- ✓ A first look at how to insert a DMEK graft using the Geuder Glass Cannula.

Presbyopic IOLs: Choosing Wisely

By Kristine Brennan, Senior Associate Editor

How to watch
and listen to
your patients to
enhance your
success rate.

Since presbyopia-correcting IOLs hit the U.S. market, starting with the AMO Array (Allergan; Irvine, Calif.), they've helped patients achieve at least partial freedom from glasses or contacts. According to the International Society of Refractive Surgery's 2015 U.S. Trends in Refractive Surgery Survey¹, presbyopic IOL implantation is not a high-volume surgery, although new lenses keep emerging on the American market.

The additional patient costs for presbyopic IOLs and the risk of nighttime visual symptoms may be barriers to their adoption, and suitable candidates require care and attention when choosing the best lenses to meet their visual goals. Below, experienced surgeons discuss lens planning for presbyopic IOL patients.

Eye Health

Ocular health makes presbyopic lens selection possible. "Obviously, do all the testing, including topography, and make sure the patient doesn't have dry eye. I think the topography and the health of the cornea and the retina are the most important things," says Jennifer Loh, MD, of Loh Ophthalmology Associates in Coral Gables, Florida. "You really have to make sure there's no other pathology that's going

to affect the patient's outcome, and if there's some treatable pathology, such as dry eye, treat it right away. That's number one," she says.

"I'm a big believer in repeating tests: Measure twice, cut once," adds Dr. Loh, who doesn't limit her screening to covered services. "You can do an OCT of the macula to rule out retinal pathology. If a patient actually has macular degeneration, for example, then it's a covered service, but not as a screening test. Corneal topography and OCT of the macula are not covered services. Patients have to have a problem like keratoconus or retinal pathology to get these paid; insurance won't cover either as a screening tool. But they're important because you can pick up so many things that will affect outcomes," she says.

Stephen V. Scoper, MD, vice president of Virginia Eye Consultants in Norfolk and a consultant to Alcon, evaluates testing performed by his staff to see if his patients meet the criteria for a multifocal. "I examine the patient, of course, and I look at all of the testing," he says. He offers suitable patients the AcrySof IQ ReSTOR +2.5 multifocal IOL with Activefocus (Alcon; Fort Worth, Texas) or the toric version. "If I know the patient is interested in an Activefocus, I'll look at the topography and the keratometry to see



100% PRESERVATIVE-FREE

ZIOPTAN[®]
(tafluprost ophthalmic solution) 0.0015%

Cosopt[®] PF
(dorzolamide HCl - timolol maleate ophthalmic solution) 2% / 0.5%



**ORDER
FREE SAMPLES**



Go to either website
and select "Request Sample"

www.Zioptan.com

www.CosoptPF.com

Cosopt is a registered trademark of Merck Sharp & Dohme Corp and is used under license. ZIOPTAN is a registered trademark of Merck Sharp & Dohme Corp and is used under license.

Santen ZIOPTAN is licensed by Santen Pharmaceutical Co., Ltd.

AKORN

©2017 Akorn, Inc. All rights reserved. P481(a) Rev 4/17

how much astigmatism they have. I'll look at their higher-order aberrations. I'll look at the angle kappa. I'll look at the macular OCT to make sure their macula is completely normal, and I'll put fluorescein in their eye to make sure they don't have significant ocular surface disease," he says.

Patient Expectations

Once screening is complete, Dr. Loh starts talking to her patients to help them select the best presbyopic IOLs. "Assuming you have a person who is physically a suitable candidate for presbyopic lenses, really trying to understand what they want by listening to what they say is critical," she says. "I'll repeat some of my questions for them a few times, just to make sure that they understand." Dr. Loh also uses a short written questionnaire for prospective refractive surgery patients to learn more about their visual priorities, and the CheckedUp system (Cirle; Miami, Fla.) to educate them about refractive cataract surgery and IOL selection. "Using a little iPad, really well-developed, cartoonlike videos explain the basic concepts of cataract surgery and the different types of lenses to the patient," she says. "You still need to talk to your patients a lot, of course, but it helps to introduce the topic."

Dr. Loh handles the lens-selection talks with her patients. "I want to find out about any hobbies, occupations and preferences they have for their vision. Some people just want to do computer work and have distance vision to play golf and sail. Other people really want to read up close." She notes that some presbyopic IOL candidates have surprisingly specific visual goals. "For example, I saw an attorney who told me point-blank that he expected to see without glasses at exactly 12 inches from his face," she recalls. More often, however, it takes careful listening and questioning to make sure that surgeon and patient have a mutual understand-



The toric version of the Tecnis Symphony extended-depth-of-focus IOL is designed to offer good vision across all distances while remediating astigmatism.

ing of near, mid-range, and distance vision. "There's a wide range of near tasks, so someone telling me that they want to see 'up close' may have a totally different concept of what means from anyone else," she says.

Dr. Scoper relies on his technicians and counselors to screen for suitability for a presbyopic lens. "We do all the testing and counseling before the patient sees the doctor. I'm a big believer in the idea that the doctor should do only what only a doctor can do. So I don't do things like explaining to a patient what cataracts are, what astigmatism is, or the types of lenses that are available. I'm lucky to have a great staff that does that before the patient comes to me," he explains.

Dr. Scoper spends a few minutes making sure patients know what to expect once he has confirmed that they are good candidates for the Activefocus IOL. "I have a little speech," he says, "and it goes like this: 'I can't give you everything, but I can give you a lot. Let me tell you what I *can* do for you and what I *cannot* do for you. Number one, this lens will give you great distance vision without any glasses. You'll be able to get up in the morning and not need glasses to watch television

and drive. The second thing it will do is bring the distance vision's clarity in to arm's-length vision. An example of this would be that when driving, you'll be able to see street signs and other cars at distance, but you'll also be able to see the dashboard of the car. You'll be able to see the kitchen counter when you're cutting up vegetables. You'll be able to see the peas on your plate when you're eating. You'll be able to see your computer and your desktop. Arm's-length vision will be very good. What it will not do is allow you to see small print up very close, nor medicine bottles or price tags. If you're going to read a novel for an hour, you're going to be more comfortable with a light pair of reading glasses. Does that sound good to you?' They usually say, 'I understand. Let's do it.'"

Visual Goals

Although newer presbyopia-correcting IOLs offer satisfactory visual results at more than one focal point, surgeons and their patients still need to prioritize. "I think there's been a paradigm shift regarding what doctors think is important to patients," says Dr. Scoper. "Early on, I and other surgeons focused heavily on near vision. With some of the early generations of multifocals, patients' distance vision wasn't as clear as it would be with a monofocal lens, but we had never talked about good distance vision and patients just assumed that they would end up with good distance vision. The number one thing that patients want but don't know to ask for is good distance vision. As surgeons, our primary goal should be good distance vision no matter what. That's what patients really need and want."

Multifocal and accommodative lenses emerged and developed roughly in tandem with the growing ubiquity of screens. This has implications for presbyopic IOL selection, according to Dr. Loh. "I think for most people

SEE WHERE THE ROAD
CAN TAKE YOU.

Introducing ground-breaking optics
powered by LED illumination.



The slit lamp is the engine that keeps your practice in motion. And the hands-down industry leader for over 60 years, Haag-Streit, now outshines the competition even more, with an LED illumination system that results in our sharpest, brightest optics ever. With a level of diagnostic detail this advanced, the road ahead becomes clearer than ever.

Driven to excellence. See even more now at [HSdriven.com](https://www.hsdriven.com).

800.787.5426

© 2017 Haag-Streit USA. All Rights Reserved.



 **HAAG-STREIT
USA**

mid-range is very important, but still, I'd never assume that. I always ask. You still find some people who never use a computer. I think most people want to see their cell phone and their computer without glasses, though."

When Dr. Scoper discusses visual goals with his patients, he emphasizes other activities of daily living to clue them into the focal point he deems second in importance to distance vision: arm's-length vision. "I used to talk mainly about computer vision when I described this to them, but now 'computer' is about the fourth or fifth word I use. The first example I give is seeing the dashboard of your car, and then seeing the kitchen counter when you're cooking and cutting up small vegetables," he says. "So much of your world is at arm's length. When you're sitting and having a conversation with somebody and you can see their face and their eyes, that's so much more important than being able to read small print. But I also tell patients that if they're going to sit down and read a book or magazine for an hour, they'll have to put on a light pair of dollar-store cheaters and turn on some good light to be comfortable."

Although he is acutely concerned about creating unrealistic expectations, Dr. Scoper says that in some cases he can, in fact, give patients good near vision by putting an Activefocus in the dominant eye, and then a ReSTOR 3.0 in the nondominant eye. "But I don't promise that," he stresses. "I don't even hint. I try to under-promise and over-deliver on that."

Dr. Scoper also tries to avoid overwhelming patients with presbyopic lens options. "I think it's important for a doctor to give one recommendation to the patient. They don't want five different things to choose from. They just want to know what's best for them," he says.

Dr. Loh says that she doesn't try to limit patients' IOL options initially. "When I discuss the lenses with them,

letting them know the pros and cons of each option, I get a little more feedback from them before I offer my recommendation of what I think would be best, but I still talk to them about everything. I've found that everyone has a different idea of what they'll be getting. You can't assume anything about people's expectations," she says.

Once a patient settles on a presbyopic IOL, Dr. Loh uses her chair time with him or her to manage expectations one more time. She emphasizes that perfect spectacle independence is not assured. "I do tell patients that there is a really high likelihood that they will need light readers. I almost exaggerate that point a little bit, because I find that it's better to put that out there from the beginning than to let them think that they're not going to wear glasses," she says.

Regarding the possible need for a postop enhancement, Dr. Loh says, "I do warn patients ahead of time that sometimes it can take more than one surgery to get everything correct." She adds that it's not a big topic of conversation, however, except on the rare occasion that a patient is truly unhappy postop.

Dr. Scoper says he will do a touch-up at no charge if necessary, but also emphasizes that it's a rare occurrence. "I use the expanded version of the Hill RBF formula, and the last time Dr. Hill ran my numbers, the percentage of patients I hit ± 0.5 D was 97 percent of all the patients I did. So I don't even talk about enhancements in advance. The counselors may mention it, but I'm doing very few enhancements."

Observation

Sometimes a patient's response on a preoperative questionnaire or even the verbal feedback they give in discussion fails to fully clarify what they really want. Both doctors say it's important to carefully observe patients to spot factors that can strongly affect their

satisfaction with presbyopia-correcting lenses.

While interacting with her patients, Dr. Loh is also assessing how their body type may influence their concept of near or intermediate distance. "If someone is really tall and has longer arms, they're going to have a different focal point than a petite female with shorter arms, for example" she says. "The distance they'll want to read from is very different, and that is a key point." Dr. Loh cautions against relying on observations alone or just the patient's questionnaire answers, however. "You really have to look at the patient, but you also have to ask them where they like to read," she stresses. "Obviously, you can look at body type and make some assumptions, but you'd still better ask, because you don't know people's true preferences."

For Dr. Scoper, body type determines whether he can mix and match lenses for a select group of patients, placing a mid-range-power multifocal in the dominant eye and one with a stronger add in the nondominant fellow eye. "I do it if they're five-foot-zero and their arms are just too short to really be able to use their intermediate vision," he says. "I can give them more by adding that in."

Observing the patient's near reading behavior preoperatively is also key, says Dr. Loh. "Someone who's already doing monovision naturally or with contact lenses, or who happens to be a moderate to high myope may say, 'Well, I still take my glasses off to read.' That really alerts me to the fact that I have to take extra care when offering presbyopic lenses," she says. "One of the biggest pearls ever taught to me is to find out what the patient's vision is without their glasses. It sounds kind of simple, but if you can't make them better than they are now without their glasses, they're not going to be happy. If someone is a moderate to high myope, if they can already read well without their glasses, say at J2 even

FOR THE REDUCTION OF IOP IN MILD TO MODERATE PRIMARY
OPEN-ANGLE GLAUCOMA AT THE TIME OF CATARACT SURGERY



and done

ONE CYPASS® MICRO-STENT IS ALL IT TAKES TO CONNECT
TO SAFE, CONSISTENT, LONG-TERM IOP CONTROL

IN THE COMPASS STUDY AT TWO YEARS^{1,2}:


- 72.5% of patients achieved a $\geq 20\%$ reduction in IOP (n=374)
- 93% of patients were medication free*
- Safety profile similar to cataract surgery alone



FOR AN EXPERIENCE LIKE NO OTHER, CONNECT WITH AN ALCON REPRESENTATIVE TODAY.

*Those patients who attained an unmedicated mean diurnal IOP reduction of 20% or more as compared to baseline in the absence of IOP-affecting surgery during the study.

References: 1. CyPass® Micro-Stent Instructions for Use. 2. Vold S, Ahmed IIK, Craven ER, et al. Two-year COMPASS trial results: supraciliary microstenting with phacoemulsification in patients with open-angle glaucoma and cataracts. *Ophthalmology*. 2016;123(10):2103-2112.



CyPass[®] Micro-Stent

IMPORTANT PRODUCT INFORMATION

CAUTION: FEDERAL (USA) LAW RESTRICTS THIS DEVICE TO SALE BY OR ON THE ORDER OF A PHYSICIAN.

INDICATION: The CyPass[®] Micro-Stent is indicated for use in conjunction with cataract surgery for the reduction of intraocular pressure (IOP) in adult patients with mild to moderate primary open-angle glaucoma (POAG).

CONTRAINDICATIONS: Use of the CyPass Micro-Stent is contraindicated in the following circumstances or conditions: (1) in eyes with angle-closure glaucoma; and (2) in eyes with traumatic, malignant, uveitic, or neovascular glaucoma or discernible congenital anomalies of the anterior chamber angle.

MRI INFORMATION: The CyPass Micro-Stent is magnetic resonance (MR) Safe: the implant is constructed of polyimide material, a non-conducting, non-metallic, non-magnetic polymer that poses no known hazards in all magnetic resonance imaging environments.

WARNINGS: Gonioscopy should be performed prior to surgery to exclude peripheral anterior synechiae (PAS), rubeosis, and other angle abnormalities or conditions that would prohibit adequate visualization of the angle that could lead to improper placement of the stent and pose a hazard.

PRECAUTIONS: The surgeon should monitor the patient postoperatively for proper maintenance of intraocular pressure. The safety and effectiveness of the CyPass Micro-Stent has not been established as an alternative to the primary treatment of glaucoma with medications, in patients 21 years or younger, in eyes with significant prior trauma, chronic inflammation, eyes with an abnormal anterior segment, eyes with chronic inflammation, eyes with glaucoma associated with vascular disorders, pseudophakic eyes with glaucoma, eyes with uveitic glaucoma, eyes with pseudoexfoliative or pigmentary glaucoma, eyes with other secondary open-angle glaucomas, eyes that have undergone prior incisional glaucoma surgery or cilioablativ procedures, eyes with laser trabeculoplasty performed \leq 3 months prior to the surgical screening visit, eyes with unmedicated IOP less than 21 mmHg or greater than 33 mmHg, eyes with medicated IOP greater than 25 mmHg, in the setting of complicated cataract surgery with iatrogenic injury to the anterior or posterior segment, and when implantation is without concomitant cataract surgery with IOL implantation for visually significant cataract. The safety and effectiveness of use of more than a single CyPass Micro-Stent has not been established.

ADVERSE EVENTS: In a randomized, multicenter clinical trial comparing cataract surgery with the CyPass Micro-Stent to cataract surgery alone, the most common postoperative adverse events included: BCVA loss of 10 or more letters at 3 months after surgery (8.8% for the CyPass Micro-Stent vs. 15.3% for cataract surgery only); anterior chamber cell and flare requiring steroid treatment 30 or more days after surgery (8.6% vs. 3.8%); worsening of visual field mean deviation by 2.5 or more decibels (6.7% vs. 9.9%); IOP increase of 10 or more mmHg 30 or more days after surgery (4.3% vs. 2.3%); and corneal edema 30 or more days after surgery, or severe in nature (3.5% vs. 1.5%).

ATTENTION: PLEASE REFER TO THE INSTRUCTIONS FOR A COMPLETE LIST OF CONTRAINDICATIONS, WARNINGS, PRECAUTIONS, AND ADVERSE EVENTS.

Alcon A Novartis Division

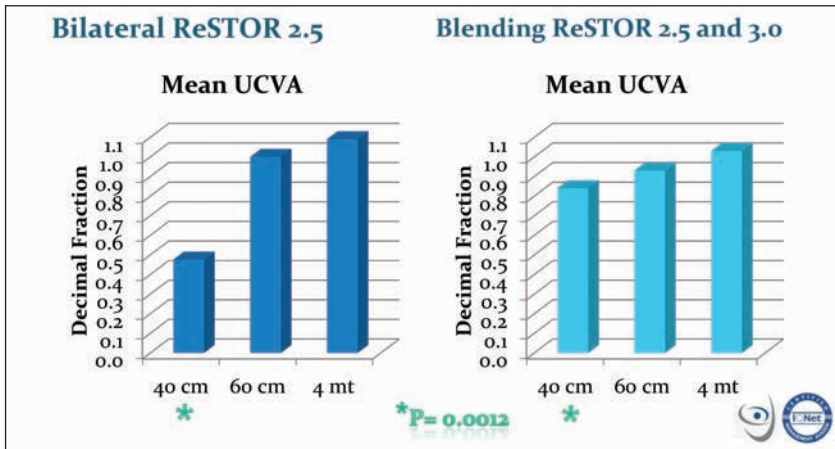
with a cataract, if you put in an EDOF or a multifocal lens and then they're J4, you might think you have a successful case. But they're going to say, 'That's not better! I could see J2 without my glasses!' So knowing where they're starting from is critical," she says.

Dr. Scoper also makes a point of asking his myopic patients when they wear their glasses. "If I've got someone who is a -5 D or above, I know that their near focal point is too close to be very practical. I'll treat them like an emmetrope, like anybody else," he says. "But if I've got someone who's a -2 D, -2.5 D, or -3 D, the first question I ask them is, 'Do you wear your glasses all day long and just look at things through your bifocal at near, or do you take your glasses off a lot for near?' If they answer, 'I leave my glasses on all day long, and I never take them off when I want to look at near,' then I'm going to go for good distance and maybe intermediate vision. But if as a -2 D, they say, 'Once I walk into the house, I leave my glasses off the whole time. The only time I put them back on is to watch television or drive,' I know they really love that uncorrected near vision. They can look across the room and their brain is used to the blur at distance. They just put their glasses on when they have to have good distance vision. If that's the only time that a -2 D wears his or her glasses, I'm going to leave them at -2 D with a monofocal lens," he says. "If they've got some astigmatism I'll correct it with a toric or the laser. I'm going to leave them nearsighted, because their brain has gotten used to that uncorrected near vision. I may make one eye -2.25 D and the other eye -1.5 D to -1.75 D and give them a little intermediate blended with near."

"A lot of these patients who read well without glasses don't even realize it," says Dr. Loh. "I know that sounds strange, but they're just so used to it that they don't think it's anything special. They won't report it to you because they just think it's normal. You can tell somewhat based on someone's refraction: If someone's a hyperope, for example, a +3.50 D, they're not going to be able to read at all without glasses. But if they're a myope, you'd better ask them things like, 'Are you reading without your glasses?' and 'Can you take your glasses off and read this card for me?' Or you may recognize it if they say something like, 'I'm really lucky. All of my friends have to wear reading glasses, and they're all jealous of me because I don't have to.' I've really learned to pay attention to this."

Evolving Lenses

Dr. Loh doesn't rule out presbyopia-correcting IOLs for patients who've been happy with monovision, but she does caution them about attempting to fix what's not broken. "I get patients that use contacts for monovision, and they've done this for 20 years and they love it. When I hear that, I



A 2013 study⁴ comparing the visual acuity of patients bilaterally implanted with ReSTOR 2.5 IOLs to patients with a ReSTOR 2.5 in the dominant eye and a ReSTOR 3.0 in the nondominant eye at six months showed that the blended-vision patients gained significantly greater near UCVA, with only slightly lower intermediate and distance UCVA.

usually tell them that I think we should recreate that surgically. They like it, they're used to it, and I've found that changing it can be a problem. So in that case, I'll usually say, 'Look. There are these other lenses out there, multifocals or EDOF, that will give good distance and intermediate vision and some near vision binocularly, and that may be beneficial to you, but you're really used to your monovision and you seem very happy with it. I think keeping it would be in your best interest.' So sometimes I'll steer people away from the multifocal or EDOF lenses because of that. But if they want to try them, that's fine. It's important to really make them understand the pros and cons of each situation."

Dr. Scoper will try placing a presbyopic IOL in the dominant eye to give good distance and intermediate, with a monofocal targeted for near vision in the nondominant eye in those patients who are well-adapted to monovision. "In their nondominant eye, I'll place a monofocal lens focused exactly to where they're used to, whether it's -2 D, -2.25 D or -2.5 D," he explains. "We're then able to give them more with intermediate vision in the dominant eye, and they love that," he reports.

Studies suggest that one way to improve near vision and thereby increase patient satisfaction with EDOF lenses like the Tecnis Symphony is to employ a blended-vision approach by targeting the dominant eye for emmetropia and the nondominant for slight myopia.^{2,3}

Both doctors say their presbyopic lens patients have few complaints about night vision. "I usually don't get too many complaints about it, but I do warn them ahead of time," says Dr. Loh. "I have had some patients who've had some glare and halos: Luckily, I haven't had anyone tell me it's been horrible or debilitating. But they'll comment on it sometimes."

Dr. Scoper reports essentially the same thing. "I may hear just a comment or an observation that rings and halos and glare are present, but it's really not a problem," he says. He also advises his patients to expect some postoperative nighttime visual symptoms. "I tell them that they'll see some glare and rings around headlights and streetlights at night, simply because the implant actually has rings in it. But I also tell them that it gets better within three or four months to the point that usually, they'll hardly notice it," he adds.

Dr. Scoper notes many patients experienced troubling nighttime symptoms and blurry distance vision with earlier generations of multifocal IOLs, and notes that visual outcomes are improving as the technology evolves. "I think that many surgeons felt like they were burned with some of the original multifocals because there was a small group of patients who really didn't do well," he says.

"I have the most familiarity right now with the Symphony (Johnson & Johnson Vision; Santa Ana, Calif.) and I have used the new Activefocus from Alcon as well," says Dr. Loh. "Both feature improvements over the earlier presbyopic lenses in that they give more intermediate vision, which is becoming more important to a growing number of patients than the reading of fine print. They do that at a cost sometimes to book-reading near vision and other up-close reading, though." Dr. Loh adds that as the lenses improve to provide better vision across a wider range of vision, talking to your patients remains critical to their satisfaction. "What I've learned is that everyone has a different idea of great vision, and I think that in order to really make someone happy, you have to find out what they really want," she says. **REVIEW**

Dr. Loh is a consultant for Johnson & Johnson Vision, Allergan and Sun Ophthalmics, and a speaker for Shire. Dr. Scoper is on the speakers' bureau and consults for Alcon, and is on the speakers' bureau of its parent company, Novartis.

1. International Society of Refractive Surgery. ISRS 2015 U.S. trends survey. <https://isrs.ao.org/resources/2015-isrs-u-s-trends-survey>. Accessed 6 December 2017.
 2. Cochener B, Concerto Study Group. Clinical outcomes of a new extended range of vision intraocular lens: International multicenter Concerto Study. *J Cataract Refract Surg* 2016;42:9:1268-1275.
 3. Breyer DRH, Kaymak H, Ax T, et al. Multifocal intraocular lenses and extended depth of focus intraocular lenses. *Asia-Pacific J Ophthalmol* 2017;6:4:339-349.
 4. Carones, F. (2013 October). Six-month results from an aspheric apodized diffractive multifocal IOL with a +2.5 D add power. Poster presented at the 31st Congress of the European Society of Cataract and Refractive Surgeons, Amsterdam, the Netherlands.

Premium IOLs: How to Spot Poor Candidates

By *Liam Jordan, Associate Editor*

How to weed out candidates who will be dissatisfied with these IOLs, even after a perfect surgery.

If you choose to offer presbyopia-correcting intraocular lenses, you're quickly faced with the problem of matching the IOL to each patient's lifestyle, which isn't always easy. In this article, we'll take a look at who isn't a suitable candidate for premium IOLs like the Symphony, ReSTOR, Tecnis Multifocal and Crystalens, and how to successfully avoid creating unhappy postop patients.

The Perfect Candidate

In an ideal world, all patients could get the procedures they want. For presbyopic IOLs, however, the perfect patient can be difficult to come by. Zaina Al-Mohtaseb, MD, an assistant professor of ophthalmology at Baylor College of Medicine, discusses her ideal candidate. "Patients with excellent ocular surfaces are the first indication of a great candidate," she says. "They should also have no co-existing ocular pathology and would like to be glasses-independent for most things, but understand they might need glasses for small print.

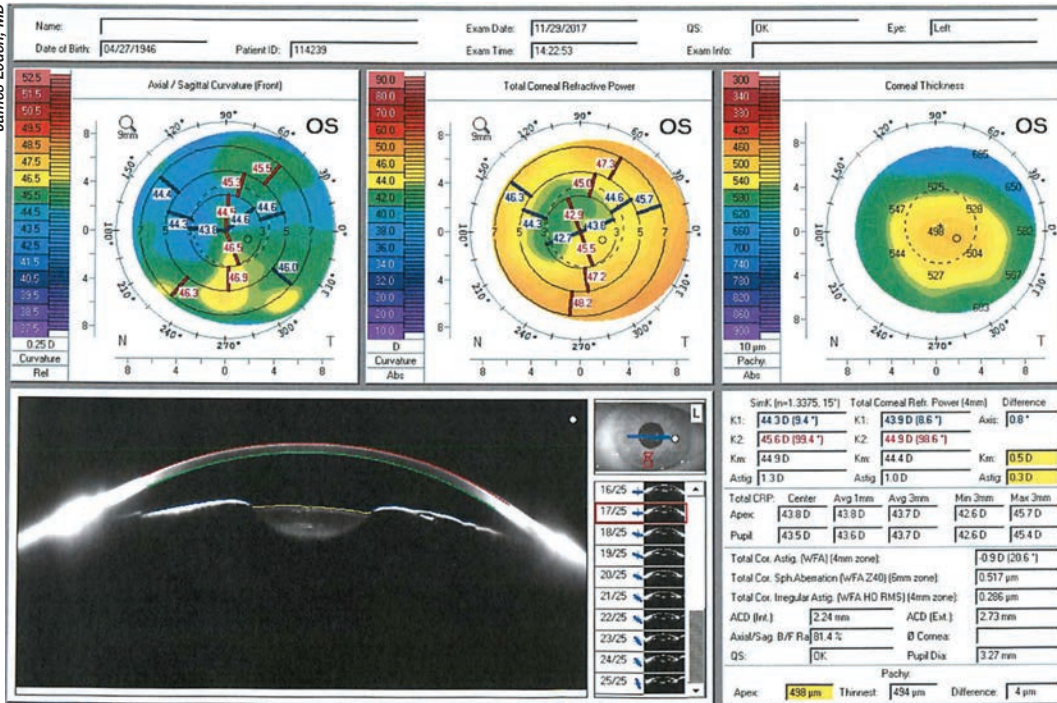
"Even if a patient is a good candidate, the most important thing is the preoperative discussion," she continues. "If the surgeon and his team take the time to discuss realistic expecta-

tions for the presbyopia-correcting lens, then most patients are happy regardless of their personality."

James Loden, MD, an ophthalmologist based in Nashville, Tenn., also discusses the importance of managing expectations preoperatively. "Sometimes, you're going to have patients who set the bar so high that even with a perfect surgery and implant, they'll be disappointed with their visual results," he says. "So it's important to manage these expectations preoperatively so they know what they're getting themselves into. It's a big-time management of expectations if pathology is present."

Dr. Loden also describes his ideal candidate for these premium IOLs. "In terms of personality type, you're going to want to look for someone who can manage their expectations—they're a realist. There is likely going to be some follow-up that they'll have to be on board for, and that's important to identify from the get-go.

"You can't be too careful," he continues. "With age, dry eye becomes more and more prevalent, which absolutely needs to be addressed before surgery. And this is true with both a standard and premium IOL. You need to make sure the ocular surface is pristine. As with most sur-



A 71-year old man presented with a history of cataract. Scans showed dry eye, and the physician prescribed Xiidra before considering IOL implantation.

geries, this will help with faster visual recovery and better postop results.” (For specific tips on matching a lens to a patient’s visual needs, see “Presbyopic IOLs: Choosing Wisely,” on pg. 30.)

Medical Pathology

Because not every patient will be an ideal candidate for these premium lenses, surgeons describe who might not be a great fit for the lenses and why. The most obvious indication that a patient will not be a great candidate comes from any medical pathology. Here are a few indications of a bad candidate to look out for:

- **Fuchs’ dystrophy.** “Most patients with co-existing corneal pathology won’t be an ideal candidate,” Dr. Mohtaseb says.

- **Advanced dry eye.** “Any pre-existing conditions need to be treated prior to surgery to ensure good outcomes,” she adds.

- **Advanced macular degeneration.** “These patients would also not be good candidates since this would

result in decreased contrast sensitivity, decreased visual acuity, and glare/halos,” she continues. “You should take a look at the retina with a slit lamp or OCT. The lens might actually make the patient’s vision worse because of their AMD.”

- **Anterior basement membrane dystrophy.** “This will just kill you on chair time,” Dr. Loden notes, because of the necessity to address the ABMD as well as the cataract. “You’ll spend more time operating, even though these patients with anterior membrane dystrophy won’t see well with the lenses implanted. They won’t be satisfied with their outcomes, and you’ll have to bring them back in to either correct the lens or explant it.”

- **Post-refractive surgery patients.** “Any patient who has had prior refractive surgeries is likely not going to get great results,” Dr. Loden claims. “If they’ve had previous surgeries that have altered their refraction, there can be residual refractive errors. The patient might be left with blurry vision and dysphotopsias.”

- **Weak zonules.** “There’s also an issue with implanting lenses in eyes with weak zonular support because they could dislocate,” Dr. Loden continues. “If you’re dead set on implanting though, you can put in a capsular tension ring, which should make it a bit easier to reposition the IOL. It just might be a pain for the patient to have issues with decentration, but that’s something you should be transparent about preop.”

- **Glaucoma.** “The earlier the disease, the more options you can explore regarding some multifocal, premium IOLs,” Dr. Loden says. “However, there are ocular refractive changes that occur after glaucoma surgery which would be a good reason to advise against these lenses. It’s especially bad to implant one of these lenses if the patient’s glaucoma is progressing or poorly controlled.”

To help catch patients such as those described above, Dr. Mohtaseb recommends, “getting topography (look at the mires) and macular OCT on patients to evaluate if a patient is a good candidate or not.”

“Ignoring these signs of bad candidates will cost you too much chair time for suboptimal results,” according to Dr. Loden. “Any ocular surface disease has to be corrected preoperatively. These patients won’t be satisfied with their outcomes otherwise, no matter how perfect the surgery and implantation is. You have to be cautious and judicious with those outcomes.

“It doesn’t matter if you’re charging them \$500 or \$1,000,” Dr. Loden continues. “Once you charge them, they expect perfection, and they don’t always understand that pathology is a limiting factor, so they’re dissatisfied with their results even if you do a perfect procedure. We need to make sure we talk about these things preop. With pathology present, you have to manage expectations.”

Psychological Mismatch

Along with the obvious medical signs of a bad candidate for these premium IOLs, there are other red flags that visual tests won’t detect. The personality types of your patients can also be a good indication of whether or not a premium IOL is right for them.

“I recommend avoiding the older generation, high-add models in obsessive/compulsive people or very particular people, given the risk for postop glares and halos,” Dr. Mohtaseb says. “More often than not, they’ll be back to have the lens explanted. There are plenty of alternatives to these high-add premium IOLs, and I am much more comfortable placing the low-add multifocals and extended-depth-of-focus lenses in these patients now. I think the most difficult patient is still the low myope (-2 D) who had crisp reading vision for years, because they’ll take a long time to adjust to their vision and probably won’t be satisfied postop-

eratively. It all goes back to managing expectations and your instinct about whether or not they’ll adjust to the lens.”

Dr. Loden also shares his experiences with evaluating the personalities of his patients to see if they’ll be a fit for these lenses. “There are definitely some psychological signs to keep an eye out for, and you’ll learn most of it from just talking with your patients. Evaluate their visual needs. Ask if they mind wearing glasses. Do they consider themselves to be obsessive or a perfectionist? What are they hoping to gain from this procedure in terms of visual acuity? Would they prefer distance or near visual acuity? It’s also important to evaluate their state of mind as best you can, too. If you have a depressed patient, you probably shouldn’t implant one of these lenses, as adjusting to the new, imperfect visual acuity might be stressful. It’s important to take the time to talk with them, and use your gut to make the call. There are plenty of other options that might better suit your patient. It’s okay to go in a different direction,” he says.

Careers

Along with a patient’s psychological makeup, his or her career should also be taken into account when looking at implanting a premium IOL. For example, say your patient is an editor who needs closer visual acuity to edit his work. You’ll definitely want to keep that in mind while evaluating whether or not to implant a premium IOL.

“In the older models of presbyopia-correcting lenses with significant add-power, some patients in certain occupations were not happy with the results of the lenses,” Dr. Mohtaseb says. “For example, night drivers or patients who required excellent and

crisp distance vision, such as pilots, were not good candidates because of the compromise of the distance vision. We looked at our surgical indications for removing these presbyopia-correcting IOLs and found that distance vision and glare, halos and dysphotopsias were the most common issues that patients had. I would also recommend avoiding implanting these lenses in very particular people, such as an engineer who asks how the optics of the lens work.”

“There are definitely some obvious indications for these lenses based on patient careers,” Dr. Loden says, “but as I said, you can figure all this out if you talk to your patients and evaluate their needs based on their lifestyles, and make a judgment call. If the patient has a profession that calls for distance visual acuity, then you’re probably best served looking elsewhere for a nonpremium lens.”

Looking Ahead

Despite the many benefits of premium IOLs, there are plenty of patients who just aren’t suited for them. Surgeons advise exploring other lens options. Even with perfect surgery and implantation, a patient not fit for these lenses will still be dissatisfied, leaving you and him frustrated. Beyond the medical contraindications, make sure your patient’s psychological makeup can adapt to these lenses.

“Taking the time to understand your patient’s needs makes the difference between a satisfied patient and a frustrated one,” Dr. Loden says. “It’s on you to recommend the lenses that are best for them.” **REVIEW**

Dr. Loden is a consultant for LENSAR, J & J vision and Lenstec. Dr. Mohtaseb is a consultant for Alcon and Allergan.

ONLY

AzaSITE®

(azithromycin ophthalmic solution) 1%



Combines Azithromycin
with DuraSite®

Now included in the
RxDirect® Service

- Eye patients save significantly on their prescription and it can be delivered to their home for free

Visit azasite.com to learn more



AzaSite® is a registered trademark of Insite Vision Incorporated and is used under license.
©2017 Akorn, Inc. All rights reserved. P807 REV 10/17

Surgeons Share Their Views on IOLs

By *Walter Bethke, Editor in Chief*

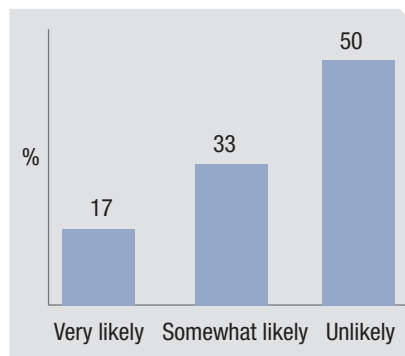
Opinions on monofocals, multifocals, torics and handling lens complications.

If surgical technique is the art that helps ensure that cataract procedures go smoothly and yield great visual results, then the intraocular lenses are the science. This month, cataract surgeons provided their opinions on IOL technology, from monofocal and multifocal/extended-depth-of-focus lenses to toric IOLs. They also shared their thoughts on which lens features, such as toricity and blue-light blocking, they found to be most useful in their practices.

This month, the e-mailed survey was opened by 992 of 7,605 subscribers to *Review's* e-mail service (13 percent open rate); of those, 57 shared their responses.

To get a sense of where you stand in the IOL landscape, read on.

Surgeons' Likelihood of Using a Presbyopic IOL in Two Years



Monofocal Lenses

These are the lenses that surgeons say they use for most of their cases. When choosing them, they look for things like ease of use, consistency and a reliable lens material.

Fifty-four percent of the surgeons say they use the Alcon IQ Aspheric IOL for most of their cases, while 31 percent prefer the J&J Vision Tecnis one-piece lens. Six percent use the B+L enVista, 4 percent like the B+L SofPort AO, 2 percent prefer the B+L Akreos AO and 2 percent like the Hoya iSymm/iSert.

"I like that the Alcon IQ unfolds slowly," says Connecticut surgeon Kevin Dinowitz. "Acrylic is less likely to cause inflammation or interfere with silicone oil retinal procedures. It gives consistently excellent outcomes."

"The lens is very quiet in the eye," avers an AcrySof IQ surgeon from Nevada. "Glistening and reflections are a little bothersome to patients." A California surgeon also uses the Alcon lens for most of his surgeries, saying, "Cons: yellow color; glistening. Pro: It's very easy to insert."

On the Tecnis side, Bruce Cohen, MD, of St. Louis says he prefers it because it "works well, has no glistenings, is easy to load and inject and

has great optics.” Lee Yasgur, MD, of Cherry Hill/Voorhees, New Jersey, agrees, saying, “The Tecnis offers ease-of-insertion, and it’s pre-loaded to avoid twists, kinks and minimize hand motion: KISS [Keep It Simple, Stupid].” Rishi Kumar, MD, of Louisville, Kentucky, says he likes the Tecnis best because it’s “pre-loaded, clear, one-piece and has no vacuoles.”

“The Bausch + Lomb enVista uses a high-quality optic and has no glis-tenings,” argues another surgeon. A surgeon from Ohio prefers the B+L SofPort AO partly due to its versatility: “It’s aspheric, compatible with use in the sulcus, with minimal dysphotop-sia,” he says. “It allows me to order one lens, as it is also my sulcus backup.”

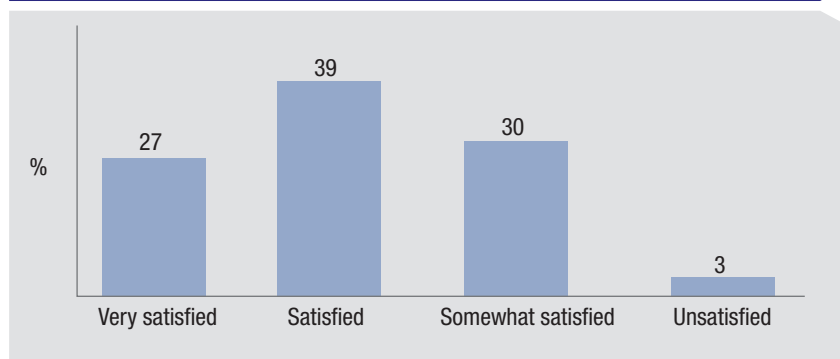
Presbyopic Lenses

Surgeons also discussed the presby-opic lenses they use, how many they implant per month and what the average charge is. Some surgeons chose more than one lens, leading to 78 re-sponses in all.

The option chosen by most surgeons was the Symphony, at 23 percent (average number implanted per month: 2.7; average charge: \$2,262). The AcrySof aspheric ReSTOR 2.5 D was next, at 22 percent (average number im-planting: 2.6; average charge: \$2,505). The third most popular option was the AcrySof aspheric ReSTOR 3 D, at 8 percent (average number implanted: 3.2; average charge: \$2,607). The rest of the field broke down as follows:

- AcrySof ReSTOR Toric 2.5: 6

Surgeon Satisfaction with Presbyopic IOLs



percent (avg. no. implanted: 2; avg. charge: \$2,769);

- Tecnis 2.75 D Multifocal: 5 percent (avg. no. implanted: 2.75; avg. charge: \$1,899);

- Tecnis 3.25 D Multifocal: 5 percent (avg. no. implanted: 4; avg. charge: \$2,300);

- AcrySof ReSTOR Toric 3 D: 5 percent (avg. no. implanted: 2; avg. charge: \$2,761); and

- Crystalens AO: 3 percent (avg. no. implanted: 2.7; avg. charge: \$2,167).

Surgeons shared the reasons they like certain presbyopic lenses, as well as what areas could use some improve-ment.

Louisville’s Dr. Kumar explains why he likes the Symphony: “It has fewer halos,” he says, “and you don’t have to be so exact with the refractive outcome. However, refraction adjustment after surgery like that used by the light-adjustable IOL would be great.” Ron Glassman, MD, of Teaneck, New Jersey, agrees up to a point. “It has less glare than older multifocals,” he says,

“but not zero.” A surgeon from Cali-fornia says he likes the Symphony, but is a bit disappointed in its near vision. “Make a higher-add component, if fea-sible,” he says.

Baltimore surgeon Ismail Shalaby uses the Alcon Aspheric ReSTOR 2.5 a lot, commenting, “Results are good with the Alcon lens, and the toric platform is excellent with minimal or no rotation. Patients haven’t reported nighttime issues.” Dr. Dinowitz often uses the Aspheric ReSTOR 2.5, but says there’s always room for improve-ment. “There’s still a learning curve involved,” he says, “and needing the perfect candidate limits the number of candidates. The need to implant both eyes to even know how it will work is a risk.” Cherry Hill’s Dr. Yasgur says that, in his experience, “Any minus correc-tion left in the the Symphony causes spiderweb haloes, and all Alcon lenses cause ‘diamond-eye’ light reflexes that patients’ family members do not like to look at.” Jonathan Adler, MD, of Bradenton, Florida, who says he of-ten uses the Alcon Aspheric ReSTOR 3 D, shares his lens wish list: “A lens that could incorporate the ReSTOR 2.5 D’s benefits with the reading vi-sion of the ReSTOR 3 D, without the added side effects of the 3 D,” he says.

Toric Lenses

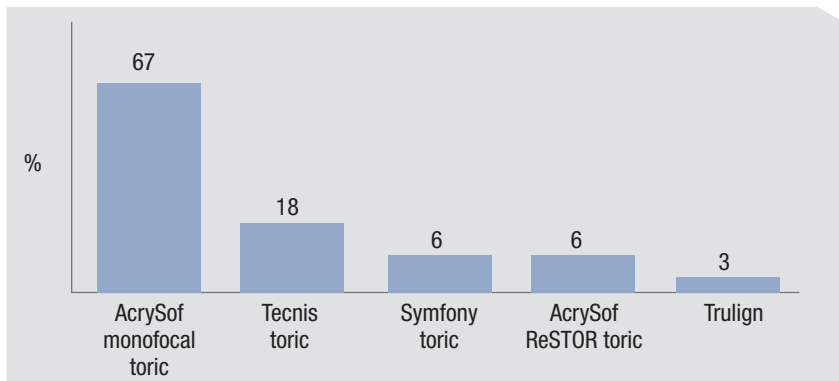
Fifty-eight percent of surgeons say they regularly use toric lenses, and

Surgeons Rank the Features of IOLs

Asphericity/neutral asphericity	4.4
Toric design	4.3
Edge design to decrease PCO	3.9
Multifocality	3.9
Blue-light blocking	3.0
Pseudo-accommodative motion	2.7

Surgeons on the survey ranked IOL features in terms of their usefulness using a numerical scale that ran from 1 (least useful) to 6 (most useful). The average scores are shown.

Toric IOL Used the Most



shared their views on these lenses' pros and cons.

In terms of the toric IOL the surgeons say they use the most, 67 percent say they use the AcrySof monofocal toric. Eighteen percent prefer the Tecnis toric. (The popularity of the other choices appears in the graph above.) They provided several reasons why they like the lenses they do, as well as thoughts on some things the lenses could do better.

"The [AcrySof monofocal toric] is easy to implant and rotate, but the translucent markings are difficult to visualize and align in larger myopic eyes," says Dr. Dinowitz. "You can't focus the cornea and the markings at the same time in the larger myopic eyes and have to focus on one plane." A New York surgeon likes using the AcrySof monofocal toric, saying, "I like the stability and refractive predictability." He adds, however, "Its maker could improve the ease of insertion at the proper axis." A surgeon from Michigan says he likes the "larger range of options for astigmatism," offered by the AcrySof toric, but says it could use "improvement in prevention of lens rotation."

Lens Complications

Unfortunately, lens implantations don't always go as smoothly as hoped, so surgeons also shared their thoughts

on suturing and explanting IOLs.

Most respondents (62 percent) say they don't find themselves suturing an IOL in order to properly fixate it; 28 percent say they have to suture-fixate a lens 1-3 times throughout the year; and 3 percent each say they have to suture a lens 4-6 times, 7-10, or more than 10 times in a year.

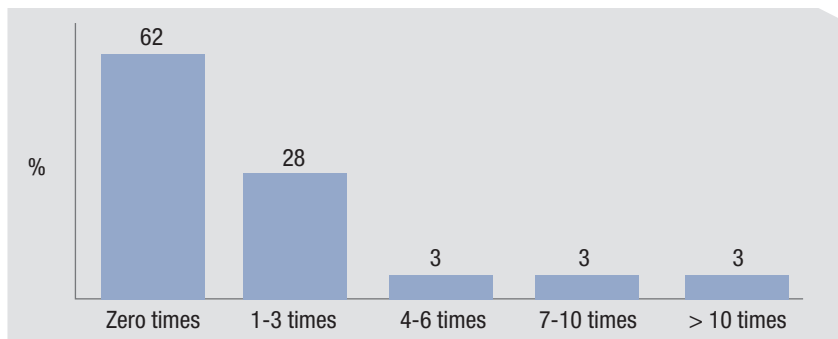
Surgeons explained why this suture fixation was necessary. "Dislocation/decentration of the IOL within the capsular bag," says a surgeon from Utah. "Also, poor zonular/capsular support. I use a ciliary sulcus suture." An ophthalmologist from Virginia says the reason is often "lack of good capsule or iris support," and that he usually uses a pars plana suture. One surgeon, who says he sutures IOLs more than 10 times a year, says the most common reason is "subluxation after years of pseudoexfoliation; I use

scleral fixation." St. Louis' Dr. Cohen says, "I used to suture IOLs when there was reduced capsule support, but enough support that one suture would do the job. I have not had to do that for several years." Dr. Yasgur says he'll suture it if "the eye presents as aphakic or with a traumatically dislocated crystalline lens, or in cases of a subluxated IOL."

In terms of explanations, surgeons' reasons for doing it in the past 12 months vary. Steven Stiles, MD, of Tarzana, California, says he explanted a lens because the "lens power was way off." Baltimore's Dr. Shalaby explants lenses due to "nyctalopia in the older multifocal IOLs." Dr. Dinowitz had to take a lens out because the patient was a challenging case, citing "the wrong IOL power in a keratoconus patient." In 2017, Dr. Yasgur had to explant a lens 15 years after it was first implanted, the culprit being "subluxation due to pseudoexfoliation." Dr. Cohen says he explanted lenses on two occasions. "One was for the wrong power in an extended-depth-of-focus lens, and the other was a multifocal case in which the patient didn't tolerate glare."

Other reasons that respondents provided for explants on this year's survey include: uveitis; multifocal issues; instability; dysphotopsias; glare/halo and positive photopsias; and patient dissatisfaction with a multifocal or EDOF lens. **REVIEW**

Surgeons' Annual Frequency of Suturing an IOL



EVERY MONDAY
E-NEWS YOU CAN USE





Have you been receiving and reading custom e-blasts from *Review of Ophthalmology*?

If not, you're missing out on valuable information!

You're a busy practitioner and not surprisingly, your e-mail inbox is often full. Fortunately, when you scan through the sender list, determining which messages to delete and which to save or read, you can feel confident knowing that e-blasts from *Review of Ophthalmology*, a Jobson Medical Information LLC publication, contain the most current and comprehensive information available in the field to keep you on the cutting edge.

Review of Ophthalmology's online stable of products includes editorial newsletters and promotional information about new products, treatments and surgical techniques, as well as alerts on continuing education courses for ophthalmologists.

 Our FREE weekly e-newsletter, *Review of Ophthalmology Online*, brings you the latest in ophthalmic research, as well as industry news. In an effort to keep eyecare professionals informed, this resource is waiting in your inbox **every Monday morning**.

 *Retina Online*, our free monthly e-newsletter, is for retina specialists and general ophthalmologists interested in enhancing their knowledge on the topics of retina and related disease diagnosis and treatment, as well as the latest in surgical procedures.

Your time is valuable — and so is your practice. These e-products are the most effective way for you to receive updates on breaking news and research — all just a click away.

DON'T MISS OUT!

Unfamiliar with our products? Visit www.reviewofophthalmology.com and check out our newsletter archives.

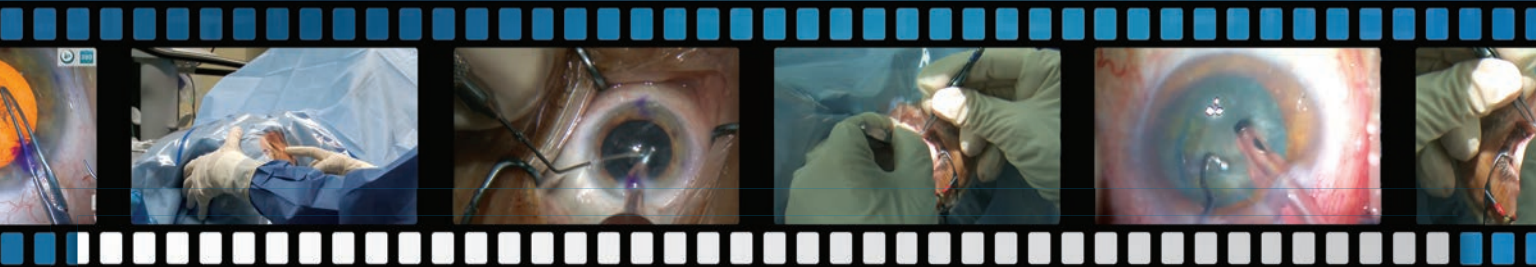
Go to www.jobson.com/globalEmail/default.aspx to sign up for the e-newsletters that interest you.



Monthly

MACKOOL ONLINE CME

CME SERIES | SURGICAL VIDEOS



To view CME video
go to:

www.MackoolOnlineCME.com

Episode 25: "The Divide and Conquer Technique"

Surgical Video by:
Richard J. Mackool, MD

Video Overview:

In response to viewer requests, this video demonstrates the Divide and Conquer procedure using a curved ultrasonic needle. A useful method of eyelash isolation is also shown.

Accreditation Statement

This activity has been planned and implemented in accordance with the accreditation requirements and policies of the Accreditation Council for Continuing Medical Education (ACCME) through the joint providership of Amedco and Postgraduate Healthcare Education, LLC (PHE). Amedco is accredited by the ACCME to provide continuing medical education for physicians.

Credit Designation Statement

Amedco designates this live activity for a maximum of .25 AMA PRA Category 1 Credits™. Physicians should claim only the credit commensurate with the extent of their participation in the activity.

MackoolOnlineCME.com MONTHLY Video Series



Richard J. Mackool, MD

Welcome to the third year of Mackool Online CME! With the generous support of several ophthalmic companies, I am honored to have our viewers join me in the operating room as I demonstrate the technology and techniques that I have found to be most valuable, and that I hope are helpful to many of my colleagues. We continue to edit the videos only to either change camera perspective or to reduce down time - allowing you to observe every step of the procedure.

As before, one new surgical video will be released monthly, and physicians may earn CME credits or just observe the case. New viewers are able to obtain additional CME credit by reviewing previous videos that are located in our archives.

I thank the many surgeons who have told us that they have found our CME program to be interesting and instructive; I appreciate your comments, suggestions and questions. Thanks again for joining us on Mackool Online CME.



CME Accredited Surgical Training Videos Now Available Online: www.MackoolOnlineCME.com

Richard Mackool, MD, a world renowned anterior segment ophthalmic microsurgeon, has assembled a web-based video collection of surgical cases that encompass both routine and challenging cases, demonstrating both familiar and potentially unfamiliar surgical techniques using a variety of instrumentation and settings.

This educational activity aims to present a series of Dr. Mackool's surgical videos, carefully selected to address the specific learning objectives of this activity, with the goal of making surgical training available as needed online for surgeons motivated to improve or expand their surgical repertoire.

Learning Objective:

After completion of this educational activity, participants should be able to:

- Demonstrate the Divide and Conquer technique, including the use of a non-angulated, curved phaco needle, during the procedure
- Incorporate a method of eyelash draping

Endorsed by:
Review of Ophthalmology®

Video and Web Production by:
JR Snowdon, Inc

Jointly Provided by:



Supported by an unrestricted independent
medical educational grant from:

Alcon

Additionally Supported by:

**Glaukos
MST
Crestpoint Management
Carl Zeiss Meditec**



GSL and Cataract Surgery: Low Risk, High Reward

An often underutilized procedure, goniosynechialysis can be a significant contributor to pressure control in angle-closure patients.

Carla J. Siegfried, MD, St. Louis

Goniosynechialysis is the process of physically separating peripheral anterior synechiae (PAS), which can develop in the trabecular meshwork when the angle is appositionally closed, contributing to the blockage of aqueous outflow. It's particularly useful as an adjunct to cataract surgery, and it can be done through a small corneal incision—the same incision you're using for the cataract extraction. The procedure is accomplished by grasping the peripheral iris and gently pulling it away from the angle, using any one of a number of handheld instruments—most commonly microsurgical forceps—under either direct or indirect visualization by gonioscopy.

Goniosynechialysis has significant potential for increased utilization, for two reasons: First, more surgeons are becoming comfortable performing gonioscopy in the office and the OR, thanks to the growing popularity of minimally invasive glaucoma surgeries, or MIGS. Second, the Effectiveness of Early Lens Extraction for the Treatment of Primary ACG study (EAGLE), published in *The Lancet* in October 2016,¹ indicated that clear

lens extraction is both more efficacious and more cost-effective than doing laser iridotomy in patients presenting with primary angle closure.

Given these two developments, if you're going in to remove the lens in a patient in whom there's a preoperative concern of angle closure, I believe it's a good idea to perform intraoperative gonioscopy after the IOL has been placed. That will allow you to determine whether there are lingering synechiae in the angle, or significant areas of synechial closure that could be opened relatively easily. If you do find synechiae in the angle, cataract surgery provides a perfect opportunity to perform goniosynechialysis to open the angle, improve trabecular outflow and potentially lower the patient's pressure.

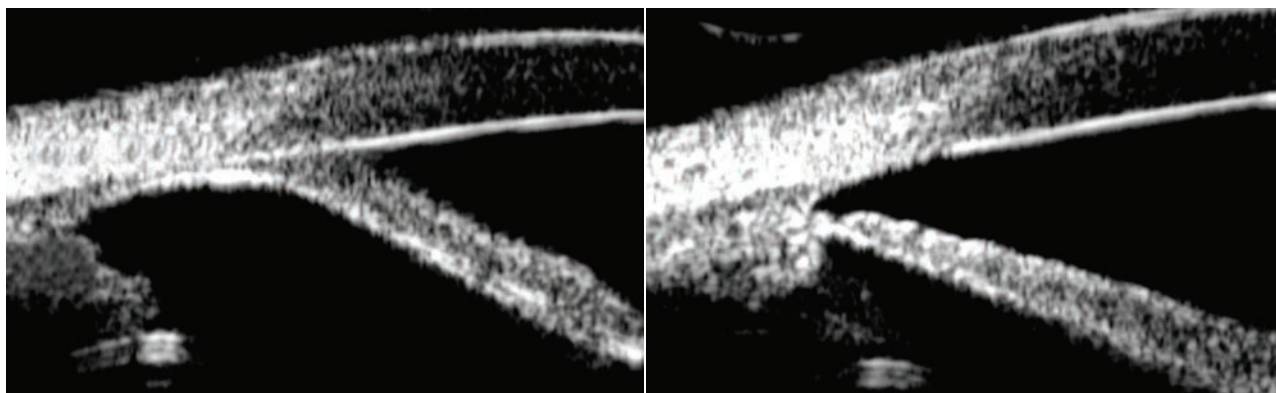
Performing the Procedure

The classic description of goniosynechialysis in patients with acute or subacute angle-closure glaucoma appeared in 1984.² Viscoelastic was used to deepen the anterior chamber; then the angle was directly visualized by gonioscopy. An irrigating cyclo-

dialysis spatula was used to separate the synechiae from the peripheral cornea via anterior to posterior movement of the iris.

Interestingly, these surgeons noted a high rate of success (80 percent) in patients who had had angle closure for less than one year, because synechiae that have been in place longer than a year are not easily separated. (There's also the issue of whether the trabecular outflow behind the synechiae is still functional when the angle has been closed for a significant time.) However, I would point out that we usually don't know how long synechiae have been present—unless there was a clear attack of angle closure or a surgical intervention—so this procedure is usually worth a try.

In terms of instrumentation, there are a variety of techniques, but many surgeons use microsurgical forceps rather than a cyclodialysis spatula. When the procedure was first performed, it was done with an irrigating spatula because they didn't have good-quality viscoelastics. Fluid irrigation into the eye kept it formed; then one could use the instrument to manipulate the tissue. This



Robert Ritch, MD

An example of a narrow angle before (left) and after goniosynechialysis was performed.

works—I’ve performed it in the past with a spatula—but I find it easier to perform with microforceps that allow me to grasp the tissue.

The postoperative protocol is straightforward. Treat any inflammation with steroids and NSAIDs. Pressure control is essential, especially in the early postoperative period, because a pressure spike can result from a release of pigment, blood or retained viscoelastic. I routinely inject a miotic intraoperatively after the procedure to try to keep the angle open; some surgeons advocate longer-term use of miotics as well.

Possible complications of goniosynechialysis include:

- **Mild to moderate postoperative inflammation.** This is probably the most common event.

- **Hemorrhage.** Hemorrhages are relatively uncommon and usually self-limiting; they can be minimized by exercising care during the procedure. If a hemorrhage does occur, it’s most likely a tear in a very focal area, so the first thing to do is to stop pulling in that location. I inject a little more viscoelastic to decrease the hemorrhage by increasing the pressure in that location. I’ve never had a serious hemorrhage—one that recurred or lasted for a long period of time—during this procedure.

- **Iridodialysis or cyclodialysis.** If you perform direct or indirect visualization of the angle during the

procedure, you’re much less likely to cause a dialysis of either the iris or the ciliary body.

- **Corneal endothelial damage.** In my experience, corneal endothelial damage is uncommon as long as one is careful to use viscoelastic and exercise caution near the cornea.

- **Problems resulting from retained viscoelastic.** This can be avoided by carefully removing viscoelastic at the end of the procedure.

GSL or Trabeculectomy?

In a primary angle-closure glaucoma patient, performing cataract extraction with goniosynechialysis instead of trabeculectomy often provides an acceptable outcome without associated risks. In my experience, it makes sense to simply remove the lens, perform goniosynechialysis and then reassess the pressure. You may be pleasantly surprised with the long-term results. (You can always go back later and do a trabeculectomy.)

Consider a patient of mine who presented at the age of 49 with a one-year history of primary angle-closure glaucoma. She had a T-max in the low 40s in both eyes and she’d undergone iridotomies in both eyes. When I first saw her, she had excellent visual acuity and was on brimonidine and travoprost, with pressures of 16 and 18 mmHg. Gonioscopy at that time revealed angle closure of grade B(C)

20-s (the “s” referring to a steep approach). Cupping was 0.6 and 0.8 with some pallor of both optic nerves. She had an inferior arcuate defect in both eyes, as well as a nasal step in her left eye. The angle had 1 to 2+ pigment, but I noted no PAS at that time.

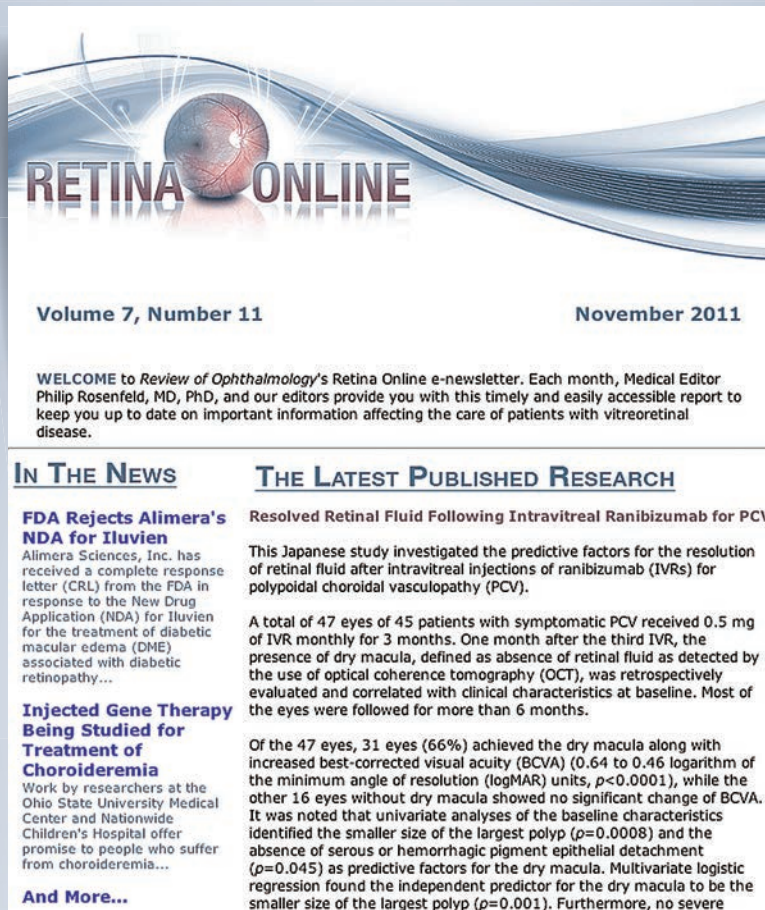I followed her for the next several years; her pressures, optic nerves and visual fields remained stable. Nevertheless, I continued to perform annual gonioscopy, which is very important in these patients, and her angles gradually became narrower with appositional closure. For that reason, I performed an argon laser iridoplasty, which opened up her angles again.

After that, her pressure and visual fields remained stable for a while, but two years later at the age of 54, her pressures were 17 and 26 mmHg and she was starting to develop peripheral anterior synechiae. (During those five years her lens likely increased its anterior-posterior diameter, pushing the iris forward and shallowing the anterior chamber. This is a significant component in progressive angle closure.) Even though she didn’t have a visually significant cataract, it was “glaucoma significant” and I performed cataract extraction along with goniosynechialysis in both eyes.

She is now seven years postop. She remains 20/20 and is off of all glaucoma medications; she has open angles, IOPs in the low teens, and

RETINA ONLINE

E-NEWSLETTER



Once a month, Medical Editor Philip Rosenfeld, MD, PhD, and our editors provide you with timely information and easily accessible reports that keep you up to date on important information affecting the care of patients with vitreoretinal disease.

3 EASY WAYS TO SUBSCRIBE!

<http://www.jobson.com/globalemail/>

Fax: 610.492.1039 or Call: 610.492.1029

REVIEW[®]
of Ophthalmology

stable visual fields and optic nerves. All of this was accomplished without resorting to trabeculectomy, which meant a shorter recovery time and lower risk of complications.

Since Campbell and Vela's initial description, a review was published of 81 patients with primary ACG with uncontrolled IOP and more than six clock hours of synechiae that underwent phaco/GSL. Eighty-nine percent had reduction of PAS and controlled IOP without medications,³ consistent with the case described above. More recent literature also supports this alternative to trabeculectomy. One study found that patients had shorter recovery times and fewer complications with GSL compared to trabeculectomy;⁴ another found similar postoperative IOP and medication use, but decreased complications with GSL;⁵ and another found no difference in postop IOP, but improved visual acuity and a deeper anterior chamber with PAS resolution.⁶

A fourth study⁷ found that when the glaucoma in angle-closure patients was already well-controlled, there was no benefit to performing goniosynechialysis while undergoing cataract extraction. However, if you can minimize your patient's use of medications long-term without the risks associated with trabeculectomy, that's a winning combination. For that reason, I think it's appropriate to consider GSL in primary angle-closure glaucoma patients who have well-controlled pressure, if they're dependent on several medications.

Strategies for Success

These suggestions will help ensure the best possible outcome when performing GSL in conjunction with cataract surgery:

- **Choose appropriate candidates.** Considerations include:
 - Goniosynechialysis is ideal when

a patient has 90 to 180 degrees of synechiae.

- Any level of angle closure is acceptable, in my opinion, including acute, subacute and "chronic" angle closure, as well as angle closure in the presence of plateau iris.

- GSL can be performed in combination with endocycloplasty.

- GSL can be used to address residual angle closure after iridotomy or argon laser iridoplasty.

If you open six clock hours, you may totally change the outflow and improve IOP control.

Contraindications, in my view, include patients with neovascularization in the angle or the iris, as well as patients with chronic or recurrent uveitis, or ICE syndrome.

- **Perform gonioscopy on your angle-closure patients regularly.** Angle closure may progress, and synechiae may develop over time.

- **Aim for IOP control during the procedure to minimize corneal edema and optimize visualization.** Having a clear cornea for visualization is crucial. If your patient has markedly elevated pressure prior to the surgery, that requires treatment, including the use of IV mannitol preoperatively.

- **If possible, perform goniosynechialysis under direct visualization.** It's important to be able to see what you're doing during the procedure, in order to avoid tearing tissue, potentially causing significant bleeding or something worse than the synechiae. (A small amount of bleeding, however, isn't unusual or harmful.) Of course, being sensitive

to the feel of what you're doing is equally important. If you have to pull forcefully and the tissue is still not releasing, it's probably wise to leave that area alone to avoid causing a tear.

The concept behind goniosynechialysis is simple and straightforward, but as with many surgical procedures, you don't want to cause a bigger problem than the initial problem you're attempting to treat.

- **Avoid working with the pupil dilated.** Constricting the pupil with Miochol or Miostat after cataract surgery is helpful; you have the pupil slightly more on stretch. If the pupil is widely dilated, it's much more difficult to see if you've broken the synechiae.

- **Using viscoelastic is crucial.** Viscoelastic helps keep the chamber formed throughout the procedure. It also helps with hemostasis and the initial viscodissection. Injecting viscoelastic directly into the angle can help to "hyper-deepen" the peripheral chamber, making it easier to identify the synechiae.

Whether you can open up some of the synechiae just by using the viscoelastic to stretch the angle is questionable, but viscoelastic will definitely allow you to differentiate appositional from synechial closure.

- **If necessary, make a second incision to reach all of the synechiae.** A two-site entry may be necessary, depending on where the synechiae are located. If some are subincisional or on the temporal side of the eye, then you'll need to make an incision on the opposite side to open those up.

- **Remember that you don't have to separate every synechia to improve outflow.** If you only open up a significant portion of the angle and leave some synechiae untouched, that doesn't mean the procedure has been a failure. Freeing up all 12 clock hours doesn't have to be your ultimate goal; if you open six clock hours, you may totally change the outflow and

improve IOP control.

• **When performing a MIGS procedure, consider doing goniosynechialysis first.** Combining goniosynechialysis and a MIGS procedure could increase flow into the anterior chamber angle and then distal to the potentially less-functional trabecular meshwork. Other angle procedures may also be performed at these locations in the future.

• **If you can't ensure good visualization through the cornea, endoscopy can be used.** Goniosynechialysis can be performed with an endoscope using a 19- or 23-ga. probe if you don't have good visualization through the cornea, but this is a more challenging technique.

• **Be sure to carefully remove the viscoelastic after the procedure.** As with any intraocular surgery, viscoelastic left behind can cause pressure spikes.

An Option Worth Considering

Performing goniosynechialysis in combination with phaco may be an effective and safe treatment option for many patients with primary angle-closure glaucoma. The technique isn't highly complex, especially if you're performing MIGS procedures, many of which require you to be comfortable visualizing and working in the anterior chamber angle.

By opening the angle, helping to re-establish trabecular meshwork flow and improving pressure control, goniosynechialysis may decrease the need for medication use, as well as saving the patient from undergoing more invasive and higher-risk procedures. [REVIEW](#)

Carla J. Siegfried, MD, is the Jacquelyn E. and Allan E. Kolker MD Distinguished Professor of Ophthalmology at Washington University School of Medicine in St. Louis. She has no financial ties to any product mentioned.

Carla J. Siegfried, MD, is the Jacquelyn E. and Allan E. Kolker MD Distinguished Professor of Ophthalmology at Washington University School of Medicine in St. Louis. She has no financial ties to any product mentioned.

1. Azuara-Blanco A, Burr J, Ramsay C, Cooper D, Foster PJ, Friedman DS, Scotland G, Javanbakht M, Cochrane C, Norrie J; EAGLE study group. Effectiveness of early lens extraction for the treatment of primary angle-closure glaucoma (EAGLE): A randomised controlled trial. *Lancet* 2016;388:10052:1389-1397.
2. Campbell DG, Vela A. Modern goniosynechialysis for the treatment of synechial angle-closure glaucoma. *Ophthalmology* 1984;91:9:1052-60.
3. Teekhasaenee C, Ritch R. Combined phaco-goniosynechialysis for uncontrolled chronic angle-closure glaucoma after acute angle-closure glaucoma. *Ophthalmology* 1999;106:669-75.
4. Lai JS, Tham CC, Lam DS. The efficacy and safety of combined phacoemulsification, intraocular lens implantation, and limited goniosynechialysis, followed by diode laser peripheral iridoplasty, in the treatment of cataract and chronic angle-closure glaucoma. *J Glaucoma* 2001;10:4:309-15.
5. Zhao X, Yang X, et al. Comparison of combined phacoemulsification, intraocular lens implantation, and goniosynechialysis with phacotrabeculectomy in the treatment of primary angle-closure glaucoma and cataract. *The Asia-Pacific Journal of Ophthalmology* 2013;2:5:286-290.
6. Zhang H, Tang G, Liu J. Effects of phacoemulsification combined with goniosynechialysis on primary angle-closure glaucoma. *J Glaucoma* 2016;25:5:e499-503.
7. Lee CK, Rho SS, Sung GJ, et al. Effect of goniosynechialysis during phacoemulsification on IOP in patients with medically well-controlled chronic angle-closure glaucoma. *J Glaucoma* 2015;24:6:405-9.

HIRE THE BEST Ophthalmic Technicians



Hire experienced, certified Ophthalmic Technicians with Local Eye Site.

Also find amazing billers, insurance coders, front desk staff & office administrators.



Local Eye Site
JOBS IN EYE CARE

localeyesite.com/hire/ophthalmic-technician

The official recruiting partner for *Review of Ophthalmology*.

Jobs appear on the ATPO career center and ATPO grads and JCAHPO pros are directed to your career opportunity.





A Look at Emerging Treatments for Uveitis

Companies and researchers are hard at work on new drugs as well as innovative delivery systems.

Elizabeth A. Atchison, MD, and Pauline T. Merrill, MD, Chicago

Non-infectious uveitis affecting the posterior segment (NIU-PS, including intermediate, posterior and panuveitis) is a relatively uncommon condition, with an incidence of about 4.6 per 100,000 person-years.¹ However, for those affected, NIU-PS can lead to a multitude of ocular problems. Compared to age-matched patients, those with NIU-PS are 10 times more likely to have blindness or low vision, twice as likely to have glaucoma, three times as likely to have a cataract and 12 times more likely to have a retinal detachment.² Improved control of inflammation can lead to decreased ocular complications, better vision and increased quality of life.³ In addition to current therapeutic options, a number of new treatment approaches for NIU-PS are on the horizon.

Traditional Local Treatment

In most cases, the initial treatment for NIU-PS is corticosteroids. For uveitis, these may be administered locally or systemically. Current local options for corticosteroid administration include ophthalmic drops, local

injection (sub-Tenon's or intravitreal) and implants (the dexamethasone intravitreal implant [Ozurdex, Allergan] and the fluocinolone acetonide intravitreal implant [Retisert, Bausch + Lomb]). In addition to risks from the individual form of administration (such as globe perforation for sub-Tenon's injection and endophthalmitis for intravitreal injection), side effects of local ophthalmic corticosteroids include a high rate of cataract and complications due to increased intraocular pressure.⁴

New Delivery Systems

Currently, there are two studies looking at novel delivery approaches for corticosteroids to treat non-infectious uveitis. The PEACHTREE (Clearside Biomedical) study is a Phase III, randomized, masked, multicenter, controlled clinical trial to study the safety and efficacy of a triamcinolone acetonide suspension injected into the suprachoroidal space of subjects with macular edema associated with non-infectious uveitis. This study is designed to evaluate whether injections every 12 weeks

may provide control of uveitic macular edema with fewer side effects than sub-Tenon's or intravitreal steroid injections.

Iontophoresis is the use of an electric current to help propel molecules across the hydrophilic cornea epithelium, classically the largest barrier to drug penetration into the eye. This would theoretically increase the bioavailability of the steroid medication, allowing greatly reduced dosing frequency and increased efficacy as compared to topical corticosteroids. This method has the advantage of not being associated with many of the needle-related risks of other local treatments. EyeGate Pharmaceuticals is currently examining iontophoresis for the delivery of dexamethasone into the eye to treat anterior non-infectious uveitis.

Intravitreal Sirolimus

Sirolimus is an immunomodulating agent that works via the mTOR pathway, reducing the number of active T-cells and the amount of inflammatory cytokines. Oral sirolimus has been shown to be effective

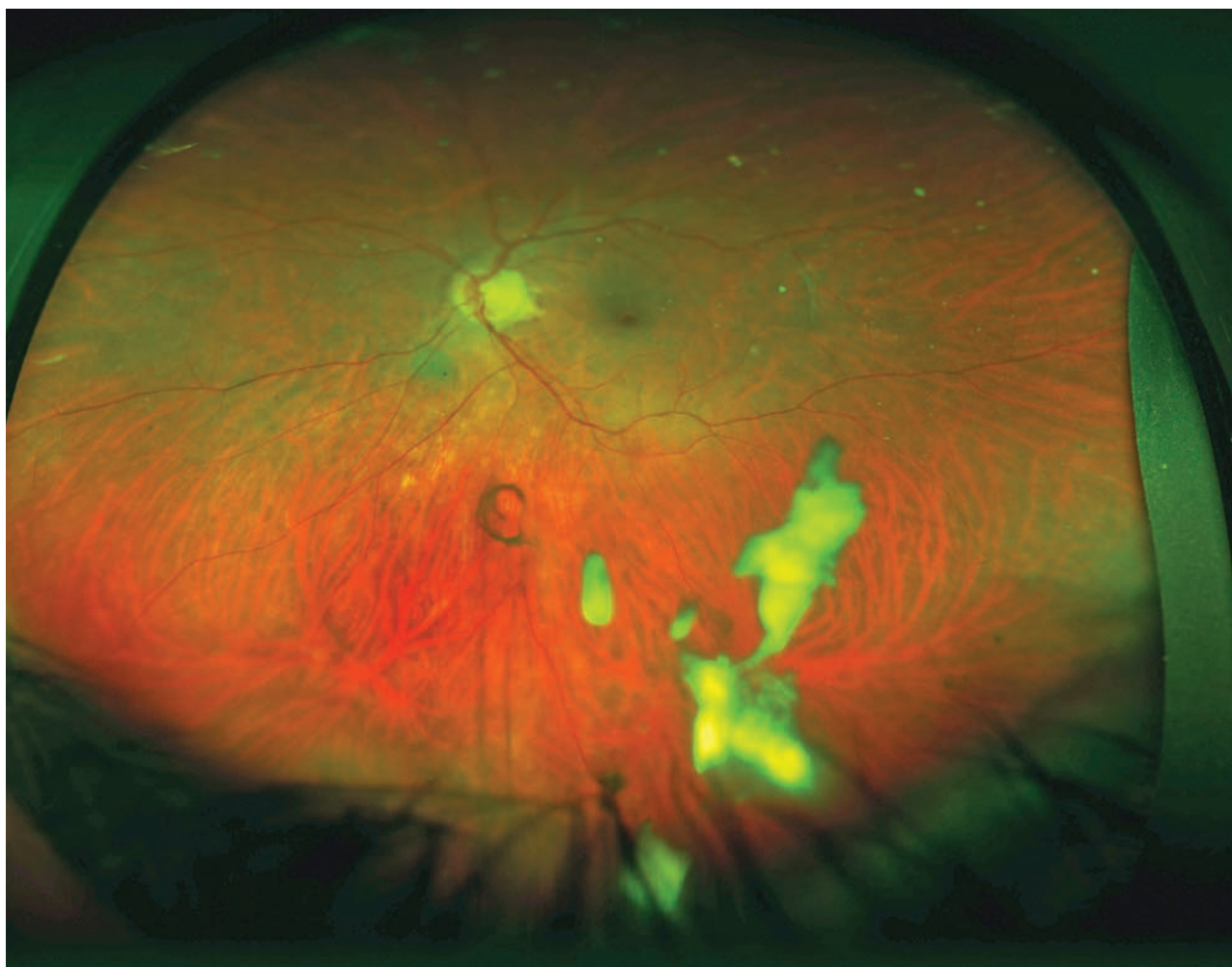


Figure 1. An intravitreal depot of sirolimus 14 days after injection.

for treating non-infectious posterior uveitis, but its side-effect profile and need for laboratory monitoring make it a less desirable treatment choice.⁵ A hydrophobic intravitreal formulation of sirolimus, which forms a depot lasting approximately two months in the vitreous (*See Figure 1*) has been evaluated in the SAKURA (Sirolimus study Assessing double-masKed Uveitis tReAtment) I and II studies (Santen Pharmaceuticals). In December of last year, the FDA informed Santen that its intravitreal sirolimus application wasn't approvable in its current form, and the agency would need additional evidence of efficacy.

The SAKURA I results were pub-

lished in 2016. This study examined 347 patients who received 44, 440 or 880 micrograms of sirolimus intravitreally. Patients were required to be off of all systemic immunomodulatory medications, except for oral steroids, which were rapidly tapered at the start of the study per protocol. The main study outcome was the proportion of patients with no vitreous haze at the end of the study. Overall, 22.8 percent in the 440-microgram group, 16.4 percent in the 880-microgram group and 10.3 percent in the 44-microgram group met this outcome at the five-month endpoint. Secondary outcomes were vitreous haze amounts of zero or 0.5+, corticosteroid ta-

pering success and best-corrected visual acuity. For the zero to 0.5+ vitreous haze outcome, 53 percent in the 440-microgram, 43 percent in the 880-microgram and 35 percent in the 44-microgram group met this broader vitreous haze outcome. Of the 69 patients on systemic corticosteroids at the start of the study, the proportion able to wean off of corticosteroids was 77 percent in the 440-microgram, 67 percent in the 880-microgram and 64 percent in the 44-microgram groups. Mean visual acuity was maintained in each group.⁶

What is potentially exciting about intravitreal sirolimus is the lower rate of ocular side effects compared to

intravitreal corticosteroids. In the study, there was a low rate of cataract and IOP change. The most common ocular adverse events were inflammatory, and there were some instances of opaque drug depot in the visual axis. There were no systemic serious adverse events related to the drug.

Systemic Treatments

Oral prednisone is very effective for the treatment and prevention of recurrence in NIU-PS. In addition to the ophthalmic side effects mentioned above, however, oral prednisone can lead to a multitude of systemic side effects, including hyperglycemia, dyslipidemia, hypertension; osteoporosis and fractures; immunosuppression and gastric reflux.

In addition to corticosteroids, other traditional options for systemic treatment include antimetabolites, T-cell inhibitors and alkylating agents. The antimetabolites include methotrexate and mycophenolate mofetil and tend to be the first-line agents for steroid-sparing systemic treatments due to their relatively favorable side-effect profile. Cyclosporine and tacrolimus are T-cell inhibitors that can be associated with hypertension and nephrotoxicity. Cyclophosphamide and chlorambucil are alkylating agents that are used for uveitis associated with severe systemic disease, such as granulomatosis with polyangiitis. Their side effects include pancytopenia, hemorrhagic cystitis and malignancies.

The Multicenter Uveitis Steroid Treatment (MUST) trial compared systemic anti-inflammatory therapy to sustained-release corticosteroid implants for NIU-PS. This longitudinal study showed that although local therapy led to faster control of inflammation, after seven years the systemic medication group had better visual acuity outcomes. The implant therapy eyes had statistically signifi-

cantly higher rates of complications related to IOP and cataracts, while the systemic therapy group had a significantly higher rate of infections requiring treatment.^{4,7}

New Systemic Options

Adalimumab (Humira, AbbVie) is a tumor necrosis factor alpha inhibitor given by subcutaneous injection. It has been used for more than a decade for inflammatory conditions such as rheumatoid arthritis, psoriasis and Crohn's disease. The VISUAL I and II trials showed benefit of adalimumab for patients with active and inactive NIU-PS, respectively, requiring systemic prednisone.^{8,9} Patients receiving adalimumab (80 mg loading dose followed by 40 mg every other week) were half as likely to fail steroid taper than those receiving placebo. Use of adalimumab was also associated with an approximately doubled time to treatment failure as compared to placebo. Based on VISUAL I and II, in 2016 the FDA expanded the indications of adalimumab to include NIU-PS.

Other Biologics

The STOP-UVEITIS study is currently evaluating tocilizumab (an anti-interleukin-6 antibody) for patients with non-infectious uveitis. This study looks at monthly IV infusions of tocilizumab in two doses and is scheduled to conclude in December of 2017 (<https://clinicaltrials.gov/ct2/show/NCT01717170>). Secukinumab is an anti-interleukin 17A antibody that was shown to be effective in quieting posterior uveitis and improving remission rates.¹⁰ Intravenous treatment was more effective than subcutaneous treatment. Sarilumab is another anti-IL-6 antibody that resulted in decreased vitreous haze and decreased oral steroid dosing when given subcutaneously every two weeks.¹¹

In conclusion, though NIU-PS continues to be a challenging condition to treat, there continue to be more therapeutic options. For local treatment, intravitreal Sirolimus may become available soon and, systemically, adalimumab is a newly approved FDA option. Also, there are many therapeutics in the pipeline that offer novel agents and new ways to use traditional drugs. **REVIEW**

Dr. Atchison is a fellow at Illinois Retina Associates and Rush University, Chicago. Dr. Merrill is a partner at Illinois Retina Associates and an assistant professor in ophthalmology at Rush. Dr. Atchison may be reached at elizabethatchison@gmail.com. Dr. Merrill may be contacted at pauline.merrill@gmail.com. They'd like to thank Quan Dong Nguyen, MD, for his contributions to the article.

1. Acharya NR, Tham VM, Esterberg E, et al. Incidence and prevalence of uveitis: Results from the Pacific ocular inflammation study. *JAMA Ophthalmol* 2013;131:11:1405-12.
2. Dick AD, Tundia N, Sorg R, et al. Risk of ocular complications in patients with noninfectious intermediate uveitis, posterior uveitis, or panuveitis. *Ophthalmology* 2016;123:3:655-62.
3. Frick KD, Drye LT, Kempen JH, et al. Associations among visual acuity and vision- and health-related quality of life among patients in the multicenter uveitis steroid treatment trial. *Invest Ophthalmol Vis Sci* 2012;53:3:1169-76.
4. Multicenter Uveitis Steroid Treatment (MUST) Trial Research Group, Kempen JH, Altaweel MM, et al. Randomized comparison of systemic anti-inflammatory therapy versus fluocinolone acetonide implant for intermediate, posterior, and panuveitis: The multicenter uveitis steroid treatment trial. *Ophthalmology* 2011;118:10:1916-26.
5. Shanmuganathan VA, Casely EM, Raj D, et al. The efficacy of sirolimus in the treatment of patients with refractory uveitis. *Br J Ophthalmol* 2005;89:6:666-9.
6. Nguyen QD, Merrill PT, Clark WL, et al. Intravitreal sirolimus for noninfectious uveitis: A phase III sirolimus study assessing double-masked uveitis Treatment (SAKURA). *Ophthalmology* 2016;123:11:2413-23.
7. Writing Committee for the Multicenter Uveitis Steroid Treatment (MUST) Trial and Follow-up Study Research Group, Kempen JH, Altaweel MM, et al. Association between long-lasting intravitreal fluocinolone acetonide implant vs. systemic anti-inflammatory therapy and visual acuity at 7 years among patients with intermediate, posterior, or panuveitis. *JAMA* 2017;317:19:1993-2005.
8. Jaffe GJ, Dick AD, Brezin AP, et al. Adalimumab in patients with active noninfectious uveitis. *N Engl J Med* 2016;375:10:932-43.
9. Nguyen QD, Merrill PT, Jaffe GJ, et al. Adalimumab for prevention of uveitic flare in patients with inactive noninfectious uveitis controlled by corticosteroids (VISUAL II): A multicentre, double-masked, randomised, placebo-controlled phase 3 trial. *Lancet* 2016;388:10050:1183-92.
10. Letko E, Yeh S, Foster CS, et al. Efficacy and safety of intravenous secukinumab in noninfectious uveitis requiring steroid-sparing immunosuppressive therapy. *Ophthalmology* 2015;122:5:939-48.
11. de Smet m, Sundaram P, Erickson K, et al. Variability in vitreous haze grading technique using a 9-step logarithmic scale in patients enrolled in the sarilumab in noninfectious uveitis (SARIL-NIU), the SATURN study. In ARVO Proceedings; 2016.

SAVE THE DATE



2018 Ophthalmology Update

FEBRUARY 17-18, 2018 • CARLSBAD, CALIFORNIA

An interdisciplinary faculty of ophthalmic subspecialists will review the continuing progress in Cataract and Refractive Surgery, Glaucoma, Retina, Neuro-Ophthalmology, Pediatric Ophthalmology, Ocular Surface Disease, Cornea and Oculoplastics.

LOCATION

Cape Rey Carlsbad, A Hilton Hotel

1 Ponto Road, Carlsbad, CA

P: (760) 602-0800

Limited rooms reserved at \$209/night.
Please visit registration site for reservation information.

PROGRAM CHAIRS

Don O. Kikkawa, MD, FACS

Robert N. Weinreb, MD

DISTINGUISHED

INVITED SPEAKERS

C. Gustavo De Moraes, MD

Audrey Ko, MD

Dan Schwartz, MD

Jonathan Song, MD, MBA

Benjamin Xu, MD, PhD

PROGRAM TIMES

Saturday, February 17

8:00am — 5:00pm

Reception to follow

Sunday, February 18

8:00am — 12:15pm

KEYNOTE SPEAKER

Larry Smarr, PhD

UCSD SPEAKERS

Natalie Afshari, MD

Andrew S. Camp, MD

Daniel L. Chao, MD, PhD

William R. Freeman, MD

Michael H. Goldbaum, MD

Weldon W. Haw, MD

Chris W. Heichel, MD

Bobby S. Korn, MD, PhD

Eric D. Nudleman, MD, PhD

Shira L. Robbins, MD

Peter J. Savino, MD

Derek S. Welsbie, MD, PhD

Kang Zhang, MD, PhD

EARLY BIRD SPECIAL: \$95*

FOR MORE INFORMATION

www.reviewofophthalmology.com/Update2018

Email: Reviewmeetings@jobson.com

Phone: 855-851-9964

*See event website for additional information.

Accreditation Statement

This activity has been planned and implemented in accordance with the accreditation requirements and policies of the Accreditation Council for Continuing Medical Education (ACCME) through the joint providership of Amedco and Postgraduate Health Education, LLC (PHE). Amedco is accredited by the ACCME to provide continuing medical education for physicians.

Credit Designation Statement

This meeting is approved for *AMA PRA Category 1 Credits™*.

Shiley Eye Institute
UC San Diego

Jointly provided by



PHE

Review of Ophthalmology®

24TH ANNUAL

OPHTHALMIC

Product Guide



Innovative products to
enhance your practice

The **future**
is in your
hands. One
tap, many
possibilities.

Experience the digital edition on your handheld device.
Use your smart device to scan the code below or visit:



www.reviewofophthalmology.com/publications/archive

Download a QR scanner app. Launch app and hold your mobile device over
the code to view www.reviewofophthalmology.com/publications/archive.

REVIEW[®]
of Ophthalmology

Corneal Marking For Toric IOLs

Researchers from the University Eye Hospital in Munich, Germany, designed a prospective case series to compare the visual outcomes, alignment accuracy and surgical time between two methods of implanting toric intraocular lenses.

The study included 29 patients (57 eyes) having cataract surgery with implantation of a toric IOL (Torbi 709 M). They were randomly assigned to one of two groups based on the marking system used (manual or digital). Patients were included if they had age-related cataract and regular corneal astigmatism of 1.25 D or higher. Visual and refractive outcomes, as well as rotational stability, were evaluated. Vector analysis was performed to evaluate total astigmatic changes.

There were 28 eyes in the manual group and 29 eyes in the digital group. The mean toric IOL misalignment was significantly lower in the digital group than in the manual group (2.0 ± 1.86 vs. 3.4 ± 2.37 degrees; $p=0.026$). The mean deviation from the target induced astigmatism was significantly lower in the digital group (0.10 ± 0.08 vs. 0.22 ± 0.14 D; $p=0.008$). During surgery, the mean toric IOL alignment time was significantly shorter in the digital group (37.2 ± 11.9 vs.

59.4 ± 15.3 seconds; $p=0.003$). In addition, the mean overall time required to perform the surgery was significantly shorter in the digital group (727.2 ± 198.4 vs. $1,110.0 \pm 382.2$ seconds; $p<0.001$).

Based on the results of this study, the researchers say that the digital tracking approach for toric IOL alignment is an efficient and safe way to improve refractive outcomes. Furthermore, they say that image-guided surgery helps streamline the workflow in refractive cataract surgery.

J Cataract Refract Surg
2017;43:1281-1286

Mayer WJ, Kreutzer T, Dirisamer M, et al.

Lamina Cribrosa Thickness in Patients with Keratoconus

In a cross-sectional, observational study comprising 45 patients with keratoconus and 56 healthy subjects, researchers from the department of ophthalmology at the Kayseri Training and Research Hospital in Kayseri, Turkey, evaluated the thickness and depth of the lamina cribrosa in the optic nerve head region of the eyes in patients with nonglaucomatous keratoconus to compare the thickness and depth with those of age-matched controls. Analysis of LC imaging was performed using spectral-

domain optical coherence tomography. Data collected included spherical equivalent, central corneal thickness, axial length, intraocular pressure and keratometry.

Eyes with keratoconus had significantly thinner LC (174.9 ± 11.4 vs. 249.1 ± 4.9 μm , $p<0.001$) compared with control-group eyes. There was no statistically significant difference in the depth of LC between the keratoconus and control groups ($p=0.3$). Multivariable analysis, controlled for age and sex, showed that the thickness of LC significantly correlated with central corneal thickness ($p<0.001$). This association persisted ($p<0.001$) after controlling for intraocular pressure, in addition to age and sex. There were no significant correlations with other factors, including the spherical equivalent ($p=0.93$) and keratometry ($p=0.46$).

The researchers note that the study showed that optical coherence tomography measurement of LC revealed thinner LC for patients with keratoconus compared with healthy controls, and speculate that the structural properties of the cornea may be related to the optic nerve.

Cornea 2017;36:1509-1513
Akkaya S, K u c uk B.


ENRICH YOUR PRACTICE

Review of Ophthalmology delivers current and comprehensive information focusing on topics such as disease diagnosis, surgical techniques and new technologies.

The *Review Group's Ophthalmic Product Guide* brings you the latest products and technology on the market. Published every February and July.



The *Review Group* also distributes a variety of supplements, guides and handbooks with your subscription to *Review of Ophthalmology*. These publications are designed to keep you informed on what's new and innovative in the industry on topics ranging from cataract refractive surgery to ocular surface disease.

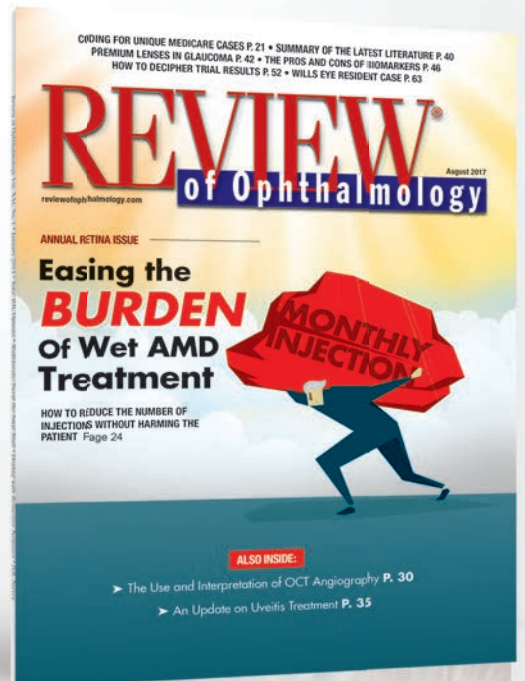

The *Review Group* also offers valuable continuing medical education sessions in both print and online formats, allowing a convenient way for you to earn CME credits. In addition, we also offer an impressive fleet

of free e-newsletters—such as *Review of Ophthalmology Online* and *Review of Ophthalmology's Retina Online*—so you can keep up to date on breaking news and the latest research.



The *Review Group* offers eyecare practitioners quality informational resources dedicated to the growth and education of the profession. The *Review Group* offers a variety of print and online products to enrich your patient care and practice needs.



The *Review Group* also spearheads meetings and conferences, bringing together experts in the field and providing a forum for practitioners that allows you to educate, and learn from others in the profession. These meetings cover a broad range of topics in the form of educational or promotional roundtables and forums.

Aerie's Rhopressa Recieves FDA Approval

Aerie Pharmaceuticals recently announced FDA approval for Rhopressa 0.02% for lowering intra-ocular pressure in patients with open-angle glaucoma or ocular hypertension.

Rhopressa is a once-daily eye drop that the company says reduces IOP by increasing the outflow of aqueous humor through the trabecular meshwork.

The three clinical trials for Rhopressa demonstrated up to 5 mmHg reductions in IOP for subjects treated once daily in the evening. For patients with baseline IOP <25 mmHg, the IOP reductions with Rhopressa dosed once daily were similar to those with timolol 0.5% dosed twice daily. For patients with baseline IOP equal to or above 25 mmHg, however, Rhopressa resulted in smaller mean IOP reductions at the morning time points than timolol 0.5% for study visits on days 43 and 90; the difference in mean IOP reduction between the two treatment groups was as high as 3 mmHg, favoring timolol.

The most common ocular adverse reaction observed in controlled clinical studies with Rhopressa dosed once daily was conjunctival hyperemia, which was reported in 53 percent of patients.

For more information on Rhopressa, visit aeriepharma.com.

Expanded Parameters for Avaira Vitality Toric

In mid-December, CooperVision announced the nationwide availability of expanded parameters for its Avaira Vitality toric two-week contact lenses, which now include plus powers, high minus powers and a -2.25-D cylinder.

The toric is made from a new silicone hydrogel material (fanfilcon A) and has a high water content and high level of oxygen permeability and transmissibility, the company says. CooperVision adds that the UV protection has also been improved to Class I, which means that the lenses now block more than 90 percent of UVA and 99 percent of UVB rays.

Avaira Vitality toric is now available in a power range of +8 to -10 D, with cylinder options of -0.75, -1.25, -1.75 and -2.25 D in axes from 10 to 180 degrees in 10-degree steps. The base curve is 8.5 mm and the diameter is 14.5 mm.

For more information, visit cooper-vision.com/contact-lenses/avaira-vitality.

Volk Optical's Next-Gen Lens Cases

Volk Optical has announced the launch of a new case design for its line of diagnostic and therapeutic ophthalmic lenses. It says that the case enhances the durability and look



of its classic case design.

The case has a design that has been engineered to withstand 50,000 openings without hinge breakage, Volk says. There is a thermoplastic rubber insert cushion in the case and a magnetic closure that holds the case shut.

Volk says that its digital series, BIO, slit lamp, laser, surgical and specialty treatment lenses are all available with the new case. The case exteriors are color-coordinated by lens family and clearly labeled with the lens name. The cover plate can also be custom engraved with doctor or practice name. Volk adds that the molded plastic exterior and interior insert are easy to wipe clean. Additionally, the nonslip stabilizing feet hold the case firmly in place.

For more information on Volk's lens cases, visit volk.com.

Practice For Sale



Practice Sales • Appraisals • Consulting
www.PracticeConsultants.com

**PRACTICES FOR SALE
NATIONWIDE**

Visit us on the Web or call us to learn more about our company and the practices we have available.

info@PracticeConsultants.com

800-576-6935

www.PracticeConsultants.com

Career Opportunities

OPHTHALMOLOGISTS
Danbury, CT

Ophthalmologists to share office with long standing Ophthalmologist in Danbury, CT. High quality equipment. \$2,250 per month or adjoining office without equipment- \$1,750 per month.

**203-545-3539 or
email mehrimd@aol.com**



**FOR CLASSIFIED
ADVERTISING
CONTACT US TODAY:**

Toll free: **888-498-1460**

E-mail: sales@kerhgroup.com



Career Opportunities



Targeting
Ophthalmologists?

**CLASSIFIED ADVERTISING
WORKS**



Contact us today
for classified advertising:
Toll free: **888-498-1460**
E-mail: sales@kerhgroup.com



FIND MORE PRACTICES FOR SALE ON



CONTACT US TODAY to list your practice:
888-498-1460
opticlassifieds@kerhgroup.com

www.opticlassifieds.com



Amelanotic fundus mass in a 73-year-old woman: metastasis or something else?

Austin R. Meeker, MD and Carol L. Shields, MD

Presentation

A 73-year-old Caucasian woman with gradual onset of blurred vision and pressure sensation in her left eye for two months presented for ophthalmic evaluation. She had a worsening of chronic headaches and new onset of floaters in the left eye, as well. She initially described her symptoms to her primary care provider who referred her to an optometrist. The optometrist saw a suspicious choroidal lesion on dilated examination of the left eye and referred her to a retinal specialist, who subsequently referred the patient to an ocular oncology specialist to rule out choroidal malignant melanoma.

Medical History

Past ocular history included cataract extraction with placement of an intraocular lens in the right eye one year prior and primary open angle glaucoma of both eyes that had been managed with latanoprost. Past medical history included hypertension and hyperlipidemia. Systemic medications included aspirin, simvastatin, metoprolol tartrate, famotidine, progesterone, montelukast, fluticasone nasal inhalation and sumatriptan. Family history was relevant for lung and colon cancer in the father. Social history was relevant for substantial secondhand smoke exposure but no personal history of smoking.

Examination

On examination, visual acuity was 20/20 in each eye. Pupils were symmetric and without afferent pupillary defect. Intraocular pressures were 13 mmHg in the right eye and 14 mmHg in the left. Extraocular movements were full bilaterally and confrontation visual fields were full in both eyes.

On examination of the anterior segment, the right eye revealed a posterior chamber intraocular lens, and the left eye had mild nuclear sclerosis and anterior cortical changes. Dilated fundus examination of the right eye demonstrated normal macula, disc, vessels and periphery, with a cup/disc ratio of 0.6 and evident posterior vitreous detachment. The left fundus was similar, with a normal macula and a cup/disc ratio of 0.6. However, in the inferior quadrant, there was an ill-defined yellow mass deep in the retina, measuring 16 x 14 mm in diameter and associated with shallow subretinal fluid, surrounding retinal pigment epithelial alterations and a large RPE detachment (*Figure 1*).

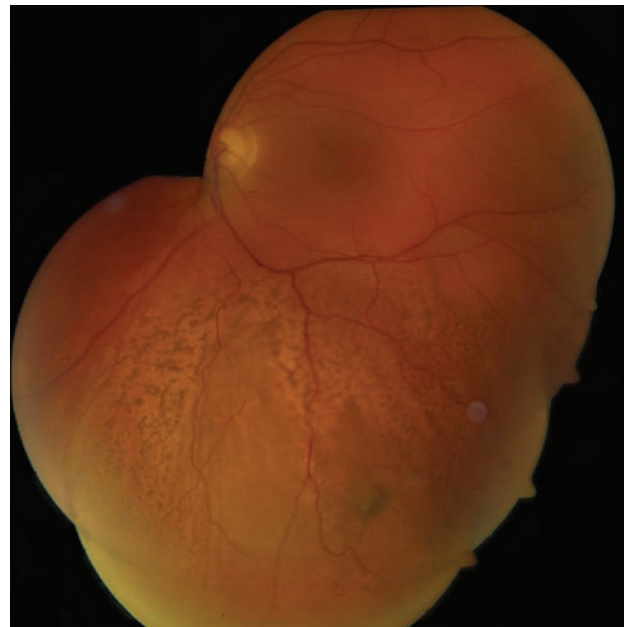


Figure 1. Montage color fundus photo of the left eye at the patient's first visit to the ocular oncology clinic. An ill-defined, 16 x 14-mm amelanotic mass is present inferior to the inferior arcade, disrupting the retinal pigment epithelium.

What is your diagnosis? What further workup would you pursue? The diagnosis appears on p. 63.

Workup, Diagnosis and Treatment

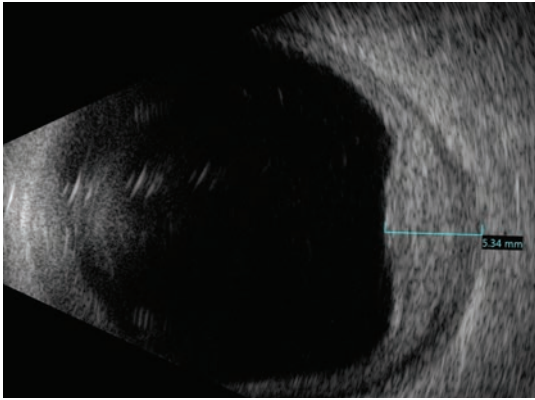


Figure 2. B-scan ultrasonography of the left eye at the first visit. A 5.3-mm, elevated, hyperdense mass is present with thickening of the choroid and sclera. There is associated sub-Tenon's fluid outside the sclera.

Further investigation was performed with ultrasonography, optical coherence tomography and autofluorescence. B-scan ultrasonography demonstrated an echodense choroidal lesion measuring 5.3 mm in thickness with subtle lucency immediately outside the globe, lining the sclera (Figure 2). OCT revealed a mass with a “lumpy-bumpy” surface contour and compression of the choriocapillaris, a peculiar retinal pigment epithelium detachment and surrounding subretinal fluid (Figure 3). Fundus autofluorescence demonstrated alternating hyper- and hypofluorescence overlying the mass, suggestive of RPE mottling and perhaps lipofuscin pigment (Figure 4).

The presence of a non-pigmented fundus mass raised suspicion for choroidal metastasis or amelanotic choroidal

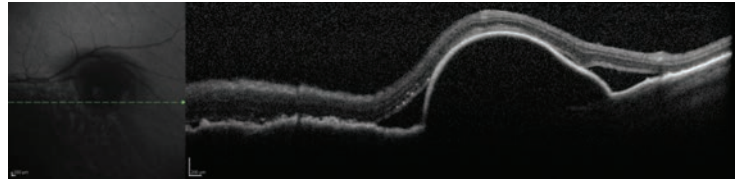


Figure 3. Ocular coherence tomography of the fundus mass in the left eye on the date the patient was first seen. The anterior face of the mass has a lumpy-bumpy contour with compression of the choriocapillaris. There's an associated pigment epithelial detachment with surrounding subretinal fluid.

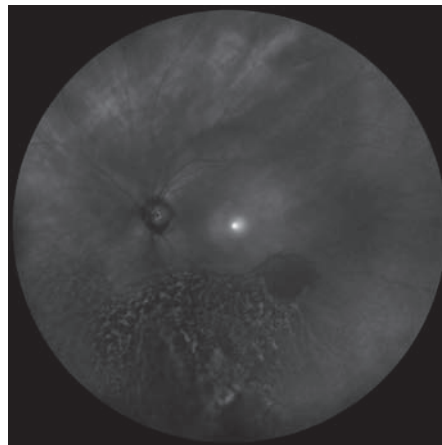


Figure 4. Fundus autofluorescence of the left eye on the date the patient was first seen. The inferior fundus mass demonstrates alternating hyper- and hypofluorescence consistent with RPE mottling, lipofuscin pigment disturbance and chorioretinal folds on the posterior margin.

malignant melanoma. An investigation for systemic malignancies was initiated and fine needle aspiration biopsy (FNAB) was performed. Chest radiograph demonstrated linear scarring and atelectasis with no evident tumor. CT of the head and chest with and without contrast were normal and MRI of the abdomen revealed only fatty liver. A mammogram was within normal limits. FNAB revealed rare atypical epithelioid cells which were non-diagnostic.

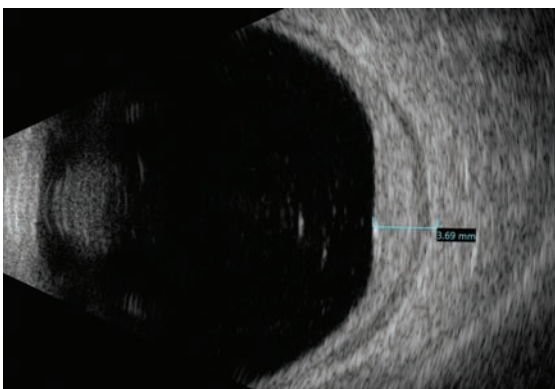


Figure 5. B-scan ultrasonography of the left eye two weeks after initiating a trial of systemic steroids. There is interval decrease in size and thickness of the echodense fundus mass and a decrease in sub-Tenon's fluid.

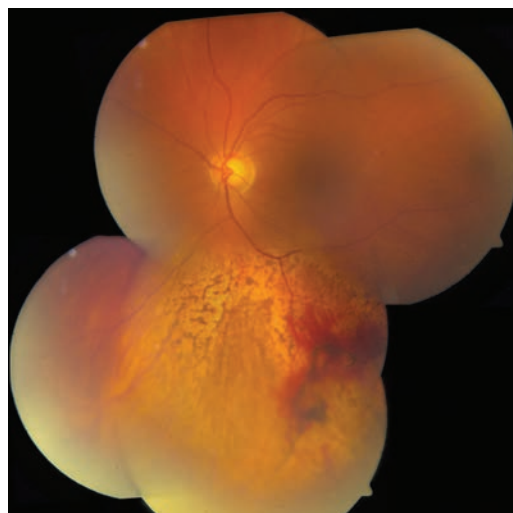


Figure 6. Montage color fundus photo of the left eye two weeks after a trial of systemic steroids. There is interval decrease in size of the mass. Vitreous hemorrhage is present along the temporal edge of the mass secondary to the fine needle aspiration biopsy.

On re-examination and review of available data, particularly with her history of chronic headache and ocular “pressure feeling,” and the ultrasound features of echolucency rimming the posterior sclera (T-sign), the differential diagnosis was broadened to include scleritis. The OCT appearance of a lumpy-bumpy surface was consistent with metastatic disease; however, extensive systemic workup revealed no evidence of primary tumor.

Discussion

There is a broad differential diagnosis for an elevated choroidal mass, particular those that are amelanotic. In the present case, choroidal neoplasia remained an important and “must-not-miss” consideration in the differential diagnosis, including both primary and metastatic tumors. Malignant melanoma is the most common primary intraocular malignant neoplasm in adults; however, clinicians should realize that choroidal metastasis is perhaps the most common intraocular malignancy in adults, particularly when considering all tumors.¹ The mass discussed here had features suggestive of both amelanotic melanoma and choroidal metastasis, given the lack of pigmentation and fairly asymptomatic presentation. OCT was more consistent with choroidal metastasis in that the tumor demonstrated a lumpy-bumpy surface contour—a feature strongly suggestive of choroidal metastasis, effusion and inflammation, but not necessarily melanoma. In a series of 31 eyes with choroidal metastasis, the characteristic lumpy-bumpy anterior contour of the mass was present in 64 percent, and compression of the choriocapillaris in 93 percent. This lumpy-bumpy surface was identified in the current case, strongly biasing the evaluation towards metastatic disease.²

B-scan ultrasonography can also aid in identification of the underlying tumor. In this case, the mass was echodense, consistent with choroidal metastasis as well as inflammation and other tumors, whereas choroidal melanoma would typically reveal echolucency. With these concerning features, systemic evaluation for a primary malignancy was instituted. In a series of 520 uveal metastases, more than 66 percent of primary tumors identified were of breast- or lung-cancer origin.³ However, there were a substantial number of cases (17 percent) for which a primary malignancy wasn’t identified.³ In the present case, mammography and chest radiograph were unremarkable, as were additional systemic studies including MRI of the abdomen and CT of the brain.

In cases of intraocular tumors without a clear diagnosis from clinical examination and non-invasive

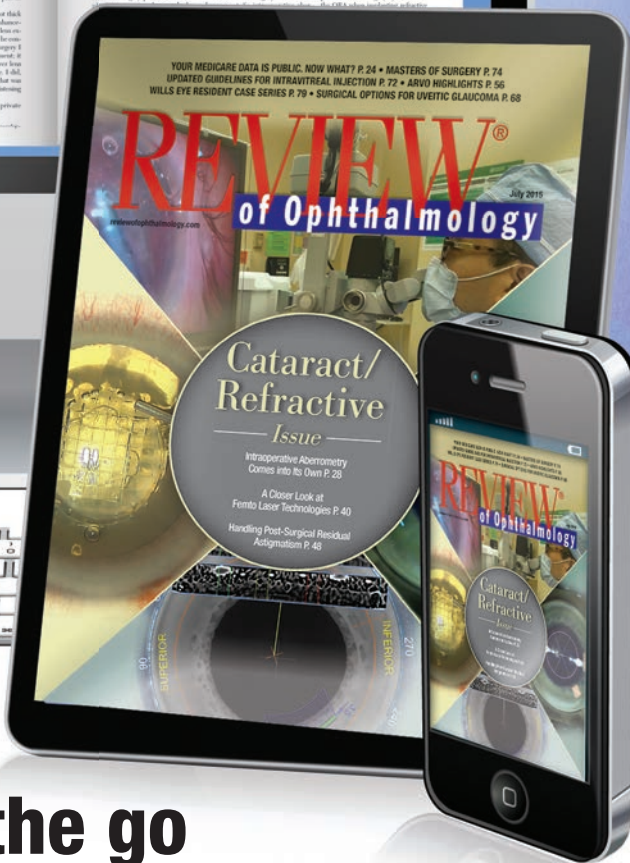
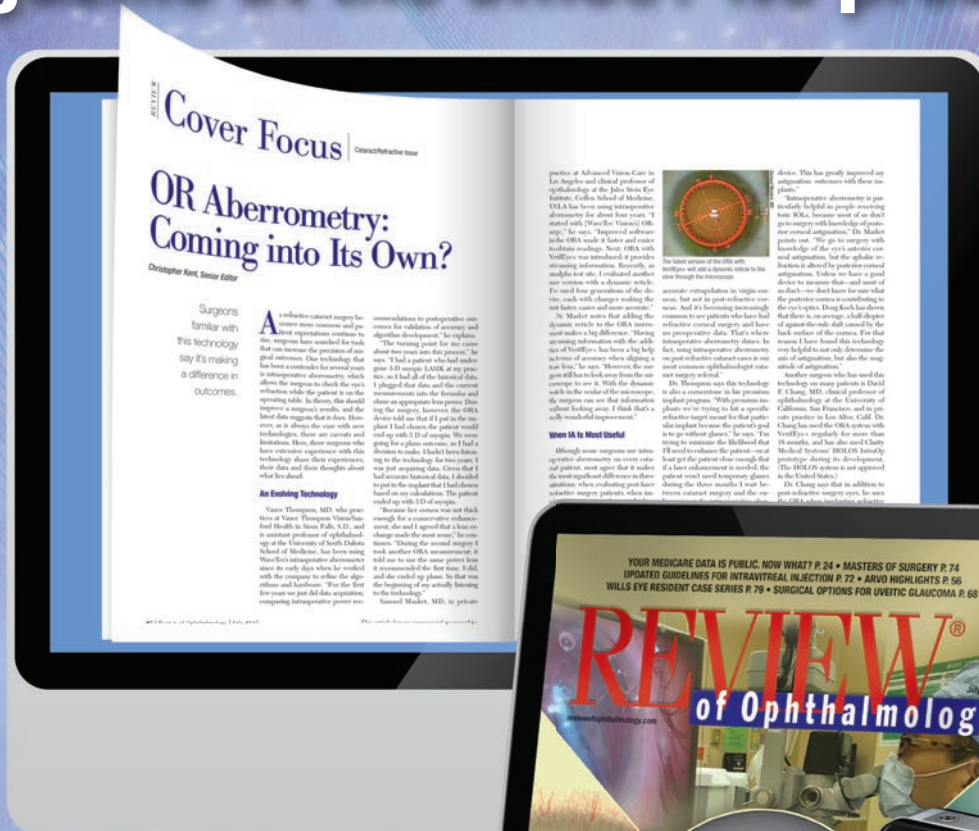Posterior scleritis was highly considered as a potential diagnosis and a trial of systemic corticosteroids was begun with close follow-up. After two weeks of treatment consisting of prednisone 60 mg daily, there was reduction of the amelanotic mass from 5.3 mm thickness to 3.7 mm (*Figure 5*), along with improvement of symptoms and the appearance of the retinal pigment epithelium detachment (*Figure 6*).

studies alone, cytopathologic diagnosis via FNAB can be employed. This proves particularly useful in amelanotic tumors that can be difficult to distinguish between amelanotic melanoma and other neoplasms, as well as lesions concerning for metastases with an unremarkable systemic workup, as in our patient.⁴ In a review of 159 patients undergoing FNAB for intraocular tumors, 140 samples provided sufficient cytopathologic material for diagnosis with 100-percent sensitivity. The remaining 19 samples demonstrated a paucity of cells resulting in a decrease to 84-percent sensitivity.⁴ In our patient, FNAB revealed rare atypical epithelioid cells with insufficient quantity for immunological studies and cytopathological diagnosis. This prompted a reassessment of the case with broadening of the differential diagnosis, including inflammatory conditions such as posterior scleritis.

Posterior scleritis is a great mimicker of ophthalmic disease. Patients with posterior scleritis may or may not have a red eye, pain, peribulbar edema or other classic signs. Posterior scleritis can also present as serous retinal detachment, macular edema, optic nerve edema or annular choroidal detachment leading to acute angle closure, which are atypical findings for the classic case.⁵ Further hiding its detection, posterior scleritis can present with substantial pain, blurred vision, redness and/or significant vitritis, or be completely asymptomatic.⁵ In the current case, the patient noted left eye “pressure,” but didn’t classify it as pain. This initial piece of evidence can be less suggestive of neoplasia, but it should be noted that choroidal melanoma can occasionally cause pain. Choroidal metastasis, especially from lung cancer, can also produce pain, further complicating the diagnostic investigation.^{3,5}

One of the most important imaging modalities in the evaluation of a fundus mass is ultrasonography. Along with measuring tumor thickness, ultrasonography allows for characterization of tumor echodensity. Unlike melanoma, which is typically echolucent, both scleritis and choroidal metastases are echodense. In closer

Left your *Review of Ophthalmology* magazine at the office? No problem!



Read *Review* on the go from any mobile device!

Simply go to www.reviewofophthalmology.com and click on the digimag link to get your current issue.

examination, one can identify another feature of scleritis, the characteristic T-sign caused by sub-Tenon's edema surrounding the optic nerve and posterior sclera that takes on a T-shaped configuration.⁵ Others have found the T-sign on B-scan ultrasonography to be useful for diagnosis of posterior scleritis, particular in those under suspicion for choroidal melanoma.⁶ In the present case, the T-sign was present in a different fashion as the sub-Tenon's fluid was primarily seen outside the inferiorly located mass, rather than at the posterior pole around the optic nerve. Despite the classic appearance of the T-sign in posterior scleritis, a recent study of 114 patients with posterior scleritis found this sign in only 41 percent of patients.⁷ In that series, the most common ultrasonographic feature of scleritis was echodensity with thickening of the sclera and choroid as seen in our patient.⁷ B-scan ultrasonography can also be useful in identifying additional suggestive features of posterior scleritis including an eyewall thickness greater than 2 mm and scleral nodules.⁸

Once diagnosed, posterior scleritis is a treatable condition with oral or periocular corticosteroids or non-steroidal anti-inflammatory medications, leading to improvement in pain and visual acuity. Despite variation in medications, anti-inflammatory therapy is the mainstay of treatment. In the aforementioned series of 114 cases of posterior scleritis, treatment ranged from topical corticosteroids to systemic immunomodulatory therapies such as mycophenolate and azathioprine.⁷ Most commonly, however, patients were treated with systemic non-steroidal anti-inflammatory drugs or systemic corticosteroids as in the present case.⁷ Across all specific treatments, the mean time to remission, which is defined as no disease activity 90

days after stopping all immunosuppressive treatments, was 210 days with a 15-percent risk of relapse.⁷ This risk of relapse wasn't significantly different between idiopathic cases or cases found to be associated with other systemic inflammatory conditions, such as rheumatoid polyarthritis and systemic lupus erythematosus.⁷

Posterior scleritis can have a multitude of presentations, allowing it to mimic other more common pathologies. Despite its rarity, posterior scleritis is an important consideration in evaluation of a fundus mass, especially in those cases without a clear diagnosis. In the present case, the patient's amelanotic mass was echodense on ultrasonography, and an unremarkable FNAB and systemic workup made neoplasia less likely. With improvement in symptoms and remission with immunosuppressive treatment, posterior scleritis remains a treatable condition. Therefore, this case of a 73-year-old woman with an amelanotic fundus mass serves as a reminder of the importance of establishing a broad differential diagnosis. **REVIEW**

1. Recchia FM. Retinal and Choroidal Tumors. In: Fineman M, Ho A, eds. Color Atlas and Synopsis of Clinical Ophthalmology (Wills Eye Institute): Retina. Philadelphia: Lippincott Williams & Wilkins, 2012.
2. Al-Dahmash SA, Shields CL, Kaliki S, et al. Enhanced depth imaging optical coherence tomography of choroidal metastasis in 14 eyes. *Retina* 2014;34:1588-1593.
3. Shields CL, Shields JA, Gross NE, et al. Survey of 520 eyes with uveal metastases. *Ophthalmology* 1997;104:1265-1276.
4. Shields JA, Shields CL, Hormoz E, et al. Fine-needle aspiration biopsy of suspected intraocular tumors. *Ophthalmology* 1993;100:1677-1684.
5. Benson WE. Posterior scleritis. *Survey Ophthalmol* 1988;32:297-316.
6. Shinisha DP, Elangovan S, Puri SK, et al. Unusual presentation of posterior scleritis. *Health Sciences* 2016;5:54-57.
7. Lavric A, Gonzalez-Lopez JJ, Majumdar PD, et al. Posterior scleritis: Analysis of epidemiology, clinical factors, and risk of recurrence in a cohort of 114 patients. *Ocul Immunol Inflamm* 2016;24:6-15.
8. McClusky, PJ, Watson PG, Lightman S, et al. Posterior scleritis: Clinical features, systemic associations and outcome in a large series of patients. *Ophthalmology* 1999;106:2380-2386.

Akorn Pharmaceuticals 31, 41

Phone (800) 932-5676
www.akorn.com

Alcon Laboratories 2, 3, 35, 36

Phone (800) 451-3937
Fax (817) 551-4352

Bausch + Lomb 7, 8

Phone (800) 323-0000
Fax (813) 975-7762

Haag-Streit 33

Phone (800) 627-6286
Fax (603) 742-7217

Imprimis Pharmaceuticals, Inc. 5

Phone (858) 704-4040
Fax (858) 345-1745
www.imprimispharma.com

Johnson & Johnson Vision (formerly AMO) 68

www.vision.abbott

Keeler Instruments 67

Phone (800) 523-5620
Fax (610) 353-7814

Oculus, Inc. 19

Phone (888) 284-8004
Fax (425) 867-1881

S4OPTIK 21, 23

Phone (888) 224-6012

Shire Ophthalmics 13, 14

www.shire.com

SightLife Surgical 29

Phone (877) 726-7632
Fax (206) 682-8504
info@sightlifesurgical.com
www.sightlifesurgical.com

Sun Ophthalmics 25, 26

SunlOnTheRise.com

This advertiser index is published as a convenience and not as part of the advertising contract. Every care will be taken to index correctly. No allowance will be made for errors due to spelling, incorrect page number, or failure to insert.

(Continued from page 15)

This leaves these residual, untreated silicone monomers. In the study, we had the option to do two light adjustments, and when the refraction was dead-on, we'd do two mandatory lock-ins. But, with every treatment we do, the pupil seems to dilate less and less. I don't know why, but that's what we observed. There's a dilation fatigue that some of these eyes demonstrated. We had to use more and more dilating drops to get them up to the diameter of the lens.

"The worst thing I experienced in the study was a patient with a macular burn," Dr. Miller continues. "It happened because they had changed the supplier of the UV filter for the Light Delivery Device and the new filter was out of spec. The eye got exposed to more light than it was supposed to. The vision dropped to 20/150, but the patient recovered to 20/22 vision." Some other adverse events that emerged in the FDA review include 1.7 percent of patients who needed a secondary surgical intervention, which was significantly higher than the historical rate (0.5 percent). These SSIs consisted of the following:

- explant due to the faulty UV filter mentioned earlier;
- explant due to a scratch on the LAL optic that occurred during implantation; lens replacement was required three weeks postop, and the secondary procedure had complications (final BSCVA: 20/20);
- explantation because the subject requested lens replacement prior to light treatment (final BSCVA: 20/15);
- Descemet's stripping endothelial keratoplasty due to corneal edema caused by implantation problems (final BSCVA: 20/26.4);
- two incidences of lysing of iris adhesions (one accompanied by a sphincterotomy) to treat posterior synechiae that were limiting pupil dilation (final BSCVA: 20/17.4 in both

instances); and

- barrier laser treatment for hemorrhagic posterior vitreous detachment and a horseshoe retinal tear with sub-retinal fluid nine months postop (final BSCVA: 20/14.5).¹

At 12 months, one eye in the RxLAL group and four in the control group had a decrease of two or more lines of BSCVA.

A couple of adverse events unique to the RxLALs UV-light adjustment process were also investigated, namely red-tinted vision (erythroptosis) and color vision abnormalities. The highest rate of erythroptosis occurred prior to the second lock-in treatment, with 49 percent of patients reporting mild erythroptosis. This decreased to 17.7 percent at one week after that lock-in, and to 0.5 percent at six months. One patient (0.3 percent) had mild erythroptosis at the 12-month exam, but it resolved two months later.¹

As for color vision, seven RxLAL (1.8 percent) eyes had a new tritan anomaly (difficulty distinguishing between blue, violet and green). Five resolved after the adjustments were complete, but two persisted. One of the latter two was due to the faulty UV filter, and still had the tritan anomaly four years later. The researchers note that both of the persistent and all but one of the transient tritan anomalies occurred before a certain safety improvement was made to the LDD to reduce the amount of UV exposure.¹

Putting It into Practice

Though the company hasn't specified a date for the rollout of the lens, surgeons have ideas how it might be used in practice.

"For patients, I think the benefit is they don't have to make a decision about the type of vision they want pre-operatively," muses Dr. Thompson. "Unlike fitting glasses, with cataract surgery we can't show them exactly what the result will be if we correct

their dominant eye to plano and the non-dominant to -1 D, because they have a cataract—their vision is blurry. With this lens, though, for the first time we can show them their visual options after the surgery and they can choose where they want their optical power to be. You can start discussing 'optimized monovision' where you can change the power of the implant so that one eye is set for the amount of monovision they need for reading or the distance they want to work at."

Dr. Miller envisions this, as well. "You can play with it," he says. "You can ask, 'Do you prefer distance vision and vision at computer distance? A little farther out? A little closer? You could simulate it with a contact lens and then dial that amount into the IOL. Though the 'screaming need' is for some sort of multifocal correction for distance and near vision, this lens won't provide that just yet. However, the company had to get the base platform onto the market first.

"The initial interest from surgeons will be for treating post-refractive surgery eyes, which will be off-label," Dr. Miller continues. "The study didn't enroll those types of eyes, but you can do them. These are the types of patients that we surgeons obsess over. They're particular about their refractive outcomes, but we have a hard time delivering good outcomes for them. So, everyone wants a solution. Therefore, my guess is that surgeons' initial foray into this technology will be for treating these eyes. Then, when they see that it works, they'll expand the LALs use to regular eyes, in a way similar to how toric IOLs were first used for the high astigmats and then their use filtered down to the less-challenging eyes." **REVIEW**

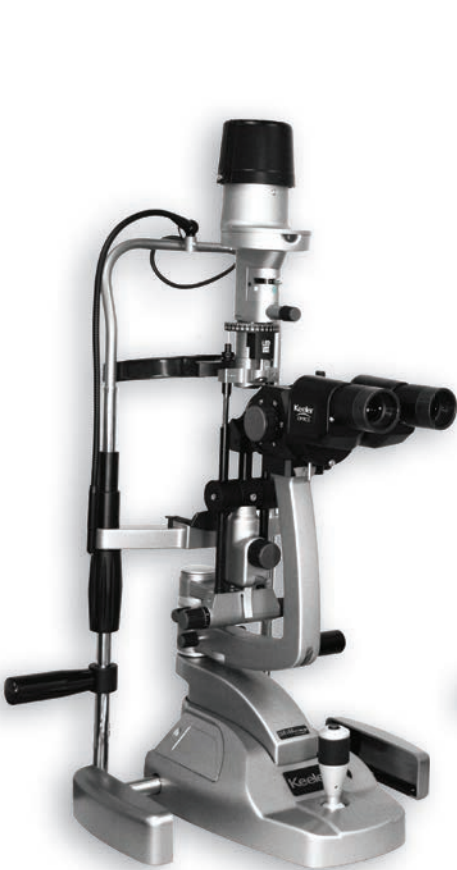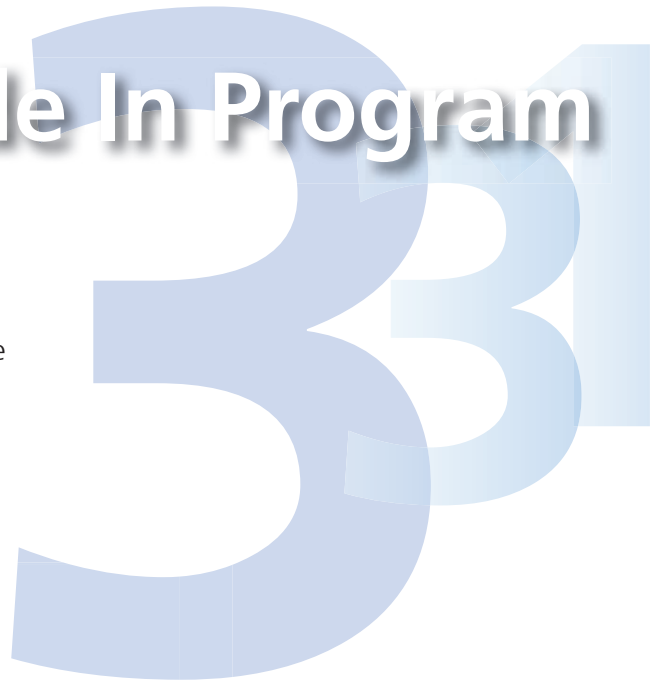Drs. Thompson and Miller consult for RxSight.

1. FDA.gov. LAL Summary of Safety and Effectiveness. https://www.accessdata.fda.gov/cdrh_docs/pdf16/P160055B.pdf. Accessed 11 December 2017.

The Keeler³ Trade In Program

Buy 3 // Trade 3 // Get 1 Free

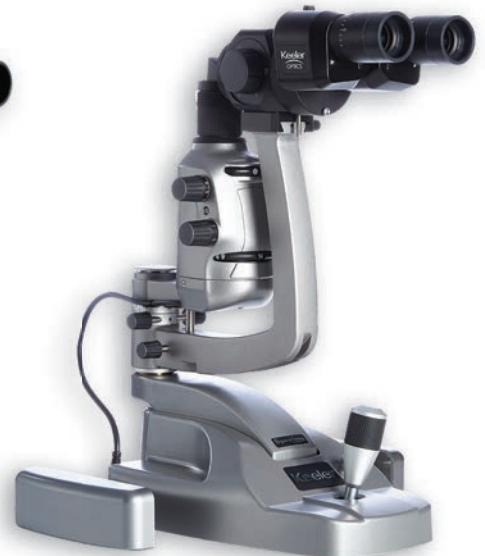The Power of 3. Purchase any 3 Keeler Slit Lamps and trade in 3 of your old Slit Lamps and we'll send you a 4th Keeler Slit Lamp absolutely free of charge.



K Series



Q Series



Z Series



Keeler Instruments, Inc. • 3222 Phoenixville Pike, bldg. 50 • Malvern, PA 19355
Tel: (800) 523-5620 • Fax: (610) 353-7814 • email: keeler@keelerusa.com

Offer valid until March 31, 2018.

Contact Keeler or one of our authorized dealers for more information.

LEAVE A LEGACY OF SEAMLESS BRILLIANCE.

Start with **ME.**

TECNIS *Symfony*[®] and TECNIS *Symfony*[®] Toric IOLs deliver state-of-the-art presbyopia mitigation and astigmatism correction* while providing a full range of high-quality, continuous vision. I've never let anything keep me from seeing the big picture. Why would you?

Don't wait to leave a legacy of seamless brilliance. Start now with TECNIS *Symfony*[®] and TECNIS *Symfony*[®] Toric Extended Depth of Focus IOLs.

*TECNIS *Symfony*[®] Toric IOLs only

The First and Only Extended Depth of Focus IOL

INDICATIONS AND IMPORTANT SAFETY INFORMATION FOR THE TECNIS SYMFONY[®] AND TECNIS SYMFONY[®] TORIC EXTENDED RANGE OF VISION IOLs

Rx Only

INDICATIONS: The TECNIS *Symfony*[®] Extended Range of Vision IOL, model ZXR00, is indicated for primary implantation for the visual correction of aphakia, in adult patients with less than 1 diopter of pre-existing corneal astigmatism, in whom a cataractous lens has been removed. The lens mitigates the effects of presbyopia by providing an extended depth of focus. Compared to an aspheric monofocal IOL, the lens provides improved intermediate and near visual acuity, while maintaining comparable distance visual acuity. The model ZXR00 IOL is intended for capsular bag placement only. The TECNIS *Symfony*[®] Toric Extended Range of Vision IOLs, models ZXT150, ZXT225, ZXT300, and ZXT375, are indicated for primary implantation for the visual correction of aphakia and for reduction of residual refractive astigmatism in adult patients with greater than or equal to 1 diopter of preoperative corneal astigmatism, in whom a cataractous lens has been removed. The lens mitigates the effects of presbyopia by providing an extended depth of focus. Compared to an aspheric monofocal IOL, the lens provides improved intermediate and near visual acuity, while maintaining comparable distance visual acuity. The model series ZXT IOLs are intended for capsular bag placement only. **WARNINGS:** May cause a reduction in contrast sensitivity under certain conditions, compared to an aspheric monofocal IOL. Inform patients to exercise special caution when driving at night or in poor visibility conditions. Some visual effects may be expected due to the lens design, including: perception of halos, glare, or starbursts around lights under nighttime conditions. These will be bothersome or very bothersome in some people, particularly in low-illumination conditions, and on rare occasions, may be significant enough that the patient may request removal of the IOL. Rotation of the TECNIS *Symfony*[®] Toric IOLs away from their intended axis can reduce their astigmatic correction, and misalignment greater than 30° may increase postoperative refractive cylinder. If necessary, lens repositioning should occur as early as possible prior to lens encapsulation. **ATTENTION:** Reference the Directions for Use for a complete listing of Indications and Important Safety Information.

TECNIS and TECNIS SYMFONY are trademarks owned by or licensed to Abbott Medical Optics Inc., its subsidiaries or affiliates.
© 2017 Abbott Medical Optics Inc. | www.TeenisIOL.com | PP2017CT1901