

PHACO: KNOW YOUR FLUIDICS OPTIONS P. 16 • MEDICARE UPDATES FOR 2017 P. 23
SECRETS FOR MANAGING GLAUCOMA WITH OCT P. 50 • A REVIEW OF PORTABLE RETINAL IMAGING P. 60
A NEW DAY DAWNS FOR DRY-EYE THERAPY P. 64 • WILLS EYE RESIDENT CASE STUDY P. 71

REVIEW[®] of Ophthalmology

CATARACT

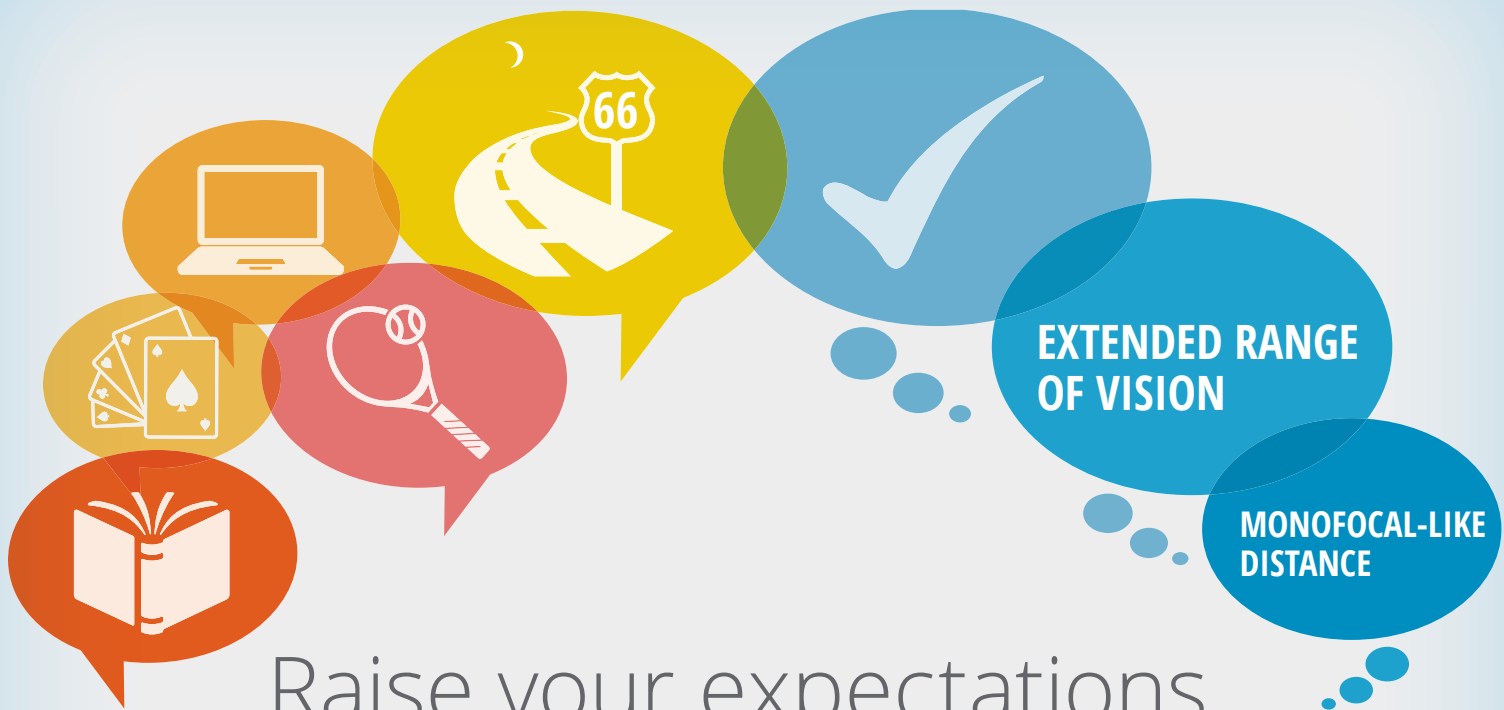REFRACTIVE
ISSUE

*Surgeons share
their best tips
and techniques
for helping you
improve your
outcomes.*

Toric IOLs: Nailing the Target Meridian **P. 26**

Tips for a Better SMILE **P. 34**

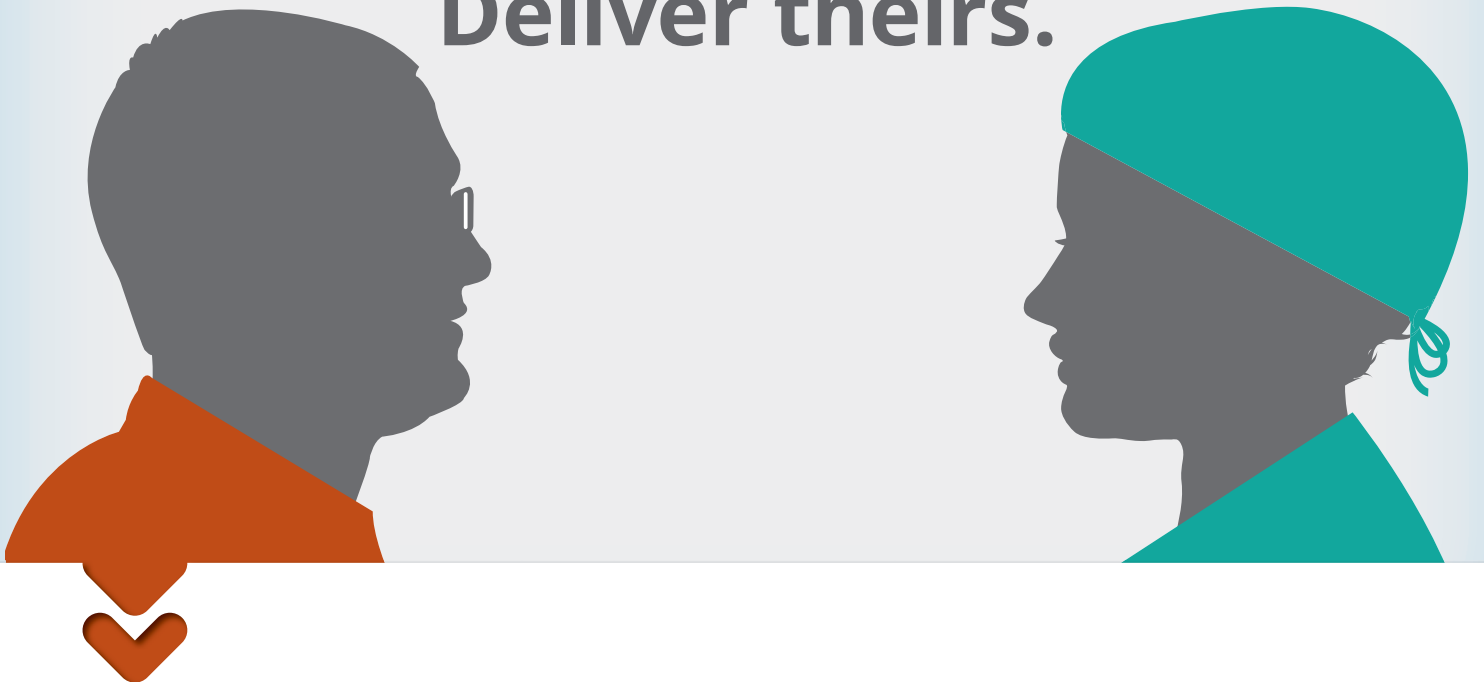
Odd Couple: Multifocals in Post-refractive Patients **P. 40**



EXTENDED RANGE OF VISION

MONOFOCAL-LIKE DISTANCE

Raise your expectations.
Deliver theirs.



Now you can give your patients the best of both worlds with the **first and only hybrid designed monofocal-multifocal IOL.**

ACTIVEFOCUS™
Optical Design

 AcrySof® IQ ReSTOR® +2.5
PRESBYOPIA-CORRECTING IOL

Alcon A Novartis
Division

© 2016 Novartis 10/16 US-RES-16-E-4014

See adjacent page for Important Product Information.

**IMPORTANT PRODUCT INFORMATION
FOR THE
ACRYSOF® IQ RESTOR® FAMILY OF IOLs**

CAUTION: Federal (USA) law restricts this device to the sale by or on the order of a physician.

INDICATIONS: The AcrySof® IQ ReSTOR® Posterior Chamber Intraocular Lens (IOL) is intended for primary implantation for the visual correction of aphakia secondary to removal of a cataractous lens in adult patients with and without presbyopia, who desire near, intermediate and distance vision with increased spectacle independence. The lens is intended to be placed in the capsular bag.

WARNINGS/PRECAUTIONS: Careful preoperative evaluation and sound clinical judgment should be used by the surgeon to decide the risk/benefit ratio before implanting a lens in a patient with any of the conditions described in the Directions for Use labeling. Physicians should target emmetropia, and ensure that IOL centration is achieved. Care should be taken to remove viscoelastic from the eye at the close of surgery.

Some patients may experience visual disturbances and/or discomfort due to multifocality, especially under dim light conditions. As with other multifocal IOLs, visual symptoms may be significant enough that the patient will request explant of the multifocal IOL. Spectacle independence rates vary with all multifocal IOLs; as such, some patients may need glasses when reading small print or looking at small objects.

Clinical studies with the AcrySof® ReSTOR® lens indicated that posterior capsule opacification (PCO), when present, developed earlier into clinically significant PCO. Prior to surgery, physicians should provide prospective patients with a copy of the Patient Information Brochure available from Alcon for this product informing them of possible risks and benefits associated with the AcrySof® IQ ReSTOR® IOLs.

Studies have shown that color vision discrimination is not adversely affected in individuals with the AcrySof® Natural IOL and normal color vision. The effect on vision of the AcrySof® Natural IOL in subjects with hereditary color vision defects and acquired color vision defects secondary to ocular disease (e.g., glaucoma, diabetic retinopathy, chronic uveitis, and other retinal or optic nerve diseases) has not been studied. Do not resterilize; do not store over 45° C; use only sterile irrigating solutions such as BSS® or BSS PLUS® Sterile Intraocular Irrigating Solutions.

ATTENTION: Reference the Directions for Use labeling for a complete listing of indications, warnings and precautions.

Left your *Review* of Ophthalmology magazine at the office? No problem!



Read *Review* on the go from any mobile device!

Go to www.reviewofophthalmology.com
and click on the digimag link to get
your current issue.

Alcon A Novartis
Division

© 2016 Novartis 10/16 US-RES-16-E-4014

Lucentis Approved for Myopic Choroidal Neovascularization

Genentech (South San Francisco, Calif.), part of Roche (Basel, Switzerland), announced in January that Lucentis (ranibizumab injection) was approved by the Food and Drug Administration for the treatment of myopic choroidal neovascularization, a sight-threatening complication of high myopia. MCNV affects more than 41,000 people in the United States.¹

Myopic choroidal neovascularization is a complication of high myopia (eyes with a refractive error of -6 D or greater, and/or axial length of 26.5 mm or more)¹ in which the eye progressively lengthens from front to back and degenerates, and neovascularization develops. The condition is most prevalent in people ages 45 to 64.¹

Until this approval for mCNV, the FDA-approved standard of care for mCNV has been verteporfin photodynamic therapy, although anti-VEGF injections were previously used off label and recommended as first-line treatments.² Lucentis inhibits choroidal neovascularization by binding to and interfering with the vascular endothelial growth factor VEGF-A, the protein implicated in the formation of incompetent blood vessels.

The findings of the RADIANCE study form the basis of Genentech's approval.³ This Phase III, 12-month, randomized, active-controlled study enrolled mCNV patients from 76 centers worldwide. They were randomized into three treatment groups: Group I received Lucentis 0.5 mg injection on day one, month one and thereafter as needed per visual acuity

stabilization guidelines. Group II received Lucentis 0.5 mg injection on day one of the study and as needed thereafter per disease-activity criteria. Group III received vPDT on day one, but were permitted treatment with Lucentis and/or vPDT based upon disease activity, at investigators' discretion, from months three through 11. Groups I and II showed dramatic gains in mean average best-corrected vision as measured by ETDRS letters at three months (10.5 and 10.6, respectively), compared to Group III (2.2 letters gained). Mean BCVA gains from baseline to month 12 were 13.8 letters for Group I; 14.4 for Group II; and, 9.3 for Group III, who were able to get Lucentis injections after three months. The results show that treatment with Lucentis on either schedule I or II resulted in dramatic early gains, and gains in BCVA continued throughout the study period. Group I patients received a median of four injections over 12 months; Groups II and III underwent a median of two. There were no adverse safety events.

"I think that having an FDA approval for Lucentis benefits patients and supports reimbursement from payers, as it is clearly superior to the other FDA-approved treatment, PDT," says John A. Wells, III, MD, of the Palmetto Retina Center in West Columbia, S.C. "The RADIANCE study


confirms my personal experience, and the collective experience of retina specialists, that PDT is vastly inferior to Lucentis 0.5 mg for the treatment of myopic CNV." Dr. Wells adds that the upswing in ETDRS letters gained by the PDT group once Lucentis was allowed after three months is also important in illustrating "that PDT is not a good option for myopic CNV if anti-VEGF therapy is available."

1. Willis JR, Vitale S, Morse L et al. The prevalence of myopic choroidal neovascularization in the United States. *Ophthalmology* 2016;123:8:1771-1782.
2. Adatia FA, Luong M, Munro M, Tufail A. The other CNVM: A review of myopic choroidal neovascularization treatment in the age of anti-vascular endothelial growth factor agents. *Survey of Ophthalmol*, 2015;60:3:204-15.
3. RADIANCE: A randomized controlled study of ranibizumab in patients with choroidal neovascularization secondary to pathologic myopia. *Ophthalmology* 2014;121:3:682-692.

ReSTOR Toric MF: New Options And Challenges

As Alcon begins its scheduled first-quarter rollout of the new ReSTOR +3 D Multifocal Toric intraocular lens, which was approved in late December of 2016, surgeons are understandably interested in giving their patients a new alternative for vision correction post-cataract, but say it's best to

(Continued on page 8)



Editor in Chief

Walter C. Bethke
(610) 492-1024
wbethke@jobson.com

Senior Editor

Christopher Kent
(814) 861-5559
ckent@jobson.com

Senior Associate Editor

Kristine Brennan
(610) 492-1008
kbrennan@jobson.com

Associate Editor

Liam Jordan
(610) 492-1025
ljordan@jobson.com

Chief Medical Editor

Mark H. Blecher, MD

Art Director

Jared Araujo
(610) 492-1032
jaraujo@jobson.com

Senior Graphic Designer

Matt Egger
(610) 492-1029
megger@jobson.com

International coordinator, Japan

Mitz Kaminuma
Reviewophthlmo@aol.com

Business Offices

11 Campus Boulevard, Suite 100
Newtown Square, PA 19073
(610) 492-1000
Fax: (610) 492-1039

Subscription inquiries:

United States — (877) 529-1746
Outside U.S. — (845) 267-3065
E-mail:

revophthalmology@cambeywest.com
Website: www.reviewofophthalmology.com



Elevating The Quality Of Care In Ophthalmology



Dell* Toric Axis Markers

Precise Alignment For Correct Toric Axis Placement,
From Upright Through The Supine Position.



8-12119: Rotating Inner Bezel Automatically Orients Marks For The IOL In The Correct Meridian. Is Upright, An Orientation Mark On The Conjunctiva. In Surgery The Rotating Inner Bezel Is Set To The Desired Meridian. While The Instrument Is Positioned So That The Vertical Conjunctival Mark Is Aligned With The 90 Degree Position On The Outer Bezel Of The Marker. The Marking Blades On The Undersurface Of The Instrument Will Automatically Place A Mark In The Correct Meridian When The Cornea Is Indented.

Bezel Automatically Orients Marks For The Placement Of A Toric IOL In The Correct Meridian. While The Patient Is Placed Vertically The Rotating Inner Bezel Is Set To The Desired Meridian. While The Instrument Is Positioned So That The Vertical Conjunctival Mark Is Aligned With The 90 Degree Position On The Outer Bezel Of The Marker. The Marking Blades On The Undersurface Of The Instrument Will Automatically Place A Mark In The Correct Meridian When The Cornea Is Indented.

8-12120: Weighted So That Correct Horizontal Orientation Is Assured. Rotating Inner Bezel Automatically Orients Blades For Corneal Marks For The Placement Of A Toric IOL In The Correct Meridian. Designed For Use With The Patient Upright Immediately Prior To Surgery, The Inner Bezel Is Rotated To The Desired Meridian, And The Cornea Is Indented. The Marking Blades On The Undersurface Of The Instrument Will Automatically Place Marks In The Correct Meridian.

www.RheinMedical.com



3360 Scherer Drive, Suite B. St.Petersburg, Florida
800-637-4346 • Tel: 727-209-2244 • Fax: 727-3418123
Email: Info@RheinMedical.com • Website: www.RheinMedical.com

*Developed In Coordination With Steven J. Dell, M.D.

Moses, Michelangelo

Considerations for Development in Japan

In prior installments of this column, in order to help entrepreneurs in their companies' early stages look for creative ways to help move programs forward or to provide additional value, we've discussed how regional licensing partnerships are an option for non-dilutive financing (financing that doesn't require the sale of shares of your company). In this month's column, we'll focus in on a few considerations related to doing business in Japan. Japan is one of the top markets for ophthalmology products in the world and, in some cases, is the second-largest market behind the United States. As such, it should be an important component in your early global development planning. In other regions such as Europe, Canada or South America, for some programs the clinical package from the U.S. is sufficient for filing, but the considerations for bringing programs to Japan are unique. If you plan to pursue a regulatory meeting in Japan, then, it's helpful to understand the nuances related to regulatory interactions there. Here, we'll cover a couple of key highlights related to the early part of the process.

In the past there's been a considerable time lag between development and approval in the United States and an ultimate launch in Japan. Given the size of the market in Japan, a more global follow-on or even parallel strategy makes sense, and can add more value to your program as you look for partnerships with global companies. In fact, Japan is becoming a market of interest earlier in products' lifecycles, and it can be very useful to show investors or global partners what a development program looks like in Japan—even if actual clinical development isn't initiated yet. We've seen many companies and entrepreneurs focus solely on Food and Drug Administration interactions through Phases I and II, all the while ignoring other territories. However, investing just a small amount of time and resources in these other regions—including Japan—can yield valuable information on regulatory interactions. A word to the wise, though: If you're going to invest extra time in Japan, start early, because it may take additional time to gain confirmed written comments.

In Japan, the FDA's counterpart is known as the Pharmaceutical and Medical Device

Agency. In many regards, the PMDA is very similar to the FDA. With some requirements having been harmonized across regions as ICH Guidances (International Council for Harmonization), components such as toxicology and manufacturing generally are consistent and many times don't require additional work or rework. In some regards, interaction with the PMDA is very similar to dealing with the FDA. One main difference between the two is that, in the initial stages of the process, rather than a single pre-IND meeting with the FDA, working with the PMDA involves a multistep process.

The first interaction with the PMDA is called the *jizen mendan* ("preliminary meeting").



This meeting has no fee associated with it, is shorter in length and requires less of a briefing package. It's important to recognize the role of this meeting: You won't leave with formal written comments from the PMDA and it isn't intended to discuss details of the development program or clinical protocols. The intention of this meeting is to confirm the materials that are to be submitted and the sponsor's questions that will be discussed at the subsequent *tainen jogen* ("full consultation meeting"). Certainly, many times it is natural to wish to obtain as much information as possible during regulatory interactions, but many times we see clients having high expectations for confirming details and answering all questions about a bridging program at this preliminary meeting. However, it's important to recognize the PMDA review isn't formalized at this stage and they will not have reviewed all the information and data.

However, this first meeting is still very important for setting the stage and starting a working dialogue, relationship and level of trust with the PMDA. The second meeting, the full consultation meeting, is more

similar to a pre-IND meeting with the FDA, in that a more detailed briefing document is submitted in advance and written comments are provided by the PMDA following the meeting. This meeting does carry a fee, which currently is in the range of \$50,000. In many instances, additional clarifications are required after this meeting, and the PMDA has always been very helpful and responsive about providing clarifications as needed.

Again, it's important to recognize that maybe several rounds of meetings might be necessary in order to finalize plans. Companies must recognize that everything won't be formalized in one meeting during a single trip to Japan. The PMDA is very thoughtful and data-driven and, in some cases, though it may not require preclinical or pharmacology studies to be repeated, it may ask for data to be presented in a different manner to help support such things as drug concentration and dosing selection.

The PMDA also views ethnic differences as very important for interpretation of clinical data. In cases in which pharmacokinetic or pharmacodynamic data is being used, you have to show how the Japanese population compares to the original data set. The PMDA typically wants to see dose ranging established in the Japanese population specifically. This is due to potential differences in both drug activity and dosing frequency, as well as to differences in practice patterns that might relate to whether the drug is used as primary, secondary or objective therapy. For example, drugs in some indications may need to be dosed more frequently in Japan than in United States.

One key point to recognize is that the PMDA has been very open to helping clients run early studies as efficiently as possible, and therefore will generally accept the Phase I/pharmacokinetics being done in the United States, if done in Japanese-American patients. But we do generally see that the PMDA wants a traditional Phase I/PK study to be conducted/repeated as a first step, even in cases where a program may have proceeded directly into Phase II in the United States, or Phase I data already exists, but with a non-Japanese population. This includes situations in which Phase III may already be completed in the United States or

(Continued on page 8)

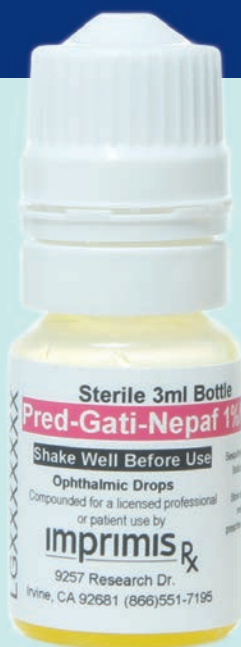LESS
DROPS®



The Right Formulation.
The Right Bottle.
The Right Price.

AS LOW AS
\$30

PRED-GATI-NEPAF*
Prednisolone acetate,
Gatifloxacin and Nepafenac



Easy to Dispense. 100% Guaranteed.

- Optimized formulation process for enhanced suspension
- PureFlow® technology allows for one way valve preventing risk of contamination
- Blue tip allows for better accuracy when targeting the eye
- Easy to open tamper proof seal

Request your 3 FREE evaluation bottles today!**

www.imprimisrx.com/drops

imprimis Rx®
844.446.6979

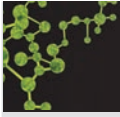
We guarantee bottles will dispense properly or your money back.

*Compounded by a pharmacist pursuant to an individual prescription. May be customized.

**Evaluation bottles are not for resale or human use.

©2017 Imprimis Pharmaceuticals, Inc. All Rights Reserved. IMPO0115 01/17

ACCREDITED
Compounding Pharmacy
A SERVICE OF ACHC



(Continued from page 6)

the product is commercialized. Similarly, many times Phase II dose ranging may also be done in the United States in Japanese-American patients. However, generally speaking, the confirmatory Phase III is required to be done in Japan.

The safety requirements are specific to the drug's indication and the amount of data already in hand from other parts of the world. In some cases, the additional safety requirements for a number of patients may be less than the full safety package already completed in the United States, and may even be in the form of an open-label study. The key is that the PMDA is looking for efficacy and safety to be established in Japanese patients. It's open to reviewing data from subgroups of patients that may be of Japanese descent from the United States to support early data. However, we usually find that the number of Japanese-American patients included in U.S. studies isn't large enough to eliminate the need for repeating Phase I and II. The PMDA is also very conscious of reducing the timeline of development between the rest of the world and registration in Japan.

In many respects the PMDA will view data in a way similar to the FDA. In some situations, they do have other thresholds. For example, in the case of dry eye, PMDA's requirement for approval is to demonstrate a statistically significant improvement in one sign only, specifically corneal staining. This is an important nuance, and is slightly different from the FDA in that there are a few products that are approved in Japan that aren't approved in the United States, namely diquafosol and repabamide. There are also areas of emphasis that the PMDA is keen to address, such as neuroprotection, given the higher incidence of low-tension glaucoma in Japan, and allergies, which are a severe problem there. In these conditions, there may be opportunities for parallel development—or even leading development—in some cases in which it makes sense.

Naturally, this article isn't intended to be an exhaustive review of regulatory strategy for Japan. However, we hope this discussion at least highlights the importance of looking into the Japanese market for your product, and considering starting an earlier dialogue with the PMDA than you may have originally planned. This will help show potential partners your focus on global development, and there may be opportunities for building and deriving additional value early. For example, some companies may see an opportunity for a potential regional partnership in Japan. We'll use this primer as a springboard for future columns on global development, including development in China and other Asian countries.

Mr. Chapin is senior vice president of the Corporate Development Group at Ora, Dr. Matsuda is general manager of Ora Japan KK, and Ms. Kawaba is a senior director of Ora Japan KK. Ora provides a comprehensive range of development, clinical-regulatory and product consulting services for developers, investors and buyers; preclinical and turnkey clinical trial services; assistance with regulatory submissions; and the integration of assets, business partnering and financing support in ophthalmology. Ora Japan KK is based in Osaka for local regulatory, clinical operations and business development support. We welcome your product development comments or questions. Please send correspondence to mchapin@oraclinical.com or visit oraclinical.com.

(Continued from page 4)

enter into the combined multifocal/toric world with eyes open, and to be prepared for new idiosyncrasies associated with getting the implantation right.

In the FDA study, at one year, the mean near acuity with the news lens was 20/25, and the mean binocular intermediate acuity at 60 cm was 20/25. Mean distance vision was 20/20. The lenses had rotated an average of around 2.5 degrees at the year mark. In terms of cylinder, at one year 75 percent of the first-implanted eyes were within 0.5 D of the preop target. Eighty percent of the second eyes were within 0.5 D of the target.

Alan Crandall, MD, director of glaucoma and cataract at the Moran Eye Center at the University of Utah, says being able to treat astigmatism adds a new dimension to the multifocal lens that patients respond to. "The increased acuity, lack of glare and unwanted images—be they from straylight or halos—is really what most of our patients are excited about when you just correct their astigmatism with a toric lens," he says. "But when they also have the ability to have distance and near vision, that's a good combination. In the past, when working with multifocals where you had to try to do limbal relaxing incisions to correct the astigmatism, they were never as accurate as what you could get with a toric lens. Patients would come back and still say it wasn't as sharp."

But Dr. Crandall says these improved outcomes come at a price. "When you put these lenses in, you have to be right on target," he avers. "I wouldn't say it demands it, but you're better off if you have a topography device that images both anterior and posterior corneal values. You also have to use multiple formulas—the Barrett, the ASCRS formula, the Olson—and then it helps to have something like ORA or Holos intraoperative aberrometry. I think this is why the penetration of toric lenses isn't high: People are concerned about getting it properly on-axis."

As for the best patient for the lens, Dr. Crandall says someone with extreme dry eye wouldn't do well, nor would someone on medication for glaucoma because the lens will result in a little loss of contrast, which such a patient can't afford. "Someone with pseudoexfoliation might not do well because the optics of the lens depend somewhat on the pupil," he adds.

Trabodenson Fails Phase III Trial for Glaucoma

On January 3, Inotek Pharmaceuticals Corporation

(Continued on page 47)

START PUTTING
THOUSANDS
OF DOLLARS BACK INTO YOUR PRACTICE.

UNLIMITED 2% CASH BACK

With the SPARK® CASH CARD every expense could be an opportunity to boost your bottom line and put thousands back into your business. Earn cash back on equipment, supplies, marketing, and everything in between.



[CapitalOne.com/SmallBusiness](https://www.CapitalOne.com/SmallBusiness)

Credit approval required. Offered by Capital One Bank (USA), N.A. © 2016 Capital One



CONTRIBUTORS

CHIEF MEDICAL EDITOR

Mark H. Blecher, MD

BOTTOM LINE

Dennis D. Sheppard, MD

CONTACT LENSES

Penny Asbell, MD

CORNEA / ANTERIOR SEGMENT

Thomas John, MD

GLAUCOMA MANAGEMENT

Peter Netland, MD, PHD
Kuldev Singh, MD

MASTERS OF SURGERY

Taliva D. Martin, MD
Sara J. Haug, MD, PhD

PEDIATRIC PATIENT

Wendy Huang, MD

PLASTIC POINTERS

Ann P. Murchison, MD, MPH

WILLS RESIDENT CASE SERIES

Allison Huggins, MD

REFRACTIVE SURGERY

Arturo S. Chayet, MD

RETINAL INSIDER

Carl Regillo, MD, FACS
Emmett T. Cunningham Jr., MD, PHD, MPH

TECHNOLOGY UPDATE

Steven T. Charles, MD
Michael Colvard, MD

THERAPEUTIC TOPICS

Mark Abelson, MD

ADVISORY BOARD

PENNY A. ASBELL, MD, NEW YORK CITY

WILLIAM I. BOND, MD, PERIN, ILL.

ALAN N. CARLSON, MD, DURHAM, N.C.

Y. RALPH CHU, MD, EDINA, MINN.

ADAM J. COHEN, MD, DOWNERS GROVE, ILL.

UDAY DEVGAN, MD, FACS, LOS ANGELES

ERIC DONNENFELD, MD, ROCKVILLE CENTRE, N.Y.

DANIEL S. DURRIE, MD, KANSAS CITY, MO.

ROBERT EPSTEIN, MD, MCHENRY, ILL.

ROBERT D. FECHTNER, MD, NEWARK, N.J.

WILLIAM J. FISHKIND, MD, TUCSON, ARIZ.

JAMES P. GILLS, MD, TARPON SPRINGS, FLA.

HARRY GRABOW, MD, SARASOTA, FLA.

DOUGLAS K. GRAYSON, MD, NEW YORK CITY

R. BRUCE GRENE, MD, WICHITA, KAN.

THOMAS S. HARBIN, MD, MBA, ATLANTA

DAVID R. HARDTEN, MD, MINNEAPOLIS

KENNETH J. HOFFER, MD, SANTA MONICA, CALIF.

JACK T. HOLLADAY, MD, MSEE, HOUSTON

JOHN D. HUNKELER, MD, KANSAS CITY, MO.

THOMAS JOHN, MD, TINLEY PARK, ILL.

ROBERT M. KERSHNER, MD, MS, FACS, BOSTON

GUY M. KEZIRIAN, MD, PARADISE VALLEY, ARIZ.

TERRY KIM, MD, DURHAM, N.C.

TOMMY KORN, MD, SAN DIEGO

DAVID A. LEE, MD, HOUSTON

FRANCIS S. MAH, MD, PITTSBURGH

NICK MAMALIS, MD, SALT LAKE CITY

WILLIAM G. MARTIN, MD, OREGON, OHIO

MIKE S. MCFARLAND, MD, PINE BLUFF, ARK.

JEFFREY B. MORRIS, MD, MPH, ENCINITAS, CALIF.

MARLENE R. MOSTER, MD, PHILADELPHIA

ROBERT J. NOECKER, MD, FAIRFIELD, CONN.

ROBERT OSHER, MD, CINCINNATI

MARK PACKER, MD, WEST PALM BEACH, FLA.

STEPHEN PASCUCCI, MD, BONITA SPRINGS, FLA.

PAUL PENDER, MD, BEDFORD, N.H.

CHRISTOPHER J. RAPUANO, MD, PHILADELPHIA

AUGUST READER III, MD, SAN FRANCISCO

TONY REALINI, MD, MORGANTOWN, W.V.

KENNETH J. ROSENTHAL, MD, GREAT NECK, N.Y.

ERIC ROTHCHILD, MD, DELRAY BEACH, FLA.

SHERI ROWEN, MD, BALTIMORE

JAMES J. SALZ, MD, LOS ANGELES

INGRID U. SCOTT, MD, MPH, HERSHEY, PA.

JOEL SCHUMAN, MD, PITTSBURGH

GAURAV SHAH, MD, ST. LOUIS

DAVID R. STAGER JR., MD, DALLAS

KARL STONECIPHER, MD, GREENSBORO, N.C.

JAMES C. TSAI, MD, NEW YORK CITY

VANCE THOMPSON, MD, SIOUX FALLS, S.D.

FARRELL C. TYSON, MD, CAPE CORAL, FLA.

R. BRUCE WALLACE III, MD, ALEXANDRIA, LA.

ROBERT G. WILEY, MD, CLEVELAND

FRANK WEINSTOCK, MD, CANTON, OHIO

JACQUELINE M.S. WINTERKORN, MD, PHD, NEW YORK CITY

BUSINESS OFFICES

11 CAMPUS BOULEVARD, SUITE 100
NEWTOWN SQUARE, PA 19073
SUBSCRIPTION INQUIRIES (877) 529-1746
(USA ONLY); OUTSIDE USA, CALL (847) 763-9630

BUSINESS STAFF

PUBLISHER

JAMES HENNE

(610) 492-1017 JHENNE@JOBSON.COM

REGIONAL SALES MANAGER

MICHELE BARRETT

(610) 492-1014 MBARRETT@JOBSON.COM

REGIONAL SALES MANAGER

MICHAEL HOSTER

(610) 492-1028 MHOSTER@JOBSON.COM

CLASSIFIED ADVERTISING

(888)-498-1460

VICE PRESIDENT OF OPERATIONS

CASEY FOSTER

(610) 492-1007 CFOSTER@JOBSON.COM

PRODUCTION MANAGER

SCOTT TOBIN

(610) 492-1011 STOBIN@JOBSON.COM

SUBSCRIPTIONS

\$63 A YEAR, \$99 (U.S.) IN CANADA,
\$158 (U.S.) IN ALL OTHER COUNTRIES.

SUBSCRIPTIONS E-MAIL:

REVOPHTHALMOLOGY@CAMBEYWEST.COM

CIRCULATION

PO BOX 71, CONGERS, NY 10920-0071
(877) 529-1746

OUTSIDE USA: (845) 267-3065

SENIOR CIRCULATION MANAGER

HAMILTON MAHER

(212) 219-7870 hmaher@jhihealth.com

CEO, INFORMATION GROUP SERVICES

MARC FERRARA

SENIOR VICE PRESIDENT, OPERATIONS

JEFF LEVITZ

VICE PRESIDENT, HUMAN RESOURCES

TAMMY GARCIA

VICE PRESIDENT, CREATIVE SERVICES & PRODUCTION

MONICA TETTAMANZI

CORPORATE PRODUCTION DIRECTOR

JOHN ANTHONY CAGGIANO

VICE PRESIDENT, CIRCULATION

EVELDA BAREA



440 Ninth Avenue, 14th Floor
New York, N.Y. 10001

REVIEW OF OPHTHALMOLOGY (ISSN 1081-0226; USPS No. 0012-345) is published monthly, 12 times per year by Jobson Medical Information, 440 Ninth Avenue, 14th Floor, New York, N.Y. 10001. Periodicals postage paid at New York, NY and additional mailing offices. Postmaster: Send address changes to Review of Ophthalmology, PO Box 71, Congers, NY 10929-0071. Subscription Prices: US One Year \$63.00, US Two Year \$112.00, Canada One Year \$99.00, Canada Two Year \$181.00, Int'l One Year \$158.00, Int'l Two Year \$274.00. For subscription information call (877) 529-1746 (USA only); outside USA, call (845)-267-3065. Or email us at revophthalmology@cambeywest.com. Canada Post: Publications Mail Agreement #40612608. Canada Returns to be sent to Bleuchip International, P.O. Box 25542, London, ON N6C 6B2.



Down, Boy.

Help Tame Postoperative Ocular Inflammation
and Pain With **LOTEMAX[®] GEL**

Indication

LOTEMAX[®] GEL (loteprednol etabonate ophthalmic gel) 0.5% is indicated for the treatment of post-operative inflammation and pain following ocular surgery.

Important Safety Information about **LOTEMAX[®] GEL**

- **LOTEMAX[®] GEL** is contraindicated in most viral diseases of the cornea and conjunctiva including epithelial herpes simplex keratitis (dendritic keratitis), vaccinia, and varicella, and also in mycobacterial infection of the eye and fungal diseases of ocular structures.
- Prolonged use of corticosteroids may result in glaucoma with damage to the optic nerve, defects in visual acuity and fields of vision. If this product is used for 10 days or longer, IOP should be monitored.
- Use of corticosteroids may result in posterior subcapsular cataract formation.
- Use of steroids after cataract surgery may delay healing and increase the incidence of bleb formation and occurrence of perforations in those with diseases causing corneal and scleral thinning. The initial prescription and renewal of the medication order should be made by a physician only after examination of the patient with the aid of magnification, and where appropriate, fluorescein staining.
- Prolonged use of corticosteroids may suppress the host response and thus increase the hazard of secondary ocular infection. In acute purulent conditions, steroids may mask infection or enhance existing infection.
- Use of a corticosteroid medication in the treatment of patients with a history of herpes simplex requires great caution. Use of ocular steroids may prolong the course and exacerbate the severity of many viral infections of the eye (including herpes simplex).
- Fungal infections of the cornea are particularly prone to develop coincidentally with long-term local steroid application. Fungus invasion must be considered in any persistent corneal ulceration where a steroid has been used or is in use.
- Patients should not wear contact lenses when using **LOTEMAX[®] GEL**.
- The most common ocular adverse drug reactions reported were anterior chamber inflammation (5%), eye pain (2%) and foreign body sensation (2%).

Please see brief summary of Prescribing Information on adjacent page.

®/™ are trademarks of Bausch & Lomb Incorporated or its affiliates. © 2015 Bausch & Lomb Incorporated. All rights reserved. Printed in USA. US/LGX/15/0041(1)

BAUSCH + LOMB



LOTEMAX[®] GEL

loteprednol etabonate
ophthalmic gel 0.5%

BRIEF SUMMARY OF PRESCRIBING INFORMATION

This Brief Summary does not include all the information needed to prescribe Lotemax Gel safely and effectively. See full prescribing information for Lotemax Gel.

Lotemax (loteprednol etabonate ophthalmic gel) 0.5%

Rx only

Initial Rx Approval: 1998

INDICATIONS AND USAGE

LOTEMAX is a corticosteroid indicated for the treatment of post-operative inflammation and pain following ocular surgery.

DOSAGE AND ADMINISTRATION

Invert closed bottle and shake once to fill tip before instilling drops.

Apply one to two drops of LOTEMAX into the conjunctival sac of the affected eye four times daily beginning the day after surgery and continuing throughout the first 2 weeks of the post-operative period.

CONTRAINDICATIONS

LOTEMAX, as with other ophthalmic corticosteroids, is contraindicated in most viral diseases of the cornea and conjunctiva including epithelial herpes simplex keratitis (dendritic keratitis), vaccinia, and varicella, and also in mycobacterial infection of the eye and fungal diseases of ocular structures.

WARNINGS AND PRECAUTIONS

Intraocular Pressure (IOP) Increase

Prolonged use of corticosteroids may result in glaucoma with damage to the optic nerve, defects in visual acuity and fields of vision. Steroids should be used with caution in the presence of glaucoma. If this product is used for 10 days or longer, intraocular pressure should be monitored.

Cataracts

Use of corticosteroids may result in posterior subcapsular cataract formation.

Delayed Healing

The use of steroids after cataract surgery may delay healing and increase the incidence of bleb formation. In those diseases causing thinning of the cornea or sclera, perforations have been known to occur with the use of topical steroids. The initial prescription and renewal of the medication order should be made by a physician only after examination of the patient with the aid of magnification such as slit lamp biomicroscopy and, where appropriate, fluorescein staining.

Bacterial Infections

Prolonged use of corticosteroids may suppress the host response and thus increase the hazard of secondary ocular infections. In acute purulent conditions of the eye, steroids may mask infection or enhance existing infection.

Viral Infections

Employment of a corticosteroid medication in the treatment of patients with a history of herpes simplex requires great caution. Use of ocular steroids may prolong the course and may exacerbate the severity of many viral infections of the eye (including herpes simplex).

Fungal Infections

Fungal infections of the cornea are particularly prone to develop coincidentally with long-term local steroid application. Fungus invasion must be considered in any persistent corneal ulceration where a steroid has been used or is in use. Fungal cultures should be taken when appropriate.

Contact Lens Wear

Patients should not wear contact lenses during their course of therapy with LOTEMAX.

ADVERSE REACTIONS

Adverse reactions associated with ophthalmic steroids include elevated intraocular pressure, which may be associated with infrequent optic nerve damage, visual acuity and field defects, posterior subcapsular cataract formation, delayed wound healing and secondary ocular infection from pathogens including herpes simplex, and perforation of the globe where there is thinning of the cornea or sclera.

The most common adverse drug reactions reported were anterior chamber inflammation (5%), eye pain (2%), and foreign body sensation (2%).

USE IN SPECIFIC POPULATIONS

Pregnancy

Teratogenic Effects

Loteprednol etabonate has been shown to be embryotoxic (delayed

ossification) and teratogenic (increased incidence of meningocele, abnormal left common carotid artery, and limb flexures) when administered orally to rabbits during organogenesis at a dose of 3 mg/kg/day (35 times the maximum daily clinical dose), a dose which caused no maternal toxicity. The no-observed-effect-level (NOEL) for these effects was 0.5 mg/kg/day (6 times the maximum daily clinical dose). Oral treatment of rats during organogenesis resulted in teratogenicity (absent innominate artery at ≥ 5 mg/kg/day doses, and cleft palate and umbilical hernia at ≥ 50 mg/kg/day) and embryotoxicity (increased post-implantation losses at 100 mg/kg/day and decreased fetal body weight and skeletal ossification with ≥ 50 mg/kg/day). Treatment of rats with 0.5 mg/kg/day (6 times the maximum clinical dose) during organogenesis did not result in any reproductive toxicity. Loteprednol etabonate was maternally toxic (significantly reduced body weight gain during treatment) when administered to pregnant rats during organogenesis at doses of ≥ 5 mg/kg/day.

Oral exposure of female rats to 50 mg/kg/day of loteprednol etabonate from the start of the fetal period through the end of lactation, a maternally toxic treatment regimen (significantly decreased body weight gain), gave rise to decreased growth and survival, and retarded development in the offspring during lactation; the NOEL for these effects was 5 mg/kg/day. Loteprednol etabonate had no effect on the duration of gestation or parturition when administered orally to pregnant rats at doses up to 50 mg/kg/day during the fetal period.

There are no adequate and well controlled studies in pregnant women. LOTEMAX should be used during pregnancy only if the potential benefit justifies the potential risk to the fetus.

Nursing Mothers

It is not known whether topical ophthalmic administration of corticosteroids could result in sufficient systemic absorption to produce detectable quantities in human milk. Systemic steroids appear in human milk and could suppress growth, interfere with endogenous corticosteroid production, or cause other untoward effects. Caution should be exercised when LOTEMAX is administered to a nursing woman.

Pediatric Use

Safety and effectiveness in pediatric patients have not been established.

Geriatric Use

No overall differences in safety and effectiveness have been observed between elderly and younger patients.

NONCLINICAL TOXICOLOGY

Carcinogenesis, Mutagenesis, Impairment Of Fertility

Long-term animal studies have not been conducted to evaluate the carcinogenic potential of loteprednol etabonate. Loteprednol etabonate was not genotoxic *in vitro* in the Ames test, the mouse lymphoma tk assay, or in a chromosome aberration test in human lymphocytes, or *in vivo* in the single dose mouse micronucleus assay. Treatment of male and female rats with up to 50 mg/kg/day and 25 mg/kg/day of loteprednol etabonate, respectively, (600 and 300 times the maximum clinical dose, respectively) prior to and during mating did not impair fertility in either gender.

PATIENT COUNSELING INFORMATION

Administration

Invert closed bottle and shake once to fill tip before instilling drops.

Risk of Contamination

Patients should be advised not to allow the dropper tip to touch any surface, as this may contaminate the gel.

Contact Lens Wear

Patients should be advised not to wear contact lenses when using LOTEMAX.

Risk of Secondary Infection

If pain develops, redness, itching or inflammation becomes aggravated, the patient should be advised to consult a physician.

Bausch + Lomb, a division of Valeant Pharmaceuticals North America LLC
Bridgewater, NJ 08807 USA

US Patent No. 5,800,807

©Bausch & Lomb Incorporated

Lotemax is a registered trademark of Bausch & Lomb Incorporated or its affiliates.

LGX.0114.USA.16

Based on 9269101/9269201

Revised: 08/2016

REVIEW[®] of Ophthalmology

February 2017 • Volume XXIV No. 2 | reviewofophthalmology.com

Cover Focus

26 | **Toric IOLs: Nailing the Target Meridian**

By Christopher Kent, Senior Editor

Surgeons explain how to provide patients with outstanding results using these lenses.

34 | **Tips for a Better SMILE**

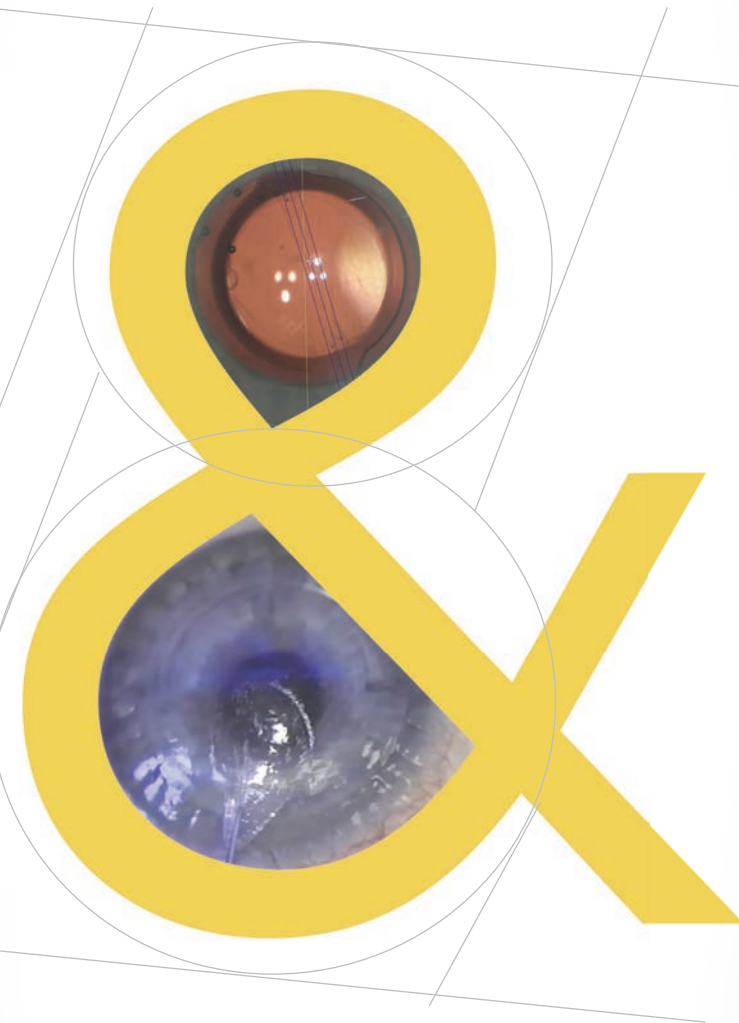
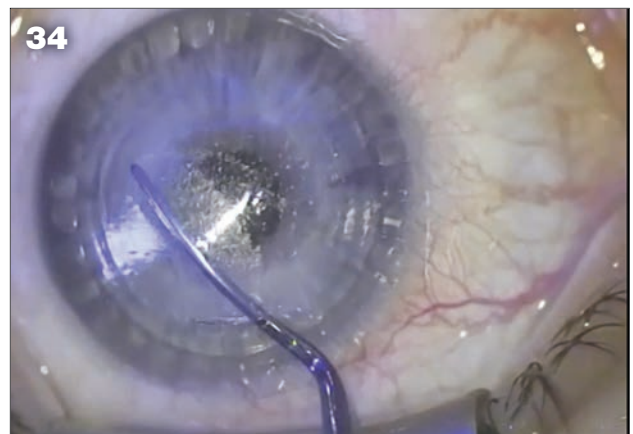
Jesper Hjortdal, MD

An expert SMILE surgeon explains how to get the most from this new procedure.

40 | **Odd Couple: Multifocals in Post-refractive Patients**

Kristine Brennan, Senior Associate Editor

A history of refractive surgery doesn't always mean multifocals are out of reach.



Departments

4 | [Review News](#)

16 | [Technology Update](#)

Phaco: Know Your Fluidics Options

The latest cataract systems offer a host of features to aid the surgeon and increase safety.

23 | [Medicare Q & A](#)

What's New in 2017?

How Medicare's updates might affect practices.

50 | [Glaucoma Management](#)

Secrets for Managing Glaucoma with OCT

Knowing OCT's advantages and pitfalls can help you make it an effective disease-monitoring tool.

60 | [Retinal Insider](#)

A Review of Portable Retinal Imaging

A guide to using devices such as smartphones as well as more exotic consumer-level cameras.

64 | [Therapeutic Topics](#)

A New Day Dawns for Dry-eye Therapy

A look at the challenges involved in getting new dry-eye therapies approved and how researchers are overcoming them.

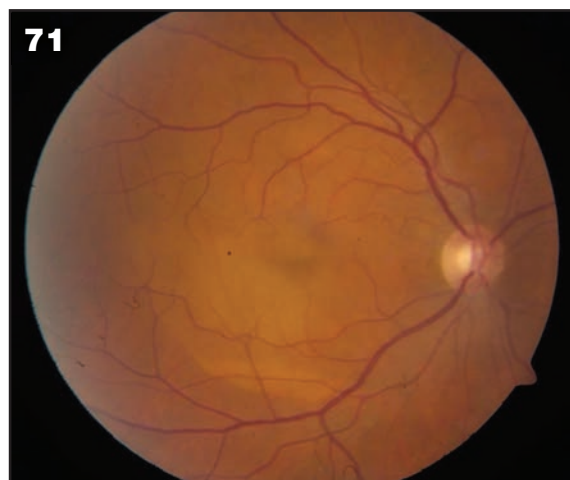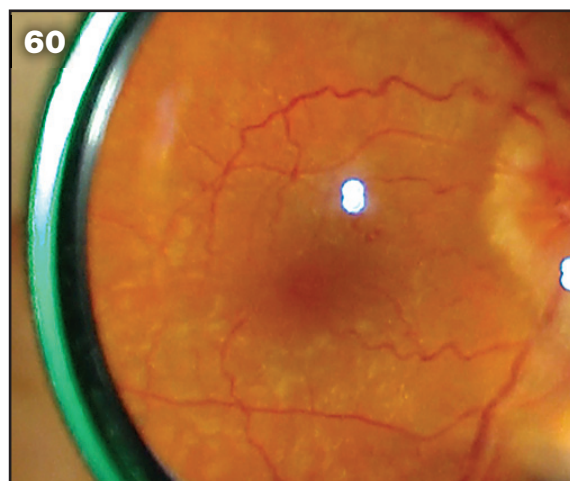
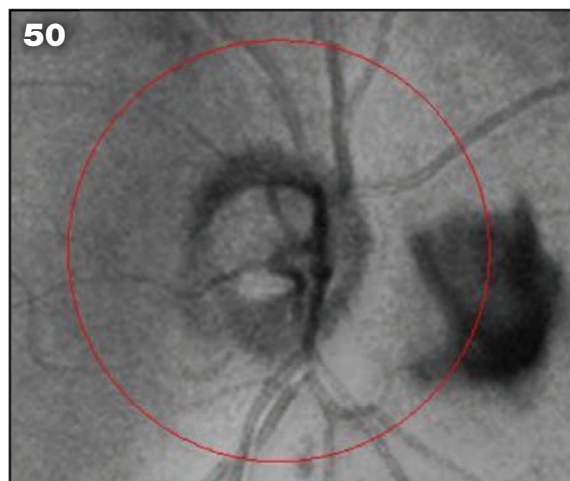
68 | [Research Review](#)

Smartphone Use and Pediatric Dry Eye

70 | [Classified Ads](#)

71 | [Wills Eye Resident Case Series](#)

74 | [Advertising Index](#)



TECNIS
Symfony[®]
Extended Range of Vision IOL

TECNIS
Symfony[®]
TORIC
Extended Range of Vision IOL

LEAVE A LEGACY OF SEAMLESS BRILLIANCE.

Start with **ME.**

TECNIS **Symfony**[®] and TECNIS **Symfony**[®] Toric IOLs deliver state-of-the-art presbyopia mitigation and astigmatism correction* while providing a full range of high-quality, continuous vision. I've never let anything keep me from seeing the big picture. Why would you?

Don't wait to leave a legacy of seamless brilliance. Start now with TECNIS **Symfony**[®] and TECNIS **Symfony**[®] Toric Extended Depth of Focus IOLs.

TECNIS IOL.COM

*TECNIS **Symfony**[®] Toric IOLs only

The First And Only Extended Depth of Focus IOL

INDICATIONS AND IMPORTANT SAFETY INFORMATION FOR THE TECNIS SYMFONY[®] AND TECNIS SYMFONY[®] TORIC EXTENDED RANGE OF VISION IOLs

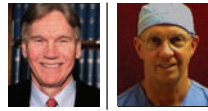Rx Only

INDICATIONS: The TECNIS **Symfony**[®] Extended Range of Vision IOL, model ZXR00, is indicated for primary implantation for the visual correction of aphakia, in adult patients with less than 1 diopter of pre-existing corneal astigmatism, in whom a cataractous lens has been removed. The lens mitigates the effects of presbyopia by providing an extended depth of focus. Compared to an aspheric monofocal IOL, the lens provides improved intermediate and near visual acuity, while maintaining comparable distance visual acuity. The model ZXR00 IOL is intended for capsular bag placement only. The TECNIS **Symfony**[®] Toric Extended Range of Vision IOLs, models ZXT150, ZXT225, ZXT300, and ZXT375, are indicated for primary implantation for the visual correction of aphakia and for reduction of residual refractive astigmatism in adult patients with greater than or equal to 1 diopter of preoperative corneal astigmatism, in whom a cataractous lens has been removed. The lens mitigates the effects of presbyopia by providing an extended depth of focus. Compared to an aspheric monofocal IOL, the lens provides improved intermediate and near visual acuity, while maintaining comparable distance visual acuity. The model series ZXT IOLs are intended for capsular bag placement only.

WARNINGS: May cause a reduction in contrast sensitivity under certain conditions, compared to an aspheric monofocal IOL. Inform patients to exercise special caution when driving at night or in poor visibility conditions. Some visual effects may be expected due to the lens design, including: perception of halos, glare, or starbursts around lights under nighttime conditions. These will be bothersome or very bothersome in some people, particularly in low-illumination conditions, and on rare occasions, may be significant enough that the patient may request removal of the IOL. Rotation of the TECNIS **Symfony**[®] Toric IOLs away from their intended axis can reduce their astigmatic correction, and misalignment greater than 30° may increase postoperative refractive cylinder. If necessary, lens repositioning should occur as early as possible prior to lens encapsulation. **ATTENTION:** Reference the Directions for Use for a complete listing of Indications and Important Safety Information.

TECNIS and TECNIS SYMFONY are trademarks owned by or licensed to Abbott Laboratories, its subsidiaries or affiliates.
© 2016 Abbott Medical Optics Inc. | www.AbbottMedicalOptics.com | PP2016CT1710


Abbott



Phaco: Know Your Fluidics Options

The latest cataract removal systems offer a host of features to aid the surgeon and increase safety. Here's what you need to know.

Christopher Kent, Senior Editor

Today's phacoemulsification systems incorporate plenty of advanced technology and clever design elements that make cataract surgery safer, faster and less taxing for the surgeon. A big part of that is fluidics—the way in which fluid is moved through the eye during surgery, which impacts how easily broken-up nucleus fragments are removed from the eye and how much the eye is disturbed by events such as occlusion of the aspiration tip.

Here, the manufacturers of the three comprehensive phaco systems available in the United States explain what makes their fluidics systems unique. Surgeons who use each system share their thoughts as well.

Alcon's Centurion Vision System: Active Fluidics

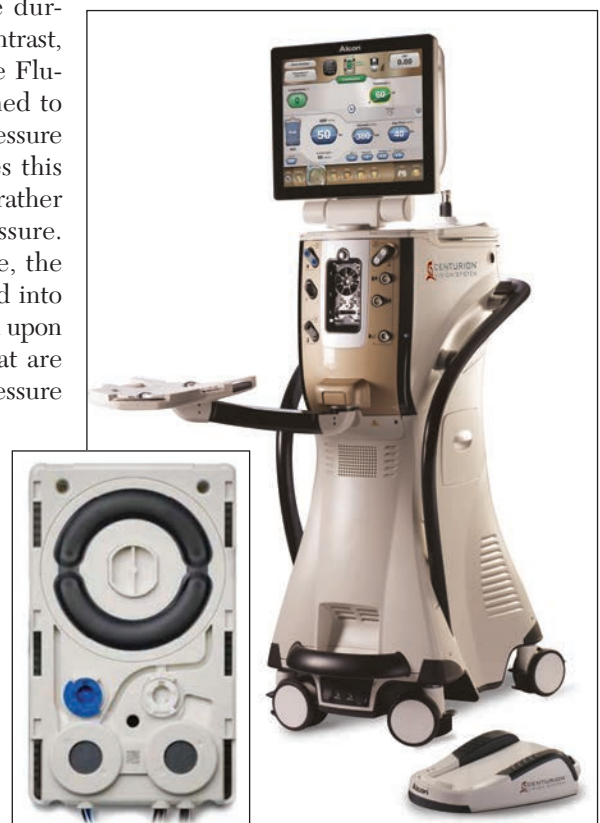Alcon's Centurion Vision System, the follow-up to the Infiniti phaco system, features what the company calls Active Fluidics Technology. Gary Sorensen, head of cataract instrumentation R&D, explains how Active Fluidics works.

"Most fluidics systems are designed

to maintain a constant pressure of fluid going into the cassette," he says. "They're usually gravity-fed; a bottle of BSS is hung above the patient and gravity provides the input pressure to maintain eye volume during the surgery. In contrast, the Centurion's Active Fluidics system is designed to maintain the target pressure inside the eye; it does this by having a variable, rather than static, input pressure. To make that possible, the bag of fluid is inserted into the machine and acted upon by pressure plates that are able to change the pressure

in the bag very rapidly in response to feedback from sensors in both the irrigation and aspiration paths within the cassette. There's also a pressure sensor on the bag itself.

Alcon's Centurion system maintains a target pressure inside the eye (instead of the fluid pressure going into the cassette). It also features a peristaltic pump (right) that doubles the available flow rate and eliminates the small pulsations usually associated with peristaltic pumps.



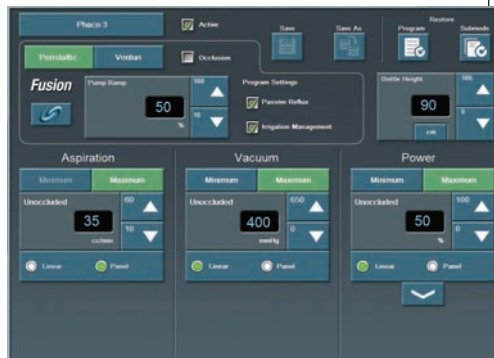“Another factor that sets the Centurion apart is its nontraditional peristaltic-style pump which, in effect, acts as two pumps pulling in parallel from the same piece of tubing,” he continues. “That has two advantages. First, we can get twice the flow rate achievable with a single pump, more than enough to overcome the resistance of the Centurion’s smaller tubing (which helps to minimize occlusion-break surge). Second, the two pumps are configured to be out of phase with each other, which cancels out the small pulsations that a peristaltic pump always produces. Those small pulses have traditionally been considered one of the downsides of peristaltic pump technology.”

Mr. Sorensen notes another design feature in the Centurion’s fluidics: rotary valves. “Standard valves close off flow by pinching the tube,” he says. “When you do that, it pushes fluid in both directions—one direction being into the eye—so when a valve closes you may see motion in the eye. We now use stopcock-type rotary valves; when open, a rotating gate is aligned with the fluid path so fluid can go by. When you turn it, it stops the flow without causing a change in volume or creating a pulse. This also makes it possible to open or close the valve just a little bit, making the flow proportional. It allows us to do a number of things that would be impossible with the old type of valve.”

In terms of being operator-friendly, Mr. Sorensen says the surgeon can now step through a series of procedures that have default values set up for all the engineering parameters, such as flow and vacuum. “The system can be used very effectively with those default settings, or it can be customized with help from Alcon personnel,” he says. “We try to keep the primary screens simple, like modern cameras; they’re point-and-shoot, but if you want to control every parameter and setting, you can.”

David Lubeck, MD, assistant clinical

professor of ophthalmology at the University of Illinois Eye Center, and director of advanced anterior segment surgery at Arbor Centers for Eyecare in Chicago, uses the Centurion system. “The Centurion fluidics control system is so adaptive and adjustable that it allows automation of the process of cataract removal,” he says. “Once a surgeon decides how he or she would like the phaco machine to behave during each phase of the procedure, Centurion can be programmed to create the desired effects. For example, the surgeon can adjust the speed at which the eye pressurizes to prevent sudden overpressurization and reverse pupillary block. As a result, chamber maintenance is so stable that cataract removal can be performed safely at near physiologic intraocular pressures of 25 to 40 mmHg. Our fluid use has been reduced to 35 to 50 ml per procedure. In my experience, surgery with the Centurion system is elegant, making it more comfortable for both surgeon and patient.”



Alan Crandall, MD, clinical professor, senior vice chair of ophthalmology and visual sciences, and director of glaucoma and cataract at the Moran Eye Center, University of Utah, says he appreciates a number of features the Centurion offers, including the

Abbott Medical Optics’ Whitestar Signature System lets the surgeon switch between a peristaltic pump and a venturi pump during surgery (see screen below), allowing the surgeon to take advantage of the different capabilities of each pump at different times.



Active Fluidics system. “The Active Fluidics system maintains the intraocular pressure, helping to maintain a very stable anterior chamber, which is important not just in routine cases but in floppy iris syndrome and pseudoexfoliation cases,” he says. “In concert with the Intrepid Balanced Tip probe, it becomes a powerful emulsification unit that uses less energy.”

AMO’s Whitestar Signature: Fusion Fluidics

Abbott Medical Optics’ Whitestar Signature System, and its recent upgrade, Whitestar Signature PRO, feature what the company calls Fusion Fluidics, with the CASE (chamber stabilization environment) system. “MK” Raheja, PhD, MBA, global head of cataract R&D for Abbott, explains what makes the Whitestar Signature’s Fusion Fluidics system unique.

“There are two different technologies that can be used to manage the fluids,” explains Dr. Raheja. “One is a peristaltic system, which uses rollers to push the liquid being removed from the eye through the tubing. The other option is a venturi system, which creates a vacuum to move the fluid. Each system has benefits. Peristaltic technology gives you great holdability and intraoperative control, which is advantageous early in the procedure. A venturi system gives the surgeon great followability; broken-up particles of the nucleus come to you, which is a big advantage during the removal part of the surgery.”

“Rather than ask the surgeon to choose one of these technologies, we made a conscious decision to design our phaco system to have both capabilities,” he explains. “That’s at the heart of what we call Fusion Fluidics. The surgeon can decide which system to use during the different parts of the surgery, using the foot pedal on the fly to engage either peristaltic or venturi aspiration.” Dr. Raheja notes that having such advanced technology in the system can seem intimidating. “As the system becomes more capable, we’re making sure it remains easy for the surgeon to use,” he says. “If a surgeon wants to alter the settings, he can, but it works beautifully in basic mode.”

Sumit Garg, MD, vice chair of clinical ophthalmology, medical director and associate professor of cataract, corneal and refractive surgery at the Gavin Herbert Eye Institute at the University of California, Irvine, uses the Whitestar Signature System. “I really enjoy operating using dual-pump fluidics,” he says. “By using the strong point of each pump I’m able to be more efficient and I find that I use less phaco energy. Having a dual pump lets me use the peristaltic pump to impale and hold the nucleus during my initial chops; subsequently, I transition to venturi fluidics for fragment removal and irrigation/aspira-

Bausch + Lomb’s Stellaris allows the surgeon to control vacuum on the fly, and its dual-linear foot pedal (below) lets the surgeon manage two parameters at once, if desired.



tion. The venturi pump allows me to keep my phaco needle near the center of the eye and use the fluidics to draw the fragments to the tip without having to ‘fish’ for fragments.”

In terms of managing post-occlusion surge, Dr. Raheja says the Signature system senses that an occlusion at the tip has occurred and automatically implements changes to minimize any surge when the occlusion breaks. Dr. Garg agrees that this makes a difference. “The combination of updated sensing and processing along with less-compliant tubing makes for improved chamber stability,” he says.

Bausch + Lomb’s Stellaris: Stable Chamber Fluidics

Bausch + Lomb’s Stellaris Vision Enhancement System features what the company calls Stable Chamber Fluidics, a vacuum-control-based system. (The Stellaris is also available as the Stellaris PC, which is capable of performing vitrectomy surgery in addition to cataract surgery. The Stellaris Elite, featuring more than a dozen new innovations, will be introduced later this year.) Chuck Hess, vice president and general manager of Bausch + Lomb’s U.S. surgical division, explains what makes the Stable Chamber Fluidics system unique.

“The Stellaris’s system allows the



surgeon to control vacuum at the tip of the device during phacoemulsification, as well as irrigation and aspiration,” he says. “This is also critical during vitrectomy surgery, which the Stellaris PC can perform.” He notes that post-occlusion surge is more of an issue with a peristaltic-pump-based system. “The Stellaris produces a very stable intraocular environment because the surgeon is able to gauge what’s happening in the eye and use the foot pedal to modulate the vacuum level. If I’m doing phaco and I see an occlusion occurring, I can reduce the vacuum by lifting up on the pedal, effectively preventing the big post-occlusion surge you may see with some systems.”

In terms of managing the system’s complexity, Mr. Hess says the development of B+L’s dual-linear foot pedal technology allows surgeons to manage multiple factors at once—if they wish. “Most surgeons like

to have two or three basic modes set up for their machines, such as dense-lens, soft-lens and small-pupil modes. On the other hand, some surgeons also like to have the ability to modulate their parameters on the fly. Dual-linear control allows the surgeon to manage two parameters, such as aspiration and power, with the foot pedal. Your foot can press down on the pedal as if it were an accelerator to control one variable, but you can also move it side to side to control a second variable.”

Inder Paul Singh, MD, who practices at The Eye Centers of Racine & Kenosha in Wisconsin, uses the Stellaris Phaco unit. “The fact that it’s vacuum-based rather than fluid-based creates many advantages,” he says. “First, you don’t have to occlude the phaco tip to build vacuum. Vacuum occurs instantaneously, allowing piec-

es of the nucleus to come to the tip so I can stay in the middle of the eye and do my usual stop-and-chop maneuver with ease, even when dealing with moderate-to-hard cataracts. This has been a big help in many small-pupil, Flomax and pseudoexfoliation cases. Vacuum-based systems also maximize efficiency for femtosecond-laser-assisted cases. In these cases, you don’t need to use as much ultrasound sculpting; the broken-up lens pieces come to the tip. This allows me to perform single-incision cataract surgery without the creation of a paracentesis because there’s no need for a second instrument to help bring them to the tip.”

Dr. Singh says he’s impressed by the chamber stability he gets. “The Stellaris decouples vacuum and flow, which leads to lower flow at high vacuum and a decreased likelihood of

surge,” he says. “It maintains excellent chamber stability even with vacuum settings of 600 mmHg. We performed a study in which we used an endoscope to video the chamber stability during a standard case, and we saw almost no movement of the iris or shallowing of the chamber.

Dr. Singh adds that he finds the dual-linear foot pedal very useful. “It gives me separate control of phaco, vacuum and irrigation,” he says. “For example, during epinuclear removal pushing down on the foot pedal controls irrigation and aspiration, but if I need a pulse of ultrasound, I can yaw to the right to get that burst. This gives me another level of control.” **REVIEW**

Dr. Singh is a consultant to Bausch + Lomb; Drs. Lubeck and Crandall are consultants for Alcon; Dr. Garg is a consultant to AMO.

HIRE THE BEST Ophthalmic Technicians



Hire experienced, certified Ophthalmic Technicians with Local Eye Site.

Also find amazing billers, insurance coders, front desk staff & office administrators.



Local Eye Site
JOBS IN EYE CARE

localeyesite.com/hire/ophthalmic-technician

The official recruiting partner for *Review of Ophthalmology*.



Indications and Usage

BromSite™ (bromfenac ophthalmic solution) 0.075% is a nonsteroidal anti-inflammatory drug (NSAID) indicated for the treatment of postoperative inflammation and prevention of ocular pain in patients undergoing cataract surgery.

Important Safety Information

- **Slow or Delayed Healing:** All topical nonsteroidal anti-inflammatory drugs (NSAIDs), including BromSite (bromfenac ophthalmic solution) 0.075%, may slow or delay healing. Topical corticosteroids are also known to slow or delay healing. Concomitant use of topical NSAIDs and topical steroids may increase the potential for healing problems.
- **Potential for Cross-Sensitivity:** There is the potential for cross-sensitivity to acetylsalicylic acid, phenylacetic acid derivatives, and other NSAIDs, including BromSite (bromfenac ophthalmic solution) 0.075%. Therefore, caution should be used when treating individuals who have previously exhibited sensitivities to these drugs.
- **Increased Bleeding Time of Ocular Tissue:** With some NSAIDs, including BromSite (bromfenac ophthalmic solution) 0.075%, there exists the potential for increased bleeding time due to interference with platelet aggregation. There have been reports that ocularly applied NSAIDs may cause increased bleeding of ocular tissues (including hyphemas) in conjunction with ocular surgery.
It is recommended that BromSite be used with caution in patients with known bleeding tendencies or who are receiving other medications which may prolong bleeding time.
- Use of topical NSAIDs may result in keratitis. Patients with evidence of corneal epithelial breakdown should immediately discontinue use of topical NSAIDs, including BromSite (bromfenac ophthalmic solution) 0.075%, and should be closely monitored for corneal health. Patients with complicated ocular surgeries, corneal denervation, corneal epithelial defects, diabetes mellitus, ocular

A DROP OF PREVENTION

FOR YOUR CATARACT SURGERY PATIENTS

Introducing the **FIRST** and **ONLY** NSAID indicated to prevent ocular pain in cataract surgery patients¹

Defend against pain and combat postoperative inflammation with the penetrating power of BromSite™ formulated with DuraSite®¹

- DuraSite increases retention time on the ocular surface and absorption of bromfenac²⁻⁵
 - Allows for increased aqueous humor concentrations
- Ensures complete coverage throughout the day with BID dosing¹

Visit bromsite.com to find out more.

BromSITE™
(bromfenac ophthalmic solution) 0.075%

Formulated with DURASITE® DELIVERY SYSTEM

surface diseases (e.g., dry eye syndrome), rheumatoid arthritis, or repeat ocular surgeries within a short period of time may be at increased risk for corneal adverse events which may become sight threatening. Topical NSAIDs should be used with caution in these patients. Post-marketing experience with topical NSAIDs also suggests that use more than 24 hours prior to surgery or use beyond 14 days postsurgery may increase patient risk for the occurrence and severity of corneal adverse events.

- BromSite should not be administered while wearing contact lenses. The preservative in BromSite, benzalkonium chloride, may be absorbed by soft contact lenses.

- The most commonly reported adverse reactions in 1% to 8% of patients were anterior chamber inflammation, headache, vitreous floaters, iritis, eye pain, and ocular hypertension.

You are encouraged to report negative side effects of prescription drugs to the FDA.

Visit www.fda.gov/medwatch or call 1-800-FDA-1088.

Please see brief summary of full Prescribing Information on the adjacent page.

NSAID=nonsteroidal anti-inflammatory drug.

References: 1. BromSite [package insert]. Cranbury, NJ: Sun Pharmaceutical Industries, Inc.; 2016. 2. Hosseini K, Hutcheson J, Bowman L. Aqueous humor concentration of bromfenac 0.09% (Bromday™) compared with bromfenac in DuraSite® 0.075% (BromSite™) in cataract patients undergoing phacoemulsification after 3 days dosing. Poster presented at: ARVO Annual Meeting; May 5-9, 2013; Seattle, Washington. 3. Bowman LM, Si E, Pang J, et al. Development of a topical polymeric mucoadhesive ocular delivery system for azithromycin. *J Ocul Pharmacol Ther.* 2009;25(2):133-139. 4. ClinicalTrials.gov. Aqueous humor concentration of InSite Vision (ISV) 303 (bromfenac in DuraSite) to Bromday once daily (QD) prior to cataract surgery. <https://clinicaltrials.gov/ct2/show/results/NCT01387464?sect=X70156&term=insite+vision&rank=1>. Accessed July 18, 2016. 5. Si EC, Bowman LM, Hosseini K. Pharmacokinetic comparisons of bromfenac in DuraSite and Xibrom. *J Ocul Pharmacol Ther.* 2011;27(1):61-66.

BromSite™ (bromfenac ophthalmic solution) 0.075% Brief Summary

INDICATIONS AND USAGE

BromSite™ (bromfenac ophthalmic solution) 0.075% is a nonsteroidal anti-inflammatory drug (NSAID) indicated for the treatment of postoperative inflammation and prevention of ocular pain in patients undergoing cataract surgery.

DOSAGE AND ADMINISTRATION

Recommended Dosing

One drop of BromSite should be applied to the affected eye twice daily (morning and evening) 1 day prior to surgery, the day of surgery, and 14 days postsurgery.

Use with Other Topical Ophthalmic Medications

BromSite should be administered at least 5 minutes after instillation of other topical medications.

Dosage Forms and Strengths

Topical ophthalmic solution: bromfenac 0.075%.

CONTRAINDICATIONS

None

WARNINGS AND PRECAUTIONS

Slow or Delayed Healing

All topical nonsteroidal anti-inflammatory drugs (NSAIDs), including BromSite (bromfenac ophthalmic solution) 0.075%, may slow or delay healing. Topical corticosteroids are also known to slow or delay healing. Concomitant use of topical NSAIDs and topical steroids may increase the potential for healing problems.

Potential for Cross-Sensitivity

There is the potential for cross-sensitivity to acetylsalicylic acid, phenylacetic acid derivatives, and other NSAIDs, including BromSite (bromfenac ophthalmic solution) 0.075%. Therefore, caution should be used when treating individuals who have previously exhibited sensitivities to these drugs.

Increased Bleeding Time of Ocular Tissue

With some NSAIDs, including BromSite (bromfenac ophthalmic solution) 0.075%, there exists the potential for increased bleeding time due to interference with platelet aggregation. There have been reports that ocularly applied NSAIDs may cause increased bleeding of ocular tissues (including hyphemas) in conjunction with ocular surgery.

It is recommended that BromSite be used with caution in patients with known bleeding tendencies or who are receiving other medications which may prolong bleeding time.

Keratitis and Corneal Reactions

Use of topical NSAIDs may result in keratitis. In some susceptible patients, continued use of topical NSAIDs may result in epithelial breakdown, corneal thinning, corneal erosion, corneal ulceration or corneal perforation. These events may be sight threatening. Patients with evidence of corneal epithelial breakdown should immediately discontinue use of topical NSAIDs, including BromSite (bromfenac ophthalmic solution) 0.075%, and should be closely monitored for corneal health.

Post-marketing experience with topical NSAIDs suggests that patients with complicated ocular surgeries, corneal denervation, corneal epithelial defects, diabetes mellitus, ocular surface diseases (e.g., dry eye syndrome), rheumatoid arthritis, or repeat ocular surgeries within a short period of time may be at increased risk for corneal adverse events which may become sight threatening. Topical NSAIDs should be used with caution in these patients.

Post-marketing experience with topical NSAIDs also suggests that use more than 24 hours prior to surgery or use beyond 14 days postsurgery may increase patient risk for the occurrence and severity of corneal adverse events.

Contact Lens Wear

BromSite should not be administered while wearing contact lenses. The preservative in BromSite, benzalkonium chloride, may be absorbed by soft contact lenses.

ADVERSE REACTIONS

Clinical Trial Experience

Because clinical trials are conducted under widely varying conditions, adverse reaction rates observed in the clinical trials of a drug cannot be directly compared to rates in the clinical trials of another drug and may not reflect the rates observed in clinical practice.

The most commonly reported adverse reactions in 1–8% of patients were: anterior chamber inflammation, headache, vitreous floaters, iritis, eye pain and ocular hypertension.

USE IN SPECIFIC POPULATIONS

Pregnancy

Risk Summary

There are no adequate and well-controlled studies in pregnant women to inform any drug associated risks. Treatment of pregnant rats and rabbits with oral bromfenac did not produce teratogenic effects at clinically relevant doses.

Clinical Considerations

Because of the known effects of prostaglandin biosynthesis-inhibiting drugs on the fetal cardiovascular system (closure of ductus arteriosus), the use of BromSite during late pregnancy should be avoided.

Data

Animal Data

Treatment of rats with bromfenac at oral doses up to 0.9 mg/kg/day (195 times a unilateral daily human ophthalmic dose on a mg/m² basis, assuming 100% absorbed) and rabbits at oral doses up to 7.5 mg/kg/day (3243 times a unilateral daily dose on a mg/m² basis) produced no structural teratogenicity in reproduction studies. However, embryo-fetal lethality, neonatal mortality and reduced postnatal growth were produced in rats at 0.9 mg/kg/day, and embryo-fetal lethality was produced in rabbits at 7.5 mg/kg/day. Because animal reproduction studies are not always predictive of human response, this drug should be used during pregnancy only if the potential benefit justifies the potential risk to the fetus.

Lactation

There are no data on the presence of bromfenac in human milk, the effects on the breastfed infant, or the effects on milk production; however, systemic exposure to bromfenac from ocular administration is low. The developmental and health benefits of breastfeeding should be considered along with the mother's clinical need for bromfenac and any potential adverse effects on the breast-fed child from bromfenac or from the underlying maternal condition.

Pediatric Use

Safety and efficacy in pediatric patients below the age of 18 years have not been established.

Geriatric Use

There is no evidence that the efficacy or safety profiles for BromSite differ in patients 65 years of age and older compared to younger adult patients.

NONCLINICAL TOXICOLOGY

Carcinogenesis, Mutagenesis and Impairment of Fertility

Long-term carcinogenicity studies in rats and mice given oral doses of bromfenac up to 0.6 mg/kg/day (129 times a unilateral daily dose assuming 100% absorbed, on a mg/m² basis) and 5 mg/kg/day (540 times a unilateral daily dose on a mg/m² basis), respectively revealed no significant increases in tumor incidence.

Bromfenac did not show mutagenic potential in various mutagenicity studies, including the bacterial reverse mutation, chromosomal aberration, and micronucleus tests.

Bromfenac did not impair fertility when administered orally to male and female rats at doses up to 0.9 mg/kg/day and 0.3 mg/kg/day, respectively (195 and 65 times a unilateral daily dose, respectively, on a mg/m² basis).

PATIENT COUNSELING INFORMATION

Slow or Delayed Healing

Advise patients of the possibility that slow or delayed healing may occur while using NSAIDs.

Concomitant Topical Ocular Therapy

If more than one topical ophthalmic medication is being used, advise patients to administer BromSite at least 5 minutes after instillation of other topical medications.

Concomitant Use of Contact Lenses

Advise patients not to wear contact lenses during administration of BromSite. The preservative in this product, benzalkonium chloride, may be absorbed by soft contact lenses.

Sterility of Dropper Tip/Product Use

Advise patients to replace the bottle cap after use and do not touch the dropper tip to any surface as this may contaminate the contents.

Advise patients to thoroughly wash hands prior to using BromSite.

Rx Only

Distributed by: Sun Pharmaceutical Industries, Inc. Cranbury, NJ 08512

BromSite is a trademark of Sun Pharma Global FZE.
SUN-OPH-BRO-017 09/2016





What's New in 2017?

This month, we take a look at Medicare's updates for 2017 and how they might affect your practice.

Q Did the 2017 Medicare Physician Fee Schedule include the 0.5-percent increase included in the Medicare Access and CHIP Reauthorization Act of 2015?

A Yes. The 2017 Physician Fee Schedule Rule published in the Federal Register on November 15, 2016 is the second since the repeal of the Sustainable Growth Rate formula by the MACRA. The 2017 conversion factor is \$35.8887, which is a slight increase from the 2016 conversion factor of \$35.8043. It includes a budget neutrality adjustment of -0.013 percent, an increase of 0.5 percent resulting from MACRA and a misvalued code reduction target adjustment of -0.18 percent.

Q Are there significant changes to RVUs for ophthalmic services?

A Of the 553 CPT codes that apply to ophthalmology and optometry within the Medicare program, 526 of them changed very little: By three percent or less. Nine procedures had substantial increases in reimbursement;

18 had substantial reductions in reimbursement. Average change in Medicare reimbursement rates for ophthalmic services is miniscule (0.01 percent). Some retina and glaucoma procedure codes were favorably revalued after significant reductions in 2016. Others were reduced when the postop period was shortened to 10 days.

Q Is there a particular type of service that changes dramatically in 2017?

A Yes. In 2017, Medicare reimbursement for all ophthalmic imaging services is dramatically reduced (*See Table 1*). The redefinition of angiography as a bilateral service magnified the reduction. Formerly, angiography was paid per eye.

Q Will hospital outpatient departments and ambulatory surgery centers experience increases in facility reimbursement in 2017?

A Various adjustments to hospital reimbursement result in a

Table 1. Medicare Payments for Ophthalmic Imaging

CPT	Description	2016	2017	Change %
92235	Fluorescein angiography*	\$111	\$87	-24%
92240	ICG angiography*	\$257	\$211	-20%
92242	FA & ICG*	N/A	\$230	N/A
92250	Fundus photography	\$79	\$67	-16%
92132	SCODI, anterior	\$35	\$32	-10%
92133	SCODI, optic nerve	\$44	\$38	-14%
92134	SCODI, retina	\$45	\$42	-8%

*In 2017, these procedures are defined as bilateral services.

Hospital Outpatient Department rate increase of 1.65 percent.

For 2017, the wage adjustment for budget neutrality in addition to the multifactor productivity-adjusted update factor increases the ASC conversion factor by 1.9 percent for those meeting the quality reporting requirements, resulting in small increases in facility reimbursement.

Q Are there new quality measures for ASCs to report in 2017?

A No. No new measures were added in 2017, which would affect payments in 2019. Seven additional measures were finalized for implementation in 2018, which will affect 2020 payments.

Q Did MACRA impose any new reporting requirements for surgeons?

A Yes. As of January 1, 2017, MACRA, Section 1848(c)(8) (B), requires collection of data to value global surgical packages including the number of and level of visits in the global period and other items and services related to surgery. The proposed rule contained onerous reporting requirements vehemently opposed by surgeons of all specialties. The final rule revises the reporting to include the following:

- submit with CPT code 99024;
- applies to groups with 10 or more practitioners;
- only applies in certain states (Florida, Kentucky, Louisiana, Nevada, New Jersey, North Dakota, Ohio, Oregon, Rhode Island);
- report services annually by more than 100 practitioners and more than 10,000 times or have allowed charges in excess

- of \$10 million annually;
- can report beginning January 1, 2017; and
- mandatory reporting starting July 1, 2017.

The final list of codes will be posted to the CMS website; there are only 40 CPT codes that might potentially apply to ophthalmology.

Some retina and glaucoma procedure codes were favorably revalued after significant reductions in 2016. Others were reduced when the postop period was shortened to 10 days

Q What CPT code changes became effective on January 1, 2017?

A Category I CPT code changes are as follows:

New code:
 Δ 92242 *Fluorescein angiography and indocyanine-green angiography (includes multiframe imaging) performed at the same patient encounter with interpretation and report.*

The following codes contain language changes described by underlines and represent clarifications and, in some cases, substantive revisions:

Δ 67101 *Repair of retinal detachment, one or more sessions; cryotherapy or diathermy including drainage of subretinal fluid when*

performed; cryotherapy.

Δ 67105 *Photocoagulation including drainage of subretinal fluid, when performed.*

Δ 92235 *Fluorescein angiography (includes multiframe imaging) with interpretation and report, unilateral or bilateral.*

Δ 92240 *Indocyanine-green angiography (includes multiframe imaging) with interpretation and report, unilateral or bilateral.*

Deleted in 2017:

Δ 92140 *Provocative tests for glaucoma, with interpretation and report, without tonography.*

Q Are there any new Category III codes for 2017?

A Released semiannually by the American Medical Association, new Category III codes became effective January 1, 2017 following the six-month implementation period that began July 1, 2016.

Δ 0444T – *Initial placement of a drug-eluting ocular insert under one or more eyelids, including fitting, training, and insertion, unilateral or bilateral.*

Δ 0445T – *Subsequent placement of a drug-eluting ocular insert under one or more eyelids, including re-training, and removal of existing insert, unilateral or bilateral.*

Δ 0449T – *Insertion of anterior segment drainage device, without extraocular reservoir; internal approach, into the subconjunctival space.*

Δ +0450T – *each additional device (List separately in addition to code for primary procedure).*

Use 92499 For removal of aqueous drainage device without extraocular reservoir, placed into the subconjunctival space via internal approach.

Two new and one revised Category III codes are effective January 1, 2017 and will be published in the 2018 CPT manual:

Δ 0464T Visual evoked potential, testing for glaucoma, with interpretation and report.

For visual evoked potential screening for visual acuity, use 0333T.

Δ 0465T Suprachoroidal injection of a pharmacologic agent (does not include supply of medication.)

To report intravitreal injection/implantation, see 67025, 67027 or 67028.

Δ 0333T Visual evoked potential, screening of visual acuity, automated, with report.

Coverage and payment for Category III codes remains at the discretion of the Medicare Administrative Contractor.

Q What types of regulatory issues were identified in the Office of Inspector General's annual work plan as areas of concern for ophthalmology in 2017?

A The annual publication of the Office of Inspector General's Work Plan contains a few targets for scrutiny of concern to ophthalmologists and optometrists. The targets are:

- Drug Waste of Single-Vial Drugs (new);
- Management Review: CMS' Implementation of the Quality Payment Program (new);
- ASC – Quality Oversight;
- Anesthesia services – Payments for personally performed services.

Q What Medicare Part B changes affect beneficiaries from a cost perspective in 2017?

A The Medicare Part B basic premium increases to \$109 for most beneficiaries. The Part B deductible increases to \$183. This is a \$17 increase from the 2016 deductible.

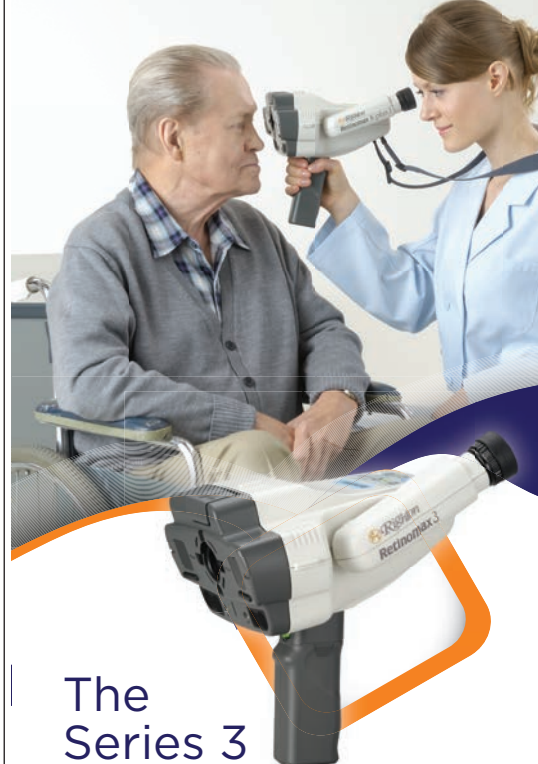Q What changes occurred with the Medicare Quality Programs?

A MACRA consolidates the current quality reporting programs of PQRS, EHR Meaningful Use and the Value-Based Payment Modifier into a new program: the Merit-Based Incentive Payment System. The law stipulates a January 1, 2017 start date, but the first bonus or penalty occurs in 2019 based on a two-year look-back. The penalties associated with the current quality reporting programs sunset after 2018.

Q Were changes made to the electronic health record Meaningful Use reporting?

A Yes. The 2015 Electronic Health Record Flexibility Rule revised the requirements for Meaningful Use attestation. For 2015 to 2017, all eligible professionals must report on 10 mandatory objectives included in the Modified Stage 2 Rule. Failure to attest for 2016 participation results in a 4-percent penalty in 2018. Providers who have already attested to MU in prior years are required to report MU for any continuous 90-day period in 2016 and 2017. The reporting deadline for 2016 is February 28, 2017. If a provider has never attested to MU and is attesting for the first time, attestation by October 1, 2017 avoids a 2018 penalty. **REVIEW**

Ms. McCune is vice president of the Corcoran Consulting Group. Contact her at DMcCune@corcoranccg.com.



The Series 3

RETINOMAX HAND-HELD Autorefractor

Precise measurements
Anywhere - Anytime



- Accurate
- Fast
- Portable
- Efficient

 **Righton**

S4 OPTIK

250 Cooper Ave., Suite 100 Tonawanda NY 14150
www.s4optik.com | 888-224-6012

Sensible equipment. Well made, well priced.
For today's modern office.

Toric IOLs: Nailing the Target Meridian

Christopher Kent, Senior Editor

Surgeons explain how to provide your patients with outstanding results using these lenses.

Like multifocal intraocular lenses, toric IOLs are considered to be premium lenses. However, they have one striking advantage over multifocal IOLs: They're not associated with many postoperative optical complaints. Instead, they correct a basic problem shared by millions of eyes, improving post-cataract surgery vision—in some cases dramatically. However, in order for a toric lens to effectively reduce or eliminate astigmatism, its toric axis must be accurately aligned with the target meridian. Every degree of misalignment eliminates about 3.3 percent of the astigmatism correction, so a multi-degree misalignment can significantly undercut the value of the lens.

To get the best outcome with a toric lens, surgeons say it's important to do three things well: measure the astigmatic axis accurately; have an effective way to visualize the target meridian when the patient is on the table; and position the lens inside the eye during surgery so the lens is aligned with that target meridian and remains there postoperatively. Here, three surgeons with extensive experience implanting these lenses share their advice on how to achieve all of these goals, whether you're using relatively low-tech instruments or the latest in advanced measuring and marking systems.

Measuring: The Basics

While advanced technology can increase the precision of lens alignment, the basic equipment found in most practices can still do a good job. [For more on this, see "Toric Lenses: What's Holding You Back?" on p. 28.] If you don't have access to the latest advanced instrumentation, Robert H. Osher, MD, a professor in the department of ophthalmology at the University of Cincinnati College of Medicine and medical director emeritus at the Cincinnati Eye Institute in Ohio, recommends relying on three basic instruments. "Everyone can do manual keratometry," he notes. "Today, the majority of cataract surgeons also have an automated keratometer—either IOLMaster or LenStar. Everybody should also have a topography unit. That's important because you need to see what kind of cylinder you're dealing with, so you can differentiate keratoconus or some irregular contact lens problem from regular cylinder. Of course, the presence of an unusual finding doesn't mean you're not going to offer a toric lens, but it certainly means that you have to explain the situation to the patient."


Stephen S. Lane, MD, medical director at Associated Eye Care and adjunct clinical professor of ophthalmology

mology at the University of Minnesota in Minneapolis, says your axis determination should be reasonably accurate if you use an automated keratometer and topography. "Primarily, you have to begin with good preoperative keratometry readings," he says. "A number of devices can give you that; even manual keratometry can give you good, reproducible data if you have someone who is very good at performing it. But today, I think most doctors are using an IOLMaster or LenStar to determine these measurements." Topcon's Aladdin and Movu's Argos are other options surgeons can use for biometry.

"Topography is probably the best technology we have today to measure the axis," Dr. Lane adds. "The axis of astigmatism should correlate quite nicely with the automated keratometry readings that you would get with an IOLMaster or LenStar, assuming that you're measuring a relatively normal, healthy cornea. They won't necessarily agree exactly, but they should be very close. Then, you can use all of the various readings to hone in on what is the most likely—or at least the average—keratometry reading. The more readings you have, the better your result. In most cases I rely on automated keratometry for magnitude; I believe topography is probably the most accurate and sensitive in terms of the axis."

More Data = Greater Accuracy

Dr. Osher explains that measuring with multiple technologies helps to eliminate outlier measurements. "All of the machines measure slightly differently," he notes. "A study we published looked at the question of how much your accuracy improves if you measure with more than one instrument and 'meld,' or average, the numbers.¹ After testing 87 eyes of 54 patients we found that if you only measure with one technology, the number you end up with will be an outlier about 20 percent of the time.



Stephen S. Lane, MD

The Verion's toric IOL guidance overlay, with the target axis set at 95 degrees. The toric IOL would be rotated to align with this 95-degree guide, with no need for ink marks.

If you measure with two technologies, that drops to 8 to 10 percent. But if you use three technologies, only about 2 percent of the numbers you end up with are outliers. Everyone does manual keratometry, and everyone should do an automated K. In addition, you should get topography, because you need to understand what the astigmatism pattern looks like."

Although the basic gear found in most practices today can do a good job of determining the target meridian and amount of astigmatism, there's no question that having additional advanced technology can increase your accuracy. Dr. Osher has access to multiple technologies and takes full advantage of them.

"Because I'm somewhat of an academician and I love technology, I collect additional measurements with other devices," says Dr. Osher. "I measure with the iTrace because I want to see the aberrometry and those Ks. I use the Pentacam because I want to measure the posterior cornea. And I have the luxury of using both the IOLMaster and the LenStar, so I end up with six sets of Ks for every patient. Of course, I would never recommend that every ophthalmologist do this, because the extra work and expense would convince many surgeons not to offer toric lenses. But I want to see all of those measurements because I think they're important. They improve my understanding and increase my confidence.

"When I average all of these mea-

S4OPTIK



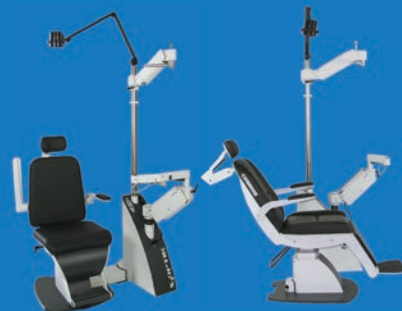SMART COMBO UNITS

space & functionality

A complete solution at an affordable price.

- Small footprint
- Robust all metal construction built for longevity
- Focus on patient comfort
- Spectacular engineering
- Smooth tilt/glide function

Configurations & solutions for every office.



S4OPTIK

250 Cooper Ave., Suite 100 Tonawanda NY 14150

www.s4optik.com | 888-224-6012

Sensible equipment. Well made, well priced.

For today's modern office.

Toric Lenses: What's Holding You Back?

Robert H. Osher, MD, medical director emeritus at the Cincinnati Eye Institute in Ohio, notes that current use of toric lenses in the United States is about 7.5 percent. “That isn’t changing very rapidly,” he says. “I can see five concerns that may be holding surgeons back: the cost to the patient; taking the time to talk to these patients; having enough technology in your practice; knowing how to interpret the technology; and knowing how to plan and execute the surgery. In reality, the surgery itself is about the same as a routine cataract, yet these lenses can give our patients the best possible vision.”

Stephen S. Lane, MD, medical director at Associated Eye Care and adjunct clinical professor of ophthalmology at the University of Minnesota in Minneapolis, agrees. “Overall, I think there are far fewer toric lenses being placed than should be,” he says. “Many patients are good candidates for these lenses. We wouldn’t prescribe eyeglasses for our patients and leave the cylinder out of the prescription, so it makes no sense to do cataract surgery and deliberately fail to correct the cylinder.”

Dr. Lane suspects that one of the barriers to wider use of toric IOLs in the United States is the belief—held by many surgeons—that to get good results it’s necessary to use advanced-technology alignment devices and/or aberrometry. “I think that’s a misunderstanding,” he says. “The first thing to remember is that the original clinical trials didn’t use anything more than manual keratometry and alignment with ink marks that the surgeon placed manually with the patient sitting upright. In the original FDA clinical trial with Alcon toric IOLs, 97 percent of patients were independent of spectacles at distance when both eyes were implanted, using what we would consider today to be relatively crude tools. So getting good results is not predicated upon having high-tech alignment devices and aberrometers. Those tools certainly can improve results, but surgeons and practices that are considering offering or starting to offer toric IOLs to their patients need to realize they don’t have to have all the toys that are now available in order to do this. You can get very good results with a few basic instruments.”

—CK

surements together, it’s amazing how consistent the numbers are,” he says. “If one measurement is an outlier, I throw it out, but I usually get very good consistency on both the meridian and the amount of cylinder. Furthermore, if more than one reading is an outlier, then I check the topography for warpage or tear-film integrity, or search for some other problem. The patient may not be an ideal candidate for a toric lens, and needs to be told.”

Marking, from Ink to High-tech

Once you’ve decided on the target meridian, you have to use some form of guidance that will allow you to align the IOL along that meridian. The least expensive and most common (and arguably least accurate) method is to place ink marks on the cornea. “We all know that ink diffuses, and in the worst-case scenario it disappears completely,” says Dr. Osher. “Even with accurate marking, ink marks are often 5 or 10 degrees off, and every degree away from the target meridian eliminates about 3.3 percent of the effect of the toric lens. That’s why I developed

the Thermodot device, which will finally be released this year by Beaver-Visitec International [Waltham, Mass.]. It makes a tiny pinpoint cautery mark that eliminates the need for ink. The mark is so small it isn’t even felt by the patient, and it’s gone in a day or two. To become even more accurate, I’d suggest iris fingerprinting, which is very inexpensive compared to aberrometry or the sophisticated registration methods. You use a camera to take a picture and then very inexpensive software tells you at which degree each iris landmark is located.”

Dr. Lane notes that you’re likely to achieve the greatest accuracy of alignment with toric IOLs when using a guidance system such as Verion, Callisto or the TrueVision system. “With those technologies, you’re trying to align the lens inside the eye relative to a fine line, as opposed to an ink mark. [Despite its drawbacks,] an ink mark can be fairly accurate—that’s what we used in the initial [toric IOL] clinical trial, producing pretty good results. But since we’re trying to get as close as we possibly can to the correct axis, there’s no question that guidance tech-

nologies can give us greater accuracy.”

In addition to using Thermodots, Dr. Osher currently favors Zeiss’s Callisto Eye System for aligning his toric lenses. “It stores the original IOL-Master biometry measurements and memorizes the anatomy,” he explains. “When you’re in the OR, you turn on the Callisto Eye System monitor and it registers and links up the preoperative and live images. Then, you press a button and the axis appears in your ocular. It looks like a two-lane highway, making it very easy to align the lens. It’s simple, quick and accurate.” [See example on p. 32.]

David F. Chang, MD, clinical professor at the University of California, San Francisco, and in private practice in Los Altos, Calif., agrees. “We’ve used the Zeiss Callisto markerless system for nearly two years, and it’s a no-brainer,” he says. “If you already have an IOLMaster 500, you can add an inexpensive camera attachment to the front of the machine. There’s no click fee, and it saves a lot of time for the surgeon and the nursing staff in terms of operating room workflow. The improved accuracy is immediately



The PROLENSA® Effect POWERED FOR PENETRATION

Advanced Formulation to Facilitate
Corneal Penetration¹⁻³

PROLENSA® delivers potency and
corneal penetration with QD dosing
at a low concentration¹⁻³

INDICATIONS AND USAGE

PROLENSA® (bromfenac ophthalmic solution) 0.07% is a nonsteroidal anti-inflammatory drug (NSAID) indicated for the treatment of postoperative inflammation and reduction of ocular pain in patients who have undergone cataract surgery.

IMPORTANT SAFETY INFORMATION ABOUT PROLENSA®

- PROLENSA® contains sodium sulfite, a sulfite that may cause allergic type reactions including anaphylactic symptoms and life-threatening or less severe asthmatic episodes in certain susceptible people. The overall prevalence of sulfite sensitivity in the general population is unknown and probably low. Sulfite sensitivity is seen more frequently in asthmatic than in non-asthmatic people.
 - All topical nonsteroidal anti-inflammatory drugs (NSAIDs), including bromfenac, may slow or delay healing. Concomitant use of topical NSAIDs and topical steroids may increase the potential for healing problems.
 - There is the potential for cross-sensitivity to acetylsalicylic acid, phenylacetic acid derivatives, and other NSAIDs, including bromfenac. Use with caution in patients who have previously exhibited sensitivities to these drugs.
 - There have been reports that ocularly applied NSAIDs may cause increased bleeding of ocular tissues (including hyphemas) in conjunction with ocular surgery. Use with caution in patients with known bleeding tendencies or who are receiving other medications which may prolong bleeding time.
- Use of topical NSAIDs may result in keratitis. Patients with evidence of corneal epithelial breakdown should immediately discontinue use of topical NSAIDs, including bromfenac, and should be closely monitored for corneal health. Patients with complicated ocular surgeries, corneal denervation, corneal epithelial defects, diabetes mellitus, ocular surface diseases (e.g., dry eye syndrome), rheumatoid arthritis, or repeat ocular surgeries within a short period of time may be at increased risk for corneal adverse events which may become sight threatening. Topical NSAIDs should be used with caution in these patients. Post-marketing experience with topical NSAIDs suggests that use more than 24 hours prior to surgery or use beyond 14 days post-surgery may increase patient risk for the occurrence and severity of corneal adverse events.
 - PROLENSA® should not be instilled while wearing contact lenses. The preservative in PROLENSA®, benzalkonium chloride, may be absorbed by soft contact lenses. Lenses may be reinserted after 10 minutes following administration of PROLENSA®.
 - The most commonly reported adverse reactions in 3%-8% of patients were anterior chamber inflammation, foreign body sensation, eye pain, photophobia, and blurred vision.

Please see brief summary of full Prescribing Information for PROLENSA® on adjacent page.

References: 1. PROLENSA Prescribing Information, April 2013. 2. Data on file, Bausch & Lomb Incorporated. 3. Baklayan GA, Patterson HM, Song CK, Gow JA, McNamara TR. 24-hour evaluation of the ocular distribution of [¹⁴C]-labeled bromfenac following topical instillation into the eyes of New Zealand white rabbits. *J Ocul Pharmacol Ther.* 2008;24(4):392-398.

PROLENSA is a registered trademark of Bausch & Lomb Incorporated or its affiliates.
© Bausch & Lomb Incorporated. All rights reserved. Printed in USA. PRA.0188.USA.15

BAUSCH + LOMB

PROLENSA®
(bromfenac ophthalmic
solution) 0.07%

BRIEF SUMMARY OF PRESCRIBING INFORMATION

This Brief Summary does not include all the information needed to prescribe Prolensa safely and effectively. See full prescribing information for Prolensa.

PROLENSA (bromfenac ophthalmic solution) 0.07%

Rx only

Initial Rx Approval: 1997

INDICATIONS AND USAGE

PROLENSA® (bromfenac ophthalmic solution) 0.07% is indicated for the treatment of postoperative inflammation and reduction of pain in patients who have undergone cataract surgery.

DOSAGE AND ADMINISTRATION

Recommended Dosing

One drop of PROLENSA ophthalmic solution should be applied to the affected eye once daily beginning 1 day prior to cataract surgery, continued on the day of surgery, and through the first 14 days of the postoperative period.

Use with Other Topical Ophthalmic Medications

PROLENSA ophthalmic solution may be administered in conjunction with other topical ophthalmic medications such as alpha-agonists, beta-blockers, carbonic anhydrase inhibitors, cycloplegics, and mydriatics. Drops should be administered at least 5 minutes apart.

CONTRAINDICATIONS

None

WARNINGS AND PRECAUTIONS

Sulfite Allergic Reactions

Contains sodium sulfite, a sulfite that may cause allergic-type reactions including anaphylactic symptoms and life-threatening or less severe asthmatic episodes in certain susceptible people. The overall prevalence of sulfite sensitivity in the general population is unknown and probably low. Sulfite sensitivity is seen more frequently in asthmatic than in non-asthmatic people.

Slow or Delayed Healing

All topical nonsteroidal anti-inflammatory drugs (NSAIDs), including bromfenac, may slow or delay healing. Topical corticosteroids are also known to slow or delay healing. Concomitant use of topical NSAIDs and topical steroids may increase the potential for healing problems.

Potential for Cross-Sensitivity

There is the potential for cross-sensitivity to acetylsalicylic acid, phenylacetic acid derivatives, and other NSAIDs, including bromfenac. Therefore, caution should be used when treating individuals who have previously exhibited sensitivities to these drugs.

Increased Bleeding Time

With some NSAIDs, including bromfenac, there exists the potential for increased bleeding time due to interference with platelet aggregation. There have been reports that ocularly applied NSAIDs may cause increased bleeding of ocular tissues (including hyphemas) in conjunction with ocular surgery.

It is recommended that PROLENSA ophthalmic solution be used with caution in patients with known bleeding tendencies or who are receiving other medications which may prolong bleeding time.

Keratitis and Corneal Reactions

Use of topical NSAIDs may result in keratitis. In some susceptible patients, continued use of topical NSAIDs may result in epithelial breakdown, corneal thinning, corneal erosion, corneal ulceration, or corneal perforation. These events may be sight threatening. Patients with evidence of corneal epithelial breakdown should immediately discontinue use of topical NSAIDs, including bromfenac, and should be closely monitored for corneal health.

Post-marketing experience with topical NSAIDs suggests that patients with complicated ocular surgeries, corneal denervation, corneal epithelial defects, diabetes mellitus, ocular surface diseases (e.g., dry eye syndrome), rheumatoid arthritis, or repeat ocular surgeries within a short period of time may be at increased risk for corneal adverse events which may become sight threatening. Topical NSAIDs should be used with caution in these patients.

Post-marketing experience with topical NSAIDs also suggests that use more than 24 hours prior to surgery or use beyond 14 days post-surgery may increase patient risk for the occurrence and severity of corneal adverse events.

Contact Lens Wear

PROLENSA should not be instilled while wearing contact lenses. Remove contact lenses prior to instillation of PROLENSA. The preservative in PROLENSA, benzalkonium chloride may be absorbed by soft contact lenses. Lenses may be reinserted after 10 minutes following administration of PROLENSA.

ADVERSE REACTIONS

Clinical Trial Experience

Because clinical trials are conducted under widely varying conditions, adverse reaction rates observed in the clinical trials of a drug cannot be directly compared to

rates in the clinical trials of another drug and may not reflect the rates observed in clinical practice.

The most commonly reported adverse reactions following use of PROLENSA ophthalmic solution following cataract surgery include: anterior chamber inflammation, foreign body sensation, eye pain, photophobia and vision blurred. These reactions were reported in 3 to 8% of patients.

USE IN SPECIFIC POPULATIONS

Pregnancy

Treatment of rats at oral doses up to 0.9 mg/kg/day (systemic exposure 90 times the systemic exposure predicted from the recommended human ophthalmic dose [RHOD] assuming the human systemic concentration is at the limit of quantification) and rabbits at oral doses up to 7.5 mg/kg/day (150 times the predicted human systemic exposure) produced no treatment-related malformations in reproduction studies. However, embryo-fetal lethality and maternal toxicity were produced in rats and rabbits at 0.9 mg/kg/day and 7.5 mg/kg/day, respectively. In rats, bromfenac treatment caused delayed parturition at 0.3 mg/kg/day (30 times the predicted human exposure), and caused dystocia, increased neonatal mortality, and reduced postnatal growth at 0.9 mg/kg/day.

There are no adequate and well-controlled studies in pregnant women. Because animal reproduction studies are not always predictive of human response, this drug should be used during pregnancy only if the potential benefit justifies the potential risk to the fetus.

Because of the known effects of prostaglandin biosynthesis-inhibiting drugs on the fetal cardiovascular system (closure of ductus arteriosus), the use of PROLENSA ophthalmic solution during late pregnancy should be avoided.

Nursing Mothers

Caution should be exercised when PROLENSA is administered to a nursing woman.

Pediatric Use

Safety and efficacy in pediatric patients below the age of 18 have not been established.

Geriatric Use

There is no evidence that the efficacy or safety profiles for PROLENSA differ in patients 70 years of age and older compared to younger adult patients.

NONCLINICAL TOXICOLOGY

Carcinogenesis, Mutagenesis and Impairment of Fertility

Long-term carcinogenicity studies in rats and mice given oral doses of bromfenac up to 0.6 mg/kg/day (systemic exposure 30 times the systemic exposure predicted from the recommended human ophthalmic dose [RHOD] assuming the human systemic concentration is at the limit of quantification) and 5 mg/kg/day (340 times the predicted human systemic exposure), respectively, revealed no significant increases in tumor incidence.

Bromfenac did not show mutagenic potential in various mutagenicity studies, including the reverse mutation, chromosomal aberration, and micronucleus tests. Bromfenac did not impair fertility when administered orally to male and female rats at doses up to 0.9 mg/kg/day and 0.3 mg/kg/day, respectively (systemic exposure 90 and 30 times the predicted human exposure, respectively).

PATIENT COUNSELING INFORMATION

Slowed or Delayed Healing

Advise patients of the possibility that slow or delayed healing may occur while using NSAIDs.

Sterility of Dropper Tip

Advise patients to replace bottle cap after using and to not touch dropper tip to any surface, as this may contaminate the contents. Advise patients that a single bottle of PROLENSA be used to treat only one eye.

Concomitant Use of Contact Lenses

Advise patients to remove contact lenses prior to instillation of PROLENSA. The preservative in PROLENSA, benzalkonium chloride, may be absorbed by soft contact lenses. Lenses may be reinserted after 10 minutes following administration of PROLENSA.

Concomitant Topical Ocular Therapy

If more than one topical ophthalmic medication is being used, the medicines should be administered at least 5 minutes apart.

Rx Only

Manufactured by:

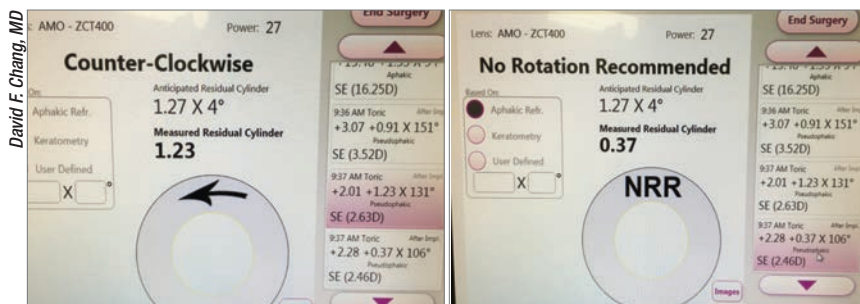
Bausch + Lomb, a division of Valeant Pharmaceuticals
North America LLC, Bridgewater, NJ 08807 USA

Product under license from:

Senju Pharmaceutical Co., Ltd., Osaka, Japan 541-0046
Prolensa is a trademark of Bausch & Lomb Incorporated or its affiliates.
© Bausch & Lomb Incorporated

Revised: 06/2016
Based on: 9306701/9306801

PRA.0119.USA.16



An example of ORA intraoperative aberrometry screenshots during the alignment of a toric IOL. (The column on the right side of the screen shows the refractive cylinder with different alignments.) Left: With 1.23 D of measured residual astigmatism, the software recommends counterclockwise rotation of the toric IOL. Right: Slight counterclockwise rotation has resulted in a reduction of the astigmatism to 0.37 D and a determination of “no rotation recommended.”

obvious when you first use it to align a toric IOL.”

Intraoperative Aberrometry

Dr. Chang likes to use intraoperative wavefront aberrometry in addition to digital intraoperative axis alignment. “I use an aphakic reading with the ORA system (Alcon) to confirm the spherical and cylindrical IOL power and a pseudophakic reading to confirm the optimal toric IOL axis alignment,” he explains. “The latter is more accurate when the intraocular pressure is elevated with enough OVD to minimize speculum artifact, and with the accuracy of the Callisto system alignment, the confirmation is usually very quick if the preoperatively selected axis is correct.

“However, sometimes ORA directs me to rotate the toric axis either clockwise or counterclockwise until the intraoperatively measured astigmatism is minimized,” he notes. “I then use Callisto to re-mark the new optimal axis. After removing the OVD, Callisto then allows me to reset the toric IOL to the exact alignment that was confirmed by ORA to be optimal.

“Often,” he adds, “there is some disagreement between different preoperative diagnostic exams with respect to cylindrical power and axis. ORA serves as my tie-breaker in that case.”

Dr. Lane has also noted that using intraoperative aberrometry on the table when the patient is aphakic may produce a different axis reading than you’ll get preoperatively using a keratometer or even topography. “The question then becomes, what is the true axis?” he says. “To remove the lens, you’ve made some incisions in the cornea, and that could possibly alter the axis of astigmatism. Whether you should assume that the intraoperative aberrometry reading is more accurate depends, in part, on how much incision distortion you’ve created and how much you’ve hydrated the wound. If you’ve made large incisions and hydrated them a lot, you might get a better result by going with what the aberrometry tells you.

“In general,” he says, “I’ll go with the aberrometry reading if it disagrees with my preoperative K-readings. But again, there’s a little bit of an art to this; it’s not pure science.”

Of course, these advanced technologies, whatever their advantages, come at a significant cost. Dr. Chang, however, believes that the cost of the additional equipment is worth it, especially if multiple surgeons can use it. “Add up all the patients who will have their astigmatism managed at your ASC over the next 10 years,” he says. “It’s easy to justify the capital cost because of the surgical workflow

efficiency you gain and the refractive premiums that patients pay to get the best outcomes.”

Aligning the Lens

Once you’ve settled on a method to display the target meridian, the last step is to align the lens and get it to remain in the position you’ve placed it. Dr. Osher says a big part of that process is managing your OVD removal correctly. “Once I put the lens in, I’ll rotate it clockwise until it’s a little short of the target meridian,” he says. “Then I go behind the optic with the I/A tip and I remove my Healon5, which I like to use because it’s so cohesive; I can easily remove it from behind the lens without affecting the Healon in front of the lens. I always take out the OVD behind the lens before the final alignment, because if I take it out afterwards it can cause the lens to move.

“Next, I inject more OVD into the bag in front of the lens,” he says. “That expands the bag so the lens will rotate more easily; you don’t want the bag to be loose and have the chamber shallowing. Now the lens will be pressed against the posterior capsule, with no OVD left behind it.

“Next I turn on my Callisto Eye system,” he continues. “I rotate the lens to my Thermodots, the two little cautery marks, and the Callisto Eye system confirms that the alignment is dead-on. Because of the expanded bag, the lens rotates very easily with the silicone tip of the I/A hand piece placed in the optic-haptic junction. It’s easy and atraumatic.”

Dr. Osher says that before removing the last OVD, he makes sure the lens is centered and perfectly coaxial. (He notes that the stereo coaxial illumination provided by his Lumera microscope makes it easy to confirm the centration.) “I hydrate the incision before removing the final bit of OVD—something most surgeons don’t do—to ensure that the chamber

won't shallow, which would allow the lens to rotate," he says. "Then I take out the OVD that's in front of the optic. As I come out, I always have a second cannula in the stab incision through which I'm injecting fluid to keep the chamber deep. Between hydrating the incision ahead of time and having that second cannula, the chamber stays nice and deep, and the lens alignment

doesn't change. Once the OVD is out, I hydrate again and make sure the incision is watertight. Then I check my alignment one more time, adjust the pressure, and I'm done."

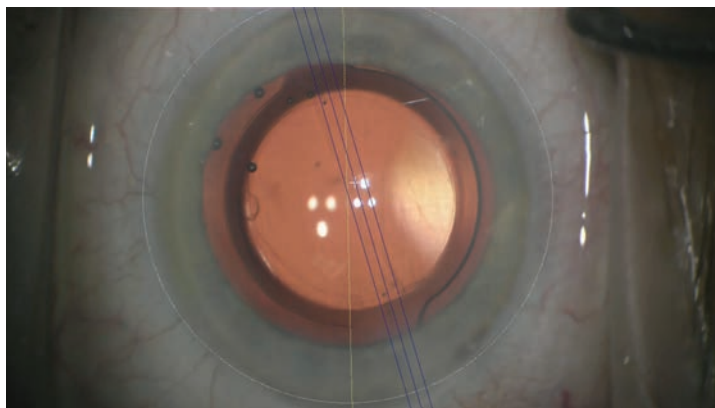
Dr. Osher notes that some surgeons like to put in a little Miochol near the end of the procedure. "Doing that makes the enlarged pupil smaller and lets you be sure the lens is centered," he says. "However, with a toric lens I wait until the very, very end because I don't want the pupil to come down and obscure my view of where the guiding dots are, so I maintain maximum pupil dilation until the surgery is over. At that point I may put in a little Miochol to confirm that I'm perfectly centered as the pupil comes down. This is particularly important with multifocal torics, which we now have in the United States."

Dr. Lane adds that surgeons shouldn't be put off by concerns about postoperative rotation. "Today's toric lenses are quite stable, with low rates of rotation and movement," he says.

Measurement Pearls

These strategies can help ensure that you get the best possible outcomes:

- **Watch out for simple, avoidable errors.** "A number of potential errors can lead to incorrect toric IOL



An example of a Callisto overlay during implantation of a toric IOL. The single yellow line marks the 180-degree axis; the three parallel blue lines show the 15-degree target meridian.

axis alignment," notes Dr. Chang. "The first—and least apparent to the surgeon—is the staff failing to carefully level the patient's head during the keratometry and topography measurements. The second potential problem is a transcription error made when going from the diagnostic machine to the operating room, such as writing 10 degrees as the operative axis instead of 110 degrees. The third potential error is mis-identifying the 180-degree axis when the patient is supine with ocular cyclotorsion; preventing this requires marking the patient while sitting upright in the preoperative area. The fourth potential source of error is during the marking of the intended toric IOL axis using a degree gauge and an ink pen, given the propensity for the ink mark to bleed, fade or smudge.

"Some of these errors are additive," he points out. "For example, the 180 axis may be a bit off while marking the upright patient, and then the ink pen mark may be 5 degrees wide. This can lead to a 10-degree misalignment on the operating table."

- **Make sure that experienced technicians are taking the measurements.** "Your results will only be as good as the talent of the individuals who take the measurements," says Dr. Osher. "Experienced technicians will make sure the head isn't tilted and the

cornea isn't bone-dry, among other things."

- **Disregard subjective measurements of the axis.** "The axis you get from a refraction isn't reliable," notes Dr. Osher. "Also, disregard any cylinder in the patient's glasses, unless the patient has high cylinder. For example, if the patient has 3 D of cylinder in her glasses, I would use that as an extra measurement. However, if the patient has

1 D, it means nothing; it could be the crystalline lens that's creating that cylinder."

High-tech Pearls

If you're able to access some of the more advanced technologies, these strategies are worth keeping in mind:

- **If possible, measure the posterior corneal surface.** Dr. Osher points out that a truly accurate determination of the toric meridian must take into account the astigmatism caused by the posterior cornea. "There are four technologies that can measure that," he says. "Douglas Koch, MD, who first pointed out the importance of this factor, did his pioneering work on Ziemer's Gallilei. A lot of us have used the Pentacam; the Cassini and OptoVue also measure the posterior cornea.

"Rather than measuring it, many surgeons who want to take this into account simply use an average of 0.3 D of posterior against-the-rule astigmatism," he continues. "This is the correct average, but after Dr. Koch alerted us to the importance of this factor, I spent several years measuring the posterior cornea on every patient. I found that the astigmatism caused by the posterior surface ranges from 0 to 0.8 D. That's a whole step on a toric lens."

David F. Chang, MD

Dr. Osher says taking posterior corneal astigmatism into account isn't difficult. "The posterior axis is always against-the-rule," he says. "So, if the patient has against-the-rule cylinder on the front of the cornea, with the steep axis at 180 degrees, you add the posterior corneal astigmatism. For example, if the patient has 1 D of cylinder at 180 degrees, and the posterior cornea has 0.5 D of cylinder, then you need to correct 1.5 D of cylinder overall. On the other hand, if the patient has with-the-rule cylinder, you subtract it. For example, if the patient has 1 D of with-the-rule cylinder at 90 degrees, and the posterior cornea measures 0.5 D, you would subtract the 0.5 D, meaning the patient actually has 0.5 D of astigmatism overall. This patient is not even a toric candidate. Finally, if the anterior astigmatism is oblique, it's a vector case, and I pay attention to the IOL recommended by the Barrett toric calculator.

"Some might say that this is a minor point—like worrying about your luggage when you're on the Titanic," he continues. "But the way I look at it, we should always do the very best we can for each of our patients. To accomplish that, we should always measure both the anterior and posterior cornea."

• **If possible, measure the entire optical system to see where the astigmatism is located.** Dr. Osher uses the iTrace for this purpose. "I always look at the two possible sources of the astigmatism—the cornea and the lens," he says. "There are three possible scenarios. Usually the astigmatism is in the cornea. Rarely—but it does happen—the astigmatism originates in the lens. The patient may have been wearing astigmatic correction and been referred in for a toric lens, but in this case you may be able to tell the patient she doesn't need a toric lens. Once the cataract is removed the astigmatism will be gone. Patients love that. I show them the iTrace readout, and they can see the corneal and len-

ticular astigmatism.

"The third scenario is the most interesting," he continues. "That's a person who has never worn glasses. This individual may have with-the-rule cylinder in the cornea that's been neutralized by against-the-rule cylinder in the lens. I tell them, 'After we take out your cataract you're going to have a lot of astigmatism, so you're a good candidate for a toric lens.' They say, 'Wait a minute, why are you trying to sell me a toric lens when I've never worn glasses?' I show them the iTrace measurements so they understand that once we take away the lens, they'll suddenly have a problem with residual astigmatism. This situation isn't common, but it definitely does happen."

Dr. Osher notes that this supports the value of taking multiple measurements. "Multiple measurements help you eliminate outliers, but they also provide additional information," he says. "Even though the amount of testing I do sounds excessive, the tests all help me gain greater understanding about my refractive cataract patient."

• **Even if you use advanced technology to align the lens, consider also marking the cornea.** "I think it's important to use a belt-and-suspenders approach," says Dr. Osher. "The more approaches you use, the better, because something can always go wrong. If lightning hits the surgery center or the technology breaks down, you still have something to go by."

Dr. Osher explains how he uses the Thermodot with iris fingerprinting. "I take a picture of the eye while the patient is at the slit lamp and I'm doing my dilated exam," he says. "Inexpensive software identifies the location of key landmarks on that iris. In the OR I can put my cursor on whatever landmark I want and the software tells me what degree it's at, so I always know exactly where I am. Then, if all of my sophisticated technology stops working—either because the machinery is temperamental, or something bleeds

and I lose registration, or fluid from I/A gets under the conjunctiva causing it to balloon up—I have a simple iris fingerprint that tells me exactly where to put my Thermodots, and the IOL will be accurately aligned."

Dr. Lane says he no longer makes an ink mark, now that he uses the more advanced alignment tools, although he agrees that there's nothing wrong with doing so as a failsafe. "To me, not having to do that is one of the advantages of using a guidance system," he says. "If the power went out, I could always sit the patient up, mark the eye and lay the patient back down, but that hasn't happened to me since I've had these instruments."

The Wave of the Future?

"There's no question that implanting toric lenses adds surgical time, and some pre-surgical discussion has to take place to ensure that patients have realistic expectations," Dr. Lane admits. "But current toric lenses are excellent, regardless of which manufacturer's lens you use. Meanwhile, the advanced alignment technology that's available will improve your results. I think the investment is worthwhile, especially in groups that have multiple surgeons doing cataract surgery, so that the surgeons can share in the expense of these instruments up front. The bottom line is that surgeons who are willing to do toric lenses will be very satisfied with the results, and they'll have a much larger group of happy patients."

Dr. Osher agrees. "I'm convinced that one day toric lenses will be the standard of care," he says. **REVIEW**

Dr. Osher is a consultant to Zeiss, Alcon, BVI and Clarity. Dr. Chang is a consultant for Clarity and Zeiss; he has no financial interest in Alcon or ORA. Dr. Lane is a consultant for Alcon.

1. Browne AW, Osher RH. Optimizing precision in toric lens selection by combining keratometry techniques. *J Refract Surg* 2014;30:1:67-72.

Tips for a Better SMILE

Jesper Hjortdal, MD, PhD, Aarhus, Denmark

An expert SMILE surgeon explains how to get the most from this new procedure.

In all areas of surgery, not just ophthalmology, the trend has been toward accomplishing the surgery's goals internally while minimizing the disruption to the exterior tissue—often the skin. In the eye, small-incision lenticule extraction—recently approved in the United States—continues this non-invasive tradition by making its major tissue modifications intrastromally, avoiding the creation of a large flap or extensive ablation with an excimer laser. I've had great success with SMILE in my refractive practice, and now use it for all of my myopes who are suitable candidates. In this article, I'll share the knowledge about SMILE that I've amassed over the years and help you get the best outcomes possible.

Preop Considerations

Screening criteria for SMILE are similar to those used for femto-flap-

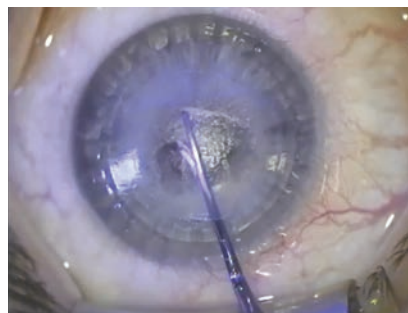
based LASIK, but there are also some limitations to the procedure that will reduce the number of potential candidates.

One of SMILE's current limitations is that the most reliable nomograms for it are primarily for myopic correction, and it's only approved in the United States for the correction of myopia up to -8 D with no more than 0.5 D of astigmatism. Also, there's a hardware limitation in that, in order to perform it, you need to use the Carl Zeiss Meditec Visumax femtosecond laser.

In terms of safety screening, we won't perform SMILE on someone with a cornea thinner than 480 μm , or whose refraction hasn't been stable for at least a year. Also, since we mainly perform SMILE on high myopes at our practice, we're reluctant to perform it on patients younger than 25, because of the potential risk of forme fruste keratoconus that might manifest in the postop years. When screening for potential ectasia risks, we look for oblique astigmatism and use the Pentacam to look for a difference in power between the inferior and superior corneas. Also, we inquire whether anyone in the patient's family has a history of keratoconus.

We take these precautions during screening because, even though SMILE is less invasive than LASIK

After the femtosecond pass, surgeons use an instrument to break the tissue connections above the lenticule. (All images: Jesper Hjortdal, MD, PhD, and Anders Ivarsen, PhD)



and should, theoretically, result in a more stable cornea biomechanically, it does loosen the fibers in the anterior part of the cornea. This means the post-SMILE cornea may still be weakened compared to non-dissected cornea. Also, even though we've never experienced it in our practice, there have been reports about ectasia occurring after SMILE.¹ However, it's worth noting that, when one reviews these reports, it appears that the patients in question had some signs of subclinical keratoconus before the SMILE procedure, such as corneal asymmetry.

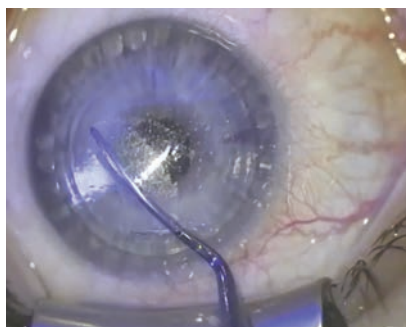
The Procedure

There are certain measures you can take to help the procedure go more smoothly, and to avoid potential difficulties.

To help understand the specific tips for the various steps of SMILE, it helps to have a general overview of the procedure. In SMILE, the surgeon uses the femtosecond laser to create a lenticule of stromal tissue within the cornea; the laser then makes a small side incision through which the tissue is removed with forceps. This removal causes corneal flattening that treats the myopia.

First, I've found it helps to give the patient a detailed explanation of what's going to occur at each phase of the procedure. We do this both in our office in the days before the procedure as well as during the actual SMILE surgery. During the procedure, I'm constantly telling the patient to keep calm, to look at the blinking green light and to not follow the light if it appears to move. I keep her looking straight during the docking step. After docking, when the patient is moved under the laser, I then explain what's going to happen in the next few seconds. This relaxes the patient and helps her to keep her gaze straight.

• **Docking and suction.** When the time comes to perform the procedure,



Surgeons say it's easier if you free the posterior side of the lenticule after the anterior side.

we instill two drops of anesthesia: one three minutes before the case and another one minute before we insert the speculum. During this period, it's important to evaluate the situation in a way similar to a LASIK protocol, to make sure you have good access to the eye and that the suction device on the laser won't collide with the speculum. Move the patient's head a few degrees to the side opposite the eye to be treated, then adjust the head so it's exactly coaxial with the laser beam.

We then perform a mild cleaning of the corneal surface to ensure there's no debris, such as mucus, in the tears. We instill a little BSS to ensure a nice wet surface, and then move the patient's laser bed from the surgical microscope to beneath the laser. When this occurs, you'll notice that the screens on the laser have changed, and you'll then have another view through the microscope that's down the laser path. You then elevate the patient bed toward the suction device and make sure to center the suction head along the visual axis, which you can accomplish by asking the patient to look at the blinking green light. The suction device then makes contact with the cornea. Make sure you've centered the procedure over the pupil and then elevate the patient bed a little more. Then, just before you have a full, curved applanation, activate the suction. Have a look at the pupil to make sure that everything is centered.

• **The femtosecond step.** At this point, it's important to tell the patient to relax. He'll be able to see with the operative eye because the suction isn't that high with SMILE. Again, tell him the procedure is about to begin, so he shouldn't move the eye or try to follow the light if it appears to move. Let him know that when the femtosecond is operating, his vision may become blurred due to small bubbles in the cornea and that it's perfectly normal. Keep him calm and apprised of how much time remains in the procedure, which usually takes 20 to 25 seconds, depending on the spot pattern. Then, when the lenticule cut is complete and the side incision has been made, the laser will stop and suction will automatically decrease. Reassure the patient that things went well and that the most difficult part is over. You then move the patient bed down beneath your surgical microscope.

It's worth noting that, in rare cases (0.7 percent in a study we performed),² you can lose suction during the procedure. To try to avoid this, the most important thing is to have the correct amount of hydration on the eye—not too much or too little. Also, you can help prevent it by, again, talking to the patient and keeping him calm. If suction loss does occur, however, your response depends on how much tissue you've cut and where you are in the procedure, per Carl Zeiss:

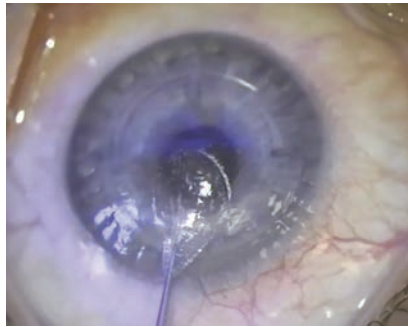
- Stage 1 (posterior lenticule cut is less than 10 percent complete): Restart the procedure;
- Stage 2 (posterior lenticule cut is greater than 10 percent done): Switch to LASIK;
- Stage 3 (lenticule side cut): Repeat the lenticule side cut, and decrease the lenticule diameter by 0.2 to 0.4 mm;
- Stage 4 (anterior lenticule cut): Repeat the anterior lenticule cut; or
- Stage 5 (anterior lenticule side cut): Repeat the anterior lenticule

side cut and decrease the lenticule diameter by 0.2 to 0.4 mm.

• **Completing the dissection.** It's now time to complete the dissection and remove the lenticule. Remind the patient to keep looking at the light, and tell him he may experience movement of the eye during the dissection.

First, use a Sinskey hook or other sharp instrument to identify the plane of the lenticule. Most surgeons do this by going to the left side of the incision and making sure that they have a plane above the lenticule before they start dissection. Then you take a dissector, either flat or curved—we prefer curved—and go to the extreme left to a place where you know you're above the lenticule and dissect with smooth movements from left to right over the anterior surface of the lenticule toward the periphery of your cap cut. This will break all the tissue connections above the lenticule. Having done that, you go below the lenticule, entering through the right side of your incision, and do the same type of dissection from right to left toward the edge of the lenticule, breaking all the connections below. Make sure you've dissected the full planes above and below the lenticule. You then remove the lenticule with forceps and place it on top of the cornea to make sure that it's complete.

Visualization can be challenging during the dissection, so here's some advice: If you go in on the left side with your Sinskey hook you'll be outside the actual lenticule. If you then move the Sinskey hook—pointed slightly upward toward the cap—across the actual border of the lenticule, you'll almost certainly be above the lenticule. A good way to gauge your position is to look for the small air bubbles in the interface: There should be no air bubbles above your Sinskey hook for your initial dissection above the lenticule. Also, it's not necessarily a catastrophe if you go below the lenticule. If you press a little with a Sinskey hook, you most often will be able to catch the edge of



With both sides free of tissue connections, remove the lenticule with forceps and make sure it's complete, with no missing pieces.

the lenticule while it's sitting on the cap. However, most surgeons find it easier to do the anterior cap layer first.

• **Two-incision technique.** You can also choose to have two incisions: one at 12 o'clock and one at 6 o'clock. Then, if you dissect from the 12 o'clock position but realize you've started with the wrong plane before you completely dissect the other plane, you'll have a second chance at success by using the incision down at 6 o'clock.

• **Low vs. high myopia.** The thicker the lenticule, the easier the dissection. So, in low myopia, you should typically add a little to the base thickness to make the lenticule easier to manipulate. In the typical SMILE case, there's a 15- μ m base thickness. So, in low myopes, you should increase that to 20 or 25 μ m, giving more bulk to the lenticule. It's like a plano ablation, so this extra tissue shouldn't have any refractive effect.

• **Notable differences from LASIK.** The dissection in SMILE is more difficult than just lifting a LASIK flap. Also, it's important to realize if you really can't get under the lenticule properly, the most likely reason is that the lenticule is still attached to the cap. So, if you find yourself having to be very aggressive and digging down under the lenticule, your first thought should be that the lenticule may actually be stuck to the cap. Therefore, instead of just continuing a rough dissection where there's no dissection plane,

go back and see whether the lenticule is actually stuck to the cap, and try to see if you can get into the plane between the lenticule and the cap at the very edge.

If it's really difficult or almost impossible to dissect, it's better to acknowledge that the lenticule wasn't properly cut and just stop—don't make a mess of the middle of the cornea. It's better to come back in a month or so when you've have time to see what happened, and consider doing another procedure such as PRK or LASIK.

• **Closing the case.** After you've removed the lenticule, flush the interface with BSS and, using either a sponge or the head used for docking, push on the cornea to squeeze out any remaining saline. Wait 30 seconds to a minute before removing the speculum to make sure that everything is in place. In some cases, you might notice that the operation caused a small epithelial defect or abrasion. If this is the case, place a bandage contact lens postop. You can typically remove the bandage lens on postop day one because the abrasion is usually healed.

We then instill Vigamox and a mild, pain-relieving NSAID drop. We prescribe a mixture of tobramycin and dexamethasone q.i.d. for a week, and then b.i.d. for another week.

Postop Matters

Though most of our SMILE cases go smoothly, it helps to be vigilant for postop problems in order to nip them in the bud. Here are the things you should be looking for.

• **Watch for inflammation.** Postop, we'll take a look to see if there is any debris or inflammation in the interface. Sometimes, you see small fibers like the kind seen after LASIK. If the debris is central, or you have a feeling that there's some epithelium in the interface, then flush the interface. (This happens rarely.) Then look for tears around your incision, which typically

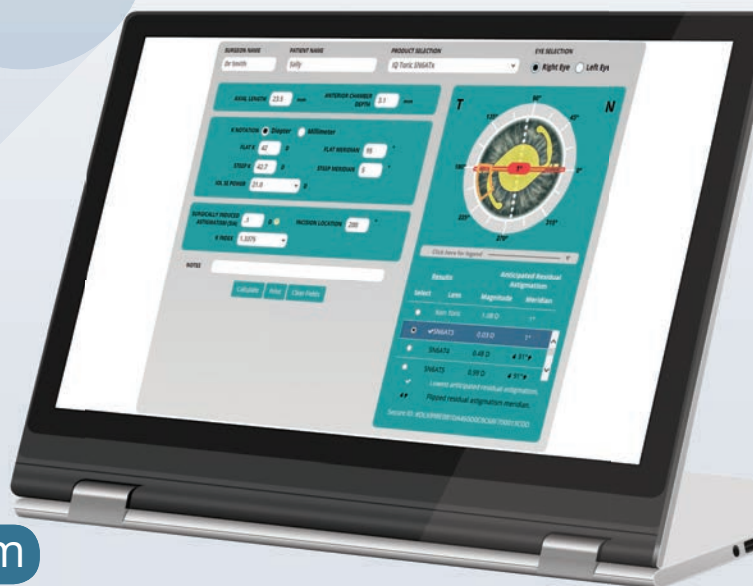NEW

ALCON ONLINE TORIC IOL CALCULATOR

Incorporating the Barrett Toric Algorithm

Explore the new features of the enhanced calculator now.

www.acrysoftoriccalculator.com



BARRETT TORIC CALCULATOR ALGORITHM

Designed to provide the **most accurate post-operative prediction** of residual astigmatism

- Theoretically accounts for posterior corneal astigmatism
- Factors patient's axial length and anterior chamber depth
- Designed to improve refractive predictability by using centroid vector value for SIA
- Provides information on anticipated post-op results for a range of Alcon Toric and non-Toric lenses
- Creates a more streamlined, intuitive user interface
- Recommends the IOL with the lowest predicted residual astigmatism

only require observation.

• **Visual results.** Visual recovery with SMILE is a little slower than LASIK. If, for example, the average LASIK patient sees 20/20 the day after surgery, a typical SMILE patient may see 20/25 or a little less. However, there are also SMILE patients who have excellent visual acuity on the first postop day. Since it's somewhat difficult to predict who will do well and who won't, we tell patients to be prepared that their vision may not be perfectly clear on day one, but they'll be fine after the first week.

In a study of 1,800 SMILE eyes at our practice, the average preoperative spherical equivalent refraction was -7.25 ± 1.84 D. Postop, the average was -0.28 ± 0.52 D, with a mean error of treatment of -0.15 ± 0.5 D. At the three month follow-up visit, 86 percent of the cases had the same or improved best-corrected distance vision.²

In another study of SMILE that included 722 cases with an average preop error of -6.8 D, at three months 88 percent of eyes were within 0.5 D of the target refraction. Sixty-three percent saw 20/25 or better at day one, which improved to 83 percent at three months postop. Though the average gain in best-corrected vision between preop and three months postop was 0.07 (logMAR), 12 eyes (1.6 percent) lost two or more lines of best-corrected vision during that period.³ In a smaller study of 45 eyes of 35 patients with an average preop error of -7 D, 86 percent of the cases saw 20/20 or better. Although 32 percent of patients gained a line of vision, 2 percent lost a line.⁴

In our study, 1.5 percent (24 eyes) lost two or more lines of BCVA. We noted, though, that of these, significantly more were treated with laser setting 1 (lower spot energy and closer spacing) than setting 2 (higher spot energy and wider spacing). Also, eight of these eyes were within our first 100 eyes treated, so there may have been a learning curve at work. It's important

Table 1. SMILE Complications

Intraoperative SMILE Complications (percent); (N=1,800)¹

- Abrasion at the incision (6)
- Lenticule extraction difficulties (1.8)
- Minor tear at the incision (1.8)
- Suction loss (0.7)
- Central abrasion (0.2)
- Cap perforation (0.2)
- Major tear (0.06)
- Lenticule extraction impossible (0.06)

Postoperative SMILE Complications (percent)

- Haze, grade 0.5 to 1 (7)
- Dry ocular surface, first day postop (4.2)
- Epithelial islands at incision site (0.6)
- Fibers in interface (0.3)
- Infiltrates/keratitis (0.27)
- Monocular ghost images (0.27)
- Inflammation in the interface (0.22)

to note, however, that by an average of 18 months postop, BCVA was within a line of preop levels in all eyes.²

The most common complications in our study were epithelial abrasions at the incision site in 6 percent of cases (n: 114), difficulty removing the lenticule in 1.8 percent (n: 34), small tears at the incision site in 1.8 percent and, in some cases, a combination of those complications. The corneal cap was perforated during surgery in four eyes and in one eye a major tear from the edge of the incision nearly divided the cap in two. However, neither of these issues resulted in late visual symptoms or a loss of BCVA. Postoperatively, the main complications in our series were corneal haze (grade 0.5 to 1) in 7 percent of cases (n: 127) and a dry ocular surface in 4 percent (n: 75).²

Overall, there were perioperative complications in 10.8 percent of the SMILE surgeries, which might appear to be relatively high when compared to LASIK. However, 59 percent of them were minor abrasions and 17 percent were small tears at the incision and weren't associated with any sequelae.

• **Enhancements.** Fortunately, en-

hancements are rare in our SMILE patients, because they're usually high myopes who are happy if their result is even -0.75 D. That said, SMILE enhancements can be a challenge due to the nature of the procedure and its use of a very fine lenticule to cause refractive change. Usually, the amount of postop error is very small, so the lenticule you'd need to remove for the enhancement would be very thin and challenging to work with. Because of this, most surgeons will use an excimer procedure for an enhancement.

In our practice, if we have to enhance a SMILE, we perform transepithelial PRK with mitomycin-C. Alternatively, you could change the SMILE cap into a flap and perform a LASIK enhancement, though this would depend on how thick you made the initial SMILE cap. The Visumax laser comes with a circle option that allows you to use it to cut down into the SMILE interface and create a flap. Then, you can use an excimer to do a LASIK. Though surface ablation enhancement works for us, the best procedure for enhancing a previous SMILE is still unclear.

With thousands of SMILE procedures under our belts now, we've learned a lot about the procedure and its idiosyncrasies. Though it does put some demands on the surgeon in terms of new instrumentation and the need to learn new techniques, we've found it an effective treatment for the myopes in our practice. **REVIEW**

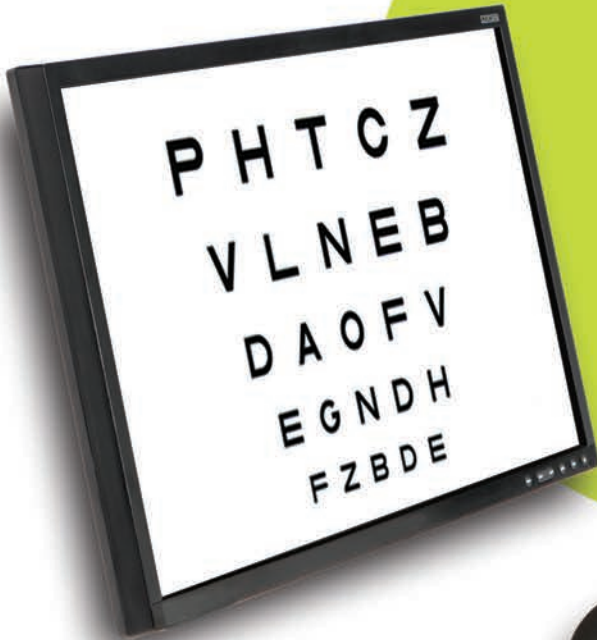Dr. Hjortdal is a clinical professor at Aarhus University, and is medical director of the Danish Cornea Bank. Aarhus University Hospital has specified research agreements with Carl Zeiss Meditec.

1. Mattila JS, Holopainen JM. Bilateral ectasia after femtosecond laser-assisted small incision lenticule extraction (SMILE). *J Refract Surg* 2016;1:32:7:497-500.
 2. Ivarsen A, Asp S, Hjortdal J. Safety and complications of more than 1500 SMILE procedures. *Ophthalmology* 2014;121:4:822-8.
 3. Hansen RS, Lyhne N, Grauslund J, Vestergaard AH. SMILE: Outcomes of 722 eyes treated for myopia and myopic astigmatism. *Graefes Arch Clin Exp Ophthalmol* 2016;254:2:399-405.
 4. Yildirim Y, Alagöz C, Demir A, et al. Long-term results of SMILE in High Myopia. *Turk J Ophthalmol* 2016;46:5:200-204.

CVS Essential

The Lombart Visual Acuity System

Simple
and Affordable.



The CVS Essential
includes:

- Monitor
- HDMI Device with Acuity Software Program
- Luminous RF Remote
- Wall Mounting Bracket with Swivel

Only

\$1,695



Acuity Systems don't have to be complicated. The CVS Essential proves they can be simple and affordable.

There are many visual acuity systems available in the market today. Many of these have features that often go unused and require extensive knowledge of their complicated remote controls to access them.

The *Lombart CVS Essential* unit was developed with the idea that an acuity system should be easy to operate, while still including the standard acuity charts commonly used in refraction. The *CVS Essential* provides quick access to charts and features, ease of installation and most of all ... is priced right!

The *CVS Essential* provides standard optotypes in a full range of Snellen Ratios. The remote control is easy to understand with quick access to all optotypes and smooth transitions when adjusting chart sizes. It offers a direct button for chart randomization as well as for Red/Green duochrome testing on all optotypes.

2.4G RF Remote



Luminous Keypad



1-800-566-2278

Call 1-800-Lombart

Or Your Local Lombart Representative

Corporate Office - 5358 Robin Hood Road, Norfolk, VA 23513-2430
757-853-8888 | FAX 757-855-1232 | 800-566-2278

www.lombartinstrument.com

lombart@lombartinstrument.com

Sales and Service Centers Coast to Coast

ATLANTA • BALTIMORE/WASHINGTON D.C. • BOSTON • BOYNTON BEACH/MIAMI • BRADENTON • CHARLOTTE • CHICAGO • CINCINNATI • DALLAS • DENVER • DETROIT • GREENSBORO • HOUSTON
JACKSON • KANSAS CITY • KNOXVILLE • LOS ANGELES • MILWAUKEE • MINNEAPOLIS • NEW JERSEY/NEW YORK/PENNSYLVANIA • NORFOLK • PORTLAND • SAN ANTONIO • SAN DIEGO • SAN FRANCISCO

Odd Couple: Multifocals And Post-refractive Eyes

Kristine Brennan, Senior Associate Editor

A history of refractive surgery doesn't always mean multifocals are out of reach.

For the right patients, multifocal IOLs can offer acute near and distance vision without sacrificing the middle range. Eyes with prior refractive surgery have traditionally been considered poor candidates. Thanks to improving lens, biometry and calculation technologies, however, cataract patients who once paid out of pocket for refractive surgery to achieve spectacle independence may now have another shot at achieving it. Here, surgeons outline their own do's and don'ts regarding the use of multifocal IOLs in post-refractive surgery patients.

Post-refractive surgery patients seeking multifocal IOLs may not find encouragement from many doctors. "I don't do that many multifocal IOLs, only 2 percent of my patients. In people who have had previous refractive surgery I generally discourage it, since I try to get them the best quality of distance vision—which usually was their previous goal—rather than the convenience of decreased reading-glasses dependency," says James A. Davison, MD, FACS, of the Wolfe Eye Clinic in Des Moines.

Tal Raviv, MD, FACS, associate clinical professor of ophthalmology at the New York Eye and Ear Infirmary of Mount Sinai Icahn School of Medicine at Mount Sinai, and the founder

and medical director of the Eye Center of New York, is more willing to use multifocal IOLs in post-refractive patients, but still acknowledges that they are imperfect candidates. "Post-refractive patients are some of the most challenging ones we have," he observes.

"I have done multifocals in post-refractive eyes, both post-LASIK and -PRK, and I'll do both hyperopic and myopic previous refractive surgery," says Daniel H. Chang, MD, of Empire Eye and Laser Center in Bakersfield, Calif. "The fact that they've had previous refractive surgery indicates that they obviously do value spectacle independence—or at least at one point they did."

Since LASIK and its precursors, RK and PRK, are now decades old, the march of time portends that former patients will return to the operating suite with high expectations when cataracts develop. "This is largely an anticipatory issue, because of the certainty of aging," observes Ming Wang, MD, PhD, of Wang Vision Institute in Nashville, and clinical associate professor of ophthalmology at the University of Tennessee. Dr. Wang estimates that cataract patients with a prior refractive history comprise well over 10 percent of his cases, and he predicts that their numbers will soon

increase nationwide. “The LASIK population peaked around 2002, when today’s cataract patients were around 40 years of age. Simple math tells us that a wave of baby-boomer patients is imminent,” he says. “They will make multifocal IOL implantation popular, along with accommodative and extended-range IOLS. There will be a new surge in such procedures.”

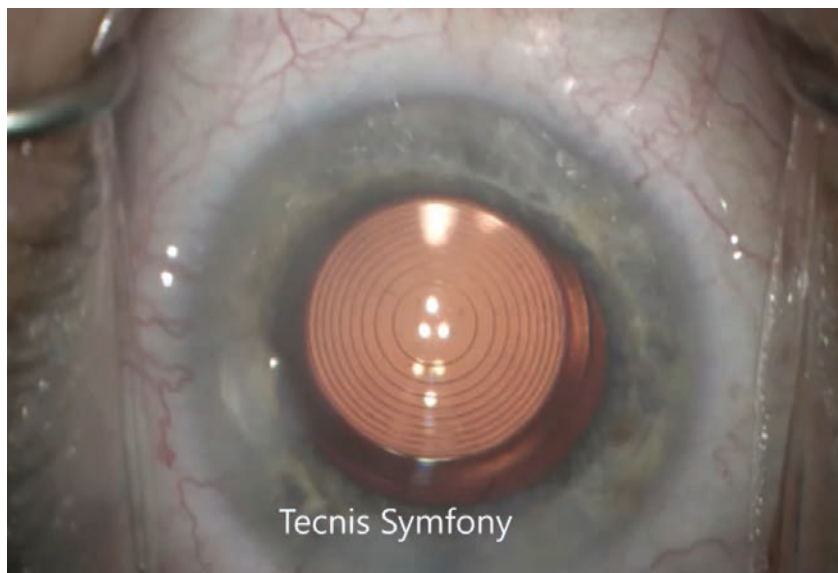
For now, though, post-refractive eyes and multifocal IOLs remain a relatively odd couple; succeeding with them requires taking extra precautions during patient screening, work-up and counseling.

Develop Exclusion Criteria

The limited literature on such eyes¹ looks at small study groups,² and suggests that while excellent outcomes are attainable, getting there often requires enhancements.³ Despite the shortage of literature on the use of multifocals in post-refractive eyes, Dr. Wang believes it’s only fair that patients seeking such procedures get checked against definitive exclusion criteria. To that end, he has developed a rough preliminary method that helps him eliminate unsuitable eyes by measuring their corneal aberrations against the amount of irregularity that a proposed multifocal lens will tolerate.⁴

“Multifocal IOLs are extremely picky regarding corneal irregularity, and introduction of a multifocal to such eyes creates higher demand on the cornea,” says Dr. Wang. “The high number of rings in their design corresponds with greater demand on the corneal surface.”

To help identify a potential fit between a given post-refractive cornea and multifocal IOL, he uses a numerical computation to determine the spatial tolerance (ST) of the IOL. He only considers a multifocal if the eye’s spatial precision falls within the lens’s tolerance parameters. Using a +3 D lens



The new Tecnis Symfony, the only extended depth-of-focus lens approved in the United States, is a viable option for patients with a history of refractive surgery who don’t want monofocal lenses.

as an example, Dr. Wang’s calculation of its ST value (the number of microns of corneal irregularity the lens will tolerate before its performance suffers) would go as follows:

Spatial Tolerance=(diffractive zone diameter-central diffractive zone diameter)/(2 X the number of rings and intervening transition zones).

The lens in the example has a 6-mm diameter optic containing a central diffractive button measuring 0.86 mm in diameter, surrounded a larger diffractive zone that’s 3.6 mm in diameter. Its distance zone goes from 3.6 mm to the outer edge of the optic. The lens has nine concentric rings with nine transition zones between them, creating 18 distinct steps. The ST value would represent the average step size for the lens:

$$ST=(3.6 \text{ mm}-0.86 \text{ mm}) / (2 \times 18)=.0761 \text{ mm, or } 76.1 \mu\text{m}.$$

If we compare this lens to a cornea with irregularity measured to be on the order of 250 μm (the SP, or spa-

tial precision value), the eye’s corneal aberrations clearly exceed the tolerance of the multifocal IOL. Unless treatment can decrease the patient’s corneal irregularity to less than 76 μm , the surgeon should use a monofocal or other lens with an ST greater than the cornea’s SP limit.

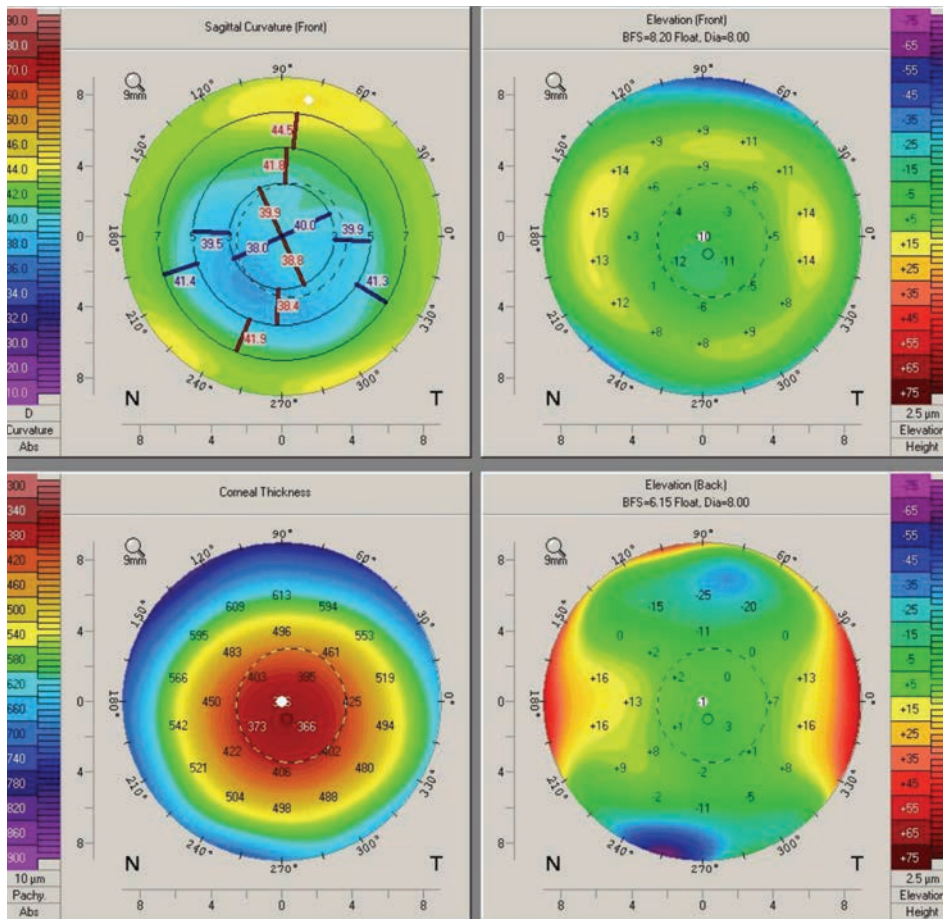
Dr. Wang stresses that his computations represent a rudimentary attempt to develop objective exclusion criteria when dealing with this highly variable patient group. “This post-refractive calculation is an early attempt to match cornea to lens tolerance. There is much work to be done on this approach. It’s still a crude model,” he emphasizes.

The fit between corneal aberration and a multifocal IOL is one factor in visual outcome, influenced by the type of refractive surgery and degree of dioptric correction patients have undergone. “In my experience with hundreds of eyes, generally cases of up to 4 D to 6 D of correction with prior myopic LASIK will be suitable for multifocals,” says Dr. Wang. He notes that he generally doesn’t put multifocals into eyes with a history of RK, early PRK or hyperopic LASIK,

although he makes occasional exceptions for hyperopic LASIK corrections no greater than 2 D to 3 D. “As a general concept, most of these cases won’t work with a lens so acutely sensitive to inaccuracy, but doing the calculation provides greater certainty in this assessment,” he states.

Similarly, Dr. Raviv uses multifocal IOLs in select post-refractive patients, the majority with a history of myopic LASIK. “The first thing that I differentiate is patients who have had myopic LASIK versus hyperopic LASIK and RK,” he says. “Radial keratotomy is much more challenging and much more difficult, due to the variation and fluctuation of the vision and the keratometry. I avoid multifocals in those patients at all costs.” Dr. Raviv also considers post-LASIK patients who’ve had a lot of dioptric correction poor candidates for multifocal IOLs. “I would avoid status post high myopia treatment, he says, “but people who’ve had under 5 D of treatment usually do pretty well.”

Dr. Chang, who notes that he is now trending towards Symphony extended-depth-of-focus lenses in post-refractive patients, also avoids multifocals in post-RK eyes, but doesn’t have hard limits regarding other types of previous surgery or degree of dioptric correction. “With post-refractive eyes, it’s a case-by-case basis. Not all LASIK is the same, for example, so you need to consider each case on an individual basis,” he says. Dr. Chang also says that patient response to the prior surgery is important when selecting suitable multifocal patients. “One of the things I always ask patients is, ‘How did you do after your initial LASIK or



Miling Wang, MD, PhD

Preoperative corneal topography is especially important in eyes with prior refractive surgery. This topography shows a decentered ablation zone, a contraindication for multifocal IOLs.

refractive surgery?’ If they respond, ‘The vision never really cleared up. I had night vision problems and never really liked it,’ that’s a big red flag, because if they had a decentered ablation or some other surgically induced problem, I’m not going to be able to fix that with a lens surgery,” he says. “If they say, ‘It was great! It stayed great for 10 years, but it’s gotten worse recently,’ then that makes me think that their problems are probably cataract-related. I can be a little bit more flexible with my IOL options.”

Rethink the Multifocal Category

“To be successful with multifocals after LASIK, we have to be con-

cerned with some of the higher-order aberrations which are inherent to and created by LASIK, as well as the dysphotopsias that multifocals can create,” says Dr. Raviv. “We didn’t want to combine those in the past, but our lenses have gotten better. Most of our patients who’ve had myopic LASIK have positive spherical aberration in the cornea. The multifocals we have now have negative spherical aberration, so we can treat that,” he continues. “Furthermore, we’ve recently gained the ability to use toric multifocal or toric EDOF lenses. A lot of post-LASIK patients have residual astigmatism, so the newer toric EDOF lenses have allowed us to treat their residual refractive error.”

Dr. Raviv has grown more will-



WORKING TOGETHER to relieve dry eyes

Clinically proven to reduce the signs and symptoms of dry eyes¹

TheraTears® Dry Eye Therapy products resulted in a **47% improvement in symptoms** and a **20% improvement in tear breakup time.**¹



RESTORES

+



CLEANSES

+



NOURISHES

More than just eye drops, dry eye therapy™

theratears.com



EVERY MONDAY
E-NEWS YOU CAN USE





Have you been receiving and reading custom e-blasts from *Review of Ophthalmology*?

If not, you're missing out on valuable information!

You're a busy practitioner and not surprisingly, your e-mail inbox is often full. Fortunately, when you scan through the sender list, determining which messages to delete and which to save or read, you can feel confident knowing that e-blasts from *Review of Ophthalmology*, a Jobson Medical Information LLC publication, contain the most current and comprehensive information available in the field to keep you on the cutting edge.

Review of Ophthalmology's online stable of products includes editorial newsletters and promotional information about new products, treatments and surgical techniques, as well as alerts on continuing education courses for ophthalmologists.

 Our FREE weekly e-newsletter, *Review of Ophthalmology Online*, brings you the latest in ophthalmic research, as well as industry news. In an effort to keep eyecare professionals informed, this resource is waiting in your inbox **every Monday morning**.

 *Retina Online*, our free monthly e-newsletter, is for retina specialists and general ophthalmologists interested in enhancing their knowledge on the topics of retina and related disease diagnosis and treatment, as well as the latest in surgical procedures.

Your time is valuable — and so is your practice. These e-products are the most effective way for you to receive updates on breaking news and research — all just a click away.

DON'T MISS OUT!

Unfamiliar with our products? Visit www.reviewofophthalmology.com and check out our newsletter archives.

Go to www.jobson.com/globalEmail/default.aspx to sign up for the e-newsletters that interest you.

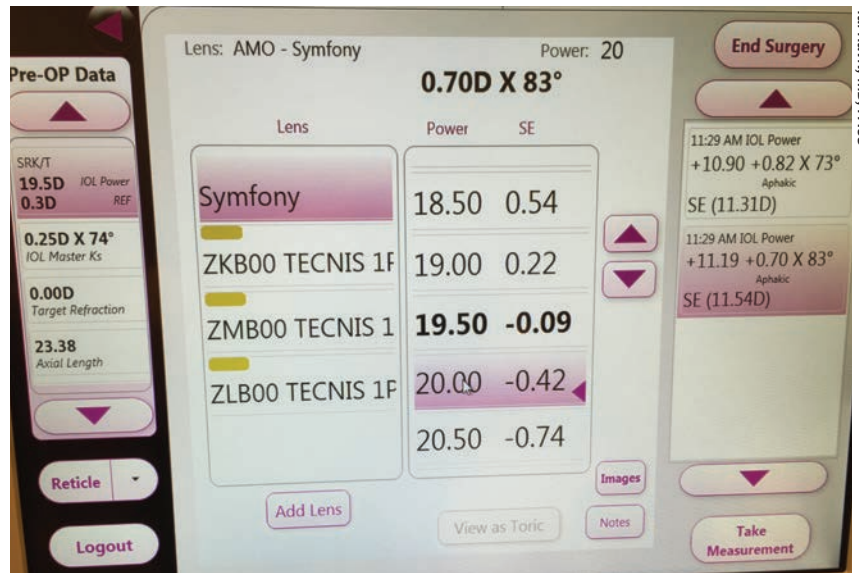
ing to implant presbyopia-correcting IOLs into post-refractive eyes with the emergence of low-add multifocals and EDOF lenses. “In 2015, we saw the advent of the low-add multifocal. I put those into post-LASIK patients and they did great, with very few nighttime symptoms and very good distance and near vision,” he says. “Now with the [Symfony] EDOF lens, we have a forgiving lens that is tolerant of some residual refractive error, something more likely to occur in a post-refractive eye. These lenses are really more suitable for post-LASIK patients.” Dr. Raviv adds that he regards EDOF IOLs as a subcategory of multifocal IOLs. “In any discussion about multifocals after LASIK, you’ve also got to include EDOFs, because those are the most user-friendly type of multifocal. It’s a subset of multifocal, and they are the lenses that I’m now primarily using,” he says.

Dr. Chang also finds the Symfony’s refractive forgiveness especially helpful in his post-refractive patients. “The jury’s still out,” he says, “but in my hands I’ve seen excellent results.”

Dr. Chang says that when considering an IOL in the post-refractive eye, the avoidance of “splitting light” is not the key factor. “The most important thing to consider is the quality of the image you’re putting on the retina,” he says. “When you look at some modeling and benchtop trials, the lenses that correct spherical aberration and chromatic aberration actually produce better image quality.”

Counsel Carefully

Dr. Chang intensifies his preoperative counseling a little when post-refractive surgery patients want presbyopia-correcting IOLs—in part because their prior results are generally so good. “With any patient, counseling is critical, but especially for post-refractive patients; their expectations may be high from LASIK, which has



Intraoperative aberrometry can aid in multifocal IOL selection in eyes that have undergone refractive surgery, which are notorious for unpredictable IOL implantation outcomes.

done well for a lot of people. You have to make sure they know what to expect,” he says. He advises patients that in addition to refractive misses, they may be at higher risk for quality-of-vision issues. “Sometimes, prior hyperopic LASIK may work against them, for example, because most of our multifocal lenses are negatively aspheric,” he says.

Although post-LASIK patients can enjoy excellent results with multifocal IOLs, Dr. Raviv is also careful to give patients a preoperative dose of realism. “We don’t promise them complete, 100-percent glasses independence,” he says. “We shouldn’t do that with any multifocal patient. I don’t mind the super type-A-triple-plus patients, because we read them the riot act, and they know what they’re getting into,” he continues. “We tell them, ‘This is the best technology we can give you: This is your eye. We’re going to match the two and do what we can. If you hate it, we’ll take it out and put in another lens, but you’re limited to this or that. That’s all we have. I’m offering you the best we’ve invented.’”

For patients who insist on sharp

near vision for reading or other close work, Dr. Raviv will use low-add multifocals. “I’ll use the Tecnis ZKB00,” he says. “It’s one of the lowest adds of the multifocals, so there’s a very low incidence of optic phenomena with that lens.”

Measuring and Operating

Dr. Chang’s preop workup of these patients differs from that for typical cases mainly in the amount of attention to corneal topography. “I’ll always review the topography a lot more closely in my previous refractive surgery patients. I’m using the Atlas topographer right now, which allows me to assess what the refractive surgery did, to make sure that the treatment zone size is good, that the centration is good and that there’s no irregular astigmatism,” he says. His preop presbyopic workup also includes a standard eye exam, biometry with the IOLMaster 700 and macular OCT with the Cirrus SD-OCT.

Dr. Raviv also doubles down on topography. “For those patients, I’m getting two sets of topographies,” he says.

“One is a standard placido disk topographer and the other is a topographer that helps me measure the posterior corneal astigmatism, and therefore the total corneal astigmatism, more accurately.”

He reports good results using modern formulas. “I like the Barrett True-K,” Dr Raviv says. “That formula seems to be very accurate. But I will also run the Shammas and the Haigis-L. Those are all found on the ASCRS post-refractive calculator. I used to use historical data. Ten years ago, we hunted down documents, trying find people’s previous Ks.” He no longer spends time on records requests to facilities around the world, however: “It turns out that the no-history methods have gotten so good that we’re using them exclusively at this point,” he says.

The second pillar of Dr. Raviv’s lens-selection strategy is interoperative aberrometry. “You just have to check off a box on the ORA indicating post-myopic LASIK, or post-hyperopic LASIK, so it feels a little bit like cheating,” he says. “I find that by combining the formulas I use with the ORA, I get very close. I use it with all my post-refractive cases and all of my multifocal patients; so certainly, with multifocal post-refractive cases I’m using ORA.”

While he doesn’t use intraoperative aberrometry, Dr. Chang is another fan of the ASCRS calculator for post-refractive eyes for preop measurements. “Warren Hill, Doug Koch and Li Wang have done a fantastic, amazing job putting that out there as a resource,” he says. “Typically for presbyopic IOLs, I will look at multiple scans and compare their consistency. That’s obviously trickier if I’m manually entering data into the ASCRS Web site, but I do use the multiple scans to make sure there’s a fair amount of consistency among them.”

In surgery, Dr. Raviv is careful to avoid LASIK flaps when implanting any IOL. “When I’m operating, I’m always very cognizant of where the

edge of the flap is. You want to make your incisions away from the flap and just stay out of its way. It’s usually not a problem, and the surgery is otherwise quite the same as it is for traditional patients,” he says.

Have a Plan B

In a patient group where both expectations and the potential for suboptimal outcomes run high, you must also be prepared to act when multifocal IOLs prove unsatisfactory. “You need to have the skills, the wherewithal and the ability to correct any unhappy patients, whether it’s because of dysphotopsia or because of residual refractive error,” stresses Dr. Raviv. “If it’s residual refractive error, you have to be ready to do one of three things: PRK touch-up or LASIK enhancement; IOL exchange; or toric rotation.” Although suboptimal outcomes are atypical if patients are carefully selected and worked up, Dr. Raviv acknowledges, “It’s much more likely for them to happen in post-refractive multifocal patients than in traditional cataract cases.”

When unhappy multifocal IOL patients present themselves, Dr. Raviv teases out the cause. “One of the simplest things to do is make sure it’s not residual refractive error. The post-LASIK eye may be more sensitive to even 0.5 D or 0.75 D of this. In the unhappy multifocal patient, is it posterior capsule opacification, or is it the lens itself? If it’s PCO, we want to address that early,” he says. “If they are immediately unhappy early on, I want to address their residual refractive astigmatism. The easiest way to do that is to put on a trial contact lens that corrects them to plano, even if it’s just -0.5 D. Some people will come back after a day or two and say it’s perfect, and then I’ll just do a touch-up on their cornea.”

“If there’s a postoperative refractive error, my patients have been prepped beforehand to understand that there’s a higher-than-normal chance for that,”

notes Dr. Chang. His next step “depends upon how unhappy the patient is,” he says, adding that he offers enhancements after waiting three to six months for the refraction to stabilize. Dr. Raviv also watches and waits for the refraction to stabilize in these cases. “For patients who are still unhappy, I’m going to wait three months,” he says. “If it’s not better, then I’ve got to do something, whether it’s explanation or something else. I’m happy to wait, unless the patient is miserable. A lot of these lenses do get better in three months.”

For a carefully selected group of patients who have had refractive surgery in the past, some surgeons say that multifocal IOLs can provide customized visual results that monofocals can’t. Although it takes careful screening, a scrupulous preoperative workup and perhaps extra time in follow-up, such care can reap rewards in terms of patient satisfaction. “Post refractive surgery patients have already invested financially in their vision, and they want to continue the good-quality uncorrected vision they have already achieved when they undergo cataract surgery,” says Dr. Raviv. “We’ve come a long way, and we now have many ways of making these patients happy.” **REVIEW**

Dr. Davison is a consultant for Alcon. Dr. Raviv is a consultant for Abbott, Ocular Therapeutics and Glaukos, and is a paid speaker for Bausch + Lomb and Shire. Dr. Chang is a consultant for Carl Zeiss Meditec AG and Abbott. Dr. Wang reports no financial interest in any products or procedures discussed in this article.

1.Khor WB, Afshari NA. The role of presbyopia-correcting intraocular lenses after laser in situ keratomileusis. *Curr Opin Ophthalmol* 2013;24:1:35-40.

2.Alfonso JF, Madrid-Costa D, Poo-Lopez A, Montes-Mico R. Visual quality after diffractive intraocular lens implantation in eyes with previous myopic laser in situ keratomileusis. *J Cataract Refract Surg* 2008;34:11:1848-1854.

3.Muftuoglu O, Dao L, Mootha VV et al. Apodized diffractive intraocular lens implantation after laser in situ keratomileusis with or without subsequent excimer laser enhancement. *J Cataract Refract Surg* 2010;36:11:1815-21.

4.Wang M. Multifocal IOLs for post-LASIK patients: Establishing clinical guidelines for patient selection. *Refractive Eyecare* 2012;16:6:1-4.

(Continued from page 8)

(Lexington, Mass.), announced that its proposed glaucoma treatment, trabodenoson, failed its FDA phase III trial. Specifically, the drug didn't achieve its primary endpoint of significantly reducing intraocular pressure compared to the placebo at every time point. Trabodenoson is designed to lower a patient's IOP by altering the natural function of the trabecular meshwork.

The MATrX-1 Phase III trial was a randomized, double-masked, placebo-controlled trial, looking at 303 subjects diagnosed with primary open-angle glaucoma or ocular hypertension and an IOP greater than or equal to 24 mmHg and less than or equal to 34 mmHg. The trial lasted for three months. The subjects' IOP was measured at four time points during the day: 8 a.m.; 10 a.m.; 12 p.m.; and 4 p.m. on days 14, 28, 42 and 84. The

researchers administered three doses of trabodenoson: 3%/1,000 mcg once daily; 4.5%/1,500 mcg twice daily; and 6%/200 mcg once daily.

There were no significant safety or tolerability events reported in the study. The safety of trabodenoson was comparable to the placebo. Just four subjects (2.2 percent) discontinued the trial because of treatment-related adverse events.

The 6%/2,000 mcg dose of trabodenoson was superior to the placebo at days 84, 42, 14 and marginally superior at 28. Daily IOP reduction at three months for this dosage was 4.25 mmHg compared to the placebo's 2.38 mmHg. This normal response confirms that the trial was properly conducted, Inotek says. However, the trial didn't achieve its goal of significantly reducing IOP compared to the placebo at all time points. Researchers attribute this to a placebo response

that was 2 to 3 mmHg greater than previously observed in their Phase II trial of the drug.

David Southwell, president and chief executive officer of Inotek, addressed the results in a conference call after the news broke. "Phase III results always contain unexpected elements, which teach us about the compounds we are developing," he said. "We clearly need to better understand these results and, particularly, what drove the placebo response."

However, Mr. Southwell remained optimistic. "Trabodenoson has identified itself as a drug with very clean safety profiles, with low side effects, both in the eye—such as hyperemia—and in the systemic compartment," he said. "This trial, by some measure, showed an even better safety and tolerability profile than previously observed, particularly with hyperemia." **REVIEW**

22ND ANNUAL **OPHTHALMIC** *Product Guide*



Innovative products to enhance your practice

The **future** is in your hands.
One tap, many possibilities.

Experience the digital edition on your handheld device. Use your smart device to scan the code below or visit:

www.reviewofophthalmology.com/supplements/

Download a QR scanner app. Launch app and hold your mobile device over the code to view <http://www.reviewofophthalmology.com/supplements/>.



REVIEW[®]
of Ophthalmology



FEBRUARY 18-19, 2017

Ophthalmology Update 2017

LOCATION

Hilton La Jolla Torrey Pines
10950 North Torrey Pines Rd.
La Jolla, CA 92037
P: 858-558-1500

PROGRAM CHAIRS

Don O. Kikkawa, MD, FACS
Robert N. Weinreb, MD

DISTINGUISHED INVITED SPEAKERS

Alex Huang, MD, PhD
Lee Jampol, MD
Rob Knight, PhD
David Serraf, MD
Jeremiah Tao, MD
Mandi Conway, MD

UCSD SPEAKERS

Natalie Afshari, MD, FACS
Daniel Chao, MD, PhD
William Freeman, MD
Michael Goldbaum, MD
Weldon Haw, MD
Chris Heichel, MD
Bobby Korn, MD, PhD, FACS
Felipe Medeiros, MD
Eric Nudleman, MD, PhD
Shira Robbins, MD
Peter Savino, MD
Karl Wahlin, MD
Derek Welsbie, MD, PhD

REGISTRATION FEE: \$95

FOR MORE INFORMATION

www.ReviewofOphthalmology.com/Update2017

Email: Reviewmeetings@jobson.com

Phone: 855-306-2474

Accreditation Statement

This activity has been planned and implemented in accordance with the accreditation requirements and policies of the Accreditation Council for Continuing Medical Education (ACCME) through the joint providership of Amedco and Postgraduate Health Education, LLC (PHE). Amedco is accredited by the ACCME to provide continuing medical education for physicians.

Credit Designation Statement

This meeting is approved for *AMA PRA Category 1 Credits™*

Shiley Eye Institute
UC San Diego

Jointly provided by



PHE

Review of Ophthalmology®

An interdisciplinary faculty of ophthalmic subspecialists will review the continuing progress in Cataract and Refractive Surgery, Glaucoma, Retina, Neuro-Ophthalmology, Pediatric Ophthalmology, Ocular Surface Disease, Cornea and Oculoplastics.

Discounted room rates available at \$209/night. Limited number of rooms available. See registration site for more information.



Photos: ©2015 Hilton Hotels & Resorts

EDUCATIONAL OBJECTIVES

After participating in this educational activity, attendees should be able to:

- Analyze new research that illustrates the key role that inflammation plays in the genesis of DME and macular edema secondary to RVO
- Engage in discussions related to emerging issues in glaucoma, including risk assessment, imaging, management and progression assessment
- Manage glaucoma using newer treatments available: surgical and pharmaceutical
- Discuss the newest glaucoma surgical devices, including those used in patients undergoing cataract surgery
- Describe outflow biology and its relevance to MIGS while citing relevant MIGS studies and trials
- Utilize advanced technologies and techniques in refractive cataract surgery, including advanced technology IOLs
- Outline current management and treatment of dry eye and keratitis.
- Discuss the rationale for anti-VEGF therapy and steroids in posterior segment diseases including age-related macular degeneration and diabetic macular edema
- Managing IOP in retina disease state treatments
- Navigate issues relating to patient compliance/adherence with eye drop medications
- Describe how various imaging technologies, such as OCT and angiography, can assist in diagnosing and monitoring ocular conditions
- Discuss options for cosmetic skin procedures

PROGRAM TIMES

Saturday, February 18th
8:00am — 5:00pm
Reception to follow
Sunday, February 19th
8:00am — 12:15pm



Managing Glaucoma with OCT: Secrets to Success

Knowing the advantages and potential pitfalls of this technology can help you make it an effective disease-monitoring tool.

Brian Francis, MD, MS, and Vikas Chopra, MD, Los Angeles

Today, optical coherence tomography has become a standard tool for diagnosing and monitoring glaucoma. As with many advanced technologies, there are several ways we can use OCT and a number of potential pitfalls to avoid. Here, we'd like to discuss some of those issues, including the limitations of this technology; the pros and cons of event-based and trend-based progression analysis; common mistakes to avoid; and ways to improve the accuracy of your interpretation of OCT data.

OCT Today

For now, OCT is most useful when a patient is either a glaucoma suspect or has early-to-moderate disease, as a tool for helping to detect damage and progression (or conversion from glaucoma suspect or ocular hypertensive to glaucoma). While there are many parallels between OCT technology and visual fields—for example, being able to use them for either event-based analysis or trend-based progression analysis—OCT is arguably a better tool for use in early disease, because when we test visual function

with a visual field test, the plasticity and overlap inherent in the visual system tend to compensate for any early damage. As a result, early damage may be picked up by an OCT scan rather than by a visual field test.

On the other hand, late in the disease OCT is less useful because of the “floor effect,” which refers to the fact that when the nerve fiber layer thickness reaches about 45 to 50 μm , it bottoms out and doesn't decrease any further—even though damage caused by the disease may continue to worsen. Once you reach that level, there's really no point in using OCT to detect progression; if you do, it may give you a false sense of security that there's no change happening when the patient may actually be getting worse. At that point we usually rely on visual fields and other functional testing to determine whether progression is occurring.

This limitation of OCT measurements could change in the future, because there's some evidence that other OCT parameters such as the thickness of the macular ganglion cell complex may still reveal change in more advanced disease. (Some

studies are currently exploring that possibility.) In addition, a newer technology called OCT angiography, or OCTA, which uses OCT to map the blood vessels in the retina, might also turn out to be helpful in advanced disease.

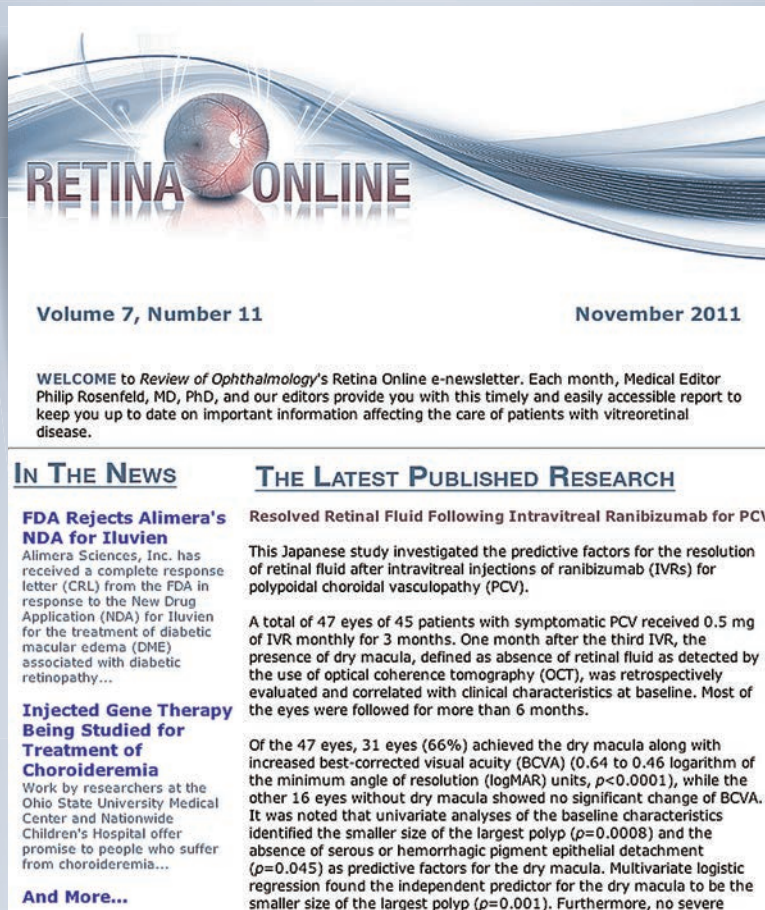OCT gives us a wealth of data to work with, because it can provide structural information about many parts of the retina and optic nerve head—and now the lamina cribrosa—while OCTA can look at the retinal and peripapillary blood vessels. In fact, one of our jobs over the next five years is to figure out which information provided by OCT is important at which stage of the disease. We may end up focusing on one group of OCT parameters in early disease and a different group in more advanced disease.

Factors Affecting OCT Accuracy

A number of things can undermine the accuracy of an OCT scan. To avoid basing a medical decision on poor data, be mindful of these five factors:

- **Signal quality.** The quality of the data in an OCT scan depends, among

RETINA ONLINE E-NEWSLETTER



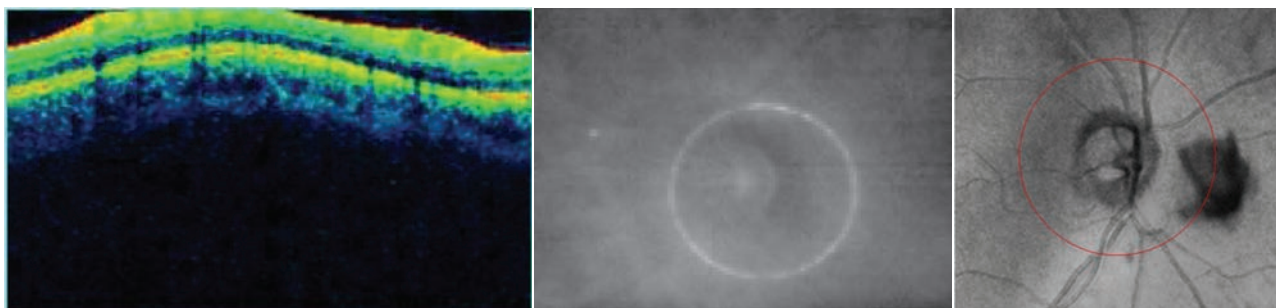
Once a month, Medical Editor Philip Rosenfeld, MD, PhD, and our editors provide you with timely information and easily accessible reports that keep you up to date on important information affecting the care of patients with vitreoretinal disease.

3 EASY WAYS TO SUBSCRIBE!

<http://www.jobson.com/globalemail/>

Fax: 610.492.1039 or Call: 610.492.1029

REVIEW[®]
of Ophthalmology



Potential problems that can undercut the accuracy of your scan. Left: The depth of the scan must be correct. Here, the display is cut off at the top because of inaccurate scan depth. The instrument may interpret the missing data as 0- μ m thickness at that location. Center: If the optic nerve is not centered in the scan circle, thickness measurements will be thrown off, giving the impression of a focal defect that doesn't exist. Right: Opacities such as this floater will disrupt the data because the instrument can't measure through them.

other things, on signal strength. Fortunately, OCT systems measure the signal-to-noise ratio of the data being received and give us a number gauging the scan quality after each measurement.

Signal strength can be decreased for a variety of reasons; the most common reasons are cataract, media opacities, corneal edema, vitreous floaters and dry eye. The latter is easy to treat, so if you get poor signal strength and the media appear clear, give the patient artificial tears right before the next scan. That often improves signal strength significantly. Lower signal strengths will often yield lower retinal nerve fiber layer thickness values that will improve with re-scanning to yield higher (and probably more accurate) values.¹

Movement and blinking artifacts can also be a problem because they interrupt the scans. This is becoming less of a problem as OCT instruments scan faster, but it's still a potential issue. You may observe these movements if you're watching the patient, but if not, you may note a break or a horizontal line in the grayscale image of the optic nerve and retina. It may look like the top half and bottom half don't line up. That means the patient moved or blinked.

Using the Zeiss Cirrus spectral-domain OCT, we consider a scan-quality reading of 7 out of 10 (or better) to mean that the scan contains

reliable, useful information. (Other manufacturers also have minimum signal strength guidelines that are considered necessary to perform analysis.) Checking the scan-quality number before you rely too much on the data is important, because the OCT will give you an analysis even if the scan had poor signal strength.

If you do find that the scan was of poor quality, then you need to figure out the reason. In that situation, every box on the OCT readout tells you something—even the parts that people don't pay much attention to, like the TSNIT graph overlay between the two eyes, and the segmentation section at the bottom.

- **Scan alignment.** Not only does the eye have to be aligned on the visual axis, but the depth of the scan has to be correct. You can see whether or not it's correct in the colored graph where the retinal data is presented as a sinusoidal pattern. The graph should be aligned centrally in the box. If it's too high or too low—too high is most common—then the scan was cut off, and you'll be missing data for that section, which the instrument will interpret as 0- μ m thickness in that area. (See the sample scan shown above, left.) That's certainly going to disrupt your data and make values less than they should be. This type of scan alignment error is quite common in eyes with high axial myopia.

- **Scan centration.** When the scan

circle isn't centered around the optic nerve (see example, above, center), the part of the circle that's too close to the nerve will measure thicker than it actually is, and the part that's farther away from the center will measure thinner. As a result, you may think there's a focal defect in the thin area. This problem usually occurs when the patient has difficulty maintaining fixation. The instrument may be centered properly at first, but then the patient moves a little or the eye shifts. A good technician will pick this up and instruct the patient to refixate.

This is an error that you won't pick up by looking at the scan quality and signal strength. The signal strength may be excellent, but if the scan is not centered properly, you're going to get misleading measurements. Fortunately, this error is becoming less common with the newer-generation OCT devices that have an auto-tracking feature to maintain scan centration.

- **Opacities.** These are usually floaters. (See example, above, right.) Floaters will disrupt the scan, because OCT technology can't measure through them. This is a problem that's often easy to fix, however; you can have the patient look away and look back. That will usually move the floater out of the field of view, or at least outside of the scan circle.

- **Segmentation errors.** The software will try to segment out the reti-



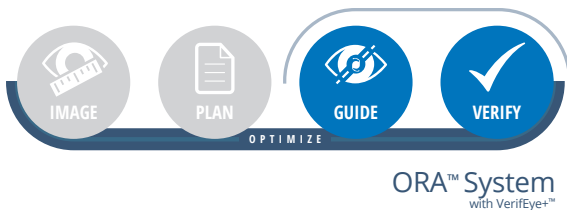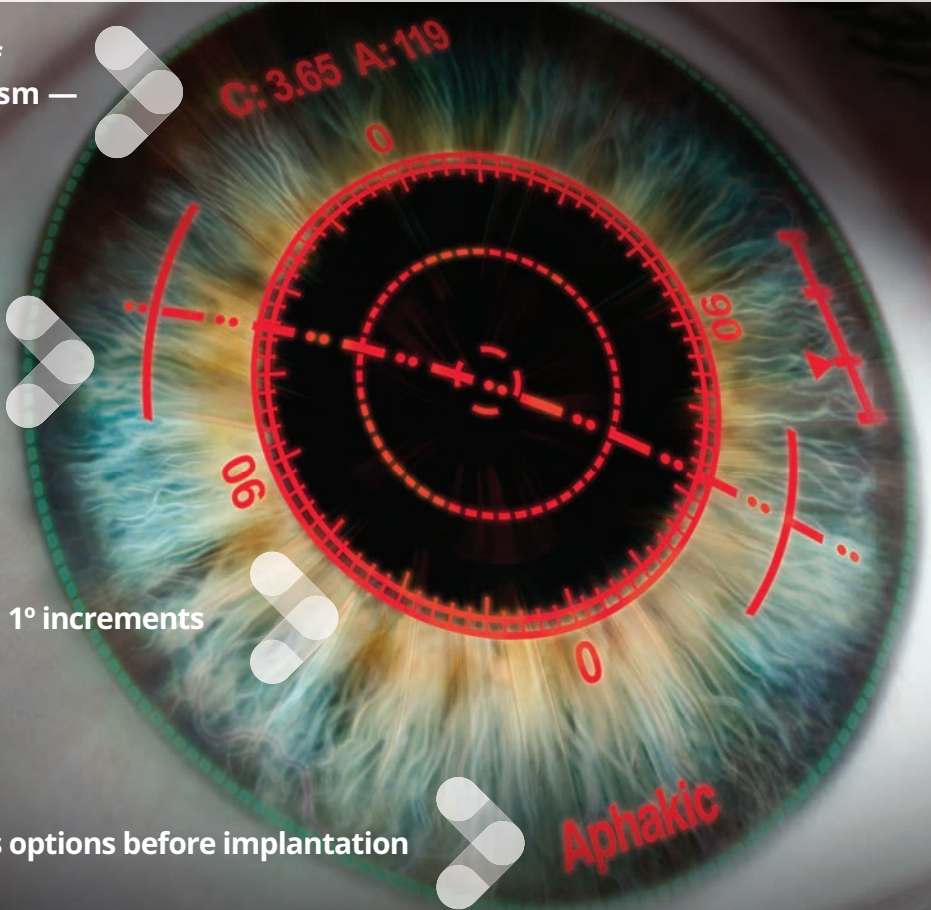
The next advancement from the leader in intraoperative aberrometry

Continuous readings of total corneal astigmatism — cylinder and axis

Live-streaming toric alignment and LRI guidance

Precise measurement in 1° increments

Assess refractive impact of lens options before implantation



Get real-time data verification with the ORA™ System with VeriEye+™.

Cataract procedures using the ORA™ System with VeriEye™ Technology have been proven to help deliver better outcomes for your astigmatic and post-LASIK patients.^{1,2}

- Provides IOL sphere, cylinder and alignment suggestions
- Dynamic variable optimization and robust reporting powered by AnalyzOR™ Technology

Contact your local Alcon rep or visit www.GuideandVerify.com for more information.

See adjacent page for important product information.



a Novartis company



Advancing CATARACT SURGERY

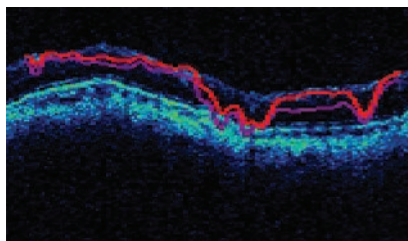
1. Alcon data on file. VeriEye+™ Technology incorporates the VeriEye® Technology validation software, but VeriEye+™ Technology was not available at the time of the study.
2. Ianchulev T, Hoffer K, Yoo S, et al. Intraoperative refractive biometry for predicting intraocular lens power calculation after prior myopic refractive surgery. *Ophthalmology*. 2014;121(1):57-60.

REVIEW | Glaucoma Management

ORA™ SYSTEM IMPORTANT PRODUCT INFORMATION

CAUTION: Federal (USA) law restricts this device to sale by, or on the order of, a physician. **INTENDED USE:** The ORA™ System uses wavefront aberrometry data in the measurement and analysis of the refractive power of the eye (i.e. sphere, cylinder, and axis measurements) to support cataract surgical procedures.

CONTRAINDICATIONS: The ORA™ System is contraindicated for patients: who have progressive retinal pathology such as diabetic retinopathy, macular degeneration, or any other pathology that the physician deems would interfere with patient fixation; who have corneal pathology such as Fuchs', EBMD, keratoconus, advanced pterygium impairing the cornea, or any other pathology that the physician deems would interfere with the measurement process; whose preoperative regimen includes residual viscous substances left on the corneal surface such as lidocaine gel or viscoelastics; with visually significant media opacity (such as prominent floaters or asteroid hyalosis) what will either limit or prohibit the measurement process; or who have received retro or peribulbar block or any other treatment that impairs their ability to visualize the fixation light. In addition, utilization of iris hooks during an ORA™ System image capture is contraindicated, because the use of iris hooks will yield inaccurate measurements. **WARNINGS AND PRECAUTIONS:** Significant central corneal irregularities resulting in higher order aberrations might yield inaccurate refractive measurements. Post refractive keratectomy eyes might yield inaccurate refractive measurement. The safety and effectiveness of using the data from the ORA™ System have not been established for determining treatments involving higher order aberrations of the eye such as coma and spherical aberrations. The ORA™ System is intended for use by qualified health personnel only. Improper use of this device may result in exposure to dangerous voltage or hazardous laser-like radiation exposure. Do not operate the ORA™ System in the presence of flammable anesthetics or volatile solvents such as alcohol or benzene, or in locations that present an explosion hazard. **ATTENTION:** Refer to the ORA™ System Operator's Manual for a complete description of proper use and maintenance of the ORA™ System, as well as a complete list of contraindications, warnings and precautions.



OCT software will try to show the segments of the retinal nerve fiber layer, but low scan quality can produce a garbled result.

nal nerve fiber layer, but if the scan quality isn't good, the segmentation will be thrown off and lead to inaccurate values. (See example, above.) The retinal nerve fiber layer is supposed to be the area between the two red lines. Anything that affects scan quality can cause this type of error.

Event-based or Trend-based?

There are two basic strategies for detecting change over a series of tests: event-based analysis and trend-based analysis. Each has advantages and limitations, so it's important to understand the difference.

- **Event-based analysis.** To perform event-based analysis, you simply compare one test to another. The practical reality is that there's a measurement error in every test we do, so in order to decide whether a change has actually occurred between the two tests, you have to first decide what amount of change in the measurements is likely to be greater than the instrument's potential error. Some current studies indicate that spectral-domain-OCT has about a 4- μm intervisit reproducibility.² So, to be sure a change is real, it should be greater than twice that, or 8 μm (approximately twice the statistical standard deviation value).

In our practice, we've chosen to be conservative and look for change greater than 10 μm ; if we don't see a 10- μm change, we take the result with a grain of salt. However, certain things can lower our threshold for detection.

If a patient has a very thin cornea, for example, that tells me that the patient may be at greater risk. In that case I'll lower my benchmark for progression to 8 μm .

Note that when doing an event-based comparison, you should compare the current test to the baseline tests—which should have been based on two stable early tests done within a limited time period—rather than comparing it to the previous test. If you only compare it to the previous test, you could miss slow progression.

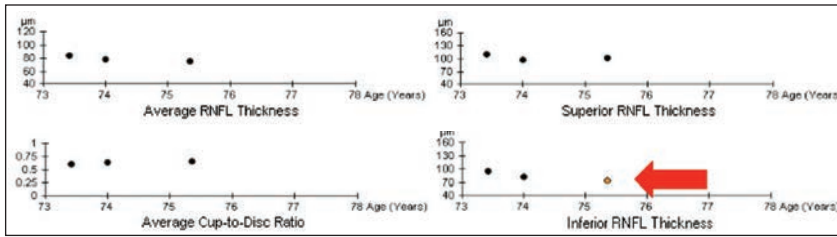
Event-based analysis has some notable limitations: It's susceptible to outliers, and it may identify false progression. On the other hand, it's easy. That's why many doctors use this kind of analysis in practice, especially if they don't have glaucoma progression analysis software, which features trend-based analysis.

- **Trend-based analysis.** This approach looks at a series of sequential tests, including your baseline tests, and measures the slope of change over time for whatever parameter you're looking at—overall change, change in the superior or inferior segments, or change in the ganglion cell complex. It's primarily concerned with the rate of change rather than the amount. (This is analogous to visual field progression detection.) As you can see in the example on the facing page, three of four parameters have remained relatively stable in this eye, but one has changed significantly over time. The software has highlighted this by turning the circle that represents that measurement orange.

The advantage of trend-based analysis is that it's less susceptible to fluctuation because it's looking at change over a period of time. The disadvantage is that it requires a large number of tests. In addition to your baseline tests, you usually need at least two or three subsequent tests to compare to your baseline to make



Alcon
a Novartis company



Trend-based analysis looks at a series of sequential test results over time. Here, three of four parameters have remained stable, but one has changed significantly, which the software has highlighted by coloring the circle orange.

the trend statistically robust. If you only get one scan a year, it can take several years to detect change using this type of analysis. Furthermore, to allow valid comparisons, it's critically important to choose baseline scans that were performed with good scan parameters.

In general, trend-based analysis is preferable to event-based analysis. However, there are many situations in which trend-based analysis can't help—even if it's available in software like Zeiss's Guided Progression Analysis. For example, a new patient may have had an OCT done on one machine and now you're doing it on another. Or you may have recently upgraded from one OCT to a newer one, perhaps from time-domain to Fourier-domain. Those two types of OCT data can't be directly compared. Practical issues like these often force us to resort to event-based analysis.

Helpful Strategies

These strategies will help you get the most from your OCT data:

- **Look at the entire readout, not just one or two numbers.** Many surgeons pick out one or two key numbers and only look at those when they review a scan. But you have to look at the entire scan to make sure the quality is good and the scan is centered. We try to discipline ourselves to avoid looking at the nerve fiber layer thickness—overall, inferior and superior—until after we review all of the other parameters, to make

sure the scan has good-quality data.

This is part of the reason for the problem referred to as “red disease,” where patients get referred—and sometimes treated—for glaucoma because they appear to have an abnormal OCT. When you look at the OCT, you find there's something wrong with the scan, not the patient. OCT is a powerful tool, but it's up to the clinician to use it correctly.

- **Look for focal change, not just overall change.** It's important to remember that retinal nerve fiber layer thinning can happen in several ways, which will be reflected in different scores. For example, you may find a global, overall decrease in average thickness, or you may find a focal decrease in one quadrant. The three most common RNFL progression patterns are:

- a new RNFL defect;
- widening of an existing defect;
- deepening of an existing RNFL defect without widening.

Studies have looked at these changes, and all of them seem to be important as a means to detect glaucoma.³ In practice, some doctors are in the habit of just looking at the overall thickness number; but for monitoring progression, if there's already a defect, you want to look at that area for changes. (The pie charts on the readout will tell you if a focal defect is getting worse.) That's important, because if a focal defect gets worse it may not cause much of a difference in the overall thickness, leading you to miss the change.

- **Be sure to account for normal aging.** There's a small loss of retinal nerve fiber layer and ganglion cells as we age, even in the healthiest of individuals, so it's important to take this into account when diagnosing or monitoring progression to avoid mistaking normal aging for disease. To do that, we need to know what the rate of normal loss is—at least on average.

Different studies have looked at this, both in a cross-sectional manner (taking a population and dividing it up into decades or five-year periods and looking at the average NFL thickness of normal patients in each age group) and longitudinal fashion (where individuals are followed over time). One study recruited 100 normal individuals for cross-sectional analysis and 35 for longitudinal analysis.⁴ That study found a loss of 0.33 µm per year using cross-sectional data and 0.52 µm per year using longitudinal. The Advanced Imaging for Glaucoma Study did both types of analysis with 192 eyes over five years. The cross-sectional analysis found a GCC loss of 0.17 µm per year and overall retinal nerve fiber layer loss of 0.21 µm per year; the longitudinal analysis found a loss of 0.25 µm per year in GCC thickness and 0.14 µm in overall nerve fiber layer thickness.⁵ (Obviously, longitudinal data is likely to be more robust, but longitudinal studies don't go on long enough to cover the age span that can be covered in a cross-sectional study.)

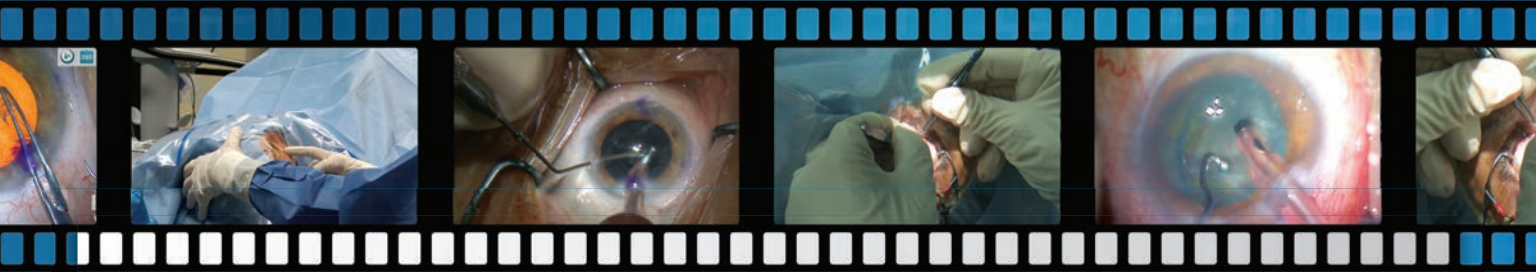
Many people combine the cross-sectional data and longitudinal data and average them. Conservatively, you're looking at about 0.2 µm per year for the NFL thickness. That's not a lot of loss, but over 10 years that can add up to several microns of change. As a result, that has to be factored into the software designed to analyze these data and taken into account when you're looking into progression without the help of software. So if



Monthly

MACKOOL ONLINE CME

CME SERIES | SURGICAL VIDEOS



To view CME video
go to:

www.MackoolOnlineCME.com

Episode 14: "Restoring Vision to a Special Young Man"

Surgical Video by:
Richard J. Mackool, MD

Video Overview:

Tom is a courageous and engaging young man with advanced Duchenne's Muscular Dystrophy. Years of steroid treatment have caused him to develop extremely dense cataracts and he is now legally blind. Severe muscular atrophy has left him quadriplegic with very significant respiratory problems that do not permit him to lie flat. Furthermore, even mild sedation could result in life-threatening oxygenation problems. In this video, our team performs cataract surgery without any sedation. Significant assistance is rendered by his mother, an RN who has essentially dedicated her life to caring for her severely disabled son. During the procedure, reverse Trendelenburg positioning, a positive pressure breathing apparatus and special draping to prevent claustrophobia enabled us to optimize his comfort and safety. Tom now has 20/20 distance and near vision in both eyes without glasses. His remarkable bravery in dealing with this dreaded disease and the dedication of his mother are more than inspirational, and their joy at the recovery of his sight was wonderful to behold. From the vantage point of this surgeon, I can only attest to what my dedicated colleagues already know; this is why we became physicians.

Accreditation Statement

This activity has been planned and implemented in accordance with the accreditation requirements and policies of the Accreditation Council for Continuing Medical Education (ACCME) through the joint providership of Amedco and Postgraduate Healthcare Education, LLC (PHE). Amedco is accredited by the ACCME to provide continuing medical education for physicians.

Credit Designation Statement

Amedco designates this live activity for a maximum of .25 AMA PRA Category 1 Credits™. Physicians should claim only the credit commensurate with the extent of their participation in the activity.

MackoolOnlineCME.com MONTHLY Video Series



Richard J. Mackool, MD

Welcome to the second year of Mackool Online CME! With the generous support of several ophthalmic companies, I am honored to have our viewers join me in the operating room as I demonstrate the technology and techniques that I have found to be most valuable, and that I hope are helpful to many of my colleagues. We continue to edit the videos only to either change camera perspective or to reduce down time - allowing you to observe every step of the procedure.

As before, one new surgical video will be released monthly, and physicians may earn CME credits or just observe the case. New viewers are able to obtain additional CME credit by reviewing previous videos that are located in our archives.

I thank the many surgeons who have told us that they have found our CME program to be interesting and instructive; I appreciate your comments, suggestions and questions. Thanks again for joining us on Mackool Online CME.



CME Accredited Surgical Training Videos Now Available Online: www.MackoolOnlineCME.com

Richard Mackool, MD, a world renowned anterior segment ophthalmic microsurgeon, has assembled a web-based video collection of surgical cases that encompass both routine and challenging cases, demonstrating both familiar and potentially unfamiliar surgical techniques using a variety of instrumentation and settings.

This educational activity aims to present a series of Dr. Mackool's surgical videos, carefully selected to address the specific learning objectives of this activity, with the goal of making surgical training available as needed online for surgeons motivated to improve or expand their surgical repertoire.

Learning Objective:

After completion of this educational activity, participants should be able to:

- Demonstrate techniques that can be employed during cataract surgery to improve the comfort and safety of patients with respiratory and/or claustrophobic problems.

Learn more about Duchenne's Muscular Dystrophy at www.endduchenne.org

Endorsed by:
Review of Ophthalmology®

Video and Web Production by:
JR Snowdon, Inc

Jointly Provided by:

AMEDCO & PHE

Supported by an unrestricted independent
medical educational grant from:

Alcon

Commercially supported by:

Carl Zeiss Meditec
Crestpoint Management
Glaukos
MST

REVIEW | Glaucoma Management

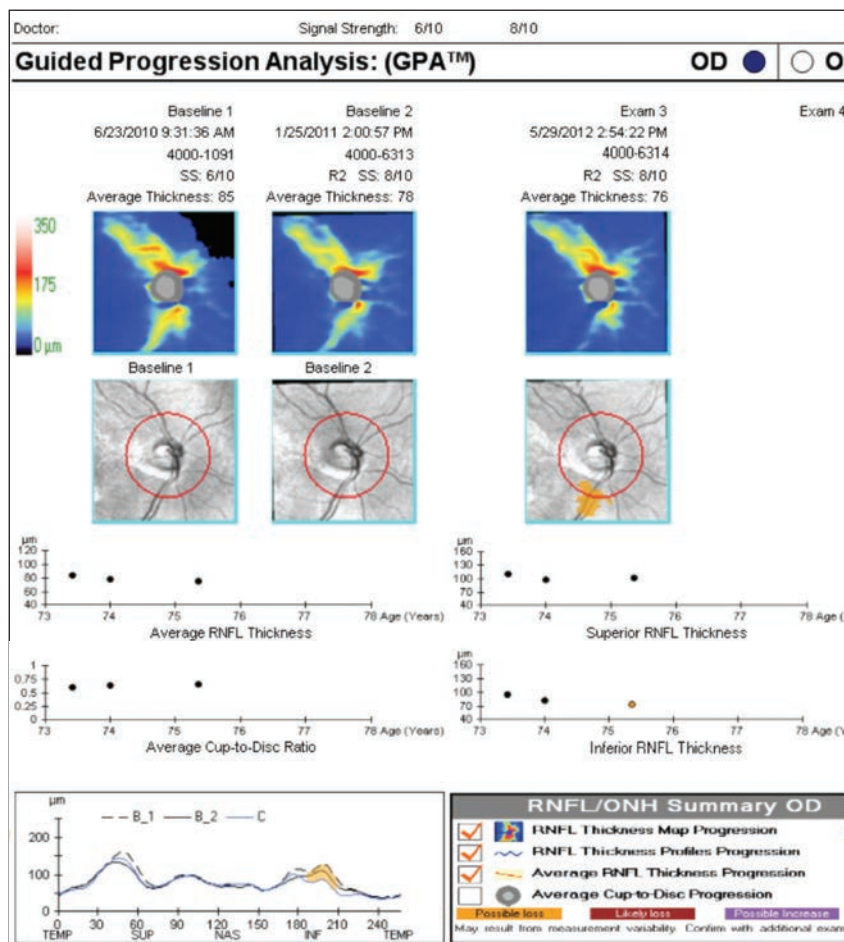
you're not using the GPA software and you're comparing two scans five years apart, trying to decide whether the patient has progressed or not, you need to be aware of that possible age-related change.

Using GPA

Zeiss's GPA is one of the programs commonly used to help analyze OCT results. The printout includes thickness charts at the top, in color; the change graphs for different parameters appear below that; and at the bottom left there's a chart that overlays the TSNIT pattern from multiple tests so you can identify any focal areas of change or loss. (See example, right) When the printout shows a yellow marker, that means it detects significant progression in that parameter; if it's red, that means the progression has been confirmed by multiple tests. In this example, the printout indicates progression of an inferior defect, noted in three different places on the printout: the area is illuminated in yellow on the black and white change map for exam #3; it's also represented by a yellow dot in the inferior segment thickness change graph; and it's colored yellow in the TSNIT graph in the lower left.

The GPA also allows you to do event-based analysis, which is sometimes useful for comparing to trend-based analysis. The readout provides a chart that shows the scores from different tests. However, as with most event-based analyses, you have to be careful. Consider the two examples on the following page (p.58). In the example on the left, the highlighted boxes are parameters that appear to be significantly changed. However, if you compare this to the trend analysis over time (as shown in the images above the boxes), there is no significant change.

The second example shows that the average RNFL thickness in this



Guided Progression Analysis shows focal areas of change or loss in yellow.

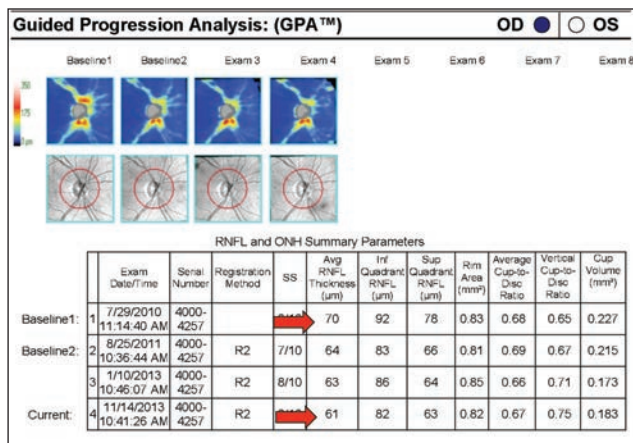
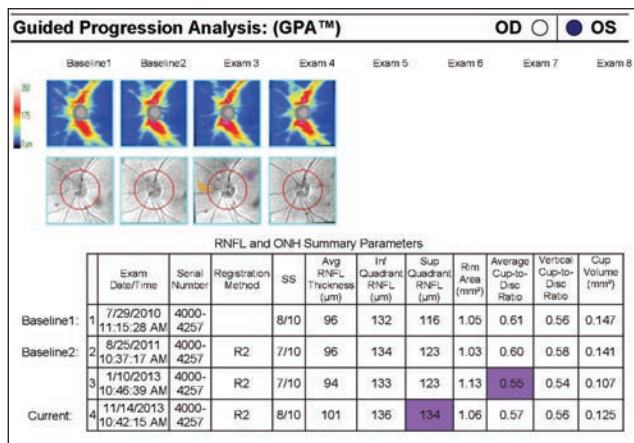
eye has decreased from 70 μm to 61 μm . You might say that's significant; it is 9 μm of change. But if you look at reference baseline exams 1 and 2, there's some variability between them, meaning the value of 70 μm should be taken with a grain of salt, and the amount of change may be less than it appears. Again, these examples demonstrate why trend-based analysis is generally preferable to event-based analysis—as long as you have sufficient data to use trend-based analysis.

Which Parameters Matter Most?

This is a challenging question that's being looked at by a number of researchers. One reason this is important is that if you have two

conflicting parameters—perhaps one looks stable while the other appears to have progressed—having a sense of which parameter is known to be associated more strongly with progression will help you judge which parameter should have more impact on your decision.

Another issue is that doctors would prefer to look at one or two things rather than a field of information when making a clinical decision. Knowing which parameters are most associated with progression should make it possible to create an index that incorporates those particular parameters, allowing doctors to get the most reliable information in a single number. Admittedly, it's always dangerous to give people a single thing to look at—we might be encouraging



Differences between individual numbers may suggest that significant change has taken place, but a closer examination of the larger picture, including trend analysis, may show that a significant change has not actually occurred.

them to ignore something else that's important. But it's better to have a composite index that takes different things into account than to only look at one piece of data, such as change in average thickness.

Our group conducted a sub-study under the Advanced Imaging for Glaucoma Study in which we identified different parameters that appeared to be especially useful for detecting progression. (We defined progression as visual field progression, to use a marker not related to nerve fiber layer change.) For example, we looked at different retinal nerve fiber layer parameters like focal loss volume; overall inferior quadrant volume; and all of the ganglion cell complex parameters. We found that one of the most sensitive predictors of progression is focal loss volume, both in the GCC and RNFL. (This supports the premise that focal change is able to detect progression earlier than overall average thickness changes.) Using that finding in concert with other relevant data, we created something we call the Glaucoma Composite Progression index. The GCP index combines structural measurements such as central corneal thickness and GCC focal loss volume with patient parameters such as age.

So far, our attempts (and many

others') are still just research; they haven't been incorporated into any instruments. But based on our own work, we can at least say that doctors should be monitoring the GCC focal loss volume. That parameter was better at predicting change than the other focal loss or overall loss measurements your instrument may provide.

Making the Most of OCT

To summarize, there's no question that OCT can help us diagnose and monitor our glaucoma patients, especially those with early or moderate disease. But you'll get the most out of your OCT scans if you:

- maintain good quality readings by monitoring scan signal quality and the alignment and centration of the scan, and watch out for opacities and segmentation errors;
- look at the entire readout, not just one or two numbers;
- look for focal change, not just overall change;
- remember to account for the aging effect; and
- use trend-based analysis whenever possible. And when you need to use event-based analysis, be aware of its potential problems so you get the best possible information from the data comparison. **REVIEW**

Dr. Francis is a professor of ophthalmology in the glaucoma service and the Rupert and Gertrude Stieger Endowed Chair at the Doheny Eye Institute, Stein Eye Institute, David Geffen School of Medicine, University of California Los Angeles. Dr. Chopra is the medical director of the Doheny Eye Centers Pasadena and an associate professor of ophthalmology of the glaucoma service in the department of ophthalmology at the David Geffen School of Medicine at UCLA. He is also the director of glaucoma research at the Doheny Image Reading Center at the Doheny Eye Institute. Drs. Francis and Chopra have no financial ties to any product mentioned.

1. Wu Z, Vazeen M, Varma R, Chopra V, Walsh AC, LaBree LD, Sadda SR. Factors associated with variability in retinal nerve fiber layer thickness measurements obtained by optical coherence tomography. *Ophthalmology* 114:1505-1512, 2007.
2. Mwanza JC, Chang RT, Budenz DL, et al. Reproducibility of peripapillary retinal nerve fiber layer thickness and optic nerve head parameters measured with cirrus HD-OCT in glaucomatous eyes. *Invest Ophthalmol Vis Sci* 2010;51:5724-5730.
3. Leung CK, Yu M, Weinreb RN, Lai G, Xu G, Lam DS. Retinal nerve fiber layer imaging with spectral-domain optical coherence tomography: Patterns of retinal nerve fiber layer progression. *Ophthalmology* 2012;119:9:1858-66.
4. Leung CK, Yu M, Weinreb RN, Ye C, Liu S, Lai G, Lam DS. Retinal nerve fiber layer imaging with spectral-domain optical coherence tomography: A prospective analysis of age-related loss. *Ophthalmology* 2012;119:4:731-7.
5. Zhang X, Francis BA, Dastiridou A, Chopra V, Tan O, Varma R, Greenfield DS, Schuman JS, Huang D; Advanced Imaging for Glaucoma Study Group. Longitudinal and cross-sectional analyses of age effects on retinal nerve fiber layer and ganglion cell complex thickness by fourier-domain OCT. *Transl Vis Sci Technol* 2016;4:5:2:1.



SAVE THESE DATES



2ND YEAR RESIDENT WET LAB PROGRAM

Dear Resident Program Director and Coordinator,

We would like to invite you to review the upcoming 2nd-Year Resident Programs for 2017 in Fort Worth. These programs offer a unique educational opportunity for second-year residents. To better familiarize beginning ophthalmologists with cataract surgery, these programs will consist of both didactic lectures and a state-of-the-art, hands-on wet lab experience. Technology and technique will be explained and demonstrated and surgeons will leave better prepared to optimize outcomes and manage complications when they arise.

The programs also serve as an opportunity for your residents to network with residents from other programs.

After reviewing the material, it is our hope that you will select and encourage your 2nd Year residents to attend one of these educational activities, which are CME accredited to ensure fair balance.

Sincerely,
Postgraduate Healthcare Education



Second-Year Wet Lab Programs: 2017

February 3 - 4
Fort Worth, TX
CLOSED
Course Director
Vikas Chopra, MD

February 24 - 25
Fort Worth, TX
Course Director
Jonathan Rubenstein, MD

www.revophth.com/CSE2ndyr2017

For more information: Visit the registration site above or
Email: dholmes@postgradhealthd.com • Call: Denette Holmes 866-627-0714

Courses are restricted to 2nd-year residents enrolled in an ophthalmology residency program at the time of the course. There is no registration fee for this activity. Air, ground transportation in Fort Worth, hotel accommodations, and modest meals will be provided through an educational scholarship for qualified participants.

Accreditation Statement

This activity has been planned and implemented in accordance with the accreditation requirements and policies of the Accreditation Council for Continuing Medical Education (ACCME) through the joint providership of Amedco and Postgraduate Healthcare Education. Amedco is accredited by the ACCME to provide continuing medical education for physicians.

Credit Designation Statement

This activity has been approved for AMA PRA Category 1 Credit™.

Endorsed by:

Review of Ophthalmology®

Jointly provided by:



Supported by an independent medical education grant from:

Alcon



A Review of Portable Retinal Imaging

A guide to using common devices such as smartphones as well as more exotic consumer-level cameras to capture images.

Melissa Sieber, MD, Murtaz Adam, MD and Sunir Garg, MD, Philadelphia

Our ability to image the eye enhances patient care and counseling, while augmenting medical education. However, outside the traditional clinical setting, standard ophthalmic cameras can be impractical and costly. Accordingly, there's been interest in adapting non-ophthalmic imaging devices that are readily available, easy to use, and relatively inexpensive for ophthalmic use.

Advancements in microfabrication, optics, digital sensors and image processing have led to progressively smaller, more portable and more powerful imaging devices. Integrating these devices into wireless networks facilitates secure image transmission for tele-ophthalmology applications. As a result, there are now numerous ways to image the retina. Here, we'll discuss a few of them.

Smartphone Ophthalmoscopy

The smartphone camera is the most ubiquitous technology available for ophthalmic imaging, and it can approach the optical quality and resolution of many commercial digital single-lens reflex cameras.

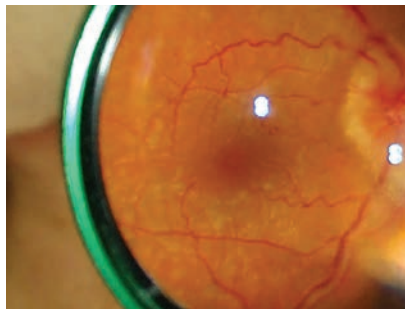

Figure 1a (left). Mydriatic fundus photo of cryptococcal meningitis with focus on the posterior pole and macula captured with a 20-D lens and smartphone camera. By capturing video instead of still photos, the best image for highlighting the pathology of interest can be selected.⁴

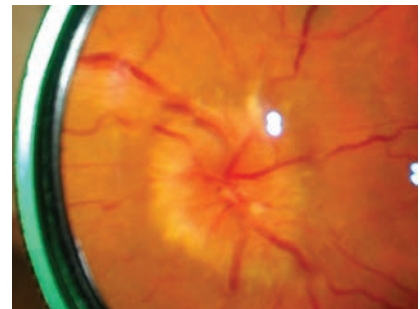


Figure 1b (right). Mydriatic fundus photo of optic-disc edema secondary to cryptococcal meningitis, captured with a 20-D lens and smartphone camera.

In 2013, the iExaminer (Welch-Allyn; Skaneateles Falls, N.Y.), an adaptive device used to capture fundus images with the iPhone became available. iExaminer captures images through undilated pupils; however, the quality and restricted field of view of this device has limited its use.

More recently, a non-mydriatic smartphone camera device called PEEK Retina (Peek Vision, London) was created by an interdisciplinary team of ophthalmologists, optics experts and engineers at London's

Moorfields Eye Hospital. It's a modular adapter created for Android-based devices that makes the camera's flash confocal with the optical sensor so it can illuminate the retina and capture a clear image. A prospective study in Kenya compared optic disc photos using PEEK Retina with a Samsung S3 phone to photos taken with a non-mydriatic fundus camera (CentreVue + Digital Retinal System, Haag-Strait; Harlow, U.K.). The images were securely transmitted and remotely graded in the U.K. The authors found

excellent agreement with vertical cup-to-disc ratio grading between the two devices. This was even more impressive because the PEEK device was operated by non-clinicians given only a brief training course, while the fundus camera was operated by an ophthalmic technician.¹ This proof-of-concept study demonstrated that a smartphone device can be used in remote areas, operated by lay examiners, recharged with mobile units not requiring constant electricity and can easily be replaced if lost or damaged.²

Another device, D-Eye (D-Eye; Pasadena, Calif.), was developed in Italy and can also be used to capture non-mydratric fundus images. A prospective, cross-sectional study of dilated eyes demonstrated 55- to 89-percent sensitivity for detection of diabetic retinopathy using the D-Eye device fitted to an iPhone 5 compared to slit lamp biomicroscopy. Differences in sensitivity rates varied depending on the degree of retinopathy.³

All three of the above devices are bundled with associated secure HIPPA-compliant apps for image transmission; however, only the iExaminer and D-Eye are approved by the Food and Drug Administration. PEEK Retina is currently seeking FDA approval.

Taking Pictures

With practice, a smartphone camera can be used to obtain high-quality images of the posterior pole through a dilated pupil.

PEEK Vision's CEO Andrew Bastawrous, who is also an ophthalmologist, developed a way to capture mydratric fundus images using a smartphone.⁴ With a smartphone's native camera application set to video mode with the flash "on," the photographer holds the phone in one hand and a 20- or 28-D lens in the other in a manner analogous to performing indirect ophthalmoscopy. By capturing

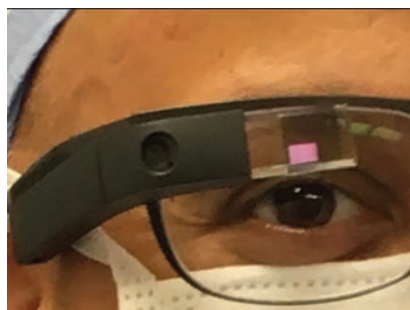


Figure 2. A surgeon wearing the Google Glass, which displays the recorded image in front of the user's eye through a prism. Google Glass has a computerized central processing unit, touchpad display screen, microphone and high-definition camera. It records in 720p with 5 MP still shots and is worn like a conventional pair of glasses.

video rather than still photos, frames that best highlight the pathology of interest can be selected (*Figure 1a and 1b, facing page*). This technique is most useful in resource-poor areas and in inpatient settings.

In the Smartphone Ophthalmoscopy and Reliability Trial, images obtained via smartphone ophthalmoscopy detected 74.3 percent of critical fundus findings (like retinal hemorrhage, subretinal fluid and optic disc edema) found on binocular indirect examination.⁵ This rate was only slightly less than the 77.1 percent detection rate for critical fundus findings with a standard fundus camera. Mul-

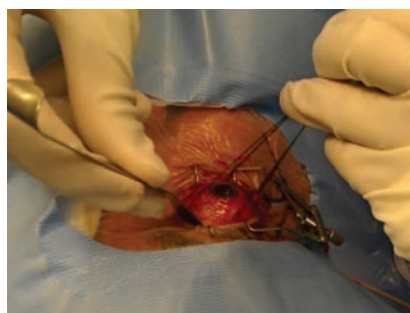


Figure 3. A still photo captured with the Google Glass during a scleral buckle surgery. Photo capture is activated with a head tilt and voice command from the surgeon. This is the surgeon's point of view when scleral quadrants are being examined prior to buckle placement.

tiple studies have validated the utility and quality of images captured using this technique,^{5,6,7} though the need for dilation and a learning curve similar to that of indirect ophthalmoscopy may limit its utility for non-ophthalmologists. Other investigators have created and tested adapters to perform head-mounted indirect ophthalmoscopy using an iPhone or GoPro camera (GoPro; San Mateo, Calif.).^{8,9}

A group from Stanford University has tried to simplify this indirect technique by using a smartphone mount to hold a 28-D lens (Paxos, Digisight Technologies; San Francisco). This might limit the bimanual variability that occurs with indirect ophthalmoscopy. Two studies demonstrated that this device is capable of producing high-quality fundus images that can be useful in screening for moderate to more advanced diabetic retinopathy.^{10,11}

Surgeon POV Recording

It's been hard to obtain surgical videos of globe and ocular adnexa from the surgeon's point of view, a perspective that helps teach surgical techniques to others. Operating microscopes obtain high-quality videos of the anterior and posterior segment, but are hampered by a static, top-down point of view. A videographer can record surgery, but an off-axis perspective and non-optimal lighting limit these videos. Surgical cameras mounted in the overhead lights work well but can be cost-prohibitive.¹² Recently, relatively affordable first-person cameras such as Google Glass and GoPro have been used effectively to record eye surgery from the surgeon's point of view.^{13,14}

Google Glass (*Figure 2*), worn like a pair of conventional glasses, contains a heads-up display with a first-person camera that is turned on with a tilt of the head. Voice commands capture still images (*Figure 3*) and 10-second

video clips. Google Glass has successfully recorded scleral buckle surgery.¹⁵ Unfortunately, there is no commercial version of Google Glass available, but Google is rumored to be working on a newer version, and there are a number of companies that support the one we've used.

The GoPro (Figure 4), designed to record extreme sports, features a high recording frame rate and dynamic lighting adaptability; it has been used to record a tap-and-inject procedure for endophthalmitis.¹⁶ The GoPro device can also be used hands-free to record photos and videos in the operating room (Figure 5). Simultaneous recording with two head-mounted GoPro cameras has also been used to record 3D video for stereoscopic viewing of scleral buckle surgery.¹⁷

Each device has some advantages. Google Glass is comfortable to wear and looks like a pair of glasses. The surgeon can see what's being recorded in real time, so adjustments in camera position are easy to make. However, the camera doesn't have a great dynamic range, and the spotlights in the operating room can overexpose the image. The GoPro camera has better dynamic range and comes with easy-to-use software that facilitates post-production zoom and adjustment of both audio and video quality. With the GoPro, the image can be sent to a smartphone so an assistant can watch the live footage. The surgeon, however, can't see what's being recorded in real time and, since the surgeon continuously moves, the forehead-mounted camera also moves. This means that the surgical field is frequently out of the frame. To increase the likelihood of capturing useful images with GoPro, simultaneous recording with two GoPro cameras, one on the head and another on the chest, has been proposed,¹⁸ or the assistant viewing the smartphone with live feed can direct the surgeon to keep the image usable.



Figure 4. The GoPro Hero4 Silver Edition. GoPro is worn on the forehead of the surgeon with the camera mounted on a head strap within a case. The compact camera is equipped with a touchscreen display, micro-speaker, and Wi-Fi. It records in 1080p and takes 12 MP still shots.

It's clear that portable ophthalmic imaging will become increasingly important in the years to come. In addition to using video equipment for recording procedures for presentations and lectures, tele-ophthalmology networks are growing both in developed and developing countries, and portable, easy-to-use, low-cost, high-resolution panophthalmic imaging is critical. Although no current portable device ideally images the anterior and posterior segments, there are several options currently available, and newer ones are in development. Additionally, first-person surgical videography offers a new and potentially better way to educate others on surgical technique, and the technology continues

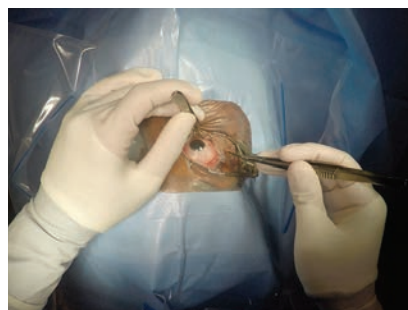


Figure 5. Still photo of scleral buckle surgery captured with GoPro Hero4 Silver. GoPro can be controlled via live stream onto a nearby smartphone or computer. This is the surgeon's point of view, showing the scleral buckle being placed around the eye.

to evolve to help us to meet the needs of patients and our profession. **REVIEW**

Melissa Sieber, MD, is a second year ophthalmology resident at Wills Eye Hospital. Murtaza Adam, MD, is a second year retina fellow at Wills Eye Hospital. Sunir Garg, MD, is a professor of ophthalmology at MidAtlantic Retina, the retina service of Wills Eye Hospital. He can be reached at sgarg@midatlanticretina.com. The authors have no financial interest in any of the products discussed.


1. Bastawrous A, Giardini M, Bolster NM, et al. Clinical validation of a smartphone-based adapter for optic disc imaging in Kenya. *JAMA Ophthalmol* 2016;134:151-158.
2. Garg SJ. Applicability of smartphone-based screening programs. *JAMA Ophthalmol* 2016;134:158-159.
3. Russo A, Morescalchi F, Costagliola C, et al. Comparison of smartphone ophthalmoscopy with slit-lamp biomicroscopy for grading diabetic retinopathy. *Am J Ophthalmol* 2015;159:360.
4. Bastawrous A. Smartphone Fundoscopy. *Ophthalmology* 2012;119:432-433.
5. Adam MK, Brady CJ, Flowers AM, et al. Quality and diagnostic utility of mydriatic smartphone photography: The smartphone ophthalmoscopy reliability trial. *Ophthalmic Surg Lasers Imaging Retina* 2015;46:631-637.
6. Ryan ME, Rajalakshmi R, Prathiba V, et al. Comparison among methods of retinopathy assessment (CAMRA) study. *Ophthalmology* 2015;122:2038-2043.
7. Haddock LJ, Kim DY, Mukai S. Simple, Inexpensive technique for high-quality smartphone fundus photography in human and animal eyes. *J Ophthalmol* 2013. doi: 10.1155/2013/518479
8. Wang A, Avallone J, Guyton DL. Head mounted digital camera for indirect ophthalmoscopy. *Invest Ophthalmol Vis Sci* 2014;55:1606-1606.
9. Welch RJ, Nguyen QD. A novel approach to ophthalmic photography using a portable and versatile camera device. *Invest Ophthalmol Vis Sci* 2015;56:4102-4102.
10. Ludwig CA, Murthy SI, Pappuru RR, et al. A novel smartphone ophthalmic imaging adapter: User feasibility studies in Hyderabad, India. *Indian J Ophthalmol* 2016;64:191-200.
11. Toy BC, Myung DJ, He L, et al. Smartphone-based dilated fundus photography and near visual acuity testing as inexpensive screening tools to detect referral warranted diabetic eye disease. *Retina* 2016;36:1000-1008.
12. Matsumoto S, Sekine K, Yamazaki M, et al. Digital video recording in trauma surgery using commercially available equipment. *Scand J Trauma Resusc Emerg Med* 2013;21:27.
13. Hashimoto DA, Phitayakorn R, Fernandez-del Castillo C, Meireles O. A blinded assessment of video quality in wearable technology for telementoring in open surgery: The Google Glass experience. *Surg Endosc* 2016;30:372-378.
14. Paro JAM, Nazareli R, Gurjala A, et al. Video-based self-review: Comparing Google Glass and GoPro technologies. *Ann Plast Surg* 2015;74:S71-S74.
15. Rahimy E, Garg SJ. Google glass for recording scleral buckling surgery. *JAMA Ophthalmol* 2015;133:710-711.
16. Calvo CM, Sridhar J, Hong BK, et al. Video recording of vitreous tap and intravitreal antibiotic injection from the surgeon's perspective. *Retina* 2015;35:2147-2149.
17. Birnbaum FA, Wang A, Brady CJ. Stereoscopic surgical recording using GoPro cameras: A low-cost means for capturing external eye surgery. *JAMA Ophthalmol* 2015;133:1483-1484.
18. Warrion KJ, Ashenurst M, Gooi A, Gooi P. A novel combination point-of-view (POV) action camera recording to capture the surgical field and instrument ergonomics in oculoplastic surgery. *Ophthalm Plast Reconstr Surg* 2015;31:321-322.

A PUBLICATION BY

REVIEW
of Ophthalmology

RETINA SPECIALIST

Retina Specialist focuses on the latest advances in the diagnosis, medical management and surgical treatment of diseases of the retina, along with practical, real-world advice from leading clinicians and other experts on managing the successful retina practice.



The new addition to the *Review* family serves the entire Retina Specialist marketplace.

Look for your issues in 2017:

» **MARCH**

» **JUNE**

» **SEPTEMBER**

» **NOVEMBER**

For inquiries contact

RETINASPECIALIST@JOBSON.COM

Advertising opportunities

JIM HENNE • PUBLISHER • 610-492-1017 • JHENNE@JOBSON.COM

MICHELE BARRETT • 215-519-1414 • MBARRETT@JOBSON.COM

MICHAEL HOSTER • 610-492-1028 • MHOSTER@JOBSON.COM

www.retina-specialist.com

A New Day Dawns for Dry-eye Therapy

A look at the challenges involved in getting new dry-eye therapies approved and how researchers are overcoming them.

Mark B. Abelson, MD, CM, FRCSC, FARVO, George Ousler, James McLaughlin, PhD, and David A. Hollander, MD, MBA, Andover, Mass.

For many years, dry eye has been a tough nut to crack from the standpoint of new therapies, since the signs and symptoms often don't line up the same way in different patients. Now, however, with the first FDA approval of a therapeutic in 13 years—*Xiidra* ophthalmic solution (lifitegrast, Shire)—it appears that researchers and clinicians are finally beginning to understand how to approach the treatment of this elusive condition, and numerous therapies are sure to follow. In this month's *Therapeutic Topics*, the authors survey the list of past treatments that didn't pass muster, discuss refinements in treatment approaches and take a look at the exciting therapies in the pipeline.

—Walter Bethke, Editor in Chief

A Tough Road

In 1995, the National Eye Institute hosted an industry workshop called Clinical Trials in Dry Eye. Looking back at the meeting report,¹ it's remarkable that so little emphasis was placed on symptoms of the disease: There was only a brief mention of a dry-eye questionnaire for symptom

assessment.² Despite this, the report did recognize the lack of correlation between diagnostic measures and symptomatic assessments, and promoted a general rubric where both signs and symptoms were part of clinical assessment of new therapies.

In hindsight, this might be considered a case of one step up, two steps back: Recognition of the importance of the disconnect between signs and symptoms is a key to understanding dry eye, but many of the studies that followed were based upon a near-impossible hurdle of co-primary endpoints. In addition, the measurement of symptoms turns out to be much more nuanced than was appreciated at the time, and an evaluation of the McMonnies symptom questionnaire showed that the design of the test failed a Rasch analysis of univariate assessments.³ This analysis tests the statistical validity of using summated scores of a specific series of questions as a reliable metric of a condition or variable. Symptom questionnaires have been refined since then, with an emphasis on a few select questions focusing on subjects reporting symptoms as they occurred instead of

retrospectively.

In the decade that followed, a host of compounds were tested as potential dry-eye therapies,⁴⁻⁷ but only one treatment was approved, the cyclosporine ophthalmic emulsion *Restasis* (Allergan). In this case, the approval used a narrow indication, improvement of tear production, as the clinical endpoint rather than the co-primary endpoints of other trials. It's for this reason that the *Restasis* label indication is for increasing tear production in patients whose tear production is presumed to be suppressed due to ocular inflammation associated with keratoconjunctivitis sicca.

Progress is Made

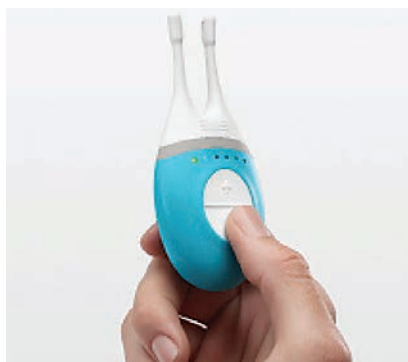Drug developers trying to devise treatments for dry eye were stymied by the unusually large degree of patient heterogeneity that is characteristic of the condition. Some patients have severe symptoms but few or none of the physical manifestations of disease, such as increased corneal staining, reduced Schirmer's scores or altered tear-film breakup times. In addition, significant variability from en-

vironmental factors such as air quality and humidity, and lifestyle factors such as computer use and medications, means that day to day, dry eye can be severe, mild or totally absent.

This kind of variability can be problematic in the setting of a clinical trial, even with large patient populations.

We can get a clue to the ways this problem has been addressed by comparing clinical trial protocols from 2004 to those in 2016. For a 2004 study,⁴ the inclusion criteria were “non-Sjögren’s dry eye with symptoms for more than six months, and intermittent or regular artificial tear use for three months.” The exclusion criteria were equally brief—patients could not have undergone LASIK, punctal occlusion or cauterization. Despite this, most patients in early studies were the most severe dry-eye sufferers, and tended to be those less responsive to any treatment. In contrast, the most recent trials have focused on either a sign or a symptom as a primary endpoint, and they include inclusion criteria of a minimal level of current disease severity (such as corneal fluorescein staining score of ≥ 2) to establish a sufficient level of disease for therapeutic assessment. In addition, tools such as the controlled adverse environment, or CAE, have provided an additional inclusion tool by identifying those dry-eye patients most likely to experience an exacerbation of their disease under conditions of environmental stress.^{8,9}

Thus, the answer to the problem of patient heterogeneity seems to involve several steps. First, it’s essential to identify dry-eye patients that share similar disease phenotypes using carefully designed inclusion criteria; this allows for an unambiguous assessment of a therapeutic effect. Since we know that some experience significant discomfort, grittiness, burning or other symptoms without showing signs such as elevated corneal staining, it follows that these patients should be



The intranasal tear neuro-stimulator from Allergan is showing potential in trials.

assessed primarily with symptomatic criteria. Refined scales for both signs and symptom assessment, such as the Ora Calibra scales used for staining and discomfort,¹⁰ improve assessment reproducibility. Similarly, inclusion based upon established signs such as corneal staining or Schirmer’s scores can be used to assess improvements in these measures independent of symptomatic improvements.

Another approach to minimizing variation in dry-eye trials is the use of adverse environments such as the CAE. The adverse environmental conditions mimic those that exacerbate dry eye and provide enhanced efficacy measures by comparing patient responses to CAE stress before and after a treatment regimen. Because dry eye is a result of a combination of physiological factors and the environmental milieu, disease variability can be reduced if parameters such as temperature and humidity are controlled. Other types of visual stress, such as computer work and reading,¹¹ have been incorporated into experimental clinical trial designs, and these show promise as a means of establishing clinically significant therapeutic benefits of an intervention.

Recent trial results show how these new approaches can impact clinical success. One recent Phase II study used CAE-based inclusion criteria to enrich the population with patients who had measurable, reproducible

signs and symptoms of dry eye. The study demonstrated significant, dose-dependent improvements in corneal staining and in the visual function subset of the ocular surface disease index,¹² and thus confirmed the benefit of CAE-based inclusion criteria. A subsequent Phase III trial replicated the staining results from Phase II. Collectively, these studies demonstrated a remarkable degree of reproducibility, a key result that was particularly encouraging for an indication such as dry eye, which is infamous for its variable nature.

Peering into the Pipeline

One drug is rarely the best drug for everyone, especially with a heterogeneous condition such as dry eye. Fortunately, several other compounds are now poised to bring their therapeutic benefits to the market. Many of these treatments are based upon distinct mechanisms of action, promising a future where ophthalmologists may be able to provide their patients with an individualized selection of suitable treatments. Different MOAs for a selection of agents also provide the potential of a future combination therapy for patients with severe dry eye. As in other diseases, it’s clear that dry eye has many phenotypical subsets that have yet to be teased out, and widening the choices for treatment is the best way to successfully treat the most patients.

Some new therapies are devices, not topical medications. The intranasal tear neuro-stimulator system (OD-01 Intranasal Device, Allergan) is a device that increases tear production with a mild nasal electrical stimulus. The stimulator has demonstrated increased Schirmer’s scores and reductions in corneal staining in open-label trials,¹³ and is currently awaiting FDA review.

Milder forms of dry eye are typically treated with artificial tears, and



several programs are exploring improvements in these formulations that may provide relief comparable to anti-inflammatories. Many of these compounds include chemically modified versions of hyaluronic acid,¹⁴ with the primary goal of providing a longer-lasting symptomatic relief that reduces the need for frequent dosing.

One of the new potential dry-eye therapeutics, SkQ1 (Mitotech, Luxembourg), has a mechanism quite different from other therapeutics: It's a free-radical scavenger that acts by reducing oxidative stress, including the oxidative stress associated with inflammation. A recently published Phase II study¹⁵ focused on therapeutic effects before and after CAE exposure, and showed that the drug provided significant improvements in both corneal staining and in multiple measures of ocular discomfort.

A second therapeutic that has completed Phase II is RGN-259 (ReGenTree; Princeton, N.J.), an ophthalmic solution containing 0.1% thymosin β 4, an endogenous, pleiotropic peptide that acts to resolve inflammatory events both by acting on cell migration and on cytokine signaling. The trial used a CAE challenge to screen and enroll an enriched patient population and measure a patient's ability to withstand an acute adverse environmental challenge to the ocular surface.¹⁶ Results from the study included significant improvement in discomfort and central corneal staining. A Phase III study for RGN-259 is in progress.

Another new potential treatment that has reached the Phase III development stage is Tavilermide (Mimetogen Pharmaceuticals, Montreal), a TrkA receptor agonist that can mimic or augment the effects of nerve growth factor. NGF is a major positive regulator of goblet cell growth, conjunctival and goblet cell mucin expression, and mucin secretion. In Phase II trials, Tavilermide significantly improved total corneal

fluorescein staining when assessed as the change from pre- to post-exposure in the CAE chamber.¹⁰ Tavilermide also showed significant improvements in diary-reported ocular dryness, and ocular discomfort was significantly improved in the high-dose treatment group ($p=0.014$). These results were encouraging, and despite missing the primary endpoints, the drug is now in Phase III development.


*There is an assortment
of molecular targets
that may be able to
provide a pathway to
dry-eye relief for our
patients.*


A handful of other compounds under development include CycIASol (Novaliq, Germany), a cyclosporine that employs a proprietary formulation designed to optimize drug delivery; BRM 421 (Brim Biotechnology, Taiwan), a neurotrophic peptide that stimulates wound healing and corneal repair; TOP1630 (Topivert, UK), a kinase inhibitor that blocks inflammatory signaling; and KPI-121 (Kala Pharmaceuticals; Waltham, Mass.) a novel formulation of loteprednol etabonate.

These examples of potential dry-eye therapies demonstrate that there is an assortment of molecular targets that may provide a pathway to dry-eye relief. Perhaps one of the most encouraging aspects of the near future of dry-eye treatments is that, with a refined roadmap to clinical success and a growing number of candidate therapies, each with a unique approach to dry eye, the odds increase that all of our patients will be able

to find a treatment best-suited to them. **REVIEW**

Dr. Abelson is a clinical professor of ophthalmology at Harvard Medical School. Mr. Ousler is vice president for dry eye at the research and consulting firm Ora Inc. Dr. McLaughlin is a medical writer at Ora. Dr. Hollander is chief medical officer at Ora, and assistant clinical professor of ophthalmology at the Jules Stein Eye Institute at the University of California, Los Angeles.

1. Lemp MA. Report of the National Eye Institute Industry workshop on Clinical Trials in Dry Eyes. *CLAO J* 1995;21:4:221.
2. McMonnies CW, Ho A. Patient history in screening for dry eye conditions. *J Amer Optom Assoc* 1987;58:296-301.
3. Gotthwal VK, Pesudovs K, Wright TA, McMonnies CW. McMonnies questionnaire: Enhancing screening for dry eye syndromes with Rasch analysis. *Invest Ophthalmol Vis Sci* 2010;51:3:1401-7.
4. ClinicalTrials.gov Identifier: NCT00037661 "INS365 Ophthalmic Solution in a Controlled AE in Patients with non-Sjogren's Dry Eye" Sponsor: Merck Sharp & Dohme Corp. First received: May 18, 2002. Last updated: October 1, 2015.
5. Sall K, Stevenson OD, Mundorf TK, Reis BL. Two multicenter, randomized studies of the efficacy and safety of cyclosporine ophthalmic emulsion in moderate to severe dry eye disease. *CsA Phase 3 Study Group. Ophthalmology* 2000;107:4:631-9.
6. ClinicalTrials.gov Identifier: NCT00198536 "Efficacy and Safety Study for Ecabet Ophthalmic Solution for Treating Dry Eye Syndrome," Sponsor: Bausch & Lomb Incorporated. First received: September 13, 2005. Last updated: March 13, 2013.
7. ClinicalTrials.gov Identifier: NCT00201981 "Study of Rebamipide Eye Drops to Treat Dry Eye," Sponsor: Otsuka Pharmaceutical Development & Commercialization, Inc. First received: September 12, 2005. Last updated: January 4, 2008.
8. Abelson R, Lane KJ, Rodriguez J, Johnston P, Angjeli E, Ousler G, Montgomery D. A single-center study evaluating the effect of the controlled adverse environment (CAE) model on tear film stability. *Clin Ophthalmol* 2012;6:1865-72.
9. González-García MJ, González-Sáiz A, de la Fuente B, et al. Exposure to a controlled adverse environment impairs the ocular surface of subjects with minimally symptomatic dry eye. *Invest Ophthalmol Vis Sci* 2007;48:9:4026-32.
10. Meerovitch K, Torkildsen G, Lonsdale J, Goldfarb H, Lama T, Cumberland G, Ousler GW 3rd. Safety and efficacy of MIM-D3 ophthalmic solutions in a randomized, placebo-controlled Phase 2 clinical trial in patients with dry eye. *Clin Ophthalmol* 2013;7:1275-85.
11. Ousler GW 3rd, Rodriguez JD, Smith LM, Lane KJ, Heckley C, Angjeli E, Abelson MB. Optimizing Reading Tests for Dry Eye Disease. *Cornea* 2015;34:8:917-21.
12. Semba CP, Torkildsen GL, Lonsdale JD, et al. A Phase II randomized, double-masked, placebo-controlled study of a novel integrin antagonist (SAR 1118) for the treatment of dry eye. *Am J Ophthalmol* 2012;153:1050-1060.
13. Friedman NJ, Butron K, Robledo N, et al. A nonrandomized, open-label study to evaluate the effect of nasal stimulation on tear production in subjects with dry eye disease. *Clin Ophthalmol* 2016;4:10:795-804.
14. ClinicalTrials.gov Identifier: NCT02205840 "A Clinical Study Evaluating the Safety and Efficacy of SI-614 Ophthalmic Solution in Patients With Dry Eye," Sponsor: Seikagaku Corporation. First received: July 30, 2014. Last updated: January 19, 2015.
15. Petrov A, Perekhvatova N, Skulachev M, et al. SkQ1 ophthalmic solution for dry eye treatment: Results of a Phase II safety and efficacy clinical study in the environment and during challenge in the CAE model. *Adv Ther* 2016;33:1:96-115.
16. Sosne G, Ousler GW. Thymosin beta 4 ophthalmic solution for dry eye: A randomized, placebo-controlled, Phase II clinical trial conducted using the controlled adverse environment (CAE) model. *Clin Ophthalmol* 2015;20:9:877-84.


ENRICH YOUR PRACTICE

Review of Ophthalmology delivers current and comprehensive information focusing on topics such as disease diagnosis, surgical techniques and new technologies.

The *Review Group's Ophthalmic Product Guide* brings you the latest products and technology on the market. Published every February and July.



The *Review Group* also distributes a variety of supplements, guides and handbooks with your subscription to *Review of Ophthalmology*. These publications are designed to keep you informed on what's new and innovative in the industry on topics ranging from cataract refractive surgery to ocular surface disease.



The *Review Group* also offers valuable continuing medical education sessions in both print and online formats, allowing a convenient way for you to earn CME credits. In addition, we also offer an impressive fleet

of free e-newsletters—such as *Review of Ophthalmology Online* and *Review of Ophthalmology's Retina Online*—so you can keep up to date on breaking news and the latest research.



The *Review Group* offers eyecare practitioners quality informational resources dedicated to the growth and education of the profession. The *Review Group* offers a variety of print and online products to enrich your patient care and practice needs.



The *Review Group* also spearheads meetings and conferences, bringing together experts in the field and providing a forum for practitioners that allows you to educate, and learn from others in the profession. These meetings cover a broad range of topics in the form of educational or promotional roundtables and forums.

www.reviewofophthalmology.com



Jobson Medical Information LLC
The *Review Group*

Smartphone Use and Pediatric Dry Eye

Researchers from Korea investigated risks and protective factors associated with pediatric dry-eye disease in relation to smartphone use rate, categorized by region and age.

They enrolled 916 children in the study and performed an ocular exam that included a slit lamp exam and tear breakup time. Researchers also administered a questionnaire to children and their families, inquiring about video display terminal use and outdoor activity. DED was defined based on the International Dry Eye Workshop guidelines, looking specifically at punctate epithelial erosion and short tear breakup time. Children were divided into: DED vs. control; urban vs. rural; younger grade (1st to 3rd) vs. older grade (4th to 6th).

A total of 6.6 percent of children were included in the DED group; 8.3 percent of children in the urban group were diagnosed with DED compared to 2.8 percent in the rural group ($p=0.03$). The rate of smartphone use was 61.3 percent in the urban group and 51 percent in the rural group ($p=0.04$). In total, 9.1 percent of children in the older-grade group were diagnosed with DED compared to 4 percent in the younger-grade group ($p=0.03$). The rate of smartphone use was 65.1 percent in older-grade children and 50.9 percent in younger-grade children ($p<0.001$). The mean daily duration of smartphone use was longer

in the DED group than controls ($p<0.001$, OR= 13.07), and the mean daily duration of outdoor activities was shorter in the DED group than controls ($p<0.01$, OR=0.33). After cessation of smartphone use for four weeks in the DED group, both subjective symptoms and objective signs had improved.

While smartphone use in children was strongly associated with pediatric DED, outdoor activity appeared to be protective against it. Older-grade students in urban environments had DED risk factors and a short duration of outdoor activity time. Therefore, the researchers say, close observation and caution are needed when older children in urban areas use smartphones, as they are more likely to develop pediatric DED.

BMC Ophthalmol 2016;16:188
Moon J, Kim K, Moon N.

IOL Powers in Aging Eyes

Because age-related changes in lens elasticity and ciliary muscle contractility can affect how ocular parameters respond to cycloplegia and intraocular lens power measurements calculated by formulas using anterior chamber depth, lens thickness or white-to-white for effective lens position prediction can therefore vary. With that in mind, researchers from Turkey sought to investigate changes in ocular parameters and IOL power calculations attributable to cycloplegia

in aging eyes.

In this cross-sectional study, looking at 38 pre-presbyopic and 42 presbyopic eyes, researchers measured pupil diameter, radius of corneal curvature values, central corneal thickness, WtW, ACD, LT and axial length, both before and after cycloplegia. Using SRK/T, Holladay 2 and Haigis formulas, researchers performed IOL power calculations. To pinpoint the effect of cycloplegia, researchers recorded refractive predictions in pre- and post-dilation conditions using the same IOL power calculations, even if post-dilation IOL power calculations had changed.

With cycloplegia, pupil diameter changed significantly more in presbyopic eyes ($p=0.001$). Central corneal thickness decreased in pre-presbyopic eyes ($p=0.048$), whereas WtW increased in presbyopic eyes ($p=0.02$). In both groups, ACD and LT changed significantly ($p<0.001$). IOL power calculations using the Holladay 2 formula differed in pre-presbyopic eyes ($p=0.042$), and refractive predictions with the Holladay 2 and Haigis formulas differed significantly in pre-presbyopic eyes ($p=0.043$ and $p=0.022$, respectively).

Considering these results, the investigators recommend that surgeons consider the effect of cycloplegia on refractive prediction errors and IOL power calculations determined with Haigis and Holladay 2 formulas,

especially in pre-presbyopic eyes.

Am J Ophthalmol 2017;173:76-83
Özyol P, Özyol E, Baldemir E.

Clinical Activity of CNV in AMD

Researchers from Boston sought to characterize the features of choroidal neovascularization in neovascular age-related macular degeneration using spectral-domain optical coherence tomography angiography and to determine whether OCTA can be used to monitor clinical activity of CNV.

In the observational, retrospective, consecutive case series, researchers looked at patients with a clinical diagnosis of neovascular AMD who underwent OCTA imaging. The patients were imaged between August and October 2014 at the New England Eye Center at Tufts Medical Center. The investigators used OCTA software to delineate the outer retina and subretinal pigment

epithelial space, if applicable.

The researchers defined clinical activity as the presence of one of the following: a new diagnosis of neovascular AMD with active leakage on FA and/or the presence of fluid on OCT, or a previous diagnosis of neovascular AMD; vision loss greater than or equal to one Snellen line; presence of new hemorrhage on fundus examination; recurrent intraretinal or subretinal fluid on structural OCT B-scans; persistent or increased intraretinal or subretinal fluid on structural OCT B-scans despite treatment; and presence of leakage on FA if performed on the same day as OCTA.

OCTA revealed CNV in 28 eyes (62.2 percent) while 17 eyes (37.8 percent) didn't demonstrate CNV vessels. The researchers classified the CNV as well-circumscribed in 12 eyes (42.8 percent) and poorly circumscribed in 16 eyes (57.2 percent). Twenty-two

eyes with CNV seen by OCTA were clinically active, whereas six eyes with visible CNV on OCTA were clinically inactive. Of the 17 eyes that didn't have evidence of CNV on OCTA imaging, 14 were clinically inactive and three were clinically active. Presence of CNV on OCTA correlated with clinical activity, and absence of CNV correlated with inactivity ($p < 0.0001$).

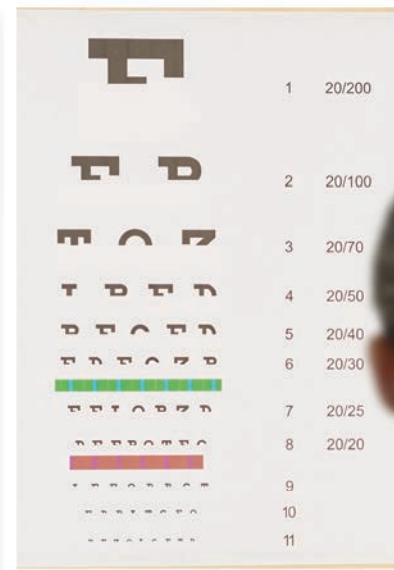
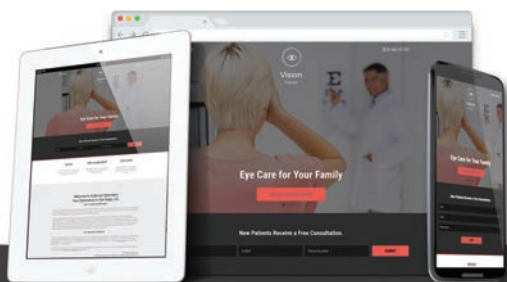OCTA is a noninvasive imaging technique that can be used to visualize blood flow comprising CNV. It detects CNV vessels in some, but not all eyes with neovascular age-related macular degeneration. Although the presence or absence of CNV vessels on OCTA was highly correlated with clinical activity of CNV, the morphologic appearance of CNV on OCTA didn't have significant correlation with clinical activity in this study.

Retina 2016;36:2265-2273
Liang M, De Carlo T, Baurnal C, Reichel E, et al.



Is there something **missing** in your online marketing?

We'll provide the focus your marketing needs. Contact us for a **free evaluation** and receive **40% off** initial setup!



877.716.0927



go.imatrix.com/ReviewOphthalmology

2017 OPTICAL DISPENSARY DESIGN TRENDS

PLUS 0% FINANCING FOR 3 YEARS*

*For well qualified applicants only.
Restrictions apply. Call for details.



1-877-274-9300



OPHTHALMOLOGY



Bassett Healthcare Network
Bassett Medical Center

Bassett Healthcare Network, a progressive health care network in central New York and major teaching affiliate of Columbia University is seeking a **General Ophthalmologist** to join a busy ophthalmology department based in the lovely village of Cooperstown. Glaucoma experience a plus!

Bassett Healthcare Network is an integrated health care system that provides care and services to people living in an eight county region covering 5,600 square miles in upstate New York. The organization includes six corporately affiliated hospitals, as well as skilled nursing facilities, community and school-based health centers, and health partners in related fields.

KEY BENEFITS OF THIS POSITION:

- Opportunities exist for both research and teaching if interested.
- Currently there are specialists in retina, cornea, pediatrics and oculoplastics.
- The support staff is well trained and experienced in both the clinic and operating room.
- Group employed model with competitive salary
- Comprehensive benefit package, including but not limited to medical, dental, CME, relocation assistance and paid malpractice insurance

Bassett Medical Center is located in Cooperstown, New York, a beautiful resort village on Otsego Lake. Home to the National Baseball Hall of Fame and Museum, the Glimmerglass Opera Company, and the Fenimore Art Museum, the area also boasts many cultural and four season recreational advantages including theater, music, museums, golf, sailing, hiking, and skiing.

EEO Employer

FOR CONFIDENTIAL CONSIDERATION, PLEASE CONTACT:
Debra Ferrari, Manager, Medical Staff Recruitment,
Bassett Medical Center, One Atwell Road, Cooperstown, NY, 13326
phone: 607-547-6982; fax: 607-547-3651; email: debra.ferrari@bassett.org
or visit our web-site at www.bassettopportunities.org

Practice For Sale



Practice Sales • Appraisals • Consulting
www.PracticeConsultants.com

PRACTICES FOR SALE
NATIONWIDE

Visit us on the Web or call us to learn
more about our company and the
practices we have available.
info@PracticeConsultants.com
800-576-6935

www.PracticeConsultants.com

REVIEW

of Ophthalmology

CONTACT US TODAY
FOR CLASSIFIED ADVERTISING
Toll free: 888-498-1460
E-mail: sales@kerhgroup.com



Photophobia and decreased vision bring a middle-aged woman to Wills' Oncology Service.

Jason Flamendorf, MD, and Carol L. Shields, MD

Presentation

A 55-year-old Caucasian female noted photophobia and blurred vision in both eyes. Her symptoms initially started three months prior to presentation with photophobia that spontaneously resolved. One month prior, she developed blurred vision associated with a head-to-toe rash, and ophthalmic evaluation revealed subretinal fluid and slight “retinal pigmentation” bilaterally. She was started on difluprednate drops four times a day, which reportedly decreased the subretinal fluid, and her visual acuity fluctuated. She presented to the Oncology Service of Wills Eye Hospital for a second opinion.

Medical History

Past medical history disclosed metastatic cutaneous malignant melanoma to the right hip from an unknown primary site one year prior to presentation. She underwent treatment with ipilimumab, pembrolizumab, and dabrafenib. Nine months following diagnosis, she was found to have brain metastases and underwent Gamma Knife radiotherapy. Additional medical history included bilateral mastectomy without need for chemotherapy, radiation or hormone therapy. The patient did not specify the reason for mastectomy, but there was a strong family history of breast cancer. In fact, there was

family history of multiple family members with cancer (lung carcinoma, prostate carcinoma, breast carcinoma, cutaneous melanoma). Her social history was unremarkable.

The patient's current medications included: dabrafenib; pembrolizumab; difluprednate drops; prednisone (patient reported that she was taking it at varying doses and frequencies); temazepam and alprazolam. Her symptoms started while she was off dabrafenib.

Examination

Ocular examination demonstrated an uncorrected visual acuity of 20/50 OD (pinhole: no improvement) and 20/60 OS (PH: 20/50). Pupils were equal, round and reactive to light without relative afferent pupillary defect. The patient declined applanation, but intraocular pressure by finger tension was normal. Confrontation visual fields and extraocular motility were full bilaterally. The anterior segment examination was only remarkable for early nuclear sclerosis bilaterally.

Dilated fundus examination revealed shallow subretinal fluid in the macular region of both eyes, with smaller pockets of fluid in the extramacular region as well (*See Fig. 1.*). Also present was bilateral subretinal vitelliform debris, which accumulated at the bottom of the subretinal fluid, producing a pseudohypopyon appearance.

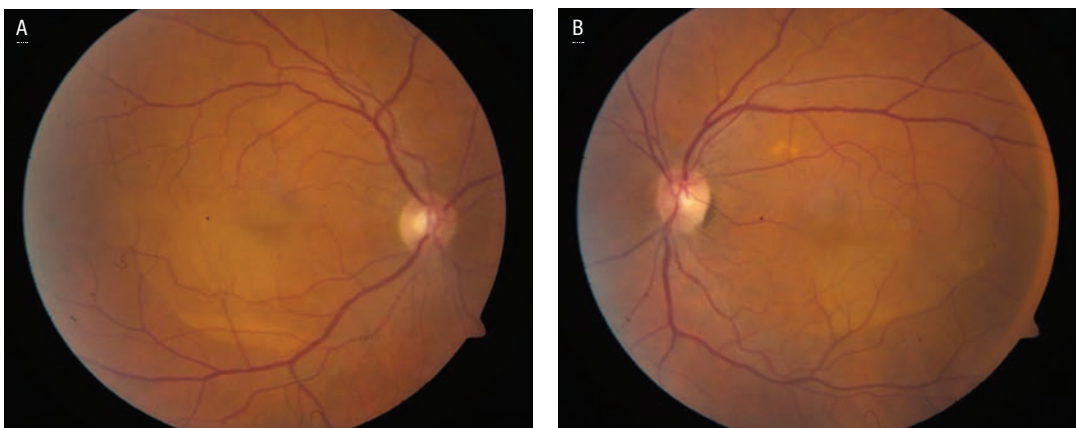


Figure 1. Fundus photos of the right (A) and left (B) eyes demonstrating dependent vitelliform lesions associated with multifocal pockets of subretinal fluid.

What is your differential diagnosis? What further workup would you pursue? Please turn to page 72

Diagnosis and Workup

Ancillary imaging was obtained including optical coherence tomography (Fig. 2), fundus autofluorescence imaging (Fig. 3A, B), and fluorescein angiography (Fig. 3C, D). OCT confirmed the presence of subretinal fluid and debris with a predominance in the fovea and inferior macula; both eyes also showed smaller areas of retinal detachment near the superior vascular arcades. The subretinal debris appeared as an irregular thickening of the photoreceptor layer, as well as a lining on the inner surface of the RPE. The inner retinal layers up to the ellipsoid zone revealed preserved architecture. The choroid appeared to be of normal thickness and vascularity. FAF showed “boat-shaped” areas of hyperautofluorescence corresponding to

Figure 3. Fundus autofluorescence imaging of the right (A) and left (B) eyes showing areas of hyperautofluorescence corresponding to the location of the vitelliform debris. Fluorescein angiography of the right (C) and left (D) eyes revealed trace hypofluorescence in corresponding areas.

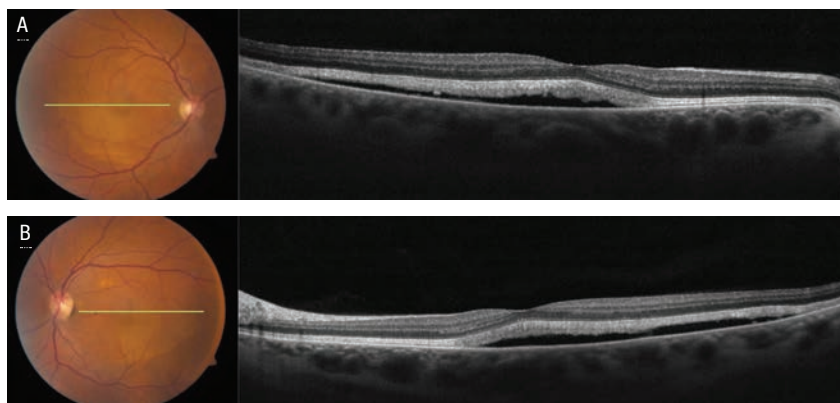
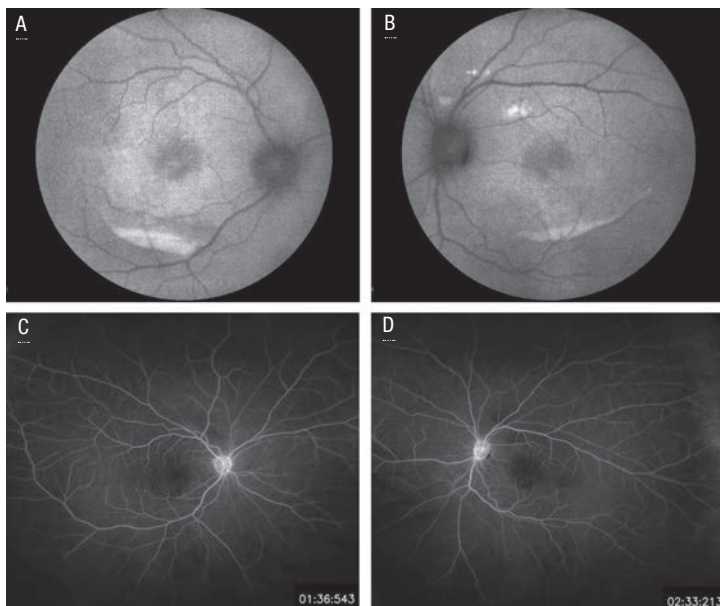


Figure 2. Foveal optical coherence tomography through the right (A) and left (B) eyes. The presence of subretinal fluid and debris is confirmed.

the vitelliform lesions observed on fundus examination, suggestive of lipofuscin accumulation. IVFA revealed trace hypofluorescence at the site of the lipofuscin debris.

The differential diagnosis for this patient with a history of metastatic cutaneous melanoma and new-onset subretinal fluid with vitelliform material included acute exudative paraneoplastic polymorphous vitelliform maculopathy (AEPPVM), choroidal metastasis, medication-associated retinopathy related to dabrafenib or pembrolizumab and adult-onset vitelliform macular dystrophy. Given the patient's melanoma history and clinical and imaging findings, a diagnosis of AEPPVM was considered. Options for management of this paraneoplastic retinopathy included observation for spontaneous resolution, plasmapheresis, intravenous immunoglobulin and corticosteroids. Per patient choice, observation was rendered.

Discussion

Paraneoplastic syndromes are a complex of signs and symptoms that result from damage to an organ or tissue remote from the site of a malignant neoplasm or related metastases.¹ The typical paraneoplastic retinopathies include cancer-associated retinopathy, melanoma-associated retinopathy, acute exudative paraneoplastic polymorphous vitelliform maculopathy, paraneoplastic optic neuropathy and others.² CAR is the most common of the intraocular paraneoplastic syndromes, and often manifests with symptoms

of rod and cone photoreceptor dysfunction. In cases of CAR, fundus examination may be normal; characteristic electroretinogram and visual field changes help establish the diagnosis. The most frequently associated malignancy is small-cell lung carcinoma, followed by gynecologic and breast carcinomas. MAR presents with rod-mediated symptoms and visual loss to a lesser degree than CAR. Similar to CAR, the fundus examination is frequently normal initially; additional diagnostic testing such as ERG, visual fields and serum anti-retinal

antibody testing support the diagnosis. MAR is most often associated with metastatic cutaneous melanoma but has also been reported with uveal melanoma.²

AEPPVM is a paraneoplastic retinopathy demonstrating bilateral multifocal pockets of subretinal fluid and subretinal vitelliform deposits documented on fundus examination and confirmed with hyperautofluorescence on FAF. This condition is usually found in patients with cutaneous melanoma or choroidal melanoma and can appear before or after detection of the primary malignancy and/or metastasis. Initially thought to be an unusual presentation of MAR, AEP-PVM seems to demonstrate a different spectrum of findings from MAR and is now classified as a separate entity.^{3,4} AEP-PVM has subsequently been identified in cases of metastatic lung and breast adenocarcinoma, as well as a single case of metastatic clear cell sarcoma of the toe.^{5,6,7} The vitelliform fundus lesions are a classic distinction of AEPPVM and are different from the features of MAR, which typically presents with a normal fundus picture but occasionally with optic nerve pallor, vascular attenuation and, rarely, retinal pigment epithelial changes.⁸

Researchers reviewed 23 cases of AEPPVM and found that the average age of onset was 59 years (range, 33 to 80). The underlying malignancies included cutaneous melanoma (44 percent), choroidal melanoma (30 percent), mucosal melanoma (4 percent), breast and lung carcinoma (9 percent) and clear cell sarcoma of the toe (4 percent); two cases had unknown primary tumors (9 percent). The onset of retinal features can occur remotely from the original diagnosis and treatment of the primary tumor, and these findings usually herald metastatic spread, often within several months.² Saad Al-Dahmash, MD, and co-workers published a series of five patients with AEPPVM managed at the Wills Eye Hospital Ocular Oncology Service.⁶ The features included blurred vision (n=5), nyctalopia (n=1) and photopsia (n=1). Visual acuity ranged from 20/30 to 20/100, with the majority of eyes seeing 20/50 or worse. Fundus, OCT and FAF findings were similar to those seen in our patient; fluorescein angiography and ERG findings were variable.

The pathogenesis of AEPPVM is poorly understood, but several studies have revealed serum autoantibodies against various retinal and retinal pigment epithelial antigens. These include antibodies against bipolar cells,³ rod outer segment protein,⁹ bestrophin 1,¹⁰ interphotoreceptor retinal-binding protein,¹¹ peroxiredoxin 3¹² and carbonic anhydrase II.^{6,13} While autoantibody testing by Western blot and immunohistochemistry is commercially available, the patient often incurs an out-of-pocket expense, and this may not be essential for establishing the diagnosis.

Treatment of AEPPVM includes observation for ill patients, reducing the underlying malignancy burden, or reducing the presumed autoimmune etiology. Our patient

chose observation, and we anticipate little change in the fundus appearance over time. Reduction of tumor burden has been found successful in a patient with AEPPVM discovered four months before a diagnosis of cutaneous metastatic melanoma.¹² Initially not responding to prednisone, the patient received temozolomide, an alkylating agent, for treatment of the underlying melanoma and regained 20/20 visual acuity OU following resolution of the subretinal fluid at one year follow-up. Reduction of autoimmune factors is accomplished with plasmapheresis and IVIg, although evidence for their use is sparse.⁸ Most important in the management of affected patients is a careful and thorough evaluation for systemic metastatic disease performed by an oncologist, even if the patient is believed to be in remission.

Other considerations in the differential diagnosis of our patient included choroidal metastases and medication-associated retinopathies, especially medications for metastatic melanoma. Subretinal vitelliform debris is not generally seen with choroidal metastases, and the OCT did not demonstrate any choroidal tumor.

Regarding medication, this patient was currently taking or had taken three medications used in the treatment of metastatic melanoma, including ipilimumab, pembrolizumab and dabrafenib, all of which have been associated with retinopathies. Ipilimumab and pembrolizumab are two monoclonal antibodies that upregulate the immune response to tumor cells by inhibiting the checkpoint sites of CTLA-4 and PD-1, respectively, on the T cell surface. In many instances, patients with AEPPVM are on medication for melanoma control, and it's challenging to sort out if the features are truly autoimmune or medication related. In the literature, there are two reports describing serous retinal detachment with and without vitelliform subretinal material suggested to be related to ipilimumab, and both patients demonstrated reduction in fundus features upon discontinuation of the medication.^{14,15} Regarding pembrolizumab, there is a single report of a patient with multiple bilateral peripheral chorioretinal scars with RPE atrophy and pigment clumping after starting pembrolizumab.¹⁶ Our patient didn't report taking ipilimumab at the time of presentation, and the lesions on fundus examination didn't resemble those reported with pembrolizumab. Finally, dabrafenib is a B-Raf inhibitor, which targets a protein in the MAP Kinase pathway, frequently dysregulated in neoplasms. While dabrafenib has not been implicated directly in retinopathy, the related family of MEK inhibitors has been associated with the presence of subretinal fluid and vitelliform lesions in some patients.¹⁷ Although our patient was taking dabrafenib when she presented to us, she reports that the symptoms started while she was off the medication, making it unlikely to be the underlying cause.

In summary, AEPPVM must be considered in the

For advertising opportunities contact:

Michelle Barrett..... (610) 492-1014 or mbarrett@jobson.com

James Henne..... (610) 492-1017 or jhenne@jobson.com

Michael Hoster (610) 492-1028 or mhoster@jobson.com

Abbott Medical Optics, Inc. (AMO) 15
Phone (800) 366-6554

Akorn Consumer Health 43
Phone (800) 579-8327
www.akornconsumerhealth.com

Alcon Laboratories 2, 3, 37, 53, 54
Phone (800) 451-3937
Fax (817) 551-4352

Bausch + Lomb 11, 12, 29, 30
Phone (800) 323-0000
Fax (813) 975-7762

Capital One Bank 9
www.CapitalOne.com/SmallBusiness

Glaukos 75
Phone (800) 452-8567
www.glaukos.com

Imprimis Pharmaceuticals, Inc. 7
Phone (858) 704-4040
Fax (858) 345-1745
www.imprimispharma.com

Lombart Instruments 39
Phone (800) 446-8092
Fax (757) 855-1232

Rhein Medical 5
Phone (800) 637-4346
Fax (727) 341-8123

S4OPTIK 25, 27
Phone (888) 224-6012

Shire Ophthalmics 76
www.shire.com

Sun Ophthalmics 20-21, 22
SunsOnTheRise.com

This advertiser index is published as a convenience and not as part of the advertising contract. Every care will be taken to index correctly. No allowance will be made for errors due to spelling, incorrect page number, or failure to insert.

differential diagnosis of patients with subretinal fluid demonstrating vitelliform lesions, whether or not a known history of malignancy exists. When present, close coordination of care with an oncologist must be undertaken to perform a thorough investigation for metastases. **REVIEW**

- Darnell RB, Posner JB. Paraneoplastic syndromes involving the nervous system. *NEJM* 2003;349:1543-1554.
- Rahimy E, Sarraf D. Paraneoplastic and non-paraneoplastic retinopathy and optic neuropathy: Evaluation and management. *Surv Ophthalmol* 2013;58:430-458.
- Borkowski LM, Grover S, Fishman GA, et al. Retinal findings in melanoma-associated retinopathy. *Am J Ophthalmol* 2001;132:273-275.
- Jampol LM, Kim HH, Bryar PJ, et al. Multiple serous retinal detachments and subretinal deposits as the presenting signs of metastatic melanoma. *Retina* 2004;24:320-322.
- Grunwald L, Kligman BE, Shields CL. Acute exudative polymorphous paraneoplastic vitelliform maculopathy in a patient with carcinoma, not melanoma. *Arch Ophthalmol* 2011;129:1104-1105.
- Al-Dahmash SA, Shields CL, Bianciotto CG, et al. Acute exudative paraneoplastic polymorphous vitelliform maculopathy in five cases. *Ophthalmic Surg Lasers Imaging* 2012;43:366-373.
- Suelves AM, Garcia-Delpech S, Gallego R, et al. Diagnostic and therapeutic challenges. *Retina* 2012;32:635-639.
- Keltner JL, Thirkill CE, Yip PT. Clinical and immunologic characteristics of melanoma-associated retinopathy syndrome: Eleven new cases and a review of 51 previously published cases. *J Neuro-Ophthalmol* 2001;21:173-187.
- Sotodeh M, Paridaens D, Keunen J, et al. Paraneoplastic vitelliform retinopathy associated with cutaneous or uveal melanoma and metastases. *Klin Monatsbl Augenheilkd* 2005;222:910-914.
- Eksandh L, Adamus G, Mosgrove L, et al. Autoantibodies against bestrophin in a patient with vitelliform paraneoplastic retinopathy and a metastatic choroidal malignant melanoma. *Arch Ophthalmol* 2008;126:432-435.
- Bianciotto C, Shields CL, Thirkill CE. Paraneoplastic retinopathy with multiple detachments of the neurosensory retina and autoantibodies against interphotoreceptor retinoid binding protein (IRBP) in cutaneous melanoma. *Br J Ophthalmol*. 2010; 94: 1684-1685.
- Korean L, He SX, Johnson MW et al. Anti-retinal pigment epithelial antibodies in acute exudative polymorphous vitelliform maculopathy. *Arch Ophthalmol* 2011;129:23-29.
- Aronow ME, Adamus G, Abu-Asab M, et al. Paraneoplastic vitelliform retinopathy: Clinicopathologic correlation and review of the literature. *Surv Ophthalmol* 2012;57:558-564.
- Crews J, Agarwal A, Jack L, et al. Ipilimumab-associated retinopathy. *Ophthalmic Surg Lasers Imaging Retina* 2015;46:658-660.
- Mantopoulos D, Kendra KL, Letson A, et al. Bilateral choroidopathy and serous retinal detachments during ipilimumab treatment for cutaneous melanoma. *JAMA Ophthalmol* 2015;133:965-967.
- Roberts P, Fishman GA, Joshi K et al. Chorioretinal lesions in a case of melanoma-associated retinopathy treated with pembrolizumab. *JAMA Ophthalmol* 2016;134:1184-1188.
- van Dijk EHC, van Herpen CML, Marinkovic M, et al. Serous retinopathy associated with mitogen-activated protein kinase inhibition (Binimetinib) for metastatic cutaneous and uveal melanoma. *Ophthalmology* 2015;122:1907-1916.

START
HERE

Choose iStent®—First and foremost.

Right from the beginning, iStent is designed to restore and maintain conventional physiological outflow in the trabecular meshwork, and deliver a favorable benefit-to-risk ratio. Studied extensively around the world, iStent has been implanted in hundreds of thousands of eyes, and is backed by years of documented efficacy and safety data. For cataract patients with open-angle glaucoma, start with the MIGS leader—and finish with leading performance.



The complete procedure.

800.GLAUKOS (452.8567) Glaukos.com

INDICATION FOR USE. The iStent® Trabecular Micro-Bypass Stent (Models GTS100R and GTS100L) is indicated for use in conjunction with cataract surgery for the reduction of intraocular pressure (IOP) in adult patients with mild to moderate open-angle glaucoma currently treated with ocular hypotensive medication. **CONTRAINDICATIONS.** The iStent® is contraindicated in eyes with primary or secondary angle closure glaucoma, including neovascular glaucoma, as well as in patients with retrobulbar tumor, thyroid eye disease, Sturge-Weber Syndrome or any other type of condition that may cause elevated episcleral venous pressure. **WARNINGS.** Gonioscopy should be performed prior to surgery to exclude PAS, rubeosis, and other angle abnormalities or conditions that would prohibit adequate visualization of the angle that could lead to improper placement of the stent and pose a hazard. The iStent® is MR-Conditional meaning that the device is safe for use in a specified MR environment under specified conditions, please see label for details. **PRECAUTIONS.** The surgeon should monitor the patient postoperatively for proper maintenance of intraocular pressure. The safety and effectiveness of the iStent® has not been established as an alternative to the primary treatment of glaucoma with medications, in children, in eyes with significant prior trauma, chronic inflammation, or an abnormal anterior segment, in pseudophakic patients with glaucoma, in patients with pseudoexfoliative glaucoma, pigmentary, and uveitic glaucoma, in patients with unmedicated IOP less than 22 mmHg or greater than 36 mmHg after "washout" of medications, or in patients with prior glaucoma surgery of any type including argon laser trabeculoplasty, for implantation of more than a single stent, after complications during cataract surgery, and when implantation has been without concomitant cataract surgery with IOL implantation for visually significant cataract. **ADVERSE EVENTS.** The most common post-operative adverse events reported in the randomized pivotal trial included early post-operative corneal edema (8%), BCVA loss of ≥ 1 line at or after the 3 month visit (7%), posterior capsular opacification (6%), stent obstruction (4%) early post-operative anterior chamber cells (3%), and early post-operative corneal abrasion (3%). Please refer to Directions for Use for additional adverse event information. **CAUTION:** Federal law restricts this device to sale by, or on the order of, a physician. Please reference the Directions for Use labeling for a complete list of contraindications, warnings, precautions, and adverse events.



 eyelove™
innovation

Eyelove is a celebration of the things we love to do with our eyes. It's also a commitment from Shire to help educate your patients about Dry Eye Disease.

Start with some eyelove. [Join us at sharesomeeyelove.com](http://sharesomeeyelove.com)

it's time for some eyelove



