

CODING FOR UNIQUE MEDICARE CASES P. 21 • SUMMARY OF THE LATEST LITERATURE P. 40  
PREMIUM LENSES IN GLAUCOMA P. 42 • THE PROS AND CONS OF BIOMARKERS P. 46  
HOW TO DECIPHER TRIAL RESULTS P. 52 • WILLS EYE RESIDENT CASE P. 63

# REVIEW<sup>®</sup> of Ophthalmology

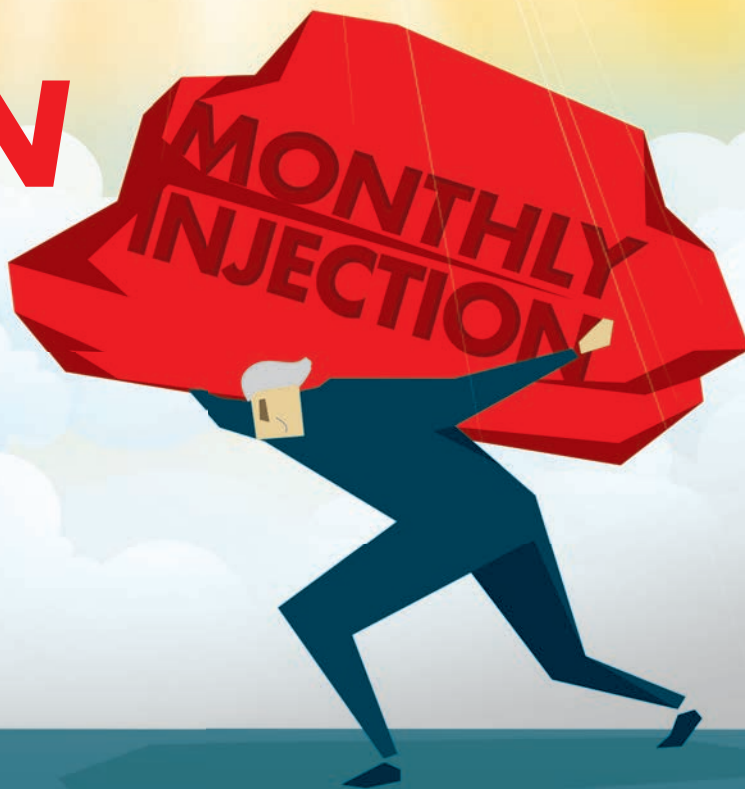August 2017

reviewofophthalmology.com

ANNUAL RETINA ISSUE

## Easing the **BURDEN** of Wet AMD Treatment

HOW TO REDUCE THE NUMBER OF  
INJECTIONS WITHOUT HARMING THE  
PATIENT Page 24



### ALSO INSIDE:

- ▶ The Use and Interpretation of OCT Angiography P. 30
- ▶ An Update on Uveitis Treatment P. 35



| Without CONTINUOUS MICRODOSING™ Delivery |



#### **INDICATION**

ILUVIEN® (fluocinolone acetonide intravitreal implant) 0.19 mg is indicated for the treatment of diabetic macular edema (DME) in patients who have been previously treated with a course of corticosteroids and did not have a clinically significant rise in intraocular pressure.

#### **Important Safety Information**

##### **CONTRAINDICATIONS**

- ILUVIEN is contraindicated in patients with active or suspected ocular or periocular infections including most viral diseases of the cornea and conjunctiva including active epithelial herpes simplex keratitis (dendritic keratitis), vaccinia, varicella, mycobacterial infections and fungal diseases.
- ILUVIEN is contraindicated in patients with glaucoma who have cup to disc ratios of greater than 0.8.
- ILUVIEN is contraindicated in patients with known hypersensitivity to any components of this product.


##### **WARNINGS AND PRECAUTIONS**

- Intravitreal injections, including those with ILUVIEN, have been associated with endophthalmitis, eye inflammation, increased intraocular pressure, and retinal detachments. Patients should be monitored following the intravitreal injection.
- Use of corticosteroids including ILUVIEN may produce posterior subcapsular cataracts, increased intraocular pressure and glaucoma. Use of corticosteroids may enhance the establishment of secondary ocular infections due to bacteria, fungi, or viruses. Corticosteroids are not recommended to be used in patients with a history of ocular herpes simplex because of the potential for reactivation of the viral infection.
- Patients in whom the posterior capsule of the lens is absent or has a tear are at risk of implant migration into the anterior chamber.

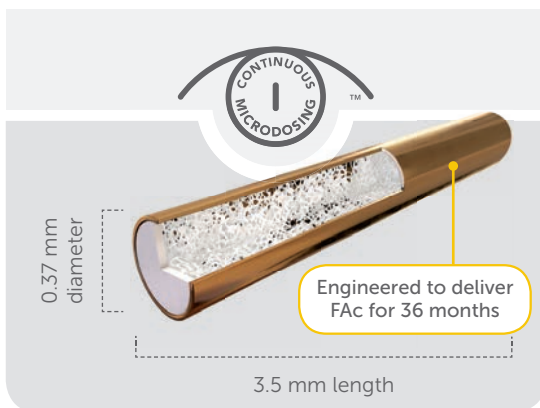##### **ADVERSE REACTIONS**

- In controlled studies, the most common adverse reactions reported were cataract development (ILUVIEN 82%; sham 50%) and intraocular pressure elevation of  $\geq 10$  mm Hg (ILUVIEN 34%; sham 10%).

| With CONTINUOUS MICRODOSING™ Delivery |



## ILUVIEN with CONTINUOUS MICRODOSING™ Delivery enables physicians to continually and consistently treat DME every day<sup>1,2</sup>



**ILUVIEN** is a CONTINUOUS MICRODOSING™ Delivery System specifically engineered for the treatment of DME in patients who have been previously treated with a course of corticosteroids and did not have a clinically significant rise in intraocular pressure.

In pivotal studies, ILUVIEN demonstrated efficacy in visual acuity through 24 months (primary endpoint), which was sustained for up to 36 months.<sup>1,2</sup>

Adverse reactions in the ILUVIEN Phase 3 clinical trials were consistent with other corticosteroid treatments.<sup>1</sup>

**Learn more at [ILUVIEN.com](http://ILUVIEN.com).**

**References:** 1. Iluvien [package insert]. Alpharetta, GA: Alimera Sciences, Inc. 2. Campochiaro PA, Brown DM, Pearson A, et al; FAME Study Group. Sustained delivery fluocinolone acetonide vitreous inserts provide benefit for at least 3 years in patients with diabetic macular edema. *Ophthalmology*. 2012;119(10):2125-2132.

Please see Brief Summary of full Prescribing Information on the following page.

CONTINUOUS MICRODOSING is a trademark of Alimera Sciences, Inc.  
ILUVIEN is a registered trademark of Alimera Sciences, Inc.  
Copyright © 2017 Alimera Sciences, Inc. All rights reserved.  
1-844-445-8843. Printed in USA. US-ILV-MMM-0480. 07/2017

**ILUVIEN**<sup>®</sup>  
(fluocinolone acetonide  
intraocular implant) 0.19mg

## BRIEF SUMMARY OF FULL PRESCRIBING INFORMATION

ILUVIEN® (fluocinolone acetonide intravitreal implant) 0.19 mg  
For Intravitreal Injection

### INDICATIONS AND USAGE

ILUVIEN® (fluocinolone acetonide intravitreal implant) 0.19 mg is indicated for the treatment of diabetic macular edema in patients who have been previously treated with a course of corticosteroids and did not have a clinically significant rise in intraocular pressure.

### CONTRAINDICATIONS

**Ocular or Periocular Infections:** ILUVIEN is contraindicated in patients with active or suspected ocular or periocular infections including most viral disease of the cornea and conjunctiva including active epithelial herpes simplex keratitis (dendritic keratitis), vaccinia, varicella, mycobacterial infections and fungal diseases.

**Glaucoma:** ILUVIEN is contraindicated in patients with glaucoma, who have cup to disc ratios of greater than 0.8.

**Hypersensitivity:** ILUVIEN is contraindicated in patients with known hypersensitivity to any components of this product.

### WARNINGS AND PRECAUTIONS

**Intravitreal Injection-related Effects:** Intravitreal injections, including those with ILUVIEN, have been associated with endophthalmitis, eye inflammation, increased intraocular pressure, and retinal detachments. Patients should be monitored following the intravitreal injection.

**Steroid-related Effects:** Use of corticosteroids including ILUVIEN may produce posterior subcapsular cataracts, increased intraocular pressure and glaucoma. Use of corticosteroids may enhance the establishment of secondary ocular infections due to bacteria, fungi, or viruses.

Corticosteroids are not recommended to be used in patients with a history of ocular herpes simplex because of the potential for reactivation of the viral infection.

**Risk of Implant Migration:** Patients in whom the posterior capsule of the lens is absent or has a tear are at risk of implant migration into the anterior chamber.

### ADVERSE REACTIONS

**Clinical Studies Experience:** Because clinical trials are conducted under widely varying conditions, adverse reaction rates observed in the clinical trials of a drug cannot be directly compared to rates in the clinical trials of another drug and may not reflect the rates observed in practice.

Adverse reactions associated with ophthalmic steroids including ILUVIEN include cataract formation and subsequent cataract surgery, elevated intraocular pressure, which may be associated with optic nerve damage, visual acuity and field defects, secondary ocular infection from pathogens including herpes simplex, and perforation of the globe where there is thinning of the cornea or sclera.

ILUVIEN was studied in two multicenter, randomized, sham-controlled, masked trials in which patients with diabetic macular edema were treated with either ILUVIEN (n=375) or sham (n=185). Table 1 summarizes safety data available when the last subject completed the last 36-month follow up visit for the two primary ILUVIEN trials. In these trials, subjects were eligible for retreatment no earlier than 12 months after study entry. Over the three-year follow up period, approximately 75% of the ILUVIEN treated subjects received only one ILUVIEN implant.

Table 1: Ocular Adverse Reactions Reported by ≥1% of Patients and Non-ocular Adverse Reactions Reported by ≥5% of Patients

Adverse Reactions	ILUVIEN (N=375) n (%)	Sham (N=185) n (%)
<b>Ocular</b>		
Cataract <sup>1</sup>	192/235 <sup>2</sup> (82%)	61/121 <sup>2</sup> (50%)
Myodesopsia	80 (21%)	17 (9%)
Eye pain	57 (15%)	25 (14%)
Conjunctival haemorrhage	50 (13%)	21 (11%)
Posterior capsule opacification	35 (9%)	6 (3%)
Eye irritation	30 (8%)	11 (6%)
Vitreous detachment	26 (7%)	12 (7%)
Conjunctivitis	14 (4%)	5 (3%)
Corneal oedema	13 (4%)	3 (2%)
Foreign body sensation in eyes	12 (3%)	4 (2%)
Eye pruritus	10 (3%)	3 (2%)
Ocular hyperaemia	10 (3%)	3 (2%)
Optic atrophy	9 (2%)	2 (1%)
Ocular discomfort	8 (2%)	1 (1%)
Photophobia	7 (2%)	2 (1%)
Retinal exudates	7 (2%)	0 (0%)
Anterior chamber cell	6 (2%)	1 (1%)
Eye discharge	6 (2%)	1 (1%)

Table 1 (continued)

Adverse Reactions	ILUVIEN (N=375) n (%)	Sham (N=185) n (%)
<b>Non-ocular</b>		
Anemia	40 (11%)	10 (5%)
Headache	33 (9%)	11 (6%)
Renal failure	32 (9%)	10 (5%)
Pneumonia	28 (7%)	8 (4%)

<sup>1</sup> Includes cataract, cataract nuclear, cataract subcapsular, cataract cortical and cataract diabetic in patients who were phakic at baseline. Among these patients, 80% of ILUVIEN subjects vs. 27% of sham-controlled subjects underwent cataract surgery.

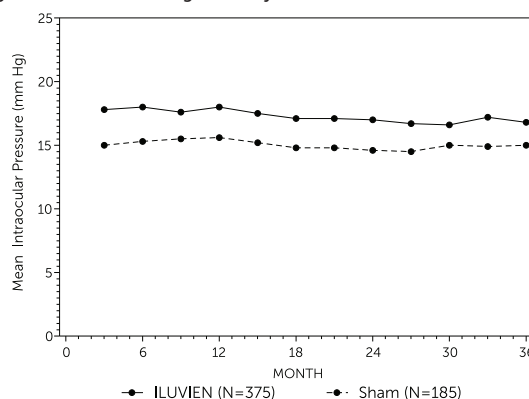
<sup>2</sup> 235 of the 375 ILUVIEN subjects were phakic at baseline; 121 of 185 sham-controlled subjects were phakic at baseline.

### Increased Intraocular Pressure

Table 2: Summary of Elevated IOP-Related Adverse Reactions

Event	ILUVIEN (N=375) n (%)	Sham (N=185) n (%)
<b>Non-ocular</b>		
IOP elevation ≥ 10 mm Hg from baseline	127 (34%)	18 (10%)
IOP elevation ≥ 30 mm Hg	75 (20%)	8 (4%)
Any IOP-lowering medication	144 (38%)	26 (14%)
Any surgical intervention for elevated intraocular pressure	18 (5%)	1 (1%)

Figure 1: Mean IOP during the study



### Cataracts and Cataract Surgery

At baseline, 235 of the 375 ILUVIEN subjects were phakic; 121 of 185 sham-controlled subjects were phakic. The incidence of cataract development in patients who had a phakic study eye was higher in the ILUVIEN group (82%) compared with sham (50%). The median time of cataract being reported as an adverse event was approximately 12 months in the ILUVIEN group and 19 months in the sham group. Among these patients, 80% of ILUVIEN subjects vs. 27% of sham-controlled subjects underwent cataract surgery, generally within the first 18 months (Median Month 15 for both ILUVIEN group and for sham) of the studies.

**Postmarketing Experience:** The following reactions have been identified during post-marketing use of ILUVIEN in clinical practice. Because they are reported voluntarily, estimates of frequency cannot be made. The reactions, which have been chosen for inclusion due to either their seriousness, frequency of reporting, possible causal connection to ILUVIEN, or a combination of these factors, include reports of drug administration error and reports of the drug being ineffective.

### USE IN SPECIFIC POPULATIONS

**Pregnancy:** Pregnancy Category C.

There are no adequate and well-controlled studies of ILUVIEN in pregnant women. Animal reproduction studies have not been conducted with fluocinolone acetonide. Corticosteroids have been shown to be teratogenic in laboratory animals when administered systemically at relatively low dosage levels. ILUVIEN should be used during pregnancy only if the potential benefit justifies the potential risk to the fetus.

**Nursing Mothers:** Systemically administered corticosteroids are present in human milk and could suppress growth and interfere with endogenous corticosteroid production. The systemic concentration of fluocinolone acetonide following intravitreal treatment with ILUVIEN is low. It is not known whether intravitreal treatment with ILUVIEN could result in sufficient systemic absorption to produce detectable quantities in human milk. Exercise caution when ILUVIEN is administered to a nursing woman.

**Pediatric Use:** Safety and effectiveness of ILUVIEN in pediatric patients have not been established.

**Geriatric Use:** No overall differences in safety or effectiveness have been observed between elderly and younger patients.

# Overprescription of Pinkeye Antibiotics Poses a Challenge

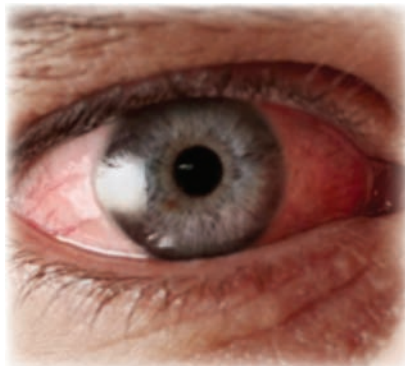
**Conjunctivitis is a presenting** complaint routinely seen by eye-care practitioners and other health-care providers. A recent study<sup>1</sup> shows that the likelihood that patients will fill a prescription for antibiotics after an acute conjunctivitis diagnosis has more to do with the type of provider they see and their level of education and affluence than medical factors that would make an antibiotic the best choice.

The researchers retrospectively reviewed data from a large national managed-care network, specifically 340,372 enrollees who received an initial diagnosis of acute conjunctivitis from 2001 through 2014, seeking those who had filled one or more antibiotic prescriptions within 14 days of diagnosis. They also analyzed those patients' demographic characteristics and medical information.

Nakul Shekhawat, MD, MPH, of the University of Michigan's Kellogg Eye Center, and colleagues found that of those 340,372 patients newly diagnosed with pinkeye during the period studied, 198,462 (58 percent) filled at least one topical antibiotic prescription within two weeks of their diagnosis. Twenty percent of that cohort (38,774) filled scripts for combined antibiotic-corticosteroid drops, which may worsen and prolong the course of viral conjunctivitis. Further analysis revealed that the more affluent and educated the conjunctivitis patient was, the likelier it was that they'd fill a prescription. There was no relationship between filling antibiotic scripts and medical risk factors such as contact lens wear,

HIV infection or AIDS.

Compared with patients first diagnosed by ophthalmologists, patients initially diagnosed with pinkeye by the following types of providers displayed higher odds ratios with 95-percent confidence intervals of filling antibiotic scripts: optometrist (OR, 1.26; 95% CI, 1.21–1.31); urgent-care physician (OR, 3.29; 95% CI, 3.17–3.41); inter-



nist (OR, 2.79; 95% CI, 2.69–2.90); pediatrician (OR, 2.27; 95% CI, 2.13–2.43); or family practitioner (OR, 2.46; 95% CI, 2.37–2.55).

Inability to quickly determine the etiology of a patient's conjunctivitis means that many patients with viral infections leave their providers' offices with just-in-case antibiotic scripts. Dr. Shekhawat says rapid-antigen testing may help cut down on the number of unnecessary antibiotic prescriptions without compromising patient safety. Citing a 2008 study<sup>2</sup> that posited savings in excess of \$400 million to insurers if rapid-antigen adenovirus testing was used to pinpoint self-limited con-

junctivitis, Dr. Shekhawat notes, "It is in insurers' financial interest to reimburse clinicians for use of this test just as they already do for strep throat, another common infection. Using point-of-care testing is likely also worthwhile from a clinical standpoint, as it reduces the likelihood of unnecessary antibiotic use and troubling downstream effects such as ocular surface toxicity and antibiotic resistance," he says.

A lack of patient education may lead patients to believe that they need antibiotics to treat every case of conjunctivitis. Another possible culprit in pediatric patients is school and day-care policies excluding children with untreated acute conjunctivitis.

Dr. Shekhawat notes that spreading the word to providers outside the eye care community is complicated by the fact that other providers see the majority of acute conjunctivitis cases (83 percent in the study). "Getting the message out is difficult because non-eye care providers are unlikely to be exposed to communications from the American Academy of Ophthalmology or similar organizations, and are far more likely to get the message if it comes from their own medical organizations," he says. "The AAO has taken part in the national Choosing Wisely campaign and discouraged indiscriminate use of antibiotics for acute conjunctivitis, but I doubt that message has permeated beyond the eye-care community. General medical societies such as the American Academy of Pediatrics should communicate with ophthalmologists to produce and dis-

## Establishing the Target Product Profile

In previous columns, we've explored the importance of an early consideration of the Target Product Profile, or the key areas of the ultimate label/package insert, such as the indication, dosage and administration, and safety. This month, using a retina drug development program as an example, we'll examine a few kinds of specific inputs for the TPP that bear consideration.

It's critical to address the potential impact TPP decisions will have on the main elements of the drug development program. The TPP may also have implications for product differentiation, which will impact future managed-care reimbursement. While certainly not an exhaustive discussion, we'll highlight some key issues encountered by our clients, particularly early-stage, new entrepreneurs.

One consideration that inevitably arises when contemplating a strategy for the development of a product with the potential to treat various types of neurodegenerative disease is whether or not to pursue an orphan-drug indication. The focus of such an indication could potentially be an inherited retinal disease like retinitis pigmentosa, Stargardt's, Leber congenital amaurosis, etc., or another, more prevalent ocular disease such as dry age-related macular degeneration or glaucoma-related neurodegeneration. While the focus of this column isn't to advise you on which indication you should pursue, we will target a few key considerations, such as:

- pathophysiology;
- patient subgroups;
- recruitment potential;
- clinical endpoints; and
- pricing.

All of these factor into the creation of the model for the financing pitch and will influence your overall likelihood of success.

We've seen situations in which the new entrepreneur creates an initial business plan based on the assumption that a trial in an orphan indication will have a "lower bar" to clear, and therefore will be quicker and have a good chance of requiring only a single trial. In most cases, however, for an orphan indication, the FDA still requires two well-controlled trials with robust endpoints shown to be correlated with visual function.

Match the program to the indication with the highest chance for success based on the therapy's mechanism, balanced with a financial outcome that investors will embrace as the best return on their investment. You may determine that the best route will be to pursue an orphan indication, and take advantage of reduced filing fees, added exclusivity and tax credits, with a pricing model consistent with the orphan drug's lower number of patients.

A key consideration when evaluating a potential orphan indication is the recruitment



of the appropriate patient population. With multiple clinical trials targeting inherited retinal diseases (many of which involve gene therapy), you need to be able to realistically assess the viability of a clinical trial, the possible need for treatment-naïve patients for the protocol and the speed of patient enrollment. Multiple clinical programs may be competing for the same limited patient base depending on the timing of specific trials. Another aspect to consider is how the landscape for the chosen orphan may look in the future should other products launch before yours; this will have an impact on the reimbursement for the use of your drug and your investors' returns.

For example, since diseases like dry AMD and Stargardt's progress slowly, generally you may be looking at an 18 to 24 month follow-up. Filling a larger study in Stargardt's may be challenging and will need to be focused on the key clinical centers (generally large institutions and universities) versus a standard dry AMD geographic atrophy trial that can tap into a broader base of investigative sites. Also, note that the recruitment process and patient demographics will impact the approach to a specific

project. For instance, a Stargardt's study for an orphan designation would involve enrollment of pediatric patients, while a dry AMD/GA study would involve the recruitment of elderly individuals.

A three-line change in ETDRS visual acuity has long remained a regulatory standard for assessing efficacy; however, visual acuity assessment is problematic in the context of severe vision impairment. With many inherited retinal diseases, vision is so poor that patients can't read an eye chart, and as a result, alternative functional endpoints are required. Recognizing this, the NEI/FDA Endpoints Workshop (November 2016) acknowledged the importance of using

visual mobility courses as clinical trial endpoints in retinal diseases associated with severe vision loss which were less amenable to standard three-line changes in visual acuity. Our group at Ora has developed standardized multicenter mobility courses that target specific retinal diseases and various levels of central acuity and peripheral vision (i.e., visual field). The diseases targeted include inherited retinal conditions like RP, Stargardt's and LCA, as well as—potentially—dry AMD. Ultimately, these courses are designed to facilitate the development process and bring new pharmaceutical products and devices to patients with these debilitating conditions. Other visual function endpoints, such as dark adaptation, may also be important in understanding functional improvements from therapy in earlier stages of dry AMD.

One of the holy grails of drug research is certainly dry AMD, particularly the prevention of progression in its earlier stages. For a given treatment program, you must be able to choose the ideal stage of disease and balance that with the length of the trial and the ability to detect a change in a relevant endpoint. Geographic atrophy is a popular regulatory endpoint because there's currently a clear definition for an endpoint based on the expansion of GA area versus other potential study designs for earlier disease. However GA's use is potentially complicated by the fact that researchers will be studying patients who may be too late in the disease process for an intervention to have a significant positive impact. In

*(Continued on page 8)*

seminate consensus statements regarding the management of conjunctivitis.”

Regarding the role of school and daycare policies in the overprescribing, Dr. Shekhawat says that state health departments vary in their guidance on kids with acute conjunctivitis. “Some states’ policies are far more nuanced and evidence-based than others. States with overly restrictive policies should formulate clear, evidence-based guidelines that discourage indiscriminate antibiotic use,” he says.

“There are no quick solutions to the antibiotic overuse identified in our study,” Dr. Shekhawat adds. “However, the policy approaches discussed above are likely to have the greatest impact, since they address some of the root causes of the problem.”

1. Shekhawat NS, Shtein RM, Blachley TS, Stein JD. Antibiotic prescription fills for acute conjunctivitis among enrollees in a large United States managed care network. *Ophthalmology*. 2017; doi: 10.1016/j.ophtha.2017.04.034. [Epub ahead of print]  
 2. Udeh B, Schneider J, Ohnsfeldt R. Cost effectiveness of a point-of-care test for adenoviral conjunctivitis. *Am J Med Sci*. 2008;336:3:254-264.


## Dextenza FDA Update

**In a Complete Response** Letter to Ocular Therapeutix regarding its resubmission of a New Drug Application for Dextenza (dexamethasone insert) 0.4 mg for the treatment of ocular pain following ophthalmic surgery, the U.S. Food and Drug Administration stated it could not approve the NDA in its present form. The CRL referred to deficiencies in manufacturing processes and analytical testing related to the manufacture of drug products identified during a pre-NDA approval inspection of the Ocular Therapeutix manufacturing facility in May 2017. FDA raised no safety or efficacy issues with the drug. **REVIEW**

Elevating The Quality Of Care In Ophthalmology



## Rhein SMILE Forceps



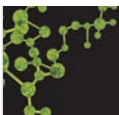
- **Designed To Easily Grasp The Inner Stromal Disk For Removal.**
- **Special Rocklinized Inner Jaws Provide Exceptional Grip.**
- **Ergonomic Handle Provides Comfortable Access To The Incision Site.**
- **Unique Low Profile Blades Minimize Incision Gape.**
- **Reusable, Autoclaveable, Made Of Titanium In The USA, Available For A 30-Day Surgical Evaluation Without Obligation, And Guaranteed For Life.**

Contact Rhein Medical At 727-209-2244 For More Information



3360 Scherer Drive, Suite B, St. Petersburg, FL 33716  
 800-637-4346 • Tel: 727-209-2244 • Fax: 727-341-8123  
 Email: [Info@RheinMedical.com](mailto:Info@RheinMedical.com) • Website: [www.RheinMedical.com](http://www.RheinMedical.com)

Libian Syble, Michelangelo, Sistine Chapel



(Continued from page 6)

contrast, the endpoints for early-stage AMD may require a longer trial with a less-well-defined regulatory endpoint. You also need to consider your ability to select the precise subgroup of patients expected to progress the quickest, and sensitive visual function endpoints beyond visual acuity.

Early interaction with the FDA is encouraged so that the ultimate plan to win approval can be outlined for your investors. For the first-time entrepreneur, it's important to remember that FDA "acceptance" of a Phase II trial isn't equivalent to the FDA accepting a plan and endpoints that may ultimately support submission and review of the NDA/Biologic License Application. Ensure that the product positioning is precise in your investor presentations.

We've seen cases in which a company will pursue both the mainstream and the orphan indications in parallel, with a plan to focus on a single lead for subsequent studies. Certainly, this requires two pricing and commercial models. Particularly in the situation in which a product is repurposed from an existing marketed drug, the threat of competitors simply compounding it needs to be considered versus your production of a high-priced orphan drug.

Another example is anti-neovascular and/or anti-inflammatory agents. From a mechanistic perspective, these drugs can be applied to various retinal diseases, such as wet AMD, diabetic macular edema, diabetic retinopathy, macular edema associated with CRVO/BRVO and, if it's an anti-inflammatory drug, perhaps posterior uveitis. Wet AMD may be the entrepreneur's first choice, based on the large markets of leading products like aflibercept, ranibizumab and bevacizumab. On the flip side, these other anti-VEGF drugs have generated such great outcomes it may appear that the bar has been set too high.

For example, looking at the current anti-VEGF market and the clinical hurdles to overcome, it may make more sense to lead with diabetic eye disease. According to the American Diabetes Association, about 29.1 million Americans (9.3 percent of the total population) have either type 1 or type 2 diabetes, with an estimated growth of about 1.4 million every year. Of this population, it was reported that about 28.5 percent had cases of diabetic retinopathy (4.2 million) and about 3.8 percent were diagnosed with DME (770,000).

For any of the above conditions, another key consideration for refining the TPP and pitch

to investors is determining whether the treatment is intended to be primary or adjunctive. The bar is high for being approved as a primary therapy, and would require clinical trials showing non-inferiority or superiority to the standard of care represented by the approved agents ranibizumab and aflibercept, with the margin of noninferiority to ranibizumab being a three- to four-letter difference at nine months for wet AMD.

Alternatively, one can explore adjunctive therapy, combining the novel approach with the standard-of-care and comparing that combination to the results of the standard-of-care alone (dosed according to its label). Since this decision relates to the design (and ultimately time and cost) of the Phase I and Phase II trials to get to a point where the program sees an increase in value to investors and partners, you have to ask: Should the focus be on newly diagnosed patients naïve to treatment, or patients who are sub-responders to existing therapy? Keep in mind complete non-responders are hard to come by, so the key will be defining the sub-responder in the inclusion/exclusion criteria, and understanding how that choice will influence recruitment. Current anti-VEGFs achieve a three-line gain in visual acuity in approximately one-third of patients. There's still room for an adjunctive therapy to possibly provide greater efficacy, or a primary therapy that uses something other than an intravitreal injection as its route of administration.

The goal is to obtain proof-of-concept, and have that data support a plan for the intended dosing and use of the drug to drive further investment. A Phase I study in retina is generally done in patients with the target disease, and can also incorporate some efficacy measures in the form of either visual function (e.g., ETDRS visual acuity) or ocular structure (e.g., optical coherence tomography) endpoints. With a focus on early OCT findings, you can sometimes obtain an earlier proof-of-concept than you can by using a visual acuity endpoint. The drug's mechanism of action also plays a key role in establishing expectations for a particular approach to reduce the edema seen with OCT, and/or drive VA changes. While either visual function or OCT improvement is an acceptable approach to establish proof-of-concept, properly setting expectations with investors and partners will help drive decision-making going into any subsequent Phase II trial. Initial trials (adjunctive or primary) may involve patients with poor VA potential, but can still be impor-

tant if they demonstrate efficacy using OCT. Such results will still carry significant weight with physicians and investors as a reason to believe.

It's important to remember to balance the impact of study design with the toxicology requirements for opening the IND to conduct the trials. If dosing is monthly and the intended follow-up is six months, for example, one needs to plan for a chronic ocular toxicology study for the IND, as opposed to a situation in which the trial is first focusing on acute dose and follow-up. Ultimately, what is the true differentiation in the TPP: dosing frequency; efficacy or both? Going after a sustained-release delivery route will impact the length of the required ocular toxicology, so if sustained release is driving the TPP, then extra time and cost will be needed for the IND. Again, it's not a matter of a right or a wrong approach, but rather ensuring that the entrepreneur considers the way in which these factors impact feasibility, time, cost, likelihood of success and, ultimately, create optimal value.

Recognize that the FDA is willing to meet with companies early in the process to discuss requirements. For the company that hasn't visited the ophthalmic division at the FDA, it may be refreshing to learn that the agency is open to discussing multiple potential indications for a single product at the pre-IND meeting, and such a meeting can be critical for gathering the input necessary for selecting the lead indication for use in your business plan.

For the first-time physician entrepreneur, developing the right financing plan relies on a well-thought-out TPP. To this end, this discussion isn't an exhaustive review, but instead highlights a few areas for consideration, and shows that there are multiple approaches to TPP design that promote value for investors and partners.

*Mr. Chapin is senior vice president of corporate development at Ora, and Mr. Diaz is an associate in corporate development. Ora provides a comprehensive range of development, clinical-regulatory and consulting services for developers, investors and buyers; preclinical and turnkey clinical trial services; assistance with regulatory submissions; and the integration of business development and fundraising support in ophthalmology. The authors welcome your comments or questions regarding product development. Please send correspondence to [mchapin@oraclinical.com](mailto:mchapin@oraclinical.com) or visit [www.oraclinical.com](http://www.oraclinical.com).*





## We foresee a bright future for your practice

**AngioVueHD OCTA is a quick, non-invasive test that will change the way you see your retina and glaucoma patients.**

- **Peace of mind:** Visualize retinal and optic disc vessels to uncover changes that could indicate ocular disease.
- **Increased revenue:** Expand the scope of your practice with state-of-the-art vascular imaging.
- **Keep existing OCT data:** Easily manage patient data with any of our affordable AngioVue® configurations.

**Visit our website to learn more about a risk-free trial of AngioVueHD.**

[optovue.com](http://optovue.com)



Our vision is foresight

**Editor in Chief**

**Walter C. Bethke**  
(610) 492-1024  
wbethke@jobson.com

**Senior Editor**

**Christopher Kent**  
(814) 861-5559  
ckent@jobson.com

**Senior Associate Editor**

**Kristine Brennan**  
(610) 492-1008  
kbrennan@jobson.com

**Associate Editor**

**Liam Jordan**  
(610) 492-1025  
ljordan@jobson.com

**Chief Medical Editor**

**Mark H. Blecher, MD**

**Art Director**

**Jared Araujo**  
(610) 492-1032  
jaraujo@jobson.com

**Senior Graphic Designer**

**Matt Egger**  
(610) 492-1029  
megger@jobson.com

**International coordinator, Japan**

**Mitz Kaminuma**  
Reviewophthalmo@aol.com

**Business Offices**

11 Campus Boulevard, Suite 100  
Newtown Square, PA 19073  
(610) 492-1000  
Fax: (610) 492-1039

**Subscription inquiries:**

United States — (877) 529-1746  
Outside U.S. — (845) 267-3065

**E-mail:**

revophthalmology@cambeywest.com

**Website:** www.reviewofophthalmology.com



# The Voice of The Doctor

Recently, an article came out in the *British Journal of Ophthalmology* exhorting physicians to listen to the “voice of the patient” with regard to treatment decisions and how therapies affect an individual’s quality of life, not just his visual acuity. Though it’s a laudable goal, the description of this movement reads partially like a backlash against a “paternalistic” view of medicine where the doctor always knows best.

I found this article to be fortuitously timed in light of our cover story on easing the stress anti-VEGF treatment places on patients’ lives, as well as our other feature on uveitis therapies, which can also seem daunting. I think the idea of listening to patients’ descriptions of their quality of life and the outcomes that are important to them has a lot of merit, but I also think we don’t want the pendulum to swing too far away from the physician. All those degrees are on the doctor’s wall for a reason: In matters of a patient’s condition and therapies, in most cases he or she actually does know best.

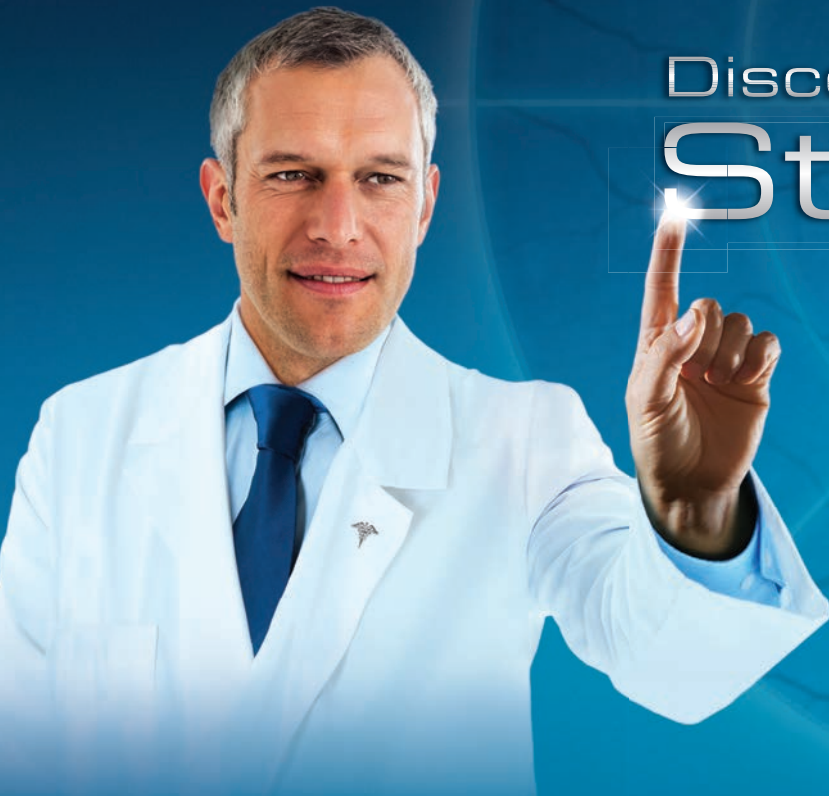There’s a middle ground between being a dictator and a doormat, however, and uveitis expert Sam Dahr, MD, alludes to it in our uveitis feature. Dr. Dahr says a patient’s acceptance of an apparently burdensome immunosuppressive therapy—which, in some circles, connote “poisons” that patients should be wary of—often hinges on how you present the option to him. Dr. Dahr notes that, if you explain the situation to the patient in the right way, acknowledging the small risk of a serious complication but also pointing out the fact that the patient will almost certainly go blind without the treatment,

the patient will likely get on board with the therapy. Using Dr. Dahr’s example, maybe if the physician considers the patient’s perspective, but focuses it through the lens of his expertise, they can lessen the burden together.

I’d also like to take this opportunity to acknowledge some changes here at *Review*. Donna McCune, vice president at Corcoran Consulting Group, has written our Medicare Q & A column for more than a decade and has always had her finger on the pulse of surgeons and their questions about reimbursement. This month’s column marks her final contribution, as she’s leaving Corcoran to assume a new position. Donna was able to anticipate ophthalmologists’ questions and concisely answer them. We wish her well. In her place comes Paul Larson, a senior consultant with CCG and another veteran in the field of coding. Readers will appreciate Paul’s insights into coding. Welcome, Paul.

There’s also a changing of the guard in our Wills Eye Resident Case Series. Allison Huggins, MD, completed her residency at Wills and passes the baton to her successor, Thomas Jenkins, MD. Allison always had an interesting, sometimes vexing, case to share with our readers, and I want to thank her for her hard work and wish her well in her future practice. For his part, Thomas has taken the reins of the column this month and has already provided us with an intriguing case to mull over. Thanks and welcome, Thomas.

—Walt Bethke, Editor in Chief



Discover

# Strength

in efficacy

As demonstrated in phase 3 clinical trials in patients with Wet AMD, Macular Edema following RVO, DME, and DR in patients with DME

**Choose EYLEA® (aflibercept) Injection from the start**

Learn about EYLEA at [EYLEA.us/ro](http://EYLEA.us/ro)

## INDICATIONS AND IMPORTANT SAFETY INFORMATION

### INDICATIONS

- EYLEA® (aflibercept) Injection is indicated for the treatment of patients with Neovascular (Wet) Age-related Macular Degeneration (AMD), Macular Edema following Retinal Vein Occlusion (RVO), Diabetic Macular Edema (DME), and Diabetic Retinopathy (DR) in Patients with DME.

### CONTRAINDICATIONS

- EYLEA® (aflibercept) Injection is contraindicated in patients with ocular or periocular infections, active intraocular inflammation, or known hypersensitivity to aflibercept or to any of the excipients in EYLEA.

### WARNINGS AND PRECAUTIONS

- Intravitreal injections, including those with EYLEA, have been associated with endophthalmitis and retinal detachments. Proper aseptic injection technique must always be used when administering EYLEA. Patients should be instructed to report any symptoms suggestive of endophthalmitis or retinal detachment without delay and should be managed appropriately. Intraocular inflammation has been reported with the use of EYLEA.
- Acute increases in intraocular pressure have been seen within 60 minutes of intravitreal injection, including with EYLEA. Sustained increases in intraocular pressure have also been reported after repeated intravitreal dosing with VEGF inhibitors. Intraocular pressure and the perfusion of the optic nerve head should be monitored and managed appropriately.

- There is a potential risk of arterial thromboembolic events (ATEs) following intravitreal use of VEGF inhibitors, including EYLEA. ATEs are defined as nonfatal stroke, nonfatal myocardial infarction, or vascular death (including deaths of unknown cause). The incidence of reported thromboembolic events in wet AMD studies during the first year was 1.8% (32 out of 1824) in the combined group of patients treated with EYLEA. The incidence in the DME studies from baseline to week 52 was 3.3% (19 out of 578) in the combined group of patients treated with EYLEA compared with 2.8% (8 out of 287) in the control group; from baseline to week 100, the incidence was 6.4% (37 out of 578) in the combined group of patients treated with EYLEA compared with 4.2% (12 out of 287) in the control group. There were no reported thromboembolic events in the patients treated with EYLEA in the first six months of the RVO studies.

### ADVERSE REACTIONS

- Serious adverse reactions related to the injection procedure have occurred in <0.1% of intravitreal injections with EYLEA including endophthalmitis and retinal detachment.
- The most common adverse reactions (≥5%) reported in patients receiving EYLEA were conjunctival hemorrhage, eye pain, cataract, vitreous floaters, intraocular pressure increased, and vitreous detachment.

Please see brief summary of full Prescribing Information on the following page.

EYLEA is a registered trademark of Regeneron Pharmaceuticals, Inc.

**REGENERON**

©2016, Regeneron Pharmaceuticals, Inc.,  
777 Old Saw Mill River Road, Tarrytown, NY 10591

 **EYLEA®**  
(aflibercept) Injection  
For Intravitreal Injection

**TARGETED SCIENCE**

All rights reserved

06/2016  
US-LEA-1648(1)



# EYLEA® (afibercept) Injection For Intravitreal Injection

## BRIEF SUMMARY OF FULL PRESCRIBING INFORMATION

### FOR COMPLETE DETAILS, SEE FULL PRESCRIBING INFORMATION.

#### 1 INDICATIONS AND USAGE

EYLEA® (afibercept) Injection is indicated for the treatment of patients with Neovascular (Wet) Age-Related Macular Degeneration (AMD), Macular Edema following Retinal Vein Occlusion (RVO), Diabetic Macular Edema (DME), and Diabetic Retinopathy (DR) in Patients with DME.

#### 2 DOSAGE AND ADMINISTRATION

**2.1 Important Injection Instructions.** For ophthalmic intravitreal injection. EYLEA must only be administered by a qualified physician.

**2.2 Neovascular (Wet) Age-Related Macular Degeneration (AMD).** The recommended dose for EYLEA is 2 mg (0.05 mL or 50 microliters) administered by intravitreal injection every 4 weeks (monthly) for the first 12 weeks (3 months), followed by 2 mg (0.05 mL) via intravitreal injection once every 8 weeks (2 months). Although EYLEA may be dosed as frequently as 2 mg every 4 weeks (monthly), additional efficacy was not demonstrated in most patients when EYLEA was dosed every 4 weeks compared to every 8 weeks. Some patients may need every 4 week (monthly) dosing after the first 12 weeks (3 months).

**2.3 Macular Edema Following Retinal Vein Occlusion (RVO).** The recommended dose for EYLEA is 0.05 mL or 50 microliters administered by intravitreal injection once every 4 weeks (monthly).

**2.4 Diabetic Macular Edema (DME).** The recommended dose for EYLEA is 0.05 mL or 50 microliters administered by intravitreal injection every 4 weeks (monthly) for the first 5 injections followed by 2 mg (0.05 mL) via intravitreal injection once every 8 weeks (2 months). Although EYLEA may be dosed as frequently as 2 mg every 4 weeks (monthly), additional efficacy was not demonstrated in most patients when EYLEA was dosed every 4 weeks compared to every 8 weeks. Some patients may need every 4 week (monthly) dosing after the first 20 weeks (5 months).

**2.5 Diabetic Retinopathy (DR) in Patients with DME.** The recommended dose for EYLEA is 2 mg (0.05 mL or 50 microliters) administered by intravitreal injection every 4 weeks (monthly) for the first 5 injections, followed by 2 mg (0.05 mL) via intravitreal injection once every 8 weeks (2 months). Although EYLEA may be dosed as frequently as 2 mg every 4 weeks (monthly), additional efficacy was not demonstrated in most patients when EYLEA was dosed every 4 weeks compared to every 8 weeks. Some patients may need every 4 week (monthly) dosing after the first 20 weeks (5 months).

**2.6 Preparation for Administration.** EYLEA should be inspected visually prior to administration. If particulates, cloudiness, or discoloration are visible, the vial must not be used. Using aseptic technique, the intravitreal injection should be performed with a 30-gauge x 1/2-inch injection needle. For complete preparation for administration instructions, see full prescribing information.

**2.7 Injection Procedure.** The intravitreal injection procedure should be carried out under controlled aseptic conditions, which include surgical hand disinfection and the use of sterile gloves, a sterile drape, and a sterile eyelid speculum (or equivalent). Adequate anesthesia and a topical broad-spectrum microbicide should be given prior to the injection. Immediately following the intravitreal injection, patients should be monitored for elevation in intraocular pressure. Appropriate monitoring may consist of a check for perfusion of the optic nerve head or tonometry. If required, a sterile paracentesis needle should be available.

Following intravitreal injection, patients should be instructed to report any symptoms suggestive of endophthalmitis or retinal detachment (e.g., eye pain, redness of the eye, photophobia, blurring of vision) without delay (see *Patient Counseling Information*).

Each vial should only be used for the treatment of a single eye. If the contralateral eye requires treatment, a new vial should be used and the sterile field, syringe, gloves, drape, eyelid speculum, filter, and injection needles should be changed before EYLEA is administered to the other eye.

After injection, any unused product must be discarded.

#### 3 DOSAGE FORMS AND STRENGTHS

Single-use, glass vial designed to provide 0.05 mL of 40 mg/mL solution (2 mg) for intravitreal injection.

#### 4 CONTRAINDICATIONS

EYLEA is contraindicated in patients with

- Ocular or periorcular infections
- Active intraocular inflammation
- Known hypersensitivity to afibercept or any of the excipients in EYLEA.

Hypersensitivity reactions may manifest as severe intraocular inflammation.

#### 5 WARNINGS AND PRECAUTIONS

**5.1 Endophthalmitis and Retinal Detachments.** Intravitreal injections, including those with EYLEA, have been associated with endophthalmitis and retinal detachments (see *Adverse Reactions*). Proper aseptic injection technique must always be used when administering EYLEA. Patients should be instructed to report any symptoms suggestive of endophthalmitis or retinal detachment without delay and should be managed appropriately (see *Dosage and Administration and Patient Counseling Information*).

**5.2 Increase in Intraocular Pressure.** Acute increases in intraocular pressure have been seen within 60 minutes of intravitreal injection, including with EYLEA (see *Adverse Reactions*). Sustained increases in intraocular pressure have also been reported after repeated intravitreal dosing with vascular endothelial growth factor (VEGF) inhibitors. Intraocular pressure and the perfusion of the optic nerve head should be monitored and managed appropriately (see *Dosage and Administration*).

**5.3 Thromboembolic Events.** There is a potential risk of arterial thromboembolic events (ATEs) following intravitreal use of VEGF inhibitors, including EYLEA. ATEs are defined as nonfatal stroke, nonfatal myocardial infarction, or vascular death (including deaths of unknown cause). The incidence of reported thromboembolic events in wet AMD studies during the first year was 1.8% (32 out of 1824) in the combined group of patients treated with EYLEA. The incidence in the DME studies from baseline to week 52 was 3.3% (19 out of 578) in the combined group of patients treated with EYLEA compared with 2.8% (8 out of 287) in the control group; from baseline to week 100, the incidence was 6.4% (37 out of 578) in the combined group of patients treated with EYLEA compared with 4.2% (12 out of 287) in the control group. There were no reported thromboembolic events in the patients treated with EYLEA in the first six months of the RVO studies.

#### 6 ADVERSE REACTIONS

The following adverse reactions are discussed in greater detail in the *Warnings and Precautions* section of the labeling:

- Endophthalmitis and retinal detachments
- Increased intraocular pressure
- Thromboembolic events

**6.1 Clinical Trials Experience.** Because clinical trials are conducted under widely varying conditions, adverse reaction rates observed in the clinical trials of a drug cannot be directly compared to rates in other clinical trials of the same or another drug and may not reflect the rates observed in practice.

A total of 2711 patients treated with EYLEA constituted the safety population in seven phase 3 studies. Among those, 2110 patients were treated with the recommended dose of 2 mg. Serious adverse reactions related to the injection procedure have occurred in <0.1% of intravitreal injections with EYLEA including endophthalmitis and retinal detachment. The most common adverse reactions (≥5%) reported in patients receiving EYLEA were conjunctival hemorrhage, eye pain, cataract, vitreous floaters, intraocular pressure increased, and vitreous detachment.

**Neovascular (Wet) Age-Related Macular Degeneration (AMD).** The data described below reflect exposure to EYLEA in 1824 patients with wet AMD, including 1223 patients treated with the 2-mg dose, in 2 double-masked, active-controlled clinical studies (VIEW1 and VIEW2) for 12 months.

**Table 1: Most Common Adverse Reactions (≥1% in Wet AMD Studies**

Adverse Reactions	EYLEA (N=1824)	Active Control (ranibizumab) (N=595)
Conjunctival hemorrhage	25%	28%
Eye pain	9%	9%
Cataract	7%	7%
Vitreous detachment	6%	6%
Vitreous floaters	6%	7%
Intraocular pressure increased	5%	7%
Ocular hyperemia	4%	8%
Corneal epithelium defect	4%	5%
Detachment of the retinal pigment epithelium	3%	3%
Injection site pain	3%	3%
Foreign body sensation in eyes	3%	4%
Lacrimation increased	3%	1%
Vision blurred	2%	2%
Intraocular inflammation	2%	3%
Retinal pigment epithelium tear	2%	1%
Injection site hemorrhage	1%	2%
Eyelid edema	1%	2%
Corneal edema	1%	1%

Less common serious adverse reactions reported in <1% of the patients treated with EYLEA were hypersensitivity, retinal detachment, retinal tear, and endophthalmitis.

**Macular Edema Following Retinal Vein Occlusion (RVO).** The data described below reflect 6 months exposure to EYLEA with a monthly 2 mg dose in 218 patients following CRVO in 2 clinical studies (COPERNICUS and GALILEO) and 91 patients following BRVO in one clinical study (VIBRANT).

**Table 2: Most Common Adverse Reactions (≥1% in RVO Studies**

Adverse Reactions	CRVO		BRVO	
	EYLEA (N=218)	Control (N=142)	EYLEA (N=91)	Control (N=92)
Eye pain	13%	5%	4%	5%
Conjunctival hemorrhage	12%	11%	20%	4%
Intraocular pressure increased	8%	6%	2%	0%
Corneal epithelium defect	5%	4%	2%	0%
Vitreous floaters	5%	1%	1%	0%
Ocular hyperemia	5%	3%	2%	2%
Foreign body sensation in eyes	3%	5%	3%	0%
Vitreous detachment	3%	4%	2%	0%
Lacrimation increased	3%	4%	3%	0%
Injection site pain	3%	1%	1%	0%
Vision blurred	1%	<1%	1%	1%
Intraocular inflammation	1%	1%	0%	0%
Cataract	<1%	1%	5%	0%
Eyelid edema	<1%	1%	1%	0%

Less common adverse reactions reported in <1% of the patients treated with EYLEA in the CRVO studies were corneal edema, retinal tear, hypersensitivity, and endophthalmitis.

**Diabetic Macular Edema (DME).** The data described below reflect exposure to EYLEA in 578 patients with DME treated with the 2-mg dose in 2 double-masked, controlled clinical studies (VIVID and VISTA) from baseline to week 52 and from baseline to week 100.

Adverse Reactions	Baseline to Week 52		Baseline to Week 100	
	EYLEA (N=578)	Control (N=287)	EYLEA (N=578)	Control (N=287)
Conjunctival hemorrhage	28%	17%	31%	21%
Eye pain	9%	6%	11%	9%
Cataract	8%	9%	19%	17%
Vitreous floaters	6%	3%	8%	6%
Corneal epithelium defect	5%	3%	7%	5%
Intraocular pressure increased	5%	3%	9%	5%
Ocular hyperemia	5%	6%	5%	6%
Vitreous detachment	3%	3%	8%	6%
Foreign body sensation in eyes	3%	3%	3%	3%
Lacrimation increased	3%	2%	4%	2%
Vision blurred	2%	2%	3%	4%
Intraocular inflammation	2%	<1%	3%	1%
Injection site pain	2%	<1%	2%	<1%
Eyelid edema	<1%	1%	2%	1%

Less common adverse reactions reported in <1% of the patients treated with EYLEA were hypersensitivity, retinal detachment, retinal tear, corneal edema, and injection site hemorrhage.

**6.2 Immunogenicity.** As with all therapeutic proteins, there is a potential for an immune response in patients treated with EYLEA. The immunogenicity of EYLEA was evaluated in serum samples. The immunogenicity data reflect the percentage of patients whose test results were considered positive for antibodies to EYLEA in immunoassays. The detection of an immune response is highly dependent on the sensitivity and specificity of the assays used, sample handling, timing of sample collection, concomitant medications, and underlying disease. For these reasons, comparison of the incidence of antibodies to EYLEA with the incidence of antibodies to other products may be misleading.

In the wet AMD, RVO, and DME studies, the pre-treatment incidence of immunoreactivity to EYLEA was approximately 1% to 3% across treatment groups. After dosing with EYLEA for 24-100 weeks, antibodies to EYLEA were detected in a similar percentage range of patients. There were no differences in efficacy or safety between patients with or without immunoreactivity.

**6.3 Postmarketing Experience.** The following adverse reactions have been identified during postapproval use of EYLEA. Because these reactions are reported voluntarily from a population of uncertain size, it is not always possible to reliably estimate their frequency or establish a causal relationship to drug exposure.

- Hypersensitivity including rash, pruritus, and urticaria as well as isolated cases of severe anaphylactic/anaphylactoid reactions.

#### 8 USE IN SPECIFIC POPULATIONS

**8.1 Pregnancy.** Pregnancy Category C. Afibercept produced embryo-fetal toxicity when administered every three days during organogenesis to pregnant rabbits at intravenous doses ≥3 mg per kg, or every six days at subcutaneous doses ≥0.1 mg per kg. Adverse embryo-fetal effects included increased incidences of postimplantation loss and fetal malformations, including anasarca, umbilical hernia, diaphragmatic hernia, gastroschisis, cleft palate, ectrodactyly, intestinal atresia, spina bifida, encephalomeningocele, heart and major vessel defects, and skeletal malformations (fused vertebrae, sternbrae, and ribs; supernumerary vertebral arches and ribs; and incomplete ossification). The maternal No Observed Adverse Effect Level (NOAEL) in these studies was 3 mg per kg. Afibercept produced fetal malformations at all doses assessed in rabbits and the fetal NOAEL was less than 0.1 mg per kg. Administration of the lowest dose assessed in rabbits (0.1 mg per kg) resulted in systemic exposure (AUC) that was approximately 10 times the systemic exposure observed in humans after an intravitreal dose of 2 mg.

There are no adequate and well-controlled studies in pregnant women. EYLEA should be used during pregnancy only if the potential benefit justifies the potential risk to the fetus. Females of reproductive potential should use effective contraception prior to the initial dose, during treatment, and for at least 3 months after the last intravitreal injection of EYLEA.

**8.3 Nursing Mothers.** It is unknown whether afibercept is excreted in human milk. Because many drugs are excreted in human milk, a risk to the breastfed child cannot be excluded. EYLEA is not recommended during breastfeeding. A decision must be made whether to discontinue nursing or to discontinue treatment with EYLEA, taking into account the importance of the drug to the mother.

**8.4 Pediatric Use.** The safety and effectiveness of EYLEA in pediatric patients have not been established.

**8.5 Geriatric Use.** In the clinical studies, approximately 76% (2049/2701) of patients randomized to treatment with EYLEA were ≥65 years of age and approximately 46% (1250/2701) were ≥75 years of age. No significant differences in efficacy or safety were seen with increasing age in these studies.

#### 17 PATIENT COUNSELING INFORMATION

In the days following EYLEA administration, patients are at risk of developing endophthalmitis or retinal detachment. If the eye becomes red, sensitive to light, painful, or develops a change in vision, advise patients to seek immediate care from an ophthalmologist (see *Warnings and Precautions*). Patients may experience temporary visual disturbances after an intravitreal injection with EYLEA and the associated eye examinations (see *Adverse Reactions*). Advise patients not to drive or use machinery until visual function has recovered sufficiently.

## REGENERON

Manufactured by:  
Regeneron Pharmaceuticals, Inc.  
777 Old Saw Mill River Road  
Tarrytown, NY 10591-6707

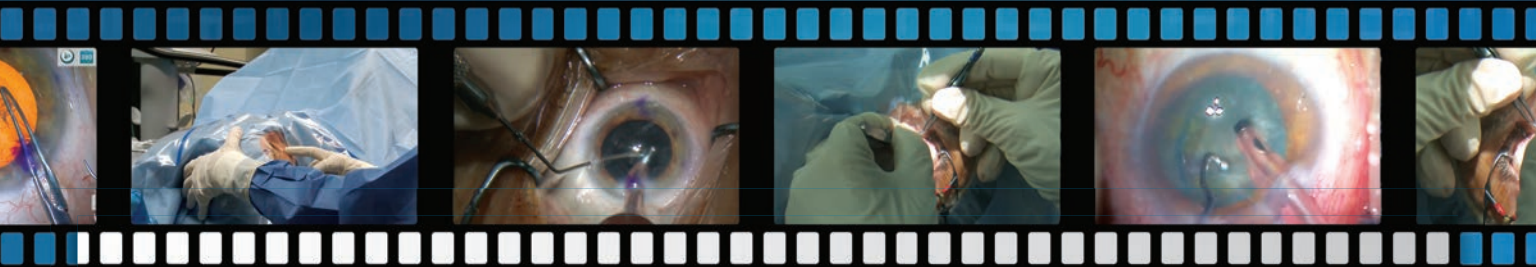
EYLEA is a registered trademark of Regeneron Pharmaceuticals, Inc.  
© 2016, Regeneron Pharmaceuticals, Inc.  
All rights reserved.  
Issue Date: June 2016  
Initial U.S. Approval: 2011  
June 2016



Monthly

# MACKOOL ONLINE CME

## CME SERIES | SURGICAL VIDEOS



To view CME video  
go to:

[www.MackoolOnlineCME.com](http://www.MackoolOnlineCME.com)

### Episode 20: “Endothelial and Zonular Issues in a Patient with Persistent Head Movement”

Surgical Video by:  
Richard J. Mackool, MD

#### Video Overview:

A very interesting case, indeed! Here we will see a patient with considerable head movement, very advanced corneal endothelial dystrophy, pseudoexfoliation, and zonular laxity that prevents nucleus rotation. In addition, the patient exhibited considerable head motion during the procedure.

#### Accreditation Statement

This activity has been planned and implemented in accordance with the accreditation requirements and policies of the Accreditation Council for Continuing Medical Education (ACCME) through the joint providership of Amedco and Postgraduate Healthcare Education, LLC (PHE). Amedco is accredited by the ACCME to provide continuing medical education for physicians.

#### Credit Designation Statement

Amedco designates this live activity for a maximum of .25 AMA PRA Category 1 Credits™. Physicians should claim only the credit commensurate with the extent of their participation in the activity.

## MackoolOnlineCME.com MONTHLY Video Series



Richard J. Mackool, MD

Welcome to the second year of Mackool Online CME! With the generous support of several ophthalmic companies, I am honored to have our viewers join me in the operating room as I demonstrate the technology and techniques that I have found to be most valuable, and that I hope are helpful to many of my colleagues. We continue to edit the videos only to either change camera perspective or to reduce down time – allowing you to observe every step of the procedure.

As before, one new surgical video will be released monthly, and physicians may earn CME credits or just observe the case. New viewers are able to obtain additional CME credit by reviewing previous videos that are located in our archives.

I thank the many surgeons who have told us that they have found our CME program to be interesting and instructive; I appreciate your comments, suggestions and questions. Thanks again for joining us on Mackool Online CME.



**CME Accredited Surgical Training Videos Now Available Online: [www.MackoolOnlineCME.com](http://www.MackoolOnlineCME.com)**

Richard Mackool, MD, a world renowned anterior segment ophthalmic microsurgeon, has assembled a web-based video collection of surgical cases that encompass both routine and challenging cases, demonstrating both familiar and potentially unfamiliar surgical techniques using a variety of instrumentation and settings.

This educational activity aims to present a series of Dr. Mackool’s surgical videos, carefully selected to address the specific learning objectives of this activity, with the goal of making surgical training available as needed online for surgeons motivated to improve or expand their surgical repertoire.

#### Learning Objective:

*After completion of this educational activity, participants should be able to:*

- Demonstrate methods to safely perform phacoemulsification in an eye with very advanced corneal endothelial dystrophy, pseudoexfoliation, and zonular laxity that prevented nucleus rotation.

Endorsed by:  
**Review of Ophthalmology®**

Video and Web Production by:  
JR Snowdon, Inc

Jointly Provided by:



Supported by an unrestricted independent  
medical educational grant from:

**Alcon**

Commercially supported by:

**Carl Zeiss Meditec**  
**Crestpoint Management**  
**Glaukos**  
**MST**

# CONTRIBUTORS

**CHIEF MEDICAL EDITOR**

Mark H. Blecher, MD

**CONTACT LENSES**

Penny Asbell, MD

**CORNEA / ANTERIOR SEGMENT**

Thomas John, MD

**GLAUCOMA MANAGEMENT**

Peter Netland, MD, PHD  
Kuldev Singh, MD

**MASTERS OF SURGERY**

Taliva D. Martin, MD  
Sara J. Haug, MD, PhD

**PEDIATRIC PATIENT**

Wendy Huang, MD

**PLASTIC POINTERS**

Ann P. Murchison, MD, MPH

**REFRACTIVE SURGERY**

Arturo S. Chayet, MD

**RETINAL INSIDER**

Carl Regillo, MD, FACS  
Emmett T. Cunningham Jr., MD, PHD, MPH

**TECHNOLOGY UPDATE**

Steven T. Charles, MD  
Michael Colvard, MD

**THERAPEUTIC TOPICS**

Mark Abelson, MD

**WILLS RESIDENT CASE SERIES**

Thomas Jenkins, MD

# ADVISORY BOARD

**PENNY A. ASBELL, MD**, NEW YORK CITY

**WILLIAM I. BOND, MD**, PEKIN, ILL.

**ALAN N. CARLSON, MD**, DURHAM, N.C.

**Y. RALPH CHU, MD**, EDINA, MINN.

**ADAM J. COHEN, MD**, DOWNERS GROVE, ILL.

**UDAY DEVGAN, MD, FACS**, LOS ANGELES

**ERIC DONNENFELD, MD**, ROCKVILLE CENTRE, N.Y.

**DANIEL S. DURRIE, MD**, KANSAS CITY, MO.

**ROBERT EPSTEIN, MD**, MCHENRY, ILL.

**ROBERT D. FECHTNER, MD**, NEWARK, N.J.

**WILLIAM J. FISHKIND, MD**, TUCSON, ARIZ.

**JAMES P. GILLS, MD**, TARPON SPRINGS, FLA.

**HARRY GRABOW, MD**, SARASOTA, FLA.

**DOUGLAS K. GRAYSON, MD**, NEW YORK CITY

**R. BRUCE GRENE, MD**, WICHITA, KAN.

**THOMAS S. HARBIN, MD, MBA**, ATLANTA

**DAVID R. HARDTEN, MD**, MINNEAPOLIS

**KENNETH J. HOFFER, MD**, SANTA MONICA, CALIF.

**JACK T. HOLLADAY, MD, MSEE**, HOUSTON

**JOHN D. HUNKELER, MD**, KANSAS CITY, MO.

**THOMAS JOHN, MD**, TINLEY PARK, ILL.

**ROBERT M. KERSHNER, MD, MS, FACS**, BOSTON

**GUY M. KEZIRIAN, MD**, PARADISE VALLEY, ARIZ.

**TERRY KIM, MD**, DURHAM, N.C.

**TOMMY KORN, MD**, SAN DIEGO

**DAVID A. LEE, MD**, HOUSTON

**FRANCIS S. MAH, MD**, PITTSBURGH

**NICK MAMALIS, MD**, SALT LAKE CITY

**WILLIAM G. MARTIN, MD**, OREGON, OHIO

**MIKE S. MCFARLAND, MD**, PINE BLUFF, ARK.

**JEFFREY B. MORRIS, MD, MPH**, ENCINITAS, CALIF.

**MARLENE R. MOSTER, MD**, PHILADELPHIA

**ROBERT J. NOECKER, MD**, FAIRFIELD, CONN.

**ROBERT OSHER, MD**, CINCINNATI

**MARK PACKER, MD**, WEST PALM BEACH, FLA.

**STEPHEN PASCUCCI, MD**, BONITA SPRINGS, FLA.

**PAUL PENDER, MD**, BEDFORD, N.H.

**CHRISTOPHER J. RAPUANO, MD**, PHILADELPHIA

**AUGUST READER III, MD**, SAN FRANCISCO

**TONY REALINI, MD**, MORGANTOWN, W.V.

**KENNETH J. ROSENTHAL, MD**, GREAT NECK, N.Y.

**ERIC ROTHCHILD, MD**, DELRAY BEACH, FLA.

**SHERI ROWEN, MD**, BALTIMORE

**JAMES J. SALZ, MD**, LOS ANGELES

**INGRID U. SCOTT, MD, MPH**, HERSHEY, PA.

**JOEL SCHUMAN, MD**, PITTSBURGH

**GAURAV SHAH, MD**, ST. LOUIS

**DAVID R. STAGER JR., MD**, DALLAS

**KARL STONECIPHER, MD**, GREENSBORO, N.C.

**JAMES C. TSAI, MD**, NEW YORK CITY

**VANCE THOMPSON, MD**, SIOUX FALLS, S.D.

**FARRELL C. TYSON, MD**, CAPE CORAL, FLA.

**R. BRUCE WALLACE III, MD**, ALEXANDRIA, LA.

**ROBERT G. WILEY, MD**, CLEVELAND

**FRANK WEINSTOCK, MD**, CANTON, OHIO

**JACQUELINE M.S. WINTERKORN, MD, PHD**, NEW YORK CITY

**BUSINESS OFFICES**

11 CAMPUS BOULEVARD, SUITE 100  
NEWTOWN SQUARE, PA 19073  
SUBSCRIPTION INQUIRIES (877) 529-1746  
(USA ONLY); OUTSIDE USA, CALL (847) 763-9630

**BUSINESS STAFF**

PUBLISHER

**JAMES HENNE**

(610) 492-1017 JHENNE@JOBSON.COM

REGIONAL SALES MANAGER

**MICHELE BARRETT**

(610) 492-1014 MBARRETT@JOBSON.COM

REGIONAL SALES MANAGER

**MICHAEL HOSTER**

(610) 492-1028 MHOSTER@JOBSON.COM

**CLASSIFIED ADVERTISING**

(888)-498-1460

VICE PRESIDENT OF OPERATIONS

**CASEY FOSTER**

(610) 492-1007 CFOSTER@JOBSON.COM

PRODUCTION MANAGER

**SCOTT TOBIN**

(610) 492-1011 STOBIN@JOBSON.COM

**SUBSCRIPTIONS**

\$63 A YEAR, \$99 (U.S.) IN CANADA,  
\$158 (U.S.) IN ALL OTHER COUNTRIES.

SUBSCRIPTIONS E-MAIL:

REVOPHTHALMOLOGY@CAMBEYWEST.COM

**CIRCULATION**

PO BOX 71, CONGERS, NY 10920-0071  
(877) 529-1746

OUTSIDE USA: (845) 267-3065

SENIOR CIRCULATION MANAGER

**HAMILTON MAHER**

(212) 219-7870 hmaher@jhihealth.com

CEO, INFORMATION GROUP SERVICES

**MARC FERRARA**

SENIOR VICE PRESIDENT, OPERATIONS

**JEFF LEVITZ**

VICE PRESIDENT, HUMAN RESOURCES

**TAMMY GARCIA**

VICE PRESIDENT, CREATIVE SERVICES & PRODUCTION

**MONICA TETTAMANZI**

CORPORATE PRODUCTION DIRECTOR

**JOHN ANTHONY CAGGIANO**

VICE PRESIDENT, CIRCULATION

**EVELDA BAREA**



440 Ninth Avenue, 14th Floor  
New York, N.Y. 10001

REVIEW OF OPHTHALMOLOGY (ISSN 1081-0226; USPS No. 0012-345) is published monthly, 12 times per year by Jobson Medical Information, 440 Ninth Avenue, 14th Floor, New York, N.Y. 10001. Periodicals postage paid at New York, NY and additional mailing offices. Postmaster: Send address changes to Review of Ophthalmology, PO Box 71, Congers, NY 10929-0071. Subscription Prices: US One Year \$63.00, US Two Year \$112.00, Canada One Year \$99.00, Canada Two Year \$181.00, Int'l One Year \$158.00, Int'l Two Year \$274.00. For subscription information call (877) 529-1746 (USA only); outside USA, call (845)-267-3065. Or email us at revophthalmology@cambeywest.com. Canada Post: Publications Mail Agreement #40612608. Canada Returns to be sent to Bleuchip International, P.O. Box 25542, London, ON N6C 6B2.



# Down, Boy.

Help Tame Postoperative Ocular Inflammation  
and Pain With **LOTEMAX<sup>®</sup> GEL**

## Indication

LOTEMAX<sup>®</sup> GEL (loteprednol etabonate ophthalmic gel) 0.5% is indicated for the treatment of post-operative inflammation and pain following ocular surgery.

## Important Safety Information about LOTE<sup>®</sup>MAX<sup>®</sup> GEL

- LOTE<sup>®</sup>MAX<sup>®</sup> GEL is contraindicated in most viral diseases of the cornea and conjunctiva including epithelial herpes simplex keratitis (dendritic keratitis), vaccinia, and varicella, and also in mycobacterial infection of the eye and fungal diseases of ocular structures.
- Prolonged use of corticosteroids may result in glaucoma with damage to the optic nerve, defects in visual acuity and fields of vision. If this product is used for 10 days or longer, IOP should be monitored.
- Use of corticosteroids may result in posterior subcapsular cataract formation.
- Use of steroids after cataract surgery may delay healing and increase the incidence of bleb formation and occurrence of perforations in those with diseases causing corneal and scleral thinning. The initial prescription and renewal of the medication order should be made by a physician only after examination of the patient with the aid of magnification, and where appropriate, fluorescein staining.
- Prolonged use of corticosteroids may suppress the host response and thus increase the hazard of secondary ocular infection. In acute purulent conditions, steroids may mask infection or enhance existing infection.
- Use of a corticosteroid medication in the treatment of patients with a history of herpes simplex requires great caution. Use of ocular steroids may prolong the course and exacerbate the severity of many viral infections of the eye (including herpes simplex).
- Fungal infections of the cornea are particularly prone to develop coincidentally with long-term local steroid application. Fungus invasion must be considered in any persistent corneal ulceration where a steroid has been used or is in use.
- Patients should not wear contact lenses when using LOTE<sup>®</sup>MAX<sup>®</sup> GEL.
- The most common ocular adverse drug reactions reported were anterior chamber inflammation (5%), eye pain (2%) and foreign body sensation (2%).

Please see brief summary of Prescribing Information on adjacent page.

®/™ are trademarks of Bausch & Lomb Incorporated or its affiliates. © 2015 Bausch & Lomb Incorporated. All rights reserved. Printed in USA. US/LGX/15/0041(1)

**BAUSCH + LOMB**

 **LOTEMAX<sup>®</sup> GEL**  
loteprednol etabonate  
ophthalmic gel 0.5%

## BRIEF SUMMARY OF PRESCRIBING INFORMATION

This Brief Summary does not include all the information needed to prescribe Lotemax Gel safely and effectively. See full prescribing information for Lotemax Gel.

## Lotemax (loteprednol etabonate ophthalmic gel) 0.5%

Rx only

Initial Rx Approval: 1998

### INDICATIONS AND USAGE

LOTEMAX is a corticosteroid indicated for the treatment of post-operative inflammation and pain following ocular surgery.

### DOSAGE AND ADMINISTRATION

Invert closed bottle and shake once to fill tip before instilling drops.

Apply one to two drops of LOTE MAX into the conjunctival sac of the affected eye four times daily beginning the day after surgery and continuing throughout the first 2 weeks of the post-operative period.

### CONTRAINDICATIONS

LOTE MAX, as with other ophthalmic corticosteroids, is contraindicated in most viral diseases of the cornea and conjunctiva including epithelial herpes simplex keratitis (dendritic keratitis), vaccinia, and varicella, and also in mycobacterial infection of the eye and fungal diseases of ocular structures.

### WARNINGS AND PRECAUTIONS

#### Intraocular Pressure (IOP) Increase

Prolonged use of corticosteroids may result in glaucoma with damage to the optic nerve, defects in visual acuity and fields of vision. Steroids should be used with caution in the presence of glaucoma. If this product is used for 10 days or longer, intraocular pressure should be monitored.

#### Cataracts

Use of corticosteroids may result in posterior subcapsular cataract formation.

#### Delayed Healing

The use of steroids after cataract surgery may delay healing and increase the incidence of bleb formation. In those diseases causing thinning of the cornea or sclera, perforations have been known to occur with the use of topical steroids. The initial prescription and renewal of the medication order should be made by a physician only after examination of the patient with the aid of magnification such as slit lamp biomicroscopy and, where appropriate, fluorescein staining.

#### Bacterial Infections

Prolonged use of corticosteroids may suppress the host response and thus increase the hazard of secondary ocular infections. In acute purulent conditions of the eye, steroids may mask infection or enhance existing infection.

#### Viral Infections

Employment of a corticosteroid medication in the treatment of patients with a history of herpes simplex requires great caution. Use of ocular steroids may prolong the course and may exacerbate the severity of many viral infections of the eye (including herpes simplex).

#### Fungal Infections

Fungal infections of the cornea are particularly prone to develop coincidentally with long-term local steroid application. Fungus invasion must be considered in any persistent corneal ulceration where a steroid has been used or is in use. Fungal cultures should be taken when appropriate.

#### Contact Lens Wear

Patients should not wear contact lenses during their course of therapy with LOTE MAX.

### ADVERSE REACTIONS

Adverse reactions associated with ophthalmic steroids include elevated intraocular pressure, which may be associated with infrequent optic nerve damage, visual acuity and field defects, posterior subcapsular cataract formation, delayed wound healing and secondary ocular infection from pathogens including herpes simplex, and perforation of the globe where there is thinning of the cornea or sclera.

The most common adverse drug reactions reported were anterior chamber inflammation (5%), eye pain (2%), and foreign body sensation (2%).

### USE IN SPECIFIC POPULATIONS

#### Pregnancy

#### Teratogenic Effects

Loteprednol etabonate has been shown to be embryotoxic (delayed

ossification) and teratogenic (increased incidence of meningocele, abnormal left common carotid artery, and limb flexures) when administered orally to rabbits during organogenesis at a dose of 3 mg/kg/day (35 times the maximum daily clinical dose), a dose which caused no maternal toxicity. The no-observed-effect-level (NOEL) for these effects was 0.5 mg/kg/day (6 times the maximum daily clinical dose). Oral treatment of rats during organogenesis resulted in teratogenicity (absent innominate artery at  $\geq 5$  mg/kg/day doses, and cleft palate and umbilical hernia at  $\geq 50$  mg/kg/day) and embryotoxicity (increased post-implantation losses at 100 mg/kg/day and decreased fetal body weight and skeletal ossification with  $\geq 50$  mg/kg/day). Treatment of rats with 0.5 mg/kg/day (6 times the maximum clinical dose) during organogenesis did not result in any reproductive toxicity. Loteprednol etabonate was maternally toxic (significantly reduced body weight gain during treatment) when administered to pregnant rats during organogenesis at doses of  $\geq 5$  mg/kg/day.

Oral exposure of female rats to 50 mg/kg/day of loteprednol etabonate from the start of the fetal period through the end of lactation, a maternally toxic treatment regimen (significantly decreased body weight gain), gave rise to decreased growth and survival, and retarded development in the offspring during lactation; the NOEL for these effects was 5 mg/kg/day. Loteprednol etabonate had no effect on the duration of gestation or parturition when administered orally to pregnant rats at doses up to 50 mg/kg/day during the fetal period.

There are no adequate and well controlled studies in pregnant women. LOTE MAX should be used during pregnancy only if the potential benefit justifies the potential risk to the fetus.

#### Nursing Mothers

It is not known whether topical ophthalmic administration of corticosteroids could result in sufficient systemic absorption to produce detectable quantities in human milk. Systemic steroids appear in human milk and could suppress growth, interfere with endogenous corticosteroid production, or cause other untoward effects. Caution should be exercised when LOTE MAX is administered to a nursing woman.

#### Pediatric Use

Safety and effectiveness in pediatric patients have not been established.

#### Geriatric Use

No overall differences in safety and effectiveness have been observed between elderly and younger patients.

### NONCLINICAL TOXICOLOGY

#### Carcinogenesis, Mutagenesis, Impairment Of Fertility

Long-term animal studies have not been conducted to evaluate the carcinogenic potential of loteprednol etabonate. Loteprednol etabonate was not genotoxic *in vitro* in the Ames test, the mouse lymphoma tk assay, or in a chromosome aberration test in human lymphocytes, or *in vivo* in the single dose mouse micronucleus assay. Treatment of male and female rats with up to 50 mg/kg/day and 25 mg/kg/day of loteprednol etabonate, respectively, (600 and 300 times the maximum clinical dose, respectively) prior to and during mating did not impair fertility in either gender.

### PATIENT COUNSELING INFORMATION

#### Administration

Invert closed bottle and shake once to fill tip before instilling drops.

#### Risk of Contamination

Patients should be advised not to allow the dropper tip to touch any surface, as this may contaminate the gel.

#### Contact Lens Wear

Patients should be advised not to wear contact lenses when using LOTE MAX.

#### Risk of Secondary Infection

If pain develops, redness, itching or inflammation becomes aggravated, the patient should be advised to consult a physician.

Bausch + Lomb, a division of Valeant Pharmaceuticals North America LLC  
Bridgewater, NJ 08807 USA

US Patent No. 5,800,807

©Bausch & Lomb Incorporated

Lotemax is a registered trademark of Bausch & Lomb Incorporated or its affiliates.

LGX.0114.USA.16

Based on 9269101/9269201

Revised: 08/2016



# REVIEW<sup>®</sup> of Ophthalmology

August 2017 • Volume XXIV No. 8 | [reviewofophthalmology.com](http://reviewofophthalmology.com)

## Cover Story

---

### 24 | **Easing the Burden of AMD Treatment**

*Christopher Kent, Senior Editor*

How to minimize the burden of anti-VEGF injections—for both patients and practices—without harming the patient.

## Cover Focus

---

### 30 | **How to Get the Most from OCT-A**

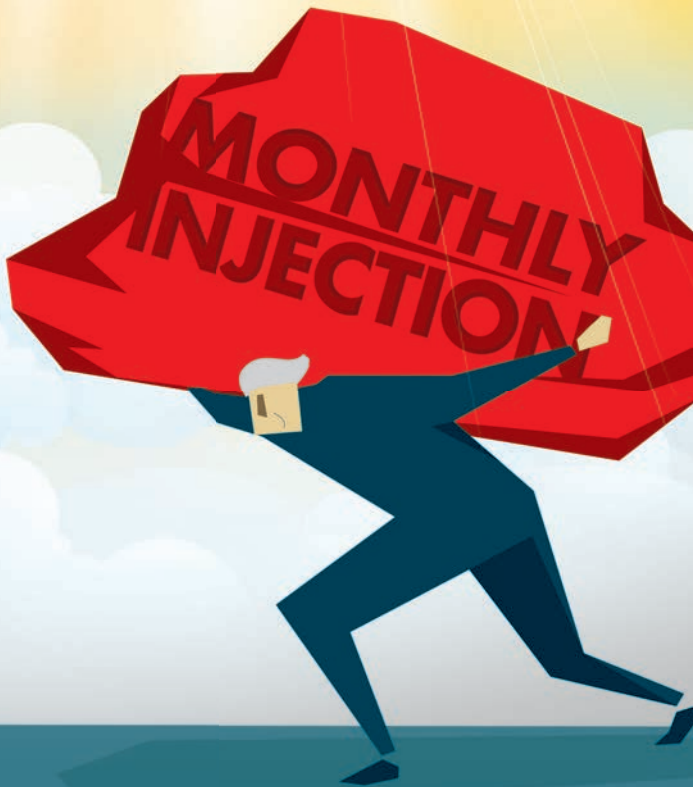*Michelle Stephenson, Contributing Editor*

Although it's not yet a mature technology, OCT-A is already providing valuable information about retinal vascular disease.

### 35 | **The Latest Treatment Approaches for Uveitis**

*Walter Bethke, Editor in Chief*

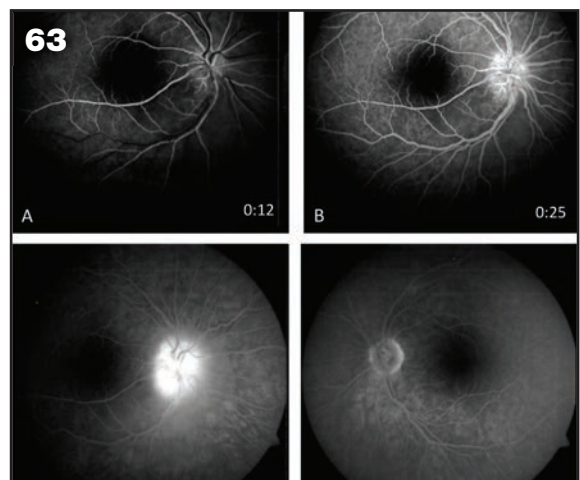


Don't hesitate to use immune-suppressing medications in severe patients, surgeons say.

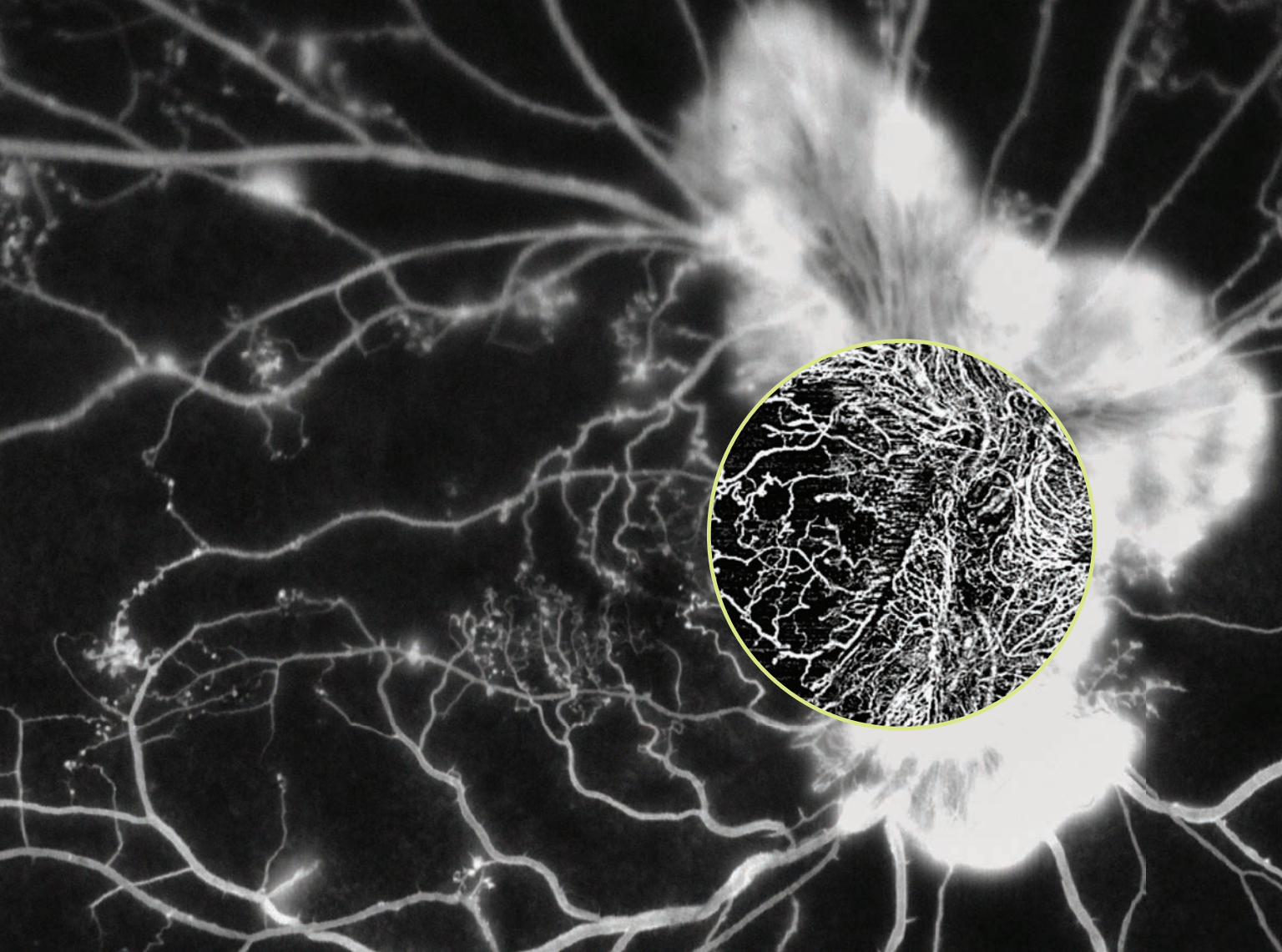


# Departments

---

- 5 | [Review News](#)
- 10 | [Editor's Page](#)  
**The Voice of the Doctor**
- 21 | [Medicare Q&A](#)  
**Billing for Patients Enrolled in QMB**  
This month, we take a look at QMB and how its billing procedures might affect your practice.
- 40 | [Research Review](#)  
**Cross-linking in Pediatric Keratoconus**
- 42 | [Glaucoma Management](#)  
**Premium Lenses, Cataract Surgery and Glaucoma**  
As technology improves and patient expectations rise, doctors treating glaucoma should consider offering premium options.
- 46 | [Therapeutic Topics](#)  
**Balancing Biomarker Applications**  
These indirect measures of therapeutic efficacy come with their own strengths and weaknesses.
- 52 | [Retinal Insider](#)  
**How to Interpret Clinical Trial Outcomes**  
Making sense of results from macular degeneration and diabetic macular edema trials.
- 60 | [Product News](#)  
**A New Option for Allergy**
- 62 | [Classifieds](#)
- 63 | [Wills Eye Resident Case Series](#)
- 66 | [Ad Index](#)





# Making the revolutionary, routine.

## ZEISS AngioPlex™ OCT Angiography



### A new era in retinal care—right now.

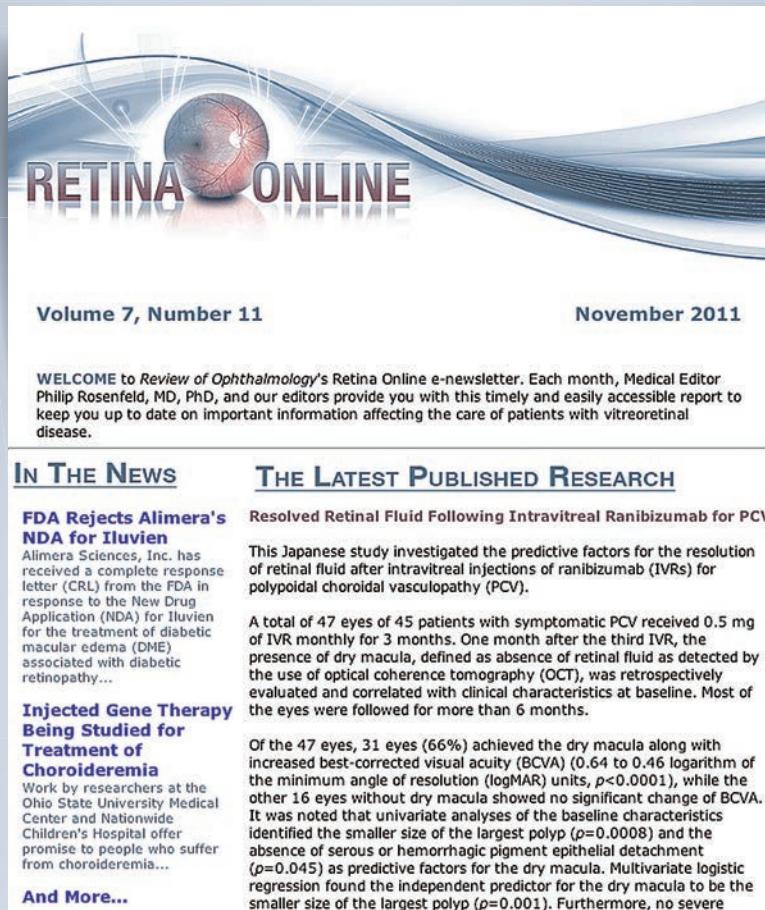- New vascular information with ultra-clear 3D microvascular visualizations
- Enhanced workflow with non-invasive, dye-free, single-scan angiography
- Advancing OCT with the powerhouse ZEISS CIRRUS™ HD-OCT platform

Visit [www.zeiss.com/us/octangio](http://www.zeiss.com/us/octangio) to learn more.



# RETINA ONLINE

## E-NEWSLETTER



Once a month, Medical Editor Philip Rosenfeld, MD, PhD, and our editors provide you with timely information and easily accessible reports that keep you up to date on important information affecting the care of patients with vitreoretinal disease.

**3 EASY WAYS TO SUBSCRIBE!**

<http://www.jobson.com/globalemail/>

Fax: 610.492.1039 or Call: 610.492.1029

**REVIEW<sup>®</sup>**  
of Ophthalmology



# Billing for Patients Enrolled in QMB

This month, we take a look at QMB and how its billing procedures might affect your practice.

## **Q** What is the Qualified Medicare Beneficiary Program?

**A** The QMB program is a Medicare Savings program that exempts Medicare beneficiaries from Medicare cost-sharing liability. Established as part of the Medicare Catastrophic Coverage Act in 1988, the program is a state Medicaid benefit that covers Medicare deductibles, co-insurance and co-payments.

Federal guidelines set an eligibility floor based on the federal poverty level and the value of a beneficiary's resources. States can choose to make these limits more generous and include more beneficiaries in their programs, in the same way that they can expand welfare benefits. In some states, the QMB program also pays the beneficiary's Medicare premium, especially where there are dual-eligible managed-care plans.

## **Q** Is it important for practices to identify QMB-enrolled patients?

**A** Yes. Under federal law, patients enrolled in the QMB program are exempt from liability for Medicare deductibles, co-insurance or co-payments. QMB applies to all Part B, Part C and DMEPOS claims. Balance-billing QMB-enrolled patients would be a violation of your Medicare provider agreement and could subject you to sanctions. CMS published a "reminder" MLN Matters SE1128 (Revised) on May 12, 2017, which "... reminds all Medicare providers that they may not bill beneficiaries enrolled in the QMB program for Medicare cost-sharing."

## **Q** Do QMB program limitations apply to Medicare Advantage Plans?

**A** Yes. The QMB program applies to Medicare Advantage (Medicare Part C) patients as well as those enrolled in regular Medicare (Part B). You may not collect an Advantage Plan co-payment from a QMB program enrollee.

## **Q** Are non-participating Medicare providers subject to the QMB program rules?

**A** The QMB program applies to all Medicare providers, both participating and non-participating. Further, you are obliged to accept assignment on all services to these patients, even if you would not do so otherwise. By accepting assignment, you agree to accept the Medicare and Medicaid payment as payment in full, regardless of whether Medicaid pays or not.

## **Q** If we are not Medicaid providers, are we required to adhere to the QMB program rules?

**A** Even if you are not enrolled as a Medicaid provider, you are still subject to the QMB program limitations. Because Medicaid won't pay you if you aren't enrolled, Medicare cost-sharing balances must be written off and may not be billed to QMB program enrollees.

## **Q** What if Medicaid does not pay even though we are enrolled providers?

**A** Even if Medicaid doesn't reimburse, you remain prohibited

from charging QMB program individuals for Medicare cost-sharing and must write off the balance. It's not uncommon to find that states set their fee schedules at or below the Medicare payment amount, limiting the state's liability to providers.

**Q How do we identify patients enrolled in the QMB program?**

**A** The May 12, 2017 transmittal states the following regarding ways to improve processes related to QMBs.

*“Determine effective means to identify QMB individuals among your patients, such as finding out the cards that are issued to QMB individuals, so you can in turn ask all your patients if they have them. Learn if you can query State systems to verify QMB enrollment among your patients. MA providers should contact the plan to determine how to identify the plan's QMB enrollees. Beginning October 1, 2017, you will be able to readily identify the QMB status of your patients with new Medicare Fee-For-Services improvements. Refer to Fee-For-Service Claims Processing System for more information about these improvements.*

**Q Are there any indicators on our Remittance Advice to identify QMB program patients?**


**A** Yes, there are three RA codes to look for when claims are paid.

- N781 – No deductible may be collected.
- N782 – No coinsurance may be collected.
- N783 – No co-payment may be collected.


Each of these also instructs

you to “Review your records for any wrongfully collected amounts above.”

**Q If the patient we're seeing is from out of state, does QMB status still apply to us?**



*Under federal law, patients enrolled in the QMB program are exempt from liability for Medicare deductibles, coinsurance or copayments.*



**A** Yes. QMB program enrollees retain their protection against cost-sharing when they cross state lines to receive care. You may not balance-bill QMB program patients even if their Medicaid is provided by a state other than the state in which care is rendered.

**Q May a patient choose to waive his QMB status?**

**A** No. QMB patients cannot choose to waive their QMB status and pay Medicare cost-sharing. One exception may be for explicitly non-covered services (i.e., cosmetic services or refractive care). Prior to seeking payment from patient for these non-covered services, be certain that

their plan (Medicare, Medicaid or MA) considers these services non-covered. Best practice would be to secure something in writing from the plan and from the patient acknowledging his financial responsibilities.

**Q Are Medicaid billing processes the same from state to state?**

**A** No. You need to determine the process to bill Medicaid for reimbursement of the beneficiaries' cost-sharing. Different processes may apply for QMB program beneficiaries. Most states have electronic processes with regular Medicare so these claims automatically cross over to Medicaid. If crossed over, it is noted on the Medicare remittance advice. In order to receive payment, you must be enrolled as a Medicaid provider.

**Q What steps should we take to be compliant with QMB program rules?**

**A** Staff should be able to identify enrolled patients and designate them as QMB-program-enrolled patients in the practice's billing software system. With the appropriate flag in the system, these patients should not be asked to pay deductibles, co-payments or co-insurance amounts, or be included in the practice's collection efforts. **REVIEW**

*Ms. McCune is the Executive Director for the Society for Excellence in Eyecare. Contact her at [DonnaMcCune@outlook.com](mailto:DonnaMcCune@outlook.com).*



# QUALITY

FOR YOUR ENTIRE OFFICE NEEDS

AAO BOOTH 3030



ORVOS EXAM ENVIRONMENTS  
BY THE EYE DESIGNS GROUP  
ORVOSEXAMS.COM

# Easing the Burden of AMD Treatment

*Christopher Kent, Senior Editor*

How to minimize the burden of anti-VEGF injections — for both patients and practices — without harming the patient.

As frequent intraocular injection of anti-VEGF drugs has become increasingly common, the issue of optimizing this expensive and burdensome process has become a major concern. Over time, the protocol known as treat and extend—in which the macula is treated monthly until dry, followed by a gradual increase in between-treatment intervals until a maximum safe interval has been determined—has become accepted as the best option. However, it continues to evolve and be refined.

Here, three experts share their current experience and thoughts on the most effective ways to use the treat-and-extend approach.

## Setting the Interval

“Managing macular degeneration is a balancing act between overtreating and undertreating,” says Carl Regillo, MD, FACS, a professor of ophthalmology at Thomas Jefferson University and director of the Retina Service at Wills Eye Hospital. “I’d say the greater of the two evils is undertreating, because if you’re not on top of the disease, the vision gains you get early on in treatment are likely to be lost to some degree.

“There’s a lot of real-world management data that shows a mean vi-

sual acuity decline in wet macular degeneration patients over years in the course of treatment,” he continues. “On the other hand, there’s also data showing that it’s possible to maintain those vision gains. In fact, there’s now some data from the prospective, controlled TREX AMD study that suggests that treat and extend used for two years compares favorably to the gold standard monthly anti-VEGF injection technique, in terms of maintaining vision gains. However, in order to achieve that level of effectiveness you have to have a low threshold for treating. You need to average a relatively high number of treatments per year, and compliance with follow-up has to be good.”

Dr. Regillo says he begins treatment with several monthly injections, regardless of which anti-VEGF drug he’s using. “I treat monthly until the macula is as good as I can get it,” he says. “Once I’ve reached that point, I’ll try to extend, usually by two-week intervals. As long as nothing is worsening and we’re able to maintain the vision gains, I’ll usually cap the extension at about 12 weeks. With today’s drugs, 25 or 30 percent of patients make it out to 12 weeks; the rest are maintained at a more frequent interval that’s specific to their needs. That might be as frequent as every four



weeks, although most patients end up in the six- to eight-week range. It's rare that a patient requires treatment more frequently than every four weeks."

Dr. Regillo says he'd like the macula to remain completely dry, but he'll sometimes tolerate small amounts of subretinal fluid. "Generally, the deeper the fluid, the better it's tolerated, especially if it's a small amount and it's not changing over time," he says. "If a small sliver of subretinal fluid doesn't go away after three consecutive monthly treatments, I'll think about extending. You can certainly tolerate some degree of pigment epithelial detachment, if that's present. If I extend and the fluid gets worse, I'll go back to a more frequent interval. Sometimes I'll even bring patients in more frequently than every four weeks to see if they're responding adequately, or if the drug is wearing off quickly."

Hemorrhages are also a reason to adjust treatment. "A new hemorrhage is an indication of new activity, and it will prompt me to reduce the interval," says Dr. Regillo. "If it's just a small hemorrhage and vision isn't affected much, I'll go back to the previous disease-free interval. But if it's a big hemorrhage—or for that matter, any major setback—I'll go all the way back to a four-week interval and maintain the patient there until the macula gets back to being as good as possible. Unfortunately, with a large hemorrhage the patient may not regain all of the lost vision.

"In this situation I'm much more cautious about re-extending, especially if the setback was a large hemorrhage," he adds. "I'll also speak to the patient's primary care provider to see if the patient is at risk for bleeding because of the use of anti-platelet or anti-coagulant agents such as aspirin, Plavix or Coumadin, and I'll work with those doctors to balance the systemic and ocular risks. Some retinal specialists will keep a patient who has had a big bleed at frequent injection intervals.

I've done that too, especially if the patient had a bad outcome in the fellow eye and has to stay on blood thinners, for example. After a large hemorrhage I may not extend that patient at all."

*"Every study we've seen has shown that the lower the number of injections—especially during the first year—the worse the outcome."*  
—Peter K. Kaiser, MD

Peter K. Kaiser, MD, the Chaney Family endowed chair in Ophthalmology Research and professor of ophthalmology at the Cleveland Clinic Lerner College of Medicine, Cole Eye Institute, says he'll extend the interval out to three or three-and-a-half months, depending on the type of lesion the patient has and the drug he's using. "I might go to the longer end of the spectrum with a type 1 lesion," he says. "The exception would be a patient with polypoidal choroidal vasculopathy who has had a major bleed in the fellow eye. For those patients, I use shorter intervals. I also keep the interval shorter with type 2 or type 3 lesions because they are more likely to produce a sudden decrease in vision from rapid activity or a bleed.

"Generally speaking, I'm wary of going beyond the amount of time that the drug has biologic activity," he adds. "I generally can go longer with aflibercept than ranibizumab or bevacizumab."

## DME and RVO

"Treating diabetic macular edema

or retinal vein occlusion is a little different," notes David M. Brown, MD, FACS, who practices at Retina Consultants of Houston and helped design many of the major trials involving anti-VEGF agents. "Diseases like DME and RVO are inner-retinal diseases, diseases predominantly of the inner capillary and inner plexiform layers. You can have recurrent edema in those areas without having catastrophic vision loss. So in a diabetic patient I do my best to eliminate fluid, but I'm much more tolerant of allowing a recurrence.

"With DME, I don't necessarily treat with anti-VEGF if your fovea is dry with a nice foveal reflex and the only edema is outside the fovea," he continues. "In that situation I treat until the foveal reflex is restored and extend when the fovea is dry. RVO and DME patients typically regain lost vision when the edema is resolved with the next injection. In contrast, macular degeneration is a disease of the retinal pigment epithelium and Bruch's membrane and the photoreceptors. You can't afford to repeatedly damage those areas, because photoreceptors don't regenerate."

"Diabetic macular edema is very different from macular degeneration," agrees Dr. Regillo. "With DME, you're treating abnormally leaking retinal blood vessels, not abnormal blood vessels that are growing and invading and destroying the RPE. So for DME, my approach is PRN. I treat until the macula is dry, and then I watch and wait. DME patients tolerate small recurrences relatively well, unlike wet macular degeneration."

Dr. Regillo points out another difference between macular degeneration and DME: the time it takes to get the macula dry. "With wet macular degeneration, you can get the macula dry, or mostly dry, after three or four monthly injections in the majority of patients. DME tends to be slower to respond, so you tend to need a longer

## Should You Worry About Macular Atrophy?

Peter K. Kaiser, MD, a professor of ophthalmology at the Cleveland Clinic Lerner College of Medicine, Cole Eye Institute, says he believes the jury is still out regarding a possible association between anti-VEGF agents and macular atrophy. “The CATT and IVAN studies, and even the HARBOR studies, have shown an increase in the amount of macular atrophy after many injections,” he says. “Like IOP increase, this happens in the setting of an increased number of injections, regardless of the drug. We know that VEGF is neuroprotective, so it’s conceivable that blocking it could lead to atrophy. But another plausible explanation is that as lesions are dried up by the anti-VEGF agent, that allows us to see the underlying dry macular degeneration progress. The macular atrophy could be progressing irrespective of the anti-VEGF injections. If I do see a patient starting to develop atrophy, I’ll try to limit the number of injections as much as I can, but I certainly don’t stop them. I’m more concerned about choroidal neovascularization than atrophy.”

David M. Brown, MD, FACS, who practices at Retina Consultants of Houston, says that while he appreciates the circumstantial evidence that seems to associate these injections with macular atrophy, he’s never been a firm believer. “I don’t think we’ve ever seen solid evidence that these drugs cause geographic atrophy,”

he says. “You never see it in diabetic patients or retinal vein occlusion patients, even after hundreds of injections. This could be an association that’s not causal, like ice cream sales correlating to basal cell carcinoma. People get basal cell carcinoma where it’s hot and sunny, and that’s where you eat ice cream. It doesn’t mean that ice cream causes basal cell carcinoma.”

“[The data suggesting an association] certainly means we should be cautious, but it doesn’t mean that we should hold back on anti-VEGF therapy,” agrees Carl Regillo, MD, FACS, director of the Retina Service at Wills Eye Hospital. “In those studies, the patients who got more treatment generally had better vision outcomes even with the atrophy. Furthermore, we don’t have proof of cause and effect. So I don’t let that possible connection affect what I do. If you cut back because you think the treatment might be promoting atrophy, you’re probably going to end up with suboptimal neovascular control. That’s likely to cause more harm than the atrophy itself in most patients. However, this concern is a good reason to avoid overtreatment. Putting everyone on a fixed monthly treatment regimen, for example, would be overtreatment, and that’s clearly not necessary.”

—CK

time frame to achieve a relatively dry macula—sometimes up to a year or more. However, after the first year DME patients tend to need a lot less treatment to keep the macula edema-free; the likelihood of having a recurrence goes down, so in most cases you can take them off treatment or switch them to very infrequent treatment. With wet macular degeneration, you usually need eight or nine injections in year one, and then six or seven in year two and beyond to maintain those vision gains. For DME it may be a similar number of treatments in the first year, but the average drops to just three or four in year two, and even less thereafter, according to several PRN treatment-based DME studies.”

Dr. Regillo adds that in many cases using treat and extend with DME patients wouldn’t reduce their treatment burden. “You’re going to be seeing diabetic retinopathy patients pretty frequently anyway, because you’re monitoring other aspects of their retinopathy,” he says. “So you’re not

reducing the burden by using a treat-and-extend approach.”

### Treatment Alternatives

Doctors agree that in some situations it may make sense to switch to PRN treatment or stop injections altogether.

- **Treating PRN instead.** Dr. Brown says that in a few cases he may be willing to shift treatment to PRN. “If I’ve extended the interval past 10 weeks and the patient is binocular, or is really anxious to stop having injections, I may switch to PRN treatment,” he says. “However, you have to be careful because if you get rid of one weed in your garden, another weed is likely to pop up. You can calm neovascularization down, but a lot of the time those patients get recurrent leakage.”

Dr. Brown says he appreciates that many surgeons don’t believe that it’s ever safe to switch to PRN when treating macular degeneration, but he notes that there’s no data showing that

Lucentis or Avastin lasts more than 10 weeks. “Eylea may or may not last longer than that,” he says. “We don’t have the data. But we have good data on Lucentis, and if the patient is coming in every 12 weeks, that patient is going naked for two weeks. And I’ve never had a patient who could go 12 weeks but not 13. On the other hand, we have a lot of patients who can go for eight weeks but not 10. That’s why, if I’m going to continue the drugs, 10 weeks is my maximum interval for Lucentis and eight weeks is my maximum for Avastin. Eylea seems to have a little more durability in the short run, but there’s not a lot of data to confirm that.”

- **Stopping because the patient seems to be “regressed.”** Dr. Regillo says that when he was first using these drugs he would sometimes stop the injections when a patient was successfully extended to 12 weeks without incident. “I thought that if we got the patient out to 12 weeks the drug was probably not having any significant

residual anti-VEGF effect,” he says. “I figured that the choroidal neovascularization was ‘regressed’ and didn’t need ongoing therapy. But published papers and personal experience have shown that most patients inevitably do recur, and every time you have a recurrence, you can have a setback that the patient may never fully recover from. So today I very rarely stop treatment, especially if a patient is doing well.”

Dr. Kaiser says he also rarely stops treatment. “If I can get patients out to three or three-and-a-half months and they remain dry for a year of extended intervals, then I’ll try getting them off the drug,” he says. “This is rare, but it does occasionally happen. However, if I do stop the injections, I’m going to bring those patients back in a month—i.e., four months after the previous injection—because I’ll want to watch them more closely.”

• **Stopping because treatment is futile.** “In wet AMD, if the patient starts to develop disciform scars or subretinal fibrosis, that means there is permanent damage to the photoreceptors,” notes Dr. Kaiser. “At that point there’s minimal visual acuity left to save, so we usually don’t continue treatment unless it’s the patient’s only eye. We might also discontinue treatment if the patient has a large subretinal hemorrhage that’s caused damage to the photoreceptors. In that situation it’s also unlikely that continued anti-VEGF is going to be all that beneficial.”

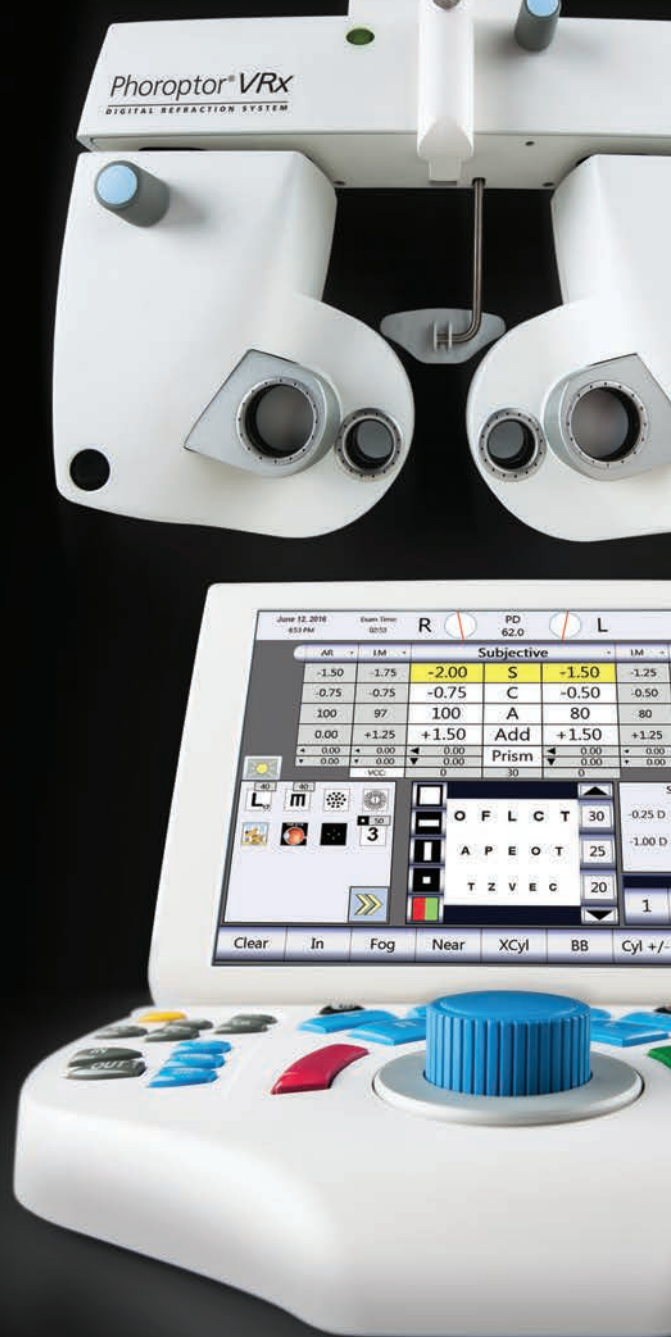Dr. Regillo says he’ll sometimes stop treatment because there’s some doubt as to whether the macular disease was ever truly neovascular. “There are a variety of conditions that can masquerade as neovascular macular degeneration, such as central serous chorioretinopathy and serous pigment epithelial detachments,” he notes.

## Treatment Strategies

When deciding on a course of treatment for your patient:

• **Make sure you have the right diagnosis.** “I think the biggest mistake clinicians make is not making sure they have the right diagnosis at baseline,” says Dr. Kaiser. “At the Cleveland clinic, as a tertiary-care center, we see a lot of patients who’ve been getting injected for diseases that are not macular degeneration and who don’t need the treatment. Thankfully, most of these patients weren’t harmed by the injections.”

Dr. Kaiser says he encounters patients with diseases that mimic macular degeneration fairly often. “For example, chronic central serous chorioretinopathy can mimic neovascularization in older patients,” he says. “That condition is different from macular degeneration in that the choroid is very thick; in macular degeneration the choroid is usually thin, except in polypoidal choroidal vasculopathy patients. In CSC, the fluid doesn’t respond at all to treatment with



# The most advanced Phoroptor® ever built.

## Phoroptor® VRx Digital Refraction System

Incredibly fast. Ultra-quiet. Effortless integration.  
Made in the USA with premium components.

Watch the video at [reichert.com/vrx](http://reichert.com/vrx)

**Reichert**  
TECHNOLOGIES

**AMETEK** © 2017 AMETEK, Inc. & Reichert, Inc. (5-2017) - Made in USA

Phoroptor is a registered trademark of Reichert, Inc. • [www.reichert.com](http://www.reichert.com)



## How Helpful is OCT Angiography?

As OCT angiography has become increasingly available, doctors are exploring its usefulness in different areas, including managing the progression of problems such as choroidal neovascularization.

Peter K. Kaiser, MD, a professor of ophthalmology at the Cleveland Clinic Lerner College of Medicine, Cole Eye Institute, says he's using OCT angiography in connection with anti-VEGF injections more frequently as time goes by. "In particular, we like the OptoVue device and the new swept-source OCT angiography devices from Zeiss," he says. "I find that this technology allows me to detect activity more easily, as well as the extent of the neovascularization, without having to do fluorescein angiography. OCT angiography gives us the same amount of information with a very quick turnaround."

"We do use more and more OCT angiography, but that doesn't show you cysts in the retina or definite activity," notes David M. Brown, MD, FACS, who practices at Retina Consultants of Houston. "It just shows me patent vessels. Nevertheless, OCT-A has a lot of promise."

Carl Regillo, MD, FACS, director of the Retina Service at Wills

Eye Hospital, says he uses OCT-A occasionally. "It's not an established diagnostic tool yet," he notes. "I'll use it when I'm trying to distinguish wet macular degeneration from one of the masquerade syndromes. Occasionally, I'll use it to determine whether the choroidal neovascularization is increasing in the course of treatment—in other words, whether or not I have the condition under control. It's easy, fast and noninvasive, and that is the advantage over a fluorescein angiogram in this setting."

Dr. Kaiser believes most ophthalmologists will eventually be using OCT-A. "It's useful not only for following choroidal neovascularization but for diagnosing masquerade syndromes and looking at ischemia in diabetic and retinal vein occlusion patients," he says. "We can often see things more clearly because there's no leakage of the dye to obscure what we're looking for. Furthermore, as the scan size becomes larger and the en face image grows, this technology will really compete with fluorescein angiography."

[To learn more about OCT-A, see "How to Get the Most From OCT-A" on page 34.]

—CK

anti-VEGF agents.

"Another problem that mimics macular degeneration is vitelliform dystrophy," he continues. "Those patients have what looks like neovascularization and subretinal fluid, but again, they won't respond to anti-VEGF treatment. In these cases, having an OCT-A instrument is useful because it can definitely help you differentiate between true wet macular degeneration and masquerade syndromes."

- **Don't undertreat.** Dr. Regillo says he believes the biggest mistake doctors make is occasionally undertreating. "If you look at real-world data, the mean number of treatments after year one tends to be lower than what studies with good outcomes would suggest it should be," he points out. "Of course, this doesn't imply that it's the doctor's or patient's fault, per se. Often it's other health problems that keep the patient from following up as recommended. DME patients are often younger, so compliance could be a bigger issue there."

Dr. Brown agrees. "It's human nature to empathize with the patient,"

he says. "It's easy to think, 'Oh, the patient really doesn't want to be coming back this often. Maybe I'll allow a little fluid and extend a little longer.' Sometimes it's a reaction to having so many patients in the waiting room. The problem is, any time you undertreat, you leave vision on the table."

"Every study we've seen to date has shown that the lower the number of injections—especially during the first year—the worse the outcomes are," adds Dr. Kaiser. "Being aggressive with treatment to get the neovascularization under control quickly is important."

- **Avoid extending too far if the patient has a lot at stake should vision loss occur.** "If some individuals get a hemorrhage or lose a line of vision, they could end up having to move into a nursing home and lose their independence," says Dr. Brown. "In that situation, I'm much more likely to treat and extend out to six weeks and see if we can keep it there."

- **Remember that it takes more injections to achieve results when managing DME.** "A lot of doctors

give up too soon, especially with DME," says Dr. Brown. "When treating macular degeneration, if you give four or five shots and the patient is still 'count fingers,' that patient is probably never going to improve. In contrast, with DME it can take eight or 10 or 12 shots to get the edema under control and improve the patient's vision. I tell my diabetic patients, 'It took you years to get into this shape; it's going to take me a while to dig you out.' They understand that."

- **Be cautious about re-extending the interval.** Dr. Regillo says that one result of his many years of experience with treat and extend is that he's much less inclined to frequently rechallenge the patient. "If a patient has fluid when I extend her to 10 weeks and I've brought her back to eight weeks, I'll probably keep her at eight weeks for a while," he says. "A lot of studies suggest that the disease-free interval remains pretty constant for a given patient.<sup>1</sup> Nevertheless, if everything is going well after six months or so and the patient is maintaining good vision, I will try extending again."

All-new!

• **Expect an occasional chronic IOP increase.** “A consistent increase in IOP after anti-VEGF injections is relatively rare, but it does happen,” says Dr. Kaiser. “I’d say it happens in fewer than 5 percent of our patients, and the IOP isn’t usually super-high; it’s manageable with IOP-lowering drops. If it starts to happen, we’ll reduce the number of injections as much as we can and try to use a longer-acting anti-VEGF agent.”

Dr. Brown notes that any injection adds volume to the eye. “Older eyes are less distensible,” he points out. “A harder, stiffer eye will be more likely to experience a pressure increase. As a result, a couple of phenomena may occur. Some patients will develop glaucoma. Other patients just get decreased compliance of the eyewall, causing their vision to gray out as the pressure rises. You do the injection and they say, ‘Doc, I can’t see.’ If that happens even once, we typically do an anterior chamber tap before each subsequent injection, taking out about the same amount of fluid I’m going to put in. I do the same thing with my glaucoma patients, and for patients with suspicious optic nerve heads.”

## Clinic Strategies

To maximize your efficiency when dealing with a large number of patients needing injections:

• **Consider using alternating treatment-only visits.** “For wet macular degeneration patients who can’t be extended much beyond six weeks, if everything has been constant in their pattern of treatment, I’ll schedule alternating treatment-only visits,” says Dr. Regillo. “That means that when they come in for their next visit, they don’t get an exam. They get their vision tested and get the OCT for me to look at to make sure the macula is still in an optimal state, and then they go right to the treatment room. They don’t get a formal examination unless they’ve had a change in their vision or the OCT shows something new. On any given day I may have five or six of these treatment-only visits. It’s a much faster encounter, and it eases the burden on both sides.”

Dr. Kaiser says he also moves to this type of format, usually after a few visits with a full exam. “It depends where the patient is in the process,” he says. “Early on, we’re much less likely to do it, but as we continue to see the patient, we’re more likely to include those types of visits. The history we take is very abbreviated; we mostly make sure there are no adverse effects. Also, there’s usually no reason to do extensive visual acuity testing or refraction at those visits.”

“The clinical exam is overutilized by some doctors,” agrees Dr. Brown. “They do it every time. It’s pretty un-  
(Continued on page 41)



# Pixel-perfect acuity testing.




**ClearChart® 4 · 4X · 4P Digital Acuity Systems**

Simple-to-use interface. 24-inch, LED backlit display.  
Custom developed for acuity testing. Made in USA.

See the full line at [reichert.com/clearchart](http://reichert.com/clearchart)

**Reichert**  
TECHNOLOGIES

**AMETEK** © 2017 AMETEK, Inc. & Reichert, Inc. (5-2017) - Made in USA

ClearChart is a registered trademark of Reichert, Inc. · [www.reichert.com](http://www.reichert.com)   

# How to Get the Most from OCT-A

*Michelle Stephenson, Contributing Editor*

Although it's not yet a mature technology, OCT-A is already providing valuable information about retinal vascular disease.

Optical coherence tomographic angiography allows surgeons to visualize retinal microvasculature without the need for injecting fluorescein contrast dye. It's a fast, noninvasive way to assess retinal structures at a microscopic level. Fluorescein angiography remains the gold standard for imaging retinal structures, but it's invasive, expensive and time-consuming.

"OCT angiography is in its infancy, but we're already finding that it gives us tremendous information about retinal vascular disease, such as branch vein occlusion and diabetic retinopathy, and it's extremely helpful for the diagnosis of wet macular degeneration," says David Boyer, MD, clinical professor of ophthalmology at the USC/Keck School of Medicine and partner at Retina Vitreous Associates Medical Group in Los Angeles.

Thomas Stone, MD, partner and chairman at Retina Associates of Kentucky, says that his practice is using it in three primary settings: retinal vascular disease; choroidal neovascularization; and select uveitis patients.

"In retinal vascular disease, like diabetes and vein occlusion, we use it if we are trying to determine macular perfusion in a patient," Dr. Stone says. "To help us with visual prognosis, we'll use OCT angiography in place of fluo-

rescein angiography. With choroidal neovascularization, we have patients in whom we are not sure whether the change on their standard OCT or the change in their vision is a progression of dry AMD or a new development of an early choroidal neovascularization. This is true in both macular degeneration and ocular histoplasmosis. We feel that, with OCT angiography, we are able to identify whether there is some flow through these active vessels rather than just a scar."

According to Dimitra Skondra, MD, PhD, assistant professor of ophthalmology at the University of Chicago and director of the J. Terry Ernest Ocular Imaging Center, "The amazing thing about OCT angiography is that it can reconstruct the information so that we can see blood vessels and blood flow in detail that we have never been able to see before without having to inject dye. We can get very valuable information about the vasculature. For the first time in imaging history, we can see all of the capillary plexi and the vasculature of the choriocapillaris in detail and in 3D reconstruction we were never able to see before. However, it's not here to replace fluorescein angiography, because fluorescein angiography provides information about the dynamic behavior of the vessels, like leakage and staining, and it can

image much farther out in the periphery as compared to OCT angiography,” she explains.

She adds that she uses OCT-A in almost all of her patients because it helps to provide more information for an accurate diagnosis, and it’s useful for showing how a patient is responding to treatment.

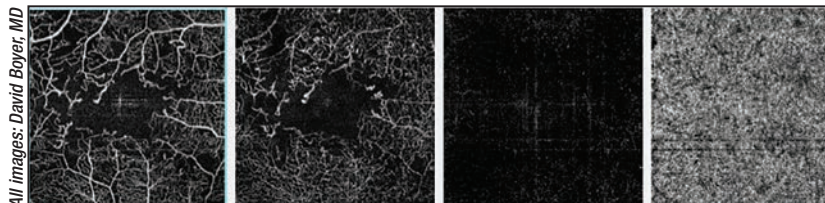
## Retinal Vascular Disease

One of the primary uses of OCT-A is in patients with retinal vascular disease. “For diabetic retinopathy, we can easily visualize the parafoveal capillary bed, and we can see the degree of ischemia very easily without doing an invasive fluorescein angiogram,” Dr. Boyer says. “In fact, it gives us more information and is better than a fluorescein angiogram as far as determining whether there is ischemia in the superficial or deep capillary plexus. You can’t really image the deep capillary plexus with fluorescein angiography, which is a common site for ischemia.”

The same is true with branch vein occlusion. “With OCT angiography, we can see areas of ischemia, and we can determine its scope,” Dr. Boyer says.

A recent study has found that OCT angiography can quantify the retinal capillary microvasculature in patients with diabetes and can potentially be used to study the effect of systemic risk factors on the microvasculature.<sup>1</sup> Previously, this was only possible using invasive techniques.

This prospective, observational study included 50 patients with type 2 diabetes with and without diabetic retinopathy. The researchers examined the retinal microvasculature with swept-source OCT angiography and semiautomated software to measure the capillary density index (CDI) and



Different depths of a retina with diabetic retinopathy imaged with OCT-A. Shown, from left to right, are the superficial, deep and outer retina, and the choriocapillaris.

fractal dimension (FD) at the superficial vascular plexus (SVP) and deep retinal vascular plexus (DVP). Additionally, they collected data on histories of patients’ glycated hemoglobin A1c, hypertension, hyperlipidemia, smoking and renal impairment.

The mean glycated hemoglobin A1c of the 50 patients, whose mean age was 59.5 years, was 7.9 percent. The mean CDI at the SVP was 0.358 in patients with no diabetic retinopathy and 0.338 in patients with proliferative diabetic retinopathy. Additionally, the CDI at the DVP was 0.361 in patients with no diabetic retinopathy and 0.345 in patients with proliferative diabetic retinopathy. The mean FD at the SVP was 1.53 in patients with no diabetic retinopathy and 1.60 in patients with proliferative diabetic retinopathy, and the mean FD at the DVP was 1.55 in patients with no diabetic retinopathy and 1.61 in patients with proliferative diabetic retinopathy. The following systemic risk factors were associated with a lower CDI: hyperlipidemia (odds ratio: 9.82), smoking (odds ratio: 10.90), and renal impairment (odds ratio: 3.72). The following systemic risk factors were associated with increased FD: increased glycated hemoglobin A1c ( $\geq 8$  percent) (odds ratio: 8.77) and renal impairment (odds ratio: 10.30).

## Choroidal Neovascularization

OCT-A has also been used in patients with choroidal neovascularization. “In cases where we are concerned about whether there is a choroidal neovascular membrane present, such as in retinal pigment epithelial detachment,

or in cases of type 3 choroidal neovascularization, such as a RAP lesion or polypoidal vasculopathy, with the en face imaging and the combination of the B-scans,

we’re able to pick up early changes and follow or treat them. It also gives us an opportunity to see the response to treatment. Many times, we will treat a patient who has some leakage and perhaps some hemorrhage, and the OCT in general shows an area of leakage but the blood blocks everything on fluorescein angiography. When we treat them, they get better, and the blood goes away. Now, we can go back and look at that area very carefully and sometimes determine that there are no signs of choroidal neovascularization. In some cases, we are then able to stop treatment,” Dr. Boyer says.

According to Dr. Stone, in cases of choroidal neovascularization, surgeons must look for a flow pattern in the choroid. “Flow, rather than an inactive scar, indicates that treatment is required,” he says.

Dr. Skondra says that using OCT-A for wet AMD masqueraders has revolutionized her practice. “These are cases where the OCT shows something very similar to AMD, but you’re unsure if it’s an active membrane or not and if it should be treated with an intravitreal injection or not,” she says. “In these cases, a fluorescein angiogram may not always provide a straightforward answer because many conditions produce findings in the angiogram that look exactly like AMD. So, in these cases, there may be a very small membrane that an angiogram cannot pick up, or the patient may have a small neovascular membrane that you’re missing. Delaying treatment may cost the patient vision. In other cases, OCT and fluorescein angiogram findings, like pattern dystrophies and central

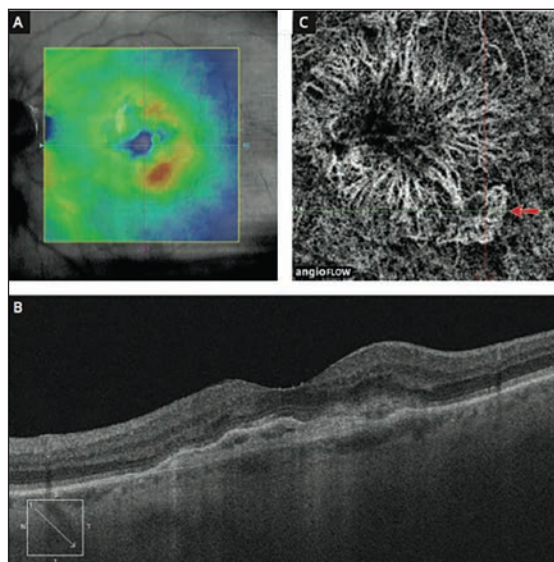
serous chorioretinopathy, may mimic wet AMD. Additionally, there is no neovascular membrane, and no intravitreal injections are needed. Many patients who were treated for wet AMD come to me for a second opinion. With the combination of information from the fluorescein angiogram, the exam, the OCT and the OCT-A, I can tell with confidence whether a patient has wet AMD and treat him or her with injections when needed, or just observe the patient if it is an AMD masquerader, preventing unnecessary injections.”

A recent study has found that OCT-A can be used to perform qualitative and quantitative analyses of neovascular lesions.<sup>2</sup>

These researchers believe that, in the future, OCT angiography may provide biomarkers of activity and guide the evaluation, treatment and monitoring of neovascularization in AMD.

Macular OCT-A images were obtained, and morphologic features and quantitative measurements of the neovascular lesion were analyzed, using en face projection images.

The study included a series of 31 eyes: 11 eyes had active neovascular lesions at baseline and after consecutive follow-up after treatment with anti-VEGF therapy, and 20 eyes had quiescent neovascular lesions. Morphologically, all the quiescent neovascular lesions and 63.6 percent of the active NV lesions demonstrated a prominent central vessel, and active lesions demonstrated a greater rate of small vessels branching (82 percent) and peripheral arcades (82 percent) than quiescent lesions (30 percent and 40 percent, respectively). This was statistically significant. The lesion area and vessel density weren't statistically significantly different after treatment or when compared to quiescent lesions, although quiescent lesions were reduced in area. Lesion pattern complexity was



In this patient, OCT showed minimal leakage and the OCT-A shows clearly defined CNV with new activity (arrow).

statistically significantly lower in the inner part of the lesion after treatment and in the total lesion of the quiescent neovascular lesion compared with the active neovascular lesions.

### **Uveitis**

OCT-A can also be used in patients with certain types of uveitis, such as Behçet's. In fact, a recent study found that OCT-A allows better visualization and characterization of perifoveal microvascular changes than fluorescein angiography in eyes with active Behçet uveitis.<sup>3</sup> The deep capillary plexus seemed to be more severely involved than the superficial capillary plexus.

In this prospective, comparative, cross-sectional study, patients presenting with clinically active Behçet uveitis involving the posterior segment were evaluated using FA, spectral domain optical coherence tomography, and OCT-A.

The study included 44 eyes of 25 patients. Perifoveal microvascular changes were more frequently observed on OCT-A (95.5 percent) than on FA (59.1 percent). Disruption of the perifoveal capillary arcade, areas of

retinal capillary nonperfusion/hypoperfusion, and perifoveal capillary abnormalities were observed more frequently using OCT-A than FA (40.9 percent vs. 25 percent, 86.4 percent vs. 34.1 percent, and 84.1 percent vs. 36.4 percent, respectively). Additionally, areas of retinal capillary nonperfusion/hypoperfusion were more frequently observed in the deep than in the superficial capillary plexus (81.8 percent vs. 63.6 percent).

### **The Future**

“OCT angiography is in its infancy and has some inherent problems, such as shadowing and other artifacts giving us false images,” says Dr. Boyer. “Companies are working to overcome these types of problems. In the future, as it becomes better and better, we'll be able to determine a greater degree of disease without doing any invasive treatment.”

Dr. Boyer notes that all of the machines are very good. “But, you can't just do OCT angiography without having an en face image or B-scans looking for areas of geographic atrophy,” he says. “Many times, patients will appear as if they have an area of choroidal neovascularization, but what you are really seeing is an area of geographic atrophy, not choroidal neovascularization. Remember that OCT angiography doesn't show leakage. Rather, it shows flow within vessels. In the beginning, practitioners may use OCT angiography as an adjunct as they become more familiar with the correlation between a fluorescein angiogram or indocyanine green and their findings on OCT-A. It has virtually eliminated the need for ICG angiography at this point. So, in some cases, it can visualize neovascularization without any signs of leakage before it can be seen on standard OCT.

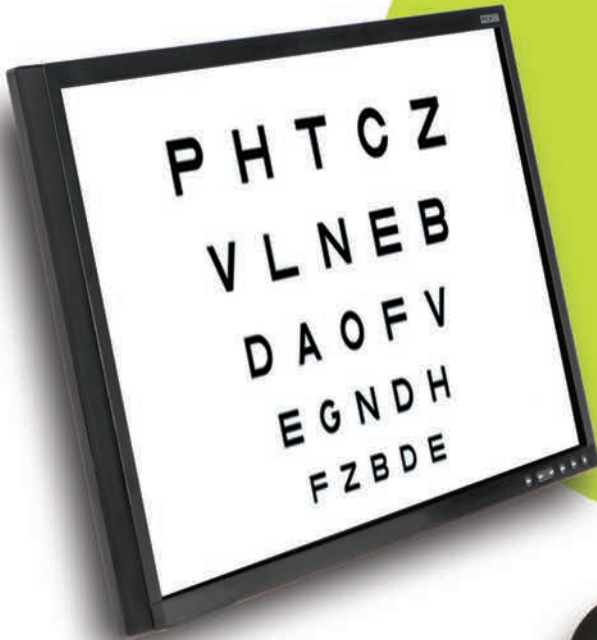*(Continued on page 59)*



# CVS Essential

The Lombart Visual Acuity System

Simple  
and Affordable.



The CVS Essential  
includes:

- Monitor
- HDMI Device with Acuity Software Program
- Luminous RF Remote
- Wall Mounting Bracket with Swivel

Only

**\$1,695**



2.4G RF Remote



Luminous Keypad



Acuity Systems don't have to be complicated. The CVS Essential proves they can be simple and affordable.

There are many visual acuity systems available in the market today. Many of these have features that often go unused and require extensive knowledge of their complicated remote controls to access them.

The *Lombart CVS Essential* unit was developed with the idea that an acuity system should be easy to operate, while still including the standard acuity charts commonly used in refraction. The *CVS Essential* provides quick access to charts and features, ease of installation and most of all ... is priced right!

The *CVS Essential* provides standard optotypes in a full range of Snellen Ratios. The remote control is easy to understand with quick access to all optotypes and smooth transitions when adjusting chart sizes. It offers a direct button for chart randomization as well as for Red/Green duochrome testing on all optotypes.

1-800-566-2278

**Call 1-800-Lombart**

Or Your Local Lombart Representative

Corporate Office - 5358 Robin Hood Road, Norfolk, VA 23513-2430  
757-853-8888 | FAX 757-855-1232 | 800-566-2278

[www.lombartinstrument.com](http://www.lombartinstrument.com)

[lombart@lombartinstrument.com](mailto:lombart@lombartinstrument.com)

Sales and Service Centers Coast to Coast

ATLANTA • BALTIMORE/WASHINGTON D.C. • BOSTON • BOYNTON BEACH/MIAMI • BRADENTON • CHARLOTTE • CHICAGO • CINCINNATI • DALLAS • DENVER • DETROIT • GREENSBORO • HOUSTON  
JACKSON • KANSAS CITY • KNOXVILLE • LOS ANGELES • MILWAUKEE • MINNEAPOLIS • NEW JERSEY/NEW YORK/PENNSYLVANIA • NORFOLK • PORTLAND • SAN ANTONIO • SAN DIEGO • SAN FRANCISCO



SAVE THE DATE

OCTOBER 13-14, 2017



# GLAUCOMA FELLOWS PROGRAM & WET LAB

Fort Worth, Texas

Dear Fellowship Program Director and Coordinator,

We would like to invite you to review the upcoming 2017 Glaucoma Fellowship Program and Wet Lab in Fort Worth at the Renaissance Worthington hotel. The program offers a unique educational opportunity for fellows by providing the chance to meet and exchange ideas with some of the most respected thought leaders in glaucoma. The Glaucoma Fellows Program and Wet Lab is designed to provide your fellows with a state-of-the-art didactic and wet lab experience. The program also serves as an opportunity for your fellows to network with fellows from other programs.

After reviewing the material, it is our hope that you will select and encourage your fellows to attend this educational activity which is CME accredited to ensure fair balance.

Sincerely,  
Postgraduate Healthcare Education

**Course Director:**

**Kuldev Singh, MD**  
*Stanford, CA*

**Wet Lab Directors:**

**Douglas J. Rhee, MD**  
*Cleveland, OH*

**Ronald Fellman, MD**  
*Dallas, TX*

**Faculty:**

James Brandt, MD  
Donald Budenz, MD  
Brian Flowers, MD  
Brian Francis, MD

Steven Gedde, MD  
JoAnn Giaconi, MD  
Dale Heuer, MD  
Cynthia Mattox, MD  
Felipe Medeiros, MD

Eydie Miller Ellis, MD  
Louis Pasquale, MD  
Harry Quigley, MD  
Angelo Tanna, MD

**For More Information & To Register:**  
[www.revophth.com/2017cseglaucoma](http://www.revophth.com/2017cseglaucoma)

Email: [dholmes@postgradhealthed.com](mailto:dholmes@postgradhealthed.com) or call Denette Holmes 866-627-0714

Participants in this course must be enrolled in a glaucoma fellowship program at the time of the course.

There is no registration fee for these activities. Air, ground transportation in Fort Worth, hotel accommodations and modest meals will be provided through an educational scholarship for qualified participants.

**Accreditation Statement**

This activity has been planned and implemented in accordance with the accreditation requirements and policies of the Accreditation Council for Continuing Medical Education (ACCME) through the joint providership of Amedco and Postgraduate Healthcare Education. Amedco is accredited by the ACCME to provide continuing medical education for physicians.

**Credit Designation Statement**

This activity has been approved for *AMA PRA Category 1 Credits™*.

Endorsed by

Review of Ophthalmology®

Jointly provided by



Supported by an unrestricted independent medical educational grant from

Alcon

# The Latest Treatment Approaches For Uveitis

Walter Bethke, Editor in Chief

Don't hesitate to use immune-suppressing medications in severe patients, surgeons say.

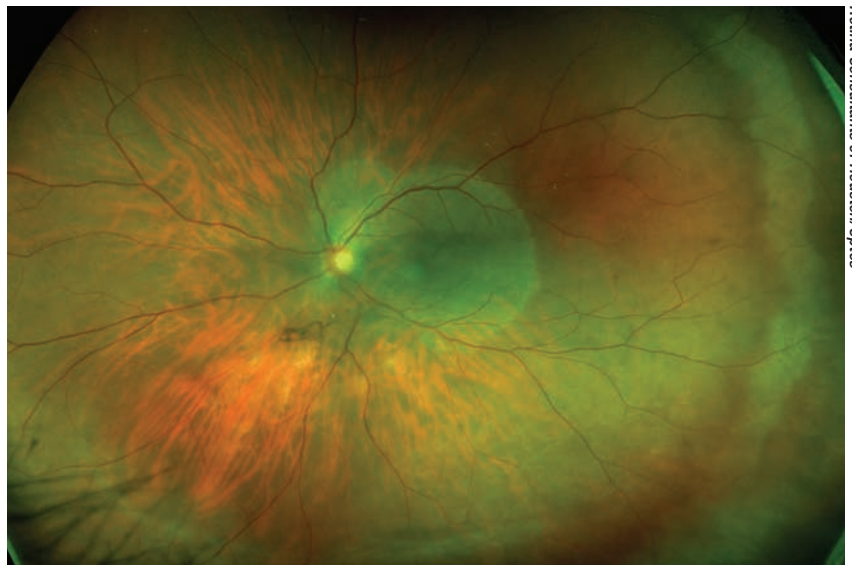
Since uveitis can be idiopathic or associated with many serious disease entities, the proper treatment approach is very nuanced, has to be tailored to the patient, and may continue for years. Also, the varieties of treatments for uveitis are almost as diverse as its causes, and carry some complications of their own, making for an apparently daunting therapeutic decision. It doesn't have to be intimidating, however, and experts say that a logical, stepwise approach to uveitis treatment can result in good outcomes. Here are experts'

top tips and techniques when faced with a patient with non-infectious intermediate, posterior or pan-uveitis.

## Initial Therapy

Here are the steps physicians take when managing a newly diagnosed uveitis patient.

First, physicians say to first make sure that you're dealing with a non-infectious uveitis. "My general approach is to first rule out infection with some targeted lab testing based on the patient's history and ophthalmic exam,"



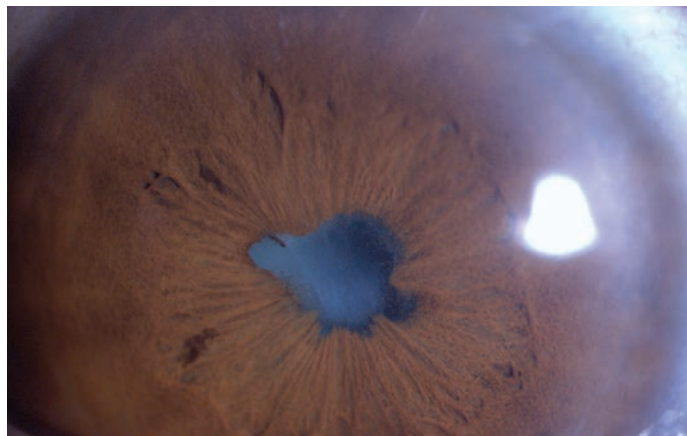Retina Consultants of Houston/Optos

After ruling out infection, physicians usually begin treating uveitis with corticosteroids, though they have a low threshold for upping the ante to immunosuppressive drugs.

explains Sam Dahr, MD, chairman of ophthalmology at Integris Baptist Medical Center in Oklahoma City. “Once I feel that there’s a reasonable chance that it’s not infectious, I’ll perform a trial of oral corticosteroids, and I’ll follow the patient especially closely for the first two weeks. If the patient worsens, I’ll then try harder to figure out if there is some sort of occult or atypical infection that I’m missing.”

Since pan-uveitis is the only variety that involves some anterior-segment inflammation, for these patients experts take steps to quiet the anterior inflammation first. “I first manage the anterior aspect of the disease, iridocyclitis, with aggressive topical therapy,” says Glenn Jaffe, MD, chief of retina at Duke University. “I generally treat every hour with Pred Forte or an equivalent, or with difluprednate (Durezol) at half that frequency, or q2h. With the Pred Forte, if there are fewer than 1+ anterior chamber cells, I might treat a little less frequently—for example q2h—but I usually like to treat aggressively, because I’ve found that if I treat aggressively in the beginning, it makes it easier for me to get the patient off the drops, as opposed to treating less aggressively and prolonging the treatment duration. I begin to taper the treatment once the anterior chamber is quiet.”

Dr. Dahr notes that physicians say the initial therapy almost always involves some corticosteroid therapy, and Dr. Jaffe agrees with that assessment. “For almost all the types of uveitis, the initial therapy usually will be corticosteroids in one form or another,” Dr. Jaffe says. “If, in addition, or as an alternative, I have made a decision to treat the patient with immunosuppressive therapy, I tailor the



In non-infectious uveitis, physicians usually quell anterior inflammation first before moving on to a therapy for the posterior segment.

immunosuppressive therapy to the specific type of uveitis. It’s important to remember that uveitis is a group of diseases—not one specific disease. Therefore, the treatment isn’t a ‘one-size-fits-all’ approach.

“For uveitis that affects the posterior segment, the first decision point is whether to use systemic or local corticosteroids. If the patient has bilateral disease or if they have disease that has a systemic component that would do well with corticosteroids, then I’m more likely—at least initially—to treat with systemic steroids, namely prednisone,” Dr. Jaffe continues. “Again, the dose I’d start with depends on the particular condition, and it’s usually in the neighborhood of 1 mg/kg/day, but will vary depending on the type of uveitis, as well as some patient factors. For example, some patients may not be able to tolerate systemic corticosteroids, such as a diabetic patient about whom you’d worry that you might worsen the diabetes with the steroid treatment; or a hypertensive patient. If they have asymmetric or unilateral disease, and they don’t have a systemic disease component that would do well with prednisone, or they are not likely to tolerate systemic corticosteroids, then I’d be more inclined to start local therapy. Local therapy options would include

a posterior sub-Tenon’s steroid injection or intravitreal steroids. However, I usually start with a posterior sub-Tenon’s injection. I can always go to an intravitreal injection later, if needed. As retinal specialists, we are almost programmed to treat people with intravitreal injections, but with a uveitis patient you can often achieve the treatment you need with a periocular steroid injection, which

has the advantages of less risk for endophthalmitis and/or an increase in intraocular pressure. Having said that, though, if the inflammation is severe, or if the patient doesn’t respond to a periocular steroid injection, I’d use an intravitreal steroid.” For the intravitreal steroid route, Dr. Jaffe says that, at this point in the therapy, he prefers either an intravitreal injection of triamcinolone acetonide (1 mg in 0.1 ml) or a short-acting sustained drug delivery system such as Ozurdex (dexamethasone implant), which lasts six weeks to three months.

• **Why steroids first?** Though there are several powerful drugs and drug delivery systems that can be brought to bear in uveitis, an initial course of steroids is considered the most prudent. “There are two reasons for giving steroids at the outset,” says Dr. Jaffe. “First, if it’s the patient’s first flare-up, you don’t necessarily know you’re going to have to treat chronically, even though many of these conditions are chronic. So, rather than commit the patient to a very long-acting implant or immunosuppressive therapy that takes several months to build up—and then you’re committing to treat him with it for years at that point—I’ll usually start with a steroid. The other reason is that steroids have a faster onset.”

## The Next Level

In certain situations, usually in the setting of recurrences or in serious diseases that need to be hit hard early on, physicians will move to systemic, steroid-sparing immunosuppressive therapy or possibly a long-term, sustained-release steroid implant.

“In certain presentations that are severe in the beginning and a form of uveitis that’s particularly serious, such as birdshot, Vogt-Koyanagi-Harada disease, Behçet’s or serpiginous chorioiditis—which are all forms that tend to recur and be blinding—I won’t wait for a recurrence,” says Dr. Dahr. “In those cases, I’ll go ahead and put them on systemic therapy from the beginning.”

In addition to these serious diseases in newly diagnosed patients, patients already on therapy may show signs that they need systemic treatment. Dr. Dahr says such signs include:

- anatomic sequelae such as progressive synechiae and iris bombe;
- steroid-induced increases in IOP;
- glaucomatous optic atrophy;
- cataract;
- vitreous opacity;
- uveitic macular edema;
- retinal capillary bed dropout;
- macular fibrosis associated with inflammatory CNV;
- loss of retinal pigment epithelium with associated retinal degeneration; and
- visual field loss.

If you move to the established immunosuppressive therapy, there are several families of drugs to choose from, each with its own dosing characteristics and mechanism of action:

- **Antimetabolites:** azathioprine (50 mg/day orally); methotrexate (usually 2.5 to 7.5 mg/week orally, occasionally subcutaneously delivered to reduce side effects) and mycophenolate mofetil (500 to 1,000 mg/day orally);

- **T-cell inhibitors:** cyclosporine

(50 to 100 mg/day orally) and tacrolimus (0.05 to 0.10 mg/kg/day orally); and

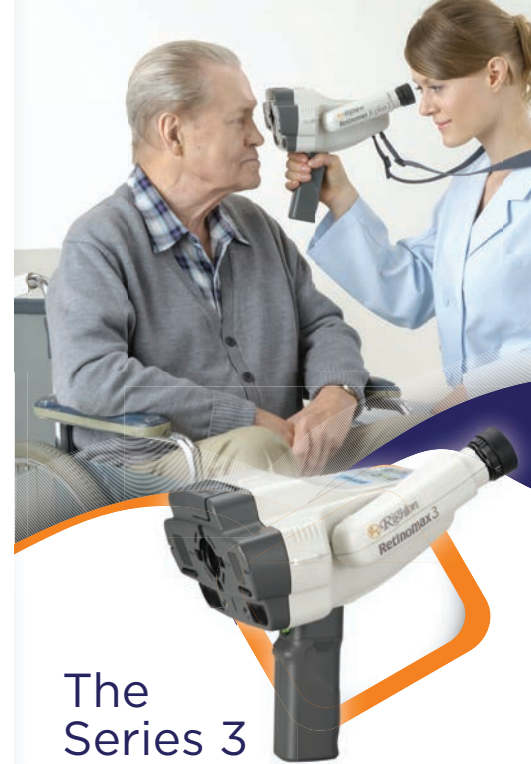- **Biologics:** infliximab (Remicade, IV infusion) and adalimumab (Humira; 80 mg initial dose, then 40 mg a week later, followed by 40 mg bi-weekly via self-administered, subcutaneous injection); and

- **Alkylating agents:** cyclophosphamide and chlorambucil (both usually oral, though they can be given via IV).

There is also the relatively new repository corticotropin injection Acthar. Though its mechanism of action is unknown, it stimulates the body’s production of steroids. There currently isn’t any clinical trial data for Acthar’s use specifically for uveitis, though its maker, Mallinckrodt Pharmaceuticals, is conducting further investigations for the condition.

Dr. Dahr explains his approach to these immunosuppressive agents: “If I think a single drug will work in the beginning, then, in adults, I’ll usually start out with mycophenolate,” he says. “In children, I’ll often start with methotrexate. Then I’ll see how things evolve over time. If there’s the sense of a response but I think I need more of a therapeutic effect, I might add a second agent. Traditionally, this second agent was a T-cell inhibitor like cyclosporine or tacrolimus (Prograf). Lately, however, it’s been more often Humira because it gained FDA approval for uveitis. I usually don’t use Humira as my primary agent unless it’s Behçet’s disease, based on the findings of an expert panel.”<sup>1</sup>

If Dr. Jaffe feels the patient needs more than the initial steroid regimen, he chooses between an immunosuppressive medication and a long-acting drug delivery system. “If someone has unilateral or very asymmetric disease; if they can’t tolerate immune-suppressing medications; if they have a systemic condition in which immune-suppressive medications are contrain-



The  
Series 3

# RETINOMAX HAND-HELD Autorefractor

Precise measurements  
Anywhere - Anytime



- Accurate
- Fast
- Portable
- Efficient

 Righton

**S4 OPTIK**

250 Cooper Ave., Suite 100 Tonawanda NY 14150  
[www.s4optik.com](http://www.s4optik.com) | 888-224-6012

Sensible equipment. Well made, well priced.

For today’s modern office.

licated; or they don't have a systemic disease for which they require either immunosuppression or a steroid, then I think the Retisert (fluocinolone acetonide intravitreal implant, Bausch+Lomb/Valeant) would be a good option, because it lasts about three years.

"If they have a bilateral or systemic disease like sarcoid which would benefit from an immunosuppressive medication, then I'd go to the immune-suppressing medication," Dr. Jaffe adds.

If he goes the immune-suppressive drug route, Dr. Jaffe says he will tailor the specific agent for the patient's disease. "For intermediate uveitis and uveitis associated with sarcoidosis, methotrexate is my first-line agent," he says. "We've published a report on its efficacy in the latter category of patients.<sup>2</sup> Methotrexate tends to have a relatively low number of side effects, is given once a week and patients tolerate it well."

Dr. Jaffe uses the anti-metabolite mycophenolate mofetil (CellCept) and azathioprine (Imuran) for conditions such as birdshot chorioretinopathy, multifocal choroiditis and panuveitis. His typical dosing is 1,000-1,500 mg b.i.d. for mycophenolate mofetil and 150 to 200 mg/day for azathioprine. He may also give Humira in combination with methotrexate. "Humira is usually given in an initial dose of 80 mg and then, one week later, it's given 40 mg/every other week."

Drs. Jaffe and Dahr prefer to take a long-term view of uveitis treatment, especially if they're using immunosuppressive agents. "Usually, when we make the decision to start someone on an immune-suppressing medication, I go into it with the idea that I'm going to try and treat him for at least two years, if possible, before deciding to start tapering it," Dr. Jaffe says. "This is because there's some evidence that if you treat someone for two years—at least in some forms of uveitis—it'll

lessen the chance that the uveitis will recur.

The other thing is, with most of these drugs—especially methotrexate—unlike corticosteroids, they don't have a very rapid effect. It takes weeks for them to build up in the system. For example, with methotrexate, it can take between eight and 12 weeks before you reach the full, effective dosing level. And, if you increase the dose, it can take another eight to 12 weeks for it to reach the new dosing level. Therefore, it wouldn't make sense to go into this thinking you're going to treat someone for four to six months, because it takes most of that time just to get the patient up to full drug levels."

If there's no response to the therapy or the disease appears to be progressing rapidly, Dr. Jaffe notes that there are even heavier-duty agents such as the alkylating agents cyclophosphamide and chlorambucil. "These are the drugs we use when nothing else is working," he says. "They can potentially cause serious side effects, including cancer, so we use them judiciously."

Dr. Dahr says the recently released results of the Multicenter Uveitis Steroid Treatment Trial help give physicians added confidence when they're considering starting systemic therapy in uveitis patients.

In the seven-year, prospective, randomized study, uveitis patients who received systemic steroids supplemented with immunosuppression had better visual acuity (by about 7.2 letters) than those randomized to receive intravitreal fluocinolone acetonide implants. "This doesn't preclude use of the Retisert," Dr. Dahr says. "But most of these cases are long-term patients, and you often have to think of a long-term game plan of five to 10 years. Over that longer time period, systemic therapy, per the results of the MUST study, probably gives you better outcomes."

## Possible Complications

Though many of these drugs are effective against uveitis, they do have potential side effects that could undermine your treatment efforts.

• **Corticosteroids.** "If we implant a Retisert and the patient is phakic in that eye, we'll usually remove the lens and place an intraocular implant at the time of the Retisert implantation," says Dr. Jaffe. "This is because we know the patient is going to need a cataract extraction down the road. And, the advantage of extracting the cataract when you put in an implant is that the latter keeps the eye quiet after surgery." With intravitreal injections, surgeons warn that there's a slight risk for complications related to the injection itself, such as intraocular infection (endophthalmitis), hemorrhage and retinal detachment.

Surgeons also note the possible complications of systemic steroid use, which include:

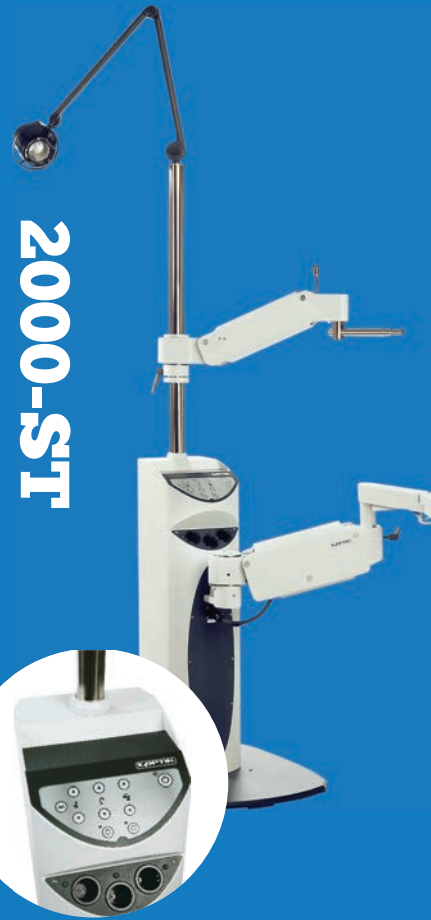- increased blood pressure;
- exacerbation of diabetes;
- bone loss;
- redistribution of body fat;
- hirsutism;
- acne;
- a variety of metabolic changes;
- weight gain;
- anxiety;
- psychosis;
- sleep disturbances; and
- tremors.<sup>3</sup>

The risk of these complications is one reason physicians prefer to have patients on 5 mg or less of a systemic steroid, and will move them onto a steroid-sparing agent if therapy will be necessary for a long period of time.

• **Antimetabolites.** Dr. Dahr says that, in the short term, the main issue with the antimetabolites is nausea. "They'll often have it for the first week or two, but it will often pass," he says. "If it doesn't, then you have to try another member of the antimetabolite family. Some patients will expe-

# S4OPTIK

## EXAMINATION STAND



2000-ST

**Modern design,  
built to last.**

**Add a superior achievement  
in engineering to your  
practice with the S4OPTIK  
2000-ST Instrument Stand**

Deliver efficient patient care with logically positioned, durable membrane switches for chair up/ down control and main power.

# S4OPTIK

250 Cooper Ave., Suite 100 Tonawanda NY 14150

[www.s4optik.com](http://www.s4optik.com) | 888-224-6012

Sensible equipment. Well made, well priced.

For today's modern office.

rience the nausea with mycophenolate mofetil, for example, but not with azathioprine. In the long term, watch their liver enzymes, white blood cell counts and hemoglobin. This is why you should get a complete blood count and a comprehensive metabolic panel every two to three months.”

• **T-cell inhibitors.** Dr. Dahr says that, with this family of drugs, you want to watch the patients’ liver enzymes, though there’s less risk of anemia or low white blood cell count. You also should monitor the patient’s blood pressure. “With cyclosporine, also watch for renal toxicity, low magnesium, elevated lipids and paresthesias,” Dr. Dahr adds.

• **Biologics.** Physicians say the primary concern when prescribing Humira is to ensure that the patient has been tested for tuberculosis, which is something the patient’s rheumatologist can usually help with.

“You have to be careful if you start a patient with intermediate uveitis on Humira because intermediate uveitis can be associated with multiple sclerosis,” warns Dr. Jaffe, “and this drug and the others in the tumor-necrosis-factor family can exacerbate pre-existing MS.”

### Future Therapies

There are some uveitis treatments in the pipeline that ophthalmologists may be gaining access to in the coming year or so.

• **Sirolimus (rapamycin, Santen).** This is an inhibitor of mTOR, or the mammalian target of rapamycin. It brings about immunoregulation by interrupting the inflammatory cascade through the inhibition of T-cell activation, differentiation and proliferation, and promotes immune tolerance by increasing regulatory T lymphocytes. Santen filed a New Drug Application for sirolimus with the Food and Drug Administration in April of 2017.

• **Durasert (fluocinolone acetate injectable implant, pSivida).**

This is a long-term steroid implant designed to release drug over a period of three years. According to Durasert’s maker, pSivida, in a second Phase III trial of the insert involving 153 patients, at six months, 22 percent of Durasert patients had a recurrence of their posterior uveitis vs. 54 percent of patients in a sham group ( $p < 0.001$ ). However, in terms of safety, the average IOP rise in the Durasert group was 2.4 mmHg, compared to 1.3 mmHg in the sham group.

Ultimately, Dr. Dahr says ophthalmologists could treat uveitis more effectively if they stopped committing two mistakes. “A large proportion of uveitis cases won’t have any defined etiology,” he says. “Because of this, physicians will have doubts, and will undertreat or not treat at all. I say it’s better to go ahead and treat appropriately with steroid-sparing agents when necessary. The other related issue is, when you do treat, don’t just hit a patient who has severe disease with steroid injections for two years. Bite the bullet and put him on steroid-sparing therapy early on. The vast number of people take these drugs without significant complications and with tremendous benefit with regard to their eye disease. Don’t hesitate. If you have a 20-year-old with a blinding eye disease, he can go blind from VKH in 18 to 24 months and then, assuming normal life expectancy, live into his 80s. Put that kid on the medicine.” **REVIEW**

*Dr. Jaffe is a consultant for AbbVie, and pSivida. Dr. Dahr has no financial interest in any product discussed.*

1. Levy-Clarke G, Jabs DA, Read RW, et al. Expert panel recommendations for the use of anti-tumor necrosis factor biologic agents in patients with ocular inflammatory disorders. *Ophthalmology*. 2014;121:785-796.e3.

2. Dev S, McCallum RM, Jaffe GJ. Methotrexate treatment for sarcoid-associated panuveitis. *Ophthalmology* 1999;106:1:111.

3. Liu D, Ahmet A, Ward L, Krishnamoorthy P, Mandelcorn E, Leigh R, Brown J, Cohen A, Kim H. A practical guide to the monitoring and management of the complications of systemic corticosteroid therapy. *Allergy Asthma Clin Immunol* 2013;9:1:30.

# Cross-linking in Pediatric Keratoconus

**In this retrospective**, interventional case series, researchers looked at pediatric patients (aged  $\leq 14$  years) with keratoconus and poor corrected distance visual acuity who underwent intracorneal ring segment implantation and cross-linking. ICRS were inserted under topical anesthesia after creating a corneal tunnel with a femtosecond laser. Cross-linking was performed one month later. Records were reviewed and data collected preoperatively and at six months, one year, two years and four years postoperatively.

Twelve patients (17 eyes; 10 male, two female) aged 9 to 14 years received ICRS implantation followed by CXL. Follow-up times ranged from six months to four years after surgery. At the six-month follow-up all eyes were evaluated; at the one-year, two-year, and four-year follow-ups 11, 10, and seven eyes were evaluated, respectively. At the six-month follow-up, mean CDVA in comparison to preoperative levels improved significantly ( $p=0.001$ ) from 20/40 to 20/25; mean uncorrected distance visual acuity also improved significantly from 20/160 to 20/50. A significant decrease in both keratometry readings and spherical equivalent (from -4 to -1.56 D) was also noted after ICRS insertion. At the one-year, two-year and four-year follow-ups, refractive values remained rela-

tively stable in comparison to the six-month follow-up, except for a minor but significant improvement in cylinder and, at four years, in UDVA. All patients tolerated the surgery well and no intraoperative or postoperative complications were reported, except for one ring segment that had to be removed after two years due to vascularization and corneal thinning.

According to the results of this study, ICRS implantation with cross-linking is a safe and effective procedure for visual rehabilitation in children with keratoconus and poor CDVA.

*Am J Ophthalmol 2017;178:51-57*  
Abdelmassih Y, El-Khoury S, Dirani A, et al.

## Femtosecond Laser-Enabled vs. Manual Descemetorhexis

**R**esearchers from Toronto, Canada, introduced a novel method for performing decemetorhexis in Descemet's membrane endothelial deratoplasty using the femtosecond laser and compared it with DMEK performed with manual decemetorhexis.

They performed a retrospective medical chart review of two groups of patients who underwent DMEK surgery combined with cataract surgery secondary to Fuchs corneal endothelial dystrophy and cataract: 17 patients underwent femtosecond-laser-enabled

descemetorhexis DMEK and 89 patients underwent DMEK surgery with manual DMEK. Best spectacle-corrected visual acuity, endothelial cell density, graft detachment rate and complications were compared.

Average age of the 106 patients (64 women and 42 men) was  $68 \pm 11$  years. Postoperative best spectacle-corrected visual acuity was  $0.19 \pm 0.13$  logarithm of the minimum angle of resolution in the FE-DMEK group and  $0.35 \pm 0.48$  LogMAR in the M-DMEK group ( $p=0.218$ ). One day after surgery, there were no significant graft detachments in the FE-DMEK group, compared with a 20-percent graft detachment rate in the M-DMEK group ( $p=0.041$ ). Rebubbling was performed in 17 percent of eyes in the M-DMEK group compared with none in the FE-DMEK group ( $p=0.066$ ). The mean endothelial cell count in the FE-DMEK and M-DMEK groups at six months after surgery was  $2,105 \pm 285$  cells/mm<sup>2</sup> (24 percent cell loss) and  $1,990 \pm 600$  cells/mm<sup>2</sup> (29 percent cell loss), respectively ( $p=0.579$ ).

Researchers say these results demonstrate that FE-DMEK shows efficacy similar to that of M-DMEK, with apparently less graft detachment and reduced need for rebubbling.

*Cornea 2017;36:767-770*  
Einan-Lifshitz A, Sorkin N, Boutin T, Showtail M, et al.



(Continued from page 29)

usual for that kind of exam to cause a change in your management. However, I do think you should examine these patients at least once every three months because you can get a hemorrhage or some other complication that you won't notice if you don't look."

- **Don't try to run your clinic yourself.** "The doctor should just be doing what he knows how to do, which is seeing the patient, talking to the patient, documenting and injecting," says Dr. Brown. "Have somebody else manage your flow. Get either a flow leader and a team manager or a clinic leader who can tell you what to do, and then do what they say."

- **Don't schedule all of your injections at once.** "Some doctors have injection clinics," Dr. Brown notes. "That makes no sense to me. What's taught in lean manufacturing is to have multiple varied things scheduled each hour. That way, while I'm seeing one or two new patients, who may take a long time, the technicians can set up two or three injections. I can then pop out and do those injections. Then, while I see the next new patients, they can set up two or three more injections."

- **If you're running behind, tell your patients the reason.** "Sometimes you can't help falling behind schedule because of an emergency," notes Dr. Brown. "In that situation, everyone in the office needs to be telling the patients the reason, and they all need to say the same thing. Patients get very annoyed if they've waited for two hours and no one has said anything to them. When that happens, the patient comes into my room and I have to defuse the patient's anger for the first three or four minutes. That's a waste of my time."

## Injection Strategies

These suggestions will help ensure

that injections are done safely and quickly:

- **To improve your injection technique, observe other surgeons who have extensive experience.** "There are a million ways to do an injection, and there are dogmas all the way around," says Dr. Brown. "Some surgeons use a drape, some don't. Some use a speculum, others don't. Some people do it one-handed; some do it two-handed. I think it's really helpful to watch someone you trust who's doing 50 or 60 injections a day and see how he or she does it. Their technique may not be perfect for you, but you'll get some ideas from watching. Most experienced surgeons will be happy to let you observe them. The idea is to learn different techniques and then experiment to find the technique that works best for you."

- **When performing the injection, minimize talking, manipulation and the number of people present.** "In this situation, less is more," says Dr. Regillo. "We always follow a standard protocol. I'm notified when the patient has been prepped; I come into the room and the technician assists me with holding the lids. We have a no-talk zone over the patient that helps minimize the risk of infection, so any counseling is done ahead of time. We've already explained to the patient why we don't talk during the injection.

"It also helps to not have family in the procedure room," he notes. "They tend to talk to each other, or the family member asks the technician questions, and the technician shouldn't be speaking once the prep has started. If the patient is well-versed in treatments and knows what to expect, it's a fairly smooth, quick and safe process."

- **Minimize the use of subconjunctival anesthetic.** "I don't use subconjunctival, although some of my partners do," says Dr. Brown. "Some of them hate the way patients flinch. To me, the increase in subconjunctival hemorrhages isn't worth it, except for

the 5 or 10 percent of patients that you'll have to scrape off the ceiling if you don't do it."


- **Don't inject until the eye is numb.** "The big mistake is injecting too soon, when the eye is still sensitive," says Dr. Kaiser. "That will cause a lot of discomfort."

- **If the patient refuses the use of Betadine, do the injection anyway.** "Betadine is important, but if the patient refuses the injection with Betadine, you're better off doing the injection without Betadine than foregoing the injection and letting the patient go blind from the disease," says Dr. Brown. "You just have to know that the patient will have an increased risk of infection. Even in this situation, the infection rate is still really low."

- **Make sure you don't leave residual disinfectant in the eye.** "Make sure you really clean the eye up with something like Betadine, but then be sure to flush all of the particulate matter out of the eye so that there's no residual cleaner left," says Dr. Kaiser. "The best injections are those in which the patient has no discomfort at home, and discomfort at home is almost always related to the cleansing, not the actual injection. I also tell my patients to use artificial tears when they go home; the flushing process helps to minimize discomfort." **REVIEW**

*Dr. Regillo does investigative work in the clinical trials of anti-VEGF drugs from Regeneron/Bayer, Genentech/Roche, Allergan, Alcon, and multiple other companies. Dr. Brown is a consultant for Regeneron/Bayer, Genentech/Roche, Allergan, Alimera, Alcon/Novartis, and Thrombogenics. Dr. Kaiser is a consultant to Alcon/Novartis, Regeneron/Bayer, Kanghong and Allergan.*

1. Freund KB, Korobelnik JF, Devenyi R, et al. Treat-and-extend regimens with anti-VEGF agents in retinal diseases: A literature review and consensus recommendations. *Retina* 2015;35:8:1489-506.



# Premium Lenses, Cataract Surgery and Glaucoma

As technology improves and patient expectations rise, doctors treating glaucoma should consider offering premium options.

*Richard A. Lewis, MD, Sacramento, Calif.*

**F**or many years, doctors treating glaucoma have focused on controlling their patients' pressures without really worrying much about getting the patient the best possible vision. However, that type of thinking is hard to justify today. Whether or not your patients have glaucoma, they want to see 20/20, and they expect to walk out of the OR seeing great. Obviously, we can't always meet those expectations, but we need to try. A lot of glaucoma doctors still make that a distant second on their priority list. I think it's time the glaucoma community got up to speed.

Today, so-called premium IOLs encompass a number of lens types, including toric, aspheric and multifocal lenses. [*Ed. note: In this article, the term "multifocal" will also refer to extended-depth-of-focus lenses.*] It may be tempting—by force of habit, if nothing else—to skip offering these to our glaucoma patients, but glaucoma patients have the same expectations as every other patient. They shouldn't be slighted because they have glaucoma. Instead, we should be emphasizing that we want to maximize the patient's vision.

Surgeons who specialize in treating glaucoma tend to be pretty conservative, and most of us have concluded that premium IOLs are not an option for glaucoma patients. That may be true for multifocals, but it's certainly not true for any of the other intraocular lenses that are thought of as premium options—especially toric lenses. Many glaucoma patients could benefit enormously from having toric lenses implanted, and toric lenses don't interfere with any aspect of glaucoma follow-up.

## Which Options Make Sense?

When you have a patient sitting in front of you with a cataract and you're deciding what type of lens to put in, there are three fundamental issues to consider:

1) *What are the patient's visual needs?* I ask every patient, "What do you do for a living? What do you do for fun?" For example, I have a patient who is a jeweler. He likes to be able to see very close to his nose without glasses. Knowing that, I left him very nearsighted after surgery, and he was happy as a clam. Had I

not asked him what he liked to do, I would have put in a standard lens and he would have been unhappy.

Similarly, some people enjoy doing needlepoint. Some work on the computer all day. Each of those individuals may want to end up with something other than plano at distance after surgery.

2) *Does the patient mind wearing glasses?* Some people hate wearing glasses while others like them. (Some people say they can't function without them.) Knowing how the patient feels about this will make a difference in the options you offer the patient.

3) *What's the status of the glaucoma?* The status of your patient's glaucoma should influence the IOL options you offer the patient, as well as your decision about whether or not to combine the cataract surgery with a MIGS procedure. That means it's important to go into detail regarding the patient's history.

Generally, the earlier the disease stage, the more options should be considered. If your patient has early ocular hypertension with no visual problems, or is at low risk for visual field loss, then multifocals are an



Doctors treating glaucoma have traditionally avoided offering premium intraocular lenses, but monofocal toric lenses such as Alcon's AcrySof IQ, Staar Surgical's toric, AMO's Tecnis toric and Bausch + Lomb's Trulign toric can be of great benefit to patients with cupping.

option. On the other hand, multifocals are contraindicated in glaucomatous patients with significant cupping or field loss. If a patient has angle closure but a healthy visual field, taking the cataract out will be curative of the glaucoma. That patient should be eligible for the full complement of options we have to offer. But if your patient has secondary glaucoma from diabetes, you have to be careful, because there are other implications, such as potential cystoid macular edema.

There's general agreement that a multifocal doesn't make sense for a glaucoma patient with anything more than early disease, primarily because of issues with follow-up. A multifocal will cause a significant reduction of visual sensitivity during visual field testing, cause wavy artifacts on OCT imaging and make optic nerve examination difficult.<sup>1,2</sup> If your glaucoma patient truly wants to be rid of spectacles, I'd suggest pursuing monovision.

However, some surgeons also believe a toric lens isn't appropriate, primarily because of the extra cost involved. Actually, toric lenses are incredibly valuable; they help people with significant astigmatism achieve great vision, and a toric lens won't impact any of those follow-up measures.<sup>3</sup> (Astigmatic keratotomy is usually effective with less than 1 D of astigmatism; beyond that, a toric IOL should be placed.) I don't think glaucoma patients with astigmatism should be shorted because they happen to have glaucoma. And yet,

when I give a talk to an audience and ask for a show of hands regarding how many offer toric lenses to their glaucoma patients, usually less than half of the doctors in the audience raise their hand.

### Choosing the Right Lens

These tips will help ensure that you'll end up with a happy patient, whatever IOL option you end up employing:

- **Remember that different premium IOLs have different impacts on contrast sensitivity.** While it's well known that multifocal IOLs can reduce contrast sensitivity—especially refractive, as opposed to diffractive, multifocals—options such as aspheric IOLs can actually improve contrast sensitivity. (Toric and accommodative IOLs have no detectable impact on contrast sensitivity.)

- **Remember that cataract surgery by itself can relieve angle-closure glaucoma.** Regardless of the type of lens you plan to implant, the best thing you can do for a patient with angle-closure glaucoma is take out the cataract. It's very curative. In these eyes, the lens is taking up a lot of space inside the eye. Once you get the lens out of there, the iris will fall back into place, relieving the angle closure.

- **Avoid using premium IOLs in glaucomatous eyes with weak zonules.** This is an important caveat to the benefits of toric lenses in glaucoma patients, depending on the type of glaucoma the patient has. An eye

with pseudoexfoliation has inherently weak zonules, which puts any intraocular lens at risk of dislocation. This can be a problem with any lens, of course—even a standard lens. But in the case of a toric lens, the axis of astigmatism has to be right on the money. If you get even a little subluxation of the lens, you're going to get distortion and/or some loss of astigmatic correction.

- **Use the best power calculation formula.** Myopia is common in glaucoma patients, and some of the newer IOL formulas work better in a highly myopic eye—notably, the Barrett and the Hill RBF.<sup>4,5</sup> Many formulas will recommend insufficient power, leaving these patients with postoperative hyperopia. On the other hand, hyperopic eyes often have angle closure. They may have an unpredictable anterior chamber depth, with the consequence that power calculations may also fail to be on target.

- **Remember that combined surgery may contraindicate implanting a toric lens.** Combining cataract and glaucoma surgery can lead to major astigmatic changes in the cornea. If you're only performing cataract surgery, most studies suggest that induced astigmatism will probably be less than 0.5 D, so you can incorporate that into your calculations. But when you're combining surgeries, induced astigmatism is much harder to predict.

For example, if you combine a trabeculectomy with cataract surgery, you'll have an open wound away from

the cataract wound. That can make the induced astigmatism much more difficult to predict and compensate for. In addition, the combined surgery may increase the possibility of zonules breaking or splitting, leading to unpredictable movement of the lens, throwing off the axis of alignment.

### **During Surgery ...**

Potential concerns during surgery include:



- **Glaucoma patients are more likely to have pupil problems than patients without glaucoma.** They often don't dilate as well as nonglaucomatous eyes, so you'll need to be extra careful. Poor visualization caused by an insufficiently dilated pupil can result in capsule tears and other complications. (There are plenty of ways to manage a small pupil, including pharmacological options such as epinephrine/lidocaine and Omidria, and techniques such as stretching or using iris hooks or a Malyugin ring.)

- **Weak zonules are an issue in some types of glaucoma.** Be prepared to insert capsular tension rings if you run into a problem with the zonules.

- **Glaucoma patients are a little more at risk for cystoid macular edema.** This is true in part because they've usually been on eye drops for a long time. (Prostaglandins in particular seem to be somewhat inflammatory.) There are pros and cons to using nonsteroidals for cataract surgery, but I think that when dealing with patients who are at risk, such as diabetic patients or those who've had CME in the past, you should use everything—steroidals and nonsteroidals—to prevent CME. (You should also avoid certain medications, such as prostaglandins, that might tend to cause it.)

- **Intraoperative aberrometry may be helpful, especially in cer-**

**tain glaucoma patients.** The vast majority of our patients—including most glaucoma patients—will get a good result without the use of intraoperative aberrometry, as long as an appropriate formula is used to calculate the lens power. The question is, what percentage of excellent outcomes is acceptable?

  
*Many glaucoma patients are being overtreated after cataract surgery, using more medications than they actually need.*  


Using intraoperative aberrometry will almost certainly improve your score in this department.

In addition, some glaucoma patients will present with problematic eyes that may need this technology to avoid a refractive surprise—such as when a bleb is overhanging the cornea, which can definitely impact the accuracy of your measurements. Also, many glaucoma patients have been using eye drops for years, leading to ocular surface problems that can affect the accuracy of your measurements.

Of course, adding another technology to your armamentarium will involve costs, having to spend a few minutes more in the OR, and the addition of another variable to the procedure. Nevertheless, using intraoperative aberrometry to help improve outcomes is worth considering.

### **Postoperative Concerns**

Whether or not you implant a premium lens, it's important to manage these issues following cataract surgery

in your glaucoma patient:

- **Be proactive regarding a postoperative pressure spike.** Glaucoma patients are more likely than others to have a postoperative pressure rise within a day or two of cataract surgery, so be prepared to manage this if it occurs. One option is to use an acute pressure-lowering drug like brimonidine or iopidine to keep pressure down; another is to burp the wound to release a little viscoelastic. Either strategy will generally tide the patient over. This is usually a 24-hour phenomenon that soon goes away.

- **Don't confuse a postoperative pressure rise with steroid-induced glaucoma.** A number of doctors have referred patients to me one week out of surgery, saying the patient has a steroid-induced glaucoma. In fact, the most common reason for a pressure rise on day one is retained viscoelastic; it has nothing to do with steroid-induced glaucoma. In my experience, you can't get a steroid-induced glaucoma in a couple of days. It takes two to four weeks for a problem of that nature to develop.

Basically, steroid-induced glaucoma is a diagnosis of exclusion. You have to exclude everything else before you conclude that steroids caused the pressure increase. If in fact the patient does develop steroid-induced glaucoma a month after surgery, the correct response is to stop the steroids and address the pressure increase until the effect wears off.

- **Don't be afraid to stop all medications after cataract surgery to reevaluate the patient's medication needs.** I think many glaucoma patients are being overtreated after they've had cataract surgery, using more medications than they actually need. Cataract surgery is a very good pressure-lowering operation, so many patients can reduce or eliminate the drugs they were using before the operation. In essence, cataract surgery is a chance

to wipe the slate clean. So it makes sense to start over again and see what the patient really needs. You'll never know if the patient's need for drops has been significantly reduced unless you stop the medications and see what happens.

I realize that some of my friends and colleagues don't agree with this strategy; they believe it puts the patient at risk. However, cataract surgery is very effective at lowering pressure. You've done a good surgery; why not let the surgery do its job? It's very unlikely that your patient will need the same number of medications he was using beforehand.

If I really feel that a patient is at high risk for a pressure rise, I'll inject a miotic during surgery or give the patient Diamox at the end of surgery to prevent that first day or two of postoperative pressure problems. But once all of that settles down, I'd

really like to know how the eye is doing before I start the patient back on glaucoma drops.

### Coming of Age

Today, I think premium lenses should be an option we offer to our glaucoma patients—with the exception of multifocals in glaucoma patients with cupping. Just remember that it's very important to take careful, accurate measurements so you get the right IOL power.

In particular, if you're a glaucoma surgeon, I urge you to fully correct your patients' astigmatism. We've been ignoring astigmatism forever; now it's time to address it, whether it's a low level that you can fix with a femtosecond laser or a higher level that calls for a toric lens. With all of the tools at our disposal, we're past the point at which we can ignore

astigmatism. Correcting astigmatism will be the standard of care in the future, and glaucoma treatment needs to come of age. **REVIEW**

*Dr. Lewis is a cataract surgeon and glaucoma specialist; the former director of the glaucoma service at the University of California, Davis; past president of the American Glaucoma Society; and past president of the American Society of Cataract and Refractive Surgery.*

1. Inoue M, Bissen-Miyajima H, Yoshino M, Suzuki T. Wavy horizontal artifacts on optical coherence tomography line-scanning images caused by diffractive multifocal intraocular lenses. *J Cataract Refract Surg* 2009;35:7:1239-1243.
2. Aychoua N, Junoy Montolio FG, Jansonius NM. Influence of multifocal intraocular lenses on standard automated perimetry test results. *JAMA Ophthalmol* 2013;131:4:481-485.
3. Brown RH, Zhong L, et al. Toric Intraocular lens outcomes in patients with glaucoma. *J Refract Surg* 2015;31:6:366-372.
4. Zaldivar R, Shultz MC, Davidorf JM, Holladay JT. Intraocular lens power calculations in patients with extreme myopia. *JCRS* 2000;26:5:668-74.
5. MacLaren RE, Sagoo MS, Restori M, Allan BD. Biometry accuracy using zero- and negative-powered intraocular lenses. *J Cataract Refract Surg* 2005;31:2:280-90.

# HIRE THE BEST Ophthalmic Technicians



Hire experienced, certified Ophthalmic Technicians with Local Eye Site.

Also find amazing billers, insurance coders, front desk staff & office administrators.



**Local Eye Site**  
JOBS IN EYE CARE

[localeyesite.com/hire/ophthalmic-technician](http://localeyesite.com/hire/ophthalmic-technician)

The official recruiting partner for Review of Ophthalmology.

Jobs appear on the ATPO career center and ATPO grads and JCAHPO pros are directed to your career opportunity.



# Balancing Biomarker Applications

Each of these indirect measures of therapeutic efficacy comes with its own strengths and weaknesses.

*Mark B. Abelson, MD, CM, FRCSC, FARVO, George Dimopoulos, PhD, George Ousler, and David Hollander, MD, MBA Andover, Mass.*

**T**he aphorism, “Treat the patient, not the disease,” sometimes credited to the great Canadian physician Sir William Osler, underscores a holistic approach that focuses less on medical metrics and more on overall quality of life. While this may seem self-evident, in today’s world of diverse diagnostic technologies, proteomics, metabolomics and genomics, it’s become increasingly difficult to treat the patient and not just the test score. Similarly, in therapeutic development, clinical study outcomes risk losing their central focus of improving patient outcomes amid a seemingly never-ending supply of data, metrics and information accumulated over the course of a clinical trial.

Recently, the Foundation for the National Institutes of Health, hoping to harmonize the process of biomarker selection among the Food and Drug Administration, NIH, industry, academia and patient groups, released a report outlining the appropriate use of biomarkers in medical research and therapeutic development.<sup>1</sup> Biomarkers are defined as any measure, from a blood test or biopsy to an imaging modality, that can be used to assess a

physiological state. Often these provide a more quantifiable, rapid and cost-effective means of assessing disease modification but, in general, the FDA has resisted their use as primary tools in therapeutic approvals. This month, we consider how the evolution of technology has and will impact ophthalmic therapies going forward.

## Biomarker Basics

The classic example of a biomarker is blood pressure: an easily measured biometric that provides direct information on the status of that aspect of a patient’s cardiovascular function and an indirect assessment of multiple organ systems. Like most biomarkers, using BP as a measure of patient health comes with a significant caveat: While reduction of elevated BP is associated with an improvement in patient health, the effect doesn’t mean the underlying cause has been addressed. In ophthalmology, elevated intraocular pressure presents a similar example of a biomarker with an unequivocal association with disease. In these cases, IOP-lowering drugs have been approved based solely on their

ability to “treat the biomarker,” knowing that, while providing a beneficial effect, they may not fully prevent further damage of the optic nerve. Treatment of IOP in combination with monitoring other risk factors and metrics is likely to provide the best window on glaucomatous progression.<sup>2-4</sup> Despite improvements in retinal imaging, intraocular pressure remains the only surrogate measure used by the FDA as the basis of approval for treatments for glaucoma, though the specific indication for topical glaucoma products most commonly reads, “For the reduction of elevated IOP in subjects with primary open angle glaucoma or ocular hypertension,” as opposed to, “For the treatment of glaucoma.”


In fact, BP and IOP are outliers in that they are the rare examples of biomarkers that are used as a basis for a therapeutic approval. More often, a direct effect on a disease state is required. For example, drug therapy for post-menopausal osteoporosis can be easily followed by radiographic measures of bone mineral density, but approvals have required demonstration of a clinically significant reduced risk

of fracture. This example highlights the distinction made in Dr. Osler's quote, and is the standard by which most drug approvals occur. Despite this, biomarkers can provide invaluable information in the course of diagnosis, and are keys to drug development programs even when they are not used as primary endpoints.

Surrogate biomarkers, used as diagnostic tests, are the stalwarts of medical diagnosis. For example, blood cell profiles and chemistries can provide clinicians with the first hint of pathology, often in the setting of an otherwise healthy routine screening. In contrast, a healthy eye exam involves few surrogate measures beyond IOP. Despite this, there are a number of ocular conditions in which biomarkers play a key role in diagnosis and therapeutic assessment.

## Biomarkers, Front to Back

The composition and relative concentrations of tear-fluid components provide insights into a number of ocular conditions, especially those involving innate immune defense responses to ocular surface pathophysiology. In conditions such as ocular allergy, dry-eye disease and keratoconus, the production of various tear film constituents may be amplified or diminished.<sup>5-7</sup> For example, specific cytokine and chemokine profiles are associated with clinical subtypes of ocular allergy (allergic conjunctivitis, vernal keratoconjunctivitis or atopic keratoconjunctivitis).<sup>5</sup> Patients with VKC show significantly higher levels of Interleukin-4 in their tear fluid than those with AC or AKC.<sup>6</sup> In dry eye, the inflammatory biomarkers that have shown tear-film upregulation include IL-1, IL-6, matrix metalloproteinase-9, Chemokine CCL5 (also known as RANTES) and macrophage inflammatory protein-1.<sup>8-11</sup> Though none of these biomarkers are specific for DE, they do confirm the inflam-



Two-dimensional electrophoresis remains a valuable tool for identifying changes in tear fluid composition. Staining shows the separation of hundreds of different components that can be identified by subsequent mass spectroscopy.

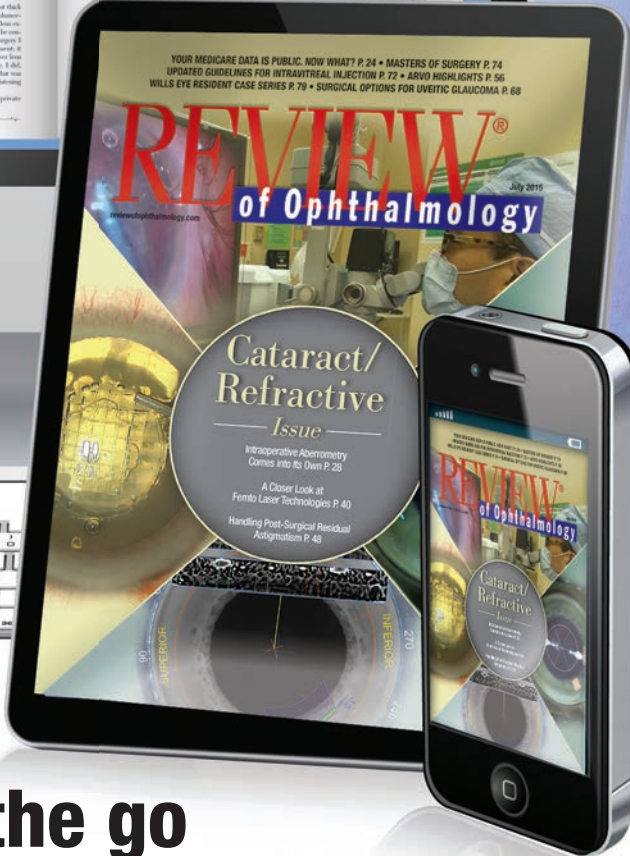
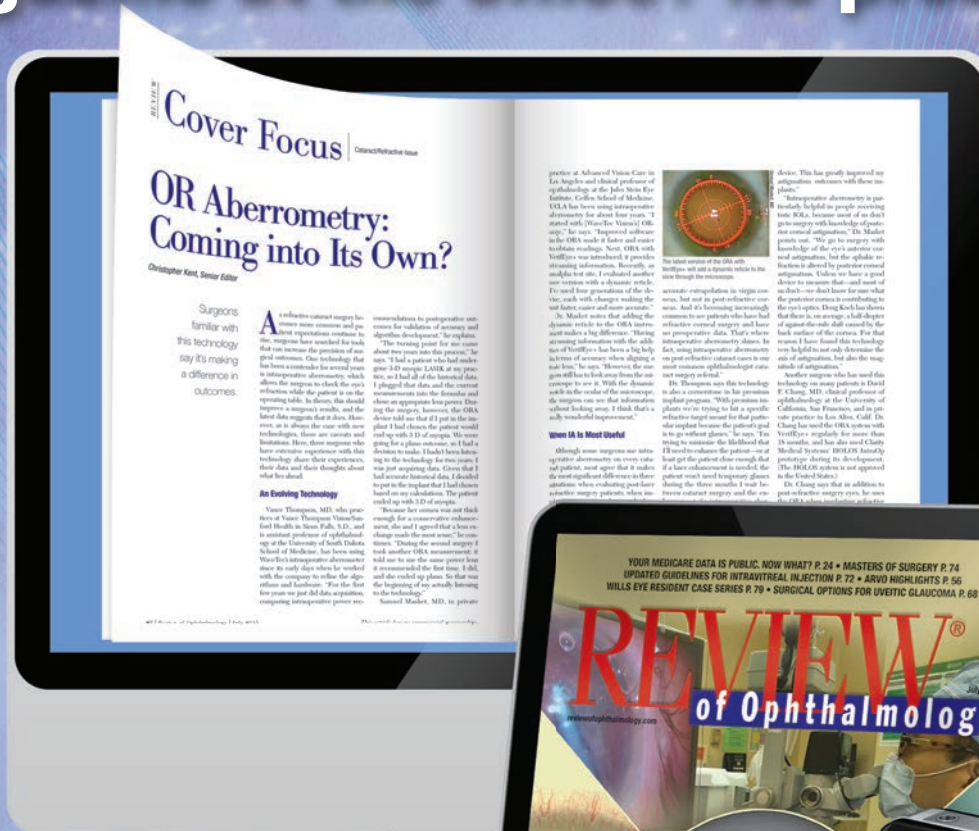matory nature of the disease. A recent study identified another tear component, lysosomal proline-rich protein 4, that may be more relevant as a specific biomarker for DE; reduced levels of this protein are reproducibly found in tears of DE subjects, and the extent of reduced expression appears to correlate with the severity of a patient's DE.<sup>12</sup> This makes LPRP4 a potential candidate as a specific biomarker for DE; as such, it could be used to identify patients for a clinical trial or to track efficacy of a prospective therapy. Quantitation of tear components are notoriously difficult, however, so additional studies are necessary to evaluate this potential biomarker as a valid DE diagnostic.

Tear film lipids, including those originating from the meibomian gland, are another important potential source of ocular surface biomarkers.<sup>13,14</sup> Variations in fatty acid compositions in the tears of patients with meibomian gland dysfunction and those with aqueous-deficient DE have been reported.<sup>15</sup> Other studies have reported changes in meibum

composition in DE patients, and showed that several lipid species were significantly increased in this demographic, especially sphingomyelin and phosphatidylcholine.<sup>16</sup> If these changes can be functionally linked to MGD, then a modulation of lipid composition may ultimately represent both a marker of the disease and a goal of therapeutic remedy.

In keratoconus patients, elevations of the inflammatory mediators IL-6, MMP-9 and RANTES/CCL5 in tear fluids have been reported, but they're also seen in other conditions associated with inflammation, such as DE.<sup>17,18</sup> Recent identification of gross cystic disease fluid protein-15 (GCDFP-15), a novel, disease-specific biomarker, suggests that it may be possible to predict or track the disease process using it.<sup>19,20</sup> Previously identified in breast cancer tissue, GCDFP-15 is downregulated in tear samples of keratoconus patients when compared to age-matched controls. It's thought to be involved in extracellular matrix homeostasis, and is regulated by transforming growth factor- $\beta$ ,

# Left your *Review of Ophthalmology* magazine at the office? No problem!



## Read *Review* on the go from any mobile device!

Simply go to [www.reviewofophthalmology.com](http://www.reviewofophthalmology.com) and click on the digimag link to get your current issue.



both of which are linked to the pathology of keratoconus.<sup>20</sup>



No single disease exacts a greater toll on ocular function than diabetes mellitus. Epidemiological studies indicate that diabetes mellitus afflicts 350 million people worldwide and is a prelude to heart disease, kidney disease, inflammatory diseases and diabetic retinopathy.<sup>5</sup> DR is a leading cause of blindness in middle-aged people, accounting for about 5 percent of their blindness worldwide, and its prevalence mirrors the upward trajectory of diabetes mellitus cases, emphasizing the need for viable biomarkers that could pinpoint early stages of retinal pathophysiology.

Numerous inflammatory cytokines and chemokines (which are also associated with other ocular pathologies) have been identified in the aqueous humor, vitreous and plasma of diabetic retinopathy patients.<sup>21</sup> In recent years, differences in levels of nerve growth factor and its active precursor pro-NGF have been identified in patients with diabetic retinopathy, with a shift in the balance toward the pro-NGF, a molecule known to promote nerve atrophy and other attributes of diabetic retinopathy.<sup>22,23</sup> It's possible that excess pro-NGF underlies part of the pathogenesis of diabetic retinopathy; therefore, changes in NGF levels in tears or in serum could be used as a disease marker.<sup>22</sup> Consistent with this are the observed correlation between NGF levels, the duration of diabetes mellitus, and patient hemoglobin A1C levels. Each of these suggest that this peptide growth factor has potential application as a biomarker of diabetic retinopathy.<sup>22</sup>

### **Imaging/Composite Biomarkers**

Imaging techniques are used to visualize changes in cellular morphology and tissue ultrastructure in almost every ophthalmic disease. In allergy and dry eye, confocal micros-

copy imaging has been used successfully to assess cellular changes in the cornea and conjunctiva by visualizing tissue immune-cell infiltration.<sup>24</sup> Fundus camera and scanning laser ophthalmoscopy imaging can detect incremental structural changes in the retina over time, providing early interventional treatment opportunities for patients with glaucoma or DR.<sup>25</sup>

  
*In recent years,  
differences in levels  
of nerve growth  
factor and its active  
precursor pro-NGF  
have been identified in  
patients with diabetic  
retinopathy ...*  


Dry age-related macular degeneration is a particular focus of image-based biomarkers, as there are few reliable indicators of the disease before significant damage to the retina has already occurred.<sup>26</sup> Clinical assessments of complement inhibitors, for example, have used changes in size of retinal lesions as an endpoint in trials of drugs such as lampalizumab, an antibody directed at complement factor D.<sup>27</sup> The search for early-stage indicators for dry AMD is ongoing, and the identification of such a biomarker would be a significant step forward.

Applications of fluorescein angiography or indocyanine green angiography to fundus imaging have yielded high-contrast images of the retina and surrounding blood vessels, which, in combination with other imaging biomarkers, can greatly improve prognoses. Furthermore, the utility of combining imaging and non-imaging

biomarkers may further refine their accuracy in identifying disease states. In glaucoma, the integration of images of optic disc cups and retinal nerve fiber layers taken by scanning laser tomography and scanning laser polarimetry, in addition to tracking IOP, may paint a more comprehensive picture of the patient's glaucoma status than either technique alone.<sup>28</sup>

We all know the saying that the eyes are the windows to the soul, but they are also the windows to systemic disease. Hypertension is an excellent example of a systemic disease that can be tracked by internal eye imaging. By examining the arrangement and structure of the posterior microvasculature of the eye through a technique such as fractal dimension analysis, a long-term, integrated measure of systemic hypertension can be obtained.<sup>29</sup> This metric can be used by clinicians when deciding the degree of intervention necessary for each patient. Systemic hypertension is known to damage the retinal blood vessel network, and images of the affected blood vessels have become a recognized diagnostic sign of long-duration hypertension among clinicians.<sup>30</sup>

Since the introduction of commercially available confocal scanning laser ophthalmoscopy and optical coherence tomography, there's been an interest in imaging ocular biomarkers that may be of value in the diagnosis of Alzheimer's disease. These high-resolution imaging techniques have played an important role in pinpointing pathological structural changes in the retina, optic nerve, retinal microvasculature and choroid.<sup>31</sup> Imaging studies have also shown that beta amyloid deposits, a hallmark signature of Alzheimer's, can be quantified on retinas and in crystalline lenses of Alzheimer's disease cohorts.<sup>32</sup>

A composite score of multiple biomarkers might be a better choice for prognosis or for therapeutic assessment, particularly for conditions such

as dry-eye disease that are difficult to objectively define. An integrated measure that incorporates both imaging and tear-assessment techniques may more reliably predict disease. An example of this is Ora's OPI 2 system, which computes a ratio of tear-film breakup to blink rate using slit lamp video.<sup>33</sup> The key with OPI 2 and other composite metrics is their incorporation into clinical testing in order to assess their utility and refine their value.

Merging ocular images and fluid biomarkers along with other types of biomarkers may help with diagnostic specificity and accuracy in other eye disorders and systemic diseases. In glaucoma, for example, the addition of quantified images of retinal structural changes to intraocular pressure or levels of proteins associated with glaucoma may provide a better assessment of the patient's future outlook. While biomarkers can serve a useful purpose in evaluating an initial disease risk or diagnosis, on numerous occasions they don't complete the narrative because of their lack of specificity for a particular disease state. Even with an extensive composite panel on hand, a larger quantity of biomarkers doesn't necessarily guarantee accuracy in a physician's prognosis.

Although biomarkers' limitations mainly stem from a lack of a clear association with the clinical characteristics of a disease, continuing research, especially in the composite biomarker area, holds promise. Metrics that change before clinical manifestations of a disease are particularly helpful, as they allow for early intervention before injury has taken place. One key example of this is the search for an early indicator of dry age-related macular degeneration. Waiting for geographic lesions to progress or for changes in three lines of visual acuity doesn't allow us to target patients at the earliest stages of disease, or to potentially treat these patients at a point in the disease when an intervention

may have a greater impact. Ultimately, the goal of biomarker research, like all medicine, is effective care for our patients. **REVIEW**

*Dr. Abelson is a clinical professor of ophthalmology at Harvard Medical School. Dr. Dimopoulos is a medical writer at Ora Inc. Mr. Ousler is vice president for dry eye at Ora. Dr. Hollander is chief medical officer at Ora, and assistant clinical professor of ophthalmology at the Jules Stein Eye Institute at the University of California, Los Angeles.*

1. <https://fnih.org/news/announcements/evidentiary-criteria-released> "Framework for Defining Evidentiary Criteria for Biomarker Qualification" accessed 6 Feb 2017.
2. Medeiros FA, Zangwill, LA, Mansouri K, Lisboa R, Tafreshi A, Weinreb RN. Incorporating risk factors to improve the assessment of rates of glaucomatous progression. *Invest Ophthalmol Vis Sci* 2012;53:4:2199-2207.
3. Kass MA, Heuer DK, Higginbotham EJ, et al. The Ocular Hypertension Treatment Study: A randomized trial determines that ocular hypotensive medication delays or prevents the onset of primary open-angle glaucoma. *Arch Ophthalmol* 2002;120:6:701-713.
4. Kalouda P, Keskin C, Anastopoulos E, Topouzis F. Achievements and limits of current medical therapy of glaucoma. *Developmental Ophthalmology* 2017;59:1-14.
5. Hagan S, Martin E, Enriquez-de-Salamanca. Tear fluid biomarkers in ocular and systemic disease: Potential use for predictive, preventive and personalized medicine. *EPMA Journal* 2016;7:15.
6. Uchio E, Ono SY, Ikezawa Z, Ohno S. Tear levels of interferon-gamma, interleukin (IL)-2, IL-4 and IL-5 in patients with vernal keratoconjunctivitis, atopic keratoconjunctivitis and allergic conjunctivitis. *Clin Exper Allerg* 2000;30:1:103-9.
7. Leonardi A, Curnow SJ, Zhan H, Calder VL. Multiple cytokines in human tear specimens in seasonal and chronic allergic eye disease and in conjunctival fibroblast cultures. *Clin Exper Allerg* 2006;36:6:777-84.
8. Boehm N, Reichardt AI, Weigand M, et al. Proinflammatory cytokine profile of tears from dry eye patients by means of antibody microarrays. *Invest Ophthalmol Vis Sci* 2011;52:7725-30.
9. Enriquez-de-Salamanca A, Castellanos E, Stern ME, Fernandez L, Carreno E, Garcia-Vasquez C, Herreras JM, Calonge M. Tear cytokine and chemokine analysis and clinical correlations in evaporative-type dry eye disease. *Mol Vis* 2010;16:862-73.
10. Choi W, Li Z, Oh HJ, Im SK, Lee SH, Park SH, You IC, Yoon KC. Expression of CCR5 and its ligands CCL3, -4, and -5 in the tear film and ocular surface of patients with dry eye disease. *Curr Eye Res* 2012;62:151-96.
11. Leonardi A, Borghesan F, Faggian D, Depaoli M, Secchi AG, Plebani M. Tear and serum soluble leukocyte activation markers in conjunctival allergic diseases. *American Journal of Ophthalmology* 2000;129:2:151-8.
12. Aluru SV, Agarwal S, Srinivasan B, Iyer GK, Rajappa SM, Tatu U, Padmanabhan P, Subramanian N, Narayanasamy A. Lacrimal proline rich 4 (LPRR4) protein in the tear fluid is a potential biomarker of dry eye syndrome. *PLoS One* 2012;7:12:e519794.
13. Butovich IA. Tear film lipids. *Exp Eye Res* 2013;117:4-27.
14. Ghosh A, Nishtala K. Biofluid lipidome: A source for potential

- diagnostic biomarkers. *Clin Transl Med*. 2017;6:1:22. Epub 2017 Jun 20.
15. Joffre C, Souchier M, Gregoire S, Viau S, Breillon L, Acar N, Bron AM, Creuzot-Garcher C. Differences in meibomian fatty acid composition in patients with meibomian gland dysfunction and aqueous deficient dry eye. *British Journal of Ophthalmology* 2008;92:116-9.
16. Lam SM, Tong L, Yong SS, Li B, Chaurasia SS, Shui G, Wenk MR. Meibum lipid composition in Asians with dry eye disease. *PLoS One* 2011;6:e24339.
17. Shetty R, Ghosh A, Lim RR, Subramani M, Mihir K, Reshma AR, Ranganath A, Nagaraj, et al. Elevated expression of matrix metalloproteinase-9 and inflammatory cytokines in keratoconus patients is inhibited by cyclosporine. *Invest Ophthalmol Vis Sci* 2015;56:2:738-50.
18. Kolozsvari BL, Petrovski G, Gogolak P, Rajnavolgyi E, Toth F, Berta A, Fodor M. Association between mediators in the tear fluid and the severity of keratoconus. *Ophthalmic Research* 2014;51:1:46-51.
19. Priyadaresini S, Hjortdal J, Sarker-Nag A, Sejersen H, Asara JM, Karamichos D. Gross cystic disease fluid protein-15/prolactin-inducible protein as a biomarker for keratoconus disease. *PLoS One* 2014;18:9:11:e113310.
20. Priyadaresini S, McKay TB, Sarker-Nag A, Karamichos D. Keratoconus in vitro and the key players of the TGF- $\beta$  pathway. *Mol Vis* 2015;21:2:577-88.
21. Cheung CM, Vania M, Ang M, Chee SP, Li J. Comparison of aqueous humor cytokine and chemokine levels in diabetic patients with and without retinopathy. *Molecular Vision* 2012; 18:830-7.
22. Mohamed R, El-Remessy AB. Imbalance of the nerve growth factor and its precursor: Implication in diabetic retinopathy. *J Clin Exp Ophthalmol* 2015;6:5.
23. Barcelona PF, Sitaras N, Galan A, et al. p75NTR and its ligand ProNGF activate paracrine mechanisms etiological to the vascular, inflammatory, and neurodegenerative pathologies of diabetic retinopathy. *J Neurosci* 2016;36:34:8826-41.
24. Villani E, Mantelli F, Nucci P. In vivo confocal microscopy of the ocular surface: Ocular allergy and dry eye. *Current Opinion Allergy Clinical Immunology* 2013;13:50:569-76.
25. Gramatikov B. Modern technologies for retinal scanning and imaging: An introduction for the biomedical engineer. *Biomedical Engineering Online* 2014;13:52.
26. Hanus J, Zhao F, Wang S. Current therapeutic developments in atrophic age-related macular degeneration. *Br J Ophthalmol* 2016;100:1:122-7.
27. <http://www.roche.com/investors/updates/inv-update-2013-08-27.htm>. Accessed 19 July 2017.
28. Windisch BK, Harasymowicz PJ, See JL, Chauhan BC, Belliveau AC, Hutchison DM, Nicoleta MT. Comparison between confocal scanning laser tomography, scanning laser polarimetry and optical coherence tomography on the ability to detect localized retinal nerve fibre layer defects in glaucoma patients. *British Journal of Ophthalmology* 2009;93:1-1.
29. Cheung CY, Thomas GN, Tay W, Ikram MK, Hsu W, Lee ML, Lau QP, Wong TY. Retinal vascular fractal dimension and its relationship with cardiovascular and ocular risk factors. *Amer J Ophthalmol* 2012;154:4:663-74.
30. Ponto KA, Werner DJ, Wiedemer L, et al. Retinal vessel metrics: Normative data and their use in systemic hypertension: Results from the Gutenberg Health Study. *J Hypertens* 2017;35:8:1635-1645.
31. Lim JKH, Li QX, He Z, Vingrys AJ, Wong VH, Currier N, Mullen J, Bui BV, Nguyen CT. The eye as a biomarker for Alzheimer's disease. *Front Neurosci* 2016;10:1-14.
32. Kerbage C, Sadowsky CH, Tariot PN, Agronin M, Alva G, Turner FD, Nilan D, Cameron A, Cagle GD, Hartung PD. Detection of amyloid beta signature in the lens and its correlation in the brain to aid the diagnosis of Alzheimer's Disease. *Amer J Alzheimer's Dis Other Dement* 2015;30:738-45.
33. Abelson R, Lane KJ, Rodriguez J, Johnston P, Angjeli E, Ousler G, Montgomery D. Validation and verification of the OPI 2.0 System. *Clin Ophthalmol* 2012;6:613-22.



# THE RICK BAY FOUNDATION

*for Excellence in Eyecare Education*

[www.rickbayfoundation.org](http://www.rickbayfoundation.org)

*Support the Education of Future Healthcare & Eyecare Professionals*



## **About Rick**

Rick Bay served as the publisher of *The Review Group* for more than 20 years.



To those who worked for him, he was a leader whose essence was based in a fierce and boundless loyalty.

To those in the industry and the professions he served, he will be remembered for his unique array of skills and for his dedication to exceeding the expectations of his customers, making many of them fast friends.

Scholarships are awarded to advance the education of students in both **Optometry** and **Ophthalmology**, and are chosen by their school based on qualities that embody Rick's commitment to the profession, including integrity, compassion, partnership and dedication to the greater good.

**Interested in being a partner with us?**

Visit [www.rickbayfoundation.org](http://www.rickbayfoundation.org)

*(Contributions are tax-deductible in accordance with section 170 of the Internal Revenue Code.)*



**THE RICK BAY FOUNDATION®**  
*for Excellence in Eyecare Education*

*(The Rick Bay Foundation for Excellence in Eyecare Education is a nonprofit, tax-exempt organization under section 501(c)(3) of the Internal Revenue Code.)*



# How to Interpret Clinical Trial Outcomes

Making sense of primary and secondary endpoint outcomes in macular degeneration and diabetic macular edema trials.

*Thomas A. Ciulla, MD, MBA, Indianapolis*

**G**iven an increasing amount of physician participation and reliance on randomized clinical trials to develop and guide treatment (See *Tables 1 & 2*), proper interpretation of RCT results is imperative. When interpreting RCT endpoints and results, clinicians must properly assess numerous study features in order to understand context and relevance to clinical practice. This article will guide you through a series of questions to consider whenever you review clinical trial results, with an emphasis on neovascular age-related macular degeneration and diabetic macular edema clinical trials.

## Eligibility Criteria

Eligibility criteria are an important initial consideration. When evaluating a study, ask: Do baseline demographics, prior treatment and disease severity or duration correlate with current clinical practice?

Inclusion and exclusion criteria determine a study's relevance to clinical practice, with broad eligibility criteria typically being more generalizable to the overall clinic population. Important criteria to review include mean

age, ethnicity, prior ocular therapy and range of eligible baseline best corrected visual acuity. For example, subjects who have undergone prior therapy for AMD or diabetic retinopathy are obviously not comparable to treatment-naïve patients. Subjects who enter trials with relatively good BCVA can't improve meaningfully due to a ceiling effect, and experience a loss of vision more often than those subjects with worse baseline BCVA, despite treatment with anti-VEGF therapy.<sup>1-4</sup>

Other important inclusion criteria include features of the disorder under investigation, such as the size and location of the choroidal neovascularization in nAMD studies, or the degree of macular ischemia and the severity of underlying diabetic retinopathy in DME studies, as well as systemic comorbidities such as uncontrolled systemic hypertension or diabetes.

## Randomization and Masking

Another important question to ask: Did the study randomize and mask treatment assignments to limit bias?

RCTs of disorders with established therapies are run with concurrent, ac-

tive standard-of-care control groups. Previously, this meant macular laser photocoagulation for DME (as in the VISTA/VIVID aflibercept trials), and more recently anti-VEGF monotherapy for both DME (as in DRCR Protocol T comparative effectiveness trial) and nAMD (as in the CATT comparative effectiveness and VIEW aflibercept trials).<sup>5-8</sup> Randomization limits selection bias, while double masking of treatment assignment, to both the subject and evaluators, limits performance and measurement bias, respectively. Non-randomized studies or those that use only baseline values as controls could suffer from multiple biases, including a placebo effect, while those that use historic controls may not use a comparable subject set.

## Endpoints

Key considerations at this phase of the evaluation are: Were endpoints relevant to clinical practice? Were validated endpoints used?

Primary endpoints should provide the most clinically important evidence of the trial's primary objective. Historically, primary endpoints have been

validated functional endpoints that involve vision, although more recently the FDA has accepted “surrogate endpoints” which can be biomarkers predictive of, and correlated to, visual function, such as change in area of geographic

atrophy in dry AMD treatment trials (as in the MAHALO and CHROMA/SPECTRI lamipalzumab trials). However, endpoints involving central visual function may be more clinically meaningful to patients in clinical practice, than surrogate or anatomic endpoints, such as the proportion of patients with a two-step progression in diabetic retinopathy severity scale. Secondary and supportive endpoints should provide additional contextual, supportive and clinical meaningfulness to the primary endpoint.

When evaluating a trial’s endpoints, also ask: Were endpoints categorical or numeric? Were relevant responder analyses assessed?

Endpoints can be categorical (non-metric) or numeric (metric) variables. The mean change in early treatment of diabetic retinopathy (ETDRS) BCVA (a numeric endpoint) involves protocol refraction by masked certified VA examiners, and is a reliable and well-established functional assessment. (Unless otherwise noted, this article will use “BCVA” to denote ETDRS best corrected visual acuity.) As a validated and continuous metric (i.e., with intermediary values between whole numbers), BCVA captures macular function better than most other endpoints, as even small changes in its magnitude can reflect marked benefit or harm for subjects.

“Responder analyses” involve categorical endpoints, such as the pro-

**Table 1: Drug and Biologic Development Process in the U.S.**

1. Preclinical laboratory testing, animal studies and formulation studies, conducted in accordance with Good Laboratory Practices (GLP)
2. Investigational New Drug (IND) submission to the FDA, prior to human clinical trials
3. Human clinical trials, conducted in accordance with Good Clinical Practice (GCP), to establish the efficacy and safety of investigational drugs, or the safety, purity and potency of a biologic product
4. Approval by an Independent Review Board (IRB), prior to initiation of each clinical trial
5. Submission to the FDA of a New Drug Application (NDA) or Biologics License Application (BLA)
6. Validation of manufacturing process
7. FDA inspection of manufacturing facilities to assess compliance with Good Manufacturing Practice (GMP) to ensure that the facilities, methods and controls are adequate to preserve the drug’s identity, strength, quality and purity
8. FDA review and approval

portion of subjects achieving the level of vision correlating to driving legally, reading without difficulty or avoiding legal blindness. Although categorical endpoints are associated with loss of information (i.e., a dichotomous outcome at the subject level, either achieving a visual milestone or not), responder analyses aren’t affected by outliers and provide context, translating a BCVA endpoint to clinically relevant functional outcomes at the subject level.<sup>9</sup> A seemingly small change in mean BCVA for an entire clinical trial cohort often translates into a large clinically meaningful change in a responder analysis at the subject level. A meta-analysis of clinical trials in nAMD published in 2007 noted that a change in mean BCVA of five letters or less can yield significant subject benefit. The meta-analysis found that a mean change in BCVA of five letters for a cohort resulted in twice as many eyes (32 vs. 16 percent) with a  $\geq 15$ -letter improvement and 28 percent fewer eyes (13 percent vs. 18 percent) with a  $\geq 15$ -letter worsening.<sup>10</sup> Other large clinical trials have demonstrated that even smaller numbers of letters gained can provide notable benefit for subjects. For example, in the MEAD trial, the 0.7-mg dexamethasone implant arm showed a 1.5-letter benefit compared to sham at three years (3.5- vs. 2-letter gain,  $p=0.023$ ), which respectively translated to 22 percent vs. 12 percent gaining at least three lines

( $p<0.001$ ), and therefore meeting its primary endpoint.<sup>11</sup>

Historically, the proportion of subjects losing less than 15 letters (three lines) of BCVA has been used as a primary endpoint in Phase III regis-

tration trials of anti-VEGF agents for nAMD (as in the MARINA and ANCHOR ranibizumab trials, as well as VIEW aflibercept trials).<sup>7,12,13</sup> The MARINA trial ushered in the age of vision-improving therapy, with 95 percent of nAMD subjects losing less than three lines, compared to 62 percent in the untreated control group.<sup>12</sup> However, in current nAMD treatment trials involving actively treated control groups (receiving standard anti-VEGF agents), a vast majority of subjects treated with anti-VEGF monotherapy would be “responders” (~95 percent losing less than 15 letters of BCVA).<sup>7, 12, 13</sup> Consequently, this endpoint would be very susceptible to ceiling effects. For example, in the VIEW aflibercept trials, which also used this primary endpoint,  $\geq 94$  percent of all subjects across treatment groups lost less than 15 ETDRS letters.<sup>7</sup>

## Analysis and Study Design

Important considerations when evaluating a study’s analysis and design include:

- **Pre-specified analysis.** A central pillar of RCT design is that endpoints and analysis be pre-specified, typically in a statistical analysis plan. Post hoc analysis, which involves the assessment of endpoints selected after unmasking of data is acceptable for hypothesis generation and planning for additional RCTs, but generally not acceptable for

# RETINA ONLINE

## E-NEWSLETTER



Once a month, Medical Editor Philip Rosenfeld, MD, PhD, and our editors provide you with timely information and easily accessible reports that keep you up to date on important information affecting the care of patients with vitreoretinal disease.

**3 EASY WAYS TO SUBSCRIBE!**

<http://www.jobson.com/globalemail/>

Fax: 610.492.1039 or Call: 610.492.1029

**REVIEW<sup>®</sup>**  
of Ophthalmology

an efficacy claim.

- **Descriptive analysis, confidence intervals and inferential analysis.** Descriptive analysis summarizes and organizes data and includes familiar terms such as mean, median and range, as well as histograms displaying the distribution of values. Exploratory analyses employing descriptive statistics are useful for hypothesis generation and may facilitate planning of additional RCTs.

Confidence intervals reflect the certainty that a result from a study sample represents a true measure of an entire population. CIs are based on the Central Limit Theorem. For sample sizes greater than 30, CI = sample mean  $\pm$  standard error of the mean, and SEM = (Standard Deviation of the sample) / (square root of the number in sample). Thus, large samples with little variation yield narrow CIs. Very large samples approaching the population size would appropriately yield a CI approaching zero, indicating that the sample mean is approaching the population mean.

For example, a mean BCVA of seven letters, derived from a sample of study subjects, with a 95% CI of four to 10 letters, indicates that there is 95-percent certainty that the true mean BCVA for the entire population under the same conditions would be four to 10 letters.

Inferential analysis involves hypothesis testing, to assess the likelihood that a difference between treatment and control groups isn't due to chance ("the null hypothesis"), but a true difference ("rejecting the null hypothesis"). The conventional threshold for statistical significance ("alpha") of  $p < 0.05$  indicates that there is less than a 5-percent likelihood that a difference between the treatment and control groups is due to a play of chance (a false positive or a type 1 error—a trade-off with a false negative or type 2 error, correlating to "beta"). Regulatory bodies usually require two RCTs with statistically significant results ( $p < 0.05$ ), to decrease

type 1 errors (because the likelihood that the outcome is due to a play of chance in both RCTs is less than  $0.05 \times 0.05$ , or less than 0.25 percent).

The power of a study reflects the chance of obtaining a true negative result (i.e., not committing a type 2 error, which equals  $1 - \beta$ , conventionally adequate at 0.8). Increasing sample size increases power, while decreasing both alpha and beta and simultaneously addressing trade-offs among these parameters.

The t-test is a familiar test for continuous variables, used to compare means between two samples, such as mean change in BCVA in the treatment group versus the control group. Similarly, analysis of variance (ANOVA) testing is a test for continuous variables, but used to compare means of three or more groups. Chi-square tests are for categorical variables, such as the proportion of subjects losing less than 15 letters. Fisher's Exact Tests are similar to Chi-Square Tests, but used with small sample sizes.

- **Controlling for multiplicity.** When RCTs perform inferential analysis on multiple endpoints, multiple doses or multiple time points (i.e., an interim analysis), type 1 error increases because, with each analysis, achieving a falsely positive significant difference between treatment and control due to a play of chance becomes increasingly likely. Consequently, analyses must control for multiplicity. Perhaps the simplest and best-known correction for multiplicity is the Bonferroni Method, which is a conservative method (used in CATT<sup>8</sup>). For example, in a study with a predefined statistical significance of  $p < 0.05$ , the Bonferroni method controls type 1 error by simply redefining statistical significance as  $p < 0.05/n$  for each analysis, where  $n$  represents the number of analyses.<sup>14</sup>

Another method, which doesn't redefine statistical significance based on the number of inferential tests, involves prespecification of the hierar-

chical order in which endpoints are inferentially assessed, and discontinuing this sequence of testing at the point at which statistical significance is not achieved (used in the VIEW<sup>7</sup> and VISTA/VIVID<sup>5</sup> trials).

- **Does the primary analysis involve superiority or non-inferiority?** RCTs can be designed as superiority or non-inferiority studies, as well as equivalence studies. In nAMD and DME clinical trials, superiority study design has been used to compare first-in-class therapies to sham control (when approved therapies didn't exist), or to previous therapies. For example, in both MARINA and RISE/RIDE, the primary endpoint analysis was superiority of ranibizumab to sham control, with respect to the proportion of nAMD subjects losing less than 15 ETDRS letters of BCVA at 12 months for MARINA, or the proportion of DME subjects gaining at least 15 ETDRS letters of BCVA at 24 months for RISE/RIDE.<sup>12,15</sup>

In ANCHOR, the primary endpoint analysis was superiority of ranibizumab vs. control verteporfin photodynamic therapy (already approved for the classic choroidal neovascular lesions enrolled in this trial), with respect to the proportion of nAMD subjects losing less than 15 ETDRS letters of BCVA at 12 months.<sup>13</sup> In VISTA/VIVID, the primary endpoint analysis was superiority of aflibercept to macular laser photocoagulation for DME, with respect to the mean change of BCVA at 12 months.<sup>5</sup>

A non-inferiority design is often used to compare a second-in-class or generic therapy to an approved therapy. Product differentiation can be achieved by less-frequent dosing, improved safety or tolerability, and/or lower cost, particularly for a generic or off-label agent such as bevacizumab. An acceptable level of difference between the two therapies is predefined as non-inferiority; typically, the 95% confidence interval of the observed difference must be less than this pre-

## Table 2: Clinical Trial Phases

### Phase I:

- Phase I studies are exploratory.
- After undergoing preclinical testing in animal models, investigational drugs move into Phase I studies, which generally involve small groups of healthy volunteers. These studies evaluate safety, dose ranges, absorption, metabolism, distribution and excretion, as well as adverse events.
- In situations in which investigational drugs for severe or life-threatening disease may be too toxic to ethically administer to healthy volunteers, Phase I studies can be conducted in subjects with the target disease.

### Phase II:

- Like Phase I studies, Phase II studies are exploratory.
- Phase II studies evaluate safety and preliminary efficacy in subjects with the target disorder; these studies can be controlled or uncontrolled.
- Dosing is often assessed in Phase II studies. Dose response can provide critical insight into the biologic plausibility of a treatment effect and provide information useful in the design of larger later-phase trials.
- Positive results in Phase II trials generally don't merit claims of efficacy, but instead can result in a call for confirmatory Phase III RCTs.

### Phase III:

- Phase III studies are larger, confirmatory RCTs designed to more thoroughly investigate the efficacy and safety of investigational drugs, or the safety, purity and potency of a biologic product. Phase III studies ("registration trials") establish the risk/benefit ratio and support approval by regulatory authorities.
- These RCTs often have a parallel-group, randomized, double-masked, multicenter design and involve extensive statistical testing and modeling.
- Randomization and masking are employed to minimize bias in treatment allocation and to allow unbiased evaluations of subjects in different treatment groups.
- Multiple centers are often employed, not only to enhance recruitment, but also to enhance generalizability of study results to a disease population, and also to minimize the risks associated with single-center trials.

### Phase IV:

- Phase IV studies are larger post-marketing studies, often done to assess less-common adverse events.

defined level. For example, in CATT, which used the Bonferroni method for multiple comparisons (alpha of 5 percent divided by six pairwise comparisons), the primary endpoint analysis was noninferiority of bevacizumab to ranibizumab regimens for nAMD, with respect to the mean change of BCVA at month 12, with the 99.2% confidence interval of the difference to fall within a prespecified five letters.<sup>8</sup> In contrast, in the VIEW trials, which used hierarchical analysis, the primary endpoint analysis was noninferiority of aflibercept regimens to ranibizumab, with respect to the proportion of subjects losing less than 15 ETDRS letters at month 12, with the 95% confidence interval of the difference to fall within a prespecified 10-percent margin for noninferiority.<sup>7</sup> Incidentally, although

equivalence isn't often used in AMD and DME studies, in the VIEW trials, the FDA suggested that a 5-percent margin could determine equivalence.<sup>7</sup>

While non-inferiority would appear on its face to represent a lower hurdle than superiority, demonstrating non-inferiority within the typically tight predefined band often requires more patients to achieve the same power.

• **Was an intent-to-treat analysis performed?** Is missing data described and addressed? In retina treatment trials, subject dropout is often related to poor response to treatment, transportation issues, cost, older age, treatment fatigue, illness and/or death.<sup>1,16-19</sup> Moreover, it's been observed that nAMD subjects ultimately lost to follow-up have worse evolving visual outcomes compared to other subjects.<sup>1,3,18</sup>

Consequently, missing data from subject dropout in RCTs may overestimate visual outcomes. Therefore, three analysis populations are typically predefined:

— The intent-to-treat population (ITT) consists of all randomized subjects who received at least one dose of the study drug and underwent at least one follow-up visit, regardless of the dose actually received or the visits completed.

— The per-protocol (PP) population consists of all ITT subjects without any significant violation of the protocol, such as missing a critical number of planned treatments.

— The safety population includes all subjects who received at least one injection of the study drug.

The main analysis for the primary efficacy endpoint should consist of the ITT population. Analysis of a per-protocol population, in which subjects lost to follow-up are excluded from analysis, can yield an overestimation of visual outcomes. In a well-managed clinical trial without high subject dropout, the ITT and PP populations would ideally be nearly identical. Similarly, analyses of an ITT population that is modified after unmasking the data (a "modified ITT population," or mITT) may allow selection bias to creep into the analysis, and should be subjected to careful scrutiny.

In the past, addressing missing data through analysis of an ITT population, with last observation carried forward (LOCF), was commonly performed (as in MARINA,<sup>12</sup> ANCHOR,<sup>13</sup> VIEW,<sup>7</sup> RISE/RIDE<sup>15</sup> and VISTA/VIVID<sup>5</sup>). However, the LOCF imputation approach relies on the erroneous assumption that vision remains constant after loss to follow-up, and consequently can inflate study results.<sup>20-23</sup> In contrast, nonresponder imputation rigorously considers any subject with missing data to have missed the endpoint, deflating study results. Additional methods such as multiple imputation (used



EVERY MONDAY  
**E-NEWS YOU CAN USE**



Have you been receiving and reading custom e-blasts from *Review of Ophthalmology*?

If not, you're missing out on valuable information!

You're a busy practitioner and not surprisingly, your e-mail inbox is often full. Fortunately, when you scan through the sender list, determining which messages to delete and which to save or read, you can feel confident knowing that e-blasts from *Review of Ophthalmology*, a Jobson Medical Information LLC publication, contain the most current and comprehensive information available in the field to keep you on the cutting edge.

*Review of Ophthalmology's* online stable of products includes editorial newsletters and promotional information about new products, treatments and surgical techniques, as well as alerts on continuing education courses for ophthalmologists.



Our FREE weekly e-newsletter, *Review of Ophthalmology Online*, brings you the latest in ophthalmic research, as well as industry news. In an effort to keep eyecare professionals informed, this resource is waiting in your inbox **every Monday morning**.



*Retina Online*, our free monthly e-newsletter, is for retina specialists and general ophthalmologists interested in enhancing their knowledge on the topics of retina and related disease diagnosis and treatment, as well as the latest in surgical procedures.

Your time is valuable — and so is your practice. These e-products are the most effective way for you to receive updates on breaking news and research — all just a click away.

**DON'T MISS OUT!**

Unfamiliar with our products? Visit [www.reviewofophthalmology.com](http://www.reviewofophthalmology.com) and check out our newsletter archives.

Go to [www.jobson.com/globalEmail/default.aspx](http://www.jobson.com/globalEmail/default.aspx) to sign up for the e-newsletters that interest you.

in CATT<sup>8</sup>) make use of other data within the study to estimate the missing data.<sup>20, 24</sup>

- **Were sensitivity analyses conducted and, if so, were they appropriate?** Sensitivity analyses are employed to confirm the robustness of data (i.e., that the observed outcomes remain true across a variety of missing data scenarios and assumptions). Historically, for the analysis of the primary endpoint, analysis using a LOCF imputation approach, or analysis of only subjects completing the particular time point of interest, or a worst observation carried forward imputation approach (WOCF) has been used.

- **Were any confounding imbalances in baseline demographics between treatment and control groups addressed?** When interpreting study results, it's important to assess if the treatment groups are balanced in demographic and clinical characteristics, especially those confounding factors known to influence the outcome measures, because even randomization can sometimes lead to imbalances, especially when evaluating subgroups (although this tends to diminish with increasing study sample size). In general, stratification at enrollment can control for two to three confounding imbalances in baseline features known to affect study outcomes,<sup>25</sup> such as age, baseline BCVA or CNV size and type in nAMD RCTs.

In addition, analysis of covariance (ANCOVA, not to be confused with ANOVA) is a familiar test of significance that can simultaneously control for covariates. Clinicians should carefully scrutinize RCTs involving important baseline demographic imbalances that haven't been addressed.

## Totality of the Data

Since they're exploratory and designed for preliminary assessment, Phase I and IIa clinical trials don't ad-

dress many of the issues noted above, as they may lack controls, randomization, masking or power for inferential analysis. In addition, regardless of phase, clinical trials often don't meet all endpoints. Consequently, assessing the totality of the data can provide insight into the utility of a potential therapy. Here are some key questions and considerations:

- **Are endpoint results internally consistent?** Are the secondary endpoints supportive of, and consistent with, the primary visual endpoints? If the primary endpoint isn't met, then secondary and supportive endpoints are generally less meaningful, although they can be important for hypothesis generation and for planning of future trials. Secondary and supportive visual function endpoints, such as responder analyses, should be internally consistent. Secondary and supportive anatomic endpoints are most commonly used to contextually support the functional benefit of an intervention, by supporting a mechanism of action and biologic plausibility. These anatomic endpoint outcomes should be consistent with the observed visual benefit of an intervention.

- **Is there a dose-response effect?** A dose-response effect is an intuitive check on the results of a RCT. Dose response suggests biologic plausibility, and typically plateaus at higher levels, resulting in dose-response curve. In addition to supporting biologic plausibility, dose response can help inform the design of larger, later-phase trials.

- **What is the actual p-value of the study?** How large is the treatment effect? Regardless of p-values, is the effect clinically meaningful? Statistical significance increases with larger effect size and lower variation. Since larger studies generally reduce variation surrounding mean values, a large study demonstrating a small treatment effect can achieve statistical significance, while a small study suggesting greater treatment effect may fail to achieve

statistical significance (a type 2 error, equal to the value of beta). In these small trials, a near-significant result may assist with hypothesis generation and inform future trial design.

For example, in the Phase II MAHALO study of lomalizumab in geographic atrophy due to AMD, which included a surrogate primary endpoint of mean change in GA lesion area at month 18, there was 20-percent reduction associated with monthly dosing compared to sham control, with a p-value of 0.117, in a mITT analysis with LOCF.<sup>26</sup> Due to the small size of this proof-of-concept study (129 subjects randomized to two dose groups or sham), which isn't uncommon for Phase II studies, there was no multiplicity adjustment and a liberal pre-specified level of significance of  $p < 0.2$  to minimize type 2 error (trading off against increased type 1 error). Given the effect size (and even greater 44-percent treatment effect in a subgroup analysis) for a blinding disorder with no approved treatment, lomalizumab advanced into Phase III trials.

The treatment effect size can be assessed further with several parameters. Absolute risk reduction (ARR) is the absolute difference in outcomes between the treatment and control groups. For example, in the MARINA trial, with 95 percent of treated subjects losing less than three lines compared to 62 percent in the sham group, the absolute risk reduction of losing at least three lines compared to sham at 12 months was 38% - 5% or 33%. The relative risk reduction (RRR) was 33%/38% or 87%. The effect size can be better understood by considering the number needed to treat (NNT), which is the reciprocal of absolute risk reduction. In MARINA, this results in an NNT of 1/0.33 or 3, indicating that a physician would need to treat three nAMD patients with monthly ranibizumab to prevent a  $\geq 3$ -line loss in one patient at 12 months. In comparison, an article in the January 17,

2008 issue of *Business Week* magazine found that the NNT to prevent myocardial infarction via a daily statin for 3.5 years approaches 100 (in those with risk factors but without prior heart disease).<sup>27</sup> One very interesting website (<http://www.thennt.com/>) uses the NNT from evidence-based studies (mostly Cochrane Reviews) to evaluate a broad range of therapies and lists an NNT of 7 to resolve bacterial conjunctivitis at two to five days via topical antibiotics.

In summary, proper interpretation of RCT results is vital in order to appropriately apply the findings to clinical practice and to guide therapy. This would include consideration of the RCT phase, design, subject selection criteria, choice of control, dose selection, masking and selection of the endpoints. Review of statistical methodology can be intimidating, but clinicians can check for vital statistical items such as predefined levels of significance, analysis populations and multiplicity, as well as any methods used to handle missing data, which is a common problem in RCTs involving elderly or ill subjects. Finally, remember that it's important to assess all the data for internal consistency, dose response, and size of treatment effect. **REVIEW**

*Dr. Ciulla is a volunteer clinical professor of ophthalmology at the Indiana University School of Medicine, and serves on the Retina Service at Midwest Eye Institute. He can be reached at thomasciulla@gmail.com, or at 317-817-1822 (phone) and 317-817-1898 (fax). He has an employment relationship with Ophthotech Corporation.*

- Rasmussen A, Bloch SB, Fuchs J, et al. A 4-year longitudinal study of 555 patients treated with ranibizumab for neovascular age-related macular degeneration. *Ophthalmology* 2013;120:12:2630.
- Ross AH, Donachie PH, Sallam A, et al. Which visual acuity measurements define high-quality care for patients with neovascular age-related macular degeneration treated with ranibizumab? *Eye (Lond)* 2013;27:1:56-64.
- Talks JS, Lotery AJ, Ghanchi F, et al. First-year visual acuity outcomes in the united kingdom of providing aflibercept according to the VIEW study protocol for age-related macular degeneration.

- Ophthalmology* 2015;123:2:337-43.
- Writing Committee for the U. K. Age-Related Macular Degeneration EMR Users Group. The neovascular age-related macular degeneration database: Multicenter study of 92,976 ranibizumab injections: Report 1: Visual acuity. *Ophthalmology* 2014;121:5:1092-101.
- Korobelnik JF, Do DV, Schmidt-Erfurth U, et al. Intravitreal aflibercept for diabetic macular edema. *Ophthalmology* 2014;121:11:2247-54.
- Diabetic Retinopathy Clinical Research N, Wells JA, Glassman AR, et al. Aflibercept, bevacizumab, or ranibizumab for diabetic macular edema. *N Engl J Med* 2015;372:13:1193-203.
- Heier JS, Brown DM, Chong V, et al. Intravitreal aflibercept (VEGF trap-eye) in wet age-related macular degeneration. *Ophthalmology* 2012;119:12:2537-48.
- CATT Research Group, Martin DF, Maguire MG, et al. Ranibizumab and bevacizumab for neovascular age-related macular degeneration. *N Engl J Med* 2011;364:20:1897-908.
- Tal J. Strategy and statistics in clinical trials: A non-statistician's guide to thinking, designing, and executing. Vol IX. Amsterdam, Boston: Academic Press, 2011:267.
- Beck RW, Maguire MG, Bressler NM, et al. Visual acuity as an outcome measure in clinical trials of retinal diseases. *Ophthalmology* 2007;114:10:1804-9.
- Boyer DS, Yoon YH, Belfort R Jr, et al. Three-year, randomized, sham-controlled trial of dexamethasone intravitreal implant in patients with diabetic macular edema. *Ophthalmology* 2014;121:10:1904-14.
- Rosenfeld PJ, Brown DM, Heier JS, et al. Ranibizumab for neovascular age-related macular degeneration. *N Engl J Med* 2006;355:14:1419.
- Brown DM, Kaiser PK, Michels M, et al. Ranibizumab versus verteporfin for neovascular age-related macular degeneration. *N Engl J Med* 2006;355:14:1432-44.
- Wang D, Li Y, Wang X, et al. Overview of multiple testing methodology and recent development in clinical trials. *Contemp Clin Trials* 2015;45:Pt A:13-20.
- Nguyen OD, Brown DM, Marcus DM, et al. Ranibizumab for diabetic macular edema: Results from two phase III randomized trials: RISE and RIDE. *Ophthalmology* 2012;119:4:789-801.
- Singer MA, Awh CC, Sadda S, et al. HORIZON: An open-label extension trial of ranibizumab for choroidal neovascularization secondary to age-related macular degeneration. *Ophthalmology* 2012;119:6:1175-83.
- van Asten F, Evers-Birkenkamp KU, van Lith-Verhoeven JJ, et al. A prospective, observational, open-label, multicentre study to investigate the daily treatment practice of ranibizumab in patients with neovascular age-related macular degeneration. *Acta Ophthalmol* 2015;93:2:126.
- Kruger Falk M, Kemp H, and Sorensen TL. Four-year treatment results of neovascular age-related macular degeneration with ranibizumab and causes for discontinuation of treatment. *Am J Ophthalmol* 2013;155:1:89-95 e3.
- Holz FG, Tadayoni R, Beatty S, et al. Multi-country real-life experience of anti-vascular endothelial growth factor therapy for wet age-related macular degeneration. *Br J Ophthalmol* 2015;99:2:220-6.
- Olsen MK, Stechuchak KM, Edinger JD, et al. Move over LOCF: Principled methods for handling missing data in sleep disorder trials. *Sleep Med* 2012;13:2:123-32.
- Wong WK, Boscardin WJ, Postlethwaite AE, et al. Handling missing data issues in clinical trials for rheumatic diseases. *Contemp Clin Trials* 2011;32:1:1-9.
- Hedden SL, Woolson RF, Carter RE, et al. The impact of loss to follow-up on hypothesis tests of the treatment effect for several statistical methods in substance abuse clinical trials. *J Subst Abuse Treat* 2009;37:1:54-63.
- Mallinckrodt CH, Sanger TM, Dube S, et al. Assessing and interpreting treatment effects in longitudinal clinical trials with missing data. *Biol Psychiatry* 2003;53:8:754-60.
- O'Neill RT, Temple R. The prevention and treatment of missing data in clinical trials: An FDA perspective on the importance of dealing with it. *Clin Pharmacol Ther* 2012;91:3:550-4.
- Cunningham ET Jr, Acharya N, Kempen JH, et al. Design and interpretation of clinic-based studies in uveitis. *Ocular Immunology and Inflammation* 2015;23:4:267-270.
- Yaspan BL, Williams DF, Holz FG, et al. Targeting factor D of the alternative complement pathway reduces geographic atrophy progression secondary to age-related macular degeneration. *Sci Transl Med* 2017;9:395.

(Continued from page 32)

So, in the future, it may be used as a screening test as part of our OCT to determine which patients need to be treated or followed more carefully."

While there's a role for OCT-A in the clinic, Dr. Stone believes this imaging technique needs to be able to image a broader area. "That's currently being developed, and I expect continued improvements," he says. "Another limitation is the degree to which OCT-A can show dynamic leakage. When I see leakage on my FA, that provides me with a hint of levels of activity. OCT-A just looks at structure. The question is, if diseases show leakage on fluorescein angiography, is there a way that can be shown on OCT-A?"

There are also practice management issues to consider. Dr. Stone explains that, in most geographic areas, payment is no different for OCT-A than it is for standard OCT. "You can't charge for an angiogram; you have to charge for OCT, so you're paying more to acquire an instrument that may not pay for itself if you don't have a patient population that might benefit from the additional information," he observes. "This being said, many of us use newer technology such as this because it provides information that is helpful for our patients, despite uncertain economics. Many smaller practices may need to figure out the financial side of it. If the economics could be worked out more thoroughly, this exciting technology could be available to more practitioners." **REVIEW**

*Dr. Boyer is a consultant to Optovue. Drs. Stone and Skondra have no financial interest in the products discussed.*

- Ting DSW, Tan GSW, Agrawal R, et al. Optical coherence tomographic angiography in type 2 diabetes and diabetic retinopathy. *JAMA Ophthalmol* 2017;135:4:306-312.
- Al-Sheikh M, Iafe NA, Phasakijwatana N, Sadda SR, Sarraf D. Biomarkers of neovascular activity in AMD using OCT angiography. *Retina* 2017 May 2. E-pub ahead of print.
- Khairallah M, Abroug N, Khoctali S, et al. Optical coherence tomography angiography in patients with Behcet uveitis. *Retina* 2016 Dec 20. E-pub ahead of print.

# FDA Approval for Zerviate 0.24%

**I**n late May, Nicox received FDA approval for Zerviate (cetirizine ophthalmic solution 0.24%) for treatment of ocular itching associated with allergic conjunctivitis.

Three randomized, double-masked, placebo-controlled, conjunctival antigen-challenge-model clinical trials established the efficacy of Zerviate. The trials studied patients with a history of allergic conjunctivitis. The most commonly reported adverse reactions (ocular hyperemia, instillation site pain and reduction in visual acuity) only occurred in 1 to 7 percent of patients treated. The recommended dose of Zerviate is one drop in each affected eye, twice daily (about eight hours apart).

For more information on Zerviate 0.24%, visit [nicox.com](http://nicox.com).

## Eyefficient's Portable Fundus Camera

**I**n mid-July, Eyefficient, through a partnership with MediWorks, introduced its new handheld fundus camera, the FC160, in the U.S. This new fundus camera joins Eyefficient's other MediWorks equipment Digital Slit Lamp Imaging and LED Vision Chart Systems.

The camera features a rechargeable lithium-ion battery. Eyefficient also says

that the portable fundus camera weighs only 420 g. Eyefficient highlights the convenience of its MediWorks products, claiming that with the Portable Fundus Camera and its other products, doctors are able to capture retinal images with ease, using features such as the fundus camera's 3.97-inch touch screen and five internal fixation targets.

For more information on Eyefficient's Portable Fundus Camera, visit [eyefficient.com](http://eyefficient.com).

## Bausch + Lomb's Fortifeye Capsular Tension Ring

Bausch + Lomb has announced the launch of its Fortifeye capsular tension ring. The ring is a pre-loaded, sterile, non-optical implant for the stabilization of the crystalline lens capsule due to weak or partially absent zonules in adult patients who are undergoing cataract extraction.

Some indications for its use include primary zonular weakness (Marfan syndrome), secondary zonular weakness (trauma or vitrectomy), cases of zonulysis, cases of pseudoexfoliation and cases of Weill-Marchesani syndrome.

The implants are made of one

continuous piece of polymethyl methacrylate. They are available in both counterclockwise and clockwise insertion options, 10-mm, 11-mm and 12-mm diameters.

For more information on the Fortifeye capsular tension ring, visit [bausch.com](http://bausch.com).

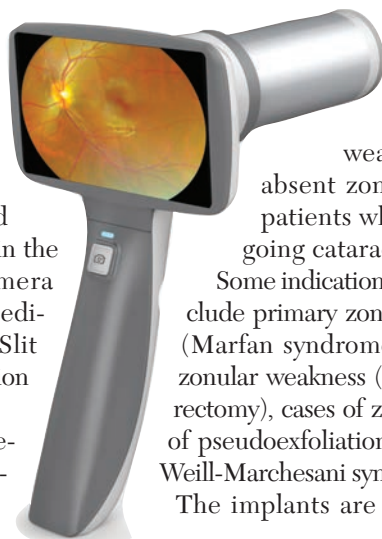
## FDA Clearance for Mynosys' Zepto

The FDA recently approved the Zepto capsulotomy system, a disposable handpiece that uses a combination of suction and low-energy pulses for high-quality, fast capsulotomies.

The device can be integrated into standard cataract surgery and is inserted through a 2.2-mm incision. The FDA clearance comes following the results of studies published in February 2016, one of which found that the Zepto produced complete, round capsulotomies with minimal zonular stress in live rabbits and human cadaver eyes.

Mynosys highlights the Zepto's unique design, which incorporates nanopulse technology that reduces surgical time. It has a four-millisecond cutting time and Mynosys says it creates a consistent and uniform capsulotomy.

For more information on Mynosys' Zepto, visit [mynosys.com](http://mynosys.com).



24<sup>TH</sup> ANNUAL  
**OPHTHALMIC**  
*Product Guide*

Innovative products to enhance your practice



The **future**  
is in your  
hands. One  
tap, many  
possibilities.

Experience the digital edition  
on your handheld device.  
Use your smart device to  
scan the code below or visit:

[www.reviewofophthalmology.com/supplements/](http://www.reviewofophthalmology.com/supplements/)

Download a QR scanner app. Launch app and hold your  
mobile device over the code to view  
<http://www.reviewofophthalmology.com/supplements/>.



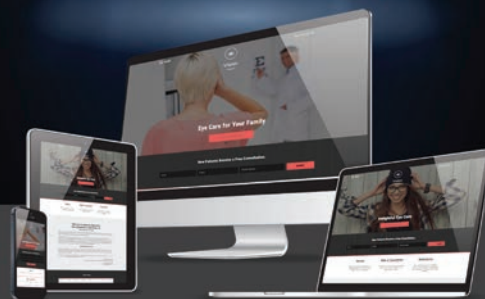**REVIEW**<sup>®</sup>  
of Ophthalmology

# ATTRACT NEW PATIENTS

with new website designs that  
are outta this world! Contact  
us for a **free evaluation** and  
receive **40% off** initial setup.

📞 877.716.0927

🌐 [go.imatrix.com/ReviewOphthalmology](http://go.imatrix.com/ReviewOphthalmology)



 **imatrix**<sup>™</sup>

PREMIER  
Google  
Partner

BBB  
ACCREDITED  
BUSINESS

**Equipment and Supplies**

**NEW**

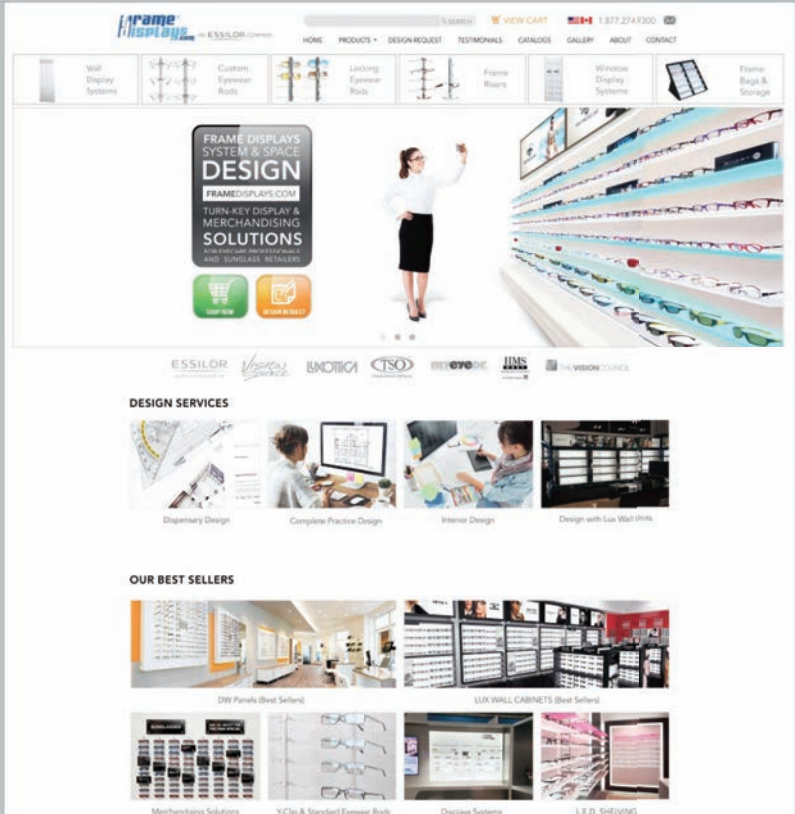
VISIT US AT OUR  
**NEW WEB SITE**  
**FRAMEDISPLAYS.COM**

SYSTEM & SPACE  
**DESIGN**

TURN-KEY DISPLAY & MERCHANDISING  
**SOLUTIONS**



**1-877-274-9300**  
[www.framedisplays.com](http://www.framedisplays.com)



ESSILOR  
VISION CARE  
LUDWICK  
EYE CENTER  
LUX WALL CABINETS  
L.E.D. SHELVING

**DESIGN SERVICES**

Dispensary Design    Complete Practice Design    Interior Design    Design with Lux Wall Units

**OUR BEST SELLERS**

DW Panels (Best Seller)    LUX WALL CABINETS (Best Seller)

Merchandising Solutions    Y-Clip & Standard Eyewear Rods    Display Systems    L.E.D. SHELVING

**Practice For Sale**



Practice Sales • Appraisals • Consulting  
[www.PracticeConsultants.com](http://www.PracticeConsultants.com)

**PRACTICES FOR SALE  
NATIONWIDE**


Visit us on the Web or call us to learn more about our company and the practices we have available.  
[info@PracticeConsultants.com](mailto:info@PracticeConsultants.com)  
**800-576-6935**  
[www.PracticeConsultants.com](http://www.PracticeConsultants.com)

**Career Opportunities**

**OPHTHALMOLOGISTS**  
Danbury, CT

Ophthalmologists to share office with long standing Ophthalmologist in Danbury, CT. High quality equipment. \$2,250 per month or adjoining office without equipment- \$1,750 per month.

**203-545-3539 or  
email [mehrimd@aol.com](mailto:mehrimd@aol.com)**



**HIGH VOLUME CATARACT AND GLAUCOMA PRACTICE SEEKS CATARACT/CORNEA/ANTERIOR SEGMENT OPHTHALMOLOGIST.**

State of the art clinical equipment and two ASCs. We desire motivated, patient-focused candidate with excellent surgical skills who seeks to practice in a team practice setting. Maryland and PA license preferred. Salary with productivity bonus and partnership opportunity in both practice and ASC.

Send CV to: **Kris Culler**  
Email: [kculler@ludwickeye.com](mailto:kculler@ludwickeye.com)  
Ludwick Eye Center  
825 Fifth Ave  
Chambersburg, PA 17201  
Fax 717-262-9714



**CONTACT US TODAY  
FOR CLASSIFIED ADVERTISING**  
Toll free: **888-498-1460**  
E-mail: [sales@kerhgroup.com](mailto:sales@kerhgroup.com)



**Targeting Ophthalmologists?**

**CLASSIFIED ADVERTISING WORKS**

- JOB OPENINGS
- CME PROGRAMS
- PRODUCTS & SERVICES
- AND MORE...

Contact us today for classified advertising:  
Toll free: **888-498-1460**  
E-mail: [sales@kerhgroup.com](mailto:sales@kerhgroup.com)

Sudden blurred vision, floaters and metamorphopsia bring a 50-year-old woman to Wills Eye Hospital.

*Jason Flamendorf, MD, and James P. Dunn, MD*

## Presentation

A 50 year-old Caucasian female with sudden onset of blurred vision, floaters and metamorphopsia in her right eye presented for ophthalmic evaluation. Four to five days prior to onset of the visual symptoms, she developed headache, fatigue and flank pain, followed by patches of hives on her torso and lower extremities. She presented to a local emergency room where a CT scan showed mesenteric adenitis. She denied any symptoms in her left eye. Of note, the patient had recently suffered a deep scratch from a stray cat she had adopted.

## Medical History

Past ocular history included LASIK in both eyes. Past medical history disclosed arthritis, chronic kidney disease and sinusitis. Family history included a father who had heart disease. Social history was significant for owning a stray cat but was otherwise unremarkable.

Current medications included: artificial tears; conjugated estrogens/bazedoxifene; levocetirizine; aspirin; vitamin D; vitamin E; and fish oil.

## Examination

Ocular examination demonstrated visual acuity of count fingers in the right eye and 20/50-2 in the left eye. Pupils were pharmacologically dilated at the time of examination. Intraocular pressures were 9 and 10 mmHg in the right and left eyes, respectively. Confrontation visual fields were diffusely constricted in both eyes. Extraocular motility was full bilaterally. The anterior segment examination revealed intact LASIK flaps and trace nuclear sclerosis of the lens bilaterally but was otherwise unremarkable.

Dilated fundus examination of the right eye demonstrated trace vitreous cell, hyperemic optic disc edema with extensive peripapillary edema, macular edema with hard exudates and venous tortuosity (*See Figure 1*). The left eye had a normal optic disc, macula and vessels. Small white lesions were observed in both eyes, nasal to the optic disc in the right eye and at the superior vascular arcade in the left eye (*Figure 1, arrows*).

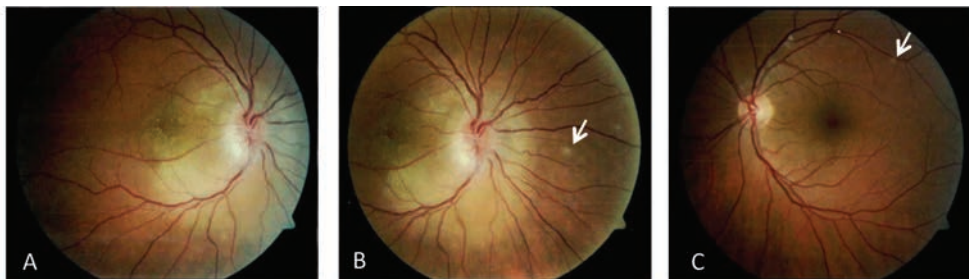


Figure 1. Fundus photos of the right eye's macula (A) and optic nerve (B) demonstrating optic disc edema with extensive peripapillary edema, macular edema, and hard exudates. The left eye (C) is normal with the exception of a white retinal lesion, also seen in the right eye (arrows).

**What is your differential diagnosis? What further workup would you pursue? Turn to p. 64 for the diagnosis.**

## Diagnosis and Management

Ancillary imaging was obtained including fluorescein angiography (Figure 2) and optical coherence tomography of the right eye (Figure 3). IVFA revealed leakage from the optic disc of the right eye without macular leakage or vasculitis; a late frame of the left eye was normal. OCT demonstrated significant thickening of the retinal nerve fiber layer, macular edema in the outer nuclear layer with associated hard exudates in the outer plexiform layer (Figure 3, arrows) and subretinal fluid. The edema was primarily peripapillary and nasal to the fovea.

The differential diagnosis of this patient with sudden onset, unilateral vision loss due to optic disc edema and leakage with associated macular edema, subretinal fluid and hard exudates included infectious, inflammatory and neoplastic etiologies. Infectious causes included

bacterial (e.g., *Bartonella*, tuberculosis, syphilis, Lyme disease), viral (e.g., mumps, herpes zoster), fungal (e.g., histoplasmosis), protozoan (e.g., toxoplasmosis) or nematodal (e.g., toxocara). Inflammatory etiologies included sarcoidosis, inflammatory bowel disease and polyarteritis nodosa. Leukemic infiltration of the optic nerve was the primary neoplastic consideration. Given the patient's history of a deep cat scratch two months prior to presentation and her CT scan showing mesenteric adenitis, serologic testing for *Bartonella henselae* and *Bartonella quintana* was performed. Titers for *B. henselae* IgM and IgG were 1:40 and  $\geq 1:1024$ , respectively; *B. quintana* titers were negative. Based on this, the patient was diagnosed with neuroretinitis secondary to cat-scratch disease and started on a 30-day course of doxycycline.

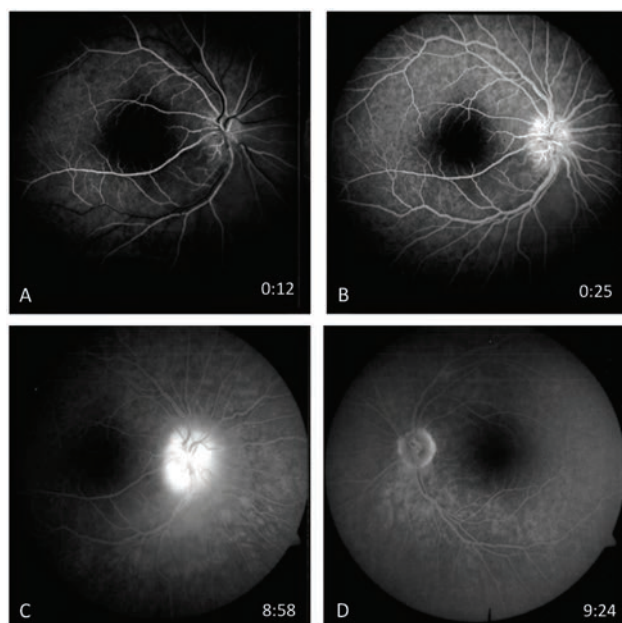


Figure 2. Fluorescein angiography reveals leakage from the optic disc in the right eye (A-C) but no macular leakage or vasculitis. A late frame of the left eye (D) is normal.

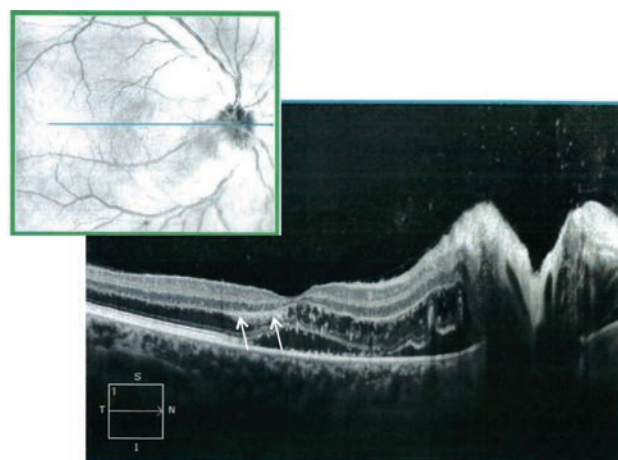


Figure 3. OCT through the macula and optic nerve of the right eye demonstrating significant thickening of the retinal nerve fiber layer, macular edema in the outer nuclear layer with hard exudates in the outer plexiform layer (arrows), and subretinal fluid.

## Discussion

*Bartonella* species are facultative intracellular, slow-growing gram negative rods that typically reside in erythrocytes or endothelial cells to evade the host's immune response.<sup>1,2</sup> Cat-scratch disease (CSD) is caused by the bacterium *B. henselae*, which is maintained and spread among cats via the cat flea and transmitted to humans through scratches, and possibly bites, from cats.<sup>3</sup> In the United States, the incidence is highest in the south Atlantic and south central

states, although the disease occurs throughout the country and worldwide.<sup>4</sup> Almost one-third of cases occur in children 14 years of age or younger, with the highest annual incidence in children 5 to 9 years old. Women are more commonly affected than men, and the peak incidence occurs in January, followed by August through November.<sup>3</sup>

The manifestations of CSD can be described as typical (85 to 90 percent) or atypical (10 to 15 percent) disease.



Typical disease consists of a painless erythematous papule or pustule that develops at the inoculation site a few days to a couple of weeks after the scratch or bite. Painful, occasionally suppurative, lymphadenopathy develops on average one to three weeks later, and approximately half of these patients have fever, malaise and anorexia. Typical disease is usually self-limited but may take weeks to resolve. Atypical disease can consist of ophthalmologic manifestations, encephalopathy, seizures, cranial or peripheral nerve palsies, hepatitis, splenitis, osteomyelitis and erythema nodosum, among myriad other findings that have been reported.<sup>1</sup>

Ophthalmologic involvement in CSD is estimated to occur in 5 to 10 percent of patients, with Parinaud oculoglandular syndrome the most common manifestation, occurring in 2 to 5 percent.<sup>2,5</sup> Neuroretinitis, although a relatively rare complication of CSD, is one of the most recognizable. One study found that 64.3 percent of patients with a clinical diagnosis of neuroretinitis had elevated *B. henselae* IgM or IgG on serology.<sup>6</sup> In comparison, only 3 percent of healthy individuals are seropositive for *B. henselae*.<sup>7</sup>

Neuroretinitis was first described by Theodor Leber in 1916, which he described as a “stellate maculopathy.”<sup>8</sup> Gass subsequently used FA to demonstrate that the site of leakage is the optic nerve, not the macula, and he suggested changing the name to “neuroretinitis.”<sup>9</sup> The typical presentation is sudden-onset unilateral vision loss associated with optic disc edema, macular edema and serous retinal detachment. A macular star pattern often develops two to four weeks after onset as the aqueous phase of the exudate is resorbed and lipid remains in the outer plexiform layer.<sup>10,11</sup> In two cohorts of patients with either CSD neuroretinitis or optic neuropathy (optic disc edema with or without macular involvement), 14.5 to 37.7 percent of eyes had an ini-

tial visual acuity of 20/40 or better, 22.6 to 33.3 percent were between 20/50 and 20/200, and 39.6 to 52.2 percent had worse than 20/200 visual acuity. Both studies found that the majority of patients achieved a visual acuity outcome of 20/40 or better, and that a relative afferent pupillary defect was present in most unilateral cases, but its absence was noted in some instances of severe vision loss, possibly due to a greater contribution from macular disease. Vitritis was present in only 13 percent of eyes.<sup>8,12</sup>

Although most commonly a unilateral disease, the case presented here demonstrates that CSD can present with bilateral but markedly asymmetric ocular findings. One series reported that 4/65 cases (6 percent) of CSD neuroretinitis were bilateral, while another found bilateral neuroretinitis in 2/26 cases (8 percent).<sup>8,12</sup> In the latter study, however, when considering the entire cohort of patients with CSD optic neuropathy, 9/53 cases (17 percent) demonstrated bilateral disease. The prevalence may be even higher if a broader spectrum of ophthalmic manifestations in individuals who are seropositive for CSD is included, with one study finding bilateral intraocular changes in 13/24 patients (54.1 percent) who were positive for *B. henselae* IgG.<sup>13</sup>

Numerous posterior segment findings in CSD have been reported, including focal or multifocal chorioretinitis,<sup>8,14</sup> intermediate uveitis and vasculitis,<sup>15</sup> retinal artery occlusion,<sup>16</sup> retinal vein occlusion,<sup>17</sup> macular hole<sup>18</sup> and choroidal neovascularization.<sup>19</sup> Interestingly, the protean manifestations of different *Bartonella* species not only depend on the particular organism involved but also the strength of the host’s immune system.<sup>2</sup> Bacillary angiomatosis, a well-known entity caused by *B. henselae* in immunocompromised patients, reflects *Bartonella*’s ability to trigger a vasoproliferative response in these individuals. Similarly, a

case report of three HIV-positive men with positive *B. henselae* serologies revealed that all presented with yellowish subretinal lesions that displayed abnormal vascular networks on FA.<sup>20</sup> The diverse manifestations of *B. henselae* necessitate maintaining a high index of suspicion for it in the work-up of these patients.

Indirect fluorescence assay (IFA) and enzyme immunoassay (EIA)<sup>21</sup> are used to assess for serologic diagnosis of *B. henselae*. IFA is the commercially available serologic test, and at an IgG titer cutoff of 1:64, one study found the test to be 88-percent sensitive and 94-percent specific.<sup>7</sup> In our patient, the titer was  $\geq 1:1024$ , which has almost 100-percent specificity for diagnosing *B. henselae*. Sensitivities and specificities are lower in HIV-positive patients,<sup>22</sup> and cross-reactivity can occur with *B. quintana*,<sup>2</sup> as well as with *Chlamydia* and *Coxiella burnetii*. Polymerase chain reaction-based testing on tissue or blood is also available and is very specific but sensitivity is suboptimal.<sup>4</sup> Finally, *B. henselae* can be cultured but tends to be very slow growing, given its fastidious nature.

Because the clinical history in our patient was so strongly suggestive of CSD, no further work-up was needed, but an MRI might be obtained in the evaluation of similar clinical presentations. CSD optic neuropathy has demonstrated enhancement of a 3- to 4-mm segment at the optic nerve-globe junction, whereas other etiologies for optic neuropathy often involve a longer segment of optic nerve that’s more posterior to the globe.<sup>23</sup> While nearly half of CSD patients have normal MRI findings, the described pattern of optic nerve enhancement may suggest *B. henselae* as the underlying etiology.

CSD is a self-limited illness, so it is difficult to draw conclusions regarding the efficacy of treatment based on published case reports given the possibility for spontaneous visual recovery. In general, antibiotics are initiated for

immunocompetent patients with atypical disease and those who are immunocompromised, with immunocompromised patients receiving a longer course of treatment.<sup>2,24</sup> Doxycycline, with or without rifampin, and erythromycin have been commonly used; ciprofloxacin and trimethoprim-sulfamethoxazole are other frequently administered antibiotics.<sup>8</sup> Based on current available data, no conclusions can be drawn about the utility of steroids.

In conclusion, cat-scratch disease secondary to *Bartonella henselae* should remain a strong consideration in a patient presenting with neuroretinitis, especially with the proper clinical context, although numerous infectious and inflammatory etiologies must be considered in the differential diagnosis. Likewise, *B. henselae* can produce diverse ophthalmic manifestations beyond neuroretinitis, requiring a high index of suspicion to make the proper diagnosis. **REVIEW**

- Giladi M, Ephros M. Harrison's Principles of Internal Medicine. 19th ed. New York: McGraw-Hill, 2014. Chapter 197, Bartonella Infections, Including Cat-Scratch Disease. <http://accessmedicine.mhmedical.com>.
- Roe RH, Jumper JM, Fu AD, et al. Ocular bartonella infections. *Int Ophthalmol Clin* 2008;48:93-105.
- Nelson CA, Saha S, Mead PS. Cat-scratch disease in the United States, 2005-2013. *Emerg Infect Dis* 2016;22:1741-46.
- Florin TA, Zaoutis TE, Zaoutis LB. Beyond cat-scratch disease: Widening spectrum of Bartonella henselae infection. *Pediatrics* 2008;121:e1413-25.
- Carithers HA. Cat-scratch Disease. An overview based on a study of 1,200 patients. *Am J Dis Child* 1985;139:1124-1133.
- Suhler EB, Lauer AK, Rosenbaum JT. Prevalence of serologic evidence of cat scratch disease in patients with neuroretinitis. *Ophthalmology* 2000;107:871-876.
- Regnery RL, Olson JG, Perkins BA, et al. Serological response to "Rochalimaea henselae" antigen in suspected cat-scratch disease. *Lancet* 1992;339:1443-5.
- Purvin V, Sundaram S, Kawasaki A. Neuroretinitis: Review of the literature and new observations. *J Neuro-Ophthalmol* 2011;31:58-68.
- Gass JDM. Diseases of the optic nerve that may simulate macular disease. *Trans Am Acad Ophthalmol Otolaryngol* 1977;83:766-769.
- Ghauri RR, Lee AG. Optic disk edema with a macular star. *Surv Ophthalmol* 1998;43:270-274.
- Wade NK, Levi L, Jones MR, et al. Optic disk edema associated with peripapillary serous retinal detachment: An early sign of systemic Bartonella henselae infection. *Am J Ophthalmol* 2000;130:327-334.
- Chi SL, Stinnett S, Eggenberger E, et al. Clinical characteristics in 53 patients with cat scratch optic neuropathy. *Ophthalmology* 2012;119:183-187.
- Curi ALL, Machado D, Heringer G, et al. Cat-scratch disease: Ocular manifestations and visual outcome. *Int Ophthalmol* 2010;30:553-58.
- Pichi F, Srivastava SK, Levinson A, et al. A focal chorioretinal Bartonella lesion analyzed by optical coherence tomography angiography. *Ophthalmic Surg Lasers Imaging* 2016;47:585-88.
- Soheilian A, Markomichelakis N, Foster CS. Intermediate uveitis and retinal vasculitis as manifestations of cat scratch disease. *Am J Ophthalmol* 1996;122:582-584.
- Eiger-Moscovich M, Amer Ragonde, Oray Merih, et al. Retinal artery occlusion due to Bartonella henselae infection: A case series. *Acta Ophthalmol* 2016;94:e367-370.
- Ormerod LD, Dailey JP. Ocular manifestations of cat-scratch disease. *Curr Opin Ophthalmol* 1999;10:209-216.
- Albini TA, Lakhanpal RR, Foroozan R, et al. Macular hole in cat scratch disease. *Am J Ophthalmol* 2005;140:149-151.
- Latanza L, Viscogliosi F, Solimeo A, et al. Choroidal neovascularisation as an unusual ophthalmic manifestation of cat-scratch disease in an 8-year-old girl. *Int Ophthalmol* 2015;35:709-716.
- Curi ALL, Machado DO, Heringer G, et al. Ocular manifestations of cat-scratch disease in HIV-positive patients. *Am J Ophthalmol* 2006;141:400-401.
- Szelc-Kelly CM, Goral S, Perez-Perez GI, et al. Serologic responses to Bartonella and Afipia antigens in patients with cat scratch disease. *Pediatrics* 1995;96:1137-42.
- Dalton MJ, Robinson LE, Cooper J, et al. Use of Bartonella antigens for serologic diagnosis of cat-scratch disease at a national referral center. *Arch Intern Med* 1995;155:1670-76.
- Schmalfuss IM, Dean CW, Siström C, et al. Optic neuropathy secondary to cat scratch disease: Distinguishing MR imaging features from other types of optic neuropathies. *Am J Neuroradiol* 2005;26:1310-1316.
- Biancardi AL, Curi ALL. Cat-scratch disease. *Ocular Immunology and Inflammation* 2014;148-154.

For advertising opportunities contact:

Michele Barrett (610) 492-1014 or [mbarrett@jobson.com](mailto:mbarrett@jobson.com)

James Henne (610) 492-1017 or [jhenne@jobson.com](mailto:jhenne@jobson.com)

Michael Hoster (610) 492-1028 or [mhoster@jobson.com](mailto:mhoster@jobson.com)

#### Alimera Sciences, Inc. 2-3, 4

Phone (844) 445-8843  
www.alimerasciences.com

#### Bausch + Lomb 15-16

Phone (800) 323-0000  
Fax (813) 975-7762

#### Carl Zeiss Meditec Inc. 19

Phone (877) 486-7473  
Fax (925) 557-4101

#### Eye Designs 23

Phone (800) 346-8890  
Fax (610) 489-1414

#### Lombart Instruments 33

Phone (800) 446-8092  
Fax (757) 855-1232

#### Optovue 9

Phone (510) 623-8868 or (866) 344-8948  
Fax (510) 623-8668

#### Regeneron Pharmaceuticals, Inc. 11, 12

Phone (914) 847-7000  
www.regeneron.com

#### Reichert Technologies 27, 29

Phone (888) 849-8955  
Fax (716) 686-4545  
www.reichert.com

#### Rhein Medical 7

Phone (800) 637-4346  
Fax (727) 341-8123

#### S40PTIK 37, 39

Phone (888) 224-6012

#### Shire Ophthalmics 67, 68

www.shire.com

This advertiser index is published as a convenience and not as part of the advertising contract. Every care will be taken to index correctly. No allowance will be made for errors due to spelling, incorrect page number, or failure to insert.



 **eyelove**<sup>®</sup>  
innovation

Eyelove is a celebration of the things we love to do with our eyes. It's also a commitment from Shire to help educate your patients about Dry Eye Disease.

Start with some eyelove. **Join us at [sharesomeeyelove.com](http://sharesomeeyelove.com)**

it's time for some eyelove



**Shire**



 eyelove<sup>®</sup>  
happy patients

What's eyelove? Eyelove is all about taking care of eyes—especially now. Eyes need more love than ever, because they've never been asked to do so much. That's why Shire has entered the world of eye care. We're committed to educating patients about Dry Eye Disease—so let's start with some eyelove.

[sharesomeeyelove.com](http://sharesomeeyelove.com)

it's time for some eyelove



