

A NEW UNDERSTANDING OF VITREOUS STRUCTURE P. 60 • NEUROPATHIC PAIN AND DRY EYE P. 52  
GLAUCOMA: SHOULD YOU ADD A NEW SURGERY? P. 48 • BREAKING NEW GROUND WITH OCT P. 18  
WILLS EYE RESIDENT CASE SERIES P. 70 • REFRACTIVE SURGERY TRENDS OF THE ISRS P. 56

# REVIEW<sup>®</sup> of Ophthalmology

January 2016

reviewofophthalmology.com



# IOL ISSUE

A Look at a Potential 'Super Formula' for Lens Power P. 42

Choosing the Best IOL for a Nonstandard Eye P. 24

Internet IOL Survey: Presbyopia Lens Adoption Down P. 38

Give Multifocal IOLS a Second Look P. 32

# Post-op relief is affordable for your patients<sup>1-3</sup>

DON'T LET POSTOPERATIVE INFLAMMATION AND PAIN LEAVE A BAD IMPRESSION

**3x** more cataract patients achieved zero inflammation on postoperative Days 8 and 15 vs placebo  
• 22%\* vs 7% on Day 8; 41%\* vs 11% on Day 15<sup>1</sup>

**2x** Nearly as many cataract patients achieved zero pain on postoperative Days 8 and 15 vs placebo  
• 58%\* vs 27% on Day 8; 63%\* vs 35% on Day 15<sup>1</sup>

WHEN TREATING ENDOGENOUS ANTERIOR UVEITIS, DUREZOL® EMULSION WAS NONINFERIOR TO PRED FORTE® (DUREZOL® EMULSION 4X DAILY VS PRED FORTE® 8X DAILY)<sup>1</sup>

- **BETTER** or comparable formulary coverage vs generic prednisolone acetate on some Medicare Part D plans<sup>4,7</sup>
- **NO** therapeutic equivalent to DUREZOL® Emulsion

\*Pooled data from placebo-controlled trials in patients undergoing cataract surgery;  $P < 0.01$  vs placebo.  
†Trademark is the property of its owner.

**CORTICOSTEROID COVERAGE IS NOT THE SAME**

LEARN MORE ABOUT DUREZOL® EMULSION FORMULARY ACCESS IN YOUR AREA AT [MYALCON.COM/FORMULARY](http://MYALCON.COM/FORMULARY)

## INDICATIONS AND USAGE:

DUREZOL® Emulsion is a topical corticosteroid that is indicated for:

- The treatment of inflammation and pain associated with ocular surgery.
- The treatment of endogenous anterior uveitis.

## Dosage and Administration

- For the treatment of inflammation and pain associated with ocular surgery instill one drop into the conjunctival sac of the affected eye 4 times daily beginning 24 hours after surgery and continuing throughout the first 2 weeks of the postoperative period, followed by 2 times daily for a week and then a taper based on the response.
- For the treatment of endogenous anterior uveitis, instill one drop into the conjunctival sac of the affected eye 4 times daily for 14 days followed by tapering as clinically indicated.

## IMPORTANT SAFETY INFORMATION

**Contraindications:** DUREZOL® Emulsion, as with other ophthalmic corticosteroids, is contraindicated in most active viral diseases of the cornea and conjunctiva including epithelial herpes simplex keratitis (dendritic keratitis), vaccinia, and varicella, and also in mycobacterial infection of the eye and fungal diseases of ocular structures.

## Warnings and Precautions

- Intraocular pressure (IOP) increase—Prolonged use of corticosteroids may result in glaucoma with damage to the optic nerve, defects in visual acuity and fields of vision. If this product is used for 10 days or longer, IOP should be monitored.
- Cataracts—Use of corticosteroids may result in posterior subcapsular cataract formation.
- Delayed healing—The use of steroids after cataract surgery may delay healing and increase the incidence of bleb formation. In those diseases causing thinning of the cornea or sclera, perforations have been known to occur with the use of topical steroids. The initial prescription and renewal of the medication order beyond 28 days should be made by a physician only after examination of the patient with the aid of magnification such as slit lamp biomicroscopy and, where appropriate, fluorescein staining.
- Bacterial infections—Prolonged use of corticosteroids may suppress the host response and thus increase the hazard of secondary ocular infections. In acute purulent conditions, steroids may mask infection or enhance existing infection. If signs and symptoms fail to improve after 2 days, the patient should be re-evaluated.



- Viral infections—Employment of a corticosteroid medication in the treatment of patients with a history of herpes simplex requires great caution. Use of ocular steroids may prolong the course and may exacerbate the severity of many viral infections of the eye (including herpes simplex).
- Fungal infections—Fungal infections of the cornea are particularly prone to develop coincidentally with long-term local steroid application. Fungus invasion must be considered in any persistent corneal ulceration where a steroid has been used or is in use.
- Contact lens wear—DUREZOL® Emulsion should not be instilled while wearing contact lenses. Remove contact lenses prior to instillation of DUREZOL® Emulsion. The preservative in DUREZOL® Emulsion may be absorbed by soft contact lenses. Lenses may be reinserted after 10 minutes following administration of DUREZOL® Emulsion.

## Most Common Adverse Reactions

- Post Operative Ocular Inflammation and Pain—Ocular adverse reactions occurring in 5-15% of subjects included corneal edema, ciliary and conjunctival hyperemia, eye pain, photophobia, posterior capsule opacification, anterior chamber cells, anterior chamber flare, conjunctival edema, and blepharitis.
- In the endogenous anterior uveitis studies, the most common adverse reactions occurring in 5-10% of subjects included blurred vision, eye irritation, eye pain, headache, increased IOP, iritis, limbal and conjunctival hyperemia, punctate keratitis, and uveitis.

For additional information about DUREZOL® Emulsion, please refer to the brief summary of Prescribing Information on adjacent page.

For more resources for eye care professionals, visit [MYALCON.COM/DUREZOL](http://MYALCON.COM/DUREZOL).

**References:** 1. DUREZOL (difluprednate ophthalmic emulsion) [package insert]. Fort Worth, TX: Alcon Laboratories, Inc; Revised May 2013. 2. Korenfeld MS, Silverstein SM, Cooke DL, Vogel R, Crockett RS; Difluprednate Ophthalmic Emulsion 0.05% (Durezol) Study Group. Difluprednate ophthalmic emulsion 0.05% for postoperative inflammation and pain. *J Cataract Refract Surg.* 2009;35(1):26-34. 3. Fingertip Formulary, November 2014 (estimate derived from information used under license from Fingertip Formulary, LLC, which expressly reserves all rights, including rights of copying, distribution and republication). 4. WellCare. Medication Guide: 2014 WellCare Classic. WellCare website. [https://www.wellcarepdp.com/medication\\_guide/default](https://www.wellcarepdp.com/medication_guide/default). Accessed November 14, 2014. 5. WellCare. Medication Guide: 2015 WellCare Classic and Simple. WellCare website. [https://www.wellcarepdp.com/medication\\_guide/default](https://www.wellcarepdp.com/medication_guide/default). Accessed November 14, 2014. 6. Humana. Drug guides for Medicare plans 2014. Humana website. <https://www.humana.com/medicare/products-and-services/pharmacy/rx-tools/medicare-drug-list/2014-print>. Updated October 30, 2014. Accessed November 14, 2014. 7. Humana. Drug guides for Medicare plans 2015. <https://www.humana.com/medicare/products-and-services/pharmacy/rx-tools/medicare-drug-list/2015-print>. Updated September 5, 2014. Accessed November 14, 2014.



## BRIEF SUMMARY OF PRESCRIBING INFORMATION

### INDICATIONS AND USAGE

#### Ocular Surgery

DUREZOL<sup>®</sup> (difluprednate ophthalmic emulsion) 0.05%, a topical corticosteroid, is indicated for the treatment of inflammation and pain associated with ocular surgery.

#### Endogenous Anterior Uveitis

DUREZOL<sup>®</sup> Emulsion is also indicated for the treatment of endogenous anterior uveitis.

### DOSAGE AND ADMINISTRATION

#### Ocular Surgery

Instill one drop into the conjunctival sac of the affected eye 4 times daily beginning 24 hours after surgery and continuing throughout the first 2 weeks of the postoperative period, followed by 2 times daily for a week and then a taper based on the response.

#### Endogenous Anterior Uveitis

Instill one drop into the conjunctival sac of the affected eye 4 times daily for 14 days followed by tapering as clinically indicated.

### DOSAGE FORMS AND STRENGTHS

DUREZOL<sup>®</sup> Emulsion contains 0.05% difluprednate as a sterile preserved emulsion for topical ophthalmic administration.

### CONTRAINDICATIONS

The use of DUREZOL<sup>®</sup> Emulsion, as with other ophthalmic corticosteroids, is contraindicated in most active viral diseases of the cornea and conjunctiva including epithelial herpes simplex keratitis (dendritic keratitis), vaccinia, and varicella, and also in mycobacterial infection of the eye and fungal disease of ocular structures.

### WARNINGS AND PRECAUTIONS

#### IOP Increase

Prolonged use of corticosteroids may result in glaucoma with damage to the optic nerve, defects in visual acuity and fields of vision. Steroids should be used with caution in the presence of glaucoma. If this product is used for 10 days or longer, intraocular pressure should be monitored.

#### Cataracts

Use of corticosteroids may result in posterior subcapsular cataract formation.

#### Delayed Healing

The use of steroids after cataract surgery may delay healing and increase the incidence of bleb formation. In those diseases causing thinning of the cornea or sclera, perforations have been known to occur with the use of topical steroids. The initial prescription and renewal of the medication order beyond 28 days should be made by a physician only after examination of the patient with the aid of magnification such as slit lamp biomicroscopy and, where appropriate, fluorescein staining.

#### Bacterial Infections

Prolonged use of corticosteroids may suppress the host response and thus increase the hazard of secondary ocular infections. In acute purulent conditions, steroids may mask infection or enhance existing infection. If signs and symptoms fail to improve after 2 days, the patient should be re-evaluated.

#### Viral Infections

Employment of a corticosteroid medication in the treatment of patients with a history of herpes simplex requires great caution. Use of ocular steroids may prolong the course and may exacerbate the severity of many viral infections of the eye (including herpes simplex).

#### Fungal Infections

Fungal infections of the cornea are particularly prone to develop coincidentally with long-term local steroid application. Fungus invasion must be considered in

any persistent corneal ulceration where a steroid has been used or is in use. Fungal culture should be taken when appropriate.

### Topical Ophthalmic Use Only

DUREZOL<sup>®</sup> Emulsion is not indicated for intraocular administration.

### Contact Lens Wear

DUREZOL<sup>®</sup> Emulsion should not be instilled while wearing contact lenses. Remove contact lenses prior to instillation of DUREZOL<sup>®</sup> Emulsion. The preservative in DUREZOL<sup>®</sup> Emulsion may be absorbed by soft contact lenses. Lenses may be reinserted after 10 minutes following administration of DUREZOL<sup>®</sup> Emulsion.

### ADVERSE REACTIONS

Adverse reactions associated with ophthalmic steroids include elevated intraocular pressure, which may be associated with optic nerve damage, visual acuity and field defects; posterior subcapsular cataract formation; secondary ocular infection from pathogens including herpes simplex, and perforation of the globe where there is thinning of the cornea or sclera.

### Ocular Surgery

Ocular adverse reactions occurring in 5-15% of subjects in clinical studies with DUREZOL<sup>®</sup> Emulsion included corneal edema, ciliary and conjunctival hyperemia, eye pain, photophobia, posterior capsule opacification, anterior chamber cells, anterior chamber flare, conjunctival edema, and blepharitis. Other ocular adverse reactions occurring in 1-5% of subjects included reduced visual acuity, punctate keratitis, eye inflammation, and iritis. Ocular adverse reactions occurring in < 1% of subjects included application site discomfort or irritation, corneal pigmentation and striae, episcleritis, eye pruritus, eyelid irritation and crusting, foreign body sensation, increased lacrimation, macular edema, sclera hyperemia, and uveitis. Most of these reactions may have been the consequence of the surgical procedure.

### Endogenous Anterior Uveitis

A total of 200 subjects participated in the clinical trials for endogenous anterior uveitis, of which 106 were exposed to DUREZOL<sup>®</sup> Emulsion. The most common adverse reactions of those exposed to DUREZOL<sup>®</sup> Emulsion occurring in 5-10% of subjects included blurred vision, eye irritation, eye pain, headache, increased IOP, iritis, limbal and conjunctival hyperemia, punctate keratitis, and uveitis. Adverse reactions occurring in 2-5% of subjects included anterior chamber flare, corneal edema, dry eye, iridocyclitis, photophobia, and reduced visual acuity.

### USE IN SPECIFIC POPULATIONS

#### Pregnancy

##### Teratogenic Effects

Pregnancy Category C. Difluprednate has been shown to be embryotoxic (decrease in embryonic body weight and a delay in embryonic ossification) and teratogenic (cleft palate and skeletal) anomalies when administered subcutaneously to rabbits during organogenesis at a dose of 1-10 mcg/kg/day. The no-observed-effect-level (NOEL) for these effects was 1 mcg/kg/day, and 10 mcg/kg/day was considered to be a teratogenic dose that was concurrently found in the toxic dose range for fetuses and pregnant females. Treatment of rats with 10 mcg/kg/day subcutaneously during organogenesis did not result in any reproductive toxicity, nor was it maternally toxic. At 100 mcg/kg/day after subcutaneous administration in rats, there was a decrease in fetal weights and delay in ossification, and effects on weight gain in the pregnant females. It is difficult to extrapolate these doses of difluprednate to maximum daily human doses of DUREZOL<sup>®</sup> Emulsion, since DUREZOL<sup>®</sup> Emulsion is administered topically with minimal systemic absorption, and difluprednate blood levels were not measured in the reproductive animal studies. However, since use of difluprednate during human pregnancy has not been evaluated and cannot rule out the possibility of harm, DUREZOL<sup>®</sup> Emulsion should be used during pregnancy only if the potential benefit justifies the potential risk to the embryo or fetus.

### Nursing Mothers

It is not known whether topical ophthalmic administration of corticosteroids could result in sufficient systemic absorption to produce detectable quantities in breast milk. Systemically administered corticosteroids appear in human milk and could suppress growth, interfere with endogenous corticosteroid production, or cause other untoward effects. Caution should be exercised when DUREZOL<sup>®</sup> Emulsion is administered to a nursing woman.

### Pediatric Use

DUREZOL<sup>®</sup> Emulsion was evaluated in a 3-month, multicenter, double-masked, trial in 79 pediatric patients (39 DUREZOL<sup>®</sup> Emulsion; 40 prednisolone acetate) 0 to 3 years of age for the treatment of inflammation following cataract surgery. A similar safety profile was observed in pediatric patients comparing DUREZOL<sup>®</sup> Emulsion to prednisolone acetate ophthalmic suspension, 1%.

### Geriatric Use

No overall differences in safety or effectiveness have been observed between elderly and younger patients.

### NONCLINICAL TOXICOLOGY

#### Carcinogenesis, Mutagenesis, and Impairment of Fertility

Difluprednate was not genotoxic *in vitro* in the Ames test, and in cultured mammalian cells CHL/IU (a fibroblastic cell line derived from the lungs of newborn female Chinese hamsters). An *in vivo* micronucleus test of difluprednate in mice was also negative. Treatment of male and female rats with subcutaneous difluprednate up to 10 mcg/kg/day prior to and during mating did not impair fertility in either gender. Long term studies have not been conducted to evaluate the carcinogenic potential of difluprednate.

#### Animal Toxicology and/or Pharmacology

In multiple studies performed in rodents and non-rodents, subchronic and chronic toxicity tests of difluprednate showed systemic effects such as suppression of body weight gain; a decrease in lymphocyte count; atrophy of the lymphatic glands and adrenal gland; and for local effects, thinning of the skin; all of which were due to the pharmacologic action of the molecule and are well known glucocorticosteroid effects. Most, if not all of these effects were reversible after drug withdrawal. The NOEL for the subchronic and chronic toxicity tests were consistent between species and ranged from 1-1.25 mcg/kg/day.

### PATIENT COUNSELING INFORMATION

#### Risk of Contamination

This product is sterile when packaged. Patients should be advised not to allow the dropper tip to touch any surface, as this may contaminate the emulsion. Use of the same bottle for both eyes is not recommended with topical eye drops that are used in association with surgery.

#### Risk of Secondary Infection

If pain develops, or if redness, itching, or inflammation becomes aggravated, the patient should be advised to consult a physician.

#### Contact Lens Wear

DUREZOL<sup>®</sup> Emulsion should not be instilled while wearing contact lenses. Patients should be advised to remove contact lenses prior to instillation of DUREZOL<sup>®</sup> Emulsion. The preservative in DUREZOL<sup>®</sup> Emulsion may be absorbed by soft contact lenses. Lenses may be reinserted after 10 minutes following administration of DUREZOL<sup>®</sup> Emulsion.

#### Revised: May 2013

U.S. Patent 6,114,319

Manufactured For:

**Alcon**  
a Novartis company

Alcon Laboratories, Inc.  
6201 South Freeway  
Fort Worth, Texas 76134 USA  
1-800-757-9195  
Manufactured By:  
Alcon Laboratories, Inc.  
6201 South Freeway  
Fort Worth, Texas 76134 USA  
or  
Catalent Pharma Solutions  
Woodstock, IL 60098

# New Heart Drug May Worsen Alzheimer's, AMD Risk

Patients with mild heart failure stand to benefit from a new drug that can halt the progression of their disease and reduce their risk of cardiovascular-related death. But the drug—a tablet that combines the agents valsartan and sacubitril, sold under the trade name Entresto by drugmaker Novartis—may be too good to be true, according to Arthur M. Feldman, MD, PhD, executive dean of the Lewis Katz School of Medicine at Temple University.

In an article published online December 7th in the *Journal of the American Medical Association*, Dr. Feldman and colleagues at Thomas Jefferson University and the University of Florida warn that valsartan/sacubitril could theoretically increase patients' risk of Alzheimer's disease and macular degeneration. The article raises these concerns about the drug, which was approved by the Food and Drug Administration in July 2015.

"Basic science data has caused us to speculate that off-target effects of valsartan/sacubitril may cause an exacerbation of Alzheimer's disease and could also exacerbate the course of macular degeneration," Dr. Feldman said. He went on to note that "doctors are prescribing these drugs without knowledge of these theoretical risks."

Valsartan/sacubitril works by inhibiting an enzyme known as neprilysin, which normally plays a critical role in breaking down a wide array of peptides in cells. Among those substances are the so-called natriuretic peptides, which function in regulating scarring and cell growth in the heart when ne-

prilysin is blocked. Because of those activities, valsartan/sacubitril can delay the progression of heart failure in some patients.

Nepriylsin, however, also normally degrades amyloid beta, a peptide that can accumulate in the brain, where it contributes to Alzheimer's disease, and in the eye, where it is implicated in macular degeneration. The balance between the production and clearance of amyloid beta is crucial to the pathogenesis of Alzheimer's disease and is suspected to influence the development of macular degeneration. In animal models, blocking neprilysin disturbs that balance and exacerbates development of Alzheimer's pathology.

Valsartan/sacubitril was approved for heart failure via the FDA's fast-track program, in which drugs that promise to fulfill unmet medical needs undergo an accelerated review process. In the studies that led to the drug's approval, no adverse events related to dementia were reported. However, according to Dr. Feldman and his colleagues, patients were followed for too short a period of time to confidently rule out potential adverse effects on cognitive function or vision, and specific tests were not performed to assess whether early changes in either Alzheimer-specific cognitive function or macular degeneration had occurred.

Moreover, preclinical studies and trials of the drug involved young monkeys and normal human volunteers. In both groups, the blood-brain barrier functions as it should. In heart failure patients, however, the blood-brain

barrier frequently is compromised by hypertension and other vascular conditions, allowing drugs to enter the central nervous system.

The FDA has required Novartis to conduct a thorough assessment of the cognitive risks associated with valsartan/sacubitril in a clinical trial in patients with heart failure and preserved ejection fraction. The data from that study will not be available until 2022.

"My hope is that physicians will be prudent with the use of this new drug," Dr. Feldman said. "The risks are theoretical, but every precaution should be taken to avoid them. The outcomes could be devastating for patients."

## Keeping Hungry Lens Cells in Check

**Researchers from Florida Atlantic University** have discovered that epithelial cells in close proximity to each other can sense when a cell is dying due to environmental stressors like UV light, smoke and other pollutants, and eat the cell before it becomes toxic.

In a study published in the *Journal of Biochemistry and Molecular Biology*, the researchers not only demonstrate that this happens with lens cells, but they uncover the molecules that are required to do it. They also reveal that the molecules needed for the cells to eat each other are degraded by UV light. When that happens, the cells lose the ability to eat each other. Since these systems are not confined to the lens and diseases of the eye such as



## Meibum Expressors

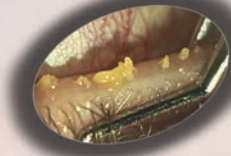
cataracts, uncovering the mechanisms and functions will provide important information in more complex tissues and disease states.

It has long been known that environmental damage is associated with cell death and that it kills tissue because it is toxic. Yet, the lens, which does not have a blood supply, gets hit by UV light and other stressors that continuously kill cells. Consistently, the lens has evolved multiple protective and repair systems to preserve its transparent function in the face of environmental insults. That's what the researchers sought to understand in this novel study.

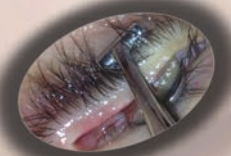They were able to establish that the intact lens is indeed capable of removing apoptotic lens cell debris and worked to identify a molecular mechanism for this process by lens cells. By using the lens as a model, they searched to understand how other cells and tissues might operate in a different way than by using blood cells.

"Accumulation of apoptotic material is toxic to epithelial cell populations, which include the cornea, skin, lungs and other tissue, and is associated with the development of multiple autoimmune, inflammatory, aging and degenerative diseases," said Marc Kantorow, PhD, author of the paper and a professor and director of graduate studies in FAU's College of Medicine. "Identifying the cell systems that protect against the effects of apoptosis-inducing insults is an important step toward understanding and developing therapies to treat these diseases."

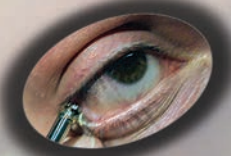Using embryonic chicken lenses, Dr. Kantorow and his collaborators engineered the lens cells to be either fluorescent red or fluorescent green—instead of what would normally be a clear lens cell. They created artificial dead green cells and fed them to the red cells. When the red cells ate the green cells, they turned yellow. They observed this mechanism in real-time using microscopy to track the digesting cells and utilized antibodies to specific



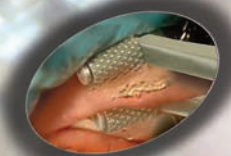08-01720 Tearse<sup>5</sup> Meibum Compression Forceps



08-01718 Battle<sup>1</sup> Eyelid Compression Forceps



08-01719 Khouri<sup>2</sup> Eyelid Squeegee



08-01716 Maskin<sup>3</sup> Meibum Expressor



08-01717 Hardten<sup>4</sup> Eyelid Compression Forceps



3360 Scherer Drive, Suite B, St. Petersburg FL 33716  
800-637-4346 • Tel: 727-209-2244 • Fax: 727-341-8123  
Email: [Info@RheinMedical.com](mailto:Info@RheinMedical.com) • Website: [www.RheinMedical.com](http://www.RheinMedical.com)

<sup>1</sup>Developed In Coordination With Juan F. Battle, M.D.  
<sup>2</sup>Developed In Coordination With Elle G. Khouri, M.D.  
<sup>3</sup>Developed In Coordination With Steven L. Maskin, M.D., Patent Pending.  
<sup>4</sup>Developed In Coordination With David R. Hardten, M.D.  
<sup>5</sup>Developed In Coordination With James Tearse, M.D.

**Editor in Chief**

**Christopher Glenn**  
(610) 492-1008  
cglenn@jobson.com

**Managing Editor**

**Walter C. Bethke**  
(610) 492-1024  
wbethke@jobson.com

**Senior Editor**

**Christopher Kent**  
(814) 861-5559  
ckent@jobson.com

**Associate Editor**

**Kelly Hills**  
(610) 492-1025  
khills@jobson.com

**Chief Medical Editor**

**Mark H. Blecher, MD**

**Art Director**

**Jared Araujo**  
(610) 492-1023  
jaraujo@jobson.com

**Senior Graphic Designer**

**Matt Egger**  
(610) 492-1029  
megger@jobson.com

**International coordinator, Japan**

**Mitz Kaminuma**  
Reviewophthalgo@aol.com

**Business Offices**

11 Campus Boulevard, Suite 100  
Newtown Square, PA 19073  
(610) 492-1000  
Fax: (610) 492-1039

**Subscription inquiries:**

United States — (877) 529-1746  
Outside U.S. — (845) 267-3065

**E-mail:**

rhsubs@halldata.com

**Website:** www.reviewofophthalmology.com



molecules to determine which molecules were needed for the cells to eat each other.

“It is widely known that cells have very specific functions and that environmental damage is associated with cell death,” said Lisa Brennan, PhD, associate research professor and a collaborator on the study. “Before this study, the common knowledge was that what removed these dead cells were specialized immune cells that literally go into the tissue and eat these dead cells and that’s how your body got rid of them. We looked at the eye lens as a model to try to search for alternate ways to get rid of these dead cells to keep a tissue alive.”

“Twenty percent of all cataracts are associated with UV light exposure and at some point in their lifetime, most people will get cataracts,” said Dr. Kantorow. “Our work has the potential to lead to the development of treatments and therapies that would eliminate the need for surgery, which is the only way to treat cataracts today.”

## Dry Eye Tied to Chronic Pain

**Researchers with Bascom Palmer Eye Institute** have found a link between dry eye and chronic pain syndromes—a finding that suggests that a new paradigm is needed for diagnosis and treatment to improve patient outcomes.

“Our study indicates that some patients with dry eye have corneal somatosensory pathway dysfunction and would be better described as having neuropathic ocular pain,” said Anat Galor, MD, MSPH, a cornea and uveitis specialist and associate professor of clinical ophthalmology at BPEI at the University of Miami Miller School of Medicine, and lead author of the study, “Neuropathic

Ocular Pain due to Dry Eye is Associated with Multiple Comorbid Chronic Pain Syndromes,” published recently in the American Pain Society’s *Journal of Pain*.

Roy C. Levitt, MD, a neuroanesthesiologist, pain specialist and geneticist also at the Miller School, and corresponding author, noted, “A multidisciplinary approach used for chronic pain treatment may also benefit these dry-eye patients.”

Their team evaluated 154 dry-eye patients from the Miami VA Hospital. “Dry-eye patients in our study reported higher levels of ocular and non-ocular pain associated with multiple chronic pain syndromes, and had lower scores on depression and quality-of-life indices consistent with a central sensitivity disorder,” said Dr. Levitt, a professor and vice chair of translational research and academic affairs. “We also suspect that neuropathic ocular pain may share causal genetic factors with other overlapping chronic pain conditions.

“Patients’ eyes may become hypersensitive to stimuli, such as wind or light, or have spontaneous pain such as a feeling of burning, which is typically associated with nerve injury,” said Dr. Levitt.

“Traditionally, eye specialists have treated dry eye with artificial tears or topical medications for the surface of the cornea,” said Dr. Galor. “However, even if these treatments improve some dry-eye symptoms, many patients continue to report underlying ocular and non-ocular pain.”

Of the implications of the study, Dr. Galor said, “Our highest priority is educating physicians that dry eye represents an overlapping chronic pain condition. Consequently, a multidisciplinary approach should be considered in the diagnosis and pain management of dry-eye patients.”

For further discussion of dry-eye-related pain, see Therapeutic Topics, p. 52. **REVIEW**



### D-KAT Digital

The first FDA 510(k) digital applanation tonometer



### 40H Slit Lamp

The next generation slit lamp featuring advanced Keeler optics



### Vantage Plus Wireless

The world's best selling binocular indirect ophthalmoscope

# MULTIPLY YOUR SAVINGS

## BUY MORE SAVE MORE

Keeler's 40H Slit Lamp is quickly gaining the reputation as a world class device.

Featuring Keeler's famous optics, 6 to 40x magnification, LED Illumination in a beautifully crafted, thoughtful design, giving you the functionality and performance you want, need and expect from a Keeler Slit Lamp.

### BUY 1 / GET 1

Purchase a Keeler 40 H Slit Lamp and you'll receive a FREE Keeler D-KAT Digital

### BUY 2 / GET 2

Purchase 2 Keeler 40H Lamps and you'll receive 2 FREE Keeler D-KAT Digitals

### BUY 3 / GET 3 + 1

Purchase 3 Keeler 40H Slit Lamps and you'll receive 3 FREE Keeler D-KAT Digitals + a FREE Keeler Vantage Plus BIO

Outfit your offices with Keeler 40H Slit Lamps before March 31, 2016 and take advantage of these great offers!

Offer expires March 31, 2016. No other Keeler offer can be combined.



# Keeler

OPTICS

Keeler Instruments, Inc. • 456 Parkway • Broomall, PA 19008  
Tel: (800) 523-5620 • Fax: (610) 353-7814 • email: keeler@keelerusa.com

# CONTRIBUTORS

**CHIEF MEDICAL EDITOR**

Mark H. Blecher, MD

**BOTTOM LINE**

Dennis D. Sheppard, MD

**CONTACT LENSES**

Penny Asbell, MD

**CORNEA / ANTERIOR SEGMENT**

Thomas John, MD

**GLAUCOMA MANAGEMENT**

Peter Netland, MD, PHD  
Kuldev Singh, MD

**MASTERS OF SURGERY**

Taliva D. Martin, MD  
Sara J. Haug, MD, PhD

**PEDIATRIC PATIENT**

Christopher M. Fecarotta, MD

**PLASTIC POINTERS**

Ann P. Murchison, MD, MPH

**WILLS RESIDENT CASE SERIES**

Alia Duranni, MD

**REFRACTIVE SURGERY**

Arturo S. Chayet, MD

**RETINAL INSIDER**

Carl Regillo, MD, FACS  
Emmett T. Cunningham Jr., MD, PHD, MPH

**TECHNOLOGY UPDATE**

Steven T. Charles, MD  
Michael Colvard, MD

**THERAPEUTIC TOPICS**

Mark Abelson, MD

# ADVISORY BOARD

**PENNY A. ASBELL, MD**, NEW YORK CITY

**WILLIAM I. BOND, MD**, PERKIN, ILL.

**ALAN N. CARLSON, MD**, DURHAM, N.C.

**Y. RALPH CHU, MD**, EDINA, MINN.

**ADAM J. COHEN, MD**, DOWNERS GROVE, ILL.

**UDAY DEVGAN, MD, FACS**, LOS ANGELES

**ERIC DONNENFELD, MD**, ROCKVILLE CENTRE, N.Y.

**DANIEL S. DURRIE, MD**, KANSAS CITY, MO.

**ROBERT EPSTEIN, MD**, MCHENRY, ILL.

**ROBERT D. FECHTNER, MD**, NEWARK, N.J.

**WILLIAM J. FISHKIND, MD**, TUCSON, ARIZ.

**JAMES P. GILLS, MD**, TARPON SPRINGS, FLA.

**HARRY GRABOW, MD**, SARASOTA, FLA.

**DOUGLAS K. GRAYSON, MD**, NEW YORK CITY

**R. BRUCE GRENE, MD**, WICHITA, KAN.

**THOMAS S. HARBIN, MD, MBA**, ATLANTA

**DAVID R. HARDTEN, MD**, MINNEAPOLIS

**KENNETH J. HOFFER, MD**, SANTA MONICA, CALIF.

**JACK T. HOLLADAY, MD, MSEE**, HOUSTON

**JOHN D. HUNKELER, MD**, KANSAS CITY, MO.

**THOMAS JOHN, MD**, TINLEY PARK, ILL.

**ROBERT M. KERSHNER, MD, MS, FACS**, BOSTON

**GUY M. KEZIRIAN, MD**, PARADISE VALLEY, ARIZ.

**TERRY KIM, MD**, DURHAM, N.C.

**TOMMY KORN, MD**, SAN DIEGO

**DAVID A. LEE, MD**, HOUSTON

**FRANCIS S. MAH, MD**, PITTSBURGH

**NICK MAMALIS, MD**, SALT LAKE CITY

**WILLIAM G. MARTIN, MD**, OREGON, OHIO

**MIKE S. MCFARLAND, MD**, PINE BLUFF, ARK.

**JEFFREY B. MORRIS, MD, MPH**, ENCINITAS, CALIF.

**MARLENE R. MOSTER, MD**, PHILADELPHIA

**ROBERT J. NOECKER, MD**, FAIRFIELD, CONN.

**ROBERT OSHER, MD**, CINCINNATI

**MARK PACKER, MD**, WEST PALM BEACH, FLA.

**STEPHEN PASCUCCI, MD**, BONITA SPRINGS, FLA.

**PAUL PENDER, MD**, BEDFORD, N.H.

**CHRISTOPHER J. RAPUANO, MD**, PHILADELPHIA

**AUGUST READER III, MD**, SAN FRANCISCO

**TONY REALINI, MD**, MORGANTOWN, W.V.

**KENNETH J. ROSENTHAL, MD**, GREAT NECK, N.Y.

**ERIC ROTHCHILD, MD**, DELRAY BEACH, FLA.

**SHERI ROWEN, MD**, BALTIMORE

**JAMES J. SALZ, MD**, LOS ANGELES

**INGRID U. SCOTT, MD, MPH**, HERSHEY, PA.

**JOEL SCHUMAN, MD**, PITTSBURGH

**GAURAV SHAH, MD**, ST. LOUIS

**DAVID R. STAGER JR., MD**, DALLAS

**KARL STONECIPHER, MD**, GREENSBORO, N.C.

**JAMES C. TSAI, MD**, NEW YORK CITY

**VANCE THOMPSON, MD**, SIOUX FALLS, S.D.

**FARRELL C. TYSON, MD**, CAPE CORAL, FLA.

**R. BRUCE WALLACE III, MD**, ALEXANDRIA, LA.

**ROBERT G. WILEY, MD**, CLEVELAND

**FRANK WEINSTOCK, MD**, CANTON, OHIO

**JACQUELINE M.S. WINTERKORN, MD, PHD**, NEW YORK CITY



**BUSINESS OFFICES**

11 CAMPUS BOULEVARD, SUITE 100  
NEWTOWN SQUARE, PA 19073  
SUBSCRIPTION INQUIRIES (877) 529-1746  
(USA ONLY); OUTSIDE USA, CALL (847) 763-9630

**BUSINESS STAFF**

PUBLISHER

**JAMES HENNE**

(610) 492-1017 JHENNE@JOBSON.COM

REGIONAL SALES MANAGER

**MICHELE BARRETT**

(610) 492-1014 MBARRETT@JOBSON.COM

REGIONAL SALES MANAGER

**MICHAEL HOSTER**

(610) 492-1028 MHOSTER@JOBSON.COM

**CLASSIFIED ADVERTISING**

(888)-498-1460

VICE PRESIDENT OF OPERATIONS

**CASEY FOSTER**

(610) 492-1007 CFOSTER@JOBSON.COM

PRODUCTION MANAGER

**SCOTT TOBIN**

(610) 492-1011 STOBIN@JOBSON.COM

**SUBSCRIPTIONS**

\$63 A YEAR, \$99 (U.S.) IN CANADA,  
\$158 (U.S.) IN ALL OTHER COUNTRIES.

SUBSCRIPTIONS E-MAIL:

REVOPHTHALMOLOGY@CAMBEYWEST.COM

**CIRCULATION**

PO BOX 71, CONGERS, NY 10920-0071  
(877) 529-1746

OUTSIDE USA: (845) 267-3065

SENIOR CIRCULATION MANAGER

**HAMILTON MAHER**

(212) 219-7870 hmaher@jhhealth.com

CEO, INFORMATION GROUP SERVICES

**MARC FERRARA**

SENIOR VICE PRESIDENT, OPERATIONS

**JEFF LEVITZ**

VICE PRESIDENT, HUMAN RESOURCES

**TAMMY GARCIA**

VICE PRESIDENT, CREATIVE SERVICES & PRODUCTION

**MONICA TETTAMANZI**

VICE PRESIDENT, CIRCULATION

**EEMELDA BAREA**



100 Avenue of the Americas  
New York, NY 10013

REVIEW OF OPHTHALMOLOGY (ISSN 1081-0226; USPS No. 0012-345) is published monthly, 12 times per year by Jobson Medical Information, 100 Avenue of the Americas, New York, NY 10013-1678. Periodicals postage paid at New York, NY and additional mailing offices. Postmaster: Send address changes to Review of Ophthalmology, PO Box 71, Congers, NY 10929-0071. Subscription Prices: US One Year \$63.00, US Two Year \$112.00, Canada One Year \$99.00, Canada Two Year \$181.00, Int'l One Year \$158.00, Int'l Two Year \$274.00. For subscription information call (877) 529-1746 (USA only); outside USA, call (845)-267-3065. Or email us at revophthalmology@cambeywest.com. Canada Post: Publications Mail Agreement #40612608. Canada Returns to be sent to Bleupich International, P.O. Box 25542, London, ON N6C 6B2.



An NSAID formulated to penetrate target ocular tissues

# PROLENSA® POWERED FOR PENETRATION

Available in a 3-mL bottle size



**PROLENSA® delivers potency and corneal penetration with QD efficacy<sup>1,2</sup>**

- **Advanced formulation delivers corneal penetration<sup>1-3</sup>**
- **Proven efficacy at a low concentration<sup>1,4</sup>**

## INDICATIONS AND USAGE

PROLENSA® (bromfenac ophthalmic solution) 0.07% is a nonsteroidal anti-inflammatory drug (NSAID) indicated for the treatment of postoperative inflammation and reduction of ocular pain in patients who have undergone cataract surgery.

## IMPORTANT SAFETY INFORMATION ABOUT PROLENSA®

### Warnings and Precautions

- Sulfite allergic reactions
- Slow or delayed healing
- Potential for cross-sensitivity
- Increased bleeding of ocular tissues
- Corneal effects, including keratitis
- Contact lens wear

### Adverse Reactions

The most commonly reported adverse reactions in 3%-8% of patients were anterior chamber inflammation, foreign body sensation, eye pain, photophobia, and blurred vision.

Please see brief summary of Prescribing Information on adjacent page.

**References:** 1. PROLENSA® Prescribing Information, April 2013. 2. Data on file, Bausch & Lomb Incorporated. 3. Baklayan GA, Patterson HM, Song CK, Gow JA, McNamara TR. 24-hour evaluation of the ocular distribution of 14C-labeled bromfenac following topical instillation into the eyes of New Zealand White rabbits. *J Ocul Pharmacol Ther.* 2008;24(4):392-398. 4. BROMDAY® Prescribing Information, October 2012.

©/™ are trademarks of Bausch & Lomb Incorporated or its affiliates.  
© 2015 Bausch & Lomb Incorporated. All rights reserved. Printed in USA. US/PRA/15/0015

**PROLENSA®**  
(bromfenac ophthalmic  
solution) 0.07%

**BAUSCH + LOMB**

## Brief Summary

**INDICATIONS AND USAGE**

PROLENSA® (bromfenac ophthalmic solution) 0.07% is indicated for the treatment of postoperative inflammation and reduction of ocular pain in patients who have undergone cataract surgery.

**DOSAGE AND ADMINISTRATION****Recommended Dosing**

One drop of PROLENSA® ophthalmic solution should be applied to the affected eye once daily beginning 1 day prior to cataract surgery, continued on the day of surgery, and through the first 14 days of the postoperative period.

**Use with Other Topical Ophthalmic Medications**

PROLENSA ophthalmic solution may be administered in conjunction with other topical ophthalmic medications such as alpha-agonists, beta-blockers, carbonic anhydrase inhibitors, cycloplegics, and mydriatics. Drops should be administered at least 5 minutes apart.

**CONTRAINDICATIONS**

None

**WARNINGS AND PRECAUTIONS****Sulfite Allergic Reactions**

Contains sodium sulfite, a sulfite that may cause allergic-type reactions including anaphylactic symptoms and life-threatening or less severe asthmatic episodes in certain susceptible people. The overall prevalence of sulfite sensitivity in the general population is unknown and probably low. Sulfite sensitivity is seen more frequently in asthmatic than in non-asthmatic people.

**Slow or Delayed Healing**

All topical nonsteroidal anti-inflammatory drugs (NSAIDs), including bromfenac, may slow or delay healing. Topical corticosteroids are also known to slow or delay healing. Concomitant use of topical NSAIDs and topical steroids may increase the potential for healing problems.

**Potential for Cross-Sensitivity**

There is the potential for cross-sensitivity to acetylsalicylic acid, phenylacetic acid derivatives, and other NSAIDs, including bromfenac. Therefore, caution should be used when treating individuals who have previously exhibited sensitivities to these drugs.

**Increased Bleeding Time**

With some NSAIDs, including bromfenac, there exists the potential for increased bleeding time due to interference with platelet aggregation. There have been reports that ocularly applied NSAIDs may cause increased bleeding of ocular tissues (including hyphemas) in conjunction with ocular surgery.

It is recommended that PROLENSA® ophthalmic solution be used with caution in patients with known bleeding tendencies or who are receiving other medications which may prolong bleeding time.

**Keratitis and Corneal Reactions**

Use of topical NSAIDs may result in keratitis. In some susceptible patients, continued use of topical NSAIDs may result in epithelial breakdown, corneal thinning, corneal erosion, corneal ulceration or corneal perforation. These events may be sight threatening. Patients with evidence of corneal epithelial breakdown should immediately discontinue use of topical NSAIDs, including bromfenac, and should be closely monitored for corneal health.

Post-marketing experience with topical NSAIDs suggests that patients with complicated ocular surgeries, corneal denervation, corneal epithelial defects, diabetes mellitus, ocular surface diseases (e.g., dry eye syndrome), rheumatoid arthritis, or repeat ocular surgeries within a short period of time may be at increased risk for corneal adverse events which may become sight threatening. Topical NSAIDs should be used with caution in these patients.

Post-marketing experience with topical NSAIDs also suggests that use more than 24 hours prior to surgery or use beyond 14 days post-surgery may increase patient risk for the occurrence and severity of corneal adverse events.

**Contact Lens Wear**

PROLENSA should not be instilled while wearing contact lenses. Remove contact lenses prior to instillation of PROLENSA. The preservative in PROLENSA, benzalkonium chloride may be absorbed by soft contact lenses. Lenses may be reinserted after 10 minutes following administration of PROLENSA.

**ADVERSE REACTIONS****Clinical Trial Experience**

Because clinical trials are conducted under widely varying conditions, adverse reaction rates observed in the clinical trials of a drug cannot be directly compared to rates in the clinical trials of another drug and may not reflect the rates observed in clinical practice.

The most commonly reported adverse reactions following use of

PROLENSA® ophthalmic solution following cataract surgery include: anterior chamber inflammation, foreign body sensation, eye pain, photophobia and vision blurred. These reactions were reported in 3 to 8% of patients.

**USE IN SPECIFIC POPULATIONS****Pregnancy**

Treatment of rats at oral doses up to 0.9 mg/kg/day (systemic exposure 90 times the systemic exposure predicted from the recommended human ophthalmic dose [RHOD] assuming the human systemic concentration is at the limit of quantification) and rabbits at oral doses up to 7.5 mg/kg/day (150 times the predicted human systemic exposure) produced no treatment-related malformations in reproduction studies. However, embryo-fetal lethality and maternal toxicity were produced in rats and rabbits at 0.9 mg/kg/day and 7.5 mg/kg/day, respectively. In rats, bromfenac treatment caused delayed parturition at 0.3 mg/kg/day (30 times the predicted human exposure), and caused dystocia, increased neonatal mortality and reduced postnatal growth at 0.9 mg/kg/day.

There are no adequate and well-controlled studies in pregnant women. Because animal reproduction studies are not always predictive of human response, this drug should be used during pregnancy only if the potential benefit justifies the potential risk to the fetus.

Because of the known effects of prostaglandin biosynthesis-inhibiting drugs on the fetal cardiovascular system (closure of ductus arteriosus), the use of PROLENSA® ophthalmic solution during late pregnancy should be avoided.

**Nursing Mothers**

Caution should be exercised when PROLENSA is administered to a nursing woman.

**Pediatric Use**

Safety and efficacy in pediatric patients below the age of 18 have not been established.

**Geriatric Use**

There is no evidence that the efficacy or safety profiles for PROLENSA differ in patients 70 years of age and older compared to younger adult patients.

**NONCLINICAL TOXICOLOGY****Carcinogenesis, Mutagenesis and Impairment of Fertility**

Long-term carcinogenicity studies in rats and mice given oral doses of bromfenac up to 0.6 mg/kg/day (systemic exposure 30 times the systemic exposure predicted from the recommended human ophthalmic dose [RHOD] assuming the human systemic concentration is at the limit of quantification) and 5 mg/kg/day (340 times the predicted human systemic exposure), respectively, revealed no significant increases in tumor incidence.

Bromfenac did not show mutagenic potential in various mutagenicity studies, including the reverse mutation, chromosomal aberration, and micronucleus tests.

Bromfenac did not impair fertility when administered orally to male and female rats at doses up to 0.9 mg/kg/day and 0.3 mg/kg/day, respectively (systemic exposure 90 and 30 times the predicted human exposure, respectively).

**PATIENT COUNSELING INFORMATION****Slowed or Delayed Healing**

Advise patients of the possibility that slow or delayed healing may occur while using NSAIDs.

**Sterility of Dropper Tip**

Advise patients to replace bottle cap after using and to not touch dropper tip to any surface, as this may contaminate the contents. Advise patients that a single bottle of PROLENSA® ophthalmic solution, be used to treat only one eye.

**Concomitant Use of Contact Lenses**

Advise patients to remove contact lenses prior to instillation of PROLENSA. The preservative in PROLENSA, benzalkonium chloride, may be absorbed by soft contact lenses. Lenses may be reinserted after 10 minutes following administration of PROLENSA.

**Concomitant Topical Ocular Therapy**

If more than one topical ophthalmic medication is being used, the medicines should be administered at least 5 minutes apart.

**Rx Only**

**Manufactured by:** Bausch & Lomb Incorporated, Tampa, FL 33637  
Under license from:  
Senju Pharmaceuticals Co., Ltd.  
Osaka, Japan 541-0046

PROLENSA is a trademark of Bausch & Lomb Incorporated or its affiliates.  
© Bausch & Lomb Incorporated. 9317600

US/PRA/14/0024

# REVIEW<sup>®</sup> of Ophthalmology

January 2016 • Volume XXIII No. 1 | [reviewofophthalmology.com](http://reviewofophthalmology.com)

## Cover Focus

### 24 | **Choosing the Best IOL for A Nonstandard Eye**

*By Christopher Kent, Senior Editor*

Surgeons offer advice on which lens options are likely to produce better results in unusual eyes.

### 32 | **Give Multifocals a Second Look**

*By Walter Bethke, Managing Editor*

How multifocal intraocular lenses with lower add powers may be more useful to patients than higher-add lenses.

### 38 | **Survey: Presbyopic IOL Adoption Slows**

*By Walter Bethke, Managing Editor*

Our Internet survey reflects readers' preferences on IOLs and other surgical issues.

### 42 | **Can 'Super Formula' Increase Accuracy?**

*By John Ladas, MD, PhD, and*

*Uday Dergan, MD*

Building on earlier lens power calculation formulas, this new approach adds a 3-D component.



# Departments

---

4 | [Review News](#)

18 | [Technology Update](#)  
**Breaking New Ground with OCT**

48 | [Glaucoma Management](#)  
**Should You Try a New Glaucoma Surgery?**

With new options available, surgeons have to decide whether it makes sense to incorporate them into their practices.

52 | [Therapeutic Topics](#)  
**Neuropathic Pain and the Artifice of Dry Eye**

How neuropathic pain relates to dry-eye diagnosis and therapeutic strategies.

56 | [Refractive Surgery](#)  
**Refractive Surgery Trends of the ISRS**  
The final ISRS survey ends on a sour note for LASIK volumes but a high note for surgeons' confidence in the procedure.

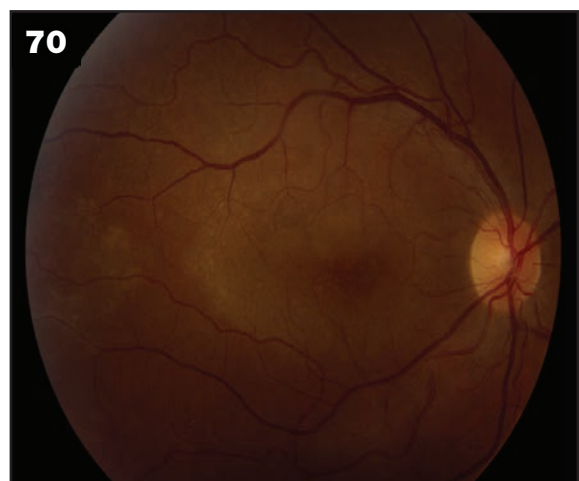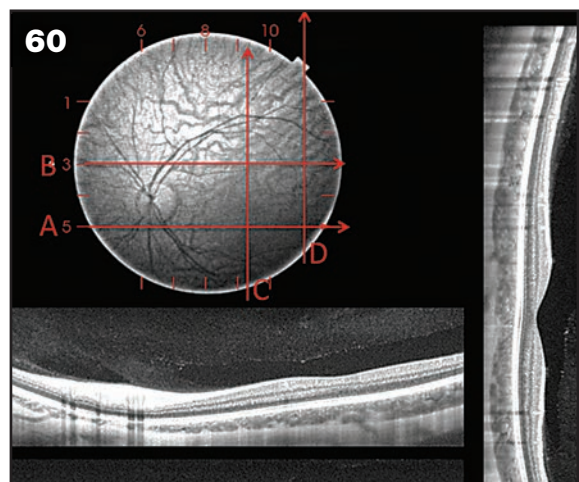
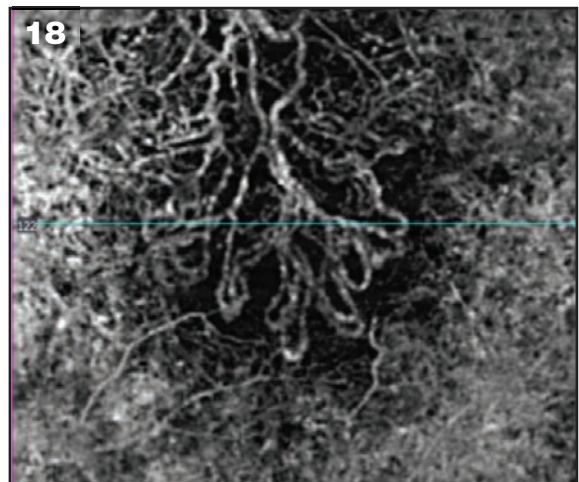
60 | [Retinal Insider](#)  
**A New Understanding of Vitreous Structure**  
Advances in imaging are changing the way we think of the vitreous and how we treat patients.

67 | [Research Review](#)  
**Pain Management Options Compared**

68 | [Classified Ads](#)

70 | [Wills Eye Resident Case Series](#)

74 | [Advertising Index](#)





Abbott

LEAVE A LEGACY OF  
EXCELLENT OUTCOMES  
FOR PATIENTS WITH  
ASTIGMATISM.

Start with  
**ME.**

My vision will only be as good as the IOL you choose. I expect nothing short of exceptional vision, without cataracts or astigmatism. The legacy you leave is the life I live. With the **TECNIS**<sup>®</sup> Toric 1-Piece IOL, I can have the sharpest vision for the long term – even in low-light conditions.

Don't wait to leave a legacy of **excellent outcomes**.  
Start now with the **TECNIS**<sup>®</sup> Toric IOL.

[TECNISIOL.COM](http://TECNISIOL.COM)

From  
**1.50 D**  
—to—  
**6.00 D**

## INDICATIONS AND IMPORTANT SAFETY INFORMATION FOR THE TECNIS<sup>®</sup> TORIC 1-PIECE IOL

### *Rx Only*

**INDICATIONS:** The TECNIS<sup>®</sup> Toric 1-Piece posterior chamber lens is indicated for the visual correction of aphakia and pre-existing corneal astigmatism of one diopter or greater in adult patients with or without presbyopia in whom a cataractous lens has been removed by phacoemulsification and who desire improved uncorrected distance vision, reduction in residual refractive cylinder, and increased spectacle independence for distance vision. The device is intended to be placed in the capsular bag.

See additional Important Safety Information on the following page.

TECNIS is a trademark owned by or licensed to Abbott Laboratories, its subsidiaries or affiliates.  
© 2016 Abbott Medical Optics Inc. | [www.AbbottMedicalOptics.com](http://www.AbbottMedicalOptics.com) | PP2015CT0834

**TECNIS**<sup>®</sup>  
TORIC ASPHERIC IOL



**Abbott**

**IMPORTANT SAFETY INFORMATION  
FOR TECNIS® TORIC 1-PIECE IOL  
(CONTINUED)**

**Rx Only**

**IMPORTANT SAFETY INFORMATION:** Rotation can reduce astigmatic correction. Misalignment greater than 30° may induce refractive error. Accurate keratometry, biometry and [www.TecnisToricCalc.com](http://www.TecnisToricCalc.com) are recommended to optimize visual outcomes. Weigh the potential risk/benefit ratio that could increase pre-existing complications or impact patient outcomes. Variability in any preoperative measurements can influence outcomes. **ATTENTION:** Please reference product DFU (Directions for Use) for a complete list of Indications and Important Safety Information.

TECNIS is a trademark owned by or licensed to Abbott Laboratories, its subsidiaries or affiliates.

[www.AbbottMedicalOptics.com](http://www.AbbottMedicalOptics.com)  
© 2016 Abbott Medical Optics Inc. | PP2015CT0834

**T E C N I S**®  
TORIC ASPHERIC IOL

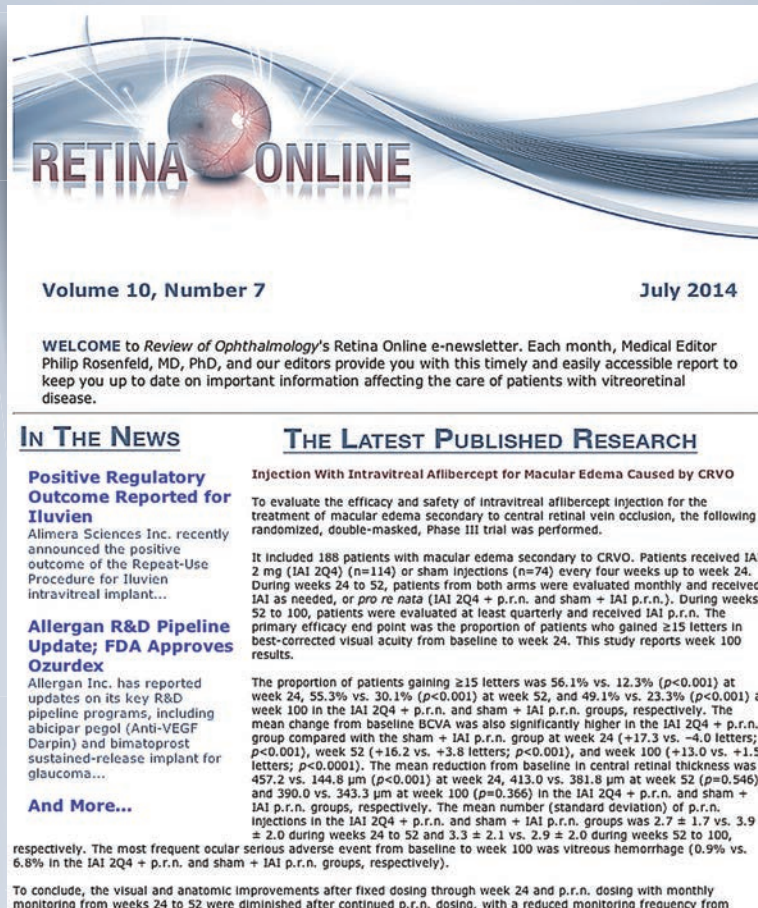Left your *Review of Ophthalmology* magazine at the office?  
**No problem!**



**Read *Review* on your desktop or mobile device!**

Simply go to [www.reviewofophthalmology.com](http://www.reviewofophthalmology.com) and click on the digital edition link to read the current issue online.

# RETINA ONLINE E-NEWSLETTER



Once a month, Medical Editor Philip Rosenfeld, MD, PhD, and our editors provide you with timely information and easily accessible reports that keep you up to date on important information affecting the care of patients with vitreoretinal disease.

**3 EASY WAYS TO SUBSCRIBE!**

<http://www.jobson.com/globalemail/>

Fax: 610.492.1039 or Call: 610.492.1027

**REVIEW**<sup>®</sup>  
of Ophthalmology

*The first and only FDA-approved product that combines  
miosis prevention and post-op ocular pain reduction in one<sup>1</sup>*

OMIDRIA<sup>®</sup> (phenylephrine and ketorolac injection) 1% / 0.3%  
IS COVERED FOR MORE CATARACT  
SURGERY PATIENTS THAN YOU THINK

Introducing

OMIDRIA**Assure**<sup>™</sup>

COVERAGE WITH CONFIDENCE

#### IMPORTANT SAFETY INFORMATION

OMIDRIA<sup>®</sup> must be added to irrigation solution prior to intraocular use.

OMIDRIA is contraindicated in patients with a known hypersensitivity to any of its ingredients.

Systemic exposure of phenylephrine may cause elevations in blood pressure.

Use OMIDRIA with caution in individuals who have previously exhibited sensitivities to acetylsalicylic acid, phenylacetic acid derivatives, and other non-steroidal anti-inflammatories (NSAIDs), or have a past medical history of asthma.

The most commonly reported adverse reactions at 2-24% are eye irritation, posterior capsule opacification, increased intraocular pressure, and anterior chamber inflammation.

Use of OMIDRIA in children has not been established.

**You are encouraged to report Suspected Adverse Reactions to the FDA. Visit [www.fda.gov/medwatch](http://www.fda.gov/medwatch), or call 1-800-FDA-1088.**

#### INDICATIONS AND USAGE

OMIDRIA is added to ophthalmic irrigation solution used during cataract surgery or intraocular lens replacement and is indicated for maintaining pupil size by preventing intraoperative miosis and reducing postoperative ocular pain.

**Please see the Full Prescribing Information for OMIDRIA at [www.omidria.com/prescribinginformation](http://www.omidria.com/prescribinginformation).**





*Because every patient  
deserves access to OMIDRIA...*

*Enroll your next cataract surgery  
patient in OMIDRIAssure now!*

**Now you can provide the benefits of OMIDRIA—  
without worrying about coverage and reimbursement**

**LIVE  
ASSISTANCE**  
INFORMATION  
HOTLINE



Personalized help with  
reimbursement services  
related to OMIDRIA

**“WE PAY THE  
DIFFERENCE”**  
COMMERCIAL  
REIMBURSEMENT  
PROGRAM\*



Assistance for patients  
with insufficient  
commercial insurance

**“EQUAL  
ACCESS”**  
PATIENT  
ASSISTANCE  
PROGRAM



Assistance for financially  
eligible uninsured or  
government-insured  
patients



Talk to your Omeros Representative today or call **1-877-OMIDRIA**  
(1-877-664-3742) to request a Patient Enrollment Form,  
or visit [www.OMIDRIAssure.com](http://www.OMIDRIAssure.com)

\*Omeros will pay your facility, on behalf of your patient, the difference between your facility's acquisition cost for OMIDRIA and the amount covered by your patient's insurance, less a \$30 patient responsibility.

Reference: 1. OMIDRIA [package insert]. Seattle, WA: Omeros Corporation; 2015.

OMEROS®, OMIDRIA®, and the OMIDRIA logo® are registered trademarks, and OMIDRIAssure™ is a trademark, of Omeros Corporation.  
© Omeros Corporation 2015, all rights reserved. 2015-214



**OMIDRIA®**

(phenylephrine and  
ketorolac injection) 1% / 0.3%



# Breaking New Ground With OCT Technology

This technology is now being used to quantify rhodopsin, visualize retinal microvasculature and examine lacrimal glands.

*Christopher Kent, Senior Editor*

**O**ptical coherence tomography has become a mainstay in modern ophthalmology; like X-rays, it can reveal what was previously unseen. And as surgeons and researchers come up with new ways to use this technology, new information and techniques soon follow. Here, doctors talk about three of the latest ways to use OCT, and where the new information they are uncovering might lead us.

## Scanning the Microvasculature

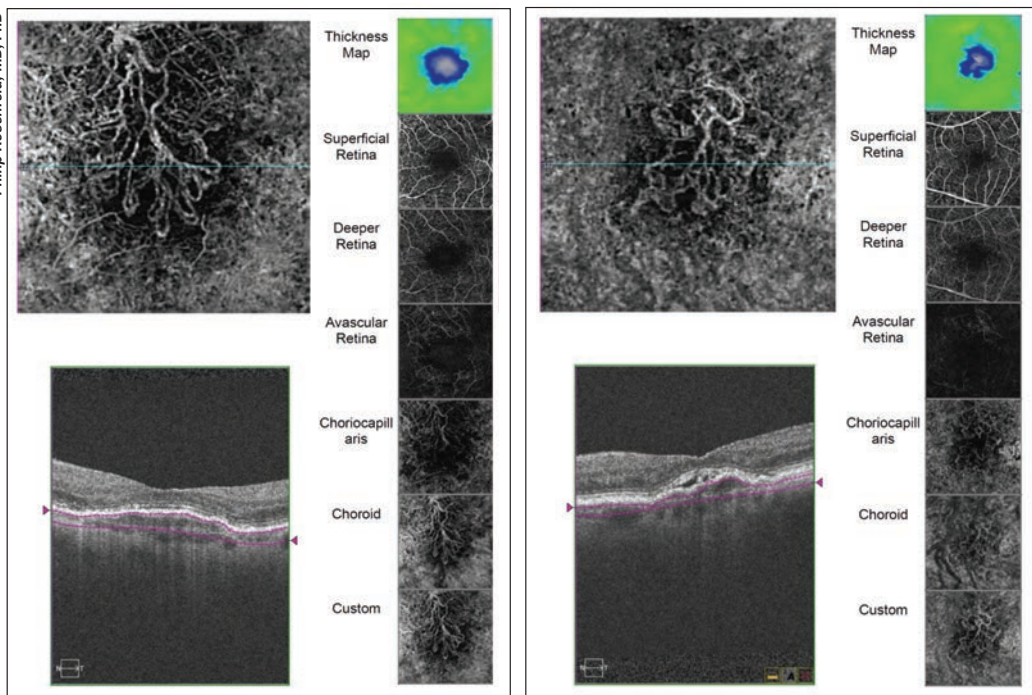
Thanks to a recent Food and Drug Administration approval, Zeiss's AngioPlex OCT system, which can perform OCT angiography, is now becoming available to surgeons in the United States. Philip Rosenfeld, MD, PhD, professor of ophthalmology at the Bascom Palmer Eye Institute at the University of Miami Miller School of Medicine, has worked with Zeiss for several years helping to develop and refine the instrument. "OCT angiography is going to revolutionize the way we manage patients in clinic," he says. "Of course, some retina specialists are skeptical, as many of us were when earlier versions of OCT were

introduced. Doctors want to know what OCT angiography will reveal that they couldn't elucidate from routine spectral-domain OCT imaging. The answer is that OCT angiography allows us to follow pathology better than we've ever been able to before. Now we can not only image structure, we can follow anything that moves through a blood vessel, and hence anything that comprises the microvasculature of the retina and the choroid, over time. That's really important because many of the diseases we treat are diseases of the microvasculature."

A technology like OCT angiography will clearly have value as a research tool, but Dr. Rosenfeld says it's also helping him in the clinic. "It has already affected our patient management in at least three areas," he says. "First, it's helping us with early detection of new blood vessels in macular degeneration and early recurrence of blood vessels in wet macular degeneration patients undergoing treatment. Second, it's helping me to exclude a diagnosis of neovascularization in patients who have what I call masquerade conditions. These patients appear to have wet macular degeneration or

active neovascularization that's leaking, but actually have central serous retinopathy, uveitis or vitelliform lesions, or what we call dysfunctional RPE syndrome, where there's fluid under the retina but it's not a VEGF-mediated process. This technology gives us a better idea of who really has neovascularization and needs to be treated.

"It's also very useful for following diabetic patients with neovascularization," he notes. "For the first time we can actually quantify the neovascularization in the macula and see if it's changing. In the past, we would look at the macula and get a fluorescein angiogram. The leakage would make it difficult to see the entire lesion, and of course, we wouldn't repeat the fluorescein angiogram at every visit. But we can repeat OCT angiography very easily and follow the location of the neovascularization, its size, its thickness, its elevation and how the neovascularization is changing, down to the micron. This really is having a clinical impact; it often causes us to change our treatment. It gives us a concrete, unambiguous way to follow these neovascular lesions."



OCT angiography reveals movement within blood vessels over short periods of time, allowing surgeons to follow the impact of a disease on the retinal microvasculature. The ability to use custom segmentation to examine specific layers of the retina can be crucial. Above: scans of two eyes with choroidal neovascularization.

## How It Works

“What’s really nice about the Zeiss AngioPlex OCT instrument is that you still have all of the imaging capabilities that you would have with standard spectral-domain OCT—all the B-scans, the raster scans, the volumetric data sets, the thickness maps and the en face imaging,” he says. “Essentially, it’s a spectral-domain instrument with an added advantage. So when you do the scan pattern for OCT angiography, you can look at the data in two ways: You can look at it in the structural format, in which you get a routine B-scan and dataset that you can segment, measure or look at the en face structural images; and you can also get en face flow images.

“Each OCT angiographic instrument uses different algorithms to generate the flow image, so I’ll just discuss the AngioPlex device, which I’m most familiar with,” he continues. “To perform angiography, the instru-

ment rapidly takes multiple B-scans at the same position. If you scan a 3 x 3-mm area, it takes four B-scans in one position; then it moves to the next position about 12  $\mu\text{m}$  away and does another four B-scans in that position. In total, it takes just over four seconds to get the scans, and you can accomplish this through an undilated pupil. You can also scan a 6 x 6-mm area; in that mode the instrument repeats each B-scan twice instead of four times. Because the 3 x 3 scan has a higher density of B-scans and more repetition, the image quality is better, showing more detail. Generally, we image a large area first; then we hone in on smaller areas of interest and get higher-quality flow maps of those areas. Of course, you can create a montage to map out a larger area, but most of the time a 6 x 6-mm scan will give you most of what you need.”

Dr. Rosenfeld points out that this technology has multiple advantages over traditional fluorescein or indo-

with flu-orescein or ICG angiography. It’s faster, safer, cheaper, more easily repeated, non-invasive and it doesn’t require IV access or dilation. It images better through cataracts, too. You can do it on pregnant patients. It’s certainly more comfortable for the patient and much easier on kids. Traditional angiography provides a single en face image; here, you can slice through the data sets. You can look at the superficial retinal circulation and the deep retinal circulation. You can look at the area around the RPE and the avascular retina. You can look at the choriocapillaris; you can look at the choroid. You can see where the pathologic changes are occurring.”

Dr. Rosenfeld adds that one of the nicest features of the AngioPlex system is that it’s just a software and hardware upgrade if you already use the Cirrus OCT 5000. “Obviously an upgrade is less expensive than buying a whole new instrument,” he says. “Technicians just need to manipulate

cyanine green angiography. “To conduct the traditional tests the patient has to be dilated, have a needle stuck in his arm and then tolerate flashing lights. You have to infuse the dye, and if the patient turns out to be allergic she could have an anaphylactic reaction, although this is rare. Generally, patients are miserable. With OCT angiography, none of this happens. Instead, the scan takes four seconds, and you’re getting microvascular detail that’s better than anything you can see


the hardware and software, which can be done with a service call.”

## Limitations

Dr. Rosenfeld notes that current OCT angiography technology has limitations, but argues that they have little impact on its usefulness. “Some surgeons have pointed out that you can’t see leakage with OCT angiography,” he says. “That’s true; you don’t see fluorescein leaking out of vessels. But leakage can be detected indirectly by just looking at macular edema—the presence of increased retinal thickness. I can only think of one disease where leakage doesn’t cause increased thickening of the retina: that’s macular telangiectasia type II. Luckily, this disease is easily diagnosed with OCT structural images and OCT angiography, so that’s not much of a disadvantage.

“People also argue that ICG angiography gives you a better image of the choroid than spectral-domain OCT angiography,” he continues. “That’s probably true, because ICG angiography may provide better penetration into the choroid. But spectral-domain technology is pretty good; you see the choriocapillaris; you see the choroid; and in our experience we’ve been able to see everything using spectral-domain OCT angiography that we were able to see using ICG angiography. So I don’t think you’re sacrificing anything.”

Dr. Rosenfeld says that artifacts may still appear in a scan, but says the companies are working to correct that. “When you look at deep retinal structures, anything the light passes through on the way to those structures that contains blood vessels will create what’s called a projection artifact,” he says. “The major retinal blood vessels will look like they’re appearing deep in the retina and choroid. The images are faint, but they’re there. Right now we don’t have ways to get rid of those



Shuliang Jiao, PhD

OCT done with visible light can be used to quantify rhodopsin, a way to gauge the health of photoreceptors. Above: A rat retina was imaged in the dark-adapted stage (left panel) and then in the light-adapted stage (middle panel). Rhodopsin distribution was calculated by the differential image of the two (right panel). The images were processed with a novel speckle-redistribution algorithm.

artifacts, but Zeiss is developing an algorithm that will remove them from the images.”

Other than that, Dr. Rosenfeld says the current image quality is excellent. “The company has improved the eye-tracking system, which is crucial when you’re repeating scans,” he notes. “After all, the only thing that should change between scans is the light scattering from the flow of blood cells through the microvasculature. That requires correcting for eye movement with micron-level precision.

“This technology is only going to get better and faster,” he adds. “You’ll be able to scan larger areas; and the future probably belongs to swept-source OCT where you have better penetration through the RPE for better choroidal imaging.”

## Monitoring Photoreceptor Health

Another new use of OCT—measuring rhodopsin in the retina—is under development in a joint effort by researchers at Bascom Palmer Eye Institute and Florida International University in Miami. Because rhodopsin plays a key role in the function of rod photoreceptors, measuring it is a promising way to judge the condition of photoreceptor health, as well as the impact of treatments intended to preserve vision.<sup>1</sup> What separates this approach from previous methods of rhodopsin measurement is that OCT technology allows the location

of the rhodopsin to be determined with precision *in vivo*, including the layer of the retina it is in. Because it can measure within a specific layer, this approach eliminates artifacts that limit the value of other measurement methods. And unlike standard OCT, this technology uses visible light (hence the name VIS-OCT). Here, three of the researchers developing this technology discuss their work.

“Conventional OCT cannot be used to do functional imaging of rhodopsin because conventional OCT uses near-infrared light to image the retina,” explains Shuliang Jiao, PhD, associate professor in the department of biomedical engineering at Florida International University. “Near infrared light is not as sensitive to the optical absorption of rhodopsin, which is the functional marker of rod photoreceptors. Our visible-light OCT uses wavelengths centered around 520 nm. We selected this wavelength because the absorption of rhodopsin is highest at 520 nm.”

Rong Wen, MD, PhD, professor of ophthalmology at Bascom Palmer Eye Institute, says the image processing is similar to standard OCT, but the procedure and the algorithms are different. “In our current protocol, we image the retina twice,” he says. “To measure rhodopsin you want to first image the dark-adapted rhodopsin, which absorbs the wavelengths of the probing light, around 520 nm. Then we remeasure after the rhodopsin has



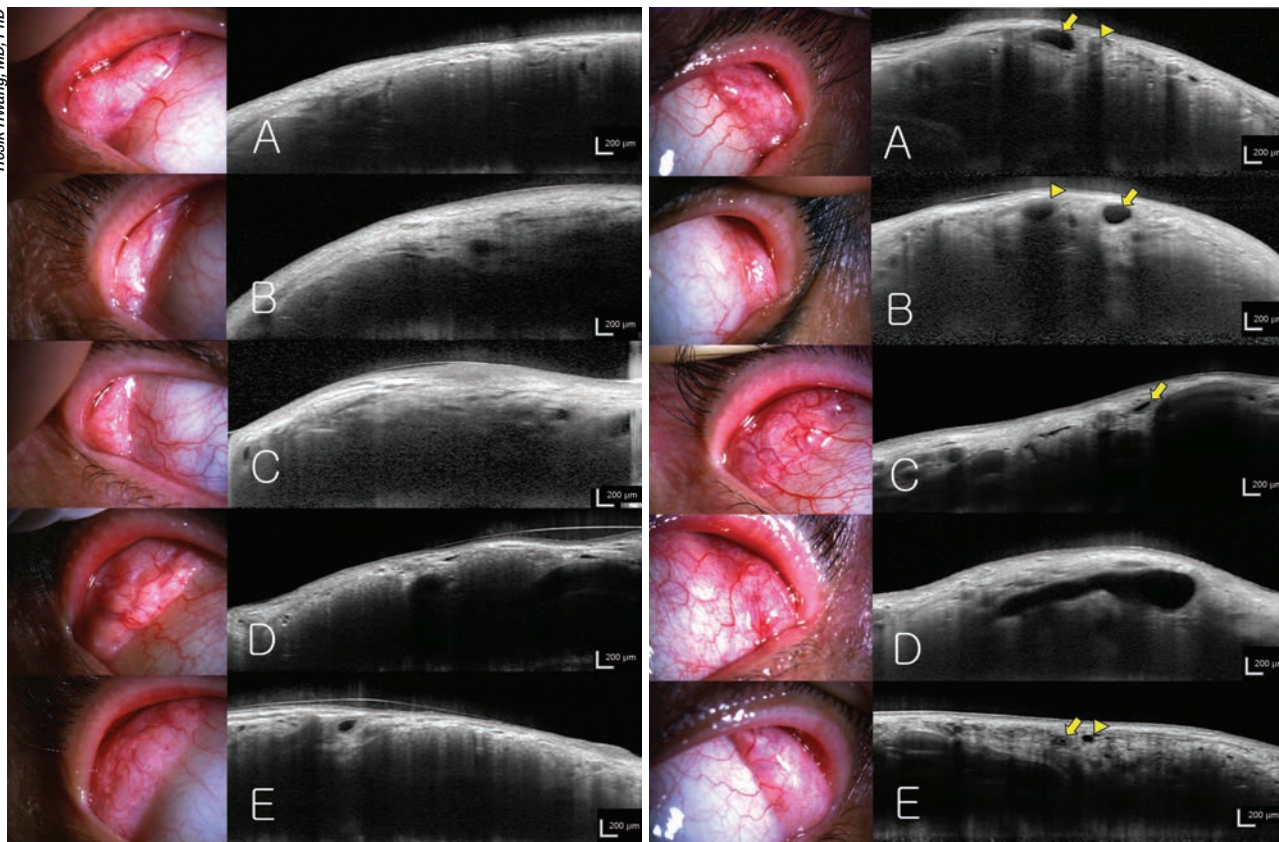
WE'RE EXPANDING OUR FIELD OF VISION

Committed to Innovations in Eye Care

---

**BAUSCH + LOMB**

Hosik Hwang, MD, PhD



OCT can be used to image the lacrimal glands, potentially helping to identify and treat dry eye. Above left: OCT scanning of exposed lacrimal glands. In 88 percent of subjects the parenchyma was clearly visible (A,B). In the other 12 percent of subjects, the margin of the lacrimal gland was indefinite and the parenchyma was not clearly visible (C). The acinar structures could be observed, as long as the lacrimal gland was well-exposed, the conjunctiva and subconjunctival tissue were thin and eyeball movement during the scan was minimal (D,E). Above right: The excretory ducts of lacrimal glands. Blood vessel lumens (arrow head) have higher signal intensity (grey), while excretory duct lumens (arrow) have minimal signal intensity (black). Cross-sections of blood vessels usually appear circular, but cross-sections of the excretory ducts usually appear ellipsoid or distorted ellipsoid (A). Behind the blood vessels (arrow head), a dark shadow appears, like an acoustic shadow in ultrasonography. Behind the excretory duct (arrow), a ‘negative shadow’ (higher signal intensity) is observed (B). Compared to blood vessels, the excretory duct wall is thick and has a high signal intensity (C). Among patients with dry-eye syndrome, the excretory ducts were excessively dilated, possibly because of obstruction of the excretory duct opening (D). The lumens of some ducts (arrow head) have minimal signal intensity like excretory ducts (arrow), but the walls are very thin; these ducts were considered to be dilated interlobular ducts or lymphatic vessels, rather than excretory ducts (E).

been light-adapted. The difference between the two reveals the amount of absorption done by the rhodopsin. By calculation you can figure out how much rhodopsin is in the retina at any given spot.

“This idea is not new,” he continues. “However, this OCT approach is new because it provides depth resolution, which means you can see how different layers contribute to the absorption. That allows us to remove layers that are not relevant to the photoreceptors to generate a better measure-

ment. Also, this method allows us to measure the distribution of rhodopsin, which is a new benefit.”

Dr. Jiao notes that the use of visible light doesn’t bother the animals currently being tested. “The light is visible, but it’s pretty weak,” he says. “The light power in the current system is less than 240 microwatts, which is very similar to current commercial machines used for lipofuscin autofluorescence imaging. So although it’s visible, it’s tolerable. We don’t foresee any problem when this is used in hu-

man eyes.”

So far, the researchers have demonstrated that the system is measuring only rhodopsin, but they haven’t had the funding to compare the quantitative VIS-OCT measurement to other types of rhodopsin measurements. “There will always be limitations to the accuracy of any measurement,” notes Byron L. Lam, MD, the Robert Z. and Nancy J. Greene Chair in Ophthalmology at Bascom Palmer. “We don’t yet know exactly how precise this measurement is. Also, we’ve only

imaged in animals so far, so we may have to adjust the technology's field of view for human eyes. We hope to image human eyes soon."

Dr. Wen notes that rat eyes and human eyes use rhodopsin in similar ways. "There's no reason this technology cannot apply to humans," he says. "There will just be some technical issues because the size of the eyes is different."

Dr. Lam sees this technology being useful both for research and in the clinic. "Researchers will be able to recreate retinal diseases in the laboratory and test different therapeutic strategies," he says. "It will also be very useful in future clinical trials of new treatments. The other important use will be in the clinic, where I see two different scenarios. First of all, you can use it in the clinic to follow a patient, to determine whether a retinal disease has progressed. You won't have to rely on the typical subjective tests that we do today, such as visual field and visual acuity. And if you're treating the patient, this will help you determine whether the treatment is working or not."

Dr. Lam says they hope that this sort of functional, objective measure will open the door for other types of functional OCT testing in the future. "The ultimate goal would be to have a functional, objective way of looking at not just photoreceptor cells, but other cells that have other functions. I think that day will come. This is just the first step."

## A New Look at Dry Eye

A third new use for OCT—imaging the lacrimal glands to help identify dry-eye syndrome—is being studied at a group of universities and hospitals in South Korea. Although several instruments are now available for evaluating the meibomian glands, few are designed to provide information about the tear-producing lacri-

mal glands. Although the work is still in its early stages, these researchers have shown that anterior segment OCT has the potential to reveal the health of these glands in ways previously not possible.

"The lacrimal glands are the most important glands in dry-eye syndrome, but there have been few techniques for imaging them," says Hosik Hwang, MD, PhD, in the department of ophthalmology at Chuncheon Sacred Heart Hospital, Hallym University, in Chuncheon, Korea. "I realized that OCT scanning of the exposed palpebral lobe could be used to visualize the parenchyma of the lobe just beneath the conjunctiva. This type of imaging could be used in Sjögren's syndrome, graft-versus-host disease and other diseases that involve the lacrimal glands."

Dr. Hwang's team conducted a study in which anterior segment OCT was used to obtain cross-sectional images of subjects' lacrimal gland palpebral lobes, *in vivo*.<sup>2</sup> "The examiner pulled the temporal part of the upper eyelid in the superotemporal direction without everting it and asked the subject to look in the inferonasal direction," he says. "Then we obtained B-scans longitudinally or transversely relative to the exposed palpebral lobe. The images allowed us to identify the excretory ducts, lobules, inter- and intralobular ducts, parenchyma and acini of the palpebral lobe." (See examples, facing page.)

Dr. Hwang points out that alternatives for imaging these glands are not practical in dry-eye patients. "OCT scanning can visualize the tomogram of lacrimal glands non-invasively," he says. "If the lacrimal gland has a tumor or is inflamed, CT scanning or MRI imaging could be performed. However, for typical dry-eye syndrome these options would not be reasonable."

Dr. Hwang acknowledges that this approach has some limitations as a means to diagnose dry eye—at least

for now. "First, all of the palpebral lobes of the patient can't easily be exposed," he says. "Second, we were only able to obtain cross-sections of a part of the palpebral lobe. Third, current OCT scans of the lacrimal glands can only reveal what is 200 to 400  $\mu\text{m}$  below the surface of the lobule. This is a function of the OCT technology. In our experiments we used the Spectralis OCT, which has a central laser wavelength of 840  $\mu\text{m}$ . On the other hand, the central wavelength of the laser of the Visante OCT is 1,300  $\mu\text{m}$ . If the Visante OCT were used for lacrimal gland scanning, the resolution would be lower but the image depth would increase."

So far, although differences between healthy and diseased eyes are apparent, the scans have not allowed researchers to conclusively identify which subjects have dry eye and which do not. The team believes this is the result of the shallow depth and low resolution they've been able to obtain so far, using current versions of OCT. Dr. Hwang says the researchers will continue gathering images and working to determine which parameters and characteristics in the lacrimal gland distinguish dry-eye syndrome from normal eyes. [REVIEW](#)

*Dr. Rosenfeld's group receives research grants from Carl Zeiss Meditec, and the University of Miami has a licensing agreement with Zeiss for some of the algorithms in the Cirrus spectral-domain instrument. Drs. Lam, Wen and Jiao have no current financial interest in VIS-OCT; however Florida International University has filed for a provisional patent, and they are named as the inventors of the technology. Dr. Hwang has no financial connection to any OCT company.*

1. Liu T, Wen R, Lam BL, Pulliafito CA, Jiao S. Depth-resolved rhodopsin molecular contrast imaging for functional assessment of photoreceptors. *Sci Rep* 2015;5:13992.

2. Doh SH, Kim EC, Chung SY, et al. Optical Coherence Tomography Imaging of Human Lacrimal Glands: An In Vivo Study. *Ophthalmology* 2015;122:11:2364-66.

# Choosing the Best IOL For a Nonstandard Eye

*Christopher Kent, Senior Editor*

Surgeons offer advice on which lens options are likely to produce better results in unusual eyes.

**S**urgery is a lot like life, in at least one respect: The greatest challenges we face are not the situations we encounter most often, but the ones that are exceptional in some way—the situations that require us to alter our strategy to achieve the best outcome. In cataract surgery, this is often the case when the eye undergoing surgery is nonstandard. Here, three experienced surgeons share their insights about choosing an intraocular lens when a standard choice might not be ideal.

## Spherical Aberration

As every cataract surgeon knows, determining the ideal power for an intraocular lens can be challenging in eyes that have previously undergone refractive surgery. But today, that's not the only concern; modern lens technology has made it possible to address the spherical aberration of the cornea, which may have been altered by that surgery. Many surgeons try to counteract the alteration by choosing an IOL with a level of positive or negative asphericity that may offset it. (In fact, this strategy is now commonly used to try to produce the best possible vision in eyes with virgin corneas, which normally have some spherical aberration as well.)

“Intraocular lens design has been one of the great innovations in ophthalmology over the past decade,” says Eric D. Donnenfeld, MD, clinical professor of ophthalmology at New York University Medical Center and a partner at Ophthalmic Consultants of Long Island. “Previous generations of lenses had positive spherical aberration that added to the net spherical aberration of the cornea, resulting in patients having significant higher-order aberrations. Those aberrations led to glare and halo, a loss of contrast sensitivity and an overall loss of vision quality.

“The advent of new-generation lenses occurred about 10 years ago when Pharmacia developed the aspheric IOL, which has negative spherical aberration,” he continues. “The negative spherical aberration offsets the positive spherical aberration of the average cornea, resulting in better contrast sensitivity. These lenses achieved New Technology IOL status from the Centers for Medicare & Medicaid Services and were reimbursed at a higher rate than other lenses because it was proven that they improved people's ability to function in tests such as driving ability.

“Today, these lenses are commonplace, and there are several different lenses that are available,” he says.

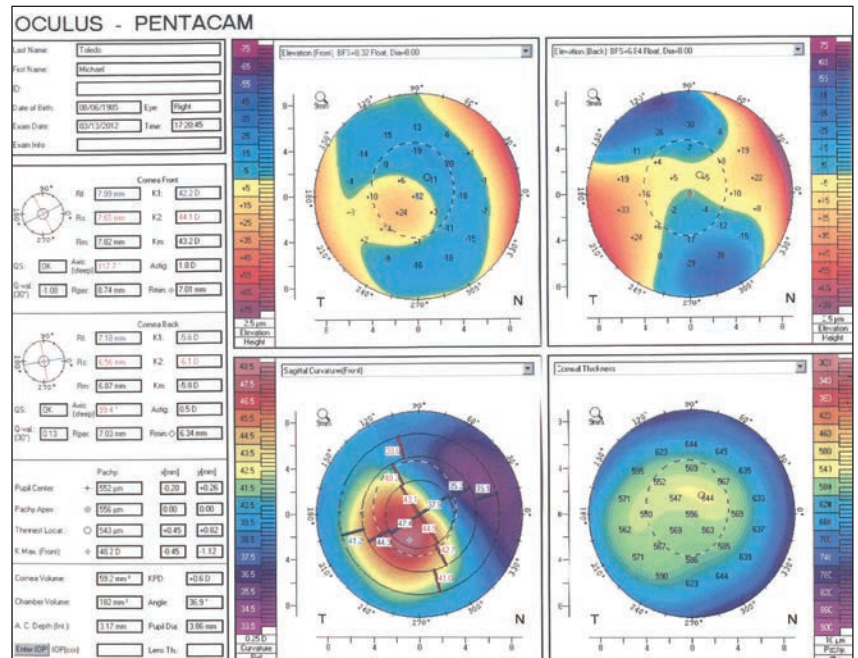
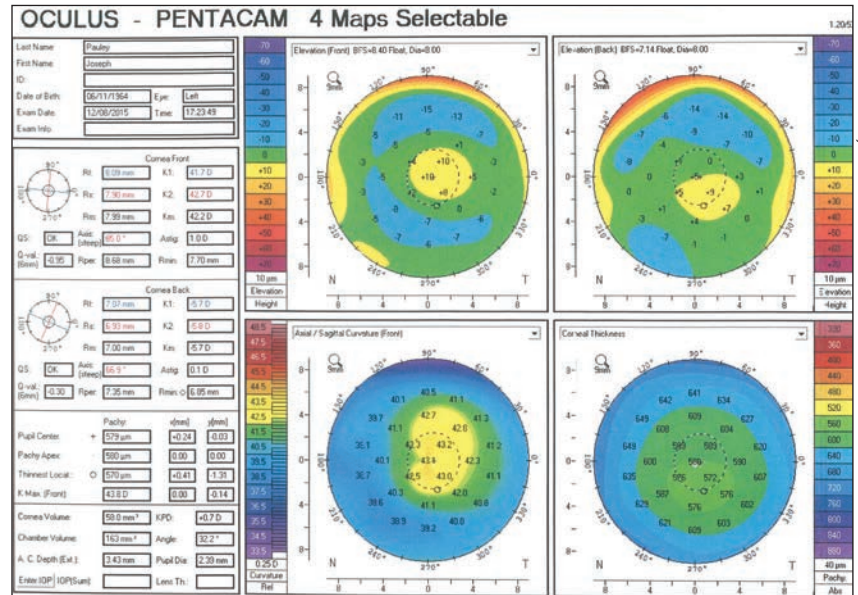


“There are negative spherical aberration lenses, low-negative spherical aberration lenses, zero spherical aberration lenses and positive spherical aberration lenses. All of these play a role in my surgical armamentarium when managing patients undergoing cataract surgery. For routine cases, I generally choose a negative spherical aberration lens, unless the eye is unusual; for the overwhelming number of patients, negative spherical aberration lenses yield better quality of vision. But for special circumstances, having the full armamentarium of lenses available is helpful for matching the patient’s preoperative status and achieving the best postoperative surgical result.”

## Managing Altered Sphericity

Dr. Donnenfeld notes that hyperopic LASIK leaves the cornea steeper, inducing negative spherical aberration. “For these patients I would either implant a zero-aberration lens or a positive spherical aberration lens,” he says. “If the topography shows that the center of the cornea is steepest along the line of sight, a positive spherical aberration lens can actually give better quality of vision. However, if it’s decentered, which commonly occurs with hyperopia, a zero aberration lens makes the most sense. (See examples, right.) On the other hand, when patients have had previous myopic LASIK their corneas are flattened, inducing positive spherical aberration. As a result, they generally have more positive aberration than a normal cornea. In this situation it’s very important not only to use a negative spherical aberration lens, but to use a lens which has the maximum amount of negative spherical aberration.”

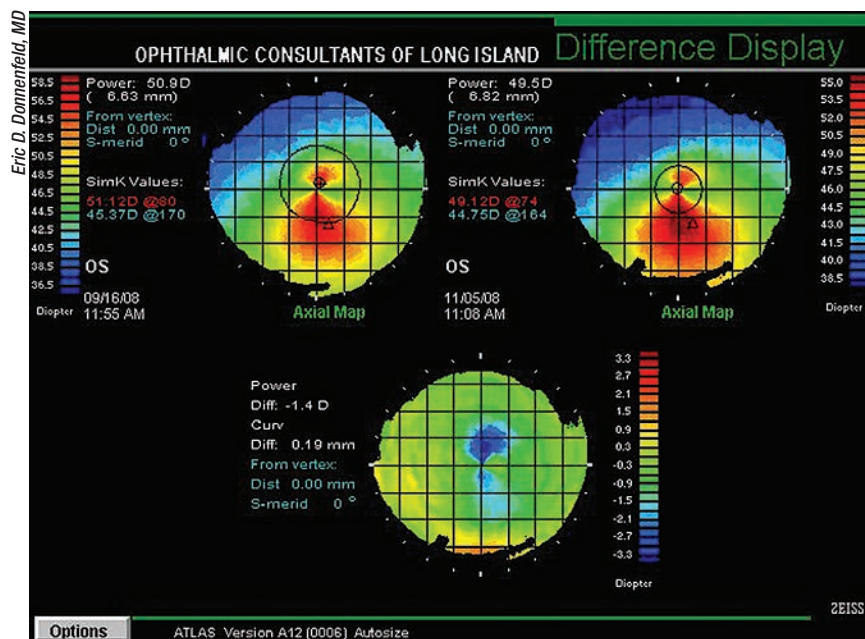
Jorge L. Alio, MD, PhD, medical director of Vissum-Instituto Oftalmológico de Alicante in Alicante, Spain, agrees. “If a patient has had previous refractive surgery, we need to be



When an eye has undergone previous hyperopic LASIK, an intraocular lens with positive spherical aberration may help to improve the patient’s vision—if the ablation is well-centered (above, top). However, hyperopic ablations are often decentered; then the positive asphericity could backfire and a zero-aberration lens would be preferable (bottom scans).

careful about lens selection, not just because of the power, which can be tricky to determine, but because you have to deal with aberrations that have been left by the refractive procedure,” he says. “I usually prefer to use a neutral-asphericity lens in these cases. The reason is that these eyes all have

some amount of optical aberration. In particular, they often have coma, and combining coma with asphericity can be problematic. A neutral lens is also less problematic if there is decentration, particularly in hyperopia. In cases with previous corneal refractive surgery I also would avoid choosing a



Keratoconic eyes generally have negative spherical aberration and decentered optical apices, making a zero-spherical aberration lens most appropriate. If the disease is mild-to-moderate (as in the case above) and the eye has some astigmatism, but not a significant amount of irregular astigmatism, a toric lens may improve vision.

multifocal lens, unless corneal aberrometry shows an absence of higher-order aberration.

“If the patient was treated for hyperopia, the eye will now have negative spherical aberration,” he continues. “In these cases, if the correction was well-centered, I prefer to use a lens with positive spherical aberration—i.e., a conventional spherical lens. On the other hand, if the eye has undergone myopic LASIK, with good centration and no significant amount of coma, then I prefer to use negative asphericity lenses to compensate for the positive spherical aberration these patients usually have.” (Dr. Alio notes that eyes that have undergone refractive surgery within the past two or three years may not have this altered corneal spherical aberration because of improvements in the software used to perform the surgery. However, the majority of patients currently undergoing cataract surgery will have had any refractive surgery performed more than three years ago.)

“Another concern when patients have had previous corneal refractive surgery is toricity,” Dr. Alio says. “If the corneal topography shows that the patient has more than 2 D of corneal astigmatism, my choice is a toric lens, with either negative or positive asphericity, depending on the centration of the previous corneal refractive surgery. Toric lenses are an excellent choice for these patients because you address both the astigmatism and the spherical component.”

However, some surgeons’ experience has made them skeptical about the significance of the sphericity of the lens. “I think it’s uncertain how much benefit patients actually get by choosing a certain degree of asphericity in the IOL,” says Richard Mackool, MD, director of the Mackool Eye Institute and Laser Center and senior attending surgeon at The New York Eye and Ear Infirmary. “About 15 years ago when aspheric IOLs first became available, I was doing about 3,500 cataract surgeries a year and I had a lot of patients

who had only had one eye done, using a standard IOL. Because the new technology was now available, I put an aspheric IOL in the second eye of about 500 patients. Not one of those patients noticed a difference. Even in the exam lane when we asked which eye was better, they couldn’t tell.

“Of course this was in normal, ambient lighting conditions where the pupil was relatively small,” he says. “But none of them noticed a difference driving at night, either. I’m aware that people have conducted tests that found that reflex stopping distance improved with an aspheric lens when driving in the dark, but no patients came in and told me that.

“It’s good that we keep searching for better IOLs, including higher-order-aberration-correcting IOLs,” he adds. “But thus far, my experience has been that to minimize problems caused by higher-order aberrations, it’s far more important for the patient to have a small pupil.” (*For more on that topic, see the sidebar on p. 30.*)

## Keratoconus

One of the issues presented by keratoconic eyes is that they are exceptionally steep, causing negative spherical aberration. “Adding additional negative spherical aberration would not be a good idea,” Dr. Donnerfeld points out. “I prefer to use a zero spherical aberration lens in these patients because these eyes also have decentered optical apices. A zero-aberration lens ensures that if the lens decenters from the line of sight it will not induce higher-order aberrations such as coma.”

In terms of implanting a toric lens, he notes that it’s impossible to fully correct an irregular cornea with a toric lens. “Toric lenses are optimal for patients who have regular bow-tie astigmatism,” he says. “However, in general, toric lenses do well when the patient has mild-to-moderate keratoconus. (*See example, above.*) I gener-

ally place the lens on the keratometric axis, but I like to confirm it with the refraction as well. On the other hand, if the patient has significant irregular astigmatism, a toric lens is generally a bad idea.”

Dr. Alio says that when dealing with a keratoconic eye he first determines how aberrated the cornea is by looking at the topography and corneal aberrometry. “If the cornea has less than 2  $\mu\text{m}$  of higher-order aberrations, then the best choice is probably a spherical lens, with or without a toric correction,” he says. “If the eye has between 2 and 4  $\mu\text{m}$ , my choice is usually a toric lens, because these eyes always have high cylinder. However, I prefer to use a neutral-asphericity lens, because the corneal eccentricity caused by the keratoconus does not combine well with negative or positive asphericity. If the patient has more than 4  $\mu\text{m}$  of higher-order aberration I strongly recommend performing a deep anterior corneal lamellar keratoplasty at the same time as the cataract surgery. Otherwise, these patients will not have good vision after cataract surgery.”

Dr. Mackool points out that typical cataract patients with keratoconus have a stable cornea because of their age; that frees the surgeon from having to worry about worsening keratoconus after implantation. “Most of these patients have significant astigmatism, and many have a lot of irregular astigmatism,” he says. “So, you’re probably not going to want to implant a multifocal—although a few of the newest multifocals might work.”

Dr. Mackool also offers some advice about determining the best refractive power for the implant. “Determining the IOL power can be very difficult because of the irregularity and multiple curvatures in the cornea,” he notes. “Conducting an aphakic refraction helps, but part of the problem in these cases is that the dilated refraction and normal-sized pupil refraction can be very different; when the pupil

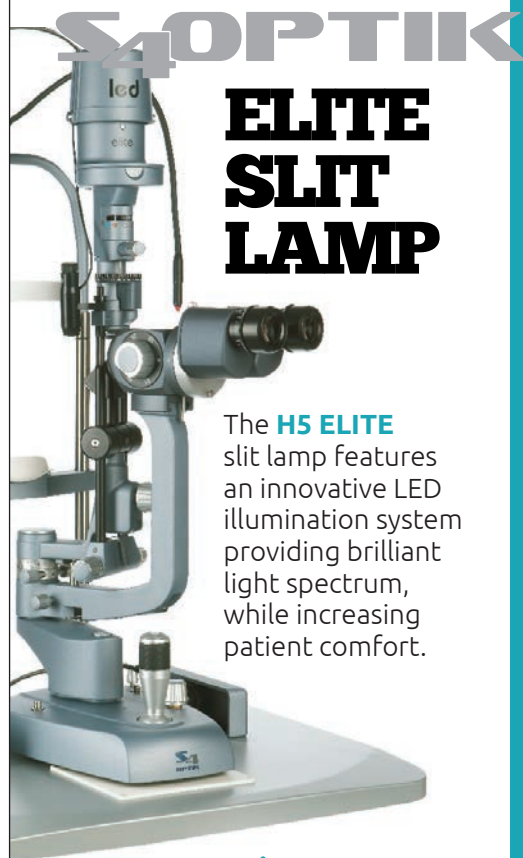is dilated the light is entering the eye through far more irregular curvature. For that reason, the aphakic refraction really should be done not while the patient is dilated immediately postop, but the next morning when the patient has a normal pupil.

“For that reason, when we have a patient with any significant keratoconus we divide the operation into two parts,” he says. “On the first day we take the cataract out and perform an aphakic refraction; the next day we put in the implant. In fact, we do this with every patient in whom we can’t measure the IOL strength accurately by the usual means, including post-LASIK eyes and eyes with nystagmus. If we find significant cylinder, we’ll often use a toric IOL, but we will seldom use a multifocal IOL in these patients. We won’t use a toric IOL if the plan is for the patient to wear a hard contact lens after surgery.”

Dr. Mackool notes that some surgeons express concern about dividing the surgery into two parts. “People say we’re doubling the risk of infection by doing this, but we’ve had zero infections and zero complications in more than 2,000 patients,” he says. “Of course, part of the reason is that we put vancomycin in the eye at the end of the procedure. We’ve done 80,000 consecutive cataract surgery operations at my surgery center without one case of endophthalmitis. There was a recent report of possible retinal vasculitis after intracameral vancomycin injection in the literature, but we’ve used vancomycin in 80,000 consecutive cases at our center with no endophthalmitis and no sign of any type of postoperative vasculopathy.”

### Multifocal Contraindications

Many surgeons avoid implanting a multifocal IOL whenever an eye has any unusual condition. However, according to Dr. Mackool, the design of some recent multifocal IOLs has



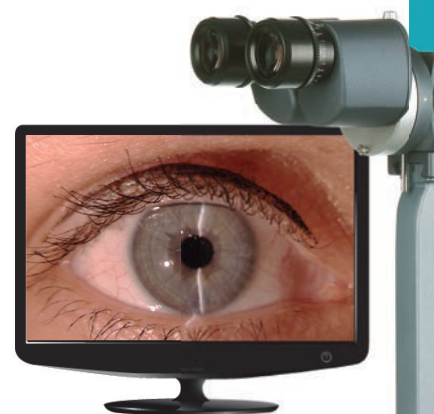## ELITE SLIT LAMP

The **H5 ELITE** slit lamp features an innovative LED illumination system providing brilliant light spectrum, while increasing patient comfort.

An extensive power range, with five magnification settings from 6x to 40x. Standard on all ELITE slit lamps.

## IMAGING

The **S4OPTIK H5 ELITE** slit lamp comes digital ready. Combine with the S4OPTIK all-in-one digital camera to acquire exceptional still and video images.



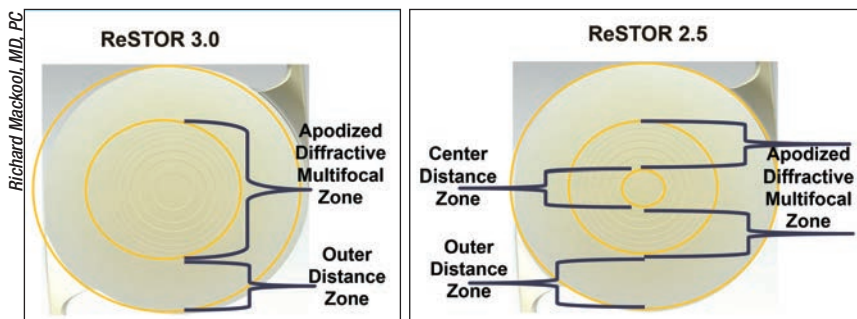
## S4OPTIK

250 Cooper Ave., Suite 100 Tonawanda NY 14150

[www.s4optik.com](http://www.s4optik.com) | 888-224-6012

Sensible equipment. Well made, well priced.

For today's modern office.



Although most surgeons are hesitant to implant a multifocal lens in an aberrated eye, some recent multifocal lenses have reduced the potential for problematic outcomes by making the center area of the lens distant-dominant, as in the ReSTOR 2.5 (pictured above, right). Where previous multifocals could cause a 20-percent reduction in distance acuity, surgeons report that this format may only reduce the patient’s distance acuity by 5 percent.

made them less problematic in non-standard eyes. “Some new IOLs under development, including the ReSTOR 2.5, which is already available, are distant-dominant in the central 1 mm,” he says. “This alleviates much of the concern we’ve had about implanting a multifocal in an aberrated eye, whether the problem is keratoconus or some other disease that causes corneal irregularity. I’ve used it successfully in these patients many times.”

Dr. Mackool says the reason this can work in an aberrated eye is the way the light is distributed by the lens. “It comes down to the percentage of light rays devoted to distance, especially in the center of the lens,” he explains. “If an eye already has some issues with focusing 100 percent of light rays appropriately—e.g., keratoconus or post-LASIK—now you may be talking about a multifocal that’s using half of the light rays for distance and half for near. This can lead to one very unhappy patient. However, if the IOL devotes the vast majority of light rays to distance because the central millimeter is 100-percent dedicated to distance, this is far less problematic.

“Prior to the availability of the ReSTOR 2.5 lens, I would tell my patients who were going to receive a multifocal lens that their distance vision would be about 20-percent reduced,” he says. “That would dissuade a lot of people

from choosing a multifocal. But with the ReSTOR 2.5, the patient may lose only 5 percent of his distance acuity. That’s insignificant to virtually everybody. I wouldn’t implant it in a professional baseball player, but that’s about the only exception.”

Nevertheless, Dr. Mackool says he avoids placing a multifocal in eyes that have corneal or retinal disease that appears to be significant—or possibly progressive. “There are a couple of reasons for that,” he says. “You don’t want even a 5-percent reduction in the patient’s acuity in that situation. If the patient doesn’t do terribly well postoperatively, then everybody will be thinking that the patient would have done better without the multifocal. You may end up in what I call a medico-legal adventure. A lawyer won’t have any trouble finding someone who will say, ‘I can’t believe they put a multifocal in this eye.’ So you want to avoid placing a multifocal in historically contraindicated eyes, where you might create headaches for the patient and you. It’s just not that important for the patient to possibly end up not needing near-vision glasses some or all of the time.”

“I tend to be conservative about placing multifocal lenses in patients who have irregular corneas,” adds Dr. Donnenfeld. “The most common irregular cornea we see is one that has undergone previous laser vision cor-

rection. If the cornea looks normal and topography shows a well-centered ablation with a modern ablation zone that’s fairly prolate, then a multifocal lens may work pretty well. But if the cornea has an older-style ablation profile, especially in patients who started out with high myopia or hyperopia, I avoid implanting multifocal lenses because of the likelihood of a loss of contrast sensitivity.”

### Weak Zonules

“If a patient has weak zonules or there’s concern about IOL decentration, a zero-aberration lens is my lens of choice because of the possibility of the IOL moving off of the visual axis,” notes Dr. Donnenfeld. “A patient who has had a previous vitrectomy, for example, will often have weak zonules. You just have to prepare for that when you operate on the patient.

“Surgeons have different opinions about the best lens to implant when zonules are weak,” he continues. “Some surgeons like to use one-piece acrylic lenses because placing them in the eye is less traumatic. Some people like three-piece lenses because they provide a pseudo capsular tension ring, holding the capsular bag in place. In addition, if the lens does dislocate, it’s much easier to suture a three-piece lens to the iris than a one-piece lens. In general, I choose to use three-piece lenses in eyes that have poor zonular support, such as patients with pseudoexfoliation, patients who have undergone trauma, and occasionally patients who have had a vitrectomy.”

Dr. Alio agrees. “If the patient has had a vitrectomy, I usually implant a three-piece lens, the Alcon MA60, and I usually use a capsular tension ring,” he says. “In many cases these capsules are quite unstable, and in my hands this approach works better.”

Dr. Mackool notes that some surgeons believe toric or multifocal IOLs should not be used in eyes with poor

order online  
www.innovativexcimer.com

# AMOILS

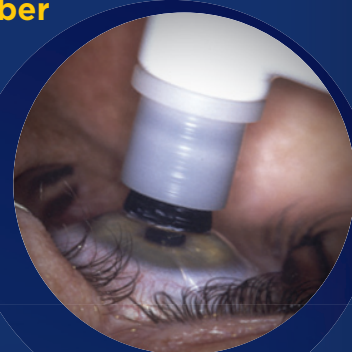AMOILS EPITHELIAL SCRUBBER

Uniform  
epithelium  
removal in  
only 5 - 7 seconds

ORDER ONLINE NOW  
www.innovativexcimer.com

Corneal Xlinking,  
PRK, & Advanced  
Surface Ablation

Improved clinical  
outcomes of CXL  
and PRK with the  
**Amoils Epithelial  
Scrubber**



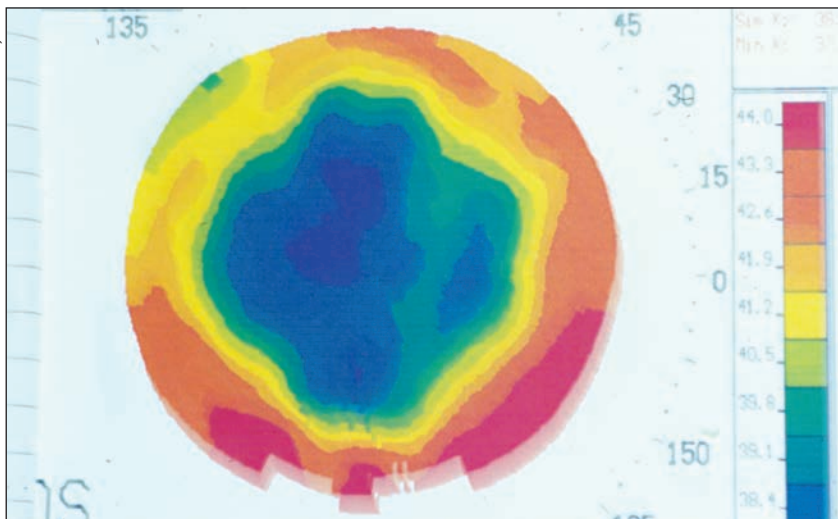
- Minimize total procedure time
- Avoid alcohol damage to surrounding tissue
- No need for subsequent scraping

CALL 1.800.461.1200

innovativexcimer.com

order online now!

Eric D. Donnenfeld, MD



A cornea that previously underwent radial keratotomy (example above) is likely to be left with multiple aberrations. Surgeons often choose a neutral-asphericity lens for these eyes, in part to avoid combining asphericity with aberrations such as coma, which can be problematic. A neutral lens is also less problematic if the ablation or lens is decentered.

zonular support, but he disagrees. "I've placed those IOLs in many of these eyes, typically pseudoexfoliation eyes with a lax zonule," he explains. "People say, 'What if the lens dislocates?' Well, then you have to fix it, just as you'd have to fix an aspheric monofocal. The fact that you might have to reposition the lens at some point doesn't decrease the patient's chances of seeing well with a toric lens or premium IOL.

"If you're dealing with an eye that you think may eventually develop IOL dislocation, my advice is, put in a capsular tension ring," he continues. "A capsular tension ring makes it much easier to reposition the IOL. If necessary, you can suture the capsular tension ring to the sclera at any axis; typically, it takes one suture on each side. If a patient comes in with a dislocated premium IOL, we don't change it to a different IOL. We reposition it just as we would reposition any other IOL. I honestly don't believe that people who have less-than-ideal capsular support should have any other IOL than the one you'd put in if they had great capsular support. We've been following that premise since toric and premium

IOLs were available, and so far our patients have all done well."

## Other Issues

Other factors may also make it advisable to consider implanting an IOL other than your standard choice:

- **Patient age.** Dr. Alio says the age of the patient does matter. "In cases of elderly patients, I don't worry as much about asphericity," he says. "These patients usually have small pupils and don't benefit much from choosing a special spherical or aspherical lens. Also, standard spherical lenses are much less expensive, which can be important to these patients. It's something to consider in patients over the age of 75.

"I also avoid using multifocal lenses in patients over 75," he adds. "The learning capacity of an aging brain is not as great as that of a young brain. Neural adaptation and contrast sensitivity both drop with age, and this becomes more significant when we reach our 70s. This is just the normal evolution of the human brain and eye and retina."

- **Patients wearing gas-perme-**

## The Pupil-Size Factor

Today, when a patient has had previous laser refractive surgery, many surgeons attempt to correct for spherical aberration that may be present in the cornea as a result of the surgery by choosing an implant with a specific amount of negative or positive spherical aberration. However, some surgeons believe this may not be necessary in many patients.

"In reality, the single most important factor in terms of how well these patients do, especially in dim illumination, is their pupil size," says Richard Mackool, MD, director of the Mackool Eye Institute and Laser Center and senior attending surgeon at The New York Eye and Ear Infirmary. "If the patient has a small pupil—the ideal pupil size is between 2 and 2.5 mm, as measured by the observer—then you pretty much don't have to worry about the higher-order aberrations that may have been introduced by the corneal procedure. So it's very important to measure the pupil size in these patients preoperatively. If the patient has a large pupil, then you should have a discussion about the possibility of using a miotic agent.

"For example, I've seen several patients over the years with large pupils post-LASIK in whom we implanted IOLs, and their best-corrected visual acuity would be something like 20/50," he says. "Then, we'd put in a miotic agent and take the pupil down to 2.5 mm, and they'd be 20/20. A number of those patients were referred to me with the idea that they might need an IOL exchange. Instead, I put them on miotics and they looked at me like, 'Why didn't somebody else think of this?' I believe the answer is simply that this approach hasn't been well-publicized." He adds that a pupil size of 2 to 2.5 mm is optimal because it provides the best depth of field, while avoiding the problem of noticeably reduced

vision in dim lighting conditions.

Dr. Mackool notes that using a miotic has had some downsides in the past, but that may be about to change. "Until now, the only miotic agent we've been able to use has been pilocarpine," he says. "A weak solution of about 0.5% is all one needs, but that means you must either obtain it from a compounding pharmacy or have the patient dilute it, because the lowest commercially available concentration is 1%. To minimize the expense and effort of obtaining it already diluted, we have patients use the 1% drops and put in a lubricating drop simultaneously, which roughly dilutes it down to 0.5%. Of course a few patients—about 10 or 15 percent of them—will need to use 1% pilocarpine because 0.5% doesn't cause enough reduction in pupil size.

"Unfortunately," he continues, "using pilocarpine for this purpose can cause other side effects. It stimulates accommodation, although that's not a problem after cataract surgery. It also gives some users a periorbital brow ache, especially the first few days they use it; that ache may continue for quite a while in some younger patients. A very small percentage of users will experience irritation or even develop a little iritis. Also, the maximum benefit you get out of pilocarpine only lasts about six hours, so the patient has to use it two or three times a day. However, this may change soon, thanks to a new miotic that promises to be much easier to use, one that reduces pupil size but doesn't stimulate accommodation. Its activity is limited to the iris only. It promises to be much better tolerated, and will have a much longer duration of action. So, help is on the way. I can't wait to get my hands on the new drop myself, because I'm tired of using reading glasses."

—CK

**able contact lenses.** "Implanting a toric lens in a keratoconus patient who wants to continue to wear gas permeable contact lenses after cataract surgery is not a good idea," says Dr. Donnenfeld. "Once the lens is placed you lose the effectiveness of the gas-permeable contact lens because the cylinder is placed inside the eye and can no longer be corrected with a contact lens."

• **Lens in the sulcus.** Dr. Donnenfeld notes that poor zonular support is a common reason for placing the lens in the sulcus. "Under these circumstances, three-piece lenses are ideal," he says. "In addition, the lens that's placed in the sulcus should have a longer length. No IOLs in

the United States are specifically designed for sulcus placement, but the STAAR AQ2010 and AQ 5010 lenses are the longest lenses currently available—13.5 and 14 mm, respectively. These are very helpful when the lens is in the sulcus, especially in larger eyes, where the white-to-white may cause helicoptering of a shorter lens."

Dr. Donnenfeld adds that in most cases, it's not a good idea to place a one-piece acrylic lens in the sulcus. "This will cause iris chafing and can induce uveitis-glaucoma-hyphema syndrome," he notes. "However, an acrylic lens placed in the bag with optic capture anteriorly is a successful procedure, and it's something that can be done for patients receiving a pre-

mium lens, such as a toric or multifocal lens, when there's a rent in the posterior capsule."

• **Silicone vs. acrylic.** Although silicone lenses work well in most situations, acrylic lenses are more popular today. "Typically, acrylic IOLs can be inserted through a smaller incision and they unfold more gently," notes Dr. Mackool. "I think the vast majority of retinal surgeons favor an acrylic IOL in eyes that are at risk of retinal detachment, because if the patient may have retinal problems or retinal detachment you may need to use silicone oil inside the eye. You tend to get beading when you have silicone oil in contact with a

(continued on page 73)



## The Complete Lid Hygiene System

100%  
PRESERVATIVE  
FREE

*"The ilast® Lid Hygiene System has been a great addition to my practice. The **unique high molecular weight hyaluronic acid** contained in both products has **water-binding properties**, providing unparalleled moisture to the delicate skin around the eye."*

*"The ilast® Lid Hygiene System has been a great addition to my practice."*



Please visit

[PURCHASEILAST.COM](http://PURCHASEILAST.COM)

or call (888) 424-1192  
for more information!



Dr. Larry E. Patterson, MD  
Eye Centers of Tennessee  
Crossville, TN

# Giving Multifocals A Second Look

Walter Bethke, Managing Editor

How multifocal IOLs with lower add powers may be more useful to patients than higher-add lenses.

Astronomers sometimes refer to the area in our solar system occupied by the Earth as the “Goldilocks Zone”: Its distance from the Sun makes it neither too hot nor too cold to support liquid water; but instead, it’s just right. Cataract surgeons are beginning to think there may be a Goldilocks zone for many patients who are candidates for multifocal intraocular lenses, too, except in this case it’s around the distance of a car’s dashboard or a desktop computer. If the add power’s focal point is any closer, some surgeons say, the patient doesn’t have much intermediate vision at all.

In this article, surgeons discuss the benefits of low- and mid-add multifocal lenses, and why they may be more attractive options for patients than lenses with higher add powers.

## High-add Issues

Surgeons say implanting a high-add multifocal, such as a +4 D, would often take a lot of adjustment on the patient’s part.

“With the original, higher-add lenses, I’d routinely counsel patients about the focal point of the add,” recalls Bakersfield, Calif., surgeon Daniel Chang. “Particularly for patients who were younger and still

working and/or using the computer a lot, that intermediate computer range was not at the lens’s best focal point. I’d let them know they might have to adjust where their computer screen sat. To look at the computer at the back of their desk, there was a dip in the vision at that distance and it would be blurrier. The high-add lenses had an optimal focal point of about 14 inches, but, functionally, a lot of things in patients’ lives was beyond that, more in the 20-inch range.”

Iselin, N.J., ophthalmologist Doug Grayson says the high-add patients’ visual needs would sometimes confuse even health-care staff. “When



The Tecnis ZKB00 has fewer diffractive rings than other versions, producing a low-add power (+2.75 D) that can be beneficial to patients who want intermediate vision.



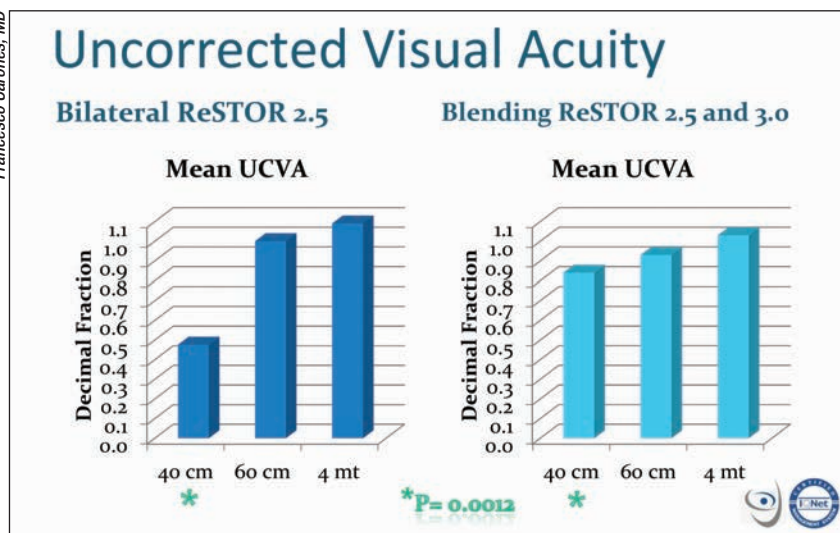
we were implanting the [Tecnis] ZMB00, they'd lose the intermediate zone of vision," he says. "If patients needed computer vision, we were actually giving them -1 D glasses to bring their vision out a little farther. That was the only solution. Some referring optometrists didn't understand the concept that they were dealing with a multifocal that had almost too-high of an add power. They were giving these patients +1 D reading glasses for the computer, but the concept is that you have to decrease the add for that distance. So, I'd end up calling them and asking them to give the patients a -1 D spectacle."

## New Adds, New Options

Surgeons say the newer add powers in the middle and low range bring a couple of benefits.

- **The intermediate focal point.** Los Altos, Calif., surgeon Bryan Lee says low- and mid-power adds mesh better with many patients' activities. "Compared to the stronger-add multifocals, the lower adds give patients a lot more intermediate vision," he says. "Our world has kind of changed. There are a lot more things today that we use our intermediate vision for than we used to, especially when you consider tablet, desktop and laptop computers, which are even being used more frequently by our cataract-age patients. Patients are willing to trade a little fine print reading ability for better intermediate vision. Also, a low- or mid-add doesn't just improve their functional vision, it also gives a more continuous range of vision."

Jeffersonville, Ind., ophthalmologist Asim Piracha says this smoother transition between intermediate and far vision in the low add powers is a result of pushing the focal point out a little farther. "I think of the mid- and low-add multifocal IOLs as kind



Milan's Francesco Carones performed a study comparing the results of bilateral implantation of the low-add ReSTOR 2.5 with a blended approach in which one eye gets the 2.5 and the other gets the 3.0. He says that though there may be more night-vision issues with the blended approach, it provides better near vision, as shown in the graph.

of progressive lenses vs. the high-adds, which are more like bifocals," he says. "With the high-add, you get near and you get far, and nothing else. And it's a really close near, so the intermediate to far-intermediate vision is just gone. This is why the patients with +4 D multifocals will need computer glasses. So the near vision is great, but the overall vision isn't very functional for many patients with a high-add lens. The low-add patients get intermediate to near vision, and they can see beyond arm's length, so it's good for phones, iPads, computers, laptops, the dinner table, car dashboards, and the like. It's a range of vision, while before, with a high-add, it was more like a bifocal, where you'd have near and then it would just drop off, and then you'd have distance vision.

"The other thing is, there's more room for error with the low-add lens," Dr. Piracha adds. "So if a low-add patient is  $\pm 0.5$  D postop, especially if it's -0.5 D, he's pretty happy because he'll have good distance vision, maybe 20/30, and still have good near. Because of this, I've

been trying to target about -0.25 D on these low adds, so if I'm off I'll be off a bit on the minus side, and they'll still be happy with their distance vision. This is different from the high-add lenses, such as the +4 D, where if the patient isn't perfectly plano he's unhappy."

Dr. Chang says the idea of needing glasses to read some fine print or perform near tasks seems to sit better with patients than having a sudden drop in vision between near and far. "I'll counsel the low-add patients that they'll still need glasses for really small print, and the FDA data shows that," he explains. "For them, it kind of makes sense to need reading glasses occasionally for small print, but to have a drop-off in their vision at the intermediate distance, as is the case with the high-add lenses, doesn't make as much sense, and is a little bit harder to deal with."

In terms of binocular uncorrected visual results, in the Food and Drug Administration study of the AcrySof IQ ReSTOR 2.5 D lens, patients saw an average of 0.01 logMAR at distance (around 20/20+), 0.25 at inter-

**Comparison of the ReSTOR 3.0 and the ReSTOR 2.5**

	ReSTOR 3.0	ReSTOR 2.5
<b>Energy @ 3mm at IOL Plane</b> (Starting Phase) Central Zone	<b>Distance: 59.0 percent</b> <b>Near: 25.5 percent</b> (0.521 waves) Diffractive	<b>Distance: 69.4 percent</b> <b>Near: 18.0 percent</b> (0.503 waves) Refractive
<b>Add Power</b> (Number of Zones) Apodized diffractive zone	<b>+3.0 D</b> (nine rings) 3.6 mm (diam.)	<b>+2.5 D</b> (seven rings) 3.4 mm (diam.)
<b>Asphericity</b>	-0.1 μm (center diffractive)	-0.2 μm (center refractive)

mediate (between 20/30 and 20/40) and 0.34 at near (between 20/40 and 20/50).<sup>1</sup> In the FDA study of the Tecnis 2.75-D (ZKB00) and 3.25-D (ZLB00) multifocals, 93 percent of the 2.75-D eyes and 96 percent of the 3.25-D eyes achieved 20/40 or better uncorrected distance vision monocularly. In terms of binocular uncorrected near acuity (40 cm), 95 percent of the 2.75-D eyes and 99 percent of the 3.25-D eyes saw 20/40 or better at six months.<sup>2</sup> When looking at the lenses' focal points, in addition to having sharp vision in the distance, on the defocus curve the 2.75-D lens peaked at 50 cm (intermediate distance) and the 3.25-D lens peaked at a closer 40 cm.

• **Diminished halos and night-vision complaints.** In some sense, this benefit of the low- and mid-add lenses could be a bigger boon to patients than enhanced intermediate vision, since it makes the lenses more tolerable for the patient and less problematic for surgeons to manage postop.

Surgeons have noticed that patients complain less about night-vision issues, glare and halos with lower-add multifocal lenses, and the data bears this out. In the FDA study of the Tecnis 2.75 D for example, the lens had fewer night-vision complaints than

the 3.25-D. Interestingly, it also had fewer night-vision complaints than the Tecnis monofocal control lens: 8.5 percent of 2.75-D patients reported moderate difficulty seeing at night vs. 9.7 percent with the monofocal, and only 0.7 percent reported severe difficulty vs. 4.1 percent with the monofocal IOL.<sup>2</sup> Though the ReSTOR 2.5-D trial didn't look at night-vision problems, the lens did post a slightly lower percentage of moderate and severe glare problems than the 4 D.<sup>1,3</sup>

Surgeons say the improvement in visual complaints is a result of both design elements, and the lower power add resulting in a smaller diffractive effect (i.e., fewer diffractive rings on the IOL), which translates into fewer visual complaints. "In the ReSTOR lens in particular, the central element has fewer rings," explains Bret Fisher, MD, of Panama City, Fla. "And the overall diffractive region of the lens is smaller compared to the 3-D add. There's also a new central refractive zone, as well as a larger peripheral refractive zone, both used for distance vision. The combination of fewer rings and the presence of these refractive zones really acts to minimize the dysphotopsias patients have at night."

Dr. Chang says that, on the 2.75-D

Tecnis, the halos are simply smaller than on higher-add versions. "Basically, the halo that the patient sees is the energy directed toward the near focal point," he explains. "So, when you're looking at a distant point source of light, it's out of focus and is instead focused on the retina as a halo. So, the higher your add in the lens, the bigger your halo. In other words, the 4-D Tecnis has a certain size halo, the 3.25-D has a smaller halo and the 2.75-D has an even smaller halo. In fact, in the past, when patients with higher-add multifocals in my practice would complain about halos, it almost always was because of the halo's size rather than its brightness. Specifically, they'd complain that the halo was too large, and that it was blocking their view of cars coming toward them at night. So, the low-add multifocals make these halos smaller. If you look at the night-vision complaint statistics on the Tecnis package insert, the halo complaints get progressively smaller as the add power decreases. There was even less difficulty at night with the low-add multifocal than with the monofocal control in the FDA approval data. That's surprising. By way of explanation, I think that, for patients, the advantage of having some add power that allows them to see their dashboard at night outweighs the disadvantage that halos produce. In fact, if you look at the halo data as an isolated complaint with the 2.75-D multifocal, it was higher than with the monofocal—but patient satisfaction was higher and night-vision complaints were lower. I think if you look at the big picture, people like the low add.

"I'd prefer to induce fewer night-vision symptoms in patients and have near vision that wasn't quite as sharp, because you can use reading glasses for the up-close things if you really want to see them," Dr. Chang continues. "But, you can't magi-

For allergic conjunctivitis<sup>1</sup>

# THE POWER TO CALM THE ITCH



**BEPREVE® — FIRST-LINE, YEAR-ROUND,  
WITH BROAD-SPECTRUM ALLERGEN COVERAGE**



Scan this QR code or visit [beprevecoupon.com](http://beprevecoupon.com) to

- Order samples
- Learn about the automatic co-pay program
- Help your patients find participating pharmacies

## INDICATION AND USAGE

BEPREVE® (bepotastine besilate ophthalmic solution) 1.5% is a histamine H<sub>1</sub> receptor antagonist indicated for the treatment of itching associated with signs and symptoms of allergic conjunctivitis.

## IMPORTANT RISK INFORMATION

BEPREVE® is contraindicated in patients with a history of hypersensitivity reactions to bepotastine or any of the other ingredients. BEPREVE® is for topical ophthalmic use only. To minimize risk of contamination, do not touch the dropper tip to any surface. Keep the bottle closed when not in use. BEPREVE® should not be used to treat contact lens-related irritation. Remove contact lenses prior to instillation of BEPREVE®.

The most common adverse reaction occurring in approximately 25% of patients was a mild taste following instillation. Other adverse reactions occurring in 2%-5% of patients were eye irritation, headache, and nasopharyngitis.

Please see the accompanying prescribing information for BEPREVE® on the following page.

Reference: 1. BEPREVE [package insert]. Tampa, FL: Bausch + Lomb, Inc; 2012.

## BAUSCH + LOMB

For product-related questions and concerns, call 1-800-323-0000 or visit [www.bepreve.com](http://www.bepreve.com).

®/TM are trademarks of Bausch & Lomb Incorporated or its affiliates.

©2014 Bausch & Lomb Incorporated. US/BEP/12/0026(1) 1/14

Made by the trusted eye-care  
specialists at **BAUSCH + LOMB**

**BEPREVE®**  
(bepotastine besilate  
ophthalmic solution) 1.5%

## BEPREVE® (bepotastine besilate ophthalmic solution) 1.5%

### HIGHLIGHTS OF PRESCRIBING INFORMATION

These highlights do not include all the information needed to use BEPREVE® (bepotastine besilate ophthalmic solution) 1.5% safely and effectively. See full prescribing information for BEPREVE®.

**BEPREVE® (bepotastine besilate ophthalmic solution) 1.5%**

Initial U.S. Approval: 2009

-----RECENT MAJOR CHANGES-----  
Contraindications (4) 06/2012

-----INDICATIONS AND USAGE-----  
BEPREVE® is a histamine H1 receptor antagonist indicated for the treatment of itching associated with allergic conjunctivitis. (1)

-----DOSAGE AND ADMINISTRATION-----  
Instill one drop into the affected eye(s) twice a day (BID). (2)

-----DOSAGE FORMS AND STRENGTHS-----  
Solution containing bepotastine besilate, 1.5%. (3)

-----CONTRAINDICATIONS-----  
Hypersensitivity to any component of this product. (4)

### FULL PRESCRIBING INFORMATION: CONTENTS\*

- 1 INDICATIONS AND USAGE
- 2 DOSAGE AND ADMINISTRATION
- 3 DOSAGE FORMS AND STRENGTHS
- 4 CONTRAINDICATIONS
- 5 WARNINGS AND PRECAUTIONS
  - 5.1 Contamination of Tip and Solution
  - 5.2 Contact Lens Use
  - 5.3 Topical Ophthalmic Use Only
- 6 ADVERSE REACTIONS
  - 6.1 Clinical Trial Experience
  - 6.2 Post-Marketing Experience
- 8 USE IN SPECIFIC POPULATIONS
  - 8.1 Pregnancy
  - 8.3 Nursing Mothers
  - 8.4 Pediatric Use
  - 8.5 Geriatric Use

### FULL PRESCRIBING INFORMATION

#### 1 INDICATIONS AND USAGE

BEPREVE® (bepotastine besilate ophthalmic solution) 1.5% is a histamine H<sub>1</sub> receptor antagonist indicated for the treatment of itching associated with signs and symptoms of allergic conjunctivitis.

#### 2 DOSAGE AND ADMINISTRATION

Instill one drop of BEPREVE into the affected eye(s) twice a day (BID).

#### 3 DOSAGE FORMS AND STRENGTHS

Topical ophthalmic solution containing bepotastine besilate 1.5%.

#### 4 CONTRAINDICATIONS

Bepreave is contraindicated in patients with a history of hypersensitivity reactions to bepotastine or any of the other ingredients [see *Adverse Reactions* (6.2)].

#### 5 WARNINGS AND PRECAUTIONS

##### 5.1 Contamination of Tip and Solution

To minimize contaminating the dropper tip and solution, care should be taken not to touch the eyelids or surrounding areas with the dropper tip of the bottle. Keep bottle tightly closed when not in use.

##### 5.2 Contact Lens Use

Patients should be advised not to wear a contact lens if their eye is red. BEPREVE should not be used to treat contact lens-related irritation.

BEPREVE should not be instilled while wearing contact lenses. Remove contact lenses prior to instillation of BEPREVE. The preservative in BEPREVE, benzalkonium chloride, may be absorbed by soft contact lenses. Lenses may be reinserted after 10 minutes following administration of BEPREVE.

##### 5.3 Topical Ophthalmic Use Only

BEPREVE is for topical ophthalmic use only.

#### 6 ADVERSE REACTIONS

##### 6.1 Clinical Trials Experience

Because clinical trials are conducted under widely varying conditions, adverse reaction rates observed in the clinical trials of a drug cannot be directly compared to rates in the clinical trials of another drug and may not reflect the rates observed in clinical practice.

#### -----WARNINGS AND PRECAUTIONS-----

- To minimize the risk of contamination, do not touch dropper tip to any surface. Keep bottle tightly closed when not in use. (5.1)
- BEPREVE should not be used to treat contact lens-related irritation. (5.2)
- Remove contact lenses prior to instillation of BEPREVE. (5.2)

#### -----ADVERSE REACTIONS-----

The most common adverse reaction occurring in approximately 25% of patients was a mild taste following instillation. Other adverse reactions which occurred in 2-5% of subjects were eye irritation, headache, and nasopharyngitis. (6)

To report SUSPECTED ADVERSE REACTIONS, contact Bausch & Lomb Incorporated, at 1-800-323-0000, or FDA at 1-800-FDA-1088 or [www.fda.gov/medwatch](http://www.fda.gov/medwatch). See 17 for PATIENT COUNSELING INFORMATION

Revised: 10/2012

#### 11 DESCRIPTION

#### 12 CLINICAL PHARMACOLOGY

- 12.1 Mechanism of Action
- 12.3 Pharmacokinetics

#### 13 NONCLINICAL TOXICOLOGY

- 13.1 Carcinogenesis, Mutagenesis and Impairment of Fertility

#### 14 CLINICAL STUDIES

#### 16 HOW SUPPLIED/STORAGE AND HANDLING

#### 17 PATIENT COUNSELING INFORMATION

- 17.1 Topical Ophthalmic Use Only
- 17.2 Sterility of Dropper Tip
- 17.3 Concomitant Use of Contact Lenses

\*Sections or subsections omitted from the full prescribing information are not listed

The most common reported adverse reaction occurring in approximately 25% of subjects was a mild taste following instillation. Other adverse reactions occurring in 2-5% of subjects were eye irritation, headache, and nasopharyngitis.

#### 6.2 Post Marketing Experience

Hypersensitivity reactions have been reported rarely during the post-marketing use of BEPREVE. Because these reactions are reported voluntarily from a population of unknown size, it is not always possible to reliably estimate their frequency or establish a causal relationship to drug exposure. The hypersensitivity reactions include itching, body rash, and swelling of lips, tongue and/or throat.

#### 8 USE IN SPECIFIC POPULATIONS

##### 8.1 Pregnancy

**Pregnancy Category C:** Teratogenicity studies have been performed in animals. Bepotastine besilate was not found to be teratogenic in rats during organogenesis and fetal development at oral doses up to 200 mg/kg/day (representing a systemic concentration approximately 3,300 times that anticipated for topical ocular use in humans), but did show some potential for causing skeletal abnormalities at 1,000 mg/kg/day. There were no teratogenic effects seen in rabbits at oral doses up to 500 mg/kg/day given during organogenesis and fetal development (>13,000 times the dose in humans on a mg/kg basis). Evidence of infertility was seen in rats given oral bepotastine besilate 1,000 mg/kg/day; however, no evidence of infertility was observed in rats given 200 mg/kg/day (approximately 3,300 times the topical ocular use in humans). The concentration of radio-labeled bepotastine besilate was similar in fetal liver and maternal blood plasma following a single 3 mg/kg oral dose. The concentration in other fetal tissues was one-third to one-tenth the concentration in maternal blood plasma.

An increase in stillbirths and decreased growth and development were observed in pups born from rats given oral doses of 1,000 mg/kg/day during perinatal and lactation periods. There were no observed effects in rats treated with 100 mg/kg/day.

There are no adequate and well-controlled studies of bepotastine besilate in pregnant

women. Because animal reproduction studies are not always predictive of human response, BEPREVE® (bepotastine besilate ophthalmic solution) 1.5% should be used during pregnancy only if the potential benefit justifies the potential risk to the fetus.

#### 8.3 Nursing Mothers

Following a single 3 mg/kg oral dose of radiolabeled bepotastine besilate to nursing rats 11 days after delivery, the maximum concentration of radioactivity in milk was 0.40 mcg-eg/mL 1 hour after administration; at 48 hours after administration the concentration was below detection limits. The milk concentration was higher than the maternal blood plasma concentration at each time of measurement.

It is not known if bepotastine besilate is excreted in human milk. Caution should be exercised when BEPREVE (bepotastine besilate ophthalmic solution) 1.5% is administered to a nursing woman.

#### 8.4 Pediatric Use

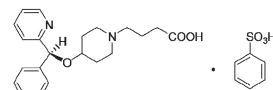
Safety and efficacy of BEPREVE (bepotastine besilate ophthalmic solution) 1.5% have not been established in pediatric patients under 2 years of age. Efficacy in pediatric patients under 10 years of age was extrapolated from clinical trials conducted in pediatric patients greater than 10 years of age and from adults.

#### 8.5 Geriatric Use

No overall difference in safety or effectiveness has been observed between elderly and younger patients.

#### 11 DESCRIPTION

BEPREVE (bepotastine besilate ophthalmic solution) 1.5% is a sterile, topically administered drug for ophthalmic use. Each mL of BEPREVE contains 15 mg bepotastine besilate. Bepotastine besilate is designated chemically as (+) -4-[(S)-p-chloro-alpha -2-pyridylbenzyl]oxy]-1-piperidine butyric acid monobenzenesulfonate. The chemical structure for bepotastine besilate is:



Bepotastine besilate is a white or pale yellowish crystalline powder. The molecular weight of bepotastine besilate is 547.06 daltons. BEPREVE® ophthalmic solution is supplied as a sterile, aqueous 1.5% solution, with a pH of 6.8. The osmolality of BEPREVE (bepotastine besilate ophthalmic solution) 1.5% is approximately 290 mOsm/kg.

**Each mL of BEPREVE® (bepotastine besilate ophthalmic solution) 1.5% contains:**

**Active:** Bepotastine besilate 15 mg (equivalent to 10.7 mg bepotastine)

**Preservative:** benzalkonium chloride 0.005%

**Inactives:** monobasic sodium phosphate dihydrate, sodium chloride, sodium hydroxide to adjust pH, and water for injection, USP.

#### 12 CLINICAL PHARMACOLOGY

##### 12.1 Mechanism of Action

Bepotastine is a topically active, direct H<sub>1</sub>-receptor antagonist and an inhibitor of the release of histamine from mast cells.

##### 12.3 Pharmacokinetics

**Absorption:** The extent of systemic exposure to bepotastine following topical ophthalmic administration of bepotastine besilate 1% and 1.5% ophthalmic solutions was evaluated in 12 healthy adults. Following one drop of 1% or 1.5% bepotastine besilate ophthalmic solution to both eyes four times daily (QID) for seven days, bepotastine plasma concentrations peaked at approximately one to two hours post-instillation. Maximum plasma concentration for the 1% and 1.5% strengths were 5.1 ± 2.5 ng/mL and 7.3 ± 1.9 ng/mL, respectively. Plasma concentration at 24 hours post-instillation were below the quantifiable limit (2 ng/mL) in 11/12 subjects in the two dose groups.

**Distribution:** The extent of protein binding of bepotastine is approximately 55% and independent of bepotastine concentration.

**Metabolism:** *In vitro* metabolism studies with human liver microsomes demonstrated that bepotastine is minimally metabolized by CYP450 isozymes.

*In vitro* studies demonstrated that bepotastine besilate does not inhibit the metabolism of various

cytochrome P450 substrate via inhibition of CYP3A4, CYP2C9, and CYP2C19. The effect of bepotastine besilate on the metabolism of substrates of CYP1A2, CYP2C8, CYP2D6 was not studied. Bepotastine besilate has a low potential for drug interaction via inhibition of CYP3A4, CYP2C9, and CYP2C19.

**Excretion:** The main route of elimination of bepotastine besilate is urinary excretion (with approximately 75-90% excreted unchanged in urine).

#### 13 NONCLINICAL TOXICOLOGY

##### 13.1 Carcinogenesis, Mutagenesis and Impairment of Fertility

Long-term dietary studies in mice and rats were conducted to evaluate the carcinogenic potential of bepotastine besilate. Bepotastine besilate did not significantly induce neoplasms in mice receiving a nominal dose of up to 200 mg/kg/day for 21 months or rats receiving a nominal dose of up to 97 mg/kg/day for 24 months. These dose levels represent systemic exposures approximating 350 and 200 times that achieved with human topical ocular use. The no observable adverse effect levels for bepotastine besilate based on nominal dose levels in carcinogenicity tests were 18.7 to 19.9 mg/kg/day in mice and 9.6 to 9.8 mg/kg/day in rats (representing exposure margins of approximately 60 and 20 times the systemic exposure anticipated for topical ocular use in humans).

There was no evidence of genotoxicity in the Ames test, in CHO cells (chromosome aberrations), in mouse hepatocytes (unscheduled DNA synthesis), or in the mouse micronucleus test.

When oral bepotastine was administered to male and female rats at doses up to 1,000 mg/kg/day, there was a slight reduction in fertility index and surviving fetuses. Infertility was not seen in rats given 200 mg/kg/day oral bepotastine besilate (approximately 3,300 times the systemic concentration anticipated for topical ocular use in humans).

#### 14 CLINICAL STUDIES

Clinical efficacy was evaluated in 2 conjunctival allergen challenge (CAC) studies (237 patients). BEPREVE (bepotastine besilate ophthalmic solution) 1.5% was more effective than its vehicle for relieving ocular itching induced by an ocular allergen challenge, both at a CAC 15 minutes post-dosing and a CAC 8 hours post dosing of BEPREVE.

The safety of BEPREVE was evaluated in a randomized clinical study of 861 subjects over a period of 6 weeks.

#### 16 HOW SUPPLIED/STORAGE AND HANDLING

BEPREVE® (bepotastine besilate ophthalmic solution) 1.5% is supplied in a white low density polyethylene plastic squeeze bottle with a white controlled dropper tip and a white polypropylene cap in the following size:

- 5 mL (NDC 24208-629-02)
- 10 mL (NDC 24208-629-01)

#### STORAGE

Store at 15° – 25°C (59° – 77°F).

#### 17 PATIENT COUNSELING INFORMATION

##### 17.1 Topical Ophthalmic Use Only

For topical ophthalmic administration only.

##### 17.2 Sterility of Dropper Tip

Patients should be advised to not touch dropper tip to any surface, as this may contaminate the contents.

##### 17.3 Concomitant Use of Contact Lenses

Patients should be advised not to wear a contact lens if their eye is red. Patients should be advised that BEPREVE should not be used to treat contact lens-related irritation.

Patients should also be advised to remove contact lenses prior to instillation of BEPREVE. The preservative in BEPREVE, benzalkonium chloride, may be absorbed by soft contact lenses. Lenses may be reinserted after 10 minutes following administration of BEPREVE.

Manufactured by: Bausch & Lomb Incorporated  
Tampa, FL 33637  
Under license from:  
Senju Pharmaceutical Co., Ltd.  
Osaka, Japan 541-0046  
®/TM are trademarks of Bausch & Lomb Incorporated or its affiliates  
© 2012 Bausch & Lomb Incorporated.

cally make halos and night-vision complaints go away.”

## Patient Selection

Though the low-add multifocals can be useful for many patients, surgeons say you still have to do your due diligence ahead of time to choose the right lens—or maybe even blend two add powers—to get the best results.

Dr. Piracha makes sure to have a thorough conversation with the patient about his occupation and any hobbies. “I have implanted a few Tecnis 3.25-D lenses, but 95 percent are the 2.75 D,” he says. “The ones for whom I recommend the 3.25 are those who say they read all the time, or ‘I want to read in bed,’ or ‘I want to be able to read a book, but I’m not on the computer that much,’ or the patient who says he likes to hold things up close while doing fine needlework or woodworking. These are usually the older patients; the same patients who would have done fine with the 4 D will do even better with the 3.25 D. However, if they mostly use the intermediate distance, such as working on the computer, or if they’re a driver by trade and night vision is important to them, I’ll use the low-add lens. A lot of my patients like to shoot rifles, so what’s nice with the low-add lens is they can see both the target and the gun sight simultaneously. That’s something monovision can’t do. One of my patients owns his own shooting range, competes professionally and trains kids, and he’s thrilled with the low-add lens.” Some surgeons will also give patients questionnaires about their activities in order to select the right lens for them.

Dr. Chang likes to observe how the patient reads firsthand. “I’ll hand him a brochure or some other educational material for him to review and just look at where he holds it,” he says. “I watch where he automatically holds it, whether it’s because of his glasses, his

current prescription or whatever. I use that range as a guide for which lens I’m going to start with. So, if he holds the material up close, then I’ll offer him a 3.25 D or potentially even a 4 D. If he holds it farther out, I’ll go for the 2.75-D add.”

A good number of surgeons will try to get the best of both worlds and will implant a low-power multifocal lens in one eye and in the other eye implant a multifocal lens with a slightly higher power to try to cover a wider focal range. Milan’s Francesco Carones has blended low- and mid-add IOLs in 700 patients. In his cases, he usually blends a low-power 2.5-D ReSTOR with a 3-D ReSTOR, and he says it works well. “My staff and I dedicate a lot of time to trying to find the best solution for each individual patient,” Dr. Carones says. “We also use activity questionnaires that ask such questions as how much time they’re using spectacles for certain activities, and how many of those activities would they like to not have to use spectacles. I’ve found that about 70 percent of my patients answer in ways that would imply they’d do better with a blended approach. About 20 percent would do better with a 3-D lens implanted bilaterally, and 10 percent would prefer bilateral 2.5-D lenses.” He implants the low-add in the dominant eye when blending.

Dr. Carones studied the results of this blending approach in 40 patients, comparing the results to 20 patients who received bilateral 2.5-D ReSTORs. Postop, in the bilateral 2.5-D group, all patients were 20/20 uncorrected for distance, and all saw 20/20 or better uncorrected at intermediate (measured as 60 cm in the study). Only six patients (30 percent) had 20/20 at 40 cm, while all saw at least 20/50 at that range. In the blended group, Dr. Carones says you can see an expanded range of vision at near: All could see 20/20 at distance. Ninety-three percent saw 20/20 or better at intermedi-

ate, and 70 percent saw 20/20 or better at near, with everyone in the group seeing at least 20/32 at near.

In day-to-day practice, surgeons say this blending can often make sense for patients. “In the first eye, I usually implant the lowest add power,” says Dr. Lee. “I’ll then wait a little longer than usual for the patient to recover since it’s a multifocal. That way, the patient has time to get used to the multifocal. When he comes back for a postop visit, I’ll talk to him about the function of that first eye, asking such questions as, ‘Do you like it? Do you want the second eye to match it? Would you instead appreciate having some more reading-distance vision in the second eye?’” If he says he’d prefer more reading vision, I’ll go for the intermediate power for the second eye. For instance, if I’m using the Tecnis, I’d implant the 3.25-D add.”

Dr. Fisher says the low-add multifocals, such as the AcrySof ReSTOR he uses, can also work when paired with a monofocal IOL that the patient had implanted in the fellow eye years previously. “I’ve done several patients who have had a monofocal IOL in one eye now for years,” he says. “I’ve been able to offer them a lower-add multifocal for the other eye, knowing that they wouldn’t feel as if they were compromising on the distance vision compared to their monofocal lens, and that they were also picking up some intermediate vision. I think that highlights what a good ‘utility player’ these lenses are becoming.” **REVIEW**

*Drs. Fisher and Carones are consultants to Alcon. Drs. Chang and Piracha are consultants to Abbott Medical Optics. Drs. Grayson and Lee have no financial interest in any of the products mentioned.*

1. [http://www.accessdata.fda.gov/cdrh\\_docs/pdf4/P040020S050b.pdf](http://www.accessdata.fda.gov/cdrh_docs/pdf4/P040020S050b.pdf). Accessed 14 Dec 2015.

2. [http://www.accessdata.fda.gov/cdrh\\_docs/pdf/P980040S049b.pdf](http://www.accessdata.fda.gov/cdrh_docs/pdf/P980040S049b.pdf). Accessed 9 Dec 2015.

3. [http://www.accessdata.fda.gov/cdrh\\_docs/pdf4/P040020c.pdf](http://www.accessdata.fda.gov/cdrh_docs/pdf4/P040020c.pdf). Accessed 14 Dec 2015.

# Presbyopic IOL Adoption Slows

Walter Bethke, Managing Editor

Some surgeons say they may wait until better presbyopic options are available.

Presbyopic intraocular lenses have been beneficial for a lot of patients desiring some more near or intermediate vision and who don't mind the trade-offs of night-vision issues, glare and halos. These positive impressions are echoed by many surgeons on our e-mail survey. Looking ahead, however, it looks as though those survey respondents who currently don't use presbyopic IOLs won't be using them any time soon, and they say it may take a new approach or new technology before they dive in.

In addition to presbyopic lenses, surgeons responding to this month's intraocular lens survey also weighed in on topics such as their favorite lens material, their opinions on IOL features and how they deal with lens complications. This month, the e-mail survey was opened by 1,259 of 8,743 subscribers to Review's electronic mail

service (14.4 percent open rate) and, of those, 80 surgeons shared their responses. See how your opinions on IOLs compare with theirs.

## Presbyopic Opinions

Three quarters of the surgeons say they use presbyopic IOLs, and they're generally satisfied with the results they get with them.

On the survey, 27 percent say they're very satisfied with presbyopic lenses and 42 percent say they're satisfied. Twenty-four percent say they're somewhat satisfied with the technology and only 7 percent are unsatisfied. Forty percent of the surgeons say they use the ReSTOR most often, 40 percent use the Tecnis multifocal the most and 20 percent primarily use the Crystalens AO.

A cataract surgeon from Indiana says he's enjoying the benefits of the

## Surgeons Rank the Features of IOLs

Asphericity/neutral asphericity	4.1
Toric design	4.1
Multifocality	3.6
Edge design to decrease PCO	3.5
Pseudo-accommodative motion	3.0
Blue-light blocking	2.9

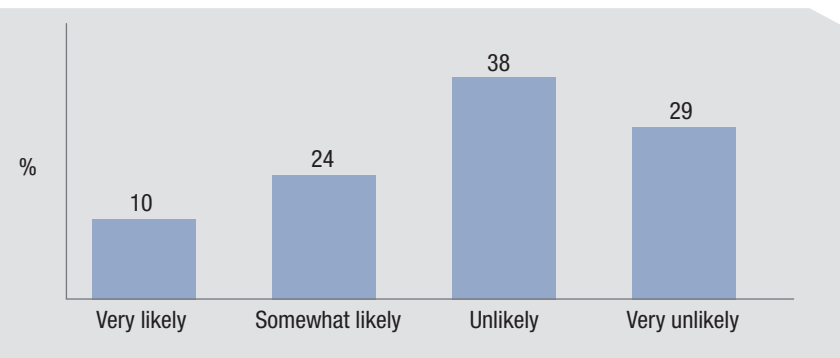
Surgeons on the survey ranked IOL features in terms of their usefulness using a numerical scale that ran from 1 (least useful) to 6 (most useful). The average scores are shown.

new 2.75-D multifocal Tecnis. “The aberration profile is much better with the lower-add multifocal,” he says. “It is substantially improved. However, any further improvements would be welcome, too.” Bruce Cohen, MD, of St. Louis also sees potential in the newer lenses. “The new Tecnis multifocals have been good thus far,” he says. “There is minimal glare and the intermediate add of the ZLB00 works well. I’ve had happy patients so far.” Dubuque, Iowa’s Juan Nieto, MD, feels the lenses have been a benefit to his practice. “I have had nice success with both the Alcon ReSTOR +3 and the Tecnis +4 multifocal,” he says. “I’ve recently started to use the Tecnis +2.75 multifocal, but I still haven’t made up my mind on that lens. I would love to have access to a toric multifocal.”

A surgeon from Tennessee says that, though he’s satisfied with his presbyopic IOL, things could be better. “Presbyopic IOLs are still a work in progress,” he says. “Nothing is very close to what we have naturally.” R. Wayne Bowman, MD, of Dallas feels similarly. “They are all a compromise,” says Dr. Bowman. “They have less-than-ideal side effect profiles and could be improved in every way.”

Though the surgeons who use the lenses are getting value from them, the results on the survey suggest that the respondents may be reaching a saturation point of sorts in which the bulk of the surgeons who were going to use presbyopic lenses have already started using them. Last year, 31 percent of surgeons said they were unlikely to begin using presbyopic lenses in the next two years, and 35 percent said they were very unlikely to begin using them in that time period. This trend continued this year, with 38 percent of the surgeons saying they’re unlikely to begin using the lenses and 29 percent declaring that they’re very unlikely to do so. The reasons they give center on issues such as night-vision problems and glare, as well as issues with some

### Likelihood of Using a Presbyopic IOL Within Two Years



patients’ postop near vision. “Multifocal vision quality is poor,” says Luther Fry, MD, of Garden City, Kan. “The Crystalens doesn’t accommodate. I’ll only use a presbyopic IOL if a truly accommodative lens becomes available. Meanwhile, I use mini-monovision for those wishing to limit their spectacle dependence.” A surgeon from Utah has had a similar experience. “The presbyopic IOLs that are presently available do not provide adequate visual quality,” he says. “And they have too many visual problems with aberrations, dysphotopsias and glare.”

### Lens Material and Design

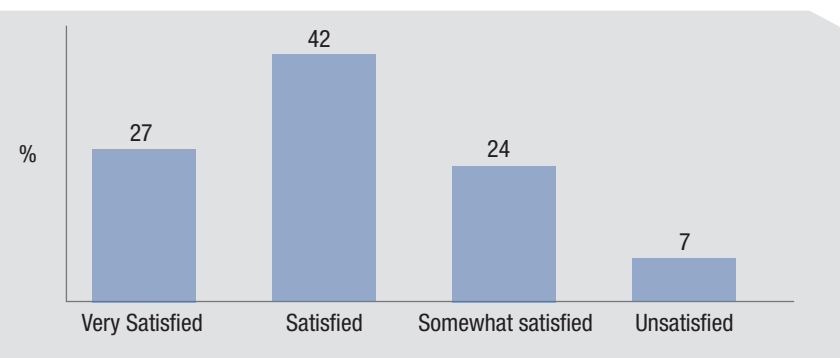
Surgeons also held forth on the various design elements in today’s IOLs, saying which ones have merit and which don’t have as much of an impact.

For monofocal IOLs, 52 percent of the surgeons say they most often use

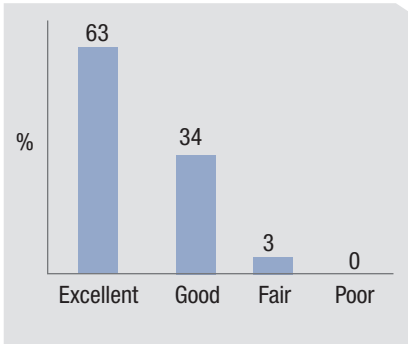the AcrySof IQ Aspheric lens, 30 percent use the Tecnis one-piece lens and 8 percent use the B + L enVista lens. The other options were chosen by less than 5 percent of respondents. Eighty-six percent think acrylic is the best material, and 7 percent like silicone.

The surgeons gave their opinions on specific lens features by ranking popular IOL design elements, such as asphericity and multifocality, on a scale from one to six, with six being the most important to them. (*The ranking results appear in the graph on p. 38.*) Toric design and asphericity/neutral asphericity were the most popular features on the survey, each with an average score of 4.1. “Asphericity gives excellent optics and improves night vision,” avers Dr. Cohen. Dr. Bowman’s top two mirror the survey’s: “Correction of astigmatism and optical quality are the two most important issues,” he says. A surgeon from Maryland feels

### Surgeon Satisfaction with Presbyopic IOLs



**Surgeons on Toric Results**



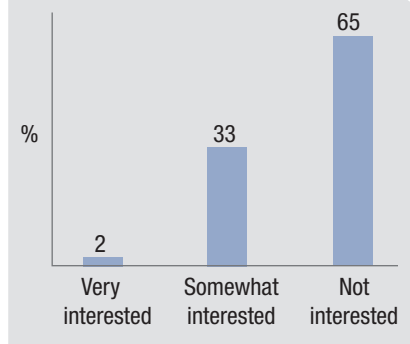
that special edge designs that decrease posterior capsular opacification can make a big difference postop. “The rate of posterior capsular fibrosis is important,” he says. “It can change the patient’s refractive error in the first few months postop when I would prefer not to perform a YAG capsulotomy. Centration and stability in the bag are very important to promote less shift-

ing.” On the low end of the scale were blue-light blocking (2.9) and pseudo-accommodative motion (3.0).

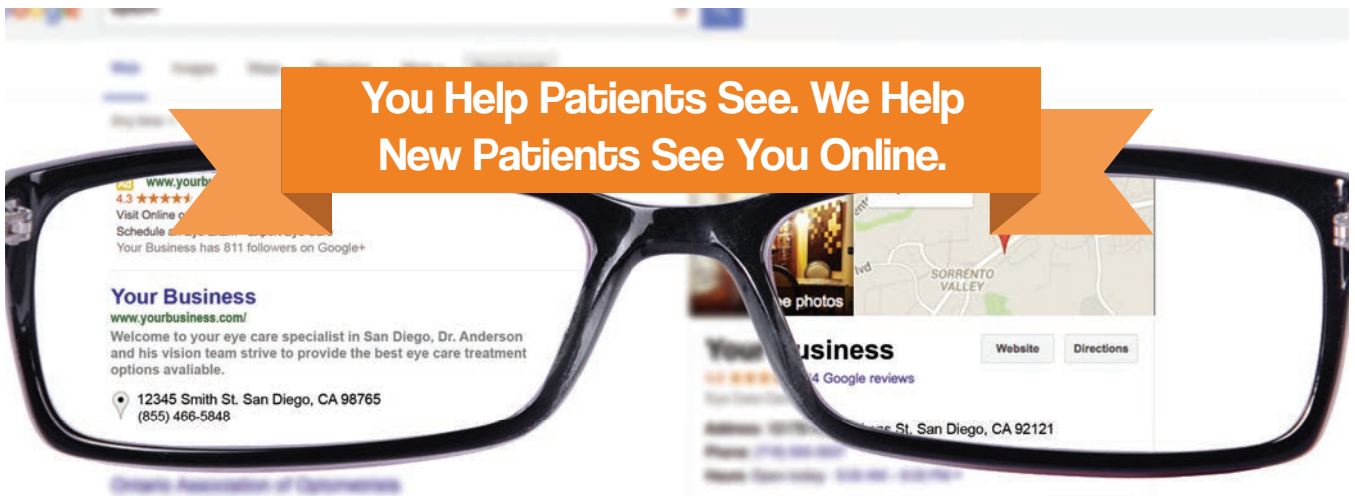
As surgeons’ rankings show, toric IOLs are very popular; 73 percent of the respondents say they use them and most are happy with their outcomes. Sixty-three percent of the surgeons say their toric IOL results are excellent and 34 percent rate them as good. Only 3 percent of the surgeons call their outcomes fair. “I get excellent visual results with toric IOLs, and very happy patients,” says a surgeon from Utah. “These IOLs provide significant improvements in vision with no visual compromises.” Dr. Nieto also values torics. “I’ve had excellent results with the Alcon toric IOLs,” he says. “It’s a wonderful lens option.” A doctor from Texas says he likes the ability to “adjust the Tecnis toric IOL forward and backward easily.”

Toric IOLs still aren’t a no-brainer, though, say surgeons, and they can

**Interest in Phakic IOLs**



come back to bite you if your preop biometry and axis marking aren’t spot-on. “Accurate placement at realistic levels of efficiency are required for high performance and satisfaction,” says a doctor from Indiana. “Intraoperative guidance systems help significantly.” Dr. Cohen says nailing that axis is crucial for success. “It’s sometimes difficult to determine the optical axis,”



Help give the gift of sight this holiday season!

Schedule your free website evaluation by January 31, 2016, and iMatrix will make a donation to Unite for Sight, a program that provides ophthalmic equipment and support to eye clinics in underserved communities around the world. Use Promo Code: **JOBAN16**

**imatrix**<sup>TM</sup>  
The Leader in Vision Care Website Services

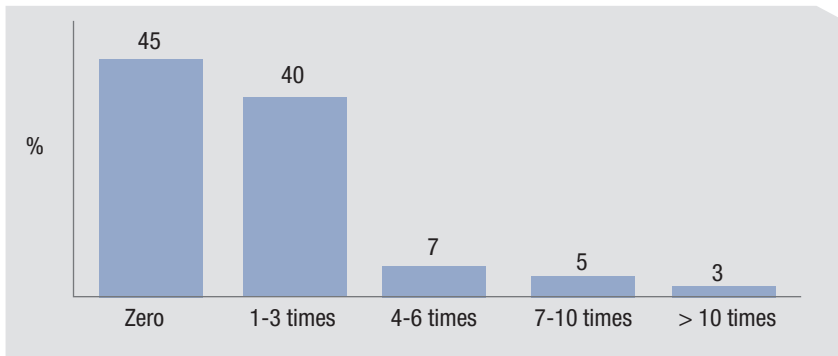
1.877.484.6212

[imatrix.com/job-jan16.html](http://imatrix.com/job-jan16.html)





## Surgeons' Annual Frequency of Suturing an IOL



he says. “Then, it can be difficult to attain the optimal astigmatic axis.” A surgeon from Texas concurs, saying, “Stability of the lens can sometimes be an issue, and marking the cornea is also variable.”

### Lens Complications

Surgeons also weighed in on what

they do when things don't go as planned with their lens implantations.

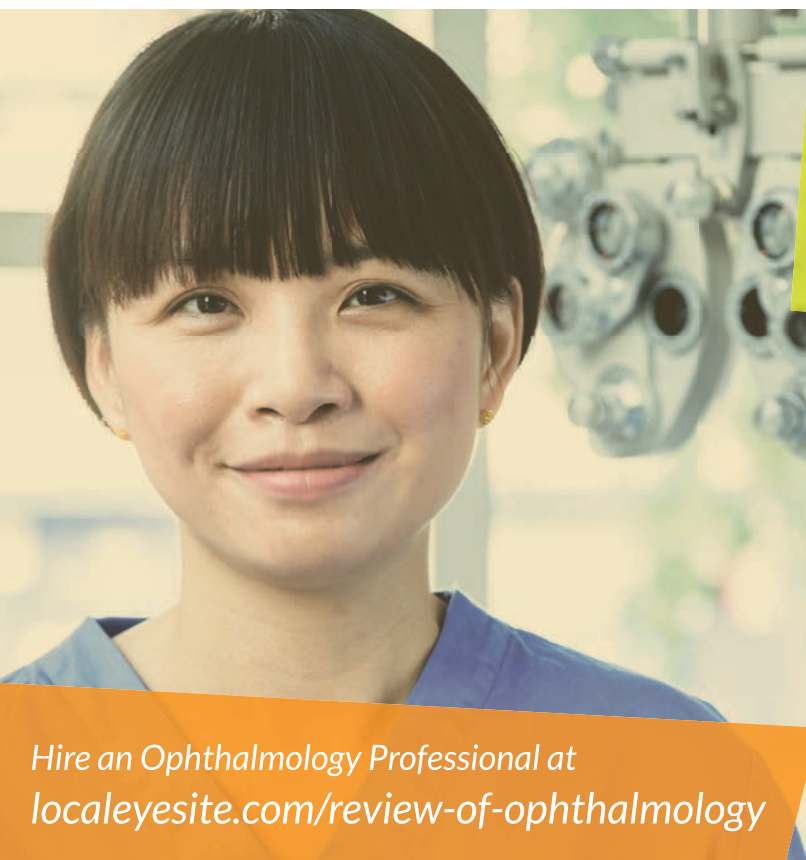When asked about instances when they need to suture-fixate an IOL, 45 percent say they haven't had to suture a lens in the past year, 40 percent had to do it one to three times, 7 percent sutured a lens four to six times, 5 percent did it seven to 10 times and 3 percent of the surgeons had to suture

a lens more than 10 times. Surgeons give various reasons for having to do this, chief among them being capsular instability. “I've done it for either a dislocated IOL postop or no capsular support during initial surgery,” says a Utah surgeon. “I suture it either to the iris or the ciliary sulcus.”

Forty-four percent of surgeons had to explant at least one lens in the past year. Here are some of the most common reasons they gave for the explantation:

- wrong power;
- decentration;
- late dislocation of lens in the bag;
- poor tolerance of a multifocal IOL; and
- uveitis/glaucoma/hyphema syndrome.

One surgeon from Washington state no doubt speaks for many of his colleagues when he says that his main reason for suturing an IOL is, “So I can sleep better.” [REVIEW](#)



## Hire the Best in Ophthalmology

“Local Eye Site makes the hiring process that much more efficient when you find candidates with the right qualifications and experience.”

Hugh Johnston  
Fischer Eye Care  
Wellesley, MA

Hire an Ophthalmology Professional at  
[localeyesite.com/review-of-ophthalmology](http://localeyesite.com/review-of-ophthalmology)

# Can ‘Super Formula’ Increase Accuracy?

John Ladas, MD, PhD, Silver Spring, MD, and Uday Devgan, MD, Los Angeles

Building on earlier IOL power calculation formulas, this new approach adds a 3-D component.

We first met at the beginning of our ophthalmology residency almost 20 years ago. The initial part of our residency involved just trying to keep our heads above water as we tried to manage a wide variety of patients. At some point, most people gravitate to things at which they are proficient and give the most satisfaction. For us, it was the elegant nature of cataract surgery. While we have continued to try and master this over the past 20 years, we

are always trying to improve. For both of us and I’m sure many of you, the focus of our improvement, over time, became the refractive outcomes we were trying to achieve.

In our residency, we were first taught about the SRK formula for selecting intraocular lens power. It was the only one written in the American Academy of Ophthalmology monograph on cataracts. The formula is:  $IOL\ Power = A\ constant - 0.9K - 2.5\ AL$ . We were also taught that there

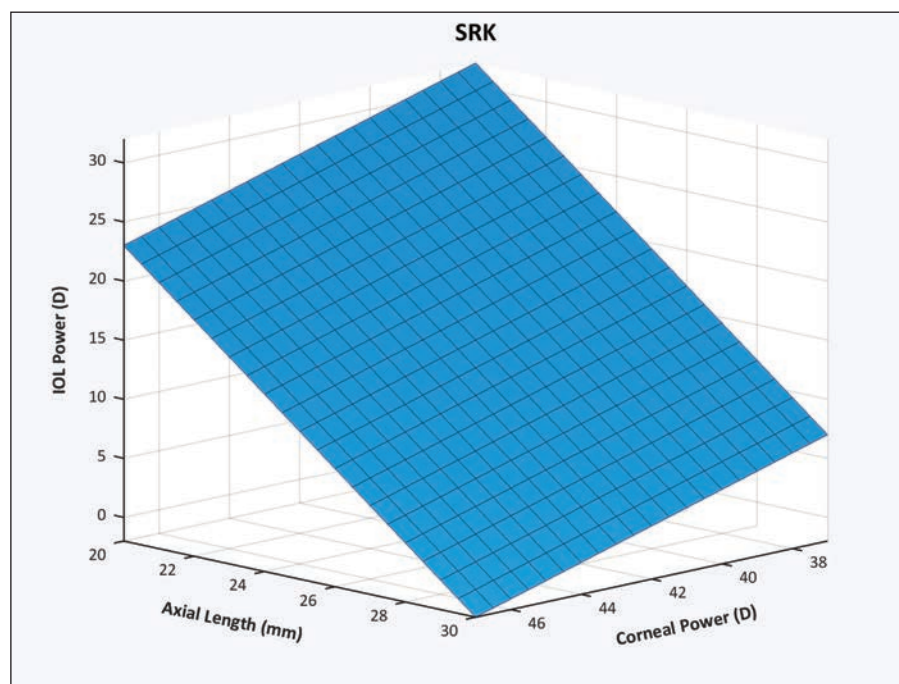


Figure 1. The original SRK formula is plotted as a plane in three dimensions.

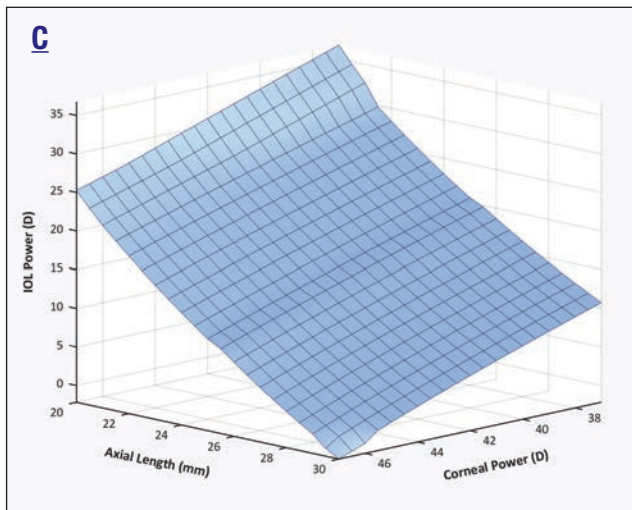
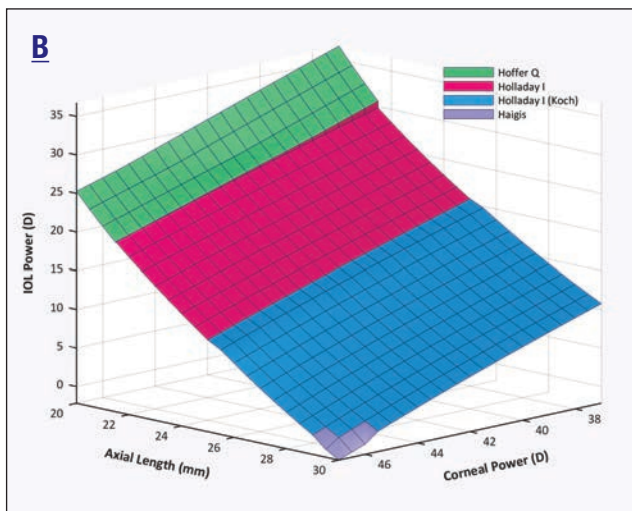
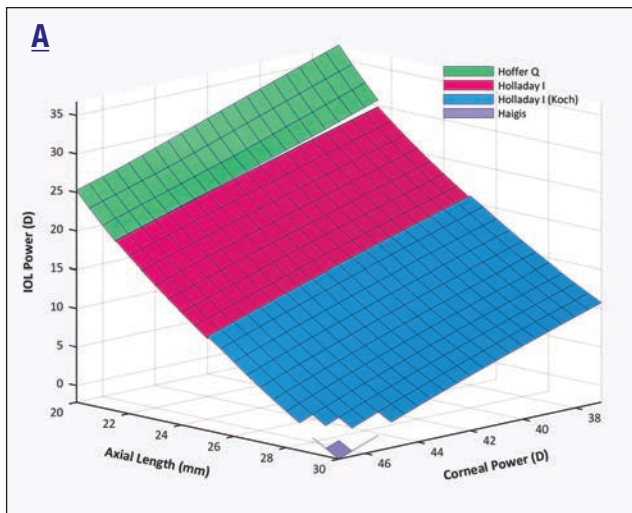


Figure 2. The initial Ladas Super Surface was constructed using the strengths of four formulas: the Hoffer Q, the Holladay 1, the Holladay 1 with the Wang-Koch axial length adjustment, and the Haigis. Figure 2a. Sections of each formula based on axial length. Figure 2b. Formulas are connected. Figure 2c. Formulas are amalgamated into one Super Surface.

end of our formal training and we went on to our careers. Throughout the next 20 years we, as many do, attempted to keep up with these and new formulas.

Over the next 10 years we came to a few conclusions. First, there was no one perfect formula for all situations. Second, although the formulas were similar in some ways, they were very different in subtle ways that could not be explained in simple terms. Also, it was very difficult to compare formulas in an objective way. And finally, optimization of any formula was critical to its accuracy.

## Two Variables

We were always very interested in the formulas and what made each one better for specific subsets of eyes (short or long axial lengths, shallow anterior chambers, flat or steep k's, etc.). They all had unique ways to determine the effective lens position, but they were all very different.

At some point, we realized that all of these formulas were essentially two-variable equations with corneal power and axial length on the x and y axis, respectively. The newer-generation formulas just added theoretical constants to make the formula more complex or adjusted it for other variables. We also started thinking about different ways to think about the math involved in these computations.

James Gleck, the author of *Chaos*, the 1980s book on entropy, stated very eloquently what we started to believe: "... graphic images are the key. It's masochism for a mathematician to do without pictures ... [Otherwise] how can they see the relationship between that motion and this? How can they develop intuition?"

So, with that mind-set we thought that, perhaps, one could go about developing a better formula than the many that existed. The first step was to graphically characterize an IOL formula. In its most simplistic form, the methodology can be demonstrated with the SRK formula in three dimensions.

This was the starting point: no longer thinking of these mathematical solutions as just numbers but as three-dimensional solutions to complex problems.

As we stated before, it is accepted that certain formulas work better in specific situations. This was a recurring conclusion that is hard to dispute. Many ophthalmologists have published tables of multiple formula choices that one could use in certain situations.

were more sophisticated formulas such as the Hoffer Q and the Holladay formulas. They existed and were good, but perhaps too sophisticated to comprehend. That was the

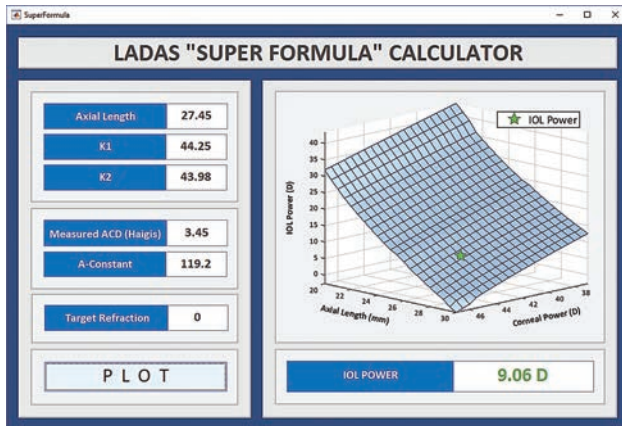


Figure 3. For the IOL calculation in an eye with axial myopia, the Ladas Super Formula localizes to the portion of the Ladas Super Surface that automatically applies the Wang-Koch axial length modification and gives us an IOL power which proved to be spot-on with a postop refraction of plano. Calculated on-line at [iolcalc.com](http://iolcalc.com).

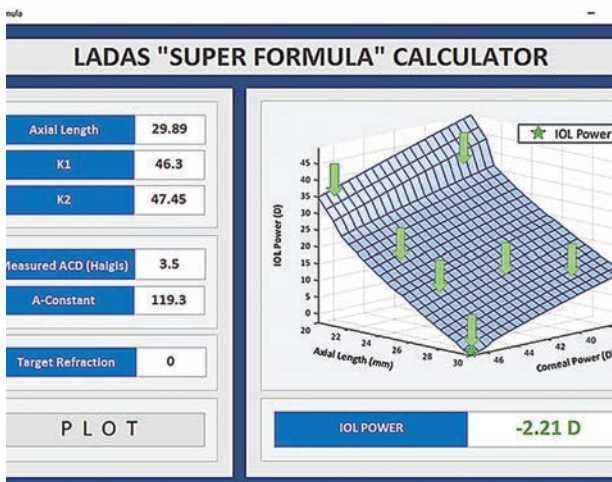


Figure 4. Each part of the graph, some of which are shown with the green arrows, will be optimized and further honed in order to produce more accurate results.

The pioneers of IOL calculation dealt with all these situations and described the dilemma in different ways throughout the years. For instance, the original SRK formula was updated with adjustment factors to shape it into the SRK II by altering the A-constant at different axial lengths. Dr. Ken Hoffer, as he advanced his formulas, placed parameters on the calculation of anterior chamber depth in his formula. Dr. Jack Holladay has described nine different eye anatomies to account for differences based on the axial length and the AC size, and added various additional input data to fine-tune his formula.

While these were great advances, it seems more likely that IOL calculations and the measurements that go into them are not a series of “if this, then that” statements, but rather a continuum.

## Super Formula

This is where the derivation of a “super surface” and “super formula” comes into play. As previously mentioned, the newer-generation formulas featured theoretical constants that added subtle curves to the surface. Our original article demonstrated them in 3D. The next thing we wanted to do was take the best portions of each of these surfaces/formulas. We amalgamated what we decided was the best of all formulas, with adjustments for our initial iteration, into a super surface or super formula. As we will explain, this is merely a starting point and not the final product. This process is shown in Figure 2.

The utility of using the “super formula” can be shown in this everyday example of a lens calculation, shown in Figure 3. From the available options, the formula that you would choose for this scenario would be limited, first, by your access to them.

Then you would probably start to run through your understanding and knowledge about this particular set of input data. There have been articles that have concluded that the SRK/T may be better in longer eyes, or perhaps the Haigis. The Holladay I or Holladay II may be suitable in this situation. This was usually when one starts to look at the recommended IOL for his patient with multiple formulas until he realizes that the answers are different.

Another thing: Did you even consider adding the Koch adjustment to the Holladay I and relying on that? Do you remember the adjustment calculation? Based on peer-reviewed literature, that is the formula/adjustment that is incorporated into the “super formula” and your calculation will be based on that current state-of-the-art data. An IOL power of 9 diopters, as can be seen in Figure 3, was localized to the correct region of the surface in this individual eye.

Hopefully, this scenario solved a clinical dilemma in this particular case, but the “super formula” as it stands works with all eyes. It factors in appropriate formulas, adjustments to these formulas and lens design to select an appropriate IOL power for any eye.

## Evolution of the Super Formula

If you conclude that this “super formula” is static and just an amalgamation of a few formulas, you’re mistaken, and you may be missing the point. The other conclusion that most would agree on is that optimization of a formula is the key to improving its accuracy. There are a few important points about optimization that are known to be critical. Thomas Olsen, the inventor of the Olsen formula, has emphasized these. First, optimization is formula-specific. Second, other variables such as ACD can be used to “optimize” a formula, such as was used in his paper on second eyes.<sup>2</sup>

The ability to optimize multiple formulas was not pos-



# Salt

## IT'S ENOUGH TO MAKE ANYBODY'S EYES FEEL DRY, GRITTY & UNCOMFORTABLE

A high salt concentration can disrupt the osmolarity balance within the tear film. Elevated tear film osmolarity (osmolarity imbalance or hyperosmolarity) is one of the primary causes of dry eye symptoms!


**TheraTears® Dry Eye Therapy with Osmo-Correction™** corrects osmolarity imbalance to restore comfort with a unique hypotonic and electrolyte balanced formula that replicates healthy tears.

**THERATEARS® DRY EYE THERAPY**  
WITH  
**OSMO-CORRECTION™**  
HYPOTONIC & ELECTROLYTE  
BALANCED



**HYPEROSMOLARITY**

Increased concentration of the tears leads to irritation and potential damage to the ocular surface.



**HEALTHY TEAR**

TheraTears® Dry Eye Therapy replicates the electrolyte balance of natural tears to restore comfort.



**DRY EYE THERAPY**  
Restores Eyes Natural Balance™

[theratears.com](http://theratears.com)



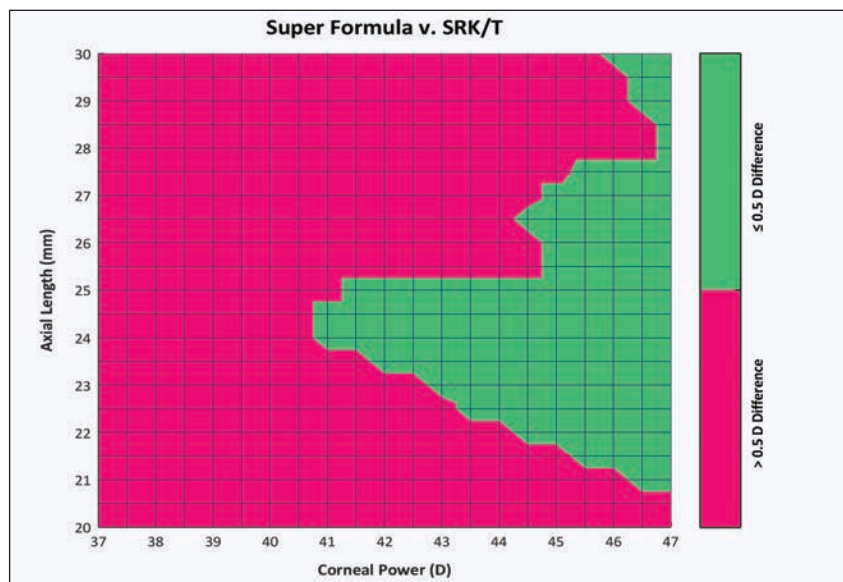


Figure 5. The intuitive Ladas-Siddiqui graph can compare two different formulas and show the areas where there is clinical agreement (green) and clinical dilemma (red). Further studies and data should be focused in these areas of clinical dilemma.

sible until now. The next step, which is currently under way and will continue, is evolution and enhancement of the super formula. Using our methodology, we can start to optimize each region of the surface. Thus, as is shown in Figure 4, we can go block-by-block and inch-by-inch on the surface and optimize it for a group of surgeons or individuals. We have recruited at least 10 major cataract and refractive groups to supply outcome data to us. With the help of Aazim Siddiqui, we have developed a program that analyzes outcome data and adjusts the surface. The Super Surface is dynamic and constantly evolving, with each adjustment helping to hone the IOL calculations further.

Another dilemma that we believe is solved by our methodology is this: Previously, anytime you optimized a formula or added a variable such as ACD, the entire “surface” was treated the same. This is problematic because the axial length and keratometry are intimately related to the calculation of the effective lens position and ultimate improvement of any formula. By collecting additional input data such as ACD, preop refraction, even gender,

etc., we can determine the relative importance of a variable and potentially incorporate it into the “super formula.” Now each “eye” or area of the surface can be adjusted more precisely.

### Comparing Formulas

Finally, using a comparative graph called the Ladas-Siddiqui graph (See Figure 5) we can compare multiple formulas and their results to determine where they differ. Rather than having to examine thousands of eyes to come to statistically significant conclusions on a better formula for a particular eye, we can target only those areas where there is a clinically significant difference. Thus, obtaining and analyzing the that data will save time and resources to improve the overall understanding and accuracy of formulas. Furthermore, future formulas and the effect of input parameters on the surface can be analyzed more precisely. For instance, we can target a specific region to examine the IOL calculations in a small subset of eyes. Some ophthalmologists have made the observation that ACD less

than 2.6 makes the calculations more difficult and highly variable. We can examine only those eyes and perhaps adjust the formula with a measured variable such as ACD, white-to-white, or just optimize for that group in that specific region of the surface.

The concept of a “super surface” is a novel method to represent IOL calculation formulas in three-dimensions, and it can be used to help determine the ideal lens power for an individual eye. Not only does the “super formula” solve a problem as it currently stands, but it also becomes the blueprint or framework to further advances in the field of lens calculations. As more data is collected, that information will be incorporated into the Ladas Super Surface, which will evolve and improve over time. For more information, visit [iolcalc.com](http://iolcalc.com). **REVIEW**

*Dr. Ladas and Dr. Devgan have an ownership interest in the Ladas Super Formula and Ladas Super Surface and associated methodologies and processes. Dr. Ladas is in private practice as surgeon/director at Maryland Eye Consultants and Surgeons, 2101 Medical Park Dr., Suite 101, Silver Spring, MD 20902. Tel 301-681-6600, [jladas@marylandeye.com](mailto:jladas@marylandeye.com). He is also an assistant professor of ophthalmology at Wilmer Eye Institute, Baltimore.*

*Dr. Devgan is in private practice at Devgan Eye Surgery, 11600 Wilshire Blvd, Suite 200, Los Angeles, CA 90025, 1 (800) 337-1969, [devgan@gmail.com](mailto:devgan@gmail.com), [www.DevganEye.com](http://www.DevganEye.com). He is also chief of ophthalmology at Olive View UCLA Medical Center and a clinical professor of ophthalmology at the Jules Stein Eye Institute, UCLA School of Medicine.*

1. Ladas J, Siddiqui A, Devgan U, Jun A. A 3-D “Super Surface” Combining Modern Intraocular Lens Formulas to Generate a “Super Formula” and Maximize Accuracy. *JAMA Ophthalmol*. Published online October 15, 2015. doi:10.1001/jamaophthalmol.2015.3832  
 2. Olsen T. Use of fellow eye data in the calculation of intraocular lens power for the second eye. *Ophthalmology* 2011;118(9):1710-5. doi: 10.1016/j.ophtha.2011.04.030. Epub 2011 Jul 2.

# Free Ophthalmology CME. From UPMC Physician Resources.



## Featured Courses:



**Transorbital Approaches:  
An Oculoplastic Perspective**  
S. Tonya Stefko, MD, reviews  
the orbital anatomy and  
reviews the transorbital and  
lateral orbital approaches.

**Ophthalmology Grand Rounds:**  
Joel Schuman, MD, FACS,  
presents a case of a patient  
with features of  
Cytomegalovirus Fuchs'  
Heterochromic Iridocyclitis.

**Retina Grand Rounds:**  
Ian Conner, MD, PhD, presents  
on secondary angle closure  
glaucoma and Joseph Martel,  
MD, discusses clinical utility of  
ultra-wide field retinal imaging.

To access CME, publications, and other resources, visit [UPMCPPhysicianResources.com/Ophthalmology](http://UPMCPPhysicianResources.com/Ophthalmology).

**UPMC** LIFE  
CHANGING  
MEDICINE



# Should You Try a New Glaucoma Surgery?

With new options available, surgeons have to decide whether it makes sense to incorporate them into their practices.

*Darrell WuDunn, MD, PhD, Indianapolis*

**T**reating glaucoma with surgery is not a perfect science. The operations we rely on—especially trabeculectomy and tube shunts—are good operations that have been around for 30 or 40 years, but they still have plenty of complications, including leakage and infections. And while cataract surgery outcomes have improved a lot over the past 20 or 30 years, glaucoma surgery outcomes have not.

I think most ophthalmologists, especially glaucoma specialists, aren't entirely satisfied with trabs and tubes. We still rely on them, in part because when glaucoma is severe, the risk/benefit ratio tilts in favor of doing the surgery, despite the potential complications. But that doesn't make them ideal, and it raises the question of what we can do for patients who only have a mild-to-moderate degree of severity—patients we don't want to put at high risk of complications with a trabeculectomy or tube. We need an in-between procedure, one that's safe and effective for patients with mild-to-moderate glaucoma. That need accounts for the current interest in the minimally invasive glaucoma

surgeries, or MIGS procedures.

Given that new procedures are now available, many ophthalmologists are wondering whether it makes sense to incorporate one of them into their practice. I'd like to offer some help answering that question.

## To Add or Not to Add?

To decide whether it's a good idea to add a new surgery to your glaucoma armamentarium, it helps to assess your practice needs, as well as your patient population, from both a practical and financial standpoint. Questions worth asking include:

- **Are you satisfied with your present surgical options?** I believe most surgeons are well aware of the shortcomings of traditional surgeries such as tubes and trabs. Nevertheless, if you do trabeculectomies and get a pressure of 10 mmHg every time, with no complications, you might not feel the need to have alternative options. Unfortunately, I don't think most of us fall into that category; we do have some problems and complications, and our outcomes don't always meet our expectations. For us, trying new

surgeries may be a sensible option.

- **Do these surgeries fit your patient demographics?** For most surgeons, tubes and trabs are not ideal for patients with mild glaucoma—patients who don't really need the low pressure that a trabeculectomy or tube might provide. Many of the new alternative surgeries don't produce very low intraocular pressures; but if you can lower the pressure somewhat, with fewer complications, that's a potentially useful trade-off for these patients.

Whether this makes sense for you may simply be an issue of how much mild glaucoma you see. The greater the percentage of your patients who have mild glaucoma but are on maximum medications and still progressing, the more likely it is that you'll help them by offering one of the MIGS procedures. Although I've tried many of these new procedures myself, my own practice is tertiary care, so I tend to get referrals from outside physicians who don't want to tackle the more complex, severe cases. But if you have a lot of patients in the mild-to-moderate group these new MIGS procedures might be very well-suited



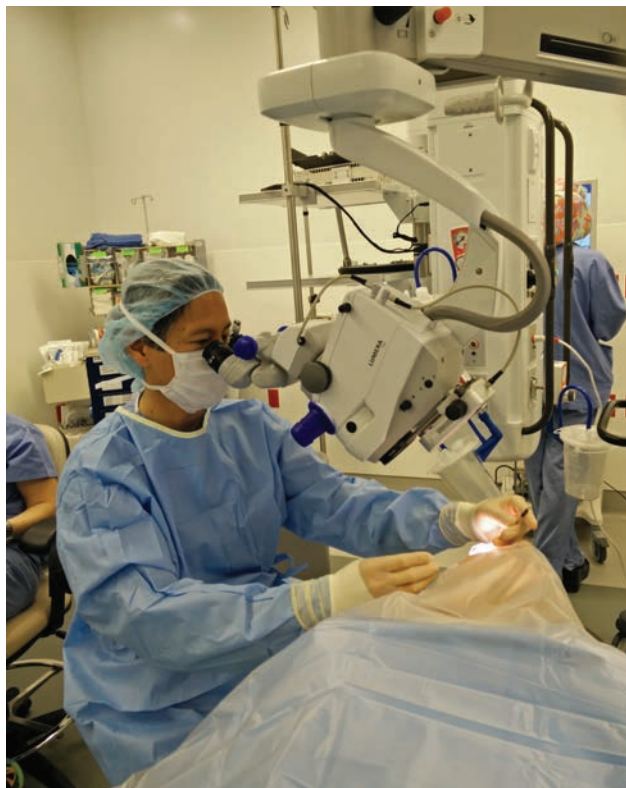
for your practice.

This could be especially important as we move forward, because it's possible that the number of these patients will increase significantly. Currently, a lot of patients don't end up getting surgery until their glaucoma is already advanced. Hopefully, 10 years from now, people will be better-educated about glaucoma and more glaucoma will be discovered before it reaches the severe stage. If that's the case, we'll be seeing more people who have mild-to-moderate glaucoma, some of whom will need an option beyond medications. These less-risky procedures could be ideal in that situation.

• **Do these surgeries fit in with your current procedures?** Many of the surgeons using MIGS procedures right now are primarily cataract surgeons. These procedures are a good fit for them, for several reasons. First, many cataract surgeons don't feel comfortable doing trabeculectomies. Second, most of their glaucoma cases aren't very severe; they just need a few more points of pressure lowering to get the patient off medications. Third, adding a MIGS procedure is just a slight modification of what they're already doing. So for them it's a fairly easy transition to add the new procedure. (That's not to say the new procedures have no value to a glaucoma specialist. I do cataract surgeries too, and some of my patients don't have severe glaucoma.)

## Which Surgery to Add?

If you want to try adding a new



When deciding whether to add a new surgery to those you offer, consider how well your current procedures are working; what percentage of your patients would be better-served; how a new procedure will fit into your current surgeries; your surgical skill level; the cost; and whether your patients will be able to manage the postoperative care requirements of the new surgery.

procedure to your armamentarium—perhaps the iStent, the Trabectome, canaloplasty, the EXPRESS shunt or ECP—a head-to-head comparison of their efficacy would be ideal. Unfortunately, at this point that doesn't exist. There aren't a huge number of good studies that have compared procedures; most reports concern a series of patients who had one type of procedure.

In lieu of that, a number of factors should be considered when deciding which one(s) to add:

• **Your surgical skill level.** If you're a very good surgeon, you can probably try any new procedure that interests you. If not, you may want to think twice about trying new surgeries that come with a big learning curve.

• **Cost considerations.** These can

be important, depending on what your financial setup is with your surgical center, because many of these new procedures have upfront costs for equipment. They may also have per-case costs; you may have to pay for each device you implant, and/or there may be a disposable part of the equipment that must be replaced each time, such as the light pipe in canaloplasty. There may also be costs involved in training your staff.

• **How far your patients have to travel.** This is relevant because some of the new procedures have fewer postoperative requirements in terms of visits. If a patient is coming a long distance, perhaps from several hundred miles away, then it would make sense to favor a procedure that doesn't require as many postoperative visits, or one that's simple enough that the referring physi-

cian can manage the postoperative care. (That's another disadvantage of trabs and tubes; they do require a fair number of postoperative visits and maybe even some additional procedures during the postoperative period.)

## Learning a New Surgery

Once you've chosen a surgery to learn, you have to decide how to develop the skills connected with that procedure. Fortunately, many of the newer procedures have evolved from earlier, more familiar procedures, which means that skills we already possess may be stepping-stones to move us into the new skill set. For example, canaloplasty is based upon several other surgeries that have

been developed over the past 20 years, including trabeculectomy, deep sclerectomy and viscocanalostomy, in which you identify Schlemm’s canal and inject viscoelastic into it.

Because most of the new surgeries are built upon previous surgeries, you can practice each step as you’re doing a traditional surgery until you’re ready to try the newer technique. When doing a trabeculectomy, for example, you can gradually practice the skills needed to perform canaloplasty. During trabeculectomy we normally just create a scleral flap and then do the sclerostomy. But before doing the sclerostomy, you can do a deep sclerectomy, which means removing a deeper block of sclera so you’re left with a thin layer of sclera overlying the choroid. You can dissect that anteriorly until you get a little bit of a Descemet’s window, and stop there; doing this will give you practice dissecting a deep sclerectomy. Each time you do it, make a bigger Descemet’s window and start looking for Schlemm’s canal. You can still go ahead with the trabeculectomy; just do what you would normally do. The extra step won’t affect your surgery very much, but it will give you practice doing the deep sclerectomy. This will allow you to develop the skills you need to perform canaloplasty gradually, over a period of months. Eventually, performing canaloplasty won’t be difficult at all.

Similarly, to prepare to implant an iStent you can practice identifying the angle at the end of cataract surgery. Simply adjust your microscope and use the gonioscopy; see if you can identify the angle, and get comfortable with that positioning of the microscope and your hands and the gonioscopy. Once you’ve done that a few times and you feel comfortable doing it, you can move on to inserting an iStent.

Sometimes learning to perform one of the new surgeries will help prepare you for others. This is true for

angle surgery. Once you’ve learned to use the Trabectome or the iStent, you’ll find it much easier to try the other devices that are going to be coming out very soon—including suprachoroidal devices, or even the new GATT technique (gonioscopy-assisted transluminal trabeculectomy) and *ab interno* canaloplasty.

*I don’t think tubes or trabs will ever disappear from our toolboxes, but I believe eventually they’ll be relegated only to the severe cases.*

Of course there are more traditional training options as well. Skills transfer courses at the AAO or ASCRS meetings are usually available, and many manufacturers are happy to train you, simply because they want you to use their device or instrument. You’ll also find plenty of videos online, showing different techniques for using these devices. (These should not be your only source of instruction, but they can be a good way to refine your techniques and get more information.) Finally, it’s always great if you can visit a surgeon who’s already doing the surgery. Nothing can replace actually seeing the surgery being done and having someone do it with you.

### **Making Our Way Forward**

One of the most interesting side effects of these new procedures is that they’ve made us rethink what we know about trabecular outflow—

how fluid gets out of the eye. When performing trabeculectomy as our main surgical option, we don’t have to think about how the fluid gets out of the eye; we just make a new opening. In the past it was widely believed that resistance to outflow was primarily at the meshwork, so we thought that putting a hole in the trabecular meshwork to create better access to Schlemm’s canal would drop the pressure quite a bit. The mixed results of these new procedures are calling that into question. So, whether or not any given procedure stands the test of time, it’s clear that their use will move our understanding of the disease forward.

In the meantime, the reality is that tubes and trabs are still the bread-and-butter procedures for most glaucoma specialists. None of the newer surgeries have become major players—at least so far. I’ve tried several of them myself, and so far I haven’t been that impressed with the outcomes. But many of these surgeries are just the first generation; new surgeries continue to be developed, and every new iteration tends to be a little bit better than the previous ones. The hope is that something will come along in the next five or 10 years that will be very effective and safe.

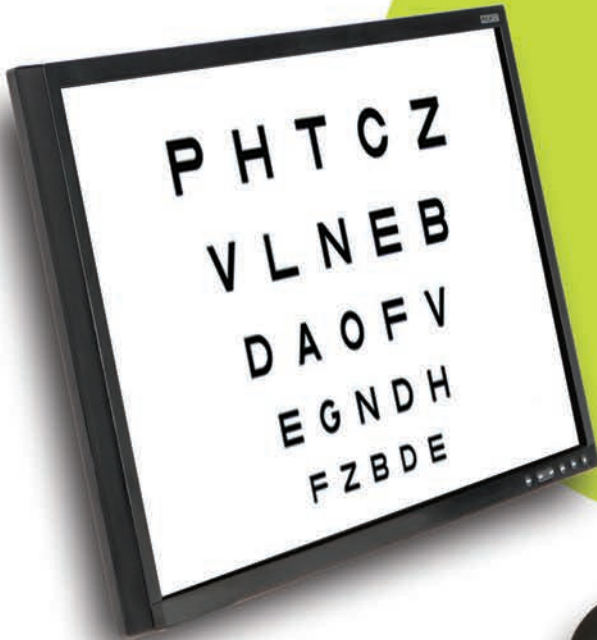I don’t think tubes and trabs will ever disappear from our toolboxes, but I believe that eventually they’ll be relegated only to the severe cases. At that point, the newer procedures will routinely be used to address the mild to moderate cases. In the meantime, I believe it’s good for us to have multiple options, and to be trying different things. **REVIEW**

*Dr. WuDunn is a professor of ophthalmology at the Eugene and Marilyn Glick Eye Institute, Indiana University School of Medicine in Indianapolis. He is an investigator for InnFocus, maker of the MicroShunt glaucoma drainage implant.*

# CVS Essential

The Lombart Visual Acuity System

Simple  
and Affordable.



The CVS Essential  
includes:

- Monitor
- HDMI Device with Acuity Software Program
- Luminous RF Remote
- Wall Mounting Bracket with Swivel

Only

**\$1,695**



Acuity Systems don't have to be complicated. The CVS Essential proves they can be simple and affordable.

There are many visual acuity systems available in the market today. Many of these have features that often go unused and require extensive knowledge of their complicated remote controls to access them.

The *Lombart CVS Essential* unit was developed with the idea that an acuity system should be easy to operate, while still including the standard acuity charts commonly used in refraction. The *CVS Essential* provides quick access to charts and features, ease of installation and most of all ... is priced right!

The *CVS Essential* provides standard optotypes in a full range of Snellen Ratios. The remote control is easy to understand with quick access to all optotypes and smooth transitions when adjusting chart sizes. It offers a direct button for chart randomization as well as for Red/Green duochrome testing on all optotypes.

2.4G RF Remote



Luminous Keypad



1-800-566-2278

**Call 1-800-Lombart**

Or Your Local Lombart Representative

Corporate Office - 5358 Robin Hood Road, Norfolk, VA 23513-2430  
757-853-8888 | FAX 757-855-1232 | 800-566-2278

[www.lombartinstrument.com](http://www.lombartinstrument.com)

[lombart@lombartinstrument.com](mailto:lombart@lombartinstrument.com)

Sales and Service Centers Coast to Coast

ATLANTA • BALTIMORE/WASHINGTON D.C. • BOSTON • BOYNTON BEACH/MIAMI • BRADENTON • CHARLOTTE • CHICAGO • CINCINNATI • DALLAS • DENVER • DETROIT • GREENSBORO • HOUSTON  
JACKSON • KANSAS CITY • KNOXVILLE • LOS ANGELES • MILWAUKEE • MINNEAPOLIS • NEW JERSEY/NEW YORK/PENNSYLVANIA • NORFOLK • PORTLAND • SAN ANTONIO • SAN DIEGO • SAN FRANCISCO

# Neuropathic Pain: The Artifice of Dry Eye

A look at neuropathic pain and its relationship to dry-eye diagnosis and therapeutic strategies.

*Mark B. Abelson, MD, CM, FRCSC, FARVO, Perry Rosenthal, MD, CM, and James McLaughlin, PhD, Andover, Mass.*

**W**e typically attribute dry-eye disease to a deficiency of lacrimal gland secretion, reduced meibomian gland function or some combination of these.<sup>1</sup> For many, sufficient mitigation of symptoms can be achieved with tear augmentation.<sup>2</sup> Others present with signs of surface desiccation and an autoimmune spectrum that is consistent with desiccating dry-eye disease such as that sometimes associated with Sjögren's syndrome. But how do we explain patients who don't show a correlation between tear deficiency or hyper-evaporation and chronic dry eye-like symptoms? In some cases, eyes that feel dry are not dry.<sup>3</sup> What of those patients who report the perception of dry eye, with burning, irritation and even ocular pain that's unresponsive to dry-eye management? In this article, we'll attempt to unravel the mysteries associated with neuropathic pain and dry eye, and its implications in dry-eye diagnosis and treatment.

## Dry Eye-Like Symptoms

Dry eye-like symptoms are triggered by specialized corneal nerve re-

ceptors<sup>4</sup> designed to protect the integrity of the mirror-smooth corneal tear film necessary for enhancing the optical quality of the external corneal surface. This collection of nociceptors—mechanoreceptors, chemoreceptors and thermoreceptors—detects the subtlest changes in the ocular surface environment and functions as our cornea's alarm system to warn us of potentially harmful disruption of the status quo. In particular, specialized thermal sensors provide an indirect measure of the thickness of the tear film. By sensing slight changes in ocular surface temperature, they monitor the rate of tear-film evaporation to provide a measure of both tear-film thickness and osmolarity in real time.<sup>5</sup> The sensors' responses to environmental conditions are a modulation of their excitability and an alteration of neuronal action potential firing rates. Like any such alarm system, modulation can be either positive or negative. As an example, on a windy day evaporation at the ocular surface is increased, and the activation of thermoreceptors will increase the firing rate of the corneal sensory nerves, triggering an increase in lacrimal gland secretion

to compensate for the accelerated tear-film thinning. Like all sensory nerves, continuous input modulates the set point, or activation threshold. All is well as long as this set point is in synchrony with other parts of the sensory feedback loop.

What happens when there is dysregulation of the sensory nerve circuit? If the triggering threshold is too high, the system will be relatively insensitive to the external environment, and the tear film will thin and break up, causing a loss of clarity, unstable vision and an exposed ocular surface. If the sensor threshold is set too low, the biological alarm will be triggered prematurely, generating dry eye-like symptoms in the presence of a normal tear film: a false alarm. These sensory circuits are described as being sensitized, and would be expected to require thicker-than-normal tear films to keep the dry-eye alarm in a silent mode. Under these conditions, sensory neurons respond to the ocular surface environment with symptoms of dryness, even though there is little or no stimulus generating that perception. Like all sensitive, powerful and complex systems, corneal in-

nervation is vulnerable to component breakdown, with the result being neuropathic pain, a disease in its own right.

## Dry Eye-Like Pain

Activation thresholds of tear film corneal sensors are lowered in the presence of inflammatory products such as pro-inflammatory cytokines.<sup>6</sup> Increased activity of sensory nerves can also cause inflammation in the form of neuro-inflammation, which in turn ramps up the activity of pain-carrying nerves, leading to a self-perpetuating phenomenon known as peripheral sensitization.<sup>7</sup> For many patients this can be reversed after resolution of the inciting stress and ocular surface inflammation.<sup>8</sup> Some dry-eye patients experience only transient episodes of pain, whereas others have persistent symptoms of chronic disease. Neuropathic pain is by definition “pain arising as direct consequence of a lesion or disease affecting the somatosensory system,” and is often chronic.<sup>9</sup>

The transmission of dry-eye pain signals to the somatosensory cortex is not a passive process. Along the way, these electrical signals are modified by feed-forward and feedback systems that typically intensify the signals. This explains the unique property of pain to become amplified during a constant noxious stimulus, in contrast to most other types of sensory responses that adapt during persistent stimulation and thereby attenuate the responses. This physiological phenomenon, known as central sensitization, occurs with dry eye-like pain as well.<sup>8</sup> Since the trigeminal brainstem was shown in animal models to be the location of central control of homeostatic corneal wetness,<sup>10</sup> corneal algesia<sup>11</sup> and aversive responses to light,<sup>12</sup> the brainstem may also be the origin of the clinical expression of dry-eye-related pain. The possibility that disorders of the dry-eye alarm system itself can explain the variety of clinical patterns associated



When dry-eye symptoms include photophobia, it's likely there's an underlying neuropathic etiology.

with dry eye-like pain offers a strikingly different perspective. Moreover, the location and persistence of this dysfunctional alarm system can alter the functional anatomy through the well-known, innately powerful neuroplasticity of the central nervous system. These maladaptive changes in the CNS result in neuropathic pain.

## Possible Origins of the Pain

For us to be able to manage these cases effectively, it's important to recognize the factors influencing neuropathic pain. Age-related dry-eye disease is characterized by the attrition of corneal nerve fibers. Its consequences are associated with an increased sensitivity to tear evaporation, or corneal evaporative hyperalgesia. Pain fiber attrition also occurs in de-afferentation hypersensitivity, a phenomenon found in the skin of healthy elderly subjects. The loss of nerve fibers in these conditions is associated with increased activity of the surviving nerves.<sup>13</sup> The parallels between this condition and age-related dry eye are striking.

In mice, it has been demonstrated that sensory nerve injuries, such as those caused by LASIK axotomies, trigger a phenotypic change in the somata of the surviving nerves from conduction to regeneration, promoting

the expression of atopic pain generators that are hypersensitive and hyper-responsive<sup>14</sup> and that are transported to the regenerating nerve sprouts and the central terminals of severed axons from the nerve somata in the trigeminal ganglion where they're expressed. This likely is responsible for the complaints of dry-eye symptoms following refractive procedures. Persistence of the regenerating phenotype long after healing has occurred, sometimes years after LASIK, as suggested by the characteristic morphology of regenerating nerves and increased numbers of mature dendritic cells in the sub-basal plexus, may explain the chronicity of dry-eye pain even in the absence of external signs of inflammation.

Even in the absence of a surgical trigger, normal afferent signals generated by tear evaporation could be augmented and distorted during their passage through a malfunctioning trigeminal brainstem. In this way, dry-eye symptoms can be experienced in certain diseases characterized by central sensory processing issues, such as fibromyalgia, with symptoms mimicking dry eye in the absence of overt signs.<sup>15</sup>

It has been well known for years that our psychological well-being profoundly influences our immunological status. Pain thresholds are also known to be increased by meditation.<sup>16</sup> The flip side of this should not be a surprise. In the present context, patients with depression or post-traumatic stress disorder have a twofold increased risk of a dry-eye diagnosis compared to those without these diagnoses. Studies with Asian populations have shown similar relationships between depression and dry eye. Data from the national Veterans Administration database demonstrated that patients with chronic pain diagnoses are more likely to also have a dry-eye diagnosis. Patients with dry eye were also found to have higher pain sensitivity at a remote site (forearm) than those without the disease.<sup>8</sup>

We see that neuropathic pain ac-

**In Memoriam: Henry F. Edelhauser, PhD**

It is with great sadness that I relate the recent death of my colleague and friend Henry F. Edelhauser, PhD. Hank spent his career, first at the Medical College of Wisconsin and, since 1989, at the Emory Eye Center in Atlanta working in translational ophthalmic research, something near and dear to my own heart.

Hank's intuitive understanding of ocular physiology and his gift for insightful clinical research led to his seminal work on the corneal endothelium and to the development of irrigating solutions for ophthalmic surgery. He was a pioneer in the development of methods for ocular drug delivery, and it's fair to say that his work improved the vision and visual health of many thousands of patients over the course of his life. As just one example, the scales that Hank developed to help us quantify the health of the corneal epithelium are used routinely here at our research firm Ora, and in specular microscopy exams in clinics all over the world every day.

I was fortunate enough to have shared a podium or two with Hank over the years, and I was always impressed by his ability to succinctly and eloquently describe the most complex of physiological concepts. The author of more than 250 publications, a past president of the Association for Research in Vision and Ophthalmology, and the recipient of numerous awards including the Proctor medal, Hank was one of the great ophthalmic researchers of our time. His passion for science was palpable and was transmitted over his long, successful career to colleagues and students alike. He will be missed.

—MBA

companying dry eye might also be born from central sensitization in the central nervous system, and this possibility should be considered when weighing the contribution of signs versus symptoms presented by our patients diagnosed with dry-eye disease.

**Diagnosis and Treatment**

Identifying patients with a neuropathic component in their dry eye may influence treatment. Neuropathic pain is typically chronic and difficult to treat. It often includes burning, sharp, needle- or foreign body-like symptoms, and neuropathy should be considered when hearing these descriptors. It can also be expressed as spontaneous, and as a response to normally non-noxious stimuli, such as photo-allodynia. Esthesiometry has demonstrated lower sensitivity to mechanical stimuli, and some dry-eye patients report hypersensitivity to chemical fumes and cold. Confocal microscopy has identified neuronal morphological alterations in the corneal sub-basal plexus in patients with chronic dry-eye symptoms,<sup>8</sup> even in the absence of external

signs of inflammation (*one author's observations—PR*). A history of abnormally heightened sensitivity to noxious stimuli and confocal morphological changes in patients with chronic dry-eye symptoms suggests a neuropathic component.

Such patients would benefit from an approach that includes treating the ocular surface with protective and anti-inflammatory agents, and treating central ocular sensory dysfunction with anti-neuropathic pain drugs. Research is needed to understand the role of the many available neuropathic pain treatments in treating dysfunctions of the ocular sensory apparatus associated with dry eye. Therapies are in development, some of which arise from studies of the pain genetics.<sup>17</sup> We need effective regimens for neuropathic pain, and an important goal would be a diagnostic algorithm for neuropathic pain associated with dry-eye disease.<sup>8</sup>

We know that dry eye is not just a simple disease of tear deficiency and/or hyper-evaporation, but rather a heterogeneous group of disease subtypes with varying pathologies of the lacrimal gland unit and ocular sensory

apparatus. It's likely that a subgroup of dry-eye patients has neuropathic pain and central sensitization, making their condition more resistant to topical therapy designed to optimize the ocular surface. Identifying these conditions is paramount to solving the mystery behind this pain, and personalizing the treatment of dry eye. **REVIEW**

*Dr. Abelson is a clinical professor of ophthalmology at Harvard Medical School, and emeritus surgeon at the Massachusetts Eye and Ear Infirmary. Dr. Rosenthal is emeritus surgeon at the Massachusetts Eye and Ear Infirmary, part-time assistant professor of ophthalmology at Harvard Medical School, founder and president of the Boston Eye Pain Foundation and founder of the Boston Foundation for Sight. Dr. McLaughlin is a medical writer at Ora Inc.*

- Mathers WD, Lane JA, Zimmerman MB. Tear film changes associated with normal aging. *Cornea* 1996;15:3:229-34.
- Lane SS. A new system, the LipiFlow, for the treatment of meibomian gland dysfunction. *Cornea* 2012;31:4:396-404.
- Galor A. Ocular surface parameters in older male veterans. *Invest Ophthalmol Vis Sci* 2013;54:2:1426-33.
- Hirata H, Meng ID. Cold-sensitive corneal afferents respond to a variety of ocular stimuli central to tear production: Implications for dry eye disease. *Invest Ophthalmol Vis Sci* 2010;51:8:3969.
- Belmonte C, Gallar J. Cold thermoreceptors, unexpected players in tear production and ocular dryness sensations. *Invest Ophthalmol Vis Sci* 2011;52:6:3888-92.
- Watkins LR. Characterization of cytokine-induced hyperalgesia. *Brain Res* 1994;654:1:15-26.
- Bhave G, Gereau RWT. Posttranslational mechanisms of peripheral sensitization. *J Neurobiol* 2004;61:1:88-106.
- Galor A. Neuropathic ocular pain: An important yet undervalued feature of dry eye. *Eye (Lond)* 2015;29:3:301.
- Geber C. Revised definition of neuropathic pain and its grading system: An open case series illustrating its use in clinical practice. *Am J Med* 2009;122:10:S3-12.
- Hirata H. A novel class of neurons at the trigeminal subnucleus interpolaris/caudalis transition region monitors ocular surface fluid status and modulates tear production. *J Neurosci*. 2004;24:17:4224-32.
- Tashiro A. Behavioral and neurophysiological correlates of nociception in an animal model of photokeratitis. *Neuroscience* 2010;169:1:455-62.
- Rahman M. Trigeminal pathways for hypertonic saline- and light-evoked corneal reflexes. *Neuroscience* 2014;277:716-23.
- Namer B. Microneurographic assessment of C-fibre function in aged healthy subjects. *J Physiol* 2009;587(Pt 2):419-28.
- Wolf G. Genetic impairment of interleukin-1 signaling attenuates neuropathic pain, autotomy, and spontaneous ectopic neuronal activity, following nerve injury in mice. *Pain* 2006;120:3:315-24.
- Rosenthal P, Borsook D. Ocular neuropathic pain. *Br J Ophthalmol*. 5 May 2015. doi:10.1136/bjophthalmol-2014-306280. [Epub ahead of print]
- Reiner K, Granot M, Soffer E. A brief mindfulness meditation training increases pain threshold and accelerates modulation of response to tonic pain in an experimental study. *Pain Med*. 8 Aug 2015. doi: 10.1111/pme.12883. [Epub ahead of print]
- Nahorski MS, Chen YC, Woods CG. New Mendelian Disorders of Painlessness. *Trends Neurosci* 2015;38:11:712-24.

# Looking deeper

# Exploring innovation

## Shire's Vision for Ophthalmics


At Shire, we're a leading biotech with a global track record for our work in rare diseases and specialty conditions.

Now we're expanding our vision and bringing the same commitment to ophthalmics. Pursuing the promise of new therapies in ophthalmics to address patients' unmet needs.

Just watch.

Visit [Shire-Eyes.com](http://Shire-Eyes.com)





# Refractive Surgery

## Trends of the ISRS

The final ISRS survey ends on a sour note for LASIK volumes but a high note for surgeons' confidence in the procedure.

*Walter Bethke, Managing Editor*

**J**ust like consulting a map while you're on a trip, a survey of your refractive colleagues can help show you whether you're on the right track or if you have to adjust your approach based on what others are doing. With this idea in mind, this year's annual survey of the U.S. members of the International Society of Refractive Surgery has data on such questions as the preferred procedures for different levels of myopia and hyperopia, which flap-making method is popular and how surgeons like to tackle astigmatism. Here is a review of the highlights of this year's survey, the final one that will be conducted, with commentary from the survey's co-creator, Mobile, Ala., surgeon Richard Duffey.

### Laser Refractive Surgery

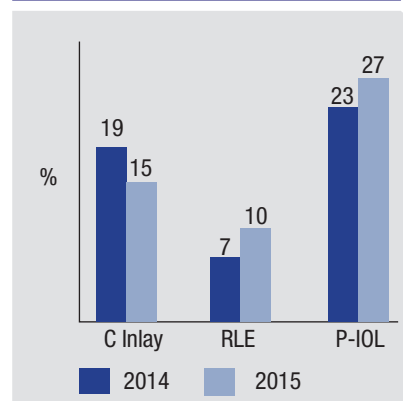
A perennial topic of conversation surrounding LASIK and PRK is that of procedure volumes. This year's survey showed a continuation of the trend in volumes flattening or even shrinking slightly.

This year, LASIK volume reported on the survey dropped 27 percent from last year, and PRK volume decreased

by 7 percent. The ratio of PRK to the total number of laser vision correction procedures remained the same as last year at 28 percent. "Clearly, LASIK reached its peak around 2001," says Dr. Duffey. "It's been on a downward trend ever since. For the high-volume surgeon, at least, it's really dwindled. The same is true for the surgeons reporting they do 25 cases per month and even five cases per month. Those groups too reached their peaks in 2001 and have been going down." The percentage of surgeons reporting that they perform 25 or more cases of LASIK each month declined from 36 percent to 22 percent. Those doing five or more cases decreased slightly from 59 percent to 56 percent.

Interestingly, though volumes have gone down, surgeons' confidence in LVC as a procedure class has gone up. Forty-four percent of respondents say they'd perform either PRK (15 percent) or LASIK (29 percent) on a high (-10 D) myope, compared to those who would prefer a phakic IOL (33 percent) or refractive lens exchange (4 percent). "It's amazing to me that we're still doing more LVC than lenses for -10 D myopes," says Dr. Duffey.

### Bilateral, Same-Day Surgery



Surgeons who are comfortable doing simultaneous, bilateral corneal inlays, refractive lens exchanges and phakic IOL procedures.

"It's true in my practice, as well. Laser vision correction is just less complex and less risky than an intraocular procedure."

On the hyperopic side, 61 percent of surgeons prefer LVC for a low hyperope (+3 D), vs. 17 percent who would prefer RLE. The situation flips for high hyperopes (+5 D), however, with 74 percent preferring RLE vs. just 8 percent who would do LVC.

In terms of flaps and residual stro-



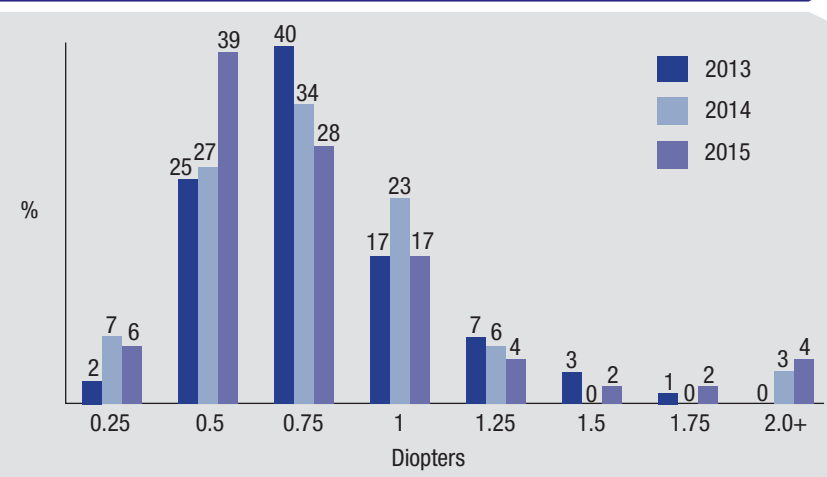
mal bed thickness, the latter has consistently increased on the study. “When we used to ask about how much stromal bed they would leave after making the LASIK flap, surgeons would often leave 250 to 225  $\mu\text{m}$ ,” recalls Dr. Duffey. “Now, it’s more commonly 275 and 300  $\mu\text{m}$ . Similarly, when surgeons were asked the thinnest cornea on which they’d perform LASIK, they used to say it didn’t make a difference if it were 450, 480 or 520  $\mu\text{m}$ . Now, many people aren’t comfortable unless the corneal thickness preop is 500 or 520  $\mu\text{m}$ . I think we’ve gotten better at preop testing.”

### Astigmatism Management

The survey also showed the trend of surgeons buying into the idea of refractive cataract surgery, where they try to provide sharp visual outcomes in addition to removing the cataract. This mainly manifests itself as their inclination to tackle astigmatism.

In 2012 for instance, only 17 percent of the survey’s respondents said they’d offer to correct 0.5 D of astigmatism. Today, however, 39 percent say they’d be willing to go after such a low amount. Overall, 73 percent of the surgeons will offer to correct astigmatism when it has reached 0.75 D; 6 percent will offer correction if it’s 0.25 D, 39 percent for 0.5 D and 28 percent for 0.75 D. By the time the level of a hypothetical patient’s cylinder is at 1.25 D, 94 percent of the surgeons surveyed will have offered to correct it. “A number of things influence this,” says Dr. Duffey. “As femtosecond technology becomes more available, it’s easy to just use it on a case. So, if you’re doing femtosecond on a cataract patient anyway, then you can just use it to correct whatever astigmatism is there. That’s certainly my approach. Speaking for myself, I have a lot of patients who come to me now because they know I’m able to get a lot of patients out of glasses, which

### Threshold At Which Surgeons Would Offer to Correct Cylinder



I do because I make sure that I correct whatever astigmatism is present. I used to get about 73 percent of my patients out of glasses with cataract surgery by using AKs, being aggressive with IOL calculations and using toric IOLs when necessary. However, that number jumped to 92 percent when I went to femtosecond technology. Before femto, I would think that something like 0.87 D wasn’t really a lot of astigmatism, so I wouldn’t worry about it; but then I’d find myself having to worry about it after the fact by doing LASIK or something else. Now I happily correct 0.5 or 0.75 D of astigmatism, because I can reliably correct it. Also, when approaching the astigmatism with a blade, I ran the risk of reversing the axis and taking someone with 0.5 D at 90 and giving him 0.5 D at 180, which patients will tell you about in a heartbeat; I would have been better off leaving that patient alone. Now, that very rarely happens with the femtosecond, in my hands.”

### Lens Surgery

One of the interesting facets of lens surgery that has emerged on the survey is the percentage of surgeons who are comfortable with performing simultaneous, bilateral lens surgery.

Last year, 7 percent of surgeons said they’d do bilateral RLE at the same visit, and 23 percent would perform bilateral phakic lens implantation. This year, 10 percent and 27 percent of surgeons are comfortable with bilateral, simultaneous RLE and phakic IOL surgery, respectively. “The perplexing part is, when I speak to surgeons, no one says he’s doing it,” says Dr. Duffey. “I know some insurance entities are making a push for bilateral, same-day surgery in California and Colorado, which could contribute to the increase. In general, I see the numbers go up each year but, anecdotally, I just don’t see people out there doing it.”

Due to a dwindling response rate, this marks the final ISRS refractive surgery survey, capping off a 19-year run of providing surgeons a barometer of the standard of care. Dr. Duffey says he appreciates what the survey has taught him. “You can see that the technology has gotten better and we’ve gotten smarter, learning from our mistakes,” he says. “We’ve shared data and have become better-educated. Meetings such as those held by the ISRS and ASCRS have helped us a lot, and I hope that these surveys also helped change the landscape and the standard of care thanks to what we’ve learned from each other.” **REVIEW**



FEBRUARY 13-14, 2016

# Ophthalmology Update

# 2016

## PROGRAM CHAIRS

Don O. Kikkawa, MD  
Robert N. Weinreb, MD

## DISTINGUISHED INVITED SPEAKERS

Kerry Assil, MD  
Helen Danesh-Meyer, MD  
Robert A. Goldberg, MD  
Jeffrey M. Liebmann, MD  
Ken K. Nischal, MD  
Srinivas R. Sadda, MD  
Ningli Wang, MD

## LOCATION

Hilton La Jolla Torrey Pines  
10950 North Torrey Pines Rd.  
La Jolla, CA 92037  
P: 858-558-1500

## 3 WAYS TO REGISTER

Call Lois DiDomenico: 877-451-6513  
Online: [www.ReviewofOphthalmology.com/Update2016](http://www.ReviewofOphthalmology.com/Update2016)  
Email: [ReviewMeetings@Jobson.com](mailto:ReviewMeetings@Jobson.com)

Please check [www.ReviewofOphthalmology.com/Update2016](http://www.ReviewofOphthalmology.com/Update2016) for up-to-date information.

### Accreditation Statement

This activity has been planned and implemented in accordance with the accreditation requirements and policies of the Accreditation Council for Continuing Medical Education (ACCME) through the joint providership of the Institute for the Advancement of Human Behavior (IAHB) and Postgraduate Health Education, LLC (PHE). IAHB is accredited by the ACCME to provide continuing medical education for physicians.

### Credit Designation Statement

IAHB designates this live activity for a maximum of 11.25 *AMA PRA Category 1 Credits™*. Physicians should claim only the credit commensurate with the extent of their participation in the activity.

©iStock.com/uschools

An interdisciplinary faculty of ophthalmic subspecialists will review the continuing progress in Cataract and Refractive Surgery, Glaucoma, Retina, Neuro-Ophthalmology, Ocular Surface Disease, Cornea and Oculoplastics.

Discounted room rates available at \$219/night. Limited number of rooms available. See registration site for more information.



Photos: ©2015 Hilton Hotels & Resorts

## EDUCATIONAL OBJECTIVES

- Analyze new research that illustrates the key role that inflammation plays in the genesis of DME and macular edema secondary to RVO.
- Engage in discussions related to emerging issues in glaucoma, including risk assessment, imaging, management and progression assessment.
- Manage glaucoma using newer pharmaceutical agents.
- Discuss the newest glaucoma surgical devices, including those used in patients undergoing cataract surgery.
- Utilize advanced technologies and techniques in refractive cataract surgery, including femtosecond laser and new ultrasound fluidics.
- Master advanced technology IOLs, improving patient selection, surgical technique and postoperative management.
- Outline current management techniques for ocular surface diseases such as dry eye and keratitis.
- Discuss the rationale for anti-VEGF therapy and steroids in posterior segment diseases including age-related macular degeneration and diabetic macular edema.
- Navigate issues relating to patient compliance/adherence with eye-drop medications.
- To understand the facial aging process and gain knowledge of possible treatments for rejuvenation.

## PROGRAM TIMES

Saturday, February 13  
8:00am — 5:00pm  
Reception to follow  
Sunday, February 14  
8:00am — 12:15pm



# A New Understanding of Vitreous Structure

Advances in imaging technologies are changing both the way we think of the vitreous and how we treat patients.

*Michael Engelbert, MD, PhD, New York City*

**T**he anatomy of the vitreous has been enigmatic until recently. A more complete understanding of vitreous structure has been limited by difficulty visualizing subtle differences between several liquid-filled spaces and the “formed” vitreous, which also consists of more than 99 percent water.

## The Pioneers’ Vision

Two pioneers of vitreous anatomy, Jan Worst and Shoji Kishi, used complementary methods to explore the vitreous spaces, the former by injecting the liquid spaces with ink,<sup>1</sup> the latter by staining the formed vitreous with fluorescein.<sup>2</sup> Their findings were also complementary, with—among other differences—Prof. Worst stating that the “premacular bursa” was a liquid space overlying the macula, and connecting to a retrociliary system of other liquid-filled spaces he termed “cisterns,”<sup>1,3</sup> while Prof. Kishi claimed that the “posterior precortical vitreous pocket”—arguably the same space—was confined, and boat-shaped.<sup>2</sup> Prof. Kishi accepted connections to other liquid spaces only later in life in the context of vitreous degeneration. He

and his team went on to utilize *in vivo* imaging techniques, namely optical coherence tomography, to characterize this space more and maintained that it was a confined space, although they noticed small connecting channels to Cloquet’s canal in some instances.<sup>4</sup>

We have utilized spectral-domain OCT<sup>5</sup> and swept-source OCT<sup>6</sup> to elucidate the anatomy of the posterior vitreous and resolve this decades-old controversy. SS-OCT with an Atlantis DRI-OCT (Topcon) allowed us to compose 18 x 18 mm maps of the posterior vitreous covering an approximately circular area surrounding fixation reaching about halfway to the equator. This coverage exceeded the reach of previous studies, and demonstrated that the bursa extended superiorly beyond the range of our instrument (See Figure 1). This discards the notion of a confined, boat-shaped space and suggests that the bursa may indeed connect to more anterior spaces, as had been proposed originally by Prof. Worst. However, when we examined potential connections of the bursa to other spaces, we found that it fuses superiorly with Cloquet’s canal at a variable distance from the optic

nerve. Of note, these were found universally, and also in young eyes without detectable vitreous degeneration. This is quite different from the proposed small connecting channel of the two spaces (Kishi), and a proposed connection of the bursa to a retrociliary circle of cisterns (Worst) and modifies our view of these spaces in a fundamental way: One can imagine these spaces like a mitten, with the thumb part at the beginning of Cloquet’s canal over the optic nerve, the finger part over the macula, and the wrist and arm making their way towards the front of the eye, terminating behind the lens in the space of Erggelet (See Figure 2).

The overall shape of the bursa appears to be quite consistent early in life, but there are significant differences in size (See Figures 3A and B). These may possibly relate to refractive error, according to Prof. Kishi, but we were unable to confirm this in our sample. However, we did observe a “giant premacular bursa” in a father and son with Stickler’s disease and high axial length (See Figure 3C).<sup>7</sup>

We also observed that fissure planes in the more central vitreous appear in the context of vitreous degeneration

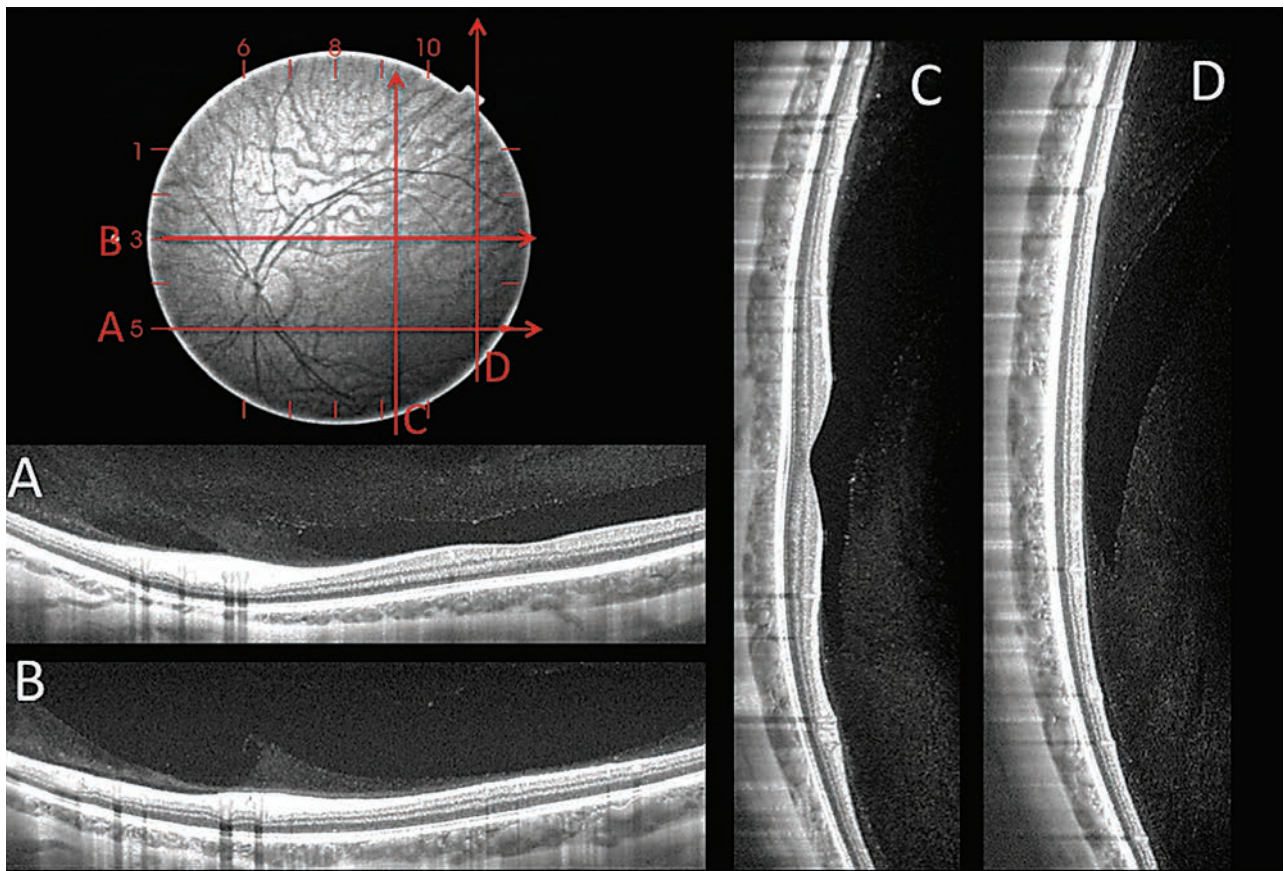


Figure 1. A horizontal SS-OCT scan at the level of the optic nerve shows the premacular bursa and the beginning of Cloquet's canal separated by what Jan Worst called the "septum interpapillomaculare" (A). The premacular bursa continues superiorly on this vertical scan through fixation obtained on upgaze (B). The superior extension of the premacular bursa and Cloquet's canal are seen to fuse at some distance from the optic nerve in this horizontal scan (C).

with age.<sup>6</sup> As Prof. Kishi had observed in cadaver eyes, these planes can eventually connect to the premacular bursa and Cloquet's canal.

While examining vitreous scans obtained with SS-OCT, we were struck by some other thin hyporefective spaces in the vitreous overlying first- and second-order blood vessels in young individuals without vitreous degeneration.<sup>8</sup> These probably correspond to the prevascular vitreous fissures observed by Georg Eisner in cadaver eyes with a modified slit lamp.<sup>9</sup> In eyes with increasing degrees of syneresis, these spaces appear to widen. In some eyes we found larger, roundish spaces, which likely correspond to the circle of cisterns surrounding the premacular bursa that Prof. Worst had demonstrat-

ed with ink injections in cadaver eyes and which can be observed during vitreous surgery employing triamcinolone staining.<sup>10</sup> Interestingly, prevascular vitreous fissures were absent in those eyes on our SS-OCT scans. We hypothesize that prevascular vitreous fissures, which were uniformly present in young eyes without vitreous degeneration, enlarge overtime, and are precursors to the cisterns found in cadaver eyes of older individuals with more advanced vitreous degeneration (See Figure 4).

### Clinical Utility

Recognition of the normal vitreous anatomy and its characteristic aging changes is helpful in the clinical setting. Recognition of liquid spaces, such

as the premacular bursa or vitreous fissures and cisterns may aid in differentiating whether the vitreous is still completely attached, or has completely separated in cases where ultrasound is equivocal. In the above-mentioned case of Stickler's disease, casual examination of the vitreous scans had suggested an early partial vitreous separation over the temporal macula, but identification of several cisterns was evidence that the bursal wall just mimicked the posterior hyaloid.

In patients with persistent visual disturbances after "floaterectomy," SS-OCT imaging of the vitreous can help identify residual cortical vitreous that would otherwise be invisible on clinical examination.<sup>11</sup> These cortical remnants probably become symptomatic when



# THE RICK BAY FOUNDATION

*for Excellence in Eyecare Education*

[www.rickbayfoundation.org](http://www.rickbayfoundation.org)

*Support the Education of Future Healthcare & Eyecare Professionals*



## **About Rick**

Rick Bay served as the publisher of *The Review* Group since 1991.

To those who worked for him, he was a leader whose essence was based in a fierce and boundless loyalty.



To those in the industry and the professions he served, he will be remembered for his unique array of skills and for his dedication to exceeding the expectations of his customers, making many of them fast friends.

Scholarships are awarded to advance the education of students in both **Optometry** and **Ophthalmology**, and are chosen by their school based on qualities that embody Rick's commitment to the profession, including integrity, compassion, partnership and dedication to the greater good.

## Interested in being a partner with us?

Visit [www.rickbayfoundation.org](http://www.rickbayfoundation.org)

*(Contributions are tax-deductible in accordance with section 170 of the Internal Revenue Code.)*



**THE RICK BAY FOUNDATION**  
*for Excellence in Eyecare Education*

*(The Rick Bay Foundation for Excellence in Eyecare Education is a nonprofit, tax-exempt organization under section 501(c)(3) of the Internal Revenue Code.)*

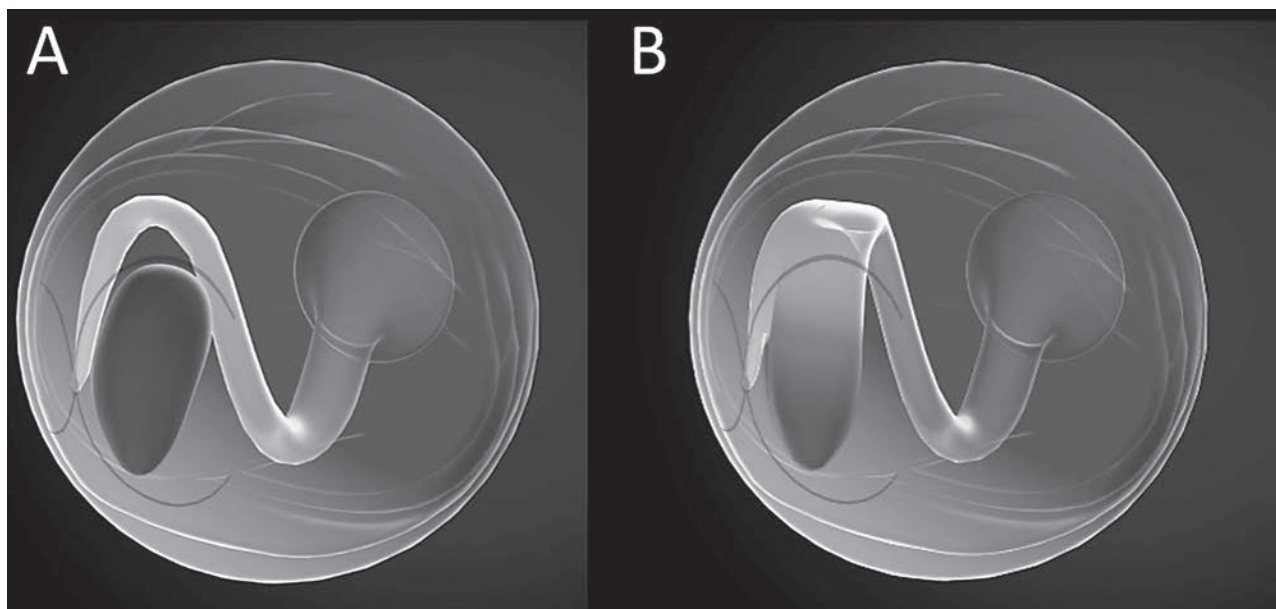


Figure 2. Juxtaposition of Shoji Kishi's model of the premacular bursa (A) and our model based on results from SS-OCT mapping of the posterior vitreous (B). Dr. Kishi maintains that the premacular bursa, or "posterior precortical vitreous pocket" is initially a confined, boat-shaped space, which does not connect to any other vitreous spaces except for a small connecting channel to Cloquet's canal, or connections formed later in life in the context of vitreous degeneration. We propose that the broad fusion of superior extension of the premacular bursa with Cloquet's canal is already present in young individuals without significant vitreous degeneration, giving rise to a mitten-shaped space, with the thumb connected to the optic nerve and the hand overlying and tethered to the premacular bursa.

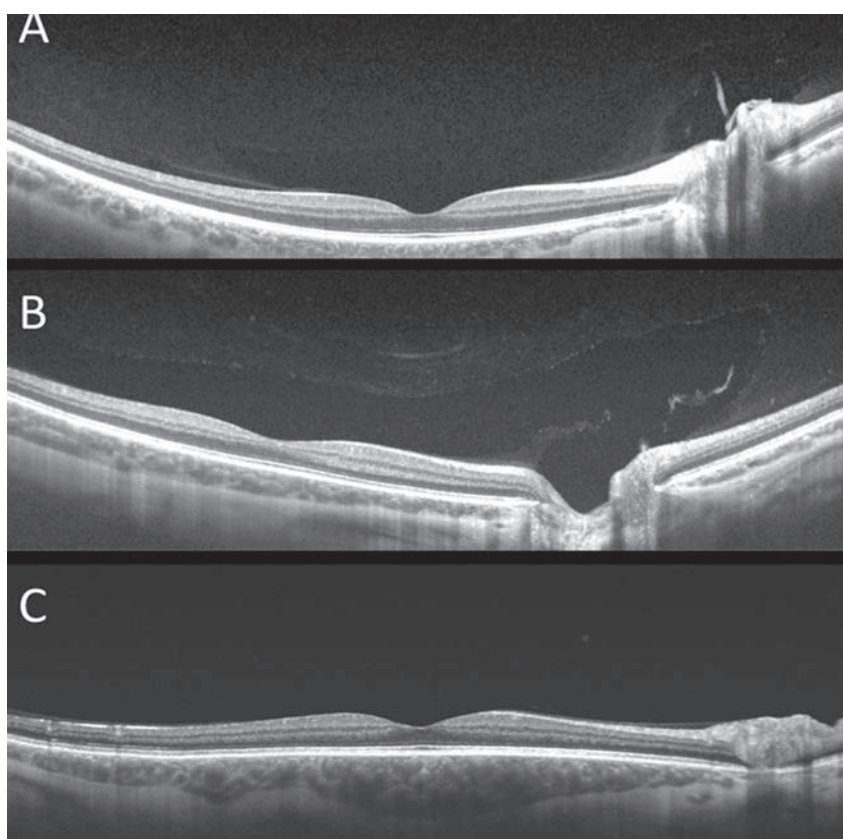


Figure 3. While the overall shape of the bursa appears to be quite consistent, there may be significant differences in size, possibly related to refractive error, age and vitreous degeneration (A, B). In this patient with Stickler's disease the bursa extends in all dimensions beyond the scan area of 18 x 18 mm (C).

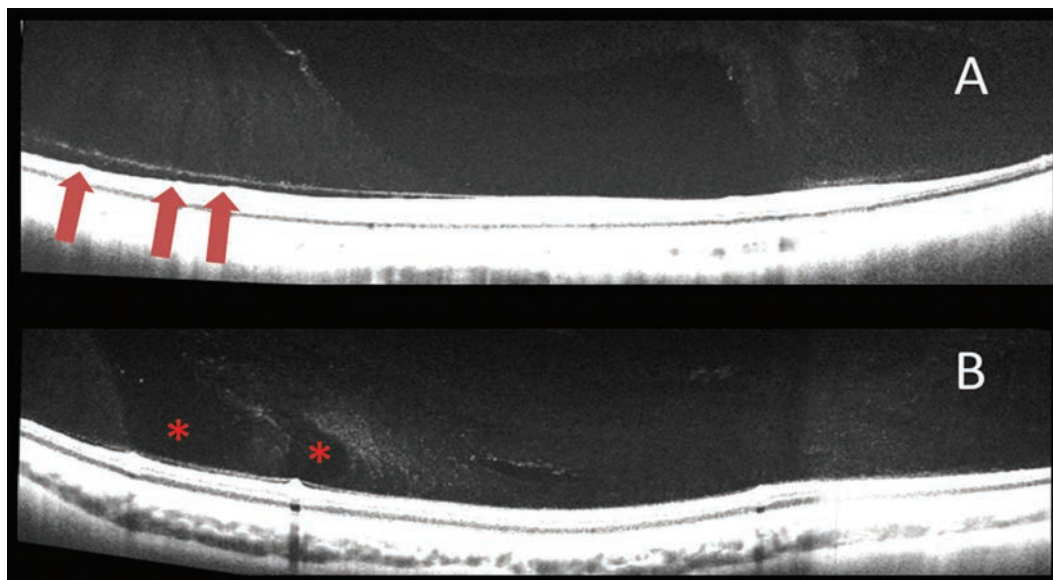


Figure 4. In eyes with little or no detectable vitreous degeneration, hyporeflective thin areas appear to emanate from the larger retinal vessels (red arrows, A). In older subjects with higher degrees of vitreous degeneration, larger areas are found in the same prevascular location (asterisks, B). The former likely correspond to Eisner’s prevascular vitreous fissures, and may represent precursors to the latter, which probably are the perimacular cisterns observed by Prof. Worst.

they separate beyond the surgically induced posterior vitreous separation and enter the line of sight, or by exerting traction and photopsias as the PVD progresses postoperatively. Unequivocally determining their presence or absence may aid in advising for repeat vitrectomy with further propagation of the PVD and close shaving to the retinal surface.

The various liquid spaces have been ascribed important roles in a variety of different diseases, including macular hole and epiretinal membrane formation,<sup>12</sup> but our understanding of the pathogenesis of these diseases has shifted the focus to the abnormal PVD and cortical vitreous remnants in a phenomenon termed vitreoschisis.

However, they may play an important role in the pathogenesis of proliferative diabetic retinopathy. Prof. Worst and Prof. Kishi both speculated that the “wolf’s jaw” configuration of fibrovascular proliferation in advanced PDR may result from proliferation of neovessels along the bursal wall.<sup>12,13</sup> They also hypothesized that

the boat-shaped hemorrhages seen in PDR came from bleeding into the premacular bursa. Since PDR can occur in both young and old individuals depending on the onset of diabetes, it is likely that the neovessels grow along different scaffolds, depending on the degree of vitreous separation and the presence or absence of vitreoschisis. One can imagine growth underneath the hyaloid as well as penetration of the latter and proliferation along the walls of the bursa, Cloquet’s canal, prevascular vitreous fissures and cisterns, as well as along vitreoschisis planes. Likewise, hemorrhages may occur in any of those spaces. Preoperative OCT is particularly helpful in these cases, as one can create a virtual map of the various planes and potentially favorable starting points, as well as forming an idea which areas may lend themselves to delamination versus segmentation.

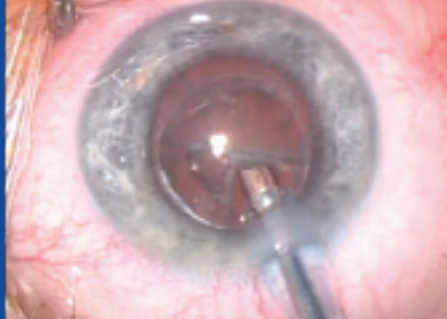In summary, vitreous imaging with SS-OCT has enhanced our understanding of both the normal vitreous anatomy and its changes during aging, as well as pathological condi-

tions, with potentially important implications for surgical treatment. **REVIEW**

*Dr. Engelbert is an attending physician and research assistant professor at the NYU School of Medicine. Contact him at Vitreous Retina Macula Consultants of New York, P.C., 460 Park Ave., 5th fl. New York, NY 10022. E-mail: michael.engelbert@gmail.com.*

1. Worst JGF. The bursa intravitrealis premacularis: New developments in ophthalmology. *Doc Ophth Proc Ser* 1976;275-9.
2. Kishi S, Shimizu K. Posterior precortical vitreous pocket. *Arch Ophthalmol* 1990;108:979-82
3. Worst JGF, Los LI. *Cisternal anatomy of the vitreous*. Amsterdam – New York: Kugler Publications 1995:24
4. Itakura H, Kishi S, Li D, Akyama H. Observation of posterior vitreous pocket using swept-source optical coherence tomography. *Invest Ophthalmol Vis Sci* 2013;54:3102-7.
5. Pang CE, Freund KB, Engelbert M. Enhanced vitreous imaging technique with spectral-domain optical coherence tomography for evaluation of posterior vitreous detachment. *JAMA Ophthalmol* 2014;132(9):1148-50.
6. Schaal K, Pang C, Pozzoni AC, Engelbert M. The premacular bursa’s shape revealed by swept-source optical coherence tomography. *Ophthalmology* 2014;121:1020-8.
7. Chen KC, Jung JJ, Engelbert M. Giant premacular bursa: A novel finding of the posterior vitreous in two patients with Stickler syndrome type 1 revealed by swept-source optical coherence tomography. *Græfe’s Arch Clin Exp Ophthalmol* 2015 Aug 6 [Epub ahead of print]
8. Pang CE, Schaal KB, Engelbert M. Association of prevascular vitreous fissures and cisterns with vitreous degeneration as assessed by swept source optical coherence tomography. *Retina* 2015;35:1875-82.
9. Eisner G. *Clinical anatomy of the vitreous*. In: Duane TD, Jaeger EA. *Biomedical Foundations of Ophthalmology*. vol.1, ch.16. Philadelphia: J.B. Lippincott Co., 1990.
10. Fine HF, Spaide RF. Visualization of the posterior precortical vitreous pocket in vivo with triamcinolone. *Arch Ophthalmol* 2006;124:1663.
11. Chen KC, Jung JJ, Engelbert M. Swept source optical coherence tomography of the posterior vitreous after pars plana vitrectomy. *Græfe’s Arch Clin Exp Ophthalmol* 2015 Apr 24 [Epub ahead of print]
12. Kishi S. Diagnostic pearls in the management of vitreomacular disorders. *Sem Ophthalmol* 1998;13:2-9.
13. Worst J. Extracapsular surgery in lens implantation (Binkhorst lecture). Part iv. Some anatomical and pathophysiological implications. *J Am Intraocul Implant Soc* 1978;4:7-14.






Save the Date



# INNOVATIVE TECHNIQUES & Controversies in Ophthalmology



FEBRUARY 12-14, 2016 • PARK CITY, UTAH  
GRAND SUMMIT AT CANYONS



**Co-Director**  
**Douglas D. Koch, M.D.**  
Houston, Texas



**Course Director**  
**Alan S. Crandall, M.D.**  
Salt Lake City, Utah



**Co-Director**  
**Stephen S. Lane M.D.**  
Minneapolis, Minnesota



**Co-Director**  
**Robert J. Cionni, M.D.**  
Salt Lake City, Utah

- Steven Charles, MD, FACS, FICS
- Garry P. Condon, MD
- David A. Crandall, MD
- James A. Davison, MD, FACS

- Kendall E. Donaldson, MD
- Nicole R. Fram, MD, FACS
- Susan M. MacDonald, MD
- Irving M. Raber, MD

- Sheri L. Rowen, MD
- Mitchell P. Weikert, MD
- Elizabeth Yeu, MD

### Schedule of Events

Agenda session times have changed this year

#### Friday, February 12

- 3:00 - 4:00PM Registration
- 4:00 - 7:00PM Evening Sessions & Working Dinner

#### Saturday, February 13

- 5:45 - 6:30AM Registration/Breakfast
- 6:30 - 12:00PM Morning Session
- 4:00 - 7:00PM Evening Session

#### Sunday, February 14

- 5:45 - 6:30AM Registration/Breakfast
- 6:30 - 12:00PM Morning Session

\*Agenda is subject to change

**Hotel Information:**  
**Grand Summit at Canyons**  
 4000 Canyons Resort Drive  
 Park City, Utah 84098

Discounted room rates are limited and based on availability, so please book early!  
 Call the hotel directly at 888-226-9667 and identify yourself as a participant of the **Park City Symposium.**

**REGISTER NOW!**  
[www.RevOPHTH.COM/PARKCITY2016](http://www.RevOPHTH.COM/PARKCITY2016)

For more information, check the registration site for faculty, agenda & number of credits or email [dholmes@postgradhealthed.com](mailto:dholmes@postgradhealthed.com) or call 866-627-0714

#### Physicians

This activity has been designed to meet the educational needs of ophthalmologists, ophthalmology residents and fellows, and other physicians and healthcare professionals involved in the care of cataract and refractive surgery patients.

#### Accreditation Statement

This activity has been planned and implemented in accordance with the accreditation requirements and policies of the Accreditation Council for Continuing Medical Education (ACCME) through the joint providership of the Institute for the Advancement of Human Behavior (IAHB) and Postgraduate Healthcare Education, LLC (PHE). The IAHB is accredited by the ACCME to provide continuing medical education for physicians.

#### Credit Designation Statement

The IAHB designates this live activity for a maximum of 15\* AMA PRA Category 1 Credits™. Physicians should claim only the credit commensurate with the extent of their participation in the activity.\*

Endorsed by

**Review Of Ophthalmology**

Jointly Provided by:

**IAHB**  
 Institute for the  
 Advancement of Human Behavior & **PHE**

Partially supported by an unrestricted independent medical educational grant from

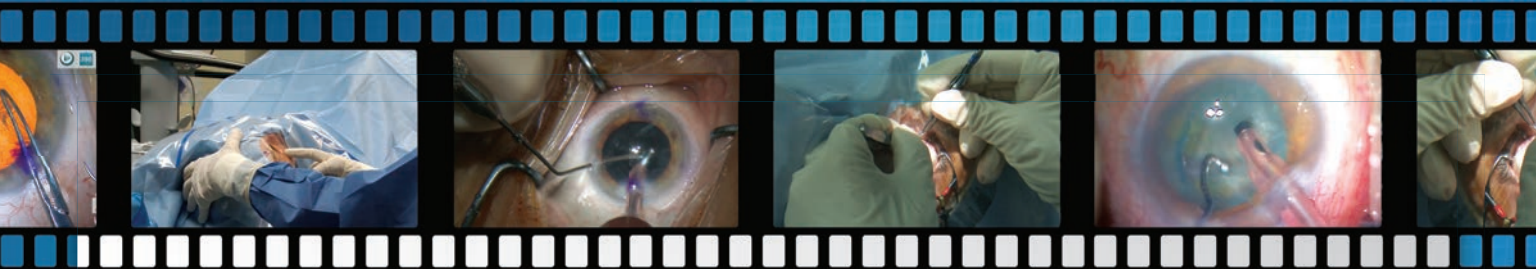
**Alcon**



Introducing

# MACKOOL ONLINE

## CME SERIES | SURGICAL VIDEOS



To view CME video  
go to:  
[www.MackoolOnlineCME.com](http://www.MackoolOnlineCME.com)

### Episode 1: My Standard Technique

Surgical Video by:  
Richard J. Mackool, MD

In our inaugural episode of Mackool Online CME, I demonstrate my standard technique for cataract removal with, in this case, implantation of a Toric IOL. Emphasis is placed on the creation and fluidics of the side port incision, proper alignment of the infusion sleeve prior to phaco, the correct foot position settings I use when chopping the nucleus and final positioning of the toric iol.

#### Accreditation Statement

This activity has been planned and implemented in accordance with the accreditation requirements and policies of the Accreditation Council for Continuing Medical Education (ACCME) through the joint providership of the Institute for the Advancement of Human Behavior (IAHB) and Postgraduate Healthcare Education, LLC (PHE). IAHB is accredited by the ACCME to provide continuing medical education for physicians.

#### Credit Designation Statement

IAHB designates this live activity for a maximum of .25 AMA PRA Category 1 Credits™. Physicians should claim only the credit commensurate with the extent of their participation in the activity.

## Introducing: MackoolOnlineCME.com



Richard Mackool, MD

I would like to welcome you to a new concept in surgeon education, Mackool Online CME.

Demonstrating ophthalmic surgical techniques has long been part of my everyday practice. Now, thanks to educational grants from several ophthalmic companies, you are able to virtually sit at the microscope with me and see the techniques and instrumentation I use with my own patients. The only editing is to show a different camera view or to remove down time – every step of every procedure will be shown just as if you are with me in the OR. We will release one new surgical video every month, allowing you to earn CME credits or simply watch the video.



**CME Accredited Surgical Training Videos Now Available Online: [www.MackoolOnlineCME.com](http://www.MackoolOnlineCME.com)**

Richard Mackool, MD, a world renowned anterior segment ophthalmic microsurgeon, has assembled a web-based video collection of surgical cases that encompass both routine and challenging cases, demonstrating both familiar and potentially unfamiliar surgical techniques using a variety of instrumentation and settings.

This educational activity aims to present a series of Dr. Mackool's surgical videos, carefully selected to address the specific learning objectives of this activity, with the goal of making surgical training available as needed online for surgeons motivated to improve or expand their surgical repertoire.

Endorsed by:  
**Review Of Ophthalmology®**

Video and Web Production by:  
**Captured Light Studio, Inc.**

Jointly Provided by:

**IAHB**  
Institute for the  
Advancement of Human Behavior

& **PHE**

Supported by an unrestricted independent  
medical educational grant from:

**Alcon**

Commercially supported by:

**Glaukos**  
Crestpoint Management  
MST

# Pain Management Options Compared

**D**espite wider spread use of 2% lidocaine gel as an anesthetic agent for ocular procedures, a group at the Department of Ophthalmology and Scientific Computing Center, SUNY Downstate Medical Center, Brooklyn, N.Y, reports that it has not yet been evaluated for use in pain reduction in outpatient eyelid surgery. The aim of their study was to investigate whether transconjunctival local anesthetic with 2% lidocaine gel can be used to reduce pain for minor eyelid procedures compared with transcutaneous administration.

The randomized controlled clinical trial enlisted 120 patients undergoing bilateral upper or lower eyelid surgery. Topical 2% lidocaine gel was administered to the palpebral conjunctiva for one minute, followed by a local transconjunctival injection. Local anesthetic was administered to the contralateral eyelid by a transcutaneous approach without use of topical anesthetic. Both injections were 1 ml of 1% lidocaine with epinephrine 1:100,000 in a 30-ga. needle. After each injection, patients rated the pain on a 0-to-10 visual analog scale. Patients were also asked for preference between the two sides.

The mean pain scores were 2.33 (standard deviation 0.98) for the transconjunctival side and 3.42 (standard deviation 0.88) for the transcutaneous side. The reduction in pain

scores for lidocaine gel-treated sides was statistically significant ( $p < 0.001$ ) when controlling for side of intervention, upper versus lower eyelid procedures, sex of participants and type of procedure. In addition, 85 percent of participants found the transconjunctival injection to be less painful than the transcutaneous ( $p < 0.001$ )

The group concludes that transconjunctival local anesthesia in conjunction with topical anesthesia with 2% lidocaine gel provides a clinically and statistically significant decrease in perceived pain when compared with transcutaneous anesthesia in patients undergoing outpatient eyelid surgery.

*Ophthalmol Plast Reconstr Surg* 2015;31:470-3.

Rafailov L, Kulak A, Weedon J, Shinder R.

## Separating Depression from Dry-Eye Disease

Research at the University of Illinois at Chicago sought to determine whether the presence of depression in dry-eye disease may cause patients to perceive symptoms in an anomalous fashion compared with patients without depression. The authors cite a similarity to the relationship between psychological and psychophysiological characteristics with fibromyalgia. They theorized that if depression were treated independently and its contribution to

patients' dry-eye symptoms were removed from the equation, then it may be possible to manage dry-eye disease with less aggressive treatments (i.e., frequency of medication intake and the type of medication).

In a case-control study, they used the Beck Depression Inventory (BDI) to measure depressive symptoms in patients with DED and controls to determine the association between depressive and DED symptoms.

Fifty-three patients with DED and 41 controls were recruited. DED symptoms were assessed using the Symptom Burden Tool and Ocular Surface Disease Index tool. Depressive symptoms were assessed using the BDI. Regression diagnostics were performed to detect outliers. Linear statistical models and polynomial regression were used to determine the relationship between depressive symptoms and DED symptoms. An independent t test was performed to determine differences in BDI scores between cases and controls. Scatter plots were generated and linear regression was used to estimate the association between scores. Logistic regression was used for the DED dichotomous outcome and depression status as exposure.

Regression models revealed that

(continued on page 71)

Equipment and Supplies

# Custom Frame Display Boards in an Instant!

Order your customized acrylic frame board in your desired size and finish. Utilize our online tool to create and price out your frame board in seconds. Smart system frame holders are included in the price!

**01** Choose your dimensions; Height & Width

**02** Choose your desired Finish/Color

**03** Choose your mounting option, with/without Standoffs

**04** See the image of your Frame Board

**05** Obtain instant Quote

**06** Place your Order

VISIT [FRAMEDISPLAYS.COM](http://FRAMEDISPLAYS.COM) AND CLICK ON CUSTOM FRAME BOARDS ICON ON THE HOME PAGE



Custom SMART System



All First time users, use code "FRAMEBOARDSALE" and save 10%

An Essilor Company



1-877-274-9300

Equipment and Supplies



**FLORIDA EYE EQUIPMENT**

**FULL SERVICE DEALER**

- Classical
- Diagnostic
- Surgical
- Retina Packages

**BUY/SELL/TRADE**  
SINCE 1989

800-336-0410

[www.floridaeye.com](http://www.floridaeye.com)

**BUYING AND SELLING PRE-OWNED OPHTHALMIC EQUIPMENT SINCE 1989**

Practice For Sale



Practice Sales • Appraisals • Consulting  
[www.PracticeConsultants.com](http://www.PracticeConsultants.com)

**PRACTICES FOR SALE NATIONWIDE**

Visit us on the Web or call us to learn more about our company and the practices we have available.

info@practiceconsultants.com  
**800-576-6935**

[www.practiceconsultants.com](http://www.practiceconsultants.com)



**Do you have Products and Services for sale?**

Call Today!  
Toll free: 888-498-1460  
E-mail: [sales@kerhgroup.com](mailto:sales@kerhgroup.com)

Space For Lease

**OFFICE SPACE FOR LEASE EXISTING 3,267 SF MEDICAL DENTAL**

Building currently occupied by a family practice dentist and is located in a highly visible shopping center. Approximately 25,000 vehicles per day. Anchored by Applebee's, OfficeDepot and Kohl's, as well as other professional, medical, and retail businesses. Situated on the busy corner of SE 270th PL & 172nd Ave SE in the busy and rapidly growing city of Covington, WA.

COVINGTON, WA

Contact: Mike Kirkland  
MK Property Services, L.L.C.  
Office: 425.888.2993, Cell: 425.455.4271  
Email: [mike@mkps.net](mailto:mike@mkps.net)

**Do You Have Positions Available?**

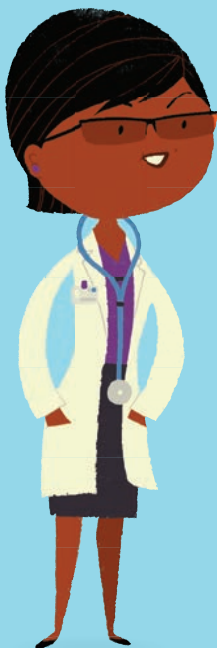Contact us today for classified advertising:  
Toll free: 888-498-1460  
E-mail: [sales@kerhgroup.com](mailto:sales@kerhgroup.com)



Career Opportunities

# General Ophthalmologist

## Minneapolis/St. Paul, Minnesota



HealthPartners Medical Group is a successful multi-specialty physician group based in Minneapolis/St. Paul, central Minnesota and western Wisconsin. Our busy Eye Care Division includes Ophthalmology, Optometry, and full service Optical. Our group of 14 Ophthalmologists includes general ophthalmologists as well as subspecialists in oculoplastics, pediatrics and retina. We're part of a highly regarded ACO, providing quality eye care to a large portion of the Twin Cities at our six well-equipped, state-of-the-art HealthPartners Eye Clinics.

We seek a full-time, BC/BE general Ophthalmologist for our metro-area practice, and encourage those with fellowship-training to apply. In addition to clinical and surgical responsibilities, you'll share in reasonable call coverage at Regions Hospital, our nationally recognized Level 1 trauma center in St. Paul.

We offer a great team of colleagues, generous benefits and compensation, and the excitement of a metropolitan practice and lifestyle. Apply online at [healthpartners.com/careers](http://healthpartners.com/careers) or email your CV and cover letter to [sandy.j.lachman@healthpartners.com](mailto:sandy.j.lachman@healthpartners.com). EOE



[healthpartners.com](http://healthpartners.com)

**REVIEW**  
of Ophthalmology

# Targeting Ophthalmologists?

**CLASSIFIED ADVERTISING  
WORKS**

Contact us today  
for classified advertising:  
Toll free: **888-498-1460**  
E-mail: [sales@kerhgroup.com](mailto:sales@kerhgroup.com)



**IMMEDIATE OPENINGS**  
Hagerstown, MD/Chambersburg, PA

High volume cataract and glaucoma practice seeks cataract/cornea/anterior segment/glaucoma ophthalmologists. State of the art clinical equipment and on site ASC. We desire motivated, patient-focused candidates with excellent surgical skills who seek to practice in a team practice setting. Maryland and PA license preferred. Salary with productivity bonus and partnership opportunity in both practice and ASC.

Send CV to: Kris Culler  
Fax 717-262-9714  
Email: [kculler@ludwickevecenter.com](mailto:kculler@ludwickevecenter.com)

Ludwick Eye Center  
825 Fifth Ave  
Chambersburg, PA 17201

**REVIEW**  
of Ophthalmology

## Do you have Products and Services for sale?

Call Today!  
Toll free: **888-498-1460**  
E-mail: [sales@kerhgroup.com](mailto:sales@kerhgroup.com)



Progressively worsening vision in one eye and recent loss of vision in the other marks a patient whose history includes syphilis.

*J. David Stephens, MD, and James P. Dunn, MD*

## Presentation

A 41-year-old man presented with one week of progressively worsening vision in the right eye, described as a black band across his visual field, and one day of vision loss in the left eye. The patient denied any other complaints on review of systems including rash, joint pain, recent illness, diarrhea, numbness, weakness, shortness of breath and chest pain. One year prior to presentation the patient had a painless penile lesion described as a pimple with some ulceration, which resolved on its own. He then developed bilateral tinnitus prior to changes in vision.

## Medical History

Past medical history was significant for syphilis, treated seven years earlier with intramuscular penicillin, and hyperthyroidism. He denied chronic medication use.

## Examination

The patient's vital signs were stable and within normal limits. Ocular examination demonstrated a best corrected visual acuity of 20/400 OD and 20/20 OS. External examination was within normal limits. Pupillary exam showed no anisocoria and no relative afferent pupillary defect. Extraocular motility was full in both eyes. Visual fields were full to confrontation OU.

Slit-lamp examination revealed 0.5+ anterior chamber cell and 1+ vitreous cell bilaterally, without conjunctival injection or posterior synechiae. Intraocular pressure was 14 mmHg OU. Fundoscopic examination of the right eye exhibited yellow, circular, placoid lesions in the macula bilaterally (See Figure 1a, 1b).

## Imaging

Fluorescein angiography showed early punctate hypofluorescence with persistent mid to late hyperfluorescence in

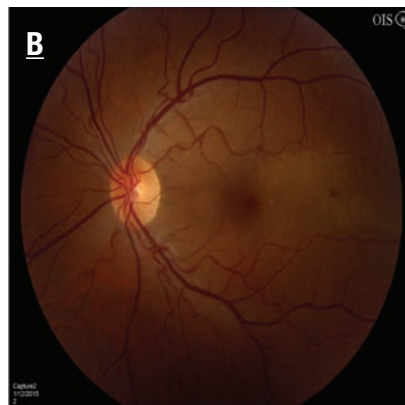
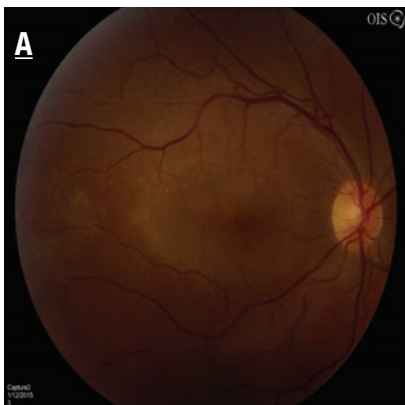

Figure 1a. Fundus photograph OD showing circular, yellow, placoid lesions in the fovea and temporal macula. Figure 1b. Fundus photograph OS showing similar yellow placoid lesions, as well as a small area of retinal hemorrhage in the temporal macula.

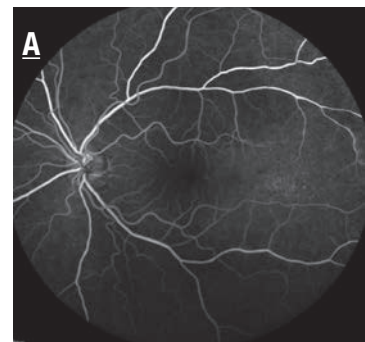


Figure 2a. Early-phase fluorescein angiography OS showing speckled hypofluorescence and scattered hyperfluorescence in the area of the placoid macular lesions.

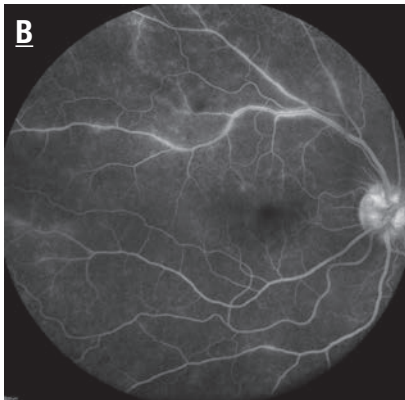


Figure 2b. Venous laminar-phase FA OD showing punctate hyperfluorescence surrounding the retinal vasculature.

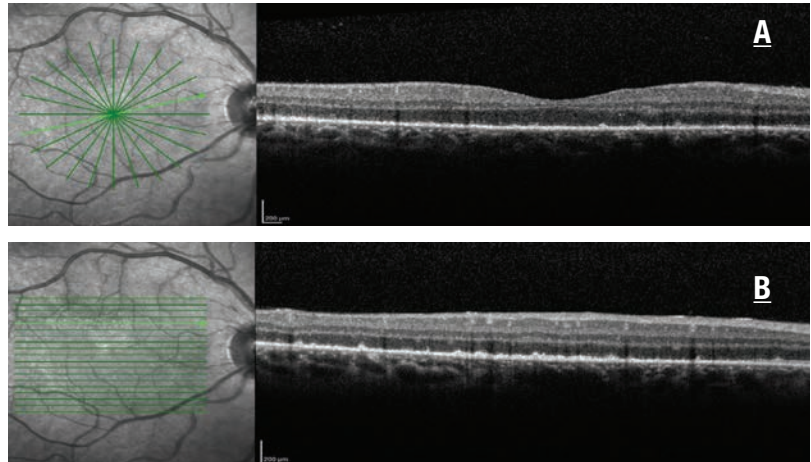


Figure 3a. Raster SD-OCT of the right eye demonstrating retinal pigment epithelium nodularity and inner segment-outer segment disruption with preserved foveal depression. The left eye demonstrated similar findings. Figure 3b. SD-OCT line scan OD demonstrating retinal pigment epithelium nodularity. The left eye demonstrated similar findings.

both eyes (See Figure 2a, left, and 2b, above). Spectral-domain optical co-

herence tomography demonstrated disruption of the junction with retinal

pigment epithelium nodularity (See Figure 3a, 3b, above).

**What is your differential diagnosis? What further workup would you pursue? Please turn to p. 72**

(continued from page 67)

the association is linear more than quadratic or cubic. After adjusting for age, sex, race and psychiatric medication, the regression coefficient between DED symptoms and depressive symptoms among DED cases was 1.22 (95% confidence interval, 0.27 to 2.18). DED symptom scores and depression scores were statistically significantly different between DED cases and controls. Adjusted logistic regression revealed an odds ratio of 2.79 (95% confidence interval, 0.96 to 8.12).

The group concludes that the study provides further evidence regarding the association between DED and depression and their symptoms. Prospective studies are needed to understand the mechanisms underlying the association between symptoms of depression and symptoms of DED.

*Cornea* 2015;34:1545-1550

Hallak J, Tibrewal S, Jain S.

**Choosing the Best IOL Power When Data May Not be Available**

**A** prospective interventional case series at the G.B. Bietti Foundation-IRCCS, Rome, Italy, compared the results of methods to calculate intraocular lens power after myopic excimer laser surgery.

Eyes were classified into four groups: Group 1 (preop keratometry available, refractive change known); Group 2 (preop keratometry available, refractive change uncertain); Group 3 (preop keratometry unavailable, refractive change known); and Group 4 (preop keratometry unavailable, refractive change unknown). The IOL power was calculated by 19 methods. The median absolute error in refraction prediction and the percentage of eyes with a refraction prediction error within  $\pm 0.5$  diopter were calculated.

In Group 1 (n=30), the Savini, Seitz/Speicher/Savini, and Masket methods provided the lowest median

absolute error (0.29 D, 0.35 D, and 0.34 D, respectively), with more than 70 percent of eyes within  $\pm 0.5$  D of the predicted refraction. In Group 2 (n=16), the Seitz/Speicher method achieved the best result (median absolute error 0.37 D), with 75 percent of eyes within  $\pm 0.5$  D of the predicted refraction. In Group 3 (n=18), the Masket method provided the lowest median absolute error (0.24 D), with 72.2 percent of eyes within  $\pm 0.5$  D of the predicted refraction. In Group 4 (n=6), the Shammas no-history method had the lowest median absolute error (0.31 D), with 83 percent of eyes within  $\pm 0.5$  D of the predicted refraction.

The researchers conclude that IOL power can be accurately calculated in post-laser surgery eyes when the preop corneal power and refractive change are known and when they are not.

*J Cataract Refract Surg* 2015;41:1880-8.

Savini G, Barboni P, Carbonelli M, Ducoli P, Hoffer KJ.

## Diagnosis, Workup and Treatment

The patient was diagnosed with bilateral chorioretinitis and retinal vasculitis with ellipsoid layer alterations. Given his clinical history and examination, the differential diagnosis consisted of infection (syphilis,

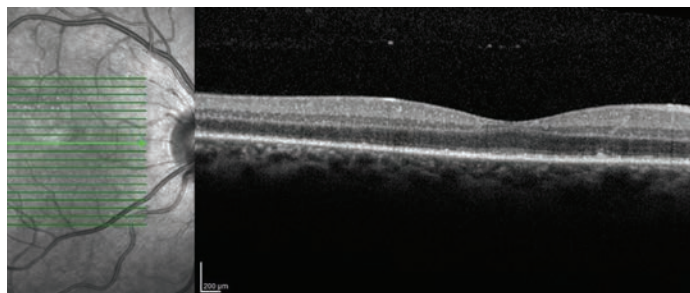
tuberculosis, Lyme disease); inflammatory diseases (sarcoidosis, granulomatosis with polyangiitis, birdshot chorioretinopathy); paraneoplastic syndromes; lymphoma; and multiple sclerosis.

and rapid plasmin reagin (RPR) at a titer of 1:128. HIV, Lyme, HLA-B27 ACE, ANA, ANCA and Quantiferon Gold were negative. The patient was diagnosed with acute syphilitic posterior placoid chorioretinitis (ASPPC), and admitted to the internal medicine service for treatment with intravenous penicillin 4 million units every four hours for 14 days. Lumbar puncture during admission was significant for negative Venereal Disease Research Laboratory testing. CSF protein was 35 mg/dL and glucose 69 mg/dL.

After treatment with penicillin, the patient had improvement in vision to 20/25 in the right eye and 20/20 in the left. Fundus photographs showed bilateral improvement in the yellow placoid lesions in the posterior pole (See Figure 4a, 4b). Follow-up SD-OCT scans demonstrated resolution of the retinal pigment epithelium nodularity and improved clarity of the inner segment-outer segment junction (See Figure 5).

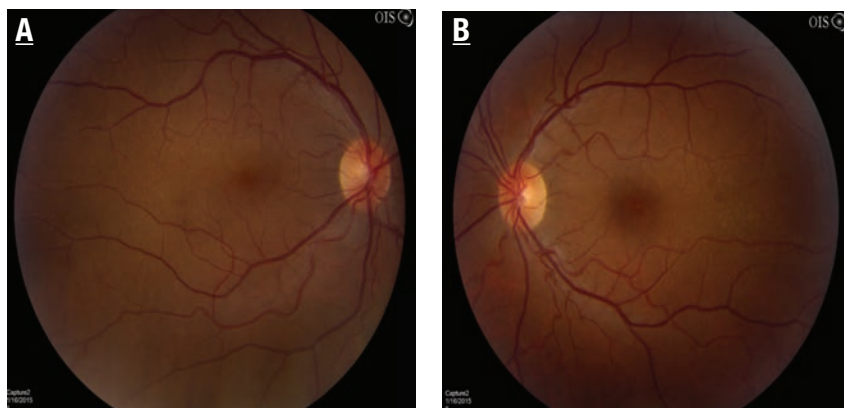

Figure 4a and Figure 4b. Fundus photos OD and OS after intravenous penicillin therapy demonstrating resolution of placoid macular lesions.



Laboratory workup revealed a positive syphilis an-

Figure 5. SD-OCT of the left eye after IV penicillin therapy showing resolution of RPE nodularity and improved clarity of the inner segment-outer segment junction.

## Discussion

Acute syphilitic posterior placoid chorioretinitis is a variant of syphilitic chorioretinitis. It is characterized by one or more outer retinal yellow, circular, placoid, lesions usually found in the macula.<sup>1</sup> The term ASPPC was first described by Donald M. Gass, MD, and colleagues, who postulated that this disease is caused by *Treponema pallidum* organisms entering the choroidal circulation to gain access to the outer retina.<sup>2</sup> In a recent retrospective analysis of 35 cases with ASPPC, patients usually presented between four and 30 days of onset of visual symptoms, and may

have unilateral or bilateral symptoms with mild anterior segment inflammation. Most patients (88 patients) had mild to moderate vitreous inflammation.<sup>1</sup>

SD-OCT findings in ASPPC show outer retinal abnormalities, which may include disruption of the inner segment/outer segment junction, nodular thickening of the retinal pigment epithelium, or loss of RPE/outer segment junction. In some cases patients may have loss of the external limiting membrane and accumulation of subretinal fluid.<sup>3</sup> Fluorescein angiography typically shows hypoflu-

orescence or faint hyperfluorescence in the early phase, with mid- and late-phase FA usually exhibiting progressive hyperfluorescence.<sup>1,4</sup>

Laboratory evaluation for ASPPC should include initial qualitative treponemal antibody assays (enzyme or chemiluminescent immunoassays) as the initial screening test. Positive tests are followed by non-treponemal RPR testing, which may then be used to quantify response to treatment.<sup>6</sup> Testing for HIV status, if unknown, should be obtained due to the high rate of co-infection and the possibility of accelerated progression to neu-



rosyphilitis in HIV-positive patients.<sup>6</sup> Although HIV has a high co-infection rate with syphilis, it does not appear to influence response to antibiotic therapy.<sup>1</sup> Once confirmed, treatment with parenteral penicillin G should be initiated. Angiographic and OCT findings are mostly reversible with appropriate therapy with IV antibiotics.<sup>1,3,4</sup> Our patient demonstrated a similar reversal of findings, with improvement in fundus appearance and OCT after antibiotics. One recent case study reported the possibility of spontaneous resolution of ASPPC.<sup>7</sup> However, due to the sight-threatening and systemic manifestations of syphilis, antibiotic therapy remains a critical component of patient care.

Between 2005 and 2013, the number of reported cases of primary and secondary syphilis cases increased from 2.9 to 5.3 cases per 100,000 people, with men accounting for 91.1 percent of cases.<sup>8</sup> As the frequency of early syphilis rises, ophthalmologists may be confronted with more cases of syphilitic uveitis.<sup>6</sup> Although ASPPC is an unusual manifestation of syphilis, it is critical to maintain a high index of suspicion in this rare but distinct manifestation of ocular syphilis and to initiate appropriate therapy promptly. **REVIEW**

1. Eandi CM, Neri P, Adelman RA, et al. Acute syphilitic posterior placoid chorioretinitis: Report of a case series and comprehensive review of the literature. *Retina* 2012;32:1915-1941
2. Gass JDM, Braunstein RA, Chenoweth RG. Acute syphilitic posterior placoid chorioretinitis. *Ophthalmology* 1990;97:1288-1297.
3. Pichi F, Ciardella AP, Cunningham ET Jr. Spectral-domain optical coherence tomography findings in patients with acute syphilitic posterior placoid chorioretinitis. *Retina* 2014;34:373-384
4. Brito P, Penas S, Carneiro A. Spectral-domain optical coherence tomography features of acute syphilitic posterior placoid chorioretinitis: the role of autoimmune response in pathogenesis. *Case Rep Ophthalmol* 2011;2:39-44
5. Veys MC, Lafaut B. Ocular syphilis, a case of acute posterior placoid chorioretinitis. *Bull Soc Belge Ophthalmol* 2013;322:21-25.
6. Davis JL. Ocular syphilis. *Curr Opin Ophthalmol*. 2014;25(6):513-8.
7. Aranda S, Amer R. Sequential spontaneous resolution of acute syphilitic posterior placoid chorioretinitis. *Eur J Ophthalmol*. 2015; 25(3):263-5.
8. Patton ME, Su JR, Nelson R, Weinstock H; Centers for Disease Control and Prevention (CDC). Primary and secondary syphilis--United States, 2005-2013. *MMWR Morb Mortal Wkly Rep* 2014;63(18):402-6.

(continued from page 30)

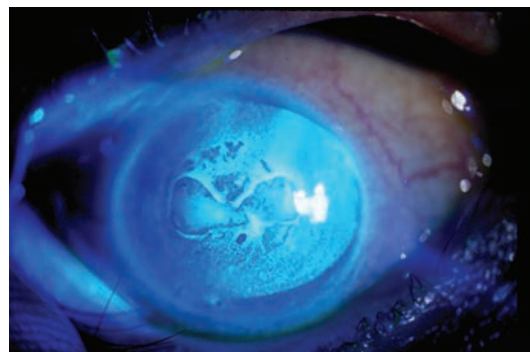
silicone lens, so you might end up having to exchange the IOL. However, this is not common today.”

Dr. Donnenfeld observes one advantage that silicone lenses appear to have over acrylics. “I’m not aware of any circumstances in which using an acrylic lens would be inappropriate, but there have been concerns about glistenings with acrylic lenses,” he says. “You don’t get glistenings with silicone lenses.”

“In general, I prefer to implant acrylic hydrophobic lenses in eyes that have had a previous vitrectomy,” says Dr. Alio. “I never use silicone lenses. In my experience, silicone lenses are much more fragile, and they decenter more easily than the acrylic lenses. They don’t fit as well in the posterior capsule. And in cases of previous vitrectomy, many cases have had silicone oil in the eye; silicone with silicone doesn’t produce good results in the postoperative period.”

• **Piggyback lens.** “There are times when a patient has had previous refractive surgery and the best refractive outcome is achieved by adding a piggyback lens,” says Dr. Donnenfeld. “Under these circumstances it’s always best to have one lens in the bag and one lens in the sulcus. The lens in the sulcus, of course, should be a three-piece lens. In addition, it’s been found that it’s best if the two lenses are made of different materials. So if a silicone lens is in the bag, place an acrylic lens in the sulcus, and vice versa. When the piggyback lens is made of the same material there are interface issues; the result is always more inflammation.”

• **Patients who have Fuchs’ dystrophy.** “In these patients I like placing a lens that leaves the patient mildly myopic,” says Dr. Donnenfeld. “They may need a DSEK in the future, which



Eric D. Donnenfeld, MD

An eye with Fuchs’ dystrophy. In this situation, some surgeons recommend implanting a lens that will leave the patient mildly myopic, because a possible future DSEK could induce a diopter of hyperopia.

could induce a diopter of hyperopia.”

• **A family history of macular degeneration.** “Many surgeons avoid using a multifocal in a patient with a family history of macular degeneration,” notes Dr. Mackool. “They’re thinking, ‘What if the patient gets macular degeneration down the road?’

“I don’t buy that reasoning,” he says. “It’s OK to use a multifocal in those patients, because first of all, you don’t know whether they’ll ever get macular degeneration. Second, medicine is likely to progress in the years ahead. Who knows what kind of therapies will appear in the next few years, therapies that may prevent them from getting the disease or at least keep it from becoming serious? And even if you do need to change the IOL at some point in the future, there may be new techniques for accomplishing that. Third, with a lens like the ReSTOR 2.5, which has far less impact on distance vision, the lens is much less likely to be an issue even if the disease does appear. So I don’t think it makes sense to limit your options too much because the patient might have a problem at some point in the future.” **REVIEW**

Dr. Mackool is a consultant to Alcon. Dr. Donnenfeld is a consultant for Alcon, Bausch + Lomb, Zeiss and Abbott. Dr. Alio has no financial ties to any product discussed.

# REVIEW Advertising Index

For advertising opportunities contact:

Michelle Barrett (215) 519-1414  
or mbarrett@jobson.com

James Henne (610) 492-1017  
or jhenne@jobson.com

Michael Hoster (610) 492-1028  
or mhoster@jobson.com

**Abbott Medical Optics, Inc. (AMO)** 13, 14  
Phone (800) 366-6554

**Akorn Consumer Health** 45  
Phone (800) 579-8327  
www.akornconsumerhealth.com

**Alcon Laboratories** 2-3  
Phone (800) 451-3937  
Fax (817) 551-4352

**Allergan, Inc.** 74, 76  
Phone (800) 347-4500

**Bausch + Lomb** 9, 10, 21, 35, 36  
Phone (800) 323-0000  
Fax (813) 975-7762

**Keeler Instruments** 7, 75  
Phone (800) 523-5620  
Fax (610) 353-7814

**Lombart Instruments** 51  
Phone (800) 446-8092  
Fax (757) 855-1232

**Omeros** 16-17  
Phone (206) 676-5000  
Fax (206) 676-5005

**Paragon BioTeck, Inc.** 31  
Phone (888) 424-1192  
www.paragonbioteck.com

**Rhein Medical** 5  
Phone (800) 637-4346  
Fax (727) 341-8123

**S4OPTIK** 27, 29  
Phone (888) 224-6012

**University of Pittsburgh** 47  
Phone (800) 533-UPMC  
www.upmc.com

This advertiser index is published as a convenience and not as part of the advertising contract. Every care will be taken to index correctly. No allowance will be made for errors due to spelling, incorrect page number, or failure to insert.

## RESTASIS® (Cyclosporine Ophthalmic Emulsion) 0.05%

**BRIEF SUMMARY—PLEASE SEE THE RESTASIS® PACKAGE INSERT FOR FULL PRESCRIBING INFORMATION.**

### INDICATION AND USAGE

RESTASIS® ophthalmic emulsion is indicated to increase tear production in patients whose tear production is presumed to be suppressed due to ocular inflammation associated with keratoconjunctivitis sicca. Increased tear production was not seen in patients currently taking topical anti-inflammatory drugs or using punctal plugs.

### CONTRAINDICATIONS

RESTASIS® is contraindicated in patients with known or suspected hypersensitivity to any of the ingredients in the formulation.

### WARNINGS AND PRECAUTIONS

#### Potential for Eye Injury and Contamination

To avoid the potential for eye injury and contamination, be careful not to touch the vial tip to your eye or other surfaces.

#### Use with Contact Lenses

RESTASIS® should not be administered while wearing contact lenses. Patients with decreased tear production typically should not wear contact lenses. If contact lenses are worn, they should be removed prior to the administration of the emulsion. Lenses may be reinserted 15 minutes following administration of RESTASIS® ophthalmic emulsion.

### ADVERSE REACTIONS

#### Clinical Trials Experience

Because clinical trials are conducted under widely varying conditions, adverse reaction rates observed in the clinical trials of a drug cannot be directly compared to rates in the clinical trials of another drug and may not reflect the rates observed in practice.

In clinical trials, the most common adverse reaction following the use of RESTASIS® was ocular burning (17%).

Other reactions reported in 1% to 5% of patients included conjunctival hyperemia, discharge, epiphora, eye pain, foreign body sensation, pruritus, stinging, and visual disturbance (most often blurring).

#### Post-marketing Experience

The following adverse reactions have been identified during post approval use of RESTASIS®. Because these reactions are reported voluntarily from a population of uncertain size, it is not always possible to reliably estimate their frequency or establish a causal relationship to drug exposure.

Reported reactions have included: hypersensitivity (including eye swelling, urticaria, rare cases of severe angioedema, face swelling, tongue swelling, pharyngeal edema, and dyspnea); and superficial injury of the eye (from the vial tip touching the eye during administration).

### USE IN SPECIFIC POPULATIONS

#### Pregnancy

#### Teratogenic Effects: Pregnancy Category C

Adverse effects were seen in reproduction studies in rats and rabbits only at dose levels toxic to dams. At toxic doses (rats at 30 mg/kg/day and rabbits at 100 mg/kg/day), cyclosporine oral solution, USP, was embryo- and fetotoxic as indicated by increased pre- and postnatal mortality and reduced fetal weight together with related skeletal retardations. These doses are 5,000 and 32,000 times greater (normalized to body surface area), respectively, than the daily human dose of one drop (approximately 28 mcL) of 0.05% RESTASIS® twice daily into each eye of a 60 kg person (0.001 mg/kg/day), assuming that the entire dose is absorbed. No evidence of embryofetal toxicity was observed in rats or rabbits receiving cyclosporine at oral doses up to 17 mg/kg/day or 30 mg/kg/day, respectively, during organogenesis. These doses in rats and rabbits are approximately 3,000 and 10,000 times greater (normalized to body surface area), respectively, than the daily human dose.

Offspring of rats receiving a 45 mg/kg/day oral dose of cyclosporine from Day 15 of pregnancy until Day 21 postpartum, a maternally toxic level, exhibited an increase in postnatal mortality; this dose is 7,000 times greater than the daily human topical dose (0.001 mg/kg/day) normalized to body surface area assuming that the entire dose is absorbed. No adverse events were observed at oral doses up to 15 mg/kg/day (2,000 times greater than the daily human dose).

There are no adequate and well-controlled studies of RESTASIS® in pregnant women. RESTASIS® should be administered to a pregnant woman only if clearly needed.

#### Nursing Mothers

Cyclosporine is known to be excreted in human milk following systemic administration, but excretion in human milk after topical treatment has not been investigated. Although blood concentrations are undetectable after topical administration of RESTASIS® ophthalmic emulsion, caution should be exercised when RESTASIS® is administered to a nursing woman.

#### Pediatric Use

The safety and efficacy of RESTASIS® ophthalmic emulsion have not been established in pediatric patients below the age of 16.

#### Geriatric Use

No overall difference in safety or effectiveness has been observed between elderly and younger patients.

### NONCLINICAL TOXICOLOGY

#### Carcinogenesis, Mutagenesis, Impairment of Fertility

**Carcinogenesis:** Systemic carcinogenicity studies were carried out in male and female mice and rats. In the 78-week oral (diet) mouse study, at doses of 1, 4, and 16 mg/kg/day, evidence of a statistically significant trend was found for lymphocytic lymphomas in females, and the incidence of hepatocellular carcinomas in mid-dose males significantly exceeded the control value.

In the 24-month oral (diet) rat study, conducted at 0.5, 2, and 8 mg/kg/day, pancreatic islet cell adenomas significantly exceeded the control rate in the low-dose level. The hepatocellular carcinomas and pancreatic islet cell adenomas were not dose related. The low doses in mice and rats are approximately 80 times greater (normalized to body surface area) than the daily human dose of one drop (approximately 28 mcL) of 0.05% RESTASIS® twice daily into each eye of a 60 kg person (0.001 mg/kg/day), assuming that the entire dose is absorbed.

**Mutagenesis:** Cyclosporine has not been found to be mutagenic/genotoxic in the Ames Test, the V79-HGPRT Test, the micronucleus test in mice and Chinese hamsters, the chromosome-aberration tests in Chinese hamster bone-marrow, the mouse dominant lethal assay, and the DNA-repair test in sperm from treated mice. A study analyzing sister chromatid exchange (SCE) induction by cyclosporine using human lymphocytes *in vitro* gave indication of a positive effect (i.e., induction of SCE).

**Impairment of Fertility:** No impairment in fertility was demonstrated in studies in male and female rats receiving oral doses of cyclosporine up to 15 mg/kg/day (approximately 2,000 times the human daily dose of 0.001 mg/kg/day normalized to body surface area) for 9 weeks (male) and 2 weeks (female) prior to mating.

### PATIENT COUNSELING INFORMATION

#### Handling the Container

Advise patients to not allow the tip of the vial to touch the eye or any surface, as this may contaminate the emulsion. To avoid the potential for injury to the eye, advise patients to not touch the vial tip to their eye.

#### Use with Contact Lenses

RESTASIS® should not be administered while wearing contact lenses. Patients with decreased tear production typically should not wear contact lenses. Advise patients that if contact lenses are worn, they should be removed prior to the administration of the emulsion. Lenses may be reinserted 15 minutes following administration of RESTASIS® ophthalmic emulsion.

#### Administration

Advise patients that the emulsion from one individual single-use vial is to be used immediately after opening for administration to one or both eyes, and the remaining contents should be discarded immediately after administration.

#### Rx Only



Based on package insert 71876US18

© 2014 Allergan, Inc.

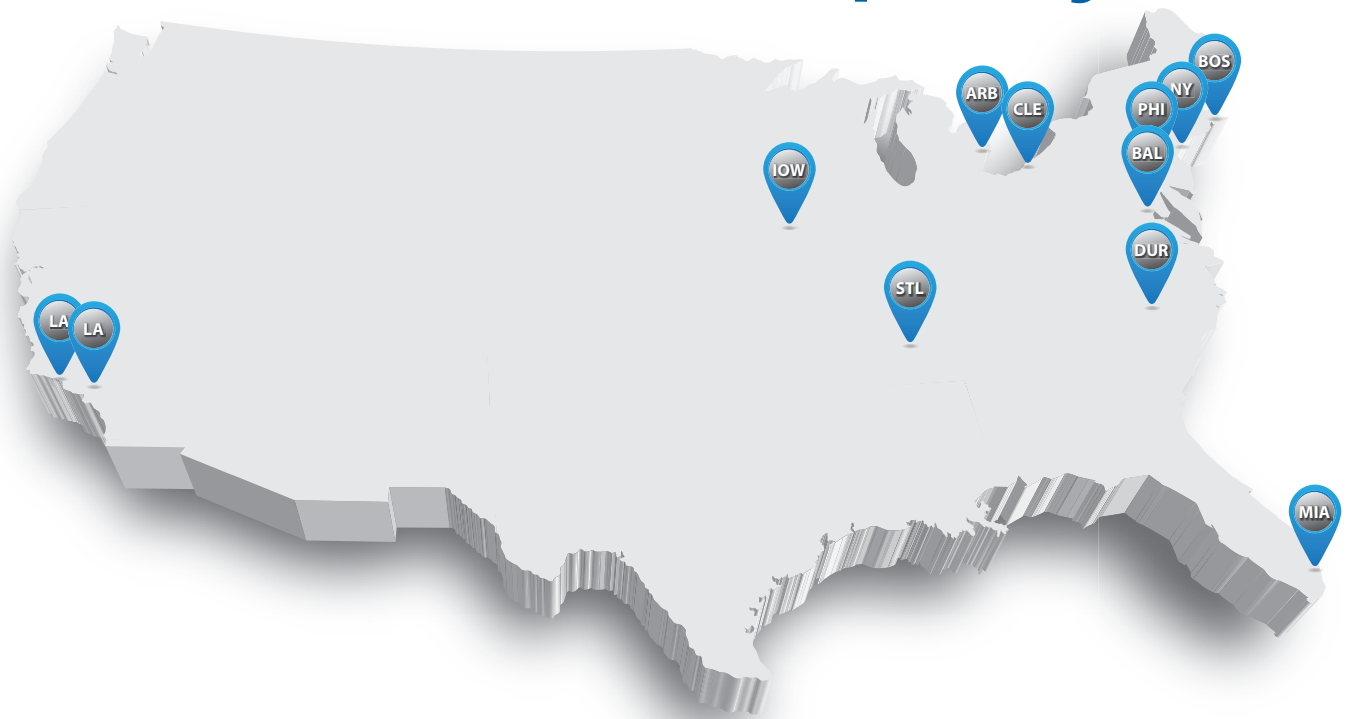
Irvine, CA 92612, U.S.A.

® marks owned by Allergan, Inc. APC21XT14

Patented. See www.allergan.com/products/patent\_notices

Made in the U.S.A.

# Great Company



Where will you find Keeler's Vantage Plus?  
Easy...the top 12 ophthalmology centers in the US\*.

## Keeler Vantage Plus

- Intelligent Optics for superior views (US Patent: 8,132,915)
- HiMag™ Lens for detailed magnified views
- Convertible Illumination LED and Xenon
- Lightest Wireless System



Get a  
**Free Keeler Indirect**  
When You  
Buy Any 3 Keeler Indirects,  
& Trade-in Any 3 Indirects  
through March 31, 2016  
Learn more at [www.keelerusa.com](http://www.keelerusa.com)

\*Top-ranked hospitals for ophthalmology –  
Source: U.S. News & World Report

Buy Online!  
[keelerusa.com](http://keelerusa.com)



**Keeler**  
OPTICS



For patients with decreased tear production presumed to be due to ocular inflammation associated with Chronic Dry Eye

## THE DRY EYE TREATMENT SHE NEEDS TODAY. BECAUSE TOMORROW MATTERS.



### RESTASIS® twice a day, every day, helps patients experience increased tear production

Increased tear production was seen at 6 months.<sup>1</sup>

#### Indication and Usage

RESTASIS® (cyclosporine ophthalmic emulsion) 0.05% is indicated to increase tear production in patients whose tear production is presumed to be suppressed due to ocular inflammation associated with keratoconjunctivitis sicca. Increased tear production was not seen in patients currently taking topical anti-inflammatory drugs or using punctal plugs.

#### Important Safety Information

##### Contraindications

RESTASIS® is contraindicated in patients with known or suspected hypersensitivity to any of the ingredients in the formulation.

##### Warnings and Precautions

**Potential for Eye Injury and Contamination:** To avoid the potential for eye injury and contamination, individuals prescribed RESTASIS® should not touch the vial tip to their eye or other surfaces.

**Use With Contact Lenses:** RESTASIS® should not be administered while wearing contact lenses. If contact lenses are worn, they should be removed prior to the administration of the emulsion. Lenses may be reinserted 15 minutes following administration of RESTASIS® ophthalmic emulsion.

##### Adverse Reactions

In clinical trials, the most common adverse reaction following the use of RESTASIS® was ocular burning (upon instillation)—17%. Other reactions reported in 1% to 5% of patients included conjunctival hyperemia, discharge, epiphora, eye pain, foreign body sensation, pruritus, stinging, and visual disturbance (most often blurring).

**Please see Brief Summary of the full Prescribing Information on adjacent page.**

Reference: 1. RESTASIS® Prescribing Information.



©2015 Allergan, Inc., Irvine, CA 92612  
\*marks owned by Allergan, Inc.  
APC55DL15 152887