

Accelerate Healing of the Ocular Surface Prior to Cataract and Refractive Surgery

Roundtable Panel



Richard L. Lindstrom, MD (Moderator), is the founder of and an attending surgeon at Minnesota Eye Consultants as well as adjunct professor emeritus at the University of Minnesota Department of Ophthalmology.



Mary E. Davidian, MD, is the founder and medical director of Highland Ophthalmology Associates LLC. She is an associate adjunct professor of Ophthalmology at The New York Eye and Ear Infirmary and New York Medical College.



Scott G. Hauswirth, OD, practices at Minnesota Eye Consultants, where he leads the optometric student externship program. He is an adjunct clinical professor at four colleges of optometry.



John D. Sheppard, MD, MMSc, is president of Virginia Eye Consultants and Professor of Ophthalmology, Microbiology & Molecular Biology at Eastern Virginia Medical School.



Scheffer C.G. Tseng, MD, PhD, is co-founder and chief scientific officer at TissueTech Inc. and also co-founder of Bio-Tissue.



Elizabeth Yeu, MD, is in private practice at Virginia Eye Consultants and serves as an assistant professor in the department of Ophthalmology at Eastern Virginia.

Outcomes following cataract and refractive surgery are determined largely by the condition of the preoperative ocular surface. As the following discussion clearly illustrates, patients with dry eye and mild or severe epithelial basement membrane dystrophy risk suboptimal results because preoperative calculations and healing both can be affected by compromised surface health.

Superficial keratectomy offers an opportunity to truly optimize the ocular surface. However, these procedures are onerous for the surgeon and significantly unpleasant for patients. This reality is one we need to carefully weigh and one we will explore in depth in the following roundtable discussion.

One thing is clear as we begin this conversation: there is a meaningful, unmet need to be able to more effectively prepare or restore the ocular surface prior to cataract and refractive surgery. It is our goal today to determine how best to address this often overlooked indication.

—Richard L. Lindstrom, MD, Moderator

DIAGNOSING EBMD

Dr. Lindstrom: It's been said that EBMD, also known as map-dot-fingerprint dystrophy, is the most common corneal dystrophy.¹ What is the exact incidence and prevalence?

Scott G. Hauswirth, OD: Although the literature is variable, it may affect as many as 42 percent of all ages worldwide, and about 76 percent over the age of 50.²

Scheffer C.G. Tseng, MD, PhD: Although these are the reported figures, because it is so often missed, I don't think anyone can know the exact number. In many cases, the eye almost looks completely normal. But, histologically, EBMD is characterized by an anomalous basement membrane that may extend into the epithelial layer inducing abnormalities of epithelial cell morphology and poor adhesion around the basement membrane.³⁻¹⁰

Dr. Lindstrom: What can we do to ensure we don't miss the diagnosis?

John D. Sheppard, MD, MMSc: One great way to find EBMD is just to look for negative fluorescein staining defects. Often, I'm concerned that these areas may be the source of intermittent symptoms in otherwise unidentified EBMD. Then, when I perform keratectomy, I discover that the defect isn't limited to that one focal area. Rather, the epithelium is diffusely defective and non-adherent throughout the cornea.

Dr. Hauswirth: I find that a careful look with direct beam is often productive, and I agree that looking for areas of negative staining is extremely valuable.

Mary E. Davidian, MD: I usually like to stain these patients with fluorescein strips following an application of proparacaine because it offers a thin application. The thicker

The PROKERA® Family of Products

By Elizabeth Yeu, MD

PROKERA® is a class II medical device comprised of a cryopreserved amniotic membrane graft fastened to a plastic ring set; it must be kept or stored in the freezer. Recently, Bio-Tissue introduced two additions to the PROKERA® family of products: PROKERA® SLIM and PROKERA® PLUS.

PROKERA® SLIM with ComfortRING™ Technology was designed with a slim profile that contours to the ocular surface, moves with the eye and maximizes amniotic membrane contact with the cornea, limbus and limbal stem cells, providing clinical benefits and maximizing patient comfort.

PROKERA® PLUS incorporates multiple layers of amniotic membrane that make it suitable for therapeutic applications requiring longer biologic action and durability on the ocular surface. It is recommended for use in severe indications such as chemical burns, Stevens-Johnson syndrome and severe corneal ulcers. In most cases of classical basement membrane dystrophy and, generally speaking, to prepare the ocular surface for cataract surgery with or without superficial keratectomy, I would select the PROKERA® SLIM. It has made this treatment option much more comfortable and has inspired me to utilize it earlier in the ocular surface disease process.

fluorescein sodium and benoxinate hydrochloride ophthalmic solution, USP 0.25%/0.4% (Fluress, Akorn Inc.) tends to sometimes mask negative staining, making it easier to miss subtler cases. Patient descrip-

tions are important too. If a patient describes chronic foreign body sensation that isn't meaningfully reflected in my exam, that's a clue.

Dr. Tseng: We perform a test that we call the screwdriver test.¹¹ You apply a dry Weck-Cel sponge (Beaver-Visitec International) directly to the cornea and make a 90-degree twist. If you create a capsulorhexis type of break, you can make the diagnosis. With a normal corneal epithelium, no wrinkle will appear. I use the screwdriver test when there is no negative staining, yet I know something's not right.

Dr. Lindstrom: I've heard this described as the wet carpet test; if you touch it with a cotton swab and you can move the epithelium a little bit, then you have reason to be suspicious.

Dr. Sheppard: Another trick is to dilate the patient and use retroillumination. The red reflex will bring out a lot of corneal pathologies. Sometimes, you'll actually see those reduplications in the basement membrane much better on retroillumination. Fuchs' dystrophy lights up beautifully that way too.

Dr. Lindstrom: In my practice, I usually see patients when they are already dilated, so I've also found retroillumination to be the most powerful tool I have. I also use oblique broad beam illumination and then also take a look at surface irregularity with the blue light.

Elizabeth Yeu, MD: We also perform topography prior to dilation. It's revealing to see the regularity of the placido disc rings and the regularity of the axial map image. If there are any suspicious steep or flat spots, I look even harder to find out what's going on there and determine if it's an epithelial-based mechanical disease. Also, the epithelium binds the weakest superiorly. So, even if you don't see EBMD anywhere else, if you lift

the superior lid margin, it's very common to discover a small little island or a ridge of EBMD close to the limbus.

Dr. Sheppard: I agree. You have to flip the lid. That huge mass of ocular surface is undetectable on a routine exam and you may see something that otherwise wouldn't be found on the routine surface exam. The average person blinks at least 16 times per minute—more than 15,000 times over a 16-hour day while awake. Surface irregularities, follicles, ingrown lashes, distichiasis and concretions are deleterious to corneal epithelial health.

Dr. Hauswirth: It can be particularly difficult to find underlying EBMD patients with punctate keratopathy. In these cases, I look for the development of macro-punctate staining and little clumps of staining that don't seem to change much over time. I find that many of these patients have underlying basement membrane dystrophy as well.

Dr. Lindstrom: I now routinely get topography on all of my cataract patients because otherwise you can miss things. I also look at tear film osmolarity, which sometimes raises a red flag. What role do these adjuncts have in your practice? Are they routine or do you rely on your slit lamp exam and then only order them when you need them?

Dr. Yeu: The goal with cataract surgery is to hit a home run, and these new tests can help with the preoperative management. I like to get both InflammDry (Rapid Pathogen Screening Inc.) and tear osmolarity. When there is a disparity between the findings, it gives me pause to take a greater look at what else could be going on.

Dr. Lindstrom: Are there any other diagnostics that you use?

EBMD Patient Wants Premium IOL A.S.A.P.

By John D. Sheppard, MD, MMSc

A 61-year-old white female with epithelial basement membrane dystrophy, Sjögren's syndrome, astigmatism, presbyopia and 2+ cortical cataract presented keenly interested in a premium cataract procedure. This type-A patient had been with our practice for several years. Upon examination, her best-corrected visual acuity was 20/100 OD, 20/50 OS and she had significant glare (>20/400 OU). In fact, she couldn't even drive. Other exam findings included IOP of 16 mmHg OU, diffuse punctate epithelial keratopathy, poor meniscus, mild meibomian

seemed to have more pronounced ocular surface disease as is evident on the Orbscan corneal topographer (Bausch + Lomb) (see **Figure 1**). Next, we looked at the Lenstar (Haag-Streit), which showed a significant difference in the astigmatic measurement compared to the OPD Scan (Nidek) (see **Figure 2**). The complete picture was as follows:

- Orbscan: 3mm zone irregularity = 4.4D
- Atlas: +2 spherical aberration -1.25 coma
- OPD Cylinder: 1.65D @ 98o
- OPD: Corneal Coma 1.478
- Lenstar Cylinder: 1.21D @ 75
- IOL: 27

It's in situations like this where we have to back up because if you don't have correlation between your various measurements of astigmatism, it will cause trouble. The patient was a busy professional and wanted to have her cataract surgery done over a holiday, but we had no choice but to take her off of the schedule.

The predominant finding in this case was the punctate keratopathy, but the patient had underlying postrefractive EBMD as well. So now, the question before us was: do we treat medically, do we perform superficial keratectomy or do we try something else? We decided on the following treatment plan:

- ProLong 0.5-mm, three-month punctal plugs (FCI Ophthalmics), both lower lids
- Cyclosporine ophthalmic emulsion 0.05% (Restasis, Allergan) b.i.d. OU
- Loteprednol etabonate ophthalmic gel 0.5% (Lotemax Gel, Bausch + Lomb) h.s. OU
- HydroEye (ScienceBased Health) 2 p.o. b.i.d.

Two weeks later, the patient returned for follow-up and we were not overly impressed with her response to traditional therapy. At this point, we utilized PROKERA[®] SLIM technology, and the amniotic membrane was fully absorbed at day seven, at which point we removed the membrane.

On this very same day, we repeated the patient's measurements, which were as follows:

- OPD: 1.60D @ 96o
- OPD: Corneal Coma 0.409
- Lenstar: 1.70 D @ 67
- IOL: 27.50

Beyond the improved correlation between the OPD and the Lenstar cylinder power, most impressively we found that the higher-order aberrations had improved remarkably, more than three-fold. We also compared the IOL calculations to those that were obtained with the initial evaluation. In the right eye, there was a half diopter spherical difference following PROKERA[®] removal, which may have led to a hyperopic surprise without the second biometry. Still, full resolution of the axis discrepancy should occur prior to final calculation and implantation.

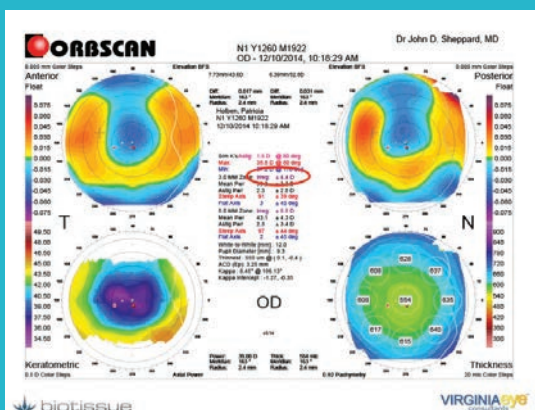


Figure 1. This patient's right eye shows more pronounced ocular surface disease.

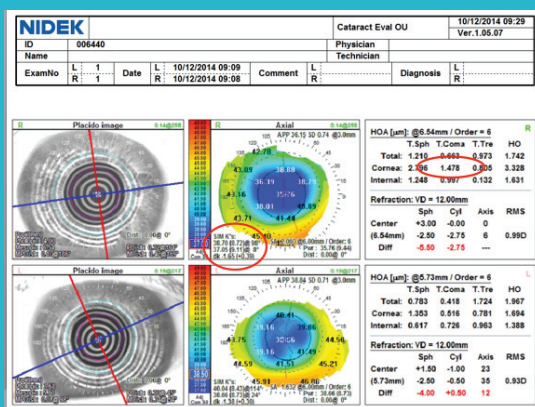


Figure 2. A preoperative look at the patient's astigmatism.

gland disease and a very rapid tear flow breakup time of less than five seconds.

The patient was very disappointed in the recent downward spiral in her vision and missed her normal way of life. She wanted surgery right away. However, as suspected, we discovered some very significant findings on her ocular surface when she returned for her cataract evaluation.

The right eye was her dominant eye and it

PROKERA® with Superficial Keratectomy Reduces Cylinder by 1.00D

By Mary E. Davidian, MD

A 63-year-old female with a history of epithelial basement membrane dystrophy and dry eyes had been referred by her optometrist in 2011 for evaluation of increased blurriness. She had some mild cataracts present at that time. She was treated with a tapering course of loteprednol etabonate ophthalmic gel 0.5% (Lotemax Gel, Bausch + Lomb), cyclosporine ophthalmic emulsion 0.05% (Restasis, Allergan) b.i.d., frequent tears and oral omega-3s. Bilateral punctal plugs also were placed, resulting in satisfactory improvement in symptoms.

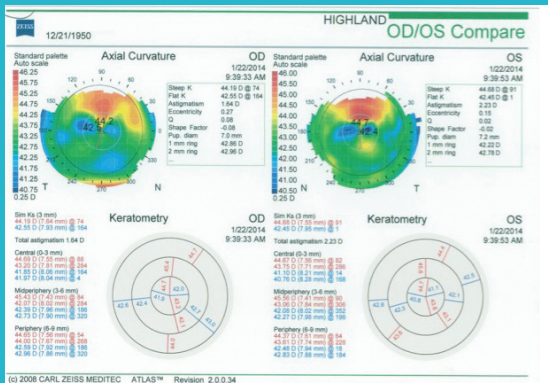
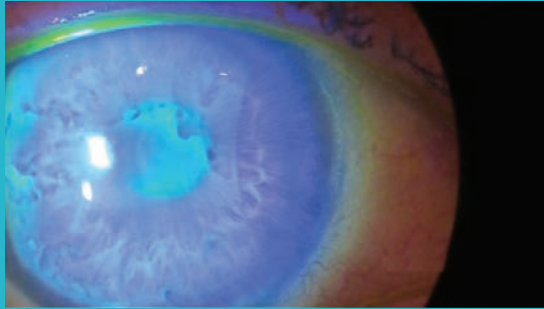
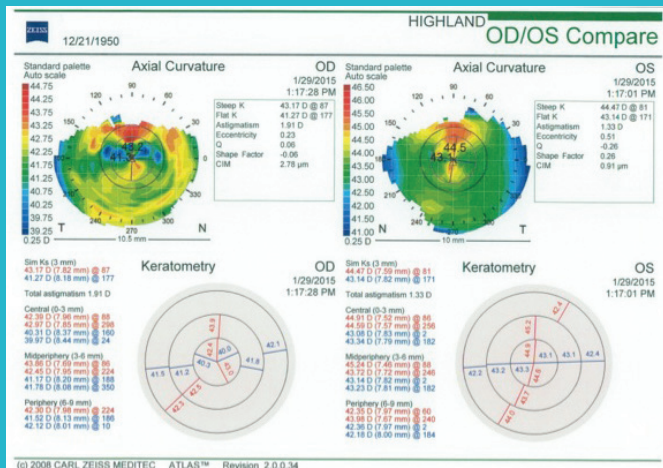
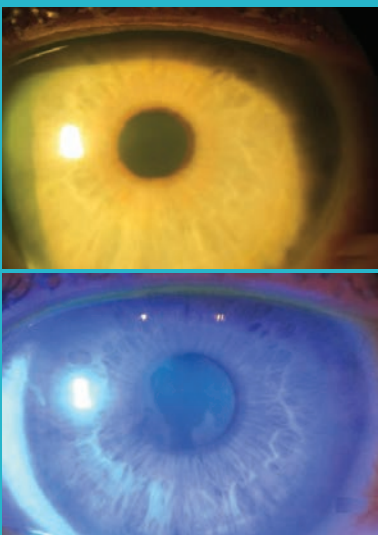


Figure 1 (top): Evidence of moderate cataract in a 63-year-old female with a history of EBMD.
Figure 2 (bottom): Pre-procedure topography of same patient.

The patient returned three years later, stating that she had tremendous difficulty driving at night due to severe glare. She was also unhappy that her optometrist needed to change her spectacle correction several times and presented to me with a specific request to undergo cataract surgery.

At this point, the patient's cataracts were moderate and her EBMD had progressed (see Figure 1). Best-corrected visual acuity was 20/20 OD, 20/30 OS and glare testing was <20/100 OU. We recommended a superficial lamellar keratectomy in the left eye with PROKERA® placement in the postop period. Pre-procedure topography is shown in Figure 2.

At two months postoperatively, the patient's astigmatism is reduced by 1.00D, her vision has improved to 20/20 on refraction and her glare testing has likewise significantly improved. Clinical presentation is illustrated in Figures 3a and 3b and the much-improved post-procedure topography is evident in Figure 4. She has requested PROKERA® in the fellow eye and cataract surgery will follow.



Figures 3a (top left) and 3b (bottom left): Improvement in patient's astigmatism, vision and glare testing two months postop.
Figure 4 (right): This patient's post-procedure topography shows much improvement.

Dr. Sheppard: Now, we have a whole palette of diagnostics—osmolarity, matrix metalloproteinase 9, interferometry—and I like to see all of them for every patient. Furthermore, in a patient who is spending \$3,000 per eye for a premium intra-ocular lens, I need that extra check and balance to make sure I'm not missing anything on the surface.

Dr. Lindstrom: Let's turn our attention to patients with diagnosed EBMD. What makes you conclude that it's so bad that you need to do a superficial keratectomy? For example, one thing that tends to tip

"PREMIUM CATARACT PROCEDURES REQUIRE PREMIUM OCULAR SURFACE MANAGEMENT."

—John D. Sheppard, MD, MMSc

me over is Salzmann's because that doesn't usually respond very well to medical therapy.

EBMD TREATMENT

Dr. Davidian: It's not easy. When a patient has mild disease, it's hard to take the plunge when I know that it can be uncomfortable and the road to cataract surgery will be longer. As I mentioned with regard to making a diagnosis, I rely most heavily on topographical changes and on what the patient is describing when making a treatment decision.

Dr. Lindstrom: In cases where you've decided a superficial keratectomy is needed, how do you decide whether to use a bandage soft contact lens or PROKERA® (Bio-Tissue)?

Dr. Davidian: A bandage contact lens is essentially little more than a piece of plastic. However, for some patients, it may be more comfortable initially because it provides a smooth ocular surface

when they blink. That being said, a bandage lens offers none of the biologic ingredients that we find in cryopreserved amniotic tissue. PROKERA® allows for better long-term healing and effects, which include decreased inflammation, decreased scarring and decreased angiogenesis. It also offers a quicker recovery and a clearer ocular surface with less hazing. This is why I tend to lean more towards PROKERA®.

Dr. Sheppard: For any procedure where I believe the surgery will be fairly straightforward, the patient

will cooperate and there will be minimum intra- and postoperative pain, I perform these operations in the clinic, and my choice is always to use PROKERA®. On the other hand, if the patient has severe Salzmann's or a pterygium, I send them to the ambulatory surgery center for better pain control. These patients fare better with a peribulbar block and dilation, then get a bandage contact lens and a patch. I see them back the next day in the clinic and apply PROKERA®.

Dr. Yeu: I do it as a staged procedure as well. A therapeutic bandage lens does give patients a good amount of comfort on the day of surgery, but PROKERA® offers the benefits of healing.

Dr. Lindstrom: Let's turn our attention now to the less severe cases of EBMD. If I look really carefully, I see some degree of EBMD on almost half of my dry-eye patients. I want to tune up the ocular surface so I can get better surgical outcomes, but I'm not likely to go so far as to perform a

superficial keratectomy. What's the best course of action?

Dr. Sheppard: Premium IOL patients, in particular, have high expectations and the pain of a superficial keratectomy is not part of their expectation package.

Dr. Lindstrom: Neither is waiting several months for medical treatment to work. How do you sufficiently tune up the surface in such cases?

Dr. Sheppard: We're using amniotic membranes more often and our threshold for using them is getting lower. PROKERA® has an excellent safety profile. It's not a steroid; it's not a bandage lens; it's not a hypoxic medium. It produces excellent oxygen permeability and can be performed quickly in the office. Every month, we're using more of these membranes for less and less significant pathology with proportionately more and more benefit.

Dr. Lindstrom: There is certainly a need for treatment that reduces the amount of time it takes to adequately heal the ocular surface in preparation for cataract surgery and PROKERA® certainly offers this. Particularly as we see the number of premium procedures grow, it will be interesting to witness how readily our colleagues adopt this protocol.

Dr. Sheppard: Premium cataract procedures require premium ocular surface management.

Dr. Lindstrom: That's very true. Unfortunately, we are often challenged by overly enthusiastic patients who are in a rush to schedule surgical procedures to accommodate career and other lifestyle demands. These patients don't want to wait months undergoing medical treatment. How long does it take to tune up the surface with PROKERA® SLIM and what other adjuncts do you use?

Clinical Pearls for Tape Tarsorrhaphy

Dr. Lindstrom: Do you recommend tape tarsorrhaphy?

Dr. Sheppard: The longer you keep the lid relatively closed, the longer the amniotic membrane lasts, so I believe tarsorrhaphy taping is very important in most cases.

Dr. Yeu: Indeed. For example, tape tarsorrhaphy is needed in cases of floppy eyelid syndrome, in patients with bulging eyes or if a patient has thinning in the inferior limbus and you want to ensure that there is no way that the ring is going to float up with a blink. After the PROKERA® goes in, I always take a look at the slit lamp to see how it's riding on the eye and, if it starts to ride up, blinking may cause the membrane to pop out. In those cases, I do a tape tarsorrhaphy.

Dr. Sheppard: Another subset of patients who need the tape tarsorrhaphy are those with ectropion of the lower lid, forniceal foreshortening or other similar anatomical conditions. Likewise, patients with lagophthalmos also require tape tarsorrhaphy.

Dr. Yeu: While tape tarsorrhaphy is sometimes indicated, it can also be counterproductive. If you are using PROKERA® to prep an ocular surface for cataract surgery in someone with a normal-shaped eye, I would not suggest a tape tarsorrhaphy. After all, we're trying to re-stimulate the blink process.

Dr. Lindstrom: How do your patients feel about the tarsorrhaphy?

Dr. Sheppard: Patients are all different. Many don't like the cosmetics of a lateral tape tarsorrhaphy, but you can match the color of the tape to the skin color so it isn't quite so apparent. My standard protocol is to use Steri-Strips (Nexcare). Our staff and I instruct the family member in removal and replacement.

Dr. Yeu: Another patient-friendly alternative is to tape only across the upper lid so it creates a protective ptosis. By leaving the lower lid undisturbed, you can simply lower the bottom lid when it's time to instill drops.

Dr. Davidian: If you're going to do a temporary tarsorrhaphy, I think Tegaderm (3M) tarsorrhaphy is most comfortable. I place the Tegaderm to the outer half of the lid so that nasally they still have an opening available to apply medications.

Dr. Lindstrom: Back in Minnesota, we use Transpore (3M), so it appears that there is no singular best approach, but rather many ways to meet the diverse needs of this somewhat diverse patient population.

OCULAR SURFACE TUNE-UPS WITH PROKERA®

Dr. Tseng: Our retrospective studies show that, on average, PROKERA® SLIM applied for an average of five days to the patient with moderate dry eye that has not responded to the conventional maximal medical treatment without superficial keratectomy results in an accelerated improvement of the corneal surface. These patients can continue to use their concurrent dry-eye medications.¹²

Dr. Lindstrom: Is the vision good right after you take it out?

Dr. Tseng: In my experience, patients' vision improves by a line or two.

Dr. Lindstrom: And after you remove PROKERA®, how long does the surface stay pristine?

Dr. Tseng: Our study shows that the benefits last about four months with moderate to severe dry-eye patients.¹²

Dr. Lindstrom: So we've got plenty of time to do the surgery. Do you perform biometry the same day that you remove PROKERA®?

Dr. Yeu: Because I use anesthetics to take it out, I don't want to do biometry measurements that same day. I bring the patient back 24 to 48 hours later to do their IOL calculations and perform surgery in a week or two.

Dr. Sheppard: In all but the most severe cases I feel comfortable removing PROKERA®, letting the patient relax for an hour or so and then getting the topography and Lenstar (Haag-Streit) measurements the same day. There appears to be less corneal molding and distortion with PROKERA® when compared to

a standard bandage contact lens, but this comparison should be the subject of a more formal prospective clinical analysis.

Dr. Lindstrom: Indeed, this is a dramatic improvement in wait times for cataract surgery. Who can explain what is involved in applying PROKERA®?

APPLYING PROKERA®

Dr. Hauswirth: First, I anesthetize the patient and rinse the PROKERA® thoroughly. Then I lean the patient back, have him look down as I lift up the upper lid and then insert the PROKERA® into the superior fornix. Finally, I ask the patient to look straight ahead while I drop it into the lower fornix. It essentially slides right on like a contact lens.

Dr. Lindstrom: What about discomfort? Do you get a lot of after-hours phone calls from worried patients?

Dr. Hauswirth: Patient education

the sensation of the ring, so now I let everyone know it's okay to take the tape off if they prefer (see "Clinical Pearls for Tape Tarsorrhaphy").

Dr. Lindstrom: Can you add medication in combination with PROKERA®?

Dr. Yeu: I actually use less medication because the membrane is able to absorb some of it.

Dr. Sheppard: Indeed, the membrane very likely reduces the surface circulation time of topical medications, extends the pharmacokinetic time line, increases the area under the curve for medication delivery and also acts as a sustained-release delivery mechanism.

Dr. Yeu: Another reason I reduce medications with PROKERA® is because I want to limit toxicities that can impede healing.

Dr. Lindstrom: To what extent do you reduce dosing?

Dr. Yeu: As an example, if I was using PROKERA® for a corneal ulcer,

be beneficial because it increases the blink rate, which is very helpful in patients who no longer have reflex blinking or in patients with an incomplete blink. In addition, research shows that the amniotic membrane contains a high amount of nerve growth factor.¹³

Dr. Lindstrom: How long do you leave PROKERA® on the eye?

Dr. Davidian: For a typical basement membrane, I leave it on for about 10 days, but I will schedule follow-up in two days to ensure that the PROKERA® is centered and that the patient is reasonably comfortable and doing well.

Dr. Yeu: I often take it out in five to seven days when it looks like the cornea underneath is no longer staining from a defect.

Dr. Hauswirth: I usually keep it in place for five to seven days for this condition.

Dr. Lindstrom: What should we be doing, Dr. Tseng?

Dr. Tseng: How long you keep PROKERA® on the eye really depends on the disease. For dry eye, assuming there is no superficial debridement, I would leave it for three to five days. However, if I touch the epithelium, I tend to keep it on for about seven to 10 days.

Dr. Sheppard: It's also worth mentioning that you don't need to clutter up your clinic bringing these patients in over and over again. Other than the initial instructions, it really doesn't require a whole lot of hand holding or observation just because you put the lens in. I bring most of my patients back for follow-up in a week.

Dr. Lindstrom: The official global period is 10 days, so if you need to see the patient again after that, you would charge him a clinic visit.

"YOU'RE NOT USING PROKERA® TO MAKE A PATIENT MORE COMFORTABLE, YOU'RE USING IT TO HEAL HER OCULAR SURFACE."
—Richard L. Lindstrom, MD

and setting the patient's expectations are extremely important. I explain that during the first 24 hours they probably will have some discomfort. It's during this first 24-hour period that patients begin to adapt to the presence of the ring under their lids. After that, they tend to do very well and the vast majority have no issues with excessive discomfort. I used to use tape tarsorrhaphies on everyone to minimize friction of the lids on the ring, but I've found that some patients like the tape less than they like

I would decrease the frequency of medication from every two hours to five times per day.

Dr. Lindstrom: This is different than using a bandage soft contact lens on a patient's eye. You're not using PROKERA® to make a patient more comfortable, you're using it to heal her ocular surface.

Dr. Tseng: That's true and, in fact, a little foreign body sensation may

In addition to their utility in treating patients with EBMD, amniotic membranes have been found to be useful in the management of a wide array of other corneal, conjunctival and ocular surface conditions, including: acute Stevens-Johnson syndrome/TEN; acute alkali acid burns; neurotrophic defects; persistent corneal epithelial defects; filamentary keratitis; microbial keratitis; vernal keratoconjunctivitis; bullous keratopathy; Salzmann's nodular degeneration; dry-eye syndrome; recalcitrant superficial punctate keratitis; oculoplastic procedures; and non-healing epithelial defects after photorefractive keratectomy/phototherapeutic keratectomy.¹⁴⁻¹⁹ However, many cataract surgeons and comprehensive ophthalmologists would rather refer these corneal cases to a specialist. Might PROKERA® change their minds?

PRACTICE GROWTH

Dr. Shepard: Absolutely. This is an opportunity for comprehensive practice growth.

Dr. Davidian: The take-home message here is that the general ophthalmologist who understandably doesn't want to deal with the more difficult cases will always have a fair number of dry-eye patients and patients with less severe EBMD. These physicians may never have entertained using PROKERA®, leaving such treatment to the corneal specialist. But, in fact, PROKERA® is a really simple procedure that can benefit your patients and your practice, and does not need to be placed exclusively by corneal specialists.

Dr. Yeu: I agree. PROKERA® offers a new opportunity for

patient retention both in terms of the pre-cataract workup and longer term management that may involve repeat treatment.

Dr. Sheppard: So we now have two groups who we can more easily treat—those with more severe ocular surface disease who return for adjunctive aggressive therapy, as well as those in whom we employ PROKERA® as a routine surface rejuvenation platform.

Dr. Lindstrom: That's exactly right. In closing, I would like to highlight the fact that many of our colleagues have considered PROKERA® as a last resort “when everything else fails” type of treatment. But in fact, as those of us here have learned, it deserves a spot much further up in the therapeutic armamentarium, both for basement membrane dystrophy and for dry eye. This technology heals patients' corneas and often allows better surface and visual recovery than we can expect with level 2 medical therapy. In addition to the benefits we will see when using this treatment earlier, PROKERA® also offers the advantage of being an alternative to more aggressive intervention. For instance, in many cases, I would suggest trying PROKERA® alone before combining it with superficial keratectomy or excimer laser PTK. In either case, patients will benefit and our practices will grow. ■

1. Reidy JJ, Paulus MP, Gona S. Recurrent erosions of the cornea: epidemiology and treatment. *Cornea*. 2000 Nov;19(6):767-71.
2. Werblin TP, Hirst LW, Stark WJ, et al. Prevalence of map-dot-fingerprint changes in the cornea. *Br J Ophthalmol*. 1981; 65(6):401-409.
3. Cogan DG, Kuwabara T, Donaldson DD, Collins E. Microcystic dystrophy of the cornea: a partial explanation for its pathogenesis. *Arch Ophthalmol*. 1974; 92:470-474.
4. Ehlers N, Møller HU. Pathology and path-

omechanisms of epithelial microcystic and basement membrane abnormalities of the cornea. *Acta Ophthalmol (Copenh)*. 1988; 66:318-26.

5. Tripathi RC, Bron AJ. Cystic disorders of the corneal epithelium. II. Pathogenesis. *Br J Ophthalmol*. 1973; 57:376-390.
6. Fogle JA, Kenyon KR, Stark WJ, Green WR. Defective epithelial adhesion in anterior corneal dystrophies. *Am J Ophthalmol*. 1975; 79:925-40.
7. Laibson PR. Microcystic corneal dystrophy. *Trans Am Ophthalmol Soc*. 1976; 74:488-531.
8. Brodrick JD, Dark AJ, Peace GW. Fingerprint dystrophy of the cornea: a histologic study. *Arch Ophthalmol*. 1974; 92:483-489.
9. Kaufman HE, Clower JW. Irregularities of Bowman's membrane. *Am J Ophthalmol*. 1966; 61:227-30.
10. Laibson PR, Krachmer JHP. Familial occurrence of dot (microcystic), map, fingerprint dystrophy of the cornea. *Invest Ophthalmol Vis Sci*. 1975; 14:397-399.
11. Huang Y, Sheha H, Tseng SCG. Self-retained amniotic membrane transplantation for recurrent corneal erosion. *J Clin Ophthalmol*, 4:272, 2013.
12. Sheha H and Tseng SCG. The role of amniotic membrane for managing dry eye disease. In: Benitez Del Castillo JM, Lemp MA (eds.). *Ocular Surface Disorders*. JP Medical London; 2013 (39) 325-329.
13. Touhami A, Grueterich M, Tseng SCG. The role of NGF signaling in human limbal epithelium expanded by amniotic membrane culture. *Invest Ophthalmol Vis Sci* 43:987-994, 2002.
14. Shay E, Khadem JJ, Tseng SC. Efficacy and limitation of sutureless amniotic membrane transplantation for acute toxic epidermal necrolysis. *Cornea* 2010;29:359-361.
15. Shammas MC, Lai EC, Sarkar JS, Yang J, Starr CE, Sippel KC. Management of acute Stevens-Johnson syndrome and toxic epidermal necrolysis utilizing amniotic membrane and topical corticosteroids. *Am J Ophthalmol* 2010;149:203-213.
16. Kheirkhah A, Johnson DA, Paranjpe DR, Raju VK, Casas V, Tseng SC. Temporary sutureless amniotic membrane patch for acute alkaline burns. *Arch Ophthalmol* 2008;126:1059-1066.
17. Pachigolla G, Prasher P, Di Pascuale MA, Mc-Culley JP, McHenry JG, Mootha VV. Evaluation of the role of ProKera in the management of ocular surface and orbital disorders. *Eye Contact Lens* 2009;35:172-175.
18. Sheha H, Liang L, Li J, Tseng SC. Sutureless amniotic membrane transplantation for severe bacterial keratitis. *Cornea* 2009;28:1118-1123.
19. Pachigolla G, Prasher P, Di Pascuale MA, Mc-Culley JP, McHenry JG, Mootha VV. Evaluation of the role of ProKera in the management of ocular surface and orbital disorders. *Eye Contact Lens* 2009;35:172-175.

The opinions expressed in this supplement to Review of Ophthalmology® do not reflect the views of or imply endorsement by the publisher of Review of Ophthalmology. Copyright 2015 Jobson Medical Information LLC.