

# Clinical Advantages of Swept-Source OCT and New Non-Damaging Laser Treatments

Three leading surgeons offer their insight and experience on imaging with optical coherence tomography as well as laser treatment options.

## New Swept-Source OCT for Glaucoma: Improvements and Advantages

A look at how this third-generation OCT differs from conventional OCT.

*Andrew J. Tatham, FRCOphth, FEBO*

When we refer to swept-source optical coherence tomography (SS-OCT), “swept source” refers to the type of laser incorporated into the device. Instead of the superluminescent diode laser typical of conventional spectral domain OCT (SD-OCT), SS-OCT uses a short-cavity swept laser. Although the swept-source laser has a wavelength centered at approximately 1  $\mu\text{m}$ , the laser actually changes, because it sweeps across a narrow band of wavelengths with each scan. Like SD-OCT, SS-OCT has a fixed reference arm, but it does not use a spectrometer. Instead, a complementary metal oxide semiconductor camera is employed, along with two fast parallel photodiode detectors. The result is that SS-OCT is able to achieve the highest imaging speed of any commercially available OCT with 100,000 A-scans obtained per second.

Additionally, SS-OCT has a high axial resolution of just 5  $\mu\text{m}$  and an improved signal-to-noise ratio.

With a basic understanding of the technical differences between conventional and SS-OCT we can now explore the advantages of this new technology.

### Advantages of SS-OCT

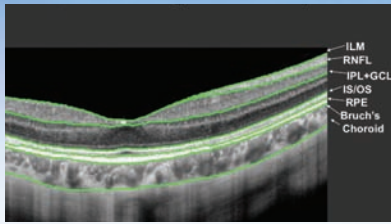
A major advantage of SS-OCT is the high imaging speed, which allows high-resolution images to be obtained while reducing the negative effect of patient’s eye movements on scan quality. SS-OCT also uses an invisible light source, which is less distracting for patients compared to the visible light used in SD-OCT.

The long wavelength and swept-source technology also provide the ability to obtain clear images of deep ocular structures such as the choroid and lamina cribrosa, the putative site of axonal damage in glaucoma.<sup>1,2</sup> Imaging of deep struc-

tures is possible, as the long wavelength of SS-OCT is less subject to light scatter by the retinal pigment epithelial (RPE). There is also less light scattering by lens opacities and therefore, SS-OCT can provide clearer images in patients with cataracts compared to conventional OCT.

A further advantage of swept-source technology is that it provides uniform sensitivity over the entire scan window, which enables the vitreous, retina and deep ocular structures to be visualized in a single scan. In comparison, conventional SD-OCT does not have the same capability and suffers from a drop off in sensitivity with changing scan depth.

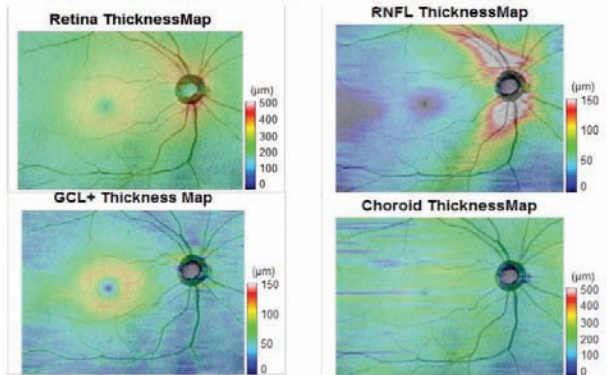
Topcon’s Deep Range Imaging OCT-1 (Atlantis)\* is an example of an SS-OCT device for posterior ocular imaging. An attractive feature of this SS-OCT is its ability to perform a wide-field scan covering a 12- x 9-mm area of the posterior pole. Using the wide-field protocol, the disc and macula can be evaluated in a single scan. This has the potential to improve our understanding of the relationship between the optic nerve and macular damage and overcomes the problems caused by differences in head position and alignment when



**Figure 1: Topcon's Deep Ranging Imaging OCT-1 Atlantis\* swept-source optical coherence tomography (OCT) also includes software that allows automated segmentation of seven layers.**

acquiring separate images of the optic nerve head and macula. Given the growing appreciation of the importance of the macula in glaucoma evaluation, there is likely to be increasing need for such a tool.<sup>3</sup>

SS-OCT also incorporates sophisticated automated segmentation software that allows identification of seven different retinal layers (see Figure 1). It is therefore possible to image the circumpapillary retinal nerve fiber layer (RNFL) and macular ganglion cell layer (GCL) using the same scan. The segmentation software also identifies the internal limiting membrane (ILM), inner plexiform layer (IPL), inner segment-outer segment junction (IS/OS), RPE, Bruch's membrane and choroid (see Figure 1). Mul-



**Figure 2: Deep Range Imaging OCT-1 Atlantis\* Swept-Source Optical Coherence Tomography (OCT) provides multiple thickness maps from one wide field scan, including the total retinal thickness (top left), retinal nerve fiber layer (RNFL) thickness (top right), ganglion cell and inner plexiform layer (GCL+) thickness (bottom left) and choroidal thickness (bottom right). The example shown is of a healthy eye.**

tiple thickness maps can then be generated (see Figure 2).

## Applications in Glaucoma

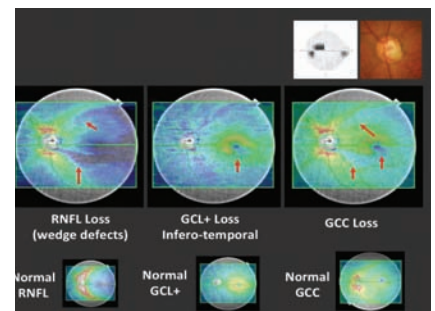
There are several possible applications of SS-OCT in glaucoma, including for disease detection, identification of novel risk factors and improving the understanding of disease mechanisms. Let's start with an example from clinical practice.

Figure 3 shows the optic disc photograph, standard automated perimetry and SS-OCT scan of the left eye of a 66-year-old female with primary open-angle glaucoma (POAG). Marked excavation and thinning of the inferotemporal neuroretinal rim is visible on the disc photograph, while on perimetry, there is evidence of a superior paracentral visual field defect consistent with the findings on optic disc examination. The SS-OCT thickness maps for the RNFL, ganglion cell layer plus inner plexiform layer (GCC, ganglion cell layer, inner plexiform layer and RNFL) are shown. All of these maps were obtained using a single, wide-field (12- x 9-mm) SS-OCT scan. Starting with the RNFL thickness map, we can see two wedge-shaped defects (red arrows), which correspond to

the changes seen on optic disc examination. Here, an advantage of the wide-field scan is that we can follow the RNFL defects toward the macula. If we then turn our attention to the GCL+ thickness map, it is apparent that there is loss of the GCL+ in the inferior macula (red arrow). The

area of inferior macula ganglion cell loss corresponds to the location of the central and superior visual field defect. In this example, there is therefore good structure-function correlation. Finally, the RNFL and GCL+ thickness maps are combined to form the GCC map, which is a useful summary of overall RNFL and GCL+ loss. This case demonstrates the potential use of SS-OCT for glaucoma diagnosis.

Recently, our research group at the Hamilton Glaucoma Center, University of California San



**Figure 3: OCT findings of a 66-year-old woman with primary open-angle glaucoma.**

Diego has been investigating the ability of the Deep Range Imaging OCT-1 Atlantis\* SS-OCT to detect glaucoma in a large cross-sectional study.

Diagnostic ability of SS-OCT. We conducted a cross-sectional observational study of subjects enrolled in the Diagnostic Innovations in Glaucoma Study (DIGS), an ongoing study at the University of California San Diego. We included 172 eyes with glaucoma and 96 healthy eyes, where glaucoma was defined by the presence of two or more consecutive abnormal visual fields or progressive glaucomatous change on masked grading of stereophotographs. The glaucomatous eyes had an average standard automated perimetry mean deviation of -5.2 ± 3.6.3 dB. All subjects were imaged using the SS-OCT 12- x 9-mm scan and the Spectralis SD-OCT (Heidelberg Engineering). The SS-

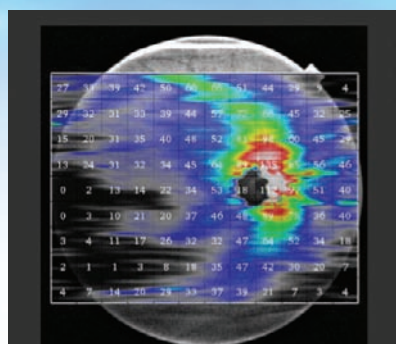


OCT displays RNFL thickness data in a 12- x 9-mm grid format (see *Figure 4*). The RNFL thickness for the entire grid was calculated and it was also possible to take averages of RNFL thickness in different regions of the retina to compare the diagnostic ability of different sectors.

Receiver operating characteristic (ROC) curves were constructed to examine the ability of the SS-OCT and Spectralis RNFL thickness measurements to distinguish glaucomatous and healthy eyes. The area under the ROC curve gives us an idea of the diagnostic ability of the device, where an area of 0.5 would represent pure chance and an area of 1.0 would indicate the device is able to discriminate perfectly between health and disease. The ROC curves showed that the Deep Range Imaging OCT global RNFL thickness for the 12- x 9-mm scan had similar diagnostic ability compared to the Spectralis SD-OCT peripapillary RNFL thickness, with both achieving ROC curve areas of 0.88 (see *Figure 5*). Sensitivities for 95 percent and 80 percent specificities were 83.7 percent and 44.6 percent for the SS-OCT 12- x 9-mm RNFL thickness and 81.2 percent and 41.7 percent for SD-OCT peripapillary RNFL thickness, respectively.

These early results indicate that Deep Range Imaging OCT\* can be used to detect glaucoma, and that the average RNFL thickness using the 12- x 9-mm scan has similar diagnostic ability compared to conventional peripapillary RNFL thickness. Further research is, however, needed to determine whether including other parameters from the wide field scan, such as GCL+ thickness, can improve diagnostic ability. It is also possible that by imaging a wider area, we may be able to improve the reproducibility of measurements.

What about the other pos-

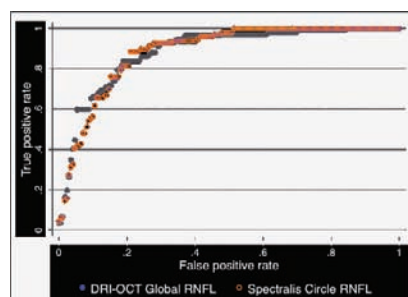


**Figure 4: The diagnostic ability of wide field DRI-OCT\* retinal nerve fiber layer measurements in glaucoma.**

sible applications of SS-OCT in glaucoma?

The lamina cribrosa, which is implicated as the principal site of damage to the retinal ganglion cell (RGC) axons in glaucoma, is a 3-D meshwork consisting of capillaries, fenestrated sheets of scleral collagenous tissue and some elastic fibers. We know from histological studies that the lamina cribrosa can undergo morphological changes in glaucomatous eyes.

For example, thinning and posterior lamina displacement have been observed and are thought to be a result of raised intraocular pressure.<sup>4,5</sup> Deformation of the lamina cribrosa could lead to compression or shearing of RGC axons and lamina capillaries, and be an underlying cause for glaucoma. For the first time, new technologies such as enhanced depth imaging (EDI) OCT and SS-



**Figure 5. ROC curves for RNFL thickness measurements derived from Topcon's Deep Range Imaging OCT\* (12- x 9-mm scan) and Heidelberg's Spectralis (circumpapillary scan).**

OCT allow us to obtain images of the lamina cribrosa *in vivo*.

Lee and colleagues recently used EDI-OCT to examine changes in the lamina cribrosa that occur with reduction in IOP.<sup>6</sup> One hundred eyes were examined and the lamina cribrosa imaged before and after at least a 20 percent reduction in IOP. A significant decrease in lamina cribrosa depth was found following a reduction in IOP and there was a significant relationship between change in lamina cribrosa depth percentage and decrease in pressure. This study therefore provides evidence that reduction in IOP may reverse some changes in the lamina cribrosa.<sup>4</sup>

In addition to generalized changes in the configuration of the lamina, there may be focal changes associated with glaucoma. Using SS-OCT, Takayama and colleagues found focal defects in the lamina cribrosa in glaucomatous eyes.<sup>1</sup> Furthermore, 3-D imaging allowed the defects to be distinguished from artifacts such as those caused by overlying blood vessels.

Our group at the University of California San Diego has recently explored the relationship between focal RNFL damage and focal lamina cribrosa defects.<sup>2</sup> We examined 20 eyes with focal RNFL defects visible on stereophotographs and used EDI-OCT to determine if these eyes might also have focal defects of the lamina cribrosa. Radial line EDI-OCT scans were examined by masked graders and 15 of 20 eyes (75 percent) with focal RNFL defects were also found to have focal defects of the lamina cribrosa compared to just one eye of 40 age-matched controls. There was also good spatial correlation between the location of the lamina cribrosa and RNFL defects.

Although we cannot be sure of cause and effect, the results suggest that localized loss of lamina

cribrosa beams may contribute to localized damage to the RNFL.

The choroid also has a possible role in glaucoma pathogenesis because it supplies the blood to the prelaminar optic nerve head and histological studies have suggested that the choroid may be thinner in those with glaucoma.<sup>7</sup> SS-OCT provides a means to evaluate the relationship between the choroid and glaucoma by studying choroidal thickness and volume *in vivo*.<sup>8</sup>

We recently performed a study of choroidal thickness in 322 healthy and glaucomatous eyes. The wide field SS-OCT enabled us to examine choroidal thickness in the macula and circumpapillary regions. We found the choroid was significantly thinner in older patients and in those with longer axial length ( $p < 0.001$  for both comparisons). Patients with glaucoma also had thinner choroids, however, once age and axial length were also accounted for in a multivariable model, there was no significant difference in choroidal thickness between healthy and glaucomatous subjects.

Older age and longer axial length

are both risk factors for glaucoma, so although choroidal thickness was not significant in the multivariable models, the choroid may still play a role in glaucoma pathogenesis. Further studies in different subtypes of glaucoma, and investigating the relationship between choroidal thickness and ocular blood flow would be interesting.

## Conclusion

Hopefully this overview has highlighted some of the potential applications of the third-generation OCT technology, SS-OCT, in glaucoma. In summary, the major advantages of SS-OCT over conventional OCT are that it is faster, can penetrate deeper, enables wide field imaging, and is very versatile with its multiple-layer segmentation. These features allow SS-OCT to quantify structural changes in the macula and optic nerve head in a single scan. Using SS-OCT, we are also learning more about the choroid and lamina cribrosa, which may lead to improvements in our understanding of mechanisms of axonal damage and the recognition of new structural risk markers.

*Dr. Tatham is an ophthalmic surgeon specializing in glaucoma. He has recently completed a glaucoma fellowship at Hamilton Glaucoma Center, University of California San Diego and is currently consultant surgeon at Princess Alexandra Eye Pavilion Edinburgh and honorary clinical senior lecturer at University of Edinburgh.*

## REFERENCES

1. Takayama K, Hangai M, Kimura Y, et al. Three-dimensional imaging of lamina cribrosa defects in glaucoma using swept-source optical coherence tomography. *Invest Optom Vis Sci*. 2013;54:4799.
2. Tatham AJ, Miki A, Weinreb RN, et al. Defects of the lamina cribrosa in eyes with localized retinal nerve fiber layer loss. *Ophthalmology*, in press.
3. Hood DC, Raza AS, de Moraes CG, et al. Glaucomatous damage of the macula. *Prog Retin Eye Res*. 2013;32:1-21.
4. Quigley HA, Hohman RM, Addicks EM, et al. Morphologic changes in the lamina cribrosa correlated with neural loss in open-angle glaucoma. *Am J Ophthalmol*. 1983;95:673-91.
5. Bellezza AJ, Rintalan CJ, Thompson HW, et al. Deformation of the lamina cribrosa and anterior scleral canal wall in early experimental glaucoma. *IOVS*. 2003;44:623-37.
6. Lee EJ, Kim TW, Weinreb RN, Kim H. Reversal of lamina cribrosa displacement after intraocular pressure reduction in open-angle glaucoma. *Ophthalmology*. 2013;120:553-559.
7. Yin ZQ, Vaegan, Millar TJ, et al. Widespread choroidal insufficiency in primary open-angle glaucoma. *J Glaucoma*. 1997;6:23-32.
8. Banitt M. The choroid in glaucoma. *Curr Opin Ophthalmol*. 2014;24:125-9.

## Clinical Efficacy of Non-Damaging Treatment Options

How the PASCAL® laser and Endpoint

Management® can be used safely and effectively.

*Prof. Paulo E. Stanga, MD, with Maria Gil-Martinez, MD, Salvador Pastor-Idoate, MD, and Claudia Quijano, MD*

**W**e have all known the side effects of laser for many years. Basically, they are secondary to a visible burn. Standard argon laser burns (530 nm) expand at the rate of 16.5 percent per year for up to four years, and this can reduce visual fields and loss of central vision.<sup>1</sup> Following Early Treat-

ment Diabetic Retinopathy Study (ETDRS) protocol for panretinal photocoagulation (PRP), between 12 percent and 30 percent of patients may fail Driver and Vehicle Licensing Agency (DVLA) binocular visual field testing.<sup>2</sup>

We have looked at burns over time and have developed a Fourier-domain OCT (FD-OCT)

and fundus autofluorescence (FAF)-guided technique with Topcon Medical Laser Systems' PASCAL® Synthesis dual-port pattern scanning retinal laser to image the burns and analyze the effects of the PASCAL® laser.<sup>3</sup> FD-OCT confirms that burns from the PASCAL® are confined and localized to the outer retina, and FAF shows burns much more clearly than on fundus biomicroscopy, especially when we are using barely visible or subthreshold burns.

In a study on healing of laser burns, we showed that PASCAL burns diminish in size rather than expand. In fact, we observed a 50 percent reduction in outer retinal burn size for 10-ms pulse



laser over one year,<sup>4</sup> which we thought was important, especially for the treatment of macular conditions such as diabetic macular edema (DME). More numerous and more closely spaced burns seem to be required. Logically, you may ask if this is clinically effective, and in fact, we have shown effectiveness in two clinical audits.<sup>5,6</sup>

## Photocoagulation with Barely Visible Burns

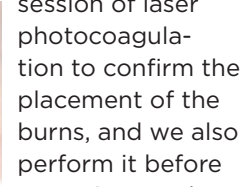
In a pilot study we conducted, we carried out photocoagulation with barely visible burns, which we found to be effective.<sup>7</sup> We compared targeted retinal photocoagulation (TRP) with reduced-fluence/minimally traumatic panretinal photocoagulation (MT-PRP) and standard-intensity PRP (SI-PRP) in proliferative diabetic retinopathy.

We enrolled patients with ischemia only in the far periphery, all of whom underwent single-session 20-ms PASCAL<sup>®</sup> 2,500 burns photocoagulation randomized to one of three treatment arms: TRP, MT-PRP or SI-PRP. We showed that the rate of response was comparable between the three groups, which we consider extremely important for the TRP and MT-PRP groups. The study also demonstrated that high-density, 20-ms PASCAL<sup>®</sup> TRP and MT-PRP using 2,500 burns did not produce increased macular thickness or any ocular adverse events in the short-term.

We believe that medium-pulsed duration laser, light or barely visible burns, allowed for a tissue healing response. In histology studies, other groups showed what we found on clinical studies with imaging. Lavinsky and Paulus<sup>8,9</sup> showed that if you create a barely visible burn, you allow for photoreceptors and RPE cells from around the burn to migrate toward the center of the burn; tis-

sue remodelling. This could explain why the burn decreases in size on imaging rather than increases.

Some people are concerned about the possibility of burning the fovea inadvertently with the PASCAL<sup>®</sup> laser when using array patterns. However, we have published a case report of a patient with accidental foveal burn without visual sequelae.<sup>10</sup> I suggest that if you are treating close to the fovea, it may be safer to use barely visible or sub-threshold burns.



*High-density, 20-ms PASCAL TRP and MT-PRP using 2,500 burns did not produce increased macular thickness or any ocular adverse events in the short-term.*

I think there's enough evidence to only use barely visible burns. We know that we are allowing for tissue healing response and the RPE and the outer retina to recover over time.

## Icing on the Cake

Topcon developed Endpoint Management<sup>®</sup>, which utilizes advanced algorithms to control both the power and the exposure time of the laser. This makes our jobs much easier by allowing precise control for titration purposes. It is available for both green (532 nm) and yellow (577 nm) laser. The burns look different, so you need to choose a wavelength, but both are safe and effective.

I tend to perform PASCAL single-session PRP with up to 3,000 burns. In one of our studies, patients were randomized to either single-session or multiple-session photocoagulation.<sup>11</sup> We found that there were no adverse events in single-session photocoagulation. We looked at average center retinal thickness with OCT and, in fact, the macula was thinner in the single-session laser group than in the multiple-session one. We think

this is because every time you carry out a laser session, you're inducing an inflammatory response in the eye, which in turn induces macular edema. The [DRCR.net](http://DRCR.net) subsequently carried out a similar study that showed similar results.<sup>12</sup> In my opinion, we should only be doing single-session PRP with a top-up session, if necessary, approximately two months later and depending on the severity of the proliferative changes.

We perform FAF after every

session of laser photocoagulation to confirm the placement of the burns, and we also perform it before repeating any laser

treatment to avoid targeting areas previously treated.

It is also important to bear in mind that when treating macular edema, as per the ETDRS,<sup>13</sup> we need to treat the area of thickening. We should not treat areas of leakage but areas of retinal thickening as per OCT.

## Examples of Note

Below are some scenarios of particular interest.

- Under-dosing. In a patient with diabetic macular edema, we initially applied only 100 spots of laser and the burns were too far from the fovea. We subsequently started working with Endpoint Management<sup>®</sup> and added more laser much closer to the fovea. Within one month, we could see significant reduction in the edema.

- Laser in the presence of ischemia. Another patient presented with significant ischemia of the posterior pole. This scenario troubles some colleagues because they worry about damaging the collateral vessels or shunts with the laser. This patient had an HbA1c of 10 and his diabetes was poorly controlled. He had significant

macular edema with a very thick (387 µm) retina. I performed single-session treatment: a modified macular grid (700 spots) of green PASCAL® laser using Endpoint Management® at 40 percent and 2,800 burns PRP. Additionally, temporal to the macula, I treated all areas of the thickened retina. One hour later, I could see very light foveal burns. OCT showed no damage in between the landmarks. One month later, a significant improvement in the overall appearance of the macula was evident. (It usually takes three months to see full results from laser.)

### Parting Thoughts and Tips

I have been using the PASCAL® laser since 2006. Patients do not report pain and there is no need for periocular anesthesia. Patients may feel a prick when I am photocoagulating along the long posterior ciliary nerves, but this treatment is very well tolerated. Those who get single-session photocoagulation receive up to 3,000 burns. Treatment times with PASCAL® are also very short; a full PRP can be performed in around four minutes.

Focal PASCAL® laser treatment remains my first option for cystoid macular edema (CME), but I do pre-treat with intravitreal pharmacotherapy if the retina is thicker than 400 µm. I use anti-vascular

endothelial growth factors to reduce the edema and carry out the laser three to four weeks later.

I also use FAF imaging prior to repeating any laser procedure to avoid targeting already treated areas. If FAF shows adequate laser coverage in the areas of retinal thickening, then I don't repeat laser; I use intravitreal pharmacotherapy.

I do single-session PRP with up to 3,000 burns and, if necessary, in combination with macular laser. It is important to remember that with PASCAL® low-fluence treatment, more burns are required than with standard intensity argon laser.

I apply 10-ms burns within the posterior pole and 20-ms outside it. I'm currently almost exclusively doing macular laser using Endpoint Management®.

*Prof. Stanga is Professor of Ophthalmology & Retinal Regeneration for the University of Manchester; Consultant Ophthalmologist & Vitreoretinal Surgeon for the Manchester Royal Eye Hospital and Director of the Manchester Vision Regeneration (MVR) Lab at NIHR/Wellcome Trust Manchester CRF.*

#### REFERENCES

1. Scharztz H, Madeira D, MacDonald HR, et al. Progressive enlargement of laser scars following grid laser photocoagulation for diffuse diabetic macular edema. *Arch Ophthalmol*. 1991;109:1549-1551.
2. Zweng HC, Little HL, Hammond AH. Complications of argon laser photocoagulation. *Trans Am Acad Ophthalmol Otolaryngol*.

1974; 78: 195-204.

3. Muqit MM, Gray JC, Marcellino GR, et al. Fundus autofluorescence and Fourier-domain optical coherence tomography imaging of 10 and 20 millisecond Pascal retinal photocoagulation treatment. *Br J Ophthalmol*. 2008;93(4):518-525.
4. Muqit MM, Henson DB, Young LB, et al. Laser tissue interactions. *Ophthalmology*. 2010;117(10):2039
5. Shanghi C, McLaughlan R, Delgado C, et al. Initial experience with the Pascal photocoagulator: a pilot study of 75 procedures. *Br J Ophthalmol*. 2006;92(6) 161-4
6. Muqit M, Shanghi V, McLaughlan R, et al. Study of clinical applications and safety for Pascal laser photocoagulation in retinal vascular disorders. *Acta Ophthalmol*. 2012;90(2):155-61.
7. Muqit MM, Young LB, McKenzie R, et al. Pilot randomized clinical trial of Pascal TargETEd Retinal versus variable fluence PANretinal 20 ms laser in diabetic retinopathy: PETER PAN study. *Br J Ophthalmol*. 2013;97(2):220-7.
8. Paulus Y, Jain A, Gariano R, et al. Healing of retinal photocoagulation lesion. *Invest Ophthalmol Vis Sci*. 2008;49:5540-5545.
9. Lavinsky D, Sramek C, Wang J, et al. Subvisible retinal laser therapy: Tritation algorithm and tissue response. *Retina*. 2013;0:1-11
10. Stanga PE, Muqit MM, Marcellino GR. Microstructural changes following inadvertent multi-spot laser photocoagulation of the fovea. *Graefes Arch Clin Exp Ophthalmol* 2012;250: 945-7.
11. Muqit MM, Marcellino GR, Henson DB, Young LB, et al. Single Session vs multiple-session pattern scanning laser panretinal photocoagulation in proliferative diabetic retinopathy: The Manchester Pascal study. *Arch Ophthalmol*. 2010;128:525-33.
12. Diabetic Retinopathy Clinical Research Network. Observational study of the development of diabetic macular edema following panretinal (scatter) photocoagulation given in 1 or 4 sittings. *Arch Ophthalmol*. 2009; 127(2): 132-40.
13. Early Treatment Diabetic Retinopathy Study research group. Photocoagulation for diabetic macular edema. Early Treatment Diabetic Retinopathy Study report number 1. *Arch Ophthalmol*. 1985;103(12):1796-806.

## OCT Imaging of the Choroid & Beyond

Imaging with optical coherence tomography has come a long way, and now allows us to reach new heights—or depths—than ever before.

*Richard F. Spaide, MD*

Conventional optical coherence tomography (OCT) allows us to image the vitreous and retina, but it is pos-

sible to achieve deeper imaging (optic nerve, sclera and choroid) with OCT. First, let's review the technology that's involved.

### SD-OCT

Spectral-domain OCT (SD-OCT) is an interferometric technique that provides depth-resolved tissue structure information encoded in the magnitude and delay of the back-scattered light by spectral analysis of the interference fringe pattern. It is a conventional form of OCT now in common practice that uses a low-coherence light source (broadband light) within a range of

wavelengths to image deep into tissue. Depth information is obtained by analyzing the output light of the interferometer with a spectrometer. The reference arm is stationary in SD-OCT. Because multiple levels of the tissue are analyzed concurrently with SD-OCT, we get much higher speed than with the time domain OCT.

In SD-OCT, light from a reference arm travels a certain length, which is referred to as a path length. By analogy, the same occurs with light reflecting from a specific layer in the eye. Combining these two creates an interferogram. When the path lengths of the two are the same, we say there is no delay between the two arms. The interferogram varies in frequency according to the mismatch in path length between the two arms. The greater the mismatch, the greater the resultant frequency, so there is in effect frequency encoding of depth.

That is the ingenious part of SD-OCT. The signal produced has a strength in proportion to the reflective property of the object being examined and a frequency according to its depth. So by teasing out the frequency and signal strength information using a Fourier transform, we can assemble the whole A-scan at once. We don't have to probe point-by-point as with time domain OCT. We can put many A scans together to form a B scan.

So the ingenious aspect of SD-OCT is that there's increasing frequency with increasing depth. Interestingly, this is also the weakness of SD-OCT because the way it detects the signal is sensitive to frequency. The sensitivity of SD-OCT drops off at increasing frequencies, so things near the zero delay line (the upper part of the OCT image) look great, but further down, the image gets worse.

When you overlay the sensitivity scan/curve on top of a typical OCT, it gets darker as you go

down into the OCT itself. Part of that is due to light loss or scattering, but a lot of it is simply because it's deeper, which may seem counter-intuitive to the way we ordinarily see. That is the problem with SD-OCT. However, we can adjust for this and push that sensitivity curve back to the anterior sclera. This technique relies on an unusual property of OCTs, but what gets formed next is an upside down image of the tissue, which has greater depth information. That's how enhanced depth imaging (EDI) works.

The peak in sensitivity is great for looking at the choroid, but not the vitreous because it is in the area of low sensitivity. So you have to figure out what you want to look at in advance. If you want to look at the retina, chose either ordinary SD-OCT or EDI. If you want to look at the vitreous, you do conventional SD-OCT, and if you want to look at the choroid, you have to rely on EDI OCT.

### SS-OCT

Swept-source OCT (SS-OCT) is a bit different. This light source is capable of producing a number of different wavelengths. It sequentially scans through individual wavelengths, which it sends into the eye and compares to the reference arm. SS-OCT rapidly builds up the interferometer, and we can decode using a simpler detection strategy than what is used in SD-OCT. We get an A-scan by means of the Fourier transform and create a B scan out of several A scans.

We have a different kind of curve with SS-OCT compared to the sensitivity fall-off with SD-OCT. Depending on certain parameters of the light source, SS-OCT is more—but not com-

pletely—flat, so as you go deeper inside the eye, there's less of a change in sensitivity. So we don't get so much of the choroid with ordinary SD-OCT, but with SS-OCT, we get great imaging; we get everything.

Also with SS-OCT, commonly available light sources operate in the 1- $\mu$ m region, so it penetrates tissue better. The upshot of this was Topcon's DRI OCT-1 Atlantis\*, the first commercial SS-OCT available for posterior imaging. It scans 100,000 A scans per second, which is very fast, and it has a 1,050-nm light source, which lets us see the vitreous, retina and choroid all in one shot. The vitreous is still a bit dark in this kind of image, but we can make it brighter or create a pseudo-color image to see it. A

### Swept-Source OCT Opportunities

Conventional OCT	• vitreous • retina
Deeper Imaging	• vitreous • retina • choroid • sclera • optic nerve

lot of changes take place in the vitreous of normal people, and SS-OCT gives us a way to look at it. Another advantage of the DRI OCT-1 Atlantis\* is that it images at a better depth (2.6 mm) than other machines and there's no fall-off in sensitivity.

### The Wave of the Future

If you want to look at just one image, SS-OCT is going to be the wave of the future. In glaucoma and high myopes, we found that when you image the lamina cribrosa, frequently you can see defects or tears. Pathologic myopia usually starts with a normal sort of eye early in life that expands over time. Curiously enough, the collagen weight in the sclera goes down, the amount of cilia or matrix decreases and everything looks like it thins. We didn't know much



about the choroid until we started really being able to look at it.

My office participated in a study with a group in Japan on the correlates of visual acuity.<sup>1</sup> We looked at any number of parameters you could think of in normal people and we plotted out and performed a statistical analysis. We found that the biggest and most significant predictor of visual acuity in high myopes with no evident macular problems is the thickness of the choroid.<sup>1</sup> We published our paper in 2012 and in 2013, two additional studies with the same results were published in other journals.<sup>2,3</sup> This finding has the potential to have huge public health impacts given the explosion in the prevalence of myopia, particularly in Asia.

We're used to thinking about high myopia and the associated vision changes as some of these really vivid things like retinal detachments, macular schisis and macular holes, but these affect only a minority of people. The other end of the spectrum presents a modest loss but in a high proportion of patients.

As some patients get older, for whatever reason, their choroid gets thinner. We call that age-related choroidal atrophy, and these patients have a kind of yellowish-white appearance to their choroidal blood vessels.

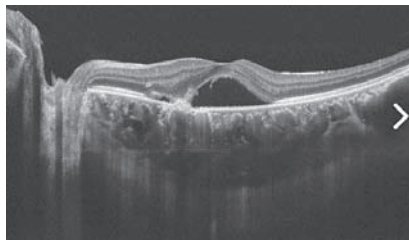
### Imaging CSC

In the 1960s, Don Gass thought that central serous chorioretinopathy (CSC) was due to choriocapillaris hyperpermeability.<sup>4</sup> He thought the choriocapillaris leaked excessive amounts of fluid that pushed its way up through the pigment epithelium and underneath the retina.

When I first became interested in imaging, I began with CSC and

indocyanine green, and found that people with CSC had these islands of hyperpermeability, so Gass was right—30 years ahead of his time, at least. He thought the hyperpermeability of the choroid created a pressure that lifted the RPE and created the leak. If that is true, then one would expect the choroid to be thicker. We looked at the choroid of patients with CSC, and it does get quite a bit thicker. Even if the subretinal fluid resolves, patients who have chronic CSC have thick choroids.

We have also found a number of patients who look like they have age-related macular degeneration (AMD), and they have neovascularization, but we don't see any other signs of AMD (e.g., drusen or focal hyperpigmentation). Interest-



**Central serous chorioretinopathy imaged using Topcon's DRI OCT-1 Atlantis.\***

ingly, the choroids in those patients are thicker, so we think that some patients who have AMD probably go through a different route. Instead of having drusen and focal hyperpigmentation, as described by AREDS, these patients have as their risk factor a thicker choroid. This same risk factor seems to lead to polypoidal choroidal vasculopathy in Asians, for instance.

I was part of a team of researchers who looked at a series of patients treated for CSC with thermal laser photocoagulation.<sup>5</sup> The fluid resolved in patients with CSC, and we measured their choroidal thick-

ness, but it didn't change. We also performed photodynamic therapy (PDT), and noted that two days after, their choroids became extra thick, then thinner as the subretinal fluid resolved. Laser treatment works and gets rid of the fluid, but at year one, the recurrence rate is the same as if they never had laser. Conversely, PDT has a very low rate of recurrence; probably because it affects the choroidal hyperpermeability, which is the root of the problem.

### Conclusion

As we've seen, when it comes to SS-OCT opportunities, conventional OCT allows us to view the vitreous and the retina, which is fine. But with the DRI OCT-1 Atlantis\*, we can accomplish even deeper imaging—with views of the vitreous, retina, choroid, sclera and optic nerve.

*Dr. Spaide practices at Vitreous-Retina-Macula Consultants of New York, where he specializes in diseases of the retina and vitreous. He has given lectures around the world and has published approximately 140 articles, book chapters and books about the diagnosis and treatment of retinal diseases.*

### REFERENCES

1. Nishida Y, Fujiwara T, Imamura Y, et al. Choroidal thickness and visual acuity in highly myopic eyes. *Retina*. 2012; 32(7):1229-1236.
2. Copete G, Flores-Moreno I, Montero J, et al. Direct comparison of spectral-domain and swept-source OCT in the measurement of choroidal thickness in normal eyes. *Br J Ophthalmol*. 2013; Nov 28. [Epub ahead of print].
3. Ho M, Liu D, Chan V, Lam D. Choroidal thickness measurement in myopic eyes by enhanced depth optical coherence tomography. *Ophthalmology*. 2013;120(9):1909-1914.
4. Gass JD. Pathogenesis of disciform detachment of the neuroepithelium. *Am J Ophthalmol*. 1967;63(3):Suppl:1-139.
5. Maruko I, Iida T, Sugano Y, et al. Subfoveal choroidal thickness after treatment of central serous chorioretinopathy. *Ophthalmology*. 2010;117:1792-1799.

*\*The DRI OCT-1 Atlantis has not been approved for sale in the United States.*

The opinions expressed in this supplement to *Review of Ophthalmology* do not necessarily reflect the views, or imply endorsement, of the editor or publisher. Copyright 2014, *Review of Ophthalmology*®. All rights reserved.