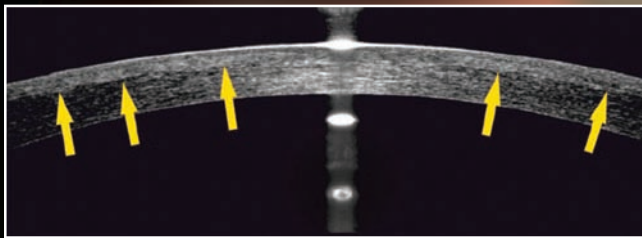
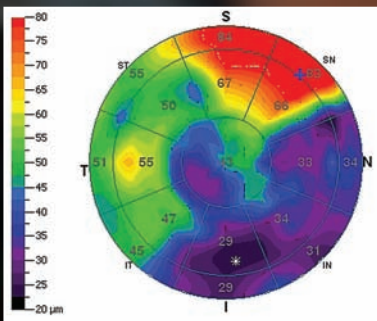
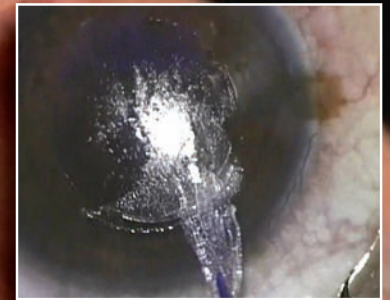


# REVIEW<sup>®</sup> of Ophthalmology

February 2014 • revophth.com



## Refractive Surgery Issue



Inlays and Presbyopia: On the Horizon P. 24

Crack a SMILE or Raise a Flap? P. 30

LASIK Xtra: Who Should Get It? P. 38

# ILEVRO™ Suspension

Designed to put potency  
precisely where you need it<sup>1,2</sup>

## ONCE-DAILY POST-OP

One drop should be applied once daily beginning 1 day prior to surgery through 14 days post-surgery, with an additional drop administered 30 to 120 minutes prior to surgery<sup>3</sup>

Use of ILEVRO™ Suspension more than 1 day prior to surgery or use beyond 14 days post-surgery may increase patient risk and severity of corneal adverse events<sup>3</sup>

### INDICATIONS AND USAGE

ILEVRO™ Suspension is a nonsteroidal, anti-inflammatory prodrug indicated for the treatment of pain and inflammation associated with cataract surgery.

#### Dosage and Administration

One drop of ILEVRO™ Suspension should be applied to the affected eye one-time-daily beginning 1 day prior to cataract surgery, continued on the day of surgery and through the first 2 weeks of the postoperative period. An additional drop should be administered 30 to 120 minutes prior to surgery.

### IMPORTANT SAFETY INFORMATION

#### Contraindications

ILEVRO™ Suspension is contraindicated in patients with previously demonstrated hypersensitivity to any of the ingredients in the formula or to other NSAIDs.

#### Warnings and Precautions

- **Increased Bleeding Time** – With some nonsteroidal anti-inflammatory drugs including ILEVRO™ Suspension there exists the potential for increased bleeding time. Ocularly applied nonsteroidal anti-inflammatory drugs may cause increased bleeding of ocular tissues (including hyphema) in conjunction with ocular surgery.
- **Delayed Healing** – Topical nonsteroidal anti-inflammatory drugs (NSAIDs) including ILEVRO™ Suspension may slow or delay healing. Concomitant use of topical NSAIDs and topical steroids may increase the potential for healing problems.
- **Corneal Effects** – Use of topical NSAIDs may result in keratitis. In some patients, continued use of topical NSAIDs may result in epithelial breakdown, corneal thinning, corneal erosion, corneal ulceration or corneal perforation. These events may be sight threatening. Patients with evidence of corneal epithelial breakdown should immediately discontinue use.

Patients with complicated ocular surgeries, corneal denervation, corneal epithelial defects, diabetes mellitus, ocular surface diseases (e.g., dry eye syndrome), rheumatoid arthritis, or repeat ocular surgeries within a short period of time may be at increased risk for corneal adverse events which may become sight threatening. Topical NSAIDs should be used with caution in these patients.

Use more than 1 day prior to surgery or use beyond 14 days post-surgery may increase patient risk and severity of corneal adverse events.

- **Contact Lens Wear** – ILEVRO™ Suspension should not be administered while using contact lenses.

#### Adverse Reactions

The most frequently reported ocular adverse reactions following cataract surgery occurring in approximately 5 to 10% of patients were capsular opacity, decreased visual acuity, foreign body sensation, increased intraocular pressure, and sticky sensation.

**For additional information about ILEVRO™ Suspension, please refer to the brief summary of prescribing information on adjacent page.**

**References:** 1. Ke T-L, Graff G, Spellman JM, Yanni JM. Nepafenac, a unique nonsteroidal prodrug with potential utility in the treatment of trauma-induced ocular inflammation. II: In vitro bioactivation and permeation of external ocular barriers. *Inflammation*. 2000;24(4):371-384. 2. Data on file. 3. ILEVRO™ Suspension package insert.

**Alcon**

a Novartis company

©2013 Novartis 2/13 ILV13030JAD

**ILEVRO™**  
**(nepafenac ophthalmic  
suspension) 0.3%**

# ILEVRO™

(nepafenac ophthalmic suspension) 0.3%

## BRIEF SUMMARY OF PRESCRIBING INFORMATION

### INDICATIONS AND USAGE

ILEVRO™ Suspension is indicated for the treatment of pain and inflammation associated with cataract surgery.

### DOSAGE AND ADMINISTRATION

#### Recommended Dosing

One drop of ILEVRO™ Suspension should be applied to the affected eye one-time-daily beginning 1 day prior to cataract surgery, continued on the day of surgery and through the first 2 weeks of the postoperative period. An additional drop should be administered 30 to 120 minutes prior to surgery.

#### Use with Other Topical Ophthalmic Medications

ILEVRO™ Suspension may be administered in conjunction with other topical ophthalmic medications such as beta-blockers, carbonic anhydrase inhibitors, alpha-agonists, cycloplegics, and mydriatics. If more than one topical ophthalmic medication is being used, the medicines must be administered at least 5 minutes apart.

### CONTRAINDICATIONS

ILEVRO™ Suspension is contraindicated in patients with previously demonstrated hypersensitivity to any of the ingredients in the formula or to other NSAIDs.

### WARNINGS AND PRECAUTIONS

#### Increased Bleeding Time

With some nonsteroidal anti-inflammatory drugs including ILEVRO™ Suspension, there exists the potential for increased bleeding time due to interference with thrombocyte aggregation. There have been reports that ocularly applied nonsteroidal anti-inflammatory drugs may cause increased bleeding of ocular tissues (including hyphemas) in conjunction with ocular surgery. It is recommended that ILEVRO™ Suspension be used with caution in patients with known bleeding tendencies or who are receiving other medications which may prolong bleeding time.

#### Delayed Healing

Topical nonsteroidal anti-inflammatory drugs (NSAIDs) including ILEVRO™ Suspension, may slow or delay healing. Topical corticosteroids are also known to slow or delay healing. Concomitant use of topical NSAIDs and topical steroids may increase the potential for healing problems.

#### Corneal Effects

Use of topical NSAIDs may result in keratitis. In some susceptible patients, continued use of topical NSAIDs may result in epithelial breakdown, corneal thinning, corneal erosion, corneal ulceration or corneal perforation. These events may be sight threatening. Patients with evidence of corneal epithelial breakdown should immediately discontinue use of topical NSAIDs including ILEVRO™ Suspension and should be closely monitored for corneal health. Postmarketing experience with topical NSAIDs suggests that patients with complicated ocular surgeries, corneal denervation, corneal epithelial defects, diabetes mellitus, ocular surface diseases (e.g., dry eye syndrome), rheumatoid arthritis, or repeat ocular surgeries within a short period of time may be at increased risk for corneal adverse events which may become sight threatening. Topical NSAIDs should be used with caution in these patients.

Postmarketing experience with topical NSAIDs also suggests that use more than 1 day prior to surgery or use beyond 14 days post surgery may increase patient risk and severity of corneal adverse events.

#### Contact Lens Wear

ILEVRO™ Suspension should not be administered while using contact lenses.

### ADVERSE REACTIONS

Because clinical studies are conducted under widely varying conditions, adverse reaction rates observed in the clinical studies of a drug cannot be directly compared to the rates in the clinical studies of another drug and may not reflect the rates observed in practice.

#### Ocular Adverse Reactions

The most frequently reported ocular adverse reactions following cataract surgery were capsular opacity, decreased visual acuity, foreign body sensation, increased intraocular pressure, and sticky sensation. These events occurred in approximately 5 to 10% of patients.

Other ocular adverse reactions occurring at an incidence of approximately 1 to 5% included conjunctival edema, corneal edema, dry eye, lid margin crusting, ocular discomfort, ocular hyperemia, ocular pain, ocular pruritus, photophobia, tearing and vitreous detachment.

Some of these events may be the consequence of the cataract surgical procedure.

### Non-Ocular Adverse Reactions

Non-ocular adverse reactions reported at an incidence of 1 to 4% included headache, hypertension, nausea/vomiting, and sinusitis.

### USE IN SPECIFIC POPULATIONS

#### Pregnancy

#### Teratogenic Effects.

**Pregnancy Category C:** Reproduction studies performed with nepafenac in rabbits and rats at oral doses up to 10 mg/kg/day have revealed no evidence of teratogenicity due to nepafenac, despite the induction of maternal toxicity. At this dose, the animal plasma exposure to nepafenac and amfenac was approximately 70 and 630 times human plasma exposure at the recommended human topical ophthalmic dose for rats and 20 and 180 times human plasma exposure for rabbits, respectively. In rats, maternally toxic doses  $\geq 10$  mg/kg were associated with dystocia, increased post-implantation loss, reduced fetal weights and growth, and reduced fetal survival.

Nepafenac has been shown to cross the placental barrier in rats. There are no adequate and well-controlled studies in pregnant women. Because animal reproduction studies are not always predictive of human response, ILEVRO™ Suspension should be used during pregnancy only if the potential benefit justifies the potential risk to the fetus.

#### Non-teratogenic Effects.

Because of the known effects of prostaglandin biosynthesis inhibiting drugs on the fetal cardiovascular system (closure of the ductus arteriosus), the use of ILEVRO™ Suspension during late pregnancy should be avoided.

#### Nursing Mothers

ILEVRO™ Suspension is excreted in the milk of lactating rats. It is not known whether this drug is excreted in human milk. Because many drugs are excreted in human milk, caution should be exercised when ILEVRO™ Suspension is administered to a nursing woman.

#### Pediatric Use

The safety and effectiveness of ILEVRO™ Suspension in pediatric patients below the age of 10 years have not been established.

#### Geriatric Use

No overall differences in safety and effectiveness have been observed between elderly and younger patients.

### NONCLINICAL TOXICOLOGY

#### Carcinogenesis, Mutagenesis, Impairment of Fertility

Nepafenac has not been evaluated in long-term carcinogenicity studies. Increased chromosomal aberrations were observed in Chinese hamster ovary cells exposed *in vitro* to nepafenac suspension. Nepafenac was not mutagenic in the Ames assay or in the mouse lymphoma forward mutation assay. Oral doses up to 5,000 mg/kg did not result in an increase in the formation of micronucleated polychromatic erythrocytes *in vivo* in the mouse micronucleus assay in the bone marrow of mice. Nepafenac did not impair fertility when administered orally to male and female rats at 3 mg/kg.

### PATIENT COUNSELING INFORMATION

#### Slow or Delayed Healing

Patients should be informed of the possibility that slow or delayed healing may occur while using nonsteroidal anti-inflammatory drugs (NSAIDs).

#### Avoiding Contamination of the Product

Patients should be instructed to avoid allowing the tip of the dispensing container to contact the eye or surrounding structures because this could cause the tip to become contaminated by common bacteria known to cause ocular infections. Serious damage to the eye and subsequent loss of vision may result from using contaminated solutions.

Use of the same bottle for both eyes is not recommended with topical eye drops that are used in association with surgery.

#### Contact Lens Wear

ILEVRO™ Suspension should not be administered while wearing contact lenses.

#### Intercurrent Ocular Conditions

Patients should be advised that if they develop an intercurrent ocular condition (e.g., trauma, or infection) or have ocular surgery, they should immediately seek their physician's advice concerning the continued use of the multi-dose container.

#### Concomitant Topical Ocular Therapy

If more than one topical ophthalmic medication is being used, the medicines must be administered at least 5 minutes apart.

#### Shake Well Before Use

Patients should be instructed to shake well before each use. U.S. Patent Nos. 5,475,034; 6,403,609; and 7,169,767.

**Alcon**

a Novartis company

ALCON LABORATORIES, INC.  
Fort Worth, Texas 76134 USA  
© 2013 Novartis 2/13 ILV13030JAD

# Probability of Blindness From Glaucoma Nearly Halved

The probability of blindness due to the serious eye disease glaucoma has decreased by nearly half since 1980, according to a study published this month in *Ophthalmology*. The researchers speculate that advances in diagnosis and therapy are likely causes for the decrease, but caution that a significant proportion of patients still progress to blindness.

A leading cause of irreversible blindness worldwide, glaucoma affects more than 2.7 million individuals aged 40 and older in the United States and 60.5 million people globally. Significant changes in diagnostic criteria, new therapies and tools as well as improvements in glaucoma management techniques have benefited individual patients; however their effect on the rates of visual impairment on a population level has remained unclear. This study, conducted by a team based at the Mayo Clinic, was the first to assess long-term changes in the risk of progression to blindness and the population incidence of glaucoma-related blindness. By identifying epidemiologic trends in glaucoma, the researchers hope to gain insight into best practices for the distribution of health and medical resources, as well as management approaches for entire populations.

The researchers reviewed every incident case (857 cases total) of open-angle glaucoma diagnosed from 1965 to 2009 in Olmsted County, Minn., one of the few places in the world where long-term population-based studies are conducted. They found that the 20-year probability and the population

incidence of blindness due to OAG in at least one eye had decreased from 25.8 percent for subjects diagnosed between 1965 and 1980 to 13.5 percent for those diagnosed between 1981 and 2000. The population incidence of blindness within 10 years of diagnosis also decreased from 8.7 per 100,000 to 5.5 per 100,000 for those groups, respectively. Yet, 15 percent of the patients diagnosed in the more recent timeframe still progressed to blindness.

“These results are extremely encouraging for both those suffering from glaucoma and the doctors who care for them, and suggest that the improvements in the diagnosis and treatment have played a key role in improving outcomes,” said Arthur J. Sit, MD, associate professor of ophthalmology at the Mayo Clinic College of Medicine and lead researcher for the study. “Despite this good news, the rate at which people continue to go blind due to OAG is still unacceptably high. This is likely due to late diagnosis and our incomplete understanding of glaucoma, so it is critical that research into this devastating disease continues, and all eye care providers be vigilant in looking for early signs of glaucoma during routine exams.”

## Diabetics Losing Vision Despite Advances

Despite recent advances in prevention

and treatment of most vision loss attributed to diabetes, a new study shows that less than half of Americans with damage to their eyes from diabetes are aware of the link between the disease and visual impairment, and only six in 10 had their eyes fully examined in the year leading up to the study.

The research, described online on Dec. 19 in *JAMA Ophthalmology*, also found that nearly half of those with diabetes and eye damage had not visited a clinician charged with managing their disease in that same time period.

“As a nation, we are woefully inadequate as health-care providers in explaining to our patients with diabetes that the condition can have a detrimental effect on their eyes,” says study leader Neil M. Bressler, MD, a professor of ophthalmology at the Johns Hopkins University School of Medicine and chief of the retina division at the Johns Hopkins Wilmer Eye Institute. “The earlier we catch diabetic eye disease, the greater the likelihood that we can help patients keep their good vision. Clearly, this research shows how far we have to go to educate people about this frequent and feared complication.”

People with diabetes have at least a 10-percent risk of developing diabetic macular edema during their lifetime, and estimates suggest that close to 745,000 of them in the United States have swelling in the macula.

Elevating The Quality Of Care In Ophthalmology



## Phillips\* Crosshair Axis Marker

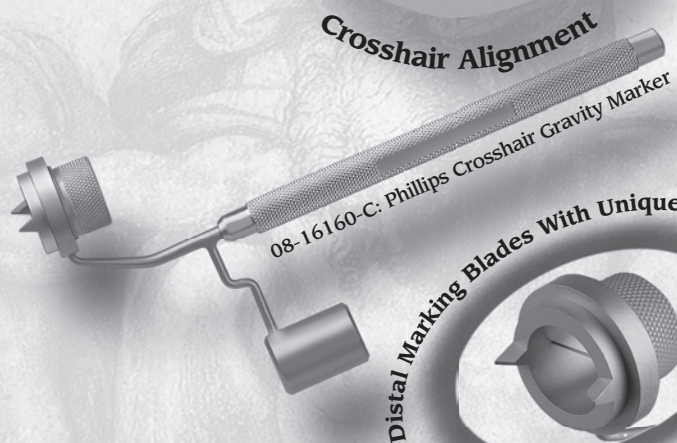
Until recently, 15 percent of patients who developed the condition and were treated for it with the standard laser therapy still lost their vision. Dr. Bressler says that ocular injections reduce the swelling and risk of vision loss to less than 5 percent. With treatment, moreover, half of patients find their vision improves, making prompt diagnosis critical.

For the study, the Johns Hopkins-led team of researchers used data collected between 2005 and 2008 from Americans enrolled in the National Health and Nutrition Examination Survey (NHANES). Among the 798 people over the age of 40 with a self-reported diagnosis of type 2 diabetes and who had retinal imaging done, 48 had diabetic macular edema and were asked in the survey whether a physician had told them about the link between diabetes and vision problems (44.7 percent were).

They were also asked whether they had seen a health-care provider about their diabetes in the previous year (46.7 percent had), and whether they had received an eye examination, including pupil dilation, in the previous year (59.7 percent had). Some 30 percent of the individuals with diabetic macular edema already had some type of vision loss related to the disease.

While some people fail to see eye doctors or diabetes educators because they lack insurance, Dr. Bressler says that most of the problem is likely a lack of understanding about the risks, and most people probably aren't referred to eye-care specialists who can quickly determine retinal vulnerability.

"We can prevent a lot of vision impairment or blindness if we can just get these people into the medical system," he says. Now that the extent of the problem is known, strategies can be developed to address issues of patient education, access to specialists and costs.



- **Gravity Weighted For Accurate Placement When Patient Is In The Upright Position.**
- **Axis Marks On Bevel To Manually Set To Desired Axis.**
- **Crosshair Function Allows Surgeon To Align Marks Directly While Viewing Topography, Allowing For A Safety Check And Finer Refinement Of Axis Before Marking.**
- **Reusable, Autoclavable, Made In The USA, Guaranteed For Life, And Available For A 30-Day Surgical Evaluation Without Obligation.**

**Contact Rhein Medical at 727-209-2244  
For More Information.**



3360 Scherer Drive, Suite B, St. Petersburg, FL 33716  
800-637-4346 • Tel: 727-209-2244 • Fax: 727-341-8123  
Email: [Info@RheinMedical.com](mailto:Info@RheinMedical.com) • Website: [www.RheinMedical.com](http://www.RheinMedical.com)  
\*Developed In Coordination With Andrew F. Phillips, M.D.

## Available Drug May Treat Aniridia

**University of British Columbia** and Vancouver Coastal Health scientists have developed a potential cure for a rare eye disease, showing for the first time that a drug can repair a birth defect.

They formulated the drug Ataluren into eye drops, and found that it consistently restored normal vision in mice who had aniridia, a condition that severely limits the vision of about 5,000 people in North America. A small clinical trial with children and teens is expected to begin next year in Vancouver, the United States and the United Kingdom.

Aniridia is caused by the presence of a “nonsense mutation”—an extra “stop sign” on the gene that interrupts production of a protein crucial for eye development.

Ataluren is believed to have the power to override the extra stop sign, thus allowing the protein to be made. The UBC-VCH scientists initially thought the drug would work only *in utero*—giving it to a pregnant mother to prevent aniridia from ever arising in her fetus. But then they gave their specially formulated Ataluren eye drops, which they call START, to two-week-old mice with aniridia, and found that it actually reversed the damage they had been born with.

“We were amazed to see how malleable the eye is after birth,” said Cheryl Gregory-Evans, PhD, an associate professor of ophthalmology and visual sciences and a neurobiologist at the Vancouver Coastal Health Research Institute. “This holds promise for treating other eye conditions caused by nonsense mutations, including some types of macular de-

generation. And if it reverses damage in the eye, it raises the possibility of a cure for other congenital disorders. The challenge is getting it to the right place at the right time.”

## Molecule Could Be Key to Corneal Transplant Success

**For the estimated 10** percent of patients whose bodies reject a corneal transplant, the odds of a second transplant succeeding are poor. All that could change, however, based on a UT Southwestern Medical Center study that has found a way to boost the corneal transplant acceptance rate.

In the study, researchers found that corneal transplants in mice were accepted 90 percent of the time when the action of an immune system molecule called interferon-gamma (IFN- $\gamma$ ) was blocked and when the mice shared the same major histocompatibility complex (MHC) genotype as the donor cornea. MHC matching is not typically done with human corneal transplants because of a high acceptance rate.

“Our findings indicate that neither MHC matching alone nor administration of anti-IFN- $\gamma$  antibody alone enhances graft survival. However, we found that when MHC matching is combined with anti-IFN- $\gamma$  therapy, long-term corneal transplant survival is almost guaranteed,” said Dr. Jerry Niederkorn, a professor of ophthalmology and microbiology at UT Southwestern and senior author of the study.

The study findings, reported in the December issue of the *American Journal of Transplantation*, suggest an option to improve the odds of a subsequent corneal transplant’s success for those patients whose first transplant was rejected.

More than 40,000 corneal trans-

plants are performed annually in the United States, making this surgical procedure one of the most common and successful in transplantation. But out of that total, about 4,000 fail, with the recipient’s body rejecting the corneal graft and requiring a second operation.

A surprising finding of the study was learning that IFN- $\gamma$  can act both as an immune system suppressor or activator, depending on the context of the histocompatibility antigens perceived by the immune system, Dr. Niederkorn said. Earlier studies indicated that this molecule only activated immune system rejection of transplants and that disabling IFN- $\gamma$  would improve the acceptance rate. But that was not necessarily the case; researchers found that when there was no MHC matching between the mice and the transplants, and IFN- $\gamma$  was disabled, the transplant rejection rate was 100 percent.

“Under those conditions, IFN- $\gamma$  was needed to maintain the T regulatory cells, which suppress the immune response,” Dr. Niederkorn said.

Rather than recommend transplant matching and inactivation of IFN- $\gamma$  for all first-time corneal transplant recipients, Dr. Niederkorn said this strategy would make the most sense for those who have already rejected a cornea, or for those individuals believed to be at risk for a corneal transplant rejection. But before a clinical trial can be launched to verify the results obtained in mice, further study is needed.

“We are working to develop an IFN- $\gamma$  antibody in eye-drop form,” Dr. Niederkorn said. “Then we need to test whether this antibody will work in animal models.”

The lead author of the study was Krishen Cunnusamy, PhD, a former postdoctoral researcher in Dr. Niederkorn’s lab and current UT Southwestern medical student. **REVIEW**

# ReSTOR® IOLs deliver **more.**



## Recommend AcrySof® IQ ReSTOR® +3.0 D Multifocal IOLs for the broadest range of vision.†

For cataract patients who desire decreased spectacle dependence for the broadest range of vision,  
**the AcrySof® IQ ReSTOR® +3.0 D Multifocal IOL delivers more:**

- The strength of true performance at all distances <sup>1</sup>
- The confidence of the trusted AcrySof® IQ platform
- The reassurance of over 93% patient satisfaction <sup>2</sup>

**For information about the lenses that give your patients more, visit [AlconSurgical.com](http://AlconSurgical.com)  
or contact your Alcon sales representative today.**

Please refer to the Important Safety Information on the accompanying page.

†. Broadest range of vision across all AcrySof® IOLs.

1. AcrySof® IQ ReSTOR® IOL Directions for Use.

2. AcrySof® IQ ReSTOR® IOL Clinical trial data on file (models SN6AD1 and SN6AD3). Fort Worth, TX; Alcon Laboratories, Inc.

© 2013 Novartis 9/13 RES13076JAD AlconSurgical.com

# Alcon®

a Novartis company

ACRY *Sof* IQ  
**ReSTOR®**

MULTIFOCAL IOLs

Deliver More



**To the Editor:**

The review (*Pediatric Patient*, December 2013) of the Pediatric Eye Disease Investigator Group's (PEDIG) article misses some contradictions in the group's reports.

A PEDIG finding was that the acuity of both the amblyopic and fellow eyes gradually improved with age prior to treatment.<sup>1</sup> (Table 3 [Baseline Characteristics According to Age at Enrollment]). The degree of improvement with increasing age was very similar to treatment outcomes. This confirmed Clarke's observation that "As in all trials, there is a possibility that those left untreated may suffer, but the no-treatment group in fact showed a tendency to spontaneous improvement."<sup>2</sup>

The lack of untreated controls in most amblyopia treatment studies makes it impossible to distinguish the effects of training and increasing literacy from the presumed benefits of treatment. The PEDIG authors agree that inclusion of an untreated control group would have been desirable from a scientific point of view.<sup>3</sup> Since "the response to treatment in this study was similar across the age range ..."<sup>4</sup> a delay in including a control group would not have incurred appreciable risk.

Spatial and temporal visual impairments are prominent features of amblyopia. Judging treatment outcomes with static and isolated optotypes may not be an optimum indicator of visual improvement. When reading ability was tested in amblyopic eyes that were successfully treated, a PEDIG study found that significant limitations were still present.<sup>5</sup>

PEDIG was formed in 1997 following a review by Snowdon and Stewart-Brown. They found "no studies of natural history of amblyopia, ... no randomised controlled trials of treatment vs. no treatment ..."<sup>6</sup> These deficiencies have still not been addressed by the PEDIG's reports. These lapses inappropriately elevate hypotheses that are based on insufficient or irrelevant data to dogma. We cannot be certain about their conclusions until objective information is available.

The clinical environment for amblyopia is complicated by the availability of many therapies in addition to occlusion and penalization. These include, among others, forehead massage, suturing eyelids closed, perceptual learning, rotating prisms, neuroadaptation, periauricular acupuncture, vision training, levodopa-carbidopa, colored lenses, Bangerter filters, supervised near work, playing computer games and neurologic organization training. The providers of these therapies claim results that are equivalent to conventional therapies. Michael Repka, MD, [of the American Academy of Ophthalmology] warned that the Affordable Care Act may encourage overutilization of amblyopia screening and treatments. He is correct, and the lack of objective data may encourage inappropriate remedies.

It is important for our profession to develop a sound basis for the diagnosis and treatment of children presumed to have amblyopia—a basis consistent with proofs of efficacy that are consistent with therapies in other specialties, a basis that shows improvement in acuity, reading rate, and other visual functions that does not occur without that treatment. We are all familiar enough with alternative treatment to know what awaits if we fail to properly address this issue now.

*Philip Lempert, MD  
Ithaca, N.Y.*

1. Pediatric Eye Disease Investigator Group. The clinical profile of moderate amblyopia in children younger than 7 years. *Arch Ophthalmol* 2002;120:281-7.
2. Clarke MP, Wright CM, Hrisos S, et al. Randomised controlled trial of treatment of unilateral visual impairment detected at preschool vision screening. *BMJ* 2003;327:1251.
3. The Pediatric Eye Disease Investigator Group. Amblyopia. *Ocular Surgery News* July 15, 2002 Page 7.
4. The Pediatric Eye Disease Investigator Group. The course of moderate amblyopia treated with patching in children: Experience of the amblyopia treatment study. *Am J Ophthalmol* 2003;136:620-9.
5. Repka MX, Kraker RT, Beck RW, Cotter SA, et al; Pediatric Eye Disease Investigator Group. Monocular oral reading performance after amblyopia treatment in children. *Am J Ophthalmol* 2008;146:942-7.
6. Snowdon S, Stewart-Brown SL. Preschool vision screening: Results of a systematic review. York: NHS centre for reviews, 1997 Report 9.



**CAUTION:** Federal (USA) law restricts this device to the sale by or on the order of a physician.

**INDICATIONS:** The AcrySof® IQ ReSTOR® Posterior Chamber Intraocular Lens (IOL) is intended for primary implantation for the visual correction of aphakia secondary to removal of a cataractous lens in adult patients with and without presbyopia, who desire near, intermediate and distance vision with increased spectacle independence. The lens is intended to be placed in the capsular bag.

**WARNING/PRECAUTION:** Careful pre-operative evaluation and sound clinical judgment should be used by the surgeon to decide the risk/benefit ratio before implanting a lens in a patient with any of the conditions described in the Directions for Use labeling. Physicians should target emmetropia, and ensure that IOL centration is achieved. Care should be taken to remove viscoelastic from the eye at the close of surgery.

Some patients may experience visual disturbances and/or discomfort due to multifocality, especially under dim light conditions. Clinical studies with

the AcrySof® ReSTOR® lens indicated that posterior capsule opacification (PCO), when present, developed earlier into clinically significant PCO. Prior to surgery, physicians should provide prospective patients with a copy of the Patient Information Brochure available from Alcon for this product informing them of possible risks and benefits associated with the AcrySof® IQ ReSTOR® IOLs.

Studies have shown that color vision discrimination is not adversely affected in individuals with the AcrySof® Natural IOL and normal color vision. The effect on vision of the AcrySof® Natural IOL in subjects with hereditary color vision defects and acquired color vision defects secondary to ocular disease (e.g., glaucoma, diabetic retinopathy, chronic uveitis, and other retinal or optic nerve diseases) has not been studied. Do not resterilize; do not store over 45° C; use only sterile irrigating solutions such as BSS® or BSS PLUS® Sterile Intraocular Irrigating Solutions.

**ATTENTION:** Reference the Directions for Use labeling for a complete listing of indications, warnings and precautions.



a Novartis company



# Trade Up To Keeler

Trade-in your old Kowa hand-held slit lamp & get  
\$600 towards Keeler's Advanced PSL Classic!



## Powerful & Portable!

- Precision machined aluminum chassis
- Advanced optics, x10 & x16 magnification
- Controllable illumination from maximum to zero
- Most Apertures and filters along with 1.mm square light patch for assessing a/c flare



## Trade-in & Special Bonus

FREE iPhone 4 Adapter and Carrying Case.  
Offer expires March 31, 2014.

Buy Online!  
[keelerusa.com](http://keelerusa.com)



**Keeler**  
OPTICS

# CONTRIBUTORS

**CHIEF MEDICAL EDITOR**

Mark H. Blecher, MD

**BOTTOM LINE**

Dennis D. Sheppard, MD

**CONTACT LENSES**

Penny Asbell, MD

**CORNEA / ANTERIOR SEGMENT**

Thomas John, MD

**GLAUCOMA MANAGEMENT**

Peter Netland, MD, PHD  
Kuldev Singh, MD

**PEDIATRIC PATIENT**

Christopher M. Fecarotta, MD

**PLASTIC POINTERS**

Ann P. Murchison, MD, MPH

**REFRACTIVE SURGERY**

Arturo S. Chayet, MD

**RETINAL INSIDER**

Carl Regillo, MD, FACS  
Emmett T. Cunningham Jr., MD, PHD, MPH

**TECHNOLOGY UPDATE**

Steven T. Charles, MD  
Michael Colvard, MD

**THERAPEUTIC TOPICS**

Mark Abelson, MD

**WILLS RESIDENTS CASE SERIES**

David Perlmutter, MD

**BUSINESS OFFICES**

11 CAMPUS BOULEVARD, SUITE 100  
NEWTOWN SQUARE, PA 19073  
SUBSCRIPTION INQUIRIES (877) 529-1746  
(USA ONLY); OUTSIDE USA, CALL (847) 763-9630

**BUSINESS STAFF**

SALES MANAGER, NORTHEAST,  
MID ATLANTIC, OHIO

**JAMES HENNE**

(610) 492-1017 JHENNE@JOBSON.COM

SALES MANAGER, SOUTHEAST, WEST

**MICHELE BARRETT**

(610) 492-1014 MBARRETT@JOBSON.COM

**CLASSIFIED ADVERTISING**

(888)-498-1460

VICE PRESIDENT OF OPERATIONS

**CASEY FOSTER**

(610) 492-1007 CFOSTER@JOBSON.COM

PRODUCTION MANAGER

**SCOTT TOBIN**

(610) 492-1011 STOBIN@JOBSON.COM

**SUBSCRIPTIONS**

\$63 A YEAR, \$99 (U.S.) IN CANADA,  
\$158 (U.S.) IN ALL OTHER COUNTRIES.

SUBSCRIPTIONS E-MAIL: [RHSUBS@HALLDATA.COM](mailto:RHSUBS@HALLDATA.COM)  
CIRCULATION E-MAIL: [RHSUBS@HALLDATA.COM](mailto:RHSUBS@HALLDATA.COM)

**CIRCULATION**

PO BOX 2026, SKOKIE, IL 60076  
(877) 529-1746  
OUTSIDE USA: (847)763-9630  
FAX: (847)763-9631

SENIOR CIRCULATION MANAGER

**HAMILTON MAHER**

(212) 219-7870 hmaher@jhihealth.com

CHIEF OPERATING OFFICER

**JEFF MACDONALD**

CEO, INFORMATION GROUP SERVICES

**MARC FERRARA**

SENIOR VICE PRESIDENT, HUMAN RESOURCES

**LORRAINE ORLANDO**

VICE PRESIDENT, CREATIVE SERVICES & PRODUCTION

**MONICA TETTAMANZI**

VICE PRESIDENT, CIRCULATION

**EMELDA BAREA**



100 Avenue of the Americas  
New York, NY 10013

# ADVISORY BOARD

**PENNY A. ASBELL, MD**, NEW YORK CITY

**WILLIAM I. BOND, MD**, PEKIN, ILL.

**ALAN N. CARLSON, MD**, DURHAM, N.C.

**Y. RALPH CHU, MD**, EDINA, MINN.

**ADAM J. COHEN, MD**, DOWNERS GROVE, ILL.

**UDAY DEVGAN, MD, FACS**, LOS ANGELES

**ERIC DONNENFELD, MD**, ROCKVILLE CENTRE, N.Y.

**DANIEL S. DURRIE, MD**, KANSAS CITY, MO.

**ROBERT EPSTEIN, MD**, MCHENRY, ILL.

**ROBERT D. FECHTNER, MD**, NEWARK, N.J.

**WILLIAM J. FISHKIND, MD**, TUCSON, ARIZ.

**JAMES P. GILLS, MD**, TARPON SPRINGS, FLA.

**HARRY GRABOW, MD**, SARASOTA, FLA.

**DOUGLAS K. GRAYSON, MD**, NEW YORK CITY

**R. BRUCE GRENE, MD**, WICHITA, KAN.

**THOMAS S. HARBIN, MD, MBA**, ATLANTA

**DAVID R. HARDTEN, MD**, MINNEAPOLIS

**KENNETH J. HOFFER, MD**, SANTA MONICA, CALIF.

**JACK T. HOLLADAY, MD, MSEE**, HOUSTON

**JOHN D. HUNKELER, MD**, KANSAS CITY, MO.

**THOMAS JOHN, MD**, TINLEY PARK, ILL.

**ROBERT M. KERSHNER, MD, MS, FACS**, BOSTON

**GUY M. KEZIRIAN, MD**, PARADISE VALLEY, ARIZ.

**TERRY KIM, MD**, DURHAM, N.C.

**TOMMY KORN, MD**, SAN DIEGO

**DAVID A. LEE, MD**, HOUSTON

**FRANCIS S. MAH, MD**, PITTSBURGH

**NICK MAMALIS, MD**, SALT LAKE CITY

**WILLIAM G. MARTIN, MD**, OREGON, OHIO

**MIKE S. MCFARLAND, MD**, PINE BLUFF, ARK.

**JEFFREY B. MORRIS, MD, MPH**, ENCINITAS, CALIF.

**MARLENE R. MOSTER, MD**, PHILADELPHIA

**ROBERT J. NOECKER, MD**, FAIRFIELD, CONN.

**ROBERT OSHER, MD**, CINCINNATI

**MARK PACKER, MD**, EUGENE, ORE.

**STEPHEN PASCUCCI, MD**, BONITA SPRINGS, FLA.

**PAUL PENDER, MD**, BEDFORD, N.H.

**CHRISTOPHER J. RAPUANO, MD**, PHILADELPHIA

**AUGUST READER III, MD**, SAN FRANCISCO

**TONY REALINI, MD**, MORGANTOWN, W.V.

**KENNETH J. ROSENTHAL, MD**, GREAT NECK, N.Y.

**ERIC ROTHCHILD, MD**, DELRAY BEACH, FLA.

**SHERI ROWEN, MD**, BALTIMORE

**JAMES J. SALZ, MD**, LOS ANGELES

**INGRID U. SCOTT, MD, MPH**, HERSHEY, PA.

**JOEL SCHUMAN, MD**, PITTSBURGH

**GAURAV SHAH, MD**, ST. LOUIS

**DAVID R. STAGER JR., MD**, DALLAS

**KARL STONECIPHER, MD**, GREENSBORO, N.C.

**JAMES C. TSAI, MD**, NEW HAVEN, CONN.

**VANCE THOMPSON, MD**, SIOUX FALLS, S.D.

**FARRELL C. TYSON, MD**, CAPE CORAL, FLA.

**R. BRUCE WALLACE III, MD**, ALEXANDRIA, LA.

**ROBERT G. WILEY, MD**, CLEVELAND

**FRANK WEINSTOCK, MD**, CANTON, OHIO

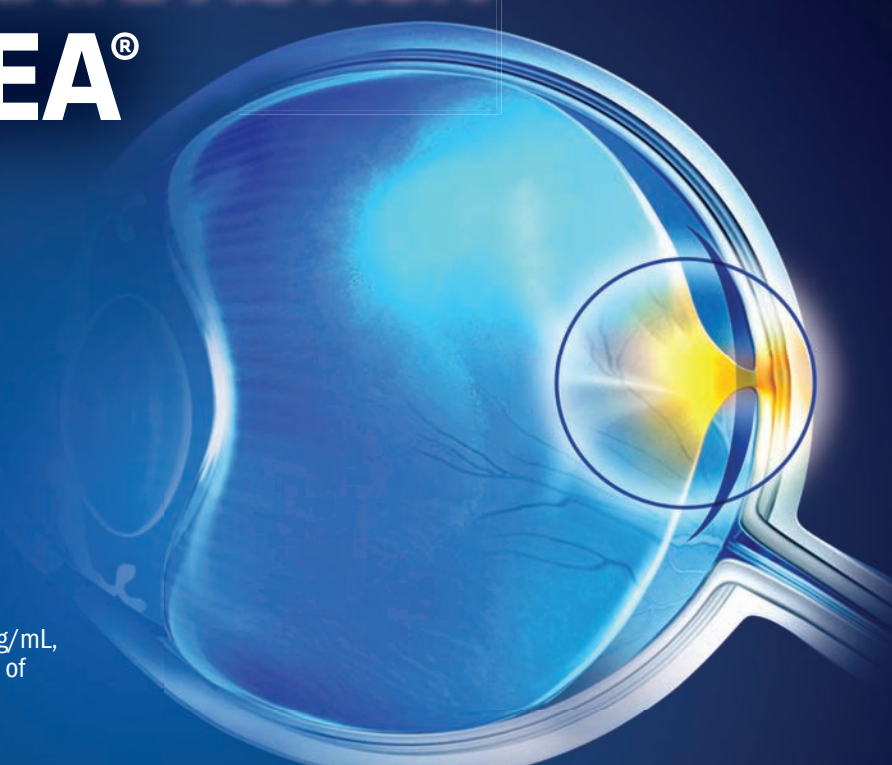
**JACQUELINE M.S. WINTERKORN, MD, PHD**, NEW YORK CITY

REVIEW OF OPHTHALMOLOGY (ISSN 1081-0226; USPS No. 0012-345) is published monthly, 12 times per year by Jobson Medical Information, 100 Avenue of the Americas, New York, NY 10013-1678. Periodicals postage paid at New York, NY and additional mailing offices. Postmaster: Send address changes to Review of Ophthalmology, PO Box 2026, Skokie, IL 60076, USA. Subscription Prices: US One Year \$63.00, US Two Year \$112.00, Canada One Year \$99.00, Canada Two Year \$181.00, Int'l One Year \$158.00, Int'l Two Year \$274.00. For subscription information call (877) 529-1746 (USA only); outside USA, call (847) 763-9631. Canada Post: Publications Mail Agreement #40612608. Canada Returns to be sent to Bleuchip International, P.O. Box 25542, London, ON N6C 6B2.V



The **FIRST AND ONLY** pharmacologic treatment for symptomatic VMA

# TAKE IMMEDIATE ACTION WITH JETREA®



## Indication

JETREA® (ocriplasmin) Intravitreal Injection, 2.5 mg/mL, is a proteolytic enzyme indicated for the treatment of symptomatic vitreomacular adhesion (VMA).

## IMPORTANT SAFETY INFORMATION

### Warnings and Precautions

- A decrease of  $\geq 3$  lines of best-corrected visual acuity (BCVA) was experienced by 5.6% of patients treated with JETREA® and 3.2% of patients treated with vehicle in the controlled trials. The majority of these decreases in vision were due to progression of the condition with traction and many required surgical intervention. Patients should be monitored appropriately.
- Intravitreal injections are associated with intraocular inflammation/infection, intraocular hemorrhage, and increased intraocular pressure (IOP). Patients should be monitored and instructed to report any symptoms without delay. In the controlled trials, intraocular inflammation occurred in 7.1% of patients injected with JETREA® vs 3.7% of patients injected with vehicle. Most of the post-injection intraocular inflammation events were mild and transient. If the contralateral eye requires treatment with JETREA®, it is not recommended within 7 days of the initial injection in order to monitor the post-injection course in the injected eye.
- Potential for lens subluxation.
- In the controlled trials, the incidence of retinal detachment was 0.9% in the JETREA® group and 1.6% in the vehicle group, while the incidence of retinal tear (without detachment) was 1.1% in the JETREA® group and 2.7% in the vehicle group. Most of these events occurred during or after vitrectomy in both groups.
- Dyschromatopsia (generally described as yellowish vision) was reported in 2% of all patients injected with JETREA®. In approximately half of these dyschromatopsia cases, there were also electroretinographic (ERG) changes reported (a- and b-wave amplitude decrease).

### Adverse Reactions

- The most commonly reported reactions ( $\geq 5\%$ ) in patients treated with JETREA® were vitreous floaters, conjunctival hemorrhage, eye pain, photopsia, blurred vision, macular hole, reduced visual acuity, visual impairment, and retinal edema.

Please see Brief Summary of full Prescribing Information on adjacent page.



VISIT [JETREACARE.COM](http://JETREACARE.COM) OR SCAN  
QR CODE FOR REIMBURSEMENT  
AND ORDERING INFORMATION

**BRIEF SUMMARY OF FULL PRESCRIBING INFORMATION**

Please see the JETREA® package insert for full Prescribing Information.

**1 INDICATIONS AND USAGE**

JETREA is a proteolytic enzyme indicated for the treatment of symptomatic vitreomacular adhesion.

**2 DOSAGE AND ADMINISTRATION**

**2.1 General Dosing Information**

Must be diluted before use. For single-use ophthalmic intravitreal injection only. JETREA must only be administered by a qualified physician.

**2.2 Dosing**

The recommended dose is 0.125 mg (0.1 mL of the diluted solution) administered by intravitreal injection to the affected eye once as a single dose.

**2.3 Preparation for Administration**

Remove the vial (2.5 mg/mL corresponding to 0.5 mg ocriplasmin) from the freezer and allow to thaw at room temperature (within a few minutes). Once completely thawed, remove the protective polypropylene flip-off cap from the vial. The top of the vial should be disinfected with an alcohol wipe. Using aseptic technique, add 0.2 mL of 0.9% w/v Sodium Chloride Injection, USP (sterile, preservative-free) into the JETREA vial and gently swirl the vial until the solutions are mixed.

Visually inspect the vial for particulate matter. Only a clear, colorless solution without visible particles should be used. Using aseptic technique, withdraw all of the diluted solution using a sterile #19 gauge needle (slightly tilt the vial to ease withdrawal) and discard the needle after withdrawal of the vial contents. Do not use this needle for the intravitreal injection.

Replace the needle with a sterile #30 gauge needle, carefully expel the air bubbles and excess drug from the syringe and adjust the dose to the 0.1 mL mark on the syringe (corresponding to 0.125 mg ocriplasmin). THE SOLUTION SHOULD BE USED IMMEDIATELY AS IT CONTAINS NO PRESERVATIVES. Discard the vial and any unused portion of the diluted solution after single use.

**2.4 Administration and Monitoring**

The intravitreal injection procedure should be carried out under controlled aseptic conditions, which include the use of sterile gloves, a sterile drape and a sterile eyelid speculum (or equivalent). Adequate anesthesia and a broad spectrum microbicide should be administered according to standard medical practice.

The injection needle should be inserted 3.5 - 4.0 mm posterior to the limbus aiming towards the center of the vitreous cavity, avoiding the horizontal meridian. The injection volume of 0.1 mL is then delivered into the mid-vitreous.

Immediately following the intravitreal injection, patients should be monitored for elevation in intraocular pressure. Appropriate monitoring may consist of a check for perfusion of the optic nerve head or tonometry. If required, a sterile paracentesis needle should be available.

Following intravitreal injection, patients should be instructed to report any symptoms suggestive of endophthalmitis or retinal detachment (e.g., eye pain, redness of the eye, photophobia, blurred or decreased vision) without delay [see Patient Counseling Information].

Each vial should only be used to provide a single injection for the treatment of a single eye. If the contralateral eye requires treatment, a new vial should be used and the sterile field, syringe, gloves, drapes, eyelid speculum, and injection needles should be changed before JETREA is administered to the other eye, however, treatment with JETREA in the other eye is not recommended within 7 days of the initial injection in order to monitor the post-injection course including the potential for decreased vision in the injected eye.

Repeated administration of JETREA in the same eye is not recommended [see Nonclinical Toxicology].

After injection, any unused product must be discarded.

No special dosage modification is required for any of the populations that have been studied (e.g. gender, elderly).

**3 DOSAGE FORMS AND STRENGTHS**

Single-use glass vial containing JETREA 0.5 mg in 0.2 mL solution for intravitreal injection (2.5 mg/mL).

**4 CONTRAINDICATIONS**

None

**5 WARNINGS AND PRECAUTIONS**

**5.1 Decreased Vision**

A decrease of  $\geq 3$  line of best corrected visual acuity (BCVA) was experienced by 5.6% of patients treated with JETREA and 3.2% of patients treated with vehicle in the controlled trials [see Clinical Studies].

The majority of these decreases in vision were due to progression of the condition with traction and many required surgical intervention. Patients should be monitored appropriately [see Dosage and Administration].

**5.2 Intravitreal Injection Procedure Associated Effects**

Intravitreal injections are associated with intraocular inflammation/infection, intraocular hemorrhage and increased intraocular pressure (IOP). In the controlled trials, intraocular inflammation occurred in 71% of patients injected with JETREA vs. 3.7% of patients injected with vehicle. Most of the post-injection intraocular inflammation events were mild and transient. Intraocular hemorrhage occurred in 2.4% vs. 3.7% of patients injected with JETREA vs. vehicle, respectively. Increased intraocular pressure occurred in 4.1% vs. 5.3% of patients injected with JETREA vs. vehicle, respectively.

**5.3 Potential for Lens Subluxation**

One case of lens subluxation was reported in a patient who received an intravitreal injection of 0.175 mg (1.4 times higher than the recommended dose). Lens subluxation was observed in three animal species (monkey, rabbit, minipig) following a single intravitreal injection that achieved vitreous concentrations of ocriplasmin 1.4 times higher than achieved with the recommended treatment dose. Administration of a second intravitreal dose in monkeys, 28 days apart, produced lens subluxation in 100% of the treated eyes [see Nonclinical Toxicology].

**5.4 Retinal Breaks**

In the controlled trials, the incidence of retinal detachment was 0.9% in the JETREA group and 1.6% in the vehicle group, while the incidence of retinal tear (without detachment) was 1.1% in the JETREA group and 2.7% in the vehicle group. Most of these events occurred during or after vitrectomy in both groups. The incidence of retinal detachment that occurred pre-vitrectomy was 0.4% in the JETREA group and none in the vehicle group, while the incidence of retinal tear (without detachment) that occurred pre-vitrectomy was none in the JETREA group and 0.5% in the vehicle group.

**5.5 Dyschromatopsia**

Dyschromatopsia (generally described as yellowish vision) was reported in 2% of all patients injected with JETREA. In approximately half of these dyschromatopsia cases there were also electroretinographic (ERG) changes reported (a- and b-wave amplitude decrease).

**6 ADVERSE REACTIONS**

The following adverse reactions are described below and elsewhere in the labeling:

- Decreased Vision [see Warnings and Precautions]
- Intravitreal Injection Procedure Associated Effects [see Warnings and Precautions and Dosage and Administration]
- Potential for Lens Subluxation [see Warnings and Precautions]
- Retinal Breaks [see Warnings and Precautions and Dosage and Administration]

**6.1 Clinical Trials Experience**

Because clinical trials are conducted under widely varying conditions, adverse reaction rates in one clinical trial of a drug cannot be directly compared with rates in the clinical trials of the same or another drug and may not reflect the rates observed in practice.

Approximately 800 patients have been treated with an intravitreal injection of JETREA. Of these, 465 patients received an intravitreal injection of ocriplasmin 0.125 mg (187 patients received vehicle) in the 2 vehicle-controlled studies (Study 1 and Study 2).

The most common adverse reactions (incidence 5% - 20% listed in descending order of frequency) in the vehicle-controlled clinical studies were: vitreous floaters, conjunctival hemorrhage, eye pain, photopsia, blurred vision, macular hole, reduced visual acuity, visual impairment, and retinal edema.

Less common adverse reactions observed in the studies at a frequency of 2% - < 5% in patients treated with JETREA included macular edema, increased intraocular pressure, anterior chamber cell, photophobia, vitreous detachment, ocular discomfort, iritis, cataract, dry eye, metamorphopsia, conjunctival hyperemia, and retinal degeneration.

Dyschromatopsia was reported in 2% of patients injected with JETREA, with the majority of cases reported from two uncontrolled clinical studies. In approximately

half of these dyschromatopsia cases there were also electroretinographic (ERG) changes reported (a- and b-wave amplitude decrease).

**6.2 Immunogenicity**

As with all therapeutic proteins, there is potential for immunogenicity. Immunogenicity for this product has not been evaluated.

**8 USE IN SPECIFIC POPULATIONS**

**8.1 Pregnancy: Teratogenic Effects**

Pregnancy Category C. Animal reproduction studies have not been conducted with ocriplasmin. There are no adequate and well-controlled studies of ocriplasmin in pregnant women. It is not known whether ocriplasmin can cause fetal harm when administered to a pregnant woman or can affect reproduction capacity. The systemic exposure to ocriplasmin is expected to be low after intravitreal injection of a single 0.125 mg dose. Assuming 100% systemic absorption (and a plasma volume of 2700 mL), the estimated plasma concentration is 46 ng/mL. JETREA should be given to a pregnant woman only if clearly needed.

**8.3 Nursing Mothers**

It is not known whether ocriplasmin is excreted in human milk. Because many drugs are excreted in human milk, and because the potential for absorption and harm to infant growth and development exists, caution should be exercised when JETREA is administered to a nursing woman.

**8.4 Pediatric Use**

Safety and effectiveness in pediatric patients have not been established.

**8.5 Geriatric Use**

In the clinical studies, 384 and 145 patients were  $\geq 65$  years and of these 192 and 73 patients were  $\geq 75$  years in the JETREA and vehicle groups respectively. No significant differences in efficacy or safety were seen with increasing age in these studies.

**10 OVERDOSAGE**

The clinical data on the effects of JETREA overdose are limited. One case of accidental overdose of 0.250 mg ocriplasmin (twice the recommended dose) was reported to be associated with inflammation and a decrease in visual acuity.

**13 NONCLINICAL TOXICOLOGY**

**13.1 Carcinogenesis, Mutagenesis, Impairment of Fertility**

No carcinogenicity, mutagenicity or reproductive and developmental toxicity studies were conducted with ocriplasmin.

**13.2 Animal Toxicology and/or Pharmacology**

The ocular toxicity of ocriplasmin after a single intravitreal dose has been evaluated in rabbits, monkeys and minipigs. Ocricplasmin induced an inflammatory response and transient ERG changes in rabbits and monkeys, which tended to resolve over time. Lens subluxation was observed in the 3 species at ocricplasmin concentrations in the vitreous at or above 41 mcg/mL, a concentration 1.4-fold above the intended clinical concentration in the vitreous of 29 mcg/mL. Intraocular hemorrhage was observed in rabbits and monkeys.

A second intravitreal administration of ocricplasmin (28 days apart) in monkeys at doses of 75 mcg/eye (41 mcg/mL vitreous) or 125 mcg/eye (68 mcg/mL vitreous) was associated with lens subluxation in all ocricplasmin treated eyes. Sustained increases in IOP occurred in two animals with lens subluxation. Microscopic findings in the eye included vitreous liquefaction, degeneration/disruption of the hyaloideocapsular ligament (with loss of ciliary zonular fibers), lens degeneration, mononuclear cell infiltration of the vitreous, and vacuolation of the retinal inner nuclear cell layer. These doses are 1.4-fold and 2.3-fold the intended clinical concentration in the vitreous of 29 mcg/mL, respectively.

**14 CLINICAL STUDIES**

The efficacy and safety of JETREA was demonstrated in two multicenter, randomized, double masked, vehicle-controlled, 6 month studies in patients with symptomatic vitreomacular adhesion (VMA). A total of 652 patients (JETREA 464, vehicle 188) were randomized in these 2 studies. Randomization was 2:1 (JETREA:vehicle) in Study 1 and 3:1 in Study 2.

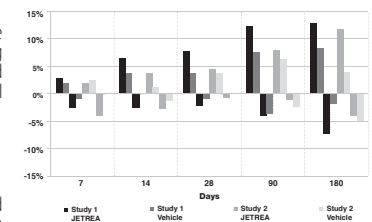
Patients were treated with a single injection of JETREA or vehicle. In both of the studies, the proportion of patients who achieved VMA resolution at Day 28 (i.e., achieved success on the primary endpoint) was significantly higher in the ocricplasmin group compared with the vehicle group through Month 6.

The number of patients with at least 3 lines increase in visual acuity was numerically higher in the ocricplasmin group compared to vehicle in both trials, however, the number of patients with at least a 3 lines decrease in visual acuity was also higher in the ocricplasmin group in one of the studies (Table 1 and Figure 1).

**Table 1: Categorical Change from Baseline in BCVA at Month 6, Irrespective of Vitrectomy (Study 1 and Study 2)**

Study 1			
	JETREA	Vehicle	Difference (95% CI)
<b><math>\geq 3</math> line Improvement in BCVA</b>			
Month 6	28 (12.8%)	9 (8.4%)	4.4 (-2.5, 11.2)
<b>&gt; 3 line Worsening in BCVA</b>			
Month 6	16 (7.3%)	2 (1.9%)	5.4 (1.1, 9.7)
Study 2			
	JETREA	Vehicle	Difference (95% CI)
<b><math>\geq 3</math> line Improvement in BCVA</b>			
Month 6	29 (11.8%)	3 (3.8%)	8.1 (2.3, 13.9)
<b>&gt; 3 line Worsening in BCVA</b>			
Month 6	10 (4.1%)	4 (5.0%)	-0.9 (-6.3, 4.5)

**Figure 1: Percentage of Patients with Gain or Loss of  $\geq 3$  Lines of BCVA at Protocol-Specified Visits**



**16 HOW SUPPLIED/STORAGE AND HANDLING**

Each vial of JETREA contains 0.5 mg ocricplasmin in 0.2 mL citric-buffered solution (2.5 mg/mL). JETREA is supplied in a 2 mL glass vial with a latex free rubber stopper. Vials are for single use only.

**Storage**

Store frozen at or below -4°F (-20°C). Protect the vials from light by storing in the original package until time of use.

**17 PATIENT COUNSELING INFORMATION**

In the days following JETREA administration, patients are at risk of developing intraocular inflammation/infection. Advise patients to seek immediate care from an ophthalmologist if the eye becomes red, sensitive to light, painful, or develops a change in vision [see Warnings and Precautions].

Patients may experience temporary visual impairment after receiving an intravitreal injection of JETREA [see Warnings and Precautions]. Advise patients to not drive or operate heavy machinery until this visual impairment has resolved. If visual impairment persists or decreases further, advise patients to seek care from an ophthalmologist.

Manufactured for: ThromboGenics, Inc.  
101 Wood Avenue South, 6<sup>th</sup> Floor  
Iselin, NJ 08830

U.S. License Number: 1866  
©2013, ThromboGenics, Inc. All rights reserved.  
Version 1.0

Initial U.S. Approval: 2012  
ThromboGenics U.S. patents: 7,445,775; 7,547,435; 7,914,783 and other pending patents.

JETREA and the JETREA logo are trademarks or registered trademarks of ThromboGenics NV in the United States, European Union, Japan, and other countries.

# REVIEW<sup>®</sup> of Ophthalmology

February 2014 • Volume XXI No. 2 | revophth.com

## Cover Focus



### 24 | **Inlays and Presbyopia: The Next Frontier**

*By Christopher Kent, Senior Editor*

A look at three leading approaches using inlays to expand presbyopic patients' range of vision.

### 30 | **Crack a SMILE or Raise a Flap?**

*By Walter Bethke, Managing Editor*

The benefits and drawbacks of this unique intrastromal refractive surgery procedure.

### 34 | **Refractive Surgeons Embrace Thin Flaps**

*By Walter Bethke, Managing Editor*

Our survey of refractive surgeons reveals the tools and techniques they like most.

### 38 | **LASIK Xtra: Is It for Everyone?**

*By Michelle Stephenson, Contributing Editor*

Surgeons have begun combining LASIK and cross-linking to avoid post-LASIK ectasia and to improve refractive outcomes.

# Departments

---

4 | [Review News](#)

17 | [Editor's Page](#)

18 | [Technology Update](#)  
**The Integrated Cataract Surgical Suite**  
By linking diagnostic and surgical instruments, companies hope to improve safety and efficacy.

42 | [Retinal Insider](#)  
**Multimodal Imaging of APMPE and Related Disorders**  
Recognizing the distinctive features of each placoid disorder is critical for accurate and timely diagnosis and management.

50 | [Therapeutic Topics](#)  
**Wide Choices for Ocular Diagnoses**  
A look at the value and utility of a range of diagnostic techniques and technology.

54 | [Glaucoma Management](#)  
**NTG: The Nocturnal Blood Pressure Factor**  
Evidence indicates that large dips in blood pressure at night correlate with progression in normal-tension glaucoma patients.

58 | [Refractive Surgery](#)  
**New Ways to Detect Keratoconus**  
Looking at corneal imaging in different ways can enhance your ability to avoid risky surgeries.

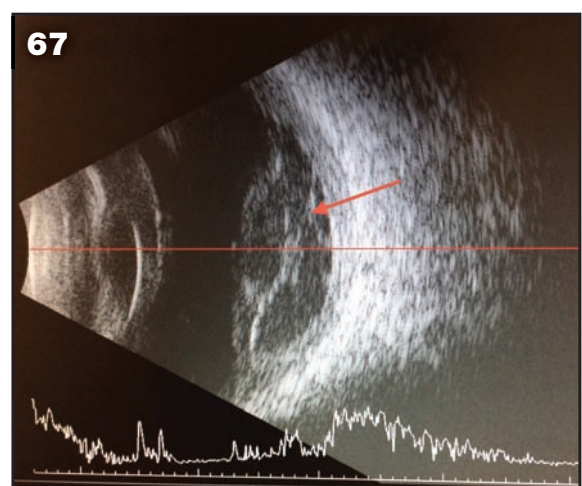
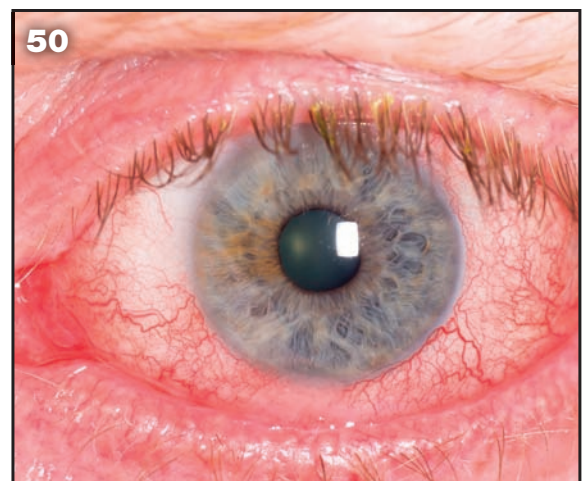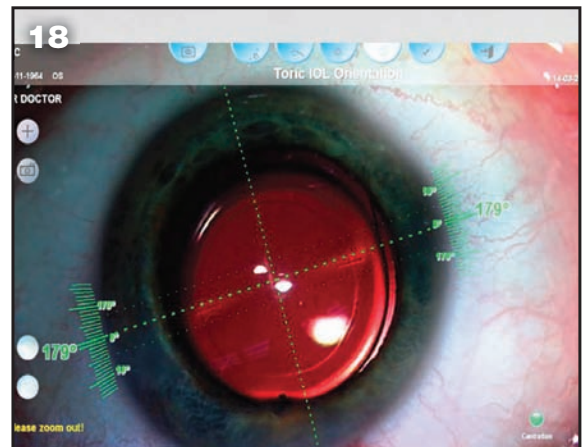
60 | [Research Review](#)  
**Effects of BAK on Surgical Outcomes**

62 | [Product News](#)  
**RPS Office Dry-Eye Test Cleared by FDA**

64 | [Classified Ads](#)

67 | [Wills Eye Resident Case Series](#)

70 | [Advertising Index](#)



The Quintessential



## BACITRACIN OPHTHALMIC OINTMENT USP

### Proven therapeutic utility in blepharitis, conjunctivitis, and other superficial ocular infections

- **Profound bactericidal effect against gram-positive pathogens<sup>1</sup>**
- **Excellent, continued resistance profile**—maintains susceptibility,<sup>2,3</sup> even against methicillin-resistant *Staphylococcus aureus*<sup>4</sup>
- Ointment provides **long-lasting ocular surface contact time** and **greater bioavailability<sup>5</sup>**
- **Anti-infective efficacy** in a lubricating base<sup>6</sup>
- **Unsurpassed safety profile**—low incidence of adverse events<sup>6</sup>
- **Convenient dosing**—1 to 3 times daily<sup>6</sup>
- **Tier 1 pharmacy benefit status**—on most insurance plans<sup>7</sup>

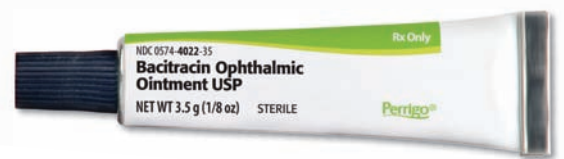Bacitracin Ophthalmic Ointment is indicated for the treatment of superficial ocular infections involving the conjunctiva and/or cornea caused by Bacitracin susceptible organisms.

#### Important Safety Information

The low incidence of allergenicity exhibited by Bacitracin means that adverse events are practically non-existent. If such reactions do occur, therapy should be discontinued.

Bacitracin Ophthalmic Ointment should not be used in deep-seated ocular infections or in those that are likely to become systemic.

This product should not be used in patients with a history of hypersensitivity to Bacitracin.



[www.perrigobacitracin.com](http://www.perrigobacitracin.com)

Please see adjacent page for full prescribing information.

**References:** 1. Kempe CH. The use of antibacterial agents: summary of round table discussion. *Pediatrics*. 1955;15(2):221-230. 2. Kowalski RP. Is antibiotic resistance a problem in the treatment of ophthalmic infections? *Expert Rev Ophthalmol*. 2013;8(2):119-126. 3. Recchia FM, Busbee BG, Pearlman RB, Carvalho-Recchia CA, Ho AC. Changing trends in the microbiologic aspects of postcataract endophthalmitis. *Arch Ophthalmol*. 2005;123(3):341-346. 4. Freidlin J, Acharya N, Lietman TM, Cevallos V, Whitcher JP, Margolis TP. Spectrum of eye disease caused by methicillin-resistant *Staphylococcus aureus*. *Am J Ophthalmol*. 2007;144(2):313-315. 5. Hecht G. Ophthalmic preparations. In: Gennaro AR, ed. *Remington: the Science and Practice of Pharmacy*. 20th ed. Baltimore, MD: Lippincott Williams & Wilkins; 2000. 6. Bacitracin Ophthalmic Ointment [package insert]. Minneapolis, MN: Perrigo Company; August 2013. 7. Data on file. Perrigo Company.

Logo is a trademark of Perrigo.

©2014 Perrigo Company Printed in USA 4022-05-01-JA 01/14

**Perrigo**® Specialty  
Pharmaceuticals

## Bacitracin Ophthalmic Ointment USP

STERILE Rx Only

**DESCRIPTION:** Each gram of ointment contains 500 units of Bacitracin in a low melting special base containing White Petrolatum and Mineral Oil.

**CLINICAL PHARMACOLOGY:** The antibiotic, Bacitracin, exerts a profound action against many gram-positive pathogens, including the common Streptococci and Staphylococci. It is also destructive for certain gram-negative organisms. It is ineffective against fungi.

**INDICATIONS AND USAGE:** For the treatment of superficial ocular infections involving the conjunctiva and/or cornea caused by Bacitracin susceptible organisms.

**CONTRAINDICATIONS:** This product should not be used in patients with a history of hypersensitivity to Bacitracin.

**PRECAUTIONS:** Bacitracin ophthalmic ointment should not be used in deep-seated ocular infections or in those that are likely to become systemic. The prolonged use of antibiotic containing preparations may result in overgrowth of nonsusceptible organisms particularly fungi. If new infections develop during treatment appropriate antibiotic or chemotherapy should be instituted.

**ADVERSE REACTIONS:** Bacitracin has such a low incidence of allergenicity that for all practical purposes side reactions are practically non-existent. However, if such reaction should occur, therapy should be discontinued.

To report SUSPECTED ADVERSE REACTIONS, contact Perrigo at 1-866-634-9120 or FDA at 1-800-FDA-1088 or [www.fda.gov/medwatch](http://www.fda.gov/medwatch).

**DOSAGE AND ADMINISTRATION:** The ointment should be applied directly into the conjunctival sac 1 to 3 times daily. In blepharitis all scales and crusts should be carefully removed and the ointment then spread uniformly over the lid margins. Patients should be instructed to take appropriate measures to avoid gross contamination of the ointment when applying the ointment directly to the infected eye.

### HOW SUPPLIED:

NDC 0574-4022-13 3 - 1 g sterile tamper evident tubes with ophthalmic tip.

NDC 0574-4022-35 3.5 g (1/8 oz.) sterile tamper evident tubes with ophthalmic tip.

Store at 20°-25°C (68°-77°F)  
[see USP Controlled Room Temperature].

Manufactured For  
**Perrigo®**

Minneapolis, MN 55427  
OS400 RC J1 Rev 08-13 A

# 19<sup>TH</sup> ANNUAL OPHTHALMIC PRODUCT GUIDE

Innovative products to enhance your practice



The future  
is in your  
hands. One  
tap, many  
possibilities.

Experience the digital edition on your handheld device. Use your smart device to scan the code below or visit:

[www.revophth.com/supplements/](http://www.revophth.com/supplements/)

Download a QR scanner app. Launch app and hold your mobile device over the code to view <http://www.revophth.com/supplements/>.



**REVIEW®**  
of Ophthalmology



**Editor in Chief**

**Christopher Glenn**  
(610) 492-1008  
cglenn@jobson.com

**Managing Editor**

**Walter C. Bethke**  
(610) 492-1024  
wbethke@jobson.com

**Senior Editor**

**Christopher Kent**  
(814) 861-5559  
ckent@jobson.com

**Associate Editor**

**Kelly Hills**  
(610) 492-1025  
khills@jobson.com

**Chief Medical Editor**

**Mark H. Blecher, MD**

**Senior Director, Art/Production**

**Joe Morris**  
(610) 492-1027  
jmorris@jobson.com

**Art Director**

**Jared Araujo**  
(610) 492-1023  
jaraujo@jobson.com

**Graphic Designer**

**Matt Egger**  
(610) 492-1029  
megger@jobson.com

**International coordinator, Japan**

**Mitz Kaminuma**  
Reviewophthalgo@aol.com

**Business Offices**

11 Campus Boulevard, Suite 100  
Newtown Square, PA 19073  
(610) 492-1000  
Fax: (610) 492-1039

**Subscription inquiries:**

United States — (877) 529-1746  
Outside U.S. — (847) 763-9630

**E-mail:**

rhsubs@halldata.com

**Website:** www.revophth.com

Professional Publications Group  
Jobson Medical Information LLC



# Making Innovations Earn Their Stripes

**Every once in a while**, one of our authors or section editors writes something that resonates beyond the topic they're addressing and seems to apply equally well to other issues. This time, the distinction goes to Dr. Abelson and his Therapeutic Topics column, in which he invokes Yogi Berra, always a sound policy. In assessing new technologies that aim to diagnose and/or follow the progress of corneal disease, Dr. Abelson says, you have to ask (paraphrasing here), are they really any better than what we have now? To be sure, these new technologies have a place; but is it along side of or in place of current practice?

The squeeze is on in medicine; no one would deny that. Though costs have leveled somewhat in recent years, we still spend an unsustainable 20 percent of our budget, \$2.79 trillion in 2012, or about \$8,915 per person on health care. Combine the cost and efficiency pressure with the influx of new technologies and the swelling ranks of an aging patient population and it's likely 10 years from now, we may not even recognize what the health-care system will have evolved into.

On the plus side, says the optimist, a more efficient new system will push activities such as data-collection and monitoring treatment to lower-level members of the new health-care team, freeing physicians and specialists to practice at the highest level of their training.

Nearly half of the 30 fastest-growing occupations from 2012 to 2022

will be health care-related, according to Bureau of Labor Statistics estimates. Among them: home health aides, physician assistants, occupational therapy assistants and dental hygienists.

And it's not just new levels of personnel that will settle into the space formerly reserved for the doctor and the patient; as much as anything, technology will be occupying that space. Patients can sit down today at a shopping mall and have their blood pressure, vision and BMI checked by kiosks. Again, the optimist says, a better-educated and more involved patient can only improve the quality of medical care. From telehealth to robotic surgery to contact lens-based detection of disease, or innovations we haven't even imagined, what another decade of innovation will bring couldn't be more exciting.

As long as we stop along the way and remember to ask of each of these new systems, innovations and improvements: Is it really better than what we have now?



# The Integrated Cataract Surgical Suite

By linking diagnostic instruments with surgical ones, companies hope to improve surgical safety and efficacy.

*Walter Bethke, Managing Editor*

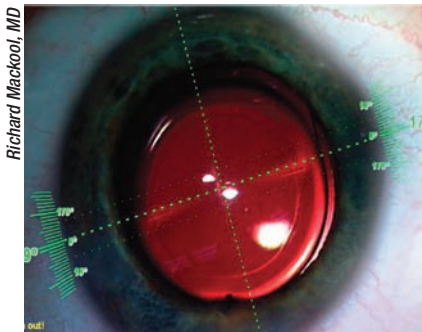
**T**he drive to integrate and connect a practice's equipment is extending into the cataract suite, as well, with the recent release of integrated systems from both Alcon and Carl Zeiss Meditec. Users say the benefits can run from simply having all the patient data transferred to the operating microscope to having the microscope display digital overlays to aid in the positioning of toric lenses. Here's a look at the two new systems and the features they bring to the practice.

## Alcon's Applied Integration

Alcon's Cataract Refractive Suite connects an imaging/measurement device called the Verion with the Centurion phaco machine, the LenSx femtosecond cataract laser and the Luxor operating microscope.

"The goal is to have all of the surgeon's in-office data acquisition easily transferable to the OR suite," says Richard J. Mackool Jr., MD, of Astoria, N.Y., who uses the system. "In the past, we would do the testing, obtaining the IOL power and astigmatism results on paper, and then make decisions about our lens choice in the

OR based on those measurements. With the Verion, the data is stored digitally on a USB memory stick that is taken to the OR and inserted into the system. The microscope retrieves the data, giving you a digital overlay that's visible in the microscope oculars and indicates the correct axis at which to implant the toric IOL. Before this, we'd mark the eye with a pen with the patient sitting up to indicate the principal meridians, then use a toric axis marker to locate the desired meridian. With the Verion, these steps are eliminated. Instead, you have a digital, real-time overlay as a direct indicator of the preop data."



The Alcon Verion can provide an axis guide in the microscope to aid in the placement of a toric intraocular lens.

The Verion system captures the globe image and maps out landmarks such as iris features and blood vessels, explains Dr. Mackool. "That's how it orients the eye in space," he says. "When you're in the OR, you capture another image and the system overlays the original reference image and the new image, so that the patient's eye under the operating microscope is oriented in space in the exact position the machine expects." Additionally, the Verion gives the surgeon the option of aligning any IOL, toric or multifocal, on the pupillary axis, the visual axis or the geometric center of the cornea. A capsulorhexis guide, which can also be centered where the surgeon chooses, is also available as an overlay, to help guide the surgeon as he creates it.

For lens selection, the Verion has such formulas as the Holladay, Holladay II, SRK/T and the Hoffer Q. "More important, after you've done a number of cases and entered the results into the system, the Verion will optimize your case results in the future by retrospectively analyzing the data so you can tailor the program you choose to the cases you perform. For instance, everyone has a differ-

ent surgical technique: Some utilize a larger capsulorhexis than others, and the effective lens position of the IOL may be different in their patients than it would be for surgeons who make a smaller capsulorhexis.”

If a surgeon uses a LenSx femtosecond laser, Dr. Mackool says the Verion data is transferrable to it as well. “The same information provided to the OR for toric lenses can be imported into the LenSx for creating arcuate incisions,” he says. “Some

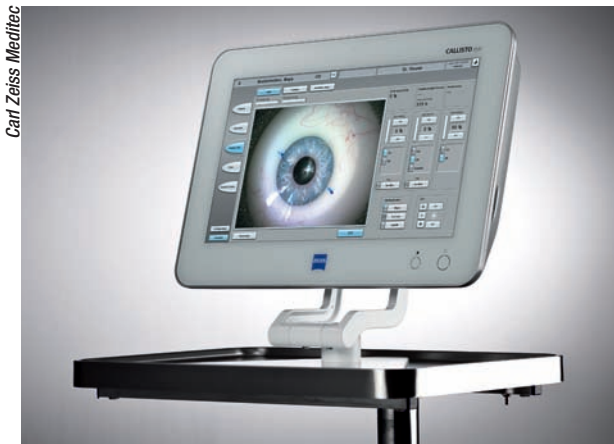surgeons prefer arcuate incisions, or combine them with a toric lens. Either way, the axis goes directly to the LenSx.”

The other part of the equation, the Luxor operating microscope, also has features to aid the surgery. “Regardless of whether the patient is looking at the microscope or looking away, the red reflex is extremely well-maintained,” says Richard Mackool Sr., MD, who also uses the system. “As such, areas of the red reflex never become dark, even in pretty extreme directions of gaze on the patient’s part. This comes in handy if you want to rotate the globe a bit in a certain direction to gain access to one area or another, which happens all the time during surgery. In fact, the reflex is so good that we rarely need to use more than 50 to 60 percent of maximum illumination.”

For information on the Verion and the integrated system, visit <https://www.myalcon.com/products/surgical/verion-guided-system/>.

## The Zeiss Cataract Suite

The brains of the integrated cataract suite from Carl Zeiss Meditec is the new Callisto computer-assisted surgery system, which acts as a hub for the company’s IOLMaster device and



If a surgeon upgrades to Callisto Eye Assistance, the Zeiss Callisto will provide intraoperative guidelines on the screen.

the OPMI Lumera microscope.

Richard Davidson, MD, associate professor of ophthalmology and medical director for the faculty practice at the University of Colorado Hospital Eye Center, used the Callisto system in its prototype stage for capsulotomy creation and the placement of toric lenses, and says he sees the potential of such integrated systems. He has also worked with the Alcon system. “This is the direction cataract surgery is heading—the integrated system,” he says. “The main benefits to the surgeon are convenience and patient safety. If you take the measurements for the IOL in your office and then transfer them to the machine, either the femtosecond laser or straight to the operating room microscope, you don’t have to worry about paper charts getting lost, choosing the wrong lens, or the lens not matching up correctly with the patient.”

The Callisto system comes in two varieties: Basic and Assistance. With Callisto Eye Basic, the aim is to simplify patient management in the operating room by importing patient lists via USB and viewing the microscope settings directly in the oculars of the device. The system will also remember the surgeon’s preferences for the microscope, allowing the surgeon to recall them later. Before the surgery,

when the patient is selected from the list, Callisto Basic will also begin recording high-definition video of the case.

If the surgeon upgrades to Callisto Eye Assistance, the Callisto display will show several forms of digital overlays to guide the physician during different phases of the procedure. If the Integrated Data Injection System is also installed, these overlays will appear right in the microscope. There are currently guides for corneal incisions, including limbal relaxing inci-

sions; capsulorhexis creation; Z Align for help in aligning toric IOLs; and K Track, which helps visualize corneal curvature in combination with a keratometer. “For now, you have to mark the eye preoperatively and the system tracks your marks,” says Dr. Davidson. “But the ultimate goal is to track based on a preop eye image. When the guides are on, the limbus is marked so you can always see it, and you also have marks for the main axis and the axis 90 degrees away from it. You get a pretty precise idea of where the lens needs to go.”

The other eventual goal of the system is to be able to transfer the information wirelessly between devices, or at least over a network. “When I used the system, the data was transferred with a flash drive,” says Dr. Davidson. “Our hospital system here is complex, so getting access to the network can be difficult, so we just used a flash drive. Eventually it will be networked and, hopefully, wireless as well. The plan is, if you have a surgery center in your office, to be able to do your IOLMaster and then walk into the OR and turn on the Callisto machine and see all of your data right in front of you.”

For information on Zeiss’ integrated cataract system, visit [http://meditec.zeiss.com/meditec/en\\_us/products.html](http://meditec.zeiss.com/meditec/en_us/products.html). **REVIEW**



# A New Year Brings New Code Changes

An overview of the new ophthalmic CPT code changes, as well as changes to facility reimbursements and doctor bonuses.

**Q** Were there changes made to the values of some ophthalmic CPT codes in 2014?

**A** The *Medicare Physician Fee Schedule*, published in November 2013, contains several relative value unit (RVU) changes. For information on the percentage of change from 2013, please see Table 1, below.

**Q** Are there any changes to ICD-9 diagnosis codes that require attention?

**A** No new ICD-9 codes were published, in anticipation of ICD-10 implementation on October 1, 2014. The Centers for Medicare & Medicaid Services expects to move forward with ICD-10 despite requests for another postponement by the American Medical Association and various specialty societies.

**Q** Are there new drug codes pertinent to ophthalmology in the 2014 Healthcare Common Procedural Coding manual?

**A** Yes, the 2014 HCPCS manual contains a new code for what is more commonly known as Jetrea (J7316, Ocriplasmin 0.125 mg).

The J7316 code will require four units on

the claim form for appropriate reimbursement of the drug vial.

**Q** Are there any Category III code changes for 2014?

**A** There are a number of changes in the hard copy of the 2014 *Current Procedural Technology Manual*. However, these Category III codes, released semiannually by the American Medical Association, were implemented on July 1, 2013:

- 0329T *Monitoring of intraocular pressure for 24 hours or longer, unilateral or bilateral, with interpretation and report;*
  - 0330T *Tear film imaging, unilateral or bilateral, with interpretation and report;*
  - 0333T *Visual evoked potential, screening of visual acuity, automated.*
- The following Category III codes are deleted in the 2014 handbook:
- 0192T *Insertion of anterior segment aqueous drainage device, without extraocular reservoir, external approach (replaced with new Category I code);*
  - 0124T *Conjunctival incision with posterior extrascleral placement of pharmacological agent.*

Coverage and payment for Category III codes remains at carrier discretion.

**Table 1. Relative Value Unit Changes**

CPT Code	Percent Change
Repair entropion, suture (67921)	15
BCL fitting (92071)	8
Fitting of CL, keratoconus (92072)	4
Repair ectropion, tarsal wedge (67916)	3
E/M new patient level 4 (99204)	-5
Intermediate Eye exam (92012)	-5
Visual field (92083)	-7
Fundus photos (92250)	-8
Placement of amniotic tissue (65778)	-10

LACRIVERA



A FRESH PERSPECTIVE™

## Q What changes were published with Category I codes in CPT 2014?

**A** Several changes exist in the *CPT* 2014 manual. There is a new code to replace Category III code 0192T, which is deleted from the 2014 *CPT* handbook:

- 66183 *Insertion of anterior segment aqueous drainage device, without extraocular reservoir, external approach.*

With this change, the 2014 *Medicare Physician Fee Schedule* will establish RVUs and a payment rate for the surgeon; previously, the reimbursement was determined by the Medicare Administrative Contractor.

Revisions were made to the two codes for amniotic membrane placement, and an additional adjustment to the language of a third:

- 65778 *Placement of amniotic membrane on the ocular surface, without sutures;*
- 65779 *Placement of amniotic membrane on the ocular surface, single layer sutured.*

The revised text below 65780, *Ocular surface reconstruction; amniotic membrane transplantation, multiple layers* states:

“For placement of amniotic membrane without reconstruction using no sutures or single layer suture technique, see 65778, 65779.”

Code 13150, *Repair, complex, eyelids, nose, ears and/or lips; 1.0 cm or less* has been deleted, and the following codes revised to reflect this change:

- 13151 *Repair, complex, eyelids, nose, ears and/or lips; 1.1 cm to 2.5 cm;*
- 13152 *2.6 cm to 7.5 cm;*
- +13153 *each additional 5 cm or less (list separately in addition to code for primary procedure).*

In the integument section, add-on code +15777, *Implantation of biologic implant (e.g., acellular dermal matrix) for soft tissue reinforcement (i.e., breast, trunk)*, has supplemental

Lacrivera. You'll want to keep an eye on us.

innovative products in the coming months.

To prove it, we'll be introducing several

shouldn't be complicated, painful or expensive.

We hear you. Treating chronic dry eye

We're  
about to  
shake  
up the  
dry eye  
industry.



parenthetical instructions that might apply in oculoplastic surgery with xenografts. The new text reads:

“For implantation of biologic implants for soft tissue reinforcement in tissues other than breast and trunk, use 17999.”

**Q What types of regulatory issues were identified in the Office of Inspector General’s annual work plan as areas of concern for ophthalmology in 2014?**

**A** Unfortunately, we don’t know at this time. The annual publication of the OIG work plan, usually occurring in the fall, was delayed until January 2014. According to the OIG website, “This change from the usual October release will better align with priorities OIG has set for the coming year, a time of continuing fiscal challenges.”

**Q Is the Recovery Audit Contractor program continuing to report successful recoupment of overpaid dollars?**

**A** Yes. The RAC program continues to thrive. Several states have Medicaid RAC programs in place. Medicaid RACs operate at the direction of the states with the discretion to determine what areas of their Medicaid programs to target.

Total corrections since the Medicare Fee-for-Service Recovery Audit Program began in October 2009 stand at \$5.7 billion. Between FY 2011 and 2012, corrected payments doubled from \$939 million to \$2.4 billion. As of June 2013, corrected payments for FY 2013 were already at \$2.3 billion.

In June 2013, all four RACs added blepharoplasty for review of physician services, hospital services and ASC services. The review is listed as

a “complex” review, which means that medical records are requested prior to any overpayment demand letter.

**Q Do any Medicare Part B changes affect beneficiaries in 2014 from a cost perspective?**

**A** The Medicare Part B premiums remain \$104.90 for most beneficiaries. The Part B deductible also remains unchanged at \$147. These beneficiary costs are the same as in 2013.

**Q Are there any bonuses for participating in the Physician Quality Reporting System or the Electronic Prescribing Incentive Program in 2014?**

**A** While 2014 is the final year to secure a bonus for successful participation in the PQRS, the final year for the eRx bonus program was 2013. It is expected that all providers except those that are exempt are using electronic prescribing systems. If not, penalties exist. For the PQRS, the bonus remains at 0.5 percent of total Medicare allowed dollars for professional services to those who successfully participate in the program. This (2014) is the final year to secure a bonus for successful participation.

**Q Will the Electronic Health Record Incentive Program continue to pay bonuses to eligible providers?**

**A** Yes. As of September 2013, the EHR Incentive Bonus Program had paid out \$3.9 billion to eligible providers: \$115 million paid to ophthalmologists and \$157 million to optometrists. Providers who have successfully attested to Stage 1 for two years, some three years, will be required to meet Stage 2 requirements for 2014. For those not yet utilizing

electronic health records, they must start by July 1, 2014 and complete their meaningful use attestation for Stage 1 by October 1, 2014 to avoid penalties in 2015. The published penalty is 1 percent for 2015, 2 percent for 2016 and 3 percent for 2017. Beyond 2017, penalties are up to 5 percent.

**Q Will the Multiple Procedure Payment Reduction continue in 2014?**

**A** Yes. The MPPR policy reduces the technical component of the second and subsequent diagnostic tests by 20 percent when more than one diagnostic test is performed at one patient encounter on the same day by the same physician or group. The list of tests includes ultrasounds, imaging and visual fields. Tests that do not have a technical component (i.e., gonioscopy) are not subject to this policy. There are no changes to the list of affected ophthalmic codes from 2013 to 2014.

**Q What’s happening with Ambulatory Surgery Centers’ facility fees in 2014?**

**A** ASC facilities realize an increase in reimbursement. For 2014, the Consumer Price Index and Multifactor Productivity Adjustment update the ASC facility rate conversion factor by 1.2 percent. This increase results in a very small but positive change to facility reimbursement.

**Q Did hospital outpatient department rates increase similarly to ASC facility rates?**

**A** Yes. Hospital outpatient department rates increased approximately 1.7 percent for 2014. **REVIEW**

*Ms. McCune is vice president of the Corcoran Consulting Group. Contact her at [DMcCune@corcoranccg.com](mailto:DMcCune@corcoranccg.com).*

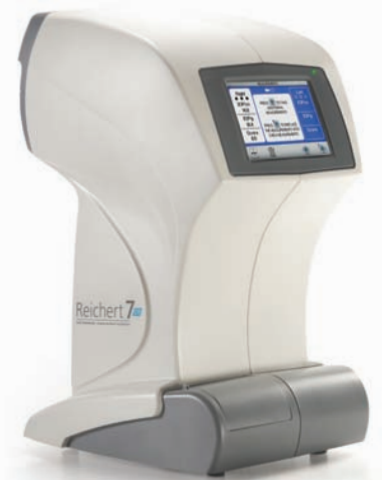**"IOP<sub>cc</sub> MAY REPRESENT  
A SUPERIOR TEST FOR  
THE EVALUATION OF  
GLAUCOMA."**

**GOLDMANN APPLANATION TONOMETRY COMPARED WITH  
CORNEAL-COMPENSATED INTRAOCULAR PRESSURE IN  
THE EVALUATION OF PRIMARY OPEN-ANGLE GLAUCOMA.  
EHRlich ET AL. BMC OPHTHALMOLOGY 2012, 12:52**

# Peer Pressure.

Reichert® 7CR is the tonometer that has everyone talking. Dozens of peer-reviewed articles demonstrate that Corneal-Compensated IOP (IOP<sub>cc</sub>) may be clinically superior to other methods of tonometry in the evaluation of glaucoma. Made possible by Reichert's patented Corneal Response Technology®

Does your tonometer have **CR**® inside? [www.reichert.com/7CR](http://www.reichert.com/7CR)



**Reichert**  
TECHNOLOGIES  
*Advancing Eye Care. Preserving Sight.™*

   [www.reichert.com](http://www.reichert.com)

Made in the USA. © 2014 AMETEK, Inc & Reichert, Inc. (10-2013) All rights reserved.

**AMETEK**  
ULTRA PRECISION TECHNOLOGIES

# Inlays and Presbyopia: The Next Frontier

*Christopher Kent, Senior Editor*

A look at three leading approaches using inlays to expand presbyopic patients' range of vision.

Periodically, the search for a “cure” for presbyopia produces a new set of treatment options. The latest approach is the corneal inlay, intended to improve near vision without compromising distance vision in emmetropic presbyopes—and possibly non-emmetropes as well.

Three variations on the concept of placing an implant inside the cornea are in different stages of the approval process. The Kamra inlay (from AcuFocus in Irvine, Calif.) uses the pinhole principle to increase depth of field; the Raindrop (from ReVision Optics in Laguna Hills, Calif.) makes the cornea multifocal by reshaping it; and the Flexivue Microlens (from Presbia in Amsterdam) creates multifocal vision using an in-cornea lens.

Here, four surgeons with extensive experience with these options discuss what they've learned about them and how they may benefit your patients.

## The AcuFocus Kamra

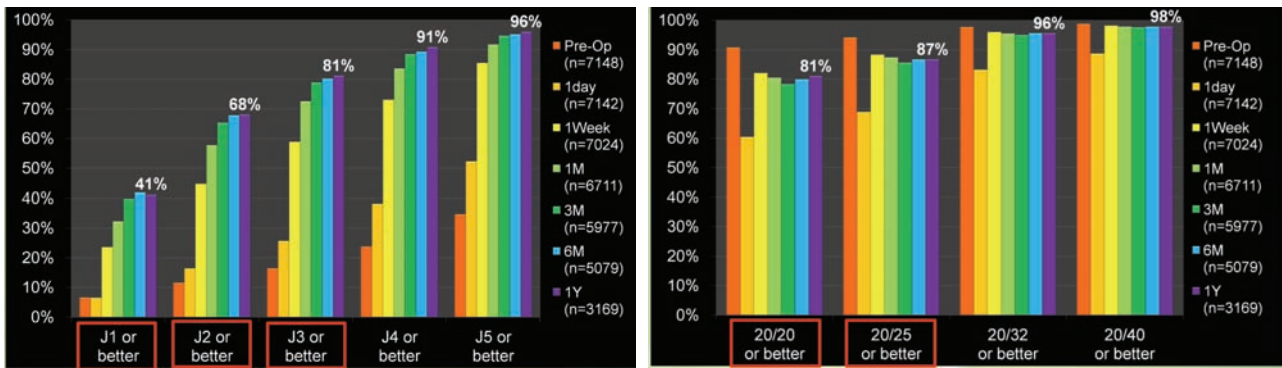
The corneal inlay closest to Food and Drug Administration approval is AcuFocus's Kamra. “The Kamra inlay is commercially available in 49 countries, and nearly 20,000 inlays have been implanted worldwide to date,” says Minoru Tomita, MD, PhD, executive medical director of the Shina-

gawa LASIK Center in Tokyo, Japan, where approximately 15,000 of those cases were performed. “The inlay is 5  $\mu\text{m}$  thick; it has a 3.8-mm outer diameter and 1.6-mm central aperture. It's made of polyvinylidene fluoride and nanoparticles of carbon, with 8,400 micro-perforations that vary in size from 5 to 11  $\mu\text{m}$ . The principle of the inlay's function is similar to that of the small-aperture effect in an f-stop camera; it has minimal effect on distance image quality but improves intermediate and near image quality.”

Dr. Tomita says that because so many Kamra inlays have been implanted around the world, it has more clinical data demonstrating effectiveness and safety than the other inlays. He notes that studies have shown that the Kamra inlay can achieve and maintain a mean uncorrected distance visual acuity of 20/20<sup>1-4</sup> and improves intermediate visual acuity.<sup>3-7</sup>

Like the other inlays, the Kamra is implanted in the nondominant eye only. “The manifest refractive spherical equivalent of the implanted eye should be between -1 and 0 D right before the surgery in order to maximize the function of the Kamra inlay,” explains Dr. Tomita. “If both eyes are ametropic and presbyopic, normal LASIK is performed first to target emmetropia by making a 100- $\mu\text{m}$  flap





Physicians at the Shinagawa LASIK center in Tokyo have implanted thousands of Kamra inlays. The chart above show the refractive results in the inlaid eye for a number of those patients. Left: uncorrected near visual acuity. Right: uncorrected distance visual acuity.

(sub-Bowman’s keratomileusis). A month later, a corneal pocket is created in the nondominant eye at a depth of 200 µm using a femtosecond laser; the inlay is inserted into the pocket.”

In terms of contraindications, Dr. Tomita says patients are excluded if they’ve had previous ocular surgeries or if they have any ocular pathology, including keratectasia, corneal degeneration, severe blepharitis, retinal disease, glaucoma, cataract, marked topographic irregularities or severe dry eyes. “If a patient with severe dry eye wants to have the inlay, we recommend that the condition be treated aggressively before the surgery,” he says.

“It’s also important to provide sufficient informed consent to the patient,” he adds. “Preoperatively, risks and precautions should be carefully explained, especially to those who are professional drivers or drive at night. Neuroadaptation is required to adjust to binocular vision with the inlay, and

this takes longer as one ages. Some patients claimed they were hesitant to drive a car for up to six months after the surgery, although these conditions eventually alleviate over time.”<sup>8,9</sup>

Dr. Tomita notes that being able to remove the inlay if the patient is unhappy is a big advantage. “Previous papers have reported that patients’ refractive state returned to within ±1 D of the preoperative refractive state after inlay removal, with no loss of corrected distance visual acuity,”<sup>10</sup> he says. “There were also reports of good recovery of corneal topography and corneal aberrometry.”<sup>11</sup> Once the inlay has been removed, the patient can be offered other treatment options.

“The Kamra inlay is at the final stages of FDA approval,” he adds. “We hope it will be approved by the end of 2014.”

### The Presbia Flexivue Microlens

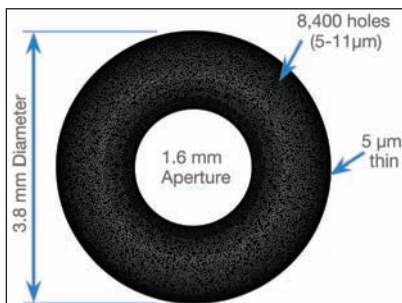
The Flexivue is a small, hydrophilic acrylic refractive inlay, 3.2 mm wide, with a 1.6-mm hole in the center. The refractive power of the ring ranges from +1.5 D to +3.5 D. Presbia announced in November that the FDA had given conditional approval to begin a Phase II trial of the inlay.

Robert K. Maloney, MD, is a clinical professor of ophthalmology at UCLA-David Geffen School of Medicine and director of the Maloney Vision Institute in Los Angeles. He is the

co-medical monitor for the FDA trial of the Presbia Flexivue inlay; he has also been an investigator for the Acu-Focus Kamra inlay. “The Flexivue is a crystal clear refractive inlay,” he says. “It has an index of refraction different from the cornea. There’s a small hole in the center of the inlay that provides distance vision and allows corneal nutrients to circulate freely from posterior to anterior. The inlay is designed to sit in the central cornea and create a multifocal effect so the patient gets good close and distance vision.”

Data from outside the United States has supported the effectiveness of the Flexivue. For example, in a study conducted by Ioannis Pallikaris, MD, PhD, and colleagues, presented at the 2013 European Society of Cataract and Refractive Surgery Annual Congress in Amsterdam, 77 presbyopic patients in Italy and Greece ranging in age from 45 to 60 received the implant. Average monocular UNVC improved from 20/100 preoperatively to 20/25 at one year postop, while binocular UDVA was unchanged. “The European data suggests that the inlay is very safe, and patients have been very happy,” notes Dr. Maloney.

“The inlay is typically implanted in the nondominant eye of a patient who is emmetropic in both eyes,” he continues. “It creates a slight myopic shift and a mild multifocal effect in the implanted eye, thus creating a small amount of monovision. It’s not an



The Kamra inlay uses thousands of tiny pinholes to increase depth of field.

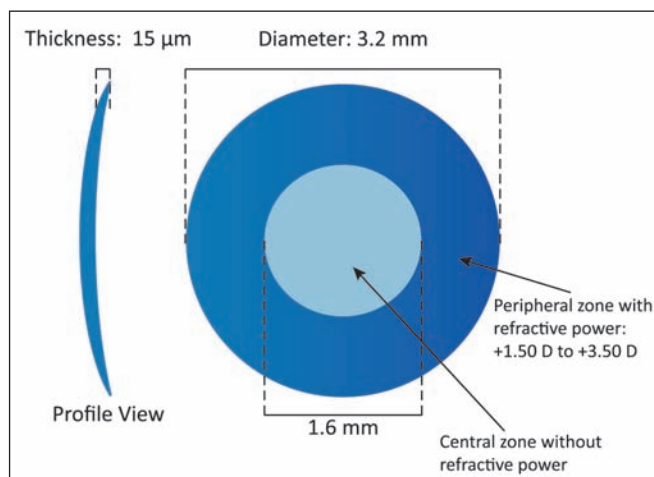
extreme multifocal, which could cause significant glare at night, and it's not a full monovision, which could cause binocular disparity. So it seems to fit in a sweet spot, with a mixture of a little monovision and multifocality. That makes it very well-tolerated."

Gustavo E. Tamayo, MD, director of the Bogota Laser Refractive Institute in Bogota, Colombia says he has implanted the Flexivue inlay in 75 patients. "I use it only in pure emmetropes, defined as those with  $\pm 1$  D of sphere and  $\pm 0.75$  D of cylinder," he says. "It's mostly being implanted in Europe, where it has the CE Mark, and South America, but it's still not widely used; maybe 1,000 have been implanted in total."

Dr. Maloney notes several differences between the Kamra and Flexivue inlays. "The Kamra inlay improves reading vision by using pinholes to increase the eye's depth of focus," he says. "The Flexivue is a refractive inlay; it improves depth of focus by altering the path of light rays to the cornea. It doesn't block out the peripheral light rays as the Kamra inlay does."

"Regarding the reduction of incoming light caused by the Kamra, one of the interesting things for me has been that patients are not complaining that their vision is dark at night," he adds. "There may be a couple of reasons for that. First, we only implant in one eye, so the other eye is normal. Second, the Kamra inlay is about 3.8 mm in diameter, so when the pupil dilates at night light enters the eye around the outer edge of the inlay. It may be that those two factors together keep people from experiencing dim vision at night."

Dr. Tamayo says the main advantage the Flexivue has compared to the other inlays is its more physiologic approach to correcting near vision. "Un-



Presbia's Flexivue Microlens creates multifocality with a ring that has refractive power surrounding a plano central region.

like the pinhole mechanism of action used by the Kamra inlay, it provides an optical correction depending on the refractive defect present," he says. "The other advantage is the fact that it does not have any issues regarding the distribution of nutrients, which can be a factor with the Raindrop and Kamra inlays. Also, the learning curve is very small; performing the surgery is simple, fast and easy. Certainly one or two days of training would be sufficient."

### Flexivue in Practice

Dr. Maloney says the Flexivue could in theory be combined with LASIK. "You'd make a flap, correct the refractive error, place the inlay and then replace the LASIK flap," he says. "Or it could be used with a SMILE-type procedure, in which you'd remove a lenticule through a stromal tunnel to correct the refractive error and then insert this inlay through the same stromal tunnel. But I don't know if that's been tried yet. Right now we're implanting it in people who are close to emmetropia. We're not doing simultaneous correction of refractive errors."

"In the trials, we're using a pocket, not a flap," he continues. "In a normal emmetrope we make a pocket with a femtosecond laser, a channel from

the central cornea to the peripheral cornea with an opening in the periphery. The surgeon grasps the inlay with a special forceps and gently slides it into the pocket, centers it over the corneal light reflex and releases it, the same way the Kamra inlay is inserted."

As far as contraindications, Dr. Tamayo says those would include the patient being unable to correct to 20/20 at near, whatever the reason. "Dry eye is not affected by the inlay, so it's not an issue," he adds.

Dr. Maloney notes that a full list of contraindications has not been developed so far. "We don't have a lot of data yet," he explains. "But obviously we don't implant the Flexivue in patients with keratoconus or significant corneal dystrophies. Also, significant astigmatism is a contraindication because the inlay doesn't correct astigmatism. We don't believe the procedure will worsen dry eye because we're not making a LASIK flap or ablating tissue."

Nevertheless, Dr. Tamayo believes that patient selection is critical. "In my opinion, a monovision test conducted with a +1.5 D contact lens in the nondominant eye is crucial because it gives the patient the opportunity to experience the controlled monovision the inlay produces," he says. He adds that the main limitation of the Flexivue may be that monovision effect. "Even though it's very small, many patients are sensitive to this approach. The rate of rejection after the monovision trial is almost 70 percent."

Along those lines, some surgeons have patients try bifocal contact lenses before agreeing to implant an inlay, but Dr. Maloney is skeptical about the validity of this approach. "Bifocal contact lenses work in a different way than these inlays," he notes. "The fact that a patient likes the effect of bifocal

contact lenses is no guarantee that he's going to like the inlay. For example, the Kamra reduces the amount of light coming in because it's pinhole-based, and it causes some glare because of the 10,000 tiny nutrient holes. A multifocal contact lens doesn't reduce the incoming light, and any glare it causes would probably be quite different from that caused by the pinholes."


In any case, Dr. Maloney says the procedure isn't difficult. "It's not like mastering cataract surgery, but you do have to be trained in it," he notes. "For a LASIK surgeon, this will be relatively easy to learn."

Dr. Tamayo notes that the FDA-approved Phase II clinical studies are just starting.

## ReVision Optics' Raindrop

John A. Hovanesian, MD, clinical assistant professor at UCLA Jules Stein Eye Institute in Los Angeles and in private practice at Harvard Eye Associates in Laguna Hills, Calif., has implanted about 40 of the Raindrop inlays as part of the current United States trial. "I've had enough experience to get a pretty good sense of how patients react to it," he says. "Generally, the reaction is something like the reaction of patients after LASIK—which makes sense because it's a very similar procedure.

"The Raindrop inlay is 2 mm in diameter and 32  $\mu$ m thick in the center," Dr. Hovanesian explains. "It's made of hydrogel, which allows nutrients and oxygen to pass through. It's currently placed in a flap interface in the cornea, although soon we'll be placing it in a corneal pocket instead. It works by causing central steepening in the cornea, producing a variable power as you move from the center toward the periphery. The result is similar to the effect of a multifocal lens. The implant has no power itself; it's a uniform disc of hydrogel. But the topographic changes in the corneal surface caused



The Raindrop inlay has no refractive power; it reshapes the cornea to create multifocality.

by the implant produce a refractive change similar to what you'd achieve by adding a lens."

Recent data indicates that the Raindrop is effective in a variety of situations, including bilateral implantation:

- **Long-term stability.** A study by Imola Ratkay, MD, PhD, that will be presented at the 2014 American Society of Cataract and Refractive Surgery meeting, reports two-year visual outcomes with the Raindrop implant in 15 presbyopic patients. Binocular uncorrected near visual acuity improved from 0.22 preop to 0.9 at two years, a gain of six lines; and binocular uncorrected distance visual acuity improved from 0.77 preop to 1.3 at two years. Acuity was stable, tending toward improvement, and at two years there were no complications.

- **Bilateral implantation.** A presentation at the 2013 ESCRS meeting reported data from a study in which 23 hyperopic subjects were implanted with the Raindrop bilaterally—first in the nondominant eye, then three to six months later in the dominant eye. Mean near vision improved from 0.54 logMAR to -0.04 logMAR and remained stable; intermediate and distance vision also improved and remained stable. Compared to a single inlay, bilateral implantation added approximately one line of improved near vision. More than 80 percent of the bilateral subjects were 20/20 or better at all distances at all follow-up visits. Task

performance improved dramatically at all distances in both bright and dim light. After nine months, all subjects were satisfied with their vision.

- **Integrating into a LASIK practice.** At this year's ASCRS meeting Yasuda Kazuomi, MD, will report early results from 107 patients implanted with the Raindrop inlay in the non-dominant eye during standard LASIK in Japan. He indicates that he had no trouble integrating the procedure, and patients have achieved good binocular vision, stable refraction and had low rates of complication.

- **Cataract surgery after an inlay.** Another ESCRS 2013 study reported a case history in which cataract surgery using a femtosecond laser was performed three years after the patient received a Raindrop implant. The surgery was successfully performed with no adjustments to accommodate the implant and no difficulty with measurements or visualization. The patient is happy with the outcome and continues to have a full range of vision.

- **Implanting in pseudophakes.** Another ESCRS 2013 presentation reported that implanting the Raindrop in the nondominant eye of pseudophakes produced positive results that compared favorably with the results from the multicenter phakic U.S. trial, significantly improving near, intermediate and distance vision.

"The data from outside the U.S. is promising and matches pretty closely what we're seeing in the U.S. trial," adds Dr. Hovanesian. "We're seeing high levels of satisfaction, high levels of spectacle independence and a low level of issues with quality of vision. We've seen very few explants or complications."

## The Raindrop in Practice

"Although there's a little adaptation required, adapting to the Raindrop is a lot easier than adapting to monovision," notes Dr. Hovanesian. "Many

patients can see very well up close and adapt to it right away. Admittedly, these are patients who have been pre-tested with multifocal contact lenses to prove that they can deal well with this type of refractive change. And that's an important point: qualifying your patients in advance is a real key to success with an inlay. This is not something you should generally do without trying it first."

As far as the advantages of this particular inlay, Dr. Hovanesian points out that the Raindrop is very thin and invisible. "The Kamra inlay is very effective, but it's visible if you look at the eye from the side, particularly if the eye is light-colored, perhaps blue or green," he says. "Some patients might see this as a disadvantage compared to an implant that's invisible. Apart from that, it's difficult to make any comparison, and I don't think there's any head-to-head data. Frankly, I'm hopeful that all three of these technologies will gain approval so that we can offer all of them to our patients."

Regarding contraindications, Dr. Hovanesian says anything that might contraindicate LASIK would also be an issue here. "I wouldn't use the Raindrop in patients with extremely dry eyes or who have corneal disorders that would make creating a corneal flap or pocket a poor idea," he says. "These patients need to have good vision in both eyes and be willing to try to adapt to a new optical system."

Dr. Hovanesian believes the learning curve will be small for most surgeons. "Typically it will be LASIK surgeons doing these procedures," he says. "As with any new device, there's a little bit of learning the right way to handle it, but after a few cases with a little bit of guidance almost anybody can do this procedure."

Dr. Hovanesian adds that the Raindrop inlay is currently in an expansion of the Phase III study. "We're continuing to collect data, and the data looks good," he says.

"We're optimistic about the results."

### Closer to a Presbyopia Cure?

"All of these inlays seem to work," notes Dr. Hovanesian. "You can make theoretical arguments as to why one might be better than the others, but they all seem to achieve a high level of near vision in the range of J1, while only minimally compromising distance vision to 20/20 or 20/25."

"Overall, the data from the FDA trial of the Kamra, like the data from outside the United States regarding the Flexivue, indicates that these inlays are very safe," adds Dr. Maloney.

Of course, they have a few disadvantages. Dr. Maloney notes that all of them reduce distance vision to some degree. "That's the trade-off for improved reading vision," he says. "And all of them cause night glare to some degree; that's the trade-off for changing the way the eye focuses light. So if patients aren't happy, it's because their night vision isn't good enough, their distance vision isn't good enough, or their reading vision isn't good enough—the inlay isn't strong enough to give them the reading vision they need. Those limitations are probably common to all inlays. But the inlays can be explanted, and vision returns to being very close to what it was before surgery. In addition, we haven't seen significant adverse effects with the current generation of these inlays."

"Using an inlay requires a compromise in distance vision," agrees Dr. Hovanesian. "That's the nature of adding something to an emmetropic visual system. However, you're usually doing it in the nondominant eye in a patient who is a good adapter. For most of these patients, what they sacrifice is well worth it for what they gain."

"The Raindrop inlay, and inlays in general, are going to serve a very important purpose," he concludes. "As they become approved, we're going to find that patients really want this kind

of technology. It's appealing because it serves emmetropic presbyopes—patients who are not well served by any other modality we have. Many of these patients are not willing to try monovision, and they're generally too young for lens implant surgery. They want a quick and easy solution, and they like the idea of something that's reversible if it doesn't work out."

"I think there will definitely be a place for these inlays in our clinical practices," agrees Dr. Maloney. "It looks like the Kamra inlay is the one closest to FDA approval, but as a surgeon I'd be very happy to add any one of them to my practice." **REVIEW**

*Dr. Tomita is a consultant for AcuFocus. Dr. Maloney is a paid consultant for Presbia, but has no equity interest or financial incentives relating to the outcome of the Flexivue trial; he has no financial interest in AcuFocus or the Kamra inlay. Dr. Tamayo is a member of the Board of Consultants for Presbia. Dr. Hovanesian is an investigator, consultant and member of the medical advisory board for ReVision Optics, but has no equity interest in the company.*

1. Tomita M, Kanamori T, et al. Simultaneous corneal inlay implantation and laser in situ keratomileusis for presbyopia in patients with hyperopia, myopia, or emmetropia: Six-month results. *J Cataract Refract Surg* 2012;38:495-506.
2. Tomita M, Kanamori T, et al. Small-aperture corneal inlay implantation to treat presbyopia after laser in situ keratomileusis. *J Cataract Refract Surg* 2013;39:898-905.
3. Waring GO 4th. Correction of presbyopia with a small aperture corneal inlay. *J Refract Surg* 2011;27:842-5.
4. Seyeddain O, Hohensinn M, et al. Small-aperture corneal inlay for the correction of presbyopia: 3-year follow-up. *J Cataract Refract Surg* 2012;38:35-45.
5. Chayet A, Garza EB. Combined hydrogel inlay and laser in situ keratomileusis to compensate for presbyopia in hyperopic patients: One-year safety and efficacy. *J Cataract Refract Surg* 2013;39:1713-21.
6. Garza EB, Gomez S, Chayet A, Dishler J. One-year safety and efficacy results of a hydrogel inlay to improve near vision in patients with emmetropic presbyopia. *J Refract Surg* 2013;29:166-72.
7. Limnopoulou AN, Bouzoukis DI, et al. Visual outcomes and safety of a refractive corneal inlay for presbyopia using femtosecond laser. *J Refract Surg* 2013;29:12-8.
8. Jackson GR, Owsley C, McGwin G Jr. Aging and dark adaptation. *Vision Res* 1999;39:3975-82.
9. King BR, Fogel SM, et al. Neural correlates of the age-related changes in motor sequence learning and motor adaptation in older adults. *Front Hum Neurosci* 2013;7:142.
10. Yilmaz OF, Alagöz N, et al. Intracorneal inlay to correct presbyopia: Long-term results. *J Cataract Refract Surg* 2011;37:1275-1281.
11. Alió JL, Abbouda A, et al. Removability of a small aperture intracorneal inlay for presbyopia correction. *J Refract Surg* 2013;29:8:550-6.

# One Plug One Size

## SnugPlug™

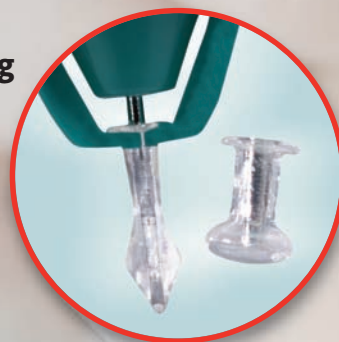That's *all* you need!

One-size-fits-all punctum plug  
**eliminates sizing** and **simplifies stocking**

Pre-stretched shape (on inserter)  
**avoids dilation** and **facilitates insertion**

Expanded shape (once inserted)  
assures snug fit and **virtually  
eliminates pop-out**

Soft collar prevents migration  
and **provides patient comfort**



FCI-Ophthalmics.com  
800.932.4202



Plug into FCI for Dry Eye Treatment and  
watch the SnugPlug insertion video.

Visit **PlugintoFCI.com** for promotional pricing

# Crack a SMILE Or Raise a Flap?

Walter Bethke, Managing Editor

The benefits and drawbacks of this unique intrastromal refractive surgery procedure.

In the evolution of refractive techniques, many surgeons have envisioned a time when intrastromal surgery would come to the fore, avoiding the need to disturb the corneal surface. Though the intrastromal procedure known as small-incision lenticule extraction—or SMILE—still involves an incision to remove stromal tissue to induce its refractive effect, some surgeons think it's the wave of the future. Though there's been no controlled, randomized comparative study of LASIK vs. SMILE, refractive experts are starting to get a sense of the relative strengths and weaknesses of the procedures. Here are their latest SMILE results, and their thoughts on how they compare to LASIK.

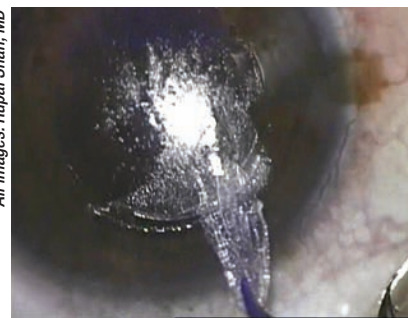
## What the Data Says

Thousands of SMILE procedures have been performed internationally, and SMILE surgeons have gotten a handle on its predictability and effectiveness. The procedure is currently approved outside of the United States for corrections up to -10 D with up to 5 D of astigmatism.

In SMILE, the surgeon programs the Carl Zeiss Meditec Visumax femtosecond laser to create an intrastromal lenticule, the thickness of which varies based on the amount of cor-

rection he wants to achieve. The laser then creates a peripheral corneal incision of 2.5 to 3 mm. The surgeon uses special SMILE forceps to go through the incision and remove the lenticule.

Amsterdam's Jesper Hjortdal, MD, and his team have performed 2,500 SMILE procedures, and Dr. Hjortdal discussed their results at the 2013 meeting of the American Academy of Ophthalmology. With SMILE, 95 percent of his patients (average preop error of -7.2 D) were within  $\pm 1$  D of the intended correction and 80 percent were within  $\pm 0.5$  D. In a paper covering the safety and complications of 1,800 SMILE eyes with a preop refraction of -7.25 D, Dr. Hjortdal reports that at three months 86 percent had unchanged or improved best-corrected vision, with 1.5 percent



Some experts say working with very thin lenticules can be challenging, since it takes skill to identify the edge.

All images: Rupal Shah, MD

(27 eyes) losing two or more lines.<sup>1</sup> The average postop refraction was  $-0.28 \pm 0.52$  D, with a mean treatment error of  $-0.15 \pm 0.5$  D. By 18 months, however, BCVA was within one line of its preop level in all eyes. Intraoperative complications included:

- epithelial abrasions in 108 eyes (6 percent);
- small tears at the incision site in 32 eyes (1.8 percent);
- difficult lenticule extraction in 34 eyes (1.9 percent);
- perforated cap in four eyes (0.2 percent) with no visual symptoms; and
- a major cap tear in one eye (0.05 percent) without visual symptoms.

Dr. Hjortdal reports intraoperative suction loss in 14 eyes (0.8 percent) that was remedied by retreatment in 13 eyes. The fourteenth eye had ghost images and had to be retreated with topography-guided PRK (which isn't available in the United States).

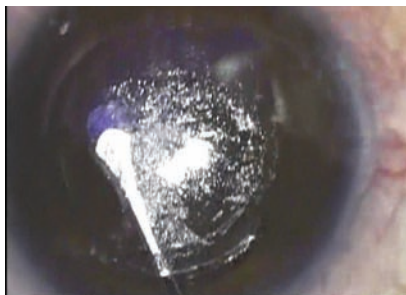
Postop complications included:

- trace haze in 144 patients (8 percent);
- day-one epithelial dryness in 90 patients (5 percent);
- interface inflammation secondary to corneal abrasion in five eyes (0.3 percent); and
- minor interface infiltrates in five eyes (0.3 percent).

The postop complications affected best-corrected vision at three months in only one case. The researchers add that in 18 eyes (1 percent) the treatment resulted in irregularities on topography that reduced vision at three months (12 eyes) or induced ghost images (six eyes). In the latter, surgeons performed topo-guided PRK in four of the eyes, which improved the vision in three. Two patients expressed dissatisfaction at the latest follow-up due to blurred vision or residual astigmatism, while the rest were satisfied.

## The Pros and Cons

After accumulating experience with



Separating the small tissue bridges in some difficult lenticules can result in some postoperative inflammation, say surgeons.

thousands of SMILE procedures, surgeons say some pros and cons are emerging:

• **Precision, and the absence of flap issues.** Dr. Hjortdal found that the procedure is more precise for certain levels of myopia than LASIK has been in his hands. “Since the cutting of the lenticule is being done in an intact cornea, I think the precision of SMILE is better than that of LASIK for moderate and high myopia,” he says. “The other advantage is you don’t have a full flap, but instead a small opening. Secondary to this you have, in theory, a more stable cornea afterward. Minor trauma to the cornea months or even years later may have less of a tendency to dislocate the anterior lamellae. You may also have less tendency to develop ectasia. Since the sensitivity of the cornea is less affected after SMILE than it is in LASIK, dry eye may be less.” To this point, Singapore ophthalmologist Jod Mehta says he can always pick up a difference in the tear film between LASIK and SMILE eyes in a contralateral eye study he’s currently engaged in. “It’s an obvious sign that you can see,” he says. “And when you ask the patients—who are masked as to what treatment is in which eye—they almost always tell you that if they have to put drops in, it’s in the eye that turns out to be the one that had LASIK.” Dr. Mehta’s LASIK vs. SMILE study is still ongoing.

On the flipside, however, there are some aspects of the SMILE procedure

that could pose more difficulties than in LASIK. “I think suction loss is the surgeon’s biggest fear when doing this procedure,” says Dr. Mehta. “You can’t stop and restart after the movement because the device is actually cutting the cornea, as opposed to ablating it—there are cutting planes that need to line up. Last year, though, Zeiss changed some of the laser programming and decreased the procedure time from 35 to 25 seconds, so patients don’t have to stay still under the laser as long as they had to before.

“Our suction loss rate was about 3.2 percent in the first 340 cases we studied,” Dr. Mehta continues. “However, if you handle suction loss correctly the patients do very well. Eighty-two percent of the suction-loss patients were able to finish their procedure on that day with a successful outcome. Two of them had to be converted to LASIK, one to LASEK.”

To help avoid suction loss from patient movement, Vadodara, India’s Rupal Shah, MD, says she tries to keep the patient calm. “It’s important to keep the patient steady, as the laser will be operating for 20 to 25 seconds,” she says. “To keep the patient from being anxious, so he can focus, keep reassuring him with such phrases as, ‘Very little time left now.’”

• **Low myopia/working with the lenticule.** Paradoxically, some surgeons have reported anecdotally that, while LASIK is easier in lower levels of myopia, SMILE may get more difficult since the lenticule is thinner and more challenging to manipulate with forceps. Dr. Mehta, however, says it’s not the manipulation that’s difficult in low myopia, it’s finding the proper tissue to manipulate. “When we teach surgeons SMILE, we start with higher myopes as patients,” he says. “They are usually between  $-5$  and  $-9$  D. This is because the lenticule is thicker in these patients. But when you’re doing a lower-level treatment, such as  $-3$  D as in one of our groups in our current study,

the difference isn't in the thickness in the lenticule because the edge of any SMILE lenticule is always 15  $\mu\text{m}$ . Instead, it's the center thickness of the lenticule that differs between low and high myopia. So, in a -1 myope the center might be 15  $\mu\text{m}$  thick, but in a -9 patient it would be around 100  $\mu\text{m}$ . It's easier to see the center thickness in the higher myopes. It's just the identification of the edge, and the edges above and below the lenticule, that the surgeon must be able to do. With more experience, you are able to identify the edges a lot more easily."

Dr. Hjortdal says SMILE can also involve some variation in the quality of the lenticule cut, causing issues in about 0.5 percent or less of patients. "This is probably related to the early stage the SMILE technique is in, but there can be a little variation in the completeness of the femtosecond laser cut," he says. "This means that sometimes you may have a slightly difficult lenticule removal and you might induce traces of hazy tissue in the interface. This may result in day-one acuity not being as good after SMILE when compared to LASIK, and you can run into problems related to the completeness of lenticule removal and smoothness. Specifically, you may have a little scar-like tissue in the interface that results from you having to be more aggressive in breaking these small tissue bridges.

"However, even though we've experienced such problems in some of our 1,800 eyes, when we have a second look at the patients in whom we noted significant problems during surgery, their condition seems to improve with time," Dr. Hjortdal adds. So, this doesn't end up in a situation of poor vision for the patients."

• **Early vs. late postop vision.** Surgeons who have done both LASIK and SMILE say they've noticed a difference in the procedures' patterns of visual recovery. "At least in the beginning, we felt there was a differ-

ence between LASIK and this type of surgery in terms of the uncorrected visual acuity on day one being a little lower with SMILE than what we've seen with LASIK," says Dr. Hjortdal. "However, it would improve during the first week. Today, though, I think this has improved, due to the experience of the surgeons and the adjustments we've made to the laser algorithm."

Dr. Mehta has noted some differences too, but in favor of SMILE. "Often LASIK patients get immediately good vision to start and then, over the first year, they get a slight deterioration in vision," he says. "But with SMILE, they get good vision and then it seems to get better over that first year."

• **Retreatments.** Surgeons have been grappling with the question of the best way to perform a retreatment on a previous SMILE patient since the procedure was introduced. "I don't think surgeons completely agree on how to perform retreatments," says Dr. Hjortdal. "If you want to adjust a diopter or so, it's probably not wise to do a new SMILE surgery, because you'd need to do that SMILE in a layer of cornea where you wouldn't interfere with the first cut. So, you'd have to go deeper or more superficial. Many surgeons—myself included—perform a PRK with the excimer to make minor corrections, if necessary."

One approach that's in its early stages is a laser software modification that allows the Visumax to turn a SMILE into a LASIK by using a circular pattern. "We did the first seven SMILE enhancement eyes with the circle software that converted the SMILE cap into a flap," says Dr. Shah. "The software works by adding a laser separation underneath the existing SMILE cap. You then lift the flap and use an excimer to perform the treatment." She says the downside, of course, is you lose the benefits of flapless SMILE. Dr. Mehta says one other approach some have used is a thin-flap

LASIK. "Some surgeons have basically done a LASIK with a 100- $\mu\text{m}$  thin flap on top of the SMILE cap," he says. "Before doing this, though, you'd need to perform an anterior segment OCT to make sure you have enough stroma between where your ablation is and where the lenticule was removed."

• **Hyperopia.** The other arena in which SMILE can't compete with LASIK, yet, is in hyperopia. SMILE is currently only approved outside the United States for myopic corrections. The main challenge is the transition zone on the edge of the lenticule. "I know the company is studying how to optimize the lenticule's shape in order to treat hyperopia," says Dr. Hjortdal. "This is because, when you treat hyperopia with SMILE, you need to remove a sort of doughnut-shaped piece of cornea, and you need smoothing at the periphery of the doughnut so as not to have an abrupt change in corneal thickness." Dr. Mehta says regression has been the main negative effect. "Walter Sekundo's group in Germany has done some hyperopic treatments," Dr. Mehta says. "And they've found they're not as stable as myopic treatments. There's been regression in the hyperopia. They've currently changed some of the nomogram, so I hope to be testing that out for them soon."

Though SMILE has some areas that could be improved, Dr. Mehta says it's moving in the right direction. "I think LASIK is technically easier to do: You just make a flap and the excimer does the treatment for you," he says. "With SMILE, there is definitely a learning curve with the technique in order to recognize the planes of the lenticule, visualization and the like. However, instruments make a huge difference, and the instrumentation for SMILE is a lot better than it was when I started three years ago. That's been a big improvement." **REVIEW**

1. Ivarsen A, Asp S, Hjortdal J. Safety and complications of more than 1,500 SMILE procedures. *Ophthalmology* 2013 Dec 20 pii: S0161-6420(13)01064-6. doi: 10.1016/j.ophtha.2013.11.006. [Epub ahead of print].





All Pupil II



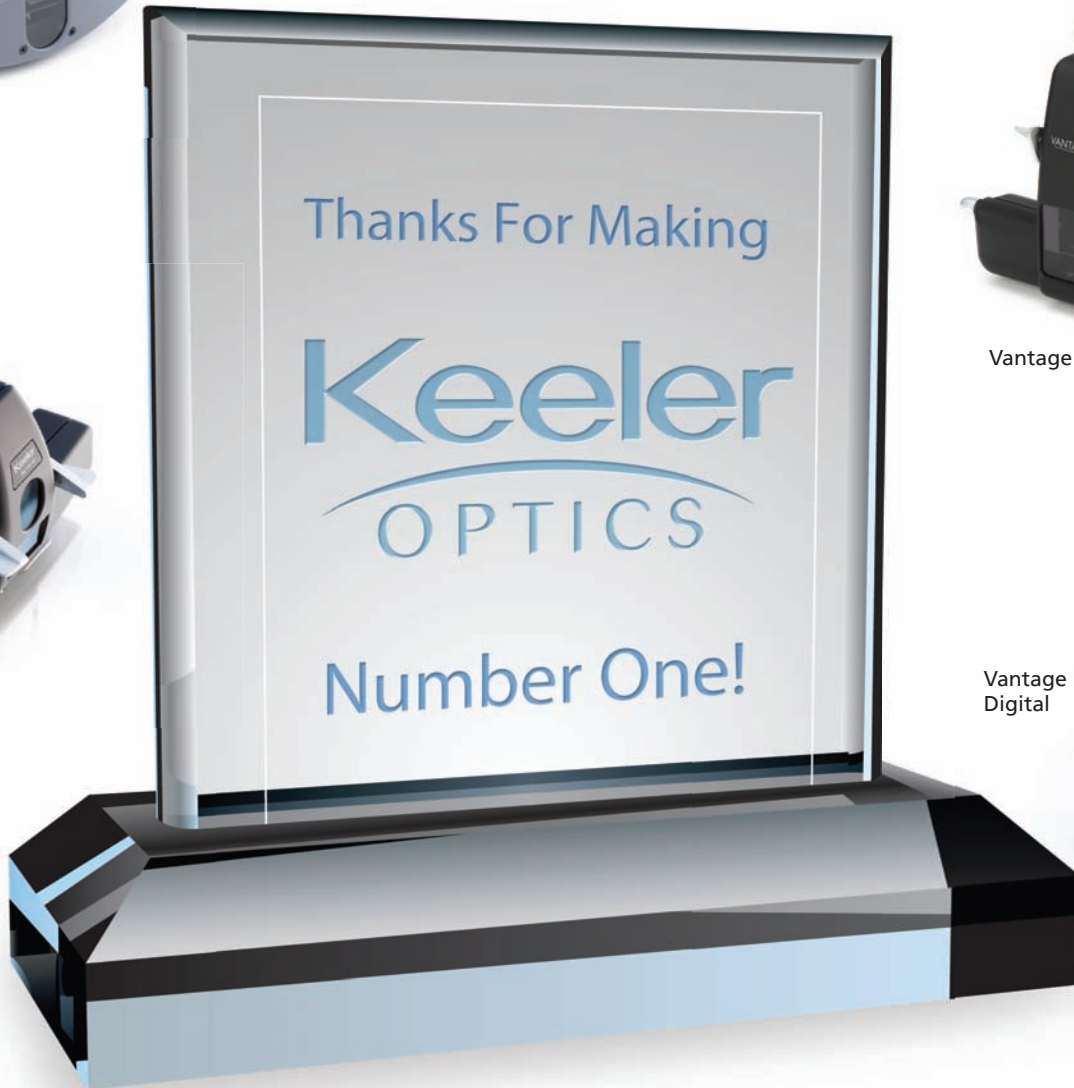Spectra Iris



Vantage Plus



Vantage Plus Digital



Get a  
**Free Keeler Indirect**  
 When You  
 Buy Any 3 Keeler Indirects,  
 & Trade-In Any 3 Indirects  
 through March 31, 2014

Learn more at [www.keelerusa.com](http://www.keelerusa.com)

For years, we've been telling you that Keeler\* is the world leader in innovation, technology, and market share.

- First Wireless Indirect
- First LED indirect
- First Digital Indirect
- First Intelligent Optical System
- Patented Hi-Mag Lens

\*iData Research Inc. 2011 – "Keeler Instruments was the leading competitor in the U.S. market for BIOs with a share of 63.6%." "The binocular indirect ophthalmoscope market has seen a great deal of innovation over the years. Keeler Instruments has been at the forefront of this innovation".

Buy Online!  
[keelerusa.com](http://keelerusa.com)



**Keeler**  
OPTICS

# Refractive Surgeons Embrace Thin Flaps

Walter Bethke, Managing Editor

Our survey of refractive surgeons reveals the tools and techniques they like most.

**T**hin is in when it comes to the LASIK flap, according to this month's survey of refractive surgeons. When LASIK first became popular, flaps were commonly around 145 to 160  $\mu\text{m}$ . However, advances in flap-making technology and the threat of ectasia, especially in higher corrections, have led surgeons toward thinner and thinner flaps, with the current average thickness hovering around 100  $\mu\text{m}$  on the survey.

Thoughts and opinions on LASIK flap creation are just one of the topics tackled by surgeons in this month's e-mail survey on refractive surgery. The survey e-mail was opened by 1,509 of 10,000 subscribers to *Review's* electronic mail service (15-percent open rate), and 69 surgeons responded. Here's what they had to say.

## The Tale of the Tape

On the survey, 59 percent of surgeons say they use flaps of 100 to 119  $\mu\text{m}$  for most of their cases, followed by 24 percent who like a thickness between 120 and 130  $\mu\text{m}$ . Six percent make flaps thinner than 100  $\mu\text{m}$ , 6 percent like flaps that are between 131 and 149  $\mu\text{m}$  and 6 percent make flaps thicker than 150  $\mu\text{m}$ . For flap-making, two-thirds of the surgeons use a femtosecond laser, with the rest

using a microkeratome.

"The 100- to 119- $\mu\text{m}$  thickness is a good balance of a stable flap and a good stromal thickness for ablation," says Los Angeles surgeon Uday Devgan. A surgeon from Memphis agrees. "It's a good compromise," he says. "It's thin enough to get the maximum amount of stroma available to ablate, but thick enough to avoid striae after repositioning." A surgeon from Indiana says this thickness range may be the threshold at which any thinner flaps might start causing issues. "It's thick enough to prevent sub-epithelial haze," he says.

The surgeons who like their flaps a little thicker, between 120 and 130  $\mu\text{m}$ , say they need that little extra thickness. "I prefer it because it's a stronger flap with less stretch that handles well," says Kurt Anderson, MD, of Dayton, Ohio. Richard Brown Jr., MD, of Fayetteville, Ark., says these flaps also work better for him. "I get consistent flaps with this thickness, with little trouble with lifting," he says. "For me, thinner flaps have a tendency to tear."

## Procedure Volume

Every surgeon has a procedure that he trusts more than the others, and for the refractive surgeons on

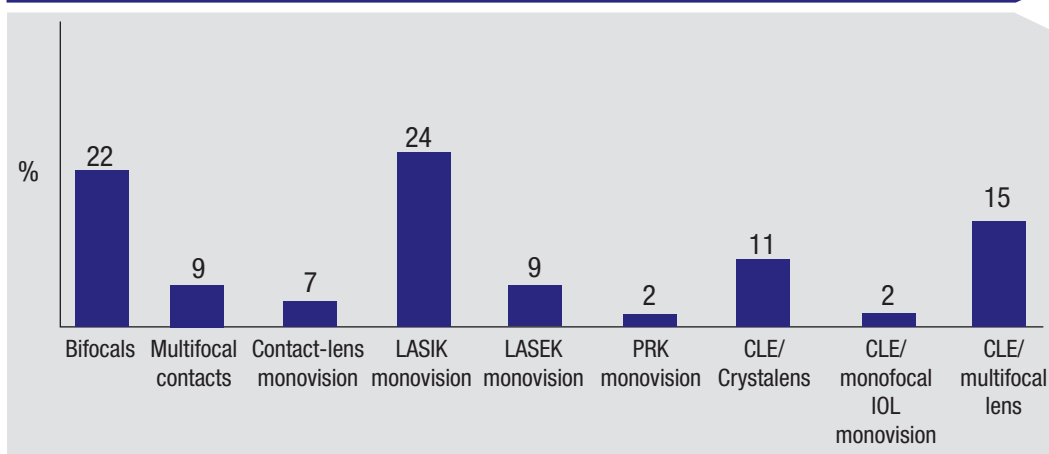
our survey it's custom LASIK, chosen by 43 percent as their procedure of choice. Twenty-eight percent say they use conventional LASIK the most, followed by PRK at 15 percent and wavefront-optimized LASIK at 13 percent.

In terms of LASIK volume, surgeons report that things are still

sluggish. Forty-eight percent of the surgeons do between five and 20 cases per month and 28 percent perform fewer than five. Eleven percent do between 21 and 50 cases and 2 percent perform between 51 and 75. On the high-end of volume, 6 percent of surgeons report doing between 76 and 100 cases, and 6 percent say they do more than 100 monthly. Surgeons say that they charge an average of \$2,452 per eye for LASIK and \$2,404 for PRK.

The procedures that surgeons favor change, however, when faced with cases that are outliers. For a high-myope (-11 D), about half (51 percent) say they think a phakic IOL is best; 16 percent like either custom or wavefront-optimized LASIK; 16 percent prefer PRK; 11 percent like using clear-lens extraction/intraocular lens implantation; 4 percent prefer conventional LASIK; and just 2 percent like LASEK. "A -11 correction is beyond the scope of good LASIK," says Dr. Devgan. "Phakic IOLs are OK, but the best option—and lowest risk—is to stick with contact lenses." A surgeon from Wisconsin thinks a phakic lens is the best option. "Optical aberrations occur with excessive corneal flattening," he says. "Although it's a small risk, retinal detachment is a risk in high myopes with clear-lens

### Best Procedure for a 45-year-old Hyperopic Presbyope



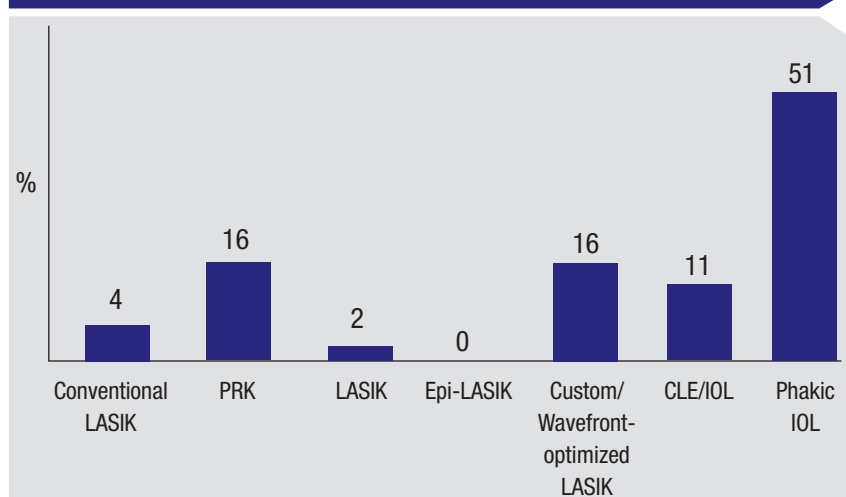
extraction/IOL implantation."

Some surgeons, however, think ablation has some benefits in these patients. "Femtosecond wavefront LASIK has been excellent for higher myopes, with accurate and quicker visual recovery and no haze concern," says Dr. Andreason. "However, corneal thickness may limit us to using custom PRK—which is good—but not my preference in this case." Clifford Salinger, MD, of Palm Beach Gardens, Fla., thinks LASEK fills the bill better, and outlines his course of action and the reasons why he likes LASEK. "Preoperatively, have the patient screened by a retinal specialist

to rule out any peripheral retinal pathology; otherwise, the patient and his attorney will point to surgery as the causative factor," he says. "LASEK allows more residual stromal bed thickness; 250 µm is an arbitrary thickness advised by the FDA that does not guarantee corneal structural integrity that would avoid long-term corneal ectasia. In addition, LASEK avoids applying a suction ring or Intralase suction to the eye that can induce structural changes to the vitreous and possibly increase the likelihood of retinal detachment."

Another challenge that refractive surgeons face is how to approach a

### Best Procedure for a -11 D Myope



45-year-old hyperopic presbyope, since no clear option has yet emerged. On the survey, the most popular options were LASIK monovision (24 percent), bifocals (22 percent), CLE/multifocal IOL (15 percent) and CLE/accommodative IOL (11) percent. All the other options were chosen by less than 10 percent of the surgeons (*the results appear in the graph on p. 35*). “This is a difficult question,” says Arkansas’ Dr. Brown. “While I am not a fan of clear-lens extraction and IOL implantation in a 45-year-old patient, for the hyperope, using CLE with a multifocal IOL and confirming with [ORA intraoperative aberrometry] has, in my experience, produced excellent results.”

Robert Epstein, MD, of McHenry, Ill., will alter his course of action depending on the patient. “If the patient is otherwise a LASIK candidate,

wavefront-guided LASIK would be done on the distance eye and possibly PRK on the near eye to minimize the risk of late ectasia,” he says. “[For] 48-year-olds the answer would be a bifocal procedure on the non-dominant eye, so there are some people whom I tell to wait until they are older. But hyperopic presbyopes have a lot to gain from refractive surgery and are the most appreciative.”

For the patient in need of an enhancement of her LASIK, surgeons are divided nearly down the middle: 50 percent will lift the previous flap and ablate and 45 percent will perform a surface procedure on top of the flap. Five percent will re-cut a flap and ablate. For his part, Dr. Epstein prefers to take the surface ablation route. “I prefer PRK over the LASIK flap only,” he says. “After many episodes of cells in the interface over the

past 23 years since I started LASIK I just find it easier to go with the slower healing of PRK for the sake of the predictability of having no problems with cells. When we used to do LASIK reoperations we did find a lower rate of epithelial cells in the interface when suturing the flap with the Barraquer eight-bite, anti-torque suture, and cells could be squirted from the interface postoperatively, but it is just too much trouble. PRK is fine.” Dr. Salinger, however, thinks a procedure that involves lifting the flap is better in the end. “I prefer it if the available corneal thickness allows for this option,” he says. “If the patient chose LASIK for the initial procedure, then lifting the flap and performing another LASIK is the fast-healing alternative that he is probably hoping for in terms of a second vision correction procedure.” **REVIEW**



# EYE CARE HAS ADVANCED

 **Local Eye Site**  
JOBS IN EYE CARE

## HAS YOUR HIRING STRATEGY?

Modernize your staffing efforts by downloading our **FREE 2014 Hiring Trends** guide today!

Download available at [localeyesite.com/c/guide](http://localeyesite.com/c/guide)



# ANATOMY OF A GREAT EXAM LANE

*Quality or Value - go ahead you can have both*

S4OPTIK products are the perfect blend of extraordinary Value and Quality. Instruments which satisfy even the most discerning practitioner.

## H + Z SERIES SLIT LAMPS

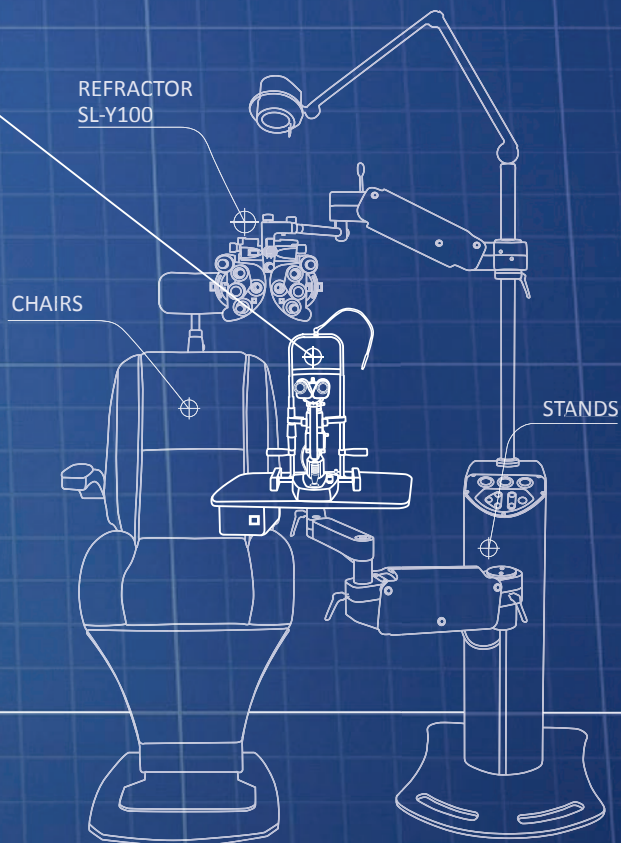
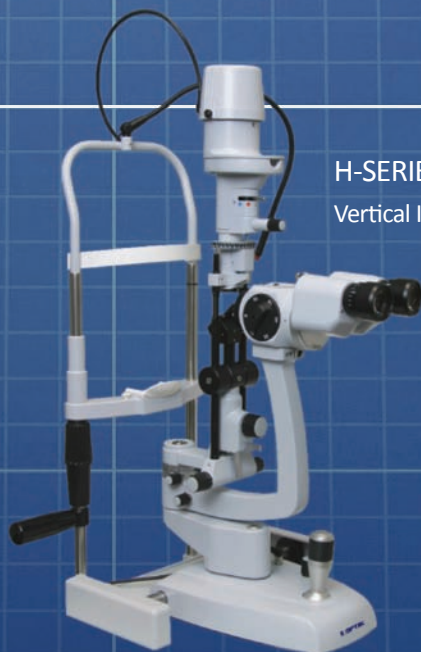### Z-SERIES

Compact Illumination Models



### H-SERIES

Vertical Illumination Models



### SLIT LAMP FEATURES

- Multilayered anti-reflective coatings
- Stunning optical quality allowing clear visualization and depth of field
- 20% increase in optical transmission
- 10% increase to the depth of field

[www.s4optik.com](http://www.s4optik.com) | [info@s4optik.com](mailto:info@s4optik.com)

# LASIK Xtra: Is It for Everyone?

Michelle Stephenson, Contributing Editor

Surgeons have begun combining LASIK and cross-linking to avoid post-LASIK ectasia and to improve refractive outcomes.

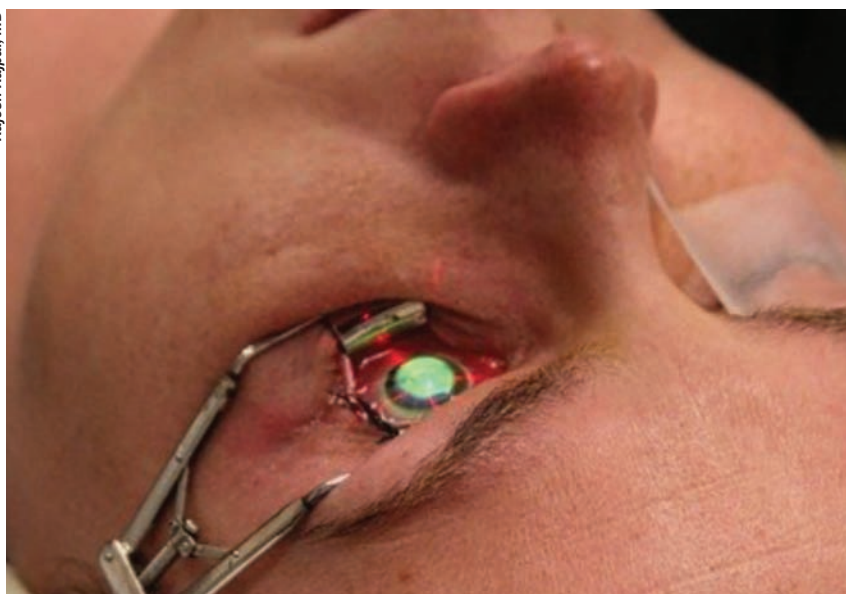Surgeons are performing LASIK in combination with cross-linking and are achieving promising results. “The goal of cross-linking in combination with LASIK is to improve LASIK outcomes in general, that is to ensure corneal stability from a biomechanical point of view and avoid corneal ectasia from a safety point of view,” says Peter Hersh, MD, who is in private practice in Teaneck, N.J.

He explains that by making a LASIK flap and removing tissue, some important anterior aspects of the corneal structure are weakened, and corneal rigidity may decrease. Dr. Hersh cites

London researcher and ophthalmologist John Marshall, PhD, who has estimated that LASIK may weaken the cornea by 15 percent to 25 percent. “In the vast majority of cases, this doesn’t lead to any clinical problem, and it certainly doesn’t lead to corneal ectasia in the vast majority of cases,” Dr. Hersh says. “Cross-linking, on the other hand, has been shown to reliably strengthen the cornea. So, the concept of combining the procedures both from a safety and efficacy point of view is of great interest.”

Dr. Hersh notes that the combined procedure, dubbed LASIK Xtra, can

Rajesh Rajpal, MD



be viewed as an extra safety element in patients who may have some theoretically greater risk: those who have thinner corneas and those who have high degrees of correction. “Strengthening the cornea with concurrent cross-linking may be beneficial in the longer-term stability of the refractive result and ultimate predictability of the procedure, he says. “Clinical studies are showing encouraging results, and further clinical work should continue to elucidate the advantages and disadvantages of the procedure.”

### Who Should Have LASIK Xtra?

Although LASIK Xtra is not approved in the United States, surgeons outside of the United States have been performing the procedure, and some believe that cross-linking should be performed on all LASIK patients.

“Internationally, some centers prefer to treat all LASIK patients, while others prefer to only treat high-risk patients,” says Rajesh Rajpal, MD, who is in private practice in the Washington, D.C., area. “These patients generally include high myopes, those with thin corneas or those with some topographic asymmetry or irregularity. High-risk patients might also be very young patients, because their corneas tend to change more over time; they may be hyperopic or they may have a family history of keratoconus. Basically, anyone who is at greater risk of developing ectasia after refractive surgery would be considered a high-risk patient. International doctors are approaching it similarly. Some say there is very little risk to LASIK Xtra, so why not treat everyone? Other doctors would rather not add anything to the procedure.”

A. John Kanellopoulos, MD, who is in private practice in Athens, Greece, and in New York City, employs cross-linking in all hyperopic LASIK cases. He also uses it in all young myopic patients over 6 D and under 30 years of age and in all patients with myopic

astigmatism when the difference in astigmatism between the two eyes is more than 0.75 D. “For example, if one eye is 1 D and the other eye is 2 D, in my protocol, this is a reason for that patient to undergo additive collagen cross-linking regardless of age,” Dr. Kanellopoulos says.

International studies have shown the benefits for patients with high myopia and high hyperopia corrections. Dr. Kanellopoulos recently concluded a long-term study comparing LASIK Xtra to standard LASIK for high myopia corrections.<sup>1</sup> “The results were compelling in favor of the LASIK Xtra cases as far as refraction accuracy and stability,” he says.

In this study, 65 eyes underwent LASIK Xtra and 75 eyes underwent LASIK alone. In the LASIK Xtra group, the mean patient age at the time of the procedure was 27.5 ±6.1 years (range: 19 to 39). Preoperatively, the mean refractive error was -6.60 ±2.02 D of sphere (range: -2.50 to -11.50), -1.35 ±1.24 D of cylinder (range: 0 to -5 D), and -6.75 ±1.75 D of manifest refractive spherical equivalent (range: -2.50 to -11.50).

In the LASIK only group, the mean preoperative refractive error was -5.14 ±1.74 D of sphere (range: -2.50 to -9.50), -0.85 ±0.75 D of cylinder (range: 0.00 to -3.50), and -5.33 ±2.34 D of manifest refractive spherical equivalent (range: -2.50 to -9.50). Mean central corneal thickness was 553.51 ±19.11 μm (range: 503 to 592) preoperatively and 454.34 ±19.98 μm (range: 422 to 515) one year postoperatively.

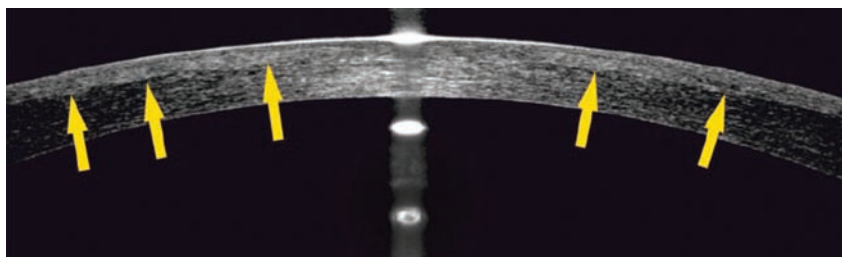
In the LASIK Xtra group, 90.8 percent of eyes had a postoperative uncorrected distance visual acuity of 20/20 (1.0 decimal) or better, and 95.4 percent had a UDVA of 20/25 (0.8 decimal) or better. In the LASIK only group, 85.3 percent of the eyes had a postoperative UDVA of better than 20/20 (1.0 decimal), and 89.3 percent had better than 20/25 (0.8 deci-

mal). The differences between the two groups at the 20/20 and the 20/25 levels were statistically significant ( $p=0.045$  and  $0.039$ , respectively).

When comparing the preoperative corrected distance visual acuity versus postoperative uncorrected distance visual acuity, in the LASIK Xtra group, 35 percent of the eyes were unchanged, 57 percent gained one Snellen line, and 8 percent gained two or more Snellen lines. No eye lost any lines. In the LASIK only group, 35 percent of the eyes were unchanged, 59 percent gained one Snellen line, and 5 percent gained two or more lines. Only 2 percent (one eye) lost one line.

In the LASIK Xtra group, 85 percent of eyes had a postoperative spherical equivalent refraction between -0.5 and 0 D, compared with 83 percent in the LASIK only group. Additionally, the LASIK Xtra group had a mean preoperative cylinder of -1.39 D, while the LASIK only group had a mean preoperative cylinder of -0.86 D. Despite this, postoperatively, 92 percent of the eyes in the LASIK Xtra group had less than 0.25 D of refractive astigmatism, compared with 94 percent in the LASIK only group.

The refractive stability is demonstrated by the manifest refractive spherical equivalent correction as seen during the one-, three-, six- and 12-month postoperative visits. One-year postoperative mean manifest refractive spherical equivalent minus the one-month baseline was -0.24 ±0.09 D in the LASIK Xtra group and -0.27 ±0.09 D in the LASIK only group. These results indicate a reduced refractive shift in the LASIK Xtra group compared to the LASIK only group. The keratometric stability is demonstrated by the K-flat and K-steep average values up to the 12-month postoperative visit. The results indicate an increased keratometric stability in the LASIK Xtra group (one year at +0.03 D in the flat and +0.05 D in the steep in comparison to one month baseline),



Anterior-segment optical coherence high-resolution cross-sectional (6-mm) image of an eye treated with LASIK Xtra for -4.50 D of sphere and -0.25 D of astigmatism obtained one year postoperatively. The intrastromal hyper-reflective sections may correlate with the depth of the prophylactic cross-linking effect.

when compared to the LASIK only group (+0.57 D and +0.54 D, respectively).

“These data suggest that LASIK Xtra is a refractive stabilizer in high myopia, presumably through its biomechanical stabilization effect,” Dr. Kanellopoulos says.

He has also studied LASIK Xtra in patients with hyperopia and hyperopic astigmatism.<sup>2</sup> In this study, 34 consecutive patients with hyperopia and hyperopic astigmatism elected to have bilateral topography-guided LASIK and were randomized to receive a single drop of 0.1 % sodium phosphate riboflavin solution under the flap followed by a three-minute exposure of 10 mW/cm<sup>2</sup> ultraviolet A light with the flap realigned in one eye and no intrastromal cross-linking in the contralateral eye. Refractive error and keratometric, topographic, and tomographic measurements were evaluated over mean follow-up of 23 months.

Preoperatively, the mean refractive spherical equivalent was +3.15 ±1.46 D and +3.40 ±1.78 D with a mean cylinder of 1.20 ±1.18 D and 1.40 ±1.80 D and mean uncorrected distance visual acuity (decimal) of 0.1 ±0.26 and 0.1 ±0.25 in the cross-linking and LASIK only groups, respectively. At two years postoperatively, the mean spherical equivalent refraction was -0.20 ±0.56 D and +0.20 ±0.40 D with mean cylinder of 0.65 ±0.56 D and 0.76 ±0.72 D and mean uncorrected distance visual acuity of 0.95 ±0.15

and 0.85 ±0.23 in the cross-linking and LASIK only groups, respectively. Eyes that underwent cross-linking demonstrated a mean regression from treatment of +0.22 ±0.31 D, whereas eyes that underwent LASIK only showed a statistically significant greater regression of +0.72 ±0.19 D ( $p=0.0001$ ).

“Topography-guided hyperopic LASIK with or without intrastromal cross-linking is safe and effective, with greater long-term efficacy (less regression) in eyes with cross-linking. Our data suggest that the regression seen with hyperopic LASIK may be related to biomechanical changes in corneal shape over time,” Dr. Kanellopoulos says.

### U.S. Trial

In the United States, a five-center clinical trial evaluating LASIK Xtra has just gotten under way. Dr. Rajpal was the first refractive surgeon to perform LASIK Xtra in the United States. “Because we are going through the Food and Drug Administration approval process, we will ultimately have data that will show whether there is a difference between regular LASIK and LASIK Xtra,” he says. “Hyperopic treatments are a good way to do that because we may be able to demonstrate stability or lack of regression in a reasonable time period. Because the rate of ectasia is so low, if the study was done to determine only whether there was a difference in the rate of ecta-

sia, it would be difficult to show statistical significance unless we treated hundreds of thousands of patients. That’s why the hyperopic study was started in this country.”

### Downsides of LASIK Xtra

“We have very good data internationally showing that performing cross-linking doesn’t have an effect on refractive outcomes, which has been one of the concerns,” Dr. Rajpal says. “Does strengthening the cornea change what you are achieving in terms of visual outcomes? While there may be a need for some adjustment in the nomogram for some patients, internationally, the data that we have seen has demonstrated that there is not really a need for adjustment. So it seems to be having some effect, and the refractive outcome does not seem to be negatively affected in any way. I feel if we can get FDA approval for this in the United States, and hyperopic LASIK may be the pathway for it, that would be a useful option for surgeons who want to offer this to their patients. I think most doctors will choose to start off with high-risk patients. Then, if they feel that it is providing a benefit to those patients, they will be much more likely to start offering it to all patients.”

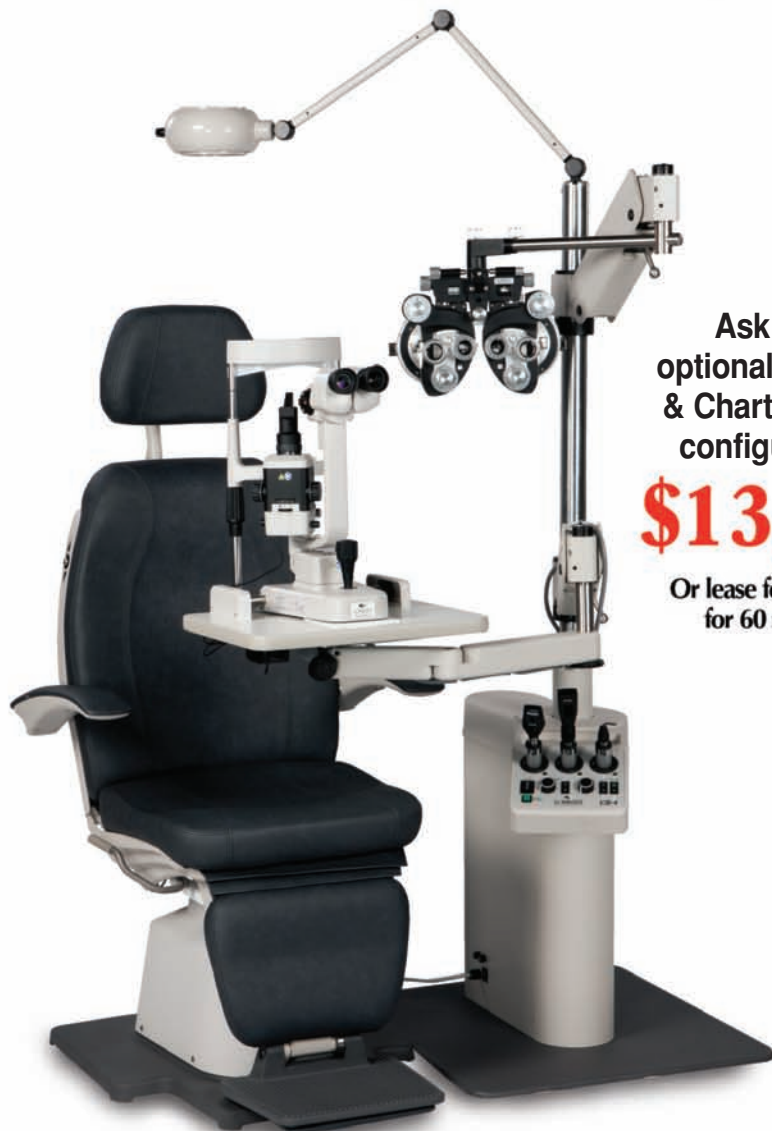He notes that there is likely no downside to the treatment other than adding a little bit of time to the procedure by applying the riboflavin and then the UV light. “That adds about three to four minutes to the total treatment,” he says. “Cost may be the only other downside. The study we are doing is using a pulsed UV light, as there is evidence that the cross-linking effect is greater when the light is pulsed. When ectasia occurs following refractive surgery, it can be very difficult to treat. So, if we can provide a procedure for our patients that reduces that risk and doesn’t add risk or significant cost, then I think it does make sense

*(continued on p. 61)*



# Invest In Your Practice And Get A Guaranteed Positive Return.

**Lombart's CS-4 Package Offers Quality, Style & Value.**



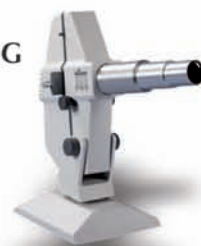Ask about optional Slit Lamp & Chart Projector configurations.

**\$13,595**

Or lease for \$269/mo. for 60 months \*

Package includes:

- The Lombart CS-4 Chair & Stand
- Topcon VT-10 Refractor
- Topcon SL-2G Slit Lamp
- Reichert LongLife Chart Projector with mount, slide & screen
- Upgrade to the Lombart CVSi21 for only \$2000 more or to the CVS-PC for only \$1500 more — Additional upgrades & configurations available.



(1-800-566-2278)

**Call 1-800-Lombart**

Or Your Local Lombart Representative.

Corporate Office - 5358 Robin Hood Road, Norfolk, VA 23513-2430  
757-853-8888 | FAX 757-855-1232 | 800-566-2278 | 800-446-8092  
[www.lombartinstrument.com](http://www.lombartinstrument.com)

ATLANTA•BALTIMORE/WASHINGTON D.C.•BOSTON•BOYNTON BEACH/MIAMI•BRADENTON•CHARLOTTE  
CHICAGO•CINCINNATI•DALLAS•DENVER•DETROIT•GREENSBORO•HOUSTON•KANSAS CITY•KNOXVILLE•LOS ANGELES  
MILWAUKEE•MINNEAPOLIS•NEW JERSEY/NEW YORK•NORFOLK•PORTLAND•SACRAMENTO•SAN DIEGO•SAN FRANCISCO

\*Lease rate subject to credit approval, 1st payment is paid for by leasing company at signing with 59 remaining rental payments of \$269 and a \$1.00 purchase option. Taxes, freight and installation additional. Hand Instruments optional. Quantities limited. Subject to change without notice.



# Multimodal Imaging of APMMPPE, Related Disorders

Recognizing the distinctive features of each placoid disorder is critical for accurate and timely diagnosis and management.

*By Meena George, MD, PhD, Pamela Golchet, MD, K. Bailey Freund, MD, and David Sarraf, MD, Los Angeles*

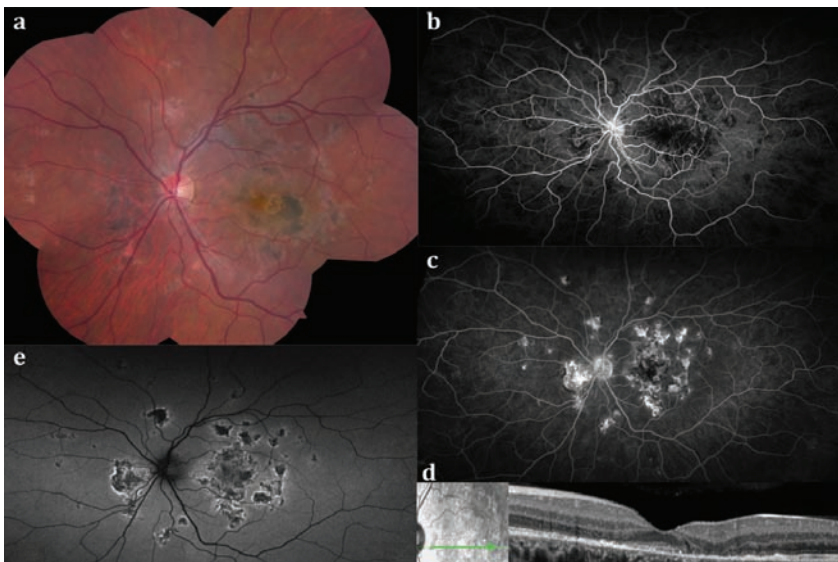
**A**cute posterior multifocal placoid pigment epitheliopathy and serpiginous choroiditis are two well-defined members of the white spot

syndromes with characteristic placoid lesions. Variant placoid entities have been described that resemble these two better-known disorders

and include macular serpiginous choroiditis, tubercular serpiginoïd choroiditis, relentless placoid chorioretinitis and persistent placoid maculopathy. Although the conditions are rare, recognizing the distinctive features of each is critical for accurate, timely diagnosis and management and, thus, for optimizing visual prognosis. In this review, we summarize the clinical presentation, diagnosis and management as guided by multimodal imaging for these variant placoid white spot syndromes.

## APMPPE

Acute posterior multifocal placoid pigment epitheliopathy (APMPPE) was first described by J. Donald M. Gass, MD, in 1968.<sup>1</sup> It typically presents in young adults with bilateral vision loss and may be preceded by a viral illness. Presenting symptoms may include photopsia, decreased vision, paracentral scotoma or metamorphopsia. There is no gender or ethnic predilection. On fundus examination, APMMPPE is characterized by randomly scattered, flat multifocal creamy white or yellow



**Figure 1.** Acute posterior multifocal placoid pigment epitheliopathy. A) Color fundus photograph showing placoid lesions in the macula and periphery of the left eye. B and C) Fluorescein angiogram of the same patient three months prior demonstrating early hypofluorescence (B) and late staining (C) of the lesions. D) SD-OCT showing lesion with irregular thickening of the retinal pigment epithelium and patchy loss of the ellipsoid zone and RPE layers. E) On fundus autofluorescence, active lesions are hypoautofluorescent due to a blocking effect by the outer retinal lesions, but with resolution develop a hyperautofluorescent rim thought to be secondary to altered RPE metabolism and lipofuscin deposition.

plaques at the level of the retinal pigment epithelium with indistinct margins. Plaques are typically located in the macula but may also involve the peripheral quadrants (See Figure 1A). New lesions can develop, and as such, lesions of differing age may be present at any given time.

On fluorescein angiography, active lesions demonstrate early hypofluorescence (See Figure 1B) and late staining (See Figure 1C). Inactive lesions show hyperfluorescence corresponding to window defects from retinal pigment epithelium atrophy. Indocyanine green angiography shows hypofluorescence of active and healed lesions.

Recent analyses of APMPE lesions using spectral-domain optical coherence tomography demonstrate various stages of retinal morphologic changes.<sup>2,3</sup> At onset, the placoid lesions appear as prominent, dome-shaped elevations of the ellipsoid zone (EZ) band, with hyper-reflective material and subretinal fluid accumulation.<sup>4</sup> Over the course of the disease, the dome-shaped lesion flattens, the EZ thickens, the outer nuclear layer shows hyperreflectivity followed by thinning, and the RPE thickens (See Figure 1D).<sup>5</sup> At three months, there is partial restoration of the outer macula, reconstitution of the EZ band and minimal residual RPE irregularity.<sup>2</sup> These findings of outer retinal pathology in the absence of inner retinal abnormalities indicate that the choroid likely plays a role in this disease.

Fundus autofluorescence in the acute phase shows hypoautofluorescence of lesions. This hypoautofluorescence may be due to a blocking effect by the outer retinal lesions versus RPE edema or direct RPE damage with decreased lipofuscin production. After resolution, lesions may demonstrate hyperautofluorescence due to deposition of lipofuscin or altered metabolism of affected

RPE cells (See Figure 1E),<sup>6</sup> but often the hypoautofluorescence persists. Further histological studies are necessary to determine the true pathogenesis and whether the primary site of damage is the outer retina and the RPE versus choroidal hypoperfusion leading to RPE and outer retinal damage.

Active plaques resolve spontaneously over a course of approximately two to four weeks, often with mottling of the RPE but without atrophy of the choroid. Visual prognosis is usually excellent, with most patients recovering their baseline visual acuity, although prognosis is less favorable when there is foveal involvement. There are uncommon cases of severe vision loss from significant RPE alterations in the fovea or due to complications from choroidal neovascularization. Recurrences are rare.

In most cases, APMPE lesions can be observed and will resolve without any intervention. However, several reports have linked APMPE to central nervous system vasculitis, with manifestations ranging from headaches to venous sinus thrombosis.<sup>7</sup> This combination of APMPE with neurologic manifestations occurs more frequently in males and very rarely can have dire consequences, including death. Treatment recommendations in such cases include IV corticosteroids followed by a slow oral taper in combination with an immunosuppressant.

### Serpiginous Choroiditis

In contrast to the typically short-lived course of APMPE, serpiginous choroiditis is characterized by bilateral, progressive and often re-

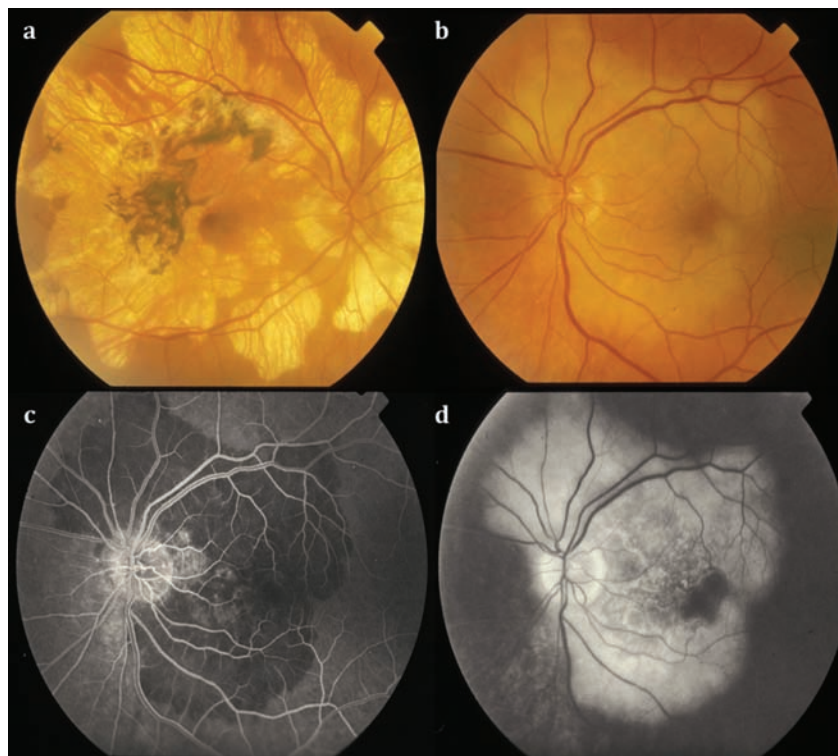


Figure 2. Classic serpiginous choroiditis. A and B) Color fundus photographs of the right and left eyes showing yellowish peripapillary serpentine lesions. The right eye (A) displays jigsaw-like chorioretinal atrophy with pigmentary changes that occurs after active lesions resolve. The left eye (B) shows active serpiginous choroiditis. On FA, active lesions (left eye) demonstrate early hypofluorescence (C) and late staining (d).

current inflammation of the choroid and outer retina.<sup>8</sup> It usually presents in healthy, white, middle-aged adults, with a slight male predilection.<sup>9</sup> Although typically a bilateral disease, patients often present with unilateral activity and decrease in vision once the fovea is affected. Other common symptoms include small scotomas or metamorphopsia.

On examination, the anterior chamber is generally quiet, whereas up to 50 percent of patients may exhibit fine cells in the vitreous. Peripapillary gray-white or yellowish serpentine lesions that extend centrifugally are the classic finding by ophthalmoscopy (See Figures 2A and 2B). Recurrences are contiguous with previous lesions and often assume a pseudopodal pattern. Chorioretinal atrophy in a jigsaw-puzzle configuration may ensue (See Figure 2A). Due to the gradual extension of these geographic (serpiginous) zones of chorioretinal and RPE infiltration and then atrophy, serpiginous choroiditis has previously been referred to as “geographic helicoid peripapillary choroidopathy”<sup>10</sup> and “geographic choroidopathy,”<sup>11</sup> among other nomenclature.

On FA, acute serpiginous lesions demonstrate early hypofluorescence (See Figure 2C) likely due to both choriocapillaris nonperfusion and blockage from RPE and outer retinal edema. Progressive hyperfluorescence at lesion margins may represent intact choriocapillaris. Over time, there is staining of the acute lesions (See Figure 2D). ICGA shows early and late hypofluorescence of

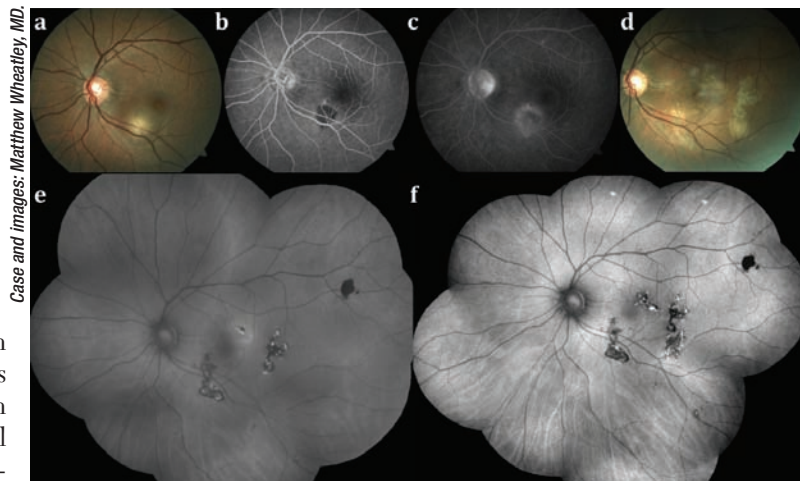


Figure 3. Tubercular serpiginoid choroiditis. A) Yellowish choroidal lesion in the inferior macula on initial presentation of tubercular serpiginoid choroiditis in a 42-year-old Indian male. The lesion demonstrates early hypofluorescence (B) and late staining (C). Over the course of two to three months, the patient developed several new lesions along with extension of existing choroidal lesions in a serpiginoid pattern (D). Wide-field autofluorescent montage demonstrating the extension of the old lesion and the presence of new foci of choroidal lesions (E). Wide-field fundus autofluorescence (F) reveals hypoautofluorescent inactive lesions as well as lesions with a stippled pattern of hypo- and hyperautofluorescence, suggestive of lesions that are still active but in the early phases of healing. The patient was treated with a four-drug TB regimen, oral prednisone and ultimately periocular and intraocular steroids in order to prevent further progression.

lesions, which appear larger than the corresponding lesions on examination or FA. Recurrences are common at the edges of prior atrophic scars and can occur after long periods of quiescence (even after several years). In the majority of patients the disease recurs, often several times.<sup>12</sup>

SD-OCT shows hyperreflectivity of the outer retina<sup>13</sup> and RPE with minimal distortion of the inner retinal layers.<sup>14</sup> Upon healing, lesions demonstrate loss of the RPE, photoreceptor outer segments, and EZ band with choroidal hyperreflectivity.<sup>14</sup>

FAF can be used to follow the course and demarcate the disease.<sup>15,16</sup> Active inflammation appears hyperautofluorescent, while older inactive lesions appear hypoautofluorescent. A hypoautofluorescent halo that surrounds all edges of active hyperautofluorescent lesions serves as a transitional stage between ac-

tive and inactive inflammation. Inactive inflammation shows dark, hypoautofluorescent lesions with sharp borders without any hyperautofluorescence at lesion edges.

With involvement of the macula, central vision is often significantly compromised. An important complication of serpiginous choroiditis is the development of choroidal neovascularization, reported to occur in about 13 to 20 percent

of cases.<sup>17,18</sup> Other complications described include cystoid macular edema, pigment epithelial detachments and branch retinal vein occlusions.<sup>19,20</sup>

Various strategies have been attempted to treat acute episodes of serpiginous choroiditis and to prevent recurrences. The mainstay of treatment is oral (or periocular) corticosteroids. Patients may relapse or recur when tapered to a dose less than 15 milligrams per day of oral prednisone.<sup>9</sup> Intravitreal corticosteroid implants may be more effective in preventing recurrences. Immunomodulatory agents including cyclosporine A, azathioprine and mycophenolate mofetil have been employed to prevent recurrences, with mixed reports of success. Additional strategies attempted are “triple-agent therapy,” which includes cyclosporine A, azathioprine and prednisolone, as well as alkylating

agents (e.g., cyclophosphamide or chlorambucil) in extreme cases, although caution must be used given the potentially severe side-effects of these drugs.<sup>9,11</sup> Laser photocoagulation and, recently, anti-VEGF agents have been used to treat CNV associated with serpiginous choroiditis.<sup>18,19,21</sup>

### Macular Serpiginous Choroiditis

A variant of serpiginous choroiditis termed “macular serpiginous choroiditis” was first described by Robert A. Hardy, MD, and Howard Schatz, MD, in 1987<sup>10</sup> and shares a number of features similar to classic peripapillary serpiginous choroiditis. However, in the latter entity, lesions begin around the nerve and recur centrifugally toward the macula, whereas macular serpiginous lesions commence in the macula and recur in a pseudopodal pattern centripetally towards the nerve.<sup>22</sup> FA and ICGA findings are essentially the same and treatment strategies are similar.<sup>23</sup> Because of its onset in the central macular region, visual acuity deteriorates early on and permanent vision loss is more profound and difficult to treat. Macular serpiginous choroiditis can also be complicated by CNV, further worsening the visual prognosis.<sup>22</sup>

### Tubercular Serpiginoid Choroiditis

Included in the differential diagnosis of the placoid entities, particularly in areas of endemic tuberculosis, such as India, is tubercular serpiginoid choroiditis. It presents in either of two ways: discrete, noncontiguous

multifocal choroiditis that later becomes diffuse and contiguous with an active advancing edge resembling classic serpiginous choroiditis (See Figure 3); or as a diffuse plaque-like choroiditis with amoeboid spread.<sup>24,25</sup> Aqueous and vitreous humor aspirates from two reported cases were positive for *Mycobacterium tuberculosis* by polymerase-chain reaction analysis.<sup>26</sup>

In a retrospective study by Reema Bansal, MD, and colleagues, of 105 patients with confirmed TB by posi-

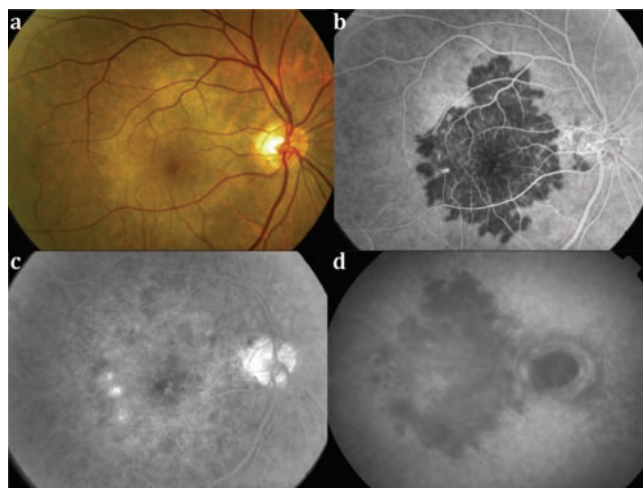


Figure 4. Persistent placoid maculopathy. A) Color fundus photograph showing white plaque-like lesion in the macula of the right eye. The patient's best-corrected visual acuity was 20/70 on presentation and declined significantly to 20/400 due to CNV. The white macular lesion becomes fainter over time on serial funduscopy. B) Early-phase FA shows hypofluorescent plaques with punctate areas of hyperfluorescence. C) Late-phase FA demonstrates multiple punctate spots of hyperfluorescence with partial filling of the hypofluorescent regions. In this particular case, there is almost complete resolution of the hypofluorescent regions. Early hyperfluorescent spots were associated with leakage and indicate choroidal neovascularization. D) Persistent hypofluorescence on indocyanine green angiography. The choroid remained hypofluorescent in the area of the lesion for a period lasting more than 14 months.

tive tuberculin skin testing or QuantiFERON-TB gold testing, more than 70 percent of cases were male, with a mean age of 33 years. The majority (80 percent) of patients presented with vitritis and over 60 percent had bilateral disease. Lesions were present in both the posterior

pole and the periphery. In contrast to classic serpiginous choroiditis, lesions were usually not contiguous with the optic disc (>85 percent). Patients treated with antitubercular therapy (four-drug regimen) and oral corticosteroids demonstrated good responses. The addition of antitubercular treatment reduced recurrences whereas those treated with oral steroids alone had a 75 percent recurrence rate. Lesions were followed using autofluorescence to monitor response to therapy.<sup>24</sup> Active lesions

showed ill-defined hyperautofluorescence with an amorphous appearance. In the early phase of healing, a thin surrounding rim of hypoautofluorescence with a central stippled pattern developed; on complete resolution, lesions were uniformly hypoautofluorescent (See Figure 3F). With treatment, the fovea was spared in 75 percent of patients, including those with macular involvement. Up to 3.5 percent of patients developed CNV.

Interestingly, 14 percent of patients were reported to have progression of disease after initiation of antitubercular therapy.<sup>24,25</sup> Some have proposed that tubercular serpiginoid choroiditis is an immune-mediated hypersensitivity reaction to the acid-fast bacilli sequestered in the RPE and that dying bacilli release proteins that can paradoxically aggravate the immune-response and initially worsen the choroiditis, a type of Jarisch-Herxheimer reaction.<sup>24,25</sup> An alternative possibility is a delayed effect of antitubercular therapy with worsening of the underlying disease by the corticosteroids.

**Table 1. Clinical & Angiographic Characteristics of Placoid White Spot Syndromes**

	APMPPE	Serpiginous Choroiditis	Relentless Placoid Chorioretinitis	Persistent Placoid Maculopathy
Lesion characteristics	Multiple posterior, creamy white-yellow lesions of varying sizes; fade in two to three weeks with subsequent RPE mottling.	Classically, serpentine gray or yellow peripapillary placoid lesions. In the macular variant, there is no extension to the disc.	Small ( $\leq 1/2$ disc area), creamy white placoid lesions at the level of the RPE, anterior and posterior to the equator. Pigmented atrophy may result within weeks, or lesions may persist and grow with new lesions developing over time. May end up with hundreds of lesions.	Geographic central whitish plaques at the level of the RPE, centered around the fovea, not contiguous with the optic disc. Lesions persist for months to years but become fainter with time.
Presenting symptoms	Sudden vision loss, photopsias, scotomas.	Loss of vision, scotomas, metamorphopsia	Decreased vision, floaters, metamorphopsia	Mild decrease in vision unless CNV present, photopsias, dyschromatopsia
Gender, Age	M = F, young	Slightly more common in males, young to middle age	Possible male preponderance, young to middle age	Possible male preponderance (only eight cases), older age (>50 yrs)
Laterality	Bilateral, usually symmetric	Bilateral. Usually one eye is active at a time.	Typically bilateral (80%)	Bilateral, symmetric
FA characteristics	Early hypofluorescence followed by late staining.	Early hypofluorescence followed by progressive hyperfluorescence at lesion margins with late staining.	Early hypofluorescence followed by late staining.	Early hypofluorescence with late partial filling; no marked leakage or staining.
ICG characteristics	Hypofluorescence throughout, less defined in late phase.	Hypofluorescence throughout, less pronounced in late phase	Hypofluorescence throughout	Hypofluorescence throughout
OCT findings	<u>Acute:</u> Dome-shaped elevations of the EZ band, hyperreflective material, subretinal fluid. <u>Late:</u> EZ thickening, ONL thinning, RPE thickening. <u>Resolution:</u> reconstitution of the EZ band, minimal RPE changes.	<u>Acute:</u> Hyperreflectivity of outer retina and RPE <u>Resolution:</u> Loss of the RPE, photoreceptor outer segments, and EZ band; normal ONL; choroidal hyperreflectivity.	<u>Acute:</u> Hyperreflectivity of the inner and outer retinal layers, subretinal fluid. <u>Resolution:</u> Normal anatomy reestablished.  (time-domain OCT findings)	<u>Acute:</u> Retinal thinning with photoreceptor and RPE disruption <u>Stability:</u> Well-defined areas of photoreceptor loss, collapse of the outer plexiform layer and thinning of the choriocapillaris.
FAF findings	Acute lesions demonstrate hypoautofluorescence and develop hyperautofluorescence with resolution.	<u>Active lesions:</u> Hyperautofluorescent <u>Inactive lesions:</u> Hypoautofluorescent <u>Transitional stage:</u> Hypoautofluorescent halo surrounding edges of active hyperautofluorescent lesion.	Extensive confluent areas of marked hypoautofluorescence corresponding to areas of chorioretinal atrophy.	Speckled pattern of hyper- and hypoautofluorescence in the macula.
Complications	Rarely significant RPE and photoreceptor atrophy or CNV resulting in vision loss.	CNV and CME in up to 20%. PED, BRVO also reported.	Subretinal fibrosis, ERM, subretinal fluid reported.	High risk for CNV with disciform scar formation, rare significant RPE atrophy.
Treatments	Generally none, occasionally corticosteroids.	Corticosteroids, plus other immunosuppressants, reservedly alkylating agents.	Prolonged corticosteroids; addition of other immunosuppressants also reported.	Oral and periocular corticosteroids; addition of other immunosuppressants such as cyclosporine.
Systemic associations	Viral prodrome, CNS signs.	Increased prevalence of systemic autoimmunity; reports of HLA-B27, Crohn's disease, celiac disease, and also sarcoid.	Hashimoto thyroiditis, aseptic meningitis, type 1 diabetes mellitus reported.	None
Course	Acute decrease in vision with spontaneous recovery and good final visual acuity.	Relapsing and progressive nature, often with loss of central vision in at least one eye.	Acute loss of vision with progression and recurrence and growth of new lesions over months to years. Good final acuity if no foveal involvement.	Persistent lesions with mild decrease in visual acuity and high risk of CNV development, potentially resulting in loss of central vision.

However, this subset of patients responded to increased oral corticosteroids or the addition of immunosuppressive therapy, supporting the former hypothesis. Thus, identifying the tubercular variant of serpiginous choroiditis is critical for initiation of appropriate antibiotics in combination with oral steroid therapy and one should not terminate antitubercular treatment even in the setting of initial paradoxical worsening.

### Relentless Placoid Chorioretinitis

Relentless placoid chorioretinitis (RPC) is an entity that has features resembling both APMPE and serpiginous choroiditis, but with an atypical retinal distribution and clinical time course.<sup>27</sup> The hallmark of this disease is the development of numerous new lesions during the disease course, which may span up to two years, eventually resulting in 50 to hundreds of lesions. Peripheral lesions can precede or occur simultaneously with posterior involvement and recurrences do not necessarily initiate at the edges of prior lesions (as in serpiginous). Because of its shared features with APMPE and serpiginous choroiditis, this entity was termed “ampiginous” by Robert B. Nussenblatt, MD.<sup>9,28</sup>

RPC presents in young patients, usually with a sudden decrease in vision and/or metamorphopsia with no history of a viral prodrome. An anterior chamber reaction or vitritis may be present.<sup>14,29</sup> Patients exhibit small, white, placoid lesions at the level of the RPE both anterior and posterior to the equator. Some of these lesions develop pigmented chorioretinal atrophy within weeks while others have a drawn out course of persistent activity or new growth. Angiographic findings are similar to those of APMPE and serpiginous choroidopathy.<sup>27,28,30</sup> Only one case of RPC with OCT imaging<sup>31</sup> and a

different case with FAF imaging<sup>16</sup> have been reported. On time-domain OCT, the active stage of the disease demonstrated hyperreflectivity of the inner and outer retinal layers with subfoveal fluid accumulation and a pigment epithelial detachment. With quiescence, normal foveal anatomy was reestablished.<sup>31</sup> FAF revealed extensive confluent areas of marked hypoautofluorescence corresponding to areas of chorioretinal atrophy.<sup>16</sup>

Vision can decrease significantly in RPC, especially with foveal involvement. However, if treated with prolonged systemic corticosteroids, most patients can recover most of their prior vision.<sup>27</sup> In the absence of treatment with systemic steroids, final visual acuity tends to be compromised with prolongation of disease course.<sup>28</sup> Complications of RPC include CNV, subretinal fibrosis, subretinal fluid and epiretinal membrane formation.

### Persistent Placoid Maculopathy

Persistent placoid maculopathy (PPM) was first described by Pamela Golchet, MD, and colleagues in 2006.<sup>32,33</sup> It resembles macular serpiginous choroiditis in its early involvement of the macula and predominantly affects middle-aged Caucasian males. Unlike in macular serpiginous choroiditis, patients with PPM initially present with only mild visual symptoms.

Anterior chamber inflammation or vitritis is typically absent.<sup>32,33</sup> On ophthalmoscopy, jigsaw-pattern, whitish placoid lesions centered around the fovea that are not contiguous with the optic disc (See Figure 4A) are noted. Unlike serpiginous or macular serpiginous choroiditis, PPM lesions have a longer time course and gradually fade over months to years without the development of new lesions. FA demonstrates early hypofluores-

cent plaques that partially fill in late phases of the study (See Figures 4B and 4C). ICGA shows hypofluorescent plaques throughout the study (See Figure 4D). SD-OCT shows retinal thinning with photoreceptor and RPE disruption. Once the disease is stable, SD-OCT shows well-defined areas of photoreceptor loss, collapse of the outer plexiform layer and thinning of the choriocapillaris.<sup>34</sup> In the presence of CNV, intraretinal fluid or neurosensory detachment may be present.<sup>35</sup> FAF shows a speckled pattern of hyper- and hypo-autofluorescence in the macula.<sup>34</sup>

Despite macular involvement, visual acuity is only mildly affected in PPM, with good prognosis for visual recovery unless RPE atrophy or CNV develops. While development of RPE atrophy is rare, CNV occurs at a much higher incidence in PPM than any of the previously described placoid diseases (only three eyes of 16 total eyes reported thus far did not develop CNV).<sup>32-34</sup> Treatment with oral or periocular corticosteroids and cyclosporine have resulted in improvement in visual acuity prior to complications with CNV.<sup>32-35</sup> In one case, chronic immunosuppression was initiated early in the diagnosis of PPM and no CNV developed in either eye at one-year follow-up.<sup>34</sup> Treatment strategies for PPM-related CNV prior to the age of anti-VEGF agents have included sub-Tenon's and intravitreal triamcinolone acetate, oral prednisone, laser photocoagulation, photodynamic therapy and submacular surgery, with limited success and subsequent formation of disciform scarring in the majority of cases.<sup>32,33</sup> There is one reported case of PPM-related CNV treated with intravitreal bevacizumab with good visual outcome followed over a period of two years.<sup>35</sup>

A summary of the clinical and angiographic characteristics of the

spectrum of placoid white spot syndromes is provided in Table 1. In 2002, Nadia Bouchenaki, MD, and colleagues described these disorders with characteristic hypofluorescence on ICGA as indicating choriocapillaris nonperfusion and classified them as inflammatory choriocapillaropathies.<sup>30</sup> With the aid of newer spectral-domain OCT studies, it appears there is also outer retinal involvement, and exactly where the site of primary insult resides still remains unclear. Future studies looking at enhanced depth imaging of the choroid may provide greater insight and understanding of the pathogenesis of placoid WSS. The etiology of WSS remains unknown, although the increased prevalence of systemic autoimmunity in patients with WSS and their relatives suggests WSS occurs in families with a genetic predisposition toward autoimmunity.<sup>36</sup>

Recognizing the different entities among the spectrum of the white-spot syndromes is important for the general ophthalmologist and especially for the retina specialist. Among the placoid WSS, APMPPE is the most common and benign with a viral prodrome and multiple creamy lesions that often fade within a few weeks as visual acuity recovers. Visual prognosis is more ominous in cases of serpiginous choroiditis, which endangers the fovea and carries a high risk of recurrences. The majority of patients with this particular placoid lesion permanently lose central vision in at least one eye. Relentless placoid chorioretinitis presents with numerous smaller lesions both anterior and posterior to the equator, with a prolonged clinical course and frequent relapses over months to years. With treatment, there is often only minimal sustained vision loss. Finally, persistent placoid maculopathy presents as a placoid lesion in the macula that persists for a time

course of months to years; although there is only a mild decrease in visual acuity, it carries a high risk of choroidal neovascularization that may result in significant loss of central vision. Obtaining imaging studies including fundus photos, FA, ICG angiography, SD-OCT and FAF is critical to establishing the correct diagnosis and guiding management. Close clinical follow-up and providing timely treatment when indicated are paramount in preventing or at least minimizing permanent vision loss. **REVIEW**

*Dr. George is in his final year of residency at the Jules Stein Eye Institute, UCLA, Los Angeles. Contact him at: meenageorge@gmail.com. Dr. Sarraf is a clinical professor of ophthalmology in the Retinal Disorders and Ophthalmic Genetics Division at Jules Stein. Contact him at dsarraf@ucla.edu or (310) 794-9921. Dr. Golchet practices at Southern California Permanente Medical Group in Woodland Hills, Calif. Dr Freund is a clinical professor of ophthalmology at NYU School of Medicine and practices at Vitreous Retina Macula Consultants of New York.*

1. Gass JD. Acute Posterior Multifocal Placoid Pigment Epitheliopathy. Arch Ophthalmol 1968;80:177-85.
2. Goldenberg D, Habet-Wilner Z, Loewenstein A, Goldstein M. Spectral domain optical coherence tomography classification of acute posterior multifocal placoid pigment epitheliopathy. Retina 2012;32:1403-10.
3. Hirano Y, Yasukawa T, Nagai H, Ogura Y. Spatio-temporal understanding of the pathology of acute posterior multifocal placoid pigment epitheliopathy. Jpn J Ophthalmol 2012;56(4):371-4.
4. Scheufler TA, Witkin AJ, Schocket LS, Rogers AH, et al. Photoreceptor atrophy in acute posterior multifocal placoid pigment epitheliopathy demonstrated by optical coherence tomography. Retina 2005;25:1109-12.
5. Cheung CM, Yeo IY, Koh A. Photoreceptor changes in acute and resolved acute posterior multifocal placoid pigment epitheliopathy documented by spectral-domain optical coherence tomography. Arch Ophthalmol 2010;128:644-6.
6. Souka AA, Hillenkamp J, Gora F, Gabel VP, Framme C. Correlation between optical coherence tomography and autofluorescence in acute posterior multifocal placoid pigment epitheliopathy. Graefes Arch Clin Exp Ophthalmol 2006;244:1219-23.
7. O'Halloran HS, Berger JR, Lee WB, Robertson DM, et al. Acute multifocal placoid pigment epitheliopathy and central nervous system involvement: nine new cases and a review of the literature. Ophthalmology 2001;108:861-8.
8. Gass JDM. Stereoscopic atlas of macular diseases: diagnosis and treatment. 3rd ed. vol 1. St Louis: Mosby, 1987.
9. Lim WK, Buggage RR, Susenblatt RB. Serpiginous Choroiditis. Surv Ophthalmol 2005;50(3):231-44.
10. Hardy RA, Schatz H. Macular geographic helioid choroidopa-

- thy. Arch Ophthalmol 1987;105:1237-42.
11. Hamilton AM, Bird AC. Geographical choroidopathy. Br J Ophthalmol 1974;58:784-97.
12. Christmas NJ, Oh KT, Oh DM, Folk JC. Long-term follow-up of patients with serpiginous choroiditis. Retina 2002;22:550-6.
13. van Velthoven ME, Ongkosuwo JV, Verbraak FD, Schlingemann RO, de Smet MD. Combined en-face optical coherence tomography and confocal ophthalmoscopy findings in active multifocal and serpiginous chorioretinitis. Am J Ophthalmol 2006;141:972-5.
14. Bansal R, Gupta A, Gupta V. Imaging in the diagnosis and management of serpiginous choroiditis. Int Ophthalmol Clin 2012;52(4):229-36.
15. Carreño E, Portero A, Herreras JM, López MI. Assessment of fundus autofluorescence in serpiginous and serpiginous-like choroidopathy. Eye (Lond) 2012;26:1232-6.
16. Yeh S, Forooghian F, Wong WT, Faia LJ, et al. Fundus autofluorescence imaging of the white dot syndromes. Arch Ophthalmol 2010;128:46-56.
17. Blumenkranz MS, Gass JD, Clarkson JG. Atypical serpiginous choroiditis. Arch Ophthalmol 1982;100:1773-5.
18. Lee DK, Suhler EB, Augustin W, Buggage RR. Serpiginous choroidopathy presenting as choroidal neovascularisation. Br J Ophthalmol 2003;87:1184-5.
19. Jampol LM, Orth D, Daily MJ, Rabb MF. Subretinal neovascularization with geographic (serpiginous) choroiditis. Am J Ophthalmol 1979;88:683-9.
20. Gupta V, Agarwal A, Gupta A, Bamberg P, Narang S. Clinical characteristics of serpiginous choroidopathy in North India. Am J Ophthalmol 2002;134:47-56.
21. Song MH, Roh YJ. Intravitreal ranibizumab for choroidal neovascularisation in serpiginous choroiditis. Eye (Lond) 2009;23:1873-5.
22. Mansour AM, Jampol LM, Packo KH, Hrisomalos NF. Macular serpiginous choroiditis. Retina 1988;8:125-31.
23. Sahu DK, Rawoof A, Sujatha B. Macular serpiginous choroiditis. Indian J Ophthalmol 2002;50(3):189-96.
24. Bansal R, Gupta A, Gupta V, Dogra MR, Sharma A, Bamberg P. Tubercular serpiginous-like choroiditis presenting as multifocal serpiginoïd choroiditis. Ophthalmology 2012;119:2334-42.
25. Gupta V, Bansal R, Gupta A. Continuous progression of tubercular serpiginous-like choroiditis after initiating antituberculosis treatment. Am J Ophthalmol 2011;152(5):857-63.
26. Gupta V, Gupta A, Arora S, Bamberg P, Dogra MR, Agarwal A. Presumed tubercular serpiginouslike choroiditis: Clinical presentations and management. Ophthalmology 2003;110:1744-9.
27. Jones BE, Jampol LM, Yannuzzi LA, Titti M, et al. Relentless placoid chorioretinitis: A new entity or an unusual variant of serpiginous chorioretinitis? Arch Ophthalmol 2000;118:931-8.
28. Jyotirmay B, Jafferji SS, Sudharshan S, Kalpana B. Clinical profile, treatment, and visual outcome of ampiginous choroiditis. Ocul Immunol Inflamm 2010;18:46-51.
29. Biswas J, Narain S, Das D, Ganesh SK. Pattern of uveitis in a referral uveitis clinic in India. Int Ophthalmol 1996-1997;20(4):223-8.
30. Bouchenaki N, Cimino L, Auer C, Tao Tran V, Herbot CP. Assessment and classification of choroidal vasculitis in posterior uveitis using indocyanine green angiography. Klin Monbl Augenheilkd 2002;219:243-9.
31. Amer R, Florescu T. Optical coherence tomography in relentless placoid chorioretinitis. Clin Experiment Ophthalmol 2008;36(4):388-90.
32. Golchet PR, Jampol LM, Wilson D, Yannuzzi LA, Ober M, Stroh E. Persistent placoid maculopathy: A new clinical entity. Trans Am Ophthalmol Soc 2006;104:108-20.
33. Golchet PR, Jampol LM, Wilson D, Yannuzzi LA, Ober M, Stroh E. Persistent placoid maculopathy: A new clinical entity. Ophthalmology 2007;114:1530-40.
34. Kovach JL. Persistent placoid maculopathy imaged with spectral domain OCT and autofluorescence. Ophthalmic Surg Lasers Imaging 2010 Nov-Dec;41 Suppl:S101-3
35. Parodi MB, Iacono P, Bandello F. Juxtafoveal choroidal neovascularization secondary to persistent placoid maculopathy treated with intravitreal bevacizumab. Ocul Immunol Inflamm 2010;18(5):399-401.
36. Pearman RB, Golchet PR, Feldmann MG, Yannuzzi LA, et al. Increased prevalence of autoimmunity in patients with white spot syndromes and their family members. Arch Ophthalmol 2009;127:869-74.





# WE'RE CHANGING THE WAY

## PATIENTS WITH VISION IMPAIRMENT ENVISION THEIR FUTURE

The Louis J. Fox Center for Vision Restoration of UPMC and the University of Pittsburgh—a joint program of the UPMC Eye Center and the McGowan Institute for Regenerative Medicine—is the first national, comprehensive, and multidisciplinary research and clinical program dedicated to ocular regenerative medicine. Our ophthalmologists and researchers focus on the discovery of new treatments for blindness and impairment through tissue regeneration, enhancement, transplantation, and technology. We're working hard to improve the quality of life for the millions of people affected by vision loss, so that we can all see a brighter future. Learn more at [UPMCPhysicianResources.com/Vision](http://UPMCPhysicianResources.com/Vision).

**UPMC** LIFE  
CHANGING  
MEDICINE

UPMC is affiliated with the University of Pittsburgh School of Medicine.



# Wise Choices for Ocular Diagnoses

A look at the value and utility of a range of diagnostic techniques and technology for anterior segment disease.

*Mark B. Abelson, MD, CM, FRCSC, FARVO, and James McLaughlin, PhD, Andover, Mass.*

**A** key part of the many debates over health care is the idea of providing the best possible care with increasingly limited resources. This attention to spending has amplified the interest in more cost-conscious medicine. A 2012 report in the *Journal of the American Medical Association* identified six areas of medical waste and, among these, overtreatment (including superfluous testing, treatments or hospitalizations) was the biggest of the offenders, with estimates of \$150 to \$225 billion wasted by such activities in the United States annually.<sup>1</sup> Lost in these arguments, at times, is that no matter the dollar figures involved, such activities are often bad medicine as well as bad economics. So perhaps a silver lining that may emerge from the chaos that is health-care reform is the reaffirmation that in medicine, as in many other avocations, less is very often more.

An example of this is the Choose Wisely campaign,<sup>2</sup> an effort spearheaded by the American Board of Internal Medicine that has recruited more than 50 specialty societies, including the American Academy of Ophthalmology, to identify tests and

procedures that are overused, provide little clinical benefit and, in some cases, may even be obstacles to achieving the best possible patient outcomes. These groups identified five or more suggested practices based upon the latest in evidence-based assessments. One of the AAO recommendations states, “Don’t perform preoperative medical tests for eye surgery unless there are specific medical indications.” So unless the patient has a history of heart disease, for example, a preoperative EKG is unnecessary. Some of the Choose Wisely recommendations run counter to established practices, but in a sense, that’s the point: They are a way of rethinking standard operating procedures in light of 21st-century economics and, most importantly, 21st-century medical evidence.

In this month’s column we examine selected front-of-the-eye diagnostics and standard operating procedures and ask how these procedures hold up to a “choose wisely” inspired evaluation. Our strong bias in this discussion is that patient history and examination remain the most valuable sources of information for diagnostic inquiry.

## Which Conjunctivitis?

Acute conjunctivitis presents with a spectrum of features that will often provide all the diagnostic data needed to determine the underlying etiology.<sup>3</sup> What we like to refer to as “Abelson’s diagnostic triad” states that if it’s itchy, it’s allergy; if it’s sticky, it’s bacterial; and if it burns it’s dry eye. Clear discharge, visual impairment, photophobia and ocular pain are other features that can be useful in whittling down the diagnosis.<sup>4</sup> Viral conjunctivitis can have a variable presentation, but a key to remember is that it’s typically follicular, so swollen lymph nodes (especially periauricular nodes) can be diagnostic. These initial assessments can be followed up by additional testing, exploratory therapeutics or both.

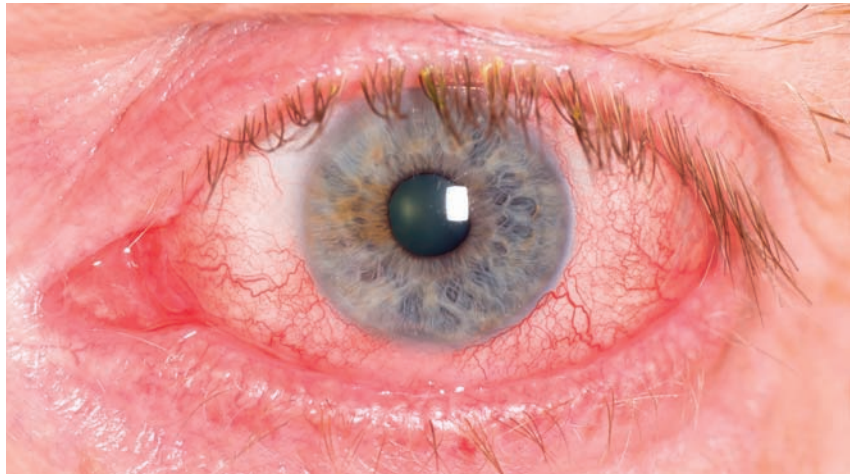
While a test dose of a topical antihistamine is probably the most efficient way to confirm a diagnosis of allergic conjunctivitis, other forms of conjunctivitis may require further investigation. Another of the AAO recommendations in the Choose Wisely campaign is “Don’t order antibiotics for adenoviral conjunctivitis (pink eye).” Despite this, recent

estimates suggest that physicians (including ophthalmologists) are not particularly adept at discriminating between bacterial or viral etiologies.<sup>4</sup> With the exception of severe cases, culturing of bacteria or viral infections is neither time- nor cost-effective. A simple, rapid test for adenovirus (Adenoplus, RPS Inc.) can help define a diagnosis when there is a question of viral vs. bacterial etiology.<sup>5,6</sup> It's worth remembering that about 80 percent of acute conjunctivitis cases are viral, and of these, between 65 to 90 percent are due to one of the adenovirus serotypes (as discussed in *Therapeutic Topics*, March 2010). The Adenoplus test can minimize misuse of antibiotics, and also can confirm the need for patient isolation to prevent the spread of virus.

## Dry-Eye Diagnostics

The diagnosis of dry eye is complex; the condition can result from any number of causes (or combinations of causes), each of which contributes to the patient's presentation.<sup>7,8</sup> Thus, patients with an aqueous deficiency of the tear film will present different symptomology from those with meibomian gland disease, but all are likely to share some degree of discomfort, surface inflammation and visual impairment. Diagnosis has traditionally been made using the combination of patient symptomology, tear assessments using Schirmer's strips and ocular surface staining. Lack of a reproducible, consistent association between signs and symptoms of dry eye represents the single biggest impediment to both accurate diagnosis and development of effective treatments.

The diagnostic tests for dry eye described in the International Dry Eye Workshop include measures of tear volume (Schirmer's test, phenol red thread test and meniscus height), physical properties (breakup times, osmolarity), composition (lactoferrin) and tear dynamics (turnover rate).<sup>8</sup>



When faced with a case of conjunctivitis, “Abelson’s triad” can help clinch the diagnosis: If it itches it’s allergy; if it’s sticky it’s bacterial; and if it burns it’s dry eye.

Review of the evidence behind each of each of these methods indicates that none alone provides the sensitivity and specificity needed for a reliable diagnostic. Without a diagnostic gold standard, the recommendations of the DEWS report leave both practitioners and clinical researchers to rely on the “tetrad” of symptom questionnaires, corneal staining, tear-film breakup and Schirmer’s test as the most reliable means of dry-eye assessment.<sup>8</sup> Research at Ora has led to the development of a number of refinements to tear-film assessments, but these are generally not suited for routine clinical practice.<sup>9-11</sup> It seems that none of these traditional metrics is a particularly wise choice, since none provides a robust metric from which to derive a therapeutic strategy. Despite this, new technologies are available or in development that attempt to address this unmet need.

Use of imaging techniques is one such area of diagnostic progress. Established technologies such as optical coherence tomography or confocal microscopy are being adapted to examine tear-film properties, corneal nerve structures, inflammatory cell infiltration and structure of meibomian glands.<sup>12,13</sup> These methodologies allow for a more precise assessment of the

tear film, and provide the means to monitor the cellular morphology associated with dry eye. It’s likely that with additional studies revealing changes in the epithelium, meibomian glands and corneal nerves associated with dry eye (both aqueous-deficient and MG disease), it will be possible to use these imaging modalities for objective diagnosis and treatment monitoring.

## Analyzing Tear Components

Efforts at characterizing tear protein components, and the potential use of protein profiling as a diagnostic tool, go back several decades.<sup>14</sup> These efforts mirror the difficulty of developing efficacious treatments, and there are still few validated tear biomarkers for dry eye; major candidates include several pro-inflammatory cytokines, metalloproteinases or lactoferrin. Several new devices designed for use in clinical practice are available that offer the ability to analyze tear constituents as a diagnostic for dry eye.<sup>15</sup> One of these, InflammDry (RPS), measures the concentration of matrix metalloproteinase 9 in a simple, one-step device similar to the Adenoplus. This protease is involved in the breakdown of epithelial integrity associated with chronic inflammation.<sup>16</sup> Tears can

(ATD), another one-step system to measure either tear lactoferrin or IgE levels is also now on the market. It's thought that a comparison of markers of inflammation (lactoferrin or MMP 9) with a primary marker of ocular allergy (IgE) will help distinguish between dry eye and chronic allergy, though proof of the utility of these devices will only come from clinical studies that track the biomarkers as a function of therapeutic regimes or correlate the biomarkers to other signs and symptoms. There are promising studies that suggest that elevated MMP 9 levels in tears are an early predictor of dry eye, and that the levels of the proteinase in tears show a significant correlation to other dry-eye signs and symptoms.<sup>16</sup> However, there are several issues with the use of MMP 9 tests for dry eye that clinicians need to be aware of, including the reported effects of contact lens use<sup>17</sup> and prostaglandin analogues<sup>18</sup> on tear levels of the proteinase. Despite these potentially confounding issues, the MMP 9 test does appear to have value as an objective measure of ocular surface inflammation.

Another tear composition diagnostic that's now widely available is the TearLab Osmolarity Test (TearLab), a device that measures the concentration of tear solutes and is described as an objective, reliable measure of the severity of dry-eye disease.<sup>19</sup> Despite this claim, there are limitations to the use of osmolarity as a diagnostic for dry eye. For instance, compensatory mechanisms, such as more rapid blinking, can significantly alter tear osmolarity, as can other factors such as patient hydration, diurnal variation, environmental conditions and other diagnostic procedures. While some have described osmolarity as the "gold standard" of dry-eye diagnostics,<sup>20</sup> it's clear that currently available measures of osmolarity alone cannot unequivocally confirm or disprove a diagnosis of dry eye. In fact, the FDA indica-

tion for TearLab describes it as an "aid in the diagnosis of dry-eye disease in patients suspected of having dry-eye disease, in conjunction with other methods of clinical evaluation."<sup>21</sup>

The value of osmolarity measurements in monitoring treatment is also unclear. In a recent retrospective study, Francisco Amparo, MD, and his colleagues at the Schepens Eye Research Institute compared osmolarity values to other measures of dry eye, including the ocular surface disease index survey and Oxford-scale rated corneal staining.<sup>22</sup> They report that while there was modest correlation between osmolarity and the more traditional measures of dry eye, there was no correlation between changes in osmolarity and improvements in OSDI or staining scores. While an alternative interpretation of this study was also recently published,<sup>23</sup> it is nonetheless hard to see how a test with a Food and Drug Administration indication to be used in conjunction with other dry-eye metrics can be considered a gold standard for either clinical diagnosis or as an endpoint (or inclusion criteria) for clinical trials.

Some of these newer technologies may provide value in diagnosis and formulation of the best treatment plans. When we consider any new diagnostics, however, remember to consider several key factors: Does the result of the test improve our ability to render an accurate diagnosis? Can the test be used to follow or modify the course of a patient's condition? If not, then what is its value? We are reminded of the Yogi Berra aphorism that, sometimes, "You can observe a lot just by watching." While there are a number of powerful, technologically sophisticated new devices either on the market or under development that will all claim to provide the key to diagnostic success, no machine has been invented that can supplant the value of a thorough patient history and exam. So, it's up to us to choose wisely

when mapping the course for diagnosis and management of all ocular surface diseases. **REVIEW**

*Dr. Abelson is a clinical professor of ophthalmology at Harvard Medical School. Dr. McLaughlin is a medical writer at Ora Inc.*

- Berwick DM, Hackbarth AD. Eliminating waste in US health care. *JAMA* 2012;307:14:1513-6.
- <http://www.choosingwisely.org/doctor-patient-lists/> accessed 6 December 2013.
- Azari AA, Barney NP. Conjunctivitis. A Systematic Review of Diagnosis and Treatment. *JAMA*. 2013;310:16:1721-1729.
- O'Brien TP, Jeng BH, McDonald M, Raizman MB. Acute conjunctivitis: Truth and misconceptions. *Curr Med Res Opin* 2009;25:8:1953-1961.
- Sambursky R, Tauber S, Schirra F, et al. The RPS adeno detector for diagnosing adenoviral conjunctivitis. *Ophthalmology* 2006;113:10:1758-1764.
- Sambursky R, Trattler W, Tauber S, et al. Sensitivity and Specificity of the AdenoPlus Test for Diagnosing Adenoviral Conjunctivitis. *JAMA Ophthalmol* 2013;131:1:17-22.
- Abelson MB, Ousler GW, Maffei C. Dry eye in 2008. *Curr Opin Ophthalmol* 2009;20:4:282-6.
- Methodologies to diagnose and monitor dry eye disease: Report of the Diagnostic Methodology Subcommittee of the International Dry Eye Work Shop (2007). [No authors listed] *Ocul Surf* 2007;5:2:108-52.
- Ousler GW 3rd, Hagberg KW, Schindelar M, Welch D, Abelson MB. The Ocular Protection Index. *Cornea* 2008;27:5:509-13.
- Walker PM, Lane KJ, Ousler GW 3rd, Abelson MB. Diurnal variation of visual function and the signs and symptoms of dry eye. *Cornea* 2010;29:6:607-12.
- Johnston PR, Rodriguez J, Lane KJ, Ousler G, Abelson MB. The inter-blink interval in normal and dry eye subjects. *Clin Ophthalmol* 2013;7:2:53-9.
- Ibrahim OM, Dogru M, Takano Y, et al. Application of visante optical coherence tomography tear meniscus height measurement in the diagnosis of dry eye disease. *Ophthalmology* 2010;117:1:923-9.
- Villani E, Baudouin C, Efron N, et al. In vivo confocal microscopy of the ocular surface: From bench to bedside. *Curr Eye Res* 2014 in press, pub online Nov 14.
- Bjerrum KB. The ratio of albumin to lactoferrin in tear fluid as a diagnostic tool in primary Sjögren's syndrome. *Acta Ophthalmol Scand* 1997;75:5:507-11.
- Sambursky R, Davitt WF 3rd, Latkany R, et al. Sensitivity and specificity of a point-of-care matrix metalloproteinase 9 immunoassay for diagnosing inflammation related to dry eye. *JAMA Ophthalmol* 2013;131:1:24-8.
- Chotikavanich S, de Paiva CS, Li de Q, et al. Production and activity of matrix metalloproteinase-9 on the ocular surface increase in dysfunctional tear syndrome. *Invest Ophthalmol Vis Sci* 2009;50:7:3203-9.
- Markoulli M, Papas E, Cole N, Holden B. Effect of contact lens wear on the diurnal profile of matrix metalloproteinase 9 in tears. *Optom Vis Sci* 2013;90:5:419-29.
- Honda N, Miyai T, Nejima R, et al. Effect of latanoprost on the expression of matrix metallo-proteinases and tissue inhibitor of metalloproteinase 1 on the ocular surface. *Arch Ophthalmol* 2010;128:4:466-71.
- Versura P, Profazio V, Campos EC. Performance of tear osmolarity compared to previous diagnostic tests for dry eye diseases. *Curr Eye Res* 2010;35:7:553-64.
- Lemp MA, Bron AJ, Baudouin C, et al. Tear osmolarity in the diagnosis and management of dry eye disease. *Am J Ophthalmol* 2011;151:5:792-798.e1.
- [http://www.accessdata.fda.gov/cdrh\\_docs/pdf8/k083184.pdf-69k-2009-07-02](http://www.accessdata.fda.gov/cdrh_docs/pdf8/k083184.pdf-69k-2009-07-02). Accessed 23 December 2013.
- Amparo F, Jin Y, Hamrah F, Schaumberg DA, Dana R. What is the value of incorporating tear osmolarity measurement in assessing patient response to therapy in dry eye disease? *Am J Ophthalmol* 2014; 157:1:69-77.
- PePOSE JS, Sullivan BD, Foulks GN, and Lemp MA. The value of tear osmolarity as a metric in evaluating the response to dry eye therapy in the clinic and in clinical trials. *Am J Ophthalmol* 2014;157:1:4-6.e1.

# OPHTHALMOLOGY 2014 UPDATE

**SAVE THE DATE**  
February 15-16



An interdisciplinary faculty of ophthalmic sub-specialties will review the continuing progress in: Cataract and Refractive Surgery, Glaucoma, Retina, Neuro-Ophthalmology, Oculoplastics, Ocular Surface Disease, Cornea and Oncology.

## Program Chairs:

Don O. Kikkawa, MD  
Robert N. Weinreb, MD

## Location

### Hilton La Jolla Torrey Pines

10950 North Torrey Pines Rd.  
La Jolla, CA 92037  
Phone: 858-558-1500

## Program Times

Saturday, February 15, 2014  
7:30am-4:30pm

*Reception to follow*

Sunday, February 16, 2014  
7:30am-12:00pm

## Program Chairs:

Don O. Kikkawa, MD  
Robert N. Weinreb, MD

## Keynote Faculty

Gholam Peyman, MD

## Featured Faculty

Malik Kahook, MD  
Eytan Blumenthal, MD  
Sameh Mosaed, MD  
Sonia Yoo, MD

## Invited Faculty

Ray Gariano, MD, PhD  
Francis Mah, MD  
Tommy Korn, MD, FACS  
Baruch Kupperman, MD, PhD

## UCSD Faculty

Natalie Afshari, MD, FACS  
William Freeman, MD  
Michael Goldbaum, MD  
Jeffrey Goldberg, MD, PhD  
Weldon Haw, MD  
Christopher Heichel, MD  
Bobby Korn, MD, PhD  
Jeffrey E. Lee, MD  
Jonathan Lin, MD, PhD  
Felipe Medeiros, MD, PhD  
Shira Robbins, MD  
Peter Savino, MD  
Linda Zangwill, PhD  
Kang Zhang, MD, PhD

## 3 WAYS TO REGISTER

Online: [www.revophth.com/Update2014](http://www.revophth.com/Update2014)

Email: [ReviewMeetings@jobson.com](mailto:ReviewMeetings@jobson.com)

Call: Lois DiDomenico 800-999-0975

This activity is approved for AMA PRA Category 1 Credit(s)™

Jointly Sponsored by

**REVIEW**  
of Ophthalmology **IAHB**



**UC San Diego**  
SHILEY EYE CENTER

Jointly Supported by Independent Educational Grants from





# NTG: The Nocturnal Blood Pressure Factor

Evidence indicates that large dips in blood pressure at night correlate with progression in normal-tension glaucoma patients.

*Carlos G. De Moraes, MD, New York City*

**O**ne of the many challenging forms that glaucoma may take is so-called normal-tension glaucoma, in which elevated intraocular pressure appears to play a less-meaningful part in the equation; these patients have IOP measurements within the statistically normal range. Recently, our group pursued a hypothesis regarding the possible connection between this type of glaucoma and blood pressure abnormalities, leading to the discovery of some previously undocumented, clinically useful associations.

Here, I'd like to share some of what we've learned so far, and ways in which this may help you care for your normal-tension glaucoma patients.

## Systemic Hypertension

Our group became interested in conducting a study after a discussion with a group of internists at Cornell University, led by Mary E. Charlson, MD, William Foley Professor of Medicine and chief of general internal medicine. Dr. Charlson is a renowned clinical epidemiologist who has been studying what happens when patients

are treated for systemic hypertension. The literature indicates that the definition of high blood pressure has been slowly changing, lowering the cutoff for what is considered elevated pressure, with the result that patients are sometimes being treated too aggressively. Dr. Charlson's work is showing that this can have deleterious effects on other organs. For example, patients with very low blood pressure are more likely to have kidney failure, heart problems and even strokes.

Given the fact that glaucoma is a progressive disease with a component of vascular abnormality—especially normal-tension glaucoma—we decided to investigate the possible correlation between glaucoma progression and very low arterial blood pressure, particularly when it occurs during sleep, and in some instances could be due to excessive treatment of systemic hypertension.

Of course, we're not the first to examine such a connection. However, most recent research on blood pressure and glaucoma has had a different focus than ours. For example, the Early Manifest Glaucoma Trial found a relationship between blood

pressure and progression, and some other epidemiologic studies such as the Barbados Eye Study have also suggested this association. However, these studies either relied on a single blood pressure measurement or just checked the pressure during the day, or for 24 hours at most. We know that like IOP, blood pressure varies a lot during the day and from one day to the next. So, we decided to monitor our subjects' blood pressure every half hour for 48 hours—on three different occasions.

In addition, there's been no consensus regarding what constitutes low blood pressure, or what parameter should be evaluated to determine whether a patient is at risk or not. So, we not only tested the hypothesis that low blood pressure is associated with progression, we also proposed a method to measure that.

## Designing the Study

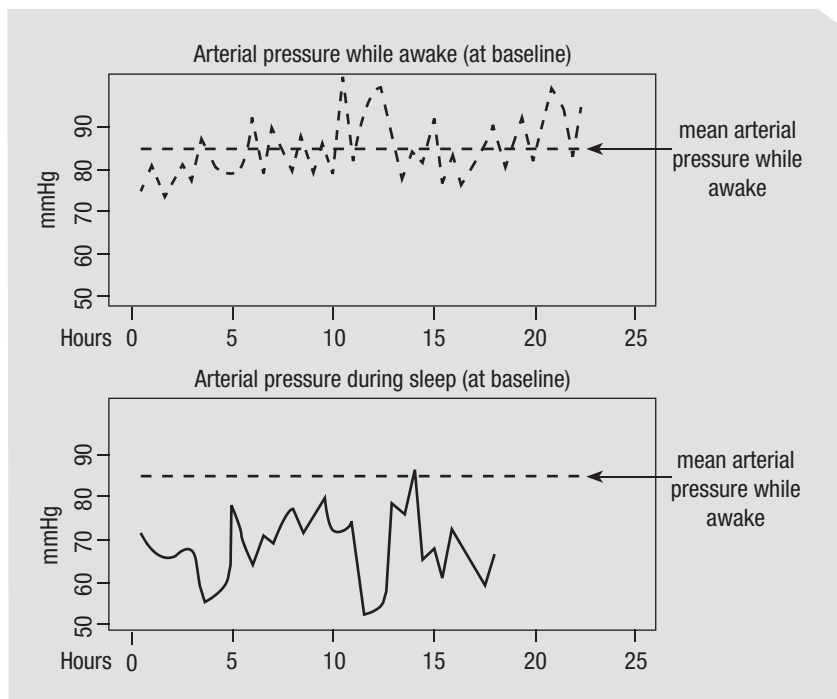
Our hypothesis was that nocturnal pressure dips could be an additional risk factor for progression, particularly in patients with normal-tension glaucoma, who are known to have a strong

IOP-independent component to their disease. The reason that pressure dips are especially dangerous is the phenomenon of autoregulation, which is our bodies' way of maintaining adequate perfusion in key organs such as the brain and the heart when blood pressure drops. The body narrows the peripheral blood vessels, causing vasoconstriction, reducing the blood flow to less critical organs—including the eye. Of course, the optic nerve is in a watershed zone in terms of circulation, so any decrease in blood flow to the eye can potentially damage the optic nerve. Thus, when blood pressure drops below a key level, the body's autoregulation kicks in; if the insult persists, we see problems such as hypoperfusion, ischemia and nerve damage.

This problem is exacerbated at night, because blood pressure is normally lower then. Meanwhile, IOP tends to go up at night. Early in the morning, just before you wake up, is when your IOP is normally the highest—at the same time your blood pressure is usually the lowest, causing an imbalance in the blood supply to your eye. Healthy people are able to compensate for this so that it doesn't cause any damage. But in glaucoma or systemic hypertension, we believe this ability is compromised.

To test whether there is a real association between nocturnal pressure dips and progression, we decided to prospectively monitor patients' nocturnal blood pressure and see whether those dips correlated with glaucoma progression during the trial period. For our study we selected patients from our office who had normal-tension glaucoma, defined as having all of their untreated IOP measurements below 21 mmHg. They also met criteria such as having at least five visual fields prior to enrollment. Overall, 32 percent of the subjects had been diagnosed with systemic hypertension prior to

## Mean Arterial Blood Pressure in an NTG Patient



In this study of normal-tension glaucoma patients, the data revealed a significant correlation between progression and both the length of time that mean nocturnal blood pressure dropped below the mean diurnal pressure, and the magnitude of the drop.

enrollment and 77 percent of that group were on medications to reduce their blood pressure.

The device we used to measure blood pressure over a 48-hour period was placed on the arm at the same location at which you would normally measure blood pressure; every 30 minutes it automatically inflated and recorded the blood pressure. The device is very noninvasive and reasonably comfortable; I don't recall any patient ever complaining about wearing it for the 48 hours. (In contrast, checking IOP over a 24-hour period requires waking the patient at intervals through the night, which is not only irritating and disruptive but may also affect the legitimacy of the measurements.) This is one of several such devices that are commercially available, and it's not very expensive.

After collecting baseline information, including 48-hour blood

pressure monitoring, the patients came back at six months and one year for visual field testing and repeat 48-hour blood pressure monitoring.

### What the Data Showed

At the end of that year we analyzed the data. From each of the 48-hour measurements, we got an average of the mean arterial pressure during the day when the patient was awake. Then we looked at the blood pressure profile when the patient was asleep and calculated how long the nocturnal mean arterial pressure was below the awake/ diurnal mean arterial pressure, and by what amount (*See figure, above*).

Comparing this to the rates of progression seen in the visual fields, we found a significant correlation between progression and both the length of time that mean nocturnal blood

pressure dropped below the mean diurnal pressure, and the magnitude of the drop. For example, if a patient had a pressure below the mean diurnal arterial pressure for five hours during the night, but he was only a few mmHg below that pressure, he could be at less risk of progression than another patient who dropped below the mean diurnal pressure for only two hours but was 30 or 40 mmHg below the diurnal pressure.

One of our analyses looked to see if patients treated for systemic hypertension had a different response than those not being treated. The data showed that for a similar amount of time and magnitude that the nocturnal pressure was below the average diurnal pressure, those being treated for systemic hypertension were more susceptible to progression than those who were not being treated for systemic hypertension. It was clear that people who don't have hypertension also can experience intense dips, but those who were being treated for systemic hypertension were more susceptible to them.

In short, our prospective study demonstrated that very low blood pressure, particularly at night, is a significant predictor of progression in normal-tension glaucoma patients.

Of course, this does leave an important question unanswered: Is this susceptibility the result of the systemic hypertension, or a side effect of the medications being used to treat the systemic hypertension? To answer that question we'll need another study, testing the patients after modifying their medications. But at least we've shown that there's an association between being overtreated for systemic hypertension and being more susceptible to the deleterious effects of nocturnal pressure dips.

### Red Flags for Clinicians

As ophthalmologists we know that

glaucoma with statistically normal pressure has a vascular component. Given the results of our research, we believe that patients with normal-tension glaucoma should be considered for evaluation for nocturnal dips in pressure—and the importance of this testing increases if the patient is being treated for systemic hypertension.

However, there are other red flags besides being treated for hypertension that should possibly trigger such monitoring:

- **Postural hypotension.** If a patient says that he feels faint when standing up too quickly, that's an indication that he has low blood pressure in general (i.e., systemic hypotension) and may have a problem with his autoregulatory mechanisms.

- **Cold hands and feet.** This can indicate insufficient blood flow to the extremities. (If this becomes extreme a person may exhibit Raynaud's phenomenon, in which extremities have an exaggerated response to cold or emotional stress. Fingers and hands can turn pale, even blue, and become cold to the touch; they may eventually become tingly or numb, and may swell and ache.)

- **Migraines.** Patients with migraines were very common in our sample—another symptom suggesting an imbalance in the autoregulatory blood pressure mechanism.

- **Myopia.** Myopia is very common in normal-tension glaucoma patients. At first, many people thought that this association was a data fluke because nearsighted people go to the eye doctor more often, so they were being diagnosed more often. But research, including animal and human research with *in vivo* imaging, suggests that the optic nerve in myopic eyes is more susceptible to damage because the myopic eye is usually longer, stretching the tissues. Of course, most people with myopia will never have a problem with normal-tension

glaucoma, but they are statistically connected. For example, Japan has a higher proportion of myopes than Western countries, and 90 percent of their open-angle glaucomas are normal-tension glaucoma. So if other risk factors such as a genetic predisposition for glaucoma are present, ophthalmologists should scrutinize myopic patients closely.

- **Systemic beta blocker use.** Plenty of literature has shown that systemic beta blockers—especially used alone—may not be the best way to treat systemic hypertension. One reason is that their main effect is to lower the heart rate and decrease the strength at which the heart pumps blood. When your body senses that blood pressure is dropping, it attempts to compensate by (among other things) increasing your heart rate and the strength of the pumping as part of autoregulation. Beta blockers can interfere with that protective mechanism. Other hypertension medications, in contrast, may act on the vessels or arteries to prevent excessively high blood pressure, allowing the heart to protect key organs when pressure drops at night.

### Clinical Management

For screening purposes, ambulatory blood pressure measurements may be performed on patients with normal-tension glaucoma—in particular patients who are progressing despite intensive IOP lowering, for no obvious reason. This will allow you to tell if significant pressure drops are occurring at night. We've used the ambulatory device in our office to monitor patients for several years; you just give it to the patient and he comes back 48 hours later. You connect the device to a computer and it shows all the blood pressure information. A clinician can easily use it.

If a normal-tension glaucoma patient is being treated for systemic



hypertension, I highly recommend that you talk to the patient's internist or cardiologist to explain what's going on and ask whether the treatment might be too aggressive. Does the patient really need such a low pressure? Causing the progression to stop may be just a matter of changing a medication, or having the patient stop taking it at night.

Of course, a few individuals will have this problem at night without having a diagnosis of systemic hypertension. Unfortunately, there are no proven treatments to help in this situation (that we're aware of), although a clinician could try some unproven treatments that might, in theory, be helpful. For example, salt-loading at night or drinking V8 Juice before bed might help to raise low blood pressure a little during sleep-time. We've tried this with moderate success, but again, there's no clinical

evidence to support this approach. It's based on physiology and our best understanding of what's happening. Ultimately, we'll need clinical trials to actually determine whether a given intervention slows or fails to slow glaucoma progression.

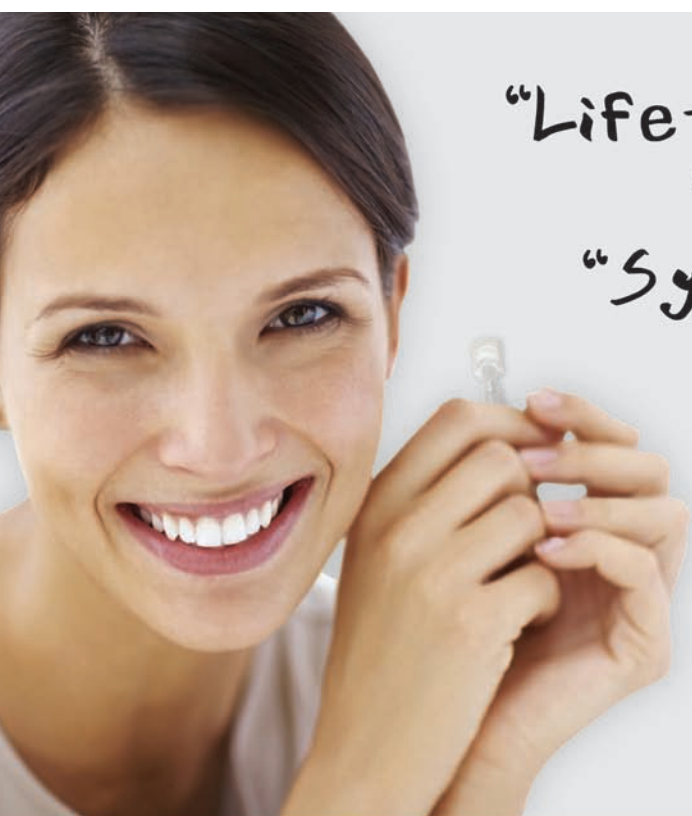### Seeing the Whole Picture

It's important to remember that before being ophthalmologists, we are physicians. We have to look at the patient as a whole. The eye interacts with everything else in the body, and factors such as autoregulation, blood pressure and IOP may be interrelated. Don't forget to consider other ailments the patient may have, and don't hesitate to talk to the patient's internist or cardiologist if blood pressure may be an issue.

The main point I hope clinicians will take from our study is that our

suspicions were confirmed: Hypertension during sleep does predict progressive visual field loss in normal-tension glaucoma. So, if you have patients with normal-tension glaucoma—especially those who keep progressing for no apparent reason—it's very worthwhile to perform ambulatory blood pressure monitoring and see if nocturnal dips are occurring. It's easy and inexpensive to do, and it may not only explain the reason for the disease and the progression, it might also help you know what to do to prevent future progression. [REVIEW](#)

*Dr. De Moraes is an associate professor of ophthalmology at New York University Medical Center, and Edith C. Blum Foundation Research Scientist at the New York Eye and Ear Infirmary. He has no financial ties to any product mentioned.*



“Life-Changing”  
“Dramatically Helped”  
“Symptoms Gone”

Just some of the testimonials for Retaine® MGD™, the only preservative-free artificial tear that utilizes electrostatic attraction to prolong corneal contact time and provide long-lasting relief of Dry Eye.

Retaine® MGD™ is like no other artificial tear. Do more...for your patients, for your practice.

**ORDER NOW**



To order, call OCuSOFT® at (800) 233-5469 or visit [www.ocusoft.com](http://www.ocusoft.com).

Sold Through Eye Care Professionals Only

OCuSOFT®  
© 2014 OCuSOFT, Inc., Rosenberg, TX 77471 USA



# New Ways to Detect Keratoconus

Looking at corneal imaging data in different ways can enhance your ability to avoid risky refractive surgery cases.

*Walter Bethke, Managing Editor*

**B**eing able to identify patients with irregular corneas is crucial to cornea specialists in general and refractive surgeons in particular, since the latter need to avoid removing tissue in corneas that are already weak. To this end, researchers and clinicians are always devising new ways to detect irregularities as early as possible. Here, physicians with a particular interest in keratoconus detection share the new methods they've developed to identify potentially troublesome eyes.

## BFTA vs. BFS

Bordeaux, France, ophthalmologist David Smadja and his research co-workers say that when they focused on the asymmetry of the cornea's posterior surface, they were able to achieve excellent sensitivity when screening patients for keratoconus. Dr. Smadja, who used the Ziemer Galilei dual Scheimpflug system, says the key is studying a parameter known as the Best-fit Toric and Aspheric surface, or BFTA, which seems to be a better option than the Best-fit Sphere, or BFS. "The BFTA has a better ability for screening out the asymmetry of

the cornea that is measured because it fits closer to the natural corneal shape by canceling out its means asphericity and toricity," explains Dr. Smadja. "What is nice about the BFTA is that comparing a cornea to it is almost like comparing the cornea to its perfect clone. Therefore, anything that will deviate from the reference surface will be a sign of irregularity or asymmetry. This method is important because when you're tracking the initial signs of asymmetry, if you don't want to have the initial bulging hidden by the effect of another fitting method—such as with the spherical reference surface, the BFS—it's important to be as close as possible to the cornea being measured.

"Comparing it to the BFS, it's not a matter of one being better or one being bad," Dr. Smadja continues. "Some people are used to seeing and interpreting BFS analyses and sometimes it's a matter of subjective interpretation of elevation patterns. So if you're used to using the BFS, it can help screen out suspect corneas—but more often with the BFS, the elevation maps can hide crucial early signs of asymmetry in the cornea. In

our study, when we compared the BFTA to the BFS to screen out the initial stage of keratoconus, we found the performance of the BFTA to be much higher than the performance of the BFS in terms of discriminating between normal and forme fruste keratoconus.<sup>1</sup> Specifically, when looking at the maximum posterior elevation, BFTA yielded a sensitivity of 82 percent and a specificity of 80 percent, compared to 51 percent and 55 percent, respectively, for the BFS. This sensitivity of 82 percent with the BFTA was then improved to nearly 90 percent when looking at the AAI [Asphericity Asymmetry Index], which quantifies the asymmetry of elevation at the back surface by using the absolute value of the max positive and max negative elevation within the 6-mm central zone. The AAI has a cutoff value of 21.5."

Though the relative importance of the anterior vs. posterior cornea for screening out forme fruste keratoconus patients has been debated for a while, Dr. Smadja thinks the evidence is shifting toward the posterior. "It's not a matter of the disease starting on the back or the front of the cornea,"

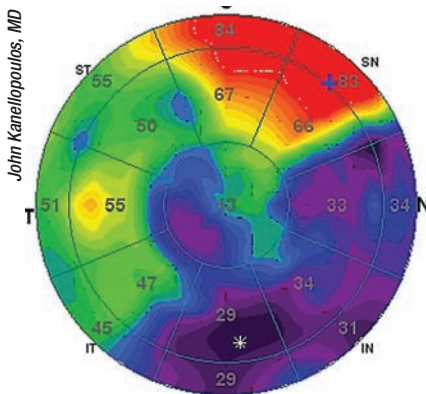
he says. “Instead, it’s more that sometimes the epithelial layer can smooth out the front surface. This smoothing can hide the first sign of asymmetry in the underlying stroma, and it’s been shown many times that the epithelial layer is thinner above a bulging of the cornea, whereas it’s thicker above a depression of the underlying stroma. So, you can’t see the stromal irregularity because what you’re imaging from the front is the epithelial layer and the epithelium has a large impact on the topographic image. So, looking at the back surface rather than the front is more sensitive for screening out the first signs of bulging.”

For surgeons who want to use some of Dr. Smadja’s findings in their practices, he has some advice. “It’s tough to give a number that would be a red flag with all the various devices, because we haven’t tested this approach with all of them,” he says. “However, what should alert the surgeon when interpreting posterior elevation maps with either the Aconic surface (Orbscan) or the Best-fit Toric Ellipsoid (BFTE) in the Pentacam, which work in a way similar to the BFTA in the Galilei, is any kind of asymmetric posterior elevation. Concerning the Galilei Analyzer specifically, the AAI was found to be the most sensitive for screening the suspicious cornea. Any AAI value above 21.5 should make you consider doing PRK rather than LASIK.”

## Epithelial Analysis

Focusing on a different parameter of the cornea, researchers in Greece have found that using anterior segment optical coherence tomography to image the epithelium showed marked differences between keratoconic and normal eyes.

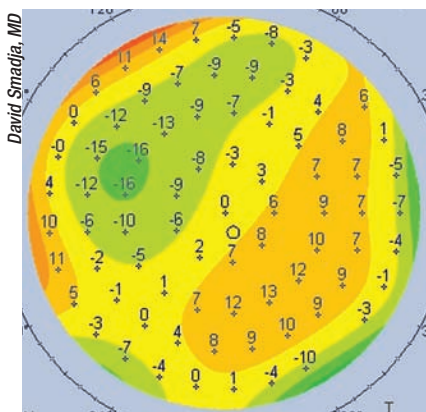
In a study presented at the 2013 meeting of the American Academy of Ophthalmology, George Chatzilaou, MD, presented results from 55 untreated keratoconus patients and 55



Researchers have found that patients with keratoconus appear to have an overall increase in epithelial thickness.

controls. The mean overall epithelial thickness was  $55.65 \pm 1.22 \mu\text{m}$  in the keratoconus patients and  $51.97 \pm 0.7 \mu\text{m}$  in the controls. The variability in topographic mapping was  $\pm 9.8 \pm 0.41 \mu\text{m}$  in keratoconus eyes and  $\pm 1.53 \pm 0.21 \mu\text{m}$  in normals. All the differences were statistically significant ( $p < 0.002$ ). The researchers say that these patients seemed to have an overall epithelial thickness increase.

Athens surgeon John Kanellopoulos was a researcher on the study and says it yielded some insights on irregular corneas. “We all know that in keratoconus the cornea epithelium remodels



A cornea can prove to be dangerously asymmetric when its posterior aspect is viewed using the Best-fit Toric and Aspheric surface parameter. This cornea has a max posterior elevation of  $13 \mu\text{m}$ .

and it thins over the area of the cone and thickens over the area adjacent to the cone in order to ‘mask’ these curvature differences and potentially improve the visual function of the cornea,” he says. “So the first thing that we look at in these spectral domain anterior segment OCT images is: Where is the thinnest location placed by the device in regard to the cornea center? When the thinnest part of the cornea is away from the cornea center, our index of suspicion for keratoconus increases, as this indicates an eccentric thinner part of the cornea, which invariably is due to keratoconus or ectasia.

“Now, what we have reported in the past with high-frequency ultrasound,” Dr. Kanellopoulos adds, “and we confirmed with our studies with a spectral domain anterior segment OCT, is that is there a very large difference in different areas and in different aspects of the cornea as far as the thickness—so increased variability of the cornea epithelial thickness can be related to keratoconus. In addition, we’ve found that, overall, the epithelial thickness is increased in keratoconic or pre-keratoconic eyes, as well. So just looking at the average corneal epithelial thickness can be a very helpful tool in picking up early keratoconus, because advanced keratoconus is obviously much easier to diagnose from the extreme irregularities of the epithelial distribution in the cornea.”

Whichever method a surgeon uses, Dr. Smadja notes that more information is always better. “It’s important to remember that in our work, we’re still just talking about one parameter,” he says. “The sensitivity achieved by one parameter is never good enough to base your conclusion on. I think that it’s best to consider different parameters when considering a change to the patient’s surgical options.” **REVIEW**

1. Smadja D, Santhiago MR, Mello GR, et al. Influence of the reference surface shape for discriminating between normal corneas, subclinical keratoconus, and keratoconus. *J Refract Surg* 2013;29(4):274-281.

# Adverse Effects of BAK On Surgical Outcomes

**A study from** University of Toronto researchers extends earlier findings of potential adverse effects of ophthalmic preservatives on surgical outcomes, showing that increased preoperative exposure to ophthalmic solutions preserved with benzalkonium chloride is a risk for earlier trabeculectomy failure, independent of the number of medications used.

A retrospective chart review selected 128 patients who had undergone a trabeculectomy between 2004 and 2006. The number and type of ophthalmic drops used preoperatively and relevant demographics were recorded. Surgical failure criteria included inadequate pressure lowering or need for postoperative ocular antihypertensives, laser trabeculoplasty, 5-fluorouracil needling or repeated surgery. Patients were examined for these criteria over a minimum postoperative period of two years. Data were assessed using Kaplan-Meier and Cox regression models.

Complete surgical success was achieved in 47.7 percent of the patients. Patients received between one and eight BAK-containing drops daily, with a median of three. Time to surgical failure in patients receiving higher preoperative daily doses of BAK was shorter than in patients who had less BAK exposure ( $p=0.008$ ). Proportional hazard modeling identified uveitic and neovascular glau-

coma as significant confounders of the univariate model ( $p=0.024$ ), although the main effect of BAK exposure was maintained, with a hazard ratio of 1.21 ( $p=0.032$ ). The number of different medications used to control intraocular pressure did not significantly affect survival time in a secondary Cox model ( $p=0.948$ ).

*J Glaucoma* 2013;22:730-735.  
Boimer C, Birt C.

## Endophthalmitis Associated With Intravitreal Injections

**A retrospective review** of patients who underwent intravitreal injections in two different settings, office-based and operating room, between January 2009 and December 2011 indicates that the rate of clinically suspected endophthalmitis after intravitreal injection is low whether the procedure is performed in the office or operating room setting.

A total of 11,710 intravitreal injections were performed by two physicians during the study period. Group A ( $n=8,647$ ) underwent intravitreal injection in the examination room in an office-based setting. The intravitreal injections performed included ranibizumab ( $n=2,041$ ), bevacizumab ( $n=6,169$ ) and triamcinolone acetate ( $n=437$ ). Diagnoses included neovascular age-related macular degeneration ( $n=5,376$ ), diabetic macular edema ( $n=1,587$ ), retinal vein occlu-

sion ( $n=1,068$ ) and miscellaneous diagnosis ( $n=616$ ). Group B ( $n=3,063$ ) underwent intravitreal injection in the operating room. There were 683 ranibizumab injections, 2,364 bevacizumab injections and 16 triamcinolone injections. Diagnoses included neovascular AMD ( $n=1,936$ ), DME ( $n=771$ ), RVO ( $n=189$ ) and miscellaneous ( $n=267$ ). There were five cases (0.043 percent) of clinically suspected endophthalmitis in the 11,710 injections. Three cases (0.035 percent) occurred in Group A and two cases (0.065 percent) occurred in group B.

*Retina* 2014;34:18-23.  
Tabandeh H, Boscia F, Sborgia A, Ciraci L, et al.

## Differences in Iris Thickness Among Ethnic Groups

**California researchers evaluating** the capability of iris thickness parameters to explain the difference in primary angle-closure glaucoma among different ethnic groups suggest that groups with historically higher prevalence of PACG (Chinese Americans) possess thicker irides than other measured groups.

In this prospective study, 259 patients with open angles and 177 patients with narrow angles from five different ethnicities (African American, Caucasian American, Hispanic American, Chinese American and Filipino American) that met the inclusion criteria were consecutively re-

cruited from the University of California, San Francisco, general ophthalmology and glaucoma clinics to receive anterior segment optical coherence tomography imaging under standardized dark conditions. Images from 11 patients were removed due to poor visibility of the scleral spurs, and the remaining images were analyzed using the Zhongshan Angle Assessment Program to assess the following measurements for the nasal and temporal angle of the anterior chamber: iris thickness at 750 and 2,000  $\mu\text{m}$  from the scleral spurs and the maximum iris thickness at the middle one-third of the iris.

In comparing iris parameters among the open-angle ethnic groups, significant differences were found for nasal iris thickness at 750 and 2,000  $\mu\text{m}$  from the scleral spurs in which Chinese Americans displayed the highest mean value ( $p=0.01$ ;  $p<0.0001$ ). Among the narrow-angle ethnic groups, significant difference was found for nasal iris thickness at 2,000  $\mu\text{m}$  from the scleral spurs, in which Chinese Americans showed the highest mean value ( $p<0.0001$ ). A significant difference was also found for temporal maximum iris thickness at the middle one-third of the iris, with African Americans exhibiting the highest mean value ( $p=0.021$ ). Iris thickness was modeled as a function of angle status using linear mixed-effects regression, adjusting for age, sex, pupil diameter, spherical equivalent, ethnicity and the use of both eyes in patients. The iris thickness difference between the narrow-angle and open-angle groups was significant ( $p=0.0007$ ).

*J Glaucoma* 2013;22:673-678.

Lee R, Huang G, Porco T, Chen Y, et al.

## Femtosecond Laser-Assisted Cataract Surgery Has a Learning Curve, But is Safe and Efficient

**R**esearchers from the department of ophthalmology at Semmelweis University analyzed the intraoperative complications of the first 100 femtosecond laser-assisted cataract surgeries, as well as possible complications of femtosecond capsulotomies. The researchers determined that while there is a learning curve, with cautious surgical technique these complications can be avoided, and the femtosecond laser-assisted method is safe and efficient for cataract surgery.

A retrospective analysis discovered the following complications: suction break (2 percent); conjunctival redness or hemorrhage (34 percent); capsule tags and bridges (20 percent); anterior tear (4 percent); miosis (32 percent); and endothelial damage due to a cut within the endothelial layer (3 percent). There were no cases of capsule blockage or posterior capsule tear. During the learning curve, there were no complications that would require vitrectomy.

*J Cataract Refract Surg* 2014;40:20-28.

Nagy Z, Takacs A, Filkorn T, Kránitz K, et al.

(continued from p. 40)

theoretically, and we are in the process of getting more data to show that.”

“Because we are going through the [FDA] approval process, we will ultimately have data that will show whether there is a difference between regular LASIK and LASIK Xtra.”

—John Kanellopoulos, MD

According to Dr. Kanellopoulos, another downside is the possibility of infection, which can result from contaminated riboflavin solution or over cross-linking. “This is the reason we use single-use containers for riboflavin and use a strictly sterile environment in a similar fashion as we do with a routine LASIK procedure,” he says. “High-fluence cross-linking is used to avoid extensive time under the UV source and a possibility for inadvertent contamination from the operating room or the health-care staff.”

Dr. Kanellopoulos notes that there is no significant learning curve when combining the two procedures. “The basic principle is to soak the underlying stroma after the end of the ablation with riboflavin, and we have chosen the one that is diluted in saline,” he says. “It is important to avoid having the riboflavin come into contact with the flap. This is why, when I pull the flap off the cornea following the femtosecond laser flap creation, I try to fold it onto itself, thus reducing its dehydration and secondarily protecting it from any riboflavin spilled over from its instillation at the end of the ablation. The soaking takes 60 seconds, and following that, the flap is repositioned in place, and the interface is rinsed copiously in order to remove any residual riboflavin and to minimize the amount of riboflavin that jumps into the flap. After repositioning the flap, I use a Johnston applanator to iron out the central part of the cornea. I use BSS to lubricate the surface. At the end of the case, I place a bandage contact lens, which I remove the next morning.” **REVIEW**

1. Kanellopoulos AJ, Asimellis G. Comparative epithelial topography and thickness changes following femtosecond-assisted high myopic LASIK with versus without prophylactic higher-fluence collagen cross-linking. *Cornea* 2014 (accepted for publication).

2. Kanellopoulos AJ, Kahn J. Topography-guided hyperopic LASIK with and without high irradiance collagen cross-linking: Initial comparative clinical findings in a contralateral eye study of 34 consecutive patients. *J Refract Surg* 2012;28(11 Suppl):S837-S840.

# RPS Office Dry-Eye Test Cleared by FDA

**R**apid Pathogen Screening announced that the Food and Drug Administration has cleared InflammDry, a rapid, disposable, in-office test to aid in the diagnosis of dry-eye disease, for sale in the United States.

InflammDry is the only rapid, in-office test to detect matrix metalloproteinase 9, a clinically relevant inflammatory marker that is consistently elevated in the tears of patients with dry-eye disease, the company says. The test plays an essential role in accurately diagnosing dry-eye disease, as clinical signs of the condition resemble other eye ailments and are not always directly related to patient complaints.

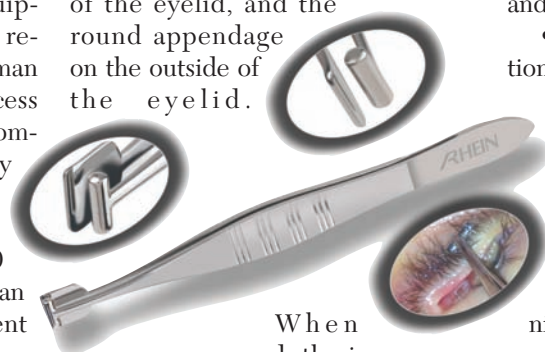
InflammDry is a single-use test that requires no additional equipment to administer or interpret results. Using a small sample of human tears, the simple, four-step process takes less than two minutes to complete and can be performed by a technician during a patient's initial workup. Results are available for the clinician in just 10 minutes, allowing a treatment plan to be established with the patient during her initial office visit.

The 510(k) clearance allows the InflammDry test to be used in physician offices that are certified to perform moderately complex tests under the Centers for Medicare & Medicaid Services' Clinical Laboratory Improvement Amendments.

The InflammDry test will also be submitted to FDA for CLIA waiver review. If granted, a waived status would allow the test to be used in any CLIA-waived physician office. For more information, visit [InflammDry.com](http://InflammDry.com) or call (941) 556-1850.

## New Rhein Compression Forceps

**R**hein Medical has introduced the Batlle Eyelid Compression Forceps (Product #08-01718), developed in coordination with Juan F. Batlle, MD. The instrument is designed with a mirror polished paddle on one side, and a mirror polished round appendage on the other side. The paddle is inserted into the inside of the eyelid, and the round appendage on the outside of the eyelid.



When compressed, the instrument forces meibum to be expressed out of the glands. The instrument is guaranteed for life, made in the United States, autoclavable and available for a surgical evaluation without obligation. For information, contact Rhein Medical at (727) 209-2244.

## CareCredit Mobile Account Management for Smartphones

**C**areCredit has launched an optimized mobile site designed to provide a secure, user-friendly experience for smartphone users.

The enhanced site allows patients to conduct a variety of mobile account-management functions, including:

- accessing account summary with a single user name and password;
- making payments and viewing payment history;
- enrolling in and viewing e-statements;
- viewing transaction history;
- updating personal information; and
- adding/changing bank information.

With more than 1 million unique visitors each month to [carecredit.com](http://carecredit.com) and more than 560,000 monthly searches on CareCredit's online Provider Locator, the optimized mobile site provides another way for people to conveniently access the information they need about CareCredit when they need it. The enhanced site works on all major mobile operating systems, including iOS, Android, BlackBerry and Windows. Users can access the optimized mobile service by visiting [gogecapital.com/carecredit](http://gogecapital.com/carecredit) from their smartphone. **REVIEW**



800.735.0357  
haag-streit-usa.com

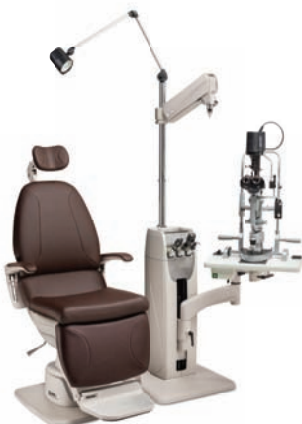# LEGENDARY IS MATERIALISTIC



14-ply birch. Forged iron. Tough, hand-sewn upholstery. These are the materials of a legend. Built into our ultra-durable exam chairs and stands to make them last for decades. And they're virtually maintenance free.

Call us materialistic. We're okay with that. Because it's what makes Reliance Medical Products Britishly Durable Since 1898.

Find your legendary exam chair and instrument stand at [reliance-medical.com](http://reliance-medical.com), or call 800.735.0357.



The Superior Practice.

© 2013 Reliance Medical Products. All Rights Reserved.

 **RELIANCE**  
INTERNATIONAL

Merchandise Offered /Equipment and Supplies

**EYE|DESIGNS**  
CUSTOM INTERIORS + FURNITURE

**PROFIT BY DESIGN**

- \_\_\_SPACE PLANNING
- \_\_\_INTERIOR DESIGN
- \_\_\_DISPLAY INNOVATION
- \_\_\_MANUFACTURING

VISIT [WWW.EYEDESIGNS.COM](http://WWW.EYEDESIGNS.COM) OR CALL 800.346.8890





[opticaldisplays.com](http://opticaldisplays.com)



**mosaic**

Mosaic is a unique combination of low profile panels visually creating different levels to incorporate the best of Synergy Pro™ and FLOT™ merchandising technologies. Plus, it has the ability to be illuminated with LED lighting. Includes signage header and mounting hardware.

**MOSAIC FLOT WALL**

- + 1 Complete Unit, FLOT Systems
- + 3 Rows of FLOT Plugs
- + 14 21" FLOT Triple Shelves OD216
- + 1 Signage Panel
- + Mounting Hardware

FLOT Shelves can be illuminated

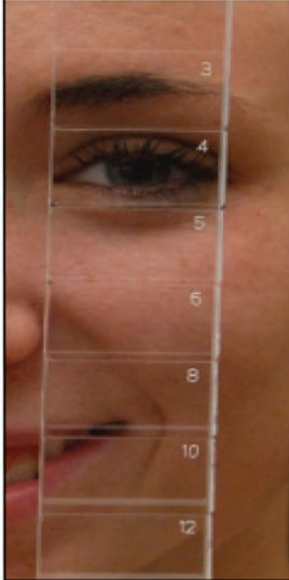
**NEW! EZ View Prism Bars™**

*The best enhancement to prism bars since we invented them in 1938!*

- When moving the position of the prism magnitude, the examiner can easily see the numbers without turning the prism bar sideways or changing position.
- A great advantage since turning prism bars during the assessment of vergence amplitudes could interfere with the accuracy of the measurement.
- This new prism bar design allows clinicians to concentrate on the important aspects of the examination and easily view the results.
- EZ View™ is particularly advantageous for less experienced examiners

Web search "Prism Bars" - Also visit for extensive product offerings

**GuldenOphthalmics**  
time saving tools  
800-659-2250 [www.guldenophthalmics.com](http://www.guldenophthalmics.com)





**FLORIDA EYE EQUIPMENT**

**PRE-OWNED OPTHALMIC EQUIPMENT**

Buying and Selling Pre-Owned Ophthalmic Instrumentation.

Contact Jody Myers at  
**(800) 336-0410**  
[EyesinFL@aol.com](mailto:EyesinFL@aol.com)

To view current inventory,  
Visit [www.floridaeye.com](http://www.floridaeye.com)  
**FLORIDA EYE EQUIPMENT**  
Since 1989

**REVIEW**  
of Ophthalmology

Targeting Ophthalmologists?

**CLASSIFIED ADVERTISING WORKS**

Contact us today for classified advertising:  
Toll free: **888-498-1460**  
E-mail: [sales@kerhgroup.com](mailto:sales@kerhgroup.com)



Equipment and Supplies

Optical Space Planning & Design





1-877-274-9300




Interior Design by *Barbara Wright design*

# OPTIQUAT™


by *Frame Displays.com*



## Modular Versatile Resourceful



- 1 Eyewear Support
- 2 Mirror
- 3 Case Support
- 4 Decorative Vase
- 5 Logo Plate
- 6 Shelf



### MODULAR OPTICAL DISPLAY PANELS

For more information please call  
1-877-274-9300

# REVIEW®

of Ophthalmology

Do you have Products and Services for sale?

**CLASSIFIED ADVERTISING WORKS**

- JOB OPENINGS
- CME PROGRAMS
- PRODUCTS
- AND MORE...

Contact us today for classified advertising:  
Toll free: **888-498-1460**  
E-mail: [sales@kerhgroup.com](mailto:sales@kerhgroup.com)



## Products and Services

### P.M. MEDICAL BILLING AND CONSULTING

**SPECIALIZING IN OPHTHALMOLOGY BILLING & CONSULTING**

- National, full service billing to ophthalmologists
- Maximum reimbursement is guaranteed
- Staff consists of Ophthalmic techs, expert coders & billers
- Increased revenue/low denial rate/complete & unrelenting follow up

**We specialize in old, outstanding AR, Practice Management & Credentialing**

Contact us at:  
[pmmedbill@aol.com](mailto:pmmedbill@aol.com)  
or call us toll-free at:  
**1-888-PM-BILLING**  
for a free in-office consultation  
[WWW.PMOPHTHALMOLOGYBILLING.COM](http://WWW.PMOPHTHALMOLOGYBILLING.COM)

## Practice For Sale



Practice Sales • Appraisals • Consulting  
[www.PracticeConsultants.com](http://www.PracticeConsultants.com)

### PRACTICES FOR SALE NATIONWIDE

Visit us on the Web or call us to learn more about our company and the practices we have available.

[info@practiceconsultants.com](mailto:info@practiceconsultants.com)  
**800-576-6935**

[www.practiceconsultants.com](http://www.practiceconsultants.com)

For classified advertising  
call **1-888-498-1460**  
or e-mail us at [sales@kerhgroup.com](mailto:sales@kerhgroup.com)



## Ophthalmology Opportunity

**Geisinger Health System (GHS) is seeking a BC/BE Cornea/Refractive Surgery Ophthalmologist for Geisinger–Scenery Park, State College, Pa.**

### About the Position

- Opportunity to start up a new practice and develop new programs
- Work with a surgical retina physician and a local optometry practice
- Enjoy a strong referral base from Geisinger's community practice sites
- Candidate should possess exceptional surgical skills and a dedication to patient care

**Geisinger Health System** serves more than 3 million people in central and northeastern Pennsylvania and is nationally recognized for innovative practices and quality care. A mature electronic health record connects a comprehensive network of 5 hospitals, 43 community practice sites and more than 900 Geisinger primary and specialty care physicians.

Discover for yourself why Geisinger is nationally recognized as a visionary model of integrated healthcare.

For more information, please visit [geisinger.org/careers](http://geisinger.org/careers) or contact: **Autum Ellis, Department of Professional Staffing, at 1-800-845-7112 or [amellis1@geisinger.edu](mailto:amellis1@geisinger.edu).**

**GEISINGER**  
HEALTH SYSTEM

Follow us:  | 

**REVIEW**  
of Ophthalmology

## Targeting Ophthalmologists?

### CLASSIFIED ADVERTISING WORKS

- JOB OPENINGS
- CME PROGRAMS
- PRODUCTS & SERVICES
- AND MORE...

Contact us today for classified advertising:

Toll free: **888-498-1460**

E-mail: [sales@kerhgroup.com](mailto:sales@kerhgroup.com)

**kerh**  
group



Failure to adhere to a prescribed drug treatment has dire consequences for a young boy referred to the Wills ER.

*Michael N. Cohen, MD, Sonia Mehta, MD, Eunice M. Kohara, DO, Christina M. Ohnsman, MD, Alex V. Levin, MD, MHSc*

## Presentation

An 11-year-old boy presented to the Wills Eye Hospital Emergency Room, referred from an outside hospital, with photophobia, redness and decreased vision in his left eye for three days. He had only mild eye pain. Two CT scans of the brain and orbits done in the days prior to referral were normal. The patient and family denied any ocular trauma, recent travel or disease contacts. The patient had vague, non-specific left leg pain without a limp. Review of systems was otherwise negative.

## Medical History

Past medical, surgical, ocular, family and social history were all non-contributory. He was on no systemic medications, and his immunizations were up to date.

## Examination

Ocular examination revealed a visual acuity of 20/20 in the right eye and light perception in the left eye. The left pupil was slightly irregular and nonreactive with an afferent pupillary defect. Goldmann applanation tonometry was 10 and 11 mmHg. Extraocular movements were full in both eyes, and there was no pain with movement. Confrontation field testing was full in the right eye and limited by the poor visual acuity in the left eye. External examination was significant only for mild lid edema and erythema of the left eye. Slit-lamp examination of the right eye was unremarkable. The left eye had moderate conjunctival injection without chemosis, minimal corneal stromal haze, moderate anterior chamber cell and a disc of fibrin in the anterior chamber overlying the pupil. The lens was clear. Dilated fundus examination of the right eye was normal. There was no view of the left eye due to white retrolental material. B-Scan ultrasound (*See Figure 1*) showed intense cellular debris in the vitreous, thickening of the choroid and thin vitreous membranes.

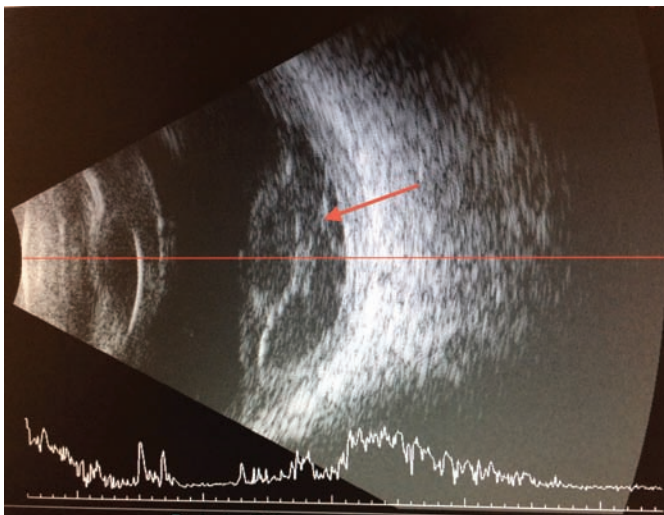


Figure 1. B-scan ultrasound of the left eye. Note the intense cellular debris, thin vitreous membranes and thickening of the choroid.

***What is your differential diagnosis? What further workup would you pursue? Please turn to p. 68***

## Diagnosis, Workup and Treatment

Differential diagnosis included inflammatory, infectious, neoplastic and traumatic causes. Brain and orbit MRI demonstrated left-sided reticulation of retrobulbar fat with enhancement of the pre-septal tissues, sclera and choroid. There was also mild enlargement with enhancement of the left lacrimal gland. The brain was normal. The patient had an elevated erythrocyte sedimentation rate (70) and C-reactive protein (3.3). Additional laboratory testing was un-

remarkable and included CBC; blood cultures; HLA B27; ACE; lysozyme; *Toxoplasma* antibodies; *Toxocara* antibodies; HSV antibodies; VZV antibodies; RPR, RF; FTA-Abs; cANCA; pANCA; chest radiograph; and urinalysis.

He was admitted with a working diagnosis of panuveitis and started on topical prednisolone acetate 1% every hour and atropine 1% twice daily. Skin testing for tuberculosis was negative at 48 hours, and he was started on a 1 mg/kg intravenous steroid pulse. He quickly felt better with vision improvement to hand motion. There was dramatic condensation of the fibrin disc in his anterior chamber. Intraocular pressure decreased to 6 mmHg. B-scan ultrasound showed dense vitreous debris with suprachoroidal collections of fluid or

blood (See Figure 2). Diagnostic pars plana vitrectomy was planned as an outpatient. After three days of intravenous steroids, he was discharged home on 60 mg of oral prednisone daily. He also continued on topical prednisolone acetate 1% every hour while awake, loteprednol ointment at bedtime, and atropine 1% twice daily.

Two days later, he presented for follow-up with fevers, eye pain and malaise. We discovered that the patient was incorrectly taking only 20 mg of prednisone daily. His anterior segment exam had regressed to its initial appearance with new early neovascularization of the iris, and his intraocular pressure was now 46 mmHg. The patient underwent pars plana vitrectomy, which revealed purulent vitreous aspirate. He was given intravitreal vancomycin and ceftazidime and admitted for intravenous antibiotics. Vitreous cultures revealed heavy growth of methicillin-sensitive *Staphylococcus aureus*. Blood cultures, echocardiogram, dental examination and bone scan were normal. The infectious disease

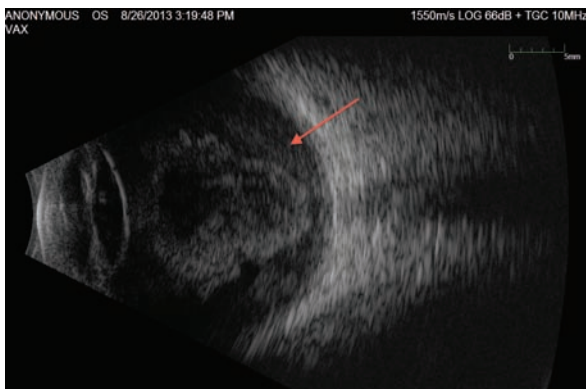

Figure 2. Follow-up B-scan ultrasound of the left eye. Note the increased amount of vitreous debris from the earlier ultrasound, as well as the presence of suprachoroidal blood or fluid (arrows).

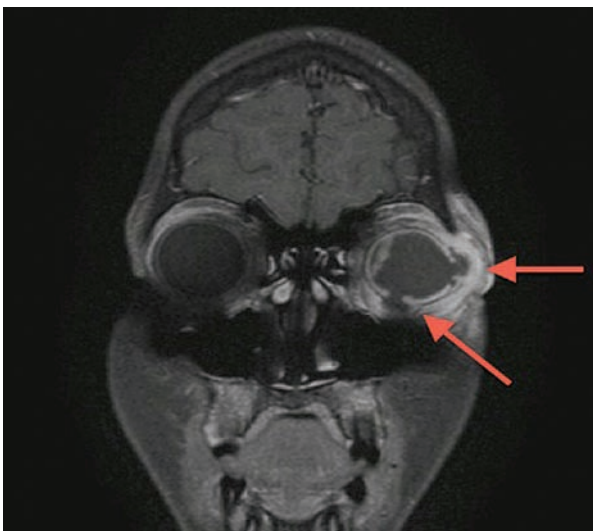


Figure 3. MRI with contrast, T1-weighted image, coronal slice. Note the two areas of globe rupture near the equator (arrows), as well as contiguous inflammation consistent with orbital abscess.

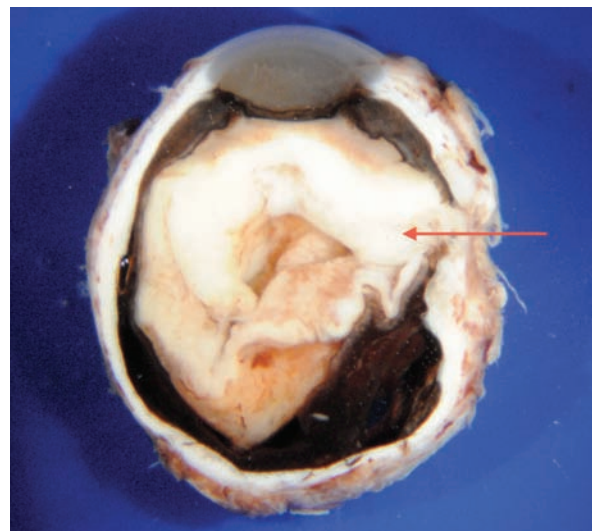


Figure 4. Gross specimen of the globe with abscess encompassing vitreous cavity, along with associated retinal detachment and choroidal hemorrhage and detachment.

service was consulted and no systemic source for infection was identified. The patient's condition continued to worsen. Four days after vitrectomy, the vision in the patient's left eye was no light perception. He developed warmth and erythema of the eyelids and started to complain of pain with

extraocular movements. MRI demonstrated two areas of globe rupture near the equator associated with contiguous orbital abscess. (See Figure 3) Enucleation was performed. Gross and microscopic examination confirmed endophthalmitis secondary to *Staphylococcus* (See Figure 4).

Two weeks after enucleation, the patient and his mother disclosed that the step-father had been physically abusive to the patient. Although there had been several instances of head trauma, they remained confident that there was never any trauma involving the eyes.

## Discussion

Infectious endophthalmitis is a rare and potentially devastating condition resulting from either the exogenous or endogenous spread of bacteria into the eye.<sup>1</sup> Most commonly, this form of panuveitis presents with reduced vision, progressive vitritis and hypopyon, as well as substantial red eye, pain and lid swelling.<sup>2</sup> Our patient had a remarkable absence of all of these signs except for the vitritis and reduced vision. Exogenous endophthalmitis is more commonly encountered and can occur following surgery, trauma, corneal ulcer or periocular infection that invades an adjacent ocular wall.<sup>3</sup> Endogenous endophthalmitis occurs through hematogenous spread of micro-organisms that cross the blood-retinal barrier. Risk factors for endogenous endophthalmitis include the presence of systemic or local infections, relative states of immunosuppression or procedures that increase the risk of blood-borne infections.

Children account for only 0.1 percent of all cases of endogenous endophthalmitis in the United States.<sup>4</sup> Reports of pediatric endophthalmitis are rare in the literature and are either stratified by specific etiology<sup>5-8</sup> or single case reports. In a recent retrospective review, over a 10-year period at a tertiary referral center, only 16 cases of pediatric endophthalmitis were identified.<sup>9</sup> No child was infected with *S. aureus* and all were obviously symptomatic and had clearly identifiable primary sources for their infection.

The majority of cases were due to exogenous causes: either posttraumatic or postsurgical.<sup>9</sup> Of the two cases with endogenous endophthalmitis, the children were systemically unwell. One patient was an infant with *Candida* sepsis, and another was immunocompromised secondary to leukemia. In children, the most commonly associated infectious sources for endogenous endophthalmitis include wound infection, meningitis, endocarditis, urinary tract infection, indwelling intravenous catheters or hemodialysis fistulas.<sup>4</sup> To our knowledge there has only been one reported case of *S. aureus* in a child. This was a case of a very low birth weight neonate with sepsis.<sup>10</sup>

A diagnosis of endophthalmitis is not often suspected in otherwise healthy pediatric patients with no prior eye surgery or trauma. Combined with poor communication in pediatric patients or denial of trauma for fear of repercussion, delay in diagnosis can occur, resulting in poor visual outcomes.

In our patient, initial suspicion for infectious endophthalmitis was low, given the lack of history of trauma, hypopyon, lid swelling or significant ocular pain. The patient was otherwise healthy with no other risk factors for endophthalmitis. Additionally, our patient's initial excellent response to both topical and intravenous steroids and then subsequent regression on an incorrectly low dose of oral steroids contributed to our thought process that he had a noninfectious, inflam-

matory condition. We still lack a clear source for his infection but suspect an episode of abusive eye trauma. One must always suspect physical abuse in a child when the extent of the injury is not consistent with the child's developmental age, or the findings on physical exam do not correlate to the history.<sup>11</sup>

Infectious endophthalmitis should be considered in the differential diagnosis of pediatric patients presenting with panuveitis, even in the absence of reported trauma or other risk factors. This may be particularly important when evaluation has not otherwise determined the etiology of the uveitis. Early diagnostic vitrectomy should be considered. **REVIEW**

1. Kernt M, Kampik A. Endophthalmitis: Pathogenesis, clinical presentation, management, and perspectives. *Clinical Ophthalmology* 2010;4:121-135.
2. Yanoff M, Duker J. *Ophthalmology*. China: Mosby, 2009. Print.
3. Jackson TL, Eykyn SJ, Graham EM, Stanford M. Endogenous Bacterial Endophthalmitis: A 17-year prospective series and review of 267 reported cases. *Surv Ophthalmol* 2003;48(4):403-423.
4. Chaudhry IA, Shamsi FA, AL-Dhibi H, Khan, AO. Pediatric Endogenous Bacterial Endophthalmitis: Case report and review of the literature. *J AAPOS* 2006;10:491-493.
5. Alfaro DV, Roth DB, Laughlin RM, et al. Paediatric posttraumatic endophthalmitis. *Br J Ophthalmol* 1995;79:888-891.
6. Good WV, Hing S, Irvine AR, et al. Postoperative endophthalmitis in children following cataract surgery. *J Pediatr Ophthalmol Strabismus* 1990;27:283-285.
7. Recchia FM, Bauman CR, Sivalingam A, et al. Endophthalmitis after pediatric strabismus surgery. *Arch Ophthalmol* 2000;118:939-944.
8. Waheed US, Ritterband DC, Greenfield DS, et al. Bleb-related ocular infection in children after trabeculectomy with mitomycin C. *Ophthalmology* 1997;104:2117-2120.
9. Thordson, JR, Harris L, Hubbard GB. Pediatric Endophthalmitis: A 10-year consecutive series. *Retina* 2008;28:S3-S7.
10. Basu S, Kumar A, Kapoor K, Bagri NK, Chandra A. Neonatal endogenous endophthalmitis: a report of six cases. *Pediatrics* 2013 Apr;131(4):e1292-7.
11. Waterhous W, Enzenauer RW, Parnley VC. Inflammatory Orbital Tumor as an Ocular Sign of a Battered Child. *Am J Ophthalmol* 1992;114:510-512.

**RESTASIS® (Cyclosporine Ophthalmic Emulsion) 0.05%****BRIEF SUMMARY—PLEASE SEE THE RESTASIS® PACKAGE INSERT FOR FULL PRESCRIBING INFORMATION.****INDICATION AND USAGE**

**RESTASIS®** ophthalmic emulsion is indicated to increase tear production in patients whose tear production is presumed to be suppressed due to ocular inflammation associated with keratoconjunctivitis sicca. Increased tear production was not seen in patients currently taking topical anti-inflammatory drugs or using punctal plugs.

**CONTRAINDICATIONS**

**RESTASIS®** is contraindicated in patients with known or suspected hypersensitivity to any of the ingredients in the formulation.

**WARNINGS AND PRECAUTIONS****Potential for Eye Injury and Contamination**

To avoid the potential for eye injury and contamination, be careful not to touch the vial tip to your eye or other surfaces.

**Use with Contact Lenses**

**RESTASIS®** should not be administered while wearing contact lenses. Patients with decreased tear production typically should not wear contact lenses. If contact lenses are worn, they should be removed prior to the administration of the emulsion. Lenses may be reinserted 15 minutes following administration of **RESTASIS®** ophthalmic emulsion.

**ADVERSE REACTIONS****Clinical Trials Experience**

Because clinical trials are conducted under widely varying conditions, adverse reaction rates observed in the clinical trials of a drug cannot be directly compared to rates in the clinical trials of another drug and may not reflect the rates observed in practice.

In clinical trials, the most common adverse reaction following the use of **RESTASIS®** was ocular burning (17%).

Other reactions reported in 1% to 5% of patients included conjunctival hyperemia, discharge, epiphora, eye pain, foreign body sensation, pruritus, stinging, and visual disturbance (most often blurring).

**Post-marketing Experience**

The following adverse reactions have been identified during post approval use of **RESTASIS®**. Because these reactions are reported voluntarily from a population of uncertain size, it is not always possible to reliably estimate their frequency or establish a causal relationship to drug exposure.

Reported reactions have included: hypersensitivity (including eye swelling, urticaria, rare cases of severe angioedema, face swelling, tongue swelling, pharyngeal edema, and dyspnea); and superficial injury of the eye (from the vial tip touching the eye during administration).

**USE IN SPECIFIC POPULATIONS****Pregnancy****Teratogenic Effects: Pregnancy Category C**

Adverse effects were seen in reproduction studies in rats and rabbits only at dose levels toxic to dams. At toxic doses (rats at 30 mg/kg/day and rabbits at 100 mg/kg/day), cyclosporine oral solution, USP, was embryo- and fetotoxic as indicated by increased pre- and postnatal mortality and reduced fetal weight together with related skeletal retardations. These doses are 5,000 and 32,000 times greater (normalized to body surface area), respectively, than the daily human dose of one drop (approximately 28 mcL) of 0.05% **RESTASIS®** twice daily into each eye of a 60 kg person (0.001 mg/kg/day), assuming that the entire dose is absorbed. No evidence of embryofetal toxicity was observed in rats or rabbits receiving cyclosporine at oral doses up to 17 mg/kg/day or 30 mg/kg/day, respectively, during organogenesis. These doses in rats and rabbits are approximately 3,000 and 10,000 times greater (normalized to body surface area), respectively, than the daily human dose.

Offspring of rats receiving a 45 mg/kg/day oral dose of cyclosporine from Day 15 of pregnancy until Day 21 postpartum, a maternally toxic level, exhibited an increase in postnatal mortality; this dose is 7,000 times greater than the daily human topical dose (0.001 mg/kg/day) normalized to body surface area assuming that the entire dose is absorbed. No adverse events were observed at oral doses up to 15 mg/kg/day (2,000 times greater than the daily human dose).

There are no adequate and well-controlled studies of **RESTASIS®** in pregnant women. **RESTASIS®** should be administered to a pregnant woman only if clearly needed.

**Nursing Mothers**

Cyclosporine is known to be excreted in human milk following systemic administration, but excretion in human milk after topical treatment has not been investigated. Although blood concentrations are undetectable after topical administration of **RESTASIS®** ophthalmic emulsion, caution should be exercised when **RESTASIS®** is administered to a nursing woman.

**Pediatric Use**

The safety and efficacy of **RESTASIS®** ophthalmic emulsion have not been established in pediatric patients below the age of 16.

**Geriatric Use**

No overall difference in safety or effectiveness has been observed between elderly and younger patients.

**NONCLINICAL TOXICOLOGY****Carcinogenesis, Mutagenesis, Impairment of Fertility**

**Carcinogenesis:** Systemic carcinogenicity studies were carried out in male and female mice and rats. In the 78-week oral (diet) mouse study, at doses of 1, 4, and 16 mg/kg/day, evidence of a statistically significant trend was found for lymphocytic lymphomas in females, and the incidence of hepatocellular carcinomas in mid-dose males significantly exceeded the control value.

In the 24-month oral (diet) rat study, conducted at 0.5, 2, and 8 mg/kg/day, pancreatic islet cell adenomas significantly exceeded the control rate in the low-dose level. The hepatocellular carcinomas and pancreatic islet cell adenomas were not dose related. The low doses in mice and rats are approximately 80 times greater (normalized to body surface area) than the daily human dose of one drop (approximately 28 mcL) of 0.05% **RESTASIS®** twice daily into each eye of a 60 kg person (0.001 mg/kg/day), assuming that the entire dose is absorbed.

**Mutagenesis:** Cyclosporine has not been found to be mutagenic/genotoxic in the Ames Test, the V79-HGPRT Test, the micronucleus test in mice and Chinese hamsters, the chromosome-aberration tests in Chinese hamster bone-marrow, the mouse dominant lethal assay, and the DNA-repair test in sperm from treated mice. A study analyzing sister chromatid exchange (SCE) induction by cyclosporine using human lymphocytes *in vitro* gave indication of a positive effect (i.e., induction of SCE).

**Impairment of Fertility:** No impairment in fertility was demonstrated in studies in male and female rats receiving oral doses of cyclosporine up to 15 mg/kg/day (approximately 2,000 times the human daily dose of 0.001 mg/kg/day normalized to body surface area) for 9 weeks (male) and 2 weeks (female) prior to mating.

**PATIENT COUNSELING INFORMATION****Handling the Container**

Advise patients to not allow the tip of the vial to touch the eye or any surface, as this may contaminate the emulsion. To avoid the potential for injury to the eye, advise patients to not touch the vial tip to their eye.

**Use with Contact Lenses**

**RESTASIS®** should not be administered while wearing contact lenses. Patients with decreased tear production typically should not wear contact lenses. Advise patients that if contact lenses are worn, they should be removed prior to the administration of the emulsion. Lenses may be reinserted 15 minutes following administration of **RESTASIS®** ophthalmic emulsion.

**Administration**

Advise patients that the emulsion from one individual single-use vial is to be used immediately after opening for administration to one or both eyes, and the remaining contents should be discarded immediately after administration.

**Rx Only**

Based on package insert 71876US17

© 2013 Allergan, Inc.  
Irvine, CA 92612, U.S.A.

® marks owned by Allergan, Inc. APC37BD13

Patented. See [www.allergan.com/products/patent\\_notices](http://www.allergan.com/products/patent_notices)

Made in the U.S.A.

REVIEW

Advertising  
Index**Alcon Laboratories****2, 3, 7, 8**

Phone (800) 451-3937  
Fax (817) 551-4352

**Allergan, Inc.****70, 72**

Phone (800) 347-4500

**FCI Ophthalmics****29**

Phone (800) 932-4202

**Keeler Instruments****9, 33, 71**

Phone (800) 523-5620  
Fax (610) 353-7814

**Lacrivera****21**

Phone (855) 857-0518  
[www.lacrivera.com](http://www.lacrivera.com)

**Lombart Instruments****41**

Phone (800) 446-8092  
Fax (757) 855-1232

**Ocusoft****57**

Phone (800) 233-5469  
Fax (281) 232-6015

**Perrigo Specialty Pharmaceuticals****15, 16**

Phone (866) 634-9120  
[www.perrigo.com](http://www.perrigo.com)

**Reichert Technologies****23**

Phone (888) 849-8955  
Fax (716) 686-4545  
[www.reichert.com](http://www.reichert.com)

**Reliance Medical****63**

Phone (800) 735-0357  
Fax (513) 398-0256

**Rhein Medical****5**

Phone (800) 637-4346  
Fax (727) 341-8123

**S4OPTIK****37**

Phone (888) 224-6012

**ThromboGenics Inc.****11, 12**

Phone (732) 590-2901  
Fax (866) 936-6676

**University of Pittsburgh****49**

Phone (800) 533-UPMC  
[www.upmc.com](http://www.upmc.com)

# Tonometry Done Right



**KAT**  
Keeler quality.



**Pulsair Desktop**  
Smallest footprint and simple to use!

*Purchase a Pulsair Desktop by  
March 31, 2014 and get  
a \$1,300 Instant Rebate!*

**Intellipuff**  
The standard for hand held mobility.

Buy Online!  
[keelerusa.com](http://keelerusa.com)



**Keeler**  
OPTICS

For patients with decreased tear production presumed to be due to ocular inflammation associated with Chronic Dry Eye

# RESTASIS<sup>®</sup> MAKES MORE OF THEIR OWN REAL TEARS POSSIBLE

Prescribe RESTASIS<sup>®</sup> for your appropriate moderate and severe Dry Eye patients and increase their own real tear production over time with continued use

For local co-pays,  
scan QR-code or visit  
[restasiscopay.com](http://restasiscopay.com)



### Indication and Usage

RESTASIS<sup>®</sup> (cyclosporine ophthalmic emulsion) 0.05% is indicated to increase tear production in patients whose tear production is presumed to be suppressed due to ocular inflammation associated with keratoconjunctivitis sicca. Increased tear production was not seen in patients currently taking topical anti-inflammatory drugs or using punctal plugs.

### Important Safety Information

#### Contraindications

RESTASIS<sup>®</sup> is contraindicated in patients with known or suspected hypersensitivity to any of the ingredients in the formulation.

#### Warnings and Precautions

**Potential for Eye Injury and Contamination:** To avoid the potential for eye injury and contamination, individuals prescribed RESTASIS<sup>®</sup> should not touch the vial tip to their eye or other surfaces.

**Use With Contact Lenses:** RESTASIS<sup>®</sup> should not be administered while wearing contact lenses. If contact lenses are worn, they should be removed prior to the administration of the emulsion.

#### Adverse Reactions

In clinical trials, the most common adverse reaction following the use of RESTASIS<sup>®</sup> was ocular burning (upon instillation)—17%. Other reactions reported in 1% to 5% of patients included conjunctival hyperemia, discharge, epiphora, eye pain, foreign body sensation, pruritus, stinging, and visual disturbance (most often blurring).

**Please see Brief Summary of the full Prescribing Information on adjacent page.**